

https://dspace.org/

A preliminary clinical report of a new composite anterior restorative material

Barbakow, F.; Friedman, M.; Retief, D. H.

1974

http://hdl.handle.net/10539/20323

Barbakow, F., Friedman, M., Retief, D. H. 1974. A preliminary clinical report of a new composite anterior restorative material. Journal of the dental association of South Africa; 29 (4):217-221

Downloaded from a DSpace repository. https://dspace.org/

J. Dent. Ass. S. Afr. Vol. 29, No. 4, pp. 217 - 221

A preliminary clinical report of a new composite anterior restorative material

F Barbakow, M Friedman and D H Retief

Dental Research Unit of the University of the Witwatersrand and the South African Medical Research Council, Johannesburg.

SUMMARY

The restoration of fractured incisal edges is not an easy procedure. The practitioner has the choice of several methods which either result in unaesthetic restorations or involve radical removal of sound tooth structure with possible pulpal damage. A new composite restorative material, Restodent, has recently become available for the conservative non-operative treatment of these lesions. Phosphoric acid etching of the enamel is employed prior to the placement of the restorations. In a preliminary clinical evaluation of this material, encouraging results have been obtained. In none of the 109 teeth restored, which included 83 anterior teeth with fractured incisal edges, did the restorations become dislodged at the enamel restoration interface. Chipping or fracture of the restored edges were observed in only 9 cases. Additional useful applications of Restodent are described.

OPSOMMING

Die herstelling van gefraktuurde insisale rande is nie maklik nie. Die praktisyn het die keuse van verskillende metodes van herstelling wat of onesteties is of radikale verwydering van gesonde tandweefsel benodig wat moontlik skade aan die pulpa tot gevolge kan hê. 'n Nuwe saamgestelde herstellingsmateriaal, Restodent, is onlangs vir die konserverende nie-operatiewe behandeling van hierdie letsels beskikbaar gestel. Fosforsuur etsing van die glasuur word gebruik voor die plasing van die herstellings. 'n Voorlopige kliniese waardering van hierdie materiaal is bemoedigend. In nie een van die 109 tande wat herstel is (en dit sluit 83 voortande met beskadigde insisale rande in), het die herstellings van die glasuurherstelling skeidingsvlak losgeraak nie. Splintering of breking van die herstelde rande het in net 9 gevalle gebeur. Ander nuttige gebruike van Restodent word ook beskryf.

INTRODUCTION

The conventional methods for treating fractured incisal edges of anterior teeth are:

1. Intra-coronal gold inlay restorations.
2. Full coverage crowns.
3. Pin-retained composite or acrylic restorations.

Each of the above methods has been employed for many years. The procedure of choice is dictated by the severity of the fractured edge, the age and the aesthetic demands of the patient.

Mainly retention, but aesthetics as well, are problems related to the classical Class IV gold inlay restoration (Kantorowicz, 1963). Consequently, the practitioner may resort to a full coverage coronal restoration. This results in greatly increased retention as well as pleasing aesthetic effects but involves the radical removal of enamel and dentine with possible pulpal sequelae.

There is a degree of controversy as to the beneficial effects of pin-retained conservative anterior restorations (Latoni-Camarena, Tomlinson and Baum, 1972). The consensus of opinion appears to favour this form of restoration under certain conditions and is certainly gaining in popularity (Lugassy, Moffa and Hozumi, 1972; Dilts, Podshadley and Neiman, 1972). However, the shearing stresses to which incisal edges are subjected may limit the practicability of this form of restorative procedure.

Approximately 80 per cent of all fractured anterior teeth occur in children (Finn, 1962). Practitioners must have encountered the difficulty of deciding what restorative procedure to adopt when a child with such a condition presents for treatment. It is incumbent on the dentist to preserve the vitality of these teeth wherever possible and to restore them skilfully to approximate their original appearance. With the restorative materials available at present, there should be no reason why fractured anterior teeth cannot be restored to biologically functional units with acceptable cosmetic appearances.

A new anterior composite restorative material, specifically developed for the conservative restoration of fractured incisal edges, has recently become available*. Restodent Incisal Edge Restorative is a diacrylate system formulated to produce a mix with good wetting and adhesive properties. The binder is a mixture of aromatic and aliphatic diacrylates, made from epoxy resins or analogues of epoxy resins, cured by a peroxide-tertiary amine catalyst system similar to that of Epoxylite HL-72. The filler is a special silica, se-

*„Restodent", Lee Pharmaceuticals, South El Monte, California, U.S.A.

lected for clarity and wear resistance. Restodent is more translucent than most restorative materials because of its area of intended use. A thixotropic coloured conditioning agent consisting of a 50 per cent phosphoric acid solution is used to etch the enamel surface prior to the application of the restorative material (Lee, 1973).

This paper is a preliminary report of a clinical study of the restoration of fractured incisal edges and other lesions with Restodent, carried out during the past 15 months.

MATERIALS AND METHODS

The clinical study was started in November, 1972 and to date the teeth of 88 patients have been restored with Restodent. The majority of teeth involved were anterior teeth with fractured incisal edges. The ages of the patients ranged from young children to adults and the extent of the fractured areas varied from simple enamel chips to grossly fractured teeth involving dentine as well as enamel. A number of these patients presented with teeth with inherited or acquired enamel defects, 22 of which were also restored with Restodent. The patients were recalled at regular intervals, the restorations examined and repaired where necessary, and the vitality of the teeth determined.

The ragged margins of the fractured edges were smoothed with abrasive discs and the entire coronal aspect of the tooth cleaned with Flowers of Pumice. The tooth was washed with water and then thoroughly dried with compressed air. Rubber dam was only applied if it was not possible to maintain a completely dry operative field. The dried tooth was then etched with the coloured 50 per cent phosphoric acid gel and the etched area extended well on to sound enamel. This acid solution contains a thixotropic agent which greatly increases the ability to control the flow of the etching solution. In addition, the colour of the solution enables the operator to identify the area to which the etching solution has been applied. The enamel surface was conditioned for 2 min whereupon the acid was washed away with a copious supply of water. The etched enamel and adjacent areas were thoroughly dried using "Prep-Dry".*

Restodent is compatible with all commercial bases and liners which may be used as clinical experience dictates, particularly in the fractured teeth of young children with marked dentinal involvement.

The size and position of the fracture or enamel defect will determine the form of matrix to be employed e.g. mylar strips or carefully trimmed celluloid crown formers. After the powder and liquid were dispensed and mixed according to the manufacturer's specifications, the resulting gel was placed on the dry, etched enamel with a plastic spatula. If a crown former was used, the excess was placed therein and fitted to the tooth. The material should not be disturbed during the setting stage because composites change rapidly from a fluid state to one of high early hardness.

A period of approximately 20 min should lapse to allow adequate setting of the restorative material prior to shaping the restoration. This was readily accomplished with tungsten carbide finishing burs, lubricated rotary discs and finally polished with lubricated rubber wheels.

As the authors acquired a better understanding of the properties and confidence in handling this new restorative material, more complex operative procedures, namely the replantation of extracted or avulsed teeth, were carried out.

RESULTS

Since this clinical investigation was begun in November 1972, a total of 88 patients were treated until the end of 1973. The number of fractured incisal edges repaired in anterior teeth totalled 83 and in addition the cusps of 4 posterior teeth and 22 enamel defects were restored. Furthermore, Restodent was used to immobilize implanted teeth in two patients (Table I).

The satisfactory restoration of a completely fractured incisal edge (Fig 1) is demonstrated in Fig 2. A hypoplastic lateral incisor which, in addition, had a fractured incisal edge (Fig 3), was successfully restored with Restodent (Fig 4). Following the accidental breakage of an endodontic reamer in an upper first premolar in an adult of 25 years, it was decided to extract the tooth, remove the broken reamer, and then to replant the tooth. The buccal surfaces of the two adjacent teeth as well as the buccal surface of the tooth to be replanted were etched (Fig 5) and the Restodent applied. This functioned satisfactorily as a splinting device (Fig 6). In another instance, following the traumatic avulsion of an upper right central incisor in a child of 9 years, the replanted tooth was again retained with the use of a Restodent splint (Fig 7). At the end of the immobilization period (Fig 8), the anatomical forms of the fractured central incisors were restored by the judicious removal of the excessive amounts of Restodent between the splinted teeth and by the careful addition of fresh restorative material (Fig 9).

An additional use of Restodent was to conceal the unaesthetic appearance of the cut retention screws of a periodontal splinting device, the Splint-Mate System* (Fig 10). The satisfactory result obtained by the selective placement of Restodent over the exposed retention screws is demonstrated in Fig 11.

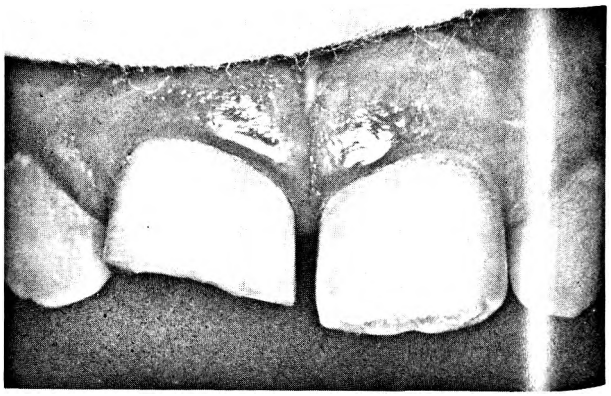

Fig. 1. Completely fractured incisal edge of a central incisor.

*Lee Pharmaceuticals, South El Monte, California, U.S.A.

*Whaledent Inc. New York, U.S.A.



Fig. 2. Satisfactory restoration of fractured incisal edge, shown in Fig. 1.

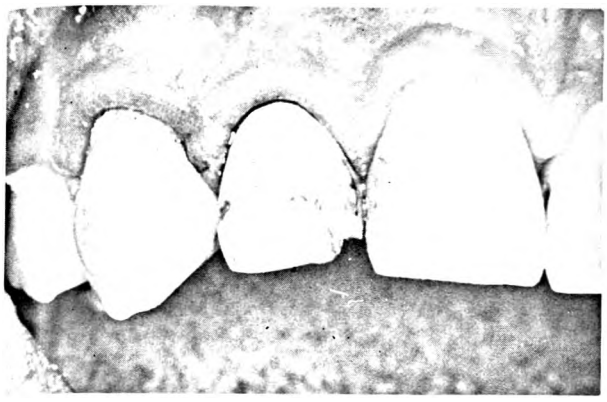

Fig. 3. Hypoplastic lateral incisor involving the incisal edge.

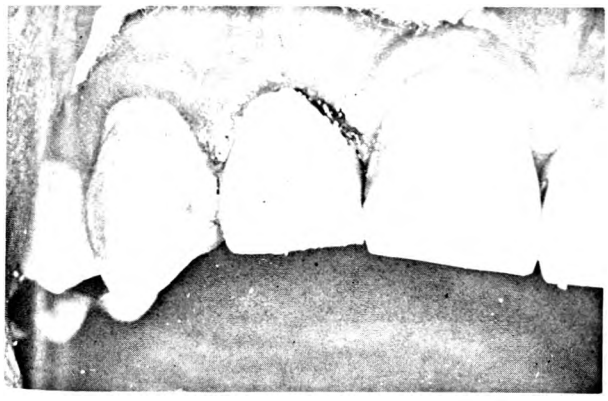

Fig. 4. Successful restoration of enamel defects, shown in Fig. 3.



Fig. 5. Replantation of upper first premolar after etching buccal surfaces of involved and adjacent teeth.

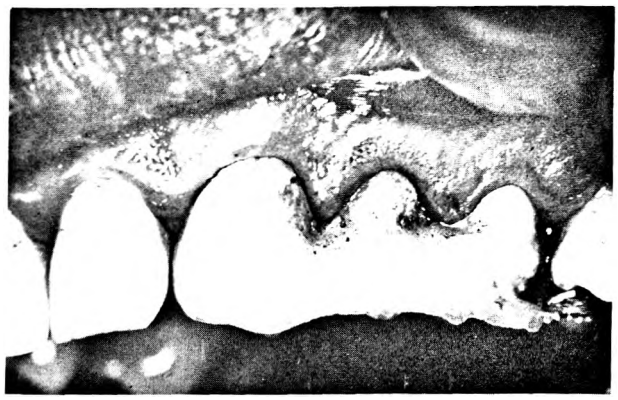

Fig. 6. Implanted tooth, shown in Fig. 5, splinted to adjacent teeth prior to trimming.

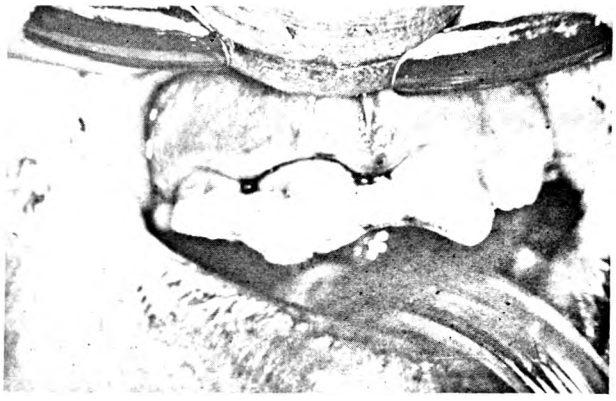

Fig. 7. Implantation of avulsed upper right central incisor immediately after splinting with Restodent.

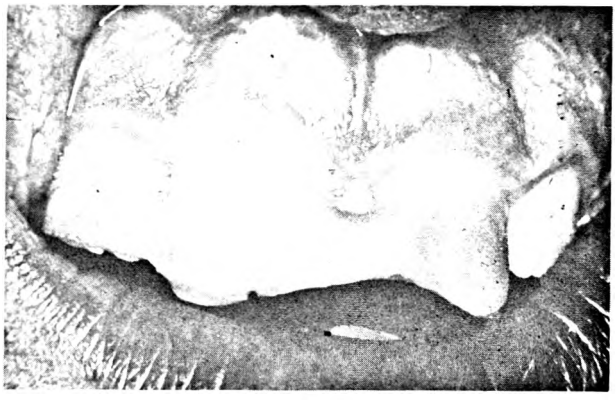

Fig. 8. Appearance of tooth shown in Fig. 7 after 6 weeks of immobilization.

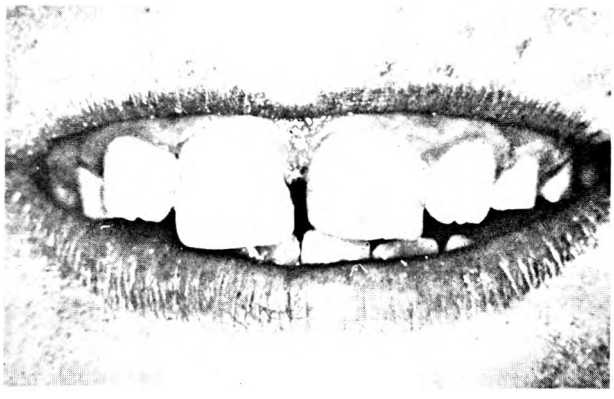

Fig. 9. Restoration of implanted and fractured incisors, shown in Figs. 7 and 8.

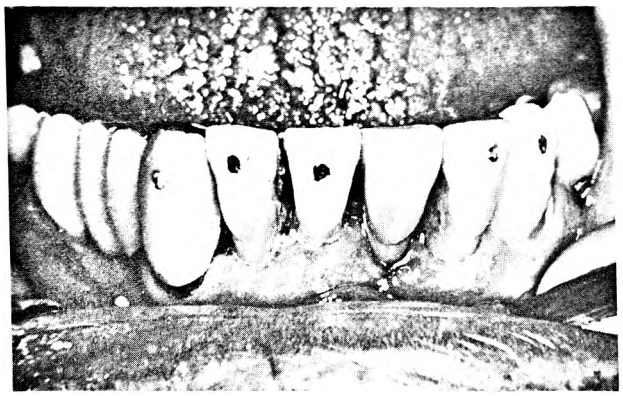

Fig. 10. Splinting of periodontally involved teeth by means of Splint-Mate System.

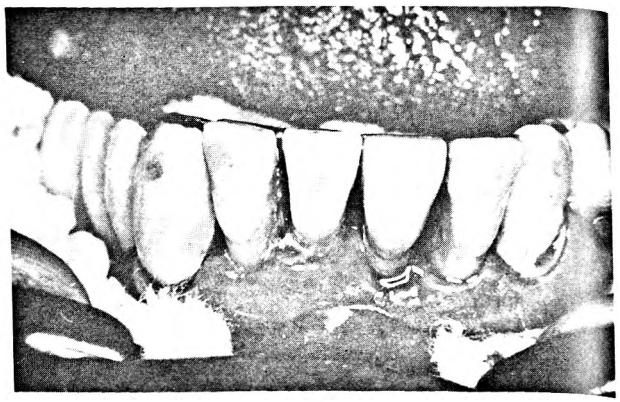

Fig. 11. Improved aesthetics of case shown in Fig. 10, obtained by concealing the retention screws with Restodent.

TABLE I: RESULTS OF CLINICAL EVALUATION OF RESTODENT

Date	Number of patients	Incisal edges restored	Posterior cusps restored	Enamel defects restored	Immobilizing splints	Fractures of restorations	Interval until fracture
Nov 72	5	4		1		1	2 months
Dec 72	4	4					
Jan 73	8	8	1	1			
Feb 73	7	6		1	1	1	2 months
March 73	9	10	1	3		1	1 month
April 73	6	6		3		2	3,5 months
May 73	16	15	1	4	1	4	1, 1, 4, 5 months
June 73	11	8		7			
July 73	4	5					
Aug 73	7	6		2			
Sept 73	1	1					
Oct 73	3	4					
Nov 73	4	4					
Dec 73	3	2	1				
TOTAL	88	83	4	22	2	9	

Nine of 83 fractured incisal edges repaired with Restodent, fractured within the material at intervals ranging from 1 to 5 months after restoration of the teeth (Table I). None of the fractures occurred at the original etched enamel/Restodent interface and varied from slight chips to more extensive fractures involving the restored incisal edge. These were readily repaired by the addition of freshly mixed material. None of the repaired cusps or enamel defects failed during this observation period.

DISCUSSION

Composite restorative materials were developed to overcome some of the deficiencies encountered with the earlier anterior restorative materials. The composites proved to have an improved stability in the oral environment and considerably increased physical properties such as reduced polymerization shrinkage, greater abrasion resistance, higher compressive strength and reduced marginal leakage (Buonocore, 1968). In addition, they produce better marginal adaptation with a consequent reduction in the rate of replacement as well as a reduced incidence of recurrent caries (Lee Pharmaceuticals, 1972).

An acute problem in dentistry is that the available restorative materials do not adhere to tooth structure. This lack of adhesion allows seepage of deleterious agents at the tooth/restoration interface. With the probable exception of the carboxylate cements (Smith, 1968), there is no known dental restorative material capable of forming permanent adhesive bonds with untreated enamel under oral conditions. Even the advent of the composite resin systems did not alter this situation (Swartz, 1969).

However, the bonding of restorative materials to enamel can be substantially improved by conditioning the enamel surface prior to placement of the restoration. Buonocore (1955) was the first to demonstrate that the bonding referred to above could be achieved by etching the enamel surface with 85 per cent phosphoric acid. Subsequently, Newman (1965) demonstrated increased retention of epoxy resins to enamel surfaces pretreated with 50 per cent phosphoric acid.

Phosphoric acid pretreatment of enamel was found to enhance the strength of attachment of acrylic resins used to restore fractured incisal edges (Laswell, Welk and Regenos, 1971). Conditioning of the enamel surface with 50 per cent phosphoric acid for 60 sec significantly increased the bonding of a conventional unfilled polymethylmethacrylate direct filling resin (Lee, Phillips and Swartz, 1971).

The usual glistening appearance of the enamel surface is dulled after a one min application of 50 per cent phosphoric acid, but is apparently restored to normal within several days (Retief, Dreyer and Gavron, 1970). Lee *et al* (1972) demonstrated by means of electron microprobe x-ray spectrophotometry that complete remineralization of etched enamel occurred within 30 days after the application of a demineralizing solution. Retief (1973) has shown that 50 per cent phosphoric acid removed the low energy organic film of mucopolysaccharide from the enamel surface which resulted in increased wettability of the enamel. This acid solution also preferentially etched the exposed mineral phase of the enamel and increased the surface area available for mechanical bonding of the restorative material to the etched enamel. The marginal leakage at the restoration/tooth interface was considerably reduced as demonstrated by radio-isotope and dye penetration studies. In his study, Retief (1973) has confirmed that mechanical retention plays the major role in the bonding of adhesives to conditioned surface enamel.

Nine of the 83 restored incisal edges fractured within the bulk of the material. None of the fractures occurred at the etched enamel/Restodent interface indicating that the mechanical bond between the etched enamel surface and the restorative material was sufficiently strong to withstand compressive and shear forces exerted on the restorations during biting. Two of the fractures occurred within the material as a result of accidental traumatic forces. Several of the other fractures within the material probably resulted from inadequate occlusal adjustment prior to polishing the restoration.

CONCLUSIONS

Despite the short period of post-operative observation, it is concluded that Restodent is of clinical value. This material enables the restoration of the anatomical form in a quick and painless procedure to an acceptable aesthetic appearance. It thus eliminates the need for operative procedures to be carried out immediately when confronted with patients presenting with fractured incisal edges. The time gained by the selective utilization of this material may be important in the maintenance of the vitality of teeth previously subjected to accidental trauma. There are also the additional applications of this material, for example as a retentive method for replanted teeth and the restoration of enamel defects.

The failures detailed in this study can mainly be attributed to inaccurate occlusal adjustment. The failures involved varying degrees of chipping of the restored incisal edges. To date no total failures i.e. the loss of "adhesion" at the etched enamel/Restodent interface have been recorded. In no case has there been any clinical evidence of pulpal damage.

ACKNOWLEDGEMENTS

The authors are indebted to Lee Pharmaceuticals for making the material available for this study and to the Staff of the Dental Research Unit for their assistance with the photography. The assistance of Miss B. Slack in typing the manuscript is gratefully acknowledged.

REFERENCES

Buonocore, M.G. (1955) A simple method of increasing the adhesion of acrylic filling materials to enamel surfaces. *Journal of Dental Research*, **34,** 849–853.

Buonocore, M.G. (1968) New anterior restorative materials. *International Dental Journal*, **18,** 406–420.

Dilts, W., Podshadley, A. & Neiman, R. (1972) Effect of pins on some physical characteristics of composite resins. *I.A.D.R. Program and Abstracts of Papers*, Abstract No. 561.

Finn, S.B. (1962) *Clinical Pedodontics*, 2nd ed., Ch. 15, p. 330. Philadelphia: W.B. Saunders Co.

Kantorowicz, G.F. (1963) *Inlays, Crowns and Bridges. A Clinical Handbook*, 1st ed., Ch. 4, p. 33. Bristol: John Wright & Sons Ltd.

Laswell, H.R., Welk, D.A. & Regenos, J.W. (1971) Attachment of resin restorations to acid pretreated enamel. *Journal of the American Dental Association*, **82,** 558–563.

Latoni-Camerena, M., Tomlinson, J.L. & Baum, L. (1972) Effect of retention pins in a composite resin. *I.A.D.R. Program and Abstracts of Papers*, Abstract No. 570.

Lee, B.D., Phillips, R.W. & Swartz, M.L. (1971) The influence of phosphoric acid etching on retention of acrylic resin to bovine enamel. *Journal of the American Dental Association*, **82,** 1381–1386.

Lee H. (1973) Personal communication.

Lee, H., Ocumpaugh, D.E., Shaffer, J. & Sheble, A.M. (1972) Sealing of developmental pits and fissures: IV. Measurements of in vivo fluoride pick-up by electron microprobe x-ray spectrophotometry. *Journal of Dental Research*, **51**, 634–639.

Lee Pharmaceuticals. (1972) Properties of composite dental restoratives. *Research Report*, 72–164. Ch. 1, pp. 1.1–1.15.

Lugassy, A.A., Moffa, J.P. & Hozumi, Y. (1972) Influence of pins upon some physical properties of composite resins. *I.A.D.R. Program and Abstracts of Papers*, Abstract No. 562.

Newman, G.V. (1965) Epoxy adhesives for orthodontic attachments: Progress report. *American Journal of Orthodontics*, **51,** 901–912.

Retief, D.H., Dreyer, C.J. & Gavron, G. (1970) The direct bonding of orthodontic attachments to teeth by means of an epoxy resin adhesive. *American Journal of Orthodontics*, **58,** 21–40.

Retief, D.H. (1973) Effect of conditioning the enamel surface with phosphoric acid. *Journal of Dental Research*, **52,** 333–341.

Smith, D.C. (1968) A new dental cement. *British Dental Journal*, **125,** 381–384.

Swartz, M.L. (1969) Research in dental materials. *Journal of the American Dental Association*, **79,** 901–917.