

https://dspace.org/

A 20-year audit from 2000 to 2020 of the management and treatment outcomes of temporomandibular joint ankylosis among a cohort of patients at Wits Oral Health Centre

Rudzani, Lalumbe Rofhiwa

2024
University of the Witwatersrand, Johannesburg
https://hdl.handle.net/10539/46368

Rudzani, Lalumbe Rofhiwa . (2024). A 20-year audit from 2000 to 2020 of the management and treatment outcomes of temporomandibular joint ankylosis among a cohort of patients at Wits Oral Health Centre [Master`s dissertation, University of the Witwatersrand, Johannesburg]. WIReDSpace. https://hdl.handle.net/10539/46368

Downloaded from a DSpace repository. https://dspace.org/

A 20-year audit from 2000 to 2020 of the management and treatment outcomes of temporomandibular joint ankylosis among a cohort of patients at Wits Oral Health Centre.

Student name : Lalumbe Rofhiwa Rudzani

Student Number : 2055874

A research report submitted to the Faculty of Health Sciences, University of the Witwatersrand, Johannesburg, in partial fulfilment of the requirements for the degree of Masters of Dentistry.

Johannesburg, 2023

Declaration

I, Rofhiwa Rudzani Lalumbe declare that this research report is my own, unaided work. It is being submitted for **Masters of Dentistry** at the University of the Witwatersrand, Johannesburg. It has not been submitted before for any degree or examination at any other University.



_____

(Signature of candidate)

21 day of April 2024 in Parktown

Dedication

I dedicate this work to my loving parents (Mr Tshidumbu Edward Lalumbe and Mrs Sundani Emelina Lalumbe).

Abstract

Background: Temporomandibular joint ankylosis (TMJA) is a pathologic condition characterised by fusion of the condyle to the fossa by bony or fibrotic tissue. The severity of the condition depends of the age of onset and whether it is unilateral or bilateral. The aim of this study was to report on management and outcomes of patients with TMJA in our unit.

Method: A retrospective analysis of the demographic, risk factors, clinical presentation, treatment modalities and outcomes of patients treated in the department of Maxillofacial and Oral Surgery from January 2000 to December 2020, at Charlotte Maxeke Johannesburg Academic Hospital (CMJAH) and Chris Hani Baragwaneth Academic Hospital (CHBAH), University of the Witwatersrand.

Results: The study included 71 cases. The age ranged from 4 years to 70 years. 49.3% (n=35) of the patients were female, while 50.7% (n=36) were male. Majority of patients (39.44%) (n=28) presented with left TMJ ankylosis, followed by right TMJ ankylosis (38.03%) (27) and bilateral TMJ ankylosis (22.54%) (n=15). Trauma was found to be the leading cause of TMJ ankylosis at 77.46% (n=55) while the cause of ankylosis in 18.31% (13) of patients was unknown and 4.23% (n=3) was caused by infection. The treatment modalities were Gap Arthroplasty, Costochondral Graft and Total Alloplastic Joint Reconstruction. Majority of patients 57,75% (n=41) had isolated GAP as the treatment modality, followed by 26.76% (n=19) who had TAJR, and 15.49% (n=11) who had CCG. Six of the nine patients who had recurrent ankylosis were treated by CCG.

Conclusion: Data analysed in this study indicate that trauma is the leading cause of TMJ ankylosis. From the findings of the present study, revealing no difference between GAP, CCG and alloplastic joint reconstruction, we conclude that irrespective of the treatment modality executed, early surgical intervention, radical and sufficient resection of ankylosed mass, early postoperative exercises, active physiotherapy and follow-up are imperative for successful rehabilitation and prevention of reankylosis of patients with temporomandibular joint ankylosis.

Acknowledgement

To the Head of Department of Maxillofacial and Oral Surgery at the WITS Oral Health centre (Prof RE Rikhotso), it has been an honour and privilege training under your guidance and supervision. Thank you for being patient and ready to assist at all times.

To my parents, thank you for your motivation and unshaken support. Thank you for helping me shape my life with positivity and love. Without you I would not have been the person I am today.

Table of contents Page

Cover page I

Declaration II

Dedication III

Abstract IV

Acknowledgment V

Table of Contents VI

List of Figures VIII

List of Tables IX

List of abbreviations X

Chapter 1: Literature review 1

Chapter 2: Aims and objectives 17

- Aims 17
- Objectives 17

Chapter 3: Materials and Methods 18

- Study design 18
- Study population 18
- Data collection 20
- Inclusion criteria 20
- Exclusion criteria 20
- Data analysis 20

Chapter 4: Results 22

Chapter 5: Discussion 27

Chapter 6: Conclusion 32

Reference 33

Appendices 39

Appendix A: Ethics Certificate 39

Appendix B: Data Collection Form 40

Appendix C: Permission Letter 41

Appendix D: Turnitin Report 42

List of Figures

Figure 1: Anatomic representation of temporomandibular joint

Figure 2: He et al classification of TMJ ankylosis

Figure 3: Clinical picture of long standing, unilateral, right TMJ ankylosis

Figure 4: Costochondral graft

Figure 5: Condylar and fossa components

Figure 6: Ramus component

Figure 7: Radiograph showing prosthetic joints.

Figure 8: Distribution of age in decades

Figure 9: Distribution of cause of ankylosis and gender

Figure 10: Distribution of treatment modalities

List of Tables

Table 1: Distribution of TMJ ankylosis

Table 2: Average of pre- and post-operative mouth opening

Table 3: Anova descriptive summary of pre-op mouth opening

Table 4: Analysis of variance summary of post-op mouth opening

List of Abbreviations

1.	Temporomandibular Joint	TMJ
2.	Intra-Capsular Fracture	ICF
3.	Computer Tomography	CT
4.	Gap Arthroplasty	GA
5.	Interpositional Gap Arthroplasty	IPG
6.	Temporalis Muscle Fascia	TMF
7.	Ramal Condylar Unit	RCU
8.	Costochondral Graft	CCG
9.	Polytetrafluoroethylene	PTFE
10.	Food and Drug Administration	FDA
11.	Wits Oral Health Centre	WOHC
12.	Temporomandibular Joint Ankylosis	TMJA
13.	Maximum Incisal Opening	MIO
14.	Total Alloplastic Joint Reconstruction	TAJR
15.	Obstructive Sleep Apnea	OSA
16.	Intermaxillary Fixation	IMF

Chapter 1: Literature review

The Temporomandibular Joint (TMJ) is composed of the temporal bone and mandibular condyle, as well as a specialized dense fibrous structure, the articular disk, several ligaments and numerous associated muscles (Miloro, 2004). The articular disk divides the joint into two compartments, the lower compartment which permits hinge motion or rotation and the superior compartment which permits sliding (translation) movements (Miloro, 2004). These movements allow mouth opening and closing for eating, talking and all other functions performed by the jaws. Figure 1 shows an anatomic diagram of the TMJ (Angin & Simsek, 2020). Temporomandibular joint ankylosis (TMJA) is a disorder characterised by fusion of the condyle to the fossa by bony or fibrotic tissue. The term ankylosis originates from the Greek word ankylose, which means “abnormal stiffening and immobility of a joint due to fusion of bone”. Temporomandibular joint ankylosis thus implies pathological fusion between the glenoid fossa of the temporal bone and the condylar process of the mandible.

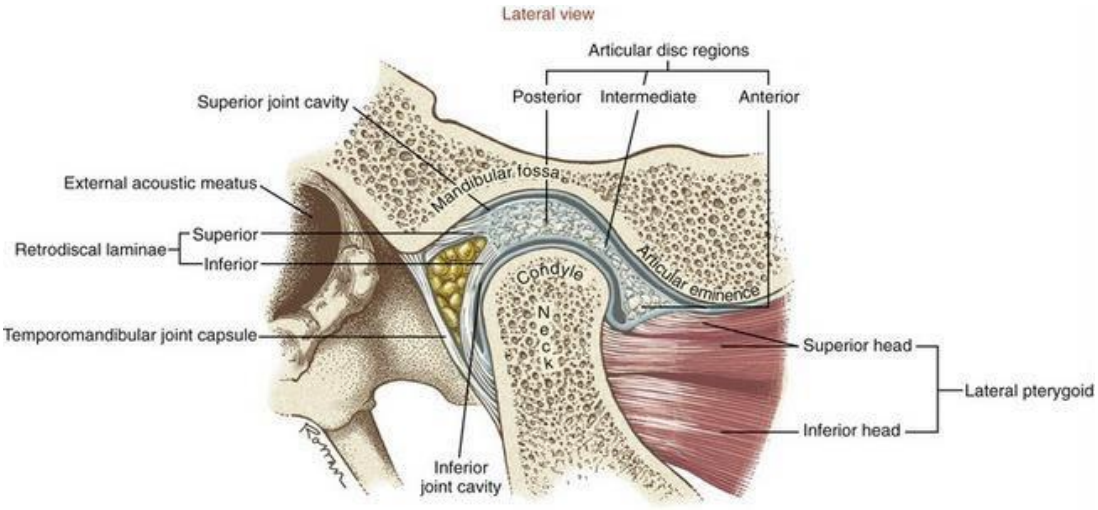

Figure 1: Anatomic representation of Temporomandibular joint.

Limited mouth opening, impaired mastication, malnutrition, poor oral hygiene and facial growth disturbances are some of the functional and aesthetic deformities that may be associated with TMJA (Wang et al., 2016). Mandibular hypomobility and subsequent retrognathia can produce oropharyngeal airspace narrowing leading to signs and symptoms of obstructive sleep apnea syndrome (Cascone et al., 2015). Ankylosis is extremely rare in Caucasians, which has prompted speculation that there may be a genetic component in the pathogenesis of ankylosis.

Aetiology

Temporomandibular ankylosis may be congenital or acquired. Acquired TMJ ankylosis is most commonly associated with trauma, local/systemic infection, previous TMJ surgery or systemic diseases such as ankylosing spondylitis, rheumatoid arthritis and psoriasis (Wolford et al., 2016). The congenital forms of TMJ ankylosis are mainly extracapsular, like synechiae and syngnathias.

Trauma

Traumatic injury to the temporomandibular articulation is by far the most common preceding cause of TMJ ankylosis. Despite condylar fractures being the leading cause of TMJ ankylosis, it is worth bearing in mind however that ankylosis is very rare in patients who suffered condylar fractures, with an incidence of approximately 0.2 to 0.4% (Wen-Ching et al., 1999; MacLennan, 1952; Ellis, 1998). Although the sequence of events that culminate in TMJ ankylosis following condylar fractures awaits elucidation, it is hypothesized that trauma results hemarthrosis which causes fibrosis and exuberant bone formation and ultimately to hypomobility of the joint (Kaban et al., 2009). The following are considered to be risk factors for the development of post-traumatic ankylosis:

1. Age: ankylosis is more common in children than in adults, because they have a higher osteogenic potential and a highly vascularised condyle (Laskin, 1978). The underdeveloped capsule readily allows for displacement of the condyle out of the fossa. Also, children have a greater propensity for prolonged, self-imposed immobilisation.
2. Status and position of the disc: Disc displacement has been implicated as a key factor in the development of TMJ ankylosis. It is thought that damage or loss of the meniscus provides a favourable condition for ankylosis by allowing bone-to-bone contact or at least close approximation of the articular parts (Laskin, 1978). Displaced or torn disc is often found in patients with traumatic TMJ ankylosis (Toyama et al., 2003; Miyamoto et al., 1999). The intact disc may therefore act as a natural impediment to trans-articular bony fusion (Laskin, 1978; Miyamoto et al., 1999).

3. Immobilisation: It is generally agreed among clinicians that prolonged immobilisation following condylar fractures increases the risk of TMJ ankylosis (Laskin, 1978). Vigorous post-injury mobilisation is thus far more critical in preventing ankylosis (Ferretti et al., 2005).
4. Severity and site of fracture: It has been theorised that condylar fractures must involve the articular surfaces to result in ankylosis, and that comminuted fractures are more likely to cause ankylosis than condylar neck fractures (Ferretti et al., 2005). In this regard, ankylosis is simply described as organisation or ossification of an intra-capsular haematoma following an intra-capsular fracture in the presence of immobility and an injured disk (Ferretti et al., 2005).

He et al classified condylar head fractures into 4 types according to the location of the fracture line:

A - fracture through lateral third of condylar head with reduction of the ramus height.

B - fracture through the central third portion of condylar head without reduction of the ramus height.

C-fracture through the medial third portion of the condylar head without reduction of the ramus height.

M-fracture with multiple fragments of the condylar head.

He et al (2006; 2014), found that sagittal condylar ICFs (type B) are more likely to cause ankylosis: the disc is displaced anteriorly and medially with the fractured condylar head fragment which leaves the cartilage of the condylar (ramus) stump uncovered. The cartilage of the condylar stump is also damaged during injury, which increases the risk of adhesion between the condylar stump and the glenoid fossa with disc displacement. He et al (2014) also found that type B ICFs and combined mandibular fractures with widened mandibular arches result in lateral/superolateral displacement of the ramus stump and its fusion with the zygomatic arch.

Following evaluation of morphology of ankylosed joints on coronal computer tomography (CTs), Ferretti et al (2005) observed that ankylosis often develops lateral

to the condylar head, which lies medial to the glenoid fossa (suggestive of a previous medial fracture dislocation) and that although the condylar head is united to the medial aspect of the ramus, it remains unankylosed to the cranial base (Ferretti et al., 2005). Based on this observation, they suggested that haematomas around the articular cavity of dislocated condylar head fractures, damage of the periarticular anatomical boundaries, communication between intra- and extra-articular fractures, disc displacement and long periods of limited mandibular mobility can induce ankylosis by endosseous vessel ossification.

Infection

The highest risk factor for TMJA in the pre-antibiotic era was infection (El-Mofty, 1972). The involvement of the TMJ could be by direct spread or haematogenous spread through the synovial blood vessels. Temporomandibular joint ankylosis following otitis media, mumps, or osteomyelitis of the zygomatico-temporal region has been reported (El-Mofty, 1972). The infection can spread to the TMJ via three potential routes: congenital dehiscence of the cartilaginous canal (Santorini's fissures), a dehiscent squamotympanic fissure or failure of closure of Huschke's foramen before the fifth year of life (Wang et al., 1991; Smith et al., 1999; Dingle, 1992).

CLASSIFICATION

Various classifications of TMJ ankylosis have been proposed. Kazanjian classified TMJ ankylosis into true (intracapsular) and false (extracapsular) ankylosis (Kazanjian, 1938). Intracapsular ankylosis refers to ankylosis between the condylar head and the mandibular fossa while extracapsular ankylosis refers to restriction of the movement of the mandible that occurs as a result of pathology or physical obstruction that is outside the TMJ itself (Kazanjian, 1938). Intracapsular ankylosis can be classified according to the type of tissue involved (bony, fibrous or fibro-osseous) and extent of fusion (complete, incomplete) (Kazanjian, 1938). Sawhney classified ankylosis according to severity into the following types (Sawhney, 1985):

Type I---- Condylar head flattened or deformed but closely approximated to the upper articular surfaces with fibrous adhesions around the joint.

Type II---- Condylar head misshaped or flattened but still distinguishable and in close approximation to the articular surface. Bony fusion of the head to the outer edge of the articular surface.

Type III--- A bony block bridges across the ramus of the mandible and the zygomatic arch. The displaced condylar head is atrophic and lying either free or fused to the medial side of the ramus (the condylar neck stump is ankylosed to the fossa while the medially displaced fractured condyle is ankylosed to the anteromedial aspect of the condylar stump).

Type IV--- A wide bony block between the ramus and the upper articular surface completely replacing the architecture of the joint.

Tripathy et al (2009) have classified ankylosis as true (bony or fibrous adhesion between the surfaces of the joint within the capsule) or false (problem lies in the surrounding structures). Recently, Dongmei He (He et al., 2014) classified ankylosis into 4 types according to the coronal CT scans (Figure 2):

Type A1— Fibrous ankylosis without bony fusion of the joint.

Type A2--- Ankylosis with bony fusion on the lateral side of the joint, while the residual condylar fragment is bigger than 0.5 of the condylar head in the medial side.

Type A3--- Ankylosis with bony fusion on the lateral side of the joint, while the residual condylar fragment is smaller than 0.5 of the condylar head in the medial side.

Type A4--- Ankylosis with complete bony fusion of the joint.

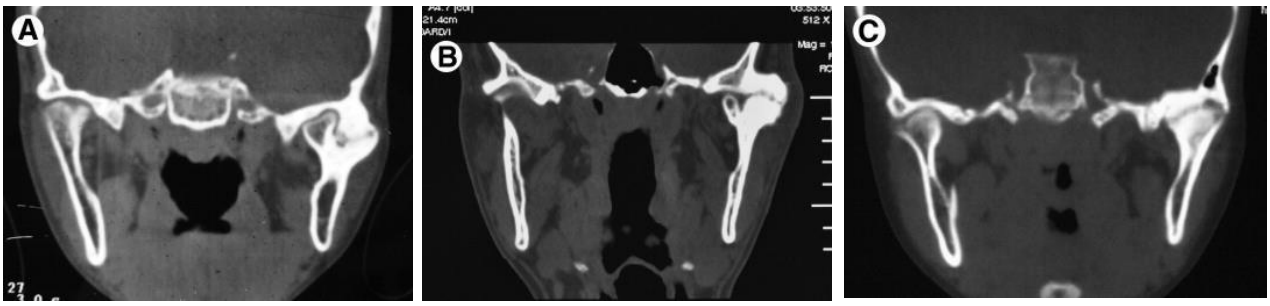

Figure 2: He et al classification of the TMJ ankylosis. A, Type A2 ankylosis; B, Type A3 ankylosis; C, Type A4.

Dimitroulis developed the following modified version of the original classification of the causes of limited mouth opening (Dimitroulis, 2004):

True Ankylosis (Intra-articular)

Tissue type: Fibrous
Fibro-osseous
Osseous
Extension: Topazian, 1964
Condyle
Sigmoid notch
Coronoid process

False ankylosis (extra-articular)

Coronoid process (trauma, hyperplasia, neoplasm)
Masticatory Muscles : scarring (trauma, surgery)
: radiotherapy
: myositis ossificans
: submucous fibrosis
: Trotter's syndrome

CLINICAL PRESENTATION

The clinical presentation of ankylosis is influenced by age of onset, duration and whether the ankylosis is unilateral or bilateral (Rowe, 1982). Patients with TMJ ankylosis present with restricted mandibular motion and, depending on the patient's age and the condition's aetiology, may have an abnormality in mandibular size and shape (Miloro, 2004). Unilateral pathology in children may result in significant problems with lower facial symmetry (Miloro, 2004). A shortened ramus on the affected side is usually accompanied by a prominent antegonial notch (Miloro, 2004). In adults, TMJA is characterized by malocclusion, limited jaw opening and decreased translation however, the morphologic characteristics found in the growing patient are frequently absent (Miloro, 2004). Patients with longstanding TMJ ankylosis caused by joint trauma during the active growth period in early childhood present mainly with: a severe bird face deformity: the term was coined by Obwegeser and Hdjianghelou (1987) to describe a clinical state of micrognathic mandible with receding chin and steep occlusal plane (El-Sheikh et al., 1996). The maxilla is usually secondarily affected, with shortening of the posterior facial height (El-Sheikh et al., 1996). There may be

associated shortening of the pterygo-masseteric muscle sling and extrinsic ligaments (El-Sheikh et al., 1996). The temporalis muscle and coronoid process become stronger and more hypertrophied, inability to open the mouth and manifestations of upper airway obstruction in the form of either snoring during sleep or obstructive sleep apnoea may be observed (El-Sheikh et al., 1996).

(i) Age at onset

In patients that developed ankylosis after the growth spurt, the only clinical sign will be restricted mouth opening. Patients that develop ankylosis in early childhood however may have retruded mandible, facial asymmetry, canting of occlusion and proclined lower anterior teeth.

(ii) Duration

Longstanding TMJ ankylosis in growing children tend to result in severe deformities.

(iii) Side involved.

Patients with unilateral TMJ ankylosis tend to present with deviation of the mandible towards the affected side and flattening of the non-affected side.

Figure 3 is a clinical picture of a patient with long standing unilateral right TMJ ankylosis, with a retruded mandible that is deviated to the right.



Figure 3: Clinical picture of long standing unilateral, right TMJ ankylosis.

TREATMENT

Treatment of TMJA appears to be centred around the theories of growth of the mandible. The two theories of growth of the mandible that seem to dominate literature is whether a condyle is a growth centre or a growth site. According to the functional matrix growth theory, the mandible grows in response to the functional matrix (space for respiration and digestion, eruption of teeth and growth of the tongue) and therefore the condyle is the growth site (Moss & Salentijn, 1969). Ware and Taylor however proposed that the cartilaginous cap of the condyle acts as an intrinsic growth centre of the mandible. It seems that surgeons who subscribe to the theory that state that condyle is the growth centre would prefer to replace the lost growth centre, and those who believe in the functional matrix theory, tend to rely on function as the prerequisite for the growth of the mandible.

The major challenge with treating TMJ ankylosis (TMJA) is that there is no accepted standard surgical protocol that has produced consistent results, and measurement of outcomes is not clear and standardised. Most studies consider the maximal incisal opening (MIO) at follow up when they report outcome on TMJ ankylosis, without considering the preoperative MIO. This can be misleading as patients with outcome MIO of 15 mm and 35 mm could have achieved equal outcomes if the former had a preoperative MIO of zero and the latter had a preoperative MIO of 20 mm. For this reason, a preoperative MIO should be used as a reference point when measuring outcomes of TMJ ankylosis, with the achieved MIO being the outcome MIO minus the preoperative MIO. This would assist in standardising and comparing of outcomes of different studies on TMJ ankylosis.

The primary objective in the treatment of TMJA is to restore altered joint mechanics (to create a pseudoarthrosis that will improve function or movement of the mandible), correct the associated dentofacial deformities, promote good oral hygiene and prevent reankylosis (Freedus et al., 1975).

It is widely accepted that surgery forms the mainstay of treatment of TMJA, however some authorities maintain that surgery and postoperative physiotherapy are equally important (Freedus et al., 1975). Gap arthroplasty (GAP), interpositional gap

arthroplasty (IPG) and or total joint reconstruction (with autogenous grafts or alloplastic materials) and distraction osteogenesis are some of the treatment modalities that have been described for TMJA.

A. Gap Arthroplasty (GA)

GA aims to create a gap between the ascending ramus and the cranial fossa, and thereby reduce the risk and rate of reankylosis. The first condylectomy was perfomed by Humphrey (Mehrotra et al., 2011) in 1854. Conservative GA (without any interpositional material) was first perfomed by Abbe (Bifano et al., 1995) in 1880. It is reported that if the gap is too small, recurrence is more likely to occur, whereas if it is too large, mandibular vertical height is lost and there is no support for mandibular rotation, which leads to deviation on mouth opening, premature occlusion on the ipsilateral site and open bite on the contralateral site in unilateral cases (Vasconcelos et al., 2009). Gap arthroplasty may lead to the development of anterior open bite and respiratory distress and anterior open bite may in bilateral cases (El-Sheik et al., 1996). Even after wide gap arthroplasty, recurrence can still develop (Roychoudhury et al., 1999). According to He et al, the recurrence rate with GA may be as high as 50% (He et al., 2011). Topazian's work also highlighted the unacceptibly high recurrence rate of ankylosis even following very wide gap arthroplasties, and this prompted the widespread use of interpositional grafting as a more effective means of reducing re-ankylosis (Topazian, 1966; Moorthy, 1983). Because of its inherent problems, GA alone has largely been abondoned as a definitive treatment modality for TMJA (Kaban et al., 1990; Matsura et al., 2001).

B. Interpositional Arthroplasty

Gap arthroplasty with interpositional grafting (IPG) has become the acceptable standard for primary surgical management of TMJ ankylosis. Interpositional material was used by Risdon (Danda et al., 2009) in 1934. The use of interpositional materials between the condylar stump and glenoid fossa is advocated in order to reduce the risk of reankylosis. Various interpositional grafts have been used, as outlined by Dimitroulis (Dimitroulis, 2004). The most popular interpositional material is the temporalis muscle fascia (TMF), with good results due to its ease of use, dependable blood supply, proximity to the

temporal joint, minimal risk of facial paralysis and minimal complications (Su-Gwan, 2001; Balaji, 2003).

A systematic review and meta-analysis on 4 studies by Katsnelson et al (Katsnelson et al., 2012) found that GA patients had significantly better postoperative MIO than those who had reconstruction of Ramal Condylar Unit (RCU) with costochondral grafts, but the absolute difference in MIO was small (2.4mm). A meta-analysis by Al-Moraissi et al (Al-Moraissi et al., 2014) however found that IPG resulted in significant improvement in MIO and lower recurrence rate when compared to GA alone.

C. Reconstruction of the TMJ

(i) Autogenous grafts Costochondral grafts

Various autogenous tissues (such as the fibular head, sternoclavicular and metatarsophalangeal joints, iliac crest, and costochondral grafts) have been used in an attempt to restore facial height, altered joint mechanics, transplant of the growth centre and reconstruct the temporomandibular joint articulation following release of TMJ ankylosis.

Since its description by Gillies in 1920, Costochondral graft (CCG) has over time gained universal endorsement for replacement of the RCU in ankylosed and non-ankylosed patients with end-stage joint disease (Gillies, 1920). Costochondral graft has gained popularity because it has three important functional parts; the bony part which is used to manage the height of the ramus of the mandible and fixation of the graft, the cartilaginous part which act as an interpositional material and the growth centre which lies between the bony and the cartilaginous part (Kennett, 1973).

The use of CCG in TMJ reconstruction has over the years been revised and subjected to scientific scrutiny (Gillies, 1920; Kennett, 1973; Poswillo, 1974). The purported advantages of CCG include ease of harvest and adaptation, minimum morbidity, numerous donor sites, regeneration of the donor site and retention of integrity after transplantation (Kennett, 1973). Also, in the growing patient, CCG with intact costochondral junction not only provides an excellent choice of autogenous tissue for replacement of a missing, malformed and or diseased condyle but also demonstrates growth potential (Figueroa et al., 1984; Ware & Taylor, 1966; Ware & Brown, 1981). Costochondral graft has been described as the

best autogenous tissue for reconstruction of the RCU by Kaban et al and Ware and Brown (Kaban et al., 1990; Ware & Brown, 1981).

The protocol most widely followed for CCG reconstruction of the TMJ following resection of the ankylosed mass is that described by Kaban et al (Kaban et al., 1990). This protocol consists of early surgical intervention, aggressive resection of 1.5-2.0 cm of the ankylotic mass via preauricular approach, ipsilateral coronoidectomy, contralateral coronoidectomy (if mouth opening is less than 35 mm), lining the TMJ with temporalis fascia, reconstruction of the TMJ with autogenous CCG harvested from 5th-7th ribs of the right chest wall (Figure 4). The rib is shaped and inserted via a Risdon approach. Four bicortical screws (2 mm miniplate and screws) are used to fixate the CCG to the lateral aspect of the ramus of the mandible. The reconstruction is followed by early mobilisation and aggressive physiotherapy. The native disc, dermis, buccal fat pad and auricular cartilage have also been used as interpositional materials.



Figure 4: Costochondral graft.

So, the main problem with the CCG relates to its high risk for failure over the medium to long period. Common complications associated with the use of CCG include unpredictable excessive growth, reankylosis, failure to grow, graft fracture or even resorption (Sidebottom, 2013). The need for intermaxillary fixation (IMF), donor site morbidity, fracture at the costochondral junction, pleural tear, persistent chest pain and neuritis are other problems associated with CCG. Furthermore, CCG is regarded as a free graft requiring a good vascular bed to take, with capillaries able to penetrate a maximum thickness of

180-220 microns of tissue, whilst scarred tissue surrounding previously operated sites averages 440 microns thickness (Sidebottom, 2013). As such, any revision surgery with CCG carries with it a very high risk of failure due to excessive scarring of the vascular bed.

(ii) Temporomandibular joint prosthesis

Besides lack of donor site morbidity and reduced hospital stay total alloplastic joint reconstruction allow for immediate function and correction of bony defects and facial asymmetry (Mercuri, 2000). After a period of uncertainty and safety concerns brought about by prostheses containing PTFEs (which caused bony resorption and foreign body reactions) such as Kent-Vitek –I and II prostheses, two FDA –approved total TMJ prosthesis have been declared safe for use in humans. First is custom made joints (TMJ Concepts Patient-Fitted Total TMJ Replacement System, Ventura, CA, USA) and second is a stock made prosthesis (Biomet Microfixation TMJ Replacement System, Jacksonville, FL, USA) (Quinn, 2000; Giannakopoulos et al., 2012). Both of these joints are metal on high molecular weight polyethelene joints.

Indications for alloplastic TMJ reconstruction include:

- Ankylosed and degenerated joints
- Severe polyarticular inflammatory joint diseases
- Failed previous autogenous or alloplastic joint reconstruction.
- Recurrent ankylosis
- Avascular necrosis.

The Biomet System is a stock and custom joint system, consisting of a fossa component (made of a grade of Ultra High Molecular Weight Polyethylene called ArCom) and a mandibular (condylar) prosthesis which is made of Cobalt Chromium Alloy (Giannakopoulos et al., 2012). The under surface of the mandibular prosthesis is coated with titanium plasma spray for increased bony integration (Giannakopoulos et al., 2012). The screws from this system are made of a titanium-aluminium-vanadium (6AL/4V titanium) alloy (Giannakopoulos et al., 2012).

Giannakopoulos et al (2012) reported statistically improvement in jaw function, pain level and incisal opening (post-operative mouth opening of 30-35mm) on 288 patients who had 442 TMJ replacement with Biomet Microfixation System. 14 of the 442 implants (3.2%) had 1 or 2 components explanted as a result of heterotopic bone formation or infection. There were however no device-related mechanical failures observed. Westermark also reported that in patients with advanced diseases, total alloplastic TMJ reconstruction is a useful treatment modality. The follow-up period in this study of 12 patients was 2-8 years. A maximum inter-incisal opening of at least 35 mm was maintained in 9 patients (Westermark, 2012).

Wolford et al (2016) reported on 32 patients with 48 ankylosed joints using TMJ Concepts prostheses. The following (preoperative to postoperative) improvements were noted: median value for TMJ pain from 8.0 to 2,5; facial pain from 8 to 4, jaw function from 8 to 2,5 and mouth opening from 14.5 to 35mm at the longest follow-up (Wolford et al., 2016). Their technique included placement of autogenous fat grafts around the TMJ Concepts total joint prosthesis to prevent postoperative heterotopic bone formation and fibrosis (Wolford et al., 2016). Their rationale for placing autologous fat grafts around the TMJ prosthesis was to obliterate the dead space surrounding the joint prosthesis, thus preventing formation and subsequent organization of a blood clot (Wolford et al., 2016). Creating this physical barrier, the fat graft serves to minimize the presence of pluripotential cells and prevent formation of extensive fibrosis and heterotopic calcification. Mercury et al (2008) also evaluated 20 patients with 33 ankylosed joints treated with TMJ Concepts prostheses and placement of periarticular autologous abdominal fat with a mean follow-up of 50.4 months. Results showed a 52% reduction in pain, 76% improvement in jaw function and 140% improvement in MIO (from 11.8 to 32.9 mm).

For reconstruction of the irreparably damaged adult TMJ, alloplastic total joint replacement is now considered the gold standard. Relative contraindications

for their use include skeletal immaturity, systemic diseases with increased susceptibility to infection and allergy to prosthetic materials (Quinn, 2000).
Their use however is not without complications. Loss of lateral pterygoid muscle attachment will restrict the joint to purely rotational movements and not allow for translatory movements. As a result of this, a 30-35 mm postoperative interincisal mouth opening is considered reasonable (Quinn, 2000). Protrusive and lateral movements will also be restricted.

The risk of wear debris, cost of the device and the finite durability of the prosthesis, with potential need for replacement after 20 years are some of the disadvantages associated with total alloplastic joint reconstruction.
(Quinn, 2000).

(iii) Lateral Arthroplasty (LAP)

Lateral arthroplasty was first described by Nitzan et al (1998) as a treatment option for Sawhney Type III ankylosis. In this procedure, the lateral ankylosed bony mass is resected but the medially displaced condylar fragment is preserved, leaving a large gap between the glenoid fossa and the ramus. The crucial point in LAP is preservation of the functional medially displaced condylar fragment. It is also purported that this medially displaced condylar fragment may also promote the development of the mandible in growing patients (He, et al., 2011).

In LAP, to prevent recurrence of the ankylotic process, the capsule is sutured lateral to the joint to cover the resection site. He et al reported a 36.4% reankylosis rate when they used this method (He et al., 2011). They then modified the technique by using TMF as an interposotional material and had a total recurrence rate of 14.6% (He et al., 2011).
Advantage of LAP is that the native disc can be sutured with the TMF as an interpositional material. Also, internal fixation is not needed, which eliminates the risk of hardware loosening or foreign body reaction.

An important prerequisite for LAP is that the medially displaced condylar fragment must be bigger than one third of the condylar head. Excessive TMJ loading force and

ultimately resorption may occur if the condylar fragment is less than one third of the condylar head

(iv) Transport distraction osteogenesis

Kaban et al (1990) recommend the use of DO to reconstruct the RCU in patients with TMJ ankylosis. Stucki-McCormick (1997) was the first to report the use of DO for the re-establishment of the condyle in two developmental disorder cases in 1997. Following condylectomy and gap arthroplasty, the jaw is mobilised and the lining created with a TMF or the native articular disk. The native mandibular stump is reshaped to make it narrow and rounded at the top. A corticotomy is created distally, leaving enough bone to serve as a transport disk. The distraction device is secured, the cortocotomy completed and mobility of the segment is tested. Active distraction starts 2-4 days postoperatively, at a rate of 1 mm/day with a rhythm of 2 or 4 activations daily.

Distraction osteogenesis eliminates the need for donor site and allows for immediate function of the TMJ. Also, bone regeneration occurs at the trailing edge of the transport disc resulting in bridging of the defect without the need for a bone graft to form a new ramus or condylar neck (Basal et al., 2014). Most importantly, the patient is able to masticate function during the process of neogenesis of the condyle.

POST-OPERATIVE PHYSIOTHERAPY

Postoperative aggressive physiotherapy is regarded as equally important as surgery and is recommended for a year (Freedus et al., 1975). Methods of mobilisation of the joint include, wooden spatulas, acrylic screws, functional appliances, exercises under general anaesthesia and use of professional skills of physiotherapist (Kaban et al., 1990; Posnick & Goldstein, 1993; Chossegros et al., 1997). The accepted protocol for postoperative physiotherapy after release of TMJ ankyloses is as follows: jaw exercises for 15 minutes six times a day under supervision, regular visits for a month, biweekly visits for the next 3 months and monthly visit for a year (El-Sheikh & Medra, 1997). However, the controversial area of postoperative physiotherapy is how soon it must it be started. Some studies recommend postoperative immobilisation for few weeks (Kaban et al., 1990; El-Sheik et al., 1996; Salins, 2000), only in bilateral cases

(El-Sheikh, 1999). Most authors advocate early mobilisation of the jaws, within 24-48 hours after release of the ankylosis (Roychoudhury et al., 1999; Kennett, 1973; Chossegros et al., 1997; Rajgopal et al., 1983). It is however very difficult to guarantee this co-operation from children.

CHAPTER 2: AIMS AND OBJECTIVES

AIMS

To retrospectively analyse the epidemiology, treatment and outcomes of patients with TMJ ankylosis

OBJECTIVE

1. To describe the demographic characteristics of patients who presented with TMJ ankylosis at Wits Oral Health Centre (WOHC) over a 20-year period.
2. To determine the causative factors of TMJ ankylosis.
3. To determine the age and common presenting symptoms.
4. To describe how patients with TMJ ankylosis were treated.
5. To compare treatment outcomes and complications among patients treated for TMJ ankylosis at WOHC.

CHAPTER 3: MATERIALS AND METHODS

Study design

This is a retrospective study of patients treated for TMJ ankylosis in the Department of Maxillo-facial and Oral Surgery at Wits Oral Health Centre. All patients managed for ankylosis from January 2000 to December 2020 will be included in the study. Clinical and radiographic records of patients treated for TMJ ankylosis will be analysed.

Study population and treatment

All patients who were treated for TMJ ankylosis between the period January 2000 to December 2020, at Charlotte Maxeke Johannesburg Academic (CMJAH) and Chris Hani Baragwaneth Academic hospital (CHBAH) were included in this study.

Mouth opening (MO) and complications such as reankylosis were the primary outcome variables. Secondary outcome variables included demographic variables, aetiology of ankylosis, laterality, treatment modality, preoperative MO and revision surgery. Treatment consisted of resection of ankylosed mass (GAP alone) via preauricular approach or GAP followed by reconstruction with costochondral graft (CCG) or stock total alloplastic joint reconstruction (TAJR). In GAP alone a 1,5-2 cm gap was created after resection of the ankylosed mass and left without any interpositional material.

For CCG, a combination of the preauricular with temporal extension and Risdon approaches was used to expose the TMJ and the mandibular ramus respectively. After GA, the MO measured up to 35 to 40 mm in all patients. If there was limitation in MO of less than 35 mm, ipsilateral followed by contralateral coronoidectomy, then pterygomasseteric sling release were also performed if needed until the patient's MO of 35 mm was reached. For CCG, the graft was harvested through a submammary incision from the $5^{th}/6^{th}$ ribs (both 5th and the 7th ribs were employed in bilateral TMJA). Thickness of cartilaginous component ranged from 3- 5 mm. Rigid internal fixation of the CCG was provided by 2 to 4 bicortical screws, secured on the mandibular ramus. Postoperative IMF was established for up to 6 weeks to stabilize the graft and promote optimal healing.

For TAJR, following this exposure, Sonopet was used to make a standard condylectomy cut from the inferior border of the zygomatic arch to the sigmoid notch inferiorly. After removal of the condyle, the ramus is then displaced superiorly into the space created by the initial condylectomy, and the second step of the osteotomy is performed 2 to 3 mm below the lowest point of the sigmoid notch and can include the coronoid process. This is necessary to create a 1.5-2 cm gap to accommodate the thickness of the glenoid fossa implant. Sonopet was then used to flatten the articular eminence. Extra-oral surgical wounds are then packed with sterile gauze. Following stretching of the mouth, Erich arch bars or Eyelets are placed, and the patient is then placed into intermaxillary fixation to the most optimal occlusion. At least four 7 mm or 9 mm length screws were used to secure the fossa component to the zygomatic arch. Next, the mandibular sizer (trial) was used to assess whether a 45mm, 50mm or 55mm prosthesis will be used. Condylar prosthesis is secured with four to six 2,7 mm screws (8- and 10-mm lengths). This is followed by release of IMF. To ensure proper matching between the fossa and the condylar prostheses, and to confirm that there are no mechanical obstructions or anterior dislocations, the mandible was then manipulated. Mouth opening exercises were commenced at day 2 postoperatively.



Figure 6: Condylar and fossa components.



Figure 5: Ramus component.

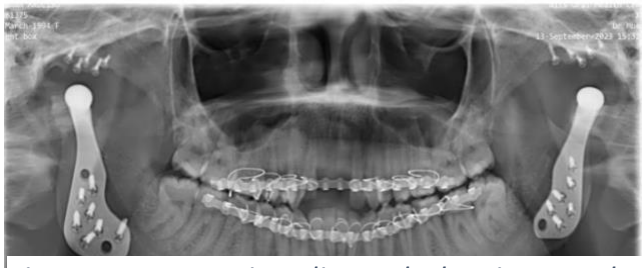

Figure 7: Panoramic radiograph showing prosthetic joints.

Next, patients were referred for intensive physiotherapy after removal of fixation. They were instructed to practice mouth-opening exercises with sticks or a TheraBite Jaw Rehabilitation System (Atos Medical, Horby, Sweden). Physiotherapy was started within 24 hours in GA and TMJ alloplastic reconstruction groups; and soon after a period of IMF in CCG group.

The primary outcome variables were maximum MO and complications during follow-up.

Data collection

A proforma which has all the variables to be investigated has been designed (ANNEXURE I). The following variables were included: Age, Gender (male/female), medical history (clear/present), medication (none/name), aetiology of ankylosis (trauma, infection, surgery, idiopathic), Diagnosis (unilateral/ bilateral), pre-operative mouth opening, treatment (GAP/CCG/alloplastic joint), post-operative mouth opening, post-operative occlusion, length of follow-up, complications (infection, reduced mouth opening, nerve injury, reankylosis), current mouth opening.

Inclusion criteria

- Clinical and radiographic evidence of TMJ ankylosis.
- Patients treated in CHBAH and CMJAH between 2000 and 2020.
- Participants who were followed-up for at least 6 months.

Exclusion criteria

- Patients treated outside of the time frame.
- Incomplete records.
- Failure to return for requisite 6 months follow up.

Data analysis

The data was analysed using IBM SPSS Statistics version 28.0.1.1 (15). The quantitative variables were initially checked for normal distribution using the

Kolmogorov-Smirnov and Shapiro-Wilk tests. A p-value > 0.05 was considered for normally distributed data. Quantitative variables that were not normally distributed were summarized as median (IQR). Categorical variables were represented as bar graphs with percentages. Comparison of the medians of quantitative variables between sub-groups of diagnosis and treatment were done using the Kruskal Wallis test. Associations with the sub-groups of diagnosis and treatment with other categorical variables were done using the Fisher's Exact/Chi-square tests. A p-value < 0.05 was considered significant.

Chapter 4: RESULTS

During the study period, 71 case treated for TMJ ankylosis at CMJAH and CHBAH were identified. The age ranged from 4 years to 70 years. 49.3% (n=35) of the patients were female, while 50.7% (n=36) were male. As indicated in table 1, majority of patients (39.44%) (n=28) presented with left TMJ ankylosis, followed by right TMJ ankylosis (38.03%) (27) and bilateral TMJ ankylosis (22.54%) (n=15).

Table 1: Distribution of TMJ ankylosis.

Type of Ankylosis	Frequency	Percentage
Left TMJ Ankylosis	28	38.44%
Right TMJ Ankylosis	27	38.03%
Bilateral TMJ Ankylosis	15	22.54%
Total	71	100%

Patients were categorised into decades, based on their age. The second decade had the most patients (20), making up 28.17% of the total number of patients. This is indicated in figure 8.

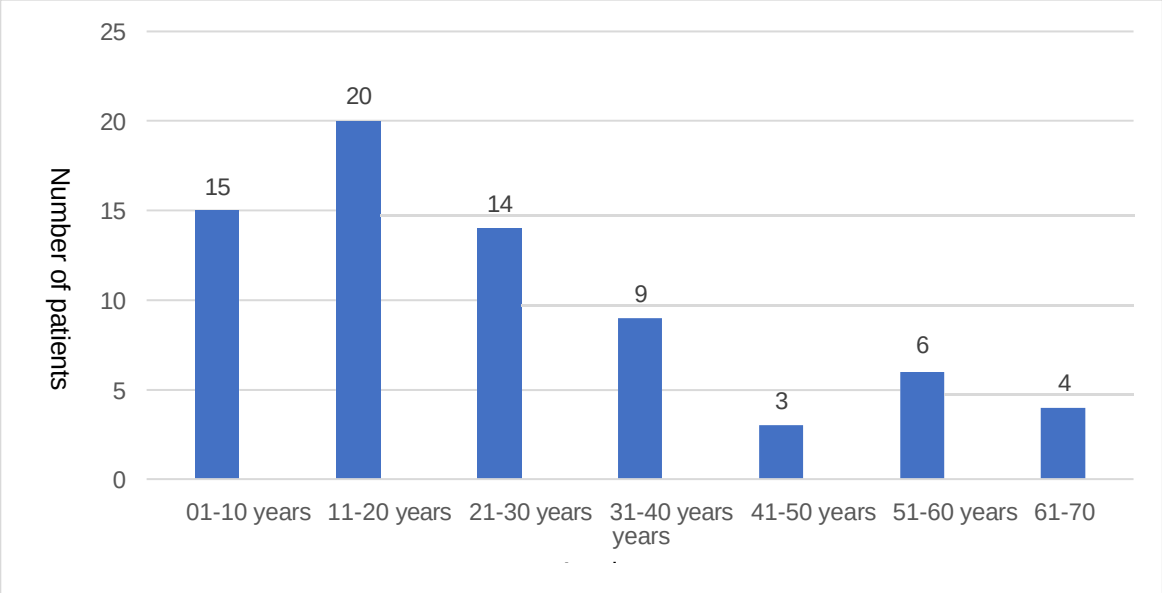

Figure 8: Distribution of age in decades.

Trauma was found to be the leading cause of TMJ ankylosis at 77.46% (n=55) while the cause of ankylosis in 18.31% (13) of patients was unknown and 4.23% (n=3) was caused by infection. Figure 9 shows the distribution and ankylosis based on cause and gender. Trauma was the leading cause of ankylosis (77.46%) (n=55), females were slightly affected more by trauma at 39.44% (n=28) and males at 38.03% (n=27).

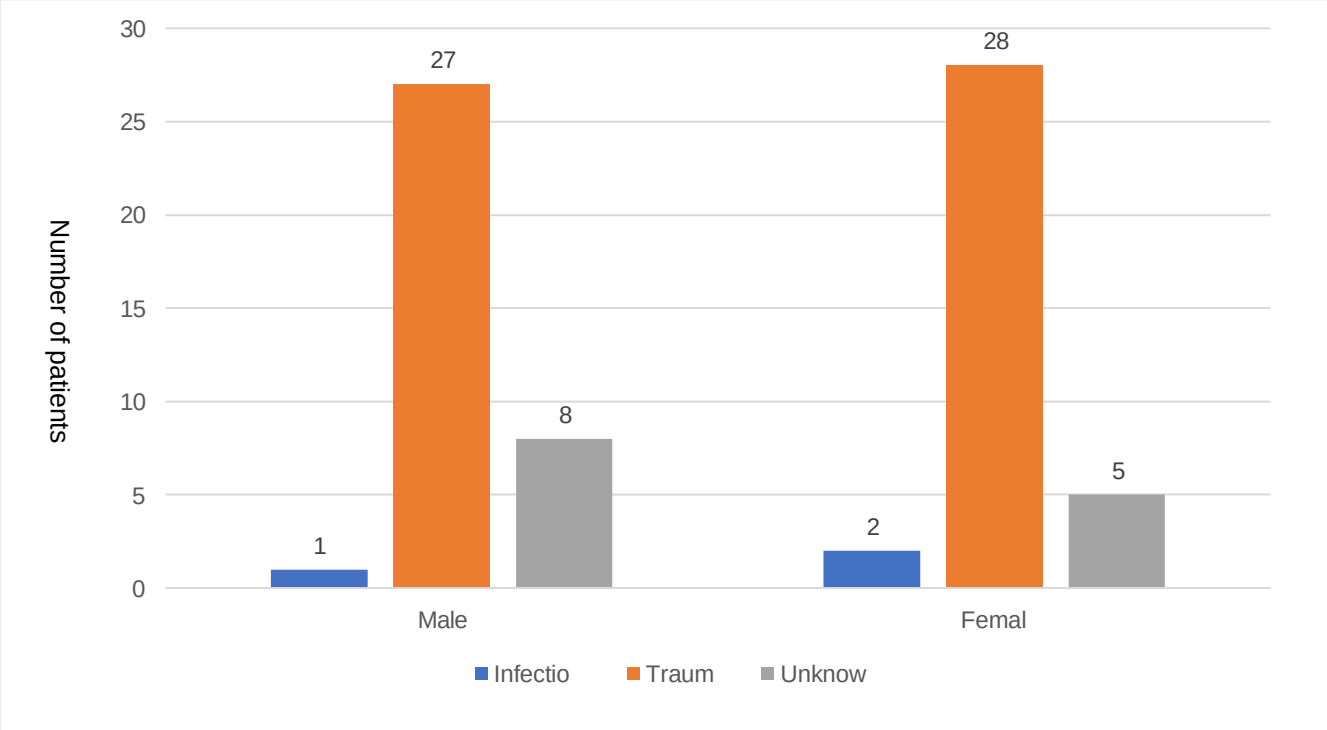

Figure 9: Distribution of cause of ankylosis and gender.

Majority of patients 57,75% (n=41) had isolated GAP as the treatment modality, followed by 26.76% (n=19) who had TAJR, and 15.49% (n=11) who had CCG. This is represented on the pie chat bellow (Figure 10).

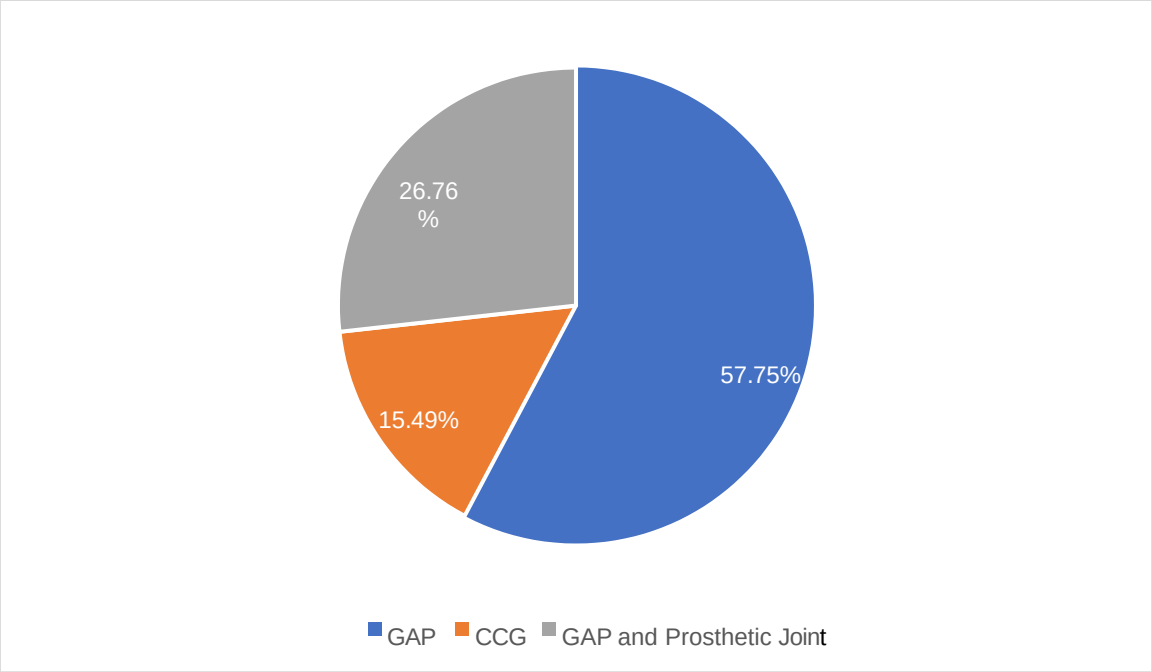

Figure 10: Distribution of treatment modalities.

Table 2 shows the mean pre- and post-operative mouth opening in mm, obtained from the different treatment options.

Table 2: Average of pre- and post-operative mouth opening.

Treatment	Preoperative Mouth opening (mm)	Postoperative Mouth opening (mm)
TAJR	1,73	33,89
GAP	1,97	32,07
CCG	0,45	32,00

The preoperative mouth opening for TAJR, GAP only and CCG were 1.73 mm, 1.97 mm and 0,45 mm respectively. After a 6-month follow-up, postoperative mouth opening for TAJR, GAP and CCG were 33.89 mm, 32.07 mm and 32,00 mm respectively.

Table 3: Analysis of variance descriptive summary of pre-operative mouth opening.

Groups	*Count*	*Sum*	*Average*	*Variance*		
CCG	11	5	0,454545	0,472727		
GAP	41	77	1,974359	11,34143		
TAJR	19	33	1,736842	16,09357		
ANOVA						
Source of Variation	*SS*	*df*	*MS*	*F*	*P-value*	*F crit*
Between Groups	17.93067	2	8.965334	0,831934	0,439587	3,131672
Within Groups	732,8017	68	10,7765			
Total	750.7324	70				

The test statistic, F, is reported in the analysis of variance table, F = 0,831934. The p-value for this statistic was p= 0.439587 > 0,05, not statistically significant, confirming no difference in the means across the groups.

Table 4: Analysis of variance summary of post-operative mouth opening.

Groups	*Count*	*Sum*	*Average*	*Variance*		
CCG	11	348	31,636	11,65455		
GAP	41	1315	32,07317	13,36951		
TAJR	19	644	33,89474	12,87719		
ANOVA						
Source of Variation	*SS*	*df*	*MS*	*F*	*P-value*	*F crit*
Between Groups	52,63106	2	26,31553	2,026299	0,139706	3,131672
Within Groups	883,1154	68	12,98699			
Total	935,7465	70				

The test statistic, F, is reported in the analysis of variance table, F = 2,026299. The p-value for this statistic is p= 0,139706 > 0,05 not statistically significant. This means that there is evidence that there were no differences in the means across groups.

The complications encounter included: reankylosis, which was reported in 9 patients. The cause of ankylosis in the first patient was juvenile rheumatoid arthritis. The cause of ankylosis in the other eight patients was trauma. The initial treatment for three

patients was GAP and CCG in the other six patients. These patients then had a second procedure (GAP and reconstruction with stock joint in 3 patients) and GAP alone in the other 6 patients. Mouth opening improved in all patients after the second procedure. Three patients treated with CCG also had excessive, unpredictable growth, resulting in facial asymmetry and malocclusion.

Deviation of the jaw to the ipsilateral side was reported in 15.49% (n=10) of the patients who had isolated GAP. Transient weakness of the zygomatic branch of the facial nerve was reported in 5.64% (n=4) of patients. These resolved spontaneously. Infection around the preauricular area was reported in 1.41% (n=1) of patients (this was treated by incision and drainage under local anaesthesia and antibiotics).

Chapter 5: DISCUSSION

Temporomandibular joint ankylosis (TMJA) is a debilitating condition with resultant difficulties in mastication, speech, and mouth opening. Diagnosis and management of patients with TMJ ankylosis poses challenges particularly in younger patients. Ultimately, the measure of successful outcome is the improvement in mouth opening, restoration of function and quality of life.

From the present study, most of the patients were young, with majority in the second decade of life. This coincides with the reported study by He et al in which the mean age was 23 years (He et al., 2008). The slight male preponderance in this study could be due to males being subjected more to outdoor activities and interpersonal violence compared to females. Qudah et al and Bello et al also reported similar findings (Qudah et al., 2005; Bello et al., 2012).

Notably, trauma was the most common aetiological factor. These results are consistent with those reported by Laskin, Chalmer et al, Maclennan and Ellis (Laskin, 1978; Chalmer & Blair, 1973; MacLennan, 1952; Ellis, 1998). Traumatic injury to the temporomandibular articulation is by far the most common preceding cause of TMJ ankylosis. Despite condylar fractures being the leading cause of temporomandibular joint ankylosis, it is worth bearing in mind that ankylosis is very rare in patients who suffered condylar fractures, with an incidence of approximately 0.2 to 0.4% (Tripathy et al., 2009; (He et al., 2010; Dimitroulis, 2004; Moss & Salentijn, 1969). Although the sequence of events that culminate in TMJ ankylosis following condylar fractures awaits elucidation, it is hypothesised that trauma results in intra-articular haematoma formation leading to fibrosis, excessive bone formation and ultimately to hypomobility of the joint (Toyama et al., 2003). Early diagnosis and management of trauma, particularly in children is of paramount importance in prevention of TMJ ankylosis. Unfortunately, in developing countries, the lack of resources and low socio-economic status remain an Achilles' heel. Those childhood traumas, predominantly falls from heights that result in maxillo-facial injuries, in particular mandibular condylar fracture, are either overlooked or never attended to. In some cases, the patients never sought medical attention or delay getting one simply because they reside far from healthcare facilities, or they cannot afford it (Sawhney, 1985).

Post-operative mouth opening at 6 months was statistically insignificant amongst the different treatment modalities. Both GA and total alloplastic joint reconstructions yielded slightly better mouth opening than CCG. Roychoudhury et al (2021) also reported improvement in MIO was more in the GA group than CCG after 12-month follow-up (Roychoudhury et al., 2021). Their explanation was that the post GA shift of fulcrum of opening to either mid ramus or last standing tooth occurs in GA (especially in bilateral cases) aids in large mouth opening. In CCG the fulcrum remains in the condylar area due to ramus-condyle unit reconstruction and that this may hinder large movements however the mouth opening achieved is adequate and within normal limits. Westermark and Aagard reported that the long period of ankylosis (from childhood for many of these patients) affects the stretching capabilities of all surrounding tissue components (Westermark, 2010; Aagaard, 2018). They concluded that it is almost impossible, under these conditions, to restore normal opening of the jaws, and suggested that a MO greater than 25 mm and maintained permanently could be considered a success. Stripping of the pterygomasseteric sling combined with the coronoidectomy greatly contribute to improved mouth opening.

According to He et al, the recurrence rate associated with GA may be as high as 50% (He et al., 2011). Gap arthroplasty in bilateral cases may result in anterior open bites, and respiratory distress (Vasconcelos, 2009). Agarwal et al (2021) also concluded that gap arthroplasty in patients with bilateral TMJA can lead to development or worsening of pre-existing mild to moderate obstructive sleep apnea (OSA) (Agarwal et al., 2021). Topazian's work also highlighted the unacceptibly high recurrence rate of ankylosis even following very wide gap arthroplasties, and this prompted the widespread use of interpositional grafting as a more effective means of reducing re-ankylosis (Topazian, 1966; Roychoudhury et al., 1999; Shira, 1983). Because of its inherent problems, GA alone has largely been abondoned as a definitive treatment modality for TMJ ankylosis (Miyamoto et al., 1999; Shira, 1983). Despite this, gap arthroplasty was chosen in this study in only unilateral cases because it is a cheap and less complex treatment modality. It appears like aggressive physiotherapy and proper counselling of the patient prior to surgery are the most important factors in preventing re-ankylosis regardless of the surgical technique used. We are also in agreement with Mittal et al (2019) that a decrease in MO does not always imply recurrence but may be a manifestation of poor compliance and failure to adhere to the prescribed physiotherapy protocol (Mittal et al., 2019). In the present study 3 patients treated by

GA ended up with recurrent ankylosis. A longer follow-up beyond 6 months could have yielded a different outcome.

Although there is widespread consensus about the suitability of CCG as a ramal condylar unit reconstructive option and it is regarded as the gold standard of TMJ reconstruction with many advantages such as biologic compatibility, remodelling capability and growth potential; their unpredictable behaviour coupled with donor site morbidity and delay in post-operative physiotherapy, could result in undesired outcomes such as reankylosis and excessive growth. Seven out of 13 patients who presented with complications had CCG treatment, five of which resulted in reankylosis. Two of these patients had facial asymmetry due to overgrowth of CCG and deviation as well as retardation of mandibular growth. In this study, nine out of 12 patients who presented with complications had CCG treatment, six of which resulted in reankylosis. Two other patients had facial asymmetry due to overgrowth of CCG and deviation as well as retardation of mandibular growth. One patient ended up with malocclusion from overgrowth of CCG. These findings are similar to those reported by Saeed et al in which 23 out of 49 patients treated with autogenous grafts (CCG) had complications, of which 18 (37%) patients suffered reankylosis, 3 patients had overgrown graft and 1 patient had malocclusion (Saeed & Kent, 2003). It appears like the ankylotic milieu that the CCG finds itself, aggravated by muscle atrophy, fibrosis of the ligaments and possible genetic factors may be contributors to the genesis of reankylosis. Costochondral graft is also reported to have a questionable prognosis in older patients and those with previous surgeries, as it appears like the cortical ribs in older patients offer poor osseointegration because of a small amount of cancellous bone (Matsura & Miyamoto, 2001).

Saeed et al (2003) also reported a high incidence of reankylosis in patients with CCG, presumably resulting from transplantation of excessive amounts of cartilage (Saeed & Kent, 2003). Perrot et al (1994) reported that when 2-3 mm of cartilage was transplanted, no overgrowth of CCG occurred (Perrot, et al., 1994). Qudah et al, evaluated 16 patients in the CCG group and demonstrated that 2 of the 16 patients showed overgrowth, this despite transplanting only 2-3 mm of cartilage (Qudah, et al., 2005). Dimitroulis also reported that CCG patients were more likely to experience complications (7/16, 43.8%) necessitating a return to theatre (Dimitroulis, 2014). Likewise, Tang et al (17.9%,5/28) also found that CCG were more likely to require re-

operation either for reankylosis or to correct excessive growth (Tang, et al., 2009). Unpredictable excessive growth and reankylosis of costochondral grafts remain the biggest drawback of TMJ reconstruction in the growing patient. He et al suggested the following steps to reduce the risk of reankylosis following CCG: rigid internal fixation for the free bone graft, using temporalis muscle fascia as a barrier to eliminate dead space, masseter muscle release and coronoidectomy as underscored by Kaban et al (He et al., 2009; Kaban et al., 1990).

The findings in this study seem to indicate that alloplastic joint reconstruction has gained popularity over CCG when TMJ reconstruction is indicated. Wolford et al also reported treatment outcomes of 32 patients with 48 ankylosed TMJ using total alloplastic joint reconstruction (Wolford et al., 2016). The following (preoperative to postoperative) improvements were noted: median value for TMJ pain from 8.0 to 2,5; facial pain from 8 to 4, jaw function from 8 to 2,5 and mouth opening from 14.5 to 35 mm at the longest follow-up. Their technique included periarticular fat grafting around the prostheses. The rationale for placing autologous fat grafts around the TMJ prosthesis is to obliterate the dead space surrounding the joint prosthesis, thus preventing formation and subsequent organization of a blood clot. Creating this physical barrier, the fat graft serves to minimize the presence of pluripotential cells and prevent formation of extensive fibrosis and heterotopic calcification (Wolford et al., 2016). For patients with a history of multiple TMJ surgeries, heterotopic bone formation or ankylosis, there is plausible justification to incorporate the periarticular fat-grafting protocol. Prospective randomised controlled studies are needed to justify routine fat grafting in non-ankylotic patients and those with no history of heterotopic bone formation.
Mercury et al (2008) also evaluated 20 patients with 33 ankylosed joints treated with TMJ Concepts prostheses and placement of periarticular autologous abdominal fat with a mean follow-up of 50.4 months. Their results showed a 52% reduction in pain, 76% improvement in jaw function and 140% improvement in MIO (from 11.8 to 32.9 mm) (Mercuri et al., 2008).

All 4 patients that had transient facial nerve weakness recovered completely within 6 months post-operatively. Similar results were reported by Rikhotso and Sekhoto

(2021). Sidebottom and Gruber (2013) also reported that 33 of their 74 patients had facial nerve paralysis (31 partial, and 2 total); all resolved fully except for the one patient who had a residual temporal branch weakness. It thus appears like the risk of permanent facial nerve damage is very low.

The present study has multiple limitations. First, the types and morphology of ankyloses were not specified. Secondly there was no standardised physiotherapy protocol (method, duration and compliance). Present study included patients with not only acquired TMJ ankylosis but systemic diseases affecting the joints, i.e. juvenile rheumatoid arthritis. In addition to re-ankylosis and MIO, other variables such as protrusion, pain and overall quality of life should be studied; and this was not evaluated in the current study. It was also not possible to determine the duration of ankylosis from the history given by the patients. A diverse age group was also included in this study, creating a non-homogenous group.

Chapter 6: CONCLUSION

The present study evaluated and compared treatment outcomes of ankylosed patients treated with GA, CCG and total alloplastic joint reconstruction. Traumatic injury to the temporomandibular articulation was by far the most common preceding cause of TMJ ankylosis. Costochondral graft remains the gold standard for reconstruction of the ramal condylar unit, especially in the growing patient.

Although no significant difference in outcomes was observed, both GAP and alloplastic TMJ prostheses appear to offer better improvement in post-operative maximum inter-incisal mouth opening and fewer complications than CCG. Despite uncertainties about their longevity and lack of growth potential, TMJ prosthesis appears to offer a viable non-autogenous functional reconstructive option to adult patients with TMJ ankylosis.

From the findings of the present study, revealing no difference between GAP, CCG and alloplastic joint reconstruction, we conclude that irrespective of the treatment modality executed, early surgical intervention, radical and sufficient resection of ankylosed mass, early postoperative exercises, active physiotherapy and follow-up are imperative for successful rehabilitation and prevention of reankylosis of patients with temporomandibular joint ankylosis. Future prospective randomised-controlled studies, involving a larger number of patients, as well as longer follow-up period that will include data on type of ankylosis and standardised physio protocol are recommended to further strengthen the findings of this study.

References

1. Aagaard, E., 2018. Evaluation of Total Alloplastic Temporomandibular Joint Replacement in TMJ Ankylosis. *Journal of Maxillofacial and Oral Surgery,* 18(2), pp. 293-298.
2. Agarwal, B. et al., 2021. Does Bilateral Gap Arthroplasty Increase the Severity of Obstructive Sleep Apnea in Patients With Temporomandibular Joint Ankylosis. *Journal of Oral and Maxillofacial Surgery ,* 79(6), p. 1344.
3. Al-Moraissi, E., El-Sharkawy, T., Mounair, R. & Ghareeb, T., 2014. A Systematic Review And Meta-Analysis of The Clinical Outcomes For Various Surgical Modalities in The Management of Temporomandibular Joint Ankylosis. *International Journal of Oral and Maxillofacial Surgery ,* 44(4), pp. 470-482.
4. Angin, S. & Simsek, B., 2020. *Comparative Kinesiology of the Human Body Normal and Pathologic Conditions..* 1st ed. Cambridge: Andre Gerhard Wolff.
5. Balaji, S., 2003. Modified Temporalis Anchorage in Craniomandibular Reankylosis. *International Journal of Oral and Maxillofacial Surgery ,* 32(5), pp. 480-485.
6. Basal, V., Singh, S., Garg, N. & Dubey, P., 2014. Transport Distraction Osteogenesis as a Method of Reconstruction of The Temporomandibular Joint Following Gap Arthroplasty For Post-Traumatic Ankylosis in Children: A Clinical and Radiological Prospective Assessment of Outcome. *International Journal of Oral and Maxillofacial Surgery ,* 43(2), pp. 227-236.
7. Bello, S., Olokun, B., Olaitan, A. & Ajike, S., 2012. Aetiology and Presentation of Ankylosis of the Temporomandibular Joint: Report of 23 Cases From Abuja, Nigeria. *The British Journal of Oral and Maxillofacial Surgery ,* 50(1), pp. 80-84.
8. Bifano, C., Hubbard, G. & Ehler, W., 1995. Total Reconstruction of The Temporomandibular Joint With Cryogenically Preserved Allograft Mandibular Condyle, Meniscus And Fossa in The Adult Goat. *Oral Surgery, Oral Medicine, Oral Pathology, Oral Radiology and Endodontics,* 80(3), pp. 267-272.
9. Cascone, P.; Basile, E.; Angeletti, D.; Vellone, V.; Ramieri, V., 2015. TMJ Replacement Utilizing Patient-fitted TMJ TJR Devices in a Re-Ankylosis Child. *Jounal of Cranio- Maxillo-Facial Surgery,* 44(4), pp. 493-499.

10. Chalmer, I. & Blair, G., 1973. Rheumatoid Arthritis of The Temporomandibular Joint: A Clinical And Radiological Study Using Circular Tomography. *The Quarterly Journal of Medicine,* 42(166), pp. 368-386.
11. Chossegros, C. et al., 1997. Comparison of Different Materials For Interposition Arthroplasty in Treatment of Temporomandibular Joint Ankylosis Surgery: Long- Term Follow-Up in 25 Cases. *The British Journal of Oral and Maxillofacial Surgery ,* 35(3), pp. 157-160.
12. Danda, A., Ramkumar, S. & Chinnaswami, R., 2009. Comparison of Gap Arthroplasty With And Without Temporalis Muscle fFap For The Treatment of Ankylosis. *Journal of Oral and Maxillofacial Surgery ,* 67(7), pp. 425-431.
13. Dimitroulis, G., 2004. The Interpositional Dermis-Fat Graft in The Management of Temporomandibular Joint Ankylosis. *International Journal of Oral and Maxillofacial Surgery ,* 33(8), pp. 755-760.
14. Dimitroulis, G., 2014. Comparison of The Outcomes of Three Surgical Treatments for End-Stage Temporomandibular Joint Disease. *International Journal of Oral and Maxillofacial Surgery ,* 43(8), pp. 980-989.

15. Dingle, A., 1992. Fistula Between The External Auditory Canal And The Temporomandibular Joint: A Rare Complication of Otitis Externa. *The Journal of Laryngology and Otology,* 106(11), pp. 994-995.
16. El-Mofty, S., 1972. Ankylosis of The Temporomandibular Joint. *Oral Surgery, Oral Medicine, and Oral Pathology,* 33(4), pp. 650-660.
17. El-Sheikh, M. & Medra, A., 1997. Management of Unilateral Temporomandibular Ankylosis Associated With Facial Asymmetry. *Journal of Cranio-Maxillofacial Surgery,* 25(3), pp. 109-115.
18. El-Sheikh, M., 1999. Temporomandibular Joint Ankylosis: The Egyptian Experience. *Annals of The Royal College of Surgeons of England,* 81(1), pp. 12-18.
19. El-Sheikh, M., Medra, A. & Ward, M., 1996. Bird face Deformity Secondary to Bilateral Temporomandibular Joint Ankylosis. *Journal of Cranio-Maxillofacial Surgery,* 24(2), pp. 96-103.
20. Ellis, E., 1998. Complications of Mandibular Condyle Fractures. *International of Oral and Maxillofacial Surgery,* 27(4), pp. 255-257.
21. Ferretti, C., Bryant, R., Becker, P. & Lawrence, C., 2005. Temporomandibular Joint Morphology Following Post-Traumatic Ankylosis in 26 Patients. *International Journal of Oral and Maxillofacial Surgery,* 34(4), pp. 376-381.
22. Figueroa, A., Gans, B. & Pruzansky, S., 1984. Long-Term Follow-Up of a Mandibular Costochondral Graft. *Oral Surgery, Oral Medicine, and Oral Pathology,* 58(3), pp. 257-268.
23. Freedus, M., Ziter, W. & Doyle, P., 1975. Principles of Treatment For Temporomandibular Joint Ankylosis. *Journal of Oral Surgery ,* 33(10), pp. 757-765.
24. Giannakopoulos, H., Sinn, D. & Quin, P., 2012. Biomet Microfixation Temporomandibular Joint Replacement System: A 3-year Follow-Up Study of Patients Treated During 1995 to 2005. *Journal of Oral and Maxillofacial Surgery,* 70(4), pp. 787-794.
25. Gillies, H., 1920. *Plastic Surgery of The Face.* Frowde: Gillies H.D.
26. He, D. et al., 2009. Intracapsular Condylar Fracture of The Mandible: Our Classification And Open Treatment Experience. *Journal of Oral and Maxillofacial Surgery ,* 67(8), pp. 1672-1679.
27. He, D. et al., 2011. Traumatic Temporomandibular Joint Ankylosis: Our Classification And Treatment Experience. *Journal of Oral and Maxillofacial*

Surgery, 69(6), pp. 1600-1607.

28. He, D., Cai, Y. & Yang, C., 2014. Analysis of Temporomandibular Joint Ankylosis Caused by Condylar Fracture in Adults. *Journal of Oral and Maxillofacial Surgery,* 72(4), p. 763.
29. He, D., Ellis, E. & Zhang, Y., 2008. Etiology of Temporomandibular Joint Ankylosis Secondary to Condylar Fractures: The Role of Concomitant Mandibular Fractures. *Journal of Oral and Maxillofacial Surgery ,* 66(1), pp. 77-84.
30. Hiatt, J. & Gartner, L., 2009. *Text book of head and nech anatom..* 4th ed. Philadelphia: Lippincott Williams & Wilkins.
31. Kaban, L., Bouchard, C. & Troulis, M., 2009. A Protocol for Management of Temporomandibular Joint Ankylosis in Children. *Journal of Oral and Maxillofacial Surgery,* 67(9), pp. 1966-1978.

32. Kaban, L., Parrott, D. & Fisher, K., 1990. A Protocol For Management of Temporomandibular Joint Ankylosis. *Journal of Oral and Maxillofacial Surgery ,* 48(11), pp. 1145-1151.
33. Katsnelson, A., Markiewicz, M., Keith, D. & Dodson, T., 2012. Operative Management of Temporomandibular Joint Ankylosis: A Systematic Review And Meta-Analysis. *Journal of Oral and Maxillofacial Surgery ,* 70(3), pp. 531-536.
34. Kazanjian, V., 1938. Ankylosis Of The Temporomandibular Joint. *American Journal of Orthodontics and Oral Surgery ,* 24(12), pp. 1181-1206.
35. Kennett, S., 1973. Temporomandibular Joint Ankylosis: The Rationale For Grafting in The Young Patient. *Journal of Oral Surgery ,* 31(10), pp. 744-748.
36. Laskin, D., 1978. Role of The Meniscus in The Etiology of Post-Traumatic Temporomandibular Joint Ankylosis. *International Journal of Oral and Maxillofacial Surgery,* 7(4), pp. 340-345.
37. MacLennan, W. D., 1952. Consideration of 180 Cases of Typical Fractures of The Mandibular Condylar Process. *British Journal of Plastic Surgery,* 5(2), pp. 122-128.
38. Marx, R., 1993. Mandibular reconstruction. *Journal of Oral and Maxillofacial Surgery*, 51(5), pp. 466-479.
39. Matsura, H. & Miyamoto, H., 2001. The Effect of GAP Arthroplasty on Temporomandibular Joint Ankylosis- An Experimental Study. *International Journal of Oral and Maxillofacial Surgery ,* 30(5), pp. 431-437.
40. Mehrotra, D., Pradhan, R., Mohammad, S. & Kumar, S., 2011. Complications Associated With Different Surgical Modalities For Management of Temporomandibular Joint Ankylosis. *Asian Journal of Oral and Maxillofacial Surgery ,* 23(3), pp. 122-127.
41. Mercuri, L., 2000. The Use of Alloplastic Prostheses For Temporomandibular Joint Reconstruction. *Journal of Oral and Maxillofacial Surgery ,* 58(1), pp. 70-75.
42. Mercuri, L., Ali, F. & Woolson, R., 2008. Outcomes of Total Alloplastic Replacement With Periarticular Autogenous Fat Grafting For Management of Reankylosis of The Temporomandibular Joint. *Journal of Oral and Maxillofacial Surgery,* 66(9), pp. 1794- 1803.
43. Miloro, M., 2004. *Peterson's Principles of Oral and Maxillofacial*

Surgery.. 2 nd. Hamilton: BC Decker Inc.

44. Mittal, N., Goyal, M., Sardana, D. & Dua, J., 2019. Outcomes of Surgical Management of TMJ Ankylosis: A Systemic Review And Meta-Analysis. *Journal of Cranio- Maxillofacial Surgery ,* 47(7), pp. 1120-1133.
45. Miyamoto, H., Kurita, K. & Isbimaru, J. G. A., 1999. A Sheep Model for Temporomandibular Joint Ankylosis. *Journal of Oral and Maxillofacial Surgery ,* 57(7), pp. 812-817.
46. Moorthy, A., 1983. Interpositional Arthroplasty For Ankylosis of The Temporomandibular Joint. *Oral Surgery, Oral Medicine, and Oral Pathology,* 55(6), pp. 545-552.
47. Moss, M. & Salentijn, L., 1969. The Primary Role of Functional Matrices in Facial Growth. *American Journal of Orthodontics,* 555(6), pp. 566-577.
48. Nitzan, D., Bar-Ziv, J. & Shteyer, A., 1998. Surgical Management of Temporomandibular Joint Ankylosis Type III by Retaining The Displaced Condyle and Disc. *Journal of Oral and Maxillofacial Surgery ,* 56(10), pp. 1133-1138.

49. Perrot, D., Umeda, H. & Kaban, L., 1994. Costochondral Graft Construction/Reconstruction of The Ramus/Condyle Unit: Lont-Term Follow-Up. *International Journal of Maxillofacial and Oral Surgery ,* 23(6), pp. 321-328.
50. Posnick, J. & Goldstein, J., 1993. Surgical Management of Temporomandibular Joint Ankylosis in The Pediatric Population. *Plastic and Reconstructive Surgery ,* 91(5), pp. 791-798.
51. Poswillo, D., 1974. Experimental Reconstruction of The Mandibular Joint. *International Journal of Oral and Maxillofacial Surgery ,* 3(6), pp. 400-411.
52. Qudah, M., Qudeimat, M. & Al-Maaita, J., 2005. Treatment of Temporomandibular Joint Ankylosis in Jordanian Children-A comparison of Two Surgical Techniques. *Journal of Cranio-Maxillofacial Surgery ,* 33(1), pp. 30-36.
53. Quinn, P., 2000. Lorenz Prosthesis. *Oral and Maxillofacial Surgery Clinics of North America,* 12(1), pp. 93-104.
54. Rajgopal, A., Banerji, P., Batura, V. & Sural, A., 1983. Temporomandibular Ankylosis: A Report of 15 Cases. *Journal of maxillofacial Surgery ,* 11(1), pp. 37-41.
55. Rikhotso, R. & Sekhoto, M., 2021. Alloplastic Total Temporomandibular Joint Reconstruction: A 10- Year Experience of the University of the Witwatersrand, Johannesburg. *Journal of Cranio-Maxillofacial Surgery*, 32(5), pp. 1658-1663.
56. Rowe, N., 1982. Ankylosis of The Temporomandibular Joint. *Journal of The Royal College of Sergeons of Edinbrugh,* 27(2), pp. 67-79.
57. Roychoudhury, A. et al., 2021. Alloplastic Total Joint Replacement in management of Temporomandibular Joint Ankylosis. *Journal of Oral Biology and Craniofacial Research,* 11(3), pp. 457-465.
58. Roychoudhury, A., Parkash, H. & Trikha, A., 1999. Functional restoration by gap arthroplasty in temporomandibular joint ankylosis A report of 50 cases. *Oral Surgery, Oral Medicine, Oral Pathology, Oral Radiology, Oral Endodontics,* 87(2), pp. 166-169.
59. Saeed, N. & Kent, J., 2003. A Retrospective Study of The Costochondral Graft in TMJ Reconstruction. *International of Oral and Maxillofacial Surgery ,* 32(6), pp. 606-609.
60. Saeed, N. & Kent, J., 2003. A Retrospective Study of The Costochondral

Graft in TMJ Reconstruction. *International Journal of Maxillofacial and Oral Surgery ,* 32(6), pp. 606-609.

61. Salins, P., 2000. New Perspectives in The Management of Craniomandibular Ankylosis. *International Journal of Oral and Maxillofacial Surgery ,* 29(5), pp. 337- 3340.
62. Sawhney, C., 1985. Bony Ankylosis of The Temporomandibular Joint: Follow-Up of 70 Patients With Arthroplasy And Acrylic Spacer Interposition. *Plastic and Reconstructive Surgery ,* 77(1), pp. 29-40.
63. Sawhney, C., 1985. Bony Ankylosis of The Temporomandibular Joint: Follow-Up of 70 Patients Treated with Arthroplasty And Acrylic Spacer Interposition. *Plastic and Reconstructive Surgery ,* 77(1), pp. 29-40.
64. Shira, R., 1983. Interpositional arthroplasty for ankylosis of the temporomandibular joint. *Oral Surgery, Oral Medicine, and Oral Pathology ,* 55(6), pp. 545-552.
65. Sidebottom, A. & Gruber, E., 2013. One-Year Prospective Outcome Analysis and Complications Following Total Replacement of The Temporomandibular Joint with The TMJ Concepts System. *Journal of Maxillofacial and Oral Surgery*, 51(7), pp. 620- 624.

66. Sidebottom, A., 2013. Alloplastic or Autogenous Reconstruction of The TMJ. *Journal of Oral Biology and Craniofacial Research,* 3(3), pp. 135-139.
67. Smith, J., Sandler, N., Ozaki, W. & Braun, T., 1999. Subjective And Objective Assessment of The Temporalis Myofascial Flap in Previously Operated Temporomandibular Joint. *Journal of Oral and Maxillofacial Surgery ,* 57(9), pp. 1058-1065.
68. Stucki-McCormick, S., 1997. Reconstruction of The Mandibular Condyle Using Transport Distraction Osteogenesis.. *The Journal of Craniofacial Surgery ,* 8(1), pp. 48-52.
69. Su-Gwan, K., 2001. Treatment of Temporomandibular Joint Ankylosis With Temporalis Muscle And Fascia Flap. *International Journal of Oral and Maxillofacial Surgery ,* 30(3), pp. 189-193.
70. Tang, W. et al., 2009. Condyle Replacement After Tumor Resection: Comparison of Individual Prefabricatd Titanium Implants And Costochondral Grafts. *Oral Surgery, Oral Medicine, Oral Pathology, Oral Radiology, and Endodontics,* 108(2), pp. 147-152.
71. Topazian, R., 1966. Comparison of GAP and Interpositional Arthroplasty in The Treatment of Temporomandibular Joint Ankylosis. *Journal of Oral Surgery ,* 24(5), pp. 405-409.
72. Toyama, M., Kurita, K., Koga, K. & Ogl, N., 2003. Ankylosis of The Temporomandibular Joint Developing Shortly After Multiple Facial Fractures. *International Journal of Oral and Maxillofacial Surgery ,* 32(4), pp. 360-362.
73. Tripathy, S., Yaseen, M., Singh, N. & Bariar, L., 2009. Interposition Arthroplasty in Post-Traumatic Temporomandibular Joint Ankylosis: A Retrospective Study. *Indial Journal of Plastic Surgery ,* 42(2), pp. 182-187.
74. Vasconcelos, B., 2009. Surgical Treatment of Temporomandibular Joint Ankylosis: Follow-Up of 15 Cases And Literature Review. *Medicina Oral, Patologia Oral y Cirugia Bucal,* 14(1), pp. 34-38.
75. Vasconcelos, B., Porto, G., Bessa-Nogueira, R. & Nascimento, M., 2009. Surgical Treatment of Temporomandibular Joint Ankylosis: Follow-Up of 15 Cases And Literature Review. *Medicina Oral, Patologia Oral y Cirugia Bucal,* 14(1), pp. 34-38.
76. Wang, H., Zhang, B. & Lou, H., 2016. Temporomandibular Joint Ankylosis Contributing to Coronoid Process Hyperplasia. *International*

Journal of Oral and Maxillofacial Surgery, 45(10), pp. 1229-1233.

77. Wang, R., Bingham, B., Hawke, M. & Kwok, P., 1991. Persistence of The Foramen of Huschke in The Adult: An Osteological Study. *The Journal of Otolaryngology,* 20(4), pp. 521-523.
78. Ware, H. & Brown, S., 1981. Growth Centre Transplantation to Replace Mandibular Condyles. *Journal of Maxillofacial Surgery,* 9(1), pp. 50-58.
79. Ware, W. & Taylor, R., 1966. Growth Centre Transplantation To Replace Damaged Mandibular Condyles. *Journal of The American Dental Association,* 73(1), pp. 128- 137.
80. Wen-Ching, E., Hnang, C. & Chen, Y., 1999. Temporomandibular Joint Reconstruction in Children Using Costochondral Graft. *Journal of Oral and Maxillofacial Surgery,* 57(7), pp. 789-798.
81. Westermark, A., 2012. Total Reconstruction of The Temporomandibular Joint. Up to 8 Years of Follow-Up of Patients Treated With Biomet Total Joint Prostheses. *International Journal of Oral and Maxillofacial Surgery ,* 39(10), pp. 951-955.

82. Wolford, L. et al., 2016. Temporomandibular Joint Ankylosis Can be Successfully Treated With TMJ Concepts Patient-Fitted Total Joint Prosthesis And Autogenous Fat Grafts. *Journal of Oral and Maxillofacial Surgery ,* 74(6), pp. 1215-1227.
83. Zhang, Y. & He, D., 2006. Clinical Investigation of Early Post-Traumatic Temporomandibular Joint Ankylosis And The Role of Repositioning Dscs in Treatment. *International Journal of Oral and Maxillofacial Surgery,* 35(12), pp. 1096- 1101.

Appendices

Appendix A: Ethics Certificate

M230130 MED22-02-190

UNIVERSITY OF THE WITWATERSRAND, JOHANNESBURG

R14/49 Dr Rofhiwa Rudzani Lalumbe

HUMAN RESEARCH ETHICS COMMITTEE (MEDICAL)

CLEARANCE CERTIFICATE NO. M230130 MED22-02-190

NAME: (Principal Investigator)	Dr Rofhiwa Rudzani Lalumbe
DEPARTMENT:	Maxillofacial and Oral Surgery Charlotte Maxeke Johannesburg Academic Hospital Chris Hani Baragwanath Academic Hospital
PROJECT TITLE:	A 20 year audit from 2000 to 2020 of the management and treatment outcomes of temporomandibular joint ankylosis among a cohort of patients at Wits Oral Health Center
DATE CONSIDERED:	27/01/2023
DECISION:	Approved unconditionally
CONDITIONS:	
SUPERVISOR:	Prof Risimati Rikhotso
APPROVED BY:	Dr C Penny, Chairperson, HREC (Medical)
DATE OF APPROVAL:	12/07/2023 **EXPIRY DATE:** 12/07/2028

This clearance certificate is valid for 5 years from date of approval. Extension may be applied for.

DECLARATION OF INVESTIGATORS

I/we fully understand the conditions under which I am/we are authorized to carry out the above-mentioned research and I/we undertake to ensure compliance with these conditions. Should any departure be contemplated, from the research protocol as approved, I/we undertake to resubmit the application to the Committee. **I agree to submit a yearly progress report** in January each year until study is closed. Failure to submit annual report will result in ethics clearance certificate suspension. The date for annual re-certification will be one year after the date of convened meeting where the study was initially reviewed. In this case, the study was initially reviewed in January and will therefore be due in the month of February each year. Unreported changes to the application may invalidate the clearance given by the HREC (Medical). Email signed copy of this ethics clearance certificate prior to commencing with the study hrec-medical.researchoffice@wits.ac.za

Principal Investigator Signature

Date 12/07/23.

PLEASE QUOTE THE PROTOCOL NUMBER IN ALL ENQUIRIES

Powered by CamScanner

Appendix B: Data Collection Form

Data Collection Form

Allocated Study Identification Code:	
Gender	
Age	
Medical History	
Diagnosis	
Cause of Ankylosis	
Type of Treatment	
Pre-operative interdental/interalveolar mouth opening (mm)	
post-operative interdental/interalveolar mouth opening (mm)	
Post-operative occlusion	
Follow-up Period	
Post-operative Complications	
Treatment of complications	
Current mouth opening (mm)	

Appendix C: Permission Letters

AHOS/ACEO WITS Oral Health Center
University of Witwatersrand
Parktown
2196

Dear Sir/Madam

RE: Request to conduct research in oral health sciences.

I Dr Lalumbe Rofhiwa Rudzani, am currently enrolled for Masters of Dentistry in Maxillo-Facial and Oral Surgery at University of Witwatersrand. The research is in partial fulfilment towards this degree. I would like to conduct a study, which involves access to data from patients records presented at oral health center. The study is titled: A 20 year audit from 2000 to 2020 of the management and treatment outcomes of temporomandibular joint ankylosis among a cohort of patients at Wits Oral Health Center. I would like to retrieve data from the records of patients that presented with temporomandibular joint ankylosis at the Maxillo-Facial and Oral Surgery department at Charlotte Maxeke Johannesburg Academic Hospital and Chris Hani Baragwanath Academic Hospital from January 2000 to December 2020.

The study will be supervised by Prof R.E Rikhotso, 011 717 2130, (Risimati.Rikhotso@wits.ac.za).

Thanking you in advance.

.....
DR R.R Lalumbe
Lalumberofhiwa@gmail.com
0615423238

.....20 April 2023.
Supported by: Dr Molokomme

.....
AHOS: Prof Shackleton
Recommended/ Not recommended

.....
ACEO: Dr Thekiso
Approved/ Not approved

Appendix C: Turnitin Report

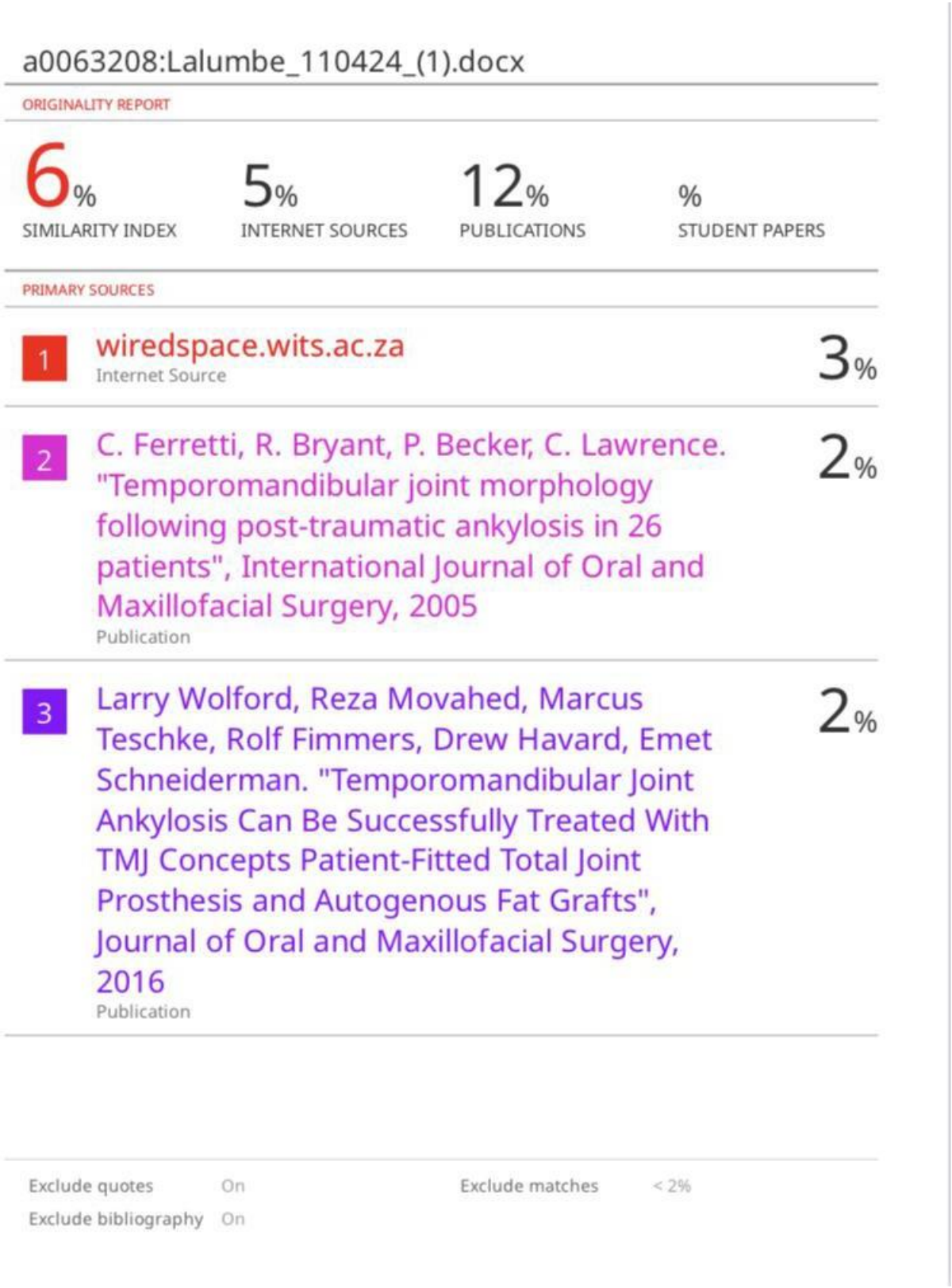

a0063208:Lalumbe_110424_(1).docx

ORIGINALITY REPORT

6%	5%	12%	%
SIMILARITY INDEX	INTERNET SOURCES	PUBLICATIONS	STUDENT PAPERS

PRIMARY SOURCES

1	wiredspace.wits.ac.za Internet Source	3%
2	C. Ferretti, R. Bryant, P. Becker, C. Lawrence. "Temporomandibular joint morphology following post-traumatic ankylosis in 26 patients", International Journal of Oral and Maxillofacial Surgery, 2005 Publication	2%
3	Larry Wolford, Reza Movahed, Marcus Teschke, Rolf Fimmers, Drew Havard, Emet Schneiderman. "Temporomandibular Joint Ankylosis Can Be Successfully Treated With TMJ Concepts Patient-Fitted Total Joint Prosthesis and Autogenous Fat Grafts", Journal of Oral and Maxillofacial Surgery, 2016 Publication	2%

Exclude quotes	On	Exclude matches	< 2%
Exclude bibliography	On		