

https://dspace.org/

A clinico-pathological study of HIV-associated cystic lymphoid hyperplasia

Dulabh, Shailen

2011-11-23
http://hdl.handle.net/10539/10830

Downloaded from a DSpace repository. https://dspace.org/

A CLINICO-PATHOLOGICAL STUDY OF HIV-ASSOCIATED CYSTIC LYMPHOID HYPERPLASIA

Shailen Dulabh

A research report submitted to the Faculty of Health Sciences, University of the Witwatersrand, Johannesburg, in partial fulfilment of the requirements for the degree of

Master of Science in Dentistry

Johannesburg, 2011

DECLARATION

I, Shailen Dulabh declare that this research report is my own work. It is being submitted for the degree of Master of Science in Dentistry at the University of the Witwatersrand, Johannesburg. It has not been submitted before for any degree or examination at this or any other University.

_____

Signature of candidate

11th day of May 2011

DEDICATION

I dedicate this work to my parents,

Dhirubhai and Kamelaben Dulabh,

for all their love and support in the realisation of my degree

"Destiny is not a matter of chance; it is a matter of choice. It is not something to be waited for; but rather, something to be achieved."

-William Jennings Bryan-

ABSTRACT

Introduction: Cystic lymphoid hyperplasia (CLH) is a common yet under recognised entity affecting the parotid gland in HIV infected patients. This is the largest global clinicopathological study of CLH to date consisting of 167 cases (85M, 82F).

Aim: To define the clinical parameters, histology and immunopathological features of CLH with a view to elucidating the aetio-pathogenesis.

Material and Methods: This retrospective study on archival cases of CLH included patientôs age, race, gender, nature of CLH, HIV status, CD4 counts and viral loads where available. Of the 167 confirmed cases of CLH, 109 cases were histologically reviewed and 25 cases were immunohistochemically analysed with CD3, CD20, CD4, CD8 and p24 using standard procedures. Ethics clearance (M080927 and M080850) was obtained.

Results: CLH mainly affects the parotid gland with a male predominance. Submandibular gland ($p = 0.27$) and bilateral parotid involvement favours females (2:1). CLH affects females at a younger mean age in both the parotid and submandibular glands (36.5, 31 years) respectively compared to males (40.9, 42.4 years) ($p = 0.0032$). Intra-lymph nodal origin is favoured with 76.1% of cases occurring within entrapped salivary gland remnants. P24 staining reveals ~90% specificity in HIV associated CLH. Immunostaining showed a CD8:CD4 of ~1:1 except in selected cases where CD4 was decreased in the interfollicular areas.

Conclusion: CLH is the preferred term to describe bilateral parotid enlargement in HIV infected patients. This study strongly supports origin of CLH following ductal ectasia of entrapped salivary gland inclusions within atypical lymphoid hyperplasia arising within lymph nodes in the context of an HIV setting. CLH should be classified as an orofacial lesion strongly associated with HIV and AIDS.

ACKNOWLEDGEMENTS

This study was facilitated through the support of my supervisors, family and colleagues. I would like to thank the Department of Oral Pathology at the University of the Witwatersrand for the time and assistance offered to me as well the Faculty Research Committee of the University for awarding me the Faculty Research Committee Individual Grant for this study.

I would like to express my gratitude to Dr. Shabnum Meer for her professionalism, patience and approach toward this study. I am immensely grateful to her for the time she has spent as my mentor, as well as her academic insight and advice in the culmination of this project.

I am also grateful to Professor Mario Altini for his permission, as well as his academic advice and assistance throughout the course of my study.

I am also grateful to other individuals who played a significant role in the course of my research: to Dr. Olga Motloung for her permission to continue my studies and for the time offered to me to complete the research as well as Mr. Eustasius Musenge for his assistance with the statistical analysis.

Finally I would like to express my sincere appreciation to my family for their unconditional support, prayers and emotional strength offered to me throughout the various stages of my studies.

TABLE OF CONTENTS

Page

DECLARATION..... ii

DEDICATION..... iii

ABSTRACT..... iv

ACKNOWLEDGEMENTS..... v

TABLE OF CONTENTS..... vi

LIST OF FIGURES..... viii

LIST OF TABLES..... xi

1.0 INTRODUCTION..... 1

2.0 LITERATURE REVIEW..... 5

2.1. Clinicopathological features of Cystic Lymphoid Hyperplasia (CLH)..... 11

2.2. Radiographic features of CLH..... 14

2.3. Macroscopic features of CLH..... 15

2.4. Microscopic features of CLH..... 15

2.5. Neoplastic associations..... 19

2.6. The role of Immunohistochemistry (IHC)..... 20

2.7. Pathogenesis..... 22

2.8. The role of fine needle aspiration cytology (FNAC)..... 26

2.9. The Diffuse Infiltrative Lymphocytosis Syndrome (DILS)..... 26

2.10. Treatment and management of CLH..... 28

3.0 AIMS..... 31

4.0 MATERIALS AND METHODS..... 32

4.1. Study Sample..... 32

4.2. Ethics..... 33

4.3. Histology..... 33
4.4. Immunohistochemistry..... 34
4.5. Statistical Analysis..... 36

5.0 RESULTS..... 38

5.1. Demographics..... 38
5.2. Clinical findings..... 40
5.3. Macroscopic findings..... 46
5.3.1. Microscopic findings..... 46
5.4.1. Histological categorisation of CLH..... 47
5.4.2. Cyst locularity..... 52
5.4.3. Epithelial lining..... 52
5.4.4. Cyst contents..... 53
5.4.5. Changes within the lymph node..... 53
5.4.6. Changes within the glandular parenchyma..... 54
5.4.7. Epimyoepithelial islands (EMIôs)..... 55
5.4.8. Human Immunodeficiency Virus (HIV) ï associated changes..... 56
5.4.9. Co-existing infections and other multinucleated giant cells (MNGCôs)..... 59
5.5. Immunohistochemical findings..... 61
5.5.1. CD20 and CD3..... 61
5.5.2. CD8 and CD4..... 66
5.5.3. p24..... 67
5.6. Study limitations..... 67

6.0 DISCUSSION..... 68

7.0 CONCLUSION..... 80

8.0 APPENDICES..... 82

8.1. Appendix 1: Raw data..... 83
8.2. Appendix 2: Ethics clearance certificate..... 92
8.3. Appendix 3: Histology and immunohistochemistry data collection sheet..... 93

9.0 REFERENCES..... 103

LIST OF FIGURES

Figure Page

5.1.1 CLH: Age categorisation according to gender and presenting decade..... 39

5.1.2 CLH: Mean age of presentation distributed by gender..... 39

5.2.1 Site distribution of CLH within the affected salivary glands and adjacent sites 41

5.2.2A. Distribution of unilateral and bilateral enlargement of the parotid glands..... 42

5.2.2B. Distribution of unilateral and bilateral enlargement of the submandibular gland 42

5.2.3 CLH: Gender distribution according to age and site..... 43

5.2.4A-C. Bilateral parotid gland enlargement in HIV infected patients with CLH, ranging from subtle enlargement (A) to gross facial swelling (B/C)..... 44

5.2.5 CT scans coronal (A) and axial (B) views showing multiple, oval, variably sized radiolucencies present bilaterally within abnormally dense parotid glands..... 45

5.3.1A, B Intraparotid lymph node showing multiple cysts with surrounding proliferative lymphoid tissue (H&E, original magnification X4..... 50

5.3.2 CLH primarily involving parotid gland parenchyma with ductal ectasia, acinar atrophy and prominent atypical lymphoid hyperplasia consistent with HIV induced lymphoid change (H&E, original magnification X10)..... 51

5.3.3 Entrapped salivary gland remnants (thin arrow) within the hyperplastic lymphoid tissue surrounding the cystic space, which is lined by pseudostratified ciliated respiratory-type epithelium (thick arrow) (H&E, original magnification X20)..... 51

5.4.1. Prominent lymphoid proliferation abutting the squamous cyst lining in CLH primarily affecting an intra-parotid lymph node. Prominent tingible body macrophages are evident (H&E, original magnification X40)... 57

5.4.2. Salivary duct remnants within lymph node parenchyma (H&E, original magnification X40)..... 57

5.4.3. Epimyoepithelial islands (arrowed) and salivary duct elements within the lymphoid hyperplasia in a lymph node demonstrating CLH (H&E, original magnification X10)..... 58

5.4.4. CLH shows squamous epithelium cyst lining permeated by lymphocytes with a subepithelial condensation of the lymphoid proliferation (H&E, original magnification X20)..... 58

5.4.5A, B Necrotising granulomatous inflammation showing a Langhans type MNGC consistent with *MTB* co-infection occurring simultaneously with CLH. [H&E, original magnification A (X4); B (X40)]..... 60

5.5.1 Strong reactive immunoexpression of CD20+ B-cells within the germinal centres with lymphocyte permeation through the squamous cyst lining (L26, original magnification X4)..... 63

5.5.2 CD3 immunopositivity was noted primarily within the interfollicular areas with minimal permeation of the epithelium by CD3+Tcells (Polyclonal, original magnification X4)..... 63

5.5.3 CD8 immunostaining mimicked that of CD3 immunoreactivity with a strong CD8+ presence in the interfollicular areas (1A5original magnification X4)..... 64

5.5.4 CD4 immunoreactivity was not as prominent and intense as the CD8+ immunopositivity within the lymphoid hyperplasia (4B12, original magnification X10) 64

5.5.5 p24 Immunopositivity within the follicular dendritic cells in the germinal centres of a lymph node affected by CLH (Kal-1, original magnification X40). 65

LIST OF TABLES

Table Page

2.1. Various terminologies used to describe cystic lymphoid hyperplasia of the parotid gland..... 7

4.4.1. List of immunohistochemical markers used in the study..... 35

5.1. Clinico-pathological features of patients affected with cystic lymphoid hyperplasia 40

5.2 Histological distribution and categorisation of CLH..... 49

CHAPTER 1

1.0 INTRODUCTION

Manifestations of the human immunodeficiency virus (HIV) infection are often evident in the head and neck region, frequently as the initial clinical feature and generally involving cervical lymph nodes and oral mucosa rather than the salivary glands. Patients infected with HIV frequently develop salivary gland enlargement during disease progression. This is due to various aetiologies including reactive/inflammatory conditions, infections and neoplasia.[1-3] In some patients, salivary gland enlargement is the first clinical manifestation of underlying HIV infection. Early recognition of this underlying pathology is necessary to ensure appropriate treatment.

HIV associated salivary gland disease is defined as the presence of xerostomia with or without accompanying swelling of the major salivary glands and invariably as a result of proliferation of lymphoid tissue.[4] While this enlargement has a predilection for the parotid gland,[5-9] some studies have shown submandibular gland involvement.[10-12] The literature is limited with regard to the extent of parotid gland involvement in the Acquired Immunodeficiency Syndrome (AIDS), especially in the advanced stage when systemic infections and disseminated neoplastic conditions are frequent.[3]

Histologically, various patterns are seen which range from an atypical lymphoid hyperplasia to explosive follicular hyperplasia commonly associated with progressive generalised lymphadenopathy (PGL), a condition highly suggestive of underlying HIV infection, as well as multicystic lymphoepithelial cysts and low grade marginal zone

lymphomas.[1,3,13] In the initial phase of the disease, inflammatory conditions usually attributable to HIV itself predominate.[13] Lymphoepithelial cysts are the most common lesions during this period[3,6] affecting 3-6% of HIV patients and causing parotid enlargement.[14] Whilst the histology of PGL is well described the proliferation of ductal epithelium that gives rise to cysts and epithelial islands within salivary glands and their associated lymph nodes is less well appreciated. These findings are regarded as a manifestation of HIV infection.[5,15,30]

Lymphoepithelial cysts are a distinct clinicopathological entity characterised by single or multiple cysts lined by epithelial and lymphoid cells and most frequently arising in the parotid glands of HIV infected patients.[3,5-8] This entity has been variably designated by a plethora of terms such as Sjögren-like syndrome,[16] benign lymphoepithelial lesion (BLEL),[1,8,17] cystic lymphoepithelial lesion,[11] HIV salivary gland disease[18] and lymphoepithelial cysts.[9,19] Most of these terms have emphasised that this lesion shares some typical features with Sjögrenôs syndrome (SS) such as xerostomia and salivary gland lymphoid infiltration with glandular atrophy.[16,20] Aguirre *et al*.[4] have alluded to the many differing designations used for cystic lymphoid hyperplasia, many of which seem misleading and confusing. In this study, we have used the term ***cystic lymphoid hyperplasia*** (CLH) to describe the benign lymphoepithelial cystic lesions occurring in the salivary glands of HIV positive individuals, a term first used by Vaillant *et al*.[21] in 1989. Seifert *et al*.[22] initially suggested in the 1992 World Health Organisation (WHO) classification of ótumour-likeô lesions of the salivary glands that CLH be included as a special form of ñlymphoepithelial cystò of the parotid gland. Furthermore, a variety of similar diseases in HIV share almost identical clinical and histological features. CLH

also shows great overlap with non-HIV associated cystic benign lymphoepithelial salivary gland lesions.[9]

The pathogenesis of the lymphoepithelial cysts remains unclear. Some investigators support the hypothesis of direct viral damage, whereas others consider the salivary lesion to be a consequence of concomitant lymphadenopathy or an autoimmune disease.[16,20] In the 1992 revised WHO classification of salivary gland tumours, lesions that morphologically resembled lymphoepithelial cysts reported in HIV negative patients were considered as a separate entity from HIV associated lymphoepithelial cyst.[22]

Sub-Saharan Africa is the epicentre of the HIV and AIDS pandemic with the highest recorded global prevalence rate, yet a large scale series of parotid gland enlargement in HIV infected patients is lacking in Africa.[25] Colebunders *et al*.[26] were the first to report this entity in 9 HIV positive adults in Zaire as early as 1988. Others have reported on the various treatment modalities used in a resource poor environment, with many patients lost to follow up.[27-29] Interestingly, with the advent of antiretroviral therapy, an increased incidence of parotid gland enlargement and other previously less common manifestations have been reported in AIDS patients with the immune reconstitution inflammatory syndrome (IRIS).[29,31]

CLH is an important and early manifestation of HIV infection and the AIDS related complex (ARC).[4] We have seen an increasing incidence of these parotid cysts in our department, which are readily visible and accessible to biopsy.[15,30] This

clinicopathological analysis of the largest known global series of CLH would certainly aid in defining this entity, expounding its recognition, aetio-pathogenesis and possible treatment and long term management strategies.

CHAPTER 2

2.0 LITERATURE REVIEW

According to the WHO there were 33.4 million people with AIDS globally as at the end of 2008.[25] Sub-Saharan Africa, is by far the worst affected in the world with an estimated 1.9 million new infections recorded in 2008 bringing the total number of people living with HIV and AIDS in the region to 22 million. Average survival in the absence of treatment is around 10 years after infection.[25] Antiretroviral (ARV) medication which may dramatically extend survival remains unavailable to most Africans.[25,29] Until 1998 South Africa had one of the fastest expanding epidemics in the world, but the HIV prevalence now seems to have stabilised and may even be declining slightly.[25]

Patients infected with HIV often develop enlargement of the major salivary glands during disease progression with or without xerostomia.[4] These enlargements, frequently cystic, represent a localised manifestation of AIDS or the AIDS related complex and may precede by months or even years, the more publicised general signs such as opportunistic infections, neoplasms and generalised lymphadenopathy, often being the initial manifestation of HIV.[12,24,30] The swellings, which mainly occur within the parotid gland, are frequently cystic, fluctuant, asymptomatic and causing considerable facial deformity.

A variety of neoplastic, both benign and malignant, as well as non-neoplastic lesions of the salivary glands may present with a predominantly cystic architecture. CLH of AIDS

is categorised as a non-neoplastic salivary gland lesion together with other tumour-like lesions of the salivary glands such as necrotising sialometaplasia, benign lymphoepithelial lesions and salivary gland cysts.[22,35,36] It presents as unicystic or multicystic, often bilateral salivary gland enlargement that occurs in patients with HIV infection or AIDS.[4] The enlargement is usually painless and often occurs with accompanying bilateral cervical lymphadenopathy or in the context of PGL.[36] The term ó*cystic lymphoid hyperplasia'* was first used in the French literature by Vaillant *et al*.[21] in 1989 to describe the parotid gland enlargement seen in 2 AIDS patients. However, Ryan *et al*.[32] recognised this entity earlier as a peculiar pattern of a peripheral lymphadenopathy developing within salivary gland lymph nodes which they suspected to be AIDS related. Others also allude to usage of the term CLH.[4,36]

According to the EC-Clearinghouse and WHO classification and diagnostic criteria for oral lesions in HIV infection, CLH was recognised as a special form of lymphoepithelial cyst classified as a manifestation less commonly associated with HIV infection (Group 2).[22,37] Due to the varied expression patterns in children and recognising that the corresponding criteria in the paediatric population are not as well defined, the Collaborative Workgroup on the Oral Manifestations of Paediatric HIV infection placed paediatric parotid gland enlargement into the group ñOro-facial lesions commonly associated with paediatric HIV infectionò.[38]

With the increase in the HIV epidemic during the late 1980ôs and early 1990ôs several researchers simultaneously reported a surge in this new entity affecting the parotid glands in homosexuals and intravenous drug abusers[16,34,39] Most descriptions of the

salivary gland enlargement were based on pathologic tissue changes seen microscopically. This invariably led to the introduction of several different terms which in essence described the same entity as highlighted in Table 2.1.

Table 2.1. Various terminologies used to describe cystic lymphoid hyperplasia of the parotid gland

Designation	Author	Year
Salivary gland lymphadenopathy associated with AIDS	Ryan *et al.*[32]	1985
Parotid swelling during HIV infection	Colebunders *et al.*[26]	1988
Benign lymphoepithelial lesions of the parotid gland	Smith *et al.*[23]	1988
Cystic lymphoid hyperplasia of the parotid gland	Vaillant *et al.*[21]	1989
HIV-associated salivary gland disease	Schiødt *et al.*[18]	1992
Cystic lymphoepithelial lesions of the salivary gland	Labouyrie *et al.*[11]	1993
HIV-related parotid lymphoepithelial cysts	Ihrler *et al.*[5]	1996
Benign lymphoepithelial cyst	Dave *et al.*[14]	2007
HIV-associated benign lymphoepithelial cyst-like lesions	Gupta *et al.*[42]	2009

The differential diagnosis of reactive lympho-proliferative-induced salivary gland enlargement in HIV positive patients includes PGL, HIV associated benign lymphoepithelial lesion (BLEL), diffuse infiltrative lymphocytosis syndrome (DILS), HIV associated benign lymphoepithelial cyst (BLEC) also known as CLH, with CLH being by far the most common. A clarification of terminology is important because these and other terms such as cystic lymphoepithelial lesion,[11] intraparotid cyst,[34] Sicca-

complex,[20] Sjögrenôs-like syndrome,[16] benign lymphoepithelial lesion (BLEL),[33,43] myoepithelial sialadenitis (MESA)[36] and HIV associated salivary gland disease (HIV-SGD)[18] have been used interchangeably causing considerable confusion.

HIV associated persistent generalised lymphadenopathy (PGL)

This refers to the extensive lymph node enlargement that occurs throughout the body in HIV infected individuals and is usually defined as the presence of lymphadenopathy in 2 or more extra-inguinal sites. The reactive follicular hyperplasia seen histologically in the lymph nodes of patients with PGL is identical to the histological changes within the intraparotid lymph nodes of HIV infected patients with parotid gland enlargement.[15,32]

Lymphoepithelial sialadenitis (LESA) and Sjögren's syndrome (SS)

Use of the terms Mikulicz disease, lymphoepithelial sialadenitis (LESA) and myoepithelial sialadenitis (MESA) have been largely discontinued. Instead the term lymphoepithelial lesion (LEL) is now preferred to describe a lymphoid infiltrate with follicular hyperplasia surrounding the salivary ducts with disorganisation and proliferation of the ductal epithelial cells to form epimyoepithelial islets or lesions.[36] Infiltration of lymphocytes into the epithelium is characteristic in cystic lymphoepithelial lesions. Chronic sialadenitis with an autoimmune basis has recently been incorporated in the spectrum of disease which is known as IgG4 sclerosing disease.[35]

Diffuse infiltrative lymphocytosis syndrome (DILS)

DILS is a subset of HIV disease manifestation characterised by a persistent circulating CD8+ lymphocytosis accompanied by diffuse visceral CD8+ lymphocytic infiltration, bilateral parotid gland swelling and cervical lymphadenopathy. The lungs and salivary glands are most commonly involved.[13,27]

HIV associated benign lymphoepithelial lesion (BLEL, BLL)

This occurs as a result of lymphocytic infiltration into the parotid gland and was originally regarded as a limited manifestation of SS.[16,20] However cases have been reported in HIV infected individuals and therefore the term HIV associated BLEL is recommended in this context.[14,33] Some cases of BLEL may progress from being a polyclonal response to a monoclonal response, with the latter marking progression to mucosa-associated lymphoid tissue (MALT) lymphoma and therefore the term BLEL without qualification is thus best avoided.[36,44]

HIV associated benign lymphoepithelial cyst (BLEC)

These parotid lesions contain epithelium lined cysts which can be unilocular or multilocular with the cystic spaces encased by dense lymphoid tissue.[45] The distinction between BLEL and BLEC is often discussed in the literature. Due to the histological similarities, it was initially believed that the LEC was merely a progression of the LEL that affected the salivary glands of patients diagnosed with SS.[16] Most BLELs present as solid masses but cystic BLEL has been described usually in the setting of SS.[19,45,33] Due to the presence of the distinct epithelial lining which encapsulates the cavity, BLEC has also been referred to as a ócystic-lymphoepithelial lesionô indicating a

continued disease process.[11] Several early reports have referred to these lesions as a BLEC, a term which appears to be the most commonly used as a result of the intense lymphoid proliferation seen histologically within the walls of the cystic structures.[1,12]

The original term ólymphoepithelial cystô was first coined by Bernier *et al*.[46] in 1958 to distinguish them from cysts that are derived from embryological (branchial arch) remnants. These authors postulated that BLECs resulted from the cystic degeneration of salivary gland inclusions within parotid lymph nodes. These lesions were rarely seen before the early 1980ôs, however their frequency increased thereafter and it became apparent that the characteristic cystic parotid lesions (LECs) had a predilection for HIV positive patients. Ryan *et al*.[32] were the first to recognise the consistent association between HIV and the BLEC. It was increasingly suggested that patients with these cysts and accompanying cervical lymphadenopathy be considered as AIDS patients until proven otherwise.[47,48] This entity has also been referred to as CLH.[4,21,22]

CLH is of clinical significance as it causes facial disfigurement and cosmetic distress to many patients. Furthermore, it is the source of social stigma as it is increasingly being recognised in the community as a sign of underlying HIV infection.[29] Patients are therefore increasingly seeking treatment to correct the facial swelling. More importantly is that there is a risk of malignant transformation reported in CLH,[64,65] an event which can be avoided with early recognition, prevention and successful treatment of CLH.

2.1. *Clinicopathological features of CLH*

Bilateral and multiple LECs of the major salivary glands and in particular of the parotid gland have been reported in 3-6% in HIV positive patients.[14,49] Although more common in HIV positive adults, an increasing number of HIV positive children are also presenting with lymphoid infiltrates in the parotid gland.[8,14] The cysts are fluctuant, painless, slow growing, generally about 2 to 5 cm in diameter and located over the mandibular angle or slightly posterior, where the tail of the parotid gland is located.[50] There is an overwhelming predilection for CLH to occur in the parotid gland with only a few case reports reporting submandibular gland involvement [10,11,33] Bilateral involvement of the parotid glands[24,27,51] is more common than unilateral occurrence, the latter showing an equal involvement of either side.[6,9] Most cases occur in Caucasian and black males,[16,24,40] however isolated cases are reported in females.[11,14] However racial variation is dependent on geographic location.

HIV infection is a major global health problem affecting both developing and developed countries and thus CLH represents an important head and neck manifestation of this disease as it impacts upon the quality of life of the patient. A global perspective of CLH shows considerable regional variation depending on the populations studied. Most cases have been reported in Africa and Latin America,[3,29,53] followed by North America and Europe [6,17,52] with isolated case reports arising from India and South East Asia.[42,54] The largest reported studies to date from Germany and Brazil comprise a combination of surgical parotid and autopsy specimens in 100 confirmed HIV positive or AIDS patients.[3,5] Histological alterations in the parotid gland consistent with underlying HIV infection were noted only in about 50% of these cases.[5] Recently, Wu *et al*.[54]

histopathologically analysed 64 cases, the largest known collection of parotid LECs in a seemingly HIV unaffected population.

Initial studies of CLH in the 1980ǿs comprised mainly isolated case reports and showed that these lesions occurred with an increased frequency amongst patients exhibiting high risk factors for transmission of HIV, i.e. intravenous drug abusers, homosexual males and prison inmates.[32,34] Isolated cases of CLH arising in HIV infected patients with possible transmission via blood transfusions and direct exposure to contaminated blood, secretions or saliva through open wounds have also been reported.[16,33]

A distinct male predominance in HIV positive adults was reported in the 1990ǿs.[17,33,43] CLH has been reported in homosexual or bisexual males and even heterosexual individuals displaying promiscuous tendencies.[4,7,52] An increase in the prevalence of CLH in the paediatric population has been noted with case reports involving children revealing a vertical mode of HIV transmission.[8,14,53]

The age and gender of patients with CLH is of particular interest and has been studied in order to quantify these variables as possible risk factors for its development in an HIV setting. Whilst the age ranges show extreme variability, HIV unrelated BLECs tend to occur at a later age of onset (5th and 6th decades)[33,45] as compared to HIV associated CLH where the patients are younger (3rd and 4th decades) and predominantly male.[9,10] The male predominance has been verified in several other reports[10,17,34] while Chetty[8] reported an earlier age of incidence in females (23-31 years) when compared to males (18-58 years). In their study of 60 patients, Terry *et al.*[33] showed an increased

male predominance (84.2%) of CLH in HIV infected individuals in contrast to the female predominance (77.3%) in non-HIV infected individuals with BLECs, findings substantiated by Wu *et al*.[54]

Gender predominance in children shows extreme variability. Chetty[8] reported 7 out of 9 paediatric patients to be male (77.8%) with ages ranging from 1 to 4 years, whereas Dave *et al*.[14] showed all 4 of their paediatric CLH cases to be female (100%). Wu *et al.*[54] noted that even though the ratio of males:females was insignificant(1:1.3) in their study of parotid BLECs in HIV negative patients, the average duration of the mass was clearly longer (29.3 years) when compared to the average cyst duration of 4 months in HIV infected patients noted by Shaha *et al*.[43]

Within the context of an HIV setting interest has also been raised as to whether the salivary gland enlargement presents as an early indicator of underlying HIV infection or as a late stage manifestation of the AIDS related complex. Sperling *et al*.[41] showed a tendency for this entity to occur in the early stages of an HIV infection when CD 4+ T-lymphocyte counts were high. In contrast, later studies show a higher incidence occurring with depleting CD4+ counts.[13,17,18] Clinicians generally believe that CLH occurs in the presence of altered immunity with diminished CD4+ T-cell counts and a corresponding elevation in CD8+ T-cell counts. Schiødt *et al*.[18] showed CD4:CD8 counts of 280:1138 and 225:900 cells per mm^3 at initial and follow-up examinations respectively, a ratio of roughly 1:4. Earlier studies had already hinted at a higher prevalence with depleted CD 4+ T-cell counts along with inverted CD4:CD8 T-lymphocyte ratios.[12,33] Whether the parotid enlargement represents an early

manifestation of an HIV infection or a prodrome to AIDS, occurring with later widespread dissemination and depleted CD 4 + T-cell counts is unclear.

2.2. Radiographic features of CLH

CLH typically presents as a single or multiple cystic radiolucency visible on computed tomography (CT) scans.[47,48] The LECs of these parotid tail lesions are usually multiple, well-circumscribed and without invasion or infiltration, which differentiates them from malignant processes.[47,50] As the clinician can detect the presence of the parotid masses but is often unable to assess their cystic nature, the role of CT scans and magnetic resonance imaging (MRI) becomes important.[47,48] CT scans are also useful for detecting early asymptomatic lesions which have not yet caused facial deformity. Dormant contra-lateral lesions are often discovered on CT scan investigations in patients seeking treatment for unilateral parotid gland enlargement.[47,48,51]

MRI scans provide important information regarding *location* (intraglandular versus extraglandular), *nature* (solid versus cystic) and *extent* of the lesion (involvement of the deep lobes and relationship of adjacent structures).[2] Mandel *et al*.[51] support the use of ultrasound which defines large, hypoechoic areas with septa to be characteristic of HIV associated LECs, however other studies deem these findings non-specific for the diagnosis of CLH, especially in cases of isolated mixed, solid and cystic nodules.[56] In children, the use of ultrasound is preferred as it is simple to perform, painless, less invasive and avoids unnecessary exposure to radiation.[51] Furthermore, it is inexpensive, easily gains patient acceptance and offers an instantaneous tissue display.

Both the cystic and lympho-proliferative nature of HIV parotid disease and the accessibility of the parotid gland lend themselves to ultrasound imaging.[15,51]

2.3. Macroscopic features of CLH

Gross inspection of the lesions after surgical removal shows moderate to well encapsulated nodules ranging from 0.5 to 5 cm and varying in consistency from soft to firm.[39] There are usually multiple cystic cavities which contain a watery, yellow-brown liquid which becomes gelatinous after fixation.[34,39] Shiny cholesterol crystals have also been noted within the fluid.[34] The inner lining of the cyst walls are shiny and grey with small nodules covered by the smooth membrane.[10]

2.4. Microscopic features of CLH

The characteristic histological picture of CLH is that of single or multiple cysts located in the gland parenchyma or within the intra-salivary lymph nodes.[9,10] The cyst lumen contains pale, homogenous, eosinophillic material with small numbers of foamy macrophages and lymphocytes.[34] The cyst lining is variable ranging from stratified squamous to cuboidal, columnar and pseudostratified respiratory-type epithelium, with areas denuded of epithelium.[8,10,39] Metaplastic squamous epithelial variants have also been reported.[1,11] The cysts are surrounded by a reactive lymphoid proliferation with prominent germinal centres. The lymphoid proliferation may involve infiltration of the ductal epithelium by lymphocytes, giving rise to LELs.[3-8]

The lymphoid infiltrate is dominated by large reactive follicles with germinal centres, which may show follicle lysis, similar to the follicles seen in reactive lymph nodes in

HIV positive patients.[15,30] Large aggregates of macrophages may be seen between the lining epithelium and the germinal centres with a mixture of small lymphocytes, plasma cells and immunoblasts present in the interfollicular regions.[34,36] Multinucleated giant cells (MNGCs) may be present within the cyst lumen, below the epithelial lining, surrounding invaginations of the epithelial lining as well as amongst the lymphohistiocytic infiltrate[10,42,57] These MNGCs resemble foreign body type giant cells[42] and Orenstein *et al*.[58] described these giant cells to be morphologically similar to Langhans type MNGCs and distinct from Warthin-Finkeldey polykaryocytes. The significance of these giant cells is as yet unknown and their appearance in isolated case reports warrants further investigation.

CLH within the salivary gland parenchyma shows variable lymphoid proliferation around the intra- and inter-lobular ducts.[34] Ductal dilatation is thought to give rise to early epimyoepithelial island formation which is usually characteristic of BLEL seen in SS and this has led to some confusion due to the histological similarities between CLH and SS.[16,20] Whilst the presence of the epimyoepithelial islands along with auto-antibodies appears to confirm a diagnosis of SS, the lymphoid cell infiltrate seen in SS is dominated by CD4 cells whereas those seen in HIV disease are predominantly CD8 cells.[12] Furthermore, the cell of origin of the epimyoepithelial islands is believed to be different in SS and CLH. In SS epimyoepithelial islands result from the proliferation of the basal myoepithelial cell and ductal cells whereas in CLH the lining ductal epithelium is thought to proliferate to form the islands.[12,59,60] Myoepithelial cell involvement in the pathogenesis of CLH has also been excluded immunohistochemically.[5]

Cyst location within the gland has been crucial in the pathogenesis of CLH. Cysts have been noted to occur both within the parotid gland parenchyma, secondary to lymphatic infiltration of the salivary gland parenchyma, within intra- and peri-parotid lymph nodes as well as simultaneously within the gland parenchyma and intranodally.[5,9,10] This has led to considerable debate regarding the initiation and pathogenesis of CLH with no consensus as yet been reached. BLECs affecting the parotid glands in HIV negative individuals has further added to the confusion.[9,33,54]

Maiorano *et al*.[9] showed that a diffuse lymphoid infiltrate is invariably observed in the glandular tissue around LECs and that it is consistently associated with ectatic changes of the striated ducts, completely replacing acinar structures in some instances. In a comparison of LECs from HIV positive and negative patients they showed that the histological features in both groups are similar and that they may simultaneously affect the gland parenchyma and intra-salivary lymph nodes. Terry and co-workers[33] reported the cystic lesions in an HIV setting to be frequently bilateral, multiple and associated with lymphadenopathy when compared to those in HIV negative patients where the lesions were generally solitary and solid.

Ryan *et al*.[32] showed 2 histological patterns of AIDS related lymphadenopathy affecting the parotid glands, the *acute* pattern characterised by enlarged germinal centres with cell destruction and phagocytosis and a *chronic* pattern characterised by atrophic germinal centres and hypervascularity. Shaha *et al*.[43] identified 3 interchangeable histopathological conditions namely; follicular hyperplasia, BLEL and the BLECs. The

histological changes seen within these LECSs were identical to those encountered in the lymph nodes of AIDS patients with PGL.

The incidence of opportunistic infections in an HIV setting are directly related to the degree of immunosuppression and are therefore reliable indicators of disease progression.[3] Opportunistic infections associated with AIDS involving the parotid gland include a wide spectrum of bacterial, viral and fungal infections, the more common being mycobacterium infection (*MTB*), cytomegalovirosis, histoplasmosis and cryptococcosis, with the deep fungal infections playing a role especially in the terminal stages of AIDS.[3,52] Tuberculosis (TB) is an important cause of death in AIDS patients and *MTB* has been shown to preferentially involve the intraparotid lymph nodes.[3] Lymph node involvement reveals chronic, non-caseating partly granulomatous inflammation with few or no MNGCs whilst cases involving the gland parenchyma only display an infiltrate of foamy macrophages, filled with *MTB*, scant areas of necrosis and no granuloma formation.[3]

Cytomegalovirus (CMV) has been implicated as a cause for the development of CLH ever since Ryan *et* al.[32] noted CMV inclusions within the cyst lining of intraparotid lymph nodes. However, latent CMV infection is not uncommonly found in the epithelial cells of salivary glands in immunocompetent people and thus it is difficult to reconcile this infection as an aetiological agent for the development of CLH. In an HIV setting, CMV inclusions seemed to be confined to the gland parenchyma, preferentially in the ductal areas rather than in acinar cells. Epstein Barr virus (EBV) and adenovirus

have also been implicated in the aetiology of CLH.[3,17,61] These infections are important in the differential diagnosis of parotid gland enlargement.

2.5. Neoplastic associations

The literature is sparse concerning neoplastic involvement of the parotid gland in AIDS, particularly in the advanced stages when disseminated neoplastic conditions are frequent.[3] Isolated case reports of salivary gland enlargement due to intraparotid Kaposiôs sarcoma have been reported in HIV infected patients.[62,63] Human Herpes Virus 8 (HHV8) and Kaposiôs sarcoma in the setting of BLECs indicate a neoplasm in the terminal stage occurring in a depleted host immune system.[62,63]

Even though CLH has been reclassified as a benign, ótumour-likeô lesion of the salivary glands,[22] whether or not these cystic lesions may transform into a lymphoma over time is unclear.[64] Furthermore CLH bears a striking resemblance to the reactive lymphoid hyperplasia seen in SS designated as BLEL or LESA and which has a high risk of malignant transformation, a 44-fold increased risk than the general population of developing salivary gland or extra-salivary lymphoma, of which 80 % are marginal zone or MALT-type lymphomas.[36] Worrying microscopic features include an infiltration of the salivary duct epithelium by lymphocytes of marginal zone or monocytoid B-type forming LELs, recognised by epimyoepithelial islands. The presence of epimyoepithelial islands in some cases of CLH poses a special risk of possible development into a MALT-type lymphoma although to date no cases of malignant transformation have been reported.[64] Further long-term studies are needed in

this regard to confirm the truly benign nature of this entity and discounting any possible risk of malignant transformation.

The association between HIV associated BLEL and malignancy is less well documented but generally accepted, with Huang *et al*.[65] reporting a higher frequency of malignancy in solid parotid masses as opposed to cystic lesions within an HIV infected population. Even so, all HIV infected patients have a higher risk of developing a malignant lymphoma due to the increased survival with the advent of highly active anti-retroviral therapy (HAART) and the increased lifetime risk of developing a malignancy, especially in the paediatric HIV population.[64,65] Therefore all HIV infected patients with parotid gland enlargement should be closely monitored for any suspicious clinical or radiographic change, including any rapid growth. In this setting, a histopathological assessment to rule out malignancy is mandatory.[13,64]

2.6. The role of immunohistochemistry (IHC)

Several studies have used IHC as an aid to define the reactive nature of CLH.[1,5,39] In order to enhance the definition of the epithelial and lymphoid components seen in AIDS related CLH, Poletti *et al*.[39] confirmed positivity with cytokeratin (CK) and epithelial membrane antigen (EMA) and negativity with carcinoembryonic antigen (CEA) within the tonsil-like squamous epithelium of the cysts. The squamous epithelium of the cysts was predominantly keratin-positive and whilst normal squamous epithelium does not usually show EMA immunoreactivity, stronger EMA reactivity was noted within the cyst wall when compared to the salivary gland epithelium.[39] They further demonstrated that the squamous epithelium contained a proper set of accessory cells of the cell-

mediated immune response lineage.[39] In this regard leukocyte common antigen (LCA) positivity revealed the presence of *intraepithelial lymphocytes* and *intraepithelial macrophages* which were positive for Ŭ1-antichymotrypsin and vimentin.[39] In addition, OKT6 and anti-S100 protein antibodies disclosed other scattered intraepithelial cells of dendritic appearance (*Langhans cells*). In the lymphoid component, the abnormal presence of suppressor T-cells (Leu-2a-positive) and reduced numbers of helper T-cells (Leu-3a-positive) were consistently shown within Leu-14-positive follicular hyperplastic centres.[39] Anti-S-100 and DRC-1 antibodies highlighted the follicular dendritic reticulum cells (DRCs) in these areas.

The HIV p24 antibody (DAKO, Glostrup, Denmark) as used in the current study was first identified by Bruner *et al*.[66] who identified the HIV-1 p24 antigen within intraparotid lymphoid lesions using a monoclonal HIV p24 antibody. This antibody identifies a part of the gag protein, a core component of the HIV-1 viral particle. Subsequently, several attempts were made to elucidate the role of an HIV infection in the development of these parotid benign lymphoepithelial cysts with this antibody.[5,9,17]

Monoclonal mouse anti-human immunodeficiency virus, p24, clone Kal-1(Dako, Glostrup, Denmark) is recommended for use in immunoexpression of p24 in HIV-1-infected cells.[67] P24 is a viral capsid protein of the HIV-1 located in the core of the virus and enclosed by a bi-layered envelope with surface projections which plays an important role in the interaction with host proteins during HIV-1 adsorption, membrane fusion and entry.[68] The immunocytochemical detection of the HIV p24 technique was further elaborated by Vicandi *et al*.[57] who found the detection of the HIV p24 protein in

the multinucleated giant cells to be a useful diagnostic aid. Uccini *et al.*[17] showed the cystic fluid component of the LECs in HIV positive patients to be a viral reservoir for the HIV-1. Clinical studies on the efficacy of the p24 stain have shown a relationship in only 3.80 % of cases with the staining being restricted to the follicular dendritic cell network within the prominent follicular hyperplasia.[69]

The pathogenesis of this entity remains unclear as to whether CLH originates within intraparotid lymph nodes or occurs as a result of a secondary lymphocytic infiltration of the parotid gland following generalised lymphadenopathy. Several attempts were made using IHC as an accessory tool to resolve this uncertainty. DôAgay *et al.*[1] in an attempt to clarify the pathogenesis claimed that the presence of human mucosal lymphocyte (HML) positive lymphocytes indicated primary involvement of epithelial structures in CLH with the lymphoid hyperplasia occurring secondarily.[1] HML antibody is specific for a membrane molecule on HMLs and stains most intra-epithelial lymphocytes and lymphocytes from the lamina propria in different mucosae, but seldom stains lymphoid organs. However, Maiorano *et al.*[9] showed that LECs have similar IHC in both HIV positive and negative patients with evidence of simultaneous involvement of intra-salivary lymph nodes and salivary gland parenchyma. There is as yet no clear consensus; however the use of IHC provides a mechanism of assessing tissue involvement in these lesions.

2.7. Pathogenesis

As mentioned, there is considerable confusion as regards the pathogenesis of this entity. Studies suggest that the peculiar affinity for CLH to affect the parotid gland is related to

the embryological development of salivary gland whereby the parotid gland is the only salivary gland to contain lymphoid tissues within its capsule.[32,59,70] The lymphoid tissues are in effect well-developed nodes that are divided into 3 superficial groups and 1 deeply located group.[59] The proportion of lymphoid and salivary tissues vary, with the former sometimes being reduced to a thin shell around the parotid lobules. The submandibular gland has 3 to 6 adjacent lymph nodes but none within the gland capsule.[32] Care should be taken in not automatically assuming that the changes in the parotid and submandibular nodes occur under the similar circumstances.[32]

While the salivary gland lymph nodes may be the primary site of viral infections or represent secondary involvement following a systemic bacterial infection, they may in certain instances also represent the site of HIV and AIDS associated salivary gland enlargement.[32,60] Usually 5 -10 lymph nodes are noted within the parotid gland as these become entrapped within the gland during embryological development.[12,32,60] Furthermore, the intraparotid lymph nodes often contain salivary gland acini and ducts. In HIV salivary gland hyperplasia develops with HIV-1 replication as evidenced by the presence of both HIV-1 major core protein and RNA within these lymph nodes.[11,24]

There are 3 main schools of thought, amid several theories, regarding the pathogenesis of CLH.[19] The first maintains that cysts develop from embryological salivary gland inclusions within intraparotid lymph nodes.[10,46] The second postulates that cyst formation occurs secondary to an HIV associated BLEL within the salivary gland parenchyma,[1,5,9] and the third considers the cysts to be variants of BLEL thereby indicating a continued disease process.[71]

The hypothesis suggested by Bernier *et al.*[46] which implicates the entrapment of salivary ducts within hyperplastic lymphoid tissue leading to subsequent cystic dilatation and BLEC formation has been supported by several authors.[10,34,59] The well-defined fibrous capsule that is usually found surrounding these cysts as well as its proliferating lymphoid cellular wall hints at its origin from an intraparotid lymph node.[12] Elliott *et al.*[10] reported all cases of LECs within intraparotid lymph nodes and stated that a salivary gland inclusion within a lymph node was a pre-requisite for the development of these LECs and Ioachim *et al.*[60] added that the lymphoid hyperplasia may subsequently cause ductal obstruction leading to cystic dilatation. In addition, Schiødt *et al.*[18] found decreased stimulated parotid flow rates among HIV positive patients with parotid enlargement when compared to HIV positive patients without parotid gland enlargement. The overall *unstimulated* salivary flow rates did not differ much between the 2 groups. Mandel *et al.*[12] however argued that the clinical signs associated with ductal obstruction, namely pain and intermittent parotid swellings during meals were absent, thereby ruling out a possibility of ductal obstruction.

The sicca complex (xerostomia and xeropthalmia) has been associated with HIV infection.[20] Expanding on this, Ulirsch *et al.*[16] proposed an auto-immune aetiology speculating that the parotid gland enlargement represented a manifestation of ópossible immunologic derangementô occurring in AIDS patients. They postulated that the polyclonal B-cell activation seen in HIV infected patients might provoke an auto-immune response to salivary tissue similar to that seen in SS and the resulting lympho-follicular hyperplasia was then thought to give rise to the BLEC. However, Ioachim *et*

al.[70] argued that even though the lymph nodes showed similar features of disease, the assumption was not in accordance with the general belief that the AIDS associated lymphadenopathies were a result of direct viral activity. Furthermore, the auto-antibodies required for a diagnosis of the sicca-complex and SS were not demonstrated and this theory was thus abandoned.[70]

dôAgay *et al.*[1] suggested that the epithelial alterations lead to reactive lymphoid hyperplasia while Ihrler *et al.*[5] proposed the opposite mode of progression. Using IHC and computer assisted 3 dimensional (3D) reconstruction on 104 HIV positive LEC cases, they showed that the lymphoid cells infiltrate salivary gland parenchyma and provoke a LEL of the striated ducts with associated ductal basal cell hyperplasia.[5] In another study, they showed a continuous spectrum of LELs developing from a lymphoid infiltration of salivary lobules to lymphoepithelial duct lesions with cystic dilatation to large ductal cysts.[6] This study mitigates against LECs developing from pre-existing lymph node inclusions and presumed the HIV associated CLH to be a consequence of ductal obstruction.[6] In support Wu *et al.*[54] attribute cyst formation to begin within a background of non-virally induced sialadenitis. They report cystic dilatation to be a type of ógranulation tissue reactionô from the parotid parenchyma and not arising from the intraparotid lymph nodes. Only a small portion of their cases tested negative for HIV with a significant number of their cases not tested for HIV. This may suggest that the mode may differ somewhat in HIV and non-HIV affected individuals. As mentioned earlier, simultaneous involvement of intra-salivary lymph nodes and salivary gland parenchyma by LECs was found in both HIV positive and negative patients.[9] The pathogenesis of these lesions remains unclear.

2.8. The role of fine needle aspiration cytology (FNAC)

Fine needle aspiration (FNA) of the BLEC usually yields a haemorrhagic, yellow fluid and cytology reveals a triad of: (1) heterogeneous lymphoid population (lymphocytes, histiocytes, plasma cells), (2) scattered foamy macrophages and (3) anucleate squamous cells.[10,72] The presence of cholesterol crystals and degenerated acinar cells has also been found within a proteinaceous background.[10] FNAC has been shown to be an effective diagnostic tool as it is an accurate, cost-effective and minimally invasive procedure in the evaluation of superficially palpable salivary tumours.[2] It is also valuable in evaluating and distinguishing between benign and malignant salivary gland lesions.[2] FNAC offers information to help plan patient treatment and in some cases avoid surgery. This is especially useful in the immunocompromised patient. FNA should always be performed to rule out other salivary gland pathology because early recognition of the voluminous reactive parotid lymphoid hyperplasia of HIV infected individuals is essential. This lympho-proliferation may be a precursor to a mucosa-associated lymphoid tissue (MALT) lymphoma.[51]

2.9. The diffuse infiltrative lymphocytosis syndrome (DILS)

The close association between CLH and DILS warrants a brief commentary on this entity. The syndrome is characterised by a persistent CD8 + T-cell lymphocytosis, a diffuse visceral CD8 lymphocytic infiltration, bilateral parotid gland swelling and cervical lymphadenopathy, with a predisposition for black males and a genetic association to the HLA-DR5 gene.[27,73-76] With HIV-1 viral replication, salivary gland

lymphoid hyperplasia develops and parotid swellings ensue in the form of parotid LECs.[32]

Even though DILS is predominantly a late-stage manifestation of an HIV infection, patients have been shown to progress more slowly to clinical AIDS suggesting that patients with DILS have a favourable prognosis.[32,73] Studies have shown that patients with DILS tended to have a longer duration of disease when compared to those without DILS and still exhibited a less advanced HIV disease stage.[75] With a decline in CD4 + T-lymphocytes being recognised as a hallmark of an underlying HIV infection, blood studies typically reveal a CD4:CD8 ratio of 1:4.[13] The favourable prognosis seen in DILS can be explained to arise from the transient expansion of the CD8 + T-cell pool that normally occurs in the early phases of an HIV infection with the infiltrating CD8+ T-lymphocytes often numerically expanded in both the tissues and the peripheral blood.[77] A similar development has not been consistently shown in cases of CLH.[73,75]

Whether or not the same scenario applies to HIV positive patients affected by CLH is unclear but the idea that CLH is a predecessor to DILS is questionable. Patients affected by CLH usually present with an aesthetic complaint regarding the facial deformity resulting from a painless unilateral or bilateral parotid expansion whereas patients with DILS have bilateral parotid gland enlargement.[13] CLH appears to represent an early manifestation of an HIV infection and even though isolated case reports reveals patients with elevated CD 8+ T-cell counts in the presence on depleting CD4+ T-cell counts, a visceral CD8+ lymphocytic infiltration is not always present.[3,11-13,17,18] At this stage evidence is lacking with regard to CLH being a pre-requisite for the

development of DILS or whether or not all CLH patients will progress to developing DILS. It can therefore be assumed that CLH and DILS are 2 separate entities until further research proves otherwise.

Histological appearance: DILS

Salivary gland enlargements in DILS show histopathological features ranging from large, well-encapsulated cysts to massive destruction of glandular structure along with fibrous tissue replacement.[13] Histologically similar to CLH, these cysts are also lined by a stratified squamous epithelium although they are larger and more numerous with increased glandular destruction.[13,27] The lumen contains a pale, homogenous material with foamy macrophages and lymphocytes.[13,76] The cyst wall also shows the presence of germinal centres and a dense infiltrate of lymphoid cells.[13]

2.10. Treatment and management of CLH

Treatment options for CLH include observation, repeat aspiration, ARV medication, sclerotherapy, radiation therapy and surgery.[14] Because of the poor prognosis attributed to HIV, traditionally observation, repeat aspiration and as a last resort, surgery was favoured, a view which is changing in view of the widespread use of ARVs and the longer survival rates. In the early 1990ôs surgical removal of the superficial lobe of the parotid gland was the treatment of choice but the danger of this lies in the possible damage to the facial nerve and the risk of increased morbidity in an immunocompromised patient along with the uncertainty of recurrence.[29,50,73] Corticosteroids as a treatment option may temporarily shrink enlarged glandular tissues, however swellings generally return with cessation of the medication.[73] FNAC may be a

useful diagnostic tool, however it is generally ineffective as a therapeutic tool as evidence of relapse does exist and surgery may become necessary when pain due to persistent and progressive swelling of the salivary gland occurs.[2,57,72]

Low dose radiation therapy (8-10 Gy) was previously reported to provide reliable but temporary cosmetic palliation for CLH.[78-80] The results were variable and this treatment mode has been shown to be ineffective at lower doses (8-24 Gy) with the re-treatment of failures yielding unsuccessful results.[79,80] Potential side effects such as xerostomia, mucositis, taste loss and osteoradionecrosis must also be considered. Children and HIV positive patients are generally more sensitive to radiation and the potential for radiation-induced malignancy exists, especially due to increased life expectancy with the advent of ARVs.[81]

It seems reasonable to observe asymptomatic patients. However, as CLH is cosmetically disfiguring and occasionally painful, more comprehensive treatment is now being sought as there are significant emotional and social sequelae. Significant reduction in cyst size has been reported with tetracycline and doxycycline sclerotherapy, with no serious complications, other than pain, tenderness and mild oedema at the injection sites.[82] Early treatment of smaller cysts shows a more favourable response as larger cysts tend to be replaced by a fibrotic mass which would then require surgery.[82] Recent therapeutic advances from South Africa show promise with Meyer *et al.*[83] showing alcohol injection sclerotherapy to be a cost-effective procedure, yielding effective results for those HIV infected patients who do not qualify for ARV treatment

and Monama *et al.*[84] demonstrating effective regression of the cysts with Bleomycin injection therapy.

ARV therapy has shown promising results for highly disfiguring and frequently cystic parotid enlargement, however patients require counselling regarding side effects and compliance may be problematic.[14,33] Dave *et al.*[14] reported a marked regress of parotid enlargement following HAART, thus avoiding xerostomia associated with surgical excision. A combination of AZT with the newer protease inhibitors seems to be successful.

CHAPTER 3

3.0 AIMS

The purpose of this study is to define the clinical parameters, histology and immunopathological features of a large series of cases of cystic lymphoid hyperplasia in HIV positive patients with a view to elucidating the aetio-pathogenesis of this lesion.

CHAPTER 4

4.0 METHODS AND MATERIALS

4.1. Study sample

A retrospective record and histological review was performed in the Division of Oral Pathology, University of the Witwatersrand, Johannesburg, South Africa where all the archived surgical specimens diagnosed as CLH during the period January 2000 until October 2009 were retrieved. Patient slides were allocated study numbers in order to maintain patient confidentiality.

The clinical findings such as the patientôs age, race, gender, HIV status, CD4 counts and viral loads where available were documented from the clinical information submitted together with the surgical specimen and recorded on the histopathological reports [Appendix 1]. Furthermore clinical parameters more specific to the nature of the CLH were also recorded. These included the site, salivary gland involved, cyst size, period and extent of presentation, symptoms, unilateral versus bilateral presentation and radiographic features where available. This was done on the entire study cohort of 167 confirmed cases of CLH.

All the haematoxylin and eosin (H&E) stained sections from the available cases seen during this set period were histologically reviewed by the investigator in conjunction with a specialist pathologist and the diagnosis confirmed. This included only 109 of the 167 confirmed cases of CLH as the sections and blocks from the remaining 58 cases

were unavailable from the archives. All the tissue specimens had been originally fixed in 10% neutral buffered formalin (18-48 hours) and routinely processed and embedded in paraffin wax.

4.2. Ethics

Ethics clearance (M080927) [Appendix 2] was granted by the Human Research Ethics Committee (Medical) of the University of the Witwatersrand to view patient hospital files in order to confirm the HIV status of the patient, the CD4 count and the viral load. Furthermore, the ethics code M080850 used for this research project is a blanket code for use on archival block material obtained from human tissues, allocated to the Division of Oral Pathology, Department of Anatomical Pathology. Permission was obtained for use of the clinical photographs.

4.3. Histology

Specific histological parameters were explored in 109 of the 167 confirmed cases of CLH which were available for review [Appendix 3]. The LECs were analysed for their occurrence within a specific salivary gland or within a lymph node, locularity, luminal contents, nature of the epithelial lining and the lymphoid proliferation encasing the cysts, presence of Warthin-Finkeldey type MNGCs and granuloma. The overall architecture of the salivary gland was also examined where present for acinar atrophy, lymphoid proliferation, inter- and intra-lobular ductal dilatation, periductal inflammation, fibrosis, cyst formation, and degree of CLH. The lymph node parenchyma was examined further for the degree and nature of the CLH process, HIV induced changes, the presence of epimyoepithelial islands, the presence of entrapped

salivary gland acini and fibrosis. In view of the strong documented association of CLH with HIV and AIDS,[4,5,8] the presence of HIV induced histological changes and immunostaining for the HIV antibody, p24, were examined in all 167 cases of CLH.

Based on the classification by Wu *et al.*[54] the cysts were categorised into 3 types:

Type 1: showing early stages of cyst formation with dilation of the ducts within focal sialadenitis, with or without epimyoepithelial island formation

Type 2: cysts which were partially encapsulated from the surrounding parotid tissue

Type 3: well encapsulated cysts found within lymph nodes

Where indicated, for example the presence of granulomas, further investigations including special stains [Ziehl Neelson (ZN), Periodic acid-Schiff (PAS)] were done to exclude the presence of further pathology such as TB and other co-infections. The presence of MNGCs has been previously recorded in other studies.[42,57]

4.4. Immunohistochemistry

IHC was performed on deparaffinised 4µ sections on a selected number of cases using the antibodies listed in Table 4.4.1.

Table 4.4.1 List of immunohistochemical markers used in the study

Antibody	Clone	Dilution	Manufacturer
P24/HIV	Kal-1	1:10	DakoCytomation, Glostrup, Denmark
CD20	L26	1:700	DakoCytomation, Glostrup, Denmark
CD3	Polyclonal	1:200	DakoCytomation, Glostrup, Denmark
CD4	4B12	1:2 /1:10	DakoCytomation, Glostrup, Denmark
CD8	1A5	1:100	Novocastra (Newcastle upon Tyne, UK)

IHC studies were performed on each commercially available antibody as listed in Table 4.4.1 using the Envision system (DakoCytomation, Glostrup, Denmark) on formalin fixed paraffin embedded tissue sections measuring 4µ in thickness that were cut from the specimens and placed on 3-aminopropyl-triethoxysilane (APES, Sigma, St Louis, Missouri,USA) glass slides. These were air dried overnight, de-waxed and hydrated through graded alcohols and water. Sections for the reactions with each antibody were immersed in citric acid (Sigma, St. Louis, Missouri, USA) buffer 0.01M, pH 6.0 and heated in a microwave oven (800 watt) on medium power for 10 minutes. For heat induced epitope retrieval, the sections for the various antibodies were subjected to1.0 mmol/L of ethylene diamine tetraacetic acid EDTA buffer (pH 9.0), heated in microwave (800 watts) on medium power for 10 minutes.

Sections were then cooled for 20 minutes. The sections were immersed in 3% hydrogen peroxide in distilled water for 5 minutes and rinsed in TBS pH 7.6 with 0.1%Tween 20 (Sigma, St Louis, Missouri). The protein was blocked for 5 -15 minutes

to block the endogenous peroxidase. Specimens were incubated with the primary antibody for 20 minutes at room temperature using the dilutions listed in Table 4.4.1. Sections were then incubated with the Envision detection kit (Dako, Denmark) for 20 minutes, then rinsed with TBST (Tris-Buffered Saline Tween-20) and incubated for 3 minutes. Chromogen was applied for 10 minutes and the colour was developed with 3,3ô-Diaminobenzidine (DAB, Sigma) resulting in a brown reaction product. Thereafter, sections were lightly counterstained with H&E for 1 minute. At the same time, the negative control was incubated for 1 hour under the same conditions with the negative control reagent and buffer for each antibody. Appropriate positive controls were included along with negative controls.

Due to budget constraints and the limitation in funding for this study, immunostaining with CD20, CD3, CD4 and CD8 was performed only in a selected number of cases (*n* = 25). Using visual impression only, with no cell counting, the immunopositivity for CD20, CD3, Cd4 and CD8 was expressed semi-quantitatively as a percentage as follows: < 10%; 10 - 50%; 50 ï 80% and > 80%. In most cases, the IHC demonstration of the monoclonal antibody HIV p24 was done as part of the routine diagnostic work up of the CLH cases. Where necessary, additional p24 stains were performed to include all cases of CLH. Immunopositivity for p24 was expressed as either positive or negative and not according to intensity.

4.5. Statistical analysis

The data in this study is mostly descriptive in nature and was analysed by the student using the Epi Info package, version 3.5.1. Significant differences were analysed using

the Student *t* test and the Chi square test with a statistical significance level of $p < 0.05$ being used.

CHAPTER 5

5.0 RESULTS

5.1. Demographics

The study population comprised 167 cases, the clinical features of which are summarised in Table 5.1. Due to the unavailability of some of the archival blocks, only 109 of the 167 cases were histologically examined. An analysis of the cases showed no gender bias, with a ratio of 1.04:1 (85 men, 82 women). CLH occurred over a wide age range between the ages of 6 and 65 years (mean, 38.25 years; median, 38 years, SD, 10.97). The female cases presented mainly in the 3rd (26%) and 4th (40%) decades compared to the males in whom CLH predominantly occurred in the 4th (38%) and 5th (25%) decades (Fig. 5.1.1). Statistically significant (p = 0.0007) younger mean and median ages (35.4; 35 years; SD, 10.71) were noted in females than in males (41.1; 40.5 years; SD, 10.54) (Fig. 5.1.2). Only 1 case occurred in the 2nd decade (0.6%) and 2 cases in the 7th decade (1.2%). In total, 6 patients (3 males, 3 females) were below the age of 15 years. The age of 3 male patients was not available.

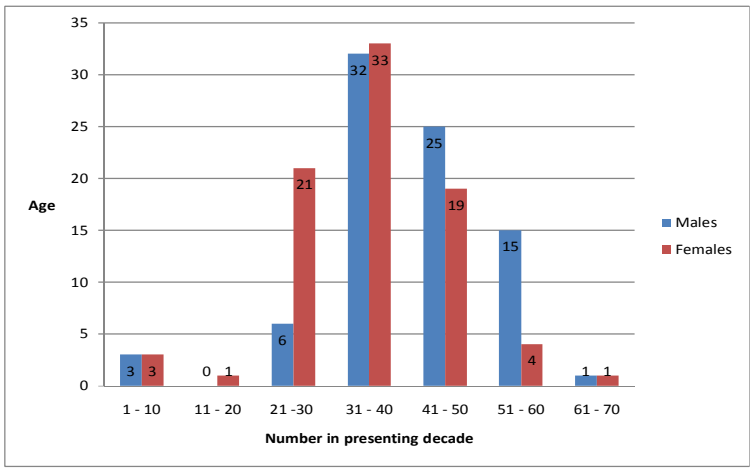

Fig. 5.1.1 CLH: Age categorisation according to gender and presenting decade

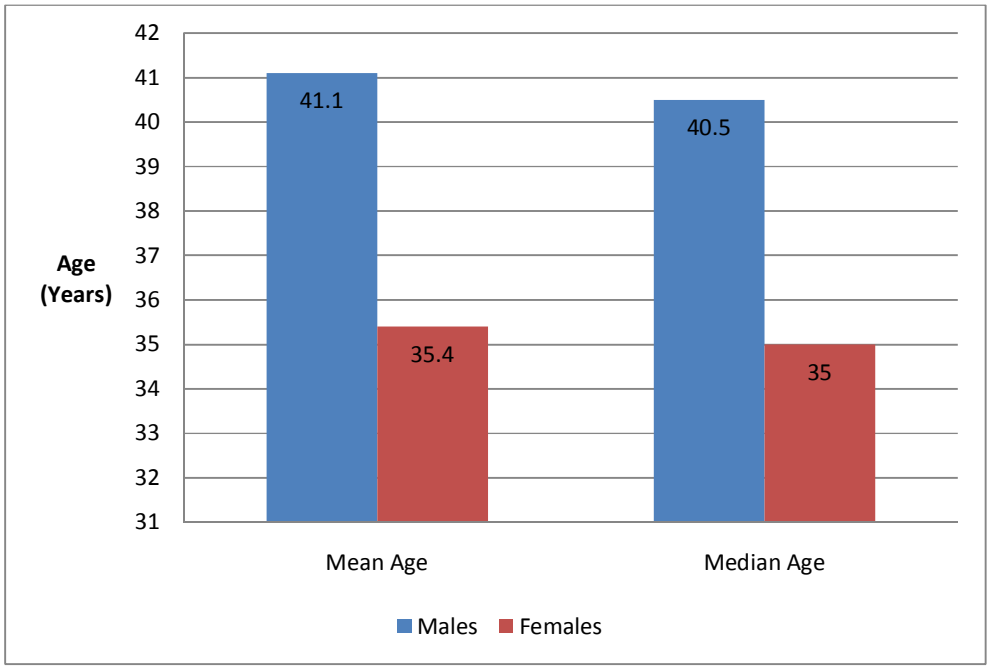

Fig. 5.1.2 CLH: Mean age of presentation distributed by gender

Table 5.1 Clinico-pathological features of patients affected with cystic lymphoid hyperplasia

Total study sample		167 patients
Gender	Males	85 (50.9 %)
	Females	82 (49.1%)
Age: (years)	Range	6 ï 65
Presenting symptoms:		
	Swelling	All cases
	Unilateral	158
	Bilateral	9
	Pain	No cases
Cyst size (macroscopic)		Varied in size from 3 ï 65 mm
Duration of cyst before diagnosis		3 ï 6 months
Confirmed HIV positive patients		20
CD4 count (cells/µL)		**Lowest:** 91; **Highest:** 490
Viral loads (only available in 2 cases)		1400 and 28000 copies/mL
Number of patients on an existing ARV regimen		3

5.2. Clinical Findings

The swellings developed over a 3 to 6 month period in 9 out of the 167 cases (5.4%). The overwhelming majority of the cases, 140 (84%), affected the parotid gland (75M; 65F) with the cysts located predominantly within the superficial lobe, 22 cases (13%) involved the submandibular gland (9M; 13F) and a single case (0.6%) involved a reactive right tonsil together with portions of the sublingual gland, which showed focal CLH change (Fig. 5.2.1). In 4 cases, the sites of involvement were labelled in the histopathology reports as right ócervical lymph nodeô, left ómandibleô and left óneckô (2 cases) and these 4 cases were categorised as ótherô (2.4%), since histologically there was only representation of lymph node parenchyma and no glandular tissue.

Of the 140 parotid gland cases, 131 cases (93.6%) were submitted as unilateral enlargement only, with no mention made in the clinical data to suggest bilateral or previous contra-lateral glandular involvement (Fig.5.2.2A,B). A further breakdown of the parotid cases revealed that 55 cases (39.3%) occurred on the patientôs right side and 49 cases (35%) on the left side. All 9 cases (6.4%) in the study population which showed bilateral enlargement occurred in the parotid gland (Figs 5.2.4A-C and 5.2.5A,B). In the remaining 27 cases (19.3%) the affected side was not indicated in the clinical information submitted. Among the 22 cases with submandibular gland involvement, 7 (32%) cases were left-sided and 5 (23%) were right-sided. In 10 cases (45%) the affected side was not stated.

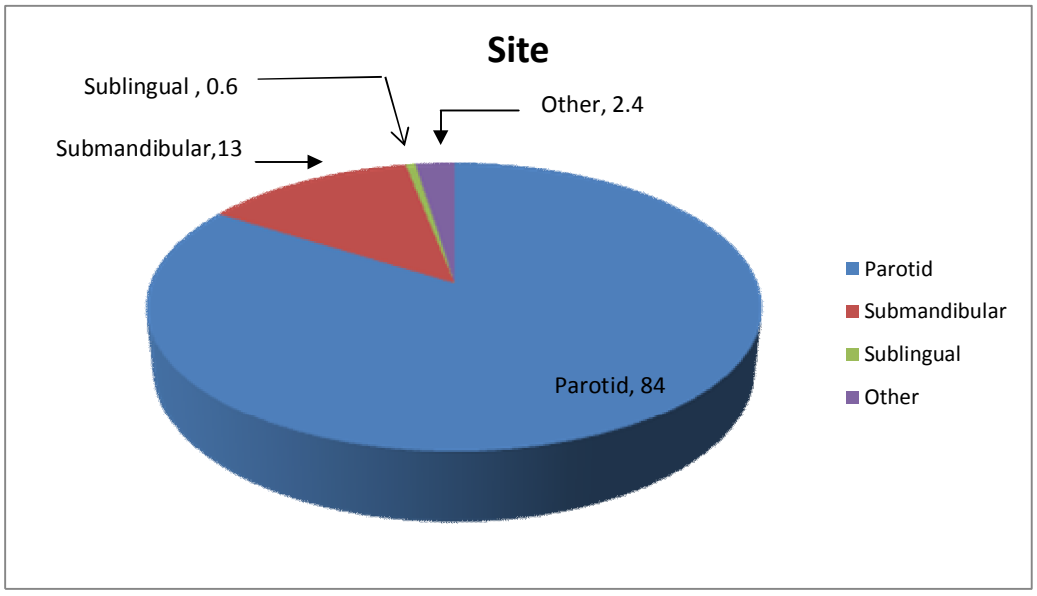

Fig. 5.2.1 Site distribution of CLH within the affected salivary glands and adjacent sites

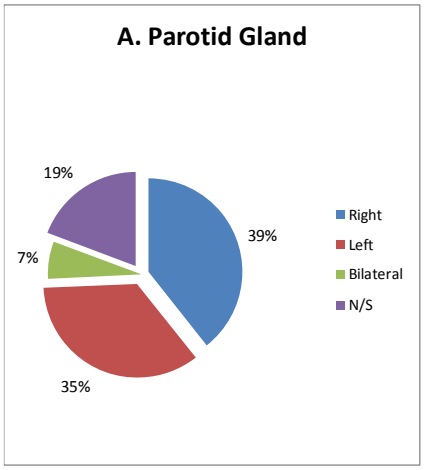

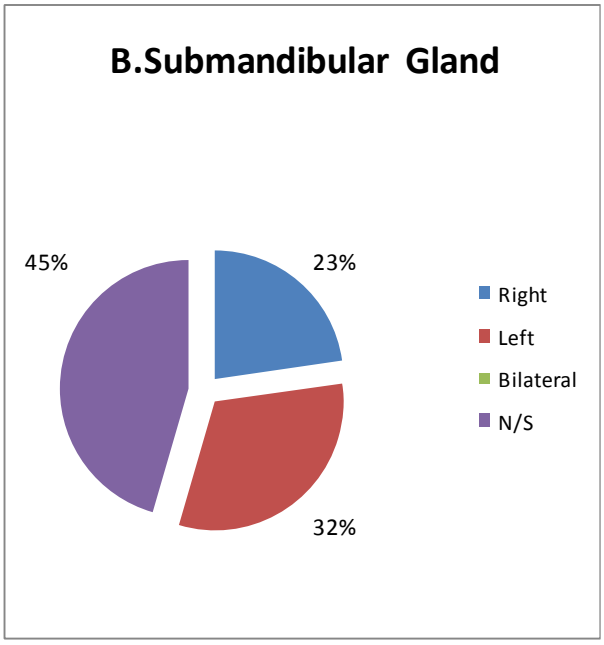

Fig. 5.2.2A,B Distribution of unilateral and bilateral enlargement of the parotid and submandibular glands

N/S = Not Specified

In addition, CLH affecting the parotid and submandibular salivary glands showed a younger mean age of presentation within females (36.5; 31 years) when compared to the males (40.9; 42.4 years) and this association was noted to be statistically significant (p = 0.0032, females and p = 0.0035, males) (Fig. 5.2.3).

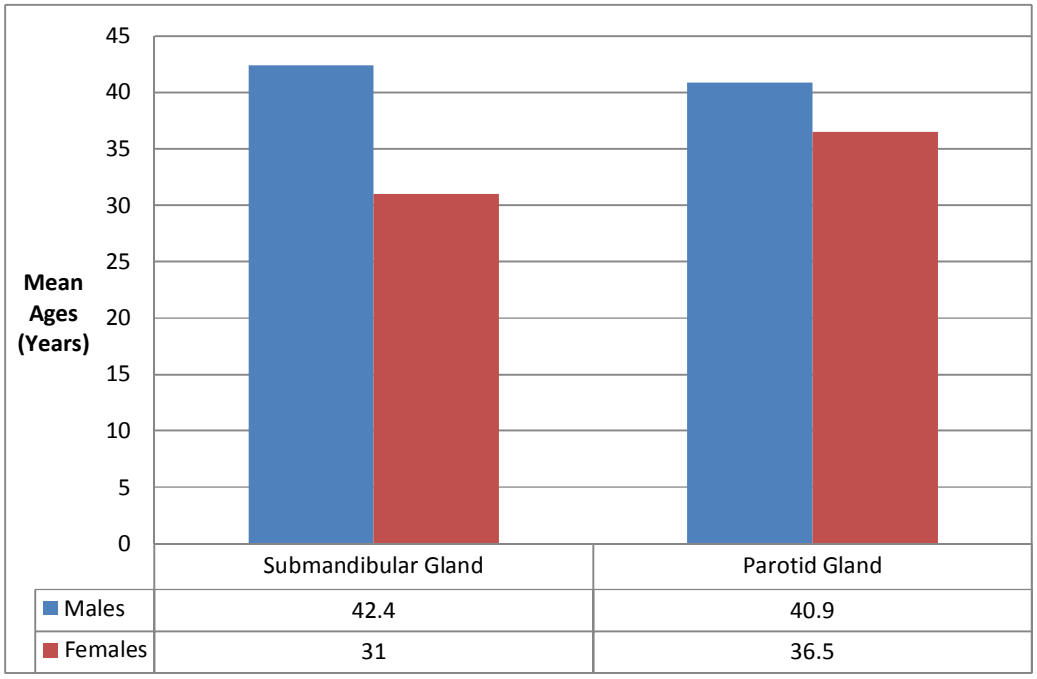

Fig. 5.2.3 CLH: Gender distribution according to age and site

The clinical concern in most cases was that of a ópparotid tumourôor parotid ócystô. The main clinical complaint was generally that of a ópainless swellingôin the parotid area. Xerostomia was not reported to be of clinical concern. It was not apparent from the clinical details received if the patients presented with any other clinical manifestations of HIV and AIDS. Only 20 (~12%) patients within the sample were tested and confirmed to be HIV positive by both the enzyme-linked immunosorbent assay (ELISA) and Western blot techniques.



Fig. 5.2.4A-C Bilateral parotid gland enlargement in HIV infected patients with CLH, ranging from subtle enlargement (A) to gross facial swelling (B/C)

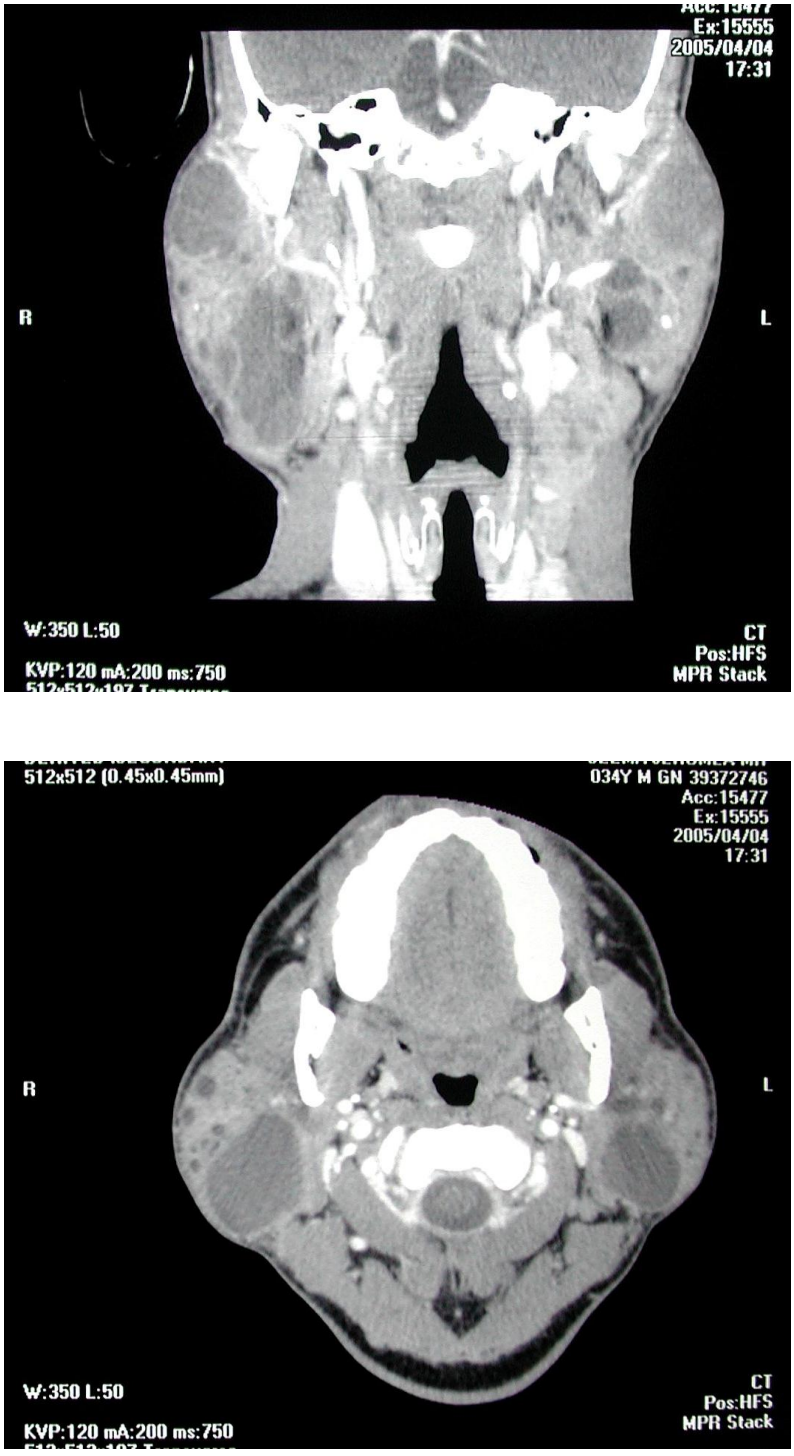

Fig. 5.2.5 CT scans coronal (A) and axial (B) views showing multiple, oval, variably sized radiolucencies present bilaterally within abnormally dense parotid glands

5.3. Macroscopic findings

The surgical specimens presented as well-circumscribed, lobulated and multicystic masses within salivary gland tissue. In 25 cases, the cystic masses were separated from the parotid parenchyma by means of a thin fibrous connective tissue layer. The swellings were rubbery-firm in consistency in 8 cases. The macroscopic cystic spaces (~40%) contained a gelatinous (mucoid) material which varied in colour from a tan-brown to a creamy-yellow straw colour. Macroscopically, the size of the cystic masses varied considerably, ranging for 3 to 65 mm in diameter. Many cases included either the intra and/or peri-parotid lymph nodes, or the submandibular lymph nodes. These lymph nodes were enlarged and measured ~10 x 15 x 25 mm in diameter. While the external surface varied from shiny and smooth to congested, the inner lining of the cysts was irregular and granular with a cobble-stone appearance. In some instances cyst wall texture had a fine nodularity and wall thickness of no more than 3-4 mm. In a single case involving a confirmed HIV positive patient, the multiple cystic structures were filled with a tan coloured, colloid-like material and the adjacent parotid gland showed areas of dense fibrosis and focal necrosis.

5.3 .1. Microscopic findings

H&E stained sections from 109 (65.3%) of the 167 cases were available from the archives and were reviewed histologically. CLH was recognised histologically as BLECs that presented as epithelial-lined unicystic or multicystic cavities surrounded by abundant hyperplastic lymphoid tissue, and either occurring in lymph node (Fig. 5.3.1) or salivary gland parenchyma (Fig. 5.3.2).

Histologically, 92 (84.4%) cases involved the parotid gland and/or lymph nodes (including 6 bilateral cases), 13 (11.9%) involved the submandibular gland, 1 (0.9%) occurred within the sublingual gland and 3 (2.8%) entitled ‘other’ presented within lymph nodes in extraglandular sites. Due to the close anatomical association of the tail of the parotid gland and the submandibular gland, some biopsy specimens were erroneously submitted as being from the submandibular gland (4 cases; 3.7%), ‘left mandible’ (1 case; 0.9%) and ‘left retromolar area’ (1 case; 0.9%). In these cases, parotid glandular tissue was noted histologically and these cases were deemed to be an extension of the reactive CLH process that had in fact, arisen from the parotid gland and subsequently re-grouped as such.

5.4.1. Histologic categorisation of CLH

The LECs were further categorised according to Wu *et al.*[54] as described earlier in Chapter 4. The overwhelming majority of CLH cases (75; 68.8%) were classified as Type III cysts, occurring within lymph nodes, with distinct encapsulation from the adjacent salivary gland (Fig. 5.3.1B), 27 (24.8%) cases were found to be partially encapsulated from the surrounding glandular tissue (Type II) and 6 (5.5%) cases were grouped as Type I cysts with cystic dilation of ducts within focal sialadenitis, with or without epimyoepithelial islands. There seemed to be a significant trend in the progression of CLH from Type I toward Type III ($p = 0.0027$). A single case (0.9%) which showed a mixed lesion with an intense lymphoid proliferation into the cyst wall could not be specifically categorised and was designated as being a mixed Type I/Type II lesion.

In addition and for further clarity regarding the cyst location, CLH was documented as occurring within *both the salivary glands and its associated lymph nodes*. Within the 109 cases examined histologically, most cysts 83 (76.1%) were located within the *intra-glandular lymph nodes only,* in 6 cases (5.5%) the CLH process affected the *salivary gland parenchyma only*, while in the remaining 20 cases (18.4%) the cysts were located *both within the intra-glandular lymph node as well as in the salivary gland parenchyma.*

Of the 83 cysts located *within glandular lymph nodes,* 69 (83.1%) involved intra-parotid lymph nodes, 11 (13.3%) occurred in the submandibular lymph nodes and 3 (3.6%) were from the group entitled ótherô. Regarding these 3 cases, there was no histological evidence of glandular tissue to allow any further comment regarding location. In the 6 cases where cyst formation was limited to the *gland parenchyma only,* 3 cases occurred in the parotid gland, 2 in the submandibular and 1 in the sublingual gland respectively. The 20 cases showing both *glandular lymph node and glandular parenchyma involvement* were found exclusively in the parotid gland and its associated lymph nodes. The 6 bilateral cases showed 3 cases with involvement of ó*intra-glandular lymph node only* ô, 1 within ó*gland parenchyma only*ô and 2 with involvement of ó*both intra-glandular lymph node and glandular parenchyma*ô (Table 5.2).

Table 5.2 Histological distribution and categorisation of CLH

LOCATION	LYMPH NODE ONLY			SALIVARY GLAND ONLY			SALIVARY GLAND & LYMPH NODE
NUMBER	83			6			20
PERCENTAGE	76.1%			5.5%			18.4%
DISTRIBUTION	PG	SBM	OTHER	PG	SBM	SBL	PAROTID
NUMBER	69	11	3	3	2	1	20
PERCENTAGE %	83.1	13.3	3.6	50	33.3	16.7	100 %
BILATERAL CASES	3			1			2

*** Total number of cases = 109, Number of bilateral cases = 6**

PG = Parotid gland**, SBM =** Submandibular gland**, SBL =** Sublingual gland

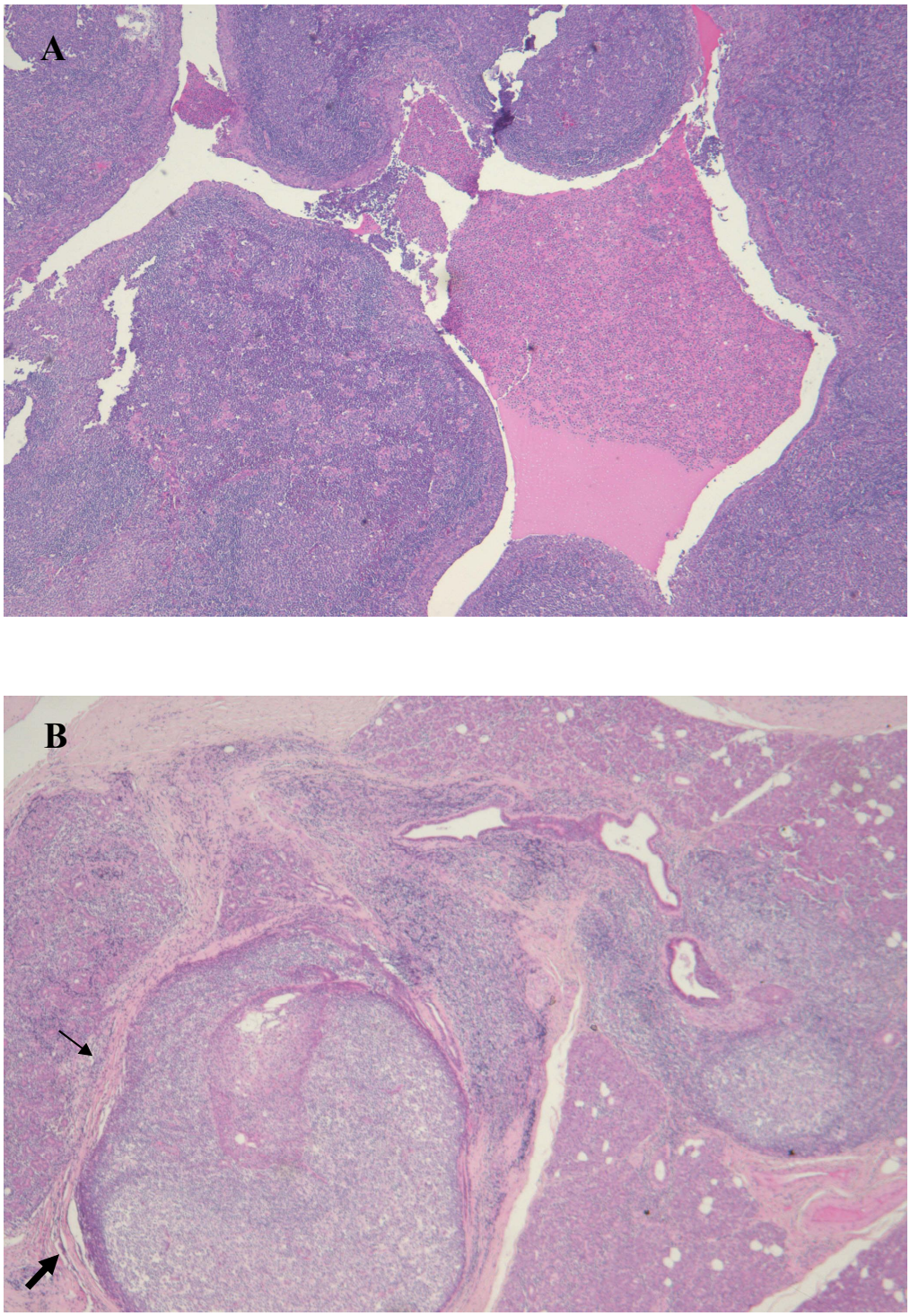

Fig. 5.3.1A,B Intraparotid lymph node showing multiple cysts with surrounding proliferative lymphoid tissue. The cyst lumen (A) is filled with mucoid material with interspersed acute and chronic inflammatory cell. Encapsulation of lymphoid tissue (arrowed) (B) demarcating a lymph node with HIV associated change including follicle lysis and serpentine germinal centres (H&E, original magnification X4)

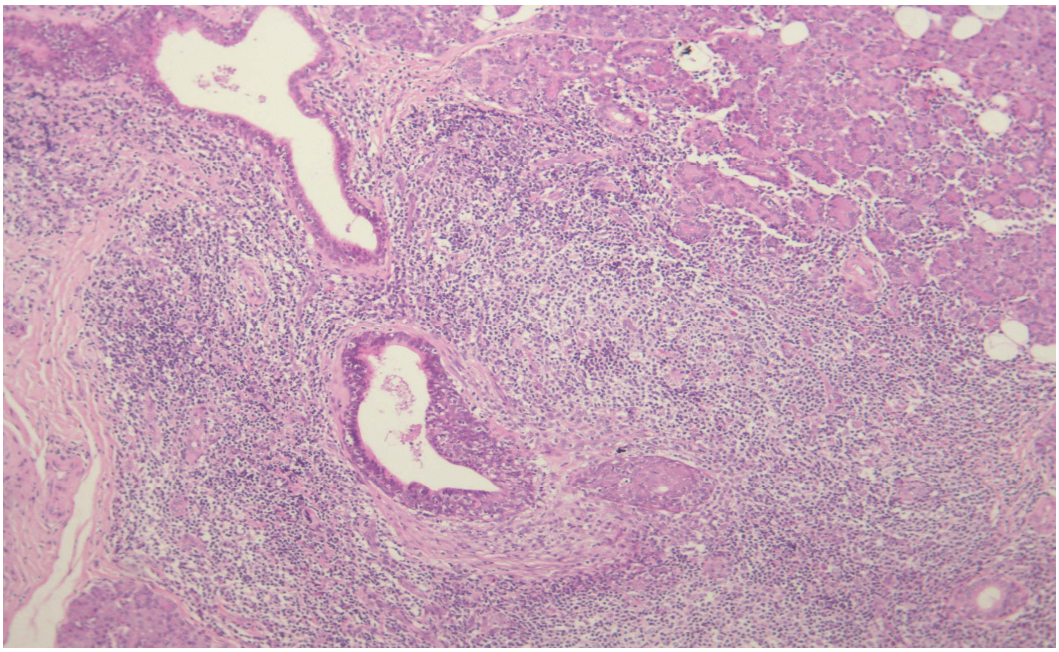

Fig.5.3.2 CLH primarily involving parotid gland parenchyma with ductal ectasia, acinar atrophy and prominent atypical lymphoid hyperplasia consistent with HIV induced lymphoid change (H&E, original magnification X10)

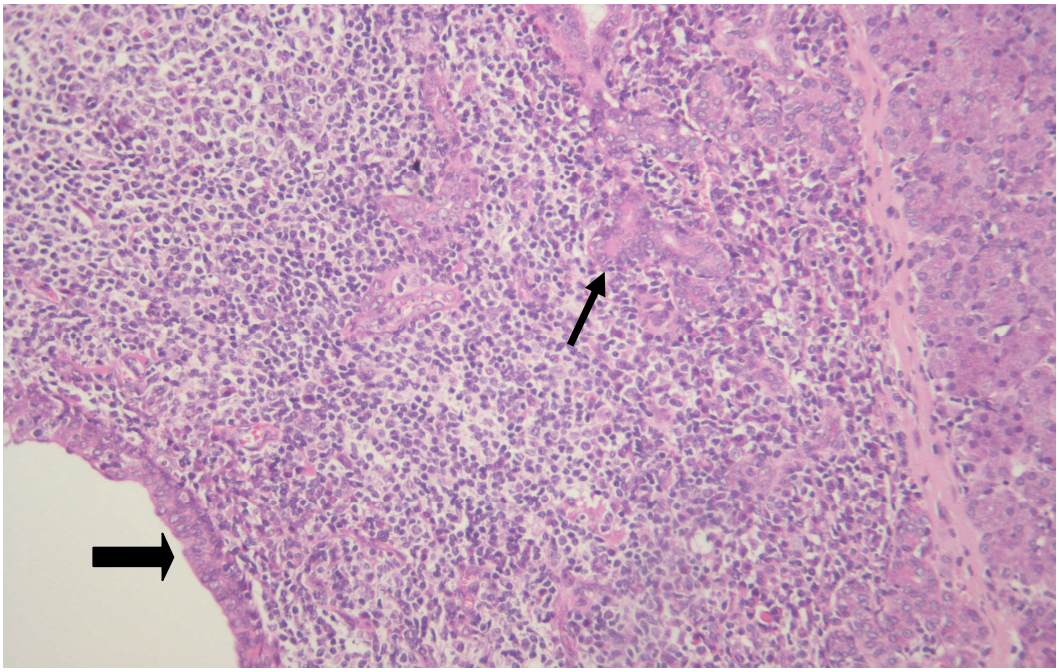

Fig.5.3.3. Entrapped salivary gland remnants (thin arrow) within the hyperplastic lymphoid tissue surrounding the cystic space, which is lined by pseudostratified ciliated respiratory-type epithelium (thick arrow) (H&E, original magnification X20)

5.4.2 Cyst locularity

Of the 109 CLH cases reviewed histologically, an astonishing 107 cases (98.2%) showed multicystic cavities distributed over the 3 locations as stated above (5.4.1). Interestingly, CLH manifesting with a unicystic pattern was evident in only 2 lesions (1.8%). Furthermore, both these cases involved the submandibular gland, 1 solely within a submandibular lymph node and the other seen in CLH occurring within the submandibular lymph node and accompanying gland parenchyma. There was extensive parenchymal destruction in the latter case, especially in areas where the CLH process seemed to overrun the glandular parenchyma causing extensive acinar and ductal atrophy.

5.4.3. Epithelial lining

The overall histological appearance of the LECs was essentially similar irrespective of whether they occurred within lymph nodes or salivary gland parenchyma. Cyst lining was devoid in areas and where present it ranged from a thin non-descript epithelial lining to non-keratinising stratified squamous to pseudostratified respiratory-type epithelium (Fig. 5.3.3). The thickness of the lining epithelium was variable ranging from 1 to 10 cell layers in thickness. In 100 cases (91.7%) the lining epithelium consisted of both non-keratinising stratified squamous and respiratory-type, and in only 1 case, the lining epithelium showed evidence of focal keratinisation. One case (0.9%) showed a mixture of flat cuboidal and squamous epithelium, while a purely squamous lining was noted in 7 cases (6.4%), including 1 case which showed peripheral palisading of the basal cells. Only 1 (0.9%) case was completely devoid of any epithelial lining. Mucous or sebaceous metaplasia was not evident within the cyst lining. Most cases (73;

67.0 %) showed papillary infoldings of the epithelium, usually 1-2 layers thick, into the cyst lumen. There was moderately intense lymphocytic permeation of the cyst lining. Prominent subepithelial lymphoid condensation admixed with other acute and chronic inflammatory cells was noted within the reactive lymphoid proliferation adjoining the cyst lining (Figs. 5.4.1 and 5.4.4).

5.4.4. Cyst contents

The cyst lumens were filled with a mucoid material (Fig. 5.3.1A) with interspersed acute and chronic inflammatory cells in most cases (100; 91.7%), with 19 cases showing cholesterol granulomas within the lumen and 9 cases being totally devoid of cyst contents. While the mucoid content was mainly gelatinous in nature, the cholesterol granuloma showed blood vessels (9 cases), fibrin (1 case) and foreign body giant cells (1 case).

5.4.5. Changes within the lymph node

CLH primarily involved the lymph nodes (83 cases; 76.1%). For the most part, the lymph nodes retained their normal glandular architecture and maintained their distinct fibrous connective tissue capsule and subcapsular sinuses. There was florid follicular hyperplasia, with an increase in the size and number of the follicles and an irregularity in the shape of the follicles, including serpentine, dumbbell and hourglass shapes (Fig. 5.3.1B). The germinal centres showed prominent tingible body macrophages and numerous mitoses. Sinus histiocytosis was evident. Scattered clear monocytoid B-cells with admixed neutrophils were noted within the sinuses. In addition, there was follicle lysis, with an attenuation of the mantle of small lymphocytes (naked germinal centres)

with an invagination of the mantle lymphocytes into the follicle. There was associated hyalinisation and fibrosis within the lymph node parenchyma. The features observed are well described HIV induced changes.[32] The HIV lymph node changes were not further categorised or graded histologically. Many of the lesions of CLH were encapsulated, however in some cases (33 cases; Type I and Type II) the cystic lymphoid proliferation was noted extending into the parotid parenchyma with/without encapsulation.

5.4.6. Changes within the glandular parenchyma

Careful examination of the lymph nodes in and around the salivary glands consistently demonstrated entrapped salivary gland remnants in each lymph node examined, with salivary duct dilatation (Figs. 5.3.3 and 5.4.2). As part of the CLH picture, unicystic or multicystic spaces were present within the hyperplastic reactive lymphoid parenchyma. 83 (76.1%) cases were defined as Type III cysts. In cases where the CLH was confined only to the lymph node, the adjacent salivary gland often showed variable multifocal periductal lymphoid aggregates with varying degrees of acinar atrophy and insipient cystic change, which probably represents areas of early CLH change encroaching upon the adjacent salivary gland parenchyma. With an increase in chronic inflammation, increased fibrosis was noted within the gland architecture.

A small number of cases (20, 18.4%) showed CLH simultaneously affecting the salivary gland and the lymph node. In these cases, the lymph nodes were well encapsulated and always revealed entrapped salivary gland tissue with visible fibrosis and increased hyalinisation within the gland. The unicystic or multicystic cysts which

were lined by a variable epithelium were prominent in both the para- and intraglandular lymph nodes as well as within the salivary gland. The cysts within the salivary gland showed similar features to those occurring within the lymph nodes; however they appeared to be smaller. Ductal dilatation and acinar atrophy were more marked than those cases where the CLH process was confined to the associated lymph nodes.

The CLH process was limited to the salivary gland only in 6 cases (5.5%), with a prominent lymphoid infiltrate within the gland and the entire gland being overrun by CLH with extensive acinar atrophy and fibrosis. The unicystic cases within the submandibular glands also showed marked ductal dilatation and prominent lymphoid stroma within the walls of the cyst and the salivary gland ducts. The hyperplastic lymphoid aggregates in the gland showed vague germinal centre formation, however they were not surrounded by the fibrous capsule. A single case revealed the presence of a mucous extravasation cyst occurring simultaneously with CLH of the submandibular gland.

5.4.7. Epimyoepithelial islands

Epimyoepithelial islands were present in 61 (56.0%) of the 109 cases histologically reviewed, usually in the lymphoid stroma of the gland. (Fig. 5.4.3) The epimyoepithelial islands were noted in 49 cases of CLH affecting the lymph node only (80.3 %), 11 (18.0%) involving both lymph node and salivary gland and only 1 (1.6%) case with salivary gland involvement only. The epimyoepithelial islands were similar to those frequently seen in LESA. The high proportion of epimyoepithelial islands present in cases of sole lymph node involvement was shown to have no statistical

significance (p = 0.13). Similarly 46 (75.4%) of these islands were present within Type III cysts but this high occurrence also showed no significance and while common in CLH of the parotid gland (52 cases, 85.2%) the association was not significant (p = 0.71).

5.4.8. HIV associated changes

On review of the histolopathology reports of the entire sample of 167 cases of CLH, an overwhelming majority of cases, 164 of the 167 cases (98.2%) showed the described HIV associated changes within the lymph nodes confirming the strong association of CLH with HIV and AIDS. Only 3 cases showed non-specific reactive lymph node changes. Of the entire cohort of 167 CLH cases, only 20 were previously confirmed HIV positive patients (Figs. 5.3.1B and 5.3.2). Positive p24 staining was present in 150 of these 167 cases (89.8%) whilst 10 cases (6.0%) with HIV associated histological features showed negative immunostaining for p24. In addition, even though epimyoepithelial islands were found to occur more commonly in the presence of these HIV associated changes (61 cases), a Fisherôs Exact Test revealed that there was no statistical association (p = 0.19).

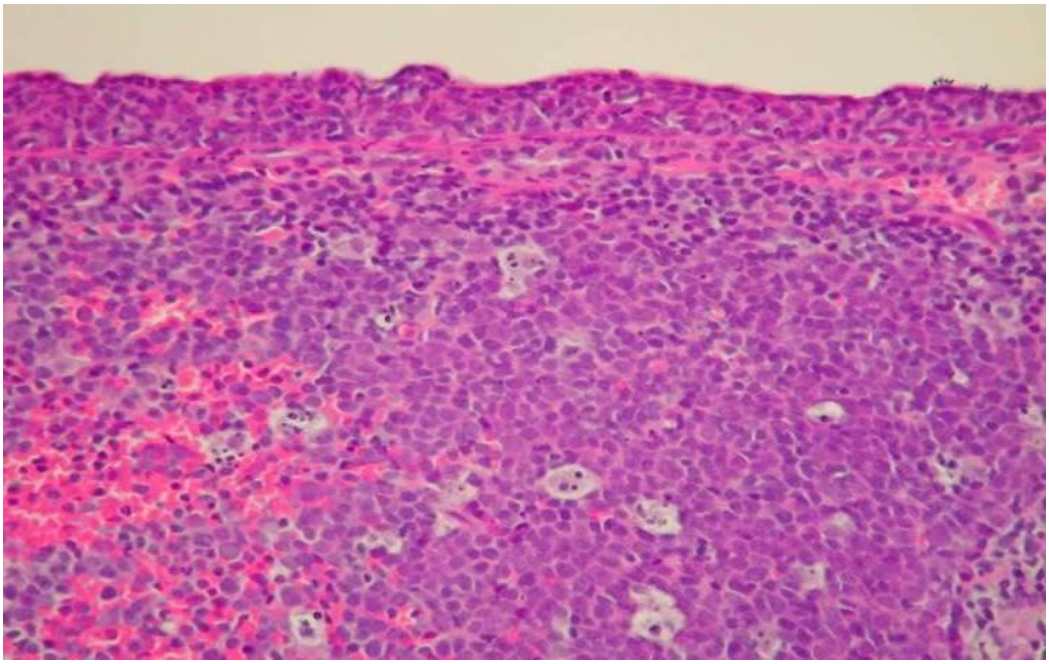

Fig. 5.4.1 Prominent lymphoid proliferation abutting the squamous cyst lining in CLH primarily affecting an intra-parotid lymph node. Prominent tingible body macrophages are evident. H&E, original magnification X40)

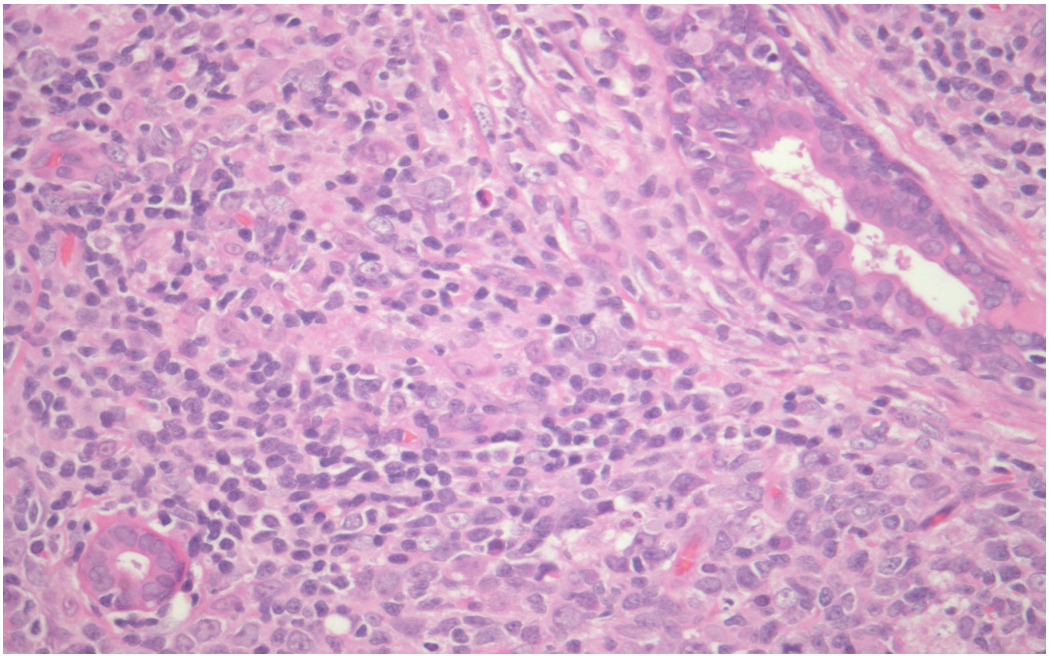

Fig. 5.4.2 Salivary duct remnants within the lymph node parenchyma (H&E, original magnification X40)

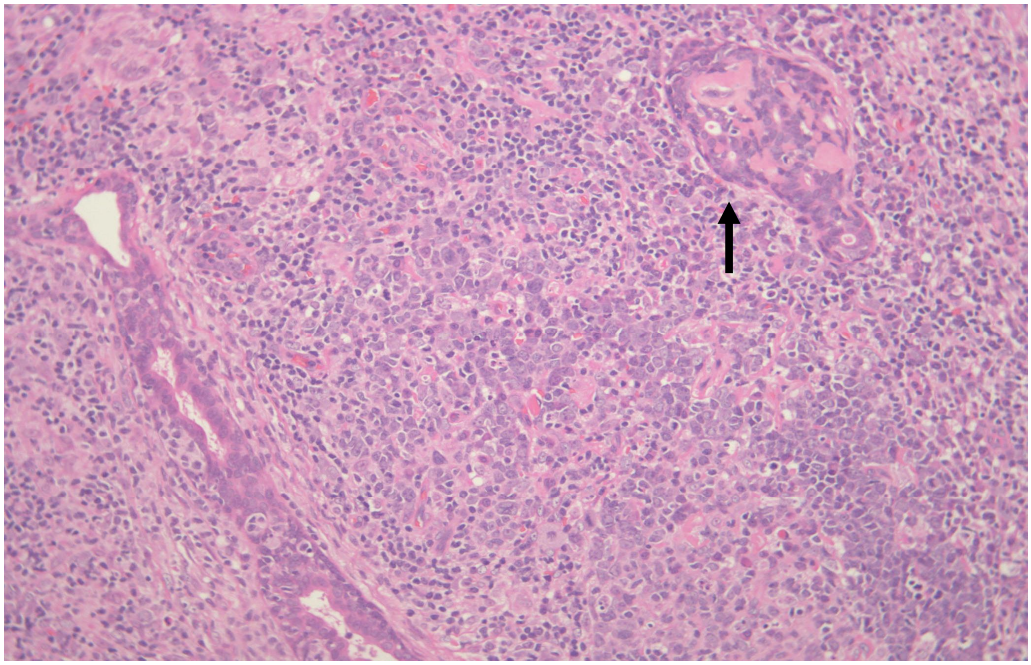

Fig. 5.4.3 Epimyoepithelial islands (arrowed) and salivary duct elements within the lymphoid hyperplasia in a lymph node demonstrating CLH (H&E, original magnification X10)

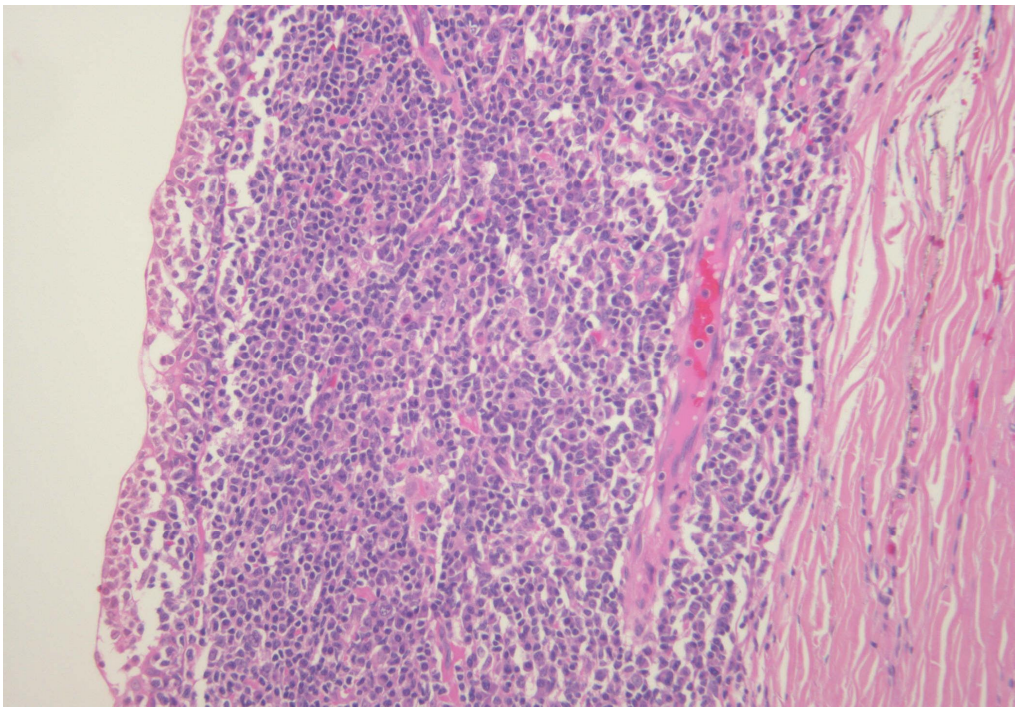

Fig. 5.4.4 CLH shows squamous epithelium cyst lining permeated by lymphocytes with a subepithelial condensation of the lymphoid proliferation (H&E, original magnification X20)

5.4.9. Co-existing infections and other multinucleated giant cells

Co-infection with *Mycobacterium tuberculosis (MTB)* was noted in 3 (2.8%) cases of CLH, with a necrotising granulomatous response with Langhans-type MNGCs noted in the hyperplastic lymphoid proliferation abutting onto the cysts. (Fig. 5.4.5A,B) Acid fast bacilli were confirmed with ZN stains in all 3 cases. Warthin-Finkeldey type MNGCs cells were seen in 34 (31.2%) cases, primarily within the lymphoid infiltrate of Type III cysts (22 cases, 64.7%) although there was no statistical association ($p = 0.76$). These giant cells were distinct from the Langhans-type MNGCs, with no associated necrosis or granulomatous inflammation. These giant cells were more common in CLH of the parotid gland (31 cases, 91.2%), however this was not statistically significant ($p = 0.55$). Similarly the higher proportion of these giant cells occurring within HIV associated changes (33 cases, 97.1%) also showed no statistical significance ($p = 0.5$). The ZN stain failed to demonstrate acid fast bacilli in any of the cases with the Warthin-Finkeldey type MNGCs. A sialolith was noted together with Warthin-Finkeldey type MNGCs in 1 case (0.9%) of simultaneous CLH involvement of salivary gland and lymph nodes.

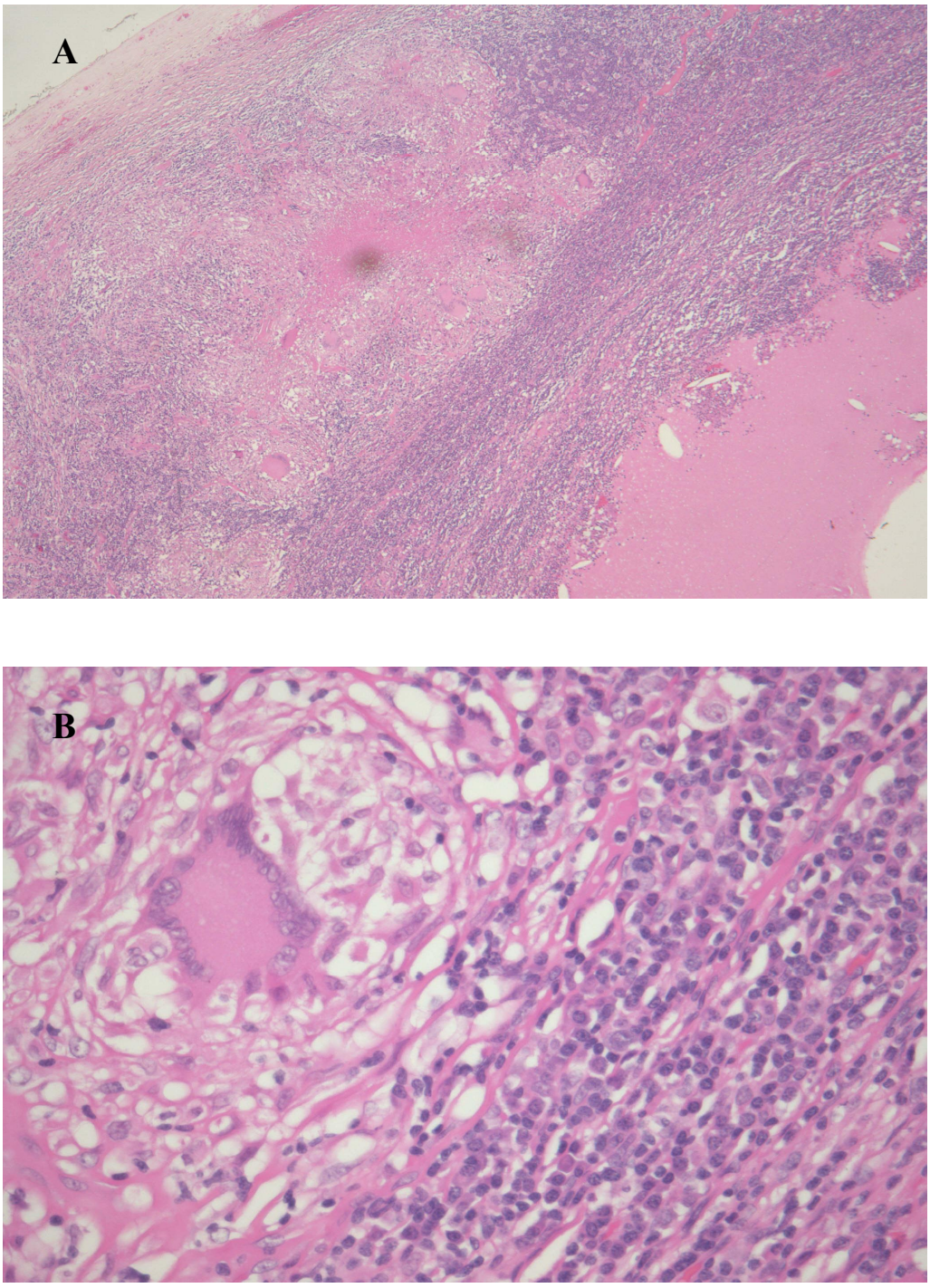

Fig. 5.4.5A,B Necrotising granulomatous inflammation showing a Langhans type MNGC consistent with *MTB* co-infection occurring simultaneously with CLH. [H&E, original magnification: A(X4); B(X40)]

5.5. Immunohistochemical findings

5.5.1. CD20 and CD3

Immunostaining with CD20 and CD3 within the lymph node parenchyma recapitulated that of the normal distribution of CD20+ B-cells and CD3+ T-cells within the germinal centres (GC) and interfollicular (IF) areas respectively. This pattern was mirrored within the hyperplastic lymphoid proliferation accompanying the cystic spaces in CLH. Most cases showed strong CD20 expression within the GCs (> 80%) when compared to a sprinkling of CD3+ T-cells within these areas (which varied from <10 % to areas showing 10 to 50% staining). Abutment of the GCs onto the overlying epithelium was regularly seen thereby giving the appearance of a strong B-cell presence in the subepithelial areas (CD20+). B-cell expression varied greatly throughout the cyst lining (< 10% to areas showing > 80% positivity).

Most of the intraepithelial lymphocytes were of a B-cell lineage (CD20+). B-cell expression varied greatly throughout the cyst lining (< 10% to > 80%) (Fig. 5.5.1) Where the lining was thin, i.e. 1-2 cell layers, few B-cells infiltrated the epithelium as opposed to areas with hyperplastic epithelium where there was a greater representation of B-cells (10 - 50%). Up to 45 % of these B-lymphocytes were seen free lying within the lumen. Permeation of CD3+ T-cells within the cyst lining was noted in only about 10% and especially in areas where the epithelium was hyperplastic. CD3 expression was very strong (> 80%) within the IF areas with representation of CD20+ B-cells ranging between <10% and 50 - 80%. The gland parenchyma showed an increased B-cell proliferation (CD20+) around the ducts with scattered B-cells permeating the gland parenchyma interstitially. CD3+ T-cell proliferation around the ducts was noted;

however there was < 10% permeation of T cells into the adjacent salivary gland parenchyma (Fig. 5.5.2).

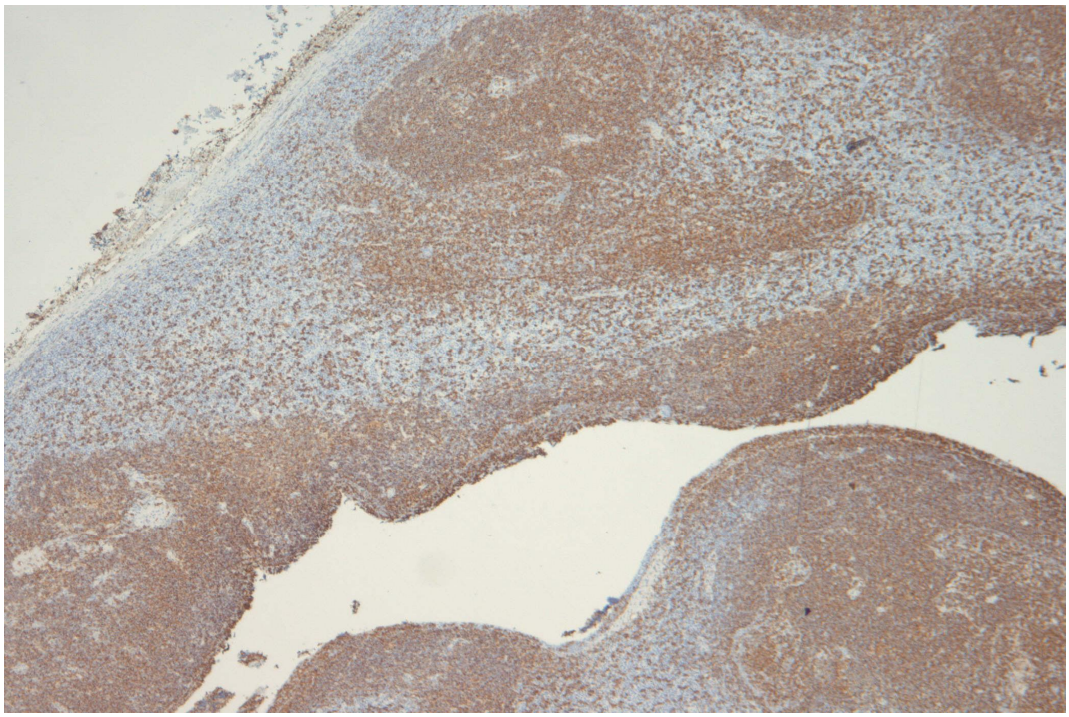

Fig. 5.5.1 Strong reactive immunoexpression of CD20+ B-cells within the germinal centres with lymphocyte permeation through the squamous cyst lining (L26, original magnification X4)

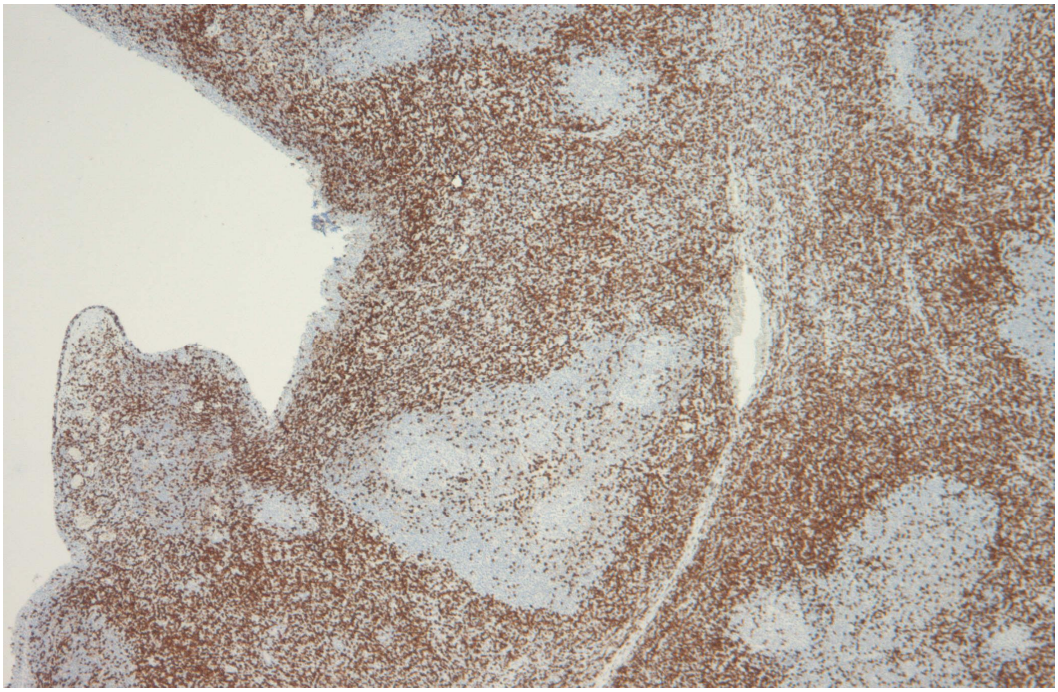

Fig. 5.5.2 CD3 immunopositivity was noted primarily within the interfollicular areas with minimal permeation of the epithelium by CD3+ T cells (Polyclonal, original magnification X4)

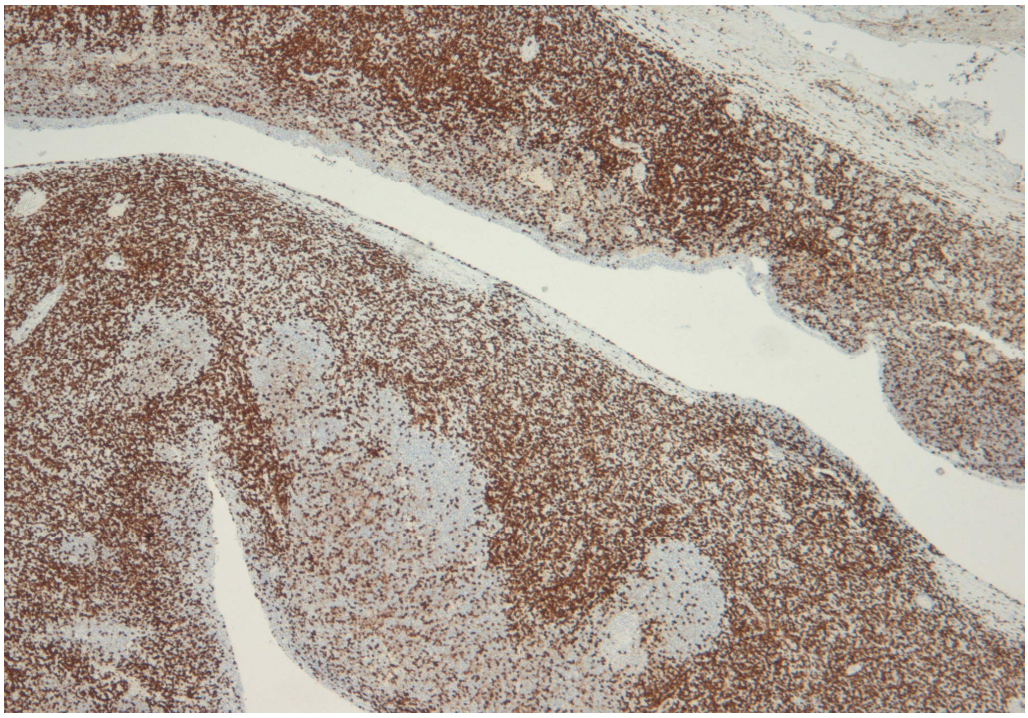

Fig. 5.5.3 CD8 immunostaining mimicked that of CD3 immunoreactivity with a strong CD8+ presence in the interfollicular areas (1A5, original magnification X4)

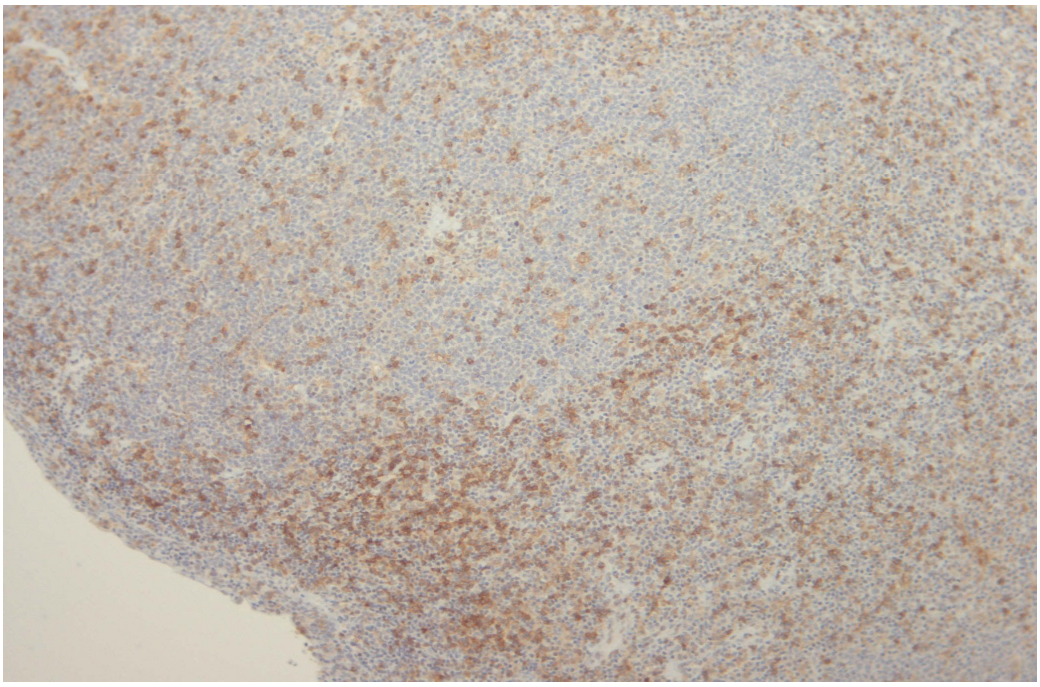

Fig. 5.5.4 CD4 immunoreactivity was not as prominent and intense as the CD8+ immunopositivity within the lymphoid hyperplasia (4B12, original magnification X10)

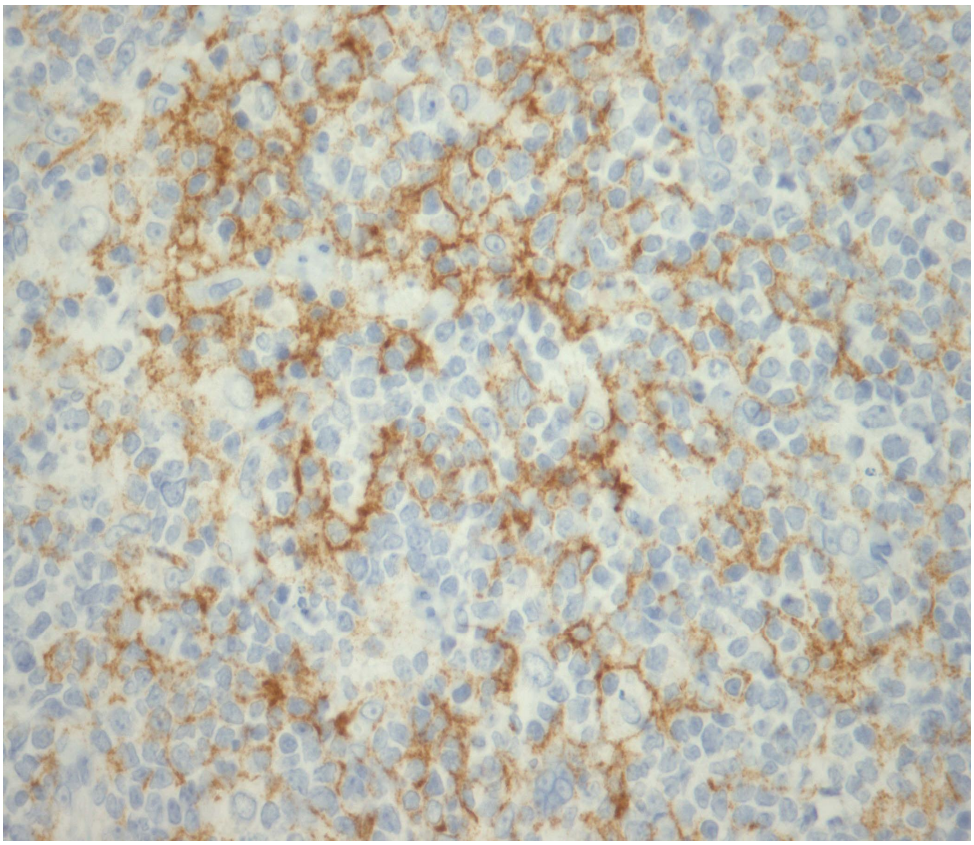

Fig. 5.5.5 p24 immunopositivity within the follicular dendritic cells in the germinal centres of a lymph node affected by CLH (Kal-1, original magnification X40)

5.5.2. CD8 and CD4

There was low to moderate expression of CD8+ T-lymphocytes in the GCs (< 10%; 10 ï 50%), however the staining intensity was generally more intense than the CD3+ and CD4+ T-lymphocytes (< 10%) in the same area. CD4 expression was stronger within the GCs in some cases and ranged from 50-80 %, leaving no clear demarcation between the GC and the IF areas. CD8 and CD4 reactivity was stronger in the IF areas (> 80 %), with CD8 generally being more intense (Figs. 5.5.3 and 5.4.4)

There was <10% permeation of the lining epithelium with CD8+ T cells, with none of the free lying cells within the lumen demonstrating CD8 positivity. The lining epithelium showed 10-50% positivity with CD4 in some cases. CD8 and CD4 positivity in the subepithelial areas which showed vague GC formation was not as marked (50 - 80%) as in the IF areas, and not as marked as the CD3 and CD20 positivity. Permeation of CD8+ cells into the adjacent gland parenchyma was much higher than that of the CD4+ cells; however the CD4+ staining around the entrapped salivary elements within the lymph node was much stronger than that of CD8 positivity. CD4 + T-cells did not permeate the epithelium of the smaller entrapped salivary gland ductules. CD8+ cells however permeated the ductules with a strong band of CD8+ cells surrounding the ducts as well as infiltrating the salivary gland interstitium. The CD8:CD4 ratio was similar in most cases except in a few cases in which the CD8 positivity tended to overshadow CD4 positivity.

5.5.3. p24

An overwhelming 150 of 167 cases (89.8%) stained positive with p24, the HIV antibody (Dako Glostrup, Denmark) including the 18 confirmed HIV positive patients. The p24 positivity was noted mainly within the follicular dendritic reticulum cells (FDRCs) in the GCs (Fig. 5.5.5). 149 of these 150 cases (99.3%) simultaneously showed histological HIV associated changes, an association which was noted to be significant ($p = 0.0003$). 12 cases (7.2%) of the entire sample stained negative for p24, including the 2 confirmed HIV positive patients, even after repeated p24 staining in the latter 2 cases. Even though the lymph nodes showed HIV associated changes, p24 immunostaining proved non-contributory in 5 cases (3.0%). The p24 positive cases showed significantly younger mean and median ages (37.8; 38 years, SD, 10.97) closer to that of the overall study (38.3, 38 years) as opposed the p24 negative cases (45.5; 49 years, SD, 10.41) [$p = 0.03$].

5.6. Study Limitations

The patient hospital records were not easily obtainable and in the majority of cases these files were unavailable. This impacted severely on the study as only 20 patients were confirmed HIV positive even though misplaced pages meant that not all of these cases had the patients CD4+ T- lymphocyte counts and HIV RNA viral loads available. In the remainder, the unavailability of the files meant that other significant data such as CD4 counts and viral loads as well as ARV therapy could not be recorded.

CHAPTER 6

6.0 DISCUSSION

CLH is a frequently encountered yet not adequately recognised entity predominantly affecting the parotid gland in HIV infected patients.[5,34] The reported prevalence of CLH is about 3-6%, yet it remains one of the most common diagnoses for parotid gland enlargement encountered in these patients.[14,65] The current study constitutes the largest global series of patients with CLH (167 cases) to date. Previous sizable studies include those reported by Ihrler *et al*.[5] (100 cases), Wu *et al*.[54] (64 cases) and Shaha *et al.*[43] (50 cases).

The literature suggests that being an HIV infected male is in itself a potential risk factor for developing CLH.[16-18,32-34] Whilst a female predominance is noted in a few studies,[14,54] most published reports show a marked prevalence of CLH in males.[24,32-34] The present study shows no gender bias with a male-to-female ratio of 1.04:1 (85 males, 82 females).

Patients with CLH in the current study ranged from 6 to 65 years, with a median age of 38 years, which is similar to those reported amongst others[18,24,43] by Kreisel *et al.*[86] (38 years), Terry *et al*.[33] (40 years) and Vargas *et al*.[3] (36.4 years). A statistically significant finding in the current study, as previously noted,[8] is the earlier median age of presentation of CLH among females (35 years) when compared to males (40.5 years) ($p = 0.0007$). Our study is also the first to show that CLH affecting both the parotid and

submandibular salivary glands presents at a younger mean age in females (36.5; 31 years respectively; $p = 0.0032$) when compared to the males (40.9; 42.4 years respectively; $p = 0.0035$). Furthermore CLH affecting the parotid glands seems to show a male predominance while cases of submandibular gland involvement seem to occur more frequently in females ($p = 0.27$).

Published reports have shown the incidence of CLH to be about 1-10 % in the HIV infected paediatric population,[8,14] with a primarily male predominance,[85] and with only 1 study showing a higher incidence in females.[14] As with the adult population, the paediatric patients in this study showed no gender bias with the 6 paediatric cases being split equally between males and females and ranging in age from 6 to 10 years (mean, 7.8 years; median, 8 years), which is comparable to the 10 patients in the study by Soberman *et al*.[85] (range: 6 months to 11 years; mean: 5 years) and the 4 patients of Dave *et al*.[14] (range: 7-17 years; mean: 12.8 years). The results of the current study were also very similar to a separate as yet unpublished study done in our department on 47 HIV infected paediatric patients with parotid enlargement which showed an age range of 1 to 13 years (mean; 7.04 years) and a male-to-female ratio of 1.2:1

CLH has been reported to occur in various racial or ethnic groups, including Mongoloid,[44,54] Indian,[42,62] Hispanic,[18] and Caucasian[18,19,32] patients, however most studies report CLH within black patients.[40,75] The entire study population of 167 cases of CLH was black. It is however inaccurate to draw conclusions regarding the racial breakdown of the study population given that the cohort has been entirely from the public sector which by nature of the demographics in South Africa comprises largely

black patients. Racial profiling in this regard is futile as there is great variability depending upon geographic location and therefore race as a risk factor for the development of CLH may not be entirely correct.

It is however, interesting to note that many studies have reported that a genetic association may be responsible for CLH of the parotid gland in black patients. This increased affinity for black patients has been explained as being linked to the major histocompatibility complex antigen (MHC class II), HLA-DR11 (formerly HLA-DR5).[76] The increased expression of HLA-DR11 phenotype is reported to play a role in mediating the immune response to the HIV, especially in patients affected by the DILS.[76]

DILS is a subset of HIV disease manifestation commonly affecting the lungs and the salivary glands and is characterised by a persistent circulating CD8+ lymphocytosis accompanied by diffuse visceral CD8+ lymphocytic infiltration, bilateral parotid gland swelling and cervical lymphadenopathy.[13,27] The genetic association with HLA-DR5 is said to occur in immuno-genetically distinct adults[76] with reports from North America suggesting that the prevalence is highest among the African-American population.[74,75] The evidence suggests that DILS appears to confer a favourable prognosis resulting in a less advanced HIV disease stage and a slower progression to AIDS.[13,73,75] Whether or not the same analogy can be applied to CLH remains to be seen and further long term, cross-comparative studies are needed to determine if CLH is indeed a precursor lesion which could lead to the development of DILS in selected patients.

It is beyond the scope of this study to comment further on the comparisons between CLH and DILS as our cases dealt strictly with patients with a confirmed diagnosis of CLH with no mention being made of the patients possibly having DILS. Also in our series of cases, the presence of co-existing contra-lateral lesions was often omitted from the history and thus true bilateralism could not be confirmed, a feature requisite for the definitive diagnosis of DILS.

Most patients in this study presented with a painless, slow-growing mass on the side of their face, which was cosmetically objectionable. Like many previous reports this study confirms the peculiar affinity of CLH for the parotid salivary gland (84.4%), with occasional involvement of the other salivary glands, tonsils and cervical lymph nodes.[5-10,11-14]

Whilst CLH typically occurs bilaterally, 158 cases (94.6%) were reported as unilateral glandular enlargement and only 9 cases (5.4%) as bilateral parotid enlargements (males:3; females:6). This however does not appear to be a true reflection of the unilateral or bilateral presentation of CLH, as the clinical data accompanying most specimens submitted for histology merely stated the site of the involved gland without any elaboration of contra-lateral glandular involvement. Similar to the study by Dave *et al.*[14] the bilateral cases in this study mainly affected females (F:M = 2:1), which is in contrast to other reports that have shown a marked male dominance for bilateral cases with M:F ratios ranging from 1:1 to 15:1, and some studies showing no females with bilateral CLH involvement.[34,48] Since the clinical data in most cases only stated the side of involvement of the biopsied gland, it is assumed that this side presented with greater

enlargement than the contra-lateral side if involved. In cases of so-called ñunilateral involvementò, it appeared that the patientôs right side (39.3%) was affected more frequently than the left (35%).

The patients in our series presented seeking aid for the facial swelling only with no symptoms of ductal obstruction, pain during meals or xerostomia. Macroscopically the cut surface often showed multiple cystic cavities containing a watery, yellow-brown liquid and with shiny cholesterol crystals occasionally discernible within the fluid (17.4 %) as noted in previous reports.[10,34,43]

The histological features of CLH are well established[3-11,24,34] The histological features observed in our series of 109 cases mirrored that of previous studies and were consistent irrespective of the gland affected or whether they occurred within a salivary gland or lymph node. Classically, there were multicystic or sometimes unicystic epithelial-lined cystic cavities surrounded by dense, hyperplastic lymphoid tissue showing prominent germinal centre formation, seen mainly in the lymph nodes approximating the salivary glands with only occasional exclusive salivary gland involvement.

Contrary to popular belief, CLH predominantly occurred solely within the peri- and intra-parotid lymph nodes (76.1%), followed by mixed intra-glandular lymph node and salivary gland involvement (18.4%), and infrequently with salivary gland involvement only (5.5%). Both the high incidence of CLH within intraglandular lymph nodes[3,10,34] as well as simultaneous lymph node and glandular involvement[5,6,9] has been previously reported. The pathological changes of CLH in both instances are substantial resulting in

this dual occurrence being the source of considerable confusion as to the exact origin of the CLH process. It is unclear as to whether CLH originates within intraparotid lymph nodes or in the salivary gland parenchyma as a result of secondary lymphoid hyperplasia within the salivary gland.

With the use of computer-assisted 3D reconstruction, Ihrler *et al*.[5] showed that the lymphoid cells infiltrate the salivary gland tissue and provoke the formation of LELs of the striated ducts with associated basal cell hyperplasia. The cystic nature of the lesions is then enhanced by duct compression caused by the lymphoid hyperplasia. However, with 76.1% of the cases in this study occurring within intraparotid lymph nodes and the fact that 90 (82.6%) of the cases studied showing entrapped salivary gland elements within the lymph nodes, this study strongly supports the view that the pathogenetic pathway of CLH commences within the entrapped salivary gland inclusions in these lymph nodes. Our findings concur with proponents of this theory who maintain that the well-defined fibrous capsule that is usually found surrounding these cysts as well as its proliferating lymphoid cellular wall hints at its origin from an intraparotid lymph node.[3,10,34] Some studies [1,9] seem to support the stance taken by Ihrler *et al*.,[5] others shown that the overall *unstimulated* salivary flow rates do not differ much between groups of HIV associated and non-HIV associated CLH.[18]

Mandel *et al*.[12] has questioned the possibility of cyst enlargement resulting from ductal obstruction in view of the absence of clinical signs associated with obstruction such as pain and intermittent parotid swellings during meals. It is also well known that intraparotid lymph nodes contain salivary gland acini and ducts which might constitute

the epithelial component of these lesions and in the context of an HIV setting, salivary gland hyperplasia develops with on-going HIV-1 replication as evidenced by the discovery of both HIV-1 major core protein[24] and HIV-1 RNA[11] within these lymph nodes and furthermore, the reactive follicular hyperplasia that is seen histologically in the lymph nodes of patients with PGL is identical to that in CLH.[13,15,24] Thus salivary gland enlargement could be part of PGL, arising from epithelial alterations leading to a reactive lymphoid tissue hyperplasia thereby providing further evidence for an intra-lymph node origin.[1,11]

A recent report on 64 cases of non-HIV associated CLH suggests that the entity is a sort of ógranulation tissue processô attributing cyst formation to be a óthree-fold processô beginning within a non virally-induced sialadenitis background from the parotid parenchyma but not arising from the intraparotid lymph nodes.[54] While these findings seem to suggest a possible differing mode of progression of non-HIV associated CLH, an earlier study concluded that the analogous histological and IHC features in both groups imply an identical pathogenetic pathway.[9]

The increase in CLH can be attributed directly to the spike in HIV incidence. Even though the histological and immunopathological features of both groups are reported to be similar, a comparison of the clinicopathological features shows HIV associated CLH to frequently occur bilaterally, more commonly in males at an earlier age of onset and presenting with larger, more numerous multicystic spaces with an associated lymphadenopathy compared to those in HIV negative patients which are generally solitary and solid.[9,33,54]

Histologic similarity of CLH to SS due to the presence of epimyoepithelial islands has been suggested in earlier studies[16,20] Epimyoepithelial islands were detected in 56% of our cases, within the lymphoid stroma of the gland and more commonly in those cases where CLH occurred predominantly within lymph nodes (80.3%) ($p = 0.13$). Interestingly while the identification of these epimyoepithelial islands appears to be pathognomonic for the LELs seen in SS, their appearance in CLH appears to be a fortuitous ($p = 0.71$).

Furthermore, whereas the lymphoid infiltrate in SS is dominated by CD4+ T lymphocytes, those seen in an HIV setting show predominantly CD8+ cells and the cell of origin of the epimyoepithelial islands in the 2 entities is thought to differ.[12,59,60] In SS the islands result from the proliferation of basal myoepithelial ductal cells whereas in CLH the lining ductal epithelium is thought to proliferate to form the epimyoepithelial island.[12,59,60] While the involvement of the myoepithelial cell in the pathogenesis of CLH has been ruled out immunohistochemically[5] their regular appearance in previous studies warrants further investigation.[34,43] The CD4: CD8 ratio in our study was ~ 1:1, however a probable shortfall in this study was that the myoepithelial cell component was unfortunately not immunohistochemically investigated.

The presence of *MTB* co-infection with CLH as noted previously[3,17,52] was seen in 3 cases. TB commonly affects patients infected with HIV and is an important cause of death in AIDS patients. *MTB* has been shown to preferentially involve the intraglandular lymph nodes as chronic, non-caseating granulomatous inflammation with

few or no MNGCs.[3] In addition to the 3 cases in which Langhans giant cells consistent with TB were identified, Warthin-Finkeldey type MNGCs were noted in 31.2% of cases, primarily within the lymphoid infiltrate ($p = 0.76$). These MNGCs were distinct from the Langhans giant cells and showed no associated necrosis or granulomatous inflammation. Whilst these cells are recognised in the paracortical region of hyperplastic lymph nodes in some patients with AIDS, their exact role is unclear.[42,57,58]

Well described HIV induced morphological changes were apparent within the lymphoid proliferation in each of the 109 CLH cases that were histologically examined. Nonetheless, IHC detection of the HIV-1 p24 antigen in the follicular dendritic cells was performed in all cases in order to elucidate the role of HIV infection in the development of CLH. P24 testing may be used to help diagnose early HIV infection.[87] A significant number of the cases in the present study exhibited simultaneous p24 positivity within a background of microscopic HIV associated change ($p = 0.0003$). Whilst only 20 patients in our sample were confirmed HIV positive, an overwhelming 150 of the 167 cases (89.8%) showed p24 immunopositivity, including 18 (90%) of the confirmed HIV positive cases, a fact consistent with previous studies[5,17,19] Although not conclusively diagnostic, p24 immunopositivity noted in most cases confers a strong correlation between HIV and CLH and the possible state of disease progression.[87] Furthermore the cases staining positive for p24 were significantly younger than those staining negative for p24 ($p = 0.03$). The negative (7.2%) and non-contributory (3.0%) p24 staining observed in a few cases is attributed to the fact that p24 is only detectable during a short window period of time and does not necessarily imply that the patient is HIV negative.[87] The use of HIV p24 antibody in paraffin-embedded tissue has made it

easier to detect HIV infection[87] but very little is known regarding the sensitivity and specificity of this monoclonal HIV p24 antibody against the gag protein of HIV-1, with a reliability of 3.8% being mentioned previously.[69] This latter figures appears disproportionally low and inconsistent with the findings of the current study. The large proportion of positively stained p24 cases in our series of suspected HIV positive patients warrants further investigation into the routine utilisation of this monoclonal p24 antibody as a possible diagnostic tool.

The IHC findings in this study recapitulates that of previous reports and of that seen in HIV induced lymphadenopathy seen in cases of PGL, with intense CD20 positivity of the B-cells within the germinal centres (GC) and the hyperplastic lymphoid follicles around the cystic spaces and moderate CD3 positivity within the T-cells located mainly within the IF areas of the lymphoid proliferation.[3,9,54] The increased intraepithelial B lymphocyte expression within the cyst lining was proportional to the degree of epithelial hyperplasia and is a feature which is consistent with both HIV [9,43,86] and non-HIV associated CLH.[44]

Although CD4+ expression was stronger (50-80%) within the GC in some cases, CD8+ expression generally overshadowed that of CD4+ and our findings are thus in agreement with Maiorano *et al*.[9] who noted an increase in IF CD8+ suppressor cells exceeding that of CD 4+ T helper cell. In most instances our series revealed a ratio of 1:1 for CD4:CD8 expression except in a few cases where decreased expression of CD4 and increased expression of CD8 within the IF areas was noted, consistent with previous findings.[1,5,9] There was an increased proliferation of CD4+ cells around the

entrapped ducts without permeation, as compared to CD8+ cells which readily permeated the ducts and revealed a strong band of CD8+ cells surrounding the duct.

The reactive lymphoid hyperplasia in CLH is an HIV induced atypical lymphoid hyperplasia, which bears a striking resemblance to the reactive lymphoid hyperplasia seen in SS and thus also poses an increased risk for the development of a MALT-type lymphoma. A higher incidence of malignancy is reported within solid parotid masses as opposed to cystic lesions within an HIV infected population.[65] The atypical lymphoid hyperplasia that infiltrates beyond the lymph node capsule and into the glandular parenchyma as noted in the present study raises concern for the development of malignancy.

In addition, the advent of ARV therapy has led to increased survival rates of many HIV infected patients and thus the lifetime risk of developing a malignancy may increase, particularly within the paediatric population. The long duration of these cysts and the concomitant gross facial deformity further heighten suspicion of possible malignant transformation which might be avoided if CLH could be successfully treated or prevented.[64] Whilst malignant transformation remains a strong risk factor, having seen a single case in our department, no cases of malignant transformation have been reported to date in the literature.[64]

A plethora of terms has been used to describe the lymphocytic parotid gland enlargement that is seen in HIV infected individuals including BLEC, BLEL DILS, HIV associated salivary gland disease and AIDS related lymphadenopathy leading to

great confusion regarding the nature of this entity. In our study we have opted to use the terms ***cystic lymphoid hyperplasia*** **(**CLH) or if in the parotid gland, *CLHP*, to describe the lymphocytic major salivary gland enlargement that is seen to affect HIV infected individuals. Terms such as HIV associated salivary gland disease[18] and AIDS related lymphadenopathy are broad categorisations whilst we believe that usage of BLEL and BLEC without qualification is best avoided as several cystic processes affecting the parotid glands present with these characteristic cystic LELs.

Whilst the term CLH has been used routinely, though not consistently, in our diagnostic services to describe these LELs, perhaps the more appropriate terminology would be *cystic lymphoid hyperplasia of HIV and AIDS*. This however may be too harsh a labelling term which could have serious social connotations, especially in the absence of clinical testing to confirm an HIV infection. We therefore feel that *CLH*, and if in the parotid gland *CLHP*, are appropriate terms as they accurately identify the underlying lympho-proliferative pathogenic pathway as well as the site of involvement.

With the global rise in HIV prevalence and the advent of ARVs new challenges lie ahead with regards to a rise in entities such as CLH for which treatment is frequently being sought as it is increasingly being recognised as a sign of an underlying HIV infection within communities. It is promising to note that newer treatment modalities reported in studies from Cape Town[83] and Pretoria[84] specifically for CLH show decreased rates of recurrence thereby reducing the effects of this entity.

CHAPTER 7

7.0 CONCLUSION

CLH is the preferred term to describe an increasingly common extraoral manifestation of patients infected with HIV and treatment is frequently being sought as the facial enlargement, particularly due to the parotid gland, is particularly disfiguring. This clinicopathological study is to the best of our knowledge the largest global series of cases of HIV associated CLH (167 cases).

Clinical Parameters:

CLH showed no gender bias, with a male-to-female ratio of 1.04:1. Females were affected with CLH at a significantly younger median age (35 years) when compared to males (40.5 years) ($p = 0.0007$). All affected patients were being black. Black females in the 3rd decade posed the greatest risk, either side being equally affected.

CLH showed an overwhelming predilection for the parotid gland (84%), followed by the submandibular gland (13%). Parotid gland involvement showed a male predominance whilst cases affecting the submandibular gland were more frequent in females ($p = 0.3$). The median age of CLH presentation in females was significantly earlier in the parotid (35 years) and submandibular glands (33 years) ($p = 0.0032$) when compared to males (40; 41.5 years respectively) ($p = 0.0035$). Bilateral glandular enlargement of the parotid showed a female predominance of 2:1.

Histology, immunopathology and pathogenesis:

The unprecedented majority for CLH occurred within the peri- and intra-parotid lymph nodes (76.1%). A high proportion of cases (82.6%) showed entrapped salivary gland elements within the lymph nodes suggesting that these structures are involved in the initiation of this entity. In the absence of confirmed HIV status, the HIV p24 antibody confirmed 90% specificity within all cases of CLH, corroborating the strong association of this entity with HIV and AIDS. The CD4: CD8 ratio was ~1: 1, except in a few cases where the decreased expression of CD4 and increased expression of CD8 within the interfollicular areas.

Even though there remains a role for primary salivary gland origin for CLH, this study strongly supports origin of CLH following ductal ectasia of entrapped salivary gland inclusions within atypical lymphoid hyperplasia arising within lymph nodes in the context of an HIV setting. The pathogenesis of CLH should thus be re-visited. Furthermore, it is imperative that CLH be classified as an orofacial lesion strongly associated with HIV and AIDS.

CHAPTER 8

8.0 APPENDICES

8.1. Appendix 1: Raw data

8.2. Appendix 2: Ethics clearance certificate

8.3. Appendix 3: Histology and Immunohistochemistry data collection 1sheet

8.1. Appendix 1: Raw Data

Year	N	TJL	A	G	R	Site.	Dx	P24	HIV Changes	Confirmed HIV	Location	U/M-Cystic	TYPE	EMI	MNGC's
2000	1	196	40	F	B	PG	CLH	p	Y	N	LN	M	3	Y	Y
2000	2	1020	30	F	B	PG	CLH	p	Y	N	LN	M	3	Y	Y
2000	3	1032/3	65	F	B	PG	CLH	p	Y	N	LN	M	3	N	N
2001	4	364	47	M	B	PG	CLH	p	Y	N	LN	M	3	Y	N
2001	5	373	31	F	B	PG	CLH	p	Y	N	LN	M	3	Y	N
2001	6	435	37	M	B	Sbm	CLH	n	Y	N	LN	M	3	Y	Y
2001	7	455	23	F	B	PG	CLH	p	Y	N	LN	M	3	Y	N
2001	8	491	53	M	B	PG	CLH	p	Y	N	LN	M	3	Y	N
2001	9	559	26	F	B	Sbm	CLH	p	Y	N	LN	U	3	N	N
2001	10	686	33	F	B	PG	CLH	p	Y	N	LN	M	3	Y	N
2001	11	786	26	F	B	PG	CLH	p	Y	N	LN	M	3	N	N
2001	12	808		M	B	PG	CLH	p	Y	N	LN + GL	M	3	Y	N
2001	13	960	44	M	B	Sbm	CLH	p	Y	N	LN	M	3	Y	N
2001	14	992	43	M	B	PG	CLH	p	Y	N	LN	M	3	N	N
2001	15	1025/6	31	F	B	*PG*	CLH	p	Y	N	LN	M	3	Y	N
2001	16	1094	51	F	B	PG	CLH	p	Y	N	LN	M	3	N	Y
2001	17	78	37	*F*	B	*PG*	CLH	nc	Y	N	LN + GL	M	2	Y	Y

2002	18	194	50	M	B	PG	CLH	p	Y	Y	GL	M	1 & 2	N	N
2002	19	207	27	M	B	PG	CLH	p	Y	N	LN	M	1	N	N
2002	20	261	39	F	B	PG	CLH	nc	Y	N	LN	M	2	N	Y
2002	21	274	40	F	B	*Mand*	CLH	p	Y	N	LN	M	3	Y	N
2002	22	294	32	F	B	PG	CLH	nc	Y	N	LN + GL	M	2	N	N
2002	23	423	38	F	B	PG	CLH	p	Y	N	LN + GL	M	2	Y	N
2002	24	445/6	45	F	B	PG	CLH	p	Y	Y	LN	M	3	Y	N
2002	25	490	34	M	B	PG	CLH	p	Y	N	LN	M	3	N	N
2002	26	513	28	F	B	PG	CLH	p	Y	N	LN	M	3	Y	N
2002	27	514	44	F	B	PG	CLH	p	Y	N	LN + GL	M	3	Y	N
2002	28	552	26	F	B	PG	CLH	p	Y	N	LN	M	3	Y	Y
2002	29	741	29	M	B	PG	CLH	p	Y	N	LN	M	3	Y	Y
2002	30	786/7	48	*M*	B	*PG*	CLH	p	Y	N	LN	M	3	N	Y
2002	31	946	35	F	B	PG	CLH	p	Y	N	LN	M	3	Y	N
2002	32	989	33	F	B	PG	CLH	p	Y	N	LN	M	3	Y	N
2002	33	1007	36	M	B	Sbm	CLH	p	Y	N	LN	M	3	Y	Y
2002	34	1031	49	F	B	PG	CLH	p	Y	N	LN	M	3	Y	Y
2002	35	1066	32	F	B	PG	CLH	p	Y	N	LN	M	2	Y	Y
2002	36	1120	42	M	B	PG	CLH	p	Y	Y	LN	M	2	Y	N
2002	37	1123	26	F	B	PG	CLH	p	Y	N	LN	M	3	N	Y

2002	38	1128	38	F	B	PG	CLH	p	Y	N	LN	M	3	N	N
2002	39	1131	45	F	B	PG	CLH	p	Y	N	LN	M	3	N	N
2002	40	1136	58	M	B	PG	CLH	p	Y	N	LN	M	2	N	Y
2002	41	1153	50	M	B	PG	CLH	p	Y	N	LN	M	2	Y	N
2002	42	1237	34	F	B	PG	CLH	p	Y	N	LN	M	3	Y	N
2002	43	1272	51	M	B	PG	CLH	p	Y	N	LN + GL	M	2	Y	N
2002	44	1294	32	F	B	PG	CLH	p	Y	N	LN	M	3	Y	N
2002	45	1378		M	B	*PG*	CLH	p	Y	N	GL	M	1	N	Y
2003	46	21	9	M	B	PG	CLH	p	Y	N	GL	M	1	N	Y
2003	47	26	56	M	B	PG	CLH	p	Y	N	LN + GL	M	2	N	N
2003	48	267	38	M	B	PG	CLH	p	Y	N	LN + GL	M	2	N	N
2003	49	294	40	M	B	PG	CLH	p	Y	N	LN	M	3	N	N
2003	50	312	38	M	B	PG	CLH	p	Y	N	LN	M	3	N	N
2003	51	492	26	F	B	PG	CLH	p	Y	N	LN	M	3	Y	N
2003	52	545	20	F	B	PG	CLH	p	ns	N	LN	M	2	N	Y
2003	53	549	43	M	B	PG	CLH	p	Y	N	LN + GL	M	2	N	Y
2003	54	732	51	M	B	PG	CLH	p	Y	N	LN + GL	M	2	Y	Y
2003	55	1065	49	F	B	PG	CLH	p	Y	N	LN + GL	M	2	Y	Y
2003	56	1080	48	M	B	PG	CLH	n	Y	Y	LN	M	3	Y	Y
2003	57	1139	45	M	B	PG	CLH	p	Y	N	LN	M	3	Y	Y

2003	58	1193	41	F	B	PG	CLH	p	Y	N	LN	M	3	Y	Y
2003	59	1201	49	F	B	PG	CLH	p	Y	N	LN	M	3	N	N
2003	60	1267	31	F	B	*Neck*	CLH	p	Y	N	LN	M	3	Y	Y
2003	61	1284/5	42	M	B	*PG*	CLH	p	Y	Y	LN	M	3	Y	Y
2003	62	1343	28	F	B	PG	CLH	nc	Y	N	LN	M	3	N	Y
2003	63	1374	35	M	B	PG	CLH	p	Y	N	LN	M	3	N	N
2003	64	1385	41	F	B	PG	CLH	p	Y	N	LN	M	2	N	N
2003	65	1401	23	F	B	PG	CLH	p	Y	N	LN	M	3	N	Y
2004	66	89	47	F	B	Sbm	CLH	p	Y	N	LN	M	3	N	N
2004	67	159	58	F	B	PG	CLH	p	Y	N	LN	M	3	N	Y
2004	68	357	35	F	B	Sbm	CLH	n	ns	N	GL	U	1	N	N
2004	69	361	58	M	B	PG	CLH	n	Y	N	LN	M	3	N	N
2004	70	940	53	M	B	PG	CLH	p	Y	N	LN	M	2	Y	Y
2004	71	1141	35	F	B	PG	CLH	p	Y	Y	LN	M	3	Y	N
2004	72	1343	26	F	B	Sbm	CLH	p	Y	Y	LN	M	3	Y	N
2005	73	37	54	M	B	Sbm	CLH	p	Y	Y	GL	M	1	Y	N
2005	74	97		M	B	Sbm	CLH	p	Y	N	LN	M	2	N	N
2005	75	385	23	F	B	PG	CLH	p	Y	N	LN	M	3	N	N
2005	76	702/3	6	F	B	*PG*	CLH	p	Y	Y	LN + GL	M	2	Y	N
2005	77	921	36	F	B	Sbm	CLH	p	Y	Y	LN	M	3	N	N

2005	78	1129	30	M	B	PG	CLH	n	Y	N	LN	M	3	N	Y
2005	79	1261	40	M	B	PG	CLH	p	Y	N	LN + GL	M	2	N	N
2005	80	1276	41	M	B	PG	CLH	p	Y	N	LN + GL	M	3	N	Y
2006	81	441	64	M	B	PG	CLH	p	Y	N	LN + GL	M	2	N	N
2006	82	645	43	F	B	PG	CLH	p	Y	N	LN	M	3	Y	N
2006	83	853	46	M	B	PG	CLH	p	Y	Y	LN	M	3	Y	N
2006	84	946	33	F	B	PG	CLH	p	Y	N	LN	M	3	Y	N
2006	85	947	39	M	B	PG	CLH	p	Y	N	LN + GL	M	2	N	Y
2006	86	1053	46	M	B	Sbm	CLH	p	Y	N	LN	M	3	Y	N
2007	87	261	26	F	B	Sbm	CLH	p	Y	N	LN	M	3	N	N
2007	88	408	34	M	B	PG	CLH	p	Y	N	LN	M	3	Y	N
2007	89	514	27	F	B	PG	CLH	p	Y	N	LN	M	3	Y	N
2007	90	607	23	F	B	PG	CLH	p	Y	N	LN	M	3	Y	N
2008	91	157	48	F	B	PG	CLH	p	Y	N	LN	M	2	Y	N
2008	92	213	53	M	B	PG	CLH	n	Y	Y	LN + GL	M	2	Y	N
2008	93	230	45	F	B	PG	CLH	p	Y	N	LN + GL	M	2	Y	N
2008	94	339	49	F	B	PG	CLH	p	Y	Y	LN	M	3	N	N
2008	95	412	54	M	B	PG	CLH	p	Y	N	LN	M	3	N	N
2008	96	415	38	M	B	PG	CLH	p	Y	N	LN + GL	M	2	N	N
2008	97	468	34	F	B	PG	CLH	p	Y	Y	LN	M	2	Y	N

2008	98	486	44	F	B	PG	CLH	p	Y	Y	LN	M	3	N	N
2008	99	867	37	M	B	PG	CLH	p	Y	Y	LN	M	3	Y	N
2008	100	970	51	F	B	PG	CLH	p	Y	N	LN	M	3	Y	N
2008	101	976	34	M	B	PG	CLH	p	Y	N	LN	M	3	Y	N
2008	102	1027	36	M	B	Sbm	CLH	p	Y	Y	LN	M	3	Y	N
2009	103	382	37	M	B	PG	CLH	p	Y	N	LN	M	3	Y	N
2009	104	455	56	M	B	PG	CLH	p	Y	N	LN	M	3	Y	Y
2009	105	487	8	F	B	*Neck*	CLH	p	Y	N	LN	M	3	N	N
2009	106	488	29	F	B	PG	CLH	p	Y	N	LN	M	3	N	N
2009	107	817	50	M	B	*Sbl*	CLH	n	Y	N	GL	M	1	N	N
2009	108	84958	30	M	B	PG	CLH	nc	Y	N	LN	M	3	Y	Y
2009	109	69801	32	M	B	PG	CLH	p	Y	N	LN + GL	M	3	Y	N
2001	110	81	58	F	B	PG	CLH	n	ns	N					
2009	111	258	38	M	B	PG	CLH	p	Y	N					
2008	112	6572	49	M	B	PG	CLH	p	Y	N					
2008	113	10651	36	F	B	PG	CLH	p	Y	N					
2008	114	12103	47	M	B	Sbm	CLH	p	Y	N					
2008	115	17976	43	M	B	PG	CLH	p	Y	N					
2008	116	36560	51	M	B	PG	CLH	p	Y	N					
2008	117	66021	40	M	B	PG	CLH	p	Y	N					

2008	118	68166	10	M	B	PG	CLH	p	Y	N
2008	119	77226	36	M	B	PG	CLH	p	Y	N
2008	120	66531	28	F	B	Sbm	CLH	p	Y	N
2007	121	6134	23	F	B	PG	CLH	p	Y	N
2007	122	5853	33	F	B	PG	CLH	p	Y	N
2007	123	9476	38	F	B	PG	CLH	p	Y	N
2007	124	22433	6	M	B	PG	CLH	p	Y	N
2007	125	23377	47	M	B	PG	CLH	p	Y	N
2007	126	60994	52	M	B	PG	CLH	p	Y	N
2007	127	65126	50	F	B	*PG*	CLH	p	Y	N
2007	128	66192	43	F	B	PG	CLH	p	Y	N
2007	129	69135	37	F	B	PG	CLH	p	Y	N
2007	130	73713	46	F	B	PG	CLH	p	Y	N
2006	131	6126	35	F	B	PG	CLH	p	Y	N
2006	132	11979	42	F	B	PG	CLH	p	Y	N
2006	133	17217	35	F	B	Sbm	CLH	p	Y	N
2006	134	23396	30	F	B	*PG*	CLH	p	Y	N
2006	135	54439	36	F	B	PG	CLH	p	Y	N
2006	136	57624	41	M	B	PG	CLH	p	Y	N
2006	137	58268	33	M	B	PG	CLH	p	Y	N

2006	138	62261	49	M	B	PG	CLH	p	Y	Y
2005	139	5445	27	M	B	PG	CLH	p	Y	N
2005	140	31356	26	M	B	PG	CLH	p	Y	N
2005	141	31401	47	M	B	PG	CLH	p	Y	N
2005	142	36949	39	M	B	PG	CLH	p	Y	N
2005	143	36951	40	M	B	PG	CLH	p	Y	N
2005	144	50170	34	M	B	PG	CLH	p	Y	N
2005	145	49956	39	M	B	Sbm	CLH	p	Y	N
2005	146	50630	42	M	B	PG	CLH	p	Y	Y
2005	147	51811	28	F	B	Sbm	CLH	p	Y	N
2005	148	58837	33	M	B	PG	CLH	p	Y	N
2005	149	59022	50	F	B	*Cerv LN*	CLH	n	Y	N
2005	150	63001	36	F	B	PG	CLH	n	Y	N
2005	151	62991	33	F	B	Sbm	CLH	p	Y	N
2005	152	63904	34	M	B	PG	CLH	n	Y	N
2004	153	5999	30	M	B	PG	CLH	p	Y	N
2004	154	6796	33	M	B	PG	CLH	p	Y	N
2004	155	8250	38	M	B	PG	CLH	p	Y	N
2004	156	11399	27	F	B	PG	CLH	p	Y	N
2004	157	11666	38	M	B	PG	CLH	p	Y	N

2004	158	15418	35	F	B	Sbm	CLH	p	Y	N
2004	159	17138	44	M	B	PG	CLH	p	Y	N
2004	160	23896	40	M	B	PG	CLH	p	Y	Y
2004	161	24328	57	M	B	PG	CLH	n	Y	N
2004	162	24855	8	F	B	Sbm	CLH	p	Y	N
2004	163	26565	53	M	B	PG	CLH	p	Y	N
2004	164	29988	45	M	B	*PG*	CLH	p	Y	N
2004	165	37669	32	F	B	PG	CLH	p	Y	N
2004	166	49045	35	M	B	PG	CLH	p	Y	N
2004	167	52410	40	F	B	Sbm	CLH	p	Y	N

Key:

N: Case number; A: Age; G: Gender; R: Race

Dx: Diagnosis

P24: p24 staining result

Location: LN: lymph node; GL: Gland

U/M cystic: Uni or multi-cystic

EMI: Epimyoepithelial islands

MNGC: Multinucleated giant cells

8.2. Appendix 2: Ethics Clearance certificate

UNIVERSITY OF THE WITWATERSRAND, JOHANNESBURG

Division of the Deputy Registrar (Research)

HUMAN RESEARCH ETHICS COMMITTEE (MEDICAL)
R14/49 Dulabh

CLEARANCE CERTIFICATE	**PROTOCOL NUMBER M080927**
PROJECT	A Clinico-Pathological Study of HIV-Associated Cystic Lymphoid Hyperplasia
INVESTIGATORS	Dr S Dulabh
DEPARTMENT	Division of Oral Pathology
DATE CONSIDERED	08.09.26
DECISION OF THE COMMITTEE*	Approved unconditionally

Unless otherwise specified this ethical clearance is valid for 5 years and may be renewed upon application.

DATE 08.09.29 **CHAIRPERSON** .....
pp (Professor P E Cleaton Jones)

*Guidelines for written 'informed consent' attached where applicable

cc: Supervisor : Dr S Meer

DECLARATION OF INVESTIGATOR(S)

To be completed in duplicate and **ONE COPY** returned to the Secretary at Room 10004, 10th Floor, Senate House, University.
I/We fully understand the conditions under which I am/we are authorized to carry out the abovementioned research and I/we guarantee to ensure compliance with these conditions. Should any departure to be contemplated from the research procedure as approved I/we undertake to resubmit the protocol to the Committee. **I agree to a completion of a yearly progress report.**

PLEASE QUOTE THE PROTOCOL NUMBER IN ALL ENQUIRIES

8.3. Appendix 3: Histology and Immunohistochemistry data collection sheet

CASE	YEAR	TJL	SITE	LOCATION LYMPH NODE VS GLAND	U/M CYSTIC	LUMEN CONTENT	EPITHELIAL LINING	INFLAMMATION INTO EPITHELIUM	SUBEPITHELIAL CONDENSATION	INTENSITY OF I INFLAMMATION	PARENCHYMA DESTRUCTION	DUCT CHANGES
1	2000	196	PG	LN	M	Empty	Resp. Type	Chronic	Chronic	Moderate	Severe, focal	Mild atrophy
2		1020	PG	LN	M	Mucoid Material	Squamous	Chronic	Intense	Intense	Generalised	Atrophy + Duct dilatation
3		1032/3	PG	LN	M	Mucoid Material	Sq	Chronic	Chronic	Intense	No	Mild Atrophy
4	2001	364	PG	LN	M	Mucoid Material	Sq + Resp	Moderate	Moderate	Moderate	Severe	Marked dilatation
5		373	PG	LN	M	Mucoid Material	Sq + Resp	Chronic	Chronic	Intense	CLH change	Atrophy + Duct dilatation
6		435	SBM	LN	M	Mucoid Material	Sq	Moderate	Moderate	Moderate	Severe	Atrophy + Duct dilatation
7		455	PG	LN	M	Mucoid Material	Sq + Resp	Mild	Moderate	Moderate	No	Mild Atrophy
8		491	PG	LN	M	Mucoid Material	Sq + Resp	Intense	Intense	Intense	Mild	Duct dilatation
9		559	SBM	LN	U	Mucoid Material	Sq + Resp	Chronic	Chronic	Moderate	No	Mild Atrophy
10		686	PG	LN	M	Mucoid Material	Sq + Resp	Intense	Chronic	Intense	CLH change	None
11		786	PG	LN	M	Mucoid Material	Sq + Resp	Intense	Moderate	Mild Chronic	No	None
12		808	PG	LN + GL	M	Mucoid Material	Sq + Resp	Intense	Intense	Mild Chronic	Focal change	Ductal dilatation
13		960	SBM	LN	M	Acute/chronic inflam	Sq + Resp	Mild	Mild	Moderate	No	No
14		992	PG	LN	M	Mucoid Material	Sq + Resp	Intense	Moderate	Moderate	No	No
15		1025/6	PG	LN	M	Mucoid Material	Sq + Resp	Intense	Intense	Chronic	No	No
16		1094	PG	LN	M	Mucoid Material	Sq + Resp	Intense	Moderate	Intense	No	No
17		78	PG	LN + GL	M	Mucoid Material	Sq + Resp	Moderate	Moderate	Intense	Dystrophic calc	Mild dilatation
18	2002	194	PG	GL	M	Mucoid Material	Sq + Resp	Moderate	Mild	Intense	Severe	Duct dilatation
19		207	PG	LN	M	Mucoid Material	Sq + Resp	Mild	Mild	Mild	Focal change	Atrophy + Duct dilatation
20		261	PG	LN	M	Mucoid Material	Sq + Resp	Moderate	Moderate	Chronic	No	Duct dilatation
21		274	Mand	LN	M	A/C chrn infl	Sq	Intense	Intense	Intense	No	Duct dilatation
22		294	PG	LN + GL	M	A/C chrn infl	Sq + Resp	Moderate	Intense	Chronic	Focal change	Duct dilatation
23		423	PG	LN + GL	M	Mucoid Material	Sq + Resp	Moderate	Moderate	Chronic	No	No
24		445/6	PG	LN	M	Mucoid Material	Sq + Resp	Mild	Mild	Chronic	Focal	No

CASE	LYMPH NODE CHANGES			TYPE			P24	EMI	MNGC	CO INFXN	HIV CHANGES	CD 20%	CD 3%	CD 8%	CD 4%
	CAPSULE	S. CAPS SINUS	ENT S.G.	T1	T2	T3									
1	Y					✓	P	N	N	N	Y				
2	Y	Y	Y			✓	P	Y	Y	N	Y				
3	Y	Y	Y			✓	P	N	N	N	Y				
4			Y			✓	P	Y	N	N	Y				
5			Y			✓	P	Y	N	N	Y				
6	Y	Y	Y			✓	N	Y	Y	N	Y				
7	Y	Y	Y			✓	P	Y	N	N	Y				
8	Y		Y			✓	P	Y	N	N	Y				
9	Y	Y				✓	P	N	N	N	Y				
10	Y	Y	Y			✓	P	Y	N	N	Y				
11	Y					✓	P	N	N	N	Y				
12	Y	Y	Y			✓	P	Y	N	N	Y				
13	Y	Y	Y			✓	P	Y	N	N	Y				
14	Y	Y	Y			✓	P	N	N	N	Y				
15	Y		Y			✓	P	Y	N	N	Y				
16	Y	Y	Y			✓	P	N	Y	N	Y				
17	Y	Y	Y		✓		Nc	Y	Y	N	Y				
18				✓	✓		P	N	N	N	Y	80 GC, 10 IF	10 GC, 80 IF	10 GC, 80 IF	10 GC, 60 IF
19			Y	✓			P	N	N	N	Y				
20	Y	Y	Y		✓		Nc	N	Y	N	Y				
21	Y	Y	Y			✓	P	Y	N	N	Y				
22	Y	Y	Y		✓		Nc	N	N	N	Y				
23	Y	Y	Y		✓		P	Y	N	N	Y				
24		Y	Y			✓	P	Y	N	N	Y	70 GC, 40 IF	30 GC, 80 IF	30 GC, 80 IF	50 GC, 70 IF

CASE	YEAR	TJL	SITE	LOCATION L/N VS GL	U/M CYSTIC	LUMEN CONTENT	EPITHELIAL LINING	INFL PERM INTO EPI	SUBEPI CONDENSTN	INTENSITY INFL INFIL	PARENCHYMA DESTRUCT	DUCT CHANGES
25	2002	490	PG	LN	M	Muc Mat	Sq + Resp	Mild	Mild	Chrn	Focal fibrosis	Duct dilatn
26		513	PG	LN	M	Muc Mat	Sq + Resp	Mild	Mild	Chrn	No	No
27		514	PG	LN + GL	M	Muc Mat	Sq + Resp	Mild	Mild	Chrn	CLH change	Dysthr Calcif
28		552	PG	LN	M	Empty	Sq + Resp	Mod	Mod	Chrn	Severe	No
29		741	PG	LN	M	Muc Mat	Sq + Resp	Int	Int	Chrn	No	No
30		786/7	PG	LN	M	Empty	Sq + Resp	Mod	Mod	Chrn	No	Duct dilatn
31		946	PG	LN	M	Muc Mat	Sq + Resp	Mild	Mild	Chrn	Focal change	No
32		989	PG	LN	M	A/C Inflam	Sq + Resp	Mild	Mild	Mod	No	No
33		1007	SBM	LN	M	Blood + A/C Infl	Sq + Resp	Mild	Mild	Chrn	No	No
34		1031	PG	LN	M	Empty	Sq + Resp	Mild	Mild	Chrn	No	No
35		1066	PG	LN	M	Blood + A/C infl	Sq + Cuboid	Mod	Mod	Chrn	Mild Atrophy	Duct dilatn
36		1120	PG	LN	M	Muc Mat	Sq + Resp	Mild	Mild	Chrn	Focal destr	Duct dilatn
37		1123	PG	LN	M	Muc Mat	Sq + Resp	Mod	Mod	Chrn	Focal change	Duct dilatn
38		1128	PG	LN	M	Muc Mat	Sq + Resp	Int	Int	Chrn	No	No
39		1131	PG	LN	M	Muc Mat	Sq + Resp	Mod	Mod	Chrn	No	No
40		1136	PG	LN	M	Empty	Sq + resp	Mild	Mild	Chrn	CLH change	Atr + Duct dilatn
41		1153	PG	LN	M	Muc Mat	Sq + Resp	Mild	Mild	Chrn	Clh change	Duct dilatn
42		1237	PG	LN	M	Muc Mat	Sq + Resp	Mod	Mod	Chrn	No	No
43		1272	PG	LN + GL	M	Muc Mat	Sq + Resp	Int	Int	Chrn	Severe	Atr + duct dilatn
44		1294	PG	LN	M	Muc Mat	Sq + Resp	Int	Int	Chrn	No	No
45		1378	PG	GL	M	A/C infl	Sq	Mod	Mod	Chrn	CLH change	Duct dilatn
46	2003	21	PG	GL	M	A/C infl	None	None	None	Chrn	No	No
47		26	PG	LN + GL	M	Muc Mat	Sq + Resp	Mod	Mod	Chrn	CLH change	Atr + duct dilatn
48		267	PG	LN + GL	M	Muc Mat	Sq + Resp	Mod	Mod	Int	Mild Atr	Duct dilatn

CASE	LYMPH NODE CHANGES			TYPE			P24	EMI	MNGC	CO INFXN	HIV CHANGES	CD 20%	CD 3%	CD 8%	CD 4%
	CAPSULE	S. CAPS SINUS	ENT S.G.	T1	T2	T3									
25	Y	Y	Y			✓	P	N	N	N	Y				
26	Y	Y	Y			✓	P	Y	N	N	Y				
27	Y	Y	Y			✓	P	Y	N	N	Y				
28	Y	Y	Y			✓	P	Y	Y	N	Y				
29	Y	Y	Y			✓	P	Y	Y	N	Y				
30	Y	Y	Y			✓	P	N	Y	N	Y				
31	Y	Y	Y			✓	P	Y	N	N	Y				
32	Y	Y	Y			✓	P	Y	N	N	Y				
33	Y	Y	Y			✓	P	Y	Y	Y (TB)	Y				
34	Y	Y	Y			✓	P	Y	Y	N	Y				
35	Y	Y	Y		✓		P	Y	Y	N	Y				
36	Y	Y	Y		✓		P	Y	N	N	Y	80 GC, 20 IF	20 GC, 80 IF	20 GC, 80 IF	05 GC, 60 IF
37	Y	Y	Y			✓	P	N	Y	N	Y				
38	Y	Y				✓	P	N	N	N	Y	80 GC, 20 IF	15 GC, 80 IF	15 GC, 80 IF	20 GC, 70 IF
39	Y	Y	Y			✓	P	N	N	N	Y				
40	Y	Y	Y		✓		P	N	Y	N	Y				
41	Y	Y	Y		✓		P	Y	N	N	Y				
42	Y	Y	Y			✓	P	Y	N	N	Y				
43	Y	Y	Y		✓		P	Y	N	N	Y				
44	Y	Y	Y			✓	P	Y	N	N	Y				
45				✓			P	N	Y	N	Y	80 GC, 10 IF	01 GC, 80 IF		
46				✓			P	N	Y	N	Y	80 GC, 05 IF	01 GC, 10 IF		
47	Y	Y	Y		✓		P	N	N	N	Y				
48	Y	Y			✓		P	N	N	N	Y				

CASE	YEAR	TJL	SITE	LOCATION L/N VS GL	U/M CYSTIC	LUMEN CONTENT	EPITHELIAL LINING	INFL PERM INTO EPI	SUBEPI CONDENSTN	INTENSITY INFL INFIL	PARENCHYMA DESTRUCT	DUCT CHANGES
49	2003	294	PG	LN	M	Muc Mat	Sq + Resp	Mod	Mod	Chrn	CLH change	Duct dilatn
50		312	PG	LN	M	Muc mat	Sq + resp	Int	Int	Chrn	Severe	Atr + duct dilatn
51		492	PG	LN	M	Muc Mat	Sq + Resp	Mod	Mod	Chrn	Focal	Atr
52		545	PG	LN	M	Muc Mat	Sq + Resp	Int	Int	Chrn	Focal change	Atr + duct dilatn
53		549	PG	LN + GL	M	Muc + Chole cleft	Sq + Resp	INt	Int	Chrn	Focal	Dystr calc + Dilatn
54		732	PG	LN + GL	M	Muc Mat	Sq + Resp	Mild	Mild	Chrn	Focal change	Atr + dilatn
55		1065	PG	LN + GL	M	Muc mat	Sq + Resp	Mod	Mod	Chrn	General	Atr + dilatn
56		1080	PG	LN	M	Muc + C/Clefts	Sq + Resp	Mod	Mod	Chrn	Focal	Atr + Dilatn
57		1139	PG	LN	M	Muc Mat	Sq + Resp	Int	Int	Chrn	Focal	Mild Atr + Dilatn
58		1193	PG	LN	M	Muc mat	Sq + Resp	Int	Int	Chrn	Focal	Mild Dilatn
59		1201	PG	LN	M	Muc mat	Sq + Resp	Int	Int	Chrn	None	No
60		1267	Neck	LN	M	Muc mat	Variable	Mild	Mild	Chrn	No	No
61		1284/5	PG	LN	M	Muc mat	Sq + resp	Int	Int	Chrn	No	No
62		1343	PG	LN	M	A/C + Blood	Variable	Mild	Mild	Chrn	None	No
63		1374	PG	LN	M	Muc mat	V	Mod	Mod	Chrn	Focal	Duct dilatn
64		1385	PG	LN	M	Muc mat	V	Mod	Mod	Int Chrn	Focal	Atr + Dilatn
65		1401	PG	LN	M	Muc mat	V	Mild	Mild	Chr	Focal	Atr + dilatn
66	2004	89	SBM	LN	M	Muc mat	V	Mod	Mod	Chrn	No	No
67		159	PG	LN	M	Muc mat	V	Int	Int	Chrn	No	No
68		357	SBM	GL	U	Empty	V	Int	Int	Chrn	Severe	Atr + dilatn
69		361	PG	LN	M	Muc + C/Clefts	V	Mod	Mod	Int Chrn	No	No
70		940	PG	LN	M	Muc mat	Sq + Resp	Mod	Mod	Chrn	CLH change	Atr + dilatn
71		1141	PG	LN	M	Muc mat	V	Mild	Mild	Chrn	No	No
72		1343	SBM	LN	M	A/C infl	V	Mod	Mod	Chrn	No	No

CASE	LYMPH NODE CHANGES			TYPE			P24	EMI	MNGC	CO INFXN	HIV	CD 20%	CD 3%	CD 8%	CD 4%
	CAPSULE	S. CAPS SINUS	ENT S.G.	T1	T2	T3					CHANGES				
49	Y	Y	Y			✓	P	N	N	N	Y				
50	Y	Y	Y			✓	P	N	N	N	Y				
51	Y	Y	Y			✓	P	Y	N	N	Y				
52	Y	Y	Y		✓		P	N	Y	N	ns				
53	Y	Y	Y		✓		P	N	Y	Y (TB)	Y				
54	Y	Y	Y		✓		P	Y	Y	N	Y				
55	Y	Y	Y		✓		P	Y	Y	N	Y				
56	Y	Y	Y			✓	N	Y	Y	N	Y				
57	Y	Y	Y			✓	P	Y	Y	N	Y	80 GC, 30 IF	30 GC, 80 IF	30 GC, 80 IF	30 GC, 80 IF
58	Y	Y	Y			✓	P	Y	Y	N	Y				
59	Y	Y				✓	P	N	N	N	Y				
60	Y	Y	Y			✓	P	Y	Y	N	Y				
61	Y	Y	Y			✓	P	Y	Y	N	Y	80 GC, 30 IF	10 GC, 80 IF	05 GC, 90 IF	01 GC, 50 IF
62	Y	Y	Y			✓	nc	N	Y	N	Y				
63	Y	Y				✓	P	N	N	N	Y				
64	Y	Y	Y		✓		P	N	N	N	Y				
65	Y	Y	Y			✓	P	N	Y	N	Y				
66	Y	Y	Y			✓	P	N	N	N	Y				
67	Y	Y	Y			✓	P	N	Y	N	Y				
68				✓			N	N	N	N	ns				
69	Y	Y	Y			✓	N	N	N	N	Y				
70	Y	Y	Y		✓		P	Y	Y	N	Y				
71	Y	Y				✓	P	Y	N	N	Y				
72	Y	Y	Y			✓	P	Y	N	N	Y				

CASE	YEAR	TJL	SITE	LOCATION L/N VS GL	U/M CYSTIC	LUMEN CONTENT	EPITHELIAL LINING	INFL PERM INTO EPI	SUBEPI CONDENSTN	INTENSITY INFL INFIL	PARENCHYMA DESTRUCT	DUCT CHANGES
73	2005	37	SBM	GL	M	Empty	Variable	Mild	Mild	Chrn	Focal	Dilatn
74		97	SBM	LN	M	Muc + A/C infl	V	Mild	Mild	Chrn	Fibrosis	Dilatn
75		385	PG	LN	M	Muc mat	V	Int	Int	Chrn	No	No
76		702/3	PG	LN + GL	M	Muc mat	V	Int	Int	Chrn	CLH change	dilatn
77		921	SBM	LN	M	Muc mat	Sq	Mild	Mild	Chrn	No	No
78		1129	PG	LN	M	Empty	Sq + Resp	Mod	Mod	Chrn	Focal	Atr + dilatn
79		1261	PG	LN + GL	M	A/C infl	Sq + Resp	Mod	Mod	Chrn	CLH change	No
80		1276	PG	LN + GL	M	Muc mat	V	Mod	Mod	Chrn	Focal	dilatn
81	2006	441	PG	LN + GL	M	Muc	V	Int	Int	Chrn	No	No
82		645	PG	LN	M	Muc mat	Sq + Resp	Mod	Mod	Chrn	CLH change	Atr + dilatn
83		853	PG	LN	M	Muc mat	V	Int	Int	Chrn	No	dilatn
84		946	PG	LN	M	Muc mat	V	Int	Int	Chrn	CLH change	Atr + dilatn
85		947	PG	LN + GL	M	Muc + C/Clefts	V	Mild	Mild	Chrn	Focal	Sialolith
86		1053	SBM	LN	M	A/C infl	V	Int	Int	Chrn	No	No
87	2007	261	SBM	LN	M	A/C infl	V	Mod	Mod	Chrn	No	No
88		408	PG	LN	M	Muc mat	V	Mod	Mod	Chrn	No	No
89		514	PG	LN	M	Muc mat	V	Mild	Mild	Int Chrn	No	No
90		607	PG	LN	M	A/C infl	Sq + resp	Mild	Mild	Chrn	No	No
91	2008	157	PG	LN	M	A/C infl	V	Mod	Mod	Chrn	Focal	Dilatn
92		213	PG	LN + GL	M	Muc mat	V	Mod	Mod	Chrn	CLH change	Atr + dilatn
93		230	PG	LN + GL	M	Muc mat	V	Int	Int	Chrn	Dyst calc	CLH change
94		339	PG	LN	M	Muc mat	V	Mod	Mod	Chrn	No	No
95		412	PG	LN	M	Muc mat	V	Mild	Mild	Chrn	No	No
96		415	PG	LN + GL	M	Muc mat	V	Mild	Mild	Chrn	CLH change	Atr + dilatn

CASE	LYMPH NODE CHANGES			TYPE			P24	EMI	MNGC	CO INFXN	HIV	CD 20%	CD 3%	CD 8%	CD 4%
	CAPSULE	S. CAPS SINUS	ENT S.G.	T1	T2	T3					CHANGES				
73	-	-	-	✓			P	Y	N	Y (TB)	Y				
74	Y	Y	Y		✓		P	N	N	N	Y				
75	Y	Y	Y			✓	P	N	N	N	Y				
76	Y	Y	Y		✓		P	Y	N	N	Y				
77	Y	Y				✓	P	N	N	N	Y				
78	Y	Y	Y			✓	N	N	Y	N	Y				
79	Y	Y	Y		✓		P	N	N	N	Y				
80	Y	Y	Y			✓	P	N	Y	N	Y				
81	Y	Y	Y		✓		P	N	N	N	Y				
82	Y	Y	Y			✓	P	Y	N	N	Y				
83	Y	Y				✓	P	Y	N	N	Y				
84	Y	Y	Y			✓	P	Y	N	N	Y	80 GC, 30 IF	10 GC, 80 IF		
85	Y	Y	Y		✓		P	N	Y	N	Y				
86	Y	Y	Y			✓	P	Y	N	N	Y				
87	Y	Y	Y			✓	P	N	N	N	Y	80 GC, 10 IF	15 GC, 90 IF	15 GC, 90 IF	05 GC, 60 IF
88	Y	Y	Y			✓	P	Y	N	N	Y				
89	Y	Y	Y			✓	P	Y	N	N	Y	90 GC, 20 IF	20 GC, 80 IF	20 GC, 80 IF	20 GC, 60 IF
90	Y	Y	Y			✓	P	Y	N	N	Y				
91	Y	Y	Y		✓		P	Y	N	N	Y				
92	Y	Y	Y		✓		P	Y	N	N	Y				
93	Y	Y	Y		✓		P	Y	N	N	Y	90 GC, 60 IF	05 GC, 90 IF	20 GC, 90 IF	15 GC, 80 IF
94	Y	Y	Y			✓	P	N	N	N	Y				
95	Y	Y	Y			✓	P	N	N	N	Y				
96	Y	Y	Y		✓		P	N	N	N	Y				

CASE	YEAR	TJL	SITE	LOCATION L/N VS GL	U/M CYSTIC	LUMEN CONTENT	EPITHELIAL LINING	INFL PERM INTO EPI	SUBEPI CONDENSTN	INTENSITY INFL INFIL	PARENCHYMA DESTRUCT	DUCT CHANGES
97	2008	468	PG	LN	M	Muc mat	Variable	Int	Int	Chrn	Focal	Dilatn
98		486	PG	LN	M	Empty	V	Mod	Mod	Chrn	No	Mild dilatn
99		867	PG	LN	M	Empty	V	Int	Int	Chrn	Mild	Mild
100		970	PG	LN	M	Empty	V	Mod	Mod	Chrn	Mild	Marked dilatn
101		976	PG	LN	M	Muc, A/C, C/cleft	V	Mild	Mild	Chrn	Focal	Atr + Dilatn
102		1027	SBM	LN	M	Muc mat	Sq + resp	Mod	Mod	Chrn	No	No
103	2009	382	PG	LN	M	Empty	V	Int	Int	Chrn	No	No
104		455	PG	LN	M	Muc mat	V	Int	INt	Chrn	Severe	Marked Atr + dilatn
105		487	Neck	LN	M	A/C infl	V	Int	Int	Chrn	No	No
106		488	PG	LN	M	A/C infl	V	Mild	Mild	Chrn	CLH change	Marked Atr + dilatn
107		817	SBL	GL	M	Empty	V	No	No	Chrn	CLH change	dilatn
108		84958	PG	LN	M	A/C infl, C/Clefts	V	Int	Int	Chrn	No	Atr + fibrosis
109		69801	PG	LN + GL	M	Muc mat	V	Mild	Mod	Chrn	CLH change	Atr + dilatn

CASE	LYMPH NODE CHANGES			TYPE			P24	EMI	MNGC	CO INFXN	HIV CHANGES	CD 20%	CD 3%	CD 8%	CD 4%
	CAPSULE	S. CAPS SINUS	ENT S.G.	T1	T2	T3									
97	Y	Y	Y		✓		P	Y	N	N	Y				
98	Y	Y	Y			✓	P	N	N	N	Y	90 GC, 20 IF	05 GC, 90 IF	05 GC, 90 IF	10 GC, 70 IF
99	Y	Y	Y			✓	P	Y	N	N	Y	90 GC, 15 IF	15 GC, 90 IF	01 GC, 60 IF	01 GC, 60 IF
100	Y	Y	Y			✓	P	Y	N	N	Y				
101	Y	Y	Y			✓	P	Y	N	N	Y	90 GC, 70 IF	20 GC, 90 IF	20 GC, 90 IF	35 GC, 70 IF
102	Y	Y				✓	P	Y	N	N	Y	90 GC, 40 IF	10 GC, 90 IF	20 GC, 90 IF	25 GC, 70 IF
103	Y	Y	Y			✓	P	Y	N	N	Y	80 GC, 15 IF	10 GC, 80 IF	15 GC, 70 IF	10 GC, 90 IF
104	Y	Y	Y			✓	P	Y	Y	N	Y	90 GC, 05 IF	45 GC, 80 IF	25 GC, 80 IF	50 GC, 25 IF
105	Y	Y	Y			✓	P	N	N	N	Y	90 GC, 20 IF	15 GC, 90 IF	01 GC, 80 IF	10 GC, 75 IF
106	Y	Y	Y			✓	P	N	N	N	Y	90 GC, 40 IF	10 GC, 80 IF	01 GC, 75 IF	10 GC, 70 IF
107	-	-	-	✓			N	N	N	N	Y	90 GC, 10 IF	05 GC, 90 IF	60 GC, 60 IF	05 GC, 90 IF
108	Y	Y	Y			✓	nc	Y	Y	N	Y	90 GC, 15 IF	20 GC, 90 IF	10 GC, 80 IF	10 GC, 70 IF
109	Y	Y	Y			✓	P	Y	N	N	Y	80 GC, 30 IF	01 GC, 80 IF	01 GC, 80 IF	10 GC, 60 IF

Key:

Heading
Lumen content
Epithelial lining
Infl perm into epi = inflammatory permeation into epithelium
Subepi condens = subepithelial condensation
Int infl infil = intensity of inflammatory infiltrate
Parenchyma destruct = parenchymal destruction
Duct changes
S. caps sinus = presence of subcapsular sinus
Ent S.G. = presence of entrapped salivary gland
Co Infxn = Presence of co-infection

Content
Muc mat = mucoid material, c/clefts = cholesterol clefts, A/c infl = acute on chronic inflammation
Sq = squamous, Resp = respiratory type,
Mod= moderate, Chrn = Chronic, Int = intense

Dystrophic calc = dystrophic calcification
Atr= atrophy, Duct dilatn = ductal dilation

GC = Germinal centre, IF = Interfollicular area

CHAPTER 9

9.0 REFERENCES

1. dôAgay MF, de Roquancourt A, Peuchmaur M, Janier M, Brocheriou C. Cystic benign lymphoepithelial lesion of the salivary glands in HIVï positive patients. Report of two cases with immunohistochemical study. *Virchows Arch A Pathol Anat Histopathol.* 1990;417:353-6.
2. Chhieng DC, Argosino R, McKenna BJ Cangiarella JF, Cohen JM. Utility of fine-needle aspiration in the diagnosis of salivary gland lesions in patients infected with human immunodeficiency virus. *Diagn Cytopathol.* 1999;21:260-4.
3. Vargas PA, Mauad T, Böhm GM Saldiva PH, Almeida OP. Parotid gland involvement in advanced AIDS. *Oral Dis*. 2003;9:55-61.
4. Aguirre JM, Martinez-Conde R, Tánago JG, Rivera JM. Cystic lymphoid hyperplasia in the parotid gland in HIV infection: report of 2 cases. *J Oral Maxillofac Surg*. 2000;58:1176-80.
5. Ihrler S, Zietz C, Riederer A, Diebold J, Löhrs U. HIV-related parotid lymphoepithelial cysts. Immunohistochemistry and 3-D reconstruction of surgical and autopsy material with special reference to formal pathogenesis. *Virchows Arch*. 1996;429:139-47.
6. Ihrler S, Steger W, Riederer A Zietz C, Vogl I, Löhrs U. [HIV-associated cysts of the parotid glands. An histomorphologic and magnetic resonance tomography study of formal pathogenesis]. *Laryngorhinootologie.* 1996;75:671-6.
7. Vargas PA, Villalba H, Passos AP, Saldiva PH, Mauad T, Caiaffa Filho HH, *et al.* Simultaneous occurrence of lymphoepithelial cysts, cytomegalovirus and mycobacterial infections in the intraparotid lymph nodes of a patient with AIDS. *J Oral Pathol Med*. 2001;30:507-9.
8. Chetty R. HIV-associated lymphoepithelial cysts and lesions: morphological and immunohistochemical study of the lymphoid cells. *Histopathology.* 1998;33:222-9.

9. Maiorano E, Favia G, Viale G. Lymphoepithelial cysts of salivary glands: an immunohistochemical study of HIV-related and HIV-unrelated lesions. *Human Pathol*. 1998;29:260-5.

10. Elliott JN, Oertel YC. Lymphoepithelial cysts of the salivary glands. Histologic and cytologic features. *Am J Clin Pathol*. 1990;93:39-43.

11. Labouyrie E, Merlio JP, Beylot-Barry M, Delord B, Vergier B, Brossard G, *et al*. Human immunodeficiency virus type 1 replication within cystic lymphoepithelial lesion of the salivary gland. *Am J Clin Pathol*. 1993;100:41-6.

12. Mandel L, Reich R. HIV parotid gland lymphoepithelial cysts: Review and Case reports. *Oral Surg Oral Med Oral Pathol*. 1992;74:273-8.

13. Mandel L, Hong J. HIV-associated parotid lymphoepithelial cysts. *J Am Dent Assoc*. 1999;130:528-32.

14. Dave S, Pernas F, Roy S. The benign lymphoepithelial cyst and a classification system for lymphocytic parotid gland enlargement in the pediatric HIV population. *Laryngoscope*. 2007;117:106-13.

15. Stanley MW, Frizzera G. Diagnostic specificity of histologic features in lymph node biopsy specimens from patients at risk for the acquired immunodeficiency syndrome. *Human Pathol*. 1986;17:1231-9.

16. Ulirsch RC, Jaffe ES. Sjörgenôs syndrome-like illness associated with the acquired immunodefiency syndrome-related complex. *Human Pathol*. 1987;18:1063-8.

17. Uccini S, Riva E, Antonelli G, D'Offizi G, Prozzo A, Angelici A, *et al*. The benign cystic lymphoepithelial lesion of the parotid gland is a viral reservoir in HIV type 1-infected patients. *AIDS Res Hum Retroviruses*. 1999;15:1339-44.

18. Schiødt M, Dodd CL, Greenspan D, Daniels TE, Chernoff D, Hollander H, *et al.* Natural history of HIV-associated salivary gland disease. *Oral Surg Oral Med Oral Pathol*. 1992;74:326-31.

19. Favia G, Capodiferro S, Scivetti M, Lacaita MG, Filosa A, Lo Muzio L. Multiple parotid lymphoepithelial cysts in patients with HIV-infection: report of two cases. *Oral Dis*. 2004;10:151-4.

20. Couderc LJ, D'Agay MF, Danon F, Harzic M, Brocheriou C, Clauvel JP. Sicca complex and infection with human immuno deficiency virus. *Arch Intern Med*. 1987;147:898-901.

21. Vaillant JM, Chomette G, Talbi M, Labrousse F, Szpirglas H, Raphael B, *et al.* [Cystic lymphoid hyperplasia of the parotid in relation to acquired immunodefiency syndrome (HIV+). Apropos of 2 cases]. *Rev Stomatol Chir Maxillofac*. 1989;90:136-41.

22. Seifert G. Tumour-like lesions of the salivary glands. The new WHO classification. *Pathol Res Pract*. 1992;188:836-46.

23. Smith FB, Rajdeo H, Panesar N, Bhuta K, Stahl R *et al.* Benign lymphoepithelial lesion of the parotid gland in intravenous drug users. *Arch Pathol Lab Med*. 1988;112:742-5.

24. Tunkel DE, Loury MC, Fox CH, Goins MA3rd, Johns ME. Bilateral Parotid Enlargement in HIV-Seropositive Patients. *Laryngoscope* 1989;99:590-5.

25. Worldwide HIV and AIDS statistics [Internet] 2010 [updated June 30 2010; cited 2010 July 4]. Available from: http://www.avert.org/worldstats.htm.

26. Colebunders R, Francis H, Mann JM, *et al.* Parotid Swelling During Human Immunodeficiency Virus Infection. *Arch Otolaryngol. Head Neck Surg*. 1988;114:330-2.

27. Feller L, White JP, Bouckaert M, Muthuphei MN. Diffuse infiltrative CD8+ lymphocytosis syndrome: review of the literature and report of a case. *SADJ*. 2007;62:314-7.

28. Bem C, Barucha H and Patil PS. Parotid disease and human immunodeficiency virus infection in Zambia. *Br J Surg*. 1992;79:768-70.

29. Owotade FJ, Fatusi OA, Adebiyi KE, Ajike SO, Folayan MO. Clinical experience with parotid gland enlargement in HIV infection: a report of five cases in Nigeria. *J Contemp Dent Pract*. 2005;6:136-45.

30. Werning JT. Infectious and systemic diseases. In: Ellis GL, Auclair PL, Gnepp DR, editors. *Surgical Pathology of the Salivary Glands*. Volume 25, Philadelphia: W.B. Saunders Co; 1991. Chapter 4, p.39-59.

31. Ortega KL, Ceballos-Salobreña A, Gaitán-Cepeda LA, Magalhães MG. Oral manifestations after immune reconstitution in HIV patients on HAART. *Int J STD AIDS*. 2008;19:305-8.

32. Ryan JR, Ioachim HL, Marmer J, Loubeau JM. Acquired immune deficiency syndrome-related lymphadenopathies presenting in the salivary gland nodes. *Arch Otolaryngol*. 1985;111:554-6.

33. Terry JH, Loree TR, Thomas MD, Marti JR. Major salivary gland lymphoepithelial lesions and the acquired immunodeficiency syndrome. *Am J Surg*. 1991;162:324-9.

34. Finfer MD, Schinella RA, Rothstein SG, Persky MS. Cystic Parotid Lesions in Patients at Risk for the Acquired Immunodeficiency Syndrome. *Arch Otolaryngol Head Neck Surg*. 1988;114:1290-4.

35. Chahin F, Kaufman MR, Abbarah T, Chahin C. Salivary Gland Tumours, Major, Benign [Internet]. 2009 [updated 2008 Nov 04; cited 2009 Nov 18]. Available from: http:// www.emedicine.com/emedicine specialities/general surgery/glands.htm.

36. Harris NL. Lymphoid proliferations of the salivary glands. *Am J Clin Pathol*. 1999; 111(1 Suppl 1):S94 ï 103.

37. Classification and diagnostic criteria for oral lesions in HIV infection. EC-Clearinghouse on Oral Problems Related to HIV Infection and WHO Collaborating Centre on Oral Manifestations of the Immunodeficiency Virus. *J Oral Pathol Med*. 1993;22:289-91.

38. Ramos-Gomez FJ, Flaitz C, Catapano P, Murray P, Milnes AR, Dorenbaum A. Classification, diagnostic criteria, and treatment recommendations for orofacial manifestations in HIV-infected paediatric patients. Collaborative Workgroup on Oral Manifestations of Pediatric HIV Infection. *J Clin Pediatr Dent*. 1999;23:85-96.

39. Poletti A, Manconi R, Volpe R, Carbone A. Study of AIDS-related lymphadenopathy in the intraparotid and perisubmaxillary gland lymph nodes. *J Oral Pathol*. 1988;17:164-7.

40. Kornstein MJ, Parker GA, Mills AS. Immunohistology of the benign lymphoepithelial lesion in AIDS-related lymphadenopathy: a case report. *Human Pathol*. 1988;19:1359-61.

41. Sperling NM, Lin PT, Lucente FE. Cystic parotid masses in HIV infection. *Head Neck*. 1990;12:337-41.

42. Gupta N, Gupta R, Rajwanshi A, Bakshi J. Multinucleated giant cells in HIV-associated benign lymphoepithelial cyst-like lesion of the parotid gland on FNAC. *Diagn Cytopathol*. 2009;37:203-4.

43. Shaha AR, DiMaio T, Webber C, Thelmo W, Jaffe BM.. Benign Lymphoepithelial Lesions of the Parotid. *Am J Surg*. 1993;166:403-6.

44. Kojima M, Nakamura N, Matsuda H, Kaba S, Itoh H, Masawa N. HIV-Unrelated Benign Lymphoepithelial Cyst of the Parotid Glands Containing Lymphoepithelial Lesion-Like Structures: A Report of 3 Cases. *Int J Surg Pathol.* 2009;17:421-5.

45. Weidner N, Geisinger KR, Sterling RT, Miller TR, Yen TS.. Benign Lymphoepithelial Cysts of the Parotid Gland. *Am J Clin Pathol*. 1986;85:395-401.

46. Bernier JL, Bhaskar SN. Lymphoepithelial lesions of salivary glands. Histogenesis and classification based on 186 cases. *Cancer*. 1958;11:1156-79.

47. Holliday RA, Cohen WA, Schinella RA, Rothstein SG, Persky MS, Jacobs JM. Benign lymphoepithelial parotid cysts and hyperplastic cervical adenopathy in AIDS-risk patients: a new CT appearance. *Radiology*. 1988;168:439-41.

48. Shugar JM, Som PM, Jacobson AL, Ryan JR, Bernard PJ, Dickman SH. Multicentric parotid cysts and cervical lymphadenopathy in AIDS patients. A newly recognised entity: CT and MR manifestations. *Laryngoscope.* 1988;98:772-5.

49. Riederer A, Zietz C, Ihrler S, Vogl T. Cystic lymphoepithelial lesions in the head and neck area in HIV-infected patients. *Laryngorhinootologie*. 1994;73:209-14.

50. Hamilton BE, Salzman KL, Wiggins RH 3rd, Harnsberger HR. Earring lesions of the parotid tail. AJNR *Am J Neuroradiol*. 2003;24:1757-64.

51. Mandel L. Ultrasound findings in HIV-positive patients with parotid gland swellings. *J Oral Maxillofac Surg*. 2001;59:283-6.

52. Yen TL, Murr AH, Rabin J, Mhatre AN, Lalwani AK. Role of Cytomegalovirus, Epstein - Barr virus and Human Herpes Virus-8 in Benign Lymphoepithelial Cysts of the Parotid Gland. *Laryngoscope*. 2004;114:1500-05.

53. Ranganathan K, Hemalatha R. Oral lesions in HIV infection in developing countries: an overview. *Adv Dent Res*. 2006;19:63-8.

54. Wu L, Cheng J, Maruyama S, Yamazaki M, Tsuneki M, Lu Y, *et al.* Lymphoepithelial cyst of the parotid gland: its possible histopathogenesis based on clinicopathologic analysis of 64 cases. *Human Pathol*. 2009;40:683-92.

55. Mandel L, Tomkoria A. Differentiating HIV-1 parotid cysts from papillary cystadenoma lymphamatosum. *J Am Dent Assoc*. 2000;131:772-6.

56. Martinoli C, Pretolesi F, Del Bono V, Derchi LE, Mecca D, Chiaramondia M. Benign lymphoepithelial parotid lesions in HIV-positive patients: spectrum of findings at Gray-Scale and Doppler Sonography. *AJR*. 1995;165:975-9.

57. Vicandi B, Jiménez-Heffernan JA, López-Ferrer P, Patrón M, Gamallo C, Colmenero C, Viguer JM.. HIV-1 (p24)-positive multinucleated giant cells in HIV-associated lymphoepithelial lesions of the parotid gland. A report of 2 cases. *Acta Cytol*. 1999;43:247-51.

58. Orenstein JM, Wahl SM. The macrophage origin of the HIV-expressing multinucleated giant cells in hyperplastic tonsils and adenoids. *Ultrastruct Pathol*. 1999;23:79-91.

59. Ioachim HL, Ryan JR, Blaugrund SM. Salivary gland lymph nodes: The site of lymphadenopathies and lymphomas associate with human immunodeficiency virus infection. *Arch Pathol Lab Med*. 1988;112:1224-8.

60. Ioachim HL, Ryan JR, Blaugrund SM. AIDS-associated lymphadenopathies and lymphomas with primary salivary gland presentation (abstract). *Lab Invest*. 1987: 56:33a.

61. Duarte MI, Amato VS, de Paula JG, Uip DE, Boulos M, Amato Neto V. Parotid enlargement due to adenovirus infection in patient with human immunodeficiency virus infection. *Rev Soc Bras Med Trop*. 1996;29:503-6.

62. Mukherjee A, Silver CE, Rosario PG, Gerst PH. Kaposiôs sarcoma of the parotid gland in acquired immunodeficiency syndrome. *Am Surg*. 1998;64:259-60.

63. Rizos E, Drosos AA, Ioannidis JP. Isolated intraparotid Kaposi sarcoma in human immunodeficiency virus type 1 infection. *Mayo Clin Proc*. 2003;78:1561-3.

64. Del Bono V, Pretolesi F, Pontali E, Martinoli C, Bassetti M, Mazzarello G, *et al.* Possible malignant transformation of benign lymphoepithelial parotid lesions in human immunodeficiency-infected patients: report of three cases. *Clin Infect Dis*. 2000;30:947-9.

65. Huang RD, Pearlman S, Friedman WH, Loree T. Benign cystic versus solid cystic lesions of the parotid gland in HIV patients. *Head Neck*. 1991;13:522-7.

66. Bruner JM, Cleary KR, Smith FB, Batsakis J.G. Immunocytochemical identification of HIV (p24) antigen in parotid lymphoid lesions. *J Laryngol Otol*. 1989 Nov;103:1063-6.

67. Kaluza G, Willems WR, Lohmeyer J, Altmannsberger M, Bohle RM, Lübke S. A monoclonal antibody that recognizes a formalin-resistant epitope on the p24 core protein of HIV-1. *Path Res Pract* 1992;188:91-6.

68. Goto T, Nakai M, Ikuta K. The life-cycle of human immunodeficiency virus type 1. *Micron* 1998;29:123-38.

69. de Paiva GR, Laurent C, Godel A, da Silva NA Jr, March M, Delsol G, *et al.* Discovery of human immunodeficiency virus infection by immunohistochemistry on lymph node biopsies from patients with unexplained follicular hyperplasia. *Am J Surg Pathol.* 2007;31:1534-8.

70. Ioachim HL, Ryan JR. Salivary gland lymphadenopathies associated with AIDS. *Human Pathol*. 1988;19:616-7.

71. Ihrler S, Zietz C, Sendelhofert A, Riederer A, Löhrs U. Lymphoepithelial duct lesions in Sjögren-type sialadenitis. *Virchows Arch* 1999;434:315-23.

72. Tao LC, Gullane PJ. HIV infection-associated lymphoepithelial lesions of the parotid gland: aspiration biopsy cytology, histology and pathogenesis. *Diagn Cytopathol.* 1991;7:158-62.

73. Tripathi AK, Gupta N, Ahmad R, Bhandari HS, Kalra P. HIV disease presenting as parotid lymphoepithelial cysts: a presumptive diagnosis of DILS. *J Assoc Physicians India*. 2004;52:921-3.

74. Schuval SJ, OôReilly, Bonagura VR. Increased frequency of HLA-DR11 in pediatric human immunodeficiency virus-associated parotid gland enlargement. *Clin Diagn Lab Immunol*.1997;4:258-260.

75. Williams FM, Cohen PR, Jumshyd J, Reveille JD. Prevalence of the diffuse infiltrative lymphocytosis syndrome among human immunodeficiency virus type 1-positive outpatients. *Arthritis Rheum*. 1998;41:863-8.

76. Itescu S, Brancato LJ, Buxbaum J, Gregersen PK, Rizk CC, Croxson TS, *et al*. A diffuse infiltrative CD8 lymphocytosis syndrome in HIV infection: a host immune response associated with HLA-DR5. *Ann Intern Med*. 1990;112:3-10.

77. Itescu S, Dalton J, Zhang H-Z, Winchester R. Tissue infiltration in a CD8 lymphocytosis syndrome associated with Human immunodeficiency virus-1 infection has a phenotypic appearance of an antigenically-driven response. *J Clin Invest*. 1993;91:2216-25.

78. Goldstein J, Rubin J, Silver C, Meritz K, Chao C, Ting J, Davis L. Radiation therapy as a treatment for benign lymphoepithelial parotid cysts in patients infected with human immunodeficiency virus-1. *Int J Radiat Oncol Biol Phys*. 1992;23:1045-50.

79. Beitler JJ, Vikram B, Silver CE, Rubin JS, Bello JA, Mitnick RJ, *et al*. Low-dose radiotherapy for multicystic benign lymphoepithelial lesions of the parotid gland in HIV-positive patients: long term results. *Head Neck*. 1995;17:31-5.

80. Beitler JJ, Smith RV, Brook A, Edelman M, Sharma A, Serrano M*, et al*. Benign parotid hypertrophy on +HIV patients: limited rate failures after external radiation. *Int J Radiat Oncol Biol Phys*. 1999;45:451-5.

81. Kooper DP, Leemans CR, Hulshof MC, Claessen FA, Snow GB. Management of benign lymphoepithelial lesions of the parotid gland in human immunodeficiency virus-positive patients. *Eur Arch Otorhinolaryngol*. 1998;255:427-9.

82. Suskind DL, Tavill MA, Handler SD. Doxycycline sclerotherapy of benign lymphoepithelial cysts of the parotid: a minimally invasive treatment. *Int J Paediatr Otorhinolaryngol*. 2000;52:157-161.

83. Meyer E, Lubbe DE, Fagan JJ. Alcohol sclerotherapy of human immunodeficiency virus related parotid lymphoepithelial cysts. *J Laryngol Otol*. 2009;123:422-5.

84. Monama GM, Tshifularo MI. Intralesional bleomycin injections in the treatment of benign lymphoepithelial cysts of the parotid gland in HIV-positive patients: case reports. *Laryngoscope*. 2010;120:243-6.

85. Soberman N, Leonidas CJ, Berdon WE, Bonagura V, Haller J, et al. Parotid enlargement in children seropositive for human immunodeficiency Virus: Imaging Findings. *Am J Res* 1991;157:553-6.

86. Kreisel FH, Frater JL, Hassan A, El-Mofty SK. Cystic lymphoid hyperplasia of the parotid gland in HIV-positive and HIV-negative patients: quantitative immunopathology. *Oral Surg Oral Med Oral Pathol.* 2010;109:567-574.

87. Monoclonal Mouse Anti-Human Immunodeficiency Virus, p24, Clone Kal-1 [package insert]. Glostrup, Denmark: DakoCytomation; 2005.