

# **A STUDY OF THE HUMAN FASCIA LATA AND ITS RELATIONSHIPS TO THE EXTENSOR MECHANISM OF THE KNEE.**

**Willem Jacobus Fourie**

Student No: 0718979D

**A dissertation submitted to the Faculty of Science, University of the Witwatersrand,  
Johannesburg, in fulfillment of the requirements for the degree of Master of Science.**

**Supervisor:** Amadi O. Ihunwo, PhD

**Johannesburg, June, 2011**



## **DECLARATION**

I declare that this dissertation is my own, unaided work. It is being submitted for the Degree of Master in Science in the University of the Witwatersrand, Johannesburg. It has not been submitted before for any degree or any examination in any other University.

**W J Fourie**

This \_\_\_\_\_ day of \_\_\_\_\_ 2011.



## **ABSTRACT**

General descriptions of the fascia lata as a structure could be found in all major anatomy textbooks. However, there is a paucity of information on the fascia lata and its surrounding structures in scientific literature. This study investigates how fascia and muscle relate in the extensor compartment of the thigh – i.e. as the muscle epimysium or as a separate fascial layer. Using detailed dissections of ten cadaver lower limbs and axial Magnetic Resonance Imaging and Ultrasonography in four volunteers, findings were compared to correlate all observed features. Results highlighted anatomical aspects and relationships not previously documented. The fascia lata demonstrated a single, epimysial relationship to the tensor fascia lata, upper sartorius and parts of the vastus medialis muscles, while forming a separate fascial layer over the lower sartorius, rectus femoris and vastus lateralis muscles. Findings suggest the fascia lata may function as more than containment of musculature and allude to functional implications for surgery and rehabilitation.



In loving memory of my parents, Pieter (1920–2008) and Helene (1924–2005) Fourie, for the early seeds of learning planted during my growth as a person.

Mother, for encouraging me to read widely and critically.

Father, for encouraging me to learn something new every day.



## **ACKNOWLEDGEMENTS**

This dissertation is the culmination of many years of patients asking “why” in the face of chronic musculoskeletal dysfunction. I acknowledge every one of you, even for the difficult questions I still cannot answer.

A special thank you to Professors Beverley Kramer and John Maina for facilitating my entry into the School of Anatomical Sciences as graduate dissector and later, Professor John Maina, for encouraging me to start this Masters degree. You will never know the exhilaration of the first time a dissection and a complex patient problem came together in a successful treatment.

I acknowledge members of the staff of the School of Anatomical Sciences for encouragement at difficult times, advice and guidance.

Special appreciation to Dr. Glen Buchannan and his staff at the Fourways Life Hospital for the use of their Magnetic Resonance Imaging and Ultrasonography equipment in obtaining the images for the correlation studies. Thank you to my colleague, Caroline Russell in London, for reading chapters, critical questions and feedback to keep me on my toes where my grasp of the English language let me down. To Dr Rosemary Crouch for forcing me to continue when giving up was the only option and lastly, to my wife Trudie for setting an ultimatum when she did, and then following that with an eternity of putting up with my procrastination.



# TABLE OF CONTENTS

DECLARATION.....	ii
ABSTRACT .....	iii
ACKNOWLEDGEMENTS .....	v
TABLE OF CONTENTS .....	vi
LIST OF FIGURES .....	ix
LIST OF TABLES .....	xi
<b>1 INTRODUCTION.....</b>	<b>1</b>
1.1 Problem statement.....	3
1.1.1 Research question.....	4
1.1.2 Hypothesis .....	5
1.2 Purpose and aims .....	5
1.3 Limitations .....	6
1.4 Organization of the remainder of this dissertation.....	6
<b>2 A GENERAL REVIEW OF LITERATURE ON FASCIA AND THE FASCIA LATA IN PARTICULAR.....</b>	<b>8</b>
2.1 Fascial understanding .....	8
2.1.1 Introduction .....	8
2.1.2 Search strategy.....	10
2.1.3 Fascial biology.....	11
2.1.4 Functions and roles of fascia .....	13
2.2 The fascia lata of the thigh.....	18
2.2.1 Search strategy.....	19
2.2.2 Results of the literature search and selection of studies .....	20
2.2.3 Overview of the literature consulted .....	22
2.2.4 Critical appraisal of literature reviewed .....	26
2.2.5 The gross morphology of the fascia lata.....	30
2.2.6 Conclusion .....	33
<b>3 RESEARCH DESIGN, METHODS AND MATERIALS .....</b>	<b>35</b>
3.1 Research method and design.....	35
3.2 Subject samples.....	36
3.3 Materials, instruments and tools .....	36
3.3.1 Cadaveric material.....	36



3.3.2	Instruments and tools.....	37
3.4	Data.....	38
3.5	Correlation study analysis.....	39
<b>4</b>	<b>DETAILED ANATOMIC DISSECTION OF THE FASCIA LATA.....</b>	<b>40</b>
4.1	Detailed dissection procedures .....	40
4.2	Image capturing .....	44
4.3	Results.....	45
4.3.1	The deep fascia or fascia lata of the thigh .....	46
4.3.2	The tensor fasciae latae muscle .....	49
4.3.3	The sartorius muscle.....	52
4.3.4	The rectus femoris muscle.....	55
4.3.5	The vastus lateralis muscle.....	58
4.3.6	The vastus medialis muscle .....	61
4.4	Summary of observations .....	66
4.5	Discussion.....	72
4.6	Conclusion .....	75
<b>5</b>	<b>CORRELATION BETWEEN DISSECTION, MAGNETIC RESONANCE IMAGING AND ULTRASONOGRAPHY OF THE FASCIA LATA.....</b>	<b>76</b>
5.1	Introduction.....	76
5.2	Detailed cross section studies procedures.....	77
5.2.1	Magnetic Resonance Imaging studies of normal human thighs .....	78
5.2.2	Ultrasonography studies of normal human thighs .....	79
5.3	Results.....	80
5.3.1	Legends.....	80
5.4	Level I - Halfway between the iliac crest and greater trochanter .....	81
5.4.1	The superficial fascia and fascia lata.....	81
5.4.2	Tensor fasciae latae muscle .....	84
5.4.3	Rectus femoris muscle.....	87
5.4.4	Sartorius muscle .....	90
5.5	Level II – 6 to 8 cm below the greater trochanter.....	93
5.5.1	The superficial fascia and fascia lata.....	93
5.5.2	Vastus lateralis muscle .....	97
5.5.3	Rectus femoris muscle.....	100
5.5.4	Sartorius muscle .....	103



5.6	Level III – halfway between levels II and 5 cm above the upper border of the patella (level IV) .....	106
5.6.1	The superficial fascia and fascia lata .....	106
5.6.2	Vastus lateralis muscle .....	109
5.6.3	Rectus femoris Muscle .....	112
5.6.4	Vastus medialis muscle .....	115
5.7	Level IV – 5 cm above the upper border of the patella .....	119
5.7.1	Superficial fascia and fascia lata .....	119
5.7.2	Vastus lateralis muscle .....	122
5.7.3	Rectus femoris muscle.....	125
5.7.4	Vastus medialis muscle .....	128
5.8	Summary of observations .....	131
5.9	Conclusion .....	132
<b>6</b>	<b>GENERAL DISCUSSION</b> .....	<b>134</b>
6.1	Principal findings .....	140
6.1.1	Literature .....	140
6.1.2	Detailed dissection study (chapter 4).....	142
6.1.3	Correlation study between dissection, Magnetic Resonance Imaging and Ultrasonography (chapter 5).....	143
6.2	Comparison with findings in related studies.....	144
6.3	Interpretation of findings .....	146
6.3.1	Detailed dissection study (chapter 4).....	147
6.3.2	Dissection, Magnetic Resonance Imaging and Ultrasonography correlation	151
6.4	Implication of the study .....	151
6.4.1	The wider knowledge base implications .....	152
6.4.2	Clinical implications.....	152
<b>7</b>	<b>CONCLUSION</b> .....	<b>157</b>
7.1	Recommendations for future research .....	158
<b>8</b>	<b>REFERENCES</b> .....	<b>159</b>



## LIST OF FIGURES

<b>Figure 4.1</b> Reflection of the fascia lata from underlying anterior thigh muscles .....	42
<b>Figure 4.2</b> The relationships (loose and close) between the fascia lata and underlying muscles in the anterior thigh.....	47
<b>Figure 4.3</b> Reflecting the fascia lata from the tensor fasciae latae muscle.....	50
<b>Figure 4.4</b> Reflecting the fascia lata from the sartorius muscle .....	53
<b>Figure 4.5</b> Reflecting the fascia lata from the rectus femoris muscle .....	56
<b>Figure 4.6</b> Reflecting the fascia lata from the vastus lateralis muscle.....	59
<b>Figure 4.7</b> Reflecting the fascia lata from the vastus medialis muscle.....	62
<b>Figure 4.8</b> Line drawings of the medial aspect of the thigh showing four different variations in fascial relationships between the fascia lata and the vastus medialis muscle as observed during careful reflection of the fascia. Areas of close epimysial relationship between fascia lata and underlying muscle are shown as the dark areas (black arrows) on the vastus medialis (VM) muscle. (P) patella, (RF) rectus femoris, (S) sartorius .....	64
<b>Figure 4.9</b> A schematic presentation of the main findings of the detailed dissection of the fascia lata. (TFL, tensor fasciae latae; S, sartorius; RF, rectus femoris; VL, vastus lateralis; VM, vastus medialis) .....	71
<b>Figure 5.1</b> Features of the superficial fascia with its membranous layers and the fascia lata at cross cut Level I.....	82
<b>Figure 5.2</b> Features of the tensor fasciae latae muscle relating to the fascia lata observed at cross cut Level I.....	85
<b>Figure 5.3</b> Features of the relationship observed between the fascia lata and the upper rectus femoris muscle at cross cut Level I.....	88
<b>Figure 5.4</b> Features of the relationships observed between the fascia lata and the upper sartorius muscle at cross cut Level I.....	91
<b>Figure 5.5</b> Features of the superficial fascia and fascia lata observed at cross cut level II	95
<b>Figure 5.6</b> Features of the relationships observed between the fascia lata and the underlying vastus lateralis muscle at cross cut Level II .....	98



<b>Figure 5.7</b> Features of the relationships observed between the fascia lata and the underlying rectus femoris muscle at cross cut Level II.....	101
<b>Figure 5.8</b> Features of the relationships observed between the fascia lata and the underlying sartorius muscle at cross cut Level II.....	104
<b>Figure 5.9</b> Features of the superficial fascia and fascia lata observed at cross cut Level III	107
<b>Figure 5.10</b> Features of the relationships observed between the fascia lata and the underlying vastus lateralis muscle at cross cut Level III.....	110
<b>Figure 5.11</b> Features of the relationships observed between the fascia lata and the underlying rectus femoris muscle at cross cut Level III.....	113
<b>Figure 5.12</b> Features of the relationships observed between the fascia lata and the underlying vastus medialis muscle at cross cut Level III.....	116
<b>Figure 5.13</b> Features of the superficial fascia and fascia lata at cross cut Level IV .....	120
<b>Figure 5.14</b> Features of the relationships observed between the fascia lata and the underlying vastus lateralis muscle at cross cut Level IV .....	123
<b>Figure 5.15</b> Features of the relationships observed between the fascia lata and the underlying rectus femoris muscle (tendinous) at cross cut Level IV .....	126
<b>Figure 5.16</b> Features of the relationships observed between the fascia lata and the underlying vastus medialis muscle at cross cut Level IV .....	129



## LIST OF TABLES

<b>Table 4.1</b>	Summary of the individual muscles dissected and their dominant relationships to the fascia lata.....	70
------------------	------------------------------------------------------------------------------------------------------	----



# 1 INTRODUCTION

*“No portion of the animal body has suffered so much at the hands of the descriptive anatomist as have those lowly tissues classed together as fascia” (Jones, 1920, p122).*

This study was born in the clinic. Over many years the question “WHY” needed answers in the face of complex musculoskeletal dysfunction. In most cases a clear understanding of functional anatomy and anatomical interaction between systems could be identified as lying at the core of the problem. It may therefore be fair to reason that fragmentation of anatomy into separate systems leads to oversimplified biomechanical models, not fully reflecting the complexity of normal human movement and function.

A probable source for simplified biomechanical models may originate from limited understanding and exposure to fascial continuity and its relations to associated anatomical structures. Anatomy teaching in undergraduate medical education is to provide students with the anatomical skills which will enable them to practice medicine (Skidmore, 1995). Although dissection as part of learning still holds several advantages (Newell, 1995), skills needed to practice have changed dramatically with the use of Computerised Tomography, Magnetic Resonance Imaging and Ultrasonography, with its need for an understanding of detailed cross-sectional and structural anatomy.

Attention to connective tissue and fasciae is not necessarily the focus of gross anatomy methodology. Exposure to the continuity of connective tissue and fasciae as the integrating matrix of the body surrounding and connecting every muscle right down to the tiniest myofibre and every single organ (Schleip et al, 2006) is a neglected part of anatomy



methodology. Using pre-prepared material and “dissection thinking” encourages a systematic approach to learning where connective tissue anatomy is often described as a suborganisation of the anatomical structures (Van der Wal, 2009) which may impact on clinical understanding of complex musculoskeletal dysfunction. Traditional views need re-thinking in the interpretation of muscle action, mechanics, musculoskeletal pain and dysfunction as fasciae could increasingly be seen as holding several of the keys of understanding (Benjamin, 2009).

“Fascia” is a vague term drawn from the Latin language for a band, bandage, bundle or strap. The term has long been used by gross anatomists to incorporate a range of undifferentiated mesenchymal tissues wrapped around more “specialised” organs and tissues, relegated to a form of packing material between them (Benjamin, 2009). In leading textbooks, fascia is simply a term applied to “masses of connective tissue large enough to be visible to the unaided eye” (Standring, 2008 p39) and classified as anatomical entities or structures related to organs.

In recent years, there has been a strong revival into both basic and applied research on the roles fasciae may play in musculoskeletal dynamics and motor coordination (Findley and Schleip, 2007; Huijing et al, 2009; Stecco et al, 2009b). These range from tension transfer and myofascial force transmission across the epimysium, and even between muscles, (Huijing and Baan, 2001, 2008; Purslow, 2002; Schleip et al, 2005; Huijing, 2009), contributing to muscle force and power (Moza and Keagy, 1969; Garfin et al, 1981; Aspden, 1990; Hukins et al, 1990; Westneat et al, 1998), to functioning as a responsive, dynamic and complex body-wide mechanosensitive system (Langevin, 2006; Schleip et al, 2006; Stecco et al, 2006; 2007a, 2007b; Benjamin, 2009) for coordinated movement.



Undoubtedly fascia is of great importance to many surgeons, physiotherapists and other professionals working in health-related fields.

One anatomical structure not often described in relation to the above roles is the fascia lata. The fascia lata is the deep fascia of the thigh briefly described as “a strong, dense, broad single layer of deep fascia investing the thigh muscles like a stocking” in most textbooks of anatomy. As part of the deep fascia of the lower limb, it has only been described in context to its position. Furthermore, regional descriptions of the thigh muscles mostly exclude detailed descriptions of the fascia lata and its relationships to underlying muscles except for the tensor fasciae latae and gluteus maximus muscles (Hollinshead, 1969).

## 1.1 Problem statement

With increased pressure on time allocated to the study of anatomy, the use of prosected specimens, illustrations, atlases and computer aids are replacing dissection as a learning method (Skidmore, 1995; Percac and McArdle, 1997). As a result, practitioners in the fields of surgery and rehabilitation start out with a fractional view of functional anatomy. This may be due to limited understanding of important fascial characteristics: firstly, that we are dealing with **fascial continuity** throughout the body and secondly the important **functional-mechanical value** of its architecture.

When dissecting, a technique of blunt dissection using a finger, handle of the scalpel or a closed forceps to separate and follow tissue planes is advised (Tobias and Arnold, 1977 p8; Kieser and Allan, 2001 p6) - especially in the limbs. For good anatomical definition, students are further advised to free and elevate a structure from its surrounding connective tissue in order to appreciate its three-dimensionality (Tobias and Arnold, 1977 p9). By aiming to visualize and present a clean, clear and orderly locomotor system, delicate and



often subtle fascia/muscle relationships are destroyed before they are noticed leaving students with a fragmented view of relationships that may play important functional biomechanical roles.

One area where there is a paucity of information is in the functional relationships of fascia to underlying muscles. Standard descriptions of fascial relationships state that the deep fascia constitutes the muscle epimysium in the neck and trunk, while it is merely referred to as a stocking in the limbs (Tobias and Arnold, 1977 p54).

The growing awareness of fascial importance in musculoskeletal dynamics is therefore calling for better documentation of fascial relationships in the body. Observed dissection relationships between the fascia lata and the underlying extensor muscles of the thigh do not seem to fully match textbook and literature descriptions. For this reason, a more complete model for the fascia lata as a structure relating to the muscles of the thigh needs to be considered.

### **1.1.1 Research question**

Taking the general views on fascial relationships and the fascia lata expressed above into consideration, the **research questions** are:

1. Is the fascia lata in a uniform “stocking” relationship to the anterior muscles of the thigh as described in anatomy texts, or are there variations in this relationship not fully documented or clear from existing texts?
2. Can observed dissection relationships be seen in thighs of living subjects with the existing diagnostic methods of Magnetic Resonance Imaging and Ultrasonography?



### **1.1.2 Hypothesis**

The fascia lata of the thigh is not just in a uniform stocking relationship to underlying muscles. Diverse fascial relationships exist that differs from documented descriptions with areas of close epimysial relationships existing between fascia and muscle not previously described in anatomy textbooks or literature. It is further hypothesized that observed fascial relationships encountered during detailed dissections can be matched with Magnetic Resonance Imaging and Ultrasonography in living subjects.

## **1.2 Purpose and aims**

The primary purpose of this study was to answer the research questions (1.1.1), to test our hypothesis (1.1.2) and to expand the general pool of knowledge about the associations between fascia and muscle.

It was aimed to answer the questions arising from the problem statement by:

- Doing an extensive literature review of current fascial understanding.
- Investigating what is known about the fascia lata from anatomy textbooks and scientific literature.
- Doing detailed layered and cross-cut dissections of preserved human cadaver thighs.
- Correlating the dissection findings with Magnetic Resonance Imaging and Ultrasonography of living volunteers.

There is an abundance of information available on fascial continuity, but information relating to specific relationships within this continuity is limited. By using the relationship



between the fascia lata and the extensor muscles of the knee as the design for this study, we attempted to move the focus from general information available about fascia and connective tissue onto a well known but poorly understood structure – the fascia lata.

### **1.3 Limitations**

An anatomical study of this nature has inherent limitations. These could be listed as the nature and familiarity of the subject matter - the fascia lata, using a relatively small sample sizes, using preserved cadaver specimens as opposed to fresh specimens and limited investigator's experience.

Dissection observations are as old as the history of anatomy itself. One would therefore assume there is little more to learn from gross anatomical dissections and macroscopic observations. Reflection of the fascia lata from the underlying muscles of the thigh is part of every dissection in anatomy learning. This thought alone put doubt on the validity of observations and interpretations in the mind of the investigator. It was therefore decided to keep the study design as simple as possible, with defined criteria in interpreting observations. Regardless of the care taken in defining the limits of the study, the final results of observations and investigations may still be open to different interpretation by different individuals or specialties in medicine and rehabilitation.

### **1.4 Organization of the remainder of this dissertation**

The remainder of this dissertation consists of a literature review (chapter 2), design, methods and materials of the study (chapter 3), the results and discussion of detailed layered dissections (chapter 4), a correlation study between cross cut dissections, Magnetic Resonance Imaging and Ultrasonography (chapter 5) and a general discussion of the



results, research questions and aims of the study (chapter 6) before a final conclusion is reached (chapter 7).

The first part of chapter two expands on the roles, significance and functions of fascia in musculoskeletal mechanics with an overview of fascial literature. From textbooks of anatomy, the morphology of the fascia lata is presented. The search for literature addressing similar issues to this present study yielded a very limited number of relevant papers for inclusion. Search results and identified studies on methods used in dissections of the thigh are discussed critically.

Chapter three describes the choice of study design, materials and methods used during detailed dissections, cross-cut (axial) dissections, Magnetic Resonance Imaging and Ultrasonography.

Results and observations are presented and discussed in chapters four and five.

A discussion of the results, observations, whether the aims of the study was achieved, recommendations regarding further studies and the possible clinical relevance of a better understanding of the fascia lata and its relationships are presented in chapters six and seven in conclusion.



## **2 A GENERAL REVIEW OF LITERATURE ON FASCIA AND THE FASCIA LATA IN PARTICULAR**

*“The journey deep into human flesh initiated by dissection is what made Western Medicine unique..... even if that has also encouraged a tendency to myopic reductionism, to miss the whole by concentrating exclusively upon the parts” (Porter, 2002, p 55).*

### **2.1 Fascial understanding**

#### **2.1.1 Introduction**

Close to 500 years after Vesalius (1514 – 1564) one may take for granted that macroanatomy of the human musculoskeletal system is well documented and appreciated. Despite this, remarks relating to inadequate attention assigned to the omnipresent connective tissue and fascial systems keep surfacing from time to time. One of the most influential anatomists of the 20<sup>th</sup> century, Professor Frederick Wood Jones writes that “in human anatomy, fascias are apt to be described without regard to their real significance and function” (Jones, 1920 p 122). Mozan and Keagy (1969) comments that “fasciae, when considered at all, are usually dismissed summarily as mere vectors for carrying neuromuscular structures to various organs and muscles, or as partitions that enable the anatomist to categorize the body into compartments”.

Before the introduction of formaldehyde as a preserving liquid in 1893, the process of body decomposition strictly dictated anatomy dissections (Moore, 2005). Dissection out of need progressed from “inside out” as the intestines were the first to putrefy. From here, the study of the body proceeded to the abdominal organs, the chest cavity and heart, following vessels and nerves before finally looking at muscles and bone. “Dissection thinking” is



still the main method of analysing the body – to dissect it into discreet anatomical structures as represented by bones, joints, muscle and organs. In this systematic approach to learning, connective tissue anatomy is often described as a suborganisation of the anatomical structures (Van der Wal, 2009). As a result, **fascial continuity** throughout the body and the important **functional-mechanical value** of its architecture may be overlooked in surgical planning and rehabilitation of musculoskeletal dysfunction.

Fascial continuity (the “whole”) throughout the body is neglected by concentrating exclusively upon the parts being treated or studied. Attempting to understand the important functional-mechanical value of fascial architecture (the “whole”) acted as stimulus for undertaking this study and review of the literature. Furthermore, studying a well known structure like the fascia lata of the thigh in isolation, without an understanding of the unifying roles played by fascia in the body, is of little practical value and does not expand our knowledge base as identified in our problem statement.

As the study of fascia, fascial continuity and relationships is a relatively young field, this literature review was expanded to include general fascial understanding in order to place the importance of a better understanding of the fascia lata and its relationships to underlying extensor muscles of the knee into context. Being a fascial structure, an appraisal of connective tissue and fascial understanding needed to be included in this review before examining literature relating to the study of the fascia lata in particular.

Studying a structure like the fascia lata needs to be done within the context of a mechanical model for human movement. In keeping with our problem statement relating to the understanding and exposure to fascial continuity and its relations to associated structures, a general review of the present knowledge base of fascia was undertaken. Vast volumes of



literature have been written on connective tissue and fascia. With the subject matter of this study being the fascia lata and its related muscles, literature reviewed was limited to fascia in general, design and architecture principles, the lower limb and possible roles of the fascia in upright posture.

### **2.1.2 Search strategy**

The start of the present study coincided with the First International Fascia Research Congress held at the Harvard Medical School in Boston, Massachusetts in 2007. Scientists and clinicians active in the field of fascia research and treatment joined in sharing views for the first time. From the start it was clear that there is a division in fascial understanding and interpretation – views from the laboratory versus views from the clinic. This study is from the background of the clinic, and therefore the histology and the laboratory findings on fascia and connective tissue were largely excluded to concentrate on the macroscopic and design principles of fascia for clinical application.

Using the proceedings from the First and Second Fascia Research Congresses (Findley and Schleip, 2007; Huijing et al, 2009) with selected papers on all the fields of fascia research, literature relating to general understanding of biologic architecture and the possible roles of fascia was identified. From the lists of references, further studies were selected for scrutiny. These studies were collected through electronic databases, the Witwatersrand University Health Sciences Library and through the library staff from other libraries.

For a general overview of fascia, anatomy, physiology and histology, textbooks in the Health Sciences library were consulted. Further searches included the electronic databases of Pubmed and Google Scholar. These searches yielded a vast number of papers and articles of general nature. A full list and discussion of this literature is beyond the scope of



this dissertation. Literature was therefore identified selectively in order to present a general background to the present study of the fascia lata and its relationships.

From the Congress proceedings, the sections on microdynamics yielded background on design. Papers on the roles of fascia in musculoskeletal force regulation and transmission and the deep fascia were studied from the sessions on anatomy and biomechanics. Further work by these authors was traced through electronic databases and the reference lists from identified papers formed the basis for a review on fascial understanding in musculoskeletal dynamics. From the proceedings of the Second Fascia Research Congress in Amsterdam (Huijing et al, 2009) further work by Huijing and Stecco as well as papers on architecture (Van der Wal, 2009) and muscle connective tissue were identified, studied and followed up with electronic database searches.

Further electronic searches yielded several additional papers towards understanding of fascia in general and aspects of fascial morphology, design and possible roles in body dynamics. Only one review article (Benjamin, 2009) was found on fascia morphology and understanding. These papers were summarised and are presented here as background to an understanding of where the present study of the fascia lata and its relationships would augment fascial understanding.

### **2.1.3 Fascial biology**

All fasciae are forms of soft connective tissue i.e. the ‘connective tissue proper’ of standard histology texts (Junqueira and Carneiro, 2003 p95). It makes up a large proportion of the total body mass, is highly specialized and has a diversity of roles. Structurally, it provides a matrix that connects and binds the cells and organs, maintains form in the body and ultimately provides mechanical support and movement quality to the body. There are two



classes of connective tissue proper – loose and dense of which dense connective tissue is the dominant component of fasciae. Dense connective tissue is made up of cells, extra cellular matrix and a clear predominance of collagen fibres. It is less flexible and far more resistant to stress than loose connective tissue and adapted to offer resistance and protection. Dense regular connective tissue is arranged according to a definite pattern e.g. sheets (aponeuroses and fasciae) or bundles (tendons and ligaments).

Fascia and all of its components provide a close connection from muscle to bone, bone to bone and organs to their supporting structures. Together they form an independent system of strength, support, elasticity, and cushioning (Lindsay, 2008 p1). It forms continuous, uninterrupted chains throughout the body. Fascia is however not a uniform tissue and is encountered in several forms during routine dissections, each of which plays a specific functional role in musculoskeletal dynamics.

During dissections, two prominent forms of fascia is routinely encountered – the superficial and deep fasciae. Each of these fascial forms plays important functional roles and is therefore included in this review although only the fascia lata (deep fascia) is the subject of this study.

**Superficial fascia:** The presence of a significant layer of fat in the superficial fascia (*panniculus adiposus*) is a distinctive human trait (Benjamin, 2009). It provides passage for nerves and blood vessels to and from the skin, and it houses various quantities of adipose tissue. It may be organised into one or more horizontal layers (membranous layers) containing varying amounts of fat (Abu-Hijleh et al, 2006).

The available movement in this layer is important for freedom of movement in the entire musculoskeletal system. This is particularly evident over highly mobile joints and on the



dorsum of the hand. Mobility protects both skin and structures deep to it from physical damage.

**Deep fascia:** The deep fascia in the limbs and back are typically dense connective tissue sheets that have large numbers of closely packed collagen fibres where the dominant cells are fibroblasts. It encapsulates individual muscles as well as groups of muscles.

#### **2.1.4 Functions and roles of fascia**

Fascia has many functions relating to musculoskeletal dynamics. These range from its role as an ectoskeleton by supplying additional muscle attachments, the importance of creating osteofascial compartments for muscles, encouraging venous return in the lower limb, dissipating stress concentration at entheses and acting as a protective sheet for underlying structures. Emphasis is placed on recognising the continuity of fascia between regions and understanding its key role in coordinating muscular activity by acting as a body-wide proprioceptive organ. Such considerations far outweigh the significance of viewing fascia in a regional context alone (Benjamin, 2009).

##### **2.1.4.1 Muscular architecture and mechanics**

Muscle architecture varies across muscles and muscle groups according to the muscles' functional roles. In a joint system, the architecture of a muscle or muscle group needs to be suited specifically to the force requirements of the joint (or joints) served. The evolutionary solution of the problem is to have several muscles or motor units of varying architecture working in synergy over the same joint (Stecco, 2004; Blazevich et al, 2006) within well contained and organised fascial compartments (Purslow, 2002). The deep fascia performs its compartmentalising role in conjunction with the associated bones and intermuscular septa to form osteofascial compartments. Each segment of a limb has its



own characteristic compartment separating functional groups of muscles with distinctive embryological origins, blood and nerve supplies. The very existence of sheets of connective tissue surrounding muscle groups in the body suggests that they may play a strategic mechanical (Aspden, 1990) and coordinating (Stecco, 2004) role in musculoskeletal function.

**On the mechanical level,** Purslow (2002) suggests that the less explained adaptation of why synergistic muscles are packed into pressure-tight compartments may be that compartmentalisation increases the efficiency of muscle contraction. Even with only one muscle contracting, compartment pressure is increased (from 15 mmHg in normal contractions to approximately 80 mmHg in titanic conditions). Westneat et al (1998) explains that increased pressure may be caused by the shortening and swelling of a constant volume of muscle tissue compressing against surrounding fascial sheaths.

Constraining lateral muscular expansion by surrounding it with a strong fascia may therefore increase the strength and stiffness of the muscle by about 5 to 10%, but possibly even by as much as 100% - even at low pressures for any given length of contraction (Aspden, 1990; Hukins et al, 1990). Conversely, cutting the fascia releases 50% of this normal pressure generation and decreases contractile force by 16% (Mozan and Keagy, 1969; Garfin et al, 1981). This aspect of efficiency of muscle contraction is one that is almost entirely overlooked by conventional experiments on muscle physiology.

**On the coordinating level,** Stecco (2004) describes well defined myofascial units comprising of monoarticular muscles, biarticular muscles, connections between deep and superficial parts of the muscles, as well as connections between agonist and antagonist for each joint of the body. For every myofascial unit he describes a well-defined centre of



coordination within the supporting and surrounding fascia involved in coordinating the available movements for every joint and limb. By muscles attaching to fascia as well as bone, muscles are effectively linked together to promote their contraction as a co-ordinated unit (Benjamin, 2009).

#### **2.1.4.2 Force transmission**

Fascial interconnections promote coordinated activity between muscles and muscle groups. Fascial routes and continuity must therefore also be recognised as a method of force transmission between muscles and its surroundings. Huijing (2009) defines this as epimuscular myofascial force transmission where contraction forces generated within a muscle are transmitted beyond its epimysium to extramuscular tissues such as the neurovascular bundles, intermuscular septa, fascial sheaths, periosteum and interosseous membranes. Muscles from an anatomical perspective can therefore not be regarded as isolated units controlling forces and moments (Benjamin, 2009). This embraces the idea that agonists and antagonists are mechanically coupled via fascia (Stecco, 2004; Huijing, 2009). Huijing (2009) further argues that forces generated within a prime mover may be exerted at the tendon of an antagonistic muscle and that myofascial force transmission can take place between all the muscles of a particular limb segment. Forces generated in one muscle can thus be transmitted to joint capsules and ligaments, other muscles within the same or even another compartment and ultimately bones.

#### **2.1.4.3 Fascia as an ectoskeleton**

Of particular interest for this study was the work by Jones (1920, 1944) and more recently Stecco et al (2006; 2007a; 2007b; 2009a; 2009b). Like muscle and bone, fascia is an adaptation of structure and function. In maintaining an upright posture, the human



musculoskeletal system has to alternate between a rigid column for stability and passive support, and a mobile unit for locomotion and movement. Muscles adapt to this dual role by gaining wide, less discrete insertions to ensheathing membranes and fasciae, as well as to its deeper intermuscular septa and partitions (Jones, 1944; Stecco et al, 2006). This is particularly true in the human lower limb.

By muscles gaining widespread and imprecise, but powerful attachments to large areas of the limb as a whole rather than to its individual moving parts only, the extensive fascial sheets provide a functional homologue of an ectoskeleton for the limb – a “soft tissue skeleton” complementing the bony skeleton (Jones, 1944). This concept is further refined by Stecco et al. (2007b) describing fascia as a flexible skeleton onto which muscle fibres are anchored with the purpose of distributing and directing muscular forces within the locomotor system. It has also been demonstrated that the fascia is maintained at a basal tension by muscular insertions into it (Stecco et al, 2007a). When these muscles contract, they transmit part of their traction forces to the fascia (Stecco et al, 2009a; 2009b), sometimes influencing body-wide responses (Myers, 2009; Stecco, 2004). Huijing and Baan (2008) suggest that one of the functions of myofascial force transmission is to stiffen this soft tissue skeleton and consequently improve its function.

It can therefore be assumed that the role of fascia as an ectoskeleton stiffened by muscles attaching into it and transmitting forces influencing the lower limb as a unit may be seen in the evolutionary changes in man changing from quadroped to biped. Adapting to an upright bipedal gait helped man become a highly successful predator by virtue of its exclusive lower limb design and exceptional endurance running ability (Carrier, 1984; Bramble and Lieberman, 2004).



The more traditional view of the human lower limb as a stabilised unit for locomotion while at the same time supporting body weight in an upright position still holds (Jones, 1944; Benjamin, 2009). Combining these dynamic and passive roles of the lower limb acted as stimulus for evolutionary changes where some muscles attach to the limb as a whole column (bone as well as fasciae) rather than to its moving parts (bony levers) only (Benjamin, 2009). This fits with the view that muscles and tendons that gain widespread insertions to fasciae use these extensive sheets as a functional homologue of an invertebrate ectoskeleton (Jones, 1944).

Bramble and Lieberman (2004) point out that the lower limb is a highly specialised unit with anatomical features that are inactive during walking and supporting an upright posture. There are basic biomechanical differences that distinguish the running gait from walking in all mammals. Walking uses pendular mechanics that differ from the mass-spring mechanics of running. Running uses collagen-rich tendons and ligaments in a compliant limb where muscles and tendons sequentially store and release strain energy during the stance phase of the stride cycle (Bramble and Lieberman, 2004). Several human features make bipedal endurance running an effective mode of transport over long distances. Whereas these efficient features can have comparatively little effect on energy saving during an inverted pendulum walk, they are estimated to save approximately 50% of the metabolic cost of running (Bramble and Lieberman, 2004).

There are several specific anatomical differences between the hind limbs of humans, primates and other mammals. Together with heavier and stronger thigh muscles, there is no other mammal that has a distinct iliotibial tract as seen in man (Kaplan, 1958). Humans further have longer legs with more compact feet, shorter toes and longitudinal arches,



expanded limb joint surfaces, a short femoral neck and a long Achilles tendon when compared to other primates (Bramble & Lieberman, 2004).

Running humans expend about double the energy per unit mass as typical mammalian quadrupeds of the same size. Humans nevertheless have exceptional locomotor stamina (Carrier, 1984). This is made possible by the efficiency of a finely tuned system of storing and recovery of the energy used for motion within each stride. Energy saving due to this transfer between potential and kinetic energy, increased efficiency of muscle contraction by compartmentalisation, fascially coordinated muscle contraction within a limb and force transmission within a fascial ectoskeleton is substantial. It is therefore fair to presume that every structure in the supporting lower limb of man contributes to minimising the use of energy per unit distance travelled – **including the fascia lata**.

## **2.2 The fascia lata of the thigh**

For a better understanding of the role of fascia in general and the fascia lata in particular, anatomical understanding of fascial relationships to its associated and surrounding structures and its architecture is essential. For the extensor muscles of the thigh, the study of muscle architecture is well established. The muscle length, muscle fascicles, pennation angles and physiological cross-sectional areas has been extensively documented (Blazevich et al, 2006; Becker et al, 2010). One omission from all these studies however, is the relationship and role of the surrounding deep fascia of the thigh – the fascia lata. All the anatomical structures and parts that constitute the extensor mechanism of the knee have been well examined and documented, but the unifying role of the fascia is poorly documented and understood. A review was therefore undertaken to establish information currently available on the morphology of the fascia lata.



Literature was widely consulted in order to gain as much information as possible regarding aspects of connective tissue and fascia relating to musculoskeletal dynamics. This included the histology of fascia and musculoskeletal architecture as discussed above. Further literature searches were narrowed to focus on the extensor mechanism of the knee with special attention to anatomical studies and other methods of gaining insight in musculoskeletal relationships and design pertaining to this particular research topic. In order to refine our study design and validity, correlation studies where anatomical dissection findings were compared with Magnetic Resonance Imaging and Ultrasonography were included. Correlation studies between combinations of the three selected methods of studying relationships were readily available, but studies relating to the present project could not be found and therefore only selected papers were included in this review. As available information on the fascia lata proved limited and not very helpful in the planning of this study, selected papers on the use and harvesting of the fascia lata in plastic and reconstructive surgery were also consulted.

### **2.2.1 Search strategy**

Between 2007 and 2010 articles, papers and studies relating to fascia and connective tissue were collected. It was initiated as an informal search using the PubMed and Google Scholar search engines to identify articles relating to fascial mechanics and morphology. Relevant articles were further scrutinised for papers from the list of references as well as hand searches from available journals in the library of the Faculty of Health Sciences, University of the Witwatersrand, Johannesburg. These search strategies yielded several articles on the general trends in fascial research and understanding. Literature relating to dissection studies of deep fascial structures was largely limited to work in areas other than the fascia lata and emanated predominantly from the Department of Human Anatomy and



Physiology, University of Padova, Italy, in collaboration with the Department of Anatomy, Université Paris Descartes, in France.

For information on the fascia lata as a structure and the extensor mechanism of the knee, textbooks from the Anatomy and Physiology, Orthopaedic Medicine, Plastic and Reconstructive Surgery and Physiotherapy sections of the University library were consulted. For descriptive trends in the relevant anatomy, older textbooks in anatomy available from the Adler Museum, Faculty of Health Sciences, University of the Witwatersrand, Johannesburg were referred to.

Looking for more detailed dissection studies, the search was extended to hard copies of journals in the anatomy, orthopaedic and related surgical fields. Detailed dissection studies of the extensor mechanism of the knee mostly yielded information on special and exclusive structures relating to surgical planning and treatment and relevant mainly to orthopaedic surgery. The views expressed on the extensor muscles – the quadriceps femoris muscle group – echoed what was found in textbooks of anatomy.

To cross check the available dissection literature, a more detailed PubMed search was done in order to find relevant information for the present study of the fascia lata, deep fascia or the iliotibial tract of the thigh relating to anatomy and dissection. As the primary aim of this study is to explore the relationship between the fascia lata and the underlying extensor muscles, further papers were identified from review articles (Smith et al, 2009; Becker et al, 2009) to search for the observed relationships between fascia and muscles in the thigh.

### **2.2.2 Results of the literature search and selection of studies**

A search for scientific papers on the PubMed Electronic Database yielded 10 papers when using search words “fascia lata AND anatomy AND gross morphology”. Non-English



articles, non-human subjects and histology articles were excluded. This left two articles relating to the fascia lata and anatomy. One was a review of fascia (Benjamin, 2009) and the other the functional anatomy of the iliotibial band for understanding the iliotibial band friction syndrome (Fairclough et al, 2006).

Using “iliotibial band AND iliotibial tract AND anatomy AND biomechanics” as search words produced two papers. One, again the paper by Fairclough et al (2006) and the other on the functional construction of the fascial system of the lower limb (Gerlach and Lierse, 1990).

Using “deep fascia AND thigh” as search words resulted in 100 papers. Again, non-English articles (15) were excluded. Further exclusions were: plastic and reconstructive surgery (36), pathological conditions (24), anatomy of vessels and nerves (18), skin (1) and hamstrings (2). Four papers were deemed relevant and selected for review. Common aspects of the pectoral and femoral fasciae (Stecco et al, 2009b), the functional construction of the fascial system of the lower limb (Gerlach and Lierse, 1990) as above, Magnetic Resonance Imaging findings on the iliotibial band friction syndrome, and a paper describing Inguinal anatomy. From the identified papers, only Gerlach and Lierse (1990) and Stecco et al (2009b) mentioned dissections of the fascia lata as part of their investigations. The paper describing a Magnetic Resonance Imaging study of the ITB and the paper on the inguinal anatomy were excluded as they proved irrelevant to the present project.

From two recent knee extensor muscle review articles (Smith et al, 2009; Becker et al, 2009) a further nine papers were viewed for sample size, methods and morphology of fascia/muscle relationships and deemed useful towards the present project.



Textbooks utilised for content on the fascia lata and the extensor mechanism of the knee spanned a time period of roughly 130 years, from 1878 (Sharpey et al.) to 2008 (Standring). Five dissection manuals were also consulted. All the textbooks and dissection manuals in Anatomy had descriptions of the fascia lata and its attachments as well as the components of the extensor compartment musculature. All the studied texts reflected essentially the same information with either more or less detailed descriptions of the material investigated.

As an abundant number of papers from the field of plastic and reconstructive surgery were identified in our literature search, three papers relating to the fascia lata itself were selected for inclusion based on improving general understanding of the subject. For further information on the relevance or not of using available diagnostic procedures (Magnetic Resonance Imaging and Ultrasonography) textbooks from the relevant sections in the same library as above were consulted, as well as papers identified from reference lists in reviewed papers.

When considering that our detailed searches basically yielded only 16 papers as vaguely relating to the morphology and relationships of the fascia lata, the above provides an indication of the paucity of literature, especially of empirical studies on this research topic.

### **2.2.3 Overview of the literature consulted**

#### **2.2.3.1 Literature relating to morphology**

The main focus and aims of the 16 papers identified as relating to the morphology and relationships of the fascia lata to underlying muscles varied significantly and it was evident that none examined the fascia lata relationships. In the two papers describing dissection and study of the fascia lata (Gerlach and Lierse, 1990; Stecco et al, 2009b) the total sample



size studied was seven legs. The primary aim of the Gerlach and Lierse (1990) study was in creating a three-dimensional model of the fascial sleeve of the lower limb (dissecting one limb), while for Stecco et al (2009b) their purpose was to clarify macroscopic and microscopic differences between the pectoral and limb fasciae in relation to underlying muscles, collagen fibres and type of innervations. In the review article discussing fascia, Benjamin (2009) placed emphasis on the functions of fascia, recognising the continuity of fascia between regions and appreciating its key role in coordinating muscular activity and acting as a body-wide proprioceptive organ.

The 11 papers (two reviews and nine studies) on the extensor mechanism of the knee, described the soft tissue components of the knee and its functions separate from its surrounding deep fascia – the fascia lata. Four of the studies addressed the vastus medialis obliquus controversy, i.e. whether the vastus medialis muscle should be seen as a single muscle, or whether the more oblique distal fibres of the muscle should be classified separately as the vastus medialis obliquus muscle (Nozic et al, 1997; Hubbard et al, 1998; Peeler et al, 2005; Toumi et al, 2007). One study (Becker et al, 2010) presents a comprehensive report on the vastus lateralis, and four papers discuss the complex distal extensor mechanism and relationships (Lieb and Perry, 1968; Reider et al, 1981; Weinstabl et al, 1989; Andrikoula et al, 2006). Smith et al (2009) presented a full review of the literature concerning vastus medialis, while Becker et al (2009) covered vastus lateralis in their review.

In two further papers (Terry, 1989; Dye et al, 2003), Terry gives a full descriptive overview of the extensor mechanism of the knee and Dye described the fascial layers anterior to the patella.



Although most of the anatomy textbooks in the Health Sciences Library were consulted, not all the available textbooks are included in this review. As an anatomic entity, the fascia lata of the thigh is well but curtly described in practically all anatomy textbooks. As a structure though, it is only described in context to its position and as “another anatomic structure.” It draws limited attention other than on descriptive terms. This is in contrast to the detailed descriptions of its continuities, its relations to and around the inguinal (Poupart’s) ligament and its attachments and the thickening of the lateral surface, the iliotibial band or tract. Descriptions of the fascia lata in dissection guides (Owen, 1890; Cunningham, 1896; Tobias and Arnold, 1977; Romanes, 1986; Kieser and Allan, 2001) do not differ much in detail from descriptions found in main textbooks of Anatomy.

#### **2.2.3.2 Literature relating to diagnostic tools**

In literature relating to the second part of this study - can relationship between fascia and muscle be seen or identified in thighs of living subjects using Magnetic Resonance Imaging and Ultrasonography – several articles were found describing the correlation between dissection, Magnetic Resonance Imaging, Ultrasonography or combinations of the three. No articles on fascia and fascial relationships were found. In two papers (Abu-Hijleh et al, 2006; Blazeovich et al, 2006), Sonography was used as research tool rather than as a diagnostic tool. We therefore only reviewed a small selected number of papers to clarify the feasibility and reliability of using Magnetic Resonance Imaging and Ultrasonography in a study of this nature while limiting ourselves to anatomical areas overlapping with the present research topic.

Both Magnetic Resonance Imaging and Ultrasonography are well established tools in evaluating and correlating specific musculoskeletal and anatomical entities (e.g. Starok et



al, 1997; Barker et al, 2009). The key value of imaging is as an accurate diagnostic tool in pathological conditions, a usefulness not missed in musculoskeletal conditions (Muhle et al, 1999; Connell et al, 2004; Girish et al, 2007). There are however limitations to all imaging tools with strengths and weaknesses of both Magnetic Resonance Imaging and Ultrasonography with its value best utilized in diagnostic and pathological fields.

Ultrasonography is fast gaining popularity in clinical practice with advances in technology and cost effectiveness of equipment (Nazarian, 2008; Jacobson, 2009).

#### **2.2.3.4 Literature relating to plastic and reconstructive surgery**

In order to gain further insight on fascia lata relationships to underlying muscles, literature from the Plastic and Reconstructive Surgery discipline were consulted. There is an abundance of literature available from this field, but only three articles were selected as representative for the needs of this project.

The deep fascia encircling the thigh, the fascia lata, has been described as a highly useful and abundant source for connective tissue needed for a variety of purposes by every surgical discipline (Amir et al, 2000). It is seen as a useful tissue to transplant as interposition material, as a contour-restoring tissue, to repair facial paralysis, aortic valve replacements (Snyderman, 1977), dural reconstructions (Amir et al, 2000) and as part of anterolateral thigh flaps used in a variety of ways in multiple body sites (Ali et al, 2009). Its popularity as a donor tissue stems from it being a sturdy layer that is sufficiently pliable in order to span irregularly shaped defects (Amir et al, 2000) and its comparative tensile strength being nearly as strong as soft steel in a weight for weight comparison (Snyderman, 1977).



## **2.2.4 Critical appraisal of literature reviewed**

### **2.2.4.1 Literature relating to dissection**

In the 12 studies relating to dissections of the fascia lata and extensor mechanism of the knee several methodological limitations were consistently identified. One major limitation was the description of dissection techniques used in order to remove the fascia lata from underlying muscle. In seven of the studies the method of fascia lata removal (how) was not recorded (Lieb and Perry, 1968; Gerlach and Lierse, 1990; Nozic et al, 1997; Andrikoula et al, 2006; Toumi et al, 2007; Stecco et al, 2009b; Becker et al, 2010). In one study the fascia lata was removed by blunt dissection (Peeler et al, 2005), two studies (Reider et al, 1981; Weinstabl et al, 1989) describe “dissected free” as the removal method while blunt and sharp dissection is mentioned as removal method by two studies (Hubbard et al, 1998; Dye et al, 2003).

In only two studies the deep fascia of the leg formed the object of study (Gerlach and Lierse, 1990; Stecco et al, 2009b). In creating a fascial model of the lower limb, Gerlach and Lierse do not describe the dissection techniques employed in any detail – simply removing the muscle to create a “hollow limb”. In the Stecco et al. study, incisions for clearing of the skin, superficial and deep fascia is described while removal of the deep fascia is not described or the findings documented in any detail. They do however mention that the fascia lata is “easily separable from all the muscles of the thigh” by a virtually uninterrupted plane of sliding between the fascia lata and the muscle bellies. The value of this study lies in the measurements of fascial thickness obtained from histology samples.

In all the remaining studies the primary focus was one or other specific part of the extensor mechanism, and the fascia lata only mentioned in passing while cleaning the area for



specific observations. Only the distal part of the quadriceps and its attachments, or the fibre angle and orientation of the muscle itself were studied.

#### **2.2.4.2 Literature used from field of radiology**

Radiology papers have a strong emphasis on identifying and describing pathology and injury within the musculoskeletal system. They consequently place a high premium on accurate anatomical correlation between dissection, Magnetic Resonance Imaging and Ultrasonography views. In the two non-diagnostic Ultrasonography papers (Abu-Hijleh et al, 2006; Blazeovich et al, 2006), Abu-Hijleh et al (2006) investigated membranous layers within the superficial fascia in different regions of the body by correlating dissection and sonography findings. They studied existence, topography and thickness of the membranous layers and concluded that the dissection findings and sonography findings corresponded reliably. Blazeovich et al (2006) identified the use of 2D Ultrasonography as a reliable method for measuring muscle thickness, muscle fascicle angles and fascicle lengths from sonographs. The echoes reflected from the superficial and deep aponeuroses and the interspace among fascicles clearly delineate these structures and allow architectural measurements. Muscle thickness has also been validated against Magnetic Resonance Imaging scans in various human muscles (Dupont et al, 2001).

No studies were found commenting on fascial relationships and therefore a number of studies were selected for guidance in interpreting the observations of the present fascia lata study. Sonin et al (1995) described the Magnetic Resonance Imaging appearance of the extensor mechanism of the knee in detail followed by the description of traumatic injury patterns. They however only described muscular, tendinous, retinacular and bony components of the anatomy with no reference to any fascial presence in their images.



Starok et al (1997) correlated Magnetic Resonance Imaging, Ultrasonography and axial dissection cuts for studying the nature of the lateral and medial patellar retinaculae. They showed good correlation between the Magnetic Resonance Imaging and Ultrasound images but identified limitations on both Magnetic Resonance Imaging and Ultrasonography investigations. Magnetic Resonance Imaging had the difficulty of identifying soft tissue components due to lower soft tissue contrast. Similarly Ultrasonography had limitations in showing deep ligament structures as discrete structures in the axial or sagittal planes. The more superficial retinaculae were seen as a hypoechoic striated bilaminar structure.

Muhle et al (1999) used correlation of Magnetic Resonance Imaging findings of anatomic features between cadaver legs and symptomatic patients in evaluating iliotibial band (ITB) friction syndrome. The value of this article lies in the use of Magnetic Resonance Imaging to identify the exact position and structure of pathologic changes.

The study of Huang et al (2005) evaluated contracture of the deltoid muscle by correlation of sonography and Magnetic Resonance Imaging. Their final conclusion is that Ultrasonography is helpful and correlates well with Magnetic Resonance Imaging. This study however only comments on pathology and not anatomic features. Closer to the thigh, Koulouris and Connell (2005) correlate Magnetic Resonance Imaging and Ultrasonography in the evaluation of soft tissue injuries of the hamstring muscle complex. Both modalities are described as equally reliable but dependant on operator experience for accuracy.

Barker et al (2009) present Ultrasonography findings on normal anatomy of the posterolateral corner of the knee. They further compare their Ultrasound findings with Magnetic Resonance images of the same region. They concluded that Magnetic



Resonance images may present incomplete visualization of some anatomic components using routine acquisitions. This may also be because of the complex anatomy crossing planes and loss of signal due to magic angle artefact. Magnetic Resonance Imaging is also limited by the need to scan with the knee in extension. Sonography has great potential to visualise superficial structures with the advantages over Magnetic Resonance Imaging of speed, safety, the ability to examine dynamically and the ability to provide comparative examination of the contralateral limb. They warn that an understanding of the normal anatomy is crucial to enable accurate examination and is aided by correlating the Sonographic and Magnetic Resonance appearances. They did not use dissection correlations, but textbook drawings.

#### **2.2.4.3 Literature used from the field of plastic and reconstructive surgery**

The papers studied with regard to its contributions towards the present research topic were limited in numbers and used only for guidance towards donor site selection and method of harvesting donor tissue, the fascia lata.

The commonly used donor site area for obtaining a fascia lata sheath is the anterolateral aspect of the thigh proximal to the knee joint (Snyderman, 1977; Amir et al, 2000; Ali et al, 2009). Fascial strips harvested could range from small pieces, strips of 10 to 15 mm wide (Snyderman, 1977) through large sheets of 10cm X 20cm (Amir et al, 2000) to full thickness fasciocutaneous and musculocutaneous flaps (Ali et al, 2009). The technique for removal of fascia lata may be through the use of a fascial stripper (Snyderman, 1977), bluntly freed from the anterior or lateral muscle compartment after surgical exposure of the fascia (Amir et al, 2000) or as part of major reconstructive procedures (Ali et al, 2009).



With regards to its relevance to our present project, all the literature report on the donor site as being anterolateral in the thigh. This is where the fascia lata is better developed and stronger with its fibre alignment more longitudinal (Snyderman, 1977; Amir et al, 2000). The method of lifting the fascia lata off underlying muscles is consistently described as by methods using blunt dissection techniques (e.g. Amir et al, 2000).

### **2.2.5 The gross morphology of the fascia lata**

*“This is the name which is given to that portion of the general aponeurotic investment of the lower limb which clothes and preserves the figure of the thigh”* (Cunningham, 1896, p210). This description summarises the textbook descriptions of the deep fascia of the thigh with more detail added by some authors.

The fascia lata is the thigh part of the “fascial skeleton” of the lower limb. It is a well-defined, tough circumferential “stocking-like” structure that contains the musculature (Standring, 2008 p1329). Septa pass from the deep surface of this fascial sheath to the bones, forming tight osteofascial compartments around the functional muscle groups (Gerlach and Lierse, 1990; Standring, 2008 p1329). This tough fascial sheath further gives additional areas of attachment to the muscles of the limb to ensure maximal work efficiency for bipedal gait (Jones, 1944 p55; Rosse and Gaddum-Rosse, 1997; Standring, 2008 p1329). Jones (1944) described this as a “functional homologue of an ectoskeleton” for the limb, while this concept was further refined by Stecco et al (2007b), describing fascia as a flexible skeleton onto which muscle fibres are anchored with the purpose of distributing and directing muscular forces within the locomotor system. It further limits outward expansion of contracting muscles, making muscular contractions more efficient



(Aspden, 1990) and by compressing veins aids in the return of blood to the heart (Rosse and Gaddum-Rosse, 1997; Moore and Dalley, 2006 p578).

Goss (1949 p467) described the fascia lata as continuous proximally with the external abdominal and lumbodorsal fasciae after being attached to the pelvic bone and inguinal ligament. Most other authors describe its proximal attachments only as the back of the sacrum and coccyx posteriorly, to the iliac crest laterally, the inguinal (Poupart's) ligament and superior ramus in front, and to the inferior pubic ramus, ischium and sacrotuberous ligament medially (Sharpey et al, 1878 p226; Jones, 1946 p559; Hollinshead, 1969 p693; Moore and Dalley, 2006 p578; Standring, 2008 p1349). Understanding the continuity of the fascial system between trunk, thigh and lower leg can therefore easily be lost or seen as of lesser functional importance.

Distally, the fascia lata is continuous with the fascia of the leg (Goss, 1949 p467; Moore and Dalley, 2006 p578). In contrast to this, Owen (1890 p452) described it as continuing with the deep fascia over the popliteus muscle of the back of the leg, and anteriorly "it does not reach below the knee, being gradually blended with the fibres of the quadriceps extensor, and with the periosteal covering of the articular ends of the bones." Other authors describe it as attaching to the upper ends of the tibia, fibula and patella (Jones, 1946 p559; Hollinshead, 1969 p694; Standring, 2008 p1350) and blending with the expansions from the quadriceps tendon to form the medial and lateral retinaculae of the patella. Near the knee it is considerably strengthened by tendinous expansions from the lower parts of the extensor and flexor muscles of the knee joint (Sharpey et al, 1878 p226).

The fascia lata differs considerably in thickness in different areas (Romanes, 1986 p136). Posteriorly and on the medial side it is particularly poorly developed over the adductor



muscles (Hollinshead, 1969 p692; Romanes, 1981 p405; Standring, 2008 p1349) and almost transparent, while extremely thick (Palastanga et al., 2002 p294) and immensely tough and strong on the lateral side (Romanes, 1981 p405, 1986 p136) where the tensor fasciae latae and expansions from gluteus maximus muscles are attached to it. It is thicker around the knee where it is strengthened by expansions from the tendon of biceps femoris laterally, sartorius medially, and quadriceps femoris anteriorly (Sharpey et al, 1878 p226; Standring, 2008 p1349). Parts of the ligamentous apparatus of the knee also need consideration as the fasciae of the lower limb are connected to them (Gerlach and Lierse, 1990).

Tobias and Arnold (1977) described the close relationship between deep fascia and its subjacent muscles in the trunk and neck as “constituting their epimysium”. Similar close relationships are however described for parts of the deep fascia of the thigh (Jones, 1944 p54; Hollinshead, 1969 p695). Hollinshead (1969) comments on the close relationship of the fascia lata to the underlying gluteus maximus muscle as “being closely attached to this muscle by the septa which it sends into it,” while Jones (1944) describes this close relationship as “gluteus maximus relinquishing its grip on the gluteal ridge of the femur and increasing its hold on the ensheathing fascia of the leg.” A similar close relationship between fascia and muscle is described for the tensor fascia lata muscle as having “altogether abandoned a bony attachment and has become incorporated into the tractus ilio-tibialis” (Jones, 1944 p54). Gluteus medius also uses the overlying fascia lata as origin (Hollinshead, 1969 p659; Standring, 2008 p1350), while vastus lateralis, vastus intermedius and the short head of biceps femoris are described as partially originating from the lateral intermuscular septum and vastus medialis from the medial septum, but not from



the fascia lata (Hollinshead, 1969 p695; Tobias and Arnold, 1977 p267; Becker et al, 2010).

The fascia lata is tightened by the pelvic deltoid muscle (Gerlach and Lierse, 1990) formed by the gluteus maximus, gluteus medius and tensor fasciae latae muscles and is attached to the femur through the lateral intermuscular septum. Distally the fascia lata passes into the patellar retinaculum, the medial and lateral collateral ligaments of the knee joint and the crural fascia (Gerlach and Lierse, 1990).

### **2.2.6 Conclusion**

Very little is available in the literature directly relating to dissection observations of the relationships between fascia lata and the underlying extensor muscles of the thigh. Only Stecco et al (2006, 2007a, b) related and described muscular attachments to covering fascial structures. More literature is available relating to the second part of the research question on the use of Magnetic Resonance Imaging and Ultrasonography studies to evaluate and correlate dissection findings. However, direct correlation studies using dissection, Magnetic Resonance Imaging and Ultrasonography on the relationships between the fascia lata and underlying extensor muscles is not readily available; hence the essence of this study.

Although areas of close epimysial and aponeurotic relationships between fascia and muscle were confirmed in reports that used routine dissections, it seems as if larger areas of close relationship between fascia and muscle could be observed macroscopically. Searching the literature directly relating to the problem statement and research question generated no literature describing the observed relationships between the fascia lata of the thigh and its underlying extensor muscles.



The fascia lata is mentioned and described in virtually all anatomy textbooks. These accounts are, however, limited to general descriptions of its attachments, morphology and generalised functions as containment structure. A great deal has been published on the extensor mechanism of the knee and muscle architecture relating to function. Most of this is largely peripheral to the research question and abundant information in the fields of connective tissue, fascial and muscular architecture is available.



### 3 RESEARCH DESIGN, METHODS AND MATERIALS

*“Ask the reason of things. Take nothing for granted, subject every common superstition and unproven therapy to scrutiny, question every step you take.”* John Hunter, 1728-1793 (Moore, 2005).

#### 3.1 Research method and design

This study comments on observed relationships between deep fascia and underlying structures encountered in detailed dissections. The variable investigated was fixed i.e. the relationship between the fascia lata and the underlying thigh muscles. It employed a *qualitative method* of research, using a *descriptive non-experimental design* with no manipulation of independent variables (*ex post facto research*) for the following reasons:

- The fascia lata and its relationships to underlying structures cannot be changed or manipulated either prior to, or at time of investigation in both preserved cadaver material and living subjects.
- By using three methods of observation i.e. dissection, Ultrasonography and Magnetic Resonance Imaging in cadaveric and living subjects, the intention was to correlate and describe similarities or deviations in observations between the three methods.
- Only characteristics of fascial arrangements between the deep fascia and the underlying muscles within the sample groups were considered and a descriptive and visual report on findings was therefore favoured.



As non-experimentally designed qualitative research, the structure of the was predetermined and only minor practical changes allowed in the details of the investigation as they became necessary to contribute to a better final understanding.

This was **correlation research** testing observations from detailed dissections. No manipulation of the independent variables took place and it was not attempted to establish a cause and effect relationship. The emphasis was on the relationship between variables by measuring differences in observations between dissection, Ultrasonography and Magnetic Resonance Imaging of the fascia lata.

### **3.2 Subject samples**

Subject samples were kept small with no control group. A sample size of ten cadaveric legs for dissection and four (two male and two female) living volunteers for Ultrasonography and Magnetic Resonance Imaging correlation were selected. The selected sample size was regarded as sufficient to draw sound conclusions from our data when considering the conclusions drawn from several studies reviewed.

### **3.3 Materials, instruments and tools**

This study, protocol number M080425, was approved by the University of the Witwatersrand Human Research Ethics Committee (Medical) on 16 July 2008 with clearance number R14/49 Fourie.

#### **3.3.1 Cadaveric material.**

Ten thighs from five preserved cadavers (two male and three female) between the ages of 70 and 85 years were investigated using macrodissection techniques. All the bodies were



embalmed in a solution containing mentholated spirits, glycerine, phenol, formaldehyde and thymol.

Detailed dissections were undertaken at the School of Anatomical Sciences, Faculty of Health Sciences at the University of the Witwatersrand, Johannesburg, South Africa.

Three of the cadavers were of average body weight, while two could be classified obese. Their causes of death did not impinge upon the structure and function of the fascial and muscular layers examined. Careful dissections were done in two stages. Six thighs (four left and two right thighs) were dissected in detail in layers from dermis to the muscle layer (chapter 4). In the remaining four thighs axial slices (cross cuts) of the anterior compartment were dissected out. These cross-cut slices were correlated with transverse Ultrasonography and axial Magnetic Resonance Imaging findings (chapter 5).

### **3.3.2 Instruments and tools.**

Standard dissection tools such as scalpels with different blade sizes, forceps, scissors and probes were used for all the dissections. Progress and findings were recorded as digital images using a Fujifilm FinePix S5800 S800 digital camera at different stages of the dissection process and stored, grouped and catalogued electronically. For close-up images, some pictures were taken through a dissection microscope and also stored electronically.

Ultrasonography and Magnetic Resonance Imaging recordings were obtained from the Radiology Department of the Life Fourways Hospital in Sandton, Johannesburg under the care of Dr. Glen Buchanan. Ultrasound images were catalogued and filed before being scanned and digitally stored, and Magnetic Resonance Imaging images were similarly scanned and stored digitally.



### **3.4 Data**

Data collection was kept formal and specific according to the predetermined model and limits of the project.

- Data from the detailed layered dissections of the left thighs were captured as digital photographic images taken during progressive stages of the dissections.
- Areas of close epimysial fascial relationships to underlying muscles were mapped on drawings of the thigh.
- Data from the cross-sectional (axial) dissections of the right thighs were similarly captured as digital photographic images. Close-up images were also taken by digital camera using the “zoom” close-up facility of the camera, as well as some pictures taken through a dissection microscope for finer detailed images of fascial relationships.
- Magnetic Resonance Imaging studies were done on a Philips Achieva 1.5 Tesla MRI machine, Royal Philips Electronics, The Netherlands. Images were obtained for coronal and axial views using T1 Weighted Turbo Spin Echo (WTSE) sequences at 5 slices per level with slice thickness at 5 mm.
- Ultrasonography studies were done with a Toshiba Xario Ultrasound machine, Toshiba Medical Systems Corporation, using a 10.2 MHz linear array sound head and a musculoskeletal setup.

Data comparison for this study was largely descriptive and deductive for comparing the three investigation techniques used.



### **3.5 Correlation study analysis**

In order for a conclusion to be drawn from comparisons between the detailed layered dissections, the cross-cut dissections, the Magnetic Resonance Imaging sequences and the Ultrasonography images, findings from the four previously determined levels (levels **I** to **IV**) described above were grouped for comparison.

No statistical analysis of corresponding prevalence of observations was necessary. All observations were at the macroscopic visual level as they would routinely be encountered in normal dissection settings.



## 4 DETAILED ANATOMIC DISSECTION OF THE FASCIA LATA

*“I love to be puzzled, for then I am sure I shall learn something valuable.”* John Hunter, 1728-1793 (Moore, 2005)

### 4.1 Detailed dissection procedures

Using macrodissection techniques with standard dissection equipment (different sized scalpels, forceps, and fine scissors), detailed layered dissections of the thigh were done with the cadaver in the supine position. The skin was carefully reflected to expose the superficial fascia (subcutaneous layer or hypodermis). The superficial fascia was inspected and removed in layers to fully expose the deep fascia of the thigh (fascia lata).

After a median longitudinal incision from the anterior superior iliac spine to patella tendon (fig 4.1 A), the fascia lata was carefully reflected in sections and from individual muscles (fig 4.1 A, B and C). Reflection of the fascia was carried out by carefully lifting the incised fascial edges from underlying structures (fig 4.1 C and D) while observing and documenting fascia/muscle relationships. The ease with which fascia and muscle could be separated from each other was noted and described as either a **close relationship** or a **loose relationship**. Care was taken not to damage underlying muscles by excessive pulling on the fascia. If damage to the muscle was observed, the fascia was removed further by sharp dissection with a scalpel and documented.



A **close relationship** was defined as a section where pulling on the fascia lata with a forceps would potentially damage the underlying muscle structure should pulling be continued (arrow, fig 4.1 C). Visible intramuscular septa passing from the deep surface of the fascia lata between muscle fascicles of the underlying muscle resisted further muscle/fascia separation and subsequently needed the use of a scalpel and sharp dissection in order to reflect the fascia fully.

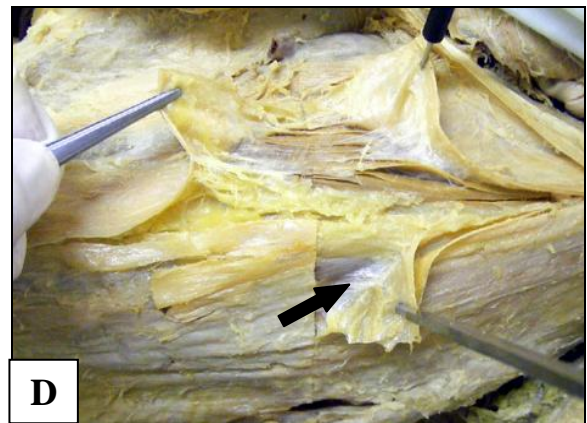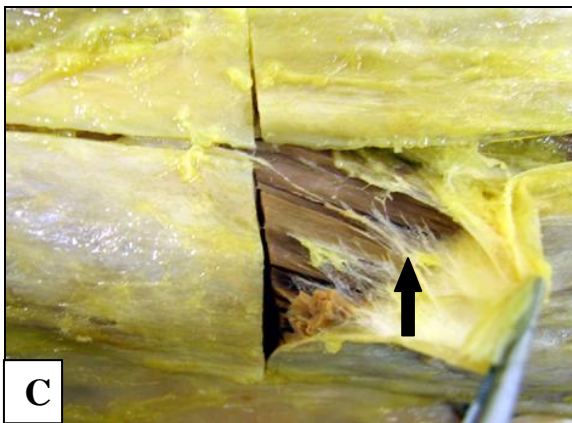
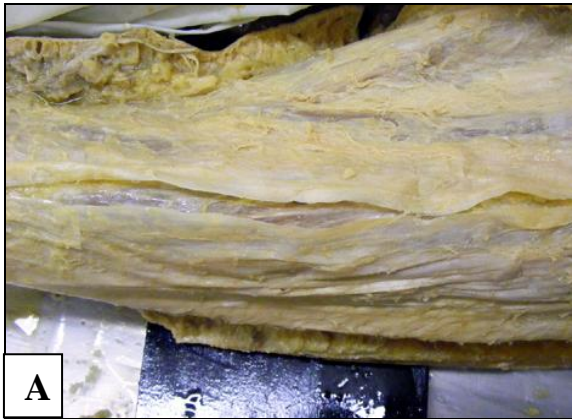A **loose relationship** was defined as a section where pulling on the fascia lata with a forceps allowed separation of fascia and muscle without resistance from intramuscular septa and no damage to underlying muscle fascicles (arrow, fig 4.1 D). Should resistance be met, further reflection using a blunt object (e.g. finger) allowed full damage-free reflection of the fascia lata.



**Figure 4.1** Reflection of the fascia lata from underlying anterior thigh muscles

- A** Median incision of the fascia lata from anterior iliac spine to patellar tendon
- B** Reflection of the fascia lata progressed from proximal to distal in sections
- C** Careful lifting of the fascia from underlying structures while noting ease of stripping and fascial relationships to the underlying structures. The arrow points to a close fascial relationship with intramuscular septa passing between the fascia lata and muscle fascicles.
- D** Careful lifting of the fascia from underlying structures while noting ease of stripping and fascial relationships to the underlying structures. The arrow points to a loose relationship between fascia and muscle.







## **4.2 Image capturing**

The various stages of the dissections and observations were photographed using a Fujifilm FinePix S5800 S800 digital camera.

Camera settings:

- F-stop – f/3.5; Exposure time – auto;
- ISO speed – ISO800;
- Focal length – auto;
- Max aperture – 3.6.

Images were grouped, catalogued and stored electronically at a resolution of 72 dpi, Bit depth 24. From these images representative images were prepared for inclusion into this printed medium using Adobe Photoshop V 6, Adobe Systems Incorporated, 345 Park Avenue, San Jose, CA 95110-2704 USA, [www.adobe.com](http://www.adobe.com). Images were cropped to eliminate unwanted background, levels and contrast adjusted, focus sharpened and resolution changed to 300dpi with image widths at 10 cm and saved as .JPG files.



### 4.3 Results

Captured observations and images from the detailed layered dissections were grouped per layer. From 1029 images captured during detailed layered dissections, the 203 best and most appropriate images were selected as representing the findings. 40 of these images were used for final preparation and inclusion in this chapter. All images were interpreted on macroscopic level only.

#### Legends

##### Shapes used on images to identify described structures.



- Arrowheads: - membranous layers within the superficial fascia



- Solid arrows: - deep fascia of the thigh, the fascia lata



- Open arrows: - adipose or loose areolar connective tissue layers between fasciae and between fascia and muscle



- Star

- Alphabets to represent separate muscles: - e.g. **S** – sartorius, **TFL** – tensor fasciae latae, **RF** – rectus femoris, **VL** – vastus lateralis, **VM** – vastus medialis



#### 4.3.1 The deep fascia or fascia lata of the thigh

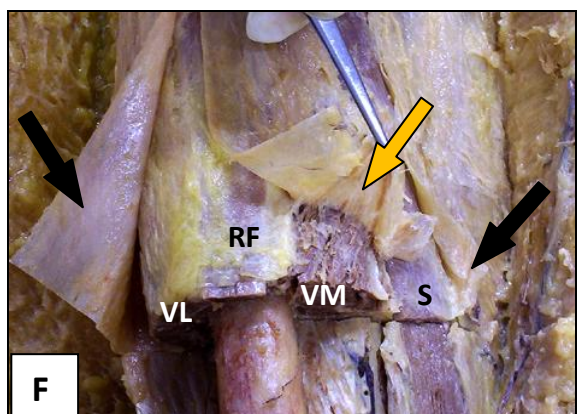
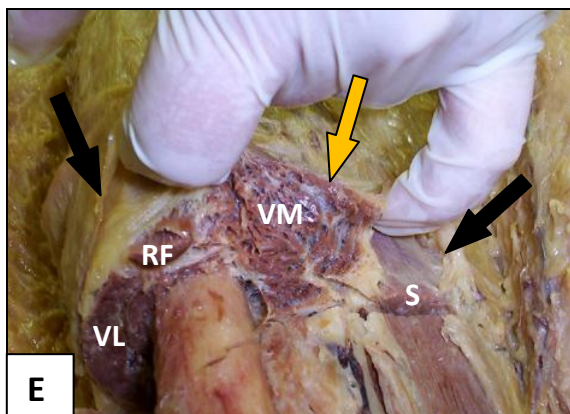
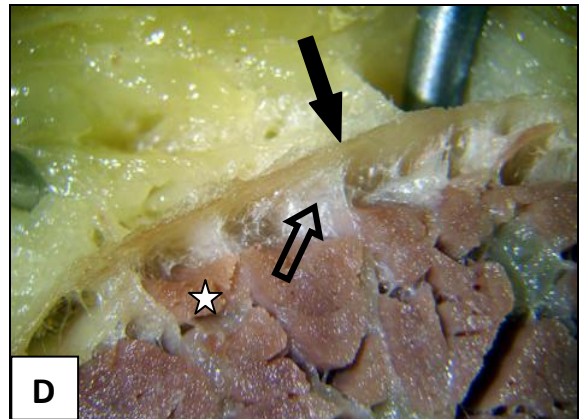
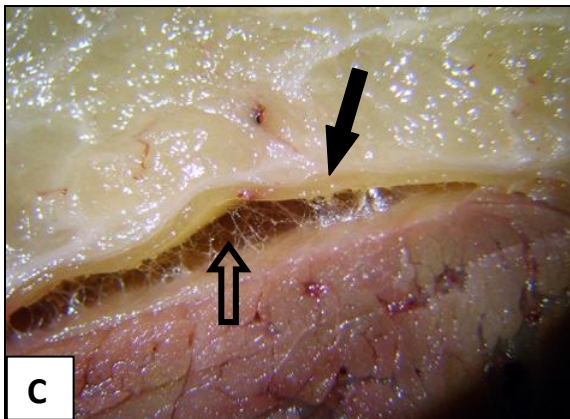
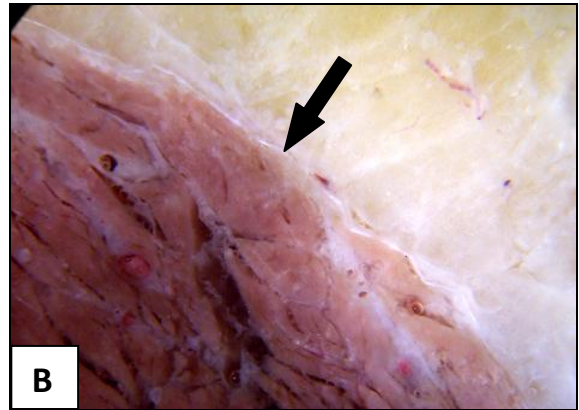
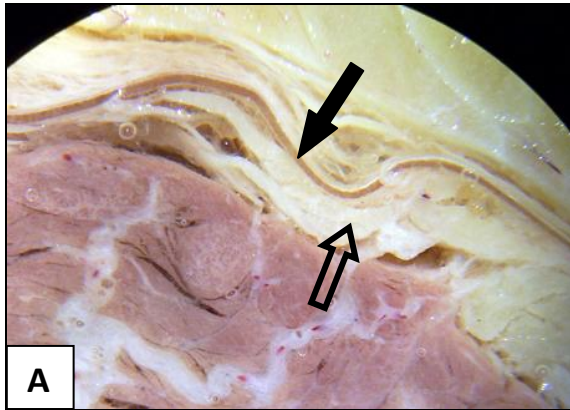
Two different relationships between the fascia lata and underlying muscles were observed. In some areas, the fascia (black arrows) was easily reflected from underlying muscles and was therefore described as an area of a **loose relationship** between fascia and muscle (fig 4.2 A and C). Reflection without damage was possible because of varying amounts of adipose tissue (open arrow, fig 4.2 A), or loose areolar connective tissue (open arrow, fig 4.2 C) between fascia and muscle. In these areas the fascia lata could be reflected without potential damage to underlying muscles ((black arrows, fig 4.2 E and F). In other areas the fascia adhered firmly to underlying muscles, forming a **close or epimysial relationship** between fascia (black arrow, fig 4.2 B) and muscle due to intramuscular septa (open arrow, fig 4.2 D) branching off the deep surface of the fascia between muscle fascicles. In areas of a close relationship, sharp dissection was needed in order to minimise muscle fascicle damage or disruption on removal of the fascia lata (yellow arrows, fig 4.2 E and F).



**Figure 4.2** The relationships (loose and close) between the fascia lata and underlying muscles in the anterior thigh

- A** A transverse section showing a loose relationship between a well defined deep fascia (black arrow) and muscle with a layer of intervening adipose tissue (open arrow)
- B** A transverse section showing a thin layer of fascia (black arrow) in close relationship to its underlying muscle
- C** A transverse tissue section with loose areolar connective tissue (open arrow) between fascia (black arrow) and muscle illustrating a **loose relationship** between fascia and muscle and easily separated by blunt dissection
- D** A transverse tissue section depicting a **close relationship** between fascia (black arrow) and muscle with intramuscular septa (open arrow) passing from the deep surface of the fascia between muscle fascicles (star)
- E** Attempted reflection of the fascia lata (black arrows) from muscles of the lower third of the thigh. Note the different fascial relationships between the vastus lateralis (VL), rectus femoris (RF) and sartorius (S) muscles in a **loose** fascial relationship and the vastus medialis (VM) muscle in a **close** fascial relationship (yellow arrow)
- F** The fascia lata over vastus lateralis (VL), rectus femoris (RF) and sartorius (S) muscles (black arrows) is easily reflected by blunt dissection. Separating the fascia lata and the vastus medialis (VM) needed sharp dissection to minimise damage to underlying muscle fascicles (yellow arrow)







#### **4.3.2 The tensor fasciae latae muscle**

On reflecting the upper fascia lata from medial to lateral, the fascia was seen to split into two laminae covering the superficial and deep surfaces of the muscle (solid arrows, fig 4.3 A, B and E). Lateral to the tensor fasciae latae muscle, the fascia lata became a single layer again continuing over the gluteus medius muscle as the thickened gluteal aponeurosis.

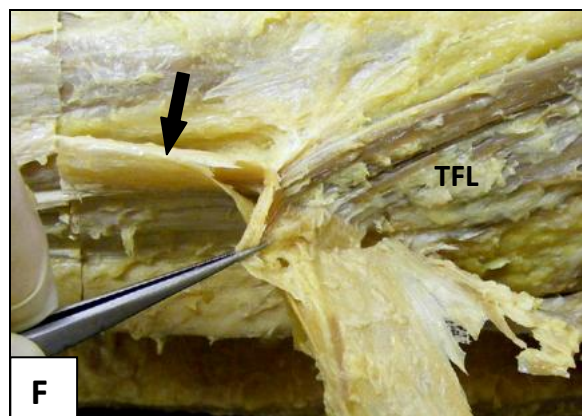
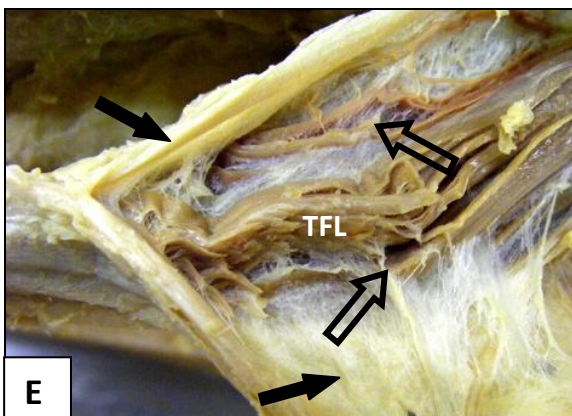
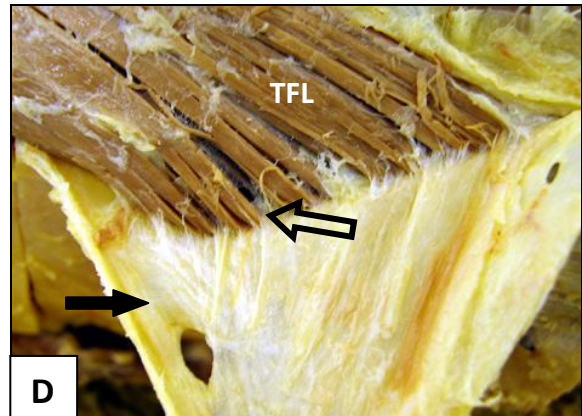
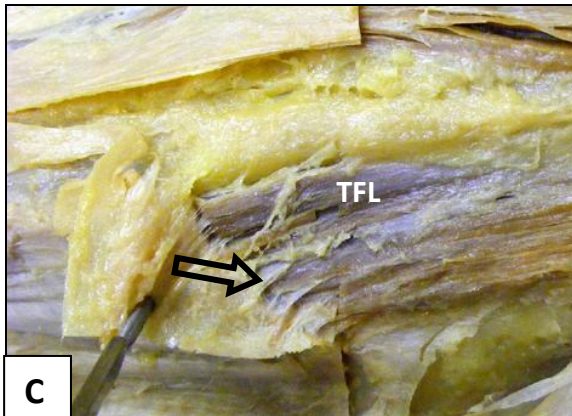
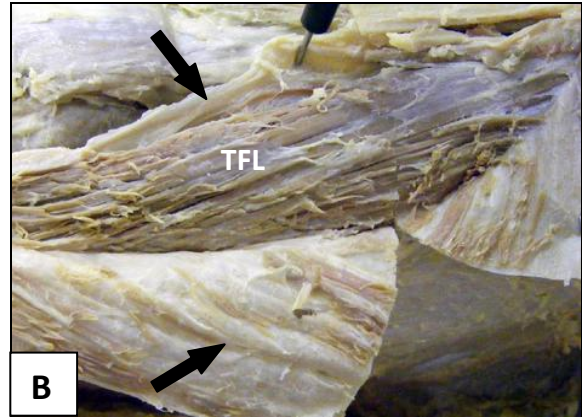

The fascia lata adhered closely to the tensor fasciae latae muscle by intramuscular septa passing from the deep surface of the fascia between muscle fascicles (open arrows, fig 4.3 C and D). A number of muscle fibres were also seen to originate from these septa. The deep surface of the muscle similarly related to the deep lamina of the fascia lata in a close relationship (fig 4.3 E). Distal to the tensor fasciae latae muscle the two fascial laminae unite again (solid arrow, fig 4.3 F) to continue as part of the thickened lateral surface of the fascia lata also described as the iliotibial tract.



**Figure 4.3** Reflecting the fascia lata from the tensor fasciae latae muscle

- A** The superficial lamina (arrow) of the fascia lata surrounding tensor fasciae latae
- B** The deep lamina of the fascia lata (pinned) surrounding the tensor fasciae latae (TFL) muscle
- C** Reflecting the fascia lata from the surface of the muscle pulls strongly into the muscle due to intramuscular septa (open arrow) passing between muscle fascicles
- D** Reflecting the fascia lata (black arrow) from the surface of the muscle pulls strongly into the muscle with potential tissue damage due to intramuscular septa (open arrow) passing between muscle fascicles
- E** When forcefully pulling on the fascia lata (black arrow) over the tensor fasciae latae muscle, it results in considerable disruption of muscle fascicles (open arrows)
- F** The superficial and deep laminae unite again into a single layer of fascia (black arrow) distal to the tensor fasciae latae (TFL) muscle







### **4.3.3 The sartorius muscle**

On reflecting the fascia lata medially, the fascia similarly divided into a superficial and deep lamina to ensheath the sartorius. Medial to the muscle the laminae became a single layer again continuing as the thin deep fascia covering the adductor muscles.

In the upper third of the sartorius muscle, the fascia lata adhered closely to the muscle (fig 4.4 A) by fascial septa passing between muscle fascicles from the deep surface of the fascia (open arrow, fig 4.4 B). The middle third of the muscle could be seen as a transition from the proximal close relationship to the loose relationship in the distal third (fig 4.4 C).

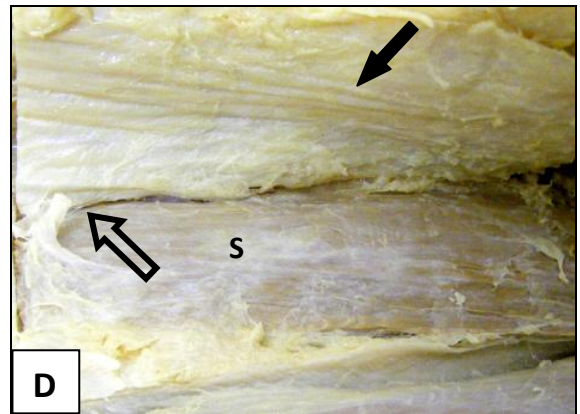
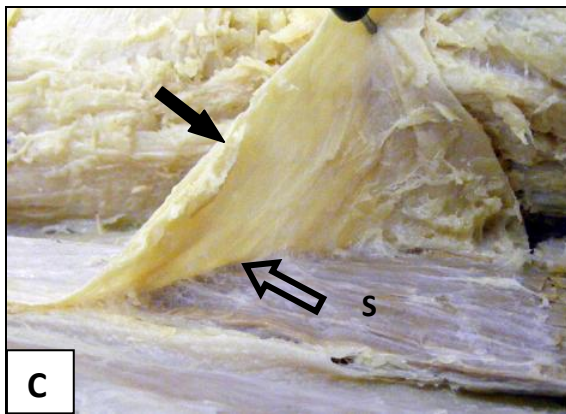
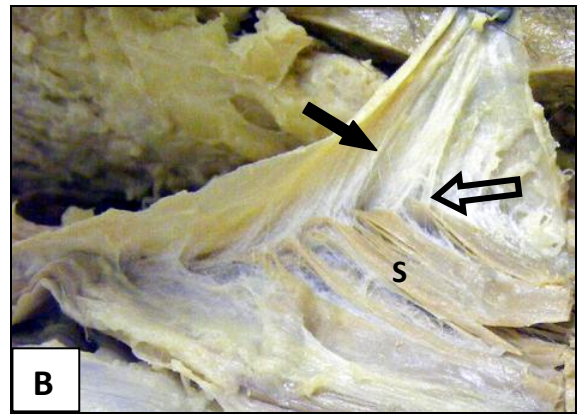
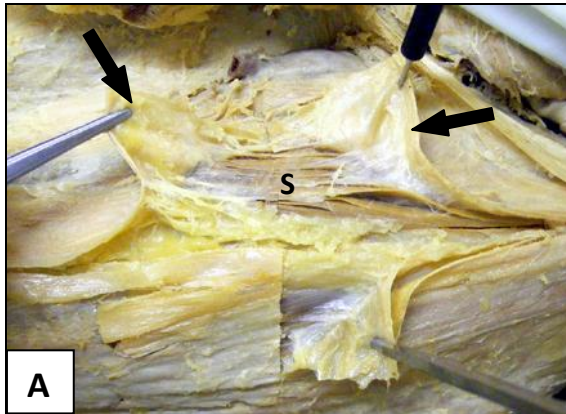
In the lower third of the muscle, the fascial sheath had a loose relationship with the sartorius muscle. Muscle and fascia were separated from each other by varying amounts of loose areolar tissue (open arrow, fig 4.4 D). In all the thighs dissected there were variations as to where the transition could be observed as complete. In all cases the transition was gradual either more proximal or more distal within the middle third.



**Figure 4.4** Reflecting the fascia lata from the sartorius muscle

- A** In the upper third of sartorius (S) the fascia lata (black arrows) is in a close relationship to the muscle
- B** Reflecting the fascia lata (black arrow) from the surface of the muscle pulls strongly into the muscle due to intramuscular septa passing between muscle fascicles (open arrow)
- C** At the level of the adductor canal the fascial relationship between fascia lata (black arrow) and the sartorius muscle (S) gradually changes from a close to a loose relationship (open arrow)
- D** In the distal third of the sartorius muscle the fascia lata is in a loose relationship (open arrow) to the muscle with loose connective tissue intervening between muscle (S) and fascia (black arrow)







#### **4.3.4 The rectus femoris muscle**

In the upper third of the fascia lata, an area where the fascia lata formed a double layer of fascia (black arrows, fig 4.5 A) to protect mainly anterior branches of the lateral cutaneous nerve of the thigh and cutaneous branches of the femoral nerve was consistently observed. This area of double fascia commonly corresponded to the upper third of the rectus femoris muscle.

Reflecting the fascia lata (black arrows) from the surface of the rectus femoris muscle could be done by blunt dissection with the fascia lifting off the entire muscle surface with ease (fig 4.5 B, D and E).

In all the dissected thighs the proximal “V” shaped area formed between the tensor fasciae latae and sartorius muscles (fig 4.5 C), a well defined adipose tissue layer (open arrow) was present between fascia and muscle epimysium. In the lower two thirds of the rectus femoris muscle, the space between fascia lata and muscle epimysium contained varying amounts of loose areolar tissue (fig 4.5 D and E) and considerably less adipose tissue right down to the quadriceps tendon.

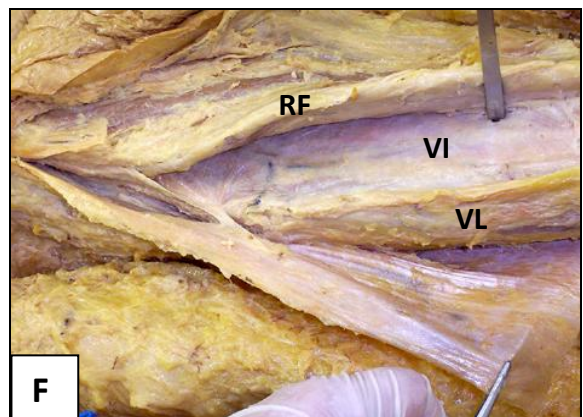
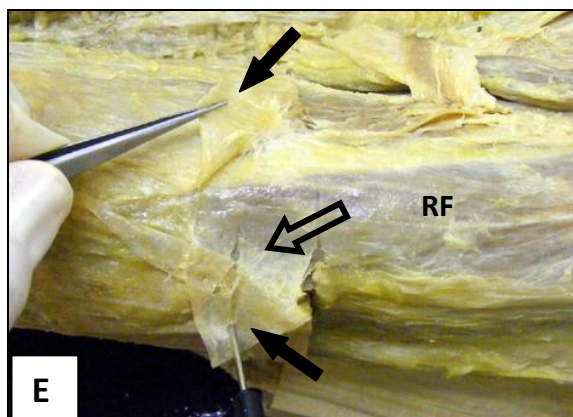
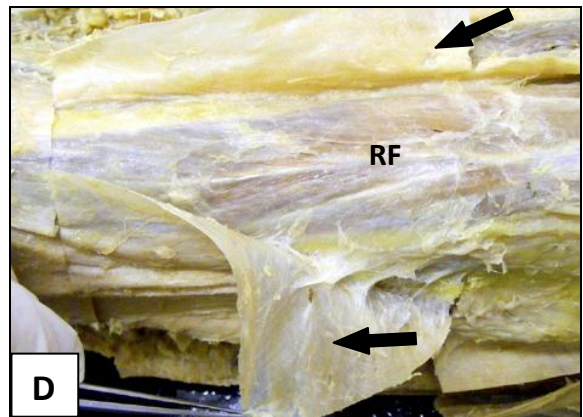
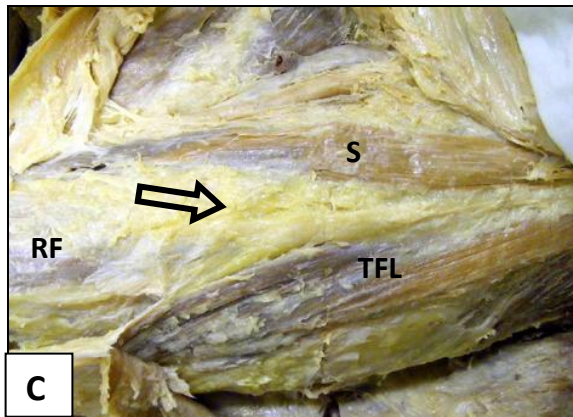
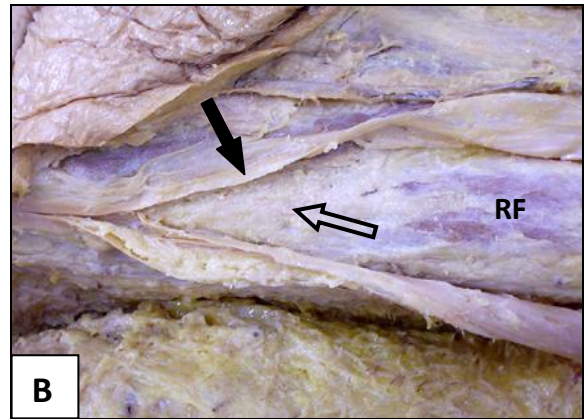
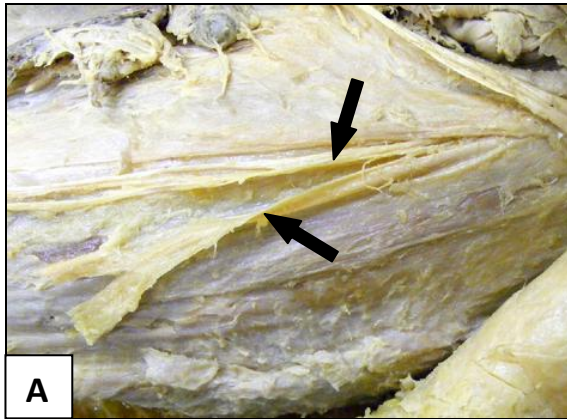
The rectus femoris muscle could easily be separated and lifted off the underlying vastus lateralis and vastus intermedius muscles by blunt dissection along its full length (fig 4.5 F). This was possible as the respective muscles each had their own epimysium with a layer of adipose and loose areolar tissue between them. The muscle stays free to slide under the fascia lata and over the vasti throughout its entire length from origin to insertion into the quadriceps tendon.



**Figure 4.5** Reflecting the fascia lata from the rectus femoris muscle

- A** The upper third of the fascia lata formed a double layer (black arrows) anterior to the rectus femoris muscle to protect anterior cutaneous branches of peripheral nerves
- B** The fascia lata (black arrow) is easily reflected from the rectus femoris (RF) muscle due to a well defined loose connective tissue layer between fascia and epimysium. Adipose tissue (open arrow) is collected in the upper third of the muscle between fascia and muscle
- C** The well defined adipose layer (open arrow) over the upper third of the rectus femoris (RF) muscle between sartorius (S) medially and tensor fasciae latae (TFL) laterally
- D** In the middle third, the fascia lata (black arrows) reflects off the rectus femoris muscle easily because of the loose relationship between fascia and muscle
- E** The fascia lata similarly reflects easily off the distal third of the rectus femoris because of the loose relationship (open arrow) between fascia and muscle
- F** The rectus femoris (RF) muscle could be separated from the underlying vastus intermedius (VI) and vastus lateralis (VL) muscles with ease







#### **4.3.5 The vastus lateralis muscle**

In all the dissections the fascia lata could easily be reflected off the underlying vastus lateralis muscle by blunt dissection from origin to insertion with a clear loose relationship between fascia and muscle epimysium throughout (fig 4.6). Varying amounts of loose areolar connective tissue and adipose tissue intervened between fascia and muscle. In cadaver specimens with more adipose tissue, the separating layer had the appearance of a distinct extra layer of fascia between fascia lata and the vastus lateralis muscle (open arrows, fig 4.6 A and F). The muscle therefore appeared free to slide under the fascia lata throughout its entire length - from origin to insertion.

The fascia lata covering the lateral aspect of the thigh (over vastus lateralis) appeared as a strong, well defined sheet of fascia. Further lateral, the fascial sheet thickened considerably to form the iliotibial band stretching from the fusion of the superficial and deep laminae of the tensor fasciae latae muscle to below the knee joint where it merged with the lateral crural fascia. Just above the knee, the deep surface of the fascia lata/ITB is firmly attached to the lateral femoral condyle (black arrow, fig 4.6 E).

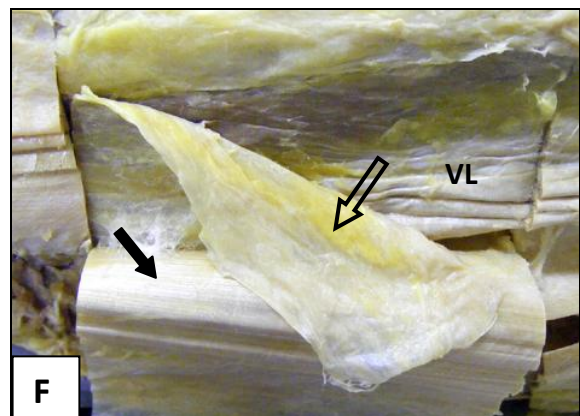
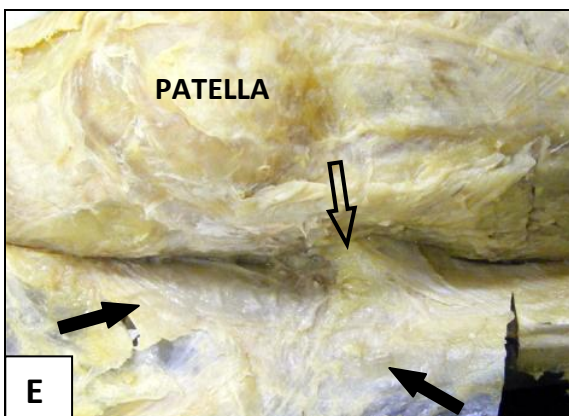
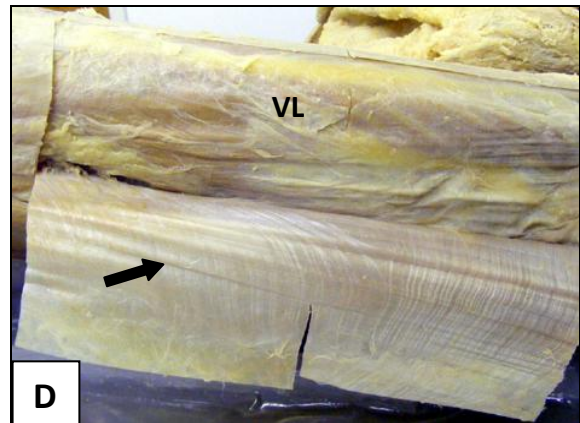
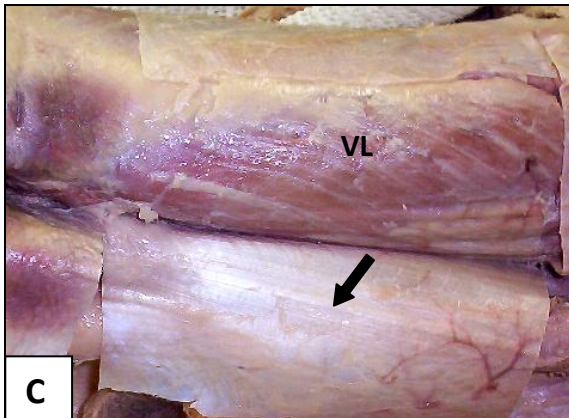
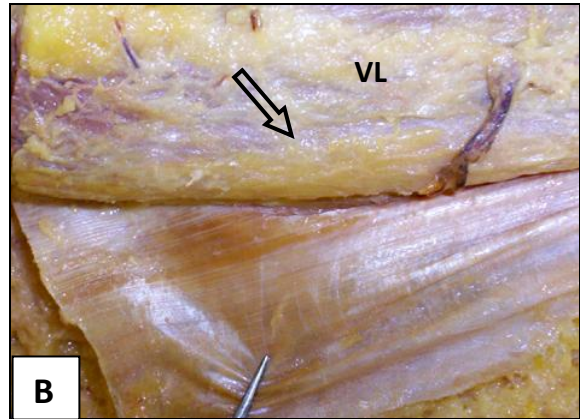
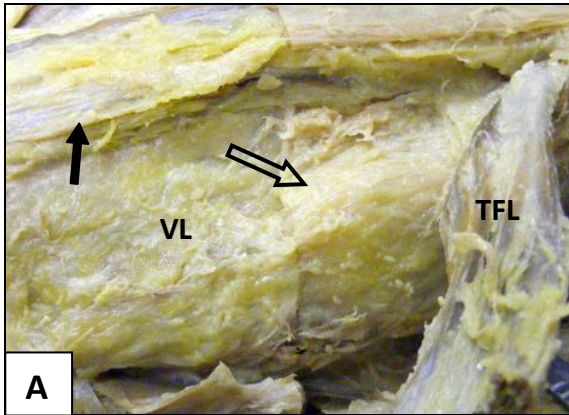
At the lateral edge of the vastus lateralis muscle, the prominent lateral intermuscular septum originates from the deep surface of the fascia lata/ITB attaching the fascia lata firmly to the femur along the lateral linea aspera. Where the vastus lateralis muscle had a clear loose relationship to the fascia lata, it has a close relationship to the lateral intermuscular septum throughout with fascial septa passing from the surface of the intermuscular septum between muscle fascicles (an epimysial relationship).



**Figure 4.6** Reflecting the fascia lata from the vastus lateralis muscle

- A** The upper vastus lateralis muscle (VL) under the tensor fasciae latae (TFL) muscle and fascia (black arrow) covered with a layer of fibroadipose tissue (open arrow)
- B** The fascia lata is easily separated from the surface of the vastus lateralis muscle. Varying amounts of loose connective and adipose tissue (open arrow) is visible in different specimens
- C** The fascia lata (black arrow) easily separated from the surface of the vastus lateralis muscle. Varying amounts of loose connective and adipose tissue is visible in different specimens
- D** The fascia lata (black arrow) easily separated from the surface of the vastus lateralis muscle. Varying amounts of loose connective and adipose tissue is visible in different specimens
- E** Right down to the level of the patella the fascia lata (black arrows) easily strips off the underlying muscle. The deep surface of the fascia lata is firmly attached to the lateral femoral condyle (open arrow)
- F** In more obese specimens the layer between fascia (black arrow) and vastus lateralis (VL) muscle resembles a separate fascia (open arrow) during careful reflection







#### 4.3.6 The vastus medialis muscle

Of all the extensor muscles of the thigh, the vastus medialis muscle showed the greatest deviation from textbook descriptions of its fascial relations. The fascia lata covering vastus medialis appeared thin and almost transparent in all cases (fig 4.7 A). Reflecting the fascia from the underlying muscle differed between all the specimens dissected. Apart from being a thin, delicate fascial sheet, varying degrees of close **and** loose relationships were observed in all the dissections.

Areas of loose relationship between fascia and muscle could be reflected with ease by blunt dissection. The extent and surface area of loose relationship varied considerably between the dissected specimens. In all the specimens, the area of loose relationship bordered on the rectus femoris muscle and became wider distally. The loose relationships however gradually changed to strong close relationships (open arrows, fig 4.7 C and D) where further attempts to reflect the fascia by purely pulling on the fascia as done for the vastus lateralis and rectus femoris muscles resulted in damage to underlying muscle tissue (open arrows, fig 4.7 E and F). Full reflection of the fascia could only be completed by sharp dissection to limit muscle fascicle damage. Well defined facial septa from the deep surface of the fascia lata passed between muscle fascicles in these areas (open arrow, fig 4.7 E).

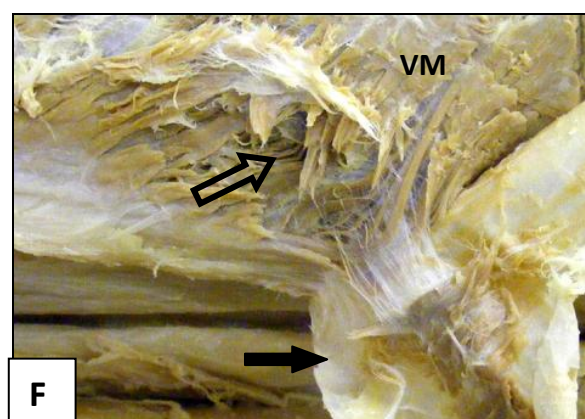
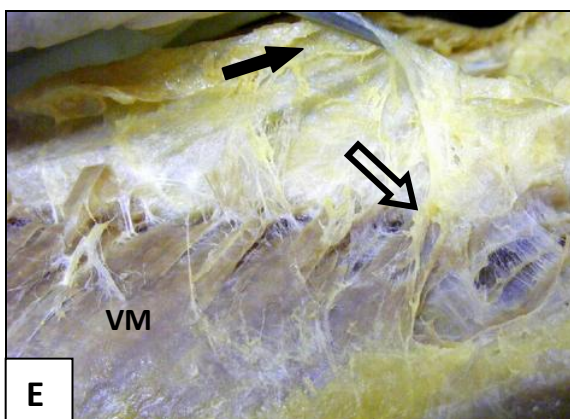
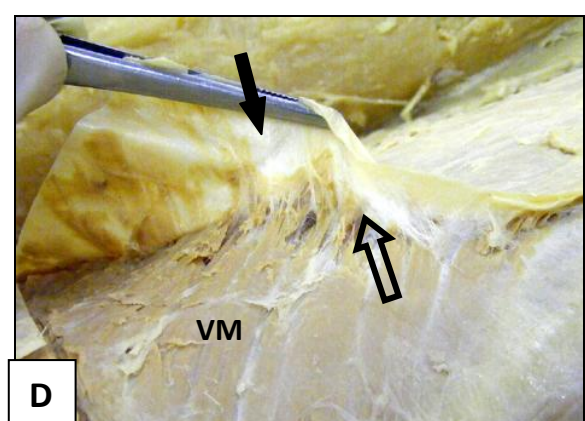
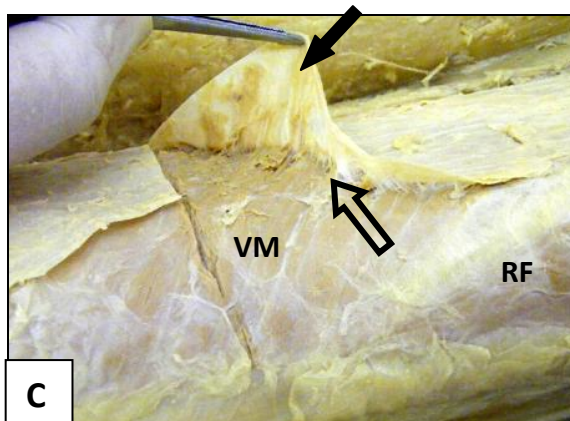

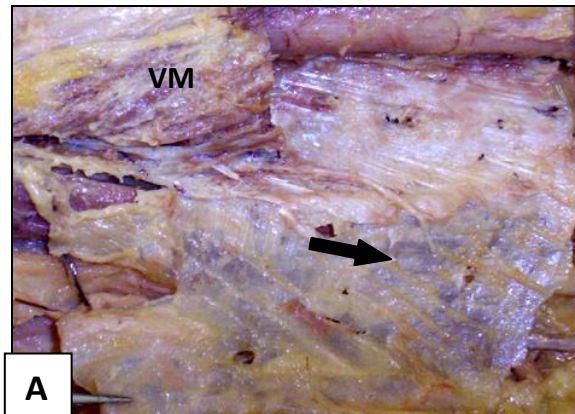
The different configurations of areas where loose and close relationships between the fascia lata and vastus medialis muscle were observed are reproduced in line drawings of the medial aspect of the thigh in figures 4.8 A, B, C and D.



**Figure 4.7** Reflecting the fascia lata from the vastus medialis muscle

- A** The medial fascia lata (black arrow) covering the vastus medialis muscle is thin and almost transparent
- B** An area of loose relationship where the loose fascia lata has been cut away (black arrow) over the vastus medialis (VM) muscle. (P, patella; RF, rectus femoris)
- C** The transition between a loose and close relationship (open arrow) between fascia lata and the vastus medialis (VM) muscle
- D** The close relationship between fascia lata (black arrow) and the vastus medialis (VM) muscle due to intramuscular septa passing between muscle fascicles (open arrow). These septa are less prominent than the septa in the tensor fasciae latae muscle
- E** The close relationship between fascia lata (black arrow) and the vastus medialis (VM) muscle due to intramuscular septa (open arrow) passing between muscle fascicles
- F** Damage (open arrow) created in the vastus medialis muscle by excessive pull on the fascia lata (black arrow)

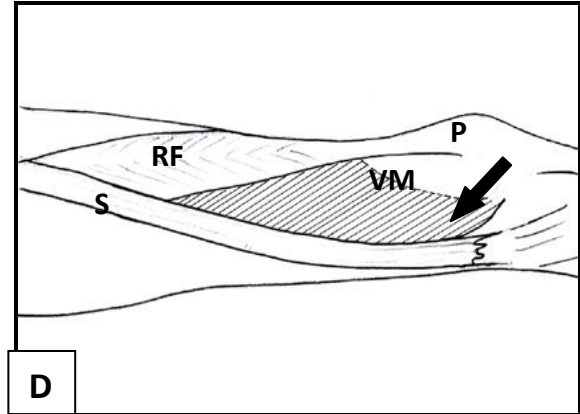
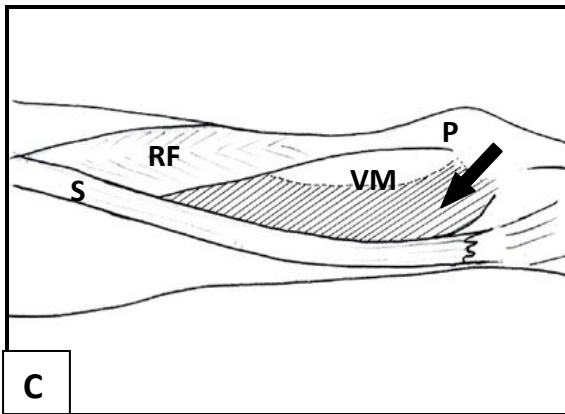
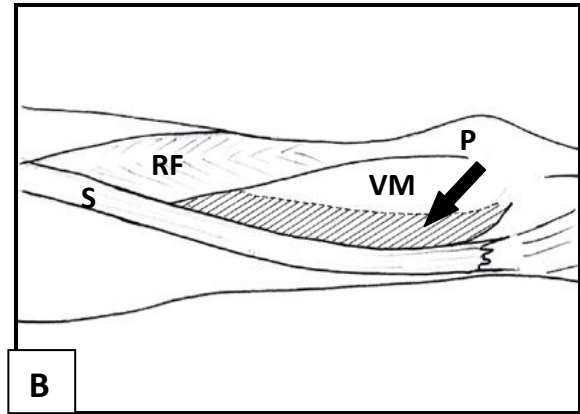
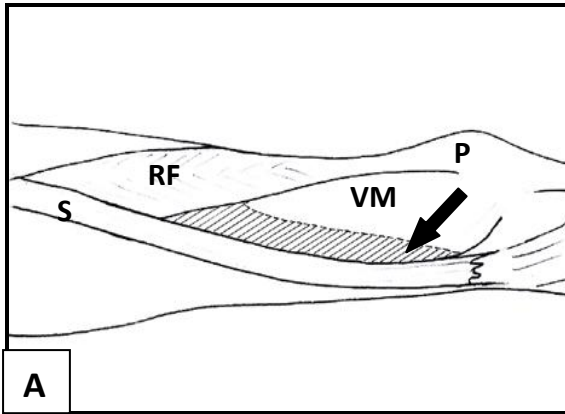






**Figure 4.8** Line drawings of the medial aspect of the thigh showing four different variations in fascial relationships between the fascia lata and the vastus medialis muscle as observed during careful reflection of the fascia. Areas of close epimysial relationship between fascia lata and underlying muscle are shown as the dark areas (black arrows) on the vastus medialis (VM) muscle. (P) patella, (RF) rectus femoris, (S) sartorius







#### **4.4 Summary of observations**

On the final removal of the layered superficial fascia (stratum membranosum and panniculus adiposus) from the fascia lata, the double layers formed by the fascia lata on itself in the upper middle third of the thigh were observed but not described in dissection texts. This double layer of fascia lata extended from the anterior superior iliac spine, medial to the tensor fasciae latae muscle origin, over the upper third of the anterior thigh, housing and protecting superficial peripheral nerves - most notably branches of the lateral cutaneous nerve of the thigh.

Reflecting and removal of the fascia lata was deliberately done carefully in sections and by pulling the fascia off the underlying muscles with minimal attempted “dissection” – either blunt or sharp. Two basic means of fascial separation were encountered:

- A loose relationship where the fascia lata could easily be reflected from the underlying muscle leaving the muscle epimysium intact.
- A close relationship where lifting the fascia lata off underlying muscles resulted in pulling into and damaging underlying muscle fascicles. Where this relationship was encountered, it was reasoned that the deep fascia/fascia lata relationship would constitute the muscle’s epimysium. In these areas, fascial septa were encountered passing from the deep surface of the fascia lata between muscle fascicles of the adjacent muscles.

Reflection and removal of the entire fascia lata from underlying muscles by blunt dissection was not possible. Areas of both easy (loose relationship) and damaging (close relationship) reflection of fascia were encountered. The most obvious areas where fascia



could not be reflected from underlying muscle without damage were: the gluteus fascia over the gluteus maximus muscle, the fascia/aponeurosis over the gluteus medius muscle and the fascia of the tensor fasciae latae muscle. The difficulty in removing the fascia from the tensor fasciae latae and gluteus maximus muscles were in keeping with descriptions by Hollinshead (1969) and Jones as having relinquished its bony attachments for wider fascial attachments (Jones, 1944). For most of the rest of the anterior thigh, reflecting the fascia lata from underlying muscles could be done with ease. There were two consistent exceptions: a close epimysial relationship found in the upper third of the sartorius muscle, and large sections of the vastus medialis muscle also having a close epimysial relationship to the fascia lata.

Reflecting fascia from the rectus femoris and vastus lateralis muscles could be done with ease. The fascia lata was separated from underlying muscle epimysium by a layer of loose connective tissue from origin to insertion for both muscles. In more adipose cadaver specimens, this intervening layer contained abundant amounts of adipose tissue giving it the appearance of a distinctly separate layer of fibrofatty connective tissue in some dissections. The loose relationship created by this layer facilitates the free sliding between the fascia lata and deeper muscular planes.

The ease with which the fascia could be reflected from the upper third of the rectus femoris muscle needs comment. A well defined area of abundant adipose tissue covering the anterior surface between the fascia lata and upper third of the rectus femoris muscle was found in all the dissected thighs on our study. In keeping with the features of membranous layers in the superficial fascia, this “functional bursa” between fascia and muscle may be an important contributor towards further reducing friction and resistance in the anterior thigh allowing economical and full hip extension during walking and running. In the distal



two thirds of the surface of the rectus femoris muscle, the sliding plane between fascia and muscle epimysium was maintained but less prominent.

For complete removal of the fascia lata, areas of difficulty in reflecting fascia from underlying muscle without damage were encountered. Two areas of close epimysial relationship were observed consistently. Both the sartorius and vastus medialis muscles had close relationships to the fascia lata. They both, however, had a mix of close as well as loose relationships to the fascia lata.

In the sartorius muscle, the area of close epimysial relationship was consistently present in the upper third of the muscle where it forms the lateral boundary of the femoral triangle. The extent of the close relationship varied between dissected thighs. Variations were always in the middle third of the muscle where the transition from a close to a loose relationship could be observed. Transitions were either more proximal or more distal from the point where sartorius was positioned next to (medial to) the vastus medialis muscle. From here, as the roof of the adductor (subsartorial, Hunter's) canal to its distal insertion as part of the anserine complex, it had a loose relationship with the fascia lata.

Over the vastus medialis muscle, a mixed fascial relationship was consistently found – areas of loose, as well as areas of close relationships. This muscle also showed the biggest variation in the surface areas where a close epimysial relationship between fascia and muscle could be observed. This close relationship was always in an area of varying width bordering onto the lateral edge of the sartorius muscle. The areas of loose relationship between fascia and muscle bordering on the rectus femoris muscle could be reflected with ease by blunt dissection. This loose relationship however gradually changed to a strong



close relationships where fascia and muscle could only be separated by careful sharp dissection.

The main observations of relationships between fascia lata and its underlying muscles of the anterior compartment of the thigh is summarised in table 4.1, and in a line drawing (fig 4.9). The yellow area represents where the well-defined adipose layer covering rectus femoris was observed. The green represent where areas of close relationships between the fascia lata and the underlying tensor fasciae latae, sartorius and vastus medialis muscles were encountered.



**Table 4.1** Summary of the individual muscles dissected and their dominant relationships to the fascia lata

Legs dissected (6):	1	2	3	4	5	6
Tensor fasciae latae	CR –100%	CR –100%	CR –100%	CR –100%	CR –100%	CR – 100%
Upper sartorius	CR –100%	CR –100%	CR –100%	CR - 100%	CR –100%	CR – 100%
Middle sartorius	CR/LR 40/60%	CR/LR 30/70%	CR/LR 50/50%	CR/LR 40/60%	CR/LR 20/80%	CR/LR 30/70%
Lower sartorius	LR –100%	LR– 100%	LR– 100%	LR– 100%	LR– 100%	LR– 100%
Rectus femoris	LR– 100%	LR– 100%	LR– 100%	LR– 100%	LR– 100%	LR– 100%
Vastus lateralis	LR– 100%	LR– 100%	LR– 100%	LR– 100%	LR– 100%	LR– 100%
Vastus medialis	CR/LR 30/70%	CR/LR 50/50%	CR/LR 80/20%	CR/LR 70/30%	CR/LR 70/30%	CR/LR 80/20%

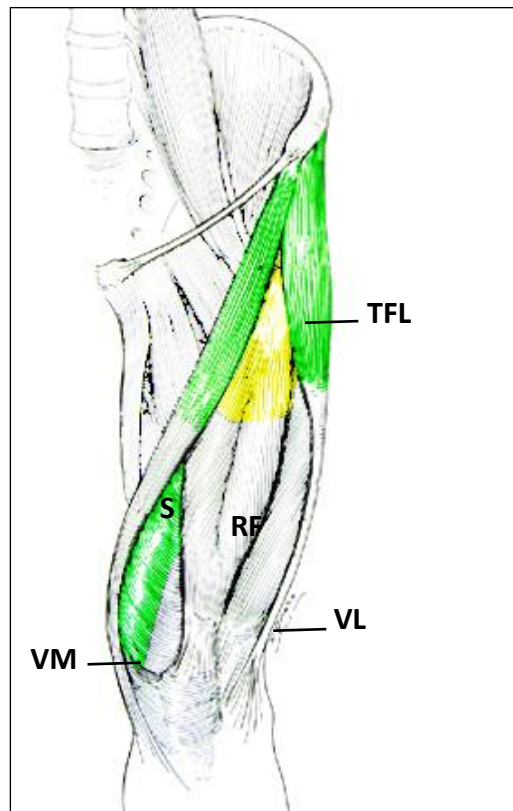
CR close relationship between fascia and muscle

LR loose relationship between fascia and muscle

CR/LR mixed close and loose relationship between fascia and muscle



**Figure 4.9** A schematic presentation of the main findings of the detailed dissection of the fascia lata. (TFL, tensor fasciae latae; S, sartorius; RF, rectus femoris; VL, vastus lateralis; VM, vastus medialis)





## 4.5 Discussion

The principle aim of using detailed dissections was to investigate the gross morphology of the fascia lata in its relationships to underlying extensor muscles of the thigh. This was in order to provide more complete anatomical data, using a descriptive non-experimental design with no manipulation of independent variables. A further aim was to determine whether areas of close fascia/muscle relationships not previously described were present within the extensor compartment of the thigh. Overall, results of this study showed that the relationships between the fascia lata and its underlying muscles are more complex than currently described in anatomical textbooks and scientific papers.

The relationships between the deep fascia and underlying structures differ in different parts of the body. This varies between close epimysial relationships as seen in muscles of the trunk and neck, and the generally accepted loose relationship as seen between fascia and muscle in the limbs (Tobias and Arnold, 1977). Where a close relationship prevails, fascia and muscle can only be separated by sharp dissection in order to limit muscle damage as the deep fascia (epimysium) sends septa (perimysium) between muscle fascicles. In areas of a loose relationship (often found in the limbs), the fascia is a membrane easily separable from underlying muscles by blunt dissection. Areas of close epimysial and aponeurotic relationships between the gluteus maximus, gluteus medius and tensor fasciae latae muscles and their respective covering deep fascia were routinely observed during dissections. Additional areas of close (epimysial) relationships between fascia and muscle were, however, also encountered during careful removal of the fascia lata from other underlying muscles of the thigh as well.



The fascia lata is a very consistent and well-defined aponeurotic-type collagenous sheath or membrane covering the muscles of the thigh (Tobias and Arnold, 1977; Standring., 2008). It is further described as easily separable from the underlying muscles (Tobias and Arnold, 1977) because of the presence of the muscle epimysium and a layer of loose connective tissue between the fascia and muscles (Stecco et al., 2009b). The loose connective tissue layer between the fascia lata and underlying muscle epimysium is rich in adipose cells in some regions, further facilitating the sliding between fascial and muscular planes.

Students in anatomy are led through the dissection of the body in a layered fashion from dermis to deep structures in a sequential way (Tobias and Arnold, 1977; Romanes, 1986; Kieser and Allan, 2001). In the case of the thigh, the following order is commonly adhered to:

- Cut through the skin from A to B. Over bony areas, to the bone and in more adipose areas through the superficial fascia, taking care not to cut into the muscle.
- Reflect and remove the skin flaps and layer of superficial fascia.
- Observe the structures of the superficial fascia by teasing out the fat to display the diffuse network of blood vessels and nerves.
- Complete the removal of the fatty tissue by stripping the superficial fascia by blunt dissection, displaying the deep fascial envelope.
- After a vertical incision of the fascia lata from iliac tubercle to patella, remove or strip the deep fascia to expose the underlying muscles.



This dissection sequence does not differ much from early dissection texts (Cunningham, 1896) and does not specify “how”: just “remove or strip”. In most cases, dissection of the inguinal region to identify the groups of lymph nodes, the saphenous vein in the superficial fascia, the saphenous opening and cribriform fascia parts of the fascia lata is described in detail. In order to concentrate on fascial relationships, detailed dissections in this study were therefore performed without the aid or reference to standard dissection manuals. Observations were recorded as digital images as they were encountered.

Although this study was primarily undertaken to observe and document deep fascia and muscle relationships, observations made during the removal of the superficial fascia need inclusion in this discussion. Like descriptions of deep fascial relationships, documentation and descriptions of the presence of membranous layers within the superficial fascia is lacking – especially in the limbs (Abu-Hijleh et al., 2006). In every dissected thigh in our study, well defined and clear membranous layers (*stratum membranosum*) were found in the superficial fascia. In the upper lateral third of the thigh, these layers were particularly well defined and easily identified. Inattentive novice dissectors may even think that they have reached the fascia lata, only to find another layer of superficial fascia adipose tissue (*panniculus adiposus*) underneath! From a functional perspective, adipose and loose connective tissue between fascial or non-elastic tissue layers serve as a means of reducing friction, shearing and resistance between structures during movement (Stecco et al., 2009b). The layered arrangement of the superficial fascia may be interpreted as another method of reducing resistance to hip extension while protecting peripheral structures from shear. Clinically, resistance-free hip extension preserves normal stride length during walking and running while protecting the lumbar spine from having to compensate by increasing the lumbar lordosis, thereby putting strain on the lumbosacral junction.



## **4.6 Conclusion**

The quadriceps muscles, fascia lata together with the tensor fasciae latae and sartorius muscles form a well integrated unit in the lower limb as a whole with distinct fascia/muscle relationships. Instead of the fascia lata being a uniform and autonomous structure in a loose relationship with respect to the underlying muscles as implicated in dissection texts (Tobias and Arnold, 1977), and described in literature (Stecco et al, 2009b), areas of mixed close and loose relationships were found unexpectedly, which have not previously been documented.



## **5 CORRELATION BETWEEN DISSECTION, MAGNETIC RESONANCE IMAGING AND ULTRASONOGRAPHY OF THE FASCIA LATA**

*“I wanted to know about the clouds and the grasses, why the leaves change colour in the autumn. I pestered people with questions about what nobody knew or cared anything about”* John Hunter, 1728-1793 (Moore, 2005).

### **5.1 Introduction**

Learning directly from dissected material has long been an established tool for students in the health sciences. Basic anatomy knowledge is progressively enhanced by more detailed studies of specific structures that may be encountered in a field of speciality.

Understanding of normal anatomy therefore becomes crucial to enable accurate examination and treatment planning. The incorporation of additional modalities for investigation of anatomical structures to enhance understanding is proving invaluable. To this end, Magnetic Resonance Imaging is a leading modality for investigating musculoskeletal structures while the advent of dynamic, high-frequency real-time ultrasound offers an alternative or complementary imaging tool to Magnetic Resonance Imaging (Girish et al, 2007).

Despite the progressive accumulation of knowledge, several structures are however still not fully described in the literature. Consequently this may lead to gaps in clinical reasoning when confronted with complex pathology or dysfunction. Over the past decade correlation studies between two or more different modalities (dissection, Magnetic Resonance Imaging and Ultrasonography) have shown promise in gaining better



understanding of functional and anatomic relationships. Examples include the patellar retinaculum (Starok et al, 1997), the iliotibial band (Muhle et al, 1999), the hamstring muscle complex (Koulouris and Connell, 2005), the membranous layers within the superficial fascia (Abu-Hijleh et al, 2006), the iliotibial band attachment to the femur (Fairclough et al, 2006) and the posterolateral corner of the knee (Barker et al, 2009).

The fascia lata of the thigh is a well known and accepted anatomical structure. It is well described in most textbooks of anatomy. Despite its wide acceptance as a structure, there is a paucity of information about its relationships to underlying muscles of the thigh. In the radiological literature, there is even less information available about the fascia lata and underlying muscles where investigations of disorders take precedence (Girish et al, 2007).

With rising interest in the larger role that fascial structures may be playing in musculoskeletal dynamics, detailed anatomical dissections of the thigh and fascia lata (chapter 4) were augmented by correlating dissection appearances (axial cuts), Magnetic Resonance Imaging and Ultrasonography images at selected levels of the thigh.

## **5.2 Detailed cross section studies procedures**

For the dissection study, four right thighs from preserved cadaver bodies (two male and two female) between the ages of 78 and 85 years were studied. Cross-cut (axial) dissections at four predetermined levels were used for this study.

The cross-section levels were:

- I.** Halfway between iliac crest and greater trochanter.
- II.** 6 to 8 cm below the greater trochanter.



**III.** Halfway between levels **II** and 5 cm above the upper border of the patella (level **IV**).

**IV.** 5 cm above the upper border of the patella.

Only the anterior compartment between the lateral and medial intermuscular septa was used for observing fascial relationships to underlying muscles and correlation with Magnetic Resonance Imaging and Ultrasonography.

- Cross-cut slices were made with a dissection scalpel and at 1.5cm thickness;
- For uniformity of documentation only the superior surface of the cross-cuts were considered;
- Cross-cut dissections were photographed in normal views and in Macro Zoom mode from a 1cm distance with the camera mounted. Several images at different distances from the specimens were taken to get the clearest view of the cut sections.

Observations were photographed with a Fujifilm FinePix S5800 S800 digital camera as described under 4.3. For better comparison with other investigation images, selected images from each dissected level were grouped together and digitally stitched to form a panoramic view of the cross-cut dissection. Stitching was done using Canon Utilities PhotoStitch version 3.1.

#### **5.2.1 Magnetic Resonance Imaging studies of normal human thighs**

Magnetic Resonance Imaging images were obtained from four healthy living volunteers of both genders (two male and two female). They were selected from two specific age groups: between 20 and 30 years (one male, one female) and between 50 and 60 years (one



male, one female). None of the volunteers had previous injury, surgery, any pre-existing or present knee or leg pathology that may influence the anatomical relationships in their thighs.

Sequences were obtained using a Philips Achieva 1.5 Tesla MRI machine, Royal Philips Electronics, The Netherlands. Coronal T1 weighted turbo spin echo sequences were done at the same levels used for the cross-cut dissection slices (levels **I** to **IV**). Five slices were done at each level with a slice thickness of 5 mm.

### **5.2.2 Ultrasonography studies of normal human thighs**

Ultrasonography images were obtained from the right legs of the same four healthy volunteers used in the Magnetic Resonance Imaging studies. Volunteers were positioned comfortably in supine lying with the thigh muscles fully relaxed.

Images were obtained using a high detail diagnostic Toshiba Xario XG ultrasound machine Toshiba Medical Systems Corporation. A 10.2 MHz linear array sound head was used with the musculoskeletal setup selected. Ultrasonography images were done at the same four levels (**I** to **IV**) as where the dissection cross-cuts and the Magnetic Resonance Imaging sequences were taken. Six images were obtained at each level, three transverse and three longitudinal images per level – lateral, median and medial for each level except for level **I** where medial images were not possible. Images were catalogued, scanned and filed.



## 5.3 Results

Observations and images from cross-cut dissections, Magnetic Resonance Imaging and Ultrasonography from each of the four selected levels (Levels **I**, **II**, **III** and **IV**) were grouped and similarities in morphological features noted. From the 1330 dissection images, 80 Magnetic Resonance Imaging images and 92 Ultrasonography images, appropriate images per level (Level **I** 20; Level **II** 21; Level **III** 23; Level **IV** 20) were selected to represent the observations and findings.

### 5.3.1 Legends

Shapes used on images to identify described structures.



- Arrowheads: - membranous layers within the superficial fascia.



- Solid arrows: - deep fascia of the thigh, the fascia lata.



- Open arrows: - adipose or loose areolar connective tissue layers between fasciae and between fascia and muscle.



- Star

- Alphabets to represent separate muscles: - e.g. S – sartorius, TFL – tensor fasciae latae, RF – rectus femoris, VL – vastus lateralis, VM – vastus medialis



## **5.4 Level I - Halfway between the iliac crest and greater trochanter**

The dissection cut at level **I** included the superficial fascia, the fascia lata, the tensor fasciae latae, rectus femoris and sartorius muscles.

### **5.4.1 The superficial fascia and fascia lata**

#### **Superficial fascia**

In all images of the superficial fascia at this level, membranous layers were seen (arrowheads on images). Closer to the deep fascia, these layers were well defined and sometimes continuous with the fascia lata, showing the same consistency as the deep fascia. The membranous layers in the upper anterolateral thigh protected peripheral nerves and vessels between fascial layers. Layers were separated by adipose and loose areolar tissue (fig 5.1 A). The membranous layers were also clearly visible in the Magnetic Resonance Imaging (fig 5.1 C) and Ultrasound (fig 5.1 D and E) images.

#### **Fascia lata**

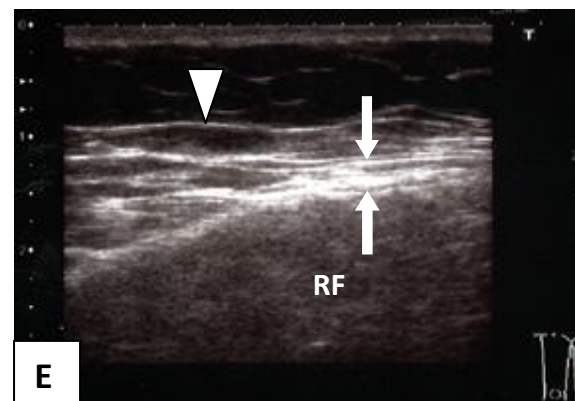
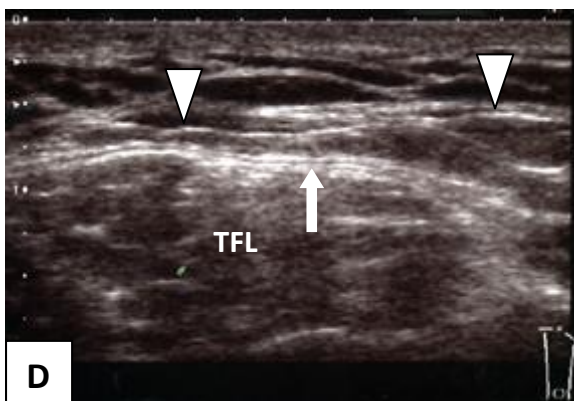
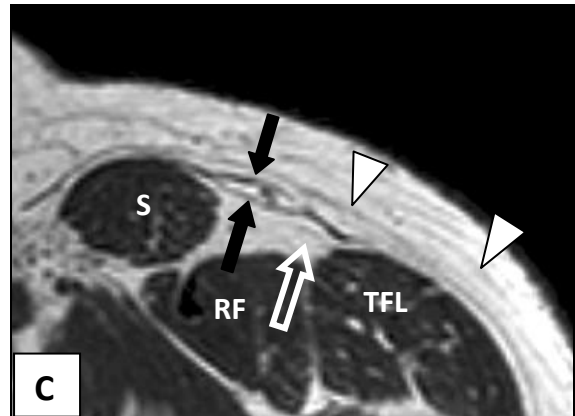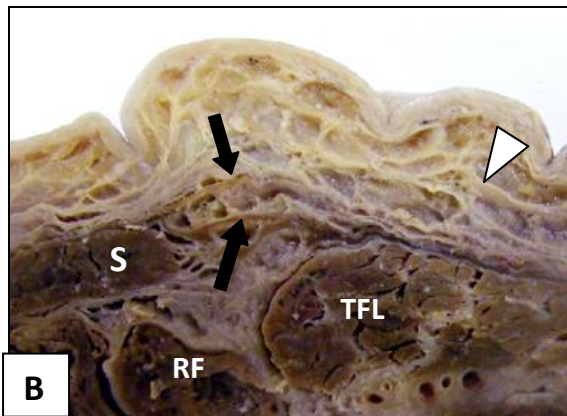
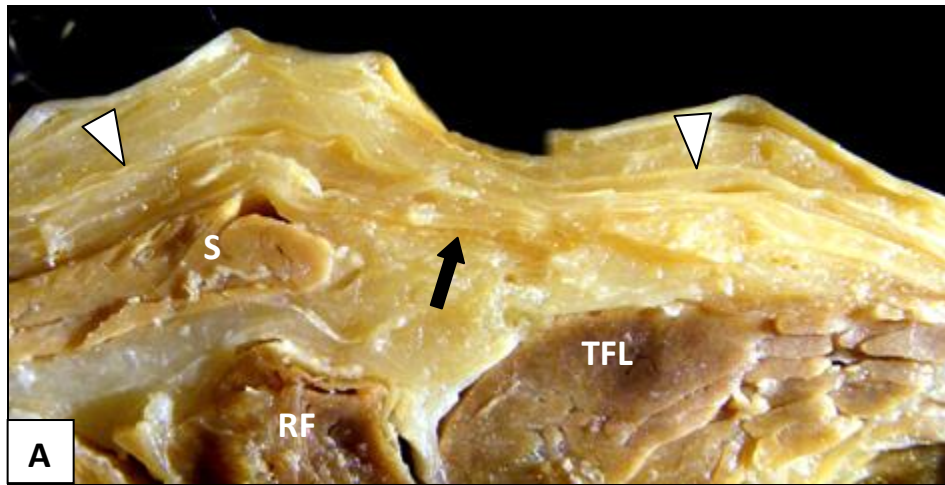
The fascia lata was well defined in all dissections (solid arrows, fig 5.1 A and B). On the Magnetic Resonance image the fascia lata was only recognisable as a separate structure where adipose tissue was present between fascial layers or between fascia and muscle (open arrow, fig 5.1C). The fascia lata was also recognisable as a separate structure on Ultrasound images (solid arrows, fig 5.1 D and E). In all dissection views, the fascia lata anteriorly formed a distinct double layer of fascia housing peripheral nerves and vessels (fig 5.1 B between solid arrows) overlaying the rectus femoris muscle. The double feature of the fascia lata was also observed in Magnetic Resonance Imaging and Ultrasound images (fig 5.1 C and E between solid arrows).



**Figure 5.1** Features of the superficial fascia with its membranous layers and the fascia lata at cross cut Level I

- A** Axial dissection cut showing two membranous layers (arrowheads), the fascia lata (solid arrow) and the sartorius (S), rectus femoris (RF) and tensor fasciae latae (TFL) muscles are clearly visible
- B** The double layer of fascia lata (between arrows) between the sartorius (S) and tensor fasciae latae (TFL) muscles anterior to the rectus femoris muscle (RF)
- C** Magnetic Resonance image showing membranous layers within the superficial fascia (arrowheads), the double layer of the anterior fascia lata (between solid arrows) and the adipose layer between fascia lata and the rectus femoris muscle (open arrow)
- D** A transverse Ultrasound image showing membranous layers (arrowheads) and fascia lata (solid arrow) over the tensor fasciae latae muscle (TFL)
- E** A transverse Ultrasound image of the anterior fascia lata showing a double layer of deep fascia between solid arrows







#### **5.4.2 Tensor fasciae latae muscle**

The close relationship between fascia lata and the tensor fascia lata muscle observed with Magnetic Resonance Imaging and Ultrasonography correlated well with observations during detailed dissections. In the cross-cut view the entire surface of the tensor fasciae latae muscle could be seen as in close relationship with the fascia lata (fig 5.2 A, B). On both the Magnetic Resonance (figure 5.2 C) and Ultrasound (fig 5.2 D) images the fascia lata could not be distinguished as separate from the muscle, and therefore interpreted as being in a close relationship to the muscle.

The fascia lata splitting into a superficial and deep lamina around tensor fasciae latae was not clearly demonstrated on any of the dissections, Magnetic Resonance or Ultrasound images macroscopically.

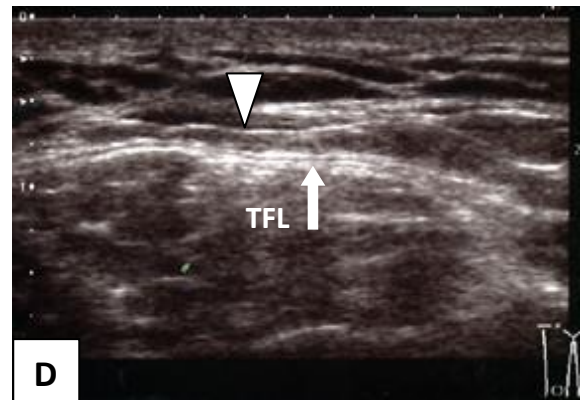
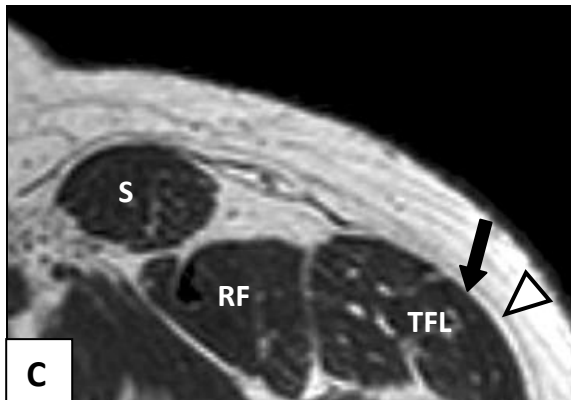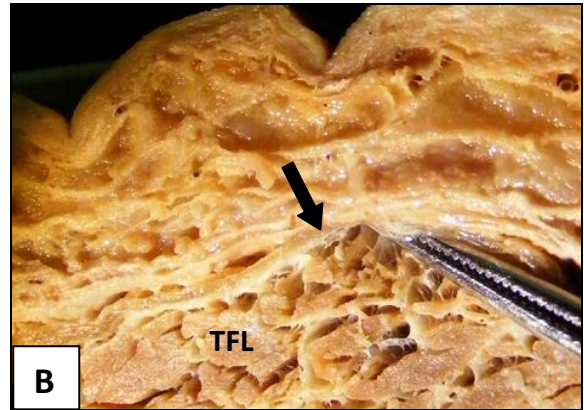
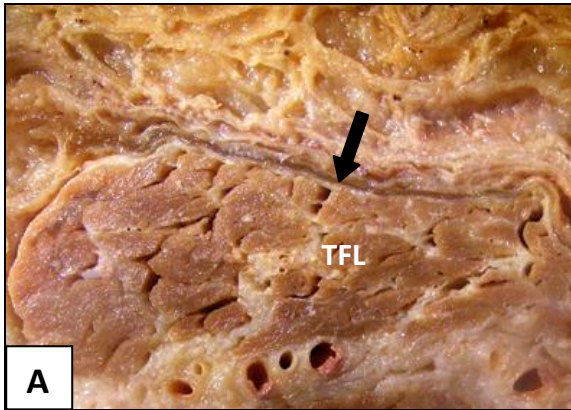
Attempted pulling of the fascia lata away from the muscle (fig 5.2 B) resulted in distortion and damage to the underlying muscle due to fascial septa passing from the deep surface of the fascia lata between the muscle fascicles of the tensor fasciae latae. Due to intermuscular septa from the deep surface of the fascia lata, fascia and muscle could only be separated by sharp dissection or forced removal resulting in muscle distortion and damage.



**Figure 5.2** Features of the tensor fasciae latae muscle relating to the fascia lata observed at cross cut Level I

- A** The fascia lata (solid arrow) closely relates to the underlying tensor fasciae latae muscle (TFL)
- B** Attempting to pull the fascia lata (solid arrow) away from the tensor fascia lata muscle (TFL)
- C** An axial Magnetic Resonance image showing a membranous layer in the superficial fascia (arrowhead), but the fascia lata (solid arrow) cannot be distinguished from the tensor fasciae latae muscle (TFL)
- D** Transverse Ultrasound image with a membranous layer (arrowhead) and fascia lata (solid arrow) visible over the tensor fasciae latae muscle (TFL)







### **5.4.3 Rectus femoris muscle**

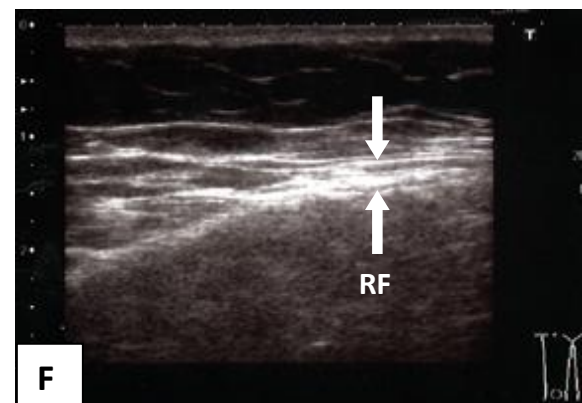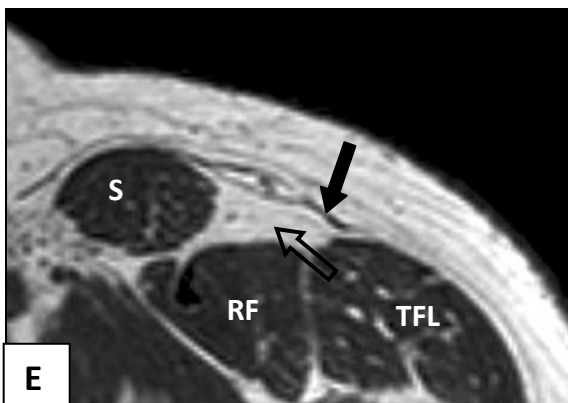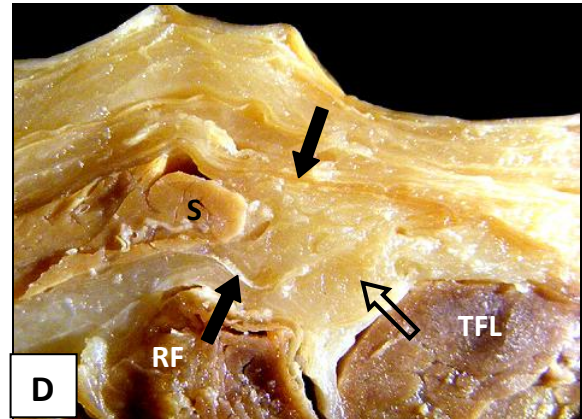
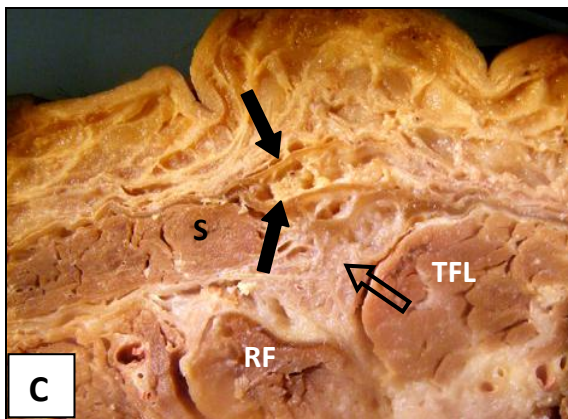

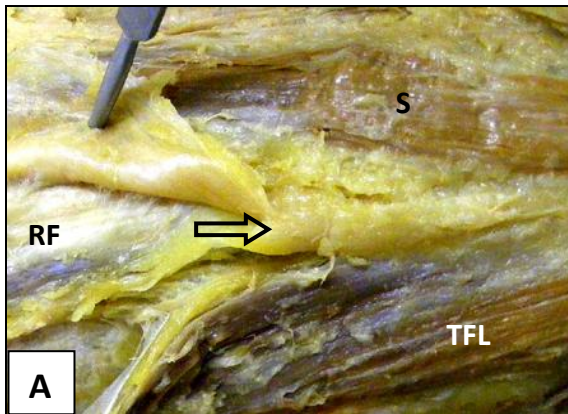
The well defined adipose layer observed in the detailed dissections covering the rectus femoris muscle was clearly visible between fascia lata and the rectus femoris muscle epimysium in all the cross-cut dissection (fig 5.1 A, D; fig 5.3 A, C and D), Magnetic Resonance Imaging (fig 5.1 B), and to a lesser degree, in the Ultrasonography images of Level I.



**Figure 5.3** Features of the relationship observed between the fascia lata and the upper rectus femoris muscle at cross cut Level I

- A** Removal of the fascia lata at this level exposed a well-defined layer of adipose tissue (open arrow) between fascia and the upper rectus femoris muscle (RF) in the “V” formed by the sartorius (S) and tensor fasciae latae (TFL) muscles
- B** Upon removal of the adipose tissue, the deep lamina of the fascia lata (solid arrow) surrounding the sartorius muscle (S) becomes clearly visible
- C** The well defined adipose layer (open arrow) between a doubled fascia lata (solid arrows) and the upper rectus femoris muscle (RF)
- D** The superficial and deep laminae (solid arrows) of the fascia lata surrounding the sartorius muscle (S) forms part of the adipose layer (open arrow) over the rectus femoris muscle (RF)
- E** An axial Magnetic Resonance image showing the well defined adipose layer (open arrow) between fascia lata (solid arrow) and the rectus femoris muscle (RF)
- F** A transverse Ultrasound image of the anterior fascia lata over the rectus femoris muscle (RF) showing a double layer of deep fascia between the solid arrows







#### **5.4.4 Sartorius muscle**

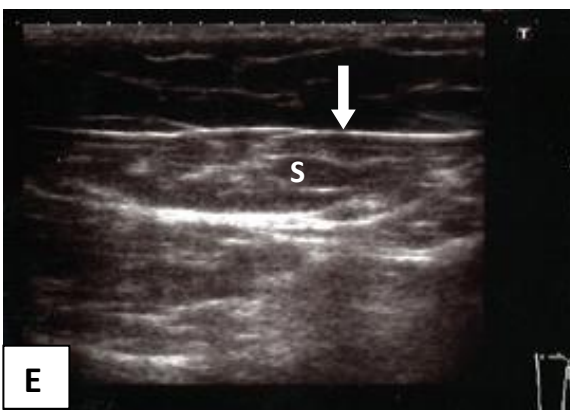
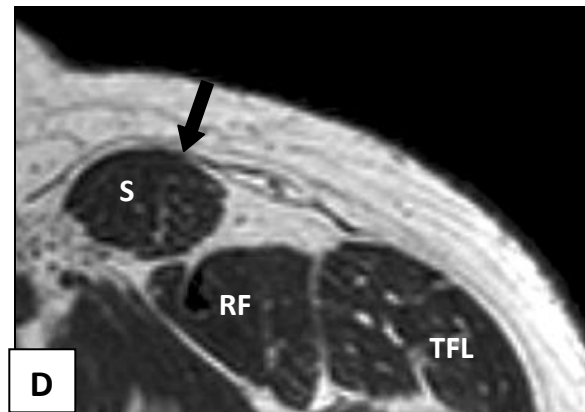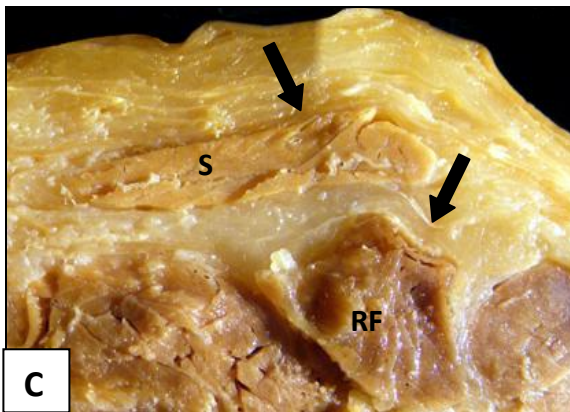
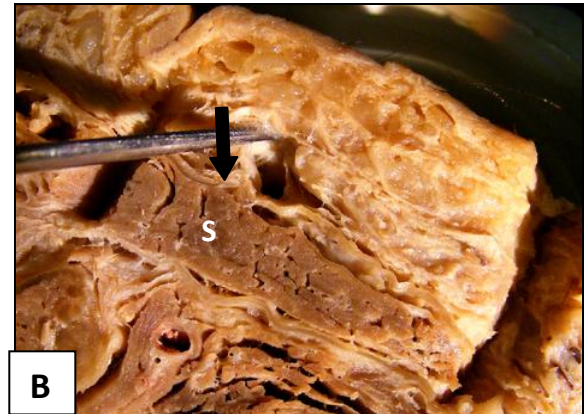
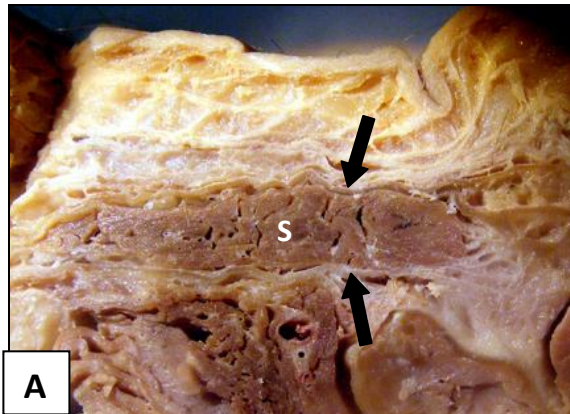
The fascia lata splits into a superficial and deep lamina closely relating to both the superficial and deep surfaces of the sartorius muscle. At this level the close relationship between fascia lata and the upper third of sartorius was visible (fig 5.4 A and B) but not well-defined in all dissection specimens due to the thinness of the covering fascia lata (fig 5.4 C). No direct conclusion regarding fascia/muscle relationship could be drawn from Magnetic Resonance images at this level (fig 5.4 D) as the fascia lata could not be distinguished from the underlying muscle. On the transverse anterior Ultrasound image (fig 5.4 E) the fascia lata appears as a single fascial layer (solid arrow) in close relationship to the underlying sartorius muscle.



**Figure 5.4** Features of the relationships observed between the fascia lata and the upper sartorius muscle at cross cut Level I

- A** The sartorius muscle (S) with the superficial and deep laminae of the split fascia lata (solid arrows)
- B** Attempting to pull the fascia lata (solid arrow) away from the muscle. A close relationship due to fascial septa from the deep surface of fascia lata is not clearly demonstrated in this image
- C** Image of a cut where the fascia lata and laminae are particularly thin (solid arrows) making a direct close relationship judgment difficult unless one can pull on the fascia lata directly
- D** On an axial Magnetic Resonance image of this level the fascia lata (solid arrow) and underlying sartorius muscle (S) cannot be seen as separate structures
- E** A transverse Ultrasound image showing the fascia lata (solid arrow) clearly defined as a single layer on the outer surface of the sartorius muscle (S)







## **5.5 Level II – 6 to 8 cm below the greater trochanter**

The dissection cut at Level **II** included the superficial fascia, the fascia lata, the vastus lateralis, rectus femoris and sartorius muscles.

### **5.5.1 The superficial fascia and fascia lata**

#### **Superficial fascia**

As observed at Level **I**, well defined membranous layers within the adipose superficial fascia were identified on dissections (arrowhead, fig 5.5 A and B) and transverse Ultrasound images (arrowhead, fig 5.5 F). Magnetic Resonance images of this level were not as clear as anticipated, and therefore the membranous layers were not clearly visible.

#### **Fascia lata**

The fascia lata was well defined in all dissections as thick laterally and thin anteromedially. The fascia lata was recognisable as a separate structure on Ultrasound images (solid arrow, fig 5.5 F). Because of the tensor fasciae latae muscle being longer in some individuals, the muscle belly was still observed on some images (fig 5.5 F) while in others, the deep and superficial laminae of the muscle had united into a single layer of fascia (fig 5.5 C and D) forming the thickened iliotibial band (ITB) of the lateral side of the thigh.

The anterior doubled layer of fascia lata housing peripheral structures observed at level **I** could still be seen on dissections (solid arrows, fig 5.5 E). The double layer appeared to extend further medially over the sartorius muscle as well, in contrast to it being well defined only anterior to the rectus femoris muscle at Level **I**. Similar to variations seen with the different view of the tensor fasciae latae muscle, there were variations in the



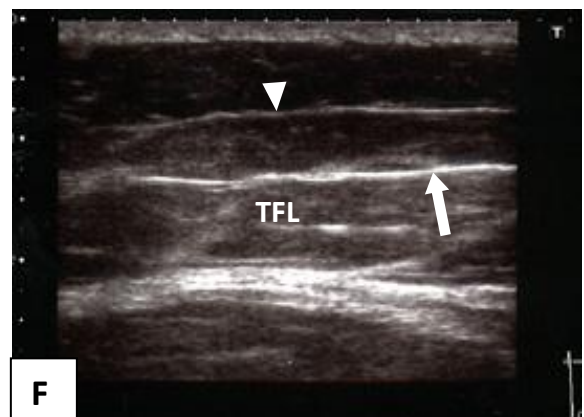
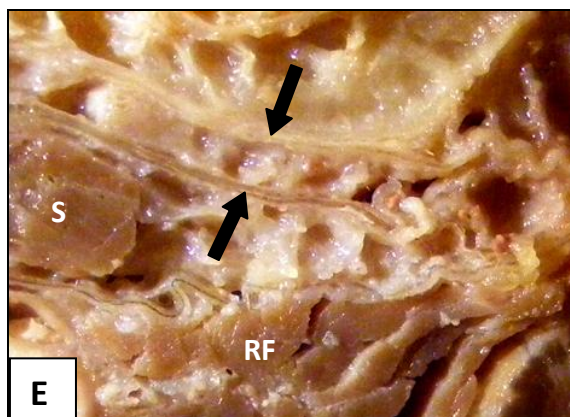
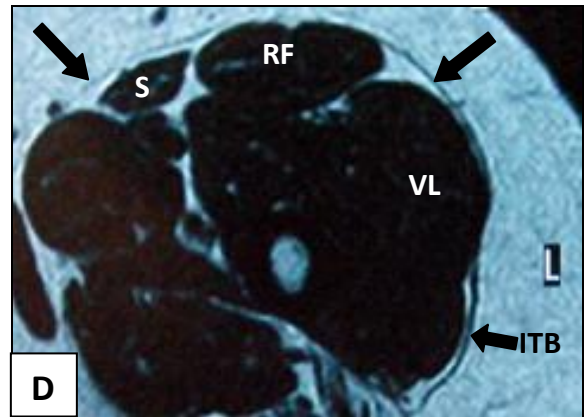
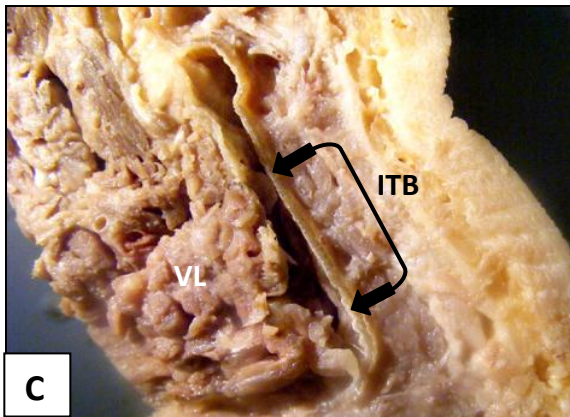
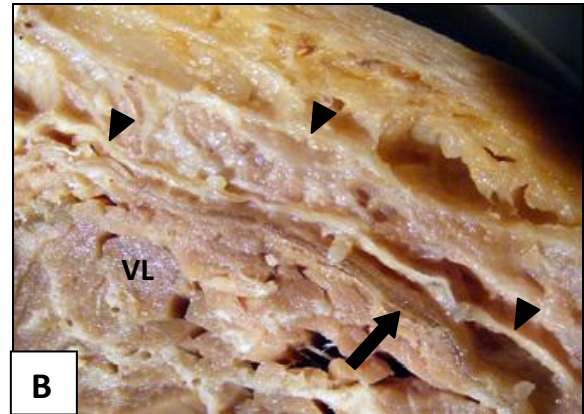
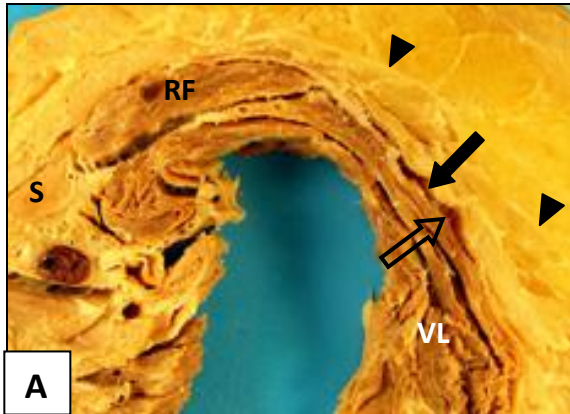
clarity of the double fascial layer at this level (Level **II**) as this phenomenon did not project as far down the front of the thigh in all individuals.



**Figure 5.5** Features of the superficial fascia and fascia lata observed at cross cut level **II**

- A** Dissection cross cut with the membranous layers within the superficial fascia visible anterolaterally (arrowheads). The fascia lata is thick laterally (solid arrow) with a loose relationship between fascia and vastus lateralis (open arrow), while thin and delicate anteromedially
- B** Well defined membranous layers (arrowheads) within the lateral superficial fascia. The deep membranous layer is well defined and could be identified as the fascia lata (solid arrow) by an unsuspecting student during routine dissections
- C** Distal to the tensor fasciae latae muscle the superficial and deep laminae of the fascia lata merge to continue as the well defined ITB (double solid arrows)
- D** Magnetic Resonance image showing the fascia lata clearly (solid arrows) and the thickened lateral fascia forming the iliotibial band (ITB)
- E** A close-up image of the double layer (solid arrows) formed by the fascia lata housing peripheral nerves and vessels anterior to the rectus femoris (RF) and sartorius (S) muscles
- F** Lateral transverse Ultrasound image showing a well defined membranous layer in the superficial fascia. The fascia lata is a single structure (solid arrow) at this level as it overlies the tensor fasciae latae muscle (TFL)







### **5.5.2 Vastus lateralis muscle**

On all the dissection cuts at level **II**, the thick, well defined fascia lata covering the vastus lateralis muscle could be identified clearly (solid arrows, fig 5.6 A). The fascia lata was in a loose relationship over the vastus lateralis muscle in all dissection specimens. This relationship was due to a distinct adipose layer identified between muscle and fascia (open arrows, fig 5.6 B and C). Although in specimens with less adipose tissue, a clear separation between fascia and muscle was poorly defined. Gentle probing (blunt dissection) could easily separate fascia (solid arrow, fig 5.6 C) from underlying muscle due to the presence of loose areolar connective tissue (open arrows, fig 5.6 C) between fascia and muscle.

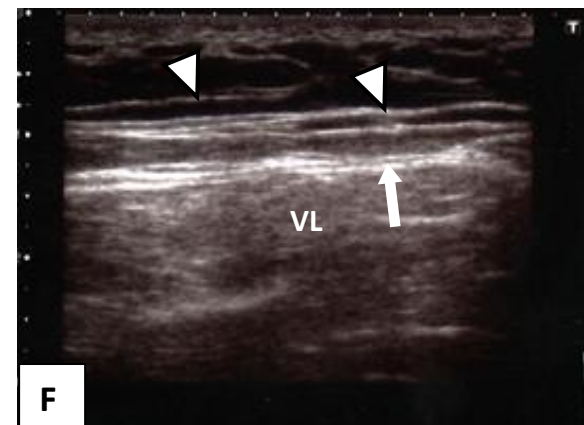
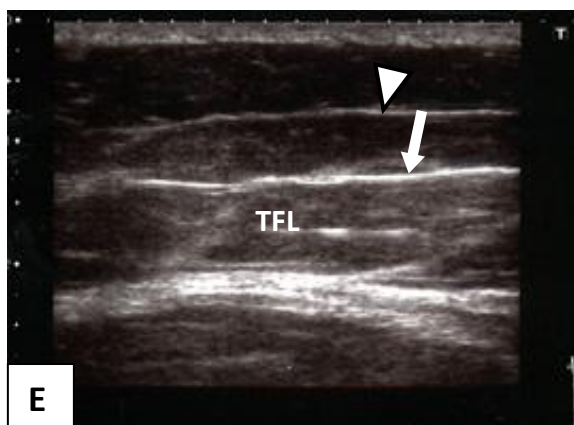
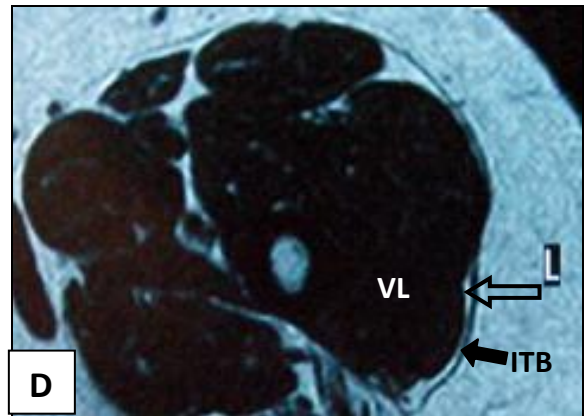

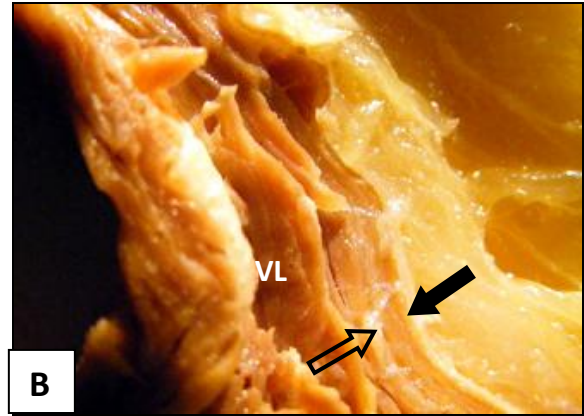
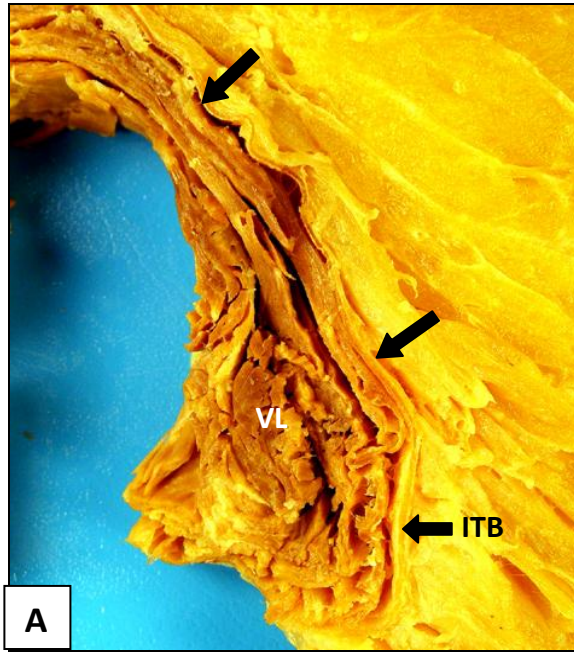
The loose relationship between the fascia lata and vastus lateralis muscle could only be observed on Magnetic Resonance Imaging in one image where adipose tissue separated fascia from muscle (fig 5.6 D). On some Ultrasound images at this level, the thickened fascia lata was a well defined single layer (solid arrow, fig 5.6 E) and in other images the gap between the fascia lata and underlying epimysium (solid arrow, fig 5.6 F) was visible.



**Figure 5.6** Features of the relationships observed between the fascia lata and the underlying vastus lateralis muscle at cross cut Level II

- A** The well defined thick fascia lata (solid arrows) covering the vastus lateralis muscle (VL) and forming the iliotibial band (ITB) laterally
- B** A closer view showing the adipose layer (open arrow) between the fascia lata (solid arrow) and the vastus lateralis muscle (VL)
- C** Attempted separation of the fascia lata (solid arrow) and underlying vastus lateralis muscle (VL) could easily be performed by blunt dissection due to varying amounts of adipose and loose areolar connective tissue between fascia and muscle (open arrows)
- D** An Axial Magnetic Resonance image with the fascia lata (solid arrow) and vastus lateralis muscle (VL) visible as two structures due to adipose tissue (open arrow) between fascia and muscle
- E** A lateral transverse Ultrasound image showing a well defined membranous layer visible within the superficial fascia. The fascia lata is a single structure (solid arrow) at this level as it overlies the tensor fasciae latae muscle (TFL)
- F** A lateral transverse Ultrasound image showing the fascia lata as a well defined structure and having a double fascia appearance (solid arrow)







### 5.5.3 Rectus femoris muscle

On all the dissection cuts at Level **II**, the rectus femoris muscle could be observed within a fascial sleeve. It had a loose relationship to the fascia lata (solid arrows, fig 5.7 A) on its outer surface. This relationship was also observed between the deep surface of the rectus femoris muscle and the adjacent deep vastus medialis (VM), intermedius (VI) and lateralis (VL) muscles (fig 5.7 A). The adipose layer between fascia lata and rectus femoris was not as prominent as at Level **I**, but still clearly visible. The fascia lata could easily be separated from the rectus femoris muscle by gentle pulling on the fascia or muscle (open arrow, fig 5.7 B).

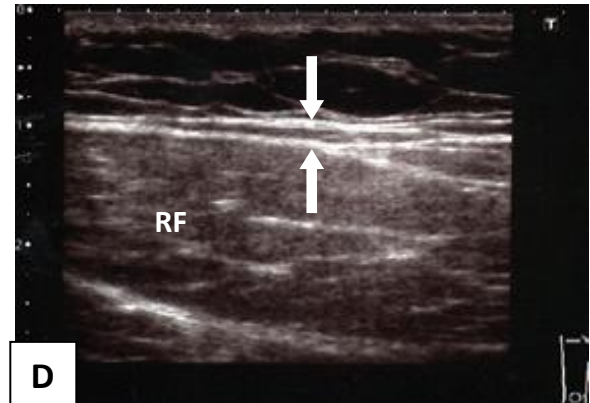
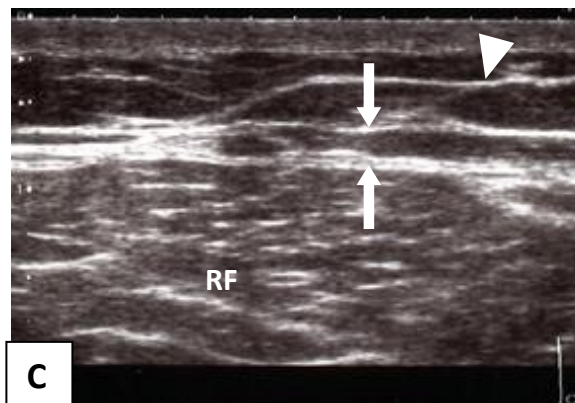
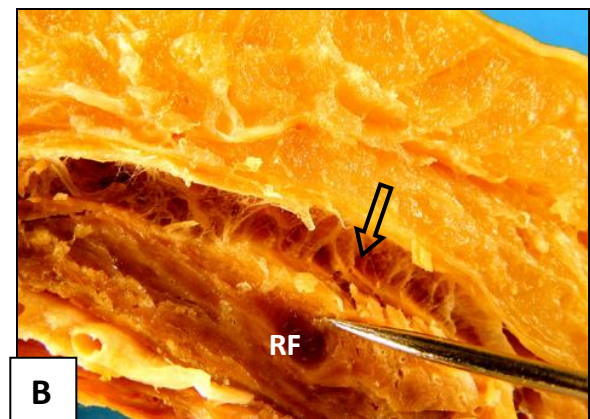
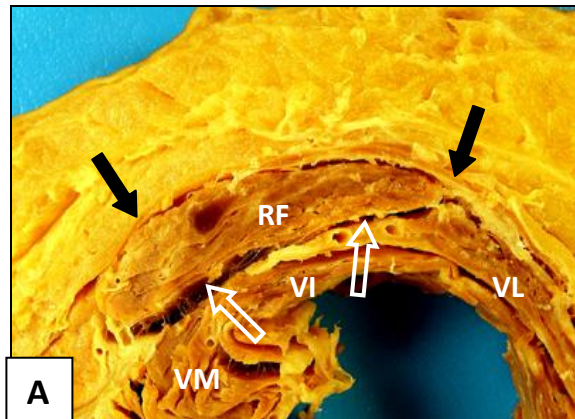
On transverse Ultrasonography images at Level **II** the fascia/adipose tissue/muscle layers were clearly visible (between solid arrows, fig 5.7 C and D) as a double appearance of the fascia over the rectus femoris muscle. Magnetic Resonance images of this level were not of good quality and no relationships could be easily identified.



**Figure 5.7** Features of the relationships observed between the fascia lata and the underlying rectus femoris muscle at cross cut Level **II**

- A** The rectus femoris muscle (RF) under the fascia lata (solid arrows). The separation between the rectus femoris muscle and deep vastus medialis (VM), intermedius (VI) and vastus lateralis (VL) muscles (open arrows) is demonstrated well
- B** Separating the rectus femoris muscle (RF) from the overlying fascia lata can easily be done by blunt dissection due to the loose relationship (open arrow) between fascia and muscle
- C** A midline transverse Ultrasound image over the rectus femoris muscle (RF) showing a space between the fascia lata and the rectus femoris muscle epimysium (between solid arrows). A well defined membranous layer (arrowhead) is also visible
- D** Another transverse Ultrasound image over the rectus femoris muscle (RF) showing a space between fascia lata and the rectus femoris muscle epimysium (between solid arrows)







#### **5.5.4 Sartorius muscle**

Although the fascia lata (solid arrows, fig 5.8 A and C) and the sartorius muscles were easily identified, the muscle/fascia relationship could not as easily be delineated or confirmed in cross-cut dissections at this level. On some of the dissection specimens at Level **II**, the fascia lata appeared as a close relationship between fascia and muscle (fig 5.8 C) while in others, the thin layer of fascia seemed to be in a loose relationship to the sartorius muscle (fig 5.8 B).

Similar to Magnetic Resonance Imaging observations of the rectus femoris muscle, no clear observation could be made regarding fascia/muscle from the one Magnetic Resonance image (fig 5.8 D) available.

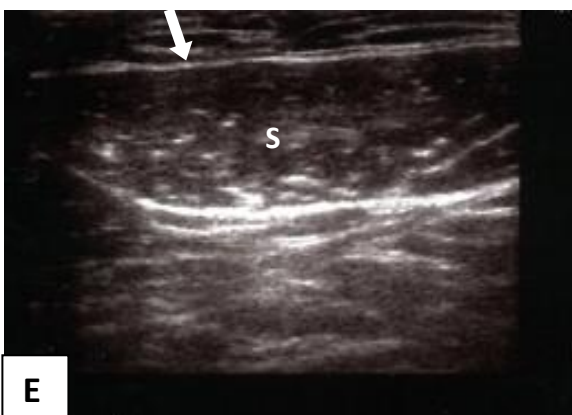
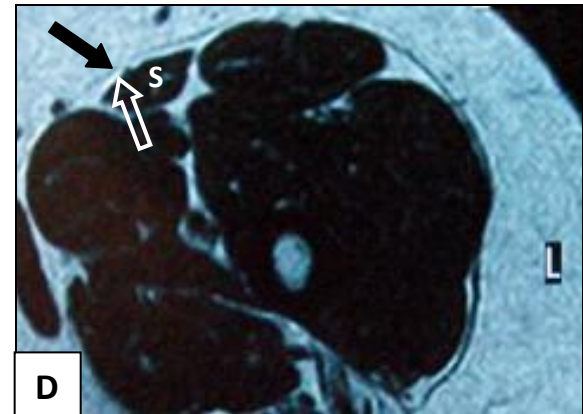
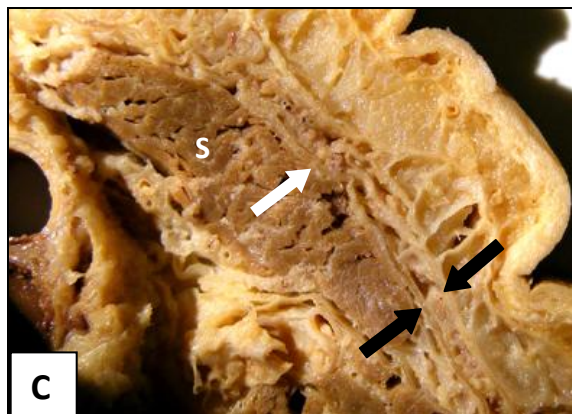

On transverse Ultrasound images of the medial aspect of the thigh at cross cut Level **II**, the sartorius muscle could be identified deep to a single thin layer of the fascia lata (solid arrow, fig 5.8 E). This had the appearance of a close relationship between fascia and muscle.



**Figure 5.8** Features of the relationships observed between the fascia lata and the underlying sartorius muscle at cross cut Level II

- A** The fascia lata (solid arrow) covering the sartorius muscle (S) is well defined but thin and almost transparent
- B** The sartorius muscle (S) on this image shows a loose relationship to the fascia lata (solid arrow) with loose areolar tissue (open arrow) between fascia and muscle
- C** In this dissection cut the fascia lata (white solid arrow) is in a close relationship with the sartorius muscle (S) while a double fascia lata layer (between solid arrows) is observed towards the lateral edge of the sartorius muscle
- D** An Axial Magnetic Resonance image with the fascia lata (solid arrow) and sartorius muscle (S) appearing as two structures due to adipose tissue (open arrow) between fascia and muscle
- E** A transverse Ultrasound image with sartorius (S) deep to a single thin layer of the fascia lata (solid arrow). This has the appearance of a close relationship between fascia and muscle







## **5.6 Level III – halfway between levels II and 5 cm above the upper border of the patella (level IV)**

The dissection cut at level **III** included the superficial fascia, the fascia lata, the vastus lateralis, rectus femoris and the vastus medialis muscles. In dissection cuts at this level, the distinction between a loose relationship and a close relationship between fascia lata and underlying muscles appeared better defined than in the previous two levels

### **5.6.1 The superficial fascia and fascia lata**

**Superficial fascia** During the detailed dissections at this level clear membranous layers were not encountered routinely. On the cross cut dissections, membranous layers were visible mostly only on the anterior and medial aspects of the thigh (arrowhead, fig 5.9 A). Ultrasonography and Magnetic Resonance images did show membranous layers both medially (arrowhead, fig 5.9 E) and laterally (arrowheads, fig 5.9 D) at this level. This was, however, not a consistent observation in any of the three modalities, especially on the lateral aspect of the thigh. (See also subsequent images in sections 5.5.2 and 5.5.4).

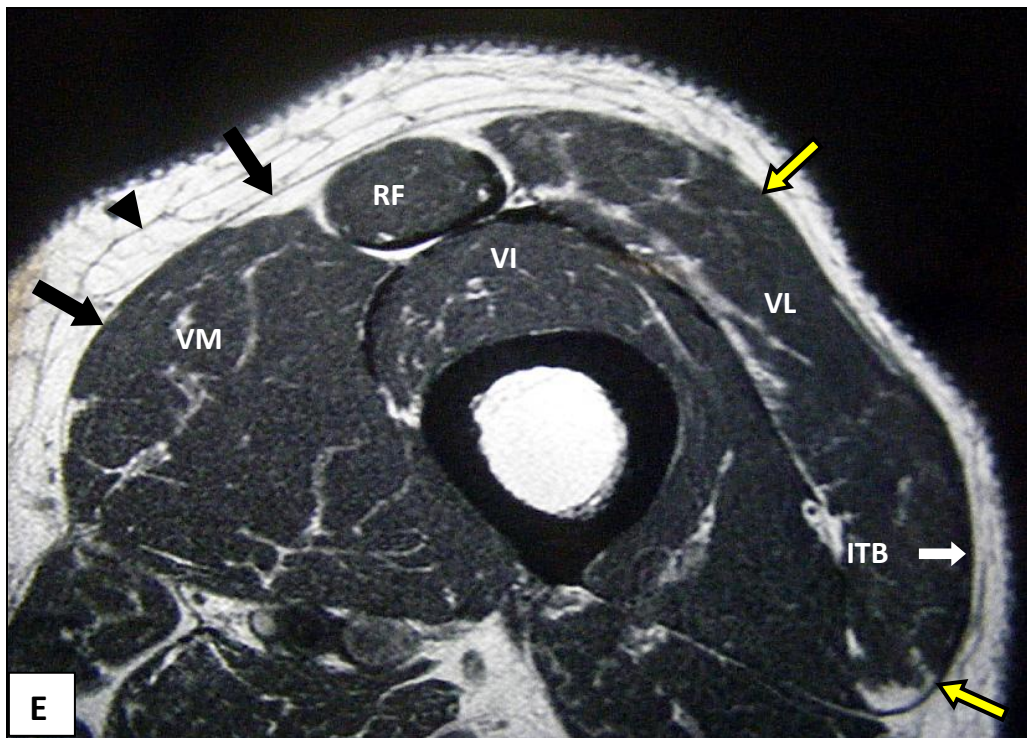
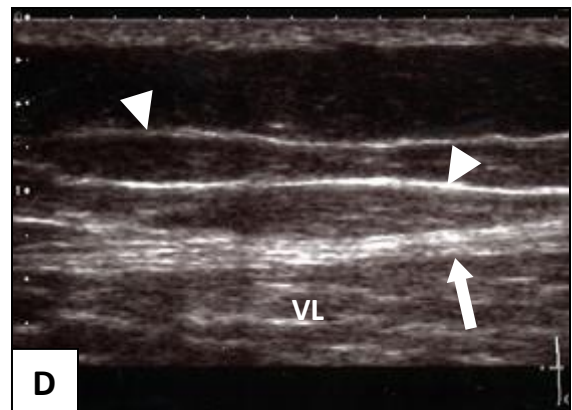
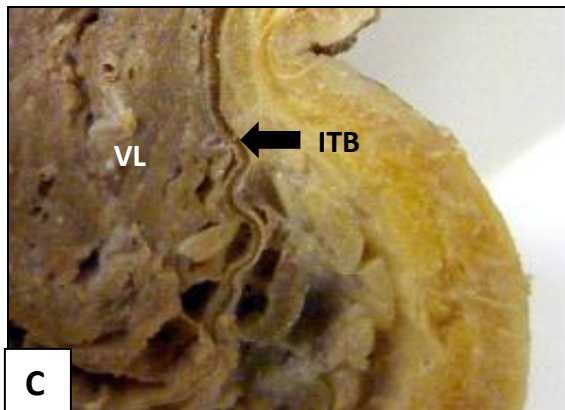
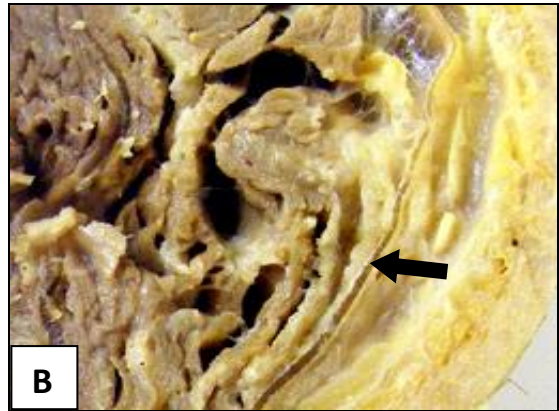
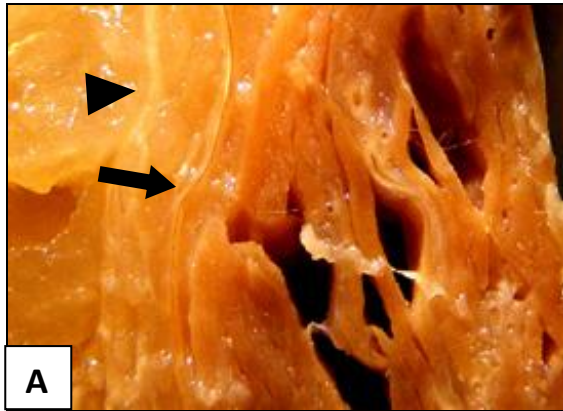
**Fascia lata** The fascia lata (solid arrows) was a well defined single fascial layer, thin and almost transparent medially (fig 5.9 A) while thick and strong on the lateral side (fig 5.9 B and C) on all the dissections. These features, thin medially (black arrows) and thick laterally (yellow arrows), were also clearly replicated in both the Magnetic Resonance Imaging (fig 5.9 E) and Ultrasonography images (solid arrow, fig 5.9 D). Laterally the fascia lata gradually thickened until it could be described as the prominently thickened iliotibial band (ITB, fig 5.8 C and E). No distinct border between fascia lata and ITB could be defined as the one gradually became the other.



**Figure 5.9** Features of the superficial fascia and fascia lata observed at cross cut  
Level **III**

- A** The fascia lata on the medial aspect of the thigh (solid arrow) is particularly thin.  
A membranous layer (arrowhead) could be defined
- B** The lateral fascia lata is thick, well defined and strong (solid arrow)
- C** The lateral aspect of the fascia lata gradually thickens to form the prominent Iliotibial tract (ITB)
- D** A lateral transverse Ultrasound image showing distinct membranous layers (arrowheads) and a thick, well defined fascia lata (solid arrow) over the vastus lateralis muscle (VL)
- E** An axial Magnetic Resonance image of level **III** showing a membranous layer medially (arrowhead), the thin fascia lata medially (black arrows) and thick fascia lata laterally (yellow arrows). Fascia and muscle cannot be readily distinguished from each other over the vastus medialis (VM) and vastus lateralis (VL) muscles. The thickened ITB (lower right white arrow) can be identified







### **5.6.2 Vastus lateralis muscle**

On all the dissections the loose relationship between the fascia lata and underlying vastus lateralis muscle was encountered. This loose relationship was well defined by loose areolar and adipose tissue between fascia and muscle (open arrows, fig 5.10 A and B). In all dissections the fascia lata could easily be detached from the underlying muscle epimysium by gentle pulling (blunt dissection) without damage to or distortion of underlying muscle fascicles.

The loose relationships observed in the detailed dissection studies could not be clearly seen or readily identified on Magnetic Resonance images (fig 5.10 C) at this level unless adipose tissue was present between fascia and muscle (open arrow, fig 5.10 C). The thickened lateral fascia lata became more evident and clearly distinguished from underlying muscle (arrow, fig 5.10 D).

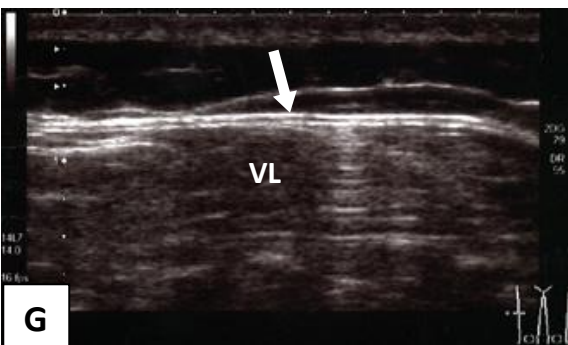
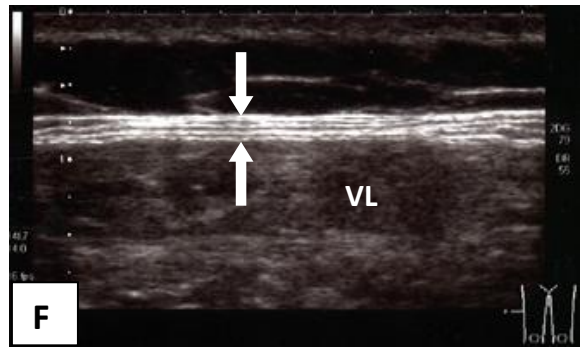
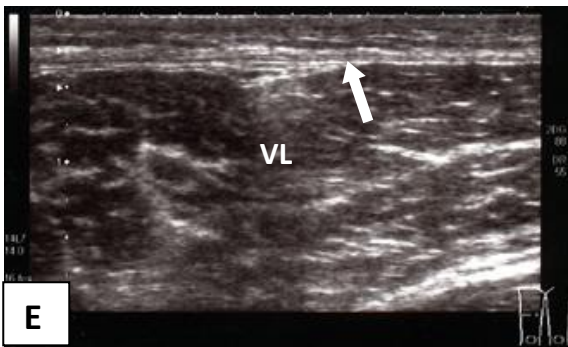
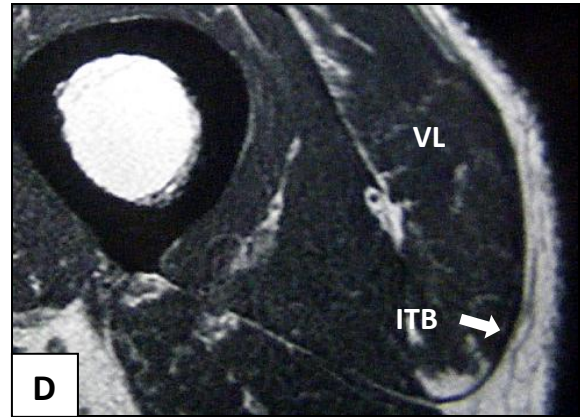
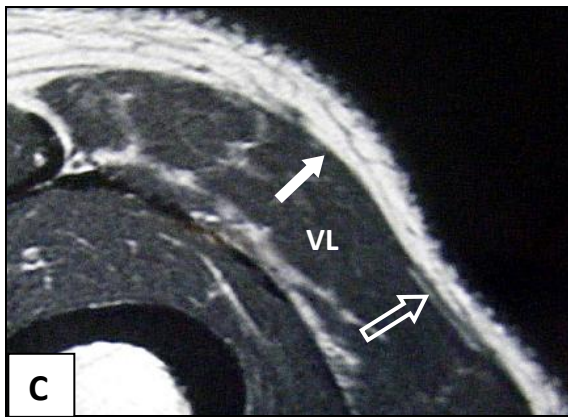
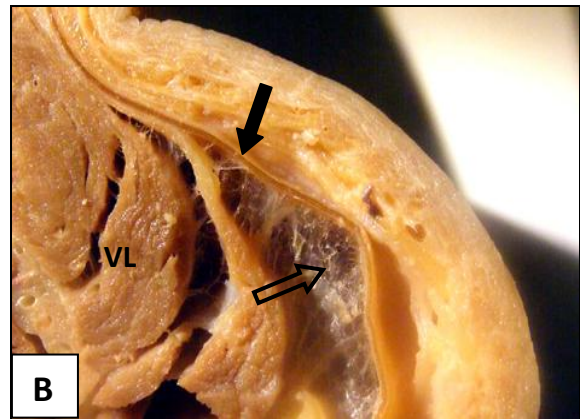
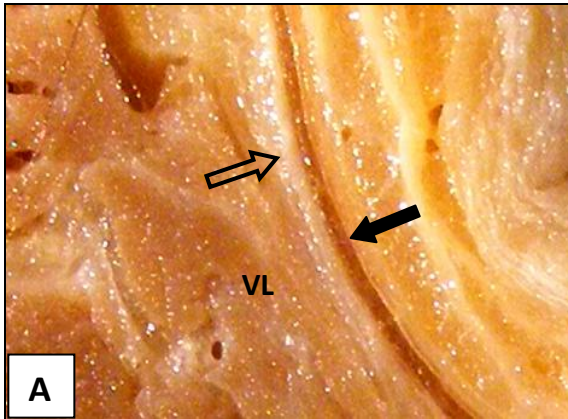
On all the lateral transverse Ultrasound images over the vastus lateralis muscle (fig 5.10 E, F and G) the fascia lata (solid arrows) was well defined and even had a trilaminar appearance in places (fig 5.10 F) not observed on dissection cuts or on Magnetic Resonance images. In Ultrasound images taken more anteriorly (fig 5.10 G) over the vastus lateralis muscle (VL) at this level, the fascia lata (solid arrow) and underlying muscle could be seen as separate from each other.



**Figure 5.10** Features of the relationships observed between the fascia lata and the underlying vastus lateralis muscle at cross cut Level **III**

- A** Adipose tissue (open arrow) between fascia lata (solid arrow) and the vastus lateralis muscle (VL)
- B** Loose areolar connective tissue (open arrow) between fascia lata (solid arrow) and the vastus lateralis muscle (VL)
- C** The fascia/muscle relationship is not clear on an axial Magnetic Resonance image (solid arrow) unless there is adipose tissue between fascia and muscle (open arrow)
- D** Where the fascia late is substantially thickened as in the region of the ITB, the fascia lata could be differentiated from the underlying muscle (solid arrow)
- E** A lateral transverse Ultrasound image showing a well defined fascia lata (solid arrow) overlaying the vastus lateralis muscle (VL). The fascia lata and muscle epimysium appear as two separate structures
- F** A lateral transverse Ultrasound image over the ITB where the fascia lata relationship to the vastus lateralis muscle appears to be formed by three fascial layers (solid arrows)
- G** A lateral transverse Ultrasound image of the same leg anterior to the ITB over the vastus lateralis muscle where the fascia lata (solid arrow) and muscle epimysium form two recognisable layers







### 5.6.3 Rectus femoris Muscle

Similar to the observations at level **II**, the rectus femoris muscle was in a loose relationship to not only the overlying fascia lata, but also to the adjacent vastus medialis, intermedius and lateralis muscles in all dissection cuts. Although an adipose layer between fascia lata and the rectus femoris muscle was absent in specimens with less adipose tissue (fig 5.11 A), the muscle could still easily be detached from its overlying fascia lata and surrounding fascial sleeve by blunt dissection (fig 5.11 B). The rectus femoris muscle could also be easily separated from the vastus intermedius muscle which lies posteriorly (fig 5.11 B). The loose relationship between fascia lata and rectus femoris was clearly observed in all dissections. The adipose layer between fascia lata and the rectus femoris muscle was less prominent at this level or present as only a thin layer of loose areolar connective tissue, to facilitate sliding between fascia and muscle.

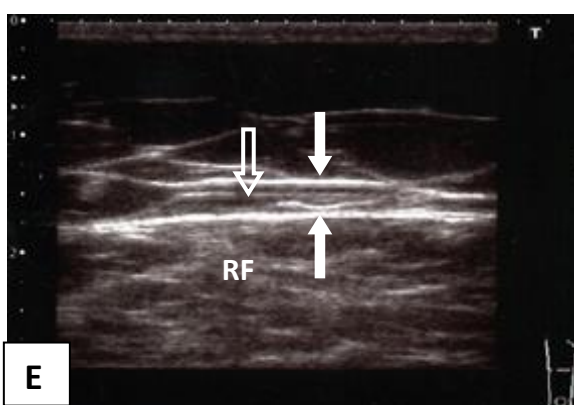
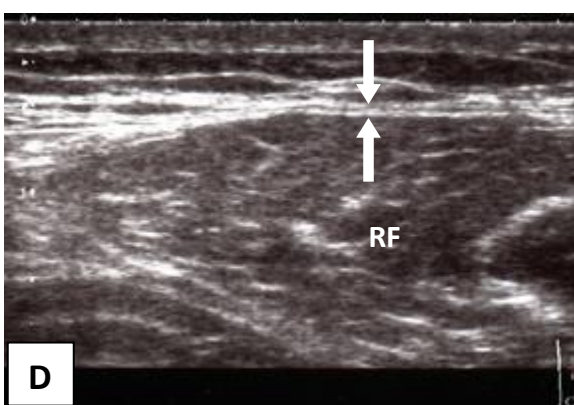
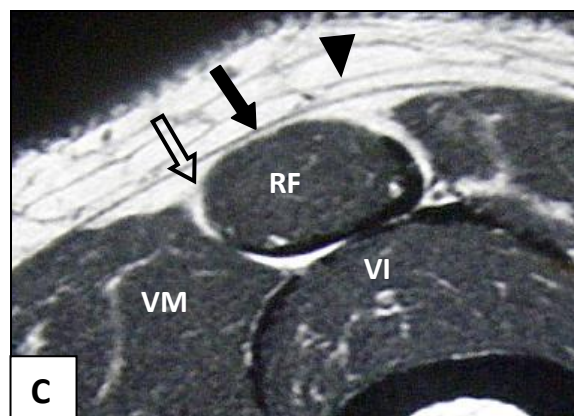
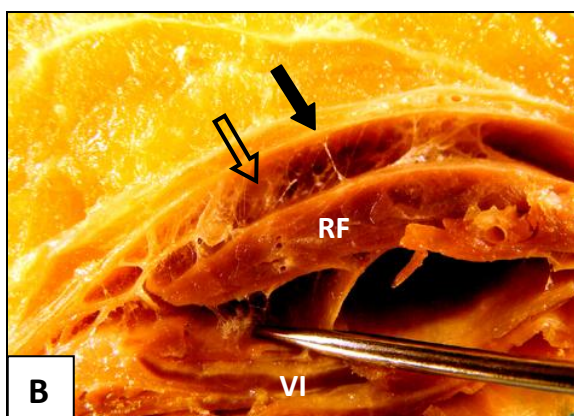

The fascia lata as a distinct structure, separate from the underlying rectus femoris muscle, was clearly observed on all the Magnetic Resonance images (solid arrow, fig 5.11 C) at this level. On anterior transverse Ultrasound images over rectus femoris, features of a double fascial arrangement were observed (fig 5.11 D and E). This double fascial layer could be interpreted as the presence of a loose relationship between fascia and muscle.



**Figure 5.11** Features of the relationships observed between the fascia lata and the underlying rectus femoris muscle at cross cut Level **III**

- A** The rectus femoris muscle (RF) under a well defined fascia lata (solid arrows). The second well defined fascial layer (arrowheads) is a membranous layer within the superficial fascia
- B** The rectus femoris muscle (RF) shows a loose relationship to the fascia lata (solid arrow) with easy separation of the muscle from the fascia lata anteriorly as well as posteriorly from the vastus intermedius muscle (VI). Loose areolar connective tissue between fascia and muscle (open arrow) makes the separation of muscle and fascia possible
- C** An axial Magnetic Resonance image showing the fascia lata (solid arrow) as separated from the underlying rectus femoris muscle (RF) by adipose tissue (open arrow)
- D** An anterior transverse Ultrasound image showing the double fascia arrangement (solid arrows) between fascia lata and the rectus femoris muscle (RF)
- E** An anterior transverse Ultrasound image of a model with more adipose tissue (open arrow) between fascia lata and the rectus femoris muscle (RF)







#### **5.6.4 Vastus medialis muscle**

The vastus medialis muscle starts relating to its overlying fascia lata in the lower half of the thigh and therefore only becomes visible as part of the cross cut dissection at Level **III**. Fascial relationship between fascia lata and the vastus medialis muscle shows similar variations between individual dissected specimens as in the detailed layered dissections (chapter 4). In all the specimens, areas of a loose relationship between fascia lata and muscle were found (between solid arrows, fig 5.12 A, B and D) bordering onto the rectus femoris muscle. The space of loose relationship between fascia and muscle was filled with adipose tissue (open arrows, fig 5.12 A, B and D). The remaining parts of the vastus medialis muscle were firmly associated with the fascia lata (lower solid arrow, fig 5.12 A) with intramuscular septa (open arrow, fig 5.12 C) passing from the deep surface of the fascia lata between muscle fascicles. In all the areas of close relationships, removal of the fascia lata from underlying muscle by purely pulling on the fascia, as done for the vastus lateralis muscle and the rectus femoris muscle resulted in damage to the underlying vastus medialis muscle fascicles.

Areas of loose relationships between fascia and muscle bordering on the rectus femoris muscle were clearly observed on Magnetic Resonance images (between solid arrows fig 5.12 D). Where a close relationship existed, it was not possible to substantiate this on Magnetic Resonance Imaging. Medial transverse Ultrasound images were clearer in showing the fascia lata as a thin layer directly in contact with the underlying muscle (fig 5.12 E and F).



**Figure 5.12** Features of the relationships observed between the fascia lata and the underlying vastus medialis muscle at cross cut Level **III**

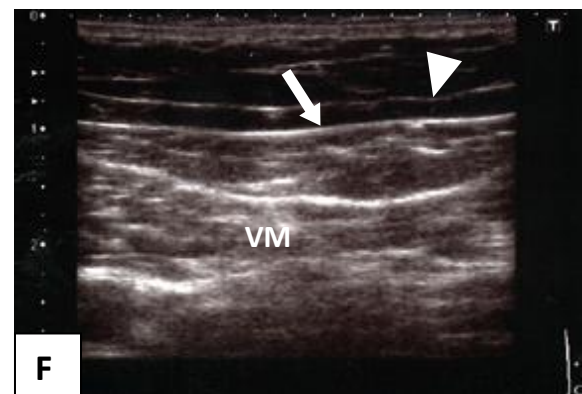
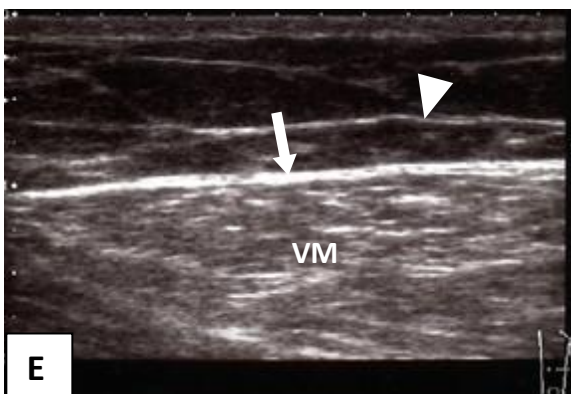
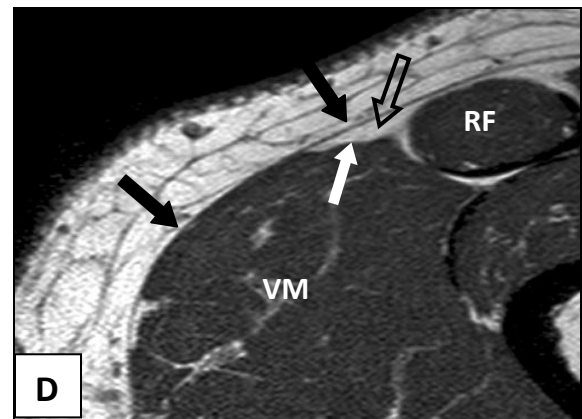
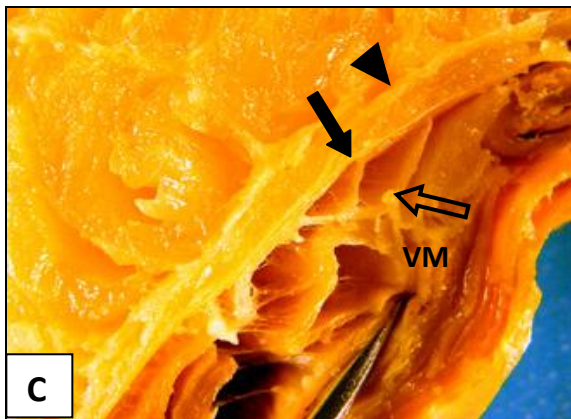
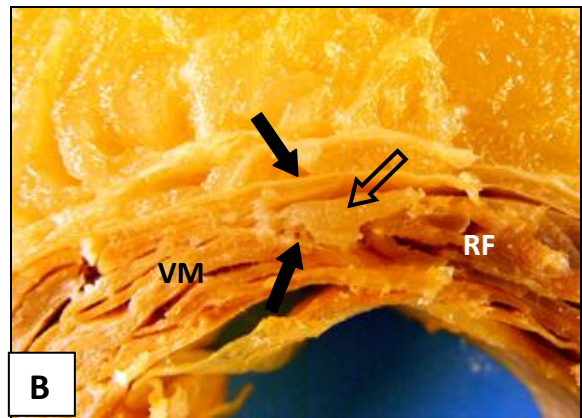
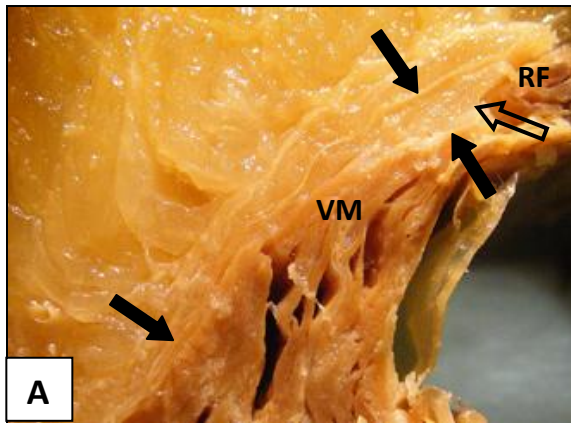
- A The vastus medialis muscle (VM) is separated from the fascia lata (solid arrow) by adipose tissue (open arrow) where it borders medially on the rectus femoris muscle (RF). Further away from the rectus femoris muscle, the fascia lata becomes closely associated with the underlying the vastus medialis muscle (lower solid arrow)
- B A closer view of the area of loose relationship (open arrow) between the vastus medialis muscle (VM) and fascia lata (between solid arrows) bordering on the rectus femoris muscle (RF)
- C The vastus medialis muscle (VM) relates closely to the overlying fascia lata (solid arrow) by intramuscular septa (open arrow) passing from the deep surface of the fascia lata between muscle fascicles. A membranous layer (arrowhead) may be confused with the fascia lata proper on this view
- D An axial Magnetic Resonance image showing an area of loose relationship (open arrow) between fascia lata and the vastus medialis muscle (VM) clearly visible between solid black and white arrows. Further away from the rectus femoris muscle (RF), fascia and muscle merge and cannot be distinguished separately (left solid arrow)
- E A medial transverse Ultrasound image over the vastus medialis (VM) muscle showing a well defined fascia lata (solid arrow) in close relationship to the



underlying muscle and a membranous layer (arrowhead) is visible within the superficial fascia

- F A medial transverse Ultrasound image with the thin, well defined fascia lata (solid arrow) and a membranous layer (arrowhead) within the superficial fascia







## **5.7 Level IV – 5 cm above the upper border of the patella**

The dissection cut at level **IV** included the superficial fascia, the fascia lata, the vastus lateralis, rectus femoris and the vastus medialis muscles. Similar to views from Level **III**, the distinctions between a loose relationship and a close relationship between fascia lata and underlying muscles could clearly be demonstrated at this level.

### **5.7.1 Superficial fascia and fascia lata**

**Superficial fascia** The adipose layer in the superficial fascia at the lower levels of the thigh was less pronounced than the upper half of the thigh and hips. Whereas membranous layers on the lateral aspect of the thigh were readily encountered in the upper levels of the dissection cuts, membranous layers in the lateral lower half of the thigh were poorly defined or absent. Well defined membranous layers were however still present medially (arrowheads, fig 5.13 B and D).

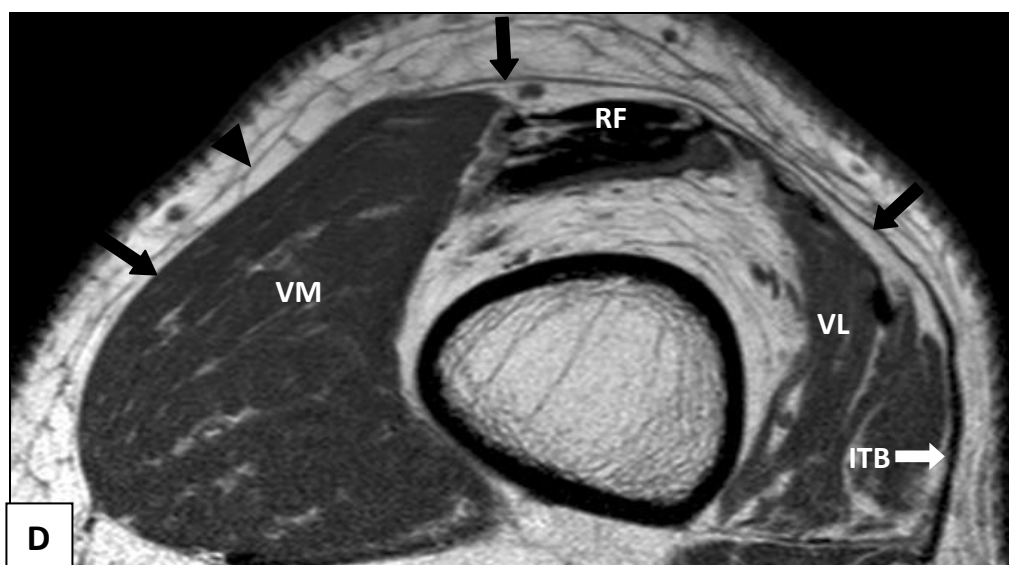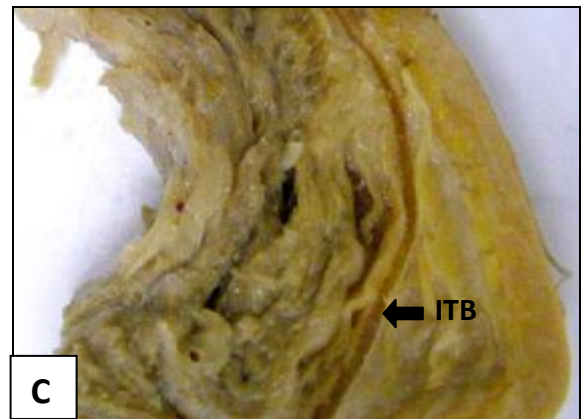
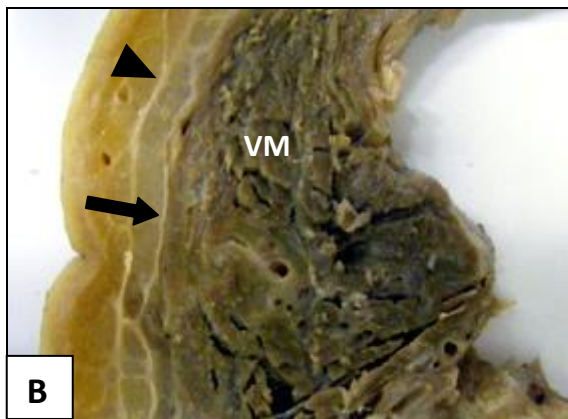
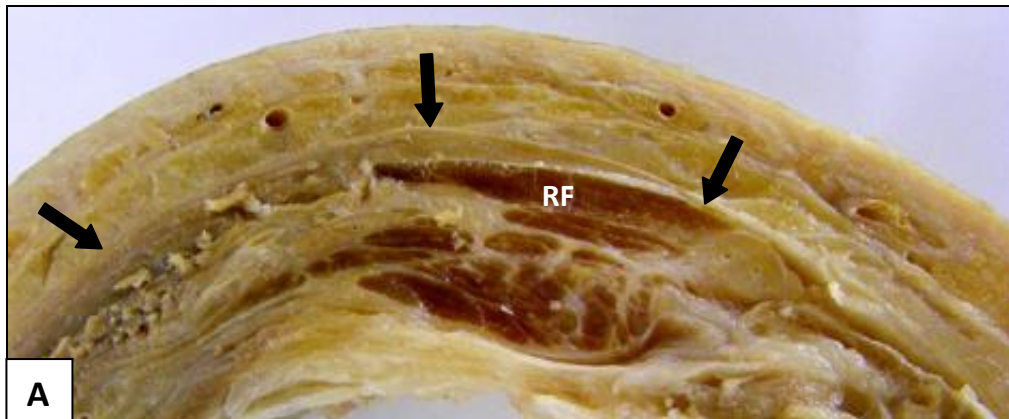
**Fascia lata** The fascia lata was particularly well defined in all the dissection cuts at this level (fig 5.13 A, B and C). Here it is the closest to traditional textbook descriptions of the fascia lata being a sleeve around the thigh: “thick and strong laterally and thin, almost transparent medially” (fig 5.13 B and C). The lateral thickened ITB part of the fascia lata was prominent and well defined on dissection cuts (solid arrows, fig 5.13 C). The axial Magnetic Resonance Imaging views at this level were closest to replicating what was observed in detailed dissections with the fascia lata thin anteromedially, thick laterally (solid arrows, fig 5.13 D) and separated from the underlying rectus femoris (RF) and vastus lateralis (VL) muscles.



**Figure 5.13** Features of the superficial fascia and fascia lata at cross cut Level **IV**

- A** Dissection view of the anterior aspect showing the fascia lata as a thin and well defined structure (solid arrows)
- B** A medial dissection view showing a well defined and visible membranous layer (arrowhead). The fascia lata (solid arrow) is thin and closely related to the underlying vastus medialis muscle (VM) making the fascia late difficult to identify as a separate structure
- C** On a lateral dissection view, the fascia lata is particularly well defined and thickened laterally to form the ITB (solid arrows)
- D** An axial Magnetic Resonance image where the medial membranous layer (arrowhead), the thin anterior fascia lata (black solid arrow) and the well defined ITB (white solid arrows) laterally can clearly be identified







### **5.7.2 Vastus lateralis muscle**

Similar to Level **III**, all the dissection cuts had a loose relationship between fascia lata and the underlying vastus lateralis muscle. This loose relationship was well defined and even more pronounced with loose areolar and adipose tissue between fascia and muscle (open arrows, fig 5.14 A B and D). In all dissections the fascia lata could easily be detached from the underlying muscle epimysium by gentle pulling (blunt dissection) without damage to or distortion of underlying muscle fascicles (fig 5.14 C).

The well defined lateral fascia lata and its thickened ITB could be clearly visualised on all the axial Magnetic Resonance images of this level (solid arrows, fig 5.14 E). Varying amounts of adipose tissue could be seen between fascia lata and muscle (open arrows, fig 5.14 E).

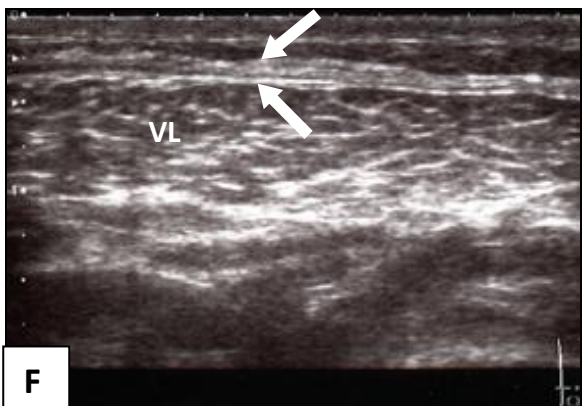
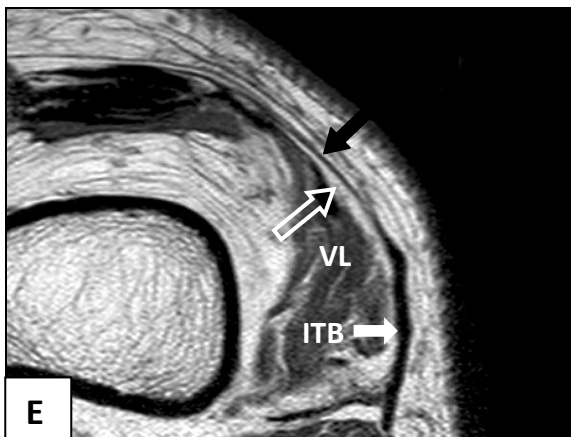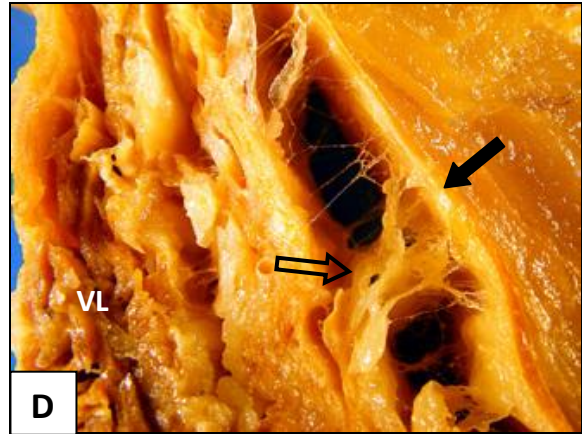
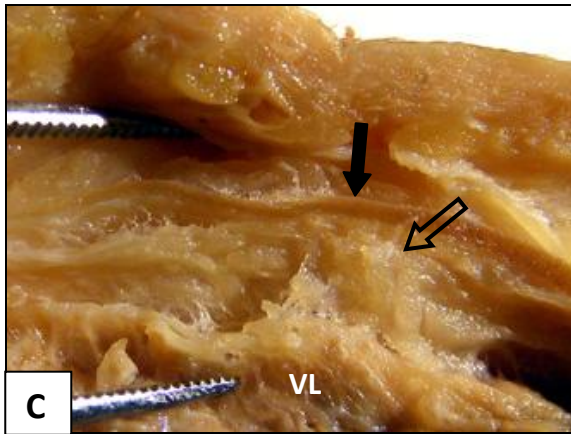
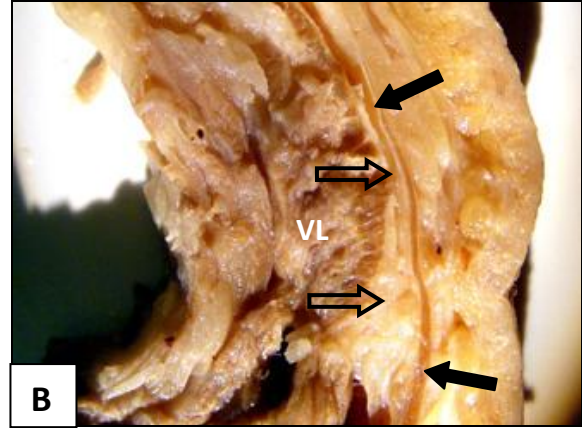
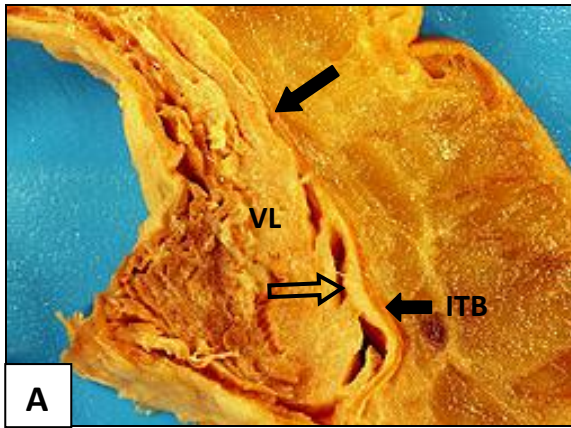
On all the lateral transverse Ultrasound images over the vastus lateralis, the fascia lata and ITB was well defined (solid arrow, fig 5.14 F).



**Figure 5.14** Features of the relationships observed between the fascia lata and the underlying vastus lateralis muscle at cross cut Level **IV**

- A** A cross cut dissection showing the vastus lateralis muscle (VL) in a loose relationship due to adipose tissue (open arrow) deep to the well defined lateral fascia lata and ITB (solid arrows)
- B** The lateral fascia lata (solid arrows) with an adipose layer (open arrows) between fascia and the vastus lateralis muscle (VL)
- C** Separation of fascia lata (solid arrow) and muscle made easy by adipose tissue (open arrow) between fascia and the vastus lateralis muscle (VL)
- D** The fascia lata (solid arrow) separating from the vastus lateralis muscle (VL) due to adipose loose areolar connective tissue (open arrow) between fascia and muscle
- E** An axial Magnetic Resonance image with the thick lateral fascia lata and ITB well defined (solid arrows). The adipose tissue (open arrow) separating the fascia lata and the vastus lateralis muscle (VL) at this level is clearly demonstrated
- F** A lateral transverse Ultrasound image showing a well defined fascia lata covering the vastus lateralis (VL) muscle. The fascial cover over the muscle appears as separated layers (solid arrows)







### **5.7.3 Rectus femoris muscle**

The rectus femoris muscle and tendon could be observed as being in a loose relationship to not only the overlying fascia lata, but also to the adjacent vasti in all dissection cuts. At this level, the rectus femoris muscle appeared as a flat tendon before it was joined by the other heads of the quadriceps group to form the quadriceps tendon (fig 5.15 A and B). The tendon appeared to be encircled by adipose tissue, allowing it to be easily separated from the surrounding fascia lata and other heads of the quadriceps group (fig 5.15 C).

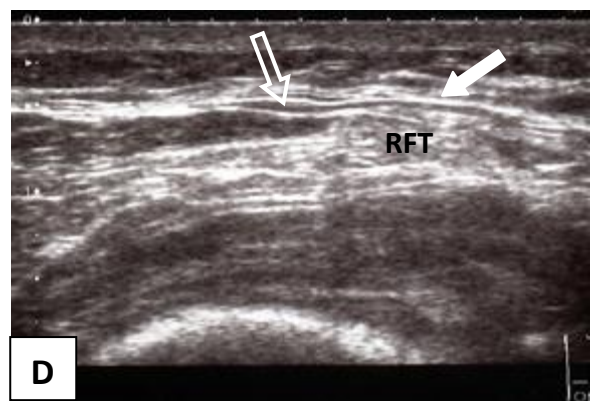
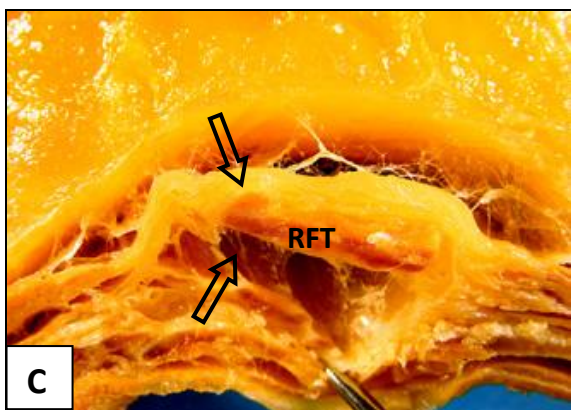
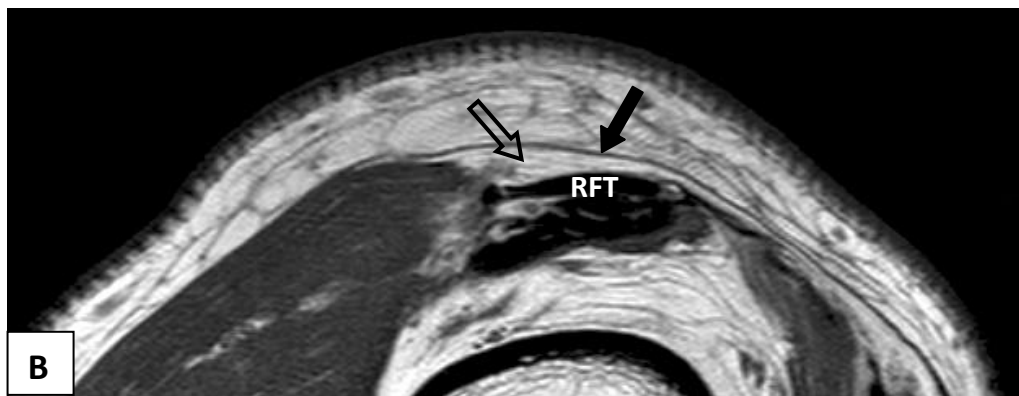
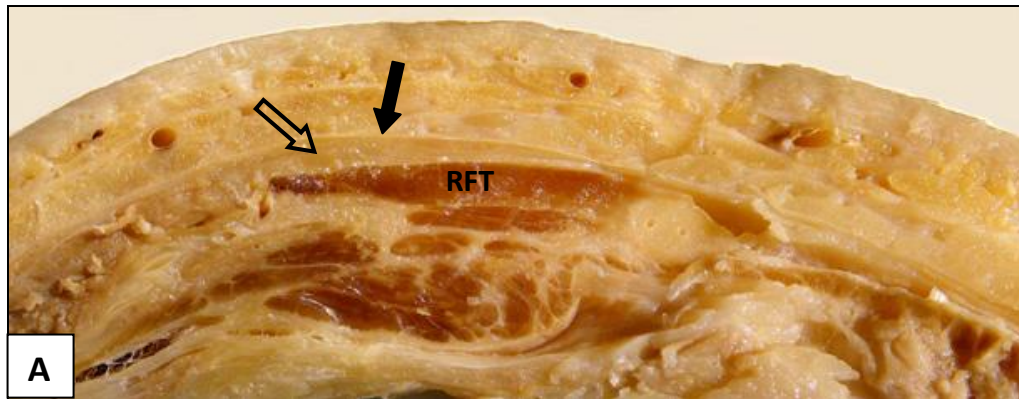
On axial Magnetic Resonance images at this level the fascia lata (solid arrow, fig 5.15 B) was well separated from the tendon of the rectus femoris muscle by adipose tissue (open arrow fig 5.15 B). On anterior transverse Ultrasound images over the rectus femoris muscle tendon, the adipose tissue (open arrow, figure 5.15 D) separating the fascia lata (solid arrow) from the tendon of the rectus femoris could also be observed.



**Figure 5.15** Features of the relationships observed between the fascia lata and the underlying rectus femoris muscle (tendinous) at cross cut Level **IV**

- A** A dissection cut showing the tendon of the rectus femoris muscle (RFT) well separated from the overlying fascia lata (solid arrow) by adipose tissue (open arrow)
- B** An axial Magnetic Resonance image clearly replicating observations from dissection views. The rectus femoris muscle tendon (RFT) is well separated from the fascia lata (solid arrow) by adipose tissue (open arrow)
- C** During dissection the tendon of the rectus femoris muscle (RFT) could easily be pulled away from surrounding structures due to varying amounts of adipose and loose areolar tissue (open arrows) surrounding it
- D** An anterior transverse Ultrasound image showing the fascia lata (solid arrow) as separate (open arrow) from the underlying tendon of the rectus femoris muscle (RFT)







#### **5.7.4 Vastus medialis muscle**

The vastus medialis muscle forms a prominent part of all cross cut views at level **IV**. At this level, the mixed relationships (loose and close relationship) between fascia and muscle were not as clearly demonstrated as at Level **III** and showed the greatest variation. In all dissection views, the close relationship between the fascia lata and the vastus medialis muscle was consistently demonstrated (solid arrow, fig 5.16 A and B). In none of the dissection cuts could the fascia lata be pulled away from the underlying muscle (fig 5.16 C) unless excessive force was used, resulting in damage to the underlying muscle structure.

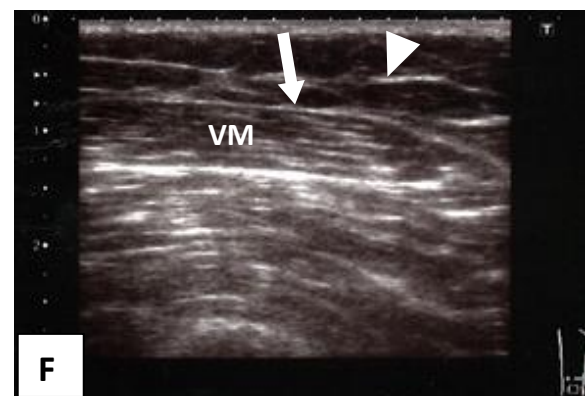
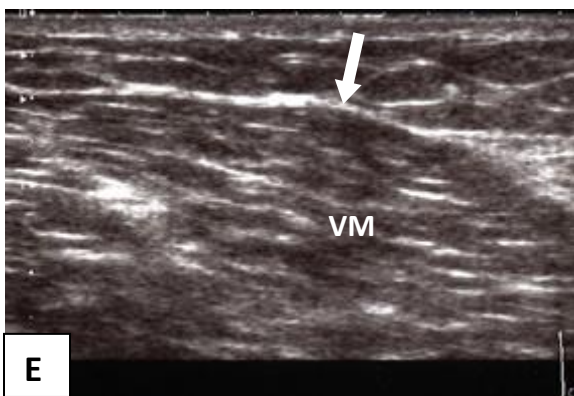
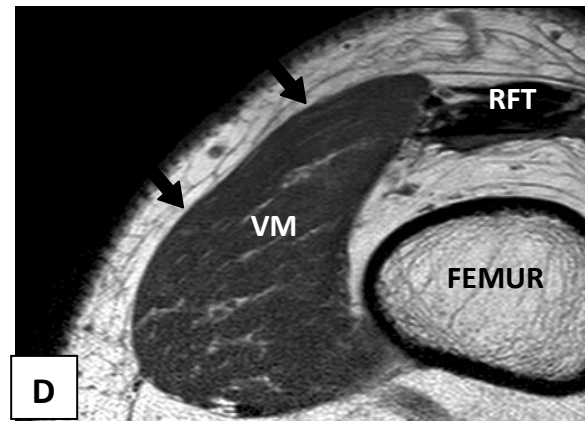

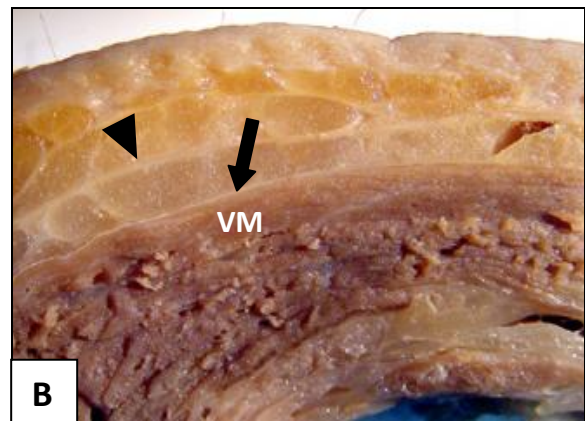
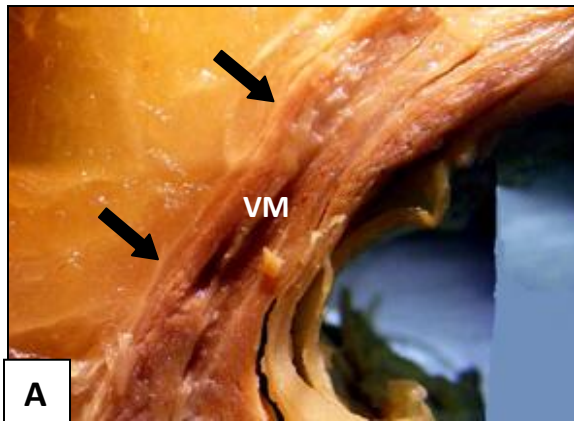
On the axial Magnetic Resonance images, the fascia lata covering the vastus medialis muscle could not be seen as a distinct and recognisable structure (fig 5.16D) and therefore accepted by implication as being in a close relationship to the underlying muscle. On medial transverse Ultrasound images the fascia lata was visible as a structure (solid arrows, fig 5.16 E and F), but always seen as part of the vastus medialis muscle epimysium/fascia.



**Figure 5.16** Features of the relationships observed between the fascia lata and the underlying vastus medialis muscle at cross cut Level **IV**

- A** The fascia lata is extremely thin at this level and difficult to visualise as a separate structure on dissection cuts (solid arrows)
- B** A closer view of the fascia lata (solid arrow) overlying the vastus medialis muscle (VM). The fascia lata appears very thin and closely related to the underlying muscle as opposed to a membranous layer (arrowhead) with underlying adipose tissue
- C** The vastus medialis muscle (VM) relates closely to the overlying fascia lata (solid arrow) by intramuscular septa (open arrow) passing from the deep surface of the fascia lata between muscle fascicles. Attempted separation of fascia and muscle at this level was not possible without damaging the underlying muscle
- D** An axial Magnetic Resonance image of the vastus medialis muscle (VM). The fascia lata could not be visualised as a distinct and recognisable structure on these images (solid arrows)
- E** A medial transverse Ultrasound image over the vastus medialis muscle (VM) showing a delicate single fascia lata (solid arrow) in close relationship to the underlying muscle
- F** A medial transverse Ultrasound image with the thin, delicate fascia lata (solid arrow) over the vastus medialis muscle (VM) and a membranous layer (arrowhead) visible within the superficial fascia







## 5.8 Summary of observations

At Level **I**, the correlation between dissection, Magnetic Resonance Imaging and Ultrasonography matched for the presence of membranous layers within the superficial fascia, the morphology of the fascia lata, the double layer within the fascia lata anterior to the rectus femoris muscle as well as the area of adipose tissue present between fascia lata and the rectus femoris muscle. For both the tensor fasciae latae muscle and the sartorius muscle, the correlation between dissection cross cuts, Magnetic Resonance Imaging and Ultrasonography could not be made with clarity and the close relationship seen between fascia lata and these muscles in the detailed layered dissections (chapter 4) could only be implied.

The correlation between dissection, Magnetic Resonance Imaging and Ultrasonography for Level **II** matched for the presence of membranous layers within the superficial fascia, the morphology of the fascia lata and the loose relationship between fascia lata and the rectus femoris muscle. Because of variants in the lengths of the tensor fasciae latae muscle, not all the images correlated well. In some Ultrasound images the tensor fasciae latae muscle was still visible, while in others only the fascia lata/ITB was seen. The loose relationship between fascia lata and the vastus lateralis muscle observed at this level on dissections correlated well with the Ultrasound images, but not with all the Magnetic Resonance images. On only one Magnetic Resonance image could the fascia lata and the vastus lateralis muscle be seen as separate structures. For sartorius the single fascia lata seen on Ultrasonography (fig 5.8 E) implied a close relationship not fully duplicated by dissection views (fig 5.8 B).



At Level **III** the correlation between modalities matched for the morphology of the fascia lata clearly showing the differences in thickness described for the lateral and medial aspects of the structure. Only the rectus femoris muscle correlated well between the three modalities. Membranous layers were not present in all specimens, and mostly only visible on the medial aspect of the thigh. One volunteer had a membranous layer visible on an Ultrasound image (fig 5.9 D). Correlation for the vastus lateralis muscle matched well between dissection and Ultrasonography (fig 5.10), but could not be seen with clarity on the Magnetic Resonance images, where fascia and muscle could not be distinguished from each other, thus implying a close relationship - not representing the dissection observations of a distinct loose relationship. All images for the vastus medialis muscle showed the fascia lata as a thin structure in close relationship with the underlying muscle (fig 5.12). It was however not clear from the images whether one could imply a close relationship from Magnetic Resonance Imaging and Ultrasonography only. Even looking at the dissection, a close relationship was not clear unless one tried to pull the fascia away from the muscle.

Dissection, Magnetic Resonance Imaging and Ultrasound images at Level **IV** matched for the greater part on all aspects of the correlations. However, a close relationship as observed in dissections for the vastus medialis muscle could only be implied by the observed relationships between fascia lata and muscle on Magnetic Resonance Imaging and Ultrasonography.

## **5.9 Conclusion**

The correlation of structural similarities and variations in anatomical features of the fascia lata and its relations to underlying muscles by using dissection, Magnetic Resonance Imaging and Ultrasonography views matches well between the three chosen modalities.



Judgements regarding observed close and loose relationships between the fascia lata and muscle could not be made without having to make certain assumptions. The value of this study lies in the correlation of dissection findings with the Magnetic Resonance Imaging and Ultrasound images. It provided another view of how a structure that appears to be in a close relationship to a muscle could actually be in a loose relationship if dissection observations are added to the interpretation of findings.



## 6 GENERAL DISCUSSION

*“It is not only necessary for a Surgeon that he should know the different parts of an animal, but he should know their uses in the machine, and in what manner they act to produce their effect.”* John Hunter, 1728-1793 (Moore, 2005).

The principle purpose of this study was to investigate the gross morphology of the fascia lata in its relationships to underlying extensor muscles of the knee. By using a descriptive non-experimental study design with no manipulation of independent variables it was aimed at providing further anatomical data for future clinical and biomechanical studies. This study was further undertaken to find if textbook descriptions cover relationships between the fascia lata and underlying muscles in sufficient detail.

This question arose from observations during routine dissections of the thigh that did not seem to be documented in texts. It was also clear from studying existing literature on the fascia lata that there seemed to be a general paucity in available literature on the understanding of fascia within a mechanical musculoskeletal context in general. The undertaking of this study was therefore aimed at addressing both problems – the discrepancy in recorded fascia lata relationships as well as augmenting general fascial understanding.

The undertaking of an anatomical study of this nature, which included three modalities of investigation on living subjects as well as preserved cadaveric material, has inherent limitations. These included the high mean age at death of the cadaver specimens, secondary changes within examined tissues likely to have occurred due to the embalming process, the general lack of literature relating to the aims of the study, the limited literature



regarding the evaluation of fascia by Magnetic Resonance Imaging and Ultrasonography and even the familiarity of the studied structure.

Overall, results showed that the relationships between the fascia lata and its underlying muscles are more complex than currently described in anatomical textbooks and scientific papers. This was clearly evident in the detailed layered dissections of the six preserved cadaver legs in this study (chapter 4). The dominant feature of these dissections was the two distinct relationships the fascia lata had to underlying thigh muscles not fully recorded in literature.

During incision and reflection of the fascia lata from the underlying anterior muscles of the thigh, **loose** muscle/fascia relationships where the fascia lata was a separate fascial layer, and **close** muscle/fascia relationships where the fascia lata acted as a muscle epimysium could be observed in all dissected specimens. In all the specimens the same pattern could be observed with only the vastus medialis muscle showing variations between specimens. This variation was however only in the extent of the loose and close relationship surface areas.

In all specimens the rectus femoris and vastus lateralis muscles had a loose relationship between fascia and muscle over its entire outer surface. The tensor fasciae latae muscle had a strong close relationship in all specimens dissected. The sartorius and vastus medialis muscles both had mixed loose and close relationships. The sartorius muscle showed a close relationship in its proximal third with the middle third being a transition area with variations between specimens, and in the distal third a loose relationship prevailed. For the vastus medialis muscle, the area of the muscle bordering on the rectus



femoris muscle showed a loose relationship of varying width while further medially, and bordering on the sartorius muscle, a close relationship was observed in all specimens.

The detailed dissection study was expanded to correlate the dissection findings above with an axial dissection, Magnetic Resonance Imaging and Ultrasonography. Correlation studies where dissection, Magnetic Resonance Imaging and Ultrasonography views of anatomical structures are compared are an accepted method to establish clarity between the three investigation modalities (Starok et al, 1997; Muhle et al, 1999; Koulouris and Connell, 2005; Abu-Hijleh et al, 2006; Fairclough et al, 2006; Barker et al, 2009). Studies reported in the literature however, only comment on the actual structure studied, its position and similarities or differences. Further comments normally focus on differences and changes to the structure under investigation in the presence of pathology (e.g. Muhle et al, 1999).

The clarity with which structures seen on dissection specimens and duplicated in Magnetic Resonance Imaging and Ultrasonography views of living volunteers was well appreciated in this study. The textbook description of a sleeve of fascia surrounding the thigh muscles, thick and well developed laterally and thin medially (Hollinshead, 1969; Standring, 2008) was clearly observed on both the Magnetic Resonance Imaging and Ultrasound images in this study.

Similarly, positions and dimensions of underlying muscles, vessels and nerves could also be visualised clearly. This feature has the advantage that every image represented what the morphology of the studied person's anatomy of a region represented at that point in time. This is an important feature as it is known that all anatomical structures have several variants of normal and undergo changes with time within the broad population (Bramble



and Lieberman, 2004). Conversely, a textbook image and description presents a view of the average, most likely anatomical arrangement of an area or structure. To this end, studying gross anatomy with the inclusion and aid of Magnetic Resonance Imaging and Ultrasonography for comparison proves invaluable for the clinician – both surgeon and therapist.

A feature of the observations from both the detailed layered dissections reported in chapter 4, and the cross cut dissections used for correlation in this chapter 5, was the definition of close relationships between the fascia lata and the underlying muscles, by the passing of fascial septa from the deep surface of the fascia lata between muscle fascicles seen in some muscles, and areas of loose relationships between fascia and muscle in others in the same compartment.

During dissection of preserved cadaver material, these features (close and loose relationships) can readily be observed during careful removal of fascia from underlying muscles (Romanes, 1986; Kieser and Allen, 2001). This is also a trait encountered by surgeons during surgery where removal of fascia from underlying muscle has to be done by either sharp dissection in cases of close relationship (e.g. removal of the deep fascia over pectoralis major by sharp dissection during modified radical mastectomies) or blunt dissection in areas of loose relationship between fascia and muscle (e.g. harvesting fascia lata as donor tissue from the lateral aspect of the thigh).

During this study though, the areas of similarity or difference between close and loose fascia/muscle relationships could only be implied from the Magnetic Resonance and Ultrasound images. In dissection specimens, a loose relationship in a more adipose cadaver was more readily observed due to the clear identification of an intervening layer of



adipose tissue. On Magnetic Resonance and Ultrasound images, comments about the presence of a loose relationship could only be made if a layer of adipose tissue intervened between fascia and muscle. This could only be done if the person studied also had a high body mass index (BMI) with more adipose tissue stored between fascia and muscle.

In individuals with a lower BMI, adipose tissue between fascia and muscle could be very sparse or even absent, with only a thin layer of loose areolar tissue between fascia and muscle. This would then give the appearance of a close relationship between fascia and muscle on Magnetic Resonance and Ultrasound images where, in reality, a loose relationship may be in existence. Examples where a relationship judgement could not be made with certainty would be the Magnetic Resonance Imaging views of the tensor fasciae latae muscle at cross cut level **I**, the rectus femoris at cross cut level **II**, the vastus lateralis and vastus medialis muscles at cross cut level **III** (where detailed dissection views showed the rectus femoris and vastus lateralis muscles as clearly in a loose relationship to the fascia lata).

This phenomenon points out the limitations of using Magnetic Resonance Imaging or Ultrasonography alone in trying to understand relationships between structures (Starok et al, 1997; Koulouris and Connell, 2005). Under dynamic living conditions a loose functional arrangement may be present between a fascia and a muscle, but not identifiable on a Magnetic Resonance image. To this end, Ultrasound images may be of more value in showing a double layer of fascia/epimysium in areas of a loose relationship (Barker et al, 2009).

A study of the fascia lata as a structure and its relationships to underlying extensor muscles of the thigh using only Magnetic Resonance Imaging or Ultrasonography investigations,



would be a pointless exercise and of very little clinical value. Only when the findings of detailed dissection relationships are added to the study, can a clearer interpretation of Magnetic Resonance and Ultrasound images be reached.

On a Magnetic Resonance image, a distinction between a close relationship and loose relationship cannot be seen unless there is intervening adipose tissue between fascia and muscle, as observed at cross cut level **IV**, where the medial membranous layer, the thin anterior fascia lata and the lateral iliotibial band are well defined. Only when the Magnetic Resonance image of a structure correlated with a detailed dissection finding of the same area, was an interpretation of a relationship seen on Magnetic Resonance Imaging possible. This still meant that a close or loose relationship can only be implied. This was seen on the correlation of findings at level **III** where the loose relationship between fascia lata and the vastus lateralis muscle cannot be identified on the Magnetic Resonance image, while clearly shown on detailed and cross cut dissection observations at this level. Ultrasound images at this level more clearly duplicated what was observed in the dissections, but still could only be described as a true loose relationship after correlation with dissection observations.

At each level similarities between the three investigation modalities were found. Not all of them were clear enough to establish a norm. This can be ascribed to normal anatomical variants, quality of images, the limitations posed by the method of investigation and small sample size.



## 6.1 Principal findings

### 6.1.1 Literature

The fascia lata as a structure is well described in textbook literature on a morphological level. This makes it an easily recognisable anatomical entity during dissections and surgery. In the general scientific literature however, the fascia lata is very seldom the sole object of study. This is evident from our literature search where only two papers were identified relating to studying the fascia lata as a structure – Gerlach and Lierse (1990) and Stecco et al (2009b). All other literature described studies on **parts** of the fascia lata – the iliotibial band (Fairclough et al, 2006), the anterior layers of the patella (Dye et al, 2003) or aspects of the distal quadriceps muscles (Lieb and Perry, 1968; Dye et al, 2003; Andrikoula et al, 2006; Toumi et al, 2007; Becker et al, 2010). Even the review on fascia by Benjamin (2009) only concentrates on the iliotibial band in its section on the fascia lata.

In surgical literature, the fascia lata is described as a highly useful and abundant source for connective tissue utilised for a variety of purposes by surgical disciplines. The area of harvest consistently described is the anterolateral surface of the thigh, above the patella, where the fascia is better developed and stronger due to its fibre alignment being more longitudinal. Donor fascia is routinely lifted by methods using blunt dissection techniques (Amir et al, 2000).

Although the fascia lata is commonly described as a tough, circumferential structure that contains the musculature in tight compartments (Gerlach and Lierse, 1990; Standring, 2008) only Aspden (1990) described it in its role as a contributor to force generation by limiting outward expansion of contracting muscles. Jones (1944) described it as an ectoskeleton for the limb, serving as additional areas of attachment to muscles to ensure



maximal work efficiency for bipedal gait (Jones, 1944; Rosse and Gaddum-Rosse, 1997; Stecco et al, 2006; Standring, 2008). Overall, there seems to be general agreement between textbook descriptions of the fascia lata morphology and other literature studied.

In searching for general fascial relationships to underlying muscles, literature is limited. Anatomy and surgical textbooks describe the relationship between the fascia lata and underlying gluteus maximus and tensor fasciae latae muscles in detail, with septa passing from the deep surface of the fascia between muscle fascicles – a close relationship between fascia and muscle (Jones, 1944; Hollinshead, 1969; Tobias and Arnold, 1977). Further close relationships are described for vastus lateralis, vastus intermedius and the short head of biceps femoris to the lateral intermuscular septum and vastus medialis to the medial intermuscular septum. Additional literature on fascia and muscle relationships seem to be largely restricted to work published by the Stecco group.

General textbook literature largely limits fascia to its regional descriptions and the structures it is related to. It further describes the histology, classification and structure of fascia in general, but gives limited attention to its many and diverse functions. Functions range from supplying additional muscle attachments, creating compartments for muscles, encouraging venous return in the lower limb, dissipating stress concentration at tendon attachments to bone and acting as a protective sheet for underlying structures (Benjamin, 2009). Additional roles relating to fascial continuity, force generation (Garfin et al, 1981; Aspden, 1990), force transmission (Huijing, 2009) and its key role in coordinating muscular activity by acting as a body-wide proprioceptive organ (Langevin, 2006) are, however, not commonly covered in textbooks. This remains the subjects for papers published in journal literature. In all the literature studied, these functional aspects are discussed as general principles and none of it relates specifically to the fascia lata.



### **6.1.2 Detailed dissection study (chapter 4)**

It would appear that the literature does not fully represent what was observed during detailed reflection of the fascia lata from the extensor muscles of the thigh. Two perspectives became evident in the detailed dissections of the thigh (chapter 4) - areas of agreement between dissection observations and the literature studied and areas of limited or no agreement.

Areas of agreement between dissection observations and literature descriptions discussed the close relationship between the tensor fasciae latae muscle and fascia lata, the prominent lateral aspect of the fascia lata – the iliotibial band, the delicate thinness of the medial fascia lata, and the close relationships between muscles and the lateral and medial intermuscular septa. Dissection observations that were not documented in the studied literature were the close relationships between muscle and fascia in the upper third of the sartorius muscle and a looser relationship in its lower third, the doubled fascia lata housing peripheral nerves and vessels in the upper anterior thigh, the prominent collection of adipose tissue over the upper third of the rectus femoris muscle, and the close relationship between the fascia lata and the vastus medialis muscle found in all the dissections.

Secondary to the main purpose of the study, the finding of prominent membranous layers within the superficial fascia needs mention. Similar to descriptions of deep fascial relationships in this study, documentation and descriptions of the presence of membranous layers (stratum membranosum) within the superficial fascia of the thigh is limited.

Membranous layers are classically described as confined to the lower anterior abdominal wall and perineum where they are referred to as Scarpa's and Colles' fasciae respectively (Abu-Hijleh et al, 2006). Similar to the dissection and Ultrasonography findings of Abu-



Hijleh et al, these layers were encountered in all our detailed and the cross-cut dissections. Axial Magnetic Resonance Imaging and Ultrasonography studies (chapter 5) confirmed their presence, but with variations as to the number of layers and distribution of layers in the distal third of the thigh.

### **6.1.3 Correlation study between dissection, Magnetic Resonance Imaging and Ultrasonography (chapter 5)**

Matching features from views of the fascia lata correlated between the three chosen modalities of cross cut dissection, axial Magnetic Resonance Imaging and transverse Ultrasonography. Corresponding and matching features were present at all four of the studied levels (levels I to IV). Matching characteristics included the membranous layers within the superficial fascia, the double layer of deep fascia in the upper anterior thigh, the loose relationships between the fascia lata and rectus femoris and vastus lateralis muscles as well as the observations of close relationships between deep fascia and tensor fasciae latae and vastus medialis muscles.

Although comparable features were present on images for most of the levels studied, a final conclusion about observed close and loose relationships between the fascia lata and adjacent muscles could not readily be made without certain assumptions. On Magnetic Resonance images, a loose relationship between muscle and fascia could only be assumed with certainty when a visible layer of adipose tissue intervened between fascia and muscle. With only a thin layer of loose areolar connective tissue present between fascia and muscle(as seen in some of the dissections of less obese specimens), seeing them as separate structures on Magnetic Resonance Imaging was not possible and unreliable. On Ultrasound images, the distinctions between single or double fascial arrangements were



clearer. Although this observation compared well with cross cut dissection images, the interpretation on whether a loose or close relationship existed between fascia and muscle could not be made confidently without the corresponding detailed dissection of the same area.

## **6.2 Comparison with findings in related studies**

Only two studies were identified that focused on the fascia lata as research topic. Gerlach and Lierse (1990) dissected one thigh to create a three-dimensional model of the fascia sleeve of the lower limb, while Stecco et al (2009b) dissected six legs. The purpose of the latter study was to clarify macroscopic, microscopic differences and regional specialisations between the pectoral and femoral fasciae. They further commented on the fascia lata as “easily separable from all the muscles of the thigh”. This “ease of separation” was also the impression gained from surgical literature.

In our study sample (six preserved cadaver thighs dissected in detail), the entire fascia lata could not be reflected from the underlying muscles with the ease described by Stecco et al (2009b). Furthermore, their study used fresh cadavers before being frozen compared to our study using embalmed cadavers only. A final judgement towards the ease of removal found in their study compared to the difficulty of removal in some parts in this study can therefore not be made for the entire fascia lata. It would however, be a consideration to include the use of fresh cadavers in future fascial studies should an opportunity arise.

In the remaining 12 studies identified in the literature, the primary focus was one or other specific part of the extensor mechanism. The fascia lata was only mentioned in passing while preparing the area for specific observations. Furthermore, only the distal part of the quadriceps and its attachments, or the fibre angle and orientation of the muscle itself were



studied. In these studies, methods of fascial removal was either not recorded (7 studies), removed by blunt dissection (1 study), “dissected free” (2 studies) or a combination of blunt and sharp dissection (2 studies). In this study, the entire fascia lata was reflected from the anterior thigh (from iliac crest to patella) with the specific aim of identifying where and to what extent relationships between areas of loose or close fascia to muscle could be observed. We encountered specific areas of loose relationship where blunt dissection was the method of reflection (rectus femoris, vastus lateralis) as well as areas of close relationships where sharp dissections needed to be employed for reflecting the fascia (tensor fasciae latae, upper sartorius, vastus medialis). Again, no comparison could be drawn between these identified studies and the present study due to entirely different study objectives. All the identified studies concentrated on soft tissue elements of the extensor mechanism of the knee while this study had the fascia lata and its relationships as study objective.

In the radiological literature no studies using dissection, Magnetic Resonance Imaging and Ultrasonography were found commenting on fascial relationships. Only a number of selected papers were therefore used for guidance to interpret the observations of the present fascia lata study. These studies generally viewed comparisons between dissection findings, Magnetic Resonance Imaging and Ultrasonography as corresponding reliably. There were however limitations to both diagnostic methods. Magnetic Resonance images may present incomplete visualization of some anatomic components using routine acquisitions, while Ultrasonography had limitations in illustrating deep ligament structures as discrete structures. Although there were no studies identified relating to our study of fascial relationships, the same inherent limitations in clearly visualising fascial relationships and interpreting findings objectively were present.



Harvesting of the fascia lata as donor tissue in reconstructive surgery could likewise not be matched for the needs of this study. Fascia lata harvesting is routinely done in the anterolateral part of the thigh. This is always described as easily stripping the fascia from underlying muscle by blunt dissection, due to an intervening layer of loose areolar connective tissue between fascia and muscle. This description of fascial relationships in the anterolateral aspect of the thigh found in surgical literature matched the loose relationships relating to the rectus femoris and vastus lateralis muscles we encountered in our detailed dissection study.

As there was a general paucity on literature relating to the present study, the principle findings of this study could therefore not be compared with related studies. The Gelach and Lierse (1990) and Stecco et al (2009b) studies had different study aims, the general quadriceps studies excluded the fascia lata from their observations, in the radiological literature there are no fascial relationship studies and the reconstructive surgical literature only comments on the anterolateral thigh.

### **6.3 Interpretation of findings**

Interpreting findings of a study on gross morphology of a structure, based on observations during dissections and correlation between three modalities, is never going to be easy. Descriptions of the fascia lata have existed since the beginning of anatomical records. However, the importance of this study lies in observations that are not well documented in literature. The findings of this study has to be seen as supplementary to general fascial awareness as well as the wider functional roles ascribed to fascia in musculoskeletal dynamics.



### **6.3.1 Detailed dissection study (chapter 4)**

From this study, it was clear that detailed dissection observations and textbook descriptions do not fully match. This could be due to “dissection thinking” (Van der Wal, 2009), modern teaching methods (Percac and McArdle, 1997), or purely that biomechanical models for musculoskeletal function tend to exclude fascia.

A full interpretation of different relationships observed between fascia and muscle within a compartment, can only be done within the context of wider functional roles played by fascia within the body. These would include strategic mechanical (Purslow, 2002) and coordinating roles (Stecco, 2004) played in musculoskeletal function and the phenomenon of epimuscular force transmission (Huijing, 2009) within a fascial ectoskeleton (Jones, 1944). Within a coordinated, energy conserving and specialised lower limb (Bramble and Lieberman, 2004), the individual findings of this study each take on a new meaning. These concepts, its interpretation and relevance are elaborated on in section 6.4 of this discussion.

#### **The double fascia lata in the upper anterior part of the thigh**

This well defined fascial tunnel encloses the proximal parts of the anterior branches of the lateral cutaneous nerve of the thigh. These nerves were embedded in and protected by fibrofatty connective tissue to facilitate friction-free sliding during hip movements. From a functional point of view these nerves would be subjected to prolonged friction during periods of extended endurance running as a specialised hunter as proposed by Bramble and Lieberman (2004). Enclosing them within a fascial compartment could therefore be interpreted as the fascia lata functioning to protect peripheral nerves and vessels.



### **The rectus femoris fat pad**

This well defined adipose layer was present in the upper third of all our dissected legs between the fascia lata and the rectus femoris muscle epimysium. Adipose tissue fills potential spaces, acting as shock absorber or reducing friction. The presence of this well developed fat pad, anterior to the upper rectus femoris muscle, can be interpreted as a mechanism to facilitate non-abrasive hip extension and maintain stride length during prolonged walking and running.

### **The loose relationships between fascia and the rectus femoris and vastus lateralis muscles**

In all our detailed dissections, the fascia lata was separated from the underlying rectus femoris and vastus lateralis muscles by a virtually uninterrupted plane of sliding created by the presence of loose areolar connective tissue, containing varying amounts of adipose tissue, between the fascia lata and the muscle bellies. This can also be seen as a means of reducing friction or resistance during quadriceps activity. Due to the angle at which these two muscles act on the patella, they transfer the largest part of their power to the patellar tendon for knee extension. This arrangement may therefore be interpreted as a mechanism to reduce the dissipation of forces created by epimuscular force transmission, in order to concentrate the generated muscle power available for knee extension.

### **The close tensor fasciae latae muscle relationship to the fascia lata**

The tensor fasciae latae muscle has been labelled with several functions over the years. These ranged from Vesalius in 1552 grouping the tensor fasciae latae muscle with other muscles of the tibia and calling it the “sixth muscle of the tibia” (quoted in Kaplan, 1958) to its latest description as a synergistic supporter of the femur on the tibia when standing



(Moore & Dalley, 2006) because of its strong association with the iliotibial band. This muscle has further been described as an extensor, abductor, flexor and/or rotator of the thigh (Kaplan, 1958). Some textbooks additionally include the roles of knee stabiliser, extensor and even weak knee flexor to its roles (Romanes, 1986; Standring, 2008). Its strong association with the iliotibial band may have led early anatomists like Albinus (1734) and Douglas (1777) quoted in Kaplan (1958) to describe its function as a real tensor of the fascia lata, causing compression of the muscles contained within the fascia, thus providing stability to these muscles and “mightily” strengthening their actions by “keeping them tight in their places”.

Within the context of raising compartment pressure and the influence this has on improving power output, as described in the studies of Mozan and Keagy (1969) Garfin et al (1981) Aspden (1990) Hukins et al (1990), Westneat et al (1998) and Purslow (2002), the tensor fasciae latae muscle’s relationship to the lateral fascia lata and iliotibial band can be seen as a “producer of compartment pressure”. Even a small increase in pressure created by pressurization from neighbouring muscles or tightening of the fascial compartment, raises the contractile efficiency of all the members of the quadriceps group. Taken together with friction reduction between fascia and muscle described above and several morphological changes to the human lower limb, described by Bramble and Lieberman (2004) to promote endurance running, the role of the tensor fasciae latae muscle can therefore be seen as contributing to energy efficient muscle activity during locomotion.

### **The close relationship between the fascia lata and vastus medialis muscle**

The close relationship between the vastus medialis muscle and fascia lata was present in varying degrees in all our dissections. This finding was the main difference we observed



between detailed dissection observations and literature descriptions and therefore probably the most difficult to interpret.

For many years the vastus medialis muscle has been seen as playing an important role in knee mechanics and rehabilitation. This has however always been without considering the role played by the fascia lata in muscular mechanics. If we consider the fascia lata as a flexible ectoskeleton with muscles attached into it, the vastus medialis muscle may not be only a “controller of patellar tracking” (Lieb and Perry, 1968) and be responsible for the last 30 degrees of knee extension (Smillie, 1970) but play an additional role in maintaining the fascia at a basal tension (Stecco et al, 2007a; 2007b). Being closely related to the fascia lata, vastus medialis is in a position to transmit more of its force to epimuscular structures than the other heads of the quadriceps group that are in loose relationships to the fascia. By transmitting forces to the fascial skeleton, vastus medialis may be seen in a proprioceptive role within the extensor compartment as well as a coordinator of forces between hip and knee in the lower limb. In the last 30 degrees of knee extension one can observe the prominent bulging of the vastus medialis muscle that has been interpreted as controlling patellar tracking. Due to its close relationship with the fascia lata, the question arises that this may be used as another mechanism to increase basal tension and compressive forces within the extensor compartment. This would increase the power output of the quadriceps group as suggested by Aspden (1990) and Purslow (2002).

### **The dual relationship between the sartorius muscle and the fascia lata**

Interpreting the observations of fascial relationships in the sartorius muscle is as difficult as interpreting those in the vastus medialis muscle and can only be speculative. If the tensor fasciae latae and vastus medialis muscles play roles in creating a coordinated



compartment with the additional ability to increase compartment pressure by influencing basal fascial tension, then the close relationship between the fascia lata and upper third of the sartorius muscle may be interpreted in the same way. With the sartorius muscle becoming part of the pes anserinus complex attaching to the medial tibia by a broadened flat tendon, as well as originating in part from the upper fascia lata, one may speculate that it plays a role in force transfer into the crural fascia, thereby promoting a coordinated lower limb as a functional unit – it becomes part of a proprioceptive fascial chain between lower limb and iliac crest.

### **6.3.2 Dissection, Magnetic Resonance Imaging and Ultrasonography correlation**

From the correlation between dissection, Magnetic resonance imaging and Ultrasonography, the primary results showed promise yet with limitations to using these three modalities in correlating fascial relationships. Although all the features observed in detailed layered dissections could also be observed on axial views, they were not clearly visible on all the examined levels. Between modalities, the Ultrasonography views were better matched to the dissection findings than the Magnetic Resonance images.

Ultrasonography is fast gaining popularity in clinical practice due to advances in technology and cost effectiveness of equipment. It has greater potential than Magnetic Resonance Imaging to visualise superficial structures with the added advantages of speed, safety, the ability to examine dynamically and the ability to provide comparative examination of the contralateral limb.

## **6.4 Implication of the study**

The implications of the results from this study can be seen predominantly in two areas. Firstly, it adds to the specific knowledge base of a well known anatomical structure – the



fascia lata of the thigh. Unfortunately, descriptions in standard Anatomy textbooks consulted spanning the past 130 years (see 2.2.5 in literature review) have been shallow and hence the relevance of this study. Secondly, the results provide clinical implications towards treatment approaches for the lower limb as the extent of the functions of the fascia lata are undermined following harvesting or removal for the use in other surgical interventions (Amir et al, 2000; Ali et al, 2009). Practical understanding of the fascia lata is brought closer by using such a well known anatomical structure as subject in the wider field of fascial research. This study sought to gain further insight across disciplines involved in studying and treating the extensor mechanism of the knee.

#### **6.4.1 The wider knowledge base implications**

The understanding of fascia as a continuous, body-wide organ influencing musculoskeletal function is reasonably new in medicine and therapy (Findley and Schleip, 2007; Benjamin, 2009; Huijing et al, 2009). This study adds to the pool of information relevant to understanding fascial relationships to underlying muscles within functional compartments. This information needs to be used to update or at least further expand the present textbook representation of an important functional tissue – the deep fascia of the body. Adding the detailed dissection observations of the fascia lata to the general fascial roles identified in available literature, adds to the growing perspective of the body as a functional unit; where changes in one area may influence movement patterns or function in distant, sometimes even seemingly unrelated parts of the body (Stecco, 2004; Myers, 2009).

#### **6.4.2 Clinical implications**

Clinicians in the fields of musculoskeletal injury, surgery, repair and rehabilitation need to be aware of the deep fascia, its functions and relationships. An improved understanding of



the fascia lata as a structure relating to the underlying extensor muscles of the thigh as being more than just a mere “stocking” has several wider clinical implications.

### **The field of rehabilitation**

More misinformation (half truths) and subjective presentations may exist for knee muscle strengthening and patellar control than in nearly any other area of musculoskeletal rehabilitation. This may be due to an inadequate understanding relating to the complex nature of the patellofemoral joint and its impact on function. Since the 1950s, generations of clinicians have been saturated with the concept that knee rehabilitation requires an emphasis on vastus medialis obliquus strengthening (Malone, 2002). Several early observations on the subject of patellar and quadriceps function may have led to long lasting traditional misinterpretation.

Smillie (1962 quoted in Malone, 2002) published the view that the vastus medialis muscle was almost entirely responsible for the stabilisation and protection of the knee joint from injury. In their anatomic/mechanical analysis of the quadriceps, Lieb and Perry (1968) concluded that the early atrophy of the vastus medialis muscle was an indication of general quadriceps insufficiency rather than a local deficiency and that the only selective function of the medialis was patellar alignment. Again, the unfortunate interpretation of their work was that the last 10<sup>0</sup> to 15° of knee extension would therefore provide a selective training stimulus for the vastus medialis muscle – particularly the oblique fibres responsible for patellar alignment (Malone, 2002). Training single muscles is near impossible.

Furthermore, literature does not support the existence of isolated vastus medialis muscle exercises (Smith et al, 2009).



None of the studies reviewed included the fascia lata in discussing the knee extension mechanism. The classification of the different extensor muscles of the thigh is purely anatomical and has no functional meaning. The motor output and recruitment of muscles is extensive and coordinated for functional purposes in performing any given task. To specifically activate an isolated muscle during functional movement would override natural movement patterns. This would be impractical, next to impossible and potentially dangerous.

Viewing the above, together with the functional roles of fascia (strategic mechanical roles in force production, coordinating movement between muscles and muscle groups, myofascial force transmission) highlighted in the literature review (2.1.4), puts the fascia/muscle relationships described in this study into a different rehabilitation perspective. Approaching rehabilitation and strengthening of the lower limb in a fragmented way where individual parts are targeted at the expense of the complete unit - including fascial structures – may result in unsatisfactory treatment outcomes. Restoring the integrity of a structure (e.g. the fascia lata) before attempting to strengthen a muscle (e.g. the quadriceps) may be a paradigm shift needed in future rehabilitation programs.

### **The field of surgery**

A second clinical implication of this study is in the field of surgery. The value of the fascia lata as a donor tissue in reconstructive surgery means that the fascia lata is compromised by surgical techniques. Reduced donor limb function is usually ascribed to a weakening of the tensor fasciae latae muscle after fascia lata harvesting, resulting in reduced hip flexion and knee extension strength. Amir et al (2000) reported on a 22% to 45% reduction in measured quadriceps power after harvest of a large fascia lata sheath for



reconstructive repair. The weakened tensor fasciae latae muscle may not be the prime reason for reduced function. The importance of an intact fascial compartment in power output, the plane of sliding between the fascia lata and vastus lateralis muscle reducing friction and the fascia lata as a flexible ectoskeleton distributing and directing muscular forces discussed above, may be the prime reason for weakness. A surgeon needs to be aware of the functional roles fulfilled by an intact fascia lata in the lower limb and the careful repair of the donor site after harvesting.

Consideration in placement and repair of surgical incisions is also important in other fields of surgery. The new anterior approach to total hip replacement passes through the upper parts of the fascia lata and the fat pad covering the upper rectus femoris. Scarring and adhesions in these highly mobile tissue layers may adversely influence rehabilitation and affect the final functional outcome of an otherwise fully successful surgical procedure. The same is true, for example, in total knee replacements, fracture repair or even the placement of drains that pass through sliding tissue layers and possibly form adhesions and tethering between fascia lata and for example the vastus lateralis muscle.

### **The field of sports performance**

A third area of clinical application of knowledge of the roles played by the fascia lata is in the controversial field of sports performance enhancement. Using engineering for performance enhancement in the competitive sports arena is not new. The principles of improved power output in tight, intact fascial compartments are used in several sports disciplines. The application and wearing of tight compression garments during sporting activities mimics the role of the deep fascia in raising compartment pressure in order to produce increased power output of a muscle group. Runners, cyclists, rugby players and



swimmers have all been using compression garments for improved performance, for example the new Speedo compression swimsuit used at the Beijing Olympic Games in 2008. Users and manufacturers of these garments report faster recovery after participation, better venous return, improved endurance and better power production to mention but a few benefits.



## 7 CONCLUSION

*“It is by Anatomy alone, that we know the true nature, and therefore the most proper cure of the greatest number of local diseases.”* William Hunter (Moore, 2005).

From this study we have to conclude that the fascia lata as a structure is not fully presented in anatomy literature. It is more than a “stocking” and should therefore be viewed as an important mechanical component of a functional lower limb. By acting as extra surfaces for wider muscle attachments, it fits the role of a flexible skeleton (ectoskeleton) distributing and directing muscular forces within the lower limb. An intact fascia lata can also be seen as crucial for power production of the important quadriceps muscle group. More efficient power production ability is an important component of energy saving mechanisms during locomotion.

Interpreting fascial relationships only from Magnetic Resonance and Ultrasonography images cannot be made without the correlation of a detailed dissection of the same area and structure as a guideline. When comparing views from crosscut dissections, Magnetic Resonance Imaging and Ultrasonography, observed features could be matched between cadaver dissections and living volunteers. Images are however not self-explanatory, they need interpretation. The quality of images is improving with more details visible.

Ultrasonography is however a modality that is user-specific and the experience of the practitioner needs to be considered in judging the final observation as reliable. Improving interpretation reliability becomes the value of such correlation studies in anatomy.



The fascia lata is not always in a uniform “stocking” relationship to the underlying muscle and so the literature does not fully reflect the observed relationships. Most Magnetic Resonance Imaging and Ultrasonography of living subjects did match the detailed cadaver dissection observations although some interpretations were still unreliable.

Further detailed dissection studies and use of Magnetic Resonance Imaging and Ultrasonography are necessary and important. Findings should be put into clinical and functional context more often. This will include surgical, trauma and rehabilitation fields where these observations need to be taken into consideration during treatment and rehabilitation.

## **7.1 Recommendations for future research**

The most obvious recommendation for future research is for more detailed dissections of fascial relationships to associated muscles for other parts of the body. Not only one anatomical area such as the thoracolumbar fascia, the plantar fascia or the fascia lata should be investigated, but the final objective should be a full “fascial relations” map of the body.

Due to tissue changes that are part of the embalming process to preserve a body, it would also be recommended that this study also be done using fresh cadavers. This would also be the ideal for all future fascial studies.

The present findings leave many areas open for assumptions in order to reliably interpret all aspects of the correlation between investigative modalities. These modalities should be included into future fascial research in order to improve clinical and diagnostic reasoning.



## 8 REFERENCES

- Abu-Hijleh M F, Roshier A L, Al-Shboul Q, Dharap A S, Harris P F. (2006). The membranous layer of the superficial fascia: evidence for a widespread distribution in the body. *Surg Radiol Anat*; 28:606-619 DOI 10.1007/s00276-006-0142-8
- Ali R S, Bluebond-Langner R, Rodriguez E D, Cheng M-H. (2009). The versatility of the anterolateral thigh flap. *Plast Reconstr Surg*; 124(6Suppl):e395-407  
doi:101097/PRS.0b013e3181bcf05c
- Amir A, Gur E, Gatot A, Zucker G, Cohen J T, Fliss D M. (2000). Fascia lata sheaths harvest revisited. *Oper Techn Otolaryng*; 11(4):304-306 doi:10.1053/otot.2000.20980
- Andrikoula S, Tokis A, Vasiliadis H S, Georgoulis A. (2006). The extensor mechanism of the knee joint: an anatomical study. *Knee Surg Sports Traumatol Arthrosc*; 14:214-220  
doi:10.1007/s00167-005-0680-3
- Aspden R M. (1990). Constraining the lateral dimensions of uniaxially loaded materials increases the calculated strength and stiffness: application to muscle and bone. *J Materials Science: Materials in Medicine*; 1:100-104
- Barker R P, Lee J C, Healy J C. (2009). Normal sonographic anatomy of the posterolateral corner of the knee. *AJR*; 192: 73-79 DOI: 10.2214/AJR.07.3743
- Becker I, Woodley S J, Baxter G D. (2009). Gross morphology of the vastus lateralis muscle: An anatomical review. *Clin Anat*;22:436-450 DOI 10.1002/ca.20792
- Becker I, Baxter G D, Woodley S J. (2010). The vastus lateralis muscle: An anatomical investigation. *Clin Anat*;23:575-585 DOI 10.1002/ca.20974



- Benjamin M. (2009). The fascia of the limbs and back – a review. *J Anat*;214:1-18.  
Doi:10.1111/j.1469.2008.01011.x
- Blazevich A J, Gill N D, Zhou S. (2006). Intra-and intermuscular variations in human quadriceps femoris architecture assessed *in vivo*. *J Anat*; 209:289-310
- Bramble D M, Lieberman D E, (2004). Endurance running and the evolution of *Homo*. *Nature*;432: 345-352
- Carrier D R. (1984). The energetic paradox of human running and hominid evolution. *Curr Anthropol*; 25 (4):483-495
- Connell D A, Schneider-Kolsky M E, Hoving J L, Malara F, Buchbinder R, Koulouris G, Burke F, Bass C. (2004). Longitudinal study comparing sonographic and MRI assessments of acute and healing hamstring injuries. *AJR*; 183:975-984
- Cunningham D J, (1896). Manual of practical anatomy. Second edition. Volume first. Upper limb; lower limb; abdomen. Young J Pentland, Edinburgh
- Dupont A C, Sauerbrei E E, De Clercq D, De Meester K, Van Elsacker L. (2001). Real-time sonography to estimate muscle thickness: comparison with MRI and CT. *J Clin Ultrasound*; 29:230-236
- Dye S F, Campagna-Pinto D, Dye C C, Shifflett S, Eiman T, (2003). Soft-tissue anatomy anterior to the human patella. *J Bone Jnt Surg*; 85A(6): 1012-1017
- Fairclough J, Hayashi K, Toumi H, Lyons K, Bydder G, Phillips N, Best T M, Benjamin M, (2006). The functional anatomy of the iliotibial band during flexion and extension of the knee: implications for understanding iliotibial band syndrome. *J Anat*; 208: 309-316



Findley T W, Schleip R (eds), (2007). Fascia research. . Basic science and implications for conventional and complementary health care. Urban & Fischer, München

Garfin S R, Tipton C M, Mubarak S J, Woo S L-Y, Hargens A R, Akeson W H, (1981). Role of fascia in maintenance of muscle tension and pressure. J Appl Physiol.:Respirat Environ Exercise Physiol; 51(2): 317-320

Gerlach U J, Lierse W, (1990). Functional construction of the superficial and deep fascia system of the lower limb in man. Acta Anat;139: 11-25

Girish G, Finlay K, Landry D, O'Neill J, Popowich T, Jacobson J, Friedman L, Jurriaans E, (2007). Musculoskeletal disorders of the lower limb – Ultrasound and Magnetic Resonance Imaging correlation. Can Assoc Radiol J; 58(3): 152-166

Goss C M, (1949). (Ed.) Anatomy of the Human Body by Henry Gray. Twenty-fifth Edition. Lea & Febiger, Philadelphia

Hollinshead W H, (1969). Anatomy for surgeons: Volume 3. The back and limbs. Second edition. Harper & Row, Publishers, New York

Huang C-C, Ko S-F, Ko J-Y, Huang H-Y, Ng S-H, Wan Y-L, Chen M-C, Cheng Y-f, Lee T-Y. (2005). Contracture of the deltoid muscle: sonographic evaluation with MRI correlation. AJR; 185:364-370

Hubbard J K, Sampson H W, Elledge J R. (1998). The vastus medialis oblique muscle and its relationship to patellofemoral joint deterioration in human cadavers. J Orthop Sports Phys Ther; 28:384-391



Huijing P A, (2009). Epimuscular myofascial force transmission: a historical review and implications for new research. International society of biomechanics Muybridge award lecture, Taipei, 2007. J Biomech; 42: 9-21 DOI: 10.1016/j.jbiomech.2008.09.027

Huijing P A, Baan G C, (2001). Myofascial force transmission causes interaction between adjacent muscles and connective tissue: effects of blunt dissection and compartment fasciotomy on length force characteristics of rat extensor digitorum longus muscle. Arch Physiol Biochem; 109(2): 97-109

Huijing P A, Baan G C, (2008). Myofascial force transmission via axtramuscular pathways occurs between antagonistic muscles. Cells Tissues Organs; 188: 400-414  
DOI:10.1159/000118097

Huijing P A, Hollander P, Findley T W, Schleip, (eds), (2009). Fascia research II. Basic science and implications for conventional and complementary health care. Urban & Fischer, München

Hukins D W L, Aspden R M, Hickey D S, (1990). Thoracolumbar fascia can increase efficiency of the erector spinae muscles. Clin Biomech; 5: 30-34

Jacobson J A, (2009). Musculoskeletal ultrasound: focused impact on MRI. AJR; 193: 619-627 DOI: 10.2214/AJR09.2841

Jones F W, (1920). The principles of anatomy as seen in the hand. J & A Churchill, London

Jones F W, (1944). Structure and function as seen in the foot. The Williams & Wilkins Company, Baltimore



- Jones F W, (1946). (Ed.) Buchanan's Manual of Anatomy. Seventh Edition. Bailliere, Tindall and Cox. London
- Jungqueira L C, Carneiro J, (2003). Basic Histology. Text and Atlas. Tenth edition. Lange Medical Books McGraw-Hill, New York
- Kaplan E B, (1958). The iliotibial tract. J Bone Jnt Surg; 40A(4): 817-832
- Kieser J, Allan J, (2001). Practical anatomy. The human body dissected. Witwatersrand University Press, Johannesburg
- Koulouris G, Connell D. (2005). Hamstring muscle complex: an imaging review. RadioGraphics; 25:571-586
- Langevin H M, (2006). Connective tissue: a body-wide signalling network? Med Hypoth; 66: 1074-1077 DOI: 10.1016/j.mehy.2005.12.o32
- Lieb F J, Perry J. (1968). Quadriceps function. An anatomical and mechanical study using amputated limbs. J Bone Jnt Surg; 50-A (8):1535-1547
- Lindsay M, (2008). Fascia. Clinical Applications for Health and Human Performance. Delmar Cengage Learning, Australia
- Malone T, Davies G, Walsh W M. (2002). Muscular control of the patella. Clin Sports Med 21: 349-362
- Moore K L, Dalley A F, (2006). Clinically orientated anatomy. Fifth edition. Lippincott Williams & Wilkins, Philadelphia
- Moore W, (2005). The Knife Man. The Extraordinary Life and Times of John Hunter, Father of Modern Surgery. Bantam Press, London



Moza L C, Keagy R D, (1969). Muscle relationships in functional fascia. A preliminary study. Clin Orthop Rel Res;67:225-230

Muhle C, Ahn J M, Yeh L, Bergman G A, Boutin R D, Schweitzer M, Jacobson J A, Haghighi P, Trudell D J, Resnick D, (1999). Iliotibial band friction syndrome: MR Imaging findings in 16 patients and MR arthrographic study of six cadaveric knees. Radiology; 212:103-110

Myers T W, (2009). Anatomy Trains (second edition). Churchill Livingstone, Edinburgh

Nazarian L N, (2008). The top 10 reasons musculoskeletal sonography is an important complementary or alternative technique to MRI. AJR; 190: 1621-1626  
DOI:10.2214/AJR.07.3385

Newell R L M. (1995). Follow the royal road: the case for dissection. Clin Anat; 8:124-127

Nozic M, Mitchell J, de Klerk D. (1997). A comparison of the proximal and distal parts of the vastus medialis muscle. Aust J Physiother; 43:277-281

Owen E, (1890). A manual of anatomy for senior students. Longmans, Green and Co. London

Palastanga N, Field D, Soames R. (2002). Anatomy and Human Movement: Structure and function. Fourth Edition. Butterworth Heinemann. Edinburgh

Peeler J, Cooper J, Porter M M, Thliveris J A, Anderson J E. (2005). Structural parameters of the vastus medialis muscle. Clin Anat; 18:281-289 doi:10.1002/ca.20110



Percac S, McArdle P J. (1997). Anatomy teaching: students' perceptions. *Surg Radiol Anat*; 19:315-317

Porter R, (2002). *Blood and Guts. A short history of medicine.* Penguin Books

Purslow P P. (2002). The structure and functional significance of variations in the connective tissue within muscle. *Comp Biochem Physiol Part A*; 133: 947-966

Reider B, Marshall J L, Koslin B, Ring B, Girgis F G. (1981). The anterior aspect of the knee joint. An anatomical study. *J Bone Jnt Surg*; 63-A(3):351356

Romanes G J, (1981). (Ed.) *Cunningham's textbook of anatomy.* Twelfth edition. Oxford University Press, Oxford

Romanes G J, (1986). *Cunningham's manual of practical anatomy.* 15<sup>th</sup> edition. Volume one. Upper and lower limbs. Oxford University Press, Oxford

Rosse C, Gaddum-Rosse P, (1997). *Hollinshead's textbook of anatomy.* 5th edition. Lippencott-Raven, Philadelphia

Schleip R, Klingler W, Lehmann-Horn F, (2005). Active fascial contractility: Fascia may be able to contract in a smooth muscle-like manner and thereby influence musculoskeletal dynamics. *Med Hypoth*; 65: 273-277 DOI: 10.1016/j.mehy.2005.03.003

Schleip R, Naylor I L, Ursu D, Melzer W, Zorn A, Wilke H-J, Lehmann-Horn F, Klingler W, (2006). Passive muscle stiffness may be influenced by active contractility of intramuscular connective tissue. *Med Hypoth*; 66: 66-71 DOI: 10.1016/j.mehy.2005.08.025



Sharpey W, Thomson A, Schäfer E A, (1878). (eds.) Quin's elements of anatomy. Volume 1. Eighth edition. Longmans, Green, and Co., London

Skidmore J R. (1995). The case for prosection: comment on R L M Newell's paper. *Clin Anat*; 8:128-130

Smillie I S. (1970). *Injuries of the Knee Joint*. 3<sup>rd</sup> edition. Williams and Wilkins  
Baltimore

Smith T O, Nichols R, Harle D, Donell S T, (2009). Do the vastus medialis obliquus and vastus medialis longus really exist? A systemic review. *Clin Anat*;22: 183-199 DOI 10.1002/ca20737

Snyderman R K. (1977). Transplantation of fascia. In: Converse J M (Ed). *Reconstructive Plastic Surgery. Principles and procedures in correction, reconstruction and transplantation*. Volume one. General Principles (second edition). W B Saunders Company, Philadelphia

Sonin A H, Fitzgerald S W, Bresler M E, Kirsch M D, Hoff F L, Friedman H. (1995). MR Imaging appearance of the extensor mechanism of the knee: functional anatomy and injury patterns. *RadioGraphics*; 15(2):376-382

Standring S, (2008). (Ed.) *Gray's Anatomy. The anatomical basis of clinical practice*. 40<sup>th</sup> Edition. Churchill Livinstone, Elsevier

Starok M, Lenchik L, Trudell D, Resnick D, (1997). Normal patellar retinaculum: MR and sonographic imaging with cadaveric correlation. *AJR*;168: 1493-1499



Stecco A, Macchi V, Stecco C Porzionato A, Day J A, Delmas V, De Caro R. (2009a).

Anatomical study of myofascial continuity in the anterior region of the upper limb. J

Bodywork Mvt Ther; 13: 53-62 DOI: 10.1016/j.jbmt.2007.04.009

Stecco A, Macchi V, Masiero S, Porzionato A, Tiengo C, Stecco C, Delmas V, De Caro R.

(2009b). Pectoral and femoral fasciae: common aspects and regional specializations. Surg

Radiol Anat;31:35-42

Stecco C, Porzionato A, Macchi V, Tiengo C, Parenti A, Aldegheri R, Delmas V, De Caro,

R, (2006). A histological study of the deep fascia of the upper limb. Ital J Anat Embriol;

111(2): 105-110

Stecco C, Gagey O, Macchi V, Porzionato A, De Caro R, Aldegheri R, Delmas V, (2007a).

Tendinous muscular insertions onto the deep fascia of the upper limb. First part:

anatomical study. Morphologie; 91(292): 29-37 DOI:10.1016/j.morpho.2007.05.001

Stecco C, Gagey O, Belloni A, Pozzuoli A, Porzionato A, Macchi V, Aldegheri R, De Caro

R, Delmas V, (2007b). Anatomy of the deep fascia of the upper limb second part: study of

innervations. Morphologie; 91(292): 38-43 DOI:10.1016/j.morpho.2007.05.002

Stecco C, Porzionato A, Macchi V, Stecco A, Vigato E, Parenti A, Delmas V, Aldegheri R,

De Caro R, (2008). The expansions of the pectoral girdle muscles onto the brachial fascia:

Morphological aspects and spatial disposition. Cells Tissues Organs; 188: 320-329

DOI:10.1159/000121433

Stecco L, (2004). Fascial manipulation for musculoskeletal pain. Piccin Nuova Libreria

S.p.A., Padova



Stecco L, Stecco C. (2009). Fascial Manipulation. Practical Part. Piccin Nuova Libreria, Padova

Terry G C, (1989). The anatomy of the extensor mechanism. Clin Sports Med; 8(2): 163-177

Tobias P V, Arnold M, (1977). Man's anatomy. A study in dissection. III back and limbs. Witwatersrand University Press, Johannesburg

Toumi H, Poumarat G, Benjamin M, Best T M, F'Guyer S, Fairclough J. (2007). New insights into the function of the vastus medialis with clinical implications. Med Sci Sports Exerc; 39:1153-1159

Van Der Wal J. (2009). The architecture of the connective tissue in the musculoskeletal system – an often overlooked functional parameter as to proprioception in the locomotor apparatus. Int J Ther Mass Bodywork; 2(4):9-23

Weinstabl R, Scharf W, Firbas W. (1989). The extensor apparatus of the knee joint and its peripheral vasti: anatomical investigation and clinical relevance. Surg Radiol Anat; 11:17-22

Westneat M W, Hale M E, McHenry M J, Long J H, (1998). Mechanics of the fast-start: muscle function and the role of intramuscular pressure in the escape behaviour of *Amia calva* and *Polypterus palmas*. J Exp Biol; 201: 3041-3055

Wheater P R, Burkitt H G, Daniels V G. (1979). Functional Histology. Churchill Livingstone, Edinburgh