

M MED RESEARCH REPORT

THE SURGICAL  
MANAGEMENT OF ORBITAL  
FRACTURES: A CASE SERIES

DR B JUGADOE

DIVISION OF OPHTHALMOLOGY  
DEPARTMENT OF NEUROSCIENCES  
FACULTY OF HEALTH SCIENCES  
UNIVERSITY OF WITWATERSRAND  
OCTOBER 2012

# THE SURGICAL MANAGEMENT OF ORBITAL FRACTURES: A CASE SERIES

Bhavna Jugadoe

A research report submitted to the Faculty of Health Sciences, University of the Witwatersrand, Johannesburg, in partial fulfillment of the requirements for the degree of Master of Medicine in Ophthalmology.

Johannesburg 2012

## DECLARATION

I, Bhavna Jugadoe, declare that this research report is my own work. It is being submitted for the degree Master of Medicine (Ophthalmology) at the University of the Witwatersrand, Johannesburg. It has not previously been submitted for any degree or examination at this or any other university.

---

\_\_\_\_ day of \_\_\_\_\_ 2012

The research reported in this dissertation was carried out at St John Eye Hospital (The Eye Unit of the Chris Hani Baragwanath Hospital) and the Wits Donald Gordon Medical Center (The Academic Hospital of the University of the Witwatersrand Medical School), Johannesburg, South Africa.

To my dearest parents, Anirudth and Sharda Jugadoe

&

My loving husband, Leraj Lekha:

Thank you for all your support and encouragement through my career.

## **ETHICS APPROVAL**

This research project was approved by the Human Research Ethics Committee (Medical) at the University of the Witwatersrand.

Clearance Certificate Number: M081111

## **PRESENTATIONS ARISING FROM THIS STUDY**

The results of this study were presented at the national congress of the Ophthalmological Society of South Africa (OSSA) in Sun City, February 2010.

Title: The surgical management of orbital fractures: A case series.

Presenter: Dr B Jugadoe

## **ABSTRACT**

### **Purpose**

The purpose of this research was to evaluate the outcomes, specifically diplopia and enophthalmos, as well as the complications of surgical repair of orbital fractures using the transconjunctival surgical approach.

### **Methods**

A cross-sectional descriptive study was conducted. Thirty patients who underwent surgical repair of an orbital fracture were included in this case series. All patients were operated using the transconjunctival surgical approach and in all cases the fracture was repaired with 0.4 mm nylon foil sheeting (Supramid). The preoperative and postoperative clinical findings of visual acuity, diplopia and enophthalmos were analyzed, and postoperative complications were noted.

## **Results**

Twenty-five of 30 patients (83%) presented with diplopia preoperatively and two patients (7%) had persistent diplopia postoperatively. Enophthalmos of greater than 2mm was present in 16 of 30 patients (53%) preoperatively and five patients (17%) had persistent enophthalmos postoperatively. All patients with persistent postoperative diplopia and or enophthalmos underwent late surgical repair (mean 10.6 months). Ten patients (33%) in this series were repaired early, within three weeks of trauma, and had no diplopia or enophthalmos postoperatively. There were no cases of lower lid retraction or ectropion. There was one complication related to the nylon foil.

## **Conclusion**

The transconjunctival surgical approach used to repair orbital fractures was associated with good functional outcomes and few complications. Early surgical repair of orbital blowout fractures and the use of nylon foil sheeting are supported by this case series.



## ACKNOWLEDGEMENTS

Many thanks to:

Prof G McLaren (Supervisor)

Prof T Carmichael

Dr K Alberto

Patients at St John and WDGMC

# CONTENTS

	<b>PAGE</b>
DECLARATION	ii
DEDICATION	iii
ETHICS APPROVAL	iv
PRESENTATIONS ARISING FROM THIS STUDY	v
ABSTRACT	vi
ACKNOWLEDGEMENTS	viii
CONTENTS	ix
LIST OF FIGURES	x
LIST OF TABLES	xi
Chapter 1.0 INTRODUCTION	1
Chapter 2.0 LITERATURE REVIEW	4
Chapter 3.0 PATIENTS AND METHODS	9
Chapter 4.0 RESULTS	14
Chapter 5.0 DISCUSSION	20
Chapter 6.0 CONCLUSION	25
Chapter 7.0 REFERENCES	26

## LIST OF FIGURES

<b>Figure</b>	<b>Page</b>
1.1 Computerized tomography scan showing left orbital blowout fracture involving the floor and medial wall	1
3.1 Transconjunctival surgical approach used to expose orbital fracture	12
3.2 Schematic diagram showing repair of a two – wall orbital blowout fracture using wraparound implant technique	13
3.3 Nylon foil sheeting (Supramid)	13
4.1 Surgical complication: Lower lid retraction	19

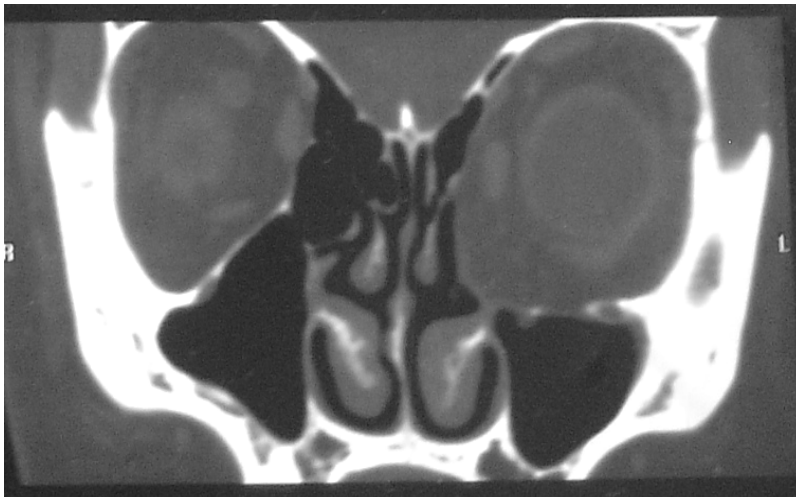## LIST OF TABLES

<b>Table</b>	<b>Page</b>
4.1 Demographic data	14
4.2 Diplopia and enophthalmos	15
4.3 Cases previously repaired using transcutaneous surgical approach	18
5.1 Cost comparison of implant materials	24

## 1.0 INTRODUCTION

Orbital fractures occur frequently as a result of blunt trauma usually from assaults, motor vehicle accidents, falls and sport injuries. <sup>1</sup>

Blowout fractures involving the orbital floor and or medial wall (Figure 1.1), orbitozygomatic fractures resulting from midfacial trauma and naso-orbito-ethmoid fractures are some commonly identified fracture patterns. <sup>1</sup>



**Figure 1.1** Computerized tomography scan showing left orbital blowout fracture involving the floor and medial wall.

As a result of associated ocular and midfacial injuries, orbital fractures are managed by ophthalmologists and oculoplastic surgeons, as well as maxillofacial surgeons. The surgical approach in each discipline, however, may differ.<sup>1</sup> Surgical approaches to the orbital floor and infraorbital rim can be broadly categorized as transconjunctival and transcutaneous (via a lower eyelid crease, subciliary or infraorbital rim incision).<sup>2,3</sup> Following the surgical incision, the successful repair of orbital fractures depend upon anatomical reduction of the fracture, adequate release of soft tissue entrapment and accurate restoration of orbital volume.<sup>3,4</sup>

Indications for the surgical repair of orbital floor fractures in adults are diplopia, enophthalmos and large fracture size.<sup>5</sup>

When repairing orbital fractures, the surgical technique used should provide adequate access and exposure necessary to accomplish the primary surgical repair as well as yield a low complication rate and provide a good functional and cosmetic result.<sup>6</sup> However, the timing of surgical repair and the choice of implant material may influence the outcomes of surgery. Persistent diplopia and enophthalmos are unfavourable outcomes following orbital fracture repair.

The purpose of this study is to report the outcomes and complication rate of surgical repair of orbital fractures by ophthalmic surgeons using the transconjunctival surgical approach and nylon foil sheeting (Supramid) in a case series of patients at St John Eye Hospital (St John) and Wits Donald Gordon Medical Center (WDGMC).

## 2.0 LITERATURE REVIEW

In 1979, Moses and McCord<sup>7</sup> demonstrated that the inferior fornix transconjunctival incision and lateral canthotomy provided adequate exposure of the orbital floor as well as the medial and lateral orbit, while still maintaining the integrity of the lower lid. While this approach has since then been advocated for the repair of orbital fractures, several studies have evaluated the outcomes and complications of surgery using the transconjunctival and transcutaneous surgical approaches.

Nunery and co-workers<sup>8</sup> evaluated a technique of nylon foil “wraparound” repair of combined floor and medial wall fractures in 98 patients (102 orbits) using the transconjunctival approach. All patients were operated within three weeks of trauma and followed-up for six months on average. Of 64 patients presenting with diplopia, none experienced diplopia postoperatively and one patient had persistent enophthalmos. In all cases there were no eyelid complications.



Hosal and Beatty<sup>9</sup> evaluated the incidence of residual diplopia and enophthalmos after surgical repair of blowout fractures in 42 patients with at least six months follow-up. Thirty-five patients experienced diplopia preoperatively and seven patients (17%) still had diplopia postoperatively. Thirteen patients had enophthalmos preoperatively and three patients (7%) had persistent enophthalmos. They found that early surgical repair within two weeks of trauma was associated with a reduced incidence of diplopia postoperatively. The surgical approach used was not described and different implant materials were used including porous implants (Medpor) and non-porous implants (Supramid).

Schmäl and co-workers<sup>10</sup> reported the outcomes after orbital fracture repair using the transconjunctival approach in 209 patients. Patients were repaired early within eight days on average and the complication rate was 2.4%. After a two year follow-up period, one patient had persistent enophthalmos and four patients had diplopia.

Biesman and co-workers<sup>11</sup> reported a 37% incidence of postoperative diplopia in the repair of orbital blowout fractures in 54 patients. The surgical technique used was not described and the timing of surgery was variable. However, the study suggested that patients with combined floor and medial wall fractures rather than those with floor fractures only were at increased risk of persistent diplopia postoperatively.

In a retrospective study of 51 patients Hawes and Dortzbach <sup>12</sup> found that postoperative diplopia and enophthalmos was influenced by timing of repair. They reported a 7% incidence of postoperative diplopia and enophthalmos when repaired early (within two months) and a significantly higher rate of persistent diplopia and enophthalmos (38% and 50% respectively) when repaired late.

Guy and co-workers <sup>13</sup> retrospectively compared the functional and cosmetic results of 50 patients with orbital floor fractures who underwent early surgical repair within two weeks of injury versus late repair. The surgical technique was not described in detail and a variety of implant materials were used including porous polyethylene (Medpor), lactasorb, bone and titanium mesh. They found no difference in surgical outcome between early and late repair.

The transconjunctival surgical approach has been associated with a lower incidence of eyelid complications including lower lid retraction, ectropion and lower lid malposition when compared to the transcutaneous surgical approach. <sup>6,8,14-17</sup> The lower rate of complications results from minimal disruption of the intraorbital connective tissue as well as the anatomical incision line. <sup>14</sup>

Westfall and co-workers<sup>18</sup> reviewed the operative complications of the transconjunctival inferior fornix approach in 1200 cases over eight years, identifying ten cases. Reported complications included eyelid laceration particularly when canthotomy was not performed, entropion, lower lid retraction or ectropion, lower lid haematoma and lacrimal sac injury.

Although much controversy surrounds the choice of implant material, alloplastic implants have almost replaced autogenous bone graft in the repair of orbital fractures.<sup>19</sup> The optimal implant should be associated with low rates of displacement and extrusion, haemorrhage and infection.<sup>9</sup> There are two broad categories of implant materials: non-porous and porous implants. Nylon foil (Supramid), silicone and polytetrafluoroethylene (Teflon) are nonporous implants, biologically inactive materials that provide structural support without promoting tissue ingrowth. This is thought to minimize the risk of cicatrization in extraocular muscles next to the implant resulting in a lower incidence of complications such as cicatricial eyelid retraction and restrictive diplopia.<sup>8,20</sup> On the other hand porous implants such as Medpor promote tissue ingrowth and integration of the implant.<sup>9,19</sup> Much like titanium implants, this may lead to fibrosis and cicatrization of orbital tissue and extraocular muscles next to the implant resulting in eyelid retraction or diplopia.<sup>8,20</sup>

In the study by Nunery <sup>8</sup> on the use of nylon foil in 98 patients, there were no implant-related complications such as displacement of the implant, haemorrhage or infection and there were no eyelid complications or postoperative diplopia.

In a larger case series of 181 patients, Park and coworkers <sup>19</sup> found that the use of smooth nylon foil implants resulted in the successful reconstruction of orbital fractures with a low complication rate of 1.7%. The transconjunctival surgical approach was used in almost all cases (98%), however all implants were secured with a titanium screw. Complications included an immediate postoperative retrobulbar haemorrhage in one patient and two patients developed late orbital infections.

In addition to the complication rate of surgery, the purpose of this study was to evaluate the incidence of postoperative diplopia and persistent enophthalmos after surgical repair of orbital fractures using the transconjunctival surgical approach and nylon foil implant in a case series of patients at St John Eye Hospital (St John) and Wits Donald Gordon Medical Center (WDGMC).

### 3.0 PATIENTS AND METHODS

A cross-sectional descriptive study was conducted. All patients who underwent surgical repair of an orbital fracture at St John over a two year period from 01 July 2007 to 30 June 2009, and all patients who underwent surgical repair of an orbital fracture at WDGMC up to 30 June 2009 were identified from the clinic records. Patients were contacted telephonically by myself and invited to participate in this case series i.e. attend a follow-up visit at the clinic where post-surgical follow-up data collection sheets were completed in order to allow for standardized data collection. Inclusion criteria were adult patients who underwent surgical repair of an orbital fracture with at least three months postoperative follow-up. Patients unable to attend a follow-up examination were excluded from the series. Thirty patients were included in this case series. Informed consent was obtained for the examination of patients for the purpose of this study.

Preoperative data that was reviewed included:

- mechanism of injury (assault with fist or foot, motor vehicle accident, sport injury, other)
- fracture pattern (blowout fracture- floor/ wall/ combined, orbitozygomatic)
- indication for surgery (diplopia, enophthalmos or risk for this, large fracture involving more than 50% orbital floor)
- timing of surgery (early repair within three weeks of trauma or late repair)
- associated ocular injuries

Postoperative follow-up examination findings that were reviewed included:

- visual acuity
- diplopia (in primary position, downgaze or no diplopia)
- enophthalmos  $> 2\text{mm}$  measured with a Hertel exophthalmometer
- lower eyelid complications such as lower lid retraction (as evidenced by increased vertical fissure height with lower lid retracted from normal position at the limbus), ectropion and canthal malposition
- other complications

The intraoperative fracture findings, surgical procedure and any intraoperative complications were noted.

#### Outcome measures

1. Diplopia present in primary position or downgaze/ no diplopia.
2. Enophthalmos  $> 2\text{mm}$  using Hertel exophthalmometer.
3. Lower eyelid complications such as lower lid retraction, ectropion and canthal malposition.
4. Other complications such as injury to the globe, conjunctiva, cannalicular and lacrimal sac injury resulting from the surgical procedure.

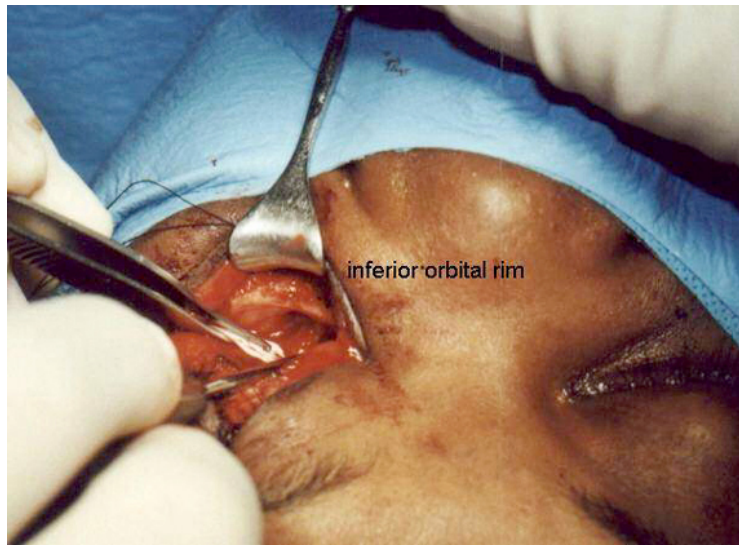### Statistical Testing:

Information from data sheets were transferred to an excel spreadsheet from which data analysis and descriptive statistics were performed.

### Description of the transconjunctival surgical approach used:

The surgical approach used was routine at St John and the WDGMC and was performed by one of two consultants from the oculoplastics clinic.

The transconjunctival incision was made through the conjunctiva of the inferior fornix. The plane between the orbicularis and orbital septum was dissected and the periosteum at the rim incised and reflected to expose the bone of the orbital rim, the orbital floor and the lateral and medial orbital walls.<sup>3,4,7,8,21</sup> (Figure 3.1) A lateral canthotomy was performed at the outset.<sup>7</sup> When indicated, the medial wall was exposed via a vertical transcutaneous incision just anterior to the medial canthal tendon.<sup>8</sup>

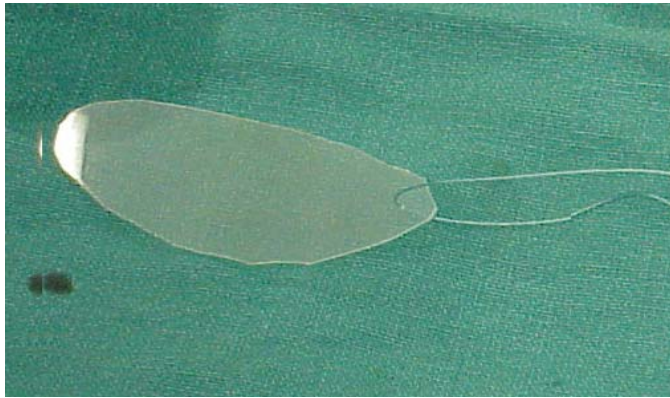


**Figure. 3.1** Transconjunctival surgical approach used to expose orbital fracture.

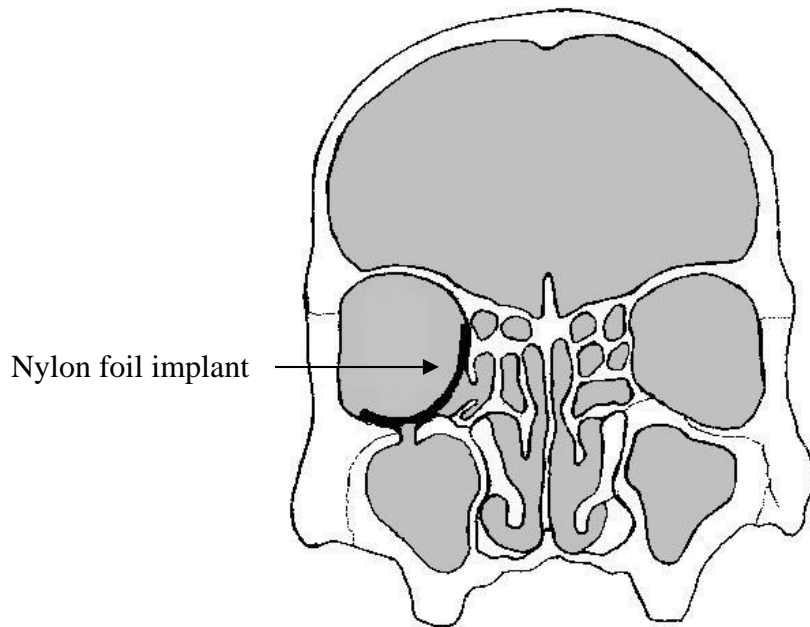
After the surgical incision was made, the surgeon then exposed and explored the orbital floor and walls. The fracture was identified, the entrapped tissue was released and the bony fragments were elevated into position or removed to allow repositioning of the orbital contents.<sup>3-5</sup>

In all cases the orbital fracture was repaired with 0.4mm nylon foil sheeting (Supramid) (Figure. 3.2). A “wraparound” technique as described by Nunery<sup>8</sup> was employed (Figure 3.3). The nylon foil sheeting was introduced through the inferior transconjunctival incision and advanced superomedially to cover the defect in the floor and medial wall. This allowed for complete coverage of the fractures with restoration of normal orbital contour. The lateral and medial canthal tendons were repaired with 5/0 prolene and the conjunctiva and lower lid retractors were sutured with 6/0 chromic.





**Figure. 3.2** Nylon foil sheeting (Supramid) used to repair the orbital fracture.



**Figure. 3.3** Diagram showing repair of a floor and medial wall orbital blowout fracture using “wraparound” technique.

## 4. RESULTS

Thirty patients were included in this case series.

Demographic data is shown in Table 4.1.

**Table 4.I.** Demographic Data

<b>Number of patients:</b>	30 (18 male, 12 female)
<b>Mean age in years:</b>	38 (range 18-61)
<b>Mechanism of injury:</b>	
Assault	22 (73%)
MVA	4 (13%)
Sport Injury	3 (10%)
Fall	1 (3%)
<b>Follow-up period:</b>	
Minimum post-operative follow-up	4 months
Average follow-up period	16.5 months (4months - 4.5years)
<b>Fracture Pattern:</b>	
Floor + medial wall	22 (73%)
Isolated floor	4 (13%)
Orbitozygomatic (including floor)	4 (13%)

The mean age was 38 years with a male: female ratio of 3: 2. The commonest cause of orbital fracture was assault in 73% of cases most frequently with the fist, followed by motor vehicle accident in 13% and sport injury in 10%. The commonest fracture pattern seen was combined floor and medial wall blowout fractures in 73% of cases. Four patients (13%) had an isolated floor fracture and four patients had an orbitozygomatic complex fracture. The minimum postoperative follow-up period was four months with a mean of 16.5 months.

Ten patients (33%) in this series were repaired early within three weeks of injury and twenty patients (66%) underwent late surgical repair.

Table 4.2 shows the rates of preoperative and postoperative diplopia and enophthalmos in both the early and late repair groups.

**Table 4.2.** Diplopia and Enophthalmos

	<b>Preoperative</b>	<b>Postoperative</b>
<b>Diplopia:</b>	<b>25 / 30 (83%)</b>	<b>2 / 30 (7%)</b>
Early repair	9 / 10 (90%)	0 / 10 (0%)
Late repair	16 / 20 (80%)	2 / 20 (10%)
<b>Enophthalmos &gt; 2mm</b>	<b>16 / 30 (53%)</b>	<b>5 / 30 (17%)</b>
Early repair	3 / 10 (30%)	0 / 10 (0%)
Late repair	13 / 20 (65%)	5 / 20 (25%)

Diplopia was the presenting symptom in 25 of 30 patients (83%) and two patients (7%) had persistent diplopia postoperatively. Enophthalmos greater than 2mm was present in 16 of 30 patients (53%) preoperatively and five patients (17%) had persistent enophthalmos postoperatively. All patients with persistent postoperative diplopia and or enophthalmos underwent late surgical repair, ranging from six weeks to four years with a mean of 10.6 months. Four patients in this series had an orbitozygomatic fracture pattern and three of these patients (75%) were in the late repair group that had persistent diplopia or enophthalmos.

### Surgical Complications

There were no cases of lower lid retraction or ectropion.

Three patients (10%) had complications related to the medial canthal incision. Two patients had a bowstring sign of the medial canthus due to disinsertion of medial canthal pucker. One of these patients also had an associated upper lid laceration and canalicular injury following the initial trauma which involved assault with a broken bottle. One patient developed a medial canthal entropion and was booked for a medial canthal entropion repair.

There was one implant-related complication (3%) where the implant migrated into the maxillary sinus. This patient had an orbitozygomatic fracture pattern with a large floor fracture (involving >50% of the orbital floor) and underwent late surgical repair eight weeks post-trauma. The patient underwent revision surgery where the nylon foil sheeting was repositioned and a second nylon foil was used to cover the floor defect.

No intraoperative complications were encountered and there was no loss of preoperative visual acuity.

#### Associated ocular injuries

One patient had an associated upper eyelid laceration and canalicular injury that required repair. Three patients had post traumatic anterior uveitis and one patient had commotio retina. One patient had traumatic optic neuropathy and iris sphincter tears.

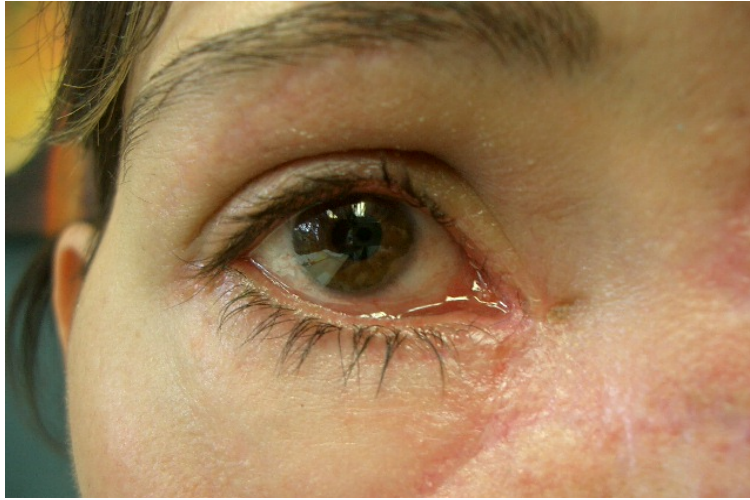#### Additional results:

Three patients (10%) in this series were previously operated by maxillofacial surgeons using the transcutaneous surgical approach and were referred for revision surgery for persistent diplopia and or enophthalmos. Table 4.3 summarizes the characteristics of these three cases.

**Table 4.3.** Cases previously repaired using transcutaneous surgical approach

	<b>Implant material</b>	<b>Residual Diplopia</b>	<b>Persistent Enophthalmos</b>	<b>Lower eyelid complications</b>
<b>Case 1</b>	Titanium microplate	Present	—	—
<b>Case 2</b>	Titanium microplate + bone graft	Present	6mm	Visible scar
<b>Case 3</b>	Bone graft	Present	—	Lower lid retraction

The implant materials used in each case were as follows: a titanium microplate system was used in one patient, autogenous bone graft was used in one patient and one patient had both a titanium plate and autogenous bone graft material. All three patients experienced postoperative diplopia and one patient had persistent enophthalmos. One patient had a visible lower lid incision scar and one patient had lower lid retraction in addition to a visible scar (Figure 4.1). These patients were referred for revision surgery. Following removal of implant materials and replacement with nylon foil, diplopia symptoms and enophthalmos were corrected in all three patients postoperatively.



**Figure 4.1** Surgical complication: Lower lid retraction. Case 3 showing lower lid complication following previous repair via transcutaneous surgical approach using bone graft. This patient also presented with persistent postoperative diplopia symptoms which resolved following revision surgery. In addition, a skin graft was required to correct the lower lid retraction.

## 5. DISCUSSION

The commonest cause of orbital fractures was assault (73%), most frequently with the fist and the most common fracture pattern seen was combined orbital floor and medial wall blowout fractures (73%).

The indications for surgical repair of orbital floor fractures in this case series of adult patients were diplopia, enophthalmos greater than 2mm and large fracture size. All patients had preoperative computerized tomography scans with axial and coronal views to adequately assess the fracture.

This case series included patients that underwent early surgical repair within three weeks of trauma, as well as patients who were repaired late. In addition, three patients (10%) underwent previous surgical repair of the same fracture by a maxillofacial surgeon and were referred for revision surgery for persistent diplopia and or enophthalmos.

The outcomes' of postoperative diplopia and enophthalmos in this series (7% and 17% respectively) were comparable<sup>9,10</sup> if not lower than those reported in other studies.<sup>11,12</sup>



Postoperatively, one patient had both diplopia and enophthalmos, one patient had only diplopia and four patients had persistent enophthalmos. These six cases were all repaired late (mean of 10.6 months). Late repair of orbital fractures was found to be impeded by the development of fibrosis and contracture of soft tissue increasing the risk of persistent diplopia and enophthalmos postoperatively.<sup>5</sup> In this series patients that were repaired early, within three weeks of trauma, had no diplopia or enophthalmos postoperatively. The lower incidence of diplopia and enophthalmos after early surgical repair of orbital fractures is supported by other studies<sup>5,8,9,10,12</sup>. The reason for late repair in this series was mostly delayed presentation, highlighting the need for early referral and subsequent early management of patients with orbital fractures in order to allow the best chance of accomplishing a good functional outcome as well as fewer complications.

Additionally, three of four patients with orbitozygomatic fractures (75%) were in the late repair group that had persistent post-operative diplopia (one patient) or enophthalmos (two patients). In orbitozygomatic fractures, direct force on the zygoma may result in fracture of the zygomatic arch, zygomatic frontal articulation, zygomatic-maxillary buttress and inferior orbital rim, and in most cases the floor is involved.<sup>1</sup> The normal contour of the orbit relies on the stability of the zygomatic-maxillary buttress laterally and the naso-maxillary buttress medially.<sup>1</sup> These fractures need to be reduced and repaired with an appropriately sized implant in order to correct the associated increased orbital volume that may result in persistent post-operative diplopia or enophthalmos.<sup>1,8</sup>

In the report by Nunery <sup>8</sup>, of 64 patients presenting with diplopia, none experienced diplopia postoperatively and one patient had persistent enophthalmos. However, all patients underwent early repair within three weeks of trauma and patients who underwent previous surgery for the same fracture were excluded from the study.

With respect to lower lid complications, there were no cases of postoperative lower lid retraction or ectropion in keeping with several studies evaluating the transconjunctival approach in the repair of orbital fractures <sup>1,8,14-17</sup>. The transconjunctival incision was associated with adequate exposure of the lower medial wall and floor. It also avoided visible scars in contrast to the transcutaneous surgical approach. One patient developed a medial canthal entropion and was booked for repair and two patients had disinsertion of medial canthal pucker. Although reported complications of the transconjunctival surgical approach are infrequent and mostly avoidable with careful surgical technique, the subsequent appropriate management results in a favourable outcome.

In this series 0.4mm thick nylon foil (Supramid) was used to repair the fracture in all cases, using the “wraparound” technique described by Nunery<sup>8</sup>. There was one implant-related complication (3%) where the implant material collapsed into the maxillary sinus. This patient had an orbitozygomatic fracture pattern with a large floor fracture (>50%) and increased intraorbital volume. Also, this was a case of late surgical repair eight weeks post-trauma. The patient underwent revision surgery requiring the placement of a second supramid implant to cover the orbital floor defect. There were no cases of haemorrhage, infection or other complications related to the nylon foil implant in this series.

Nylon foil is a non-porous implant that provides structural support without encouraging tissue in-growth and was therefore used in all cases.<sup>8</sup> This is thought to minimize the risk of cicatrization in extraocular muscles next to the implant resulting in a lower incidence of complications such as cicatricial eyelid retraction and restrictive diplopia.<sup>8,20</sup> The low rate of complications associated with nylon foil implant in this study was in keeping with previous reports.<sup>8,19</sup>

Furthermore, non-porous implants such as nylon foil are much more cost effective than both porous implants and titanium plates (Table 5.1).

**Table 5.1** Cost comparison of implant materials

	Nylon foil 0.4mm (non-porous)	Porous polyethylene	Titanium mesh
Cost in Rands per case	<b>R 248.50</b>	R 2706.93 – R 5259.00	R 4155.07

The limitation of this study was the small number of patients and therefore a larger prospective clinical study would be required to further evaluate the transconjunctival surgical approach and nylon foil implant in the repair of orbital fractures.

## **6. CONCLUSION**

In this case series, the transconjunctival surgical approach and nylon foil wraparound technique used to repair orbital fractures were found to produce good functional outcomes with few complications. The optimal results attained by early surgical repair of orbital blowout fractures and the use of nylon foil (Supramid) implant was demonstrated by this study.

## 7. REFERENCES

1. Cruz AA, Eichenberger GC. Epidemiology and management of orbital fractures. *Curr Opin Ophthalmol* 2004;15:416-421.
2. Wilson S, Ellis E. Surgical approaches to the infraorbital rim and orbital floor: The case for the subtarsal approach. *J Oral Maxillofac Surg* 2006;64:104-107.
3. Smith ML, Williams JK, Gruss JS. Management of Orbital fractures. *Plast Reconstr Surg* 1998;5:312-324.
4. Foster JA, Holck DEE, Koltai PJ. Orbital fractures: Indications and surgical techniques. *Am Orthopt J* 2004;54:13-23.
5. Burnstine MA. Clinical recommendations for repair of isolated orbital floor fractures: an evidence-based analysis. *Ophthalmology* 2002;109:1207-1210.
6. Kushner GM. Surgical approaches to the infraorbital rim and orbital floor: The case for the transconjunctival approach. *J Oral Maxillofac Surg* 2006;64:108-110.
7. McCord CD, Moses JL. Exposure of the inferior orbit with fornix incision and lateral canthotomy. *Ophthalmic Surg* 1979;10:53-63.

8. Nunery WR, Tao JP, Johl S. Nylon foil “wraparound” repair of combined orbital floor and medial wall fractures. *Ophthal Plast Reconstr Surg* 2008;24:271-275.
9. Hosal BM, Beatty RL. Diplopia and enophthalmos after surgical repair of blowout fracture. *Orbit* 2002;21:27-33.
10. Schmäl F, Basel T, Grenzebach UH, Thiede O, Stoll W. Preseptal transconjunctival approach for orbital floor fracture repair: ophthalmological results in 209 patients. *Acta Oto-Laryngologica* 2006;126:381-389.
11. Biesman BS, Homblaus A, Lisman R, Kazlas M. Diplopia after surgical repair of orbital floor fractures. *Ophthal Plast Reconstr Surg* 1996;12:9-16.
12. Hawes MJ, Dortzbach RK. Surgery on orbital floor fractures. *Ophthalmology* 1983;90:1066-1070.
13. Guy JBS, Hasan MS, McCann JD, Goldberg RA. Early versus late repair of orbital blowout fractures. *Ophthalmic Surg Lasers Imaging* 2009;40:141-148.
14. Baumann A, Ewers R. Use of the preseptal transconjunctival approach in orbit reconstruction surgery. *J Oral Maxillofac Surg* 2001;59:287-291.

15. Manganello-Souza LC, de Freitas RR. Transconjunctival approach to zygomatic and orbital floor fractures. *Int J Oral Maxillofac Surg* 1997;26:31-34.
16. Patel PC, Sobota BT, Patel NM, Greene JS, Millman B. Comparison of transconjunctival versus subciliary approaches for orbital fractures: a review of 60 cases. *J Craniomaxillofac Trauma* 1998;4:17-21.
17. Appling WD, Patrinely JR, Salzer TA. Transconjunctival approach vs subciliary skin-muscle flap approach for orbital fracture repair. *Arch Otolaryngol Neck Surg* 1993;119:1000-1007.
18. Westfall CT, Shore JW, Nunery WR, Hawes MJ, Yaremchuk MJ. Operative complications of the transconjunctival inferior fornix approach. *Ophthalmology* 1991;98:1525-1528.
19. Park DJJ, Garibaldi DC, Iliff N, Grant MP, Merbs SL. Smooth nylon foil (Suprafoil) orbital implants in orbital fractures: A case series of 181 patients. *Ophthal Plast Reconstr Surg* 2008;24:266-270.
20. Lee HBH, Nunery WR. Orbital adherence syndrome secondary to titanium implant material. *Ophthal Plast Reconstr Surg* 2009;25:33-36.



21. Hawes MJ, Dortzbach RK. Blow-out fractures of the orbital floor. In: Dortzbach RK, editor. Ophthalmic plastic surgery: Prevention and management of complications. New York: Raven Press, 1994:195-207.