

DOI 10.24425/pjvs.2020.132751

Original article

# Histomorphometrical changes in intestine structure and innervation following experimental fumonisins intoxication in male Wistar rats

H. Rudyk<sup>1</sup>, E. Tomaszewska<sup>2</sup>, M.B. Arciszewski<sup>3</sup>, S. Muszyński<sup>4</sup>,  
A. Tomczyk-Warunek<sup>5</sup>, P. Dobrowolski<sup>6</sup>, J. Donaldson<sup>7</sup>, O. Brezryn<sup>1</sup>,  
I. Kotsyumbas<sup>1</sup>

<sup>1</sup>The State Scientific Research Control Institute of Veterinary Medicinal Products and Feed Additives (SCIVP), Donetska 11, 79019 Lviv, Ukraine

<sup>2</sup>Department of Animal Physiology,  
University of Life Sciences in Lublin, Akademicka 12, 20-950 Lublin, Poland

<sup>3</sup>Department of Animal Anatomy and Histology,  
University of Life Sciences in Lublin, Akademicka 12, 20-950 Lublin, Poland

<sup>4</sup>Department of Physics, University of Life Sciences, Akademicka 13, 20-950 Lublin, Poland

<sup>5</sup>Locomotor System Research Department, Chair and Department of Rehabilitation and Orthopaedics,  
Medical University in Lublin, Jaczewskiego 8, 20-090 Lublin, Poland

<sup>6</sup>Department of Comparative Anatomy and Anthropology,  
Maria Curie-Skłodowska University, Akademicka 19, 20-033 Lublin, Poland

<sup>7</sup>School of Physiology, Faculty of Health Sciences,  
University of the Witwatersrand, 7 York Road, 2193 Parktown, Johannesburg, South Africa

## Abstract

Fumonisin are highly toxic metabolites produced by *Fusarium proliferatum* and *Fusarium verticillioides*. Little is known about the effects of a chronic low level of fumonisins on intestinal structure and innervation in monogastric animals, even though the intestine is the first organ exposed to fumonisins. The influence of the most prevalent strains of fumonisins, FB1 and FB2, on intestinal and liver morphology, the enteric nervous system and intestinal epithelial cell proliferation was investigated in an experimental rat model of fumonisin intoxication. Adolescent (5-weeks-old), male Wistar rats were randomly divided into a control group (C group) not treated with fumonisins or intoxicated with fumonisins (FB group). FB1 together with FB2 were daily administered intragastrically at a dose of 90 mg/kg body weight for 21 days. The damaging effect was assessed by determination of the activity of ALAT and AspAT. Samples from the small intestine and liver were taken and blood samples were collected to determine the activity of gamma-glutamyl transferase (GGT) and amylase. The exposure to FBs resulted in histopathological degenerative alterations in hepatocytes, including mild vacuolar degeneration and ballooning. FB exposure was also toxic in the duodenum and jejunum, where significant changes in morphology, cell proliferation, collagen wall fibres and innervation were observed. Taken together, the results obtained strengthen the hypothesis that chronic exposure to FBs could induce intestinal damage, including damage to the enteric nervous system and may have consequences for general health.

**Key words:** mycotoxins, food contamination, small intestine morphology, rodents

## Introduction

*Fusarium proliferatum* and *Fusarium verticillioides* produce highly toxic metabolites called fumonisins, that are present in cereal grains or crop products and are resistant to the pelleting process. Various strains of fumonisins exist, including fumonisins A, C, P and four different fumonisins B (FBs). However, only FB1 and FB2 are toxicologically significant due to their relative abundance in feed (Šegvić and Pepeljnjak 2001). FBs are involved in the regulation of cell growth, differentiation and even cancer transformation as they have been shown to be inhibitors of *de novo* sphingolipid synthesis, including the synthesis of lipids via nerve cells (Ross et al. 1992). The species most susceptible to the effects of FBs are horses and pigs, in which clinical problems associated with FB ingestion have been reported (equine leukoencephalomalacia; porcine pulmonary edema) (Voss et al. 2007). Additionally, hepatic or renal FB toxicity has been observed in horses, sheep, rodents and poultry (Riley and Voss 2006, Antonissen et al. 2015). Several studies have demonstrated immunotoxic and carcinogenic effects attributed to FB1 (Norred et al. 1993). FBs are also possible etiological factors in the skeletal problems observed in livestock (Kierończyk et al. 2017). Since 2002 FB1 has been considered by the International Agency for Research on Cancer as possibly carcinogenic to humans (Group 2B). The European Commission and the FDA in the USA have issued guidelines on the total amount of fumonisins that are acceptable in human foods and animal feed (FDA 2001, EC 2006). FBs are most frequently detected in South American (77%), African (72%) and Southern European (70%) samples. The economic loss in animal husbandry is difficult to calculate as information about subclinical effects on animal health and productivity losses caused by chronic low level exposure is limited (Voss et al. 2007, Antonissen et al. 2015).

Reduced villus length and villus-to-crypt ratio was noted in the jejunum of broilers exposed to high FB1 concentrations ( $\geq 100$  mg/kg feed) for 28 days (Rauber et al. 2013). Similarly, following two weeks of exposure to FB1 (300 mg/kg feed), villus atrophy and goblet cell hyperplasia was observed in broiler chickens (Brown et al. 1992). The intestinal epithelial integrity in pigs was disturbed as a result of FB1 on the expression of cell junction proteins E-cadherin and occludin (Bouhet and Oswald 2007, Basso et al. 2013). Furthermore, FB1, alone or with FB2, modulates intestinal immunity and modifies the fecal microbiota composition in pigs (Burel et al. 2013).

The awareness of fumonisins intoxication is increasing and the effects of subclinical intoxication are being

intensively investigated. However, still little is known about the effects of a chronic low level of FBs on intestinal structure and innervation in monogastric animals, although the intestine is the first organ exposed to FBs.

The objective of this study was to evaluate the effects of FB1 together with FB2 on the intestinal and liver morphology, the enteric nervous system and epithelial cell proliferation.

## Materials and Methods

All experimental procedures were approved by the Local Ethics Committee at the State Scientific Research Control Institute of Veterinary Medicinal Products and Feed Additives (SCIVP), Lviv, Ukraine, and complied with the Directive 2010/63/EU of the European Parliament and of the Council on the protection of animals used for scientific purposes.

FBs culture material was produced *in vitro* from a culture of *F. verticillioides* (Institute of Veterinary Medicine of The National Academy of Agrarian Sciences of Ukraine, Kiev, Ukraine) in tryptone glucose yeast broth medium in Petri dishes. Autoclaved, sterilized corn grains were plated equidistantly in Petri dishes and incubated at 25°C for 4-5 weeks. The contaminated grains were then ground and extracted with ethanol for 24 h. The extract obtained was then filtered and concentrated by evaporation. As shown by HPLC analysis (National Veterinary Research Institute, Puławy, Poland), the contaminated corn contained 75% of FB1 and 25% of FB2 (182.0 and 59.5  $\mu\text{g}/\text{kg}$ , respectively) (Rudyk et al. 2019).

Twelve adolescent (5-weeks-old) male Wistar rats were housed individually in polypropylene cages (the dimensions of 380 x 200 x 590 mm) and allowed a one week acclimatization period, during which they were accustomed to the laboratory conditions. The rats were kept at a temperature of  $21\pm 3^\circ\text{C}$ , humidity of  $55\pm 5\%$ , with a 12h/12h day/night cycle and had free access to water. After the acclimatization period, the rats were randomly allocated to either a control group (C group;  $n=6$ ) not treated with fumonisins and a group intoxicated with fumonisins (FB group;  $n=6$ ). The rats in both groups were fed *ad libitum* standard laboratory rodents diet. Fumonisin toxicosis was induced in the rats from the FB group by daily intragastric administration of FBs (FB1+FB2). FBs have been given at a dose of 90 mg/kg body weight per rat in 0.5 ml of 0.9% saline solution for 21 days by oral gavage. Control animals received saline solution only in the corresponding amount and manner. As the median lethal dose ( $\text{LD}_{50}$ ) of FB for rats is not known (McKean et al. 2006), in the preliminary study  $\text{LD}_{50}$  (900 mg/kg body weight) was established. The dose

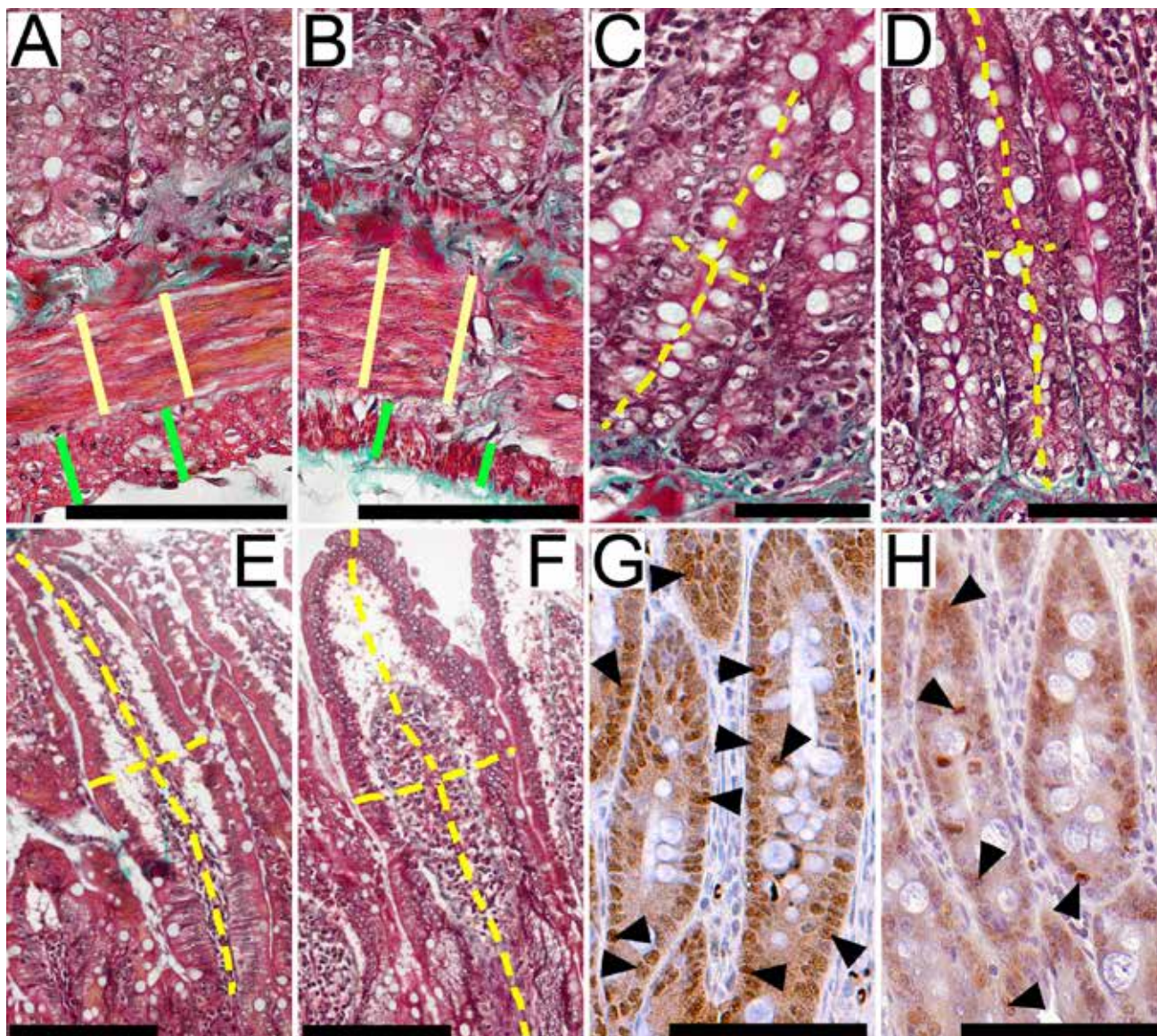


Fig. 1. Representative pictures of intestinal myenteron (A, B); crypts (C, D) and villus (E, F) in formaldehyde-fixed sections from the jejunum of rats from the control group (A, C, E) and from the FB-intoxicated group (B, D, F). A and B show measurement scheme of longitudinal (a continuous green line) and circular (a continuous yellow line); C and D show measurement scheme of the depth (a long dashed yellow line) and the thickness (a short dashed yellow line) of the crypt; E and F show measurement scheme of the length (a long dashed yellow line) and the thickness (a short dashed yellow line) of the villus. Representative pictures of the immunohistochemical reactions for Ki-67 done on formaldehyde-fixed sections from the jejunum of rats from the control group (G) and from the FB-intoxicated group (H). Black arrows show representative positive reactions. Each scale bar = 100  $\mu$ m.

of FB1+FB2 (75% and 25%, respectively) administered was equal to 0.1 of the established  $LD_{50}$  value and was sufficient to induce subclinical intoxication in all of the infected rats in this study. After 21 days rats were fasted for 24 hours, weighed and euthanized by  $CO_2$  inhalation.

Blood samples were collected immediately, using standard venipuncture of the heart, into 6 ml vacuum tubes, for hematological and biochemical analyses. Serum was immediately separated by centrifugation and frozen at  $-80^{\circ}C$  for further analyses. Toxicosis was confirmed by raised liver enzyme activities. Liver

and kidneys were dissected out and weighed. Liver and small intestine samples were collected for histomorphometrical analyses.

#### Serum biochemical analyses

Blood serum activity of aspartate transaminase (AST), alanine transaminase (ALT), gamma-glutamyl transferase (GGT) and amylase were determined colorimetrically using a Mindray BS-120 biochemical analyzer (Bio-Medical Electronics, Shenzhen, China) and sets of ready-made biochemical reagent kits (Alpha Diagnostics, Warsaw, Poland). Given that both the

activity of AST and ALT were determined, the ratio of AST and ALT was calculated as the de Ritis coefficient (Botros and Sikaris 2013).

### Tissue collection and histomorphometrical analysis

One 1.0-cm-long segment from the duodenum (10 mm distal to the pylorus) and one 1.0-cm-long segment from the jejunum (50% of the total length of jejunum) were obtained from each rat and gently cut open longitudinally along the mesentery line, avoiding any damage to the mucosa. Intestinal samples were washed gently with warm (37°C) 0.9% saline solution, then placed flat (without being stretched) into standard histological cassettes in such a way that the mucosa had no contact with any of the cassette walls. The liver samples were collected from the same lobe in each rat. All samples were fixed in 4% buffered formaldehyde (pH 7.0) for 24 hours (Klebaniuk et al. 2018). Next, all samples (liver and small intestine) were dehydrated in Ottix Plus, cleared in Ottix Shaper solvent substitutes (DiaPath, Martinengo, Italy) and then embedded in paraffin using a tissue processor (STP 120, Thermo Scientific, Waltham, MA, USA). Paraffin-fixed samples were sectioned and subjected to histology as previously described (Tomaszewska et al. 2017, 2018a). Briefly, twenty 4 µm thick cross sections (with 10-µm interval after each five-slice section) were cut with a microtome (Microm HM 360, Microm, Walldorf, Germany). Each of the five semi-serial cuts was then placed on one microscopic slide. In further analysis, two of the five cuts from each slide were analyzed.

Masson's trichrome staining was used to differentiate the structures of the small intestine wall (Tomaszewska et al. 2018b). Picrosirius red staining (PSR) was used to differentiate collagen fibers in the connective tissue, where thicker collagen fibres (type I or mature collagen) are red and thinner fibers (type III or immature collagen) are green in polarized light (Tomaszewska et al. 2014). The images were obtained with the use of an optical microscope (Olympus CX43; Olympus, Tokyo, Japan) equipped with a CDD camera (SC50 Olympus, Tokyo, Japan).

The thickness of the myenteron (longitudinal and circular lamina, as presented in Fig. 1A, 1B), submucosa, mucosa and villus epithelium (the height of enterocytes, measured as the distance from brush-border membrane to the basolateral membrane) were analyzed in the following manner: eight measurements of each variable were made on each of the slices analyzed, which gives 64 measurements from each sample of intestine (duodenum and jejunum), from each rat (as described above, two slices from each of 4 slides from each rat were analyzed). The 64 measurements

were then averaged and expressed as the mean thickness for each rat. Finally, these 6 mean measurements from 6 rats were used to calculate a mean thickness of myenteron, submucosa, mucosa or villus epithelium for one treatment group.

The total number of crypts and villi per millimeter of mucosa were counted from four different sections on each of the slides analyzed. Crypt depth (defined as the depth of the invagination between adjacent villi, from the bottom of crypt to the base of the villus, Fig. 1C, 1D) and width (measured in the middle of the crypt depth), villus height (from the tip of the villus to the villus-crypt junction, Fig. 1E, 1F) and width (measured in the middle of the villus height, Fig. 1E, 1F), the ratio of villi length to crypt depth (villus/crypt ratio) and the number of enterocytes and goblet cells per 100 µm of villus epithelium were calculated for four vertically oriented and well defined villi and crypts for each of the slices analyzed. A total of 32 measurements of each parameters listed above for each rat were obtained (4 measurements on 2 slices on 4 slides). They were used to calculate the mean value, per rat. Finally, these means from the six rats in each group were used to calculate the mean per single treatment group. The small intestinal absorptive surface measurements were taken under the same scheme as describes elsewhere (Kisielinski et al. 2002).

Microscopic observation of the liver samples allowed us to identify and assess normal liver structure, including portal triads and terminal hepatic venules, which are necessary for the evaluation of lobular architecture and the presence of small hepatocytes (a characteristic of hepatic tissue regeneration). Moreover, the following parameters were analyzed: intercellular space and amount of collagen (%); fractal dimension of intercellular space; total number of cells per mm<sup>2</sup>; total hepatocyte number per mm<sup>2</sup>; non-hepatocyte cell numbers per mm<sup>2</sup>; hepatocyte nuclei number per mm<sup>2</sup>; number of mononuclear hepatocytes per mm<sup>2</sup>; number of multinucleated hepatocytes per mm<sup>2</sup>.

All analyses of the captured images (intestine and liver) were performed with the use of graphical analysis software Olympus cellSens version 1.5 (Olympus, Tokyo, Japan). The structure of the liver was analyzed with the use of graphical analysis software ImageJ 1.48r (National Institute of Health, USA), using the appropriate build-in tools and macros.

### Immunohistochemistry

Immunohistochemical staining was performed using rabbit polyclonal antibodies directed against Ki-67 (AbCam ab15580, Cambridge, UK, dilution 1:50; to identify proliferating cells) and 200 kD neurofilament heavy subunit neuronal marker (AbCam

Table 1. Serum biochemical parameters measured in control and fumonisins-intoxicated male Wistar rats.

| Item                | Group       |             | p-value |
|---------------------|-------------|-------------|---------|
|                     | Control     | Fumonisin   |         |
| AST (U/L)           | 117±25      | 439±32      | ***     |
| ALT (U/L)           | 70±4        | 66±6        | n.s.    |
| The De Ritis ratio  | 1.67±0.09   | 6.66±0.03   | ***     |
| Total protein (g/L) | 74.1±4.2    | 63.3±6.5    | **      |
| Urea (mmol/L)       | 5.6 ± 0.6   | 7.1 ± 0.5   | ***     |
| GGT (U/L)           | 2.0±0.11    | 3.0±0.19    | ***     |
| Amylase (U/L)       | 1715 ± 80.7 | 2038 ± 44.8 | ***     |

Statistical significance: n.s. – not significant; \*\*  $p < 0.01$ ; \*\*\*  $p < 0.001$ .

AST – aspartate transaminase; ALT – alanine transaminase; GGT – gamma-glutamyl transferase.

ab8135, Cambridge, UK, dilution 1:200; to localize the submucous and myenteric plexuses). Immunohistochemical procedures have been previously described (Tomaszewska et al. 2012), according to the manufacturer's protocols. Microscopic images of the immunohistochemistry reactions were subjected to further analysis and the variables analyzed included: regarding Ki-67 - the number of proliferating cells per 0.01 mm<sup>2</sup> of the gland surface and the proliferating cell index, as the number of proliferating cells as the percent of all gland cells (Fig. 1G, 1H); regarding neurofilament detection - the cross sectional area of the nerve ganglion, sphericity, perimeter and mean diameter. A total number of 32 measurements of each parameter analyzed was obtained per rat and the measurements were performed in the manner described above.

### Statistical analysis

Each individual rat was considered as an experimental unit. The data were analyzed using Statistica 13 software (TIBCO Software Inc., Palo Alto, CA, USA). The normality of data distribution was tested using the Shapiro-Wilk test. Comparisons between normally distributed data were carried out using the Student's t test. When the data did not meet the assumptions for parametric tests, the Mann-Whitney U test was applied. For all tests a p-value less than 0.05 was considered statistically significant. All results are expressed as means ± standard deviation.

## Results

### Body weight, liver and kidneys weight

The mean body weight of the rats was not different between groups at the start of the experiment (C group: 212±3 g; FB group: 223±4 g). At the end of experiment

the control rats were significantly heavier ( $p < 0.05$ ) than the FB-intoxicated rats (C group: 235±2 g; FB group: 219±3 g). FB-intoxicated rats had significantly heavier livers (39.7±1.3 g) compared to those of the control rats (33.9±0.2 g;  $p < 0.05$ ). The liver weight relative to body weight (14.42±0.08 g/kg of body weight) in the control group was significantly lower ( $p < 0.05$ ) than that observed in the FB-intoxicated group (18.12±0.59 g/kg of body weight). There were no significant differences in kidney weight between the control and FB-intoxicated groups (5.2±0.1 g and 6.5±0.5 g, respectively). The relative kidneys weight was significantly higher ( $p < 0.05$ ) in the FB-intoxicated group (2.96±0.22 g/kg of body weight) compared to that of the control group (2.21±0.04 g/kg of body weight).

### Serum biochemistry

Serum AST activity was significantly higher in the FB group compared to the control group ( $P < 0.001$ ), while the ALT activity was not different between groups (Table 1). The physiological ranges for serum AST and ALT activity for rats are reported as 95-100 U/L and 49-69 U/L, respectively (Harkness and Wagner 1995). The De Ritis ratio was elevated ( $p < 0.001$ ) in the FB group compared to that in the control group. Serum GGT and amylase activities were also significantly increased ( $p < 0.001$ ) in FB-intoxicated rats (Table 1).

### Gastro-intestinal tract morphology

Total duodenal wall thickness did not differ among groups (Table 2). The FB intoxication resulted in a significant reduction in the longitudinal layer of the myenteron ( $p < .001$ ), while the circular layer was similar to that of the control group. Moreover, the thickness of the mucosa was similar in both groups, but a significantly reduced submucosa thickness was observed in the FB-intoxicated rats ( $p < 0.001$ ). The FB intoxica-

Table 2. Effect of dietary fumonisins intoxication on the histomorphometrical parameters of the duodenum in male Wistar rats.

| Item   | group             |                   | p-value |
|--|-------------------|-------------------|---------|
|  | control           | fumonisin         |         |
| Total thickness ( $\mu\text{m}$ )                      | 840 $\pm$ 150     | 874 $\pm$ 94      | n.s.    |
| Myenteron thickness ( $\mu\text{m}$ )                  |                   |                   |         |
| Longitudinal lamina                                    | 69.3 $\pm$ 10.7   | 43.9 $\pm$ 13.0   | ***     |
| Circular lamina  | 63.8 $\pm$ 16.0   | 66.8 $\pm$ 9.8    | n.s.    |
| Mucosa thickness ( $\mu\text{m}$ )                     | 698 $\pm$ 109     | 740 $\pm$ 94      | n.s.    |
| Submucosa thickness ( $\mu\text{m}$ )                  | 52.3 $\pm$ 13.3   | 42.2 $\pm$ 6.5    | ***     |
| Villus length ( $\mu\text{m}$ )                        | 561 $\pm$ 56      | 433 $\pm$ 90      | *       |
| Villus thickness, ( $\mu\text{m}$ )                    | 99.7 $\pm$ 27.1   | 100.1 $\pm$ 21.9  | n.s.    |
| Total number of villi ( $\text{mm}^{-1}$ )             | 8.65 $\pm$ 1.49   | 8.04 $\pm$ 1.19   | n.s.    |
| Villus epithelium thickness ( $\mu\text{m}$ )          | 18.1 $\pm$ 3.6    | 18.4 $\pm$ 5.6    | n.s.    |
| Crypt depth ( $\mu\text{m}$ )                          | 204 $\pm$ 34      | 159 $\pm$ 52      | ***     |
| Crypt width ( $\mu\text{m}$ )                          | 49.5 $\pm$ 10.6   | 39.6 $\pm$ 7.6    | ***     |
| Crypt number ( $\text{mm}^{-1}$ )                      | 19.3 $\pm$ 3.1    | 21.0 $\pm$ 4.6    | n.s.    |
| Intestine absorptive surface ( $\mu\text{m}^2$ )       | 10.13 $\pm$ 1.58  | 9.56 $\pm$ 2.55   | n.s.    |
| Enterocyte number per 100 $\mu\text{m}$ of villus      | 15.1 $\pm$ 3.1    | 15.6 $\pm$ 3.1    | n.s.    |
| Number of goblet cells per 100 $\mu\text{m}$ of villus | 4.65 $\pm$ 1.08   | 2.71 $\pm$ 0.64   | ***     |
| Villus/crypt ratio                                     | 2.96 $\pm$ 0.42   | 2.89 $\pm$ 0.66   | n.s.    |
| Thin/thick collagen ratio                              | 0.080 $\pm$ 0.031 | 0.131 $\pm$ 0.033 | **      |
| Ki number per 0.01 $\text{mm}^2$ of the gland surface  | 70.4 $\pm$ 15.4   | 44.6 $\pm$ 8.5    | **      |
| Ki index (%)   | 45.6 $\pm$ 7.5    | 31.5 $\pm$ 3.4    | **      |

Statistical significance: n.s. – not significant; \*  $p < 0.05$ ; \*\*  $p < 0.01$ ; \*\*\*  $p < 0.001$ .

Villus/crypt ratio - the ratio of the villi length to the crypt depth; Ki number - the number of proliferating cells; Ki index - the number of proliferating cells in relation to all gland cells.

tion also resulted in significantly narrower and shallower crypts ( $p < 0.001$  for both parameters), as well as significantly shorter villi ( $p < 0.05$ ), with a higher number of goblet cells ( $p < 0.001$ ). No other changes in the duodenum were observed.

The influence of the fumonisins on the histomorphometrical parameters of the jejunum in rats is presented in Table 3. Total jejunal wall thickness did not differ between groups. FB intoxication resulted in a significant reduction in both laminae of the myenteron ( $p < 0.001$  and  $p < 0.05$ , for longitudinal and circular lamina, respectively). Moreover, the thickness of mucosa and submucosa was significantly reduced in FB-intoxicated rats ( $p < 0.05$  for both parameters). Although the number of villi did not change after FB intoxication, the villi became significantly shorter and thicker in rats from the FB group ( $p < 0.001$  for both cases). The intake of FB toxins resulted in significantly deeper crypts ( $p < 0.001$ ), a reduced absorptive surface

area in the jejunum ( $p < 0.001$ ), as well as a reduced length of villi to the depth of crypt ratio ( $p < 0.01$ ). No other changes in the jejunum were observed.

A lowered proliferation rate of intestinal gland cells and a reduced Ki index were observed in the FB group, irrespective of the section of intestine examined (Table 2 and Table 3;  $p < 0.01$  for all parameters). FB intoxication resulted in a significantly reduced area and mean diameter of the submucous plexus in the duodenum (Table 4,  $p < 0.01$  for both parameters) as well as a significant reduction in all of the parameters measured in both plexuses in the jejunum ( $p < 0.005$  for all parameters in the myenteric plexus and  $p < 0.01$  for perimeter and mean Feret diameter and  $p < 0.05$  for area and mean diameter in the submucous plexus) except sphericity. Sphericity measured in the jejunum was significantly increased ( $p < 0.001$  and  $p < 0.05$  for the myenteric and submucous plexuses, respectively; Table 5) in FB intoxicated rats.

Table 3. Effect of dietary fumonisins intoxication on the histomorphometrical parameters of the jejunum in male Wistar rats.

| Item   | Group             |                   | p-value |
|--|-------------------|-------------------|---------|
|  | Control           | Fumonisin         |         |
| Total thickness ( $\mu\text{m}$ )                      | 725 $\pm$ 85      | 742 $\pm$ 112     | n.s.    |
| Myenteron thickness ( $\mu\text{m}$ )                  |                   |                   |         |
| Longitudinal lamina                                    | 55.4 $\pm$ 10.6   | 37.7 $\pm$ 9.4    | ***     |
| Circular lamina  | 53.7 $\pm$ 14.3   | 58.8 $\pm$ 7.1    | *       |
| Mucosa thickness ( $\mu\text{m}$ )                     | 632 $\pm$ 91      | 672 $\pm$ 66      | *       |
| Submucosa thickness ( $\mu\text{m}$ )                  | 34.5 $\pm$ 8.0    | 30.7 $\pm$ 5.9    | *       |
| Villus length ( $\mu\text{m}$ )                        | 611 $\pm$ 63      | 442 $\pm$ 70      | ***     |
| Villus thickness, $\mu\text{m}$                        | 84.1 $\pm$ 13.9   | 112.8 $\pm$ 13.3  | ***     |
| Total number of villi ( $\text{mm}^{-1}$ )             | 9.61 $\pm$ 2.09   | 10.13 $\pm$ 1.02  | n.s.    |
| Villus epithelium thickness ( $\mu\text{m}$ )          | 19.6 $\pm$ 2.8    | 20.5 $\pm$ 4.3    | n.s.    |
| Crypt depth ( $\mu\text{m}$ )                          | 149 $\pm$ 26      | 192 $\pm$ 49      | ***     |
| Crypt width ( $\mu\text{m}$ )                          | 44.3 $\pm$ 7.9    | 45.4 $\pm$ 9.6    | n.s.    |
| Crypt number ( $\text{mm}^{-1}$ )                      | 20.5 $\pm$ 4.2    | 20.8 $\pm$ 2.6    | n.s.    |
| Intestine absorptive surface ( $\mu\text{m}^2$ )       | 12.96 $\pm$ 1.81  | 8.51 $\pm$ 1.52   | ***     |
| Enterocyte number per 100 $\mu\text{m}$ of villus      | 15.3 $\pm$ 1.4    | 15.3 $\pm$ 2.7    | n.s.    |
| Number of goblet cells per 100 $\mu\text{m}$ of villus | 4.72 $\pm$ 1.89   | 3.83 $\pm$ 0.99   | n.s.    |
| Villus/crypt ratio                                     | 4.21 $\pm$ 0.64   | 2.43 $\pm$ 0.81   | **      |
| Thin/thick collagen ratio                              | 0.065 $\pm$ 0.024 | 0.219 $\pm$ 0.061 | ***     |
| Ki number per 0.01 $\text{mm}^2$ of the gland surface  | 71.2 $\pm$ 13.1   | 37.4 $\pm$ 6.9    | **      |
| Ki index (%)   | 47.8 $\pm$ 11.5   | 35.5 $\pm$ 6.2    | **      |

Statistical significance: n.s. – not significant; \*  $p < 0.05$ ; \*\*  $p < 0.01$ ; \*\*\*  $p < 0.001$ .

Villus/crypt ratio – the ratio of the villi length to the crypt depth; Ki number – the number of proliferating cells; Ki index – the number of proliferating cells in relation to all gland cells.

FB intake also resulted in a significant increase of intercellular space, by 213% ( $p < 0.001$ ), and in its fractal dimension ( $p < 0.001$ ) compared to that of the control group (Table 6). Moreover, a decrease in collagen area and in its fractal dimension in the liver of FB-intoxicated rats was observed ( $p < 0.001$  for both parameters). The total number of nuclei ( $p < 0.01$ ), hepatocyte nuclei ( $p < 0.001$ ), multinuclear and mononuclear nuclei ( $p < 0.001$  and  $p < 0.05$ , respectively) were reduced in the FB group. Only the number of non-hepatocyte cells was similar in both groups.

### Collagen fibers

PSR staining was evaluated to identify the collagen maturity and the type I (thick, mature) versus type III collagen (thin, immature) fibers. The thick collagen fibers stain red or yellow and the thin collagen fibers stain green. It was possible to determine collagen maturity through the calculation of the ratio of green to red

collagen fibers (immature to mature ratio). In the control group, the amount of immature collagen fibers both in the duodenum and jejunum was significantly lower compared to that observed in the FB-intoxicated rats. The FB-intoxication also resulted in a 1.6-fold ( $p < 0.01$ ) and 3.37-fold ( $p < 0.001$ ) increase in immature collagen fibers in the duodenum and jejunum, respectively (Fig. 2; Table 2 and 3).

### Histopathological analysis of the liver tissue

Microscopic assessment of liver structure in FB-intoxicated rats showed no marked differences in portal triads and terminal hepatic venule distribution in the tissue. However, irregularity in hepatocyte cords was observed in FB intoxicated rats, as well as irregular sinusoids with blurred borders. Moreover, FB intoxication caused heterogeneous and darker staining of hepatocyte cytoplasm, showing rough endoplasmic reticulum deposits compared to that observed

Table 4. Effect of dietary fumonisins intoxication on the histomorphometrical parameters of the enteric nervous plexuses in the duodenum of male Wistar rats.

| Item                                  | Group       |             | p-value |
|---------------------------------------|-------------|-------------|---------|
|                                       | Control     | Fumonisin   |         |
| Myenteric plexus                      |             |             |         |
| Area ( $\mu\text{m}^2$ )              | 2175±1514   | 2341±1542   | n.s.    |
| Perimeter ( $\mu\text{m}$ )           | 213±110     | 223±113     | n.s.    |
| Mean Feret diameter ( $\mu\text{m}$ ) | 63.3±31.1   | 67.0±33.1   | n.s.    |
| Mean diameter ( $\mu\text{m}$ )       | 45.5±115.0  | 48.0±13.8   | n.s.    |
| Sphericity                            | 0.277±0.223 | 0.259±0.188 | n.s.    |
| Submucous plexus                      |             |             |         |
| Area ( $\mu\text{m}^2$ )              | 1114±618    | 777±378     | **      |
| Perimeter ( $\mu\text{m}$ )           | 137±42      | 120±41      | n.s.    |
| Mean Feret diameter ( $\mu\text{m}$ ) | 41.1±12.6   | 36.1±11.9   | n.s.    |
| Mean diameter ( $\mu\text{m}$ )       | 35.6±8.1    | 29.3±6.1    | **      |
| Sphericity                            | 0.442±0.178 | 0.377±0.217 | n.s.    |

Statistical significance: n.s. – not significant; \*\*  $p < 0.01$ .

Table 5. Effect of dietary fumonisins intoxication on the histomorphometrical parameters of the enteric nervous plexuses in the jejunum of male Wistar rats.

| Item                                  | Group       |             | p-value |
|---------------------------------------|-------------|-------------|---------|
|                                       | Control     | Fumonisin   |         |
| Myenteric plexus                      |             |             |         |
| Area ( $\mu\text{m}^2$ )              | 2770±1430   | 1862±1230   | ***     |
| Perimeter ( $\mu\text{m}$ )           | 272±115     | 207±102     | ***     |
| Mean Feret diameter ( $\mu\text{m}$ ) | 81.7±22.8   | 61.8±29.7   | ***     |
| Mean diameter ( $\mu\text{m}$ )       | 50.7±11.4   | 42.4±10.5   | ***     |
| Sphericity                            | 0.162±0.168 | 0.309±0.261 | ***     |
| Submucous plexus                      |             |             |         |
| Area ( $\mu\text{m}^2$ )              | 1353±1053   | 688±324     | *       |
| Perimeter ( $\mu\text{m}$ )           | 152±68      | 107±34      | **      |
| Mean Feret diameter ( $\mu\text{m}$ ) | 45.2±18.5   | 32.1±9.1    | **      |
| Mean diameter ( $\mu\text{m}$ )       | 37.3±13.7   | 27.9±7.0    | *       |
| Sphericity                            | 0.327±0.174 | 0.440±0.197 | *       |

Statistical significance: n.s. – not significant; \*  $p < 0.05$ ; \*\*  $p < 0.01$ ; \*\*\*  $p < 0.001$ .

in the control group. Ballooning symptoms as well as an increased number of Kupffer cells were also observed in the livers of the FB-intoxicated rats.

## Discussion

The dose of FBs which results in toxicity, as well as the clinical signs of toxicity vary between different

species and depend on sex and age (Ledoux et al. 1992). A diagnosis of fumonisin toxicosis is difficult and is based only on the presence of clinical signs, histopathological examination or the presence of fumonisins in the feed. Loss of body weight is not always reported. Gelderblom et al. (1994) first reported a significant decrease in body weight as a result of reduced feed intake in rats consuming FB-contaminated feed (250 mg/kg), while the consumption of fed contamina-

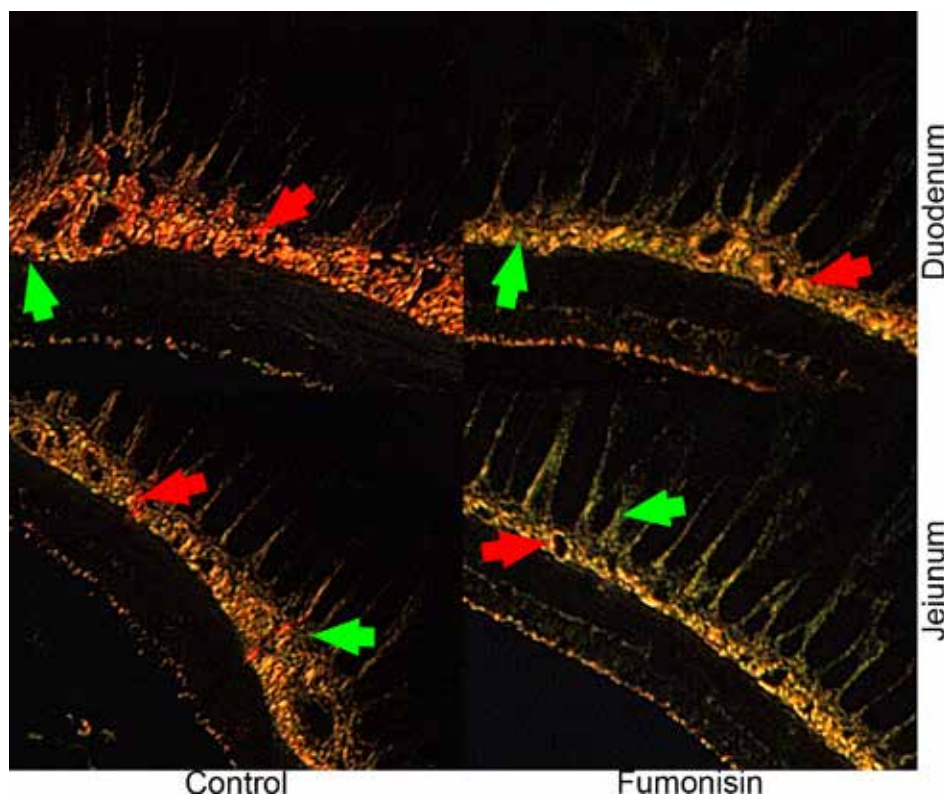


Fig. 2. Representative photographs of the collagen total area. Collagen type I – mature (red arrows) and collagen type III – immature (green arrows) in the small intestine of control and FB intoxicated male Wistar rats. The 4  $\mu$ m sections of wall intestine were PSR stained. Scale bar = 50  $\mu$ m.

Table 6. Effect of dietary fumonisins intoxication on the histomorphometrical parameters of the liver in male Wistar rats.

| Item                                     | Group             |                   | p-value |
|--|-------------------|-------------------|---------|
|  | Control           | Fumonisin         |         |
| Intercellular space (% of area fraction) | 5.62 $\pm$ 1.10   | 11.97 $\pm$ 1.106 | ***     |
| Collagen area (%)                        | 3.68 $\pm$ 0.76   | 1.44 $\pm$ 0.30   | ***     |
| Intercellular space fractal dimension    | 1.398 $\pm$ 0.048 | 1.648 $\pm$ 0.053 | ***     |
| Collagen area fractal dimension          | 1.725 $\pm$ 0.047 | 1.434 $\pm$ 0.062 | ***     |
| Number of cells (per mm <sup>2</sup> )   |                   |                   |         |
| Total nuclei                             | 375 $\pm$ 49      | 319 $\pm$ 37      | **      |
| Total hepatocyte nuclei                  | 241 $\pm$ 39      | 178 $\pm$ 23      | ***     |
| Mononuclear hepatocytes                  | 218 $\pm$ 33      | 13 $\pm$ 22       | ***     |
| Multinuclear hepatocytes                 | 23 $\pm$ 9        | 15 $\pm$ 3        | *       |
| Non-hepatocyte cells                     | 134 $\pm$ 33      | 141 $\pm$ 27      | n.s.    |

Statistical significance: n.s. – not significant; \* p<0.05; \*\* p<0.01; \*\*\* p<0.001.

ted with FB1 (50 or 100 mg/kg of feed) for 21 days did not affect feed intake and thus body weight (Abel and Gelderblom 1998). In the current study, FB-intoxication also had effect on body weight and the clinical chemistry, and histomorphometrical results support the histopathological observations that the liver is the main target organ affected by FBs. The changes in serum biochemistry parameters (including the

De Ritis ratio) observed in the FB rats are indicative of liver damage and are in agreement with previous studies that found FB1+FB2 to be hepatotoxic to rats, resulting in significantly elevated serum ALT and AST activities (Voss et al. 1995, Gelderblom et al. 1996). Significantly elevated serum amylase activity in FB-treated rats was also observed in the current study, which could be indicative of pancreatic or liver injury.

Gamma-glutamyl transferase, which is commonly used as a marker of liver disease and bile duct problems, was also significantly higher in FB-intoxicated rats. This finding is also in agreement with some previous studies that have reported fumonisin-induced pancreatic necrosis (Voss et al. 2007). Moreover, the small intestine is exposed to the highest level of FBs and the intestinal epithelial cells are in direct contact with FBs consumed in the diet. Norred et al. (1993) have shown that 80% of FB1 given to rats is excreted in the feces within 48 hours of consumption, and enterohepatic circulation prolongs the exposure of intestinal cells to FBs. Martinez-Larranaga et al. (1999) have showed that intestinal absorption of intragastrically administered FB1 (10 mg/kg body weight) in rats is low (3.5% of dose), but rapid. Similarly in pigs, the bioavailability of FB1 after intragastric administration is between 3–6% (Prelusky et al. 1995). However, whether this low bioavailability, a consequence of reduced intestinal absorption, is caused by poor transport of the FBs across the epithelium of the intestine or by the strong binding of fumonisins with the chyme, remains unclear (Bouhet and Oswald 2007).

For this reason, despite low bioavailability of FBs, oral exposure to FBs is associated with histopathological degenerative alteration in hepatocytes like mild vacuolar degeneration and ballooning, which were also observed in our rats. When changes in biochemical indicators occur in the absence of severe clinical symptoms, histopathological assessment is the only way we are able to determine the degree of advancement and classification of the pathological lesions. The histopathological assessment includes the assessment of various structures within the intestinal mucosa including: epithelium (size of enterocytes, number of goblet cells, cell infiltration), lamina propria (fibrosis), crypts (depth) and intestinal villi (length, width, shape). Many of the histopathological changes observed in our rats occurred irrespective of the section of intestine analyzed. Our present data and former studies in domestic animals suggest that FBs could impair the intestinal absorption of nutrients.

This could be partly explained by the villous fusion and atrophy observed in the intestine of pigs treated with 30 mg of FB1/kg of feed (Piva et al. 2005) and chickens fed with 61–546 mg of FB1/kg of feed (Javed et al. 2005). Hyperplasia of intestinal goblet cells and the mild to moderate tissue lesions, including villi atrophy and fusion are observed in broiler chickens and pigs exposed to FB1 (Brown et al. 1992, Grenier et al. 2012, Rauber et al. 2013). Broiler chickens fed a diet contaminated with FBs (18.6 mg FB1+FB2/kg feed) for 15 days displayed reduced small intestinal length, in the absence of any other changes in the duo-

denum and jejunum (Antonissen et al. 2015). However, reduced ileal crypt depth has also been noted (Antonissen et al. 2015).

The above mentioned results, irrespective of the section of the intestinal tract, are all related to the negative impact of FBs on intestinal epithelial cell proliferation, the reduction in villus renewal and impairment of intestinal absorption of nutrients (Bouhet and Oswald 2007, Robert et al. 2017). Proliferating cells are more sensitive to the toxic effects of FB1 than confluent cells (Bouhet et al. 2004, Antonissen et al. 2015).

There are many reports on the observed FB-induced changes in histological structure of the small intestine mucosa in various animal species. However, there is a paucity of data on the effects of FBs on the intestinal wall innervation in the duodenum and jejunum. Our study showed, for the first time, that chronic exposure to FBs by intragastric administration resulted in alterations in two nerve plexuses in the wall of the gastrointestinal tract. The submucosal plexus regulates the configuration of the intestinal luminal surface, controls glandular secretions, alters electrolyte and water transport and regulates local blood flow. The myenteric plexus controls muscle membrane motility and is particularly responsible for regulation of the frequency and contractile force of the muscle membrane of the gastrointestinal tract. The parameters investigated in both plexuses of the rats in the current study were significantly reduced. The changes in intestinal innervation and the significantly reduced myenteron observed in the rats could result in decreased secretory function of the small intestine and significantly weakened motor activity. Furthermore, our findings showed that exposure to the FBs for 21 days in rats at a dose of 0.1 of the estimated LD<sub>50</sub> could have influence the elasticity or healing process of the small intestine by influencing the ratio of different types of collagens fibers (type I and III).

We showed that FBs negatively influence small intestine regeneration and the histomorphometric parameters associated with the physiological functioning of the small intestine. FBs exposure was toxic in both the duodenum and jejunum, where significant changes in the morphology, cell proliferation, collagen wall fibers and innervation were observed. Taken together, the results obtained strengthen the hypothesis that chronic exposure to FBs could induce intestinal damage including damage to the enteric nervous system and can have consequences for overall health.

## References

- Abel S, Gelderblom WC (1998) Oxidative damage and fumonisin B1-induced toxicity in primary rat hepatocytes and rat liver in vivo. *Toxicology* 131: 121-131.
- Antonissen G, Croubels S, Pasmans F, Ducatelle R, Eeckhaut V, Devreese M, Verlinden M, Haesebrouck F, Eeckhout M, De Saeger S, Antlinger B, Novak B, Martel A, Van Immerseel F (2015) Fumonisin B1 affects the intestinal microbial homeostasis in broiler chickens, predisposing to necrotic enteritis. *Vet Res* 46: 98.
- Basso K, Gomes F, Bracarense AP (2013) Deoxynivalenol and fumonisin, alone or in combination, induce changes on intestinal junction complexes and in E-cadherin expression. *Toxins (Basel)* 5: 2341-2352.
- Botros M, Sikaris KA (2013) The De Ritis ratio: the test of time. *Clin Biochem Rev* 34: 117-130.
- Bouhet S, Hourcade E, Loiseau N, Fikry A, Martinez S, Roselli M, Galtier P, Mengheri E, Oswald IP (2004) The mycotoxin, fumonisin B1 alters the proliferation and the barrier function of porcine intestinal epithelial cells. *Toxicol Sci* 77: 165-171.
- Bouhet S, Oswald IP (2007) The intestine as a possible target for fumonisin toxicity. *Mol Nutr Food Res* 51: 925-931.
- Brown TP, Rottinghaus GE, Williams ME (1992) Fumonisin mycotoxicosis in broilers: performance and pathology. *Avian Dis* 36: 450-454.
- Burel C, Tanguy M, Guerre P, Boilletot E, Cariolet R, Queguiner M, Postollec G, Pinton P, Salvat G, Oswald IP, Fravallo P (2013) Effect of low dose of fumonisins on pig health: immune status, intestinal microbiota and sensitivity to Salmonella. *Toxins (Basel)* 5: 841-864.
- EC (European Commission) (2006) Commission Recommendation No 576/2006 of 17 August 2006 on the presence of deoxynivalenol, zearalenone, ochratoxin A, T-2 and HT-2 and fumonisins in products intended for animal feeding. *Off J Eur Union* L229:7. <https://eur-lex.europa.eu/legal-content/EN/TXT/PDF/?uri=CELEX:32006H0576&from=EN>
- FDA (Food and Drug Administration) (2001) Guidance for Industry: Fumonisin levels in human foods and animal feeds. *Federal Register*, 66: 56688-56689.
- Gelderblom WC, Cawood ME, Snyman SD, Marasas WF (1994) Fumonisin B1 dosimetry in relation to cancer initiation in rat liver. *Carcinogenesis* 15: 209-214.
- Gelderblom WC, Smuts CM, Abel S, Snyman SD, Cawood ME, van der Westhuizen L, Swanevelder S (1996) Effect of fumonisin B1 on protein and lipid synthesis in primary rat hepatocytes. *Food Chem Toxicol* 34: 361-369.
- Grenier B, Bracarense AP, Schwartz HE, Trumel C, Cossalter AM, Schatzmayr G, Kolf-Clauw M, Moll WD, Oswald IP (2012) The low intestinal and hepatic toxicity of hydrolyzed fumonisin B1 correlates with its inability to alter the metabolism of sphingolipids. *Biochem Pharmacol* 83: 1465-1473.
- Harkness JE, Wagner JE (1995) *The biology and medicine of rabbits and rodents*, 4th ed., Williams & Wilkins, Philadelphia.
- Javed T, Bunte RM, Dombink-Kurtzman MA, Richard JL, Bennett GA, Côté LM, Buck WB (2005) Comparative pathologic changes in broiler chicks on feed amended with *Fusarium proliferatum* culture material or purified fumonisin B1 and moniliformin. *Mycopathologia* 159: 553-564.
- Kierończyk B, Rawski M, Józefiak D, Świątkiewicz S (2017) Infectious and non-infectious factors associated with leg disorders in poultry – a review. *Ann Anim Sci* 17: 645-669.
- Kisielinski K, Willis S, Prescher A, Klosterhalfen B, Schumpelick V (2002) A simple new method to calculate small intestine absorptive surface in the rat. *Clin Exp Med* 2: 131-135.
- Klebianik R, Tomaszewska E, Dobrowolski P, Kwiecień M, Burmańczuk A, Yanovych D, Zasadna Z, Szymańczyk S, Burmańczuk N, Muszyński S (2018) Chloramphenicol-induced alterations in the liver and small intestine epithelium in pigs. *Ann Anim Sci* 18: 429-440.
- Ledoux DR, Brown TP, Weibking TS, Rottinghaus GE (1992) Fumonisin toxicity in broiler chicks. *J Vet Diagn Invest* 4: 330-333.
- Martinez-Larranaga MR, Anadon A, Diaz MJ, Fernandez-Cruz ML, Martinez MA, Frejo MT, Martinez M, Fernandez R, Anton RM, Morales ME, Tafur M (1999) Toxicokinetics and oral bioavailability of fumonisin B1. *Vet Hum Toxicol* 41: 357-362.
- McKean C, Tang L, Tang M, Billam M, Wang Z, Theodorakis CW, Kendall RJ, Wang JS (2006) Comparative acute and combinative toxicity of aflatoxin B1 and fumonisin B1 in animals and human cells. *Food Chem Toxicol* 44: 868-876.
- Norred WP, Plattner RD, Chamberlain WJ (1993) Distribution and excretion of [<sup>14</sup>C] fumonisin B1 in male Sprague-Dawley rats. *Nat Toxins* 1: 341-346.
- Piva A, Casadei G, Pagliuca G, Cabassi E, Galvano F, Solfrizzo M, Riley RT, Diaz DE (2005) Activated carbon does not prevent the toxicity of culture material containing fumonisin B1 when fed to weanling piglets. *J Anim Sci* 83: 1939-1947.
- Prelusky DB, Savard ME, Trenholm HL (1995) Pilot study on the plasma pharmacokinetics of fumonisin B1 in cows following a single dose by oral gavage or intravenous administration. *Nat Toxins* 3: 389-394.
- Rauber RH, Oliveira MS, Mallmann AO, Dilkin P, Mallmann CA, Giacomini LZ, Nascimento VP (2013) Effects of fumonisin B1 on selected biological responses and performance of broiler chickens. *Pesq Vet Bras* 33: 1081-1086.
- Riley RT, Voss KA (2006) Differential sensitivity of rat kidney and liver to fumonisin toxicity: organ-specific differences in toxin accumulation and sphingoid base metabolism. *Toxicol Sci* 92: 335-345.
- Robert H, Payros D, Pinton P, Théodorou V, Mercier-Bonin M, Oswald IP (2017) Impact of mycotoxins on the intestine: are mucus and microbiota new targets? *J Toxicol Environ Health B Crit Rev* 20: 249-275.
- Ross PF, Rice LG, Osweiler GD, Nelson PE (1992) A review and update of animal toxicoses associated with fumonisin-contaminated feeds and production of fumonisins by *Fusarium* isolates. *Mycopathologia* 117: 109-114.
- Rudyk H, Tomaszewska E, Kotsyumbas I, Muszyński S, Tomczyk-Warunek A, Szymańczyk S, Dobrowolski P, Wiącek D, Kamiński D, Brezvyň O (2019) Bone homeostasis in experimental fumonisin intoxication of rats. *Ann Anim Sci* 19: 403-419.

- Šegvić M, Pepeljnjak S (2001) Fumonisin and their effects on animal health - a brief review. *Vet Arhiv* 71: 299-323.
- Tomaszewska E, Dobrowolski P, Puzio I (2012) Postnatal administration of 2-oxoglutaric acid improves the intestinal barrier affected by the prenatal action of dexamethasone in pigs. *Nutrition* 28: 190-196.
- Tomaszewska E, Dobrowolski P, Puzio I, Prost Ł, Kurlak P, Sawczuk P, Badzian B, Hułas-Stasiak M, Kostro K (2014) Acrylamide-induced prenatal programming intestine structure in guinea pig. *J Physiol Pharmacol* 65: 107-115.
- Tomaszewska E, Dobrowolski P, Kwiecień M (2017) Alterations in intestinal and liver histomorphology and basal hematological and biochemical parameters in relation to different sources of dietary copper in adult rats. *Ann Anim Sci* 17: 477-490.
- Tomaszewska E, Dobrowolski P, Muszyński S, Kwiecień M, Kasperk K, Knaga S, Tomczyk-Warunek A, Kowalik S, Jeżewska-Witkowska G, Grela ER (2018a) Intestinal mucosa develops in a sex-dependent manner in Japanese quail (*Coturnix japonica*) fed *Saccharomyces cerevisiae*. *Br Poult Sci* 59: 689-697.
- Tomaszewska E, Muszyński S, Dobrowolski P, Kwiecień M, Klebaniuk R, Szymańczyk S, Tomczyk A, Kowalik S, Milczarek A, Świetlicka I (2018b) The influence of dietary replacement of soybean meal with high-tannin faba beans on gut-bone axis and metabolic response in broiler chickens. *Ann Anim Sci* 18: 801-824.
- Voss KA, Chamberlain WJ, Bacon CW, Riley RT, Norred WP (1995) Subchronic toxicity of fumonisin B1 to male and female rats. *Food Addit Contam* 12: 473-478.
- Voss KA, Smith GW, Haschek WM (2007) Fumonisin: Toxicokinetics, mechanism of action and toxicity. *Anim Feed Sci Tech* 137: 299-325.

Reproduced with permission of copyright owner. Further reproduction prohibited without permission.