



Topographical and histological evaluation of the iliolumbar veins in a South African population: A cadaveric study.

by

Arthur Tsalani Manjatika (2228141)

Supervisor

Dr Joshua Gabriel Davimes, PhD. Lecturer

School of Anatomical Sciences

University of the Witwatersrand

Co-supervisor

Dr Pedzisai Mazengenya, PhD. Senior Lecturer

School of Anatomical Sciences

University of the Witwatersrand

A Dissertation submitted to the Faculty of Health Sciences, University of the Witwatersrand, Johannesburg, in fulfilment of the requirements for the degree of Master of Science in Medicine.

Johannesburg

23rd July 2021

DECLARATION

I, Arthur Tsalani Manjatika (Student number: 2228141), declare that this Dissertation is my own, unaided work. It is being submitted for the Degree of Master of Science in Medicine at the University of the Witwatersrand, Johannesburg. It has not been submitted before for any degree or examination at any other University.

A handwritten signature in black ink, appearing to read 'Manjatika', with a stylized flourish at the end.

(Signature of candidate)

On the 23rd of July 2021 in Johannesburg, South Africa.

ABSTRACT

Introduction

Safe operative techniques to the anterior and lateral lumbar spine and the posterior abdominal wall structures require an excellent working knowledge of this region's anatomy and anatomical variations. The iliolumbar veins (ILVs) and their high frequency of variations are crucial to lumbosacral spine and pelvic region surgical interventions since their damage during surgery may result in significant hemorrhage. Therefore, the purpose of the current study was to describe the topographic anatomy and characterize the anatomical variations of the ILVs and determine the tissue composition of the ILVs in South African White cadavers.

Materials and Methods

A total of 89 adult cadavers of the White South African population were accessed from the School of Anatomical Sciences at the University of the Witwatersrand and comprised the sample size of this study. The specimens used were of known sex and age. The dissection of the ILVs was done following the standard methods. The course, morphometrics, drainage patterns, location, and relations to the lumbar plexus of the ILVs were studied and recorded. The descriptive data were analyzed using SPSS® version 23 (IBM®). Histograms and Shapiro Wilk tests were used to test for the normality of data. The comparisons for mean values were obtained using two sample student t tests. A total of 19 ILVs were harvested, and their proximal and distal sections were processed for Hematoxylin and Eosin, Masson's trichrome and Verhoeff's histological stains. The stained sections were viewed under a light microscope, and their tissue composition was determined. Specifically, the total percentage of elastin and collagen available in the ILVs and their ratio was determined using the Image J software (Fiji 2012 version).

Results

Iliolumbar veins (ILVs) were observed in 100% of the study population. The proximal iliolumbar vein (PILV) was the most prevalent, with a frequency of 93.5% of the observed cases. The maximum number of four trunks of the ILVs was observed on the left side, and this was higher in females than males ($p=0.021$). On the left side, ILVs drained primarily into the external iliac vein (EIV) while on the right side, they drained into the internal iliac vein (IIV) ($p=0.001$). The majority (64.8%) of ILVs had two tributaries. On the left side, ascending lumbar

veins (ALVs) drained the space between the 4th and 5th lumbar vertebra (L4/L5) ($p=.008$) and predominantly in males ($p=.014$). Close to half (45.8%) of ILVs anastomosed with each other. The common trunk of ALV and ILVs (ALV-ILV) anastomosed with PILVs more on the right side of the body ($p=.011$). On the left side, the ILVs terminated into the iliac vessels laterally ($p=.001$), while on the right side, the ILVs terminated into the iliac vessels posteriorly ($p=.001$). A total of 35.5% of the ILVs were in direct relation to the L4 spinal nerve root of the lumbosacral trunk. A large proportion (42.2%) of ILVs were found at the S1 vertebral level. A total of 28% of the ALVs were located at less than 30mm from the inferior vena cava (IVC), most of which occurred in females ($p=.048$) and on the right side of the body. On the left side, the PILVs had higher elastic fibres than the right side ($p=.030$). In the ILVs, the elastic to collagen fibre Area Ratio was 1: 9.

Conclusions

The current study showed that the patterns of the ILVs vary within the White South African population group similar to reports from other studied population groups in the world. Structurally, ILVs have more collagen fibres than elastic fibres in their walls, and this poses a risk for avulsion when retracted during surgery. Therefore, it is essential to identify the variant patterns of the ILVs before surgical operations to minimize bleeding and blood loss during surgery of the lumbar and sacral regions.

ACKNOWLEDGEMENTS

So many people have directly and indirectly contributed to my success in acquiring a Master's degree. Most specifically, I am grateful to the following:

- My supervisors, Dr Pedzisai Mazengeny and Dr Joshua Davimes. A big thank you for the guidance and the overall Master's degree training.
- Dr Mazengeny, thank you for the research and conference sponsorship.
- Dr Davimes, thank you for your help from the preparations room, dissection, histology lab, and all the software training. You were always there to give your helping hand.
- Thanks to Mrs. Hasiena Ali for taking your time to train me on how to process, section and stain histology slides.
- Thanks to Mr. Brandley Khoza for running up and down to help me with protective equipment throughout the dissection period.
- Thanks to Mrs. Glynis Veale for the help with conference trip preparations (paying the registration fee and booking an air ticket).
- Thanks to Prof Amadi Ihunwo for the additional learning platform in the dissection Halls.
- Thanks to the Faculty of Health Sciences Biostatistics department for all the help with statistical analysis training and consultations (specifically Zvifadzo Matsena Zingoni).
- Thanks to my employer, the University of Malawi, College of Medicine, for the study leave and scholarship.
- Thanks to Beit Trust hardship funds during the Covid 19 pandemic.
- Thanks to my guardians for always checking on me and all the encouragements, especially during the Covid 19 pandemic (Mr. J Pahuwa and Mrs. M Pahuwa)
- Thanks to my relatives, friends, and colleagues for your encouragements (Dr A. Mwakikunga, Masauli, Richard, Tinyade, Jacqueline, Phunziro, Godfrey, Kwenelle, Focus, Michael, Tawina, Nyasa, Rabelani, Asmau, Elna, Dr Hassan, Dr Abdurrahman).

CONFERENCE AND PRESENTATIONS

1. Anatomical Society of the Southern Africa (ASSA) World Day Virtual Symposium 14 October 2020. Poster presentation titled “Anatomical study of the variations of iliolumbar veins: a pilot cadaveric study”.

2. Wits Faculty of Health Sciences Virtual Research Day and Postgraduate Expo 15 October 2020. Poster presentation titled “Morphology and morphometry of the iliolumbar veins: a pilot cadaveric study”.

TABLE OF CONTENTS

Contents

DECLARATION	ii
ABSTRACT.....	iii
ACKNOWLEDGEMENTS	v
CONFERENCE AND PRESENTATIONS	vi
TABLE OF CONTENTS.....	vii
LIST OF TABLES	xi
LIST OF FIGURES	xiii
CHAPTER 1: INTRODUCTION	1
1.1 General introduction.....	1
1.2 Rationale of the study.....	3
1.3 Aims and Objectives	4
1.3.1 Aims.....	4
1.3.2 Objectives	4
CHAPTER 2: LITERATURE REVIEW	5
2.1 Anterior surgical approach technique	5
2.2. Anatomical variations	5
2.2.1 Sources of vascular anatomical variations.....	6
2.2.2 Consequences of anatomical variations.....	6
2.3. Anatomy of iliolumbar veins (ILVs).....	7
2.4. Variations of iliolumbar veins (ILVs).....	8
2.4.1 ILV trunk	8
2.4.2 Classification of ILVs.....	12
2.4.3 Topography of ILVs and Lumbosacral plexus	14
2.4.4 ILVs and Lumbosacral vertebra	15
2.4.5 ILVs and surrounding muscles	16
2.5 The morphometries of ILVs	16
2.5.1 Distance between ostium of ILV and the origin of the IVC.....	16
2.5.2 Length of ILV trunk	17
2.5.3 Distance between ostium of ILVs and the lumbosacral plexus.....	17
2.6 Histology of ILVs.....	18
2.6.1 Veins and their functions	18
2.6.2 Layers of veins.....	18

CHAPTER 3: MATERIALS AND METHODS	20
3.1 Sample	20
3.2 Cadaveric Data	20
3.2.1 Study Type and Period	20
3.2.2 Exclusion criteria	20
3.2.3 Dissection method	20
3.2.4 Morphometries of the ILVs	21
3.2.5 Intra-observer error	22
3.2.6 Inter-observer error	22
3.2.7 Statistical analysis	23
3.3 Histological data	23
3.3.1 Tissue sample and harvesting	23
3.3.2 Exclusion criteria	23
3.3.3 Selected histological site	23
3.3.4 Tissue processing	24
3.3.5 Tissue sectioning	24
3.3.6 Tissue staining	24
3.4 Evaluation of histological features	25
3.4.1 Determination of Vessel wall thickness	25
3.4.2 Elastic fibre content	26
3.4.3 Collagen fibre content	26
3.4.4 Elastic fibre to collagen fibre ratio	26
3.5 Observer bias for histological feature quantification	27
3.6 Statistical analysis	27
CHAPTER 4: RESULTS	28
4.1 Demographic data (Age, weight, and height)	28
4.2 Variations of ILVs	28
4.2.1 Prevalence of ILVs	28
4.2.2 Number of ILV main trunks/stems	32
4.2.3 Terminal drainage of ILVs	33
4.2.4 Tributaries of ILVs	39
4.2.5 Tributary draining sites	43
4.2.6 Anastomosis of ILVs	45
4.2.7 Entry positioning of ILVs into terminal drainage	49
4.3 Classification of ILVs	50

4.4 Topography of ILVs.....	52
4.4.1 ILVs and Lumbar plexus	52
4.4.2 ILVs location on the Lumbosacral vertebral regions	56
4.5 Morphometry of ILVs	61
4.5.1 Distance from the origin of IVC to ostia of ILVs.....	61
4.5.2 Length of ILV trunks.....	63
4.5.3 Distance from obturator nerve (ON) to ILVs ostia.....	65
4.5.4 Iliolumbar veins and the lumbosacral trunk (LST)	67
4.6 Histology of ILVs.....	72
4.6.1 ILV wall tissue composition.....	72
4.6.2 Vessel wall thickness (in mm).....	74
4.6.3 Elastic fibre percentage area.....	75
4.6.4 Collagen fibre percentage area	76
4.6.5 Elastic to collagen percentage area ratio	77
CHAPTER 5: DISCUSSION.....	79
5.0 Introduction	79
5.1 Demographic data	79
5.2 Variations of ILVs.....	80
5.2.1 Prevalence of ILVs	80
5.2.2 Number of ILV main trunks/stems.....	82
5.2.3 Terminal drainage of ILVs	83
5.2.4 Tributaries of ILVs	86
5.2.5 Drainage sites of the ILV tributaries	88
5.2.6 Anastomosis of ILV tributaries	89
5.2.7 Entry positioning of ILVs into terminal drainage	90
5.3 Classification of ILVs (Unruh classification)	91
5.4 Topography of ILVs.....	93
5.4.1 ILVs and Lumbar plexus (Obturator nerve and lumbosacral trunk)	93
5.4.2. Obturator nerve (ON) and ILVs	93
5.4.3 Lumbosacral trunk (LST) and iliolumbar veins (ILVs)	94
5.4.4 ILVs and Lumbosacral vertebra	96
5.5 Morphometrics of ILVs.....	99
5.5.1 Distance between the ostium of the ILV and the origin of inferior vena cava (IVC)	99
5.5.2 Length of ILV trunks.....	100

5.5.3 Distance between obturator nerve (ON) and iliolumbar veins (ILVs)	101
5.5.4 Distance between Lumbosacral trunk (LST) and ILVs	102
5.6 Histology of the ILVs.....	104
5.6.1 ILV layers and thickness	104
5.6.2 Elastic and collagen fibres content	104
CHAPTER 6: RECOMMENDATIONS AND CONCLUSION	106
6.1 Limitations	106
6.2 Recommendation for further studies	106
6.3 Conclusions	106
REFERENCES	108
Appendix 1: Histological tissue processing and staining.	125
Appendix 2: Cadaveric data collection tool.....	129
Appendix 3: Color area percentage calculations	131
Appendix 4: Ethical Clearance	134

LIST OF TABLES

Chapter 2

Table 2.1: Prevalence of Iliolumbar veins (ILVs) across population groups	9
Table 2.2: The number of ILV main trunks across population groups	10
Table 2.3: Classification of Iliolumbar veins (ILVs) by Unruh et al. (2008).	13
Table 2.4: The distance from the Ostium of ILV and the origin of the IVC across population groups.....	17

Chapter 4

Table 4.1: The age, sex, weight, and height distribution among the cadaveric sample.....	28
Table 4.2: Prevalence of the iliolumbar vein (ILV) trunks in relation to laterality.....	29
Table 4.3: The number of Iliolumbar vein (ILV) trunks and their distribution between sex and laterality.....	33
Table 4.4: The proportional distribution of the types of anastomosis present with sex and laterality.	46
Table 4.5: The relation of the direction of ILVs entry into terminal drainage and laterality.	49
Table 4.6: Sex and laterality distribution of ILVs using Unruh et al. (2008) Classification system.	50
Table 4.7: The Obturator nerve (ON) course in relation to all ILVs and laterality.	52
Table 4.8: The course of the L4 spinal nerve root of LST (L4/LST) in relation to all ILV trunks and laterality.....	54
Table 4.9: The course of the L5 spinal nerve root of LST (L5/LST) in relation to all ILV trunks and laterality.....	54
Table 4.10: The course of the Lumbosacral trunk (LST) in relation to ILV trunks and laterality.	55
Table 4.11: The general location of ILVs on the lumbosacral vertebra.	57
Table 4.12: The mean distances from the origin of the inferior vena cava (IVC) to the ILVs between sex and laterality.....	62
Table 4.13: The range of ILV trunks length between sex and laterality.....	64
Table 4.14: The mean length of ILV trunks between sex and laterality.....	64
Table 4.15: The median and interquartile (IQ) range of distance from ON to ILV trunks between the sex and laterality.....	66
Table 4.16: The range of distance from L4/LST to ILV trunks between the sex and laterality.....	68
Table 4.17: The mean distances and standard deviations (SD) from L4/LST to ILVs ostia between sex and laterality.....	68
Table 4.18: The range of distance from L5/LST to ILVs ostia between the sex and laterality.....	69
Table 4.19: The mean distances and standard deviations (SD) from L5/LST to ILVs ostia between sex and laterality.....	70
Table 4.20: The range of distance from LST to ILV trunks between the sex and laterality... ..	71
Table 4.21: The mean distances and standard deviations (SD) from LST to ILVs ostia between sex and laterality.....	71

Chapter 5

Table 5.1: Prevalence of Iliolumbar vein (ILV) trunks across populations.	81
Table 5.1: Prevalence of Iliolumbar vein (ILV) trunks across populations.....	81
Table 5.2: Proportions of the number of ILVs across populations.	83
Table 5.3: Terminal drainage of the iliolumbar veins (ILVs) across populations.	85
Table 5.4: Classification of the iliolumbar veins (ILVs) by Unruh et al. (2008) across population groups.....	93

LIST OF FIGURES

Chapter 2

Figure 2.1: A diagram showing the arrangement of veins and anatomy of the iliolumbar veins (ILVs). Photograph adapted and modified from (Kostov *et al.*, 2021). IVC= Inferior vena cava; CIV= Common iliac vein; ALV= Ascending lumbar vein; AV= Azygous vein; HV= Hemizygous vein; LV= Lumbar veins; LRV= Left renal vein; RRV= Right renal vein. 8

Figure 2.2: A diagram showing the iliolumbar vein (ILV) drainage pattern variations. Photograph adapted and modified from (Kostov *et al.*, 2021) ILV drains into 1=EIV; 2= Confluence of CIV; 3=IIV; 4=CIV. CIV= Common iliac vein, EIV= External iliac vein, IIV= Internal iliac vein, Rt= Right side, Lt= Left side). 11

Figure 2.3: A photograph showing the direction of entry of iliolumbar veins (ILVs) into terminal drainage. S= Superior, I= Inferior, M= Medial, L= Lateral. 12

Figure 2.4: A photograph showing ILV classification by Unruh *et al.* (2008). Red arrow pointing at ILVs. CIV= Common iliac vein, ALV= Ascending lumbar vein, ALV-ILV= Ascending lumbar vein and Iliolumbar vein common trunk, PILV= Proximal iliolumbar vein, DILV= Distal iliolumbar vein, Lt= Left, Rt= Right, S= Superior, I= Inferior, M= Medial, L= Lateral. 14

Figure 2.5: A photomicrograph of the vein stained with Hematoxylin and Eosin (H&E) showing the layers of the wall. 19

Chapter 3

Figure 3.1: A diagram showing red arrows illustrating the morphometries that were taken (a-d). Diagram adapted and modified from Unruh *et al.* (2008). IVC= Inferior vena cava, ILV= Iliolumbar veins, ON= Obturator nerve, LST= Lumbosacral trunk. 22

Figure 3.2: A photograph showing selected sites (circled in red color) for tissue harvesting. S= Superior, I= Inferior, M= Medial, L= Lateral. 24

Figure 3.3: A photomicrograph showing measurements taken to determine the vessel wall thickness on one segment of a tissue section. 26

Chapter 4

Figure 4.1 A photograph (A-B) showing ILV trunks circled in red. (A) ALV-ILV trunk and (B) ALV and PILV trunks. ALV= Ascending lumbar vein, ALV-ILV= Ascending lumbar vein and Iliolumbar vein common trunk, PILV= Proximal iliolumbar vein, IVC= Inferior vena cava, CIV= Common iliac vein, EIV= External iliac vein, IIV= Internal iliac vein, Rt= Right side, Lt= Left side, S= Superior, I= Inferior, M= Medial, L= Lateral. 30

Figure 4.2: A photograph (A-C) showing the combination of ILV trunks circled in red. (A) ALV, PILV and DILV trunks; (B) ALV-ILV, PILV and DILV trunks; (C) ALV, PILV, DILV and AILV trunks. ALV= Ascending lumbar vein, ALV-ILV= Ascending lumbar vein and Iliolumbar vein common trunk, PILV= Proximal iliolumbar vein, DILV= Distal iliolumbar vein, AILV= Accessory iliolumbar vein, IVC= Inferior vena cava, CIV= Common iliac vein, EIV= External iliac vein, IIV= Internal iliac vein, Rt= Right side, Lt= Left side, S= Superior, I= Inferior, M= Medial, L= Lateral..... 31

Figure 4.3: A bar graph showing proportional distributions of iliolumbar veins (ILVs) amongst sex and laterality. ALV= Ascending lumbar vein, ALV-ILV= Ascending lumbar vein and Iliolumbar vein common trunk, PILV= Proximal iliolumbar vein, DILV= Distal iliolumbar vein, AILV= Accessory iliolumbar vein.32

Figure 4.4: A photograph (A-D) showing the number of ILV trunks circled in blue. (A) One ILV; (B) Two ILVs; (C) Three ILVs; (D) Four ILVs. ILV= Iliolumbar vein, IVC= Inferior vena cava, CIV= Common iliac vein, EIV= External iliac vein, IIV= Internal iliac vein, Rt= Right side, Lt= Left side, S= Superior, I= Inferior, M= Medial, L= Lateral.33

Figure 4.5: A photograph (A-C) showing the terminal drainage of ILVs circled in yellow. ILVs were draining into (A) IIV; (B) CIV; (C) EIV. ALV= Ascending lumbar vein, ALV-ILV= Ascending lumbar vein and Iliolumbar vein common trunk, PILV= Proximal iliolumbar vein, DILV= Distal iliolumbar vein, Rt= Right side, Lt= Left side, S= Superior, I= Inferior, M= Medial, L= Lateral.35

Figure 4.6: A bar graph showing Ascending lumbar vein (ALV) terminal drainage in relation to sex. CIV= Common iliac vein, EIV= External iliac vein, IIV= Internal iliac vein, IVC= Inferior vena cava.36

Figure 4.7: A bar graph showing Ascending lumbar vein and Iliolumbar vein common trunk (ALV-ILV) terminal drainage in relation to sex. CIV= Common iliac vein, EIV= External iliac vein, IIV= Internal iliac vein.37

Figure 4.8: A bar graph showing Proximal iliolumbar vein (PILV) terminal drainage in relation to sex. CIV= Common iliac vein, EIV= External iliac vein, IIV= Internal iliac vein. * $p < 0.05$, ** $P \leq 0.01$, *** $p < 0.001$37

Figure 4.9: A bar graph showing Distal iliolumbar vein (DILV) terminal drainage in relation to sex. CIV= Common iliac vein, EIV= External iliac vein, IIV= Internal iliac vein. ** $P \leq 0.005$38

Figure 4.10: A bar graph showing Accessory iliolumbar vein (AILV) terminal drainage in relation to sex. CIV= Common iliac vein, EIV= External iliac vein, IIV= Internal iliac vein, IIV&EIV= drainage into both Internal iliac vein and External Iliac vein.38

Figure 4.11: A bar graph showing proportions of tributaries in all Iliolumbar vein (ILV) trunks. ALV= Ascending lumbar vein, ALV-ILV= Ascending lumbar vein and Iliolumbar vein common trunk, PILV= Proximal iliolumbar vein, DILV= Distal iliolumbar vein, AILV= Accessory iliolumbar vein.39

Figure 4.12: A bar graph showing the distribution of Ascending lumbar vein (ALV) tributaries among sex and laterality.40

Figure 4.13: A bar graph showing the distribution of Ascending lumbar vein and Iliolumbar vein common trunk (ALV-ILV) tributaries among sex and laterality.41

Figure 4.14: A bar graph showing the distribution of Proximal iliolumbar vein (PILV) tributaries among sex and laterality.41

Figure 4.15: A bar graph showing the distribution of Distal iliolumbar vein (DILV) tributaries among sex and laterality.42

Figure 4.16: A bar graph showing the distribution of Accessory iliolumbar vein (AILV) tributaries among sex and laterality.42

Figure 4.17: A photograph (A-B) showing tributaries draining sites for iliolumbar veins circled in red. Dashed arrows are pointing at tributaries of ILVs. (A) ALV drainage sites and (B) PILV draining sites. ALV= ascending lumbar vein, PILV= proximal iliolumbar vein,

EIV= External iliac vein, IIV= Internal iliac vein, Lt= Left side, Rt= Right side, S= Superior, I= Inferior, M= Medial, L= Lateral.....	44
Figure 4.18: A photograph (A-B) showing tributaries draining sites for ILVs circled in red. Dashed arrows are pointing at tributaries of ILVs. (A) DILV drainage sites and (B) AILV draining sites. ALV= Ascending lumbar vein, PILV= Proximal iliolumbar vein, DILV= Distal iliolumbar vein, AILV= Accessory iliolumbar vein, S= Superior, I= Inferior, M= Medial, L= Lateral.	45
Figure 4.19: A photograph (A-B) showing single anastomosis of the ILVs circled in purple. Anastomosing tributaries are highlighted with red dotted lines. (A) Type 1; (B) Type 3. ALV= Ascending lumbar vein, PILV= Proximal iliolumbar vein, ALV-ILV= Ascending lumbar vein and Iliolumbar vein common trunk, S= Superior, I= Inferior, M= Medial, L= Lateral.	47
Figure 4.20: A photograph (A-B) showing single and double anastomosis of the ILV circled in purple. Anastomosing tributaries are highlighted with red dotted lines. (A) Type 4; (B) Type 6. ALV= Ascending lumbar vein, PILV= Proximal iliolumbar vein, ALV-ILV= Ascending lumbar vein and Iliolumbar vein common trunk, DILV= Distal iliolumbar vein, AILV= Accessory iliolumbar vein, S= Superior, I= Inferior, M= Medial, L= Lateral.	48
Figure 4.21: A photograph showing triple anastomosis (Type 7) of the ILV circled in purple. Anastomosing tributaries are highlighted with red dotted lines. ALV= Ascending lumbar vein, PILV= Proximal iliolumbar vein, ALV-ILV= Ascending lumbar vein and Iliolumbar vein common trunk, DILV= Distal iliolumbar vein, AILV= Accessory iliolumbar vein, S= Superior, I= Inferior, M= Medial, L= Lateral.	49
Figure 4.22: A photograph showing the entry position of the iliolumbar veins (ILVs). Red arrows showing directions of ILVs entry into terminal drainage. S= Superior, I= Inferior, M= Medial, L= Lateral.	50
Figure 4.23: A photograph (A-C) showing the classification of iliolumbar veins by Unruh et al. (2008). ILVs circled in red. (A) Type 1; (B) Type 2; (C) Type 3. ALV= Ascending lumbar vein, PILV= Proximal iliolumbar vein, ALV-ILV= Ascending lumbar vein and Iliolumbar vein common trunk, DILV= Distal iliolumbar vein, AILV= Accessory iliolumbar vein, S= Superior, I= Inferior, M= Medial, L= Lateral.	51
Figure 4.24: A photograph (A-B) showing the course of the obturator nerve in relation to Iliolumbar vein (ILV) trunks. (A) Anterior course to ILVs (red circles); (B) Anterior course (blue circles) and inferior course to ALV (yellow arrow and circle). ALV= Ascending lumbar vein, ALV-ILV= Ascending lumbar vein and Iliolumbar vein common trunk, PILV= Proximal iliolumbar vein, DILV= Distal iliolumbar vein, CIV= Common iliac vein, Rt= Right side, S= Superior, I= Inferior, M= Medial, L= Lateral.	53
Figure 4.25: A photograph (A-B) showing relations of the lumbosacral trunk (LST) and iliolumbar veins (ILV). (A) LST coursing posterior to ILVs; (B) ILV sandwiched between the L4 and L5 spinal nerve roots of the LST. PILV= Proximal iliolumbar veins, S= Superior, I= Inferior, M= Medial, L= Lateral.	56
Figure 4.26: A bar graph showing the specific location of Ascending lumbar veins (ALVs) on the lumbosacral vertebra.	58
Figure 4.27: A bar graph showing the specific location of the Ascending lumbar vein and iliolumbar vein common trunk (ALV-ILVs) on the lumbosacral vertebra.	58
Figure 4.28: A bar graph showing the specific location of the Proximal iliolumbar veins (PILVs) on the lumbosacral vertebra.	59

Figure 4.29: A bar graph showing the specific location of the Distal iliolumbar veins (DILVs) on the lumbosacral vertebra.	60
Figure 4.30: A bar graph showing the specific location of the Accessory iliolumbar veins (AILVs) on the lumbosacral vertebra.	61
Figure 4.31: A bar graph showing the mean distances from the origin of inferior vena cava (IVC) to iliolumbar veins (ILVs) ostia between sides of the body and sex. Values with no standard deviation (SD) had no error bars.	63
Figure 4.32: A bar graph showing the mean length of ILV trunks between sides of the body and sex. Values with no standard deviation (SD) had no error bars (AILV trunks).....	65
Figure 4.33: A photograph showing the intersections (red circle) of the obturator nerve in relation to ILV trunks. (A) There is no intersection with the ALV-ILV trunk; (B) Intersection at the midpoint of the PILV trunk, (C) Intersection at the ostium of DILV. PILV= Proximal iliolumbar vein, ALV-ILV= Ascending lumbar vein and iliolumbar vein common trunk, DILV= Distal iliolumbar vein, S= Superior, I= Inferior, M= Medial, L= Lateral.	67
Figure 4.34: A photomicrograph of an H & E stained section showing the presence of all tunicae in the iliolumbar vein walls.	72
Figure 4.35: A photomicrograph of a Masson's trichrome stained section, showing the presence of collagen fibres in the iliolumbar vein layers (green color).....	73
Figure 4.36: A photomicrograph showing a smooth muscle synthesizing and secreting collagen fibres in the iliolumbar veins. Yellow dashed lines show collagen within smooth muscles. Black arrows show collagen surrounding smooth muscles.	73
Figure 4.37: A photomicrograph of Verhoeff's stained section showing the presence of elastic fibres (black color) in the iliolumbar vein layers. Red dashed arrows showing scattered elastic fibres.	74
Figure 4.38: A bar graph showing the mean wall thickness measurements for iliolumbar veins (ILV).....	75
Figure 4.39: A bar graph showing the mean elastic fibre percentage area for the iliolumbar veins. PILV= Proximal iliolumbar vein, DILV= Distal iliolumbar vein.	76
Figure 4.40: A bar graph showing mean collagen fibre percentage area for iliolumbar veins (ILV). PILV= Proximal iliolumbar vein, DILV= Distal iliolumbar vein.	77
Figure 4.41: A bar graph showing elastin to collagen fibre percentage area for iliolumbar veins (ILVs).	78

LIST OF ABBREVIATIONS

AILV = Accessory iliolumbar vein

ALV = Ascending Lumbar vein

CIV = Common iliac vein

DILV = Distal iliolumbar vein

EIV = External iliac vein

EVG = Elastin Van Gieson's

H&E = Hematoxylin and Eosin

IIV = Internal iliac vein

ILV = Iliolumbar vein

IVC = Inferior vena cava

LST = lumbosacral trunk

L4 = Lumbar vertebra level 4

L5 = Lumbar vertebra level 5

L4/L5 = Intervertebral disc space between lumbar vertebra level 4 and 5

L4-L5 = Region between vertebral level 4 and 5

L4/LST= L4 spinal nerve root of the lumbosacral trunk

L5/LST= L5 spinal nerve root of the lumbosacral trunk

L5/S1 = Intervertebral disc space between lumbar vertebral level 5 and sacral vertebra level 1

MM = Millimeters

ON = Obturator nerve

PILV = Proximal iliolumbar vein

S1 = Sacral vertebra level 1

S2 = Sacral vertebra level 2

SPSS = Statistical package for social scientist

CHAPTER 1: INTRODUCTION

1.1 General introduction

The use of the anterior retroperitoneal surgical approach to the lumbosacral spine is preferred during pelvic and spinal surgery (Tribus and Belanger, 2001; Hamid *et al.*, 2007; Hamdan *et al.*, 2008; Chiriano *et al.*, 2009; Asha *et al.*, 2012; Klezl *et al.*, 2014; Bateman *et al.*, 2015; Smith *et al.*, 2017; Bassani *et al.*, 2019; Pelletier *et al.*, 2021). This approach has advanced to cover all aspects of spinal surgery, ranging from deformity, degenerative diseases, and trauma (Holt *et al.*, 2003; Wood *et al.*, 2010; Czerwein *et al.*, 2011; Hrabalek *et al.*, 2012; Barrey *et al.*, 2013; Phan *et al.*, 2017; Xu *et al.*, 2018; Benrashid *et al.*, 2020). The advantage of this approach includes enhanced alignment of the spine in spinal fusion procedures, implant of devices in degenerative disc diseases and performance of discectomy (Brewster *et al.*, 2008; Sheng *et al.*, 2008; Pinson *et al.*, 2017; Zairi *et al.*, 2017; Davis *et al.*, 2019). It exposes fewer vertebral spine levels, which decreases muscle damage (Czerwein *et al.*, 2011; Barrey *et al.*, 2013; Nalbandian *et al.*, 2013; Phan *et al.*, 2017; Zairi *et al.*, 2017). Retraction of the great vessels to adequately expose the lumbosacral junction and 4th and 5th lumbar intervertebral (L4/L5) disc spaces during anterior approaches has significant complications, with vascular injuries, especially of the iliolumbar veins (ILVs), being the most common and devastating consequences in this area (Baker *et al.*, 1993; Gumbs *et al.*, 2005; Ikard, 2006; Inamasu and Guiot, 2006; Khamanarong *et al.*, 2009; Fantini and Pawar, 2013; Bateman *et al.*, 2015; Woods *et al.*, 2017; Manunga *et al.*, 2020).

Vascular injuries during the anterior exposure are potentially life-threatening (Nguyen *et al.*, 2006; Schwender *et al.*, 2009; Chou *et al.*, 2016). Minor vascular injuries are any cases in which sutures are required to control bleeding (Asha *et al.*, 2012; Mobbs *et al.*, 2016). Major vascular injuries are described as any cases that need a transfusion, multi-suturing and vessel reconstruction or those resulting in blood loss higher than 300 ml (Hamdan *et al.*, 2008; Chiriano *et al.*, 2009; Asha *et al.*, 2012; Nourian *et al.*, 2016). In extreme cases, intraoperative multiple vascular injuries can lead to blood loss of about 5000 ml (Nguyen *et al.*, 2006). Mechanisms of injury to vascular structures include excessive traction, avulsion and/or laceration (Escobar *et al.*, 2003; Santos *et al.*, 2008; Schwender *et al.*, 2009; Hrabalek *et al.*, 2012; Klezl *et al.*, 2014). The occurrence of most intraoperative vascular injuries is due to incorrect identification, dissection, and control of vessels during the exposure phase as opposed

to the surgical procedure itself (Rajaraman *et al.*, 1999; Brau *et al.*, 2004; Nguyen *et al.*, 2006; Hamdan *et al.*, 2008; Nourian *et al.*, 2016; Manunga *et al.*, 2020). Unknown variation of the typical vascular anatomy contributes greatly to these injuries (Weiner *et al.*, 2001; Hamdan *et al.*, 2008). Disastrous sequelae of vascular injuries include hypotension, shock and death in some acute cases, false aneurysm, and thromboembolism have been previously reported (Ikard, 2006; Nguyen *et al.*, 2006; Platzer *et al.*, 2006; Santos *et al.*, 2008; Glotzbecker *et al.*, 2009; Barrey *et al.*, 2013; Pinson *et al.*, 2017; Reilly *et al.*, 2017).

Venous injuries occur more frequently than arterial injuries during the retraction and mobilization of vessels to expose the vertebral region of interest (Rajaraman *et al.*, 1999; Gumbs *et al.*, 2005; Brewster *et al.*, 2008; Asha *et al.*, 2012; Nalbandian *et al.*, 2013; Manunga *et al.*, 2020). Many of these injuries occur at the 4th and 5th lumbar (L4–L5) vertebral level (Kiray *et al.*, 2004; Hamid *et al.*, 2007; Schwender *et al.*, 2009; Wood *et al.*, 2010; Czerwein *et al.*, 2011; Asha *et al.*, 2012; Hrabalek *et al.*, 2012; Liu, 2012; Zahradnik and Kashyap, 2012). The L4–L5 level, in particular, poses difficulties to surgeons because the common iliac vessels course over the anterior surface of the body of the L5 vertebra from right to left, and vessel handling in this area can lead to accidental vascular laceration or avulsion (Oskouian and Johnson, 2002; Gumbs *et al.*, 2005; Kang *et al.*, 2006; Brewster *et al.*, 2008; Santos *et al.*, 2008; Eck and Vaccaro, 2013; Kim *et al.*, 2013).

The iliolumbar vein (ILV) drains the psoas and iliac fossa muscles and the L4-L5 lumbar vertebral regions (Jasani and Jaffray, 2002; Hamid *et al.*, 2007; Davis *et al.*, 2019). The vein is normally encountered during the exposure of the lumbosacral junction and 4th and 5th lumbar intervertebral (L4/L5) space (Jasani and Jaffray, 2002; Czerwein *et al.*, 2011; Winder and Gambhir, 2016; Chung *et al.*, 2020). Due to its proximity to these structures, the ILV is vulnerable during surgery and its injuries often leading to severe hemorrhage (Czerwein *et al.*, 2011; Davis *et al.*, 2019). Iatrogenic vascular injuries have been reported to range from 1% up to 24% (Holt *et al.*, 2003; Brewster *et al.*, 2008; Chiriano *et al.*, 2009; Asha *et al.*, 2012; Nalbandian *et al.*, 2013; Teli *et al.*, 2013). It is therefore recommended to initially identify and ligate the vein to allow for safe exposure and reduce bleeding during surgery (Jasani and Jaffray, 2002; Brewster *et al.*, 2008; Hrabalek *et al.*, 2014). The surgical ligation of the ILV does not affect the venous circulation of the affected regions due to extensive collateral circulation (Hamid *et al.*, 2007; Kachlik *et al.*, 2010).

Reducing the ILV complications is dependent on the knowledge of its detailed anatomy (Chiriano *et al.*, 2009; Lolis *et al.*, 2011). Understanding the ILV detailed anatomy has been made difficult due to its higher variability in anatomical presentation and the limited comprehensive anatomical description studies (Jasani and Jaffray, 2002; Kiray *et al.*, 2004; Hamdan *et al.*, 2008). The variability seems to be population specific (Sheng *et al.*, 2008; Lolis *et al.*, 2011). The current study examined the topographic anatomy of ILVs and their histological composition in a White South African population. Knowledge of the variant anatomy of the ILVs is vital to reduce intraoperative vascular complications and improves patient outcomes (Davis *et al.*, 2019). The incidence of variations of the ILVs has not received much attention, especially in African countries. In this era of improved quality of healthcare and a continuous quest for better ways to manage patients, thorough knowledge of normal anatomy and their variations are vital (Wind and Valentine, 2013; Yammine, 2014). Most importantly, precise descriptions of these variations should be examined across the population, sex, and age groups to guide clinicians globally (Yammine, 2014).

1.2 Rationale of the study

The ILVs are considered highly variable, like many other veins, but there is a lack of information on the detailed variant patterns of these veins considering their proximity and involvement in lumbar spine surgery. The available literature on the anatomy of ILVs comprises small case series and studies with low sample sizes and no conclusive information on their histology and variant patterns in different populations. In addition, the available classification systems of these important veins are often vague. Therefore, the purpose of the current study is to provide a more thorough and precise description of the topographic anatomy and tissue composition of the ILVs in a large sample of White South African cadavers.

1.3 Aims and Objectives

1.3.1 Aims

To describe the normal macro- and micro-anatomy and anatomical variations of the iliolumbar veins in an adult White South African cadaveric cohort.

1.3.2 Objectives

1. To determine course and drainage patterns of iliolumbar veins
2. To describe the relations of iliolumbar veins with the lumbar plexus (ON and LST)
3. To determine the position of iliolumbar veins in relations to the lumbosacral vertebral spine
4. To determine the morphometries of the iliolumbar veins (length and distance to nearby structures)
5. To describe the tissue composition (wall thickness, elastic, and collagen fibre content) of iliolumbar veins.

CHAPTER 2: LITERATURE REVIEW

2.1 Anterior surgical approach technique

The anterior surgical approach to the lumbosacral spine is performed through the anterior abdominal wall to provide optimum vision and access to the anterior spine to perform any indicated surgical procedure (Holt *et al.*, 2003; Eck and Vaccaro, 2013; Kim *et al.*, 2013; Phan *et al.*, 2017). Successful performance of this procedure requires adequate knowledge of the vascular, nervous, and overlying abdominal viscera as it utilizes the potential space between peritoneal contents and the kidneys and the psoas muscle (Bianchi *et al.*, 2003; Ikard, 2006; Eck and Vaccaro, 2013; Kim *et al.*, 2013). This approach can be done retroperitoneally or transperitoneally (Nguyen *et al.*, 2006; Kim *et al.*, 2013; Phan *et al.*, 2017). The retroperitoneal approach is the most used as it avoids mobilization of enteric structures (Scaduto *et al.*, 2003; Eck and Vaccaro, 2013; Phan *et al.*, 2017). The retroperitoneal approach also minimizes intra-abdominal injury risk (Bianchi *et al.*, 2003; Brewster *et al.*, 2008). The left side retroperitoneal approach is mainly preferred because the abdominal aorta is retracted more easily and safely than the inferior vena cava (IVC) (Ikard, 2006; Brewster *et al.*, 2008; Chiriano *et al.*, 2009; Schwender *et al.*, 2009; Eck and Vaccaro, 2013; Klezl *et al.*, 2014).

2.2. Anatomical variations

Anatomical variations are mild deviations to the morphology and topography of typical body structures (Satti *et al.*, 2007; Sikka and Jain, 2012; Wind and Valentine, 2013). In general, their frequencies range from 30% to 50% in clinical practice (Wind and Valentine, 2013). Often, they do not affect the body's normal physiology (Moore *et al.*, 2018). They are mostly incidental findings during routine students' dissections or during imaging, surgical procedures, and autopsies (Straus and Temkin, 1943; Moore *et al.*, 2018; Hamabe *et al.*, 2020). Occasionally, some are discovered upon the manifestation of usual or unusual symptoms (Moore *et al.*, 2018; Sañudo *et al.*, 2021). Cadaveric dissections provide the best way of discovering these anatomical variations owing to the nature of wide exposure of structures provided by this method (Moore *et al.*, 2018).

Anatomical variations are broadly grouped into morphometric (size), occurrence (presence or absence or multiple) and spatial (origin, branching patterns, drainage areas, course) (Wind and Valentine, 2013; Yammine, 2014). These variations range from those normal and harmless to those incompatible with life (Moore *et al.*, 2018).

A variation may be clinically significant in one population, which may not be the case in another population (Sañudo *et al.*, 2021). The knowledge of anatomical variation becomes essential to clinicians working with diverse population groups. Besides, individuals of the same species do not usually have identical anatomy of structures, and these variations may also be related to sex and laterality (left or right side of the body) (Moore *et al.*, 2018; Sañudo *et al.*, 2021).

2.2.1 Sources of vascular anatomical variations

Structural anatomical variations may be caused by aberrant processes of vascular embryologic developmental timing and persistence of structures that are destined to obliterate (Sikka and Jain, 2012; Wind and Valentine, 2013). These errors may be triggered by genetic, chromosomal, environmental factors or a combination of all (Moore *et al.*, 2018; Sañudo *et al.*, 2021). Considerable variations exist in the branching patterns of neurovascular structures, and most of these occur in veins (Uhl *et al.*, 2010; Moore *et al.*, 2018). Venous malformations occur during the embryo's late development because of multiple channels in which veins may develop and flow (Uhl *et al.*, 2010; Almeida, 2018). These variations may be in the trunk's number or the caliber, and its tributaries and such a range of possibilities have different clinical impacts (Uhl *et al.*, 2010).

During development, the arrangement of veins usually parallels the neuronal networks (Uhl *et al.*, 2010). This arrangement is because nerves develop first, and the Schwann cells that coat them secrete vascular endothelial growth factors that attract developing veins to their proximity (Uhl *et al.*, 2010). Therefore, unrecognized variations of veins may put additional injury risks to the surrounding neuronal structures during surgical procedures (Ellis, 2002; Uhl *et al.*, 2010).

Variations of the lumbosacral and pelvic venous systems are very frequent and are of clinical importance owing to the surgical procedures done in this region (Kachlik *et al.*, 2010; Vidal *et al.*, 2010; Venieratos *et al.*, 2012; Wind and Valentine, 2013; Shin *et al.*, 2015; DePietro *et al.*, 2020; Hamabe *et al.*, 2020). While some authors attempted to describe these variations, it is still evident that not all anatomical variations, especially those of the ILVs, have been precisely described (Vilensky and Carmichael, 2010; Hamabe *et al.*, 2020).

2.2.2 Consequences of anatomical variations

Most of the anatomical variations are asymptomatic and remain undetected unless they cause malfunctioning of body organs in any way (Moore *et al.*, 2018; Sañudo *et al.*, 2021). Under certain conditions like surgical operations, these unrecognized harmless variations may have

significant adverse effects, like profuse haemorrhage in the event of accidental injury to veins (Sañudo *et al.*, 2021). These variations are also essential in intravascular diseases like arteriovenous malformations and occlusion (Shoja *et al.*, 2006; Sikka and Jain, 2012).

The presence of these variations may mimic some known or unknown pathology during diagnostic imaging, and patients may have to be exposed to unnecessary tests (Freeman *et al.*, 2019). In patients with actual pathology, they may suffer from delayed intervention, which may be fatal. Therefore, it is important to describe these variations to aid diagnosis in differentiating them from pathological processes that will warrant further evaluation (Freeman *et al.*, 2019).

Ignorance of the anatomical variations contributes to 10% of clinical malpractice, which is believed to be underreported (Tibrewal, 2006; Yammine, 2014; Sañudo *et al.*, 2021). The unexpected anatomical pattern is also known to contribute to about 25% of all surgical technical errors (Ellis, 2002; Regenbogen *et al.*, 2007). While it is common practice to overlook these variations, their presence offers an invaluable clue to the compromised embryonic development. It may alert clinicians of other significant devastating variations (Sañudo *et al.*, 2021). Therefore, it is crucial to know the likely implications of these variations in terms of physical examinations, diagnosis, and treatments to achieve optimal patient outcomes (Moore *et al.*, 2018).

2.3. Anatomy of iliolumbar veins (ILVs)

The ILVs are horizontally oriented veins that are located at the L5 vertebral body level (Kim *et al.*, 2013). They accompany the two branches of the iliolumbar artery (Hamid *et al.*, 2007). The ILVs may join with the ascending lumbar vein (ALV) to form a common trunk (Figure 2.1) (Lolis *et al.*, 2011; Kostov *et al.*, 2021). The ILVs are covered anterolaterally by the medial border of psoas muscles and posteriorly by the iliacus muscles (Kiray *et al.*, 2004; Standring, 2015; Mahan *et al.*, 2017; Moore *et al.*, 2018). The ILV drains L4-L5 lumbar vertebral regions, the psoas and iliacus muscles (Jasani and Jaffray, 2002; Hamid *et al.*, 2007; Davis *et al.*, 2019). They drain their blood into the common iliac vein (CIV) posterolaterally (Sheng *et al.*, 2008; Kunakornsawat *et al.*, 2012; Barrey *et al.*, 2013; Nalbandian *et al.*, 2013; Davis *et al.*, 2019). The obturator nerve (ON) passes anterior to the ILVs while the lumbosacral trunk (LST) passes posterior to the ILVs on their way to innervate the pelvic and thigh regions (Standring, 2015; Moore *et al.*, 2018).

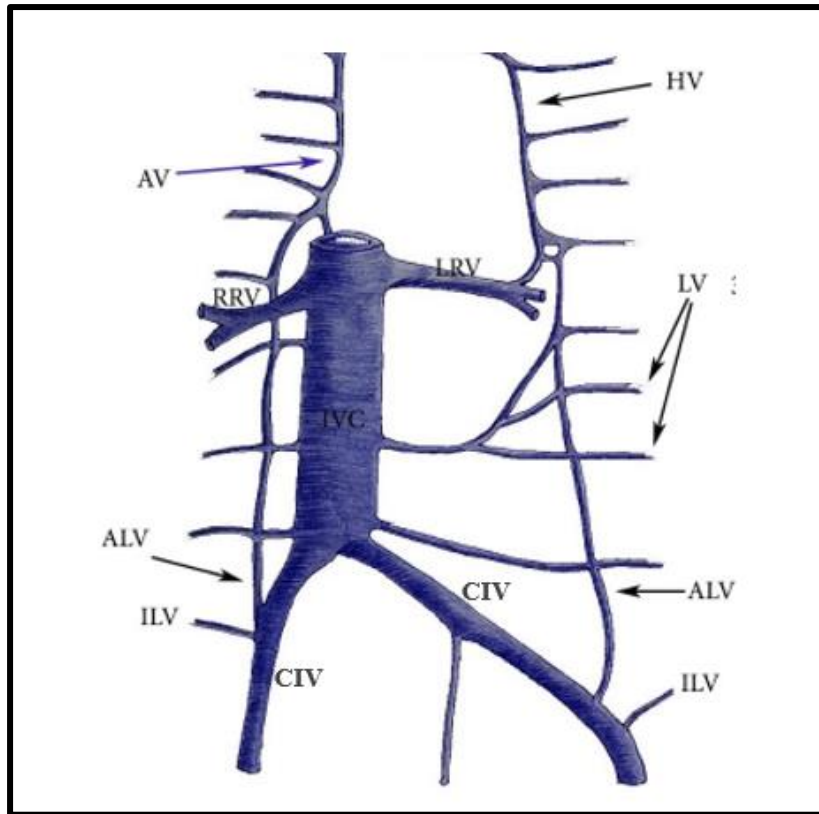


Figure 2.1: A diagram showing the arrangement of veins and anatomy of the iliolumbar veins (ILVs). Photograph adapted and modified from (Kostov *et al.*, 2021). IVC= Inferior vena cava; CIV= Common iliac vein; ALV= Ascending lumbar vein; AV= Azygous vein; HV= Hemizygous vein; LV= Lumbar veins; LRV= Left renal vein; RRV= Right renal vein.

2.4. Variations of iliolumbar veins (ILVs)

2.4.1 ILV trunk

2.4.1.1 Prevalence of ILV

Unlike other lumbar veins, the ILVs are highly variable (Hamid *et al.*, 2007; Lolis *et al.*, 2011). The presence of ILVs was found in 84.2% of cases in the French population (Barrey *et al.*, 2013), in 93.3% of cases in the American population (Davis *et al.*, 2019) and 100% of cases in the British and Turkish populations (Jasani and Jaffray, 2002; Kiray *et al.*, 2004). The absence of ILVs was reported to be 51%, with no significant difference between the sides of the body and the sex in the Caucasian population (Lolis *et al.*, 2011). In another study in the American population, 1.3% of cases with absent ILV were all in females (Nalbandian *et al.*, 2013). Thus, this varied presence of ILVs is likely to be population specific as illustrated in Table 2.1, and there is a need to determine the presence of ILVs using a larger sample size of a known population group.

Table 2.1: Prevalence of Iliolumbar veins (ILVs) across population groups

Study (Author and Year)	Population group	Sample size	Incidence (%)
Jasani and Jaffray (2002)	British	8	100
Kiray <i>et al.</i> (2004)	Turkish	19	100
Hamid <i>et al.</i> (2007)	French	13	96.0
Sivakumar <i>et al.</i> (2007)	British	23	100
Sheng <i>et al.</i> (2008)	Chinese	15	100
Lolis <i>et al.</i> (2011)	Caucasian	50	49.0
Barrey <i>et al.</i> (2013)	French	146	84.2
Nalbandian <i>et al.</i> (2013)	American	159	98.7
Davis <i>et al.</i> (2019)	American	15	93.3

2.4.1.2 Number of main trunk/stems of the ILVs

ILVs vary in the number of the main trunks (Nalbandian *et al.*, 2013; Teli *et al.*, 2013). Variation in the number of the trunks is vital to the surgeons as they are required to ligate all the trunks to reduce iatrogenic injuries (Jasani and Jaffray, 2002). In a study in the Indian population, both males and females showed the presence of a single ILV trunk on the right side but multiple trunks on the left side (Teli *et al.*, 2013). Unruh *et al.* (2008) reported the presence of two trunks of ILVs but did not ascertain the sex and laterality associations. The presence of multiple ILVs was more prevalent in males than in females (Nalbandian *et al.*, 2013). Despite using a small sample size, Unruh *et al.* (2008) concluded that the maximum number of ILVs that can occur on one side is four (Table 2.2). While the presence of multiple tributaries is considered hazardous during surgery (Jasani and Jaffray, 2002), there is a great need to determine the maximum number of ILVs that may require ligation to avoid iatrogenic injuries (Unruh *et al.*, 2008).

Table 2.2: The number of ILV main trunks across population groups

Study (Author and Year)	Population group	No trunk	One trunk	Two trunks	Three trunks	Four trunks
Jasani and Jaffray (2002)	British	-	Yes	Yes	-	-
Hamid <i>et al.</i> (2007)	French	-	Yes	Yes	-	-
Unruh <i>et al.</i> (2008)	American	-	Yes	Yes	Yes	Yes
Nalbandian <i>et al.</i> (2013)	American	Yes	Yes	Yes	Yes	Yes
Teli <i>et al.</i> (2013)	Indian	-	Yes	Yes	-	-

2.4.1.3 Terminal drainage of ILVs

Apart from the variant number of the ILV trunks, their terminal drainage points of ILVs also vary (DePietro *et al.*, 2020). In most cases, the ILV drains into the common iliac veins (CIV) (Figure 2.2) (Kiray *et al.*, 2004; Ikard, 2006; Sivakumar *et al.*, 2007; Sheng *et al.*, 2008; Kunakornsawat *et al.*, 2012; Barrey *et al.*, 2013; Davis *et al.*, 2019). Other studies in the American, British, French and Turkish populations noted that ILVs also drains into the internal iliac vein (IIV) and external iliac vein (EIV) with variable frequencies (Kiray *et al.*, 2004; Hamid *et al.*, 2007; Unruh *et al.*, 2008; Kunakornsawat *et al.*, 2012; Nayak, 2018; Davis *et al.*, 2019). The CIV was the only terminal drainage in the Thai, Chinese and Indian populations (Arthornthurasook and Gaew-Im, 1987; Sheng *et al.*, 2008; Teli *et al.*, 2013). The association between the terminal drainage points of ILV and sex has not been determined in the previous studies (Sheng *et al.*, 2008; Davis *et al.*, 2019). The differences in the terminal drainage of the ILV into the CIV, EIV and IIV may be ascertained by examining larger study samples (Kiray *et al.*, 2004).

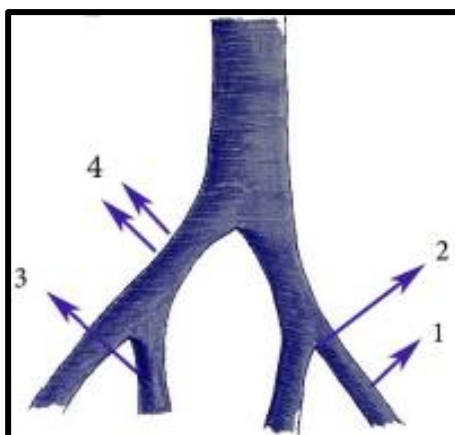


Figure 2.2: A diagram showing the iliolumbar vein (ILV) drainage pattern variations. Photograph adapted and modified from (Kostov et al., 2021) ILV drains into 1=EIV; 2= Confluence of CIV; 3=IIV; 4=CIV. CIV= Common iliac vein, EIV= External iliac vein, IIV= Internal iliac vein, Rt= Right side, Lt= Left side).

2.4.1.4 Tributaries of ILVs

The tributaries emptying into the ILVs are also highly variable, with more than one being reported (Jasani and Jaffray, 2002; Nalbandian *et al.*, 2013; Teli *et al.*, 2013). In the American population group, Davis *et al.* (2019) found that the left ILVs tended to have more tributaries but did not report the sex differences. The presence of multiple tributaries is considered a risk for haemorrhage if all tributaries are not ligated (Jasani and Jaffray, 2002; Eck and Vaccaro, 2013; Teli *et al.*, 2013). Two tributaries were named inferior lumbar veins and superior iliac veins in the French populations (Hamid *et al.*, 2007). The maximum number of tributaries of the ILVs and information about sex and laterality differences are not clearly documented. There is a need to determine them using a large sample size study (Jasani and Jaffray, 2002; Teli *et al.*, 2013).

2.4.1.5 Drainage sites for ILV Tributaries

All tributaries of ILVs are known to drain the iliacus muscle and psoas muscle (Jasani and Jaffray, 2002; Teli *et al.*, 2013). ILV and its tributaries are also regarded as an equivalent of the fifth lumbar (L5) vertebra veins (Sivakumar *et al.*, 2007; Unruh *et al.*, 2008; Nalbandian *et al.*, 2013). Some tributaries drain the region from the L4/L5 intervertebral disc and transverse process of the fourth lumbar (L4) vertebra and iliac fossa (Jasani and Jaffray, 2002; Kiray *et al.*, 2004; Hamid *et al.*, 2007). Even though some authors believe that ILVs may anastomose directly with each other or with internal vertebral veins, most of these tributaries were not followed to determine all the sites they drain (Jasani and Jaffray, 2002; Teli *et al.*, 2013). Thus,

there is a need to evaluate the sites drained by ILVs to determine structures likely to have their primary venous drainage compromised with ligation of these veins during surgery.

2.4.1.6 Entry positioning of ILVs into terminal drainage

The ILVs are described to terminate either posterior or lateral to the iliac vessels they drain into (Nalbandian *et al.*, 2013). Posterior location (Figure 2.3) and entry may obscure some of these vessels during imaging, thus, giving a false impression of their absence (Barrey *et al.*, 2013). Lateral location and entry of these vessels into the iliac veins may predispose these vessels to greater risk of rupture during medial retraction of iliac vessels to expose the intervertebral disc space of interest (Czerwein *et al.*, 2011; Eck and Vaccaro, 2013; Kim *et al.*, 2013). There is limited literature describing the specific direction of entry in which the ILVs drain into their terminal iliac vessels with respect to sex and laterality (Nalbandian *et al.*, 2013).

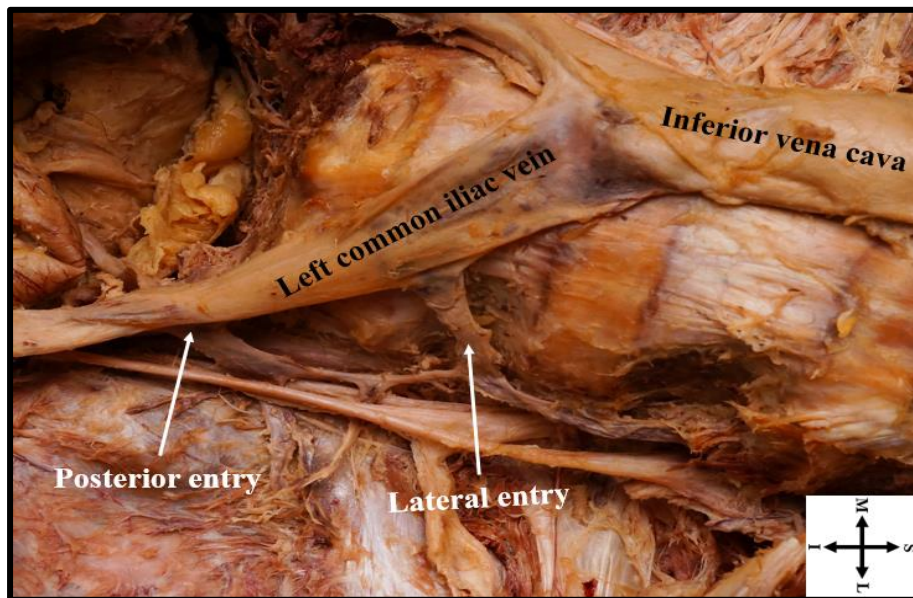


Figure 2.3: A photograph showing the direction of entry of iliolumbar veins (ILVs) into terminal drainage. S= Superior, I= Inferior, M= Medial, L= Lateral.

2.4.2 Classification of ILVs

The ascending lumbar vein (ALV) may be present as a trunk of the iliolumbar system or an independent trunk that ascends directly off the CIV (Jasani and Jaffray, 2002; Kim *et al.*, 2013; Rhee *et al.*, 2015). Due to the interconnection of these veins, different authors have referred to them with more confusing names as inferior lumbar veins or lateral lumbosacral veins (Hamid *et al.*, 2007; Unruh *et al.*, 2008). Despite their interconnections, these veins are considered separately as the ALVs are longitudinal veins ascending along the course of the IVC to connect iliac veins to the azygos system of veins (Morita *et al.*, 2007; Lolis *et al.*, 2011; Terayama *et*

al., 2015; Badagabettu *et al.*, 2016; Maloor *et al.*, 2017). On the other hand, the ILVs are horizontal veins that collect blood from the iliacus muscle, psoas muscle, L5 vertebra and iliac bone, and drains it into the CIV (Sheng *et al.*, 2008; Lolis *et al.*, 2011; Kunakornsawat *et al.*, 2012; Teli *et al.*, 2013). In addition, ILVs accompany the two branches of the iliolumbar artery (Hamid *et al.*, 2007). These veins also exist with different nomenclature (Kachlik *et al.*, 2010).

Several researchers have described the classification of the various patterns of the ILV differently. The variations have been classified into four main types (Sheng *et al.*, 2008; Nalbandian *et al.*, 2013) and six main types (Arthornthurasook and Gaew-Im, 1987; Jasani and Jaffray, 2002; Kiray *et al.*, 2004; Sivakumar *et al.*, 2007). To minimize confusion in the descriptions, Unruh *et al.* (2008) simplified the classification of these variations into three main types (Table 2.3) and (Figure 2.4). All the available classifications do not account for the absence of ILVs. Unruh *et al.* (2008) adopted the classification system, which offers more clinical relevance and allows for any recently discovered variants that do not align perfectly into the three types.

Table 2.3: Classification of Iliolumbar veins (ILVs) by Unruh *et al.* (2008).

TYPE	DESCRIPTION
1	There is a shared ALV-ILV trunk with additional distal ILVs.
2	There is a shared ALV-ILV trunk without additional distal ILVs.
3	There are separate ALV and ILV venous trunks.

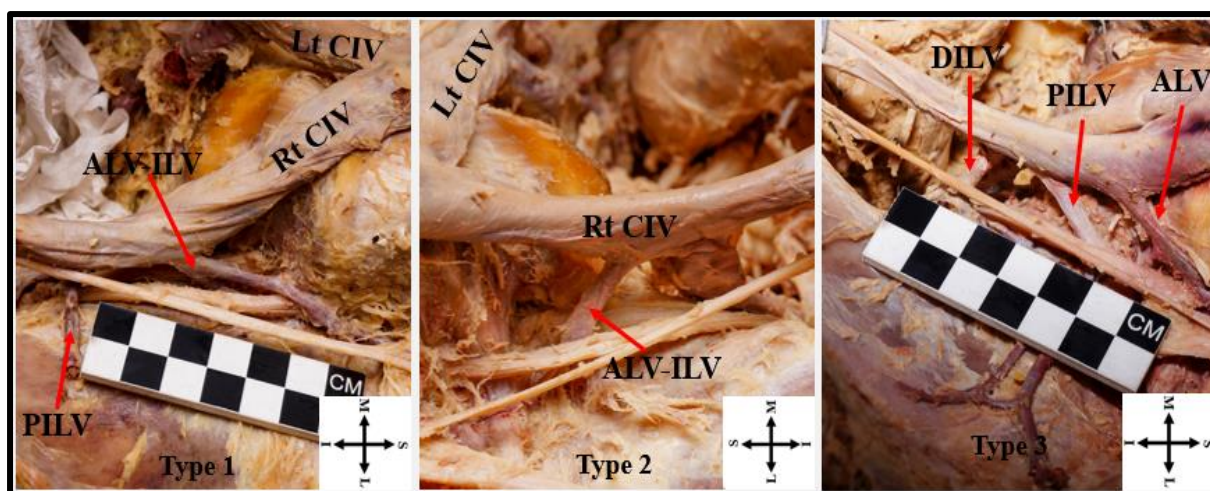


Figure 2.4: A photograph showing ILV classification by Unruh et al. (2008). Red arrow pointing at ILVs. CIV= Common iliac vein, ALV= Ascending lumbar vein, ALV-ILV= Ascending lumbar vein and Iliolumbar vein common trunk, PILV= Proximal iliolumbar vein, DILV= Distal iliolumbar vein, Lt= Left, Rt= Right, S= Superior, I= Inferior, M= Medial, L= Lateral.

2.4.3 Topography of ILVs and Lumbosacral plexus

2.4.3.1 Lumbosacral plexus

The intimate relations of the ILV to the lumbosacral plexus, specifically the obturator nerve (ON) and lumbosacral trunk (LST), are also highly variable (Kiray *et al.*, 2004; Hamid *et al.*, 2007). The lumbosacral plexus consists of the lumbar and sacral plexuses of nerves that are united in the pelvis to form a single plexus (Tung *et al.*, 2005; Planner *et al.*, 2006). The Lumbar plexus is formed in the retroperitoneal space in the abdomen within the psoas major muscle from the contributions of ventral rami of lumbar spinal nerve roots (L1-L4), with or without 12th thoracic (T12) ventral nerve root contributions (Moro *et al.*, 2003; Benglis *et al.*, 2009; Matejčík, 2010; Mirilas and Skandalakis, 2010; Uribe *et al.*, 2010; Le *et al.*, 2013; Barber *et al.*, 2017; Tanida *et al.*, 2017). These nerve roots' ventral position to the lumbar spine places them at a greater risk of iatrogenic injuries during anterior lumbar spine surgeries (Tubbs *et al.*, 2005; Guérin *et al.*, 2011).

2.4.3.2 Relationship of ILVs to Obturator Nerve (ON)

One of the greater motor branches of the lumbar plexus is the ON (Tubbs *et al.*, 2005; Le *et al.*, 2013). It is formed by the union of the anterior divisions of the ventral rami of L2-L4 spinal nerve roots. It emerges from the posterior medial border of the psoas major muscle (Sim and Webb, 2004; Kirchmair *et al.*, 2008; Kumka, 2010; Mirilas and Skandalakis, 2010). It then

descends lateral to the L5 vertebra body and adjacent intervertebral disc (Sim and Webb, 2004; Kirchmair *et al.*, 2008; Warner and Tubbs, 2020). On its course, it passes anterior to ILVs, then posterior to the common iliac vein and artery and lateral to internal iliac vein and artery before piercing the obturator foramen to access the medial thigh (Standring, 2015; Moore *et al.*, 2018). A cadaveric study in Indians reported the course of ON in relation to ILVs to be variable, with up to 45% of ON lying posterior to ILVs (Teli *et al.*, 2013).

2.4.3.3 Relationship of the ILVs to Lumbosacral Trunk (LST)

The LST serves as a connection between the lumbar plexus and the sacral plexus (Schmidt *et al.*, 2017). It arises from portions of L4 anterior rami nerve root and all L5 ventral rami (Sim and Webb, 2004; Ergun and Lakadamyali, 2010; Matejčík, 2010). The union of the L4 and L5 of LST occurs either above, below or at the most anterior part of the sacroiliac joint (Waikakul *et al.*, 2010; Schmidt *et al.*, 2017). The LST runs on the medial side of the psoas muscle, descends against the alar of the sacrum and posterior to ILVs before it enters the lesser pelvis to join the S1 nerve root (Sim and Webb, 2004; Ergun and Lakadamyali, 2010; Standring, 2015; Schmidt *et al.*, 2017; Moore *et al.*, 2018). The LST course in relation to ILV has also been demonstrated to be variable, with up to 60% of LST lying anterior to ILVs in the American and Indian populations (Unruh *et al.*, 2008; Teli *et al.*, 2013). This variation was more pronounced in males than females in the American population group (Unruh *et al.*, 2008). The paucity of information still exists on the relationship of the lumbar plexus nerves and the ILVs with respect to sex and laterality (Sheng *et al.*, 2008; Lolis *et al.*, 2011; Teli *et al.*, 2013; Davis *et al.*, 2019).

2.4.4 ILVs and Lumbosacral vertebra

Classically, ILVs are located at the L5 vertebral body level (Kim *et al.*, 2013). With the emerging literature, the precise location of the ILVs in relation to the lumbosacral vertebral spine has been demonstrated to be variable (Davis *et al.*, 2019). The location of the ILVs varies from L4 down to the 2nd sacral (S2) vertebra level (Sivakumar *et al.*, 2007; Unruh *et al.*, 2008; Davis *et al.*, 2019). On the right side, the ILVs were reported to be located lower on the lumbosacral vertebral levels than on the left side (Lolis *et al.*, 2011). Due to the presence of multiple ILV trunks, it is crucial to know the specific point at which each ILV trunk may be located to reduce the risk of inadvertent venous injuries as most of the ILV injuries occur at the L4/L5 intervertebral disc space level (Kiray *et al.*, 2004; Unruh *et al.*, 2008; Wood *et al.*, 2010; Eck and Vaccaro, 2013; Nalbandian *et al.*, 2013).

2.4.5 ILVs and surrounding muscles

The ILV and its tributaries are covered laterally and superficially by the medial border of psoas muscles (Standring, 2015; Mahan *et al.*, 2017). Psoas muscles arise from the anterior surface and lower borders of the transverse processes of all the lumbar vertebra (Penning, 2000; Tatu *et al.*, 2002; Jemmett *et al.*, 2004; Bui *et al.*, 2008; Arbanas *et al.*, 2009; Sajko and Stuber, 2009; Tanida *et al.*, 2017). Psoas muscles receive their blood supply from the lumbar, iliolumbar, and psoas branch of the external iliac arteries, and they drain their blood into the ILVs (Standring, 2015; Mahan *et al.*, 2017).

The ILVs lie superficial to the iliacus muscles (Kiray *et al.*, 2004; Standring, 2015; Moore *et al.*, 2018). The iliacus muscle arises from the concavity of the iliac fossa, and it forms a conjoint tendon with psoas muscle that inserts on the trochanter of the femur (D'Costa *et al.*, 2008; Sajko and Stuber, 2009; Medalie *et al.*, 2011; Standring, 2015; Unat *et al.*, 2019; Park *et al.*, 2020). The iliacus muscle gets its blood supply from the lumbar branch of the iliolumbar artery and deep circumferential iliac artery and is drained by ILVs and deep circumferential iliac veins (Medalie *et al.*, 2011; Standring, 2015).

2.5 The morphometries of ILVs

2.5.1 Distance between ostium of ILV and the origin of the IVC

The distance between the ostium of ILVs and the origin of the IVC helps in determining the risk of ILV avulsion during retraction of the CIV to expose the intervertebral disc space (Sivakumar *et al.*, 2007; Davis *et al.*, 2019). The risk of avulsion is higher when the distance between the ostium of ILV and the origin of the IVC is less than 30 mm (Sivakumar *et al.*, 2007; Lolis *et al.*, 2011; Davis *et al.*, 2019). Distances as short as 11mm and 14 mm have been reported in the American and British populations, respectively (Table 2.4) (Sivakumar *et al.*, 2007; Unruh *et al.*, 2008).

Additionally, the distance from the ostium of ILV to the origin of the IVC also helps surgeons in defining the search area for the ILVs to be ligated (Unruh *et al.*, 2008). Studies have reported that the distance from the ostium of ILVs to the origin of IVC tends to be longer on the left side than on the right side (Kiray *et al.*, 2004; Hamid *et al.*, 2007; Unruh *et al.*, 2008; Lolis *et al.*, 2011). The mean distance from the ostium of ILVs to the origin of IVC was reported to be longer in females than in males (Sivakumar *et al.*, 2007; Unruh *et al.*, 2008). There is a need to determine the maximum distance of locating the ILVs from the origin of the IVC reference point (Unruh *et al.*, 2008).

Table 2.4: The distance from the Ostium of ILV and the origin of the IVC across population groups

Study (Author and Year)	Population group	Overall Mean (mm)	Range (mm)
Jasani and Jaffray (2002)	British	35 ± 0.0	20.0 – 50.0
Kiray <i>et al.</i> (2004)	Turkish	51.9 ± 17.8	-
Hamid <i>et al.</i> (2007)	French	33.3 ± 0.0	-
Sivakumar <i>et al.</i> (2007)	British	43.8 ± 0.0	14.0 - 88.0
Sheng <i>et al.</i> (2008)	Chinese	35.2 ± 0.0	21.9 - 48.2
Unruh <i>et al.</i> (2008)	American	55.6 ± 0.0	11.1 - 116
Lolis <i>et al.</i> (2011)	Caucasian	50.3 ± 19.9	14.0 - 89
Teli <i>et al.</i> (2013)	Indian	35 ± 9.9	-

2.5.2 Length of ILV trunk

The ILV trunk is adequately exposed and ligated before an attempt to expose the intervertebral disc is made (Eck and Vaccaro, 2013; Kim *et al.*, 2013). The ILV trunk length variation may render ligation during surgery difficult, mainly when the trunk is short (Jasani and Jaffray, 2002). The short trunk may increase the probability of injuries to the CIV walls during vein retraction (Jasani and Jaffray, 2002). Males have been reported to have longer ILV trunks than females (Unruh *et al.*, 2008). In addition, the ILV trunk is longer on the left side than on the right side in the Caucasian population (Lolis *et al.*, 2011). There is no consensus on the population specificity for the length and side variations of the ILV trunk. Therefore, it is recommended to examine the ILV variations in a larger sample of known population affinity (Lolis *et al.*, 2011).

2.5.3 Distance between ostium of ILVs and the lumbosacral plexus

Much as the lumbosacral plexus nerves may be lying either anterior or posterior in relation to ILVs, these nerves cross near or at the ostium of the ILVs into the iliac veins (Jasani and Jaffray, 2002; Sheng *et al.*, 2008). This proximity makes the nerves highly susceptible to ligation with the vein's lateral portion if the ILV is inadequately exposed (Jasani and Jaffray, 2002). In cases of accidental haemorrhage, the ON and LST can also be damaged by clamps that are used to

control the bleeding (Jasani and Jaffray, 2002). Unruh *et al.* (2008) observed that the distance between the ostium of ILVs and the lumbosacral plexus were significantly higher in males than in females.

2.6 Histology of ILVs

2.6.1 Veins and their functions

Veins are a thin-walled type of blood vessel that relay blood from the organs to the heart (McMonagle and Stephenson, 2014). They act as functional reserves since they hold about 65-75% of the systemic blood volume at any given time, and their inadvertent rupture may lead to excessive haemorrhage (McMonagle and Stephenson, 2014; Sidawy and Perler, 2018).

Veins are divided into small, medium, or large depending on their size (Ross and Pawlina, 2016). Small veins have a diameter of 1 mm or less (Ross and Pawlina, 2016). The diameter of medium-sized veins measures up to 10mm, and most named veins, for example, the ILVs, fall in this group (Hamid *et al.*, 2007; Teli *et al.*, 2013; Ross and Pawlina, 2016; Davis *et al.*, 2019). Veins with a diameter greater than 10mm belong to the large group (Ross and Pawlina, 2016).

2.6.2 Layers of veins

Classically, the venous wall is made up of tunica intima, media and adventitia as shown in Figure 2.5 (Berridge *et al.*, 2013; Ovalle and Nahirney, 2013; Devi, 2016; Ross and Pawlina, 2016). Tunica intima is closely related to the lumen of the veins and consists of endothelial cells that lies on the basal lamina, a thin subendothelial layer of loose connective tissue and occasional internal elastic membrane (Devi, 2016; Ross and Pawlina, 2016). Tunica media consists of bundles of circularly arranged smooth muscles dispersed with collagen fibres. Longitudinally arranged smooth muscles may at times be present in the tunica media just beneath the adventitia (Mescher and Junqueira, 2013; Ross and Pawlina, 2016). However, the poorly defined tunica adventitia consists of longitudinally arranged smooth muscles, a network of elastic and collagen fibres, vasa and nerve vasorum and some adipose tissue (Mescher and Junqueira, 2013; McMonagle and Stephenson, 2014; Devi, 2016; Ross and Pawlina, 2016).

Despite the vascular wall's overall design being the same, some layers may be absent or extremely thin depending on venous segments (Berridge *et al.*, 2013). Macro-anatomical differences between proximal and distal ILVs are documented, but no studies describe the microanatomical differences, particularly the thickness of the iliolumbar venous wall (Sheng *et al.*, 2008; Unruh *et al.*, 2008; Teli *et al.*, 2013; Davis *et al.*, 2019). During surgery, bleeding

from thinner walled vessels is difficult to control. It is unknown whether bleeding will be more difficult to control in either the ruptured proximal ILV or distal ILV (Kiray *et al.*, 2004).

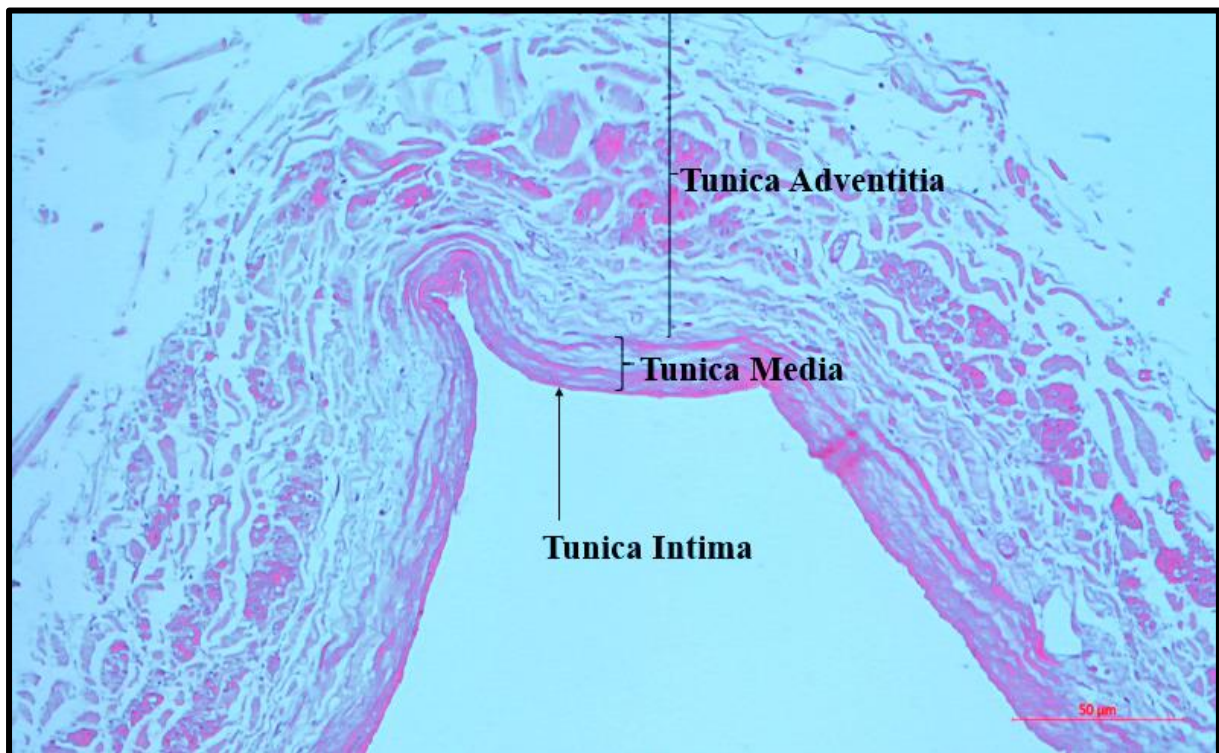


Figure 2.5: A photomicrograph of the vein stained with Hematoxylin and Eosin (H&E) showing the layers of the wall.

Veins from different anatomical locations vary in their mechanical properties and may be affected differently during retraction (Bia *et al.*, 2005; Valdez-Jasso *et al.*, 2008; Zócalo *et al.*, 2013; Latimer *et al.*, 2014). Elastic and collagen fibres content and their ratios are the main determinants of the mechanical properties of blood vessels (Silver *et al.*, 2003; Zócalo *et al.*, 2013; Latimer *et al.*, 2014).

Elastic fibres are highly refractile and allow resilient rebound when the vessel wall is stretched (Elsharawy *et al.*, 2007; Lai and Lü, 2012; Berridge *et al.*, 2013). On the other hand, collagen fibres are tough and give support and shape to blood vessels (Elsharawy *et al.*, 2007). Collagen fibres act to stiffen the vessel wall and limit its extensibility (Elsharawy *et al.*, 2007; Berridge *et al.*, 2013). The differences in elastic and collagen fibre content and their ratios in proximal and distal ILVs are not known. Examination of the tissue composition of these veins is imperative in determining the veins at higher risk of avulsion during retraction.

CHAPTER 3: MATERIALS AND METHODS

3.1 Sample

A total of 89 cadavers of adult White South Africans obtained from the School of Anatomical Sciences at the University of the Witwatersrand were utilized in the study. This population group was chosen because it is the only population group available in the School of Anatomical Sciences for education and research. The other races (Black South Africans, Colored South Africans, Indian South Africans and Unspecified South Africans) are not part of the body donation program (Statistics South Africa, 2016). The age range was 46-102 years. The sample size was determined by calculating the sample size for an infinite population using the confidence level of 95% and a confidence interval of 5. The sample was then adjusted to the total population of 120 cadavers that could be available in the dissection halls. The sample size (92) was then verified using the Research systems online sample size calculator (Aapor, 2012). A convenience sampling method was used. In convenience sampling, a population sample that is easy to access and that may represent a larger population is used, and this was ideal in the current study. Ethical approval for the present study was covered under the Human Tissue Act No. 65 of 1983 with the ethical waiver **W-CBP-210401-01** obtained from the University of the Witwatersrand Research Ethics (Appendix 4).

3.2 Cadaveric Data

3.2.1 Study Type and Period

The current study was a cross-sectional descriptive cadaveric study. Cadaveric dissections and data collections were done from July 2020 to November 2020, when national lockdown level 3 restrictions due to the Corona virus disease of 2019 (Covid 19) were in place.

3.2.2 Exclusion criteria

All cadavers that presented with anatomical variations of the IVC and CIV were excluded from the present. In addition, cadavers with visible trauma or previous surgery to the lumbar region were also excluded. Five of the total dissected cadavers successfully met the exclusion criteria. Amongst those excluded, two (one male, one female) had duplication of IVC, two (both females) had the absence of the right CIV, and one (female) had evidence of previous lumbar spine surgery.

3.2.3 Dissection method

The dissection was conducted as described by Davis *et al.* (2019) and Unruh *et al.* (2008). To maximize the use of anatomical body donations and obtain as much information as possible,

the dissections were initiated by second-year medical and allied health sciences students during their routine posterior abdominal wall and lumbar plexus dissection practicals. To control for potential damage to the relative structures due to the pre-exposure of this region, students were advised to preserve as many structures as possible of this region. Teaching assistants helped in ensuring students' compliance with the advice.

To study the ILVs, the cadavers were put in the supine position. A midline incision from the xiphoid process to the pubic symphysis was made to open the anterior abdominal wall. The peritoneal contents were moved upwards, and the retroperitoneal space was accessed. The IVC and its point of origin were located together with the abdominal aorta. The lumbar vertebra and the iliopsoas muscle were also identified, followed by excision of the abdominal aorta and its branches (common iliac arteries). The ILVs were then identified on both the left and right sides.

The origin, course and variations of each ILV were analyzed and recorded in the data collection sheet (Appendix 2). The number of tributaries of the ILVs was also studied and documented. Drainage sites to the associated structures were also observed. Each vein and its tributaries were analyzed according to the organs/structures they drain and classified as draining the psoas muscle, iliac fossa, iliacus muscle, L5 vertebral body, L4/L5 disc space, L4 vertebral body or all of these structures. The ON and LST were also identified after removing the psoas major (occasionally with psoas minor) muscle. The relationship of the ILVs to the ON and LST was observed and recorded as either posterior or anterior. In cases where anterior or posterior relations could not fit properly, the relations of ILVs to ON and LST were described as superior or inferior.

3.2.4 Morphometries of the ILVs

Measurements of the distance between vessels and nerves were made with a digital Vernier caliper (accuracy $\pm 0.02\text{mm}$, resolution $\pm 0.01\text{mm}$, repeatability $\pm 0.01\text{mm}$) on both the left and right sides. The length of the ILVs was measured using a string by following their curves and the distance transferred to a ruler. The following parameters were measured (Figure 3.1).

- a) The distance from the origin of IVC to the ostium of the ILVs into the iliac veins (1)
- b) The distance from the ostium of the ILVs into the iliac veins to the point of intersection with ON (where there was no intersection, the shortest distance from the ostium of the ILV to the nerve was measured) (2).
- c) The distance from the ostium of the ILVs into the iliac veins to the point of intersection with LST (3).

d) The distance from the ostium of the ILV to the point where ILV receives its first tributary (length of the stem/trunk of the ILV) (4).

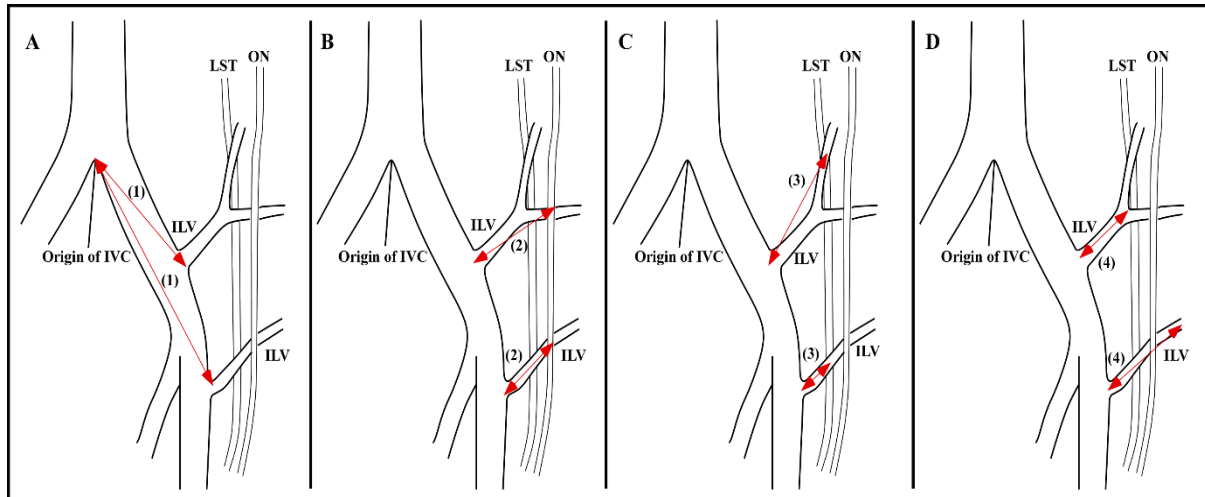


Figure 3.1: A diagram showing red arrows illustrating the morphometries that were taken (a-d). Diagram adapted and modified from Unruh *et al.* (2008). IVC= Inferior vena cava, ILV= Iliolumbar veins, ON= Obturator nerve, LST= Lumbosacral trunk.

3.2.5 Intra-observer error

Intra and inter-observer statistics were calculated using Lin's concordance coefficient of reproducibility (Lawrence and Lin, 1989). For intra-observer repeatability, the primary observer (A. Manjatika) took all the measurements in twelve (six males, six females) cadavers and repeated the exact measurements on the same cadavers two weeks later. The obtained results of the test and retest measurements were used to calculate the coefficient of intra-observer error. No significant difference between the two separate measuring occasions was observed (RC=.995, 95%CI for RC= lower .994 and upper=.996).

3.2.6 Inter-observer error

For inter-observer repeatability, the primary observer (A. Manjatika) took the measurements in ten (five males, five females) randomly selected cadavers. A month later, the secondary observer (co-supervisor) took measurements in the same cadavers, followed by the calculation of the error coefficient. No significant difference between the two separate measurements was observed (RC=.994, 95%CI for RC= lower .992 and upper .996).

3.2.7 Statistical analysis

The data was managed in Microsoft Excel 2010 (Microsoft Corporation) and was exported into SPSS® version 23 (IBM®) for statistical analysis. Histograms and the Shapiro Wilk test were used to test for the normality of the data (Razali and Wah, 2011). For the data that resulted in the normal distribution, the mean and standard deviation were calculated for numerical variables. On the other hand, the median and interquartile range were calculated for data that were not normally distributed. The frequencies and percentages of every categorical variable were also calculated. The comparisons for the mean values of left–right sides and males–females were obtained using a two-sample student t-test, and a significant difference was inferred when $p < .05$. All data were analyzed with the assistance of a biostatistician from the Faculty of Health Sciences statistical support service at the University of the Witwatersrand.

3.3 Histological data

3.3.1 Tissue sample and harvesting

A total of ten proximal ILVs (five males, five females) and nine distal ILVs (five males, four females) were harvested from the left and right sides from randomly selected cadavers and stored in 10% neutral buffered formalin.

3.3.2 Exclusion criteria

Cadavers who had known vascular diseases at the time of death were excluded. ILVs in which the trunk length was less than 5mm were also excluded. ILVs with evidence of gross venous diseases (obliteration of iliac veins which extended to ILVs) were also excluded.

3.3.3 Selected histological site

The sample site for the histological evaluation was taken at the midsection of the main ILV trunk. A 10mm vein segment was harvested from each proximal and distal ILV selected (Splith *et al.*, 2014). The edges of each vein section were trimmed for uniformity, leaving a segment of 8mm for processing. The decision for this site was made to ensure consistency of comparisons for all the sections (Figure 3.2).

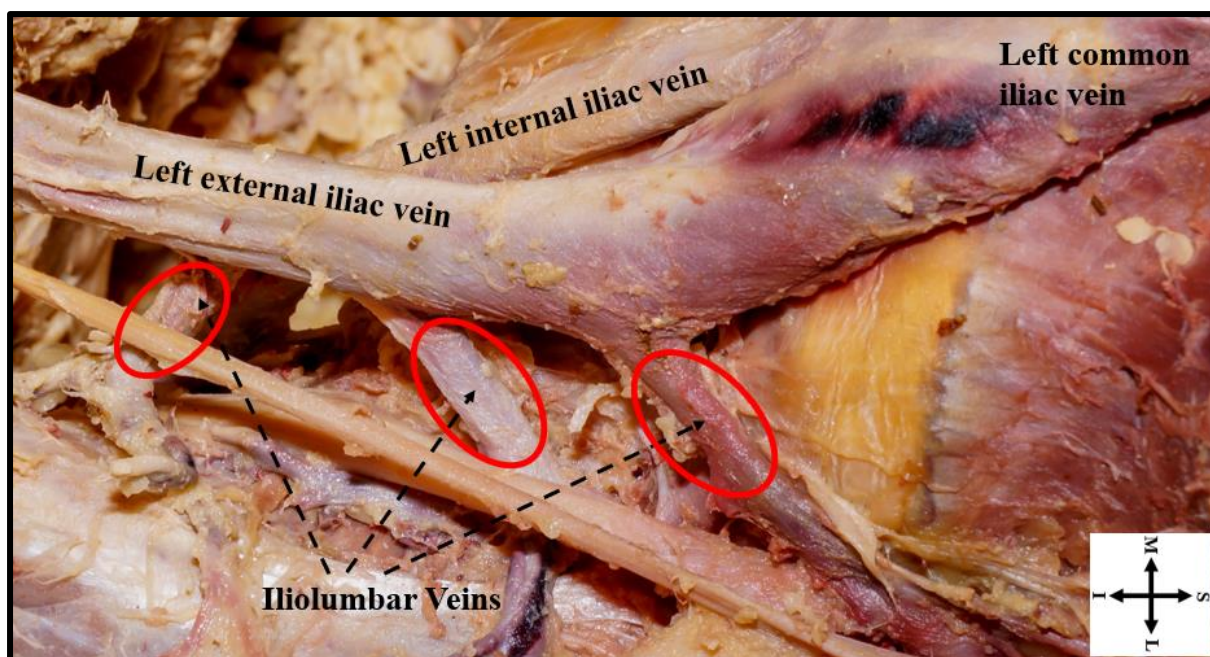


Figure 3.2: A photograph showing selected sites (circled in red color) for tissue harvesting. S= Superior, I= Inferior, M= Medial, L= Lateral.

3.3.4 Tissue processing

Tissue samples of approximately 8 mm in length and variable width were processed using the Automated Tissue Processing machine (Shandon citadel 1000) (Appendix 1, A). Briefly, the tissues were dehydrated in a series of increasing alcohol concentrations, followed by immersing them in chloroform and then melted paraffin wax. Once processed, the tissues were embedded in paraffin wax and the tissue blocks were allowed to cool for a day (Da Silva, 2013).

3.3.5 Tissue sectioning

Solidified wax blocks with the embedded tissue samples were serially sectioned in cross-section at a thickness of 5 μ m using a microtome. Sections then stayed afloat on 30% alcohol, followed by a warm water bath containing 2ml gelatine solution and then lifted onto gelatine coated glass slides. Each glass slide had three sections from the same tissue. The floating process prevented the tissue from folding. The glass slides with the sections were dried overnight in an incubator at 40 degrees Celsius (Appendix 1, A) (Da Silva, 2013).

3.3.6 Tissue staining

Hydration was done on the sections before using all the histological stains. The tissues were dewaxed using two baths of xylene. Then hydration was performed using decreasing concentrations of alcohol. The hydration process was completed by rinsing the tissue in running tap water.

Following Hydration, sections were then stained with Hematoxylin and Eosin (H&E) (Appendix 1, B), Modified Verhoeff's stain (Deran Reddy's modified methodology) (Appendix 1, C) and Masson's trichrome stain (Appendix 1, D). The H&E stained sections were used to evaluate the overall morphology of the venous wall. The Verhoeff's (Deran Reddy) stained sections were used to evaluate elastic fibres. Verhoeff's (Deran Reddy) stain stained elastic fibres black, collagen fibres red and smooth muscles yellow. Masson's trichrome stained sections were used to evaluate collagen fibres. It stained collagen fibres green and smooth muscles red.

3.4 Evaluation of histological features

Images of stained sections were captured with a digital camera mounted on the light microscope (Zeiss Axioscope). Stacks of images were moved to Image J software for histological feature quantification and analysis (Schindelin *et al.*, 2012; Da Silva, 2013). Vessel wall thickness and general appearance were determined in H&E stained sections. Area percentages of collagen fibres were evaluated from Masson's trichrome stained sections (collagen fibres stain green under this stain) and Area percentages of elastic fibres (black colored) in Verhoeff's (Deran Reddy) stained sections (Suvik and Effendy, 2012; Kazlouskaya *et al.*, 2013). The distance and color measurements were calibrated in Image J software before use (Elsharawy *et al.*, 2007; Rangan and Tesch, 2007).

3.4.1 Determination of Vessel wall thickness

Each section was divided into three segments to measure as many points as possible. Three different points were identified on each segment, and three measurements were taken to represent an average of that point (a total of nine separate measurements). An average of the three separate segment measurements was calculated to represent the thickness of that section (Figure 3.3). Since each slide had three sections, the measurement procedure was repeated on the remaining two sections, and their average represented the thickness of the whole vessel (for example, male left proximal 1).

The lines were drawn on the image from the intimal (luminal) surface to the outer surface of the tunica adventitia to represent the overall thickness of the venous wall.

Additional lines were drawn to determine the thickness of tunica adventitia and the combined tunica intima and tunica media thickness. These tunica measurements were done using Masson's trichrome stained sections as the tunica demarcations were very distinct in them. All

the measurements were calculated using images taken at the same magnification and the appropriate scale was set in Image J before use.

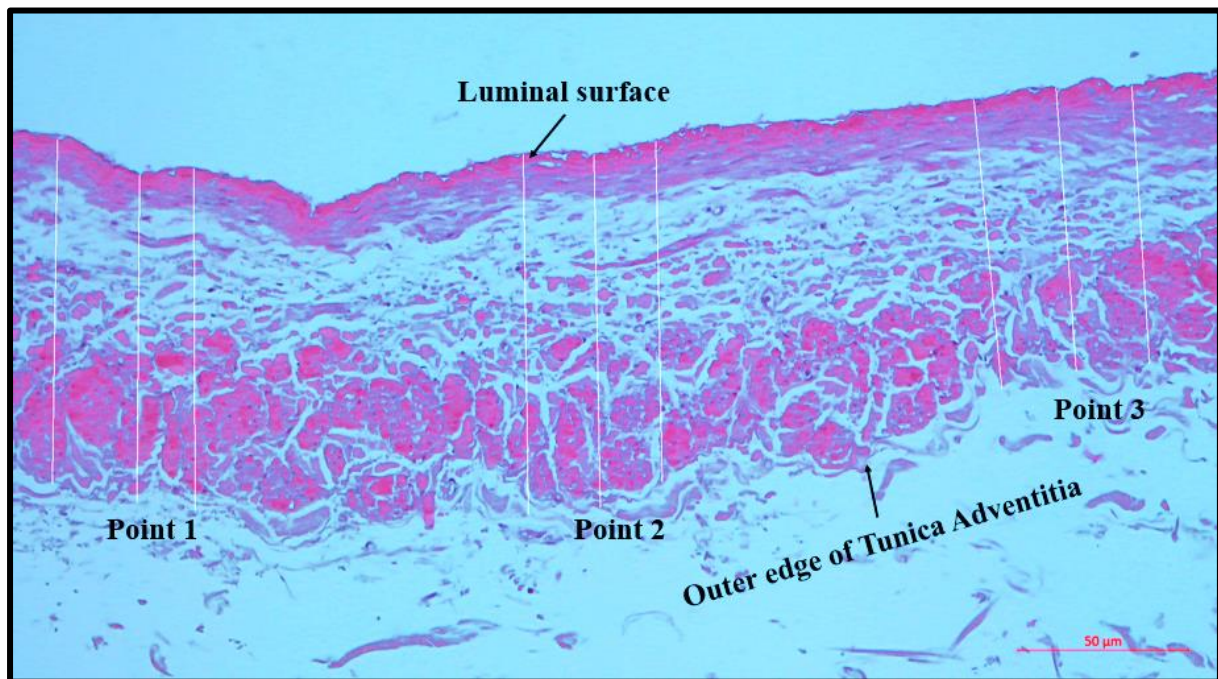


Figure 3.3: A photomicrograph showing measurements taken to determine the vessel wall thickness on one segment of a tissue section.

3.4.2 Elastic fibre content

Color area percentage of elastic (internal elastic lamina) fibres were calculated on Verhoeff's (Deran Reddy) stained sections. The elastic fibres were detected as a continuous black line running between tunica intima and tunica media. Additional elastic fibres scattered in the tunica adventitia were also quantified using Image J with distance and color measurements calibration before use (Appendix 3).

3.4.3 Collagen fibre content

Color area percentage of collagen fibres, both found in the tunica media and tunica adventitia, were calculated as one on Image J software (Elsharawy *et al.*, 2007). The collagen content color area percentage was done using Masson's trichrome stained sections (Appendix 3).

3.4.4 Elastic fibre to collagen fibre ratio

The Area percentage of collagen fibres (numerator) was divided by the Area percentage of elastic fibres (denominator) to determine the collagen fibre to elastic fibre ratio.

3.5 Observer bias for histological feature quantification

Observer bias was determined by repeating calculations on sections stained for the presence of elastic and collagen fibres. The calculations were made at two weeks' interval on four samples that were chosen randomly. The results of the two separate calculations showed no statistically significant difference.

3.6 Statistical analysis

Each tissue sample's histological features were documented in Microsoft Excel 2010 (Microsoft Corporation) and analyzed using SPSS® version 23 (IBM®). The normality of the sample data was determined using the Shapiro-Wilk Test. Significant differences between mean values were determined using the independent Student's t-test. A significance level of $p < .05$ was used for all comparisons.

CHAPTER 4: RESULTS

4.1 Demographic data (Age, weight, and height)

A total of 84 (94.4%) of 89 dissected cadavers were analyzed. There were 43 (51.2%) males and 41 (48.8%) females with no statistically significant proportional differences ($p=.78$). Sixty-three (75%) of the 84 cadavers (32 males, 31 females) were of known age, and their ages were recorded. The mean age was 75.11 ± 12.57 years. For histological evaluations, the sampled population mean age was 72.29 ± 5.707 years with no statistically significant mean difference between males and females ($p=.82$). Seventy-nine (94%) of the 84 cadavers (41 males, 38 females) had their weight and height records. The mean weight was 63.65 ± 15.10 kilograms, and no statistically significant difference in the mean weight between males and females ($p=.18$) were observed. The mean height was 1.67 ± 0.09 meters, and this was significantly higher in males than in females ($p=.001$) (Table 4.1).

Table 4.1: The age, sex, weight, and height distribution among the cadaveric sample.

	Age (Years)		Weight (Kilograms)		Height (Meters)	
	Male	Female	Male	Female	Male	Female
Minimum	55	46	38	30	1.55	1.50
Maximum	96	102	95	95	1.85	1.83
Mean and Standard deviation	$75.47 \pm$	$74.74 \pm$	$65.80 \pm$	$61.32 \pm$	$1.72 \pm$	$1.62 \pm$
	11.63	13.67	15.21	14.82	0.08*	0.07

*= statistically significant difference.

4.2 Variations of ILVs

4.2.1 Prevalence of ILVs

There was a 100% presence of ILV trunks in both males and females (84 analysed cadavers) and both sides of the body (168 sides). A total of 415 ILV trunks were observed. The majority of the ILVs on both sides were the proximal ILV (PILV) trunks which were present in 157 (93.5%) sides, followed by Ascending lumbar vein and Iliolumbar vein (ALV-ILV) common trunks, as shown in Table 4.2, Figures 4.1A-B and 4.2A-C.

Table 4.2: Prevalence of the iliolumbar vein (ILV) trunks in relation to laterality.

ILV Trunk Type	Left side ILVs	Right side ILVs	Total frequency in sides of the body	Percentage
Ascending lumbar vein (ALV)	28	25	53 / 168	31.5%
Ascending lumbar vein and iliolumbar vein (ALV-ILV)	56	59	115/ 168	68.5%
Proximal ILV (PILV)	79	78	157 / 168	93.5%
Distal ILV (DILV)	37	43	80 / 168	47.6%
Accessory ILV (AILV)	6	4	10 / 168	6.0%
Total trunks	206	209		

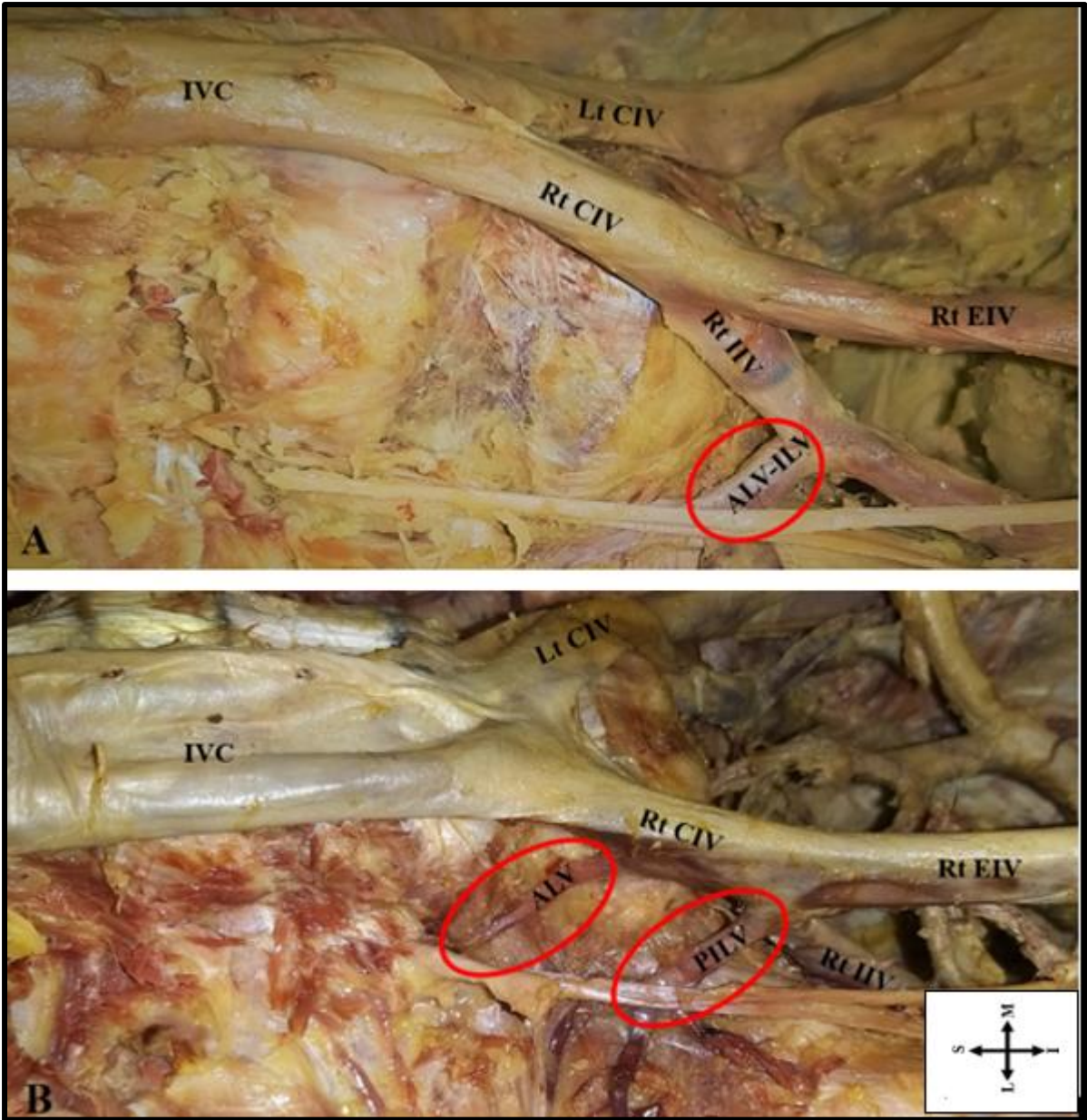


Figure 4.1 A photograph (A-B) showing ILV trunks circled in red. (A) ALV-ILV trunk and (B) ALV and PILV trunks. ALV= Ascending lumbar vein, ALV-ILV= Ascending lumbar vein and Iliolumbar vein common trunk, PILV= Proximal iliolumbar vein, IVC= Inferior vena cava, CIV= Common iliac vein, EIV= External iliac vein, IIV= Internal iliac vein, Rt= Right side, Lt= Left side, S= Superior, I= Inferior, M= Medial, L= Lateral.

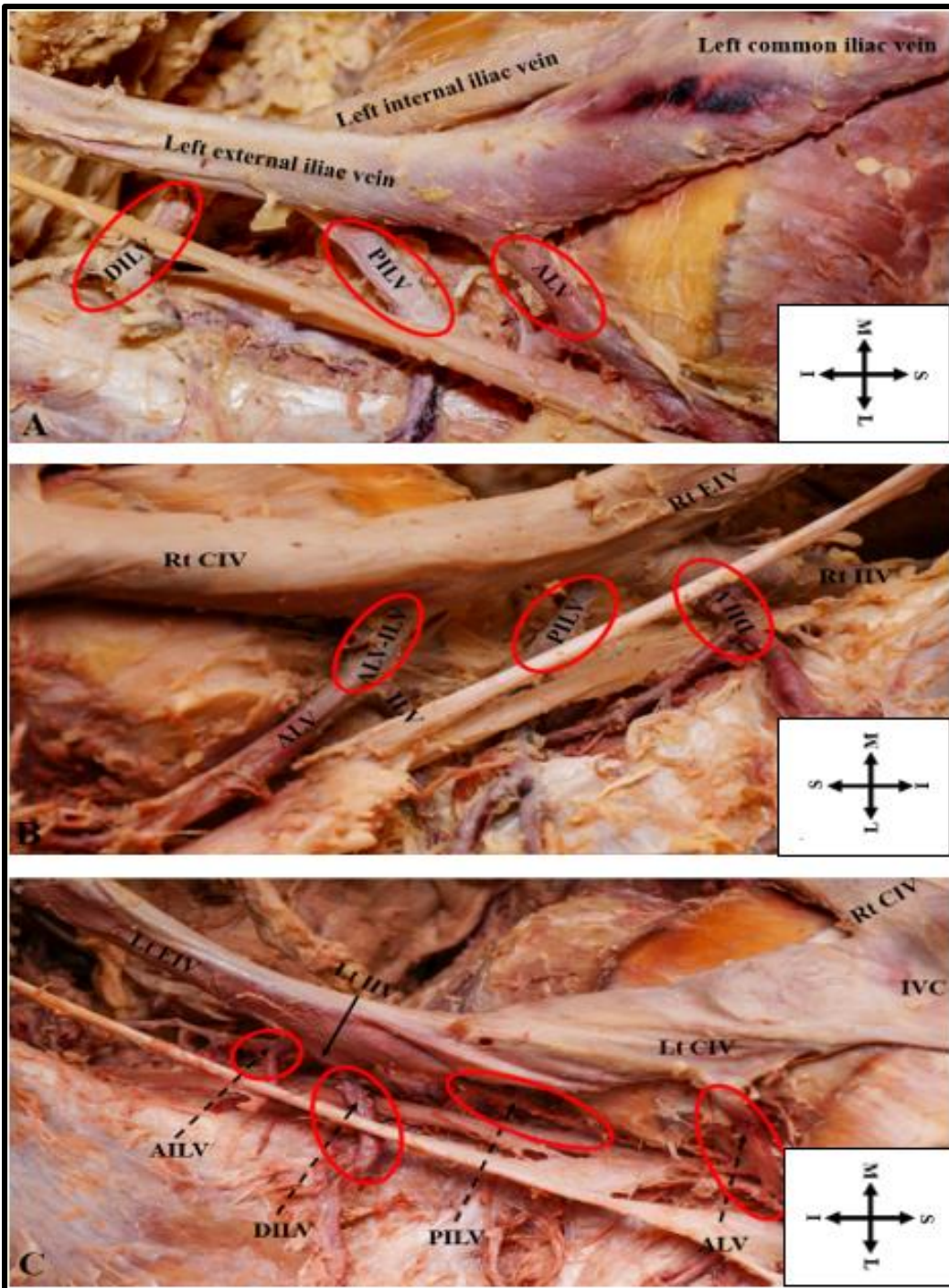


Figure 4.2: A photograph (A-C) showing the combination of ILV trunks circled in red. (A) ALV, PILV and DILV trunks; (B) ALV-ILV, PILV and DILV trunks; (C) ALV, PILV, DILV and AILV trunks. ALV= Ascending lumbar vein, ALV-ILV= Ascending lumbar vein and Iliolumbar vein common trunk, PILV= Proximal iliolumbar vein, DILV= Distal iliolumbar vein, AILV= Accessory iliolumbar vein, IVC= Inferior vena cava, CIV= Common iliac vein, EIV= External iliac vein, IIV= Internal iliac vein, Rt= Right side, Lt= Left side, S= Superior, I= Inferior, M= Medial, L= Lateral.

The left side had a higher proportion of ALVs ($p=.56$). Males had more ALV trunks than females ($p=.56$). The right side had more ALV-ILV trunks than the left side ($p=.69$) (Figure 4.3). No significant differences existed between sex and sides of the body in relation to the presence of ALV-ILV trunks. Males had a large proportion of PILVs (51%), with equal proportions between the sides of the body. The right side of the body had a higher proportion of DILVs (53.75%), and this was not different from the left side of the body ($p=.34$). The presence of AILVs was significantly higher in females on the left side of the body ($p=.021$).

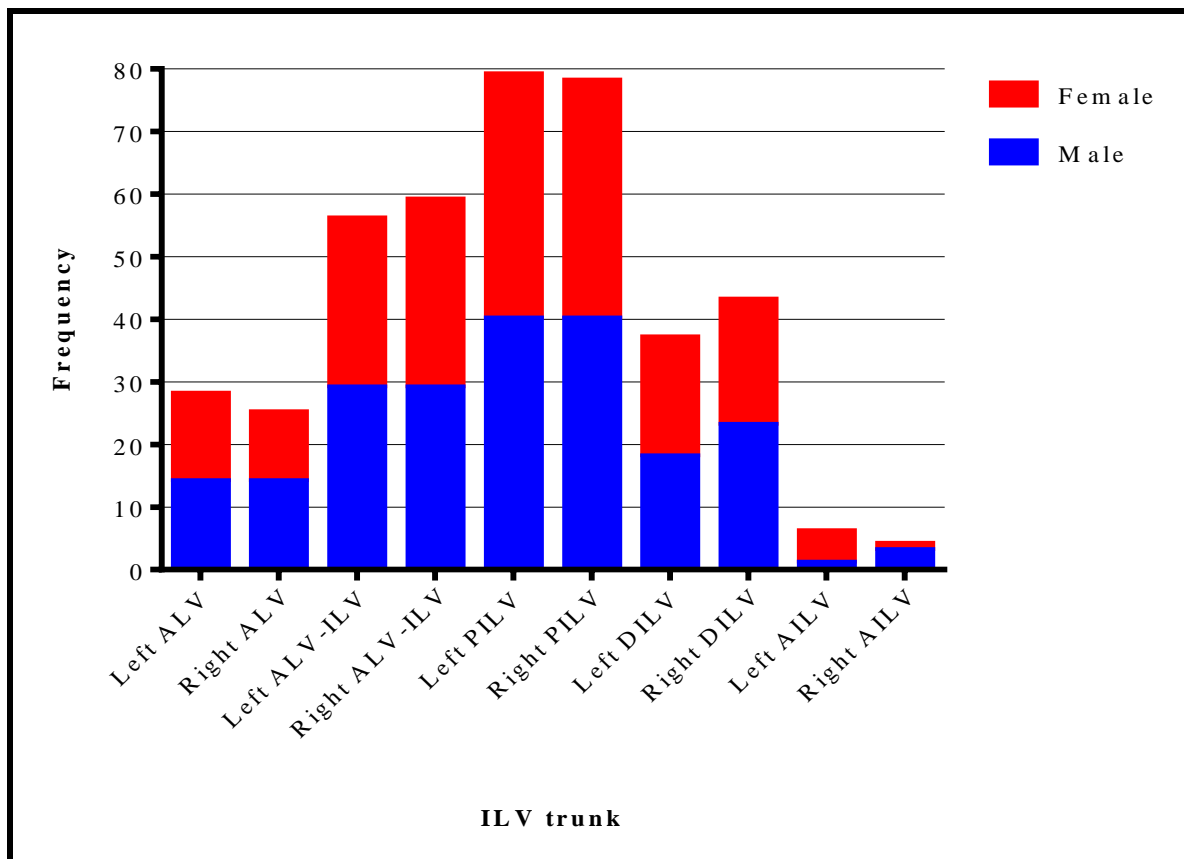


Figure 4.3: A bar graph showing proportional distributions of iliolumbar veins (ILVs) amongst sex and laterality. ALV= Ascending lumbar vein, ALV-ILV= Ascending lumbar vein and Iliolumbar vein common trunk, PILV= Proximal iliolumbar vein, DILV= Distal iliolumbar vein, AILV= Accessory iliolumbar vein.

4.2.2 Number of ILV main trunks/stems

The maximum number of ILVs main trunks present was four (Figure 4.4A-D). The maximum number was significantly more apparent in females ($p=.021$) and on the left side. The left side had a higher frequency of double main ILV trunks (50%), while the right side exhibited a higher frequency of three main ILV trunks (46.4%). (Table 4.3).

Table 4.3: The number of Iliolumbar vein (ILV) trunks and their distribution between sex and laterality.

Side	Left			Right		
	Male	Female	Total	Male	Female	Total
1	3	2	5 (6%)	3	3	6 (7.1%)
2	22	20	42 (50%)	17	18	35 (41.7%)
3	17	14	31 (36.9%)	20	19	39 (46.4%)
4	1	5	6 (7.1%)	3	1	4 (4.8%)

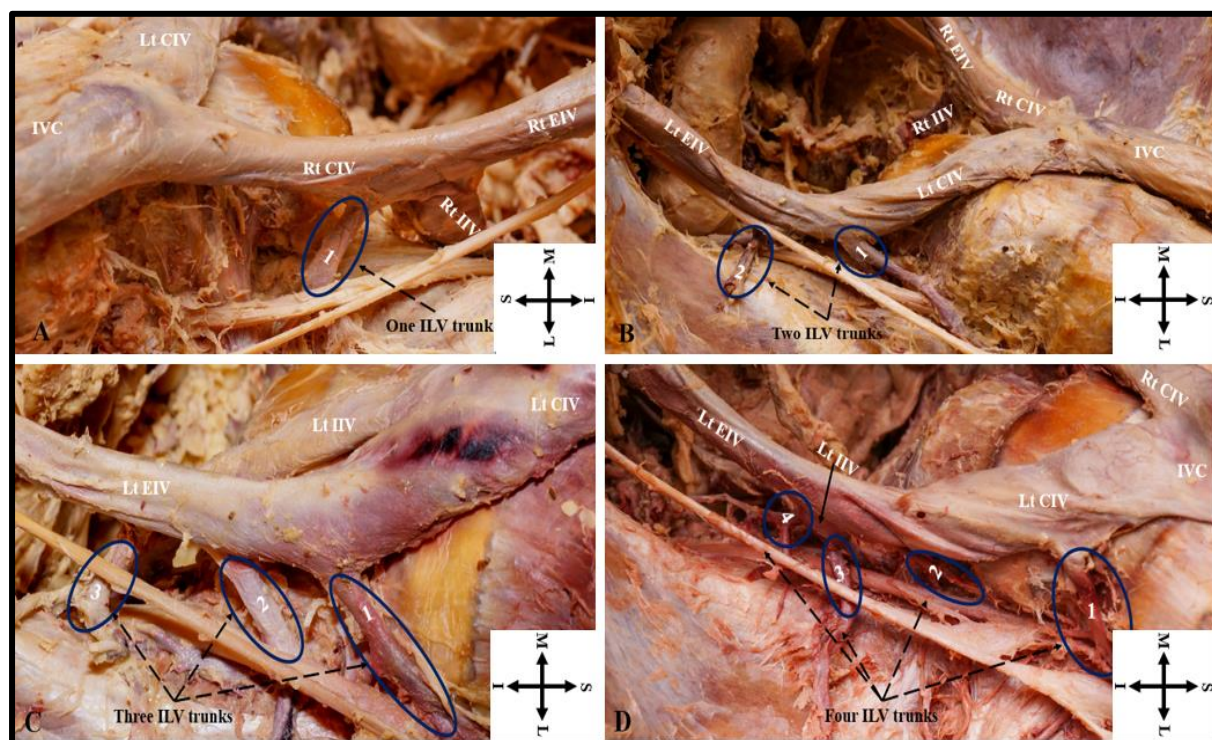


Figure 4.4: A photograph (A-D) showing the number of ILV trunks circled in blue. (A) One ILV; (B) Two ILVs; (C) Three ILVs; (D) Four ILVs. ILV= Iliolumbar vein, IVC= Inferior vena cava, CIV= Common iliac vein, EIV= External iliac vein, IIV= Internal iliac vein, Rt= Right side, Lt= Left side, S= Superior, I= Inferior, M= Medial, L= Lateral.

4.2.3 Terminal drainage of ILVs

4.2.3.1 Overall drainage of ILVs

The majority of the ILVs (56.6%) drained into common iliac veins (CIV) (Figure 4.5A-C) with no significant differences between sex and laterality ($p=.23$). Drainage of the ILVs into external

iliac veins (EIV) was significantly higher on the left side ($p=.001$). In comparison, drainage of the ILVs into the internal iliac vein (IIV) was significantly higher on the right side ($p=.001$). On the right side, the ILVs in males drained significantly higher into the IIV ($p=.001$), while on the left side, the ILVs in males drain significantly higher into EIV ($p=.001$). On the right side ILVs in females drained significantly higher into IIV ($p=.004$), while on the left side, there were no significant drainage differences ($p=.82$).

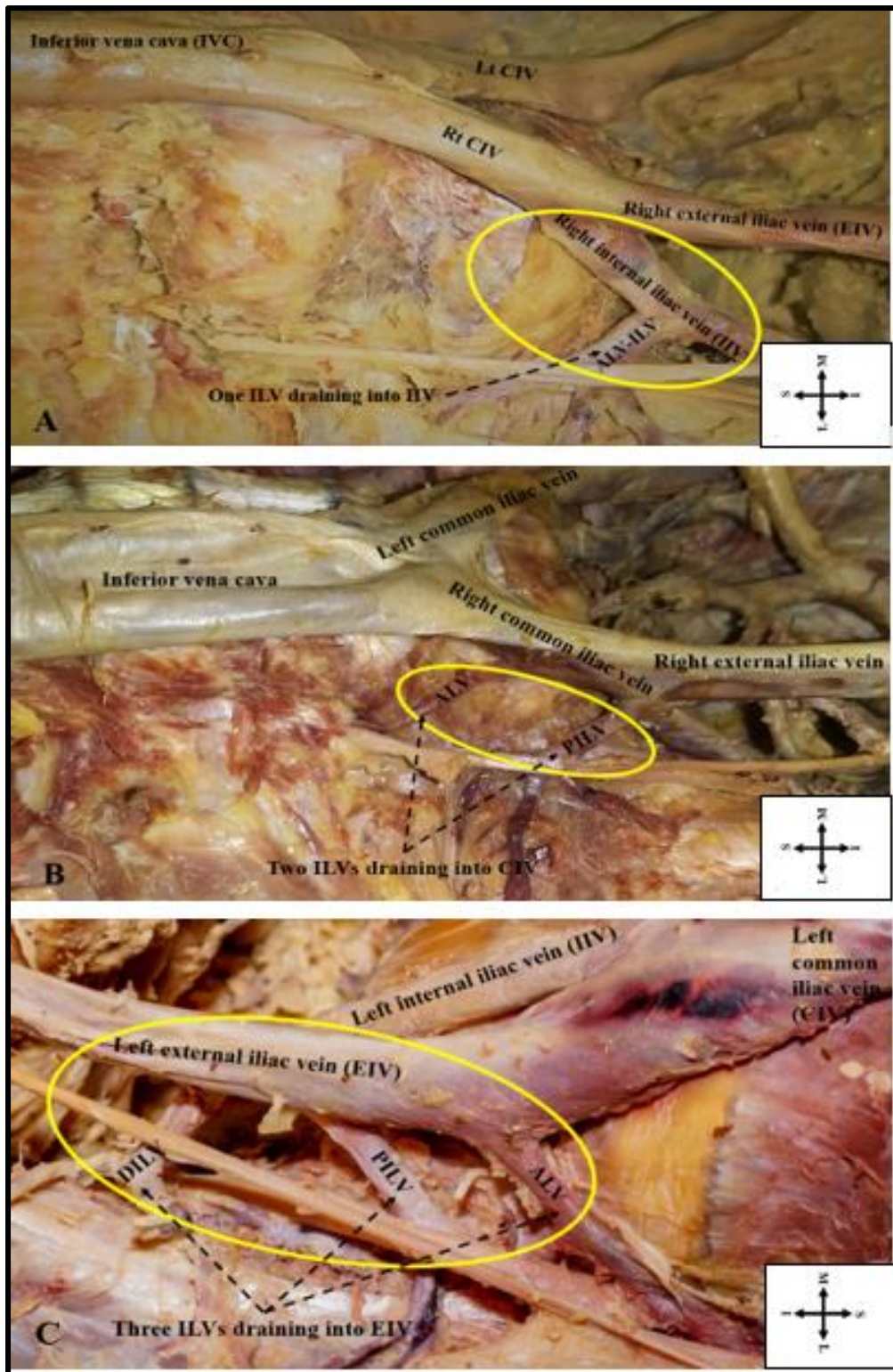


Figure 4.5: A photograph (A-C) showing the terminal drainage of ILVs circled in yellow. ILVs were draining into (A) IIV; (B) CIV; (C) EIV. ALV= Ascending lumbar vein, ALV-ILV= Ascending lumbar vein and Iliolumbar vein common trunk, PILV= Proximal iliolumbar vein, DILV= Distal iliolumbar vein, Rt= Right side, Lt= Left side, S= Superior, I= Inferior, M= Medial, L= Lateral.

4.2.3.2 Specific Terminal drainage of ILV trunks

The majority of ALVs (90.7%) drain into CIV (Figure 4.6) with no significant differences between the sex ($p=.31$) and sides of the body ($p=.54$). Most of ALV-ILVs (96.5%) drain into CIV with no significant sex ($p=.79$) and laterality differences ($p=.79$) (Figure 4.7). The highest proportion (44.9%) of PILVs drain into CIV. Drainage of PILVs into EIV was significantly higher on the left side ($p=.022$) with no significant sex differences ($p=.25$). Both male ($p=.003$) and female ($p=.005$) PILVs drain significantly higher (70.8%) into IIVs on the right side (Figure 4.8). The majority of DILVs (58%) drain into IIV, which was significantly higher on the right side ($p=.002$). In males and on the left side, DILVs (73.3%) drained into EIV ($p=.011$) while those on the right side (71.4%) drain significantly higher into IIVs ($p=.005$). Females showed no significant side differences (Figure 4.9). The majority of AILVs (80%) drained into IIV with no significant sex and laterality differences. 10% of AILVs drained into both IIV and EIV (Figure 4.10).

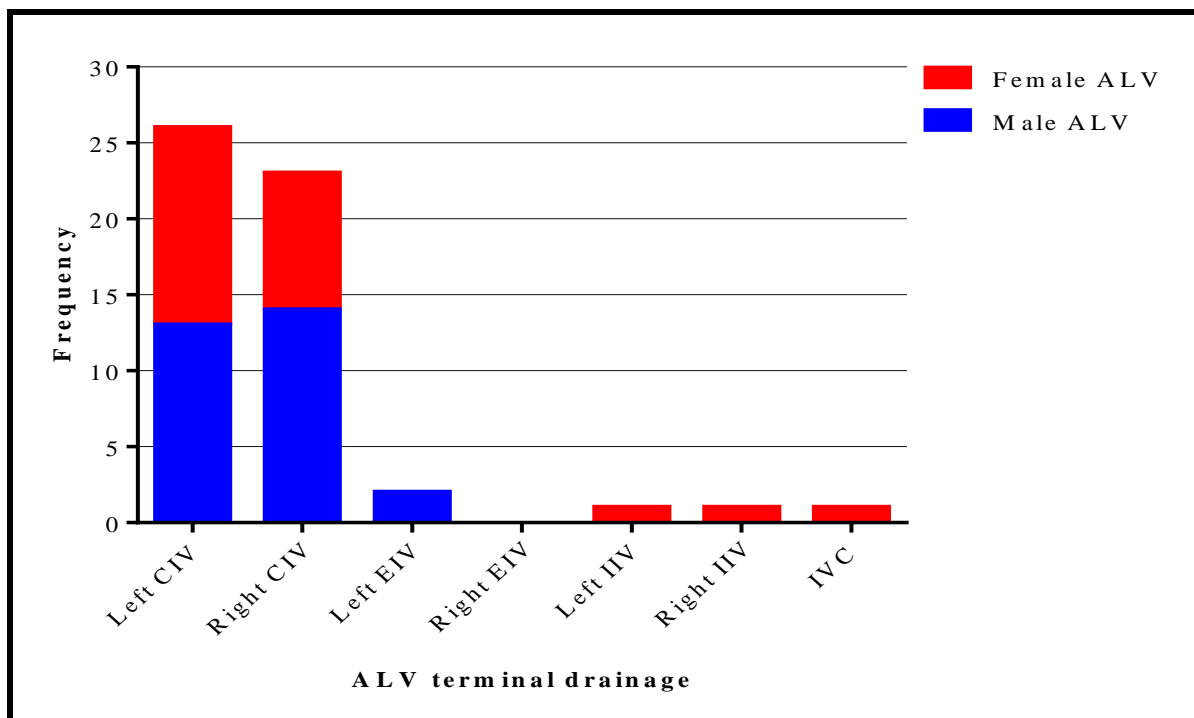


Figure 4.6: A bar graph showing Ascending lumbar vein (ALV) terminal drainage in relation to sex. CIV= Common iliac vein, EIV= External iliac vein, IIV= Internal iliac vein, IVC= Inferior vena cava.

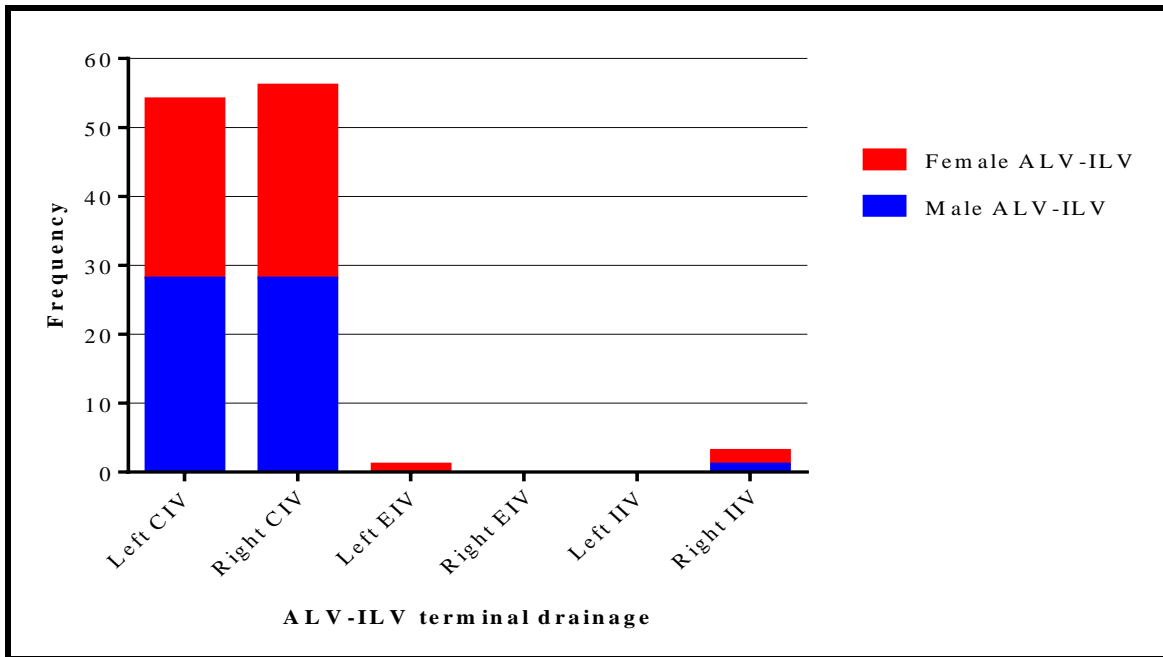


Figure 4.7: A bar graph showing Ascending lumbar vein and Iliolumbar vein common trunk (ALV-ILV) terminal drainage in relation to sex. CIV= Common iliac vein, EIV= External iliac vein, IIV= Internal iliac vein.

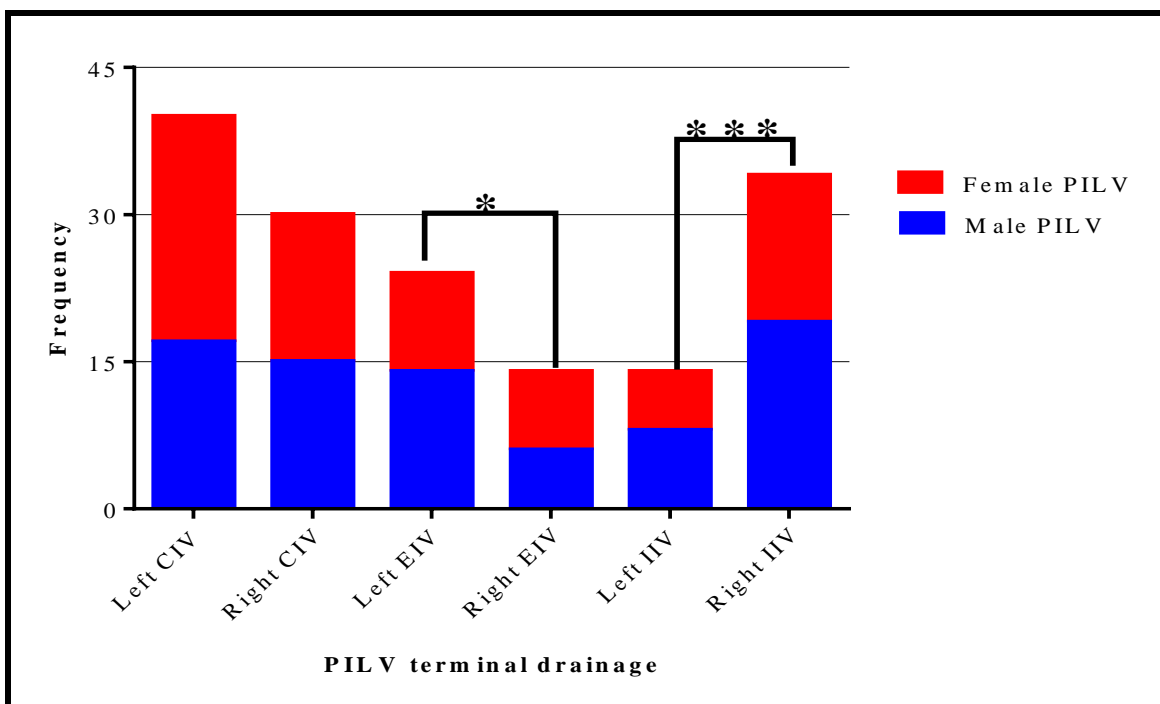


Figure 4.8: A bar graph showing Proximal iliolumbar vein (PILV) terminal drainage in relation to sex. CIV= Common iliac vein, EIV= External iliac vein, IIV= Internal iliac vein. * $p < 0.05$, ** $P \leq 0.01$, *** $p < 0.001$.

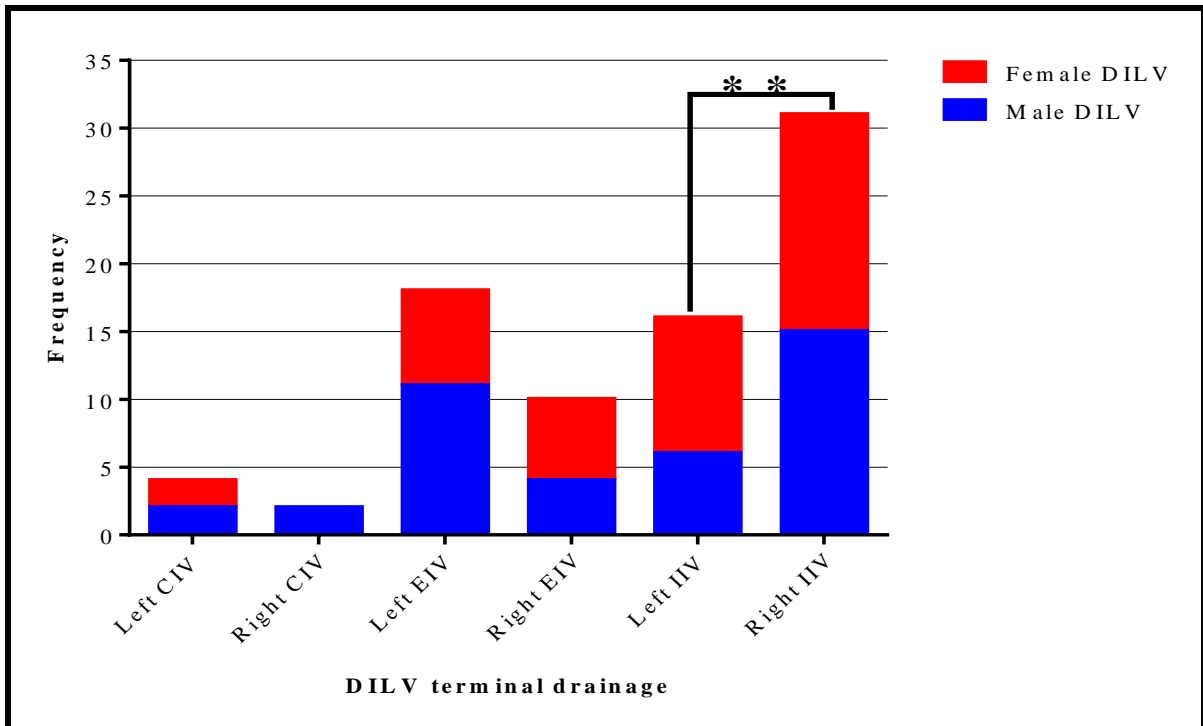


Figure 4.9: A bar graph showing Distal iliolumbar vein (DILV) terminal drainage in relation to sex. CIV= Common iliac vein, EIV= External iliac vein, IIV= Internal iliac vein. ** $P \leq 0.005$.

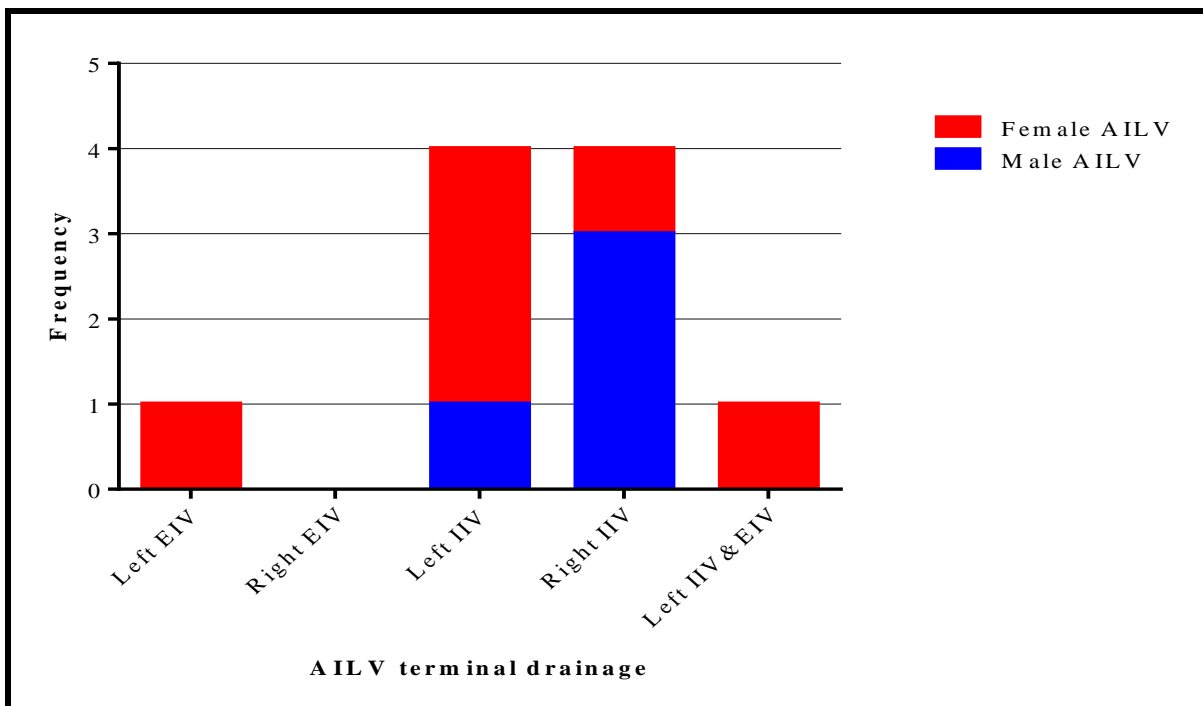


Figure 4.10: A bar graph showing Accessory iliolumbar vein (AILV) terminal drainage in relation to sex. CIV= Common iliac vein, EIV= External iliac vein, IIV= Internal iliac vein, IIV&EIV= drainage into both Internal iliac vein and External Iliac vein.

4.2.4 Tributaries of ILVs

4.2.4.1 Tributaries of ILVs in general

Most (64.8%) of the ILVs had two tributaries. The maximum number of tributaries was six (Figure 4.11). The presence of five tributaries was significantly higher on the right side ($p=.005$). No significant sex differences were observed ($p=.84$).

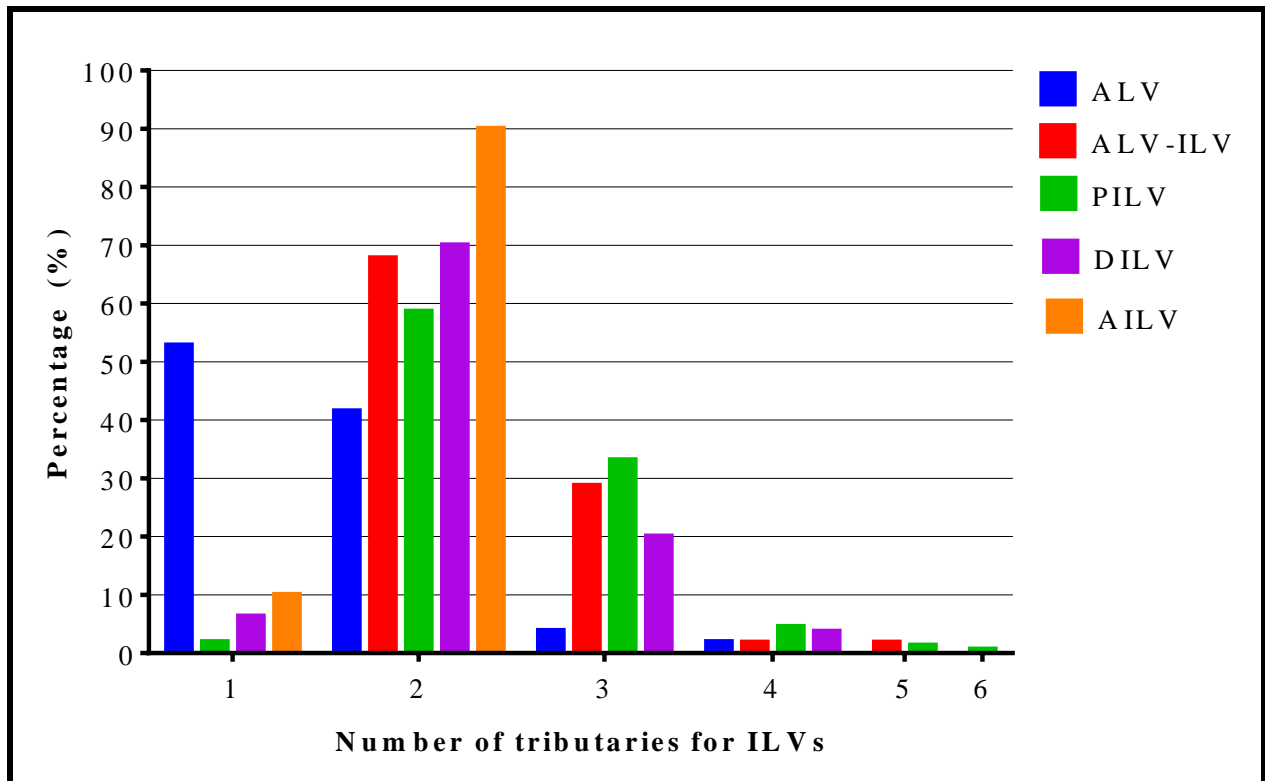


Figure 4.11: A bar graph showing proportions of tributaries in all Iliolumbar vein (ILV) trunks. ALV= Ascending lumbar vein, ALV-ILV= Ascending lumbar vein and Iliolumbar vein common trunk, PILV= Proximal iliolumbar vein, DILV= Distal iliolumbar vein, AILV= Accessory iliolumbar vein.

4.2.4.2 Tributaries of each ILV trunk

The majority of ALV trunks (52.8%) received one tributary in the lumbosacral region. The maximum number of tributaries observed was four, and they were all observed in females and on the left side. The left side had a higher number of tributaries ($p=0.56$) (Figure 4.12). Most of the ALV-ILV trunks had two tributaries (67.8%) with equal proportions between sex and laterality. The presence of more than three tributaries was only observed on the right side. The maximum number of tributaries into the ALV-ILV was five (Figure 4.13). The PILVs had a maximum number of six tributaries (in males, on the right side). Most of the PILV trunks had

two tributaries (58.6%). The presence of three tributaries was significantly higher in males ($p=.0499$). No significant differences were noted regarding the proportions of tributaries and laterality ($p=.91$) (Figure 4.14). The DILVs received a maximum of four tributaries, and this was all observed in males. The majority of DILVs (70%) had two tributaries (Figure 4.15). AILVs (90%) had two tributaries with no significant side differences ($p=.37$). The maximum number of tributaries observed (two) was significantly higher in females on the left ($p=.02$) (Figure 4.16).

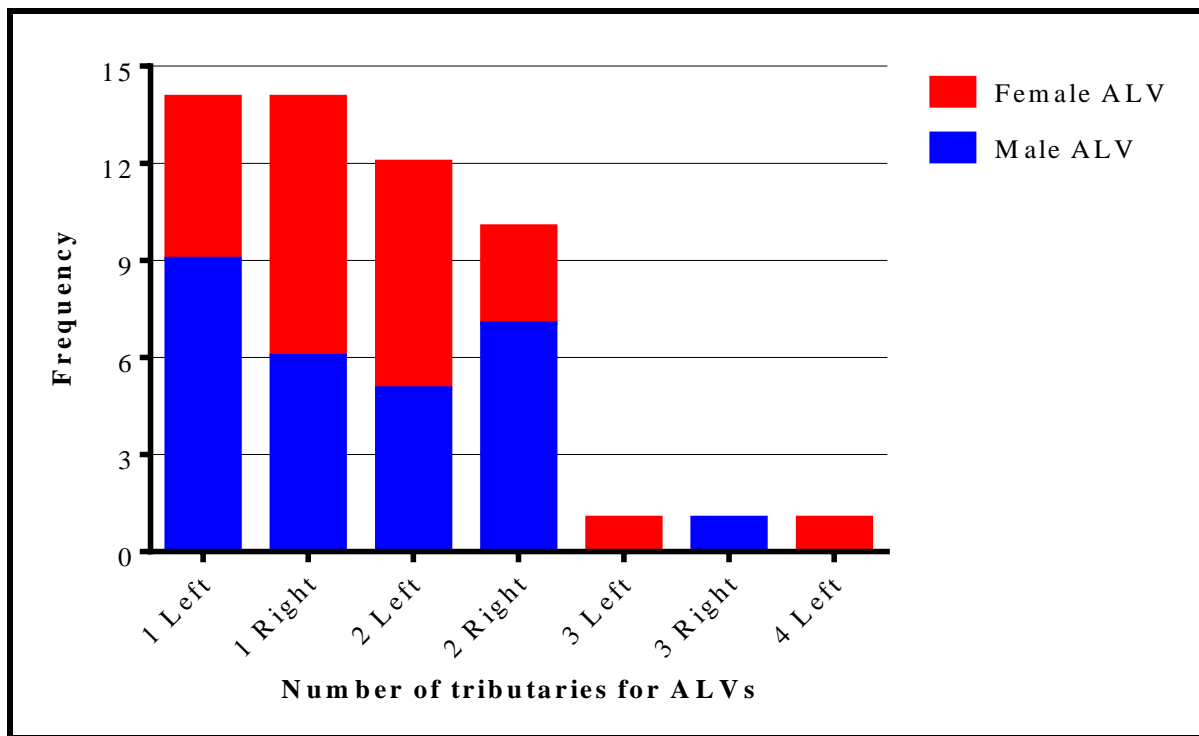


Figure 4.12: A bar graph showing the distribution of Ascending lumbar vein (ALV) tributaries among sex and laterality.

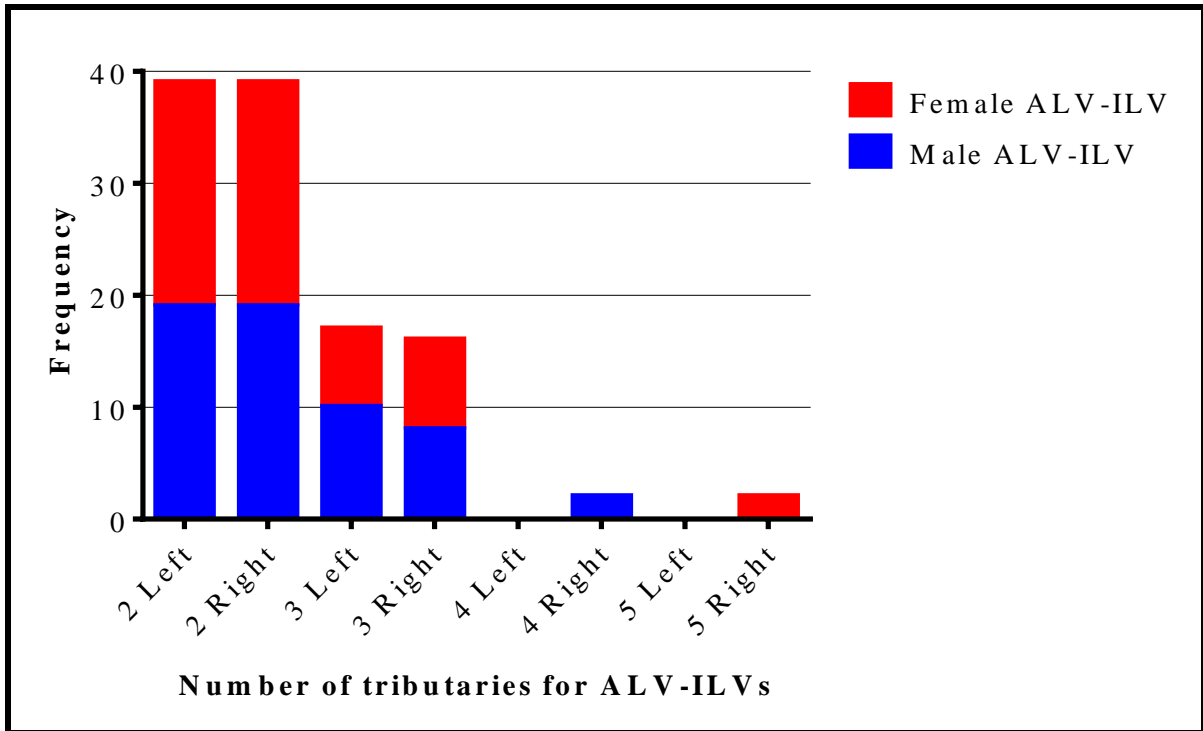


Figure 4.13: A bar graph showing the distribution of Ascending lumbar vein and Iliolumbar vein common trunk (ALV-ILV) tributaries among sex and laterality.

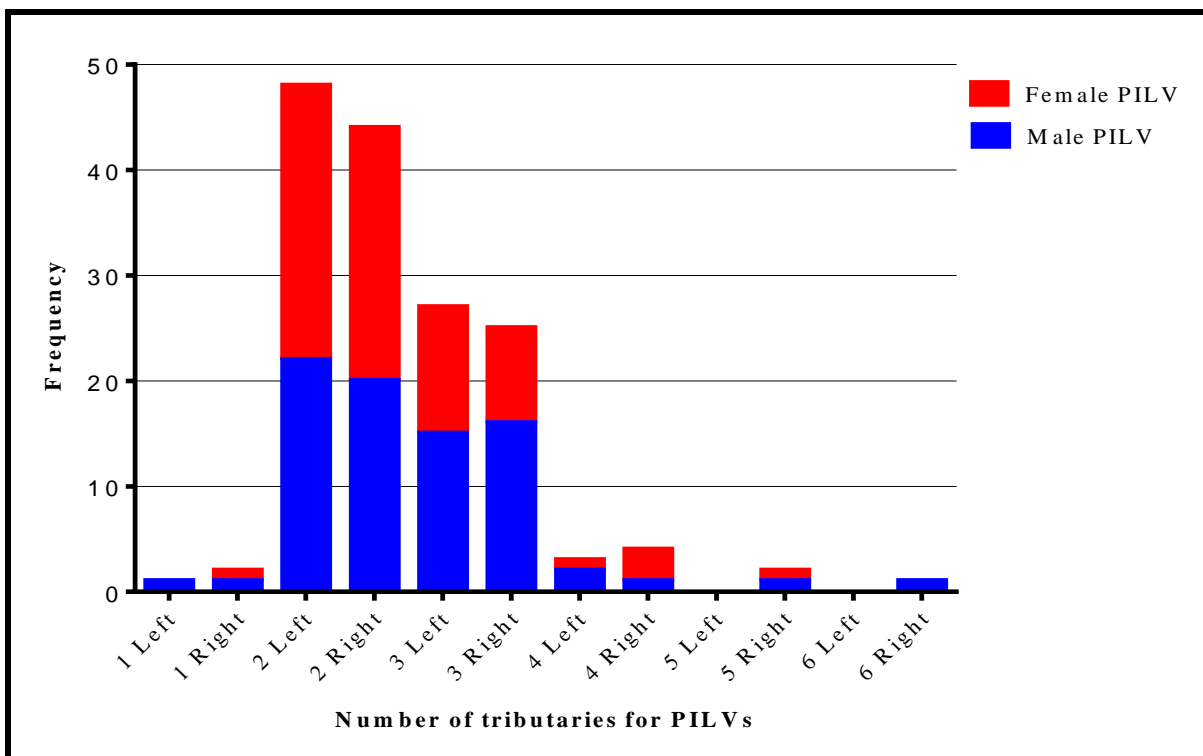


Figure 4.14: A bar graph showing the distribution of Proximal iliolumbar vein (PILV) tributaries among sex and laterality.

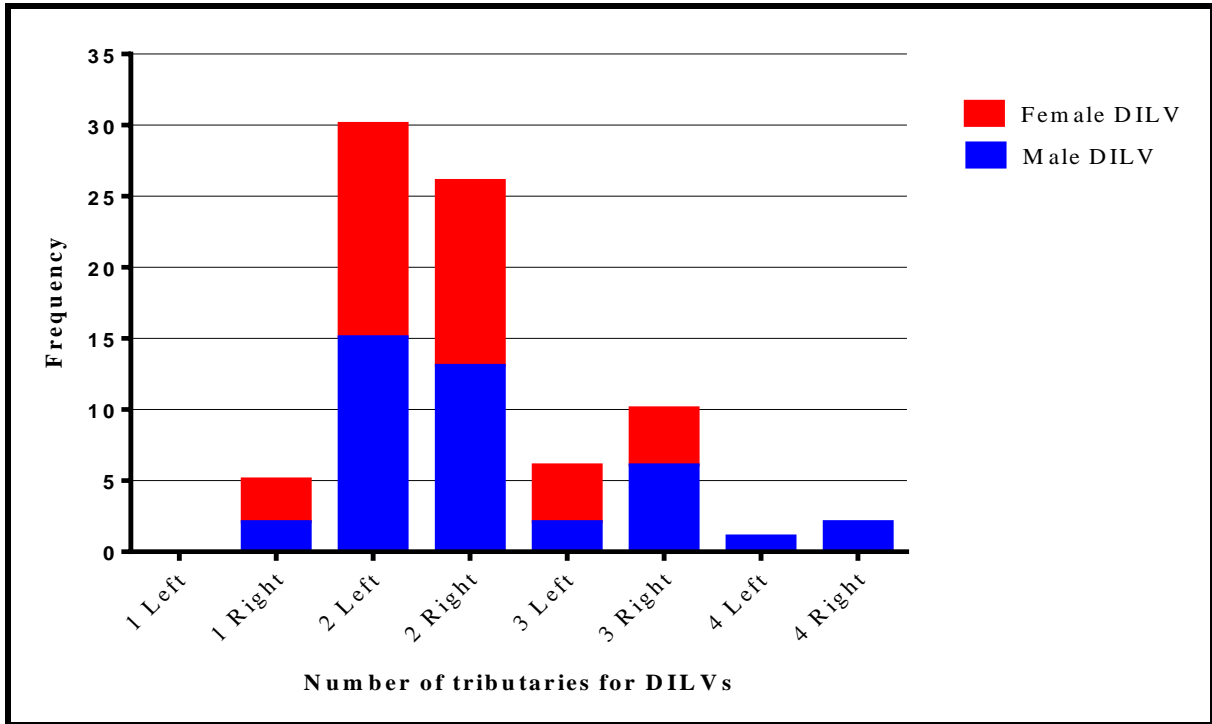


Figure 4.15: A bar graph showing the distribution of Distal iliolumbar vein (DILV) tributaries among sex and laterality.

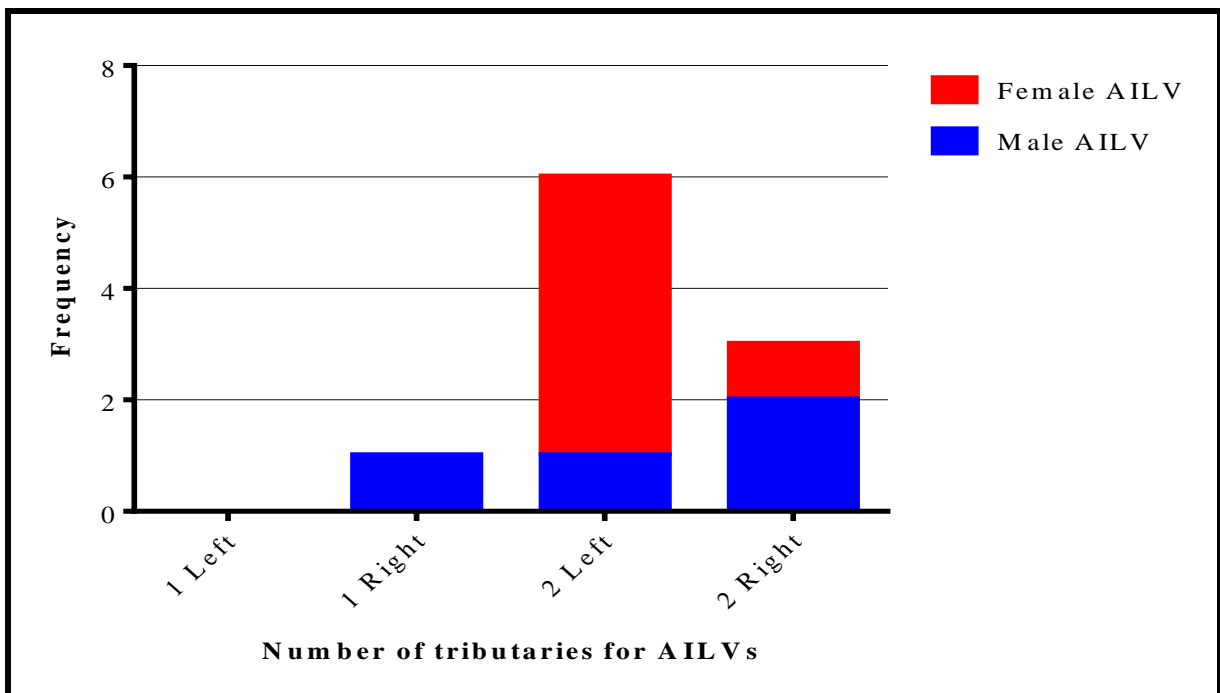


Figure 4.16: A bar graph showing the distribution of Accessory iliolumbar vein (AILV) tributaries among sex and laterality.

4.2.5 Tributary draining sites

The highest proportion of the ALVs (43.4%) drain the L5 vertebra region (Figure 4.17A-B). Drainage of the region around L4/L5 (85.7%) vertebra by ALVs was significantly high on the left side ($p=.008$). On the left side, males showed a significantly higher proportion of draining L4/L5 disc space ($p=.014$). A greater proportion of ALV-ILVs (42.6%) drained the iliac fossa, iliacus muscle, psoas major muscle and the L5 vertebral region; the proportions were significantly higher in males on the left side ($p=.039$). Females had a significantly higher proportion of ALV-ILVs draining L5 vertebral on the right ($p=.018$). The majority of the PILVs (55.1%) drained the combination of iliac fossa, iliacus muscle, psoas major muscle and the L5 vertebral region. There were no significant proportional differences between the left and right sides of the body ($p=.36$) and sex ($p=.54$). The majority of the DILVs (67%) drain the iliac fossa and iliacus muscle with no statistically significant proportional differences between left and right sides of the body ($p=.56$) and sex ($p=.85$). AILVs predominantly (90%) drain iliac fossa and iliac muscle with no statistically significant differences on sex ($p=.37$) and laterality ($p=.64$) (Figure 4.18A-B).

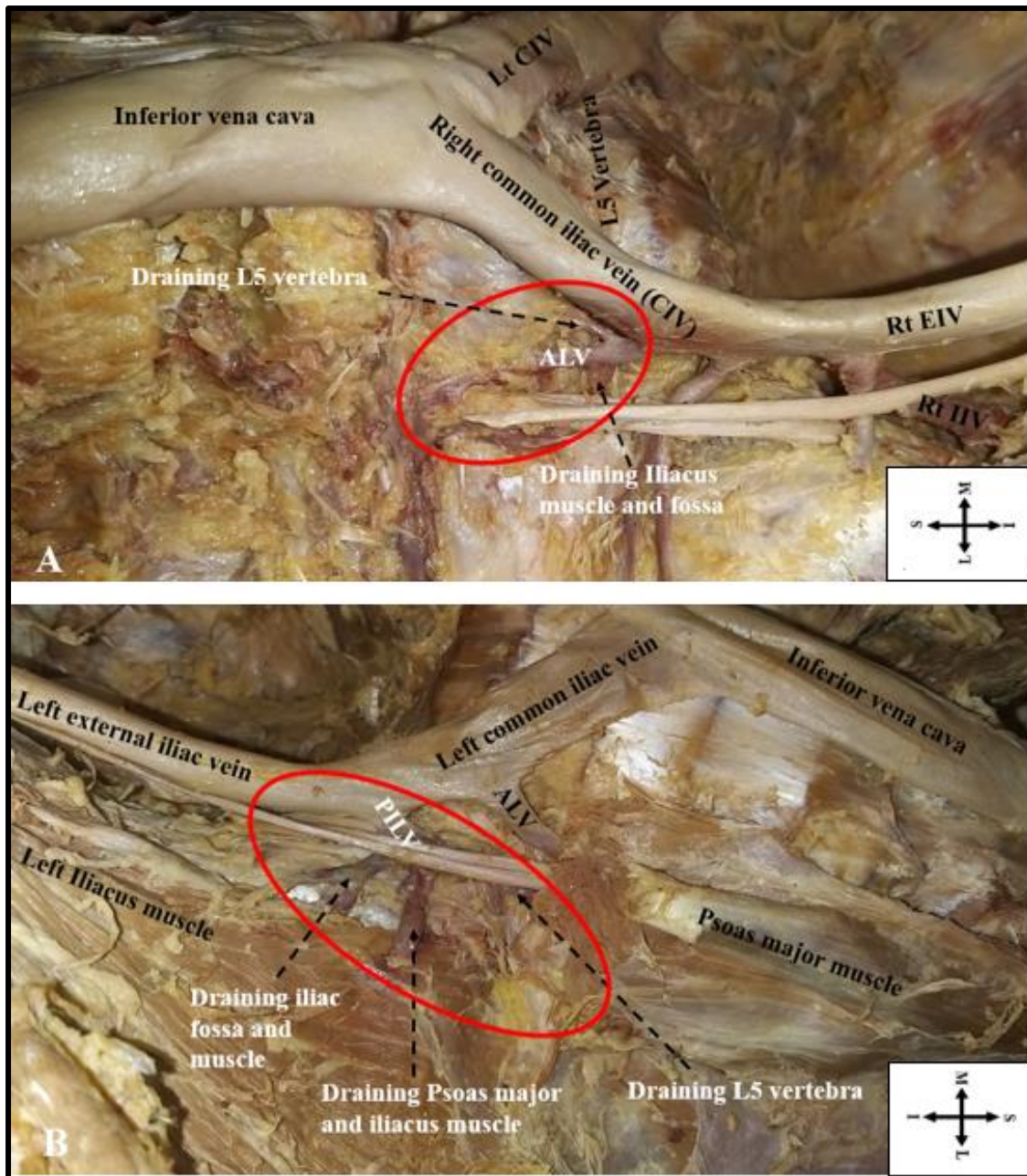


Figure 4.17: A photograph (A-B) showing tributaries draining sites for iliolumbar veins circled in red. Dashed arrows are pointing at tributaries of ILVs. (A) ALV drainage sites and (B) PILV draining sites. ALV= ascending lumbar vein, PILV= proximal iliolumbar vein, EIV= External iliac vein, IIV= Internal iliac vein, Lt= Left side, Rt= Right side, S= Superior, I= Inferior, M= Medial, L= Lateral.

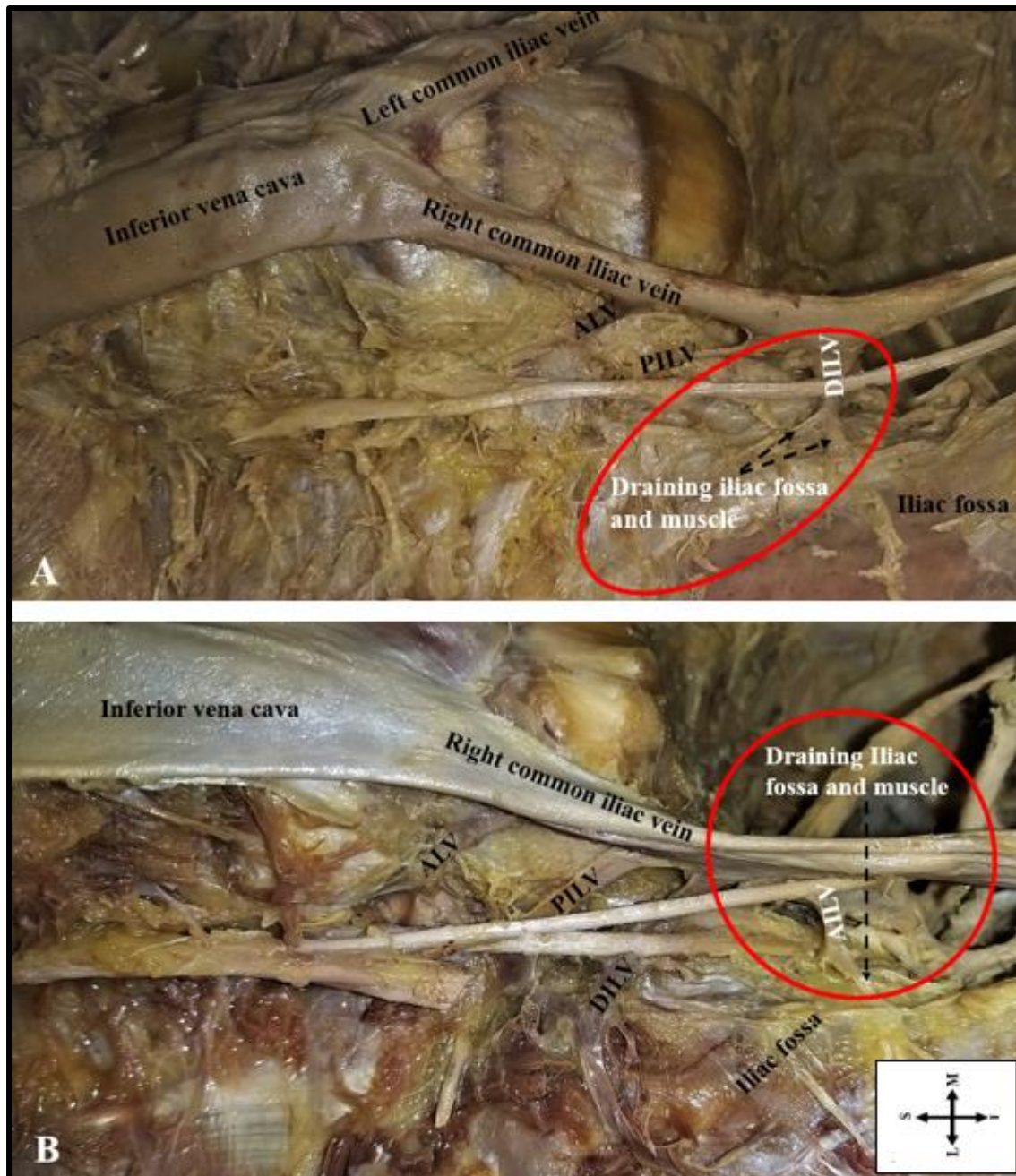


Figure 4.18: A photograph (A-B) showing tributaries draining sites for ILVs circled in red. Dashed arrows are pointing at tributaries of ILVs. (A) DILV drainage sites and (B) AILV draining sites. ALV= Ascending lumbar vein, PILV= Proximal iliolumbar vein, DILV= Distal iliolumbar vein, AILV= Accessory iliolumbar vein, S= Superior, I= Inferior, M= Medial, L= Lateral.

4.2.6 Anastomosis of ILVs

The tributaries of 77 (45.8%) ILVs anastomosed with each other (Table 4.4) (Figures 4.19A-B, 4.20A-B and 4.21). A large proportion (48%) of the anastomoses were classified as type 1

anastomosis (anastomosis between ALV and PILV). Proportions of type 3 (73.3%) (anastomosis between ALV-ILV and PILV) anastomosis were significantly higher on the right side of the body ($p=.011$). No proportionally significant sex differences were observed.

Table 4.4: The proportional distribution of the types of anastomosis present with sex and laterality.

Type	Type of tributary anastomosis	Left side			Right side			Total
		Male	Female	Total	Male	Female	Total	
1	ALV and Proximal ILV	10	10	20 (58.8%)	9	8	17 (39.5%)	37 (48%)
2	ALV and Distal ILV	0	0	0 (0%)	0	1	1 (2.3%)	1 (1.3%)
3	ALV-ILV and Proximal ILV	2	2	4 (11.8%)	5	6	11 (25.6%)	15 (19.5%)
4	Proximal and Distal ILV	2	0	2 (5.9%)	3	3	6 (14.0%)	8 (10.4%)
5	Distal and accessory ILV	0	0	0 (0%)	1	1	2 (4.6%)	2 (2.6%)
6	ALV-ILV, Proximal and Distal ILV	3	4	7 (20.6%)	2	4	6 (14.0%)	13 (16.9%)
7	ALV-ILV, Proximal, Distal, and accessory ILV	0	1	1 (2.9%)	0	0	0 (0%)	1 (1.3%)
Total				34 (100%)			43 (100%)	77 (100%)

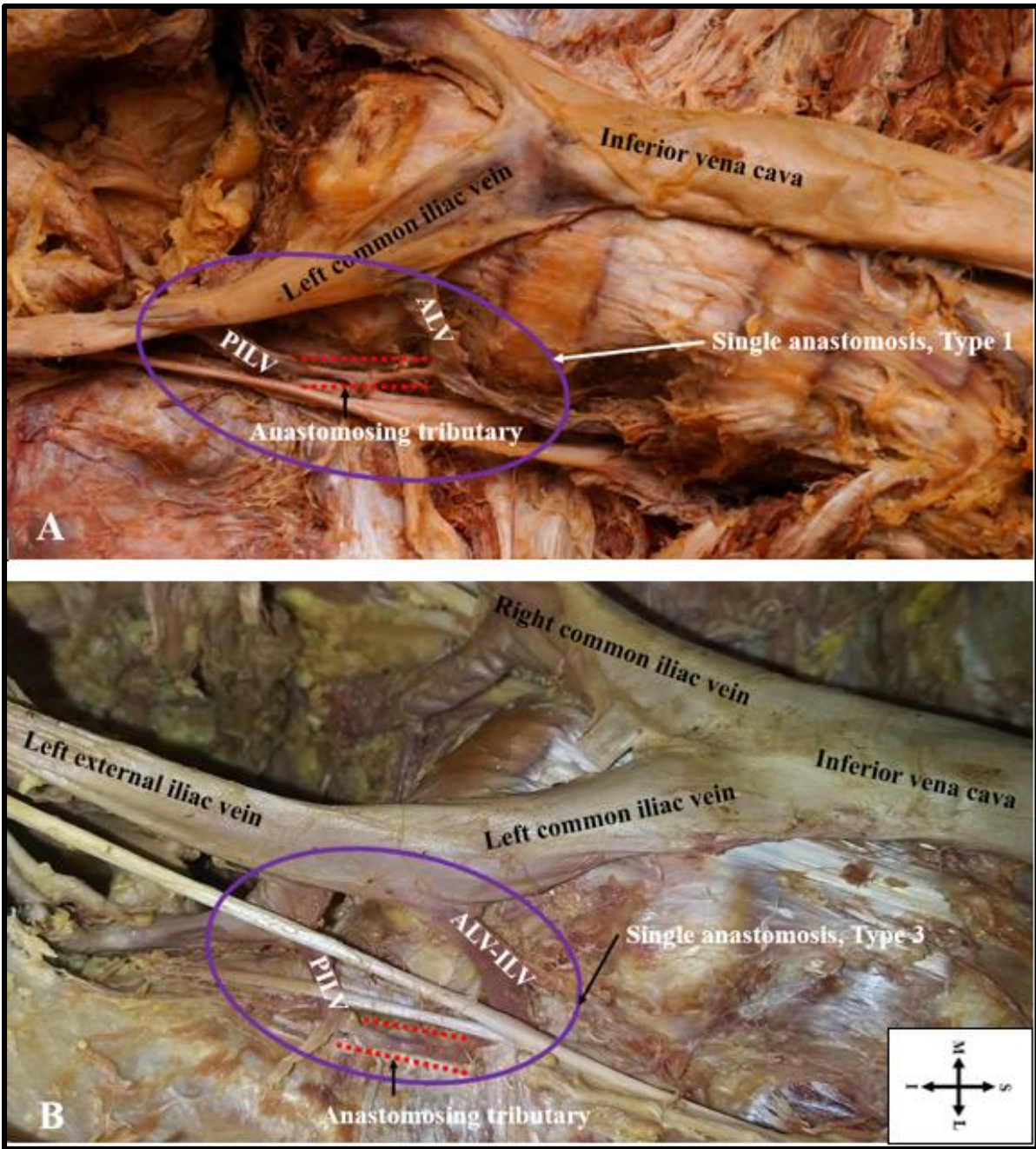


Figure 4.19: A photograph (A-B) showing single anastomosis of the ILVs circled in purple. Anastomosing tributaries are highlighted with red dotted lines. (A) Type 1; (B) Type 3. ALV= Ascending lumbar vein, PILV= Proximal iliolumbar vein, ALV-ILV= Ascending lumbar vein and Iliolumbar vein common trunk, S= Superior, I= Inferior, M= Medial, L= Lateral.

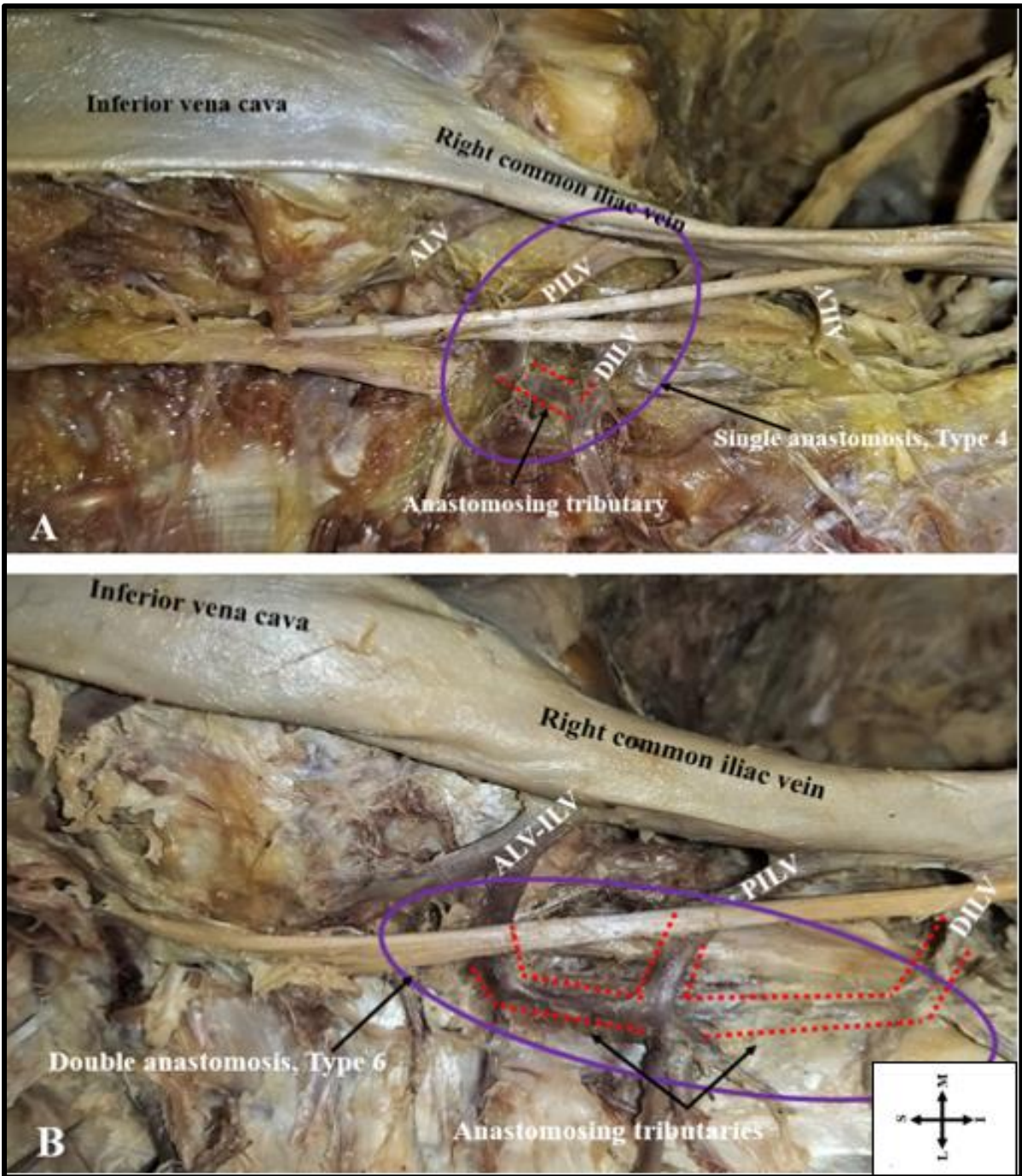


Figure 4.20: A photograph (A-B) showing single and double anastomosis of the ILV circled in purple. Anastomosing tributaries are highlighted with red dotted lines. (A) Type 4; (B) Type 6. ALV= Ascending lumbar vein, PILV= Proximal iliolumbar vein, ALV-ILV= Ascending lumbar vein and Iliolumbar vein common trunk, DILV= Distal iliolumbar vein, AILV= Accessory iliolumbar vein, S= Superior, I= Inferior, M= Medial, L= Lateral.

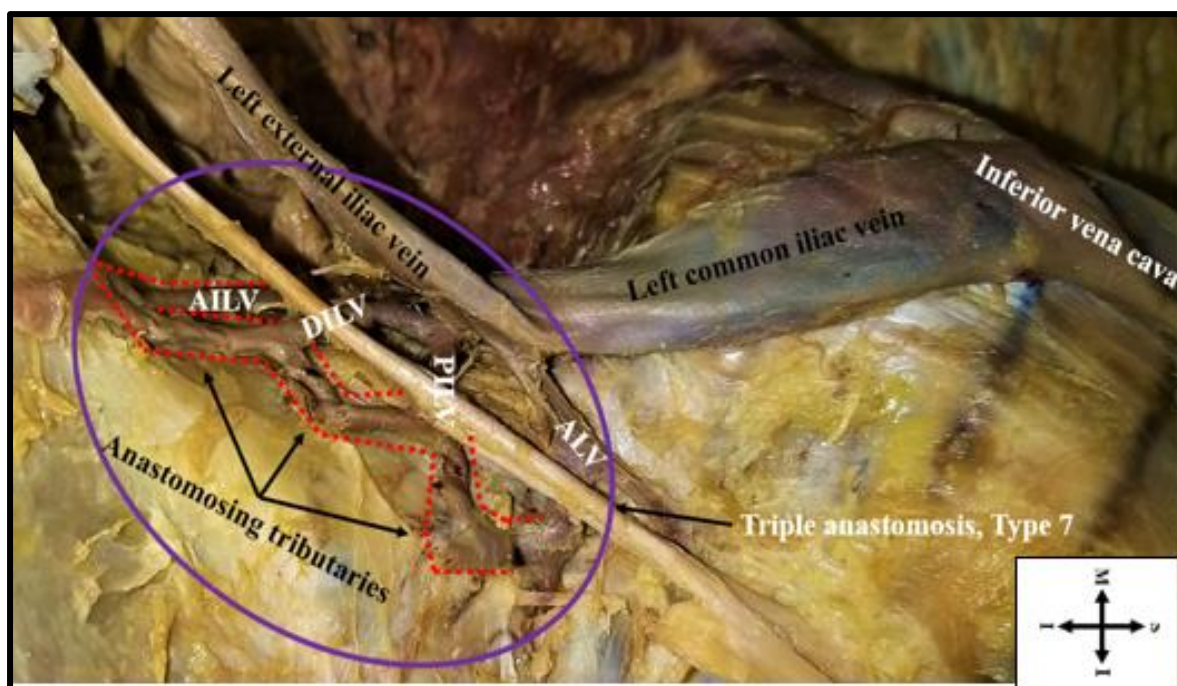


Figure 4.21: A photograph showing triple anastomosis (Type 7) of the ILV circled in purple. Anastomosing tributaries are highlighted with red dotted lines. ALV= Ascending lumbar vein, PILV= Proximal iliolumbar vein, ALV-ILV= Ascending lumbar vein and Iliolumbar vein common trunk, DILV= Distal iliolumbar vein, AILV= Accessory iliolumbar vein, S= Superior, I= Inferior, M= Medial, L= Lateral.

4.2.7 Entry positioning of ILVs into terminal drainage

The direction of entry of ILVs into terminal drainage was predominantly lateral (Figure 4.22) on the left side ($p=.001$) and predominantly posterior on the right side ($p=.001$), as shown in Table 4.5 below. There were no statistically significant sex differences.

Table 4.5: The relation of the direction of ILVs entry into terminal drainage and laterality.

ILV trunk	Left side			Right side		
	Lateral	Posterior	P-value	Lateral	Posterior	P-value
ALV	27	0	.001	1	25	.001
ALV-ILV	53	3	.001	7	52	.001
PILV	44	35	.152	4	74	.001
DILV	27	10	.001	6	37	.001
AILV	4	2	.248	0	4	.005
Total	155	50	.001	18	193	.001
	205			210		

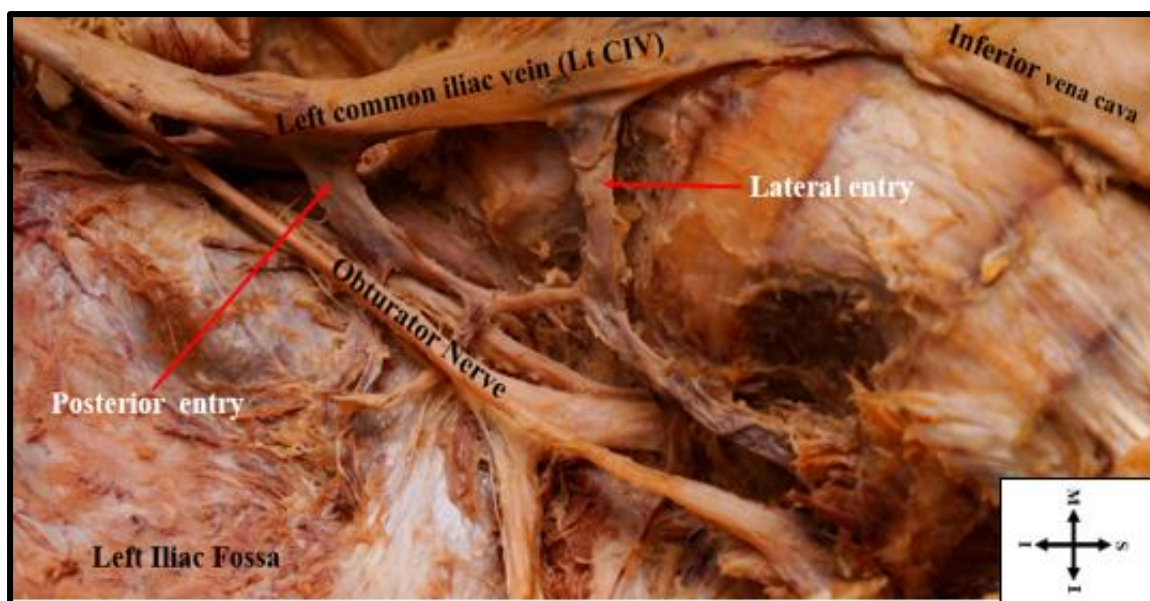


Figure 4.22: A photograph showing the entry position of the iliolumbar veins (ILVs). Red arrows showing directions of ILVs entry into terminal drainage. S= Superior, I= Inferior, M= Medial, L= Lateral.

4.3 Classification of ILVs

The majority of the cadavers (60.71%) showed Unruh *et al.* (2008) classification type 1 (Table 4.6). Type 2 was the least observed (6.55%) (Figure 4.23A-C). The differences between the left and right sides of the body in this type were not statistically significant ($p=.66$). There were no sex differences amongst all types.

Table 4.6: Sex and laterality distribution of ILVs using Unruh *et al.* (2008) Classification system.

Side	Left side			Right side			Total
	Male	Female	Total	Male	Female	Total	
1	25	25	50	25	27	52	102 (60.71)
2	3	2	5	3	3	6	11 (6.55%)
3	15	14	29	15	11	26	55 (32.74%)
Total	43	41	84	43	41	84	168 (100%)

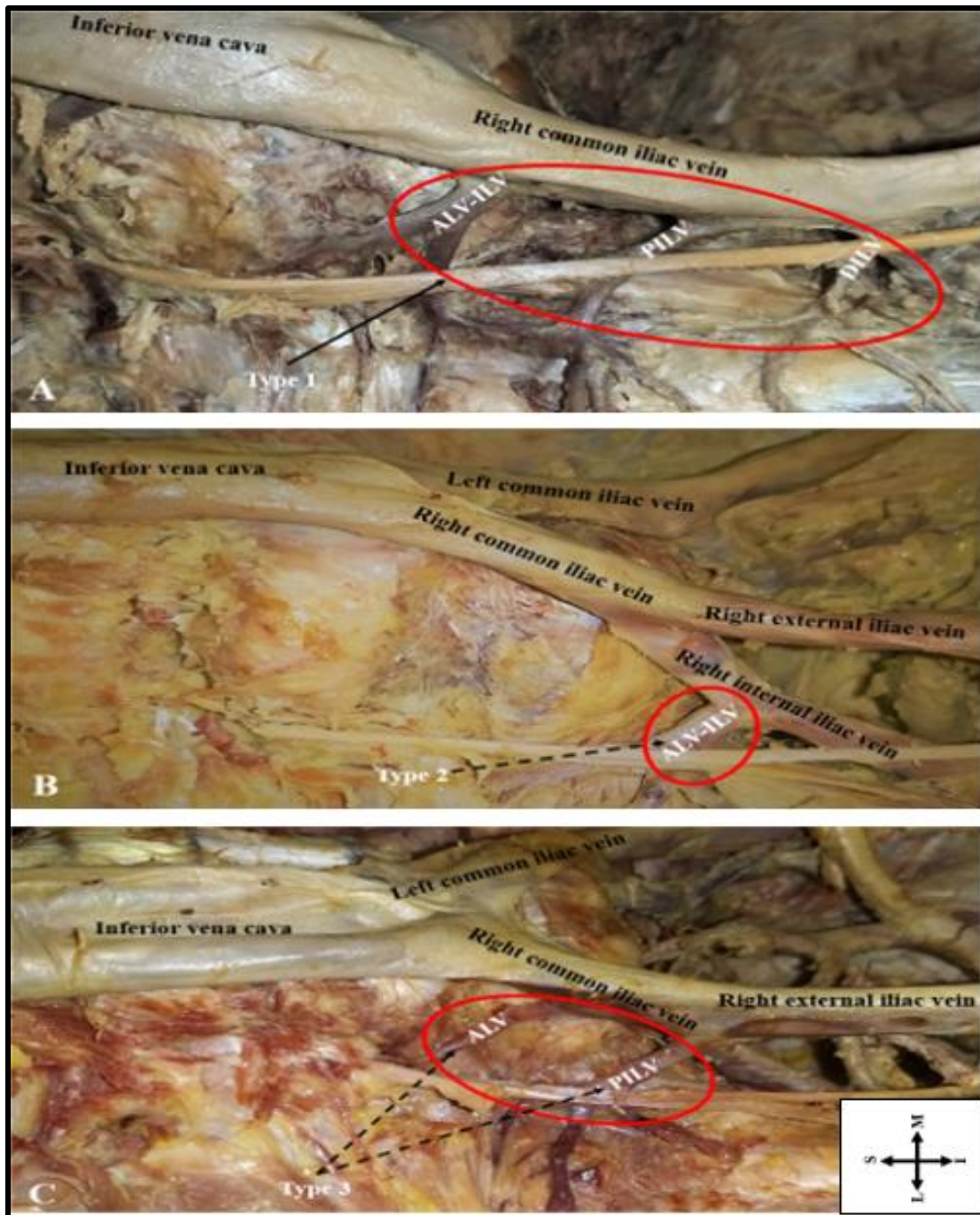


Figure 4.23: A photograph (A-C) showing the classification of iliolumbar veins by Unruh *et al.* (2008). ILVs circled in red. (A) Type 1; (B) Type 2; (C) Type 3. ALV= Ascending lumbar vein, PILV= Proximal iliolumbar vein, ALV-ILV= Ascending lumbar vein and Iliolumbar vein common trunk, DILV= Distal iliolumbar vein, AILV= Accessory iliolumbar vein, S= Superior, I= Inferior, M= Medial, L= Lateral.

4.4 Topography of ILVs

4.4.1 ILVs and Lumbar plexus

4.4.1.1 Obturator nerve (ON) and ILVs

Overall, ON coursed anterior to the majority (96.4%) of ILVs (Figure 4.24A-B). ON coursed anterior to the majority (77.4%) of ALVs with no significant sex ($p=.79$) and laterality ($p=.51$) differences. ON occurred anterior to most (97.4%) of the ALV-ILVs. ON coursed inferior to ALV-ILVs on the right side in females. ON coursed inferior to ALV-ILVs on the left side in males. ON coursed anterior to all (100%) PILVs, DILVs and AILVs (Table 4.7).

Table 4.7: The Obturator nerve (ON) course in relation to all ILVs and laterality.

ILV Type	Course of ON				Total
	Anterior		Inferior		
	Left	Right	Left	Right	
ALV	22	19	6	6	53 (12.8%)
ALV-ILV	55	57	1	2	115 (27.8%)
PILV	79	78	0	0	157 (37.8%)
DILV	37	43	0	0	80 (19.3%)
AILV	6	4	0	0	10 (2.3%)
Total	400 (96.4%)		15 (3.6%)		415 (100%)

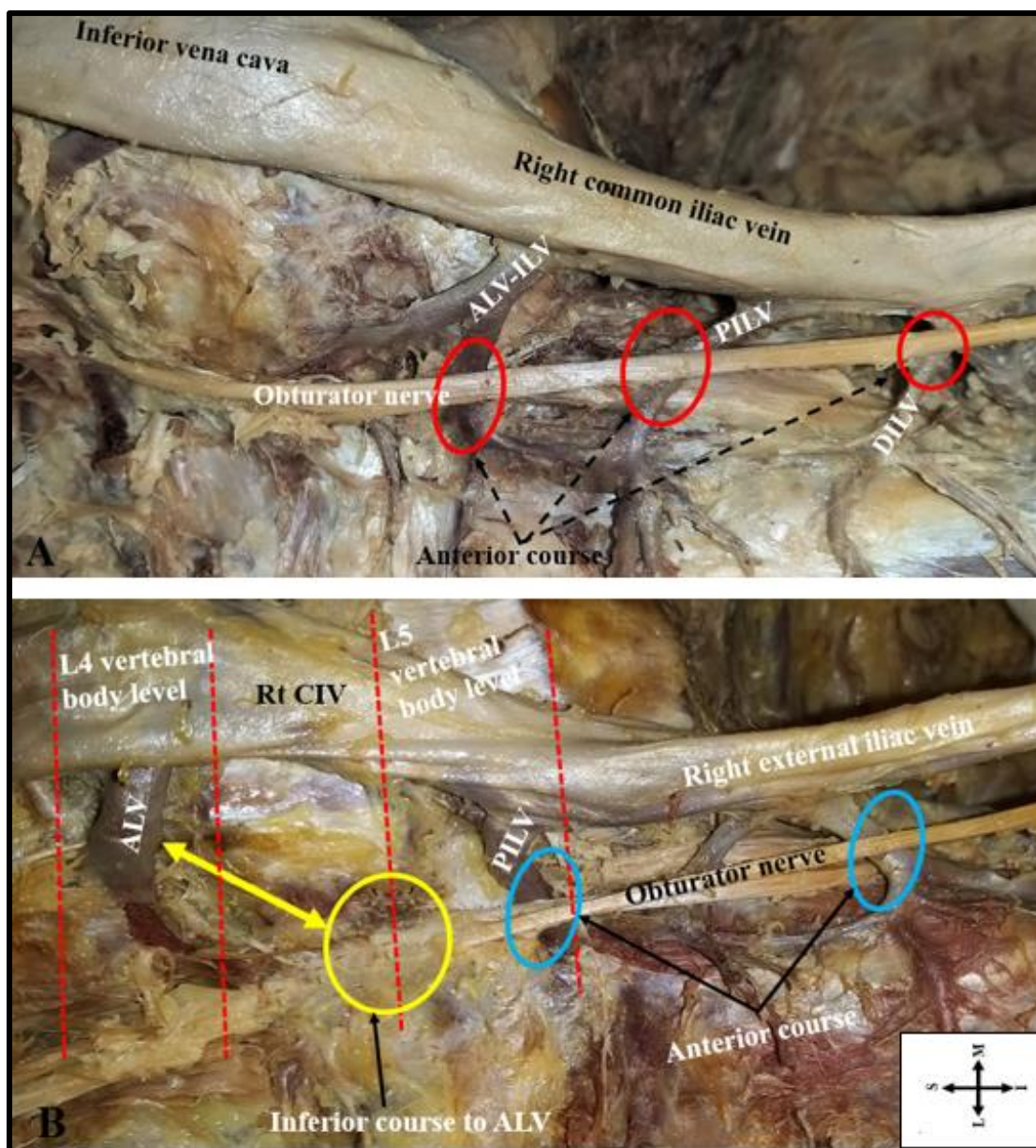


Figure 4.24: A photograph (A-B) showing the course of the obturator nerve in relation to Iliolumbar vein (ILV) trunks. (A) Anterior course to ILVs (red circles); (B) Anterior course (blue circles) and inferior course to ALV (yellow arrow and circle). ALV= Ascending lumbar vein, ALV-ILV= Ascending lumbar vein and Iliolumbar vein common trunk, PILV=Proximal iliolumbar vein, DILV= Distal iliolumbar vein, CIV= Common iliac vein, Rt= Right side, S= Superior, I= Inferior, M= Medial, L= Lateral.

4.4.1.2 LST and ILVs relations

A large proportion of ILVs (35.8%) was in direct relation to the L4 spinal nerve root of the LST (L4/LST), followed by LST (union of L4 & L5 spinal nerve roots) (Figure 4.25A-B). The majority of the L4/LST (67.4%) were anterior to ILVs, and a large proportion (48.3%) of these

were PILVs. L4/LST was anterior to ALV-ILV trunks significantly higher on the right side of the body ($p=.001$). The L4/LST occurred posterior to ALV-ILV trunks significantly higher on the left side of the body ($p=.001$) (Table 4.8). L4/LST coursed anteriorly to DILV trunks significantly higher in females on the left side of the body ($p=.005$). L5 spinal nerve root of the LST (L5/LST) coursed posterior to ILVs in most of the cases (91.4%), and a large proportion (44.4%) of these were PILVs. L5/LST coursed posteriorly to ALVs significantly higher on the left side of the body ($p=.016$) (Table 4.9). L5/LST occurred posterior to DILVs significantly higher in females on the left side of the body ($p=.002$). The majority (93.5%) of LST (union of L4 & L5 spinal nerve roots) coursed posterior to ILVs, of which a large proportion (44.1%) of these were PILVs (Table 4.10). LST coursed posteriorly to AILVs in males only on the left side of the body ($p=.014$).

Table 4.8: The course of the L4 spinal nerve root of LST (L4/LST) in relation to all ILV trunks and laterality.

ILV Type	The course of L4/LST						Total
	Anterior		Posterior		Inferior		
	Left	Right	Left	Right	Left	Right	
ALV	14	12	1	1	5	4	37
ALV-ILV	0	44***	45***	1	1	2	93
PILV	36	34	2	3	0	0	75
DILV	4**	1	1	2	0	0	8
AILV	0	0	1	1	0	0	2
Total	145 (67.4%)		58 (27.0%)		12 (5.6%)		215 (100%)

* $p<0.05$, ** $P \leq 0.01$, *** $p<0.001$.

Table 4.9: The course of the L5 spinal nerve root of LST (L5/LST) in relation to all ILV trunks and laterality.

ILV Type	The course of L5/LST				Total
	Posterior		Inferior		
	Left	Right	Left	Right	
ALV	12*	5	3	4	24
ALV-ILV	39	28	4	5	76
PILV	38	37	0	0	75
DILV	5	3	0	0	8
AILV	1	1	0	0	2
Total	169 (91.4%)		16 (8.6%)		185 (100%)

* $p<0.05$, ** $P \leq 0.01$, *** $p<0.001$.

Table 4.10: The course of the Lumbosacral trunk (LST) in relation to ILV trunks and laterality.

ILV Type	The course of LST						Total
	Anterior		Posterior		Inferior		
	Left	Right	Left	Right	Left	Right	
ALV	0	2	3	2	4	5	16
ALV-ILV	0	0	10	11	0	1	22
PILV	0	0	40	43	1	0	84
DILV	0	0	32	39	0	0	71
AILV	0	0	5	3	0	0	8
Total	2 (1.0%)		188 (93.5%)		11 (5.5%)		201 (100%)

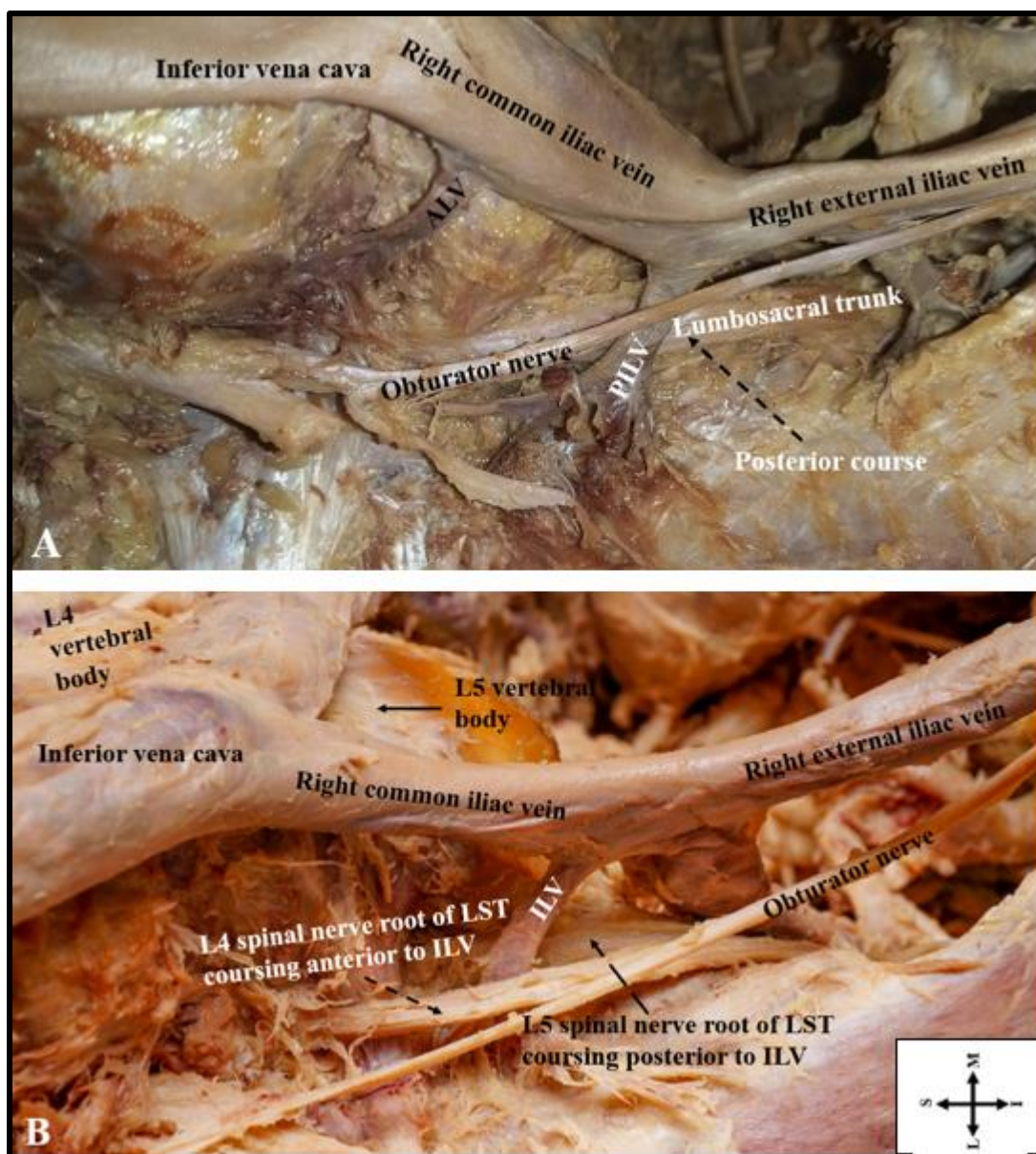


Figure 4.25: A photograph (A-B) showing relations of the lumbosacral trunk (LST) and iliolumbar veins (ILV). (A) LST coursing posterior to ILVs; (B) ILV sandwiched between the L4 and L5 spinal nerve roots of the LST. PILV= Proximal iliolumbar veins, S= Superior, I= Inferior, M= Medial, L= Lateral.

4.4.2 ILVs location on the Lumbosacral vertebral regions

The highest proportions (42.2%) of all ILVs occurred at the level of the S1 vertebra. This was regardless of sex and laterality (Table 4.11).

Table 4.11: The general location of ILVs on the lumbosacral vertebra.

Vertebra Level	Left side ILVs			Right side ILVs			Total
	Male	Female	Total	Male	Female	Total	
L4	2	1	3	3	3	6	9 (2.2%)
L4/L5	1	1	2	0	3	3	5 (1.1%)
L5	30	25	55	34	28	62	117 (28.2%)
L5/S1	28	33	61	23	25	48	109 (26.3%)
S1	41	44	85	49	41	90	175 (42.2%)
Total	102	104	206	109	100	209	415 (100%)

The majority of ALVs occurred at the level of the L5 vertebral body, and males had a significantly higher proportion ($p=.012$) but no significant side differences ($p=.62$). Females had a wider range of locations of ALVs on the right side (L4 to S1). The location of ALVs at the level of L5/S1 disc space was significantly higher in females on the left side ($p=.003$) (Figure 4.26). The majority of the ALV-ILVs (64.3%) occurred at the level of the L5 vertebral body, and there were no statistically significant differences between sex ($p=.51$) and laterality ($p=.51$). Males had a narrower range of locations of ALV-ILVs (L4/L5 to L5) (Figure 4.27). The majority of PILVs (53.5%) were located at the level of the S1 vertebra. There were no significant differences between sex ($p=.36$) and laterality ($p=.76$) (Figure 4.28). Most DILVs (93.8%) were located at the level of the S1 vertebra with no significant differences between sex ($p=.62$) and laterality ($p=.25$). Females had a wider range of locations of DILVs on the right side (Figure 4.29). The majority of AILVs (90%) were lying at the level of the S1 vertebra, and this was significantly higher in females on the left ($p=.021$) (Figure 4.30).

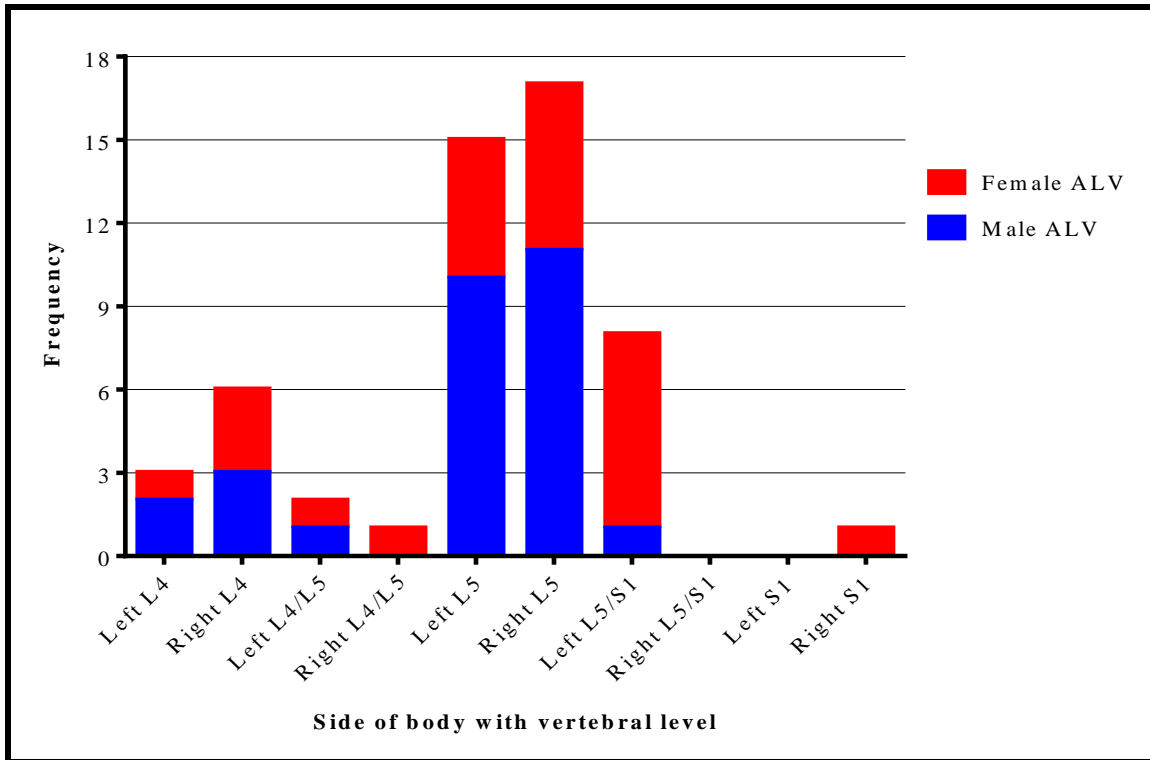


Figure 4.26: A bar graph showing the specific location of Ascending lumbar veins (ALVs) on the lumbosacral vertebra.

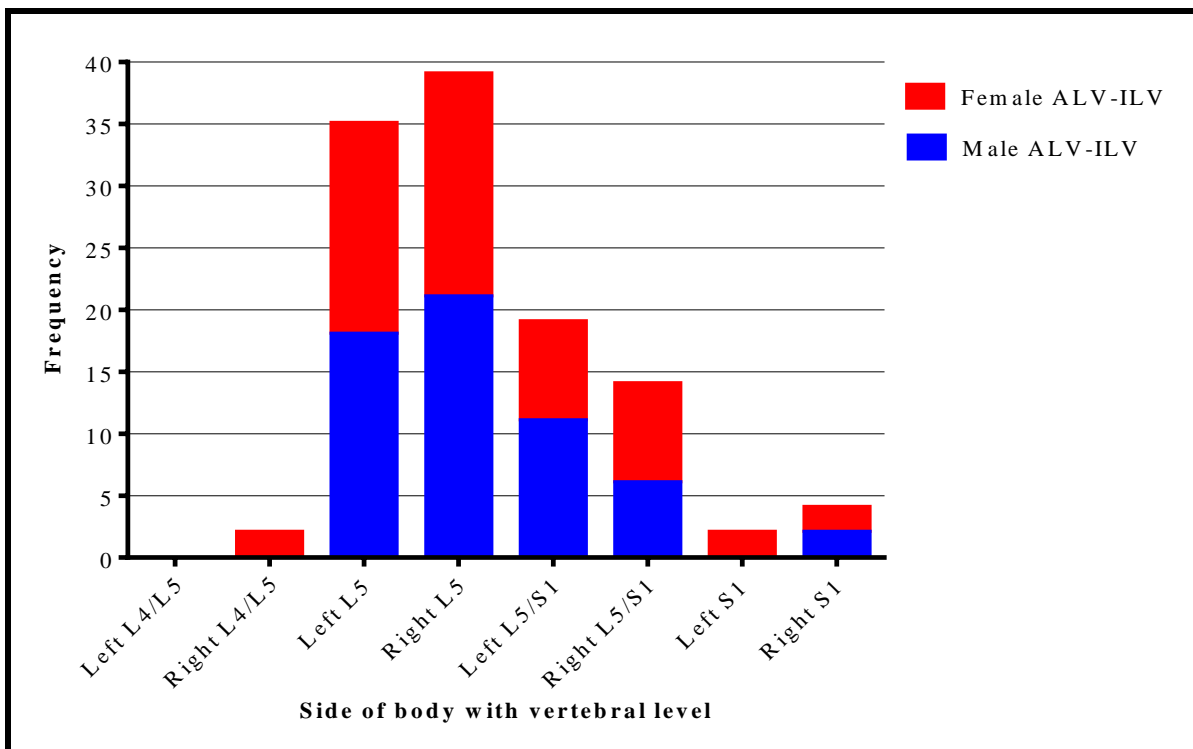


Figure 4.27: A bar graph showing the specific location of the Ascending lumbar vein and iliolumbar vein common trunk (ALV-ILVs) on the lumbosacral vertebra.

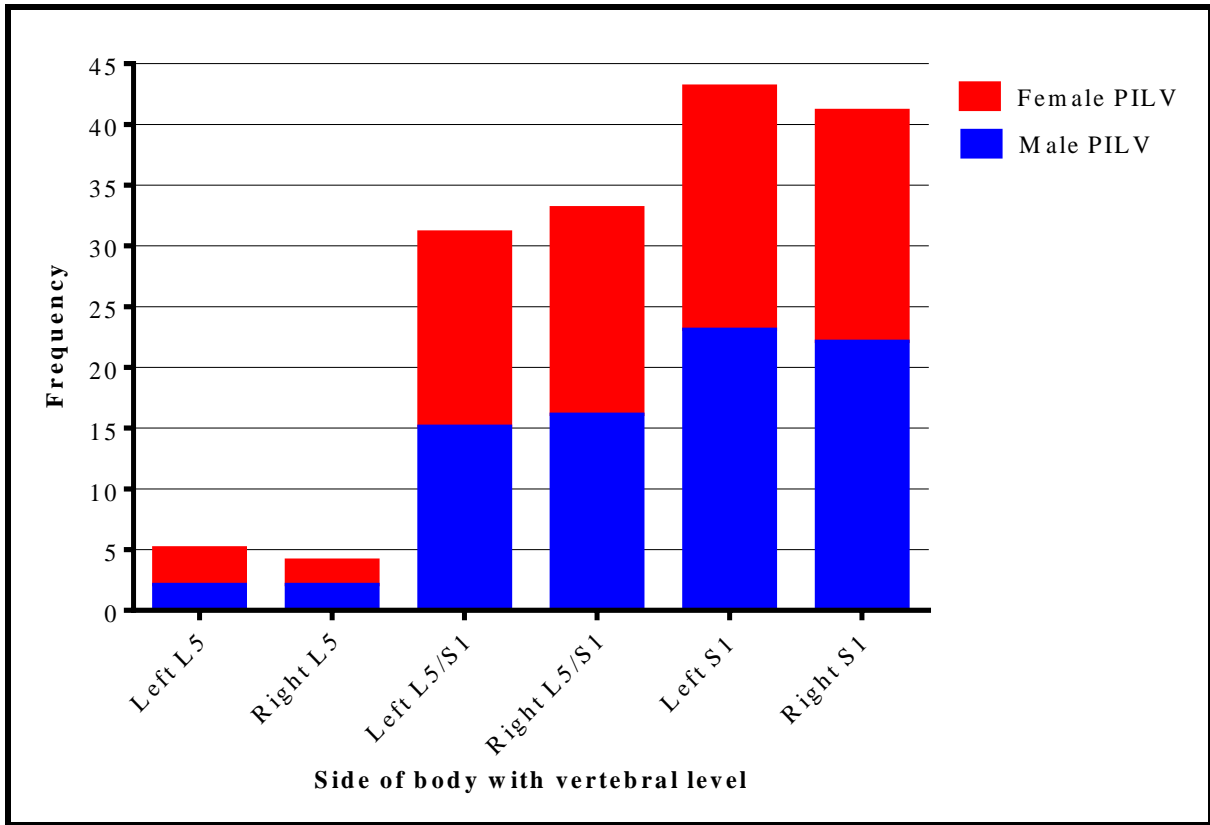


Figure 4.28: A bar graph showing the specific location of the Proximal iliolumbar veins (PILVs) on the lumbar and sacral vertebrae.

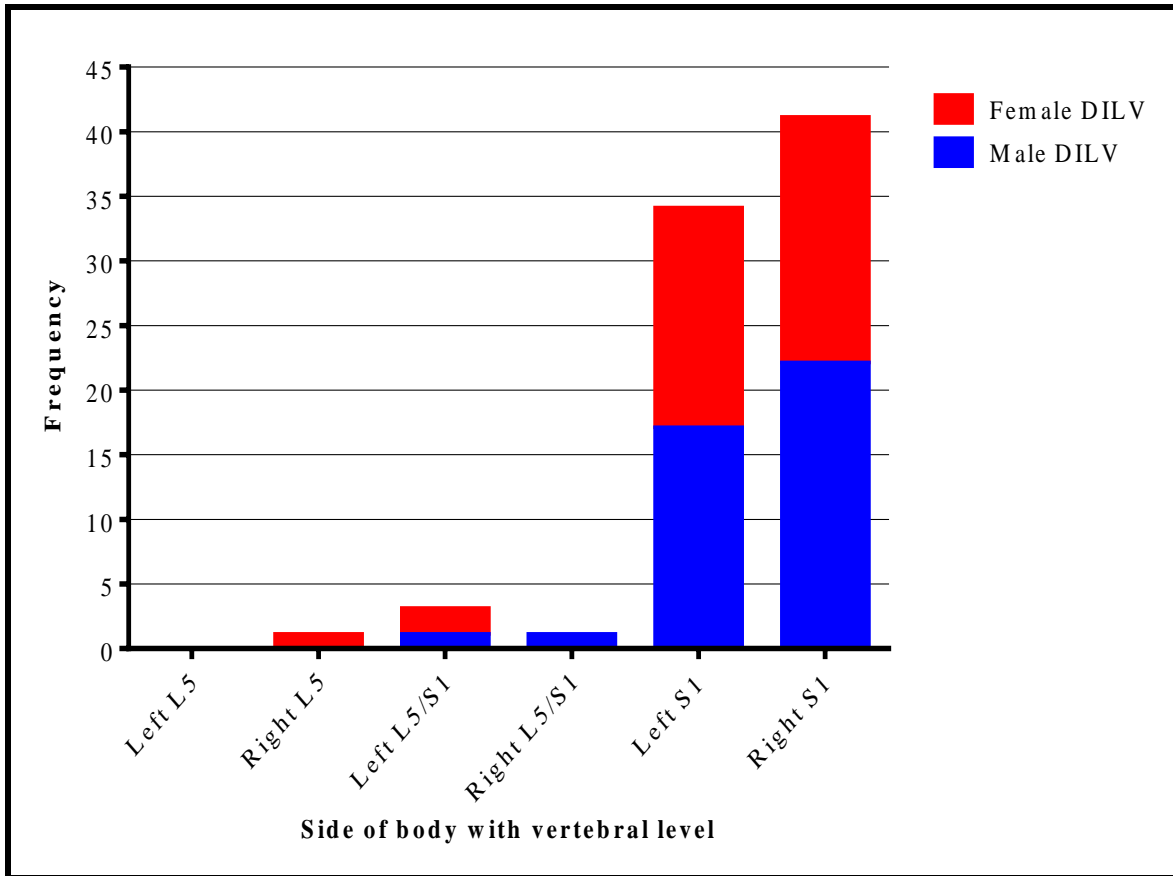


Figure 4.29: A bar graph showing the specific location of the Distal iliolumbar veins (DILVs) on the lumbar and sacral vertebrae.

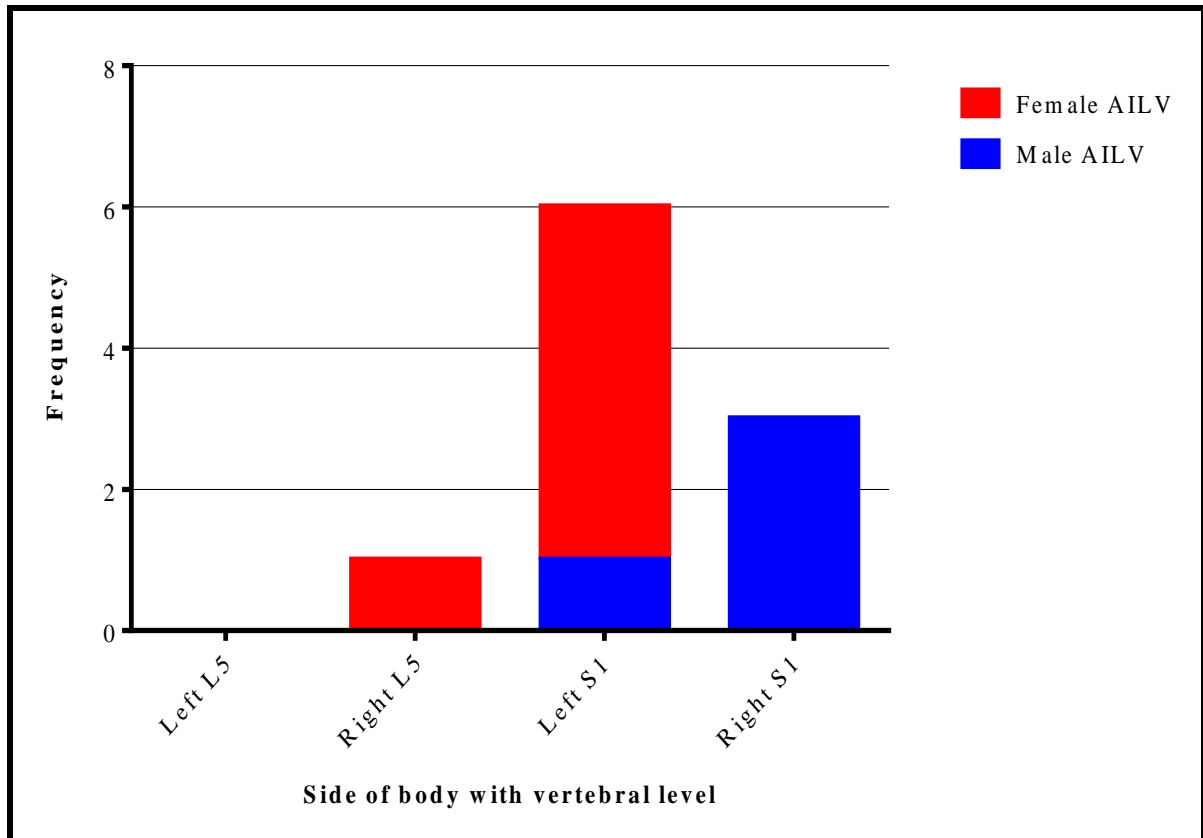


Figure 4.30: A bar graph showing the specific location of the Accessory iliolumbar veins (AILVs) on the lumbosacral vertebra.

4.5 Morphometry of ILVs

4.5.1 Distance from the origin of IVC to ostia of ILVs

The overall mean distance from the origin of IVC to ALVs was 42.16 ± 12.27 mm (left side 52.70 ± 15.04 , right side 31.62 ± 9.50) (Figure 4.31). The distance from the origin of IVC to ALV ranged from 19-87mm. About a third (28%) of the ALVs occurred at less than 30mm from the origin of IVC, most of which were in females ($p=.048$) and on the right side of the body. The overall mean distance from the origin of IVC to ALV-ILVs was 49.23 ± 11.50 mm (left side 60.42 ± 11.22 , right side 38.04 ± 11.78). The distance from the origin of IVC to ALV-ILVs ranged from 19-82mm. Thirty percent (30.5%) of ALV-ILVs on the right side occurred at less than 30mm from the origin of IVC with equal sex proportions. The overall mean distance from the origin of IVC to PILVs was 70.11 ± 10.36 mm (left side 81.08 ± 10.14 , right side 59.13 ± 10.58). The distance from the origin of IVC to PILVs ranged from 36-112mm. The overall mean distance from the origin of IVC to DILV was 80.19 ± 10.82 mm (Left side 89.06 ± 10.58 , right side 71.32 ± 11.07). The distance from the origin of IVC to DILV ranged from 50-116mm. The overall mean distance from the origin of IVC to AILV was 85.18 ± 9.98 mm

(left side 97.38 ± 5.55 , right side 73.00 ± 14.42). The distance from the origin of IVC to AILV ranged from 61-104mm. The left side mean distances were significantly higher in all ILV trunks ($p=.003$ for ALVs, $p=.002$ for ALV-ILVs, $p=.001$ for PILVs, DILVs and AILVs) (Table 4.12). No statistically significant sex differences for mean distances were observed for all ILV trunks.

Table 4.12: The mean distances from the origin of the inferior vena cava (IVC) to the ILVs between sex and laterality.

Side of body Distance from the origin of IVC to	Left (Mean and SD) in mm			Right (Mean and SD) in mm			P- Value
	Male	Female	P- value	Male	Female	P- Value	
ALV	50.79± 15.98	54.61± 14.37	.51	32.46± 5.92	30.55± 12.98	.63	.003
ALV-ILV	59.02± 11.75	61.88± 10.67	.35	37.83± 11.99	37.83± 11.77	.89	.002
PILV	82.14± 8.93	80.00± 11.26	.35	61.23± 10.25	56.92± 10.60	.07	.001
DILV	89.37± 10.40	88.75± 11.02	.86	70.90± 10.15	71.82± 12.41	.80	.001
AILV	89.00± 0.00	99.04± 4.18	.09	75.00± 19.80	69.00± 0.00	.85	.001

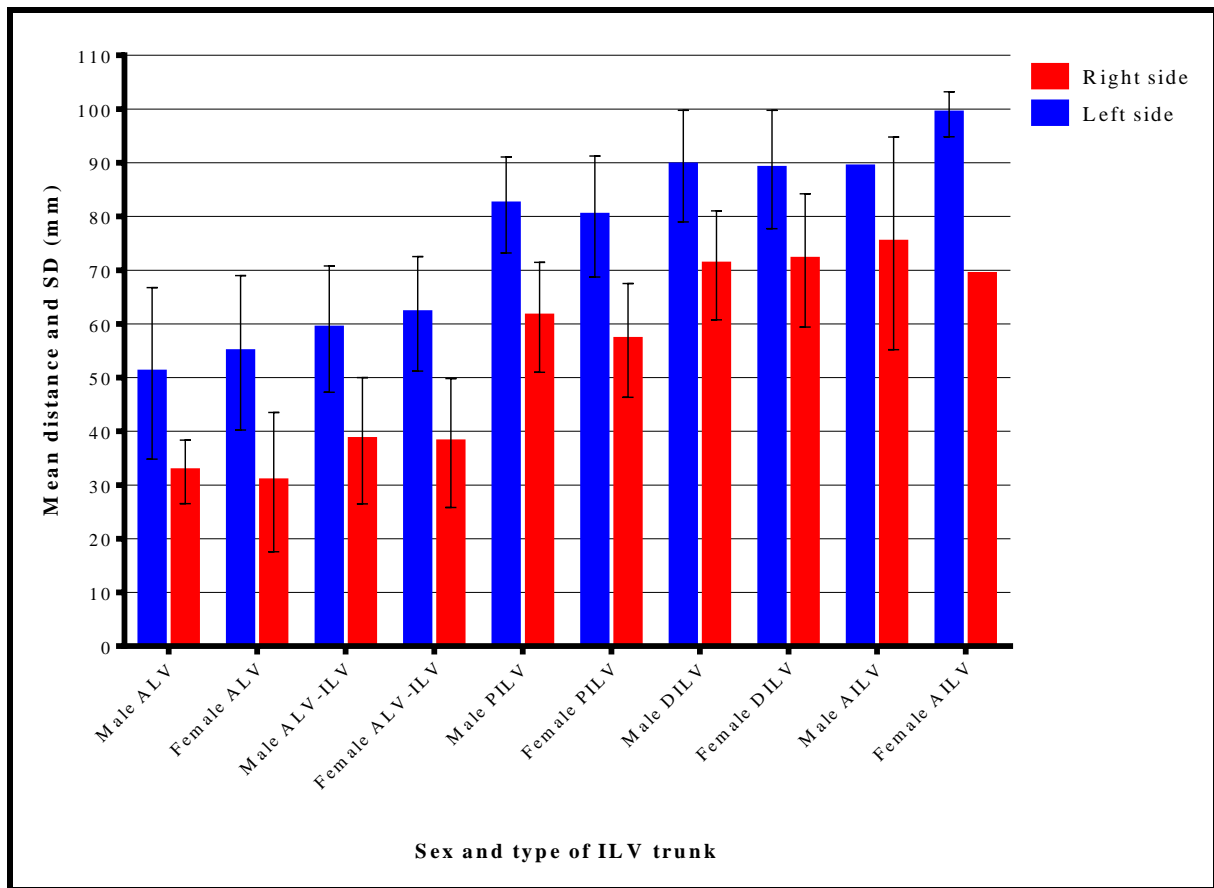


Figure 4.31: A bar graph showing the mean distances from the origin of inferior vena cava (IVC) to iliolumbar veins (ILVs) ostia between sides of the body and sex. Values with no standard deviation (SD) had no error bars.

4.5.2 Length of ILV trunks

The overall mean length of all ILV trunks was 14.09 ± 7.15 mm. The length of all ILV trunks ranged from 2.5-53mm. The overall mean length of ALV trunks was 18.72 ± 8.51 mm (left side 21.21 ± 11.68 , right side 16.23 ± 5.34). The ALV trunks length ranged from 5.9-53mm, and this range was higher in males on the left side of the body, as shown in (Table 4.13). The overall mean length of ALV-ILV trunks was 15.01 ± 5.75 mm (left side 15.46 ± 6.24 , right side 14.54 ± 5.26). The length of ALV-ILV trunks ranged from 6-35mm, and this range was higher in males on the left side of the body. The overall mean length of PILVs was 13.49 ± 6.94 mm (left side 13.16 ± 6.77 , right side 13.82 ± 7.11). PILV trunks had a range from 3-51mm, and this range was higher in males on the right side of the body. The overall mean length of DILVs was 10.85 ± 6.72 mm (left side 11.02 ± 7.4 , right side 10.68 ± 6.05). Length of DILVs ranged from 2.5-41mm, and this range was higher in females on the left side of the body. The overall mean length of AILV trunks was 12.38 ± 7.81 mm (left side 10.77 ± 10.16 , right side 14.00 ± 5.46).

The length of AILVs ranged from 4.8-31mm, and this range was higher in females on the left side of the body. The median for the left side was 9.8mm and 6.9mm for males and females, respectively. The median for the right side for males was 13.9mm. The mean length for ALV trunks was significantly higher than that of DILV trunks ($p=.039$). There were no significant mean length differences between the laterality and sex for all ILV trunks (Table 4.14) (Figure 4.32).

Table 4.13: The range of ILV trunks length between sex and laterality.

Side	Left (Range in mm)		Right (Range in mm)	
	Male	Female	Male	Female
ILV Trunk				
ALV	8.2 – 53.0 (44.8*)	5.9 – 31.1 (25.2)	7.8 – 22.5 (14.7)	8.5 – 32.0 (23.5)
ALV-ILV	6.4 – 35.0 (28.6*)	6.3 – 23.6 (17.3)	7.0 – 27.3 (20.3)	6.0 – 25.5 (19.5)
PILV	3.7 – 32.0 (28.3)	3.0 – 26.0 (23.0)	4.3 – 51.0 (46.7*)	4.0 – 25.9 (21.9)
DILV	2.5 – 25.0 (22.5)	3.8 – 41.0 (37.2*)	4.5 – 31.5 (27.0)	3.3 – 26.0 (22.7)
AILV	9.8 – 9.8 (0)	4.8 – 31.0 (26.2*)	8.4 – 19.3 (10.9)	-

* for the higher range.

Table 4.14: The mean length of ILV trunks between sex and laterality.

Side of body	Left (Mean and SD) in mm			Right (Mean and SD) in mm			P-Value
	Male	Female	P-value	Male	Female	P-Value	
Length of ILV trunk							
ALV	24.61± 13.91	17.55± 7.63	.12	16.80± 4.32	15.56± 6.50	.58	.25
ALV-ILV	16.87± 7.19	13.84± 4.53	.08	14.58± 5.43	14.51± 5.19	.97	.79
PILV	14.31± 7.34	11.98± 5.99	.13	14.92± 8.03	12.66± 5.88	.16	.79
DILV	9.62± 5.45	12.15± 8.64	.30	10.55± 6.13	10.83± 6.12	.88	.76
AILV	9.81± 0.00	11.72± 11.05	–	13.85± 0.00	–	–	–

–AILV trunks length were not normally distributed (Shapiro Wilk Test=.018).

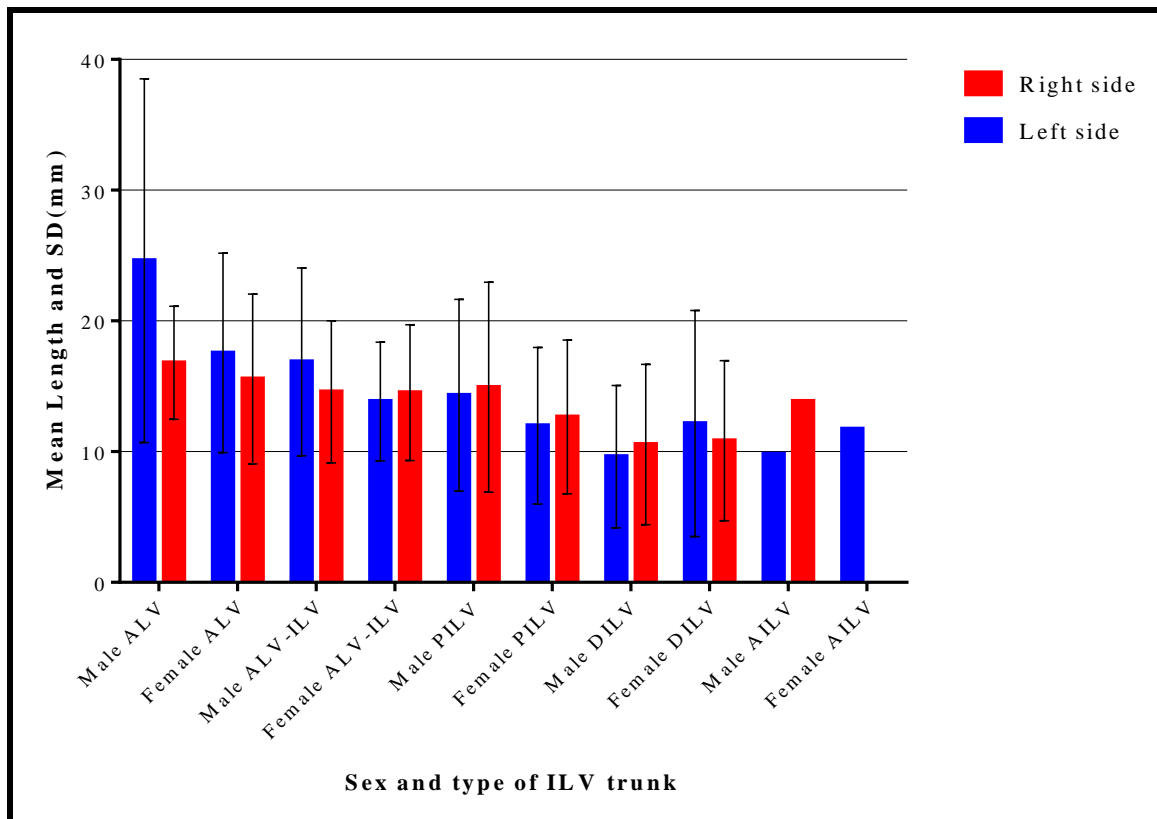


Figure 4.32: A bar graph showing the mean length of ILV trunks between sides of the body and sex. Values with no standard deviation (SD) had no error bars (AILV trunks).

4.5.3 Distance from obturator nerve (ON) to ILVs ostia

The overall mean distance from ON to the ostium of the ALV trunk was 22.13 ± 10.95 mm (left side 24.39 ± 14.41 , right side 19.88 ± 7.49). The left side mean was higher ($p=.049$). There were no significant mean differences between the sex (left side $p=.21$, right side $p=.27$). The distance from ON to the ostium of the ALV trunk ranged from 0-62.7mm, and the range was higher in males on the left side. The ON intersected with very few (3%) ALVs on the right side and in females only. The overall mean distance from the ON to the ostium of the ALV-ILV trunk was 13.42 ± 6.45 mm (left side 13.22 ± 6.76 , right side 13.59 ± 6.15). The differences between the mean of the sides of the body ($p=.84$) and sex (left side $p=.12$, right side $p=.71$) were not statistically significant. The distance from the ON to the ostium of the ALV-ILV trunk ranged from 0-35mm, and the range was higher in males on the left side. Few (11%) ALV-ILV trunks intersected with ON, and almost half (45%) of the intersections were at the ostium of ALV-ILVs. The distance from ON to the ostium of the PILV trunk ranged from 0-18.4mm, with the left side having a higher range in males. No significant median differences were observed between the sides of the body and sex (Table 4.15). The majority (58%) of the PILV trunks intersected with ON, in which 58% of the intersections were at the ostium of PILVs

(Figure 4.33). The distance from ON to the ostium of the DILV trunk ranged from 0-21.9mm, and the range was higher in males on the left side. The right-side median was higher in females. The majority (58%) of the DILV trunks intersected with ON, in which 80% of the intersections were at the ostium of DILVs. The distance from ON to the ostium of the AILV trunk ranged from 0-8.9mm, with males on the right side having a higher range. Over three-quarters (78%) of the AILV trunks intersected with ON, in which 86% of these intersections were at the ostium of AILVs.

Table 4.15: The median and interquartile (IQ) range of distance from ON to ILV trunks between the sex and laterality.

Side	Left (Median and IQ range in mm)		Right (Median and IQ range in mm)	
	Male	Female	Male	Female
ILV Trunk				
ON to ALV	24.2* (IQ, 24.8)	18.9 (IQ, 18.9)	20.55 (IQ, 9.7)	20.6 (IQ, 13.8)
ON to ALV-ILV	13.6 (IQ, 7.8)	11.8 (IQ, 7.4)	13.7 (IQ, 9.8)	14.9* (IQ, 6.8)
ON to PILV	5.5 (IQ, 10.1)	6.2* (IQ, 5.0)	5.7 (IQ, 8.2)	5.8 (IQ, 9.9)
ON to DILV	2.2 (IQ, 8.6)	3.0 (IQ, 7.3)	0.0 (IQ, 6.0)	4,2* (IQ, 9.1)
ON to AILV	–	–	–	–

* for the higher median. – AILVs had no median and IQ range.

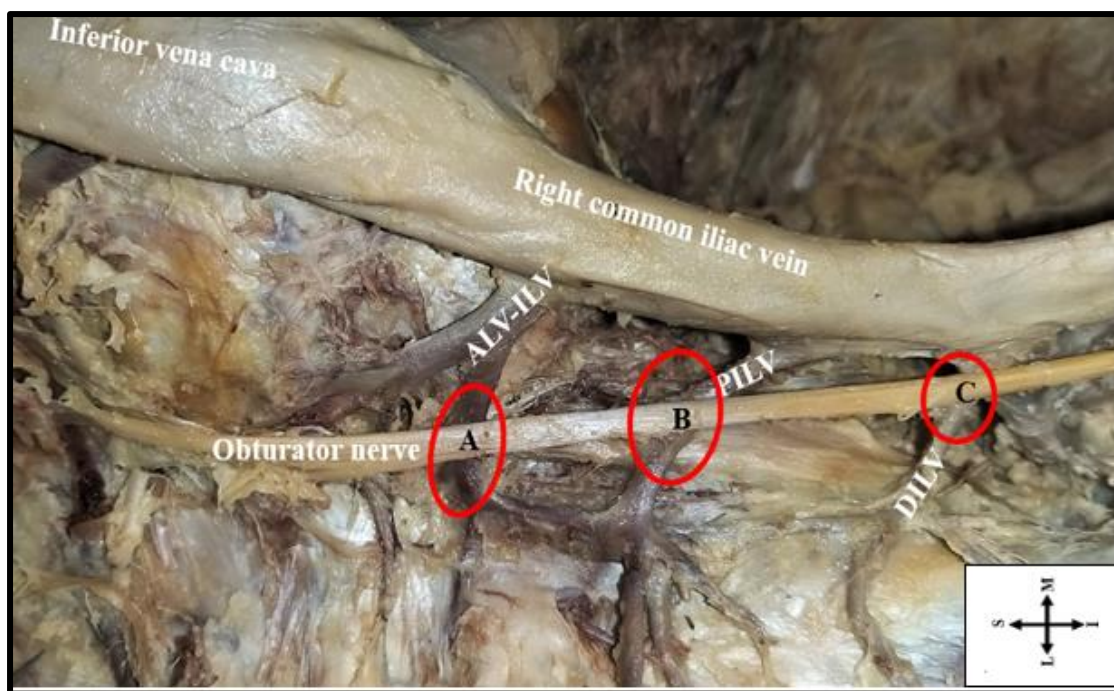


Figure 4.33: A photograph showing the intersections (red circle) of the obturator nerve in relation to ILV trunks. (A) There is no intersection with the ALV-ILV trunk; (B) Intersection at the midpoint of the PILV trunk, (C) Intersection at the ostium of DILV. PILV= Proximal iliolumbar vein, ALV-ILV= Ascending lumbar vein and iliolumbar vein common trunk, DILV= Distal iliolumbar vein, S= Superior, I= Inferior, M= Medial, L= Lateral.

4.5.4 Iliolumbar veins and the lumbosacral trunk (LST)

4.5.4.1 Distance from L4 spinal nerve root of LST (L4/LST) to ILVs ostia

The overall mean distance from L4/LST to the ostium of the ALV trunk was $21.72 \pm 8.8\text{mm}$ (left side 21.89 ± 11.14 , right side 21.55 ± 6.49). The L4/LST to the ostium of the ALV distance ranged from 6.4-43.7mm, and this range was higher on the left side in females (Table 4.16). Very few (6%) of the ALV trunks intersected with L4/LST. The L4/LST to the ostium of the ALV-ILV distance ranged from 7.3-36.8mm, and this range was higher on the left side in males. The overall mean distance from L4/LST to the ostium of the ALV-ILV trunks was $15.90 \pm 5.57\text{mm}$ (left side 16.03 ± 6.59 , right side 15.78 ± 4.55). The L4/LST to the ostium of the ALV-ILV trunks mean distance was significantly higher in males on the left side ($p=.03$). Intersections were observed in 20% of the ALV-ILVs. The overall mean distance from L4/LST to the ostium of the PILV trunks was $10.50 \pm 4.07\text{mm}$ (left side 10.82 ± 3.7 , right side 10.17 ± 4.44). There was no significant sex (left side $p=.370$, right side $p=.521$) and laterality ($p=.758$) mean differences (Table 4.17). The distance from L4/LST to the ostium of the PILV ranged from 0-18.7mm, and this range was higher on the right side in males. Intersections between

L4/LST and PILV trunks occurred in the majority (72%) of the PILV trunks, with only 5% of these at the ostium of the PILVs. The L4/LST to the ostium of the DILV distance ranged from 0-11.6mm, which was higher on the left side in females. The overall mean distance was $6.88 \pm 7.4\text{mm}$ (left side 4.26 ± 2.84 , right side 9.5 ± 2.59), and this was significantly higher in females on the left side ($p=.043$). Intersections of L4/LST and DILV trunks existed in half of the DILV trunks, with 20% of them at the ostium of the DILV trunks. The only observed AILV trunk, which was on the right side in females, occurred at 9.2mm away from the L4/LST.

Table 4.16: The range of distance from L4/LST to ILV trunks between the sex and laterality.

Side	Left (Range in mm)		Right (Range in mm)	
	Male	Female	Male	Female
L4/LST to ALV	11.5 – 43.7 (32.2)	6.4 – 43.7 (37.3*)	13.9 – 34.5 (20.6)	11.4 – 30.0 (18.6)
L4/LST to ALV-ILV	7.5 – 36.8 (29.3*)	8.3 – 22.6 (14.3)	8.6 – 29.4 (20.8)	7.3 – 25.6 (18.3)
L4/LST to PILV	0 – 18.4 (18.4)	5.5 – 16.7 (11.2)	0 – 18.7 (18.7*)	0 – 17.7 (17.7)
L4/LST to DILV	0	0 – 7.9 (7.9*)	11.6 – 11.6 (0)	6.6 – 10.3 (3.7)

* for the higher range.

Table 4.17: The mean distances and standard deviations (SD) from L4/LST to ILVs ostia between sex and laterality.

Side of body	Left (Mean and SD) in mm			Right (Mean and SD) in mm			P-Value
	Male	Female	P-value	Male	Female	P-Value	
L4/LST to ALV	23.79± 10.71	19.57± 11.85	.41	21.67± 6.17	21.4± 7.38	.83	.83
L4/LST to ALV-ILV	18.12± 8.17	13.94± 3.6	.03	16.12± 4.65	15.41± 4.53	.59	.80
L4/LST to PILV	11.37± 4.2	10.27± 3.15	.37	9.67± 4.73	10.62± 4.24	.52	.76
L4/LST to DILV	0.00± 0.00	4.26± 2.84	.043	11.6± 0.00	8.45± 2.62	.21	.10

4.5.4.2 Distance from L5 spinal nerve root of LST (L5/LST) to ILVs ostia

The overall mean distance from L5/LST to the ostium of the ALV trunk was 23.68 ± 12.32 mm (left side 23.57 ± 15.35 , right side 23.79 ± 9.29) with no significant sex and laterality differences. The L5/LST to the ostium of the ALV distance ranged from 7.4-59.6mm, and this range was higher on the left side (Table 4.18). Only 4% of the ALVs intersected with L5/LST. The overall mean distance from L5/LST to the ostium of the ALV-ILV trunk was 16.85 ± 6.60 mm (left side 16.21 ± 6.62 , right side 17.49 ± 6.57). The mean distance was higher in males on the left side ($p=.008$) (Table 4.19). The L5/LST to the ostium of the ALV-ILV distance ranged from 5.6-38.1mm, and this range was higher on the left side in males. L5/LST to ALV-ILV trunk intersections was observed in 18% of the ALV-ILV trunks. The distance from L5/LST to the ostium of the PILV ranged from 0-21.8mm, and this range was higher on the right side in females. The overall mean distance from L5/LST to the ostium of the PILV trunk was 10.75 ± 4.24 mm (left side 10.57 ± 4.26 , right side 10.84 ± 4.21). There was no significant sex and laterality mean distance differences. Intersections existed in the majority (72%) of the PILVs, with only 4% of these at the ostium of PILV trunks. L5/LST to the ostium of the DILV distance ranged from 2.1-12.3mm, and this range was higher on the left side in females. The overall mean distance from L5/LST to the ostium of the DILV trunk was 8.38 ± 2.4 mm (left side 5.83 ± 3.39 , right side 10.93 ± 1.4). The only observed AILV was on the left side in females and occurred at 11.5mm away from the L5/LST.

Table 4.18: The range of distance from L5/LST to ILVs ostia between the sex and laterality.

Side	Left (Range in mm)		Right (Range in mm)	
	Male	Female	Male	Female
ILV Trunk				
L5/LST to ALV	7.3 – 38.9 (31.6)	8.2 – 59.6 (51.4*)	13.4 – 23.8 (10.4)	16.8 – 42.8 (26)
L5/LST to ALV-ILV	8.7 – 38.1 (29.4*)	7.6 – 24 (16.4)	5.6 – 31.1 (25.5)	8.6 – 31.5 (22.9)
L5/LST to PILV	0 – 15.2 (15.2)	5.5 – 21.8 (16.3)	3.8 – 18.7 (14.9)	0 – 17.7 (17.7*)
L5/LST to DILV	-	2.1 – 9.6 (7.5*)	-	9.5 – 12.3 (2.8)

* for higher range.

Table 4.19: The mean distances and standard deviations (SD) from L5/LST to ILVs ostia between sex and laterality.

Side of body	Left (Mean and SD) in mm			Right (Mean and SD) in mm			P-Value
	Male	Female	P-value	Male	Female	P-Value	
L5/LST to ALV	25.79± 11.42	21.63± 18.72	.62	19.8± 4.11	28.78± 12.17	.16	.84
L5/LST to ALV-ILV	18.84± 7.47	13.58± 4.43	.008	18.03± 7.68	17.01± 5.61	.67	.22
L5/LST to PILV	10.14± 4.15	10.97± 4.43	.56	10.78± 4.28	10.89± 4.26	.94	.76
L5/LST to DILV	–	5.83± 3.39	–	11± 0.00	10.9±1.98	.76	.06

4.5.4.3 Distance from LST to ILVs ostia

The overall mean distance from LST to the ostium of the ALV trunk was 27.99 ± 13.58 mm (left side 34.26 ± 16.23 , right side 21.72 ± 10.93). The mean distance was significantly higher in males on the left side ($p=.035$). The LST to the ostium of the ALV distance ranged from 0-61.9mm, and this range was higher on the left side in males (Table 4.20). Intersections were observed in 11% of the ALVs and were all at the ostium of the ALV trunk. The LST to the ostium of the ALV-ILV distance ranged from 0-27.6mm, and this range was higher on the right side in males. The overall mean distance from LST to the ostium of the ALV-ILV trunk was 11.68 ± 6.45 mm (left side 7.99 ± 5.65 , right side 15.37 ± 7.24). The right-side mean distance was significantly higher ($p=.039$) (Table 4.21). Intersections were observed in 9% of the ALV-ILVs and were all at their ostium. The LST to the ostium of the PILV distance ranged from 0-21.8mm, and this range was higher on the right side in females. The overall mean distance from the LST to the ostium of the PILV trunk was 6.92 ± 6.1 mm (left side 6.72 ± 5.9 , right side 7.12 ± 6.3). Intersections existed in 48% of the PILVs, with 68% of these at their ostium. LST to the ostium of the DILV distance ranged from 0-21.5mm, and this range was higher on the right side in males. The overall mean distance from the LST to the ostium of the DILV trunk was 7.55 ± 5.32 mm (left side 8.07 ± 5.35 , right side 7.02 ± 5.29). Intersections existed in 29% of the DILVs, with 81% of them at their ostium. There was no significant sex and laterality mean distance differences for PILVs and DILVs. The LST to the ostium of the AILV distance ranged from 0-21mm, and this range was higher on the right side in males. The overall mean distance

from the LST to the ostium of the AILV trunk was $9.94 \pm 7.53\text{mm}$ (left side 12.88 ± 5.16 , right side 7.00 ± 0.00), with the left side mean distance higher ($p=.058$). Intersections existed in 50% of the AILVs, with all of them at the ostium of AILVs.

Table 4.20: The range of distance from LST to ILV trunks between the sex and laterality.

Side	Left (Range in mm)		Right (Range in mm)	
	Male	Female	Male	Female
LST to ALV	33.4 – 61.9 (28.5*)	16.6 – 35 (18.4)	16.6 – 36.8 (20.2)	0 – 26 (26)
LST to ALV-ILV	0 – 16.3 (16.3)	0 – 9.5 (9.5)	5.1 – 27.6 (22.5*)	4.7 – 17.7 (13)
LST to PILV	0 – 20 (20)	0 – 13.8 (13.8)	0 – 17 (17)	0 – 21.8 (21.8*)
LST to DILV	0 – 19.4 (19.4)	0 – 16.1 (16.1)	0 – 21.5 (21.5*)	0 – 12.6 (12.6)
LST to AILV	12.1 – 12.1 (0)	7.6 – 21 (13.4)	0 – 14 (14*)	–

* for the higher range.

Table 4.21: The mean distances and standard deviations (SD) from LST to ILVs ostia between sex and laterality.

Side of body	Left (Mean and SD) in mm			Right (Mean and SD) in mm			P-Value
	Male	Female	P-value	Male	Female	P-Value	
LST to ALV	47.93± 14.25	24.0± 7.99	.035	26.06± 8.73	16.3± 12.11	.20	.08
LST to ALV-ILV	9.4± 6.67	6.23± 4.29	.44	18.43± 7.92	11.8± 4.72	.10	.039
LST to PILV	7.83± 6.84	5.56± 4.61	.24	6.25± 5.96	8.17± 6.70	.34	.70
LST to DILV	8.57± 5.73	7.43± 4.98	.56	7.58± 5.64	6.33± 4.90	.47	.79
LST to AILV	12.1± 0.00	13.08± 5.94	.78	7.00± 0.00	–	–	.058

4.6 Histology of ILVs

4.6.1 ILV wall tissue composition

The H & E stains showed the presence of all three tunicae (Figure 4.34). The tunica intima was very thin, consisting of endothelial and subendothelial connective tissue. The tunica media had both circularly and longitudinally arranged smooth muscle with collagen fibres in between. The tunica adventitia had longitudinally arranged smooth muscles, collagen fibres, vasa vasorum, nerve vasorum and adipocytes. No differences in terms of composition were observed.

The Masson's trichrome stained sections showed collagen fibres (green color) in the tunica media and adventitia, both within and between the smooth muscles (Figure 4.35 and Figure 4.36). The Verhoeff's stained sections revealed elastic fibres (black color) between the tunica intima and media, forming a discontinuous internal elastic lamina. Some elastic fibres were scattered between the smooth muscles of tunica media and adventitia (Figure 4.37).

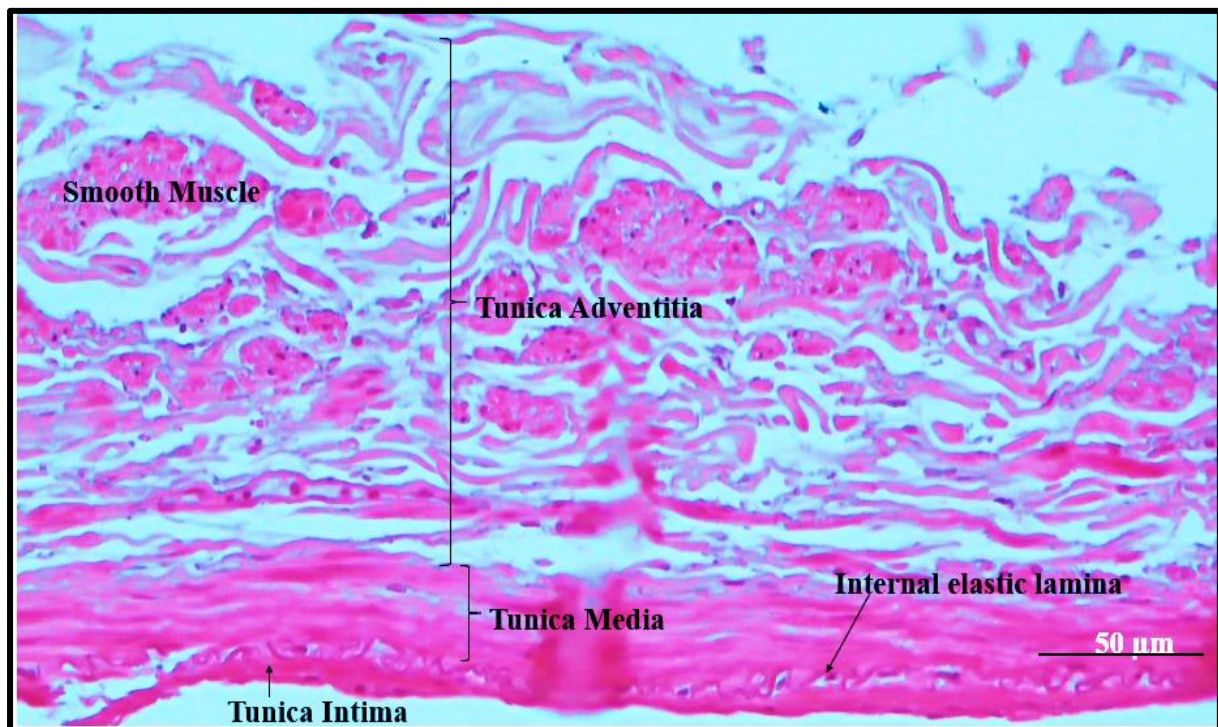


Figure 4.34: A photomicrograph of an H & E stained section showing the presence of all tunicae in the iliolumbar vein walls.

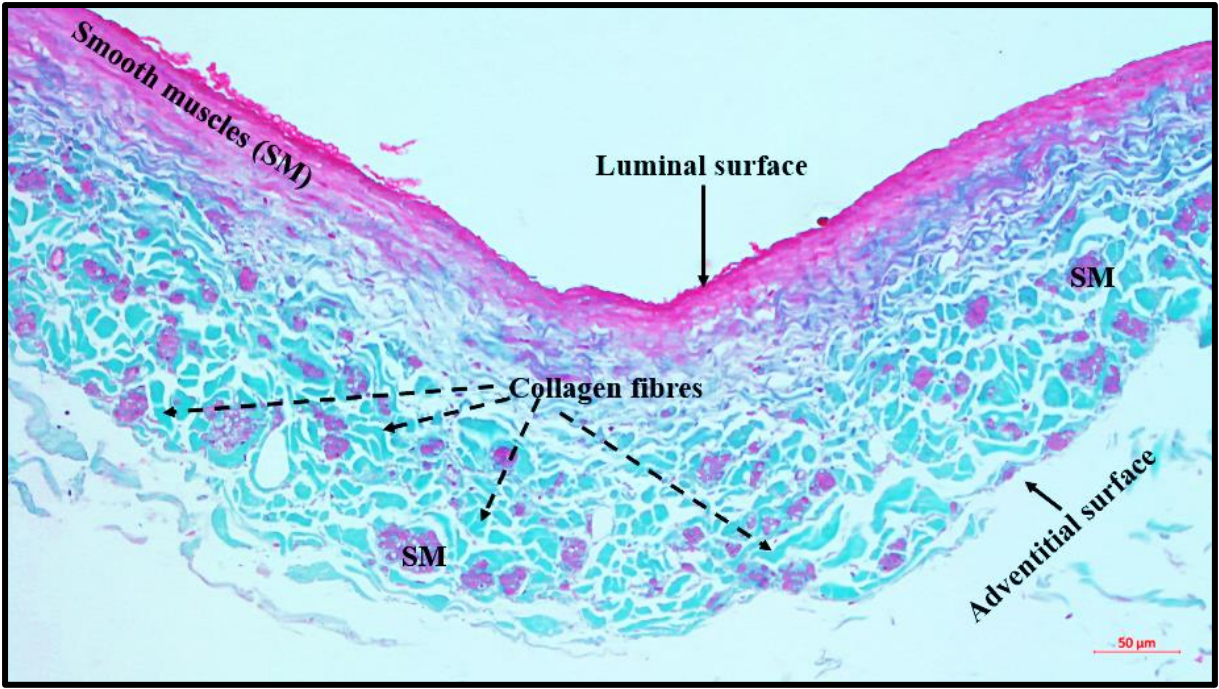


Figure 4.35: A photomicrograph of a Masson's trichrome stained section, showing the presence of collagen fibres in the iliolumbar vein layers (green color).

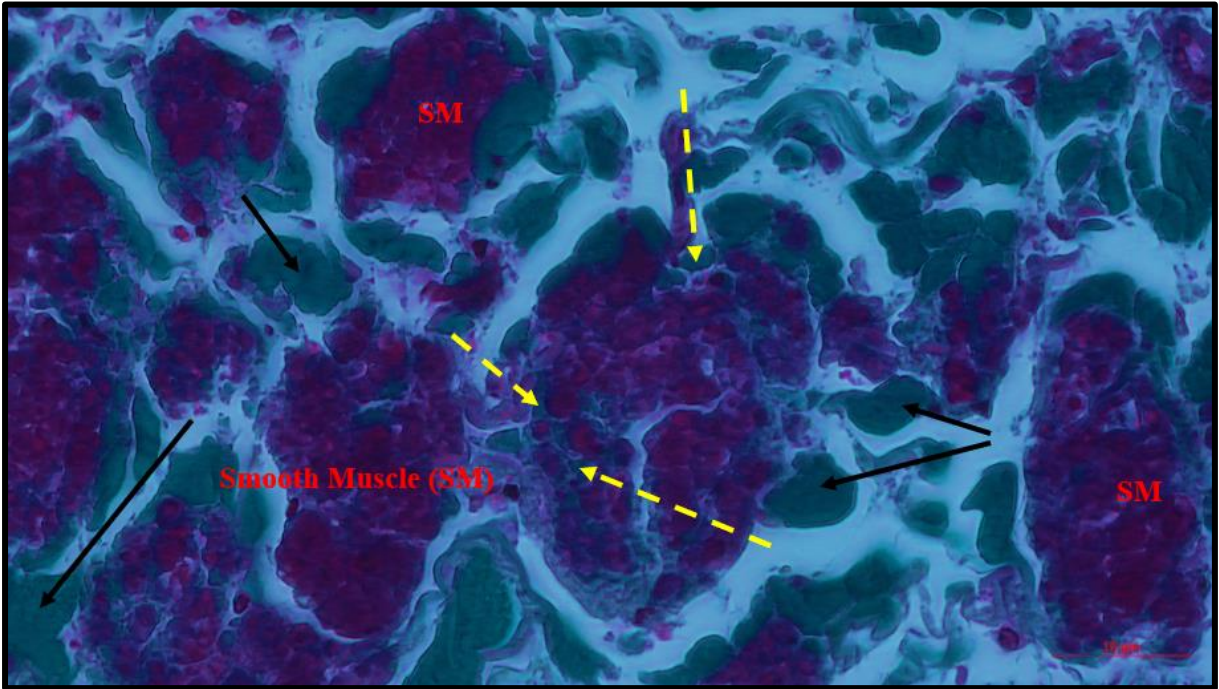


Figure 4.36: A photomicrograph showing a smooth muscle synthesizing and secreting collagen fibres in the iliolumbar veins. Yellow dashed lines show collagen within smooth muscles. Black arrows show collagen surrounding smooth muscles.

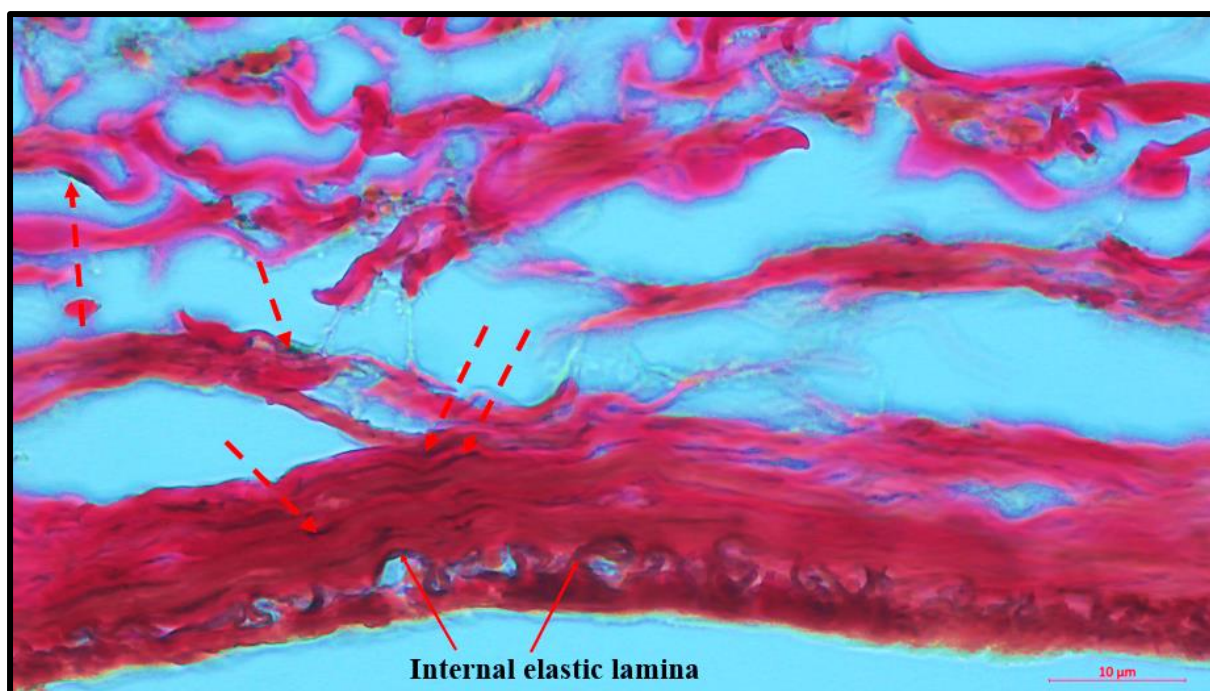


Figure 4.37: A photomicrograph of Verhoeff's stained section showing the presence of elastic fibres (black color) in the iliolumbar vein layers. Red dashed arrows showing scattered elastic fibres.

4.6.2 Vessel wall thickness (in mm)

The overall mean wall thickness of the PILVs was 0.219 ± 0.056 mm, with the left side mean marginally higher ($p=.051$) (Figure 4.38). The overall mean wall thickness of the DILVs was 0.226 ± 0.062 mm with no significant laterality differences ($p=.50$). The tunica adventitia's mean thickness was 0.169 ± 0.055 mm for PILVs and 0.171 ± 0.056 mm for DILVs. There were no significant mean differences between the sides of the body (PILV $p=.14$, DILV $p=.36$). The tunica media and intima's mean thickness was 0.044 ± 0.011 mm for PILVs, and 0.055 ± 0.017 mm for DILVs with no significant laterality differences (PILV $p=.11$, DILV $p=.71$). The tunica media to tunica adventitia ratio was 1: 3.48. No significant sex differences were observed in all the wall thickness layers.

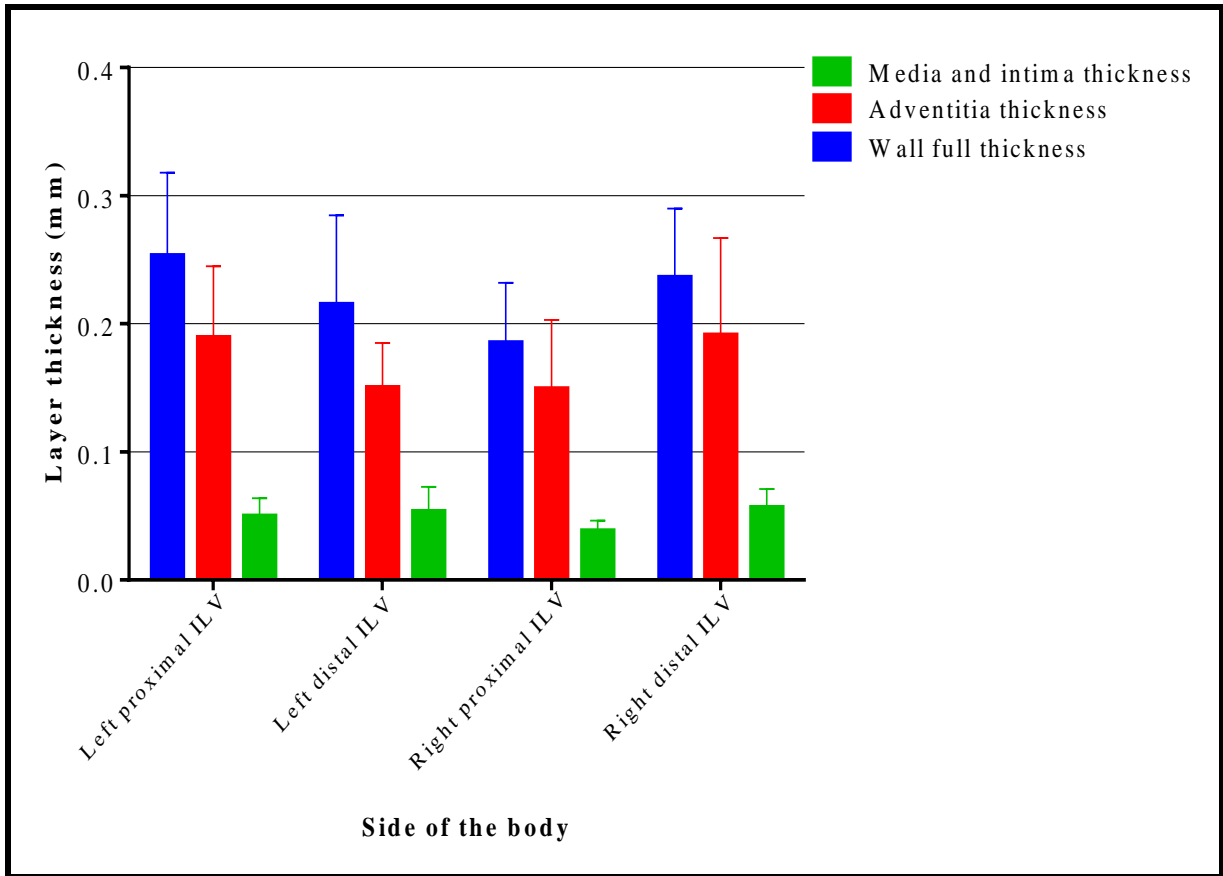


Figure 4.38: A bar graph showing the mean wall thickness measurements for iliolumbar veins (ILV).

4.6.3 Elastic fibre percentage area

The overall mean for elastic fibre percentage area was $1.381 \pm 0.503\%$ (PILVs $1.327 \pm 0.473\%$, DILVs $1.434 \pm 0.532\%$), and the mean differences for PILV and DILVs were not statistically different ($p=.84$). The left side PILVs had a significantly higher mean than the right side PILVs ($p=.03$) (Figure 4.39). No significant laterality differences for distal ILVs was observed ($p=.25$). There were no significant mean differences for sex ($p=.84$).

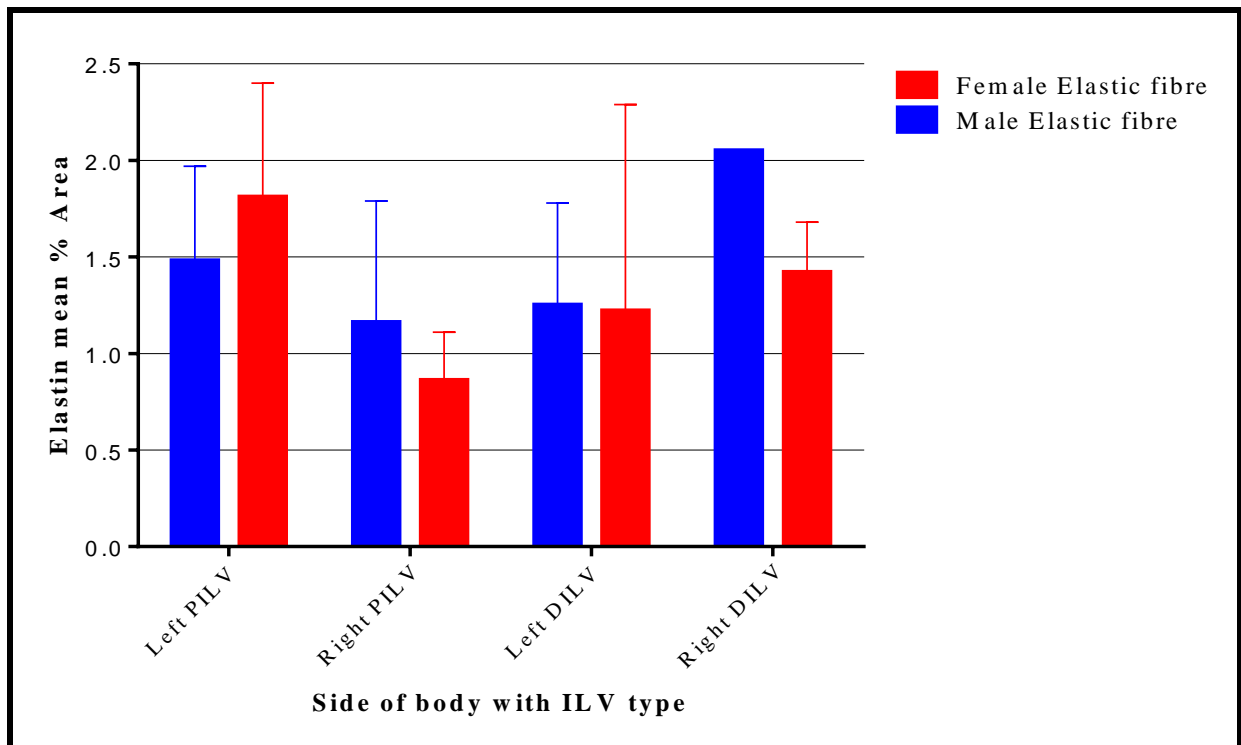


Figure 4.39: A bar graph showing the mean elastic fibre percentage area for the iliolumbar veins. PILV= Proximal iliolumbar vein, DILV= Distal iliolumbar vein.

4.6.4 Collagen fibre percentage area

The overall mean for collagen fibre percentage area was $12.478 \pm 4.262\%$ (PILVs $12.657 \pm 4.353\%$, DILVs $12.298 \pm 4.175\%$), and the mean differences for PILV and DILVs were not statistically significant ($p=.83$). No significant laterality differences for PILVs ($p=.12$) and DILVs ($p=.09$) were observed. There were no significant mean differences for sex ($p=.67$) (Figure 4.40).

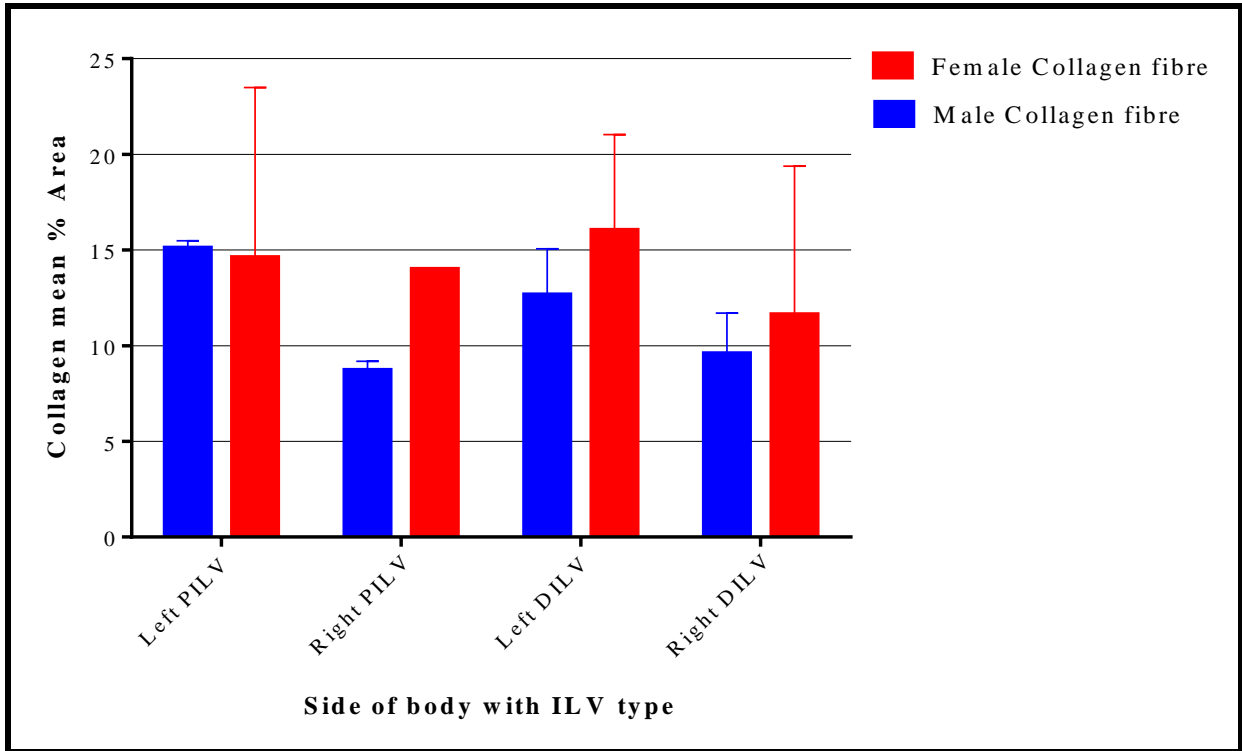


Figure 4.40: A bar graph showing mean collagen fibre percentage area for iliolumbar veins (ILV). PILV= Proximal iliolumbar vein, DILV= Distal iliolumbar vein.

4.6.5 Elastic to collagen percentage area ratio

The overall elastic to collagen fibre ratio was 1:9.1 (1.381:12.478). The differences between the elastin to collagen ratio for proximal and distal ILVs were not statistically significant (p=.81) (Figure 4.41).

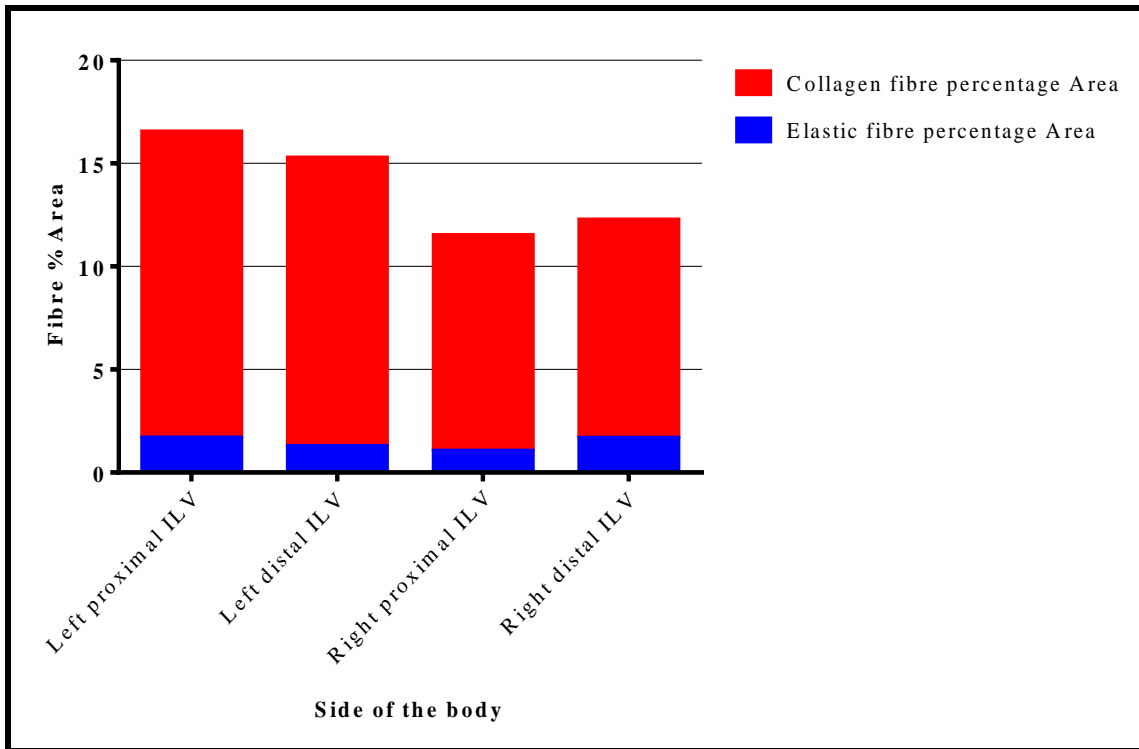


Figure 4.41: A bar graph showing elastin to collagen fibre percentage area for iliolumbar veins (ILVs).

CHAPTER 5: DISCUSSION

5.0 Introduction

The current study aimed to describe the macro and microanatomy of the ILVs with respect to sex and laterality in the White South African population group. This chapter discusses the results of the macro anatomy first, succeeded by the histology of the ILVs. To achieve more useful clinical application, both general and precise anatomical descriptions of the ILVs have been discussed.

5.1 Demographic data

The number of male and females in the current study group was nearly equal. This may be due to equal numbers of sex that are included in the University of the Witwatersrand School of Anatomical Sciences body donation program. The minor male-dominant proportions observed in the analysed cadavers are like what some authors recorded (Sheng *et al.*, 2008; Davis *et al.*, 2019). In the current study, males slightly dominated because the majority of the excluded cadavers were females. Some authors, however, had more females in their study groups (Hamid *et al.*, 2007; Sivakumar *et al.*, 2007). Notably, these proportions are a direct opposite of the sex distribution in the general South African population (Statistics South Africa, 2016). Nevertheless, the proportional differences did not show any statistical significance; hence sex associations with ILV variations may not be biased.

The mean age in the current study is similar to that reported by Davis *et al.* (2019). Although the mean in the current study is higher than what was reported in one radiological study (Hamid *et al.*, 2007), it still falls within the range of most patients that undergo lumbosacral spinal surgeries due to degenerative diseases (Hamid *et al.*, 2007; Davis *et al.*, 2019). Additionally, the minor mean age differences between sex exclude the potential tissue compositions differences that may be age-related (McMonagle and Stephenson, 2014; Sidawy and Perler, 2018).

As observed in the current study, males being significantly taller than females is common (Max *et al.*, 2013; Bailey, 2020). In addition, the average heights are representative of the general adult heights in the South African population, and the locations of ILVs will likely be the best representation (World Data, 2021).

5.2 Variations of ILVs

5.2.1 Prevalence of ILVs

The ILVs are well known for their variability in the lumbosacral region, and the variations may be population specific (Hamid *et al.*, 2007; Lolis *et al.*, 2011). Determining the presence and absence of ILVs in a particular population group may help in informing surgeons of the vessels that are most likely to be ligated during their preoperative planning. The current study investigated the variability of the ILVs with respect to the laterality and sex.

The results showed that ILV trunks were present in both sides of the body and the sexes examined. Their presence was observed in five different forms or combinations (ALV, ALV-ILV, PILV, DILV, and AILV) (Figures 4.1A-B and 4.2A-C). It should be noted that not all of these five different trunks existed on the same side and in the same individuals at the same time. Some authors described the existence of a combination of ALV, ILV, and ALV-ILV trunks (Jasani and Jaffray, 2002; Unruh *et al.*, 2008; DePietro *et al.*, 2020). Previously, Unruh *et al.* (2008) stated that ILV trunks might be as many as four per side. On the other hand, Nalbandian *et al.* (2013) observed more than three ILVs. However, no attempts were made to name all the possible four ILV trunks (Unruh *et al.*, 2008; Nalbandian *et al.*, 2013). In the current study, a maximum of four ILV trunks was observed. Four ILV trunks were present in small proportions (6.0%) in both males and females and on both left and right sides. Apart from the known PILV (Unruh *et al.*, 2008; Teli *et al.*, 2013), the description of the presence of a DILV or the third ILV was also previously made (Teli *et al.*, 2013). Since the nomenclature of the fourth ILV was not made elsewhere in similar studies (Hamid *et al.*, 2007; Unruh *et al.*, 2008; Kachlik *et al.*, 2010), it has been named in the current study as an accessory ILV (AILV) to denote its number and relationship to the already three named ILVs (i.e. ALV, ALV-ILV, PILV and DILV).

Regardless of the laterality and sex, a PILV will always be predominantly present, and surgeons should anticipate finding one when exposing the lumbosacral vertebral spine (Eck and Vaccaro, 2013; Kim *et al.*, 2013). Unlike the presence of other ILVs in which significant sex differences were not observed, the presence of the AILV trunk was significantly higher in females and on the left side of the body. This could be so to cater for the drainage of blood from the widely spread structures in the much larger female pelvic region (Standring, 2015; Moore *et al.*, 2018).

The presence of ILV trunks in both sides of the body and sex in the present study concurs with the findings from similar cadaveric studies that reported 100% presence of ILV trunks (Kiray

et al., 2004; Sivakumar *et al.*, 2007; Sheng *et al.*, 2008). However, these findings differ significantly from some previously reported findings indicating variable frequencies on the presence of ILVs (Table 5.1) (Hamid *et al.*, 2007; Lolis *et al.*, 2011; Barrey *et al.*, 2013; Nalbandian *et al.*, 2013; Davis *et al.*, 2019). The total absence of ILV trunks is questionable, particularly in studies based on patient surgical data files and radiological imaging (Barrey *et al.*, 2013; Nalbandian *et al.*, 2013). Failure to detect ILVs could probably be a result of the limited field of exposure during surgical procedures (Nalbandian *et al.*, 2013), misclassification of ILVs found due to different nomenclatures (Hamid *et al.*, 2007; Lolis *et al.*, 2011), or the methodology of study used as some vessels may not be detected during imaging studies (Datta *et al.*, 2007; Diesinger *et al.*, 2012; Barrey *et al.*, 2013). Despite cadaveric studies providing the much-required field of exposure of veins of interest, Davis *et al.* (2019) still reported missing ILVs in their cadaveric studies in the American population. However, it is not known what leads to the absence of ILVs, and it can be assumed to be an incidental variation that is likely population specific (Diesinger *et al.*, 2012; Barrey *et al.*, 2013; Davis *et al.*, 2019).

Table 5.1: Prevalence of Iliolumbar vein (ILV) trunks across populations.

Study (Author and Year)	Incidence of ILVs (%)	Sample size	Population group	Study Type
Jasani and Jaffray (2002)	100	8	British	Cadaveric
Kiray <i>et al.</i> (2004)	100	19	Turkish	Cadaveric
Hamid <i>et al.</i> (2007)	96.0	13	French	Cadaveric
Sivakumar <i>et al.</i> (2007)	100	23	British	Cadaveric
Sheng <i>et al.</i> (2008)	100	15	Chinese	Cadaveric
Lolis <i>et al.</i> (2011)	49.0	50	Caucasian	Cadaveric
Barrey <i>et al.</i> (2013)	84.2	146	French	3D CT angiography
Nalbandian <i>et al.</i> (2013)	98.7	159	American	Retrospective review patient files
Davis <i>et al.</i> (2019)	93.3	15	American	Cadaveric
Current study	100	89	White South African	Cadaveric

5.2.2 Number of ILV main trunks/stems

The variability in the number of ILV trunks present may be considered detrimental as some of the trunks may be missed during the ligation, especially if the patient has multiple venous trunks (Unruh *et al.*, 2008). Therefore, it is essential to determine the maximum number of ILV main trunks that surgeons may need to locate and ligate to avoid iatrogenic injuries (Jasani and Jaffray, 2002).

The results of the current study showed that the number of ILV trunks present ranged from one to four bilaterally and in both sexes. The prevalence of a single trunk in the present study is lower than those reported in previous studies (Jasani and Jaffray, 2002; Hamid *et al.*, 2007; Nalbandian *et al.*, 2013). Additionally, a single ILV trunk was present on both sides of the body, a finding which disputes previous observations that a single ILV trunk is found only on the right side of the body (Teli *et al.*, 2013). This finding further supports population specificity in the frequency of ILVs.

The proportions of two ILV trunks in the current study are higher than those previously reported (Jasani and Jaffray, 2002; Hamid *et al.*, 2007; Nalbandian *et al.*, 2013). Reports of single and double ILV trunks without proportional descriptions also exist in the literature (Teli *et al.*, 2013). Although not statistically significant, the results from the current study concur with previous findings that showed that a single trunk of ILV is more prevalent on the right side and double trunks on the left side (Hamid *et al.*, 2007; Teli *et al.*, 2013).

The proportions of three ILV trunks in the current study are also higher than those reported by Nalbandian *et al.* (2013). Albeit the lack of explicit declaration of the study population groups by other authors, the current study has shown that the proportions of the number of main trunks are significantly variable from those of undefined population groups (Table 5.2) (Jasani and Jaffray, 2002; Hamid *et al.*, 2007; Nalbandian *et al.*, 2013). The present study concurs that the maximum number of ILV trunks that surgeons should anticipate finding is four (Unruh *et al.*, 2008). Contradicting the findings that multiple ILVs were significantly more in males (Nalbandian *et al.*, 2013), the present study did not find significant sex differences, probably because of population differences. Interestingly, the maximum number of ILVs was significantly higher in females on the left side, which may be attributed to the wide spread of

structures in the female pelvic region that may require independent ILV trunks for venous drainage (Standring, 2015; Moore *et al.*, 2018).

Thus, the findings in the present study have shown that the variability of the number of ILV trunks is likely to be population specific. Regardless of the significant maximum number of ILVs being on the left side of the body and in females, no significant risk of injury exists between the sides of the body and the sex of the present study group, as most of the observed differences are marginal proportions.

Table 5.2: Proportions of the number of ILVs across populations.

Study (Author and Year)	No trunk	One trunk	Two trunks	Three trunks	Four trunks
Jasani and Jaffray (2002)	0.00%	68.75%	31.25%	0.00%	0.00%
Hamid <i>et al.</i> (2007)	0.00%	78.00%	22.00%	0.00%	0.00%
Nalbandian <i>et al.</i> (2013)	1.30%	73.00%	17%	6.90%	1.80%
Current study	0.00%	6.55%	45.83%	41.67%	5.95%

5.2.3 Terminal drainage of ILVs

5.2.3.1 General terminal drainage of ILVs

The detailed description of the terminal drainage of ILVs may allow surgeons to easily locate and monitor the ILVs during exposure of intervertebral disc spaces (Kiray *et al.*, 2004; Kim *et al.*, 2013). Additionally, this description may also help in determining and controlling the larger valveless iliac vessel likely to bleed profusely in cases of inadvertent rupture of ILVs (Kiray *et al.*, 2004; Kachlik *et al.*, 2010; Schwartz *et al.*, 2010; Kim *et al.*, 2013; Moore *et al.*, 2018).

Similar to previous studies, the current study showed that the ILVs might drain into the common iliac vein (CIV), external iliac vein (EIV) and internal iliac vein (IIV) with variable frequencies across the sex and laterality (Kiray *et al.*, 2004; Hamid *et al.*, 2007; Kunakornsawat *et al.*, 2012; Nayak, 2018; DePietro *et al.*, 2020). On the contrary, some authors reported CIV to be the only terminal drainage of ILVs (Table 5.3) (Arthornthurasook and Gaew-Im, 1987; Jasani and Jaffray, 2002; Sivakumar *et al.*, 2007; Sheng *et al.*, 2008; Nalbandian *et al.*, 2013).

The main terminal drainage in the present study was CIV, which corresponds with reports from other populations (Kiray *et al.*, 2004; Ikard, 2006; Hamid *et al.*, 2007; Kunakornsawat *et al.*, 2012; Barrey *et al.*, 2013; Davis *et al.*, 2019). Despite this similarity, frequencies in the present study are significantly lower than those reported by some authors (Kiray *et al.*, 2004; Hamid *et al.*, 2007; Sheng *et al.*, 2008; Kunakornsawat *et al.*, 2012; Nalbandian *et al.*, 2013; Davis *et al.*, 2019). On the other hand, the frequencies in the present study are significantly higher than those reported by Unruh *et al.* (2008). Although the CIV might be labelled as the main terminal drainage of ILVs, its frequencies vary across population groups, and clinicians should always consider this when dealing with patients from diverse population groups.

While the frequencies of drainage of ILVs into EIV and IIV are very variable, the drainage into EIV was reported to be significantly high on the left side of the body, while the drainage of ILVs into IIV is higher on the right side (Kiray *et al.*, 2004; Hamid *et al.*, 2007). Similarly, the current study showed drainage of ILVs into EIV to be higher on the left side of the body while the drainage of ILVs into IIV is higher on the right side. In addition, the current study found that in males, ILVs drain more frequently into EIV on the left side and into IIV on the right side. In females, ILVs drain more frequently into IIVs on the right side and no significant differences on the left side. A separate author found no significant sex differences in the Turkish population group, suggesting that this could be because of different study population groups (Kiray *et al.*, 2004).

One ILV was found to be draining into both IIV and EIV, and no previous studies reported this finding. Although rare case scenario, such a presentation may increase the risks of iatrogenic injuries, and inadvertent damage may lead to excessive haemorrhage due to its connection to two large valveless iliac vessels (Kiray *et al.*, 2004; Morita *et al.*, 2007; Kachlik *et al.*, 2010; Schwartz *et al.*, 2010; Kim *et al.*, 2013). Rarely, ILVs may also drain into the inferior vena cava (IVC). While no previous studies reported ILVs draining into IVC, an ALV branch in the current study was observed to drain into the IVC on the right side (Unruh *et al.*, 2008; Kunakornsawat *et al.*, 2012; Nalbandian *et al.*, 2013). This finding was probably because the origin of the IVC was at the level of the L5 vertebra, the position at which the majority of right ALVs were both located and draining.

Table 5.3: Terminal drainage of the iliolumbar veins (ILVs) across populations.

Study (Author and Year)	CIV	EIV	IIV	IIV & EIV	IVC
Arthornthurasook and Gaew-Im (1987)	100%	–	–	–	–
Jasani and Jaffray (2002)	100%	–	–	–	–
Kiray <i>et al.</i> (2004)	78.9%	5.3%	15.8%	–	–
Hamid <i>et al.</i> (2007)	77.0%	4%	19%	–	–
Sivakumar <i>et al.</i> (2007)	100%	–	–	–	–
Sheng <i>et al.</i> (2008)	100%	–	–	–	–
Kunakornsawat <i>et al.</i> (2012)	75.9%	21.6%	2.5%	–	–
Nalbandian <i>et al.</i> (2013)	100%	–	–	–	–
Davis <i>et al.</i> (2019)	92.9%	7.1%	–	–	–
Current study	56.6%	16.9%	26.00%	0.25%	0.25%

5.2.3.2 Specific terminal drainage of ILVs

While the terminal drainage of all ILVs has always been generalized by previous authors (Kiray *et al.*, 2004; Unruh *et al.*, 2008; Kunakornsawat *et al.*, 2012; Davis *et al.*, 2019), the variability in their drainage may still cause confusion clinically, especially when more than one ILV is present. The five different ILV trunks found in the current study indicates the need for specific descriptions. To aid in more accurate clinical identification and monitoring of ILVs and their terminal drainage, the present study further provides a precise description of the drainage of each ILV and how it varies between sex and sides of the body. The current study is the first study to offer a detailed description of the terminal drainage of each ILV; hence a direct comparison with other generalized reports is challenging.

The main terminal drainage of ALV was CIV, and this does not vary with sex or laterality (DePietro *et al.*, 2020). Rarely, an ALV may drain into EIV in males and into IIV or IVC in females (Venieratos *et al.*, 2012; Maloor *et al.*, 2017; DePietro *et al.*, 2020). This variation may probably be dependent on how low or high the ALV trunk is located with respect to the lumbosacral vertebra in a specific population group (Davis *et al.*, 2019).

The drainage of ALV-ILV is primarily into the CIV, regardless of the laterality or sex (DePietro *et al.*, 2020). At times, an ALV-ILV trunk may drain into IIV on the right side in both males and females or into the EIV (DePietro *et al.*, 2020). Contrary to some reports that drainage into EIV is higher on the left side (Kiray *et al.*, 2004; Hamid *et al.*, 2007), drainage of ALV-ILV

into the EIV was not statistically significant as it was observed only in one female on the left side of the body.

Of all the ILVs encountered, PILVs demonstrated a more significant variability of the terminal drainage, with drainage into the CIV being probably the most frequent. PILVs on the left side drained more frequently into EIV while those on the right side drained more frequently into IIVs. The variations in relation to the laterality correspond with what was described before for all ILVs in general (Kiray *et al.*, 2004; Hamid *et al.*, 2007). This similarity was probably because PILVs were the most prevalent ILV trunks in the current study. Clinically, this finding may likely help in locating PILVs, especially when using the terminal drainage to trace a PILV trunk for ligation. For example, surgeons using the left side retroperitoneal approach may easily identify PILVs by tracing all tributaries emptying into EIV (Eck and Vaccaro, 2013; Kim *et al.*, 2013; Rhee *et al.*, 2015).

DILVs, when present, drain most frequently in the IIV and less frequently into the CIV and EIV. Drainage of DILVs into IIV is more prevalent on the right side, while drainage into EIV is more prevalent on the left side in males only (Kiray *et al.*, 2004; Hamid *et al.*, 2007). Thus, when operating on male patients, surgeons may easily locate DILVs for ligation by tracing tributaries draining into EIV on the left side of the body and by tracing tributaries draining into IIV on the right side of the body (Kiray *et al.*, 2004; Hamid *et al.*, 2007; Nayak, 2018). The main terminal drainage for the AILVs was IIV. However, variability may be present in females in which EIV or a union of IIV and EIV may be the possible terminal drainage.

The findings in the present study have shown that the terminal drainage of ILVs is very variable in relation to different studies from various population groups, laterality and sex. Additionally, the present study has also provided a detailed description of terminal drainage of each ILV and indicated how surgeons might utilize this information to better manage and control ILVs during exposure of lumbosacral intervertebral disc space.

5.2.4 Tributaries of ILVs

Tributaries draining into ILV trunks vary in their numbers, with multiples being common (Jasani and Jaffray, 2002; Nalbandian *et al.*, 2013; Teli *et al.*, 2013). Multiple tributaries are regarded as deleterious clinically as failure to identify all tributaries for ligation could lead to inadvertent rupture during medial mobilization of iliac vessels and consequent haemorrhage (Jasani and Jaffray, 2002; Kim *et al.*, 2013; Teli *et al.*, 2013).

The current study has shown that the number of tributaries draining into ILV trunks ranges from one to a maximum of six. In addition, few trunks of ILVs had a single tributary. Other studies reported the proportions of the presence of a single tributary to be around 6% without indicating the specific trunk of the ILV the tributary drains into (Jasani and Jaffray, 2002; Teli *et al.*, 2013). The present study observed that ALV trunks received a single tributary more frequently than any ILV trunk. This could be so because the ALV primarily serves to connect the ILVs to the azygous system of veins creating an anastomosis between the venous systems (Lolis *et al.*, 2011; Eck and Vaccaro, 2013; Standring, 2015).

The presence of two tributaries was reported with variable proportions without indication of the specific ILV trunks they drained into (Jasani and Jaffray, 2002; Hamid *et al.*, 2007; Nalbandian *et al.*, 2013; Teli *et al.*, 2013). The current study agrees with the findings due to the presence of these tributaries in large proportions in all the ILV trunks. This is because most venous confluences are formed by two venous tributaries (Standring, 2015; Moore *et al.*, 2018). Additionally, the current study has shown that two tributaries are predominant in the more distally located ILV trunks (i.e., DILV and AILV).

The presence of three or more tributaries in the previous studies corresponds with the findings in the current study (Jasani and Jaffray, 2002). However, the proportions in the present study are significantly smaller than those reported in another study in the Indian population (Teli *et al.*, 2013). This significant difference may be attributed to normal variations across populations (Teli *et al.*, 2013; Davis *et al.*, 2019). The current study found the presence of three or more tributaries principally on PILVs. More PILV tributaries, coupled with the predominant presence of PILV trunks supports the propositions that this is likely the main ILV trunk draining the lumbosacral region. This information is essential to reduce the chances of accidental damage to the veins (Jasani and Jaffray, 2002; Teli *et al.*, 2013; Davis *et al.*, 2019).

The left side was reported to have more ILV tributaries than the right side (Teli *et al.*, 2013; Davis *et al.*, 2019). This was only true for the proportions of tributaries of AILV in the current study. On the other hand, the presence of five tributaries was significantly higher on the right side than on the left side, but the overall proportions of multiple tributaries were higher on the right side than the left side. This may be considered advantageous to surgeons who prefer the left side retroperitoneal approach when exposing the lumbosacral vertebra (Eck and Vaccaro, 2013; Kim *et al.*, 2013). Thus, the observed variability of the laterality discrepancies with other authors may be ascribed to population specificity.

Significant sex differences were observed on the maximum number of tributaries. The maximum number of tributaries in ALVs (four) and AILVs (two) were found in females, while the maximum number of tributaries in PILVs (six) and DILVs (four) were found in males. Apart from that, the current study did not find significant differences in terms of sex, concurring with previous authors (Teli *et al.*, 2013). The maximum number of tributaries in major ILV trunks in males may likely be because of centrally congested structures in the pelvis, requiring more tributaries than having individual main trunks for immediate drainage of blood (Standring, 2015; Moore *et al.*, 2018).

5.2.5 Drainage sites of the ILV tributaries

ILVs drain a considerably wide range of structures in the lumbosacral and pelvic region (Jasani and Jaffray, 2002; Sivakumar *et al.*, 2007; Nalbandian *et al.*, 2013; Teli *et al.*, 2013). Defining specific ILV draining sites may help determine structures likely to lose their primary venous drainage following inadvertent ILV rupture (Kiray *et al.*, 2004; Hamid *et al.*, 2007).

Although ALVs may drain iliac fossa, iliac muscle, psoas major, L5, L4/L5, L4, it never drains more than two of these structures at a time. It should also be noted that ALVs never drained L5/S1 region and below, even though some of them may be located at these vertebral levels. The drainage of L5 vertebra body by ALVs may imply ALVs to be an equivalent of 5th lumbar segmental veins, thus, supporting previous findings, although they generalized it to all ILVs (Jasani and Jaffray, 2002; Kiray *et al.*, 2004; Sivakumar *et al.*, 2007; Unruh *et al.*, 2008; Lolis *et al.*, 2011; Nalbandian *et al.*, 2013). Following an accidental rupture of ALVs during intervertebral disc space exposure, surgeons should anticipate acute compromise to the L5 vertebral body drainage area. Additionally, the drainage of the L4/L5 region, which is significant on the left side and in males, necessitates the identification and ligation of ALVs when left side retroperitoneal approach to the lumbosacral spine is indicated (Eck and Vaccaro, 2013; Kim *et al.*, 2013).

The current findings show that PILVs are the only ILVs that may drain all the structures, from the L4 vertebral body down to the S1 vertebral body, the surrounding iliac fossa, iliacus muscle, and psoas major muscle, either singly or in combination. This indicates that the PILVs are major veins draining the lumbosacral region. Similarly, Hamid *et al.* (2007) observed that the PILV is the primary vein of this region but referred to PILVs as inferior lumbar veins, and they did not describe the drainage of the L5 vertebral body and below. The closest findings to the current study used a different nomenclature and did not report drainage of vertebral regions

below the L5 vertebra body (Hamid *et al.*, 2007). Nevertheless, this difference may be because of the different population groups studied.

The current study shows that ALV-ILV drainage sites vary considerably from L4 vertebral body to L5 vertebral body and the neighboring musculature. If present, the ALV-ILV trunk is second to PILVs in terms of the drainage coverage area for most structures in the iliolumbar region and their avulsion during surgery will cause excessive blood loss (Kim *et al.*, 2013; Rhee *et al.*, 2015). Just like ALVs, the ALV-ILVs do not drain the L5/S1 region and below. Significant differences in the drainage sites of ALV-ILVs exists, with more male ALV-ILVs draining multiple structures on the left side, while more female ALV-ILVs were draining the L5 vertebral body on the right side. Previous reports did not observe sex and laterality significant differences (Jasani and Jaffray, 2002; Hamid *et al.*, 2007; Unruh *et al.*, 2008; Teli *et al.*, 2013). These observed differences emphasize the need to scrutinize specific patient vascular anatomy prior to selecting a surgical approach (Kim *et al.*, 2013).

Primarily, both DILVs and AILVs drain the iliac fossa and iliac muscle regardless of sex and laterality. Interestingly, small proportions (5%) of DILVs also drained the L5 vertebra body, which is inconsistent with reports that DILVs never drain the L5 vertebral body level in the American population (Unruh *et al.*, 2008). Additionally, the DILVs draining L5 vertebral level were all on the left side of the body. Thus, this difference with other reports may likely be due to population differences (Unruh *et al.*, 2008). Presumably, rupture of DILVs and AILVs may not result in significant haemorrhage, as their drainage field is very narrow.

5.2.6 Anastomosis of ILV tributaries

Communications (anastomosis) between tributaries serve as alternative channels in which blood may flow if any obstruction is in their normal routes (Moore *et al.*, 2018). The presence of anastomosis supports the need to carefully identify the vessels and ligate them as this will have no significant effect on the general circulation (Hamid *et al.*, 2007; Kim *et al.*, 2013). Inadvertent rupture, because of failing to perform prior ligation, may lead to excessive acute haemorrhage, which may have immediate effects on the general circulation and lead to surgical failure (Eck and Vaccaro, 2013; Kim *et al.*, 2013; Rhee *et al.*, 2015). Knowledge of these collateral blood pathways becomes crucial, especially when ligation of some veins will be mandatory (Kunakornsawat *et al.*, 2012; Kim *et al.*, 2013).

The present study found almost half of the study population to have ILV-ILV anastomosis, ranging from tributaries of two trunks communicating (single anastomosis) to tributaries of all trunks present communicating (triple anastomosis) (Figures 4.19-4.21). These anastomoses existed with variable frequencies, and this is the first study to report on ILV-ILV anastomosis. All the anastomosis observed have been classified into seven types for a detailed description (Table 4.4). Some authors believed that the ILVs might anastomose with internal venous vertebral plexus (IVVP), though this lacked explicit demonstration (Jasani and Jaffray, 2002; Hamid *et al.*, 2007; Unruh *et al.*, 2008; Kunakornsawat *et al.*, 2012; Teli *et al.*, 2013; Davis *et al.*, 2019). The existence of ILV to internal venous vertebral plexus anastomosis substantiates the impression that anastomosis of some sort may exist amongst the ILVs. Furthermore, the anastomosis strengthens suggestions that ILVs may likely be part of a more extensive venous system (Hamid *et al.*, 2007; Unruh *et al.*, 2008; Kim *et al.*, 2013).

Notably, the anastomosis of tributaries from all four trunks (type 7) (triple anastomosis) was observed on the left side in the females. This was so because females had four trunks proportionally more than males on the left side. The right side of the body showed higher proportions of type 3 anastomosis (the second most common type). This was probably because the right side of the body had relatively more tributaries than the left side. Despite this significant laterality difference, surgeons should still expect almost equal chances of finding anastomosis, be it the left or right side of the body or be it in males or females (Kim *et al.*, 2013).

Clinically, anastomosis of ILVs may be crucial as most of these vessels lie around the level of L5 to the S1 vertebra body. Ligation of one trunk which lies at the level of the intervertebral disc of interest may not compromise the blood flow from its drainage sites (Hamid *et al.*, 2007). On the other hand, the presence of these massive communications may lead to profuse bleeding in cases of accidental rupture of one of these valveless ILV trunks (Kiray *et al.*, 2004; Eck and Vaccaro, 2013; Kim *et al.*, 2013; Rhee *et al.*, 2015).

5.2.7 Entry positioning of ILVs into terminal drainage

The ILVs are located posterolateral to the iliac vessels they drain into (Nalbandian *et al.*, 2013). Posteriorly located ILVs may likely be obscured during preoperative imaging and subsequently falsely interpreted as absent (Datta *et al.*, 2007; Diesinger *et al.*, 2012; Barrey *et al.*, 2013). Laterally located ILVs, on the other hand, may be at a greater risk of rupture during medial retraction (Czerwein *et al.*, 2011; Eck and Vaccaro, 2013; Kim *et al.*, 2013). To our knowledge,

no previous studies described the direction of entry of ILVs into their terminal drainage, and the current study is the first to provide such a precise and crucial description.

The current study found that ILVs of the right side of the body enter into their respective terminal drainage posteriorly. In contrast, ILVs of the left side of the body enter their drainage laterally. This observation was consistent for both males and females. The laterality differences was probably because the common iliac vein (CIV) on the left side courses more medially to the structures it drains on its way to join the right-sided inferior vena cava (IVC), thus exposing its lateral side for the possible direction of entry of the ILVs. The CIV, on the right side of the body, courses more anteriorly to the structures it drains, making its posterior surface a possible entry direction of ILVs (Standring, 2015; Moore *et al.*, 2018).

While most ILVs exhibited significant differences in the direction of entry with respect to the laterality, the left-sided PILVs and AILVs did not (Table 4.5). Thus, during the search for ILVs to be ligated, surgeons should note that the direction of entry of PILVs and AILVs is very variable on the left side of the body. Without other studies to compare this finding with, this variability may be implied to be likely population specific, owing to the results that terminal drainage of PILVs varies considerably across population groups.

This knowledge of side of the laterality significant differences will likely lead to surgeon's success in their efforts to identify and locate the ILVs to perform the required ligation (Czerwein *et al.*, 2011; Eck and Vaccaro, 2013; Kim *et al.*, 2013). The right-sided ILVs may potentially be obscured from view when looking at anterior-posterior radiographic images during preoperative planning, thus may be the reason for observation of the absence ILVs in some studies (Datta *et al.*, 2007; Diesinger *et al.*, 2012; Barrey *et al.*, 2013). If not correctly identified and ligated when using the left side retroperitoneal approach, the left-sided ILVs may be excessively stretched during the medial retraction of iliac vessels to expose the intervertebral disc space of interest, thus putting them at a greater risk of rupture (Czerwein *et al.*, 2011; Eck and Vaccaro, 2013; Kim *et al.*, 2013).

5.3 Classification of ILVs (Unruh classification)

A wide range of classification systems of the ILVs exist in the literature and cause confusion to clinicians (Unruh *et al.*, 2008). To provide a more useful anatomical and clinically relevant description of ILVs, the current study adopted the use of the simplified Unruh *et al.* (2008) classification and consolidated all the known classifications into this system (Arthornthurasook

and Gaew-Im, 1987; Kiray *et al.*, 2004; Sivakumar *et al.*, 2007; Sheng *et al.*, 2008; Unruh *et al.*, 2008; Nalbandian *et al.*, 2013).

The presence of type 1 as the main type in the current study population group shows a significant variability rate with other studies (Jasani and Jaffray, 2002; Unruh *et al.*, 2008). However, most studies done in different population groups did not report the presence of this type 1 variation (Kiray *et al.*, 2004; Hamid *et al.*, 2007; Sivakumar *et al.*, 2007; Sheng *et al.*, 2008; Nalbandian *et al.*, 2013; Davis *et al.*, 2019). No significant sex and laterality differences were observed in this variation type. The authors who previously reported the type 1 variation did not describe the sex and laterality differences (Jasani and Jaffray, 2002; Unruh *et al.*, 2008).

Unlike type 1, type 2 variation is reported widely in the literature (Table 5.4). The fact that the observed frequencies of the type 2 pattern of ILVs agree with some reported findings (Sivakumar *et al.*, 2007; Unruh *et al.*, 2008) does not preclude the notion that significant proportional differences exist across population groups (Jasani and Jaffray, 2002; Kiray *et al.*, 2004; Hamid *et al.*, 2007; Sheng *et al.*, 2008; Nalbandian *et al.*, 2013; Davis *et al.*, 2019). Type 2 variation was more associated with either the left side of the body (Arthornthurasook and Gaew-Im, 1987) or the right side of the body (Hamid *et al.*, 2007). Just like some authors, the current study did not observe the laterality differences (Kiray *et al.*, 2004; Unruh *et al.*, 2008).

The present findings also show that the presence of type 3 variation is variable across population groups. Nalbandian *et al.* (2013) reported that type 3 variation is associated more with males than females. The current study did not observe sex associations with the type 3 variation. The rest of the prior reports did not describe sex differences, arguably making this difference population specific (Jasani and Jaffray, 2002; Kiray *et al.*, 2004; Hamid *et al.*, 2007; Sheng *et al.*, 2008; Unruh *et al.*, 2008; Davis *et al.*, 2019).

Consolidating all the formerly known classification systems into Unruh classification (Table 5.4) excludes some reports and explains why most authors did not attempt to do it (Sheng *et al.*, 2008; Nalbandian *et al.*, 2013; Davis *et al.*, 2019). While this may warrant a modification to Unruh *et al.* (2008) classification system, the current findings correspond with this classification as no new variants were observed, notwithstanding the use of larger sample size (Hamid *et al.*, 2007; Nalbandian *et al.*, 2013; Davis *et al.*, 2019). Thus, the present study supports the use of Unruh *et al.* (2008) classification. Knowledge of this variability is crucial for clinicians/surgeons working with diverse populations, and the need to do pre-operative

venous imaging becomes imperative (Datta *et al.*, 2007; Unruh *et al.*, 2008; Diesinger *et al.*, 2012; Nalbandian *et al.*, 2013; Davis *et al.*, 2019).

Table 5.4: Classification of the iliolumbar veins (ILVs) by Unruh *et al.* (2008) across population groups.

Study (Author and Year)	Population group	Type 1	Type 2	Type 3
Arthornthurasook and Gaew-Im (1987)	Thai	0.00%	42.90%	57.10%
Jasani and Jaffray (2002)	British	31.25%	68.75%	0.00%
Kiray <i>et al.</i> (2004)	Turkish	0.00%	26.30%	73.70%
Hamid <i>et al.</i> (2007) ×	French	0.00%	69.00%	27.00%
Sivakumar <i>et al.</i> (2007)	British	0.00%	13.00%	87.00%
Sheng <i>et al.</i> (2008)	Chinese	0.00%	26.70%	73.30%
Unruh <i>et al.</i> (2008)	American	53.00%	5.00%	42.00%
Nalbandian <i>et al.</i> (2013) ×	American	0.00%	73.00%	25.70%
Davis <i>et al.</i> (2019) ×	American	0.00%	46.7%	46.7%
Current study	White South African	60.71%	6.55%	32.74%

× studies with some excluded values due to the absence of ILV trunk.

5.4 Topography of ILVs

5.4.1 ILVs and Lumbar plexus (Obturator nerve and lumbosacral trunk)

The intimate relation of the course of the obturator nerve (ON) and lumbosacral trunk (LST) to ILVs makes them susceptible to inadvertent injury during the ligation of the ILVs to expose intervertebral disc spaces (Unruh *et al.*, 2008; Teli *et al.*, 2013; Standring, 2015; Barber *et al.*, 2017; Moore *et al.*, 2018). In addition, these nerves may also be damaged by clamps when controlling haemorrhage (Jasani and Jaffray, 2002). Identification of the course of these nerves may both be used to prevent their accidental damage and may also act as landmarks for locating ILVs (Unruh *et al.*, 2008).

5.4.2. Obturator nerve (ON) and ILVs

The current study found that most obturator nerves (ONs) lie anterior to ILVs in 96.4% of cases. This finding is similar to previous reports (Unruh *et al.*, 2008), but the remainder of the ON coursed inferior to ILVs, as opposed to the previously reported posterior course (Figure 4.24A-B) (Unruh *et al.*, 2008; Teli *et al.*, 2013). The anterior or posterior course of ON in relation to ILVs was also reported by Teli *et al.* (2013), who observed ON coursing anterior to ILVs in 55% and posterior to ILVs in 45% of ILVs. Despite this being the case, some authors

reported observing ON coursing anterior in 100% of ILVs (Jasani and Jaffray, 2002; Kiray *et al.*, 2004; Hamid *et al.*, 2007; Sheng *et al.*, 2008). The discrepancies in observation may be attributable to the differences in the dissection skills and or naming of the ILV trunks (Hamid *et al.*, 2007; Sheng *et al.*, 2008; Unruh *et al.*, 2008; Teli *et al.*, 2013).

The findings in the current study show that the course of ON in relation to PILVs, DILVs and AILVs is always anterior on both sides of the body and sex. Although specific ILV names were not reported by the previous authors, the current findings suggest that the relation of ON to these ILVs is not variable and precisely, these are possibly the ILVs that were reported in cases where ON coursed anteriorly only to ILVs (Jasani and Jaffray, 2002; Kiray *et al.*, 2004; Hamid *et al.*, 2007; Sheng *et al.*, 2008). For these ILVs, the consistent anterior course of ON may potentially be used by surgeons as a landmark in their quest to secure ILVs for ligation (Unruh *et al.*, 2008).

The ON coursed inferior to both ALV and ALV-ILV trunks in fewer cases. The variability of these two ILV trunks possibly suggests that they may have a posterior relation to ILVs formerly reported (Unruh *et al.*, 2008; Teli *et al.*, 2013). Of note was that the inferior relation of ON to ALV-ILV trunks was observed only in males on the left side and only in females on the right side. For the inferior relation of ON to ALV, males had larger proportions on both sides of the body. This inferior relation was probably because of the higher location of these ILV trunks in relation to the lumbosacral vertebra. Should a decision to locate ILV positions using the course of ON being made, surgeons may need to ponder on these freshly observed relations as the superiorly located ILVs (ALV and ALV-ILV) may be easily missed and potentially be ruptured during medial retraction of great vessels (Unruh *et al.*, 2008; Rhee *et al.*, 2015).

5.4.3 Lumbosacral trunk (LST) and iliolumbar veins (ILVs)

The current study reveals that ILVs have direct and variable relations to LST and L4 and L5 anterior rami spinal nerve roots before they joined to form LST (Kirchmair *et al.*, 2008). To our knowledge, the present study is the first to describe the ILVs in relation L4 and L5 anterior rami spinal nerve roots and LST (Figure 4.25A-B). This observation of ILVs being sandwiched between L4 and L5 anterior rami spinal nerve roots was because most of the union of the L4 and L5 anterior rami spinal nerve roots in the current study population group were formed below the level of sacroiliac joint (Waikakul *et al.*, 2010; Schmidt *et al.*, 2017). This made the ILVs located above this level to be sandwiched in between.

Overall, LST coursed posterior to all ILVs in the majority (69.1%) of cases. This finding of LST coursing posterior to ILVs concurs with previous reports (Kiray *et al.*, 2004; Unruh *et al.*, 2008). However, some authors documented that LST coursed posterior to ILVs in all their cases, a finding which differs significantly from the current study (Hamid *et al.*, 2007; Sheng *et al.*, 2008). Reports of LST coursing posterior to ILVs in 40% of study in Indian populations are significantly lower than proportions in the current study and are highly in support of population-specific variability (Teli *et al.*, 2013).

While posterior and anterior relations of LST to ILVs are widely reported (Jasani and Jaffray, 2002; Kiray *et al.*, 2004; Unruh *et al.*, 2008; Teli *et al.*, 2013), the current study reports for the first time, the inferior relation of LST to ILVs. Overall, LST was inferior to ILVs in 6.4% of cases, in both males and females, and on both sides of the body. This was probably because some ILVs were located at the level of the L4 vertebra body, a location slightly higher than the exit point of L4 and L5 anterior rami spinal nerve roots (Standring, 2015; Moore *et al.*, 2018). During the search for ILVs for ligation, surgeons should probably expect to find ILVs either anterior, posterior, or superior to LSTs, regardless of the laterality and sex.

5.4.3.1 L4 spinal nerve root of LST (L4/LST) and Iliolumbar veins (ILVs)

Out of all observed LST relationships, the relation of L4 spinal nerve root to ILVs was most common, with many of them coursing anteriorly to ILVs. When an ALV-ILV trunk is present, the L4 spinal nerve root was observed to course anterior to it more on the right side of the body and posterior to it on the left side of the body. The L4 spinal nerve root coursed anteriorly to DILVs more in females on the left side of the body than in males. This predominantly unusual anterior course will likely predispose the L4 spinal nerve root to accidental injuries during ligation of ILVs, especially when the use of right-side retroperitoneal approach to expose the intervertebral disc space is indicated (Eck and Vaccaro, 2013; Kim *et al.*, 2013; Rhee *et al.*, 2015).

5.4.3.2 L5 spinal nerve root of LST (L5/LST) and Iliolumbar veins (ILVs)

The L5 spinal nerve root coursed posterior to ILVs, except for ALV and ALV-ILV trunks. The observed course of L5 spinal nerve root varies as either posterior or inferior to ALV and ALV-ILV trunks, with the posterior course being more common. On the other hand, the course of L5 spinal nerve root in relation to PILV, DILV and AILVs is always posterior, regardless of sex and laterality. L5 spinal nerve root relation to DILVs is similar to the L4 spinal nerve root, except that it is posterior this time. The consistently posterior course of L5 spinal nerve root

could probably be because it descends directly anterior on the underlying sacral bone and all its ventral rami contribute to the formation of LST (Sim and Webb, 2004; Ergun and Lakadamyali, 2010; Matejčík, 2010; Standring, 2015; Moore *et al.*, 2018).

When the ILVs are correctly identified and ligated, the L5 spinal nerve root will unlikely be exposed to injuries during the intervertebral disc space exposure (Hamid *et al.*, 2007; Sheng *et al.*, 2008). Despite this, the L5 spinal nerve root may be damaged by clamps used to control haemorrhage in cases where adequate exposure was not achieved, and avulsion has occurred (Jasani and Jaffray, 2002; Eck and Vaccaro, 2013; Kim *et al.*, 2013).

5.4.3.3 Lumbosacral trunk (L4&L5) and Iliolumbar veins (ILVs)

The current study found the lumbosacral trunk (LST) course to be variable but principally posterior in relation to ILVs. While this finding is not different from the previously reported (Jasani and Jaffray, 2002), the proportions in the current study are significantly higher than those reported by other authors, suggesting population specific differences (Kiray *et al.*, 2004; Unruh *et al.*, 2008; Teli *et al.*, 2013). Reports that LST lies posterior to ILVs more in males have been observed only in the DILVs of the left side (Unruh *et al.*, 2008).

The LST always coursing posterior in relation to DILVs and AILVs is possibly because these ILVs are chiefly located at the level of S1, way after the LST has already received L4 and L5 spinal nerve roots contributions (Waikakul *et al.*, 2010; Schmidt *et al.*, 2017). Though this posterior course is comparable to some reports (Hamid *et al.*, 2007; Sheng *et al.*, 2008), it is very uncertain to conclude that their reports were describing the DILVs and AILVs. This is so because of the different nomenclature used (Hamid *et al.*, 2007; Sheng *et al.*, 2008; Unruh *et al.*, 2008).

The findings in the current study have shown that the relations of LST and its L4 and L5 spinal nerve roots are very variable with regards to ILVs in the current study group. This variability makes scrutiny of individualized patient anatomy a necessity during preoperative planning of the lumbosacral spine (Eck and Vaccaro, 2013; Kim *et al.*, 2013).

5.4.4 ILVs and Lumbosacral vertebra

5.4.4.1 General location of ILVs

The detailed description of the relative location of the ILVs may help surgeons in their preoperative planning to pinpoint their search area for easy ligation of ILVs (Sivakumar *et al.*, 2007; Unruh *et al.*, 2008; Eck and Vaccaro, 2013; Nalbandian *et al.*, 2013; Davis *et al.*, 2019).

Additionally, the precise location may also help in determining the ILVs at a greater risk of avulsion during medial retraction of great vessels (Kiray *et al.*, 2004). The current study provides both general and specific location of ILVs and their variability in relation to sex and laterality to aid in more accurate identification and control of ILVs.

The present results show that ILVs may be located at any level between the L4 vertebra body and just below the S1 vertebra body, with over a third of them lying at the level of the S1 vertebra body. This greater variability is regardless of sex and laterality, and the current findings concur with previous reports (Kiray *et al.*, 2004; Sheng *et al.*, 2008; Davis *et al.*, 2019). The current study also shows that the previously described “triangular search area” (Sivakumar *et al.*, 2007) for locating ILVs is narrow for the present study group as some ILVs may be located above the L5 vertebral body level. Should the access to L4/L5 intervertebral disc space become necessary, surgeons should consider exposing as far as the L4 vertebral body to identify and control ILVs, thus ensuring safe surgery (Hamid *et al.*, 2007; Kim *et al.*, 2013; Rhee *et al.*, 2015).

Reports that most ILVs are usually located just below L4/L5 disc space were in agreement with over three-quarters of all the ILVs observed in the current study (Davis *et al.*, 2019). The location of the majority of ILVs below the level of L4/L5 disc space may potentially be advantageous as most of them may not be directly encountered during the intervention of L4/L5 intervertebral disc space (Kim *et al.*, 2013; Rhee *et al.*, 2015). Nevertheless, surgeons should still approach this area cautiously as forceful retraction of great vessels may still result in avulsion of the nearby low-lying ILVs (Rhee *et al.*, 2015).

5.4.4.2 Specific location of ILVs

The current findings support the previous reports that found that the ALVs are usually located at the level of the L5 vertebra (Sheng *et al.*, 2008). Additionally, in the current study population, the location of ALVs at the level of L5 vertebra was predominantly in males. Another significant difference was observed on the ALVs located on the L5/S1 intervertebral disc space, as they were more in females and on the left side of the body. However, there are no previous reports demonstrating significant sex differences on the location of the ALVs in the Turkish (Kiray *et al.*, 2004), Chinese (Sheng *et al.*, 2008) and American populations (Davis *et al.*, 2019). In addition, the wide range of variable ALV location mainly manifested in females and on the right side of the body. Previous authors reported a narrow range of possible ALV locations, and this difference could be because of population differences (Kiray *et al.*, 2004;

Sheng *et al.*, 2008; Davis *et al.*, 2019). Surgeons considering the right side retroperitoneal approach to the lumbosacral spine should anticipate the variable location of ALVs in their preoperative planning, even though most of them may be easily identified at the level of the L5 vertebral body.

Reports of most ALV-ILV trunks lying at the level of the L5 vertebral body corresponds with the current findings (Sheng *et al.*, 2008). Like ALVs, a wide variation was apparent in females on the right side of the body. This variation was observed previously by Lolis *et al.* (2011) in the Caucasian population. This could be because the iliac veins on the right side do not cross over the midline to join the inferior vena cava (IVC), unlike those on the left side, which pulls their tributaries up the lumbosacral spine on their way to join the IVC. The pulling of tributaries up the lumbosacral spine thereby narrows the ILV location range (Standring, 2015; Moore *et al.*, 2018).

The majority of the PILVs, DILVs and AILVs are found at the level of the S1 vertebral body or below. The only statistically significant difference observed was for the location of AILVs at the level of the S1 vertebra, which was higher in females on the left side of the body. However, the current findings differ significantly with some reports from the Turkish and American populations that did not observe most of the ILVs lying at the level of S1 vertebra, and may be attributable to normal population differences (Kiray *et al.*, 2004; Davis *et al.*, 2019).

The more distal location of most PILVs, DILVs and AILVs, makes them less susceptible to avulsion injuries when the management of the L4/L5 and L5/S1 intervertebral disc space pathologies are indicated (Eck and Vaccaro, 2013; Kim *et al.*, 2013). For L4/L5 intervertebral disc space interventions, the distally located ILVs may not stretch and rupture during the medial retraction of great vessels (Kiray *et al.*, 2004). In cases of L5/S1 intervertebral disc space interventions, these distally located ILVs may still be less vulnerable as exposure to this space is not affected by their presence (Schwartz *et al.*, 2010; Eck and Vaccaro, 2013; Kim *et al.*, 2013; Rhee *et al.*, 2015; Chung *et al.*, 2020).

The current study has shown that ILVs location with respect to the lumbosacral spine varies greatly with sex and laterality. Population-specific differences, especially from the Turkish, Chinese and American populations, have also been demonstrated (Kiray *et al.*, 2004; Sheng *et al.*, 2008; Davis *et al.*, 2019).

5.5 Morphometrics of ILVs

5.5.1 Distance between the ostium of the ILV and the origin of inferior vena cava (IVC)

The distance between the ostium of the ILV and the origin of IVC (ILV-IVC) helps in determining the risk of ILV avulsion during retraction of the great vessels to expose the intervertebral disc space. The risk of avulsion is increased when the distance between the ostium of the ILV and the origin of IVC is less than 30 mm (Sivakumar *et al.*, 2007; Lolis *et al.*, 2011; Davis *et al.*, 2019). Additionally, the ILV-IVC distance also helps surgeons define the search area range for the ILVs to be ligated. The current study determined this distance for each trunk of ILVs.

All the ILV trunks in the current study were found in the 0-115mm from the origin of IVC, similar to previous reports (Unruh *et al.*, 2008). Females had a slightly higher range on the left side, probably because of their wider pelvis, and it should be recommended that the search area for ILVs on the left side may need to be expanded more distally in females than in males (Sivakumar *et al.*, 2007; Unruh *et al.*, 2008). In addition, this broader range makes the ILVs on the left side in females less susceptible to avulsion as traction force during mobilization may not be felt by the more distally located ILVs (Sivakumar *et al.*, 2007; Unruh *et al.*, 2008; Kim *et al.*, 2013).

The present findings also suggest that the ALV and ALV-ILV trunks are at higher risk of avulsion because of their closeness to the origin of IVC, and this necessitates their ligation before intervertebral disc exposure (Jasani and Jaffray, 2002; Sivakumar *et al.*, 2007; Sheng *et al.*, 2008; Lolis *et al.*, 2011; Davis *et al.*, 2019). Female ALVs on the right side pose a greater risk of avulsion, and this is a direct opposite of reports that it is the male's left-sided ALVs at greater risk (Sivakumar *et al.*, 2007). The risk of ALV-ILV trunk avulsion is shared equally amongst males and females.

The overall mean distance from the origin of IVC to ALVs in the current study is similar to that reported by Lolis *et al.* (2011) but higher than that reported by Sheng *et al.* (2008). Although not specific to the type of ILV that was studied, the mean distance from the origin of IVC to ALVs in the current study is also higher than those previously documented (Jasani and Jaffray, 2002; Hamid *et al.*, 2007; Teli *et al.*, 2013). The overall mean distance from the origin of IVC to ALV-ILVs corresponds to that reported by Lolis *et al.* (2011), but it is higher than that reported by Hamid *et al.* (2007). Interestingly, all the previously reported overall mean distances from the origin of IVC to ILVs from the American, British, Caucasian, Chinese,

French, Indians and Turkish populations, are significantly lower than those of PILV, DILV and AILV in the current study. This reveals that population specificity may likely be a significant contributing factor (Jasani and Jaffray, 2002; Kiray *et al.*, 2004; Hamid *et al.*, 2007; Sivakumar *et al.*, 2007; Sheng *et al.*, 2008; Unruh *et al.*, 2008; Lolis *et al.*, 2011; Teli *et al.*, 2013). It may, therefore, be suggested that the long distance to the PILVs, DILVs and AILVs places them slightly above the danger of avulsion during the mobilization and retraction of great vessels (Sivakumar *et al.*, 2007; Lolis *et al.*, 2011; Eck and Vaccaro, 2013; Kim *et al.*, 2013; Davis *et al.*, 2019).

Regardless of the type of ILV trunk available, the findings in the present study substantiate reports that the distance from the origin of IVC to ILVs is significantly longer on the left side than the right side (Kiray *et al.*, 2004; Hamid *et al.*, 2007; Unruh *et al.*, 2008; Lolis *et al.*, 2011; Davis *et al.*, 2019). This is because the origin of IVC is displaced more to the right side than the left side (Standring, 2015; Moore *et al.*, 2018).

While some authors reported that the mean distance from the origin of IVC to ILV tends to be longer in females than in males in the British and American populations, the present study found no sex differences, probably because of the different population groups studied (Sivakumar *et al.*, 2007; Unruh *et al.*, 2008).

5.5.2 Length of ILV trunks

Adequate exposure of an ILV trunk for ligation before exposure of the intervertebral disc space is important (Eck and Vaccaro, 2013; Kim *et al.*, 2013; Rhee *et al.*, 2015). The variation of the ILV trunk length makes ligation during surgery difficult, especially for the short trunks (Jasani and Jaffray, 2002). The shorter trunks further increase the risk for sidewall injury to the iliac veins during retraction (Jasani and Jaffray, 2002).

The current study showed that the range of the length of ILVs is wider than the previously reported ranges (Arthornthurasook and Gaew-Im, 1987; Jasani and Jaffray, 2002; Sheng *et al.*, 2008; Unruh *et al.*, 2008). On the other side, the range of ILV length in the current study is narrower than the range of ILV length reported by Davis *et al.* (2019). Except for PILVs on the right side, the current study supports that the ILVs on the left side are usually longer than those on the right side (Unruh *et al.*, 2008; Lolis *et al.*, 2011; Davis *et al.*, 2019). This may be attributable to the more medial course of the left common iliac vein (CIV), in which the pulled tributaries (ILVs) will have to make up for this in their length to achieve drainage of their

designated areas (Standring, 2015; Moore *et al.*, 2018). The PILVs on the right side, on the other hand, did not follow this observation probably because of the uneven distribution of length of PILVs, which was in males (Shapiro Wilk test .001). Despite the PILVs on the right side being longer than the left side, the present findings still support the likelihood of the ILVs on the right side not only being difficult to ligate but also being difficult to control their bleeding through suturing (Jasani and Jaffray, 2002; Unruh *et al.*, 2008; Lolis *et al.*, 2011; Kim *et al.*, 2013; Davis *et al.*, 2019). The current findings also suggests that caution should be taken in cases where the right side retroperitoneal approach is the only feasible approach (Eck and Vaccaro, 2013; Kim *et al.*, 2013; Rhee *et al.*, 2015).

It has been postulated that males tend to have longer ILV trunks than females, and the findings in the current study support this in terms of the range of PILVs, ALV-ILVs and ALVs on the left side only (Unruh *et al.*, 2008). On the other hand, females accounted for wider ranges in the lengths of ALVs on the right side and DILVs on the left side, indicating that variations exist. Thus, regardless of the retroperitoneal approach to be used, these variations necessitate a preoperative evaluation of patient-specific venous anatomy (Kim *et al.*, 2013).

Though the overall mean length in the present study concurs with some reported overall mean lengths (Jasani and Jaffray, 2002; Kiray *et al.*, 2004; Unruh *et al.*, 2008), it is significantly lower than that of Davis *et al.* (2019). These population specific variations are further supported by one overall mean significantly lower than what has been reported in the current study (Sheng *et al.*, 2008). The present findings also show that sex and laterality mean length differences for each specific type of ILV trunk are not statistically significant.

The findings in the current study further suggest that the more proximally located ILVs (ALV, ALV-ILVs and PILVs) have larger mean length and their ligation during the exposure of the intervertebral disc space is easy (Jasani and Jaffray, 2002; Eck and Vaccaro, 2013; Kim *et al.*, 2013). This has been substantiated by the mean length of ALVs being significantly higher than that of the DILVs. Therefore, it should be noted that the distally located ILVs may increase the risk of sidewall injuries to the iliac veins, which may lead to profuse haemorrhage (Jasani and Jaffray, 2002; Kim *et al.*, 2013).

5.5.3 Distance between obturator nerve (ON) and iliolumbar veins (ILVs)

The closer the obturator nerve (ON) and the lumbosacral trunk (LST) courses in relation to ILVs, the more they are susceptible to inadvertent injuries during the exposure and ligation of

ILVs, which may result in significant numbness and weakness to the thigh muscles (Jasani and Jaffray, 2002; Sheng *et al.*, 2008; Kim *et al.*, 2013; Rhee *et al.*, 2015). The current study describes the variability of the relative distances of ON and LST to ILVs.

The current findings show that ON courses and intersects with all the ILVs at variable distances (Jasani and Jaffray, 2002; Sheng *et al.*, 2008; Unruh *et al.*, 2008). The ON has potentially fewer chances of being injured during the ligation of ALVs and ALV-ILVs. This may be because the ALV and ALV-ILVs intersect less frequently with the ON and their distance is longer than the other ILVs. Should an inadvertent haemorrhage occur, the ON may likely be injured by clamps used to control the bleeding, especially if the ruptured vessels are PILVs, DILVs and AILVs as these vessels intersect more frequently with ON (Jasani and Jaffray, 2002). Thus, it is essential to properly dissect and ligate these ILVs to avoid accidental injuries to the ON (Sheng *et al.*, 2008; Kim *et al.*, 2013). Despite the few ON-ALV intersections occurring in females and on the right side only, the current findings show that the variability of the ON to ILV intersections are not dependent on sex and laterality.

The present findings concur with reports that the ON to ILV distances are longer in males, but the differences are not statistically significant (Unruh *et al.*, 2008). The current study also found that the range of ON to ILV distance is much wider on the left side of the body (Unruh *et al.*, 2008). Thus, surgeons opting for the left side retroperitoneal approach may need to worry less about accidental injuries to the ON during the exposure of the intervertebral disc spaces (Eck and Vaccaro, 2013; Kim *et al.*, 2013; Rhee *et al.*, 2015).

All the ON to ILV mean distances in the current study are much lower than those previously reported in the British and Chinese populations (Jasani and Jaffray, 2002; Sheng *et al.*, 2008). However, the ON to ALV-ILV mean distance in the current study is comparable to a single previous study of the American population (Unruh *et al.*, 2008). This may suggest population specific variations in the ON-ILV distances (Jasani and Jaffray, 2002; Sheng *et al.*, 2008; Unruh *et al.*, 2008).

5.5.4 Distance between Lumbosacral trunk (LST) and ILVs

Similar to the obturator nerve (ON), the current findings show that L4 spinal nerve root, L5 spinal nerve root and lumbosacral trunk (L4 and L5) all intersect with the ILVs in variable frequencies (Jasani and Jaffray, 2002; Sheng *et al.*, 2008; Unruh *et al.*, 2008). In cases where the LST is present, its chances of being injured inadvertently during the ligation of ILVs are

high, as it is the only nerve trunk that intersects with all ILV trunks. It should be noted that the limited exposure of PILVs for their ligation may increase the chances of injury to both LST and its spinal nerve roots. This is because the PILV trunks share more intimate relations with the LST than other ILV trunks, like reports from the British and Chinese populations (Jasani and Jaffray, 2002; Sheng *et al.*, 2008). The findings in the current study also show that the L5 spinal nerve root does not intersect with the DILVs and AILVs irrespective of sex and laterality. This may likely be because of the more distal and lateral location of these ILVs (Moore *et al.*, 2018).

The ranges in the current study demonstrate a greater variability of the distances. Except for ALVs and PILVs, the range of LST to ILVs were higher in males and on the right side, similar to that of the American population (Unruh 2008). Conversely, the higher ranges for L5 spinal nerve root were predominantly on the left side and in females. The range of distance of L4 spinal nerve root to ILVs, on the other hand, had no statistically significant sex and laterality prevalence. Thus, these variable ranges necessitate preoperative examination of patient-specific anatomy to reduce the chances of injuries to the LSTs (Kim *et al.*, 2013; Rhee *et al.*, 2015). The ranges of ILVs to both the LST and its spinal nerve roots in the current study implies that the LSTs may be at a greater risk of accidental injuries when attempts to ligate or control bleeding are made in the present study group than in the American population group (Unruh *et al.*, 2008). However, ligation of ALVs poses less chances of injuries to the LSTs due to their wider range.

The overall mean distance of ILV to LST in the current study are similar to those previously reported in the Chinese and American populations (Sheng *et al.*, 2008; Unruh *et al.*, 2008). Nevertheless, they are significantly lower than those reported by Jasani and Jaffray (2002) in the British population. The only significant laterality mean differences were observed for ALV and ALV-ILV trunks. The mean distance of ALV-ILV to both L4 and L5 spinal nerve roots were higher on the left side. The mean distance of LST to both ALV and ALV-ILV trunks were significantly higher on the right side of the body and validated previous reports (Unruh *et al.*, 2008). Unlike Unruh *et al.* (2008), who reported higher mean distances in males in the American population, the differences in the mean distance for sex were not observed in the current study. Of note is that the relations of both L4 and L5 spinal nerve roots to DILV and AILVs were observed only in females, on the left side and right side of the body, respectively. Thus, these findings support variations across population groups and call for individualized

scrutiny of patient vascular anatomy preoperatively (Jasani and Jaffray, 2002; Sheng *et al.*, 2008; Unruh *et al.*, 2008).

5.6 Histology of the ILVs

5.6.1 ILV layers and thickness

Description of iliolumbar venous wall thickness may help in determining the vessels that may likely be difficult to control for bleeding in the event of massive haemorrhage (Kiray *et al.*, 2004). The current findings show that both PILVs and DILVs conform to the general description of the histological layers of veins (Oklu *et al.*, 2012; Berridge *et al.*, 2013; Ovalle and Nahirney, 2013; Evans *et al.*, 2015; Ross and Pawlina, 2016; Sidawy and Perler, 2018). Like previous reports, the tunica adventitia is the most prominent layer in the ILVs, with its thickness being three times that of the tunica media and tunica intima combined (Schwartz *et al.*, 2010; Berridge *et al.*, 2013). During surgery, inadvertent haemorrhage from the proximal ILVs on the left side may potentially be easier to control than from those on the right side because the proximal ILVs on the left side are marginally thicker ($p=.051$) (Kiray *et al.*, 2004). On the other hand, the relatively thin walled PILVs on the right side may be prone to varicosity and inadvertent rupture during retraction of great vessels (Eck and Vaccaro, 2013; Kim *et al.*, 2013; Sidawy and Perler, 2018). No significant laterality differences was observed for the distal ILVs (DILVs). Noteworthy is that significant differences between male and female ILV wall thicknesses were not observed in the current study.

5.6.2 Elastic and collagen fibres content

The presence of elastic and collagen fibres in a vessel may help in determining the vessels that have an increased risk of rupture during the retraction of great vessels to expose the lumbosacral spine (Bia *et al.*, 2005; Zócalo *et al.*, 2013; Latimer *et al.*, 2014).

Contrary to the common belief about medium-sized veins, the current study's findings show that ILVs contain elastic fibres (Elsharawy *et al.*, 2007; Mescher and Junqueira, 2013; Devi, 2016; Ross and Pawlina, 2016). The elastic fibres present were found in the tunica intima as internal elastic lamina and some scattered fibres in the tunica adventitia (Elsharawy *et al.*, 2007; Ross and Pawlina, 2016). The scattered elastic fibres were probably secreted by the smooth muscles that were abundant in tunica adventitia and tunica media (McMonagle and Stephenson, 2014; Sidawy and Perler, 2018). The presence of more elastic fibres in the left proximal ILVs potentially supports the use of the left side retroperitoneal approach since these ILVs may be more resilient to traction forces during medial retraction of great vessels than the right proximal

ILVs (Elsharawy *et al.*, 2007; Valdez-Jasso *et al.*, 2008; Lai and Lü, 2012; Berridge *et al.*, 2013; Kim *et al.*, 2013).

Though not significant, the ILVs on the left side contains a higher amount of collagen fibres than the ILVs on the right side. No significant sex differences were observed, concurring with a previous author that veins of the same caliber have similar collagen content (Li, 2018). The collagen fibres were found in both within and around the smooth muscles located in the tunica media and tunica adventitia offering structural support to the walls of the veins (Figure 4.35 and 4.36) (Haviarova *et al.*, 1999; Elsharawy *et al.*, 2007; Ross and Pawlina, 2016). In cases where veins are affected by age-related degenerative changes, smooth muscles are activated to synthesize collagen fibres to repair the vessel wall (Vvali and Ra, 2002; Wali and Eid, 2002; Naoum *et al.*, 2007; Lim and Davies, 2009; McMonagle and Stephenson, 2014; Sidawy and Perler, 2018). This, in turn, makes the vessels more rigid and increases their likelihood of rupture during the retraction of the vessels (Kim *et al.*, 2013; McMonagle and Stephenson, 2014; Sidawy and Perler, 2018). Nonetheless, most patients who require spinal exposure are often younger, and surgeons should still consider this, especially when deliberating lumbosacral spinal operations in geriatric groups (Rhee *et al.*, 2015).

The presence of more collagen fibres than elastic fibres in the walls of ILVs substantiates the functions of veins as capacitance vessels in general (Schwartz *et al.*, 2010; Zócalo *et al.*, 2013; Latimer *et al.*, 2014; McMonagle and Stephenson, 2014; Sidawy and Perler, 2018). Furthermore, this also makes the need for ligation of ILVs prior to exposure of lumbosacral vertebra an absolute necessity since these vessels will be more resistant to the retraction of great vessels (Schwartz *et al.*, 2010; Kim *et al.*, 2013).

CHAPTER 6: RECOMMENDATIONS AND CONCLUSION

6.1 Limitations

The current study utilized formalin fixed cadavers, and the formalin may cause shrinkage of vessels thereby reducing their dimensions. This might make comparisons with studies from frozen specimens difficult (Uhl *et al.*, 2010). Dissection approaches may have slightly changed the position of ILVs and their surrounding ON and LST; thus, the dimensions of ILVs to these relative structures may only act as relative guidance during surgery.

6.2 Recommendation for further studies

Since this is the first study to observe and report the differences in the direction of entry of ILVs into their terminal drainage in a defined population group, further studies will be required in different population groups to validate the current findings. Despite using a large sample size with almost equal male and female proportions, no significant sex differences were observed, and this may likely be different from other population groups. Besides, two ILVs showed a variability pattern from this finding. Therefore, it is imperative to verify this with other population groups.

The massive anastomosis between ILV trunks also requires further study. The patterns may likely be different in a population group that presents with less ILV trunks. ILVs being sandwiched between L4 and L5 spinal nerve roots also needs further studies. A high prevalence of ILVs lying in between L4 and L5 spinal nerve roots signifies this variation may be population specific. Thus, further studies in diverse population groups may help in understanding this relationship better and its clinical implications.

6.3 Conclusions

The current study has shown that the patterns of the ILVs are not only variable across population groups but also within the White South African population group. The specific and detailed anatomy of each ILV has been provided. Most noteworthy findings included the presence of anastomosing tributaries, ILVs having a specific direction of entry into terminal drainage and ILVs being sandwiched between L4 and L5 spinal nerve roots of LST. Thus, the current study substantiates the need for routine preoperative evaluation of patient specific vascular morphology.

The basic histology of the ILVs has shown that there are more collagen fibres than elastin fibres, regardless of sex and laterality. The findings have also demonstrated that PILVs on the

left side have a reduced risk of rupture during the retraction of great vessels due to high elastic fibre content. Besides, bleeding from PILVs on the left side will be easier to control due to their thickness. Thus, the current study supports the preference of the left side retroperitoneal approach when managing the lumbosacral and L4/L5 intervertebral disc spaces.

REFERENCES

- Aapor (2012) *Creative research systems; Sample size formular for our calculator*. Available at: <https://www.surveysystem.com/sample-size-formula.htm> (Accessed: July).
- Almeida, J. (2018) *Atlas of Endovascular Venous Surgery E-Book*. Elsevier Health Sciences.
- Arbanas, J., Starcevic Klasan, G., Nikolic, M., Jerkovic, R., Miljanovic, I. and Malnar, D. (2009) 'Fibre type composition of the human psoas major muscle with regard to the level of its origin', *Journal of Anatomy*, 215(6), pp. 636-641.
- Arthornthurasook, A. and Gaew-Im, K. (1987) 'Study of ascending lumbar and iliolumbar veins', *Spine*, 12(1), pp. 70-72.
- Asha, M. J., Choksey, M. S., Shad, A., Roberts, P. and Imray, C. (2012) 'The role of the vascular surgeon in anterior lumbar spine surgery', *British Journal of Neurosurgery*, 26(4), pp. 499-503.
- Badagabettu, S. N., Shetty, P. and D'Souza, M. R. (2016) 'A unique variation of azygos system of veins', *Journal of Cardiovascular Echography*, 26(2), p. 61.
- Bailey, R. (2020) *Why Men Are Typically Taller Than Women*. Available at: thoughtco.com/why-men-are-typically-taller-than-women-3975666 (Accessed: 15 February).
- Baker, J. K., Reardon, P. R., Reardon, M. J. and Heggeness, M. H. (1993) 'Vascular injury in anterior lumbar surgery', *Spine*, 18(15), pp. 2227-2230.
- Barber, S. M., Boghani, Z., Steele, W., Blacklock, J. B., Trask, T. and Holman, P. (2017) 'Variation in psoas muscle location relative to the safe working zone for L4/5 lateral transpsoas interbody fusion: A morphometric analysis', *World Neurosurgery*, 107, pp. 396-399.
- Barrey, C., Ene, B., Louis-Tisserand, G., Montagna, P., Perrin, G. and Simon, E. (2013) 'Vascular anatomy in the lumbar spine investigated by three-dimensional computed tomography angiography: the concept of vascular window', *World Neurosurgery*, 79(5-6), pp. 784-791.

- Bassani, R., Gregori, F. and Peretti, G. (2019) 'Evolution of the anterior approach in lumbar spine fusion', *World Neurosurgery*, 131, pp. 391-398.
- Bateman, D. K., Millhouse, P. W., Shahi, N., Kadam, A. B., Maltenfort, M. G., Koerner, J. D. and Vaccaro, A. R. (2015) 'Anterior lumbar spine surgery: a systematic review and meta-analysis of associated complications', *The Spine Journal*, 15(5), pp. 1118-1132.
- Benglis, D. M., Vanni, S. and Levi, A. D. (2009) 'An anatomical study of the lumbosacral plexus as related to the minimally invasive transpsoas approach to the lumbar spine', *Journal of Neurosurgery: Spine*, 10(2), pp. 139-144.
- Benrashid, E., Sanchez, L. A., Ohman, J. W. and Jim, J. (2020) 'Contemporary Outcomes of Anterior Spine Exposure: The Influence of Prior Abdominal or Spine Surgery and Exposure Level and Extent', *Journal of Vascular Surgery*, 72(1), p. e130.
- Berridge, B. R., Van Vleet, J. F. and Herman, E. (2013) 'Cardiac, vascular, and skeletal muscle systems', *Haschek and Rousseaux's Handbook of Toxicologic Pathology*, pp. 1567-1665.
- Bia, D., Aguirre, I., Zócalo, Y., Devera, L., Fischer, E. C. and Armentano, R. (2005) 'Regional differences in viscosity, elasticity, and wall buffering function in systemic arteries: pulse wave analysis of the arterial pressure-diameter relationship', *Revista Española de Cardiología (English Edition)*, 58(2), pp. 167-174.
- Bianchi, C., Ballard, J. L., Abou-Zamzam, A. M., Teruya, T. H. and Abu-Assal, M. L. (2003) 'Anterior retroperitoneal lumbosacral spine exposure: operative technique and results', *Annals of Vascular Surgery*, 17(2), pp. 137-142.
- Brau, S. A., Delamarter, R. B., Schiffman, M. L., Williams, L. A. and Watkins, R. G. (2004) 'Vascular injury during anterior lumbar surgery', *The Spine Journal*, 4(4), pp. 409-412.
- Brewster, L., Trueger, N., Schermer, C., Ghanayem, A. and Santaniello, J. (2008) 'Infraumbilical anterior retroperitoneal exposure of the lumbar spine in 128 consecutive patients', *World Journal of Surgery*, 32(7), pp. 1414-1419.

Bui, K. L., Ilaslan, H., Recht, M. and Sundaram, M. (2008) 'Iliopsoas injury: an MRI study of patterns and prevalence correlated with clinical findings', *Skeletal Radiology*, 37(3), pp. 245-249.

Chiriano, J., Abou-Zamzam Jr, A. M., Urayeneza, O., Zhang, W. W. and Cheng, W. (2009) 'The role of the vascular surgeon in anterior retroperitoneal spine exposure: preservation of open surgical training', *Journal of Vascular Surgery*, 50(1), pp. 148-151.

Chou, E. L., Colvard, B. D. and Lee, J. T. (2016) 'Use of aortic endograft for repair of intraoperative ilio caval injury during anterior spine exposure', *Annals of Vascular Surgery*, 31, pp. 207. e5-207. e8.

Chung, N.-S., Lee, H.-D. and Jeon, C.-H. (2020) 'Vascular anatomy and surgical approach in oblique lateral interbody fusion at lumbosacral transitional vertebrae', *Journal of Orthopaedic Science*.

Czerwein, J. K., Thakur, N., Migliori, S. J., Lucas, P. and Palumbo, M. (2011) 'Complications of anterior lumbar surgery', *Journal of the American Academy of Orthopaedic Surgeons*, 19(5), pp. 251-258.

D'Costa, S., Ramanathan, L. A., Madhyastha, S., Nayak, S., Prabhu, L. V., Rai, R. and Saralaya, V. V. (2008) 'An accessory iliacus muscle: a case report', *Romania Journal of Morphology and Embryology*, 49(3), pp. 407-409.

Da Silva, R. (2013) *Anatomical study of the variation in the branching patterns and histology of the aorta in a South African population*. University of Cape Town.

Datta, J. C., Janssen, M. E., Beckham, R. and Ponce, C. (2007) 'The use of computed tomography angiography to define the prevertebral vascular anatomy prior to anterior lumbar procedures', *Spine*, 32(1), pp. 113-119.

Davis, M., Jenkins, S., Bordes, S., Iwanaga, J., Loukas, M., Uribe, J., Hynes, R. A. and Tubbs, R. S. (2019) 'Iliolumbar vein: anatomy and surgical importance during lateral transpsoas and oblique approaches to lumbar spine', *World Neurosurgery*, 128, pp. e768-e772.

DePietro, D. M., Carlon, T., Trerotola, S. O. and Sudheendra, D. (2020) 'Endovascular Treatment of an Anatomically Complex Iliac Lesion and a Review of Variant Iliac Venous Anatomy', *Journal of Vascular and Interventional Radiology*, 31(2), pp. 260-264.

Devi, S. V. (2016) *Basic Histology: A Color Atlas & Text*. Jaypee Brothers, Medical Publishers Pvt. Limited.

Diesinger, Y., Charles, Y., Bouaka, D., Godet, J. and Steib, J. (2012) 'Preoperative phlebography in anterior L4-L5 disc approach. Clinical experience about 63 cases', *Orthopaedics & Traumatology: Surgery & Research*, 98(8), pp. 887-893.

Eck, J. C. and Vaccaro, A. (2013) *Surgical Atlas of Spinal Operations*. Jaypee Brothers, Medical Publishers Pvt. Limited.

Ellis, H. (2002) 'Medico-legal litigation and its links with surgical anatomy', *Surgery (Oxford)*, 20(8), pp. 1-2.

Elsharawy, M. A., Naim, M. M., Abdelmaguid, E. M. and Al-Mulhim, A. A. (2007) 'Role of saphenous vein wall in the pathogenesis of primary varicose veins', *Interactive Cardiovascular and Thoracic Surgery*, 6(2), pp. 219-224.

Ergun, T. and Lakadamyali, H. (2010) 'CT and MRI in the evaluation of extraspinal sciatica', *The British Journal of Radiology*, 83(993), pp. 791-803.

Escobar, E., Transfeldt, E., Garvey, T., Ogilvie, J., Graber, J. and Schultz, L. (2003) 'Video-assisted versus open anterior lumbar spine fusion surgery: a comparison of four techniques and complications in 135 patients', *Spine*, 28(7), pp. 729-732.

Evans, J. D. W., Horton-Szar, D. and Newby, D. E. (2015) *Crash Course Cardiovascular System Updated Edition - E-Book*. Elsevier Health Sciences.

Fantini, G. A. and Pawar, A. Y. (2013) 'Access related complications during anterior exposure of the lumbar spine', *World Journal of Orthopedics*, 4(1), p. 19.

Freeman, C. W., Lazor, J. W., Loevner, L. A. and Nabavizadeh, S. A. (2019) 'Variations of the CNS venous system mimicking pathology: spectrum of imaging findings', *Journal of Neuroimaging*, 29(6), pp. 673-688.

Glantzbeck, M. P., Bono, C. M., Wood, K. B. and Harris, M. B. (2009) 'Thromboembolic disease in spinal surgery: a systematic review', *Spine*, 34(3), pp. 291-303.

Guérin, P., Obeid, I., Gille, O., Bourghli, A., Luc, S., Pointillart, V., Cursolle, J. C. and Vital, J.-M. (2011) 'Safe working zones using the minimally invasive lateral retroperitoneal transpoas approach: a morphometric study', *Surgical and Radiologic Anatomy*, 33(8), pp. 665-671.

Gumbs, A. A., Shah, R. V., Yue, J. J. and Sumpio, B. (2005) 'The open anterior paramedian retroperitoneal approach for spine procedures', *Archives of Surgery*, 140(4), pp. 339-343.

Hamabe, A., Harino, T., Ogino, T., Tanida, T., Noura, S., Morita, S. and Dono, K. (2020) 'Analysis of anatomical variations of intrapelvic vessels for advanced pelvic surgery', *Biomedical Central Surgery*, 20(1), pp. 1-7.

Hamdan, A. D., Malek, J. Y., Schermerhorn, M. L., Aulivola, B., Blattman, S. B. and Pomposelli Jr, F. B. (2008) 'Vascular injury during anterior exposure of the spine', *Journal of Vascular Surgery*, 48(3), pp. 650-654.

Hamid, M., Toussaint, P., Delmas, V., Gillot, C., Coutaux, A. and Plaisant, O. (2007) 'Anatomical and radiological evidence for the iliolumbar vein as an inferior lumbar venous system', *Clinical Anatomy*, 20(5), pp. 545-552.

Haviarova, Z., Weismann, P., Stvrtinova, V. and Benuska, J. (1999) 'The determination of the collagen and elastin amount in the human varicose vein by the computer morphometric method', *General Physiology and Biophysics*, 18, pp. 30-33.

Holt, R. T., Majd, M. E., Vadhva, M. and Castro, F. P. (2003) 'The efficacy of anterior spine exposure by an orthopedic surgeon', *Clinical Spine Surgery*, 16(5), pp. 477-486.

Hrabalek, L., Adamus, M., Gryga, A., Wanek, T. and Tucek, P. (2014) 'A comparison of complication rate between anterior and lateral approaches to the lumbar spine', *Biomedical Papers*, 158(1), pp. 127-132.

- Hrabalek, L., Adamus, M., Wanek, T., Machac, J. and Tucek, P. (2012) 'Surgical complications of the anterior approach to the L5/S1 intervertebral disc', *Biomedical Papers*, 156(4), pp. 354-358.
- Ikard, R. W. (2006) 'Methods and complications of anterior exposure of the thoracic and lumbar spine', *Archives of Surgery*, 141(10), pp. 1025-1034.
- Inamasu, J. and Guiot, B. (2006) 'Vascular injury and complication in neurosurgical spine surgery', *Acta Neurochirurgica*, 148(4), pp. 375-387.
- Jasani, V. and Jaffray, D. (2002) 'The anatomy of the iliolumbar vein: a cadaver study', *The Journal of Bone and Joint Surgery. British volume*, 84(7), pp. 1046-1049.
- Jemmett, R., Macdonald, D. and Agur, A. (2004) 'Anatomical relationships between selected segmental muscles of the lumbar spine in the context of multi-planar segmental motion: a preliminary investigation', *Manual Therapy*, 9(4), pp. 203-210.
- Kachlik, D., Pechacek, V., Musil, V. and Baca, V. (2010) 'The venous system of the pelvis: new nomenclature', *Phlebology*, 25(4), pp. 162-173.
- Kang, B.-U., Lee, S.-H., Jeon, S.-H., Park, J. D., Maeng, D. H., Choi, Y. G. and Tsang, Y.-S. (2006) 'An evaluation of vascular anatomy for minilaparotomic anterior L4–5 procedures', *Journal of Neurosurgery: Spine*, 5(6), pp. 508-513.
- Kazlouskaya, V., Malhotra, S., Lambe, J., Idriss, M. H., Elston, D. and Andres, C. (2013) 'The utility of elastic Verhoeff-Van Gieson staining in dermatopathology', *Journal of Cutaneous Pathology*, 40(2), pp. 211-225.
- Khamanarong, K., Sae-Jung, S., Supa-Adirek, C., Teerakul, S. and Prachaney, P. (2009) 'Aortic bifurcation: a cadaveric study of its relationship to the spine', *Medical Journal of the Medical Association of Thailand*, 92(1), p. 47.
- Kim, D. H., Vaccaro, A., Dickman, C. A., Cho, D., Lee, S. K. and Kim, I. (2013) *Surgical Anatomy and Techniques to the Spine E-Book*. Elsevier Health Sciences.

Kiray, A., Akcali, O., Guvencer, M., Tetik, S. and Alici, E. (2004) 'Iliolumbar veins have a high frequency of variations', *Clinical Orthopaedics and Related Research*®, 425, pp. 252-257.

Kirchmair, L., Lirk, P., Colvin, J., Mitterschiffthaler, G. and Moriggl, B. (2008) 'Lumbar plexus and psoas major muscle: not always as expected', *Regional Anesthesia & Pain Medicine*, 33(2), pp. 109-114.

Klezl, Z., Swamy, G. N., Vyskocil, T., Kryl, J. and Stulik, J. (2014) 'Incidence of vascular complications arising from anterior spinal surgery in the thoraco-lumbar spine', *Asian Spine Journal*, 8(1), p. 59.

Kostov, S., Kornovski, Y., Slavchev, S., Ivanova, Y., Dzhenkov, D., Dimitrov, N. and Yordanov, A. (2021) 'Pelvic Lymphadenectomy in Gynecologic Oncology—Significance of Anatomical Variations', *Diagnostics*, 11(1), p. 89.

Kumka, M. (2010) 'Critical sites of entrapment of the posterior division of the obturator nerve: anatomical considerations', *The Journal of the Canadian Chiropractic Association*, 54(1), p. 33.

Kunakornsawat, S., Prasaritha, T., Korbsook, P., Vannaprasert, N., Tungsiripat, R. and Tansatit, T. (2012) 'Variations of the iliolumbar and ascending lumbar veins', *Clinical Spine Surgery*, 25(8), pp. 433-436.

Lai, M. and Lü, B. (2012) 'Tissue Preparation for Microscopy and Histology'.

Landini, G. (2020) 'Threshold color', October 2020. Available at:

<https://blog.bham.ac.uk/intellimic/g-landini-software/>.

Latimer, C. A., Nelson, M., Moore, C. M. and Martin, K. E. (2014) 'Effect of collagen and elastin content on the burst pressure of human blood vessel seals formed with a bipolar tissue sealing system', *Journal of Surgical Research*, 186(1), pp. 73-80.

Lawrence, I. and Lin, K. (1989) 'A concordance correlation coefficient to evaluate reproducibility', *Biometrics*, pp. 255-268.

- Le, T. V., Burkett, C. J., Deukmedjian, A. R. and Uribe, J. S. (2013) 'Postoperative lumbar plexus injury after lumbar retroperitoneal transpsoas minimally invasive lateral interbody fusion', *Spine*, 38(1), pp. E13-E20.
- Li, W. (2018) 'Biomechanical property and modelling of venous wall', *Progress in Biophysics and Molecular Biology*, 133, pp. 56-75.
- Lim, C. and Davies, A. (2009) 'Pathogenesis of primary varicose veins', *British Journal of Surgery*, 96(11), pp. 1231-1242.
- Liu, Y. (2012) 'Analysis of vascular injury in lumbar spine surgery', *Pakistan Journal of Medical Sciences*, 28(5), pp. 791-794.
- Lolis, E., Panagouli, E. and Venieratos, D. (2011) 'Study of the ascending lumbar and iliolumbar veins: surgical anatomy, clinical implications and review of the literature', *Annals of Anatomy-Anatomischer Anzeiger*, 193(6), pp. 516-529.
- Mahan, M. A., Sanders, L. E., Guan, J., Dailey, A. T., Taylor, W. and Morton, D. A. (2017) 'Anatomy of psoas muscle innervation: cadaveric study', *Clinical Anatomy*, 30(4), pp. 479-486.
- Maloor, P., Nayak, S. B., Reghunathan, D., Shetty, S. and Prabhu, G. (2017) 'Multiple variations of azygos system of veins: a case report', *Journal of Morphological Sciences*, 34(1), pp. 7-9.
- Manunga, J., Alcala, C., Smith, J., Mirza, A., Titus, J., Skeik, N., Senthil, J., Stephenson, E., Alexander, J. and Sullivan, T. (2020) 'Technical approach, outcomes, and exposure-related complications in patients undergoing anterior lumbar interbody fusion', *Journal of Vascular Surgery*.
- Matejčík, V. (2010) 'Anatomical variations of lumbosacral plexus', *Surgical and Radiologic Anatomy*, 32(4), pp. 409-414.
- Max, R., Cameron, A. and Hanna, R. (2013) 'Human Height', *Our World In Data*.
- McMonagle, M. and Stephenson, M. (2014) *Vascular and Endovascular Surgery at a Glance*. Wiley.

- Medalie, D. A., Llull, R. and Heckler, F. (2011) 'The iliacus muscle flap: an anatomical and clinical evaluation', *Plastic and Reconstructive Surgery*, 127(4), pp. 1553-1560.
- Mescher, A. L. and Junqueira, L. C. U. (2013) *Junqueira's Basic Histology: Text and Atlas*. McGraw-Hill Medical.
- Mirilas, P. and Skandalakis, J. E. (2010) 'Surgical anatomy of the retroperitoneal spaces, part IV: retroperitoneal nerves', *The American Surgeon*, 76(3), pp. 253-262.
- Mobbs, R. J., Phan, K., Daly, D., Rao, P. J. and Lennox, A. (2016) 'Approach-related complications of anterior lumbar interbody fusion: results of a combined spine and vascular surgical team', *Global Spine Journal*, 6(2), pp. 147-154.
- Moore, K. L., Agur, A. M. R. and Dalley, A. F. (2018) *Clinically Oriented Anatomy*. Wolters Kluwer.
- Morita, S., Kimura, T., Masukawa, A., Saito, N., Suzuki, K. and Mitsunashi, N. (2007) 'Flow direction of ascending lumbar veins on magnetic resonance angiography and venography: would "descending lumbar veins" be a more precise name physiologically?', *Abdominal Imaging*, 32(6), pp. 749-753.
- Moro, T., Kikuchi, S.-i., Konno, S.-i. and Yaginuma, H. (2003) 'An anatomic study of the lumbar plexus with respect to retroperitoneal endoscopic surgery', *Spine*, 28(5), pp. 423-427.
- Nalbandian, M. M., Hoashi, J. S. and Errico, T. J. (2013) 'Variations in the iliolumbar vein during the anterior approach for spinal procedures', *Spine*, 38(8), pp. E445-E450.
- Naoum, J. J., Hunter, G. C., Woodside, K. J. and Chen, C. (2007) 'Current advances in the pathogenesis of varicose veins', *Journal of Surgical Research*, 141(2), pp. 311-316.
- Nayak, S. B. (2018) 'Dangerous twisted communications between external and internal iliac veins which might rupture during catheterization', *Anatomy & Cell Biology*, 51(4), p. 309.
- Nguyen, H.-V., Akbarnia, B. A., van Dam, B. E., Raiszadeh, K., Bagheri, R., Canale, S., Sylvain, G. M., Barone, R. and Bench, G. (2006) 'Anterior exposure of the spine for removal of lumbar interbody devices and implants', *Spine*, 31(21), pp. 2449-2453.

Nourian, A. A., Cunningham, C. M., Bagheri, A., Bruffey, J. D. and Eastlack, R. K. (2016) 'Effect of anatomic variability and level of approach on perioperative vascular complications with anterior lumbar interbody fusion', *Spine*, 41(2), pp. E73-E77.

Oklu, R., Habito, R., Mayr, M., Deipolyi, A. R., Albadawi, H., Hesketh, R., Walker, T. G., Linskey, K. R., Long, C. A. and Wicky, S. (2012) 'Pathogenesis of varicose veins', *Journal of Vascular and Interventional Radiology*, 23(1), pp. 33-39.

Oskouian, R. J. and Johnson, J. P. (2002) 'Vascular complications in anterior thoracolumbar spinal reconstruction', *Journal of Neurosurgery: Spine*, 96(1), pp. 1-5.

Ovalle, W. K. and Nahirney, P. C. (2013) *Netter's Essential Histology: with Student Consult Access*. Elsevier Health Sciences.

Park, J.-A., Lee, S.-H., Koh, K.-S. and Song, W.-C. (2020) 'Femoral nerve split with variant iliacus muscle: a potential source of femoral nerve entrapment', *Surgical and Radiologic Anatomy*, 42, pp. 1255-1257.

Pelletier, Y., Lareyre, F., Cointat, C. and Raffort, J. (2021) 'Management of vascular complications during anterior lumbar spinal surgery using mini-open retroperitoneal approach', *Annals of Vascular Surgery*.

Penning, L. (2000) 'Psoas muscle and lumbar spine stability: a concept uniting existing controversies', *European Spine Journal*, 9(6), pp. 577-585.

Phan, K., Xu, J., Scherman, D. B., Rao, P. J. and Mobbs, R. J. (2017) 'Anterior lumbar interbody fusion with and without an “access surgeon”: a systematic review and meta-analysis', *Spine*, 42(10), pp. E592-E601.

Pinson, H., Hallaert, G., Herregodts, P., Everaert, K., Couvreur, T., Caemaert, J., Kalala, J.-P. and Van Roost, D. (2017) 'Outcome of anterior lumbar interbody fusion: a retrospective study of clinical and radiologic parameters', *World Neurosurgery*, 103, pp. 772-779.

Planner, A., Donaghy, M. and Moore, N. (2006) 'Causes of lumbosacral plexopathy', *Clinical Radiology*, 61(12), pp. 987-995.

Platzer, P., Thalhammer, G., Jaindl, M., Obradovic, A., Benesch, T., Vecsei, V. and Gaebler, C. (2006) 'Thromboembolic complications after spinal surgery in trauma patients', *Acta Orthopaedica*, 77(5), pp. 755-760.

Rajaraman, V., Vingan, R., Roth, P., Heary, R. F., Conklin, L. and Jacobs, G. B. (1999) 'Visceral and vascular complications resulting from anterior lumbar interbody fusion', *Journal of Neurosurgery: Spine*, 91(1), pp. 60-64.

Rangan, G. K. and Tesch, G. H. (2007) 'Quantification of renal pathology by image analysis (Methods in Renal Research)', *Nephrology*, 12(6), pp. 553-558.

Razali, N. M. and Wah, Y. B. (2011) 'Power comparisons of shapiro-wilk, kolmogorov-smirnov, lilliefors and anderson-darling tests', *Journal of Statistical Modeling and Analytics*, 2(1), pp. 21-33.

Regenbogen, S. E., Greenberg, C. C., Studdert, D. M., Lipsitz, S. R., Zinner, M. J. and Gawande, A. A. (2007) 'Patterns of technical error among surgical malpractice claims: an analysis of strategies to prevent injury to surgical patients', *Annals of surgery*, 246(5), pp. 705-711.

Reilly, E. F., Weger, N. S. and Stawicki, S. P. (2017) 'Vascular injury during spinal surgery', *International Journal of Academic Medicine*, 3(3), p. 39.

Rhee, J., Boden, S. D. and Wiesel, S. W. (2015) *Operative Techniques in Spine Surgery*. Wolters Kluwer Health.

Ross, M. H. and Pawlina, W. (2016) *Histology: A Text and Atlas : with Correlated Cell and Molecular Biology*. Wolters Kluwer Health.

Sajko, S. and Stuber, K. (2009) 'Psoas Major: a case report and review of its anatomy, biomechanics, and clinical implications', *The Journal of the Canadian Chiropractic Association*, 53(4), p. 311.

Santos, E. R., Pinto, M. R., Lonstein, J. E., Denis, F., Garvey, T. A., Perra, J. H., Transfeldt, E. E. and Schwender, J. D. (2008) 'Revision lumbar arthrodesis for the treatment of lumbar cage pseudoarthrosis: complications', *Clinical Spine Surgery*, 21(6), pp. 418-421.

Sañudo, J., Vázquez, R. and Puerta, J. (2021) 'Meaning and clinical interest of the anatomical variations in the 21 st century', *European Journal of Anatomy*, 7(S1), pp. 1-3.

Satti, S., Cerniglia, C. and Koenigsberg, R. (2007) 'Cervical vertebral artery variations: an anatomic study', *American Journal of Neuroradiology*, 28(5), pp. 976-980.

Scaduto, A. A., Gamradt, S. C., Warren, D. Y., Huang, J., Delamarter, R. B. and Wang, J. C. (2003) 'Perioperative complications of threaded cylindrical lumbar interbody fusion devices: anterior versus posterior approach', *Clinical Spine Surgery*, 16(6), pp. 502-507.

Schindelin, J., Arganda-Carreras, I., Frise, E., Kaynig, V., Longair, M., Pietzsch, T., Preibisch, S., Rueden, C., Saalfeld, S. and Schmid, B. (2012) 'Fiji: an open-source platform for biological-image analysis', *Nature Methods*, 9(7), pp. 676-682.

Schmidt, C. K., Iwanaga, J., Yilmaz, E., Wilson, C., Oskouian, R. J. and Tubbs, R. S. (2017) 'Absence of the lumbosacral trunk', *Cureus*, 9(10).

Schwartz, S. I., Brunickardi, F. C., Andersen, D., Hunter, J., Dunn, D., Pollock, R. E. and Matthews, J. (2010) *Schwartz's Principles of Surgery, Ninth Edition*. McGraw-Hill Education.

Schwender, J. D., Casnellie, M. T., Perra, J. H., Transfeldt, E. E., Pinto, M. R., Denis, F., Garvey, T. A., Polly, D. W., Mehbod, A. A. and Dykes, D. C. (2009) 'Perioperative complications in revision anterior lumbar spine surgery: incidence and risk factors', *Spine*, 34(1), pp. 87-90.

Sheng, L., Xu, Y.-q., Ding, Z.-h., Wang, Y.-l., Shi, J.-h. and Zhong, S.-z. (2008) 'Clinical anatomic study of the lower lumbar anterolateral vein: with respect to retroperitoneal endoscopic surgery', *Chinese Journal of Traumatology (English Edition)*, 11(2), pp. 110-113.

Shin, M., Lee, J. B., Park, S. B., Park, H. J. and Kim, Y. S. (2015) 'Multidetector computed tomography of iliac vein variation: prevalence and classification', *Surgical and Radiologic Anatomy*, 37(3), pp. 303-309.

Shoja, M. M., Tubbs, R., Khaki, A., Shokouhi, G., Farahani, R. and Moein, A. (2006) 'A rare variation of the vertebral artery', *Folia Morphologica*, 65(2), pp. 167-170.

Sidawy, A. N. and Perler, B. A. (2018) *Rutherford's Vascular Surgery and Endovascular Therapy, E-Book*. Elsevier Health Sciences.

Sikka, A. and Jain, A. (2012) 'Bilateral variation in the origin and course of the vertebral artery', *Anatomy Research International*, 2012.

Silver, F. H., Snowhill, P. B. and Foran, D. J. (2003) 'Mechanical behavior of vessel wall: a comparative study of aorta, vena cava, and carotid artery', *Annals of Biomedical Engineering*, 31(7), pp. 793-803.

Sim, I. and Webb, T. (2004) 'Anatomy and anaesthesia of the lumbar somatic plexus', *Anaesthesia and Intensive Care*, 32(2), pp. 178-187.

Sivakumar, G., Paluzzi, A. and Freeman, B. (2007) 'Avulsion of ascending lumbar and iliolumbar veins in anterior spinal surgery: an anatomical study', *Clinical Anatomy*, 20(5), pp. 553-555.

Smith, T. J., Bauer, A. T., Kallies, K. J., Al-Hamadani, M. and Gundersen, S. (2017) 'Outcomes of anterior exposure for spinal surgery at an independent Academic Medical Center', *Wisconsin Medical Journal*, 116(1), pp. 15-21.

Splith, K., Fellmer, P., Matia, I., Varga, M., Oliverius, M., Kuhn, S., Feldbrügge, L., Krenzien, F., Hau, H.-M. and Wiltberger, G. (2014) 'Antibody-mediated rejection of arterialised venous allografts is inhibited by immunosuppression in rats', *Plos One*, 9(3), p. e91212.

Standring, S. (2015) *Gray's Anatomy E-Book: The Anatomical Basis of Clinical Practice*. Elsevier Health Sciences.

Statistics South Africa (2016) *Community Survey, Statistics release*. Available at: www.statssa.gov.za (Accessed: 10 February).

Straus, W. L. and Temkin, O. (1943) 'Vesalius and the problem of variability', *Bulletin of the History of Medicine*, 14(5), pp. 609-633.

- Suvik, A. and Effendy, A. (2012) 'The use of modified Masson's trichrome staining in collagen evaluation in wound healing study', *Malaysian Journal of Veterinary Research*, 3(1), pp. 39-47.
- Tanida, S., Fujibayashi, S., Otsuki, B., Masamoto, K. and Matsuda, S. (2017) 'Influence of spinopelvic alignment and morphology on deviation in the course of the psoas major muscle', *Journal of Orthopaedic Science*, 22(6), pp. 1001-1008.
- Tatu, L., Parratte, B., Vuillier, F., Diop, M. and Monnier, G. (2002) 'Descriptive anatomy of the femoral portion of the iliopsoas muscle. Anatomical basis of anterior snapping of the hip', *Surgical and Radiologic Anatomy*, 23(6), pp. 371-374.
- Teli, C. G., Kate, N. N. and Kothandaraman, U. (2013) 'Morphometry of the iliolumbar artery and the iliolumbar veins and their correlations with the lumbosacral trunk and the obturator nerve', *Journal of Clinical and Diagnostic Research*, 7(3), p. 422.
- Terayama, H., Yi, S.-Q., Shoji, S., Tanaka, O., Kanazawa, T., Kosemura, N., Tamura, M., Sekiguchi, M., Naito, M. and Akamatsu, T. (2015) 'Anomalous connection of the left posterior renal vein with the left ascending lumbar vein in a Japanese cadaver', *Folia Morphologica*, 74(4), pp. 544-547.
- Tibrewal, S. (2006) 'The anatomy knowledge of surgical trainees: the trainer's view', *The Bulletin of the Royal College of Surgeons of England*, 88(7), pp. 240-242.
- Tribus, C. B. and Belanger, T. (2001) 'The vascular anatomy anterior to the L5-S1 disk space', *Spine*, 26(11), pp. 1205-1208.
- Tubbs, R. S., Salter, E. G., Wellons, J. C., Blount, J. P. and Oakes, W. J. (2005) 'Anatomical landmarks for the lumbar plexus on the posterior abdominal wall', *Journal of Neurosurgery: Spine*, 2(3), pp. 335-338.
- Tung, T. H., Martin, D. Z., Novak, C. B., Lauryssen, C. and Mackinnon, S. E. (2005) 'Nerve reconstruction in lumbosacral plexopathy: case report and review of the literature', *Journal of Neurosurgery: Pediatrics*, 102(1), pp. 86-91.

- Uhl, J.-F., Gillot, C. and Chahim, M. (2010) 'Anatomical variations of the femoral vein', *Journal of Vascular Surgery*, 52(3), pp. 714-719.
- Unat, F., Sirinturk, S., Cagimni, P., Pinar, Y., Govsa, F. and Chatzioglou, G. N. (2019) 'Macroscopic observations of muscular bundles of accessory iliopsoas muscle as the cause of femoral nerve compression', *Journal of Orthopaedics*, 16(1), pp. 64-68.
- Unruh, K. P., Camp, C. L., Zietlow, S. P. and Huddleston III, P. M. (2008) 'Anatomical variations of the iliolumbar vein with application to the anterior retroperitoneal approach to the lumbar spine: a cadaver study', *Clinical Anatomy*, 21(7), pp. 666-673.
- Uribe, J. S., Arredondo, N., Dakwar, E. and Vale, F. L. (2010) 'Defining the safe working zones using the minimally invasive lateral retroperitoneal transpsoas approach: an anatomical study', *Journal of Neurosurgery: Spine*, 13(2), pp. 260-266.
- Valdez-Jasso, D., Haider, M. A., Banks, H., Santana, D. B., German, Y. Z., Armentano, R. L. and Olufsen, M. S. (2008) 'Analysis of viscoelastic wall properties in ovine arteries', *Transactions on Biomedical Engineering*, 56(2), pp. 210-219.
- Venieratos, D., Panagouli, E. and Lolis, E. (2012) 'Variations of the iliac and pelvic venous systems with special attention to the drainage patterns of the ascending lumbar and iliolumbar veins', *Annals of Anatomy-Anatomischer Anzeiger*, 194(4), pp. 396-403.
- Vidal, V., Monnet, O., Jacquier, A., Bartoli, J.-M. and Tropiano, P. (2010) 'Accessory iliac vein: surgical implications', *Clinical Spine Surgery*, 23(6), pp. 398-403.
- Vilensky, J. A. and Carmichael, S. W. (2010) 'The compendium of anatomical variants: New goals and format'. Wiley Online Library.
- Vvali, M. and Ra, E. (2002) 'Changes of elastic and collagen fibers in varicose veins', *International Angiology*, 21, pp. 337-43.
- Waikakul, S., Chandraphak, S. and Sangthongsil, P. (2010) 'Anatomy of L4 to S3 nerve roots', *Journal of Orthopaedic Surgery*, 18(3), pp. 352-355.
- Wali, M. A. and Eid, R. A. (2002) 'Intimal changes in varicose veins: an ultrastructural study', *Journal of Smooth Muscle Research*, 38(3), pp. 63-74.

- Warner, T. and Tubbs, R. S. (2020) 'Lumbar Plexus', in *Surgical Anatomy of the Lateral Transposas Approach to the Lumbar Spine*. Elsevier, pp. 45-81.
- Weiner, B. K., Walker, M. and Fraser, R. D. (2001) 'Vascular anatomy anterior to lumbosacral transitional vertebrae and implications for anterior lumbar interbody fusion', *The Spine Journal*, 1(6), pp. 442-444.
- Wind, G. G. and Valentine, R. J. (2013) *Anatomic exposures in vascular surgery*. Lippincott Williams & Wilkins.
- Winder, M. J. and Gambhir, S. (2016) 'Comparison of ALIF vs. XLIF for L4/5 interbody fusion: pros, cons, and literature review', *Journal of Spine Surgery*, 2(1), p. 2.
- Wood, K. B., DeVine, J., Fischer, D., Dettori, J. R. and Janssen, M. (2010) 'Vascular injury in elective anterior lumbosacral surgery', *Spine*, 35(9S), pp. S66-S75.
- Woods, K. R., Billys, J. B. and Hynes, R. A. (2017) 'Technical description of oblique lateral interbody fusion at L1–L5 (OLIF25) and at L5–S1 (OLIF51) and evaluation of complication and fusion rates', *The Spine Journal*, 17(4), pp. 545-553.
- World Data (2021) *Average sizes for men and women*. Available at: <https://www.worlddata.info/average-bodyheight.php> (Accessed: 10 february 2021).
- Xu, D. S., Walker, C. T., Godzik, J., Turner, J. D., Smith, W. and Uribe, J. S. (2018) 'Minimally invasive anterior, lateral, and oblique lumbar interbody fusion: a literature review', *Annals of Translational Medicine*, 6(6).
- Yammine, K. (2014) 'Evidence-based anatomy', *Clinical Anatomy*, 27(6), pp. 847-852.
- Zahradnik, V. and Kashyap, V. S. (2012) 'Alternative management of iliac vein injury during anterior lumbar spine exposure', *Annals of Vascular Surgery*, 26(2), pp. 277. e15-277. e18.
- Zairi, F., Sunna, T., Westwick, H., Weil, A., Wang, Z., Boubez, G. and Shedid, D. (2017) 'Mini-open oblique lumbar interbody fusion (OLIF) approach for multi-level discectomy and fusion involving L5–S1: Preliminary experience', *Orthopaedics & Traumatology: Surgery & Research*, 103(2), pp. 295-299.

Zócalo, Y., Bia, D., Cabrera-Fischer, E. I., Wray, S., Galli, C. and Armentano, R. L. (2013) 'Structural and functional properties of venous wall: relationship between elastin, collagen, and smooth muscle components and viscoelastic properties', *International Scholarly Research Notices*, 2013.

Appendix 1: Histological tissue processing and staining.

A. Tissue processing

The tissues were processed using an automatic tissue processor (Shandon citadel 1000) as follows:

Step	Solution	Duration in solution	Time
1	10% buffered formalin	4 Hours	11 am – 3 pm
2	70% alcohol for	1 Hour	3 pm – 4 pm
3	95% alcohol	2 Hours	4 pm – 6 pm
4	95% alcohol	1 ^{1/2} Hours	6 pm – 7:30 pm
5	95% alcohol	1 ^{1/2} Hours	7:30 pm – 9 pm
6	100% alcohol	1 hour	9 pm – 10 pm
7	100% alcohol	2 Hours	10 pm – 12:00
8	100% alcohol	1 Hour	12:00 – 1 am
9	Chloroform	1 Hour	1 am – 2 am
10	Chloroform	2 Hours	2 am – 4 am
11	Wax	2 Hours	4 am – 6 am
12	Wax	2 Hours	6 am – 8 am

Paraffin embedding

1. Warm the wax as well as the metal moulds and a pair of forceps, making sure that the temperature does not exceed 60°C.
2. Once the wax has melted, fill the metal mould with wax.
3. Cool briefly, and then cover with the plastic cassette accordingly.
4. Quickly top up with more melted wax and cool for approximately 20 minutes.
5. Separate the metal mould from the plastic cassette.

B. Hematoxylin and Eosin staining

Hydration

1. Dewax in xylene for 10 minutes.
2. Dewax in xylene for 10 minutes.

3. Immerse in 100% alcohol for 10 dips.
4. Immerse in 100% alcohol for 10 dips.
5. Immerse in 95% alcohol for 10 dips.
6. Wash in distilled water for 5 minutes.

Nuclear staining

1. Stain with Meyer's hematoxylin for 10 minutes.
2. Wash in running tap water for 5 minutes.
3. Differentiate in 1% acid alcohol - 5 dips.
4. Wash in running tap water for 5 minutes.
5. Blue in Scott's tap water for 5 minutes.
6. Wash in running tap water for 5 minutes.

Cytoplasm staining

1. Stain in eosin for 2 minutes.
2. Wash in running tap water - 3 dips.

Dehydration and mounting

1. Immerse in 70% alcohol - 10 dips.
2. Immerse in 95% alcohol - 10 dips.
3. Immerse in 100% alcohol - 10 dips.
4. Immerse in 100% alcohol - 10 dips.
5. Clear in xylene - 10 dips.
6. Clear in xylene - 10 dips.
7. Mount in Entellen.

C. Staining for elastic fibres (Modified Verhoeff's stain (Deran Reddy))

1. Deparaffinize and hydrate sections to water.
2. Stain in modified Verhoeff working elastic solution at room temperature for 7 minutes (or in a 60 °C oven for 3 ½ minutes).

To prepare modified Verhoeff working elastic solution, mix 3 parts alcoholic hematoxylin 3%, 2 parts ferric chloride 2% aqueous, and 1 part Lugol's iodine

3. Wash in tap water for 1 minute.
4. Differentiate in Ferric Chloride solution, 0.4% aqueous for 75 seconds, check differentiation microscopically for black fibres on a grey background.
5. Wash in running tap water for 5 minutes.
6. Counterstain in Van Gieson solution for 1 minute.
7. Blot dry and clear in 100% alcohol, two changes of xylene, and mount with Entellen.

Results

Elastic fibres = Black/ brown

Collage fibres = Red

Smooth muscles = Yellow

D. Staining for collagen fibres (Masson's trichrome stain)

1. Deparaffinize sections and bring to water.
2. Wash in running tap water for 5 minutes.
3. Stain nuclei with Celestine blue- hematoxylin method:
Stain in Celestine blue solution for 5 minutes
Rinse in distilled water - 10 dips
Stain with Alum hematoxylin for 5 minutes
Wash in water until blue for about 10 minutes.
4. Differentiate with 1% acid alcohol 10 quick dips.
5. Wash well in tap water for 5 minutes.
6. Stain in Acid Fuchsin solution for 5 minutes.
7. Rinse in distilled water.
8. Treat with Phosphomolybdic acid solution for 2 minutes.
9. Drain.
10. Stain with light green for 5 minutes.
11. Rinse in distilled water.
12. Treat with 1% Acetic acid in distilled water - 10 dips.
13. Treat with 1% Acetic acid in absolute alcohol - 10 dips.
14. Dehydrate through alcohols, clear and mount.

Results:

Nuclei = Blue black

Cytoplasm, muscle, fibrin, and erythrocytes = Red

Collagen = Blue/green

Appendix 2: Cadaveric data collection tool

- a) ID number: _____ b) Sex: _____
 b) Age at death: _____ d) Race: _____

1. Presence of iliolumbar veins (YES / NO)

Iliolumbar vein (ILV)	Left	Right
Present		

2. Iliolumbar trunk or main stem and position (lateral or posterior) (tick for present)

	ALV	Proximal ILV	Distal ILV	ALV-ILV	Any other ILV	Total present number
Left						
Right						

3. Terminal drainage point for the iliolumbar vein (IVC, CIV, EIV, IIV)

	ALV	Proximal ILV	Distal ILV	ALV-ILV	Any other ILV
Left					
Right					

4. Classification of iliolumbar veins (Unruh Type 1, 2, or 3)

Side	Type	Description (ALV-ILV and more, ALV-ILV only, All separate)
Left		
Right		

5. Number of tributaries draining into iliolumbar veins (1, 2, 3, 4, 5 or more)

	ALV	Proximal ILV	Distal ILV	ALV-ILV	Any other ILV
Left					
Right					

6. Iliolumbar vein drains (iliac fossa, iliac muscle, psoas major, L5 vertebra)

	ALV	Proximal ILV	Distal ILV	ALV-ILV	Any other ILV
Left					
Right					

7. Iliolumbar vein lies (**A**nterior, **S**uperior, **I**nferior, or **P**osterior) to obturator nerve

	ALV	Proximal ILV	Distal ILV	ALV-ILV	Any other ILV
Left					
Right					

8. Iliolumbar vein lies (**A**nterior, **S**uperior, **I**nferior, or **P**osterior) to lumbosacral trunk

	Left					Right				
LST	ALV	Proximal ILV	Distal ILV	ALV-ILV	Any other ILV	ALV	Proximal ILV	Distal ILV	ALV-ILV	Any other ILV
L4										
L5										
L4&L5										

9. Morphometries of iliolumbar veins (distance to the iliolumbar vein)

	Left					Right				
Length (mm)	ALV	Proximal ILV	Distal ILV	ALV-ILV	Any other ILV	ALV	Proximal ILV	Distal ILV	ALV-ILV	Any other ILV
IVC										
TRUNK										
ON										
LST										

10. Iliolumbar vein lies lateral at the level of (L4, L4/5, L5, L5/S1, S1 and below)

	ALV	Proximal ILV	Distal ILV	ALV-ILV	Any other ILV
Left					
Right					

Any additional comments

Level of the aortic bifurcation

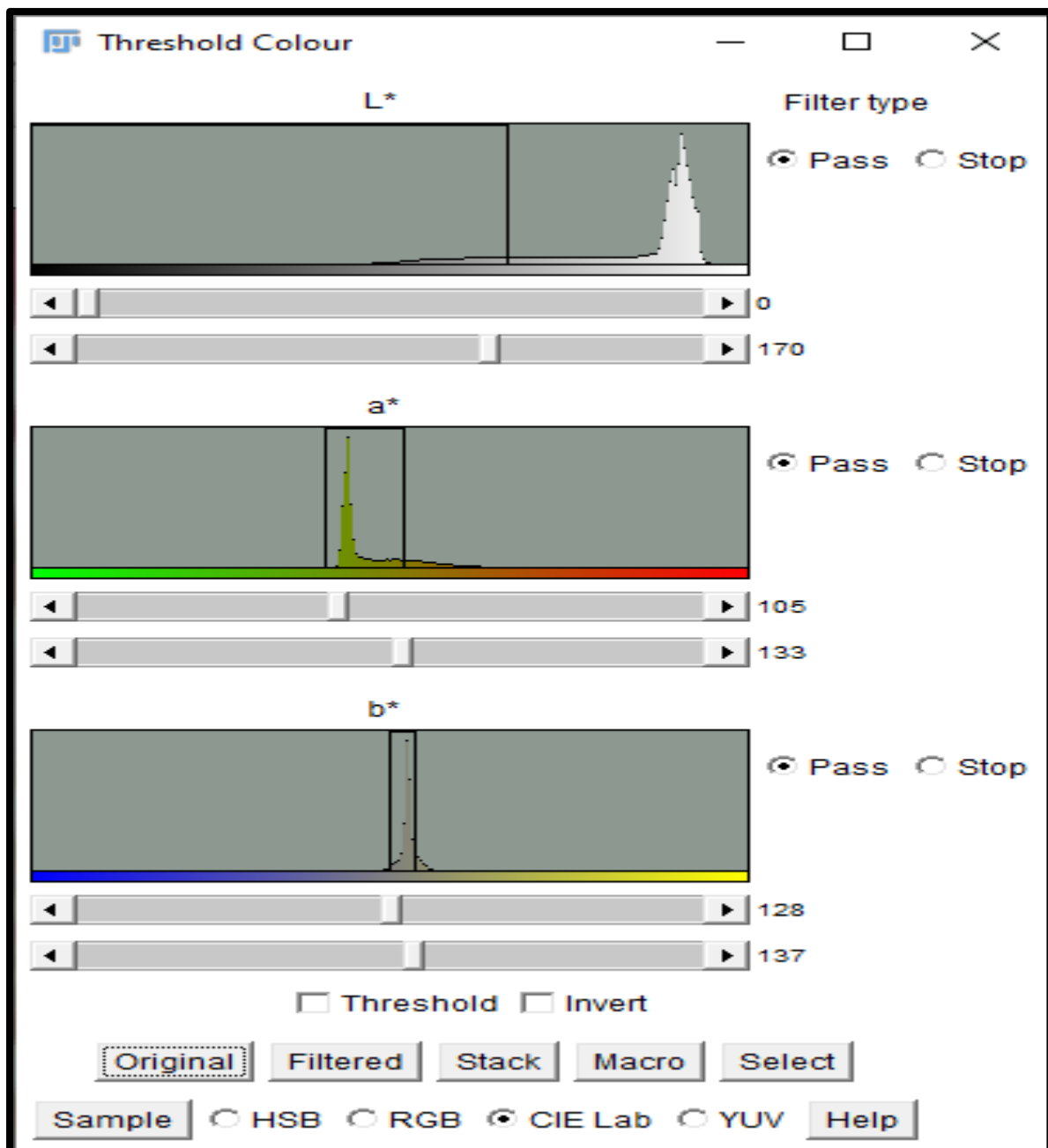
Level of origin of the IVC

Appendix 3: Color area percentage calculations

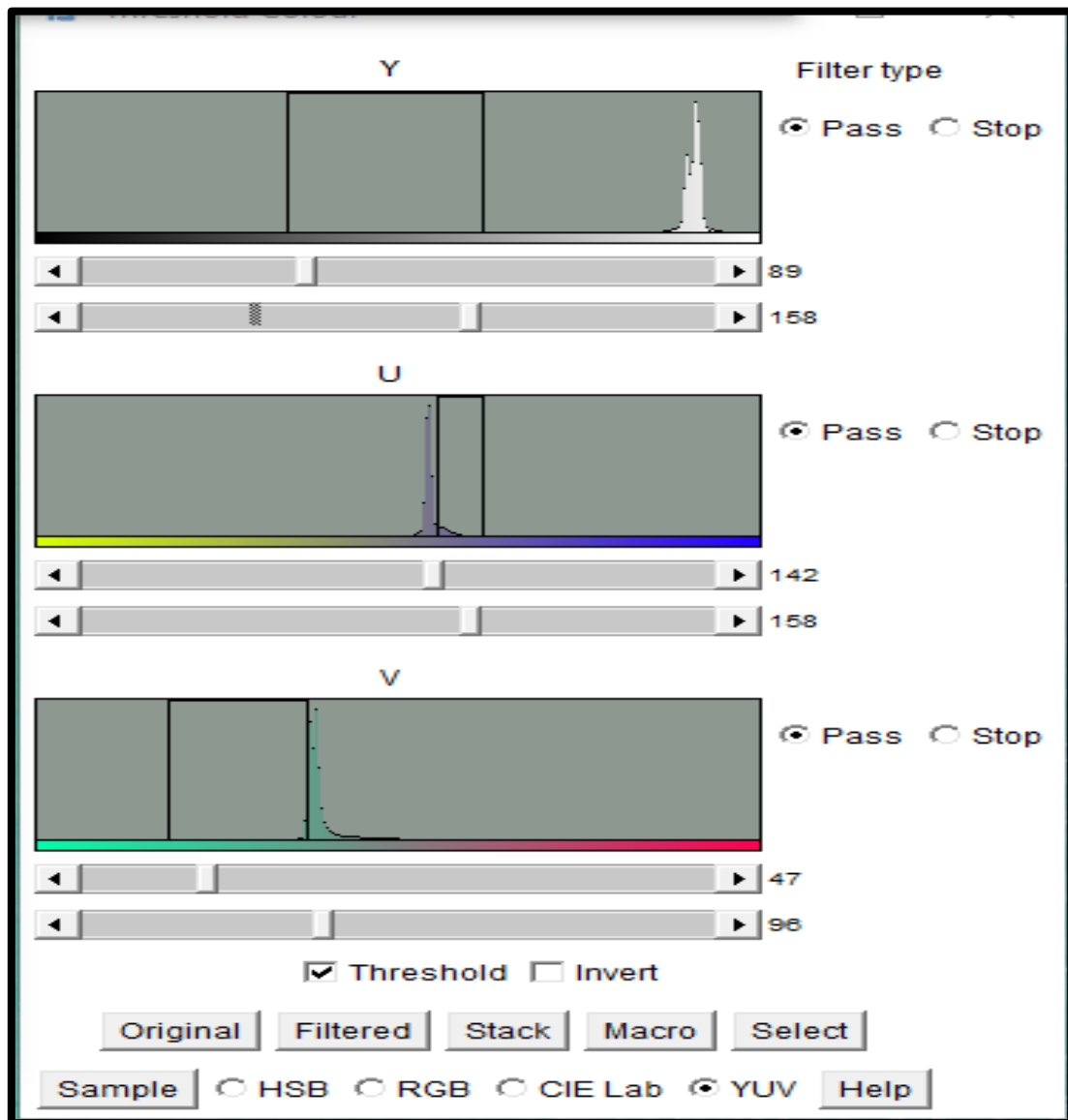
Fiji (Image J 2) has Threshold Color plugins already embedded, and an additional plugin, “Threshold Color” by Landini (2020), was used.

To calculate the area color percentage,

1. Open Image J
2. Set scale bar
3. Open target image
4. Go to Plugins > Threshold color
5. Choose color space > HSB/RGB/YUV based on best settings
6. Use polygon tool and select a ROI (zoom in close)
7. Click sample button-then zoom out
8. Use “Original” or “filtered” toggles to check the thresholding levels
9. Once achieved tick Threshold box
10. Go to Image>Type> 8-Bit
11. Then use polygon tool to highlight the entire ROI
12. Go to Analyze> Analyze particles > tick clear results and summarize
13. Note %Area
14. Repeat for multiple images of the same section and then average the color area %



Color space settings for Elastic fibre area percentage calculations



Color settings for Collagen fibre area percentage calculation.

Appendix 4: Ethical Clearance

School of Anatomical Sciences

University of the Witwatersrand, Johannesburg
7 York Rd, Parktown, 2193, South Africa • Tel: +27 11 717 2713 • Fax: +27 86 589 7863 • www.wits.ac.za



12 April 2021

To whom it may concern

Ethics waiver: W-CBP-210401-01

It is hereby confirmed that the ethics waiver W-CBP-210401-01 (attached) has been granted to Mr. Arthur Tsalani Manjatika, Student Number 2228141, for his research entitled: Topographical and histological evaluation of the iliolumbar veins in a South African population: A cadaveric study.

This waiver is granted for projects on collections housed in the School of Anatomical Sciences.

Kind regards,

A handwritten signature in black ink, appearing to read 'M. Steyn'.

Professor Maryna Steyn
Holder: Ethics waiver

A handwritten signature in black ink, appearing to read 'Lynne Schepartz'.

Prof Lynne Schepartz
Acting Head of School
School of Anatomical Sciences
Faculty of Health Sciences



UNIVERSITY OF THE
WITWATERSRAND,
JOHANNESBURG



HUMAN RESEARCH ETHICS
COMMITTEE (MEDICAL)

Office of the Deputy Vice-Chancellor (Research & Post Graduate Affairs)

TO: Professor M Steyn
School: Anatomical Sciences
Medical School
University

E-mail: Maryna.Steyn@wits.ac.za

CC: Supervisor: <>
and <HREC-Medical.ResearchOffice@wits.ac.za>

FROM: Iain Burns
Human Research Ethics Committee (Medical)
Tel: 011 717 1252

E-mail: Iain.Burns@wits.ac.za

DATE: 01/04/2021

REF: R14/49

PROTOCOL NO: W-CBP-210401-01 (This is your ethics application study reference number.
Please quote this reference number in all correspondence relating to this study)

PROJECT TITLE: *Research on cadaveric material
Research conducted on donated bodies and their tissues
under sections 62-64 under the National Health Act No.61 of 2003
Formerly W-CJ-140604-1*

Please find attached the Ethics Waiver Certificate for the above project. I hope it goes well and that an article in a recognized publication comes out of it. This will reflect well on your professional standing and contribute to the Government funding of the University.

A handwritten signature in black ink, appearing to be 'Iain Burns'.

MSWorks2000/Iain0007/ClearScanWaiver.wps



Office of the Deputy Vice-Chancellor (Research & Post Graduate Affairs)

01/04/2021

Ref: W-CBP-210401-01

TO WHOM IT MAY CONCERN

Waiver: This certifies that the following research does not require clearance from the Human Research Ethics Committee (Medical)

Investigator: Professor M Steyn
Student No. (if appropriate):
Staff No. (if appropriate): A0002304

Supervisor:

School: Anatomical Sciences
Department: Medical School
University

Project title: *Research on cadaveric material
Research conducted on donated bodies and their tissues
under sections 62-64 under the National Health Act No.61 of 2003
Formerly W-CJ-140604-1*

Reason: Statutory waiver
No living human participants will be involved in the study

Dr CB Penny
Chairperson: Human Research Ethics Committee (Medical)

Research Office Secretariat:
Third Floor, Phillip Tobias Building, corner of St Andrews and York Roads, Parktown,
Johannesburg 2193
Postal address: Private Bag 3, Wits 2050
Tel Nos: +27 (0)11 717 1234/1252/2656/2700
Office E-mail: HREC-Medical.ResearchOffice@wits.ac.za
Website:
<https://www.wits.ac.za/research/researcher-support/research-ethics/ethics-committees/>