

## The Treatment of an Unusual Periodontal Lesion — A Case Report

A. Volchansky

C.J. Dreyer

Dental Research Unit of the University of the Witwatersrand and South African Medical Research Council and the Department of Oral Medicine and Periodontology, University of the Witwatersrand.

### SUMMARY:

*This misadventure with a rubber band led to a very unusual clinical situation in which extensive detachment of periodontal tissues occurred in an otherwise healthy young person. The clinical and radiological examinations provided evidence of re-attachment of the gingival tissue and regeneration of the alveolar bone.*

A 13 year old girl was referred to the authors because of mobility of the upper central incisors. Orthodontic treatment had been completed 6 months prior to the referral. Three months after the completion of orthodontic treatment a diastema developed between the maxillary central incisors. As the labial frenum was felt to be causing the splaying a frenectomy was done with electrocautery and the patient was instructed to use elastic bands to approximate the central incisors.

### OPSOMMING:

*Hierdie ongelukkige voorval met die gomlastiek band het tot 'n ongewone kliniese toestand gelei, waar die aangehegting van die periodontale weefsels grootliks vernietig is in 'n andersins gesonde jong persoon. Die kliniese en radiologiese ondersoek het getoon dat daar tekens van heraanhegting van die gingivale weefsels was sowel as regenerasie van die alveolêre been.*

### EXAMINATION

Clinical examination revealed that granulation tissue was present labial and distal to the maxillary central incisors with pus expressible from the distal of the right central. The gingival tissue throughout the remainder of the mouth was healthy. The upper central incisors were labial to the arch and were overerupted with their incisal edges angulated to the occlusal plane. No obvious occlusal interferences were noted between posterior teeth. There was

grade III mobility of the right central and grade II mobility of the left central incisor.

The greatest depth of pocketing approximated the apices of the two central incisors. The affected teeth gave vitality responses within normal range. No abnormalities were detected on physical and haematological examination.

Full mouth radiographic examination was carried out at the time of referral. The radiographs of the maxillary incisor region showed a considerable loss of bone adjacent to the incisors. The degree of periodontal involvement can be seen on the radiographs taken with diagnostic wires inserted into the periodontal pockets (Figs. 1 a & b). No obvious abnormality was detected on the other intraoral radiographs.

The localised inflammatory condition was thought to have resulted from a combination of too-rapid orthodontic movement, traumatism, the effects of electroautery, lack of function and secondary infection.

#### TREATMENT

Initial treatment took the form of grinding the teeth to reduce occlusal trauma and facilitate function. This was followed by gingival curettage. Within one

month clinical improvement was noted with a reduction in mobility and granulation tissue. Soon however, there was regression to the previous state. It was then decided to splint the teeth and perform an exploratory operation. A splint was constructed and cemented. It consisted of a round 040 stainless steel wire soldered to orthodontic bands on the upper incisors and canines.

An inverse - bevel incision was made on the labial aspect of the gingiva from lateral to lateral incisor with two releasing incisions and the tissue was reflected. This revealed denudation of the labial and distal surfaces of the roots of the central incisors and of the mesial surface of the right lateral incisor; and the presence of an elastic band around the apices of the two central incisors. The extent of the loss of bone and the position of the elastic band (Fig. 2) could be assessed only after the granulation tissue had been removed. The elastic band was removed, the affected areas were curetted thoroughly and the root surfaces planed. The flap was replaced and sutured into position and a periodontal dressing was placed over the wound. The post-operative period was uneventful. The splint was left in place for 3 months, during which time occlusal adjustment was carried out and repeated scalings were done.

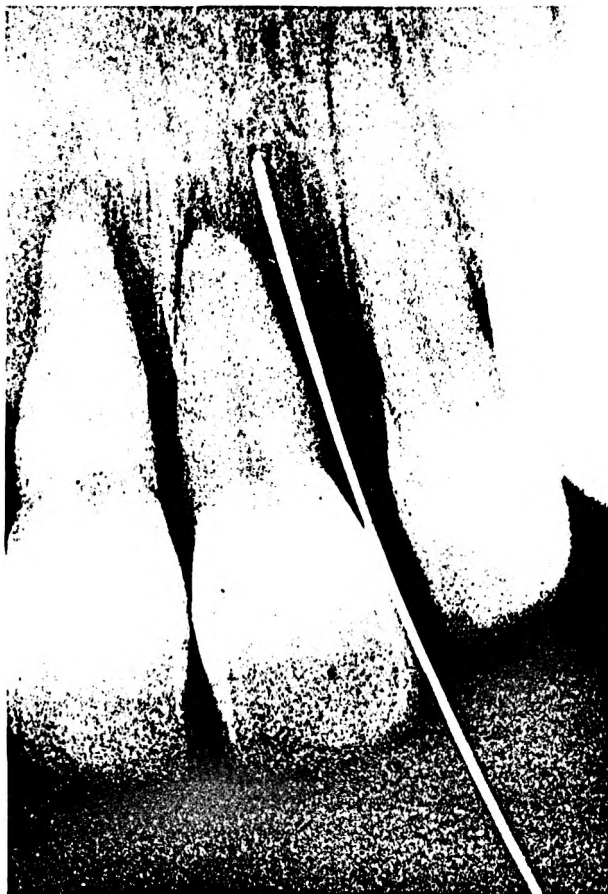

Fig. 1 a: Radiograph of upper central incisors, with a silver point inserted into the periodontal pocket.

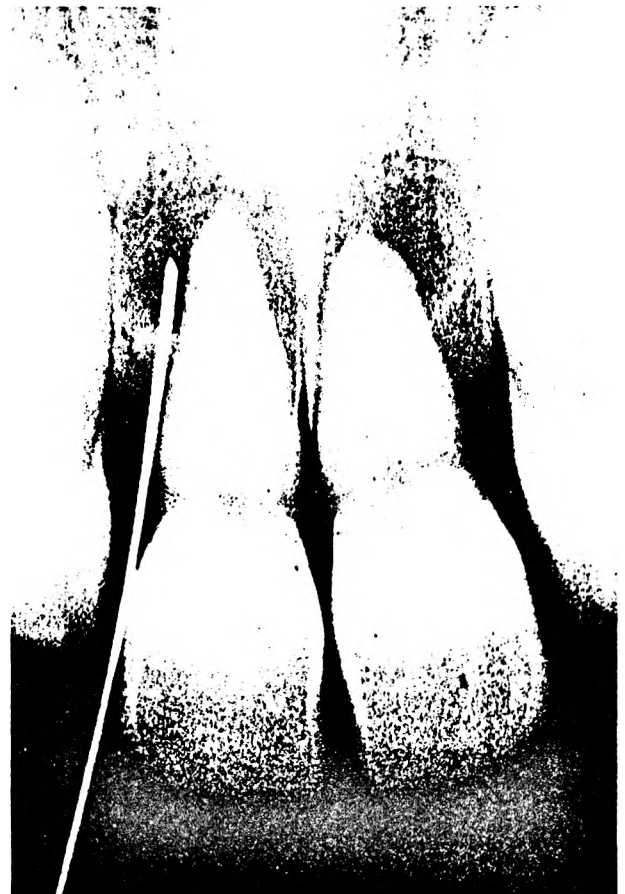

Fig. 1 b: Radiograph of upper central incisors, with a silver point inserted into the periodontal pocket.

The patient was next examined and radiographed approximately a year after the splint was removed. At this time the mobility of the incisors had decreased but the radiograph showed the presence of a radiolucent area distal to the upper right central incisor.

Two years after surgical intervention, the gingiva around the left central incisor was healthy but there was granulation tissue labio-distal to the right incisor protruding from a pocket. (Fig. 3). Curettage and occlusal adjustment were carried out, and the patient was seen twice in the ensuing 18 months.




Fig. 2: Photograph of the lesion after reflection of the soft tissues. The elastic band around the apices of the central incisors and the loss of bone on the distal and labial aspects of the incisors is seen.



Fig. 3: Clinical photograph taken 2 years post-operatively, showing inflammation and recession of the labial gingiva of the upper right central incisor.




Fig. 4: Clinical photograph 4 1/2 years post-operatively. The recession labial to the upper right central incisor persists, but gingival inflammation is minimal.

Four and a half years after surgical treatment, clinical and radiographic examinations were again undertaken. There was slight mobility of both central incisors. Periodontal pocketing was minimal but marked gingival recession had occurred labial to the right central incisor (Fig. 4). The radiograph of the central incisor region revealed an improved alveolar bone condition with evidence of regeneration (Fig. 5).

DISCUSSION

The accidental production of periodontal lesions by elastic bands appears to be uncommon. Kwapis and Knox (1972) and Cooper *et al* (1970) report cases of accidental extrusion of teeth by elastics. In these cases the patients were also unaware of the continued pressure of the elastic bands. This report is presented not only because it draws attention to the danger of prescribing elastic bands without an orthodontic aid for retaining it, but also because of the noteworthy re-attachment that was achieved. Ramfjord (1951) defined the term re-attachment as a unification or attachment between tooth and the adjacent soft tissue wall of the periodontal pocket. Despite Ramfjord's definition and the correlation he



Fig. 5: Radiograph 4 1/2 years post-operatively with evidence of alveolar regeneration distal to the upper central incisors.

established between the clinical and histological evidence of re-attachment, the subject of re-attachment still remains a controversial and extensively debated topic. Some of the work related to this aspect of dentistry that has been published during the past 20 years may be divided into four main categories:

Clinical assessment of the healing of periodontal lesions: Beube (1947), Linghorne and O'Connell (1950), Morris (1953), Macapanpan (1954), Beube (1960), Orban (1960), Waerhaug (1960), Listgarten (1967);

Histological studies of the effects of experimental procedures on re-attachment: Ramfjord (1951), Baume (1952), Butcher (1953), Schaffer and Zander (1958), Engler, Ramfjord and Hiniker (1965), Thilander and Hugoson (1970).

Muco-gingival surgery — evaluation of the attachment after the surgery, including flap procedures and pellicle grafts: Wilderman, Wentz and Orban (1960), Kohler and Ramfjord (1960), Glickman *et al* (1963), Hiatt (1968), Listgarten (1971), Listgarten (1972).

In recent years the emphasis has been placed on the re-attachment after free gingival grafts: Nabers (1966 a & b), Gargiulo, A.W. (1967), Oliver, Loe and Karring (1968), Staffileno (1969), Sugarman (1969), Hawley and Staffileno (1970), Klaven (1970), Brackett and Gargiulo (1970).

The extent of the detachment of the epithelium and periodontal connective tissue from the tooth was assessed preoperatively and at the time of the surgical treatment. Surgical intervention was designed to eliminate the periodontal pocket and this necessitated the removal of its epithelial lining to prepare the site for re-attachment of the connective tissue and epithelium. Although the pocket approximated the apices of the involved teeth and the gingival tissue overlaying the defect was attenuated, reattachment was obtained by muco-gingival surgery without having to resort to grafting.

The extent of the re-attachment cannot be determined with certainty, unless the teeth and supporting tissues are removed for histological study. The clinical evidence indicated that extensive re-attachment had taken place and been maintained for over 4 years.

#### ACKNOWLEDGEMENTS:

The authors would like to express their appreciation to: Professors D.H. Retief, J. Lemmer, Dr. P. Cleaton-Jones and Mrs. M. Jansen for their help in the preparation of this paper.

#### REFERENCES

Baume, L.J. (1952). Observations concerning the histogenesis of the epithelial attachment.

*Journal of Periodontology*, **23**, 71-84 (concluded p 108).

Beube, F.E. (1947). A study on reattachment of the supporting structures of the tooth. *Journal of Periodontology*, **18**, 55-56.

Beube, F.E. (1960). The problem of reattachment. *Journal of Periodontology*, **31**, 310-322.

Brackett, R.C. & Gargiulo, A.W. (1970). Free gingival grafts in humans. *Journal of Periodontology*, **41**, 581-586.

Butcher, E.O. (1953). The cuticles, epithelial attachment and reattachment in the incisor of the rhesus monkey. *British Dental Journal*, **94**, 199-201.

Cooper, M.B., Levin, M.A. & Dombrowski (1970). Case Report: Report of an elastic orthodontic band lost in the sulcus over two upper central incisors. *Pennsylvania Dental Journal*, **37**, 7, 238.

Engler, W.O., Ramfjord, S.P. & Hiniker, J.J. (1965). Development of epithelial attachment and gingival sulcus in rhesus monkeys. *Journal of Periodontology*, **41**, 581-586.

Gargiulo, A.W. (1967). Histo-clinical evaluation of free gingival grafts. *Periodontics*, **5**, 285-291.

Glickman, I, Smulow, J.B., O'Brien, T. & Tannen, R. (1963). Healing of the periodontium following mucogingival surgery. *Oral Surgery, Oral Medicine and Oral Pathology*, **16**, 530-538.

Hawley, C.E. & Staffileno, H. (1970). Clinical evaluation of free gingival grafts in periodontal surgery. *Journal of Periodontology*, **41**, 105-112.

Hiatt, W.H., Stallard, R.E., Butler, E.D. & Badgett, B. (1968). Repair following mucoperiosteal flap surgery with full gingival retention. *Journal of Periodontology*, **39**, 11-16.

Klavan, B., (1970). The replaced graft. *Journal of Periodontology*, **41**, 406-411.

Kohler, C.A. & Ramfjord, S.P., (1960). Healing of gingival mucoperiosteal flaps. *Oral Surgery, Oral Medicine and Oral Pathology*, **13**, 89-103.

Kwapis, B.W. & Knox, J.E., (1972). Extrusion of teeth by elastics: report of two cases. *Journal of the American Dental Association*, **84**, 629-631.

Linghorne, W.J. & O'Connell, D.C. (1950). Studies in the regeneration and reattachment of supporting structures of the teeth. I. Safe tissue reattachment. *Journal of Dental Research*, **29**, 419-428.

Listgarten, M.A. (1967). Electron microscopic features of the newly formed epithelial attach-

- ment after gingival surgery. *Journal of Periodontal Research*, 2, 46-52.
- Listgarten, M.A. (1971). Periodontal tissue repair over surgically exposed dentin and cementum surfaces. I.A.D.R. 49th General Meeting, Abstract 473.
- Listgarten, M.A. (1972). Electron microscopic features of the junction between surgically denuded root surfaces and regenerated periodontal tissues. *Journal of Periodontal Research*, 7, 68-90.
- Macapanpan, L.C. (1954). Union of the enamel and gingival epithelium. *Journal of Periodontology*, 25, 243-245.
- Morris, M.L., (1953). The reattachment of human periodontal tissues following surgical detachment: a clinical and histological study. *Journal of Periodontology*, 24, 220-228.
- Nabers, J.M., (1966)a. Extension of the vestibular fornix, utilizing a gingival graft. Case Report. *Journal of Periodontics*, 4, 77-79.
- Nabers, J.M. (1966)b. & Free gingival grafts. *Journal of Periodontics*, 4, 243-245.
- Oliver, R.C., Loë, H. & Karring, T., (1968). Microscopic evaluation of the healing and revascularization of free gingival grafts. *Journal of Periodontal Research*, 3, 84-95.
- Orban, B.J. (1960). Current concepts concerning gingival anatomy. Epithelial attachment (the attached epithelial cuff.) *Dental Clinics of North America*, p.705-713.
- Ramfjord, S.P., (1951). Experimental periodontal reattachment in rhesus monkeys. *Journal of Periodontology*, 22, 67-77.
- Schaffer, E. & Zander, H.A., (1958). Histological evidence of reattachment of periodontal pockets. *Paradontologie*, 7, 101-107.
- Staffileno, H. (1969). Palatal flap surgery: mucosal flap (split thickness) and its advantages over the mucoperiosteal flap. *Journal of Periodontology*, 40, 381-387.
- Sugarman, E.F., (1969). A clinical and histological study of the attachment of grafted tissue to bone and tooth. *Journal of Periodontology*, 40, 381-387.
- Thilander, H. & Hugoson, A., (1970). The border zone tooth-enamel and epithelium after periodontal treatment. An experimental electron microscopic study in the cat. *Acta Odontologica Scandinavica*, 28, 147-155.
- Waerhaug, J., (1960). Current concepts concerning gingival anatomy. The dynamic epithelial cuff. *Dental clinics of North America*, pp. 715-722.
- Wilderman, M.N., Wentz, F.M. & Orban, B.J. (1960). Histogenesis of repair after mucogingival surgery. *Journal of Periodontology*, 31, 283-299.