

# **EFFECTS OF A CRUDE *ALOE VERA* LEAF EXTRACT ON DIET-INDUCED METABOLIC DYSFUNCTION IN GROWING RATS**

**Zinhle Pearl Gasa**

A dissertation submitted to the Faculty of Health Sciences, University of Witwatersrand, School of Physiology in fulfillment of the requirements for the degree of Master of Science in Medicine.

Johannesburg, South Africa, 2012

The copy right of the above mentioned described thesis rest with the author or the University to which it was submitted. No portion of the text derived from it may be published without the prior written consent of the author or University (as may be appropriate). Short quotations may be included in the text of thesis or dissertation for purposes of illustration, comment or criticism, provided full acknowledgement is made of the source, author and University.

**DECLARATION**

I, Zinhle Pearl Gasas, declare that the work contained in this dissertation is my own, except where others have helped as indicated in the acknowledgements and the reference list. This dissertation is being submitted for the degree of Master of Science in Medicine in the Faculty of Health Sciences at the University of the Witwatersrand, Johannesburg, South Africa. The work herein has not been submitted before for any degree or examination at any University.

.....

Zinhle Pearl Gasas

Signed on the.....day of.....2012

I certify that all the experimental procedures used in this dissertation were approved by the Animal Ethics Screening Committee of the University of the Witwatersrand (AESC number: 2010/45/2A).

## CONFERENCE PRESENTATIONS

The following poster presentation is offered in support of this dissertation.

- 1) Authors: **Gasa ZP**, Makaula S and Erlwanger KH. Effects of fenofibrate and a crude *Aloe vera* leaf extract on diet-induced obesity in growing rats. 39<sup>th</sup> Congress of the Physiology Society of Southern Africa (PSSA), held at the University of Western Cape, Cape Town, from 29-31 August 2011. Preliminary data was presented as a poster that was ranked as the second best poster in the Johnny Van der Walt student poster competition. Subsequently the abstract was published as part of special edition of conference proceedings in an ISI-accredited journal: *Scientific Research Essays* (2012) Vol 7, 51-52.

## **DEDICATION**

*This research is dedicated to my mother Dudu Gladys Gasa who made sure that I am provided for from the first grade up until the post graduate level, since no man can choose a womb in which they come from to this earth, if I were to be given a chance to make that choice I would choose the same in which I came from.*

*Secondly I would like to dedicate this to my grandmother Sizakele Julia Gasa, my uncle Nhlanhla Joseph Gasa and my brother Sihle Gasa for lovingly and patiently giving me direction in my life, all of you have played a significant role in my life, I would not have come this far if it weren't for you, thank you for the support and love.*

*To my supervisor, Associate Professor Kennedy Erlwanger, co-supervisor Dr Siyanda Makaula and the Head of School of Physiology Professor, David Gray for their guidance and support.*

## **ACKNOWLEDGEMENTS**

My dissertation is a result of many hours of hard work and invaluable assistance of several people therefore I would like to express my gratitude and appreciation to the following people for their contribution to the successful completion of this study

**Central Animal Service:** I would like to extend my sincere gratitude to the staff of the Central Animal Services for their assistance with the care and welfare of the animals.

**Kennedy Erlwanger:** For his supervision, for his fatherly love and academic support. Thank you for the words of encouragement and mentorship. I wish God continues to bless you.

**Siyanda Makaula:** For assistance with some of the laboratory techniques performed in this study. Thank you for the useful explanations and comments.

**Margaret Badenhorst:** For her technical assistance with the processing of tissue for histology, and for running the ELISAs for Insulin hormonal assays as well as for technical assistance with the preparation of some of the reagents I used in the study.

**Eliton Chivandi:** For his technical assistance with liver lipid determination performed in this study and useful explanation regarding the laboratory work.

**Busisani Lembede, Mhlengi Magubane, Monique Weideman, Rachel Dangarembizi and Vernice Peterson:** For their invaluable assistance with the animal handling and lab work.

**Friends and family:** Finally I would like to thank my friends and family who have been there for me through the challenging times. I will always appreciate the support and love that they gave me. Thanks to Sanele Nyembe for being there for me and keeping me sane.

**Financial support:** The work in this dissertation was funded by grants from the Medical Faculty Research Endowment Fund of the University of Witwatersrand and the National Research Foundation (NRF) of South Africa, without their financial support this research would not have succeeded. I would also like to thank TATA Africa and the NRF for providing me scholarships

To God almighty our heavenly Father I give glory and honor for the gift of a beautiful life and all the blessings He has given me.

## ABSTRACT

The high prevalence of metabolic syndrome in children is mainly due to the adoption of an unhealthy diet and a sedentary lifestyle. The disorder is also associated with obesity, insulin resistance, hypertension and increased blood levels of triglycerides, free fatty acids and glucose. Although metabolic syndrome and its metabolic complications can be managed by the use of conventional medicines such as fenofibrate and metformin, there is a growing use of plants with medicinal properties. *Aloe vera* has been used for several medicinal purposes such as wound and burn healing, treatment of diabetes and treatment of cancer. *Aloe vera* also has biological activities that include anti-inflammatory, anti-microbial and laxative effects. Previous studies exploring the metabolic effects of *Aloe vera* have been in adult animals where metabolic syndrome was induced by the use of pharmacological agents. However, its beneficial effects in growing children who are at risk of developing metabolic syndrome have not been fully explored.

The objectives of this study were to evaluate the effects of a crude *Aloe vera* leaf extract on circulating metabolic substrates, the morphometry and morphology of the gastrointestinal tract and the liver function of growing rats.

Fifty-nine male Sprague-Dawley rats of 21 days old were randomly divided into one of six treatment groups. Group I (control) was fed normal rat chow (NRC) with plain gelatine cubes (vehicle). Group II received a high carbohydrate diet (HCD) with plain gelatine cubes; Group III received normal rat chow and fenofibrate at 100mg.kg<sup>-1</sup>; Group IV received a HCD and



fenofibrate at  $100\text{mg}\cdot\text{kg}^{-1}$ ; Group V received a normal rat chow and *Aloe vera* at  $300\text{mg}\cdot\text{kg}^{-1}$ ; Group VI received a HCD and *Aloe vera* at  $300\text{mg}\cdot\text{kg}^{-1}$ . The *Aloe vera* and fenofibrate were suspended in gelatine cubes and administered daily. After 20 weeks of feeding, the rats were fasted over night and an oral glucose tolerance test (OGTT) was performed. The rats were then euthanized after 48 hours of re-feeding and tissues were collected for further analysis. The data was expressed as mean  $\pm$  SEM and analyzed by a one-way ANOVA. A repeated measures ANOVA was used for statistical analysis of the data from the oral glucose tolerance test. The values were considered statistically significant when  $p < 0.05$  followed by a Bonferroni *Post hoc* test.

After 20 weeks, the growing rats fed a high carbohydrate diet had a significantly higher body mass than the other groups ( $p < 0.05$ , ANOVA), however the administration of fenofibrate prevented the high carbohydrate-induced increase in body mass whilst *Aloe vera* was not effective. Linear growth as measured by the tibial length was not significantly different between the groups ( $p > 0.05$ , ANOVA). There was no significant difference in the mass and relative density of the tibia bones of the rats between the groups. Feeding rats a HCD resulted in a higher ( $p < 0.05$ , ANOVA) visceral fat mass in the rats. Fenofibrate administration prevented the HCD-induced visceral fat mass gain whilst *Aloe vera* administration had no effect. Whilst the treatments did not result in any significant differences in the lengths and mass of the small intestine, the mass of the large intestine was significantly lower in the rats that received the HCD alone ( $p < 0.05$ , ANOVA). Fenofibrate administration resulted in a significantly increased liver mass compared to the other groups ( $p < 0.05$ , ANOVA). However there was no significant difference in the lipid and glycogen content in the liver.

Fasting concentrations of metabolic substrates (glucose, triglycerides and free fatty acids) were not significantly different between the groups and no significant differences were observed in the circulating concentrations of insulin and the homeostasis model assessment of insulin resistance (HOMA-IR) (ANOVA;  $p > 0.05$ ). The OGTT did not show any abnormalities in the ability of the rats to handle a glucose load between the groups.

An indirect assessment of liver function was performed by measurements of the blood concentrations of alkaline phosphatase (ALP), total bilirubin (TBIL), alkaline transaminase (ALT) and gamma-glutamyl transferase (GGT). There were significantly increased ( $p < 0.05$ ) ALP levels in rats fed NRC + FENO compared to the others. TBIL levels were significantly lower in rats fed a NRC + Av ( $p < 0.05$ , ANOVA) however the TBIL levels were within the normal range. The alkaline transaminase (ALT) levels were not significantly different between the groups ( $p < 0.05$ , ANOVA) and GGT was not detectable in any of the groups.

Weaning rats onto a high carbohydrate diet and feeding them the diet for 20 weeks resulted in the development of visceral obesity without altering the glucose tolerance and metabolic substrates. The treatment with fenofibrate prevented the high carbohydrate diet-induced visceral adiposity however compared to fenofibrate, treatment with the *Aloe vera* leaf preparation was not significantly effective.

## TABLE OF CONTENT

DECLARATION.....	i
CONFERENCE PRESENTATIONS.....	ii
DEDICATION.....	iii
ACKNOWLEDGEMENTS.....	iv
ABSTRACT.....	vi
TABLE OF CONTENT.....	ix
LIST OF FIGURES.....	xiii
LIST OF TABLES.....	xiv
LIST OF ABBREVIATIONS.....	xv
CHAPTER ONE- INTRODUCTION.....	1
1.0. Preface.....	2
1.1 Introduction.....	3
1.1.1. Insulin release.....	3
1.1.2. Consequences of metabolic syndrome.....	5
1.1.2.1. Complications of diabetes.....	6
1.1.3. Fenofibrate.....	8
1.1.4. <i>Aloe vera</i> .....	9

1.1.4.1.	Classification .....	10
1.1.4.2.	Structural composition and bioactive chemical constituents .....	12
1.1.4.3.	Therapeutic uses of <i>Aloe vera</i> .....	15
1.1.5.	Gastrointestinal system .....	17
1.1.6.	Justification of the study .....	19
1.1.7.	Aims of the study .....	20
CHAPTER TWO-MATERIALS AND METHODS.....		22
2.1.	Study setting .....	23
2.1.1.	Ethical approval.....	23
2.1.2.	Experimental design.....	23
2.2.	Materials .....	24
2.2.1.	Plant collection.....	24
2.3.	Methods .....	25
2.3.1.	Preparation of <i>Aloe vera</i> leaf extracts .....	25
2.3.2.	Feeds.....	25
2.3.3.	Housing of animals.....	26
2.4.	Analytical procedures .....	27
2.4.1.	Body mass .....	27

2.4.2.	Oral glucose tolerance test (OGTT) and measurement of fasting metabolic substrates (triglycerides (TGs) and glucose) .....	27
2.5.	Terminal Procedures.....	28
2.5.1.	Blood sampling and plasma processing .....	28
2.5.2.	Visceral measurements and histology .....	29
2.5.3.	Determination of liver lipid content.....	29
2.5.4.	Determination of hepatic glycogen content .....	30
2.5.5.	Tibia lengths and masses.....	31
2.5.6.	Plasma free fatty acid concentrations.....	31
2.5.7.	Measurement of liver enzymes and total bilirubin in serum.....	32
2.5.8.	Insulin measurements.....	33
2.5.9.	Statistical analysis .....	34
CHAPTER THREE-RESULTS .....		35
3.1.	Mortality and morbidity of the animals.....	36
3.2.	The effects of <i>Aloe vera</i> leaf extract on body mass gain.....	36
3.3.	The effect of <i>Aloe vera</i> leaf extract on the linear growth (tibia) .....	38
3.4.	The effect of <i>Aloe vera</i> leaf extract on circulating insulin and metabolic substrates .....	40
3.5.	Effects of <i>Aloe vera</i> leaf extract on abdominal visceral organ morphometry and morphology.....	42

3.5. The effect of <i>Aloe vera</i> leaf extract on the response to an oral glucose load .....	49
3.7. The effect of <i>Aloe vera</i> leaf extract on liver enzymes and total bilirubin .....	51
3.8. The effect of <i>Aloe vera</i> leaf extract on hepatic lipid and glycogen content .....	54
CHAPTER FOUR- DISCUSSION .....	57
CHAPTER FIVE- CONCLUSION AND RECOMENDATIONS .....	65
CHAPTER SIX-REFERENCES .....	68
APPENDIX .....	81

## LIST OF FIGURES

Figure 1.1 Insulin secretion in the beta cell triggered by an increase in blood glucose levels....	4
Figure 1.2 <i>Aloe vera</i> plant .....	11
Figure 1.3 <i>Aloe vera</i> plant and the bioactive chemical constituents.....	12
Figure 3.1 Effect of <i>Aloe vera</i> leaf extract on body mass gain .....	37
Figure 3.2 Effect of <i>Aloe vera</i> leaf extract on visceral fat mass.....	43
Figure 3.3 Effect of <i>Aloe vera</i> leaf extract on the liver mass .....	44
Figure 3.4 Effects of <i>Aloe vera</i> leaf extract on the response to an oral glucose load.....	50
Figure 3.5 Effect of <i>Aloe vera</i> leaf extract on hepatic lipid content of growing rats .....	55
Figure 3.6 Effect of <i>Aloe vera</i> leaf extract on hepatic glycogen content of growing rats .....	56

## LIST OF TABLES

Table 1.1: Bioactive chemical constituents of <i>Aloe vera</i> . .....	13
Table 3.1 Effect of <i>Aloe vera</i> leaf extract on the length and mass of the tibias of growing rats. .....	39
Table 3.2: Effect of <i>Aloe vera</i> leaf extract on fasting concentrations of metabolic substrates and circulating insulin. ....	41
Table 3.3: Effect of <i>Aloe vera</i> leaf extract on the absolute mass (g) and the mass (% relative to tibia length) of the viscera and, length (mm) of GIT segments of growing rats. ....	45
Table 3.4: Effect of a crude <i>Aloe vera</i> leaf extract on microscopic measurements of small intestine in growing rats. ....	48
Table 3.5: Effect of <i>Aloe vera</i> extract on the liver enzymes (ALT, ALP and GGT) and total bilirubin of the growing rats. ....	52



## LIST OF ABBREVIATIONS

AESC	Animal Ethics Screening Committee
ALT	Alanine-amino Transferase
ANOVA	Analysis of variance
<i>Av</i>	<i>Aloe vera</i>
ALP	Alkaline Phosphatase
BM	Body mass
DM	Diabetes mellitus
FENO	Fenofibrate
FFAs	Free fatty acids
GGT	Gamma-glutamyl transferase
GLUTs	Glucose transporters
HCD	High carbohydrate diet
NRC	Normal rat chow
OGTT	Oral Glucose Tolerance Test

PPAR- $\alpha$	Peroxisome proliferator activated receptor
alpha	
NaOH	Sodium hydroxide
TBIL	Total bilirubin
TGs	Triglycerides
T1DM	Type I diabetes mellitus
T2DM	Type II diabetes mellitus
WHO	World Health Organization

# **CHAPTER ONE- INTRODUCTION**

## 1.0. Preface

Metabolic syndrome is a disorder characterized by several risk factors including obesity, insulin resistance and diabetes mellitus (DM). There is a resultant chronic increased glucose blood level (hyperglycaemia) due to a lack/reduction in insulin action. The disorder is also associated with hypertension, increased blood levels of triglycerides and free fatty acids.

Obesity is mainly caused by a lack of exercise or excess consumption of diets that are rich in refined sugars and fats. Unfortunately, the prevalence of obesity and its complications is increasing in children. Despite the use of conventional drugs such as fenofibrate, antihypertensives, statins and metformin for the management of the metabolic syndrome associated with obesity, the management of obesity related metabolic syndrome in many communities also includes the use of several medicinal plants. Among these plants, *Aloe vera* is commonly used as herbal medicine in many cultures. *Aloe vera* has been shown to have antidiabetic effects through mechanisms that are yet to be fully explored. It has been previously reported that the anti-diabetic effects of *Aloe vera* in streptozotocin (STZ)-induced diabetic rats is mediated through the presence of glucomannans and phytosterols which decrease serum cholesterol. The current study aimed to establish an animal based model of diet-induced metabolic dysfunction and to investigate whether dietary supplementation with *Aloe vera* delayed the development of diet-induced metabolic dysfunction in growing rats. In an effort to fully understand the possible mechanism(s) of action of *Aloe vera* the study explored some of the regulatory mechanisms by which *Aloe vera* could modify dietary-induced metabolic dysfunction in growing rats by focusing on metabolically active tissues, namely the liver and adipose tissue. Chapter 1 describes the physiology of insulin release,

consequences of metabolic dysfunction, pharmacology and some general therapeutic effects of *Aloe vera*. The aims, the objectives and justification for the study are also included in this introductory chapter.

## **1.1 Introduction**

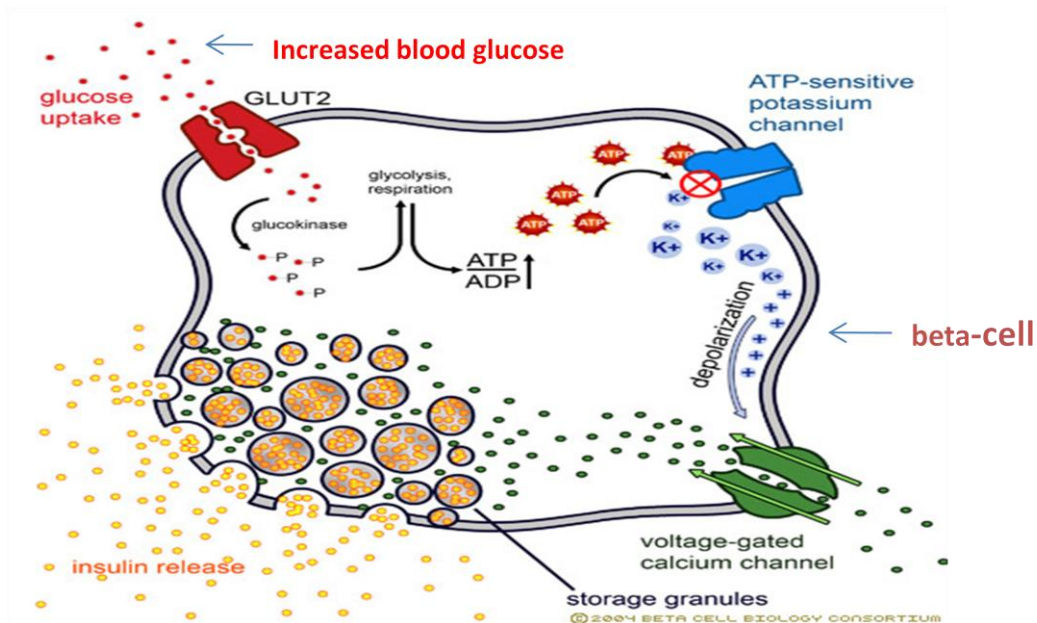
Metabolic syndrome a lifestyle disease, is a common metabolic disorder characterized by a group of metabolic risk factors, the five risk factors are visceral obesity, dyslipidemia ( $\geq 3.87$  mmol.L<sup>-1</sup> triglycerides in circulation) with fatty liver due to accumulation of triglycerides in the liver, lower than normal HDL cholesterol, elevated fasting blood glucose ( $\geq 4$  mmol. L<sup>-1</sup>) and High blood pressure (Ker *et al.*, 2007). In 2008, over 1.4 billion adults (20 years and older) were overweight and over 500 million were obese. The number of overweight children below the age of five was estimated to be over 42 million in 2010 (WHO) and 35 million of these were in developing countries such as South Africa (Rossouw *et al.*,2012).

The high prevalence of childhood obesity is mainly due to the adoption of an unhealthy diet and a sedentary lifestyle (Slyper, 2004). Metabolic risk factors that develop due to the consumption of a high carbohydrate diet are strongly linked to the rapid release of insulin and the development of insulin resistance (McKeown *et al.*, 2004).

### **1.1.1. Insulin release**

Under normal conditions, the concentration of blood glucose is maintained within a narrow range mainly through metabolic hormones. The hormones include glucagon that plays an

essential role when the blood glucose levels are low while the pancreatic  $\beta$ -cell hormone, insulin decreases blood glucose levels when they are high. When blood glucose concentrations increase after a meal, insulin secretion is triggered. Through facilitated diffusion, glucose is transported into pancreatic cells via GLUT-2 causing an increase in the ATP/ADP ratio which depolarizes the plasma membrane of the  $\beta$  cells. This causes the ATP-sensitive potassium ( $K_{ATP}$ ) channel to close (Figure 1.1), thereby causing an influx in  $Ca^{2+}$  which stimulates insulin secretion (Ashcroft and Gribble, 1999). Insulin then enhances glucose uptake by the adipose and muscle cells, the target tissues for insulin action where the glucose is converted into glycogen and lipids (Shepherd and Kahn, 1999). Insulin release therefore triggers several processes that ensure the storage of nutrients via its action on its target cells.



**Figure 1.1. Insulin secretion in the beta cell triggered by an increase in blood glucose levels (Modified from Beta Cell Biology Consortium, 2004 [www.betacell.org/content/articleview/article\\_id/1/](http://www.betacell.org/content/articleview/article_id/1/)).**

The process of insulin secretion described above may be disturbed as a result of excess consumption of carbohydrates leading to insulin resistance (Basciano *et al.*, 2005). Insulin resistance is a condition wherein the activity of insulin is inadequate to exert an effect on insulin receptors in liver and adipose tissues (Ingelsson *et al.*, 2005). Decreased insulin sensitivity may result in impaired cellular glucose uptake and an increase in blood glucose concentrations. As a result of impaired glucose storage, fat deposition begins to occur around visceral organs. Visceral fat deposition is one of the characteristics of insulin resistance and is linked with the development of metabolic dysfunction (McKeown *et al.*, 2004). In addition, excess consumption of diets rich in carbohydrates may stimulate lipolysis causing an increase in blood triglyceride concentrations (Thorburn, 1989). Insulin resistance is strongly linked to the development of cardiovascular disease and diabetes mellitus. The following section will focus on one of the components of metabolic syndrome, diabetes mellitus.

### **1.1.2. Consequences of metabolic syndrome**

Diabetes mellitus (DM) is a metabolic disorder characterized by increased blood glucose levels (hyperglycaemia) (Grover *et al.*, 2002). Hyperglycaemia can be due to a deficiency or insulin's inability to exert its blood glucose lowering effects (Groop, 1992). Diabetes mellitus is a major public health problem. An estimated 171 million people were diagnosed with diabetes in the year 2010 worldwide. ). The number is expected to grow to 366 million in 2030 (IDF, Diabetes Atlas, 2012). In 2003, 3.4 % of the 24 million South Africans were diabetic with an expected increase to 3.9 % by 2025 (Rheeder P, 2006. There are two common types of

DM, type I diabetes mellitus (T1DM) and type II diabetes mellitus (T2DM). T1DM is an autoimmune disease that is caused by the pancreatic  $\beta$  cell's inability to secrete insulin (Kumar and Clark, 2002). T1DM can affect both adults and children, it was traditionally termed "juvenile diabetes" due to its high prevalence in children.

The increasing prevalence of diabetes is associated with several factors that include age and the rapid increase in metabolic dysfunction or obesity, due to a lack of exercise and the adoption of western diets rich in carbohydrates (Chan and Abrahamson, 2003). Although the cause of diabetes is unclear, it involves both an impaired insulin secretion and development of insulin resistance. Insulin resistance usually results as a consequence of insulin's inability to exert its effect on insulin receptors which is associated with obesity (mostly occurs in T2DM). The World Health Organization reported that diabetes mellitus was one of the major causes of deaths worldwide (WHO, report, 1999). In South Africa, the number of people suffering from diabetes has been rising significantly over the years (King *et al.*, 1998). Diabetes is one of the leading causes of death that result from long-term exposure to microvascular complications (Chan and Abrahamson, 2003).

#### **1.1.2.1. Complications of diabetes**

Hyperglycemia is a common cause of complications in diabetic patients (Reusch, 2003). Complications of hyperglycemia are divided into microvascular (nephropathy, neuropathy and retinopathy) and macrovascular (myocardial infarction, stroke and peripheral arterial disease) (Fowler, 2008). Retinopathy is the most common microvascular complication and may develop as early as 7 years before the diagnosis of diabetes in patients with diabetes (Fong *et*



*al.*, 2004). Diabetic retinopathy is caused by damage of the blood vessels in the retina resulting in the formation of a blood-retinal barrier, therefore causing blindness (Fowler, 2008). Diabetic nephropathy refers to the damage in the kidneys especially in diabetic patients with high blood pressure and is the leading cause of renal failure (Wolf, 2004).

Macrovascular complications are the main cause of morbidity and mortality in diabetic patients. Macrovascular diseases are those that damage large blood vessels. Damage can cause blood vessels to narrow, which decreases blood supply in areas in need of blood. One of the complications is stroke, where the blood supply to the brain and heart is decreased (Sweetnam *et al.*, 2012). These complications usually result from disturbances in glucose homeostasis due to insulin resistance, which lead to structural changes in different cells such as cardiomyocytes, adipocytes and hepatocytes (Burns *et al.*, 1999). Uncomplicated metabolic dysfunction can be managed by lifestyle changes such as daily exercise and adopting a healthy diet. However, pharmacological intervention is necessary to manage the metabolic dysfunction in complicated cases (Chan and Abrahamson, 2003). Treatment methods for metabolic dysfunction aim at lowering increased fatty acids and glucose levels back to normal (Li *et al.*, 2004). Pharmacological agents, such as, fenofibrate, metformin, statins and antihypertensives have been used for the treatment of some of the complications of metabolic syndrome. For my study, I chose to use fenofibrate as a positive control pharmacological agent for comparison to *Aloe vera*. The following section describes the mechanisms by which fenofibrate exerts its action.

### 1.1.3. Fenofibrate

Fenofibrate is a lipid lowering agent and is mainly used to reduce cholesterol in patients that are at risk of developing cardiovascular disease. Fenofibrate is a fibric acid derivative whose effect is mediated via the activation of peroxisome proliferator activated receptor alpha (PPAR- $\alpha$ ) (Staels *et al.*, 1998). PPAR- $\alpha$  is a ligand-activated transcription factor. The role of PPAR- $\alpha$  is to regulate the expression of genes involved in  $\beta$ -oxidation of fatty acids (van Raalte *et al.*, 2005). Through the activation of PPAR- $\alpha$ , fenofibrate increases lipolysis and eliminates triglycerides from plasma by activating lipoprotein lipase (Staels *et al.*, 1998). Fibrates stimulate the uptake of FFAs by hepatic cells and the conversion of FFAs to acyl-CoA derivatives by the  $\beta$ -oxidation pathways in mitochondria resulting in a reduction in fatty acid and triglyceride synthesis (Staels *et al.*, 1998).

Pharmaceutical industries are still emerging worldwide to develop more effective pharmacological agents, however, the efficacy of these agents has been debatable due to their unwanted side effects and because they can be quite costly and inaccessible to low resourced communities. Hence, the importance of medicinal plants has not been diminished. Natural products are known to play a significant role in the development of modern medicine (Joseph and Raj, 2010). Hence, the World Health organization estimates that more than 70 percent of the population in underdeveloped and developing countries rely on traditional plants for medicinal treatment and primary health care (WHO, 2008)

*Aloe vera* is one of the few medicinal plants that has stood the test of time as a popular herbal medicine with wide spread use in many cultures around the world (Tanaka *et al.*, 2006).

#### **1.1.4. *Aloe vera***

The plant *Aloe vera* is widely distributed in Africa with origins in the Arabian Peninsula of Northern Africa. *Aloe vera* is a member of the Liliaceae family; the family includes 300 or more species (Rajasekaran *et al.*, 2006). *Aloe vera* commonly called *Aloe* is a cactus like short-stemmed succulent plant with green sharp pointed leaves that are fleshy and spiny containing a clear viscous gel (Joseph and Raj, 2010). *Aloe vera* grows in arid climates and can reach heights of 10-20 meters with a stem ranging up to three meters in diameter. The flowers are produced annually in summer, they are bright orange in colour and spike up to 90 cm tall (Yates, 2002). The term *Aloe* is derived from Arabic “alloeh” which means a bitter substance (Joseph and Raj, 2010). The bitterness results from the presence aloin and aloemodin (Joseph and Raj, 2010). *Aloe vera* secretes two types of fluid containing proteins and cellular elements. One is a reddish-yellow thick bitter fluid secreted from the pericyclic cells of the plant and the other, a transparent mucilage gel produced by tubular cells in the central parenchyma zone of the leaf (Joseph and Raj, 2011). These fluids are mainly used for laxative (reddish-yellow) and several medical (gel) purposes some of which will be summarized in the following sub sections.

#### **1.1.4.1. Classification**

Kingdom : Plantae

Division : Magnolio

Class : Liliopsida

Order : Liliales

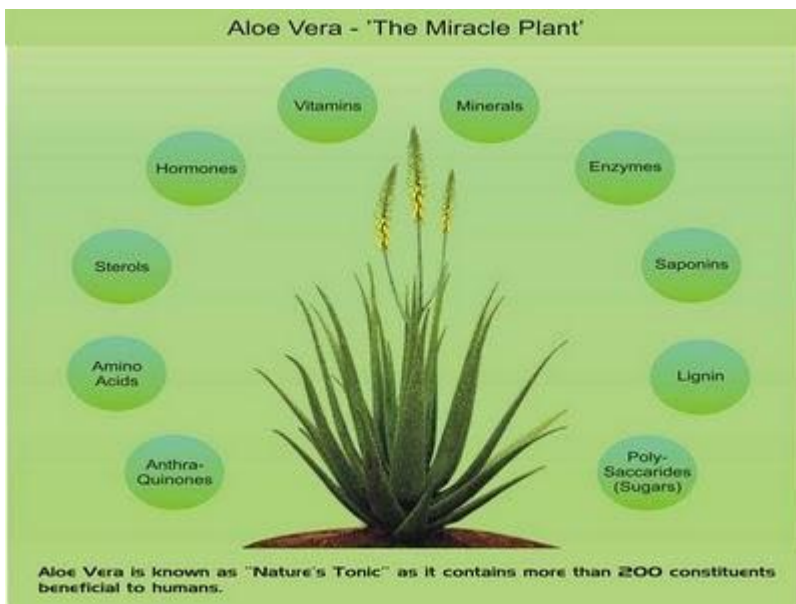
Family : Aloaceae

Genus : *Aloe*

Species : *vera*



**Figure 1.2. *Aloe vera* plant**



**Figure1.3. *Aloe vera* plant and the bioactive chemical constituents**  
(<http://mumbai.olx.in/Aloe-vera-products-id-4852352>)

#### **1.1.4.2. Structural composition and bioactive chemical constituents**

##### ***Structural composition***

The *Aloe* leaf is divided into two parts, an outer green rind and the inner colourless parenchyma containing gel (Hamman, 2008). The *Aloe vera* gel contains up to 99.5 % water with an average pH of 4.5, the remaining 0.5-1 % is solid material (Eshun and He, 2004; Hamman, 2008). Various chemical constituents have been isolated from both the solid and the gel material of the *Aloe vera* leaf (Figure 1.3). The solid material consists of many bioactive compounds. The many health benefits of *Aloe vera* have been attributed to its bioactive constituents found in the gel of the leaves (Hamman, 2008). Present in the gel are

polysaccharides such as proteins, glucomannan, calcium, zinc, glucose, salicylic acid, vitamins, lignins, saponins and amino acids (Atherton, 1998). Chemical compounds such as anthraquinones (aloin, aloe-emodin) are found in the latex leaf lining (Kemper and Chiou, 1999). Components present in *Aloe vera* are summarized in the table (Table 1.1) and described in more detail below.

**Table 1.1: Bioactive chemical constituents of Aloe vera (Hamman, 2008; Josephs and Raj, 2010).**

<b>Class</b>	<b>Compounds</b>
<b>Vitamins</b>	B <sub>1</sub> , B <sub>2</sub> , B <sub>6</sub> , choline, β-carotene, folic acid
<b>Proteins</b>	Lectins, lectin-like substances
<b>Polysaccharides</b>	Mannan, acetylated mannan, glucomannan, galactan, cellulose, pectic substance
<b>Anthraquinones</b>	Aloe-emodin, aloetic-acid, Aloin A and B, emodin, chromones
<b>Enzymes</b>	Alkaline phosphate, amylase, carboxypeptidase, catalase, lipase
<b>Monosaccharides</b>	Mannose, aldopentose, glucose, <i>L</i> -rhamnose

Amylase and lipase are biochemical catalysts that play an important role in digestion by breaking down fats and sugars (Fermenta *et al.*, 1999). The presence of carboxy-peptidase plays an important role in the reduction of inflammation. Following tissue injury, bradykinin produces pain associated with vasodilation during inflammation. When *Aloe vera* is used to treat inflammation, it hydrolyses bradykinin by carboxy-peptidase and helps reduce inflammation by producing an analgesic effect (Obata *et al.*, 1993; Shelton 1991).

*Aloe vera* also contains significant quantities of minerals such as sodium, potassium, calcium, magnesium, manganese, copper, zinc, chromium and iron. These minerals play an important role in the functioning of various enzymes. For example, magnesium helps inhibit histidine decarboxylase preventing the formation of histamine from the amino acid histidine (Shelton 1991). Histamine is involved in allergic reactions causing itching and pain (Shelton 1991).

Sugars contained in *Aloe vera* are found in the mucilage layer of the plant under the rind, surrounding the gel (Joseph and Raj, 2010). They mainly comprise both mono- and polysaccharides such as acemannan, however the most common are the polysaccharides specifically the gluco-mannans (Beta - (1, 4) - linked acetylated mannan). When taken orally, some of these bind to receptor sites that line the gut and form a barrier, possibly helping to prevent 'leaky gut syndrome' i.e. preventing absorption of unwanted material. Some can also be ingested by enterocytes, through a process of cellular absorption known as pinocytosis. Unlike other sugars that are broken down prior to absorption, the polysaccharides can be absorbed in the same form without being broken down. Once in the bloodstream, they act as immuno-modulators where they play a role in enhancing and retarding the immune response (Green, 1996; Kahlon *et al* 1991).

*Aloe vera* consists of free anthraquinones and their derivatives such as barbaloin, isobarbaloin, anthrone-C-glycosides and chromones found in the sap. These compounds play an important role in absorption from the gut. Anthraquinones also exert antimicrobial properties and analgesic effects (Joseph and Raj, 2010).



### **1.1.4.3. Therapeutic uses of *Aloe vera***

*Aloe vera* is one of the most significant plants used in modern traditional medicine and has gained its popularity in homeopathy and conventional medicine over the centuries (Joseph and Raj, 2010). *Aloe vera* has been shown to have therapeutic effects for several conditions and ailments such as cancer, cardiovascular disorders, wounds, inflammation and metabolic dysfunction (e.g. diabetes mellitus).

#### ***Immunomodulatory and antitumor effects***

Fresh leaves and exudates i.e. lectin-like substances extracted from *Aloe* plants may have biological activities that may boost the immune system and alternatively destroy cancerous tumors (Winters, 1993). Polysaccharides from the central gel of *Aloe vera* such as acemannan have beneficial anti-cancer effects. Its therapeutic effects are through the activation of immune cells such as macrophages thus destroying tumor cells (Zhang and Tinzard, 1996).

#### ***Wound healing***

One of the fundamental uses of *Aloe vera* is an aid in wound healing. Several studies have shown that *Aloe vera* is effective on wound healing (Feily and Namazi, 2009). Evidence on the effects on wound healing is however limited and contradictory (Vogler and Ernest, 1999).

Some studies have shown *Aloe vera* to promote wound healing while others observed that wounds to which *Aloe vera* was applied were slower to heal (Schmidt and Greenspoon, 1991; Kaufman *et al.*, 1988). A meta-analysis intervention study that included clinical trials for burn healing provided some evidence to support that topical application of *Aloe vera* could be effective in burn wound healing for first to second degree burns (Maenthaisong *et al.*, 2007).

### ***Anti-inflammatory and antibacterial effects***

*Aloe vera* is reported to have anti-inflammatory effects when used topically (Reuter *et al.*, 2008). The plant has also been shown to reduce the inflammatory response in rats with carrageenan-induced arthritis (Davis *et al.*, 1992), an animal model which mimicks rheumatoid arthritis in humans. The anti-inflammatory therapeutic effects of *Aloe vera* are thought to be through the stimulation of fibroblast cell growth and the inhibition of arachidonic acid pathways via cyclooxygenase (Vazquez *et al.*, 1996). The inhibition of the biosynthetic pathways of prostaglandins is through active steroid-like compounds contained in the central part of the leaf (Reuter *et al.*, 2008). *Aloe vera* has also been shown to have antibacterial activities that are thought to play a role in the treatment of minor skin infections and may possibly inhibit fungal growth (Sumbul *et al.*, 2004).

### ***Antidiabetic effects***

Evidence show that *Aloe vera* may play a role in the treatment of diabetes mellitus. Previous studies have shown that oral administration of processed *Aloe vera* gel reduced circulating blood glucose levels in an obese mice model (Kim *et al.*, 2009). *Aloe vera* has been shown to lower blood glucose, cholesterol and lipid levels in streptozotocin-induced diabetes rat models and its administration significantly increased plasma insulin levels (Hamman, 2008). Similar findings were also reported where *Aloe vera* leaf pulp lowered blood glucose levels in neonatal STZ-induced type- II diabetic rats (Can *et al.*, 2004). The antidiabetic effects of *Aloe vera* are thought to be due to the presence of mannans antraquinones and lectins (Can *et al.*, 2004). It has also been suggested that the mechanism by which *Aloe vera* lowered the blood glucose levels was by enhancing glucose metabolism (Hamman. 2008).

Most medicinal plants are taken orally and as a consequence the first point of contact with the body is the gastrointestinal tract (GIT). The next section gives a brief overview on the GIT.

### **1.1.5. Gastrointestinal system**

The gastrointestinal tract (GIT) is a complex organ serving as the first point of entry of any orally administered dietary ingesta (Sorensen, 2009). Hence, the structure of the GIT is well adapted to carry out several functions that include digestion, absorption and protection.

For most mammalian species, the development of the GIT is divided into three stages: (i) the prenatal stage characterized by minimal stimulation from the GIT lumen. (ii) The neonatal stage, at this stage the development of the GIT is stimulated by liquid feed from the mother's milk and (iii) the post-weaning stage, which is a stage that involves the adaptation of the GIT to utilize solid feeds (Zabielski *et al.*, 2008). At the beginning of weaning, the motility,

digestive and absorptive functions of the GIT are yet to be developed and prepared for solid feeds, hence this is the most critical stage for the structure of the GIT to develop to its full capacity.

Although the GIT mucosa undergoes structural and functional changes in structures such as the villi and crypts which are related to exchange and absorptive processes during postnatal development (Vigueras *et al.*,1999), diet plays a major role in the structure and the functioning of the GIT by inducing the release of regulatory and tropic hormones (Sorensen, 2009).

*Aloe vera* contains bioactive compounds such as carbohydrates and proteins (Hamman, 2008; Josephs and Raj, 2010). Carbohydrates can influence the GIT's response to a diet and result in adaptive changes in the GIT (Lairon *et al.*, 2007). Some compounds found in complex carbohydrates are not digested until they reach the large intestine, hence their physical and chemical properties may have an important physiological effect throughout the GIT (Schneeman, 2007). Carbohydrates such as non-starch polysaccharides have properties such as water-holding capacity and non-digestibility, as a result these compounds are primary substrates for growth of micro flora in the large intestine where they function as prebiotics (Schneeman, 2007).

A study done in human subjects showed that *Aloe vera* supplementation decreased the stool specific gravity; this indicated a water-holding property and improved gastrointestinal motility (Bland, 1985). Bland (1985) also found *Aloe vera* to have alkalizing effects where the

gastrointestinal pH increased after *Aloe vera* administration. *Aloe vera* also improved protein digestion and absorption (Bland, 1985).

The GIT is sensitive to dietary manipulation during the neonatal stage. Therefore, the ingestion of *Aloe vera* in growing rats might have a direct long lasting effect on the GIT structure and function (Pacha, 2000). Medicinal plants can be toxic especially when used chronically, it is therefore important to also assess their effects on the general health status of individuals using them by monitoring specific surrogate markers of organ function.

#### **1.1.6. Justification of the study**

Previous studies exploring the metabolic effects of *Aloe vera* have been in adult animals and the metabolic dysfunction has generally been induced by use of pharmacological agents such as streptozotocin (STZ). Several rat models have been used for *in vivo* studies on obesity and diabetes mellitus. These include the use of pharmacological agents such as streptozotocin and genetic strains such as obese Zucker rats (Buettner et al., 2006). However, these models do not represent childhood metabolic dysfunction sufficiently. The current study on recently weaned rats exposed to a high-carbohydrate diet was an attempt to fill part of the lack of information on the effects of *Aloe vera* on diet-induced metabolic dysfunction in growing rats as an experimental model for the condition in children.

### 1.1.7. Aims of the study

The aim of the study was to evaluate whether *Aloe vera* delays the development of a high carbohydrate diet-induced metabolic dysfunction in growing rats. Thus, the major objectives were to:

- a) Establish an animal based model of diet-induced metabolic dysfunction
- b) Explore whether dietary supplementation with *Aloe vera* delayed the development of diet-induced metabolic dysfunction in growing rats by exploring its regulatory mechanism with special focus on its effect on concentrations of:
  - i) Circulating insulin and metabolic substrates (glucose, triglycerides and free fatty acids)
  - ii) Hepatic storage of metabolic substrates (lipids and glycogen)
- c) Determine the effects of *Aloe vera* on the morphometry and morphology of the abdominal viscera by gross macroscopic and microscopic measurements.
- d) Determine the effects of *Aloe vera* on growth performance (body mass and linear growth).
- e) Assess the effects of *Aloe vera* extracts on surrogate markers of liver function i.e. alkaline phosphatase (ALP), alanine transaminase (ALT), gamma glutamyl transpeptidase (GGT) and total bilirubin (TBIL).

I thus hypothesized that:

- a. The high carbohydrate diet would induce metabolic dysfunction in the rats after 20 weeks of feeding and
- b. Administration of *Aloe vera* would prevent/delay the development of the diet induced metabolic dysfunction without adverse effects in the rats.

# **CHAPTER TWO-MATERIALS AND METHODS**



## **2.1. Study setting**

The study was conducted in the Central Animal Services animal unit and the School of Physiology at the Faculty of Health Sciences, University of the Witwatersrand, Johannesburg, South Africa.

### **2.1.1. Ethical approval**

Ethical approval for the study was obtained from the Animal Ethics Screening Committee (AESC) of the University of the Witwatersrand (Ethics clearance number: 2010/45/2A) and the study was undertaken according to international standards of animal care and use in research. To comply with restrictions by the AESC *in vivo* acute toxicity studies were not performed in this study.

### **2.1.2. Experimental design**

Fifty-nine male, 21 day old Sprague Dawley rats were randomly divided into six treatment groups. Group I received normal rat chow + plain gelatine cubes (NRC) and served as the control. Group II received a high carbohydrate diet + plain gelatine cubes (HCD) and group III received normal rat chow + fenofibrate (100 mg.kg<sup>-1</sup>) (NRC + FENO). Group IV received a high carbohydrate diet + fenofibrate (HCD + FENO) and group V received normal rat chow + *Aloe vera* (300 mg.kg<sup>-1</sup>) (NRC + Av). The last group (group VI) received a high carbohydrate diet + *Aloe vera* (HCD + Av). The *Aloe vera* and fenofibrate were administered daily in 2 ml

gelatine cubes, which were prepared as described by Kamerman *et al.*, (2004). The fenofibrate was used as a positive control pharmacological agent.

## **2.2. Materials**

### **2.2.1. Plant collection**

Fresh *Aloe vera* plants were sourced from a commercial plant nursery (Flora farm) in Boksburg, South Africa. The farm is on longitude of 28<sup>o</sup> 24'15 East and latitude 26<sup>o</sup> 82'10 South with a mean annual minimum temperature of 14<sup>o</sup>C, mean annual maximum temperature of 30<sup>o</sup>C, mean annual minimum rainfall of 450mm and mean annual maximum rainfall of 500mm. The *Aloe vera* plant was authenticated by the University of the Witwatersrand Herbarium Research and Media Officer, Mr Donald McCallum. A sample of the plant was deposited in the University Herbarium with voucher number: Ben Beya 1.

## **2.3. Methods**

### **2.3.1. Preparation of *Aloe vera* leaf extracts**

The crude *Aloe vera* leaf extract was prepared from fresh *Aloe vera* leaves as modified from Rajasekaran *et al.*, (2004) so as to include some solid particulate leaf matter. The *Aloe vera* leaves were washed with distilled water, sliced and homogenized with an equal volume of distilled water using a blender (Warring ®, Lasec SA Company, USA). The homogenate was filtered through a muslin cloth. The filtrate was dried in an oven (Salvis ®, Oakton Instruments, USA) at 40 °C and the resultant residue was stored in tightly dark, tightly sealed bottles at 4 °C and then the requisite amounts of *Aloe vera* extracts were suspended in gelatine cubes at the time of administration to the animals. To prepare the gelatine cubes, 8g gelatine (Davis gelatine, Johannesburg, South Africa), 17 g brown sugar (Tongaat Hulett South Africa Ltd) and 5mL Bovril (Bovril, Uniliver, Johannesburg, South Africa) were mixed in 100 mL of boiling water (Kammerman *et al.*, 2004).

### **2.3.2. Feeds**

The experimental diet was high in carbohydrates and fats, and resembled a Western diet (Pickavance *et al.*, 1999). To prepare the high carbohydrate diet, 1.32 kg of normal rat chow powder, 280 g brown sugar (Tongaat Hulett South Africa Ltd), four cans (385 g) of condensed

milk (Nestle gold cross full cream sweetened condensed milk, Nestle South Africa) was mixed in 800 ml of boiling water. The high carbohydrate diet (experimental diet) consisted of 65 % carbohydrates derived from maize and simple carbohydrates (sugar), 19 % protein derived from soya and fish, 16% fat derived from milk products and fish (Majane *et al.*, 2009; du Toit *et al.*, 2008). The diet has previously been shown to induce hyperphagia (Pickavance *et al.*, 1999). To prepare the control diet, normal rat chow (Epol, South Africa) was mixed in water to make a similar pasty consistency to the high carbohydrate diet. In comparison, the control diet consisted of 60 % carbohydrates derived from maize, 30 % protein derived from soya and fish and 10 % fat derived from fish without milk products.

### **2.3.3. Housing of animals**

The animals were housed individually in standard rat cages with bedding of hard wood shavings, pieces of paper were added to the cages for environmental enrichment. The rats were kept in a controlled environment with a room temperature of  $22 \pm 1$  °C and 12 h light-dark cycle (lights on 07:00 to 19:00). The rats were allowed to adapt to the housing conditions and interventions (feeding and weighing) three days before the commencement of the experimental trials. The animals were given access to food and water *ad libitum*.

## **2.4. Analytical procedures**

### **2.4.1. Body mass**

The rats were weighed (Precisa balance 310M, Instrulab, Switzerland) twice a week to monitor growth performance. The body mass measurements also allowed for adjustment of the amount of *Aloe vera* and fenofibrate (SIGMA, USA) in the gelatine cubes to maintain a constant dosage rate over the 20-week study period.

### **2.4.2. Oral glucose tolerance test and measurement of fasting metabolic substrates (triglycerides and glucose)**

After the 20<sup>th</sup> week of intervention, the rats were fasted overnight, restrained in perspex rat restrainers for one hour and then blood was collected following a pin-prick of the tail with a sterile 21G needle (Loxham *et al.*, 2007). The collected blood was used to determine fasting glucose and triglycerides using a calibrated glucometer (Glucometer Elite ® 3947, Bayer Company, Japan) and a calibrated triglyceride meter (Accutrend triglycerides, Roche Company, Mannheim, Germany) respectively. Immediately after the fasting metabolic substrate measurements, an OGTT was performed to assess the rats' ability to tolerate a glucose load. The fasted rats were orally gavaged with glucose (3g.kg<sup>-1</sup>) made up at 50% w/v solution, D-Glucose, Sigma Aldrich) and blood was collected from the tail tip at 15, 30, 60, 120 and 180 min after glucose administration (Loxman *et al.*, 2007; Muellenbach, 2009). The blood glucose concentrations were determined using a glucometer as described earlier.

## **2.5. Terminal Procedures**

Following the OGTT the rats were put back on to their respective diets for 48 hours and then fasted for 12 hours before being euthanased by overdose of sodium pentobarbitone (Euthanaze, Centaur labs, Johannesburg, South Africa) administered intra-peritoneally at  $150 \text{ mg}\cdot\text{kg}^{-1}$  body mass.

### **2.5.1. Blood sampling and plasma processing**

After the animals were euthanased, blood samples were collected via cardiac puncture using 21G needles and 10ml syringes. Half of the blood (5 mL) was transferred into plain blood tubes (Geiner Bio-one GmbH, Austria) and the rest into EDTA tubes (Novo Nordisk Company, Johannesburg, South Africa). The blood samples were spun for 10 min at  $5000 \times g$  at  $10^{\circ}\text{C}$  in a centrifuge (SorvallRT @6000B, Pegasus Scientific Inc., Rockville USA). The plasma and serum were collected and then stored at  $-20^{\circ}\text{C}$  for the analysis of free fatty acids, insulin and markers of liver function.

### **2.5.2. Visceral measurements and histology**

After euthanasia, the thorax and abdomen were cut open by midline incision and the viscera namely the visceral fat (abdominal fat pad), liver, pancreas, stomach, caecum, large and small intestines were harvested and weighed (Precisa balance 310M, Instrulab, Switzerland). The intestines were gently stretched out on a board and their lengths were measured using a ruler. The stomach and the intestines were then emptied of their content and weighed. The mass of the liver was also recorded and part of the liver was stored at  $-20^{\circ}\text{C}$  for determination of lipid and glycogen content. Segments (1cm long) of the small intestine and the liver were collected for histology and stored in 10 % formalin in phosphate buffered saline. The intestinal segments and liver samples were routinely processed and stained using haematoxylin and eosin. The slides were viewed under a light microscope using an eye piece micrometer (Reichert®, Austria). For the small intestines the villus heights and crypt depths were measured. An assessment of morphometry of the liver was done under the light microscope to assess for signs of pathology. Using a high power magnification of 400X, the liver cell size and the number of cells within a linear field  $100\ \mu\text{m}$  was measured.

### **2.5.3. Determination of liver lipid content**

The procedure by Bligh and Dyer (1959) was followed for the extraction of lipids. Briefly, the frozen liver samples were thawed and 5-7 g of the frozen liver sample was steeped in 50 ml of chloroform methanol (2:1) (MERCK Chemicals, South Africa). The samples were then

incubated overnight at 4<sup>0</sup>C. The samples were filtered through a filter paper (Whatmann®, No 1 size 50 mm, England) into a separating funnel and 30 ml 0.9 % of saline was added and mixed thoroughly. The solution was then left overnight to separate into two layers. The bottom layer (chloroform) was collected into a round bottomed flask (SCOTT DURAN, Germany) and the lipids were recovered by evaporating the solvent at 37<sup>0</sup> C using a rotor evaporator (Labocon (Pty) Ltd, Krugersdrop, Transvaal, South Africa). The residual oil was then made up to 20ml with chloroform and stored at 4<sup>0</sup>C. To determine the percentage of lipids in each sample, an aliquot of 2 ml was collected into a dry pre-weighed vial and re-dried at 50<sup>0</sup>C, in an oven (Salvis ®, Oakton Instruments, USA). The mass of the lipid, multiplied by a factor of 10, was expressed as a percentage of the original weight of the liver sample.

#### **2.5.4. Determination of hepatic glycogen content**

Liver glycogen was determined by a method of indirect hydrolysis as described by Passonneau and Lauderdale (1974). In summary, 0.1 g liver sample was homogenized in 1ml of 0.03M HCl using an ultra turrex homogenizer (Janke & Kunkel GmbH & Co IKA-Werk D7813, Staufen). One milliliter of 1M HCl was then added to hydrolyse the glycogen, the tubes were sealed and allowed to stand in boiling water for 2 hours. A volume of 1mL 1M NaOH was then added to neutralise the acid before the determination of glucose. The glucose concentration was determined using a glucose-oxidase based reaction on Accu-Chek Active glucose meter (Roche, Germany). Glycogen concentration was reported as glucose equivalents in the homogenate.



### **2.5.5. Tibia lengths and masses**

The right femoral head was dissected away from the acetabulum at the hip joint and the soft tissues were removed from the bones (tibia). The length of the tibia was measured using a ruler. The bones were then dried in an oven (Salvis ®, Oakton Instruments, USA) at 40 °C for 7 days (until constant mass) and then weighed to determine their dry mass.

The density of the bones was calculated using the following formula:

$$\text{Bone density (mg.mm}^{-1}\text{)} = \text{Mass of the bone (mg)} / \text{length of the bone (mm)}$$

### **2.5.6. Plasma free fatty acid concentrations**

The concentration of free fatty acids in plasma was determined colorimetrically using a free fatty acids half-micro test kit (Roche Diagnostic, Germany) according to the manufacturer's instructions. All the reagents were supplied in the kit; however, additional reagents for the preparation of a palmitic acid standard solution were required and were supplied by SIGMA Aldrich (South Africa). The standard solution was prepared according to the manufacturer's instructions. The assay employed an optimized enzymatic colorimetric technique for free fatty acids. Standards, controls and samples were pipetted into 96 well polystyrene microplates. Absorbances were read using a spectrophotometer (Labsystems, Multiskan, Ascent, AEC Amersham) which measured the intensity of colour at a wavelength of 546 nm. According to

the manufacturer's instructions, the kit had a dilution limit of 1.5 mM free fatty acids. The concentrations of free fatty acids in each sample was then calculated using the formula:

$$C = (V/\epsilon \times d \times v) \times \Delta A \text{ (mM sample solution), where:}$$

C= Concentration (mM)

V= Final volume (ml)

v= Sample volume (ml)

d= light path (cm)

$\epsilon$ = absorption coefficient of dye at 546nm

$\Delta A$ = Absorbance difference

### **2.5.7. Measurement of liver enzymes and total bilirubin in serum**

The alkaline phosphatase (ALP) enzyme activity ( $\text{U.L}^{-1}$ ) was measured using a Reflotron machine (Reflotron<sup>®</sup>, Roche diagnostics LTD, Burgess Hill West Sussex, RH159RY, United Kingdom). The machine was calibrated according to manufacturer's instructions, after which drops of serum were placed on the test strips. The test strips for the alkaline phosphatase were Reflotron<sup>®</sup> (ALP) (Roche Diagnostics GmbH, Mannheim, Germany). The serum concentrations of total bilirubin (TBIL), gamma-glutamyl transferase (GGT) and alanine

transaminase (ALT) were measured using a calibrated colorimetric chemistry analyser (IDEXX VetTest ® Chemistry Analyser, The Netherlands).

### **2.5.8. Insulin measurements**

The hormone insulin was determined by enzyme linked immunosorbent assay (ELISA) using a Rat insulin kit (DRG ®, Rat Insulin High Range, USA) according to manufacturer's instructions. The manufacturers indicate that the kit is 100% specific and has been validated for the determination of rat insulin. All reagents and plates were supplied in the kit. The assay employed a quantitative sandwich enzyme immunoassay technique which utilizes a monoclonal antibody specific for rat insulin. Absorbencies were measured at 450 nm using a plate reader (Multiskan Ascent, Lab system, model n° 354, Helsinki, Finland). A standard curve was constructed and the concentrations of insulin in the samples were determined. The kit had a detection limit of  $1.5\mu\text{g.L}^{-1}$ .

The fasting glucose levels and insulin data were then used to determine fasting whole-body insulin sensitivity using the homeostasis model assessment of insulin resistance (HOMA-IR) by using the formula described by Mathews *et al.*, 1985:

$$[\text{Fasting plasma glucose (mg.dl}^{-1}) \times \text{fasting plasma insulin (}\mu\text{U.mL}^{-1})] / 405$$

### **2.5.9. Statistical analysis**

All data are expressed as mean  $\pm$  standard error of mean (SEM). A one way analysis of variance (ANOVA), followed by a Bonferroni *post hoc* test, was used to detect differences between the groups to assess the effect of *Aloe vera* on the parameters measured. A repeated measures ANOVA was used for statistical analyses of the OGTT. Statistical significance was accepted at  $p < 0.05$ . All the statistical analysis was performed using Graph Pad Prism version 5.0 (Graph Pad software, San Diego, C.A).

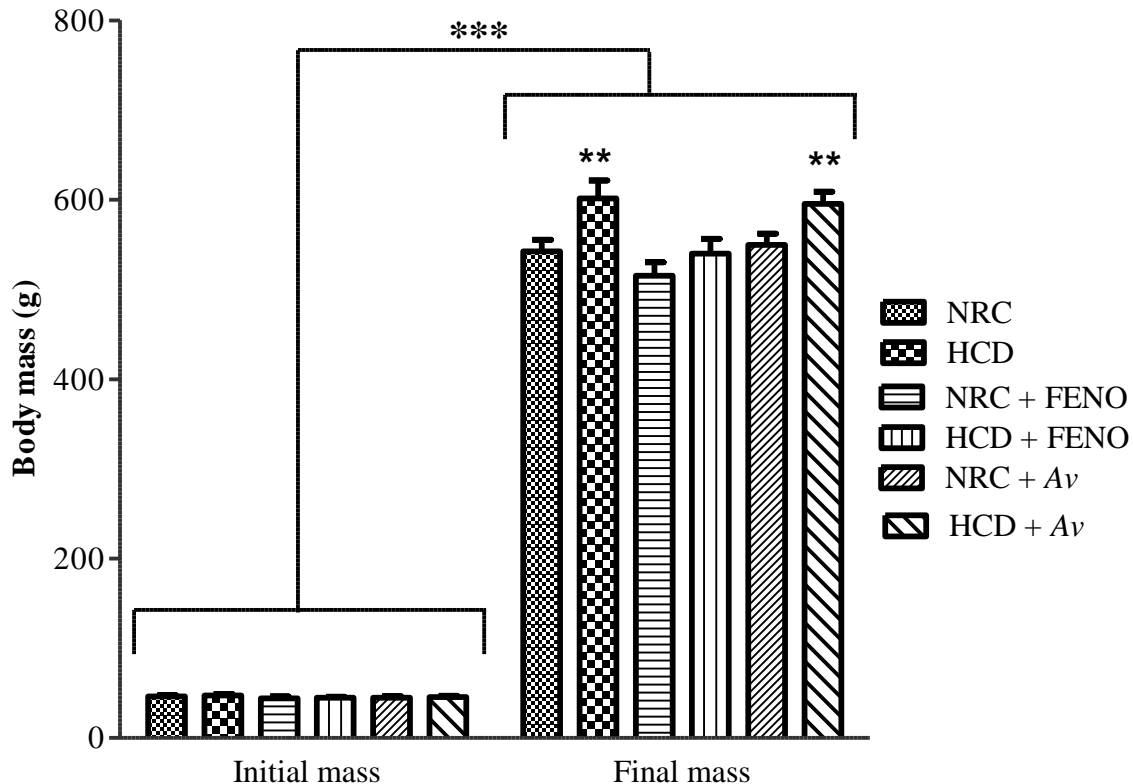
# **CHAPTER THREE-RESULTS**

### **3.1. Mortality and morbidity of the animals**

During the study, all the animals remained healthy and consequently no incidental or iatrogenic rat mortalities were recorded.

### **3.2. The effects of *Aloe vera* leaf extract on body mass gain**

Figure 3.1 shows the initial and terminal body masses of the rats. There was no significant difference observed ( $p > 0.05$ ) in the initial body mass between the rats in the different groups. After 20 weeks on the various treatments, all animals had a significant increase in body mass gain ( $p < 0.0001$ ). The rats fed a HCD had significantly ( $p < 0.001$ ) higher body masses as compared to the other groups, however fenofibrate administration prevented the HCD-induced increase in body mass whilst *Aloe vera* administration had no significant effect.



**Figure 3.1. Effect of *Aloe vera* leaf extract on body mass gain**

**Key:** NRC, normal rat chow; HCD, high carbohydrate diet; FENO, fenofibrate ( $100 \text{ mg.kg}^{-1}$ ); *Av*, *Aloe vera* ( $300 \text{ mg.kg}^{-1}$ ). The data in figure 3.1 show that there were no differences ( $p > 0.05$ ) in the initial body mass of rats ( $n = 59$ ) allocated to the different groups at 3 weeks of age (initial mass), however all rats had a significant increase in body mass after 20 weeks (final mass) of intervention. Rats fed a HCD had a significantly increased body mass compared to others after 20 weeks of intervention; however, fenofibrate administration prevented the diet-induced increase in body mass whilst *Aloe vera* had no significant effect. Data is represented as mean  $\pm$  SEM. \*\*:  $p < 0.001$ ; \*\*\*:  $p < 0.0001$ .

### **3.3. The effect of *Aloe vera* leaf extract on the linear growth (tibia)**

There were no significant differences observed in the lengths of the tibia (Table 3.1) between the groups ( $p > 0.05$ ). There were also no significant differences in the tibia masses and densities of the bones.



**Table 3.1 Effect of *Aloe vera* leaf extract on the length and mass of the tibias of growing rats.**

	NRC	HCD	NRC + FENO	HCD + FENO	NRC + <i>Av</i>	HCD + <i>Av</i>
	n=10	n=10	n=9	n=10	n=10	n=10
<b>Tibia</b>						
Length (mm)	44.70±0.45	44.20±0.51	44.00±0.97	42.40±0.82	44.60±0.64	43.00±0.67
Mass (mg)	0.86±0.04	0.78±0.04	0.88±0.06	0.78±0.10	0.90±0.07	0.91±0.04
Density (mg.mm <sup>-1</sup> )	0.02±0.00	0.02±0.00	0.02±0.00	0.02±0.00	0.02±0.00	0.02±0.00

**Key:** NRC, normal rat chow; HCD, high carbohydrate diet; FENO, fenofibrate; *Av*, *Aloe vera*. The results in this table show that there were no significant ( $p>0.05$ ) differences between the groups. Data is represented as mean  $\pm$  SEM. n= 10 per group except for NRC + FENO where n= 9.

### **3.4. The effect of *Aloe vera* leaf extract on circulating insulin and metabolic substrates**

Table 3.2 shows the circulating levels of metabolic substrates and insulin of the growing rats after the 20-week intervention. There was no significant difference ( $p>0.05$ ) in the plasma concentrations of free fatty acids, insulin, HOMA-IR, fasting glucose and triglycerides between the groups.

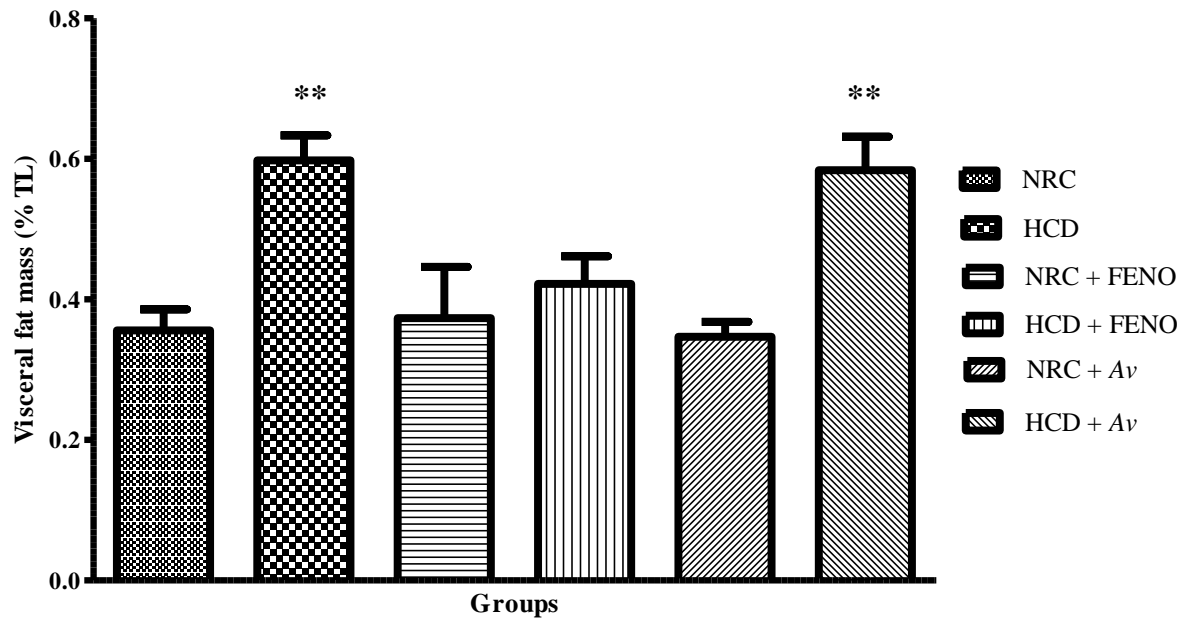
**Table 3.2: Effect of *Aloe vera* leaf extract on fasting concentrations of metabolic substrates and circulating insulin.**

	NRC n=10	HCD n= 10	NRC+FENO n= 9	HCD + FENO n= 10	NRC + Av n= 10	HCD + Av n= 10
Glucose (mmol.L <sup>-1</sup> )	3.61±0.16	3.74±0.12	3.87±0.16	3.77±0.15	3.64±0.15	3.69±0.16
FFAs (mM)	0.21±0.04	0.20±0.02	0.15±0.01	0.19±0.04	0.19±0.01	0.16±0.01
TGs (mmol.L <sup>-1</sup> )	1.54±0.09	1.96±0.13	1.45±0.23	1.77±0.20	1.26±0.02	1.42±0.11
Insulin (µg.L <sup>-1</sup> )	124.60±11.71	141.37±16.94	139.95±16.03	135.17±18.81	159.68±11.69	123.38±14.80
HOMA-IR	20.05±2.13	23.40±3.08	24.05±2.88	22.23±2.87	25.71±1.83	20.32±2.62

**Key:** FFAs, free fatty acids; TGs, triglycerides; NRC, normal rat chow; HCD, high carbohydrate diet; FENO, fenofibrate; Av, *Aloe vera*; HOMA-IR, homeostasis model assessment of insulin resistance (HOMA-IR) . The results in this table indicate that there were no differences in circulating metabolic substrates, insulin and the HOMA-IR in all the groups ( $p>0.05$ ). Data is presented as mean  $\pm$  SEM. n= 10 per group except for NRC + FENO where n= 9.

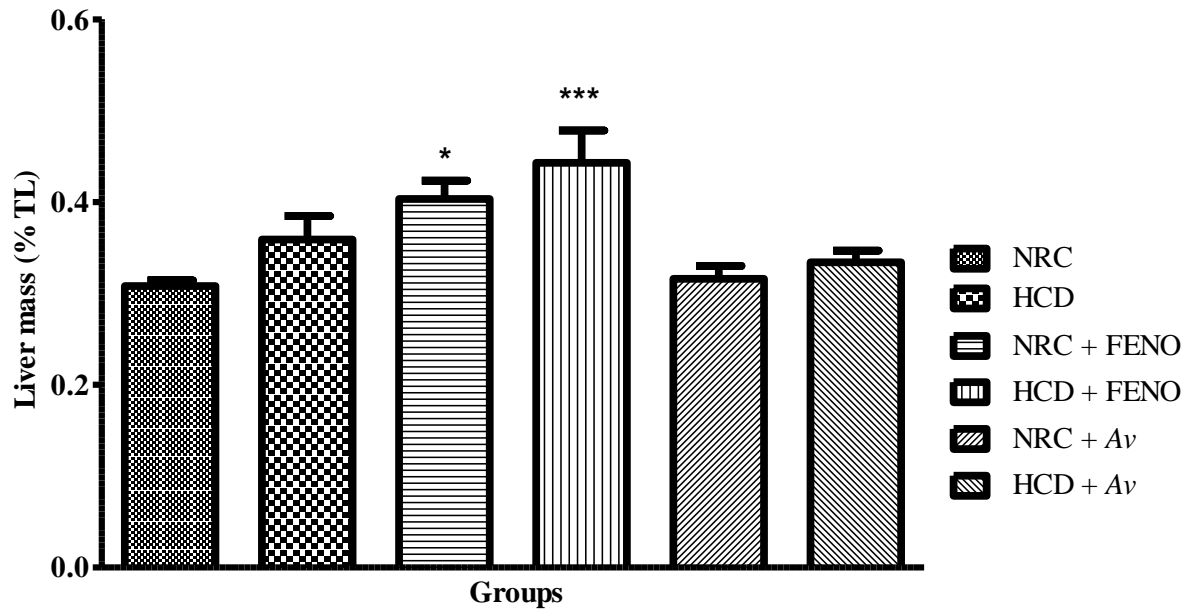
### **3.5. Effects of *Aloe vera* leaf extract on abdominal visceral organ morphometry and morphology**

Due to observed differences in body mass of the rats after the interventions, when considering the relative mass/length of the visceral organs, I also expressed them relative to tibia length, which was not significantly different between the groups. Figure 3.2 shows the relative mass of the visceral fat of the growing rats after the interventions. Feeding rats a HCD significantly ( $p=0.003$ ) increased the visceral fat mass. Fenofibrate administration prevented the HCD-induced visceral fat mass gain whilst *Aloe vera* administration had no effect. Figure 3.3 shows the relative mass of the liver of the growing rats after the interventions. There was a significant increase in the relative mass of the liver of growing rats administered fenofibrate. Table 3.3 shows that there was no significant difference in the absolute mass of the large intestine, however, when considering the large intestine mass relative to tibia length, rats fed a HCD alone had significantly lower large intestine mass than others. There was no significant difference in the absolute stomach mass across the groups, however when considering the relative mass of the stomach, rats fed a NRC+FENO had significantly ( $p<0.0001$ ) higher mass than others. The diets, drug intervention and *Aloe vera* had no significant effect on the small intestinal villus height and crypt depth ( $p>0.05$ ) (Table 3.4). There were no signs of histopathology in the microscopic examination of the liver (data not shown). There were no significant differences in the cell size (NRC=  $6.10 \pm 0.23 \mu\text{m}$ ) vs (FENO=  $6.56 \pm 0.24 \mu\text{m}$ ) of the hepatocytes and the number of cells per 100  $\mu\text{m}$  length of a high power field (NRC=  $10.32 \pm 0.19 \mu\text{m}$ ) vs (FENO=  $10.39 \pm 0.18 \mu\text{m}$ ).



**Figure 3.2. Effect of *Aloe vera* leaf extract on visceral fat mass**

**Key:** NRC, normal rat chow; HCD, high carbohydrate diet; FENO, fenofibrate ( $100 \text{ mg.kg}^{-1}$ ); *Av*, *Aloe vera* ( $300 \text{ mg.kg}^{-1}$ ); TL, tibia length. The data in Figure 3.2 shows that after 20 weeks of intervention the relative mass of the visceral fat (expressed as a percentage tibia length) of the rats fed a HCD was significantly greater than the rats in the other groups, however fenofibrate administration prevented the diet-induced increase in visceral fat mass whilst *Aloe vera* had no effect. The data is presented as mean  $\pm$  SEM. \*\*:  $p < 0.003$ .  $n = 10$  per group except NRC + FENO where  $n = 9$ .



**Figure 3.3. Effect of *Aloe vera* leaf extract on the liver mass**

**Key:** NRC, normal rat chow; HCD, high carbohydrate diet; FENO, fenofibrate ( $100 \text{ mg.kg}^{-1}$ ); *Av*, *Aloe vera* ( $300 \text{ mg.kg}^{-1}$ ); TL, tibia length. The data in Figure 3.3 shows that after 20 weeks of intervention the mass of the liver (expressed as a percentage tibia length) of the rats administered with fenofibrate was significantly greater than that of rats in the other groups whilst *Aloe vera* had no significant effect. Data is presented as mean  $\pm$  SEM. \*:  $p < 0.05$ ; \*\*\*:  $p < 0.0001$ .  $n = 10$  per group except NRC + FENO where  $n = 9$ .

**Table 3.3: Effect of *Aloe vera* leaf extract on the absolute mass and the mass (% relative to tibia length) of the viscera and, length of GIT segments of growing rats.**

<b>Organs</b>	NRC	HCD	NRC + FENO	HCD + FENO	NRC + Av	HCD + Av
	n=10	n=10	n=9	n=10	n=10	n=10
Visceral fat (g)	15.90 ± 1.31	26.42 ± 1.56**	16.64 ± 3.40	17.74 ± 1.52	15.55 ± 0.99	25.11 ± 2.26**
Liver (g)	13.69 ± 0.38	15.92 ± 1.17	17.92 ± 0.85*	18.84 ± 1.26*	14.10 ± 0.57	14.33 ± 0.49
LI (g)	2.47 ± 0.09	2.05 ± 0.10	2.20 ± 0.06	2.03 ± 0.07	2.33 ± 0.08	1.99 ± 0.09
LI (g) (%TL)	5.51 ± 0.15	4.62 ± 0.20*	5.04 ± 0.24	4.81±0.21	5.24±0.17	5.24±0.17
LI (mm)	248.50 ± 6.91	223.00 ± 9.07	252.22 ± 8.94	230.00 ± 9.19	253.00 ± 9.43	241.00 ± 6.23

---

**Table 3.3 cont.**

SI (g)	8.72 ± 2.77	9.32 ± 2.94	9.38 ± 3.14**	8.94 ± 2.77	9.25 ± 2.96	9.00 ± 2.85
SI (g) (%TL)	19.46 ± 1.35	21.09 ± 0.70	21.46 ± 0.88	21.22 ± 0.98	20.72 ± 0.58	20.96 ± 0.74
SI (mm)	1395.00 ± 19.69	1288.00 ± 18.90	1387.78 ± 17.78	1320.50 ± 14.80	1396.00 ± 33.41	1328.00 ± 31.6
Stomach (g)	2.26 ± 0.14	2.25 ± 0.10	2.62 ± 0.05	2.23 ± 0.07	2.40 ± 0.08	2.20 ± 0.06
Stomach (g) (%TL)	5.06 ± 0.30	5.09 ± 0.19	5.97 ± 0.19*	5.27 ± 0.17	5.38 ± 0.15	5.11 ± 0.15
Pancreas (g)	1.67 ± 0.14	1.62 ± 0.11	1.78 ± 0.13	1.65 ± 0.15	1.68 ± 0.09	1.58 ± 0.09
Pancreas (g) (%TL)	3.71 ± 0.27	3.66 ± 0.23	4.24 ± 0.35	3.89 ± 0.34	3.78 ± 0.22	3.68±0.24

---



---

**Table 3.3 cont**

Caecum (g)	1.67 ± 0.04	1.51 ± 0.071	1.60 ± 0.13	1.61 ± 0.11	1.66 ± 0.05	1.57 ± 0.08
Caecum (g) (%TL)	3.75 ± 0.09	3.41 ± 0.17	3.68 ± 0.37	3.81 ± 0.29	3.74 ± 0.14	3.66 ± 0.22

---

**Key:** BM, body mass; SI, small intestine; LI, large intestine; g, gram. NRC, normal rat chow; HCD, high carbohydrate diet; FENO, fenofibrate; *Av*, *Aloe vera*; TL, tibia length; *cont*, continued. Data is presented as mean ± SEM. Data in the same row indicate significant differences. n= 10 per group except NRC + FENO where n=9. \*: p<0.02, \*\*: p<0.006. The results in this table indicate feeding rats a HCD resulted in a higher (ANOVA; p<0.003) visceral fat mass than the other groups. Fenofibrate administration prevented the HCD-induced visceral fat mass gain whilst *Aloe vera* administration had no effect. There was a significant increase (p<0.0001) observed in the relative mass of the liver of growing rats administered fenofibrate.

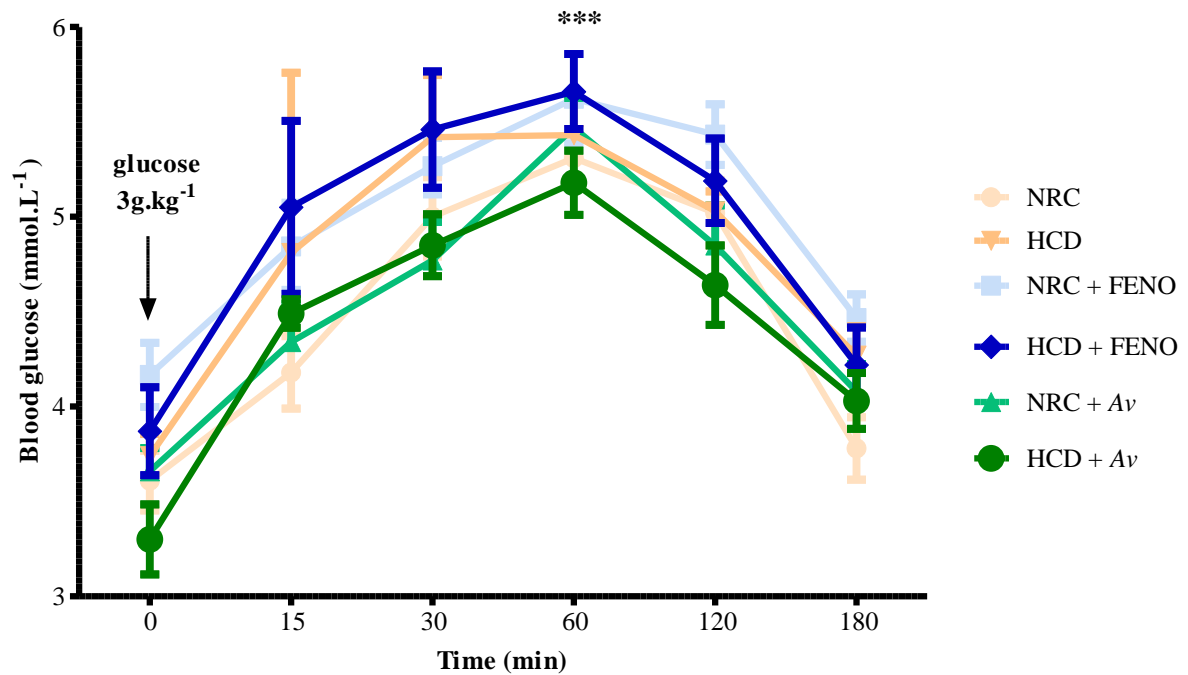
**Table 3.4: Effect of a crude *Aloe vera* leaf extract on microscopic measurements of small intestine in growing rats.**

		NRC	HCD	NRC+FENO	HCD+FENO	NRC + Av	HCD + Av
		n=10	n=10	n= 9	n= 10	n=10	n= 10
Villus ( $\mu\text{m}$ )	Height	49.20 $\pm$ 3.02	53.40 $\pm$ 4.48	47.75 $\pm$ 3.28	58.60 $\pm$ 2.56	51.20 $\pm$ 1.85	48.80 $\pm$ 1.59
Crypt ( $\mu\text{m}$ )	depth	22.20 $\pm$ 0.80	19.80 $\pm$ 0.97	21.00 $\pm$ 0.41	23.00 $\pm$ 0.84	20.02 $\pm$ 0.58	18.80 $\pm$ 1.59
VH/CD ratio		2.22 $\pm$ 0.10	2.70 $\pm$ 0.16	2.27 $\pm$ 0.16	2.54 $\pm$ 1.10	2.53 $\pm$ 0.08	2.59 $\pm$ 0.19

**Key:** NRC, normal rat chow; HCD, high carbohydrate diet; FENO, fenofibrate; Av, *Aloe vera*. VH, Villus height; CD, crypt depth (VH/CD). Results in this table indicate that the morphometry of the small intestine villi and crypts was not significantly ( $p > 0.05$ ) affected after 20 weeks of feeding *Aloe vera* extract. n= 10 per group except NRC + FENO where n=9.

### **3.5. The effect of *Aloe vera* leaf extract on the response to an oral glucose load**

Figure 3.4 shows the results of the glucose tolerance test for all groups. The basal glucose concentrations were within the normal range i.e. 3.9 to 5.5 mmol.L<sup>-1</sup>. There was a significant increase in blood glucose levels following the glucose load with the peak blood concentrations attained between 30 and 60 minutes. There were no significant differences between the treatment groups. The blood glucose levels returned to basal levels by 180 minutes in all the groups.



**Figure 3.4. Effects of *Aloe vera* leaf extract on the response to an oral glucose load**

**Key:** NRC, normal rat chow; HCD, high carbohydrate diet; FENO, fenofibrate ( $100 \text{ mg.kg}^{-1}$ ); *Av*, *Aloe vera* ( $300 \text{ mg.kg}^{-1}$ ). The data in Figure 3.4 show the changes in blood glucose concentration following the oral administration of  $3 \text{ g.kg}^{-1}$  glucose solution to fasted rats. There was no significant difference in fasting glucose levels (time 0). There was a significant increase in blood glucose following glucose administration in all the groups. The peak blood glucose concentration which occurred between 30 and 60 minutes, were significantly higher than basal fasting glucose levels, and returned to basal levels by 180 minutes in all groups. \*\*\*:  $p < 0.0001$ .  $n=10$  per group except NRC + FENO where  $n=9$ .

### **3.7. The effect of *Aloe vera* leaf extract on liver enzymes and total bilirubin**

Rats fed a NRC+ Av had significantly lower TBIL ( $p < 0.02$ ) as compared to rats fed a HCD. The ALP levels were significantly higher ( $p > 0.01$ ) in the FENO group, however no significant differences were observed in ALT levels between the groups (Table 3.5). GGT levels were below the detectable range ( $1-6 \text{ U.L}^{-1}$ ) for the diagnostic equipment (VetLab) used for the assay in all the groups.

**Table 3.5: Effect of *Aloe vera* extract on the liver enzymes (ALT, ALP and GGT) and total bilirubin of the growing rats.**

	NRC	HCD	NRC+FENO	HCD+FENO	NRC + Av	HCD + Av
	n= 10	n= 10	n= 9	n= 10	n= 10	n= 10
ALP (U.L <sup>-1</sup> )	202.30±22.12	140.30±9.07	270.25±15.44**	158.67±15.74	234.67±19.04	125.67±11.68
ALT (U.L <sup>-1</sup> )	20.21±1.03	25.21±6.22	23.93±3.74	32.76±3.84	22.84±3.08	22.17±4.93
TBIL(μmol.L <sup>-1</sup> )	6.17±0.40	9.67±1.28	7.67±1.17	9.17±2.27	3.33±1.33*	4.67±0.80
GGT	nd	nd	nd	nd	nd	nd

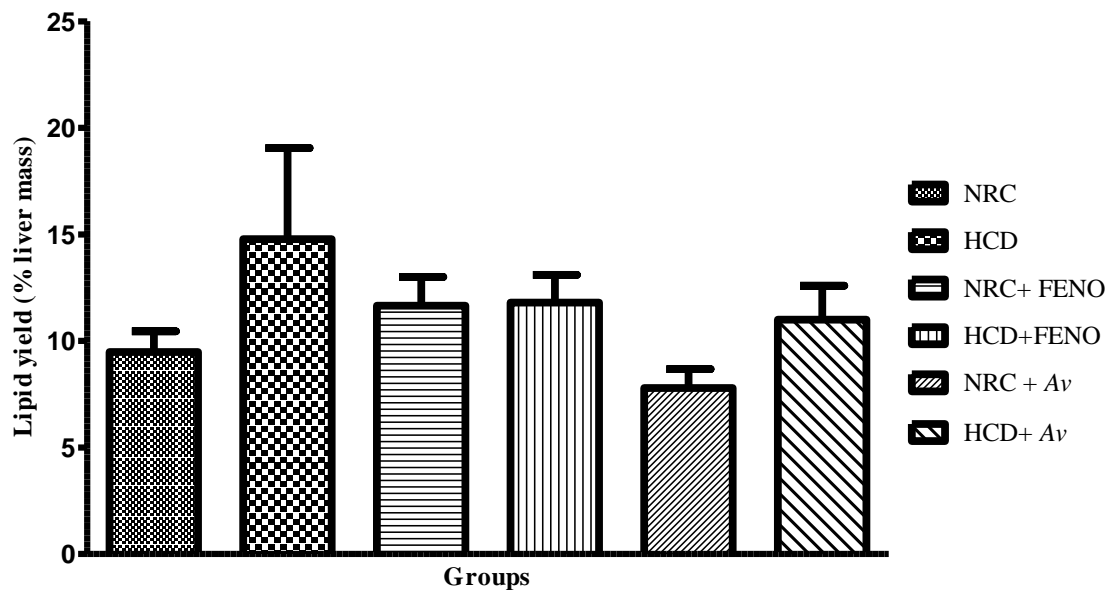
**Key:** NRC, normal rat chow; HCD, high carbohydrate diet; ALP, alkaline phosphatase (normal range (36-126 U.L<sup>-1</sup>); ALT, alanine transaminase TBIL, total bilirubin; LM, liver mass; FENO, fenofibrate (100 mg.kg<sup>-1</sup>); Av, *Aloe vera* (300 mg.kg<sup>-1</sup>); nd, not detectable. The results in this table indicate that there were significantly (p<0.05) higher ALP levels in the NRC + FENO group as

compared to others. TBIL levels were significantly ( $p < 0.05$ ) lower in the NRC + Av group, however no differences were detected in ALT levels in all the groups ( $p > 0.05$ ). Data is represented as mean  $\pm$  SEM.  $n = 10$  per group except NRC + FENO where  $n = 9$ . \* $p < 0.02$ ; \*\* $p < 0.01$ .

### **3.8. The effect of *Aloe vera* leaf extract on hepatic lipid and glycogen content**

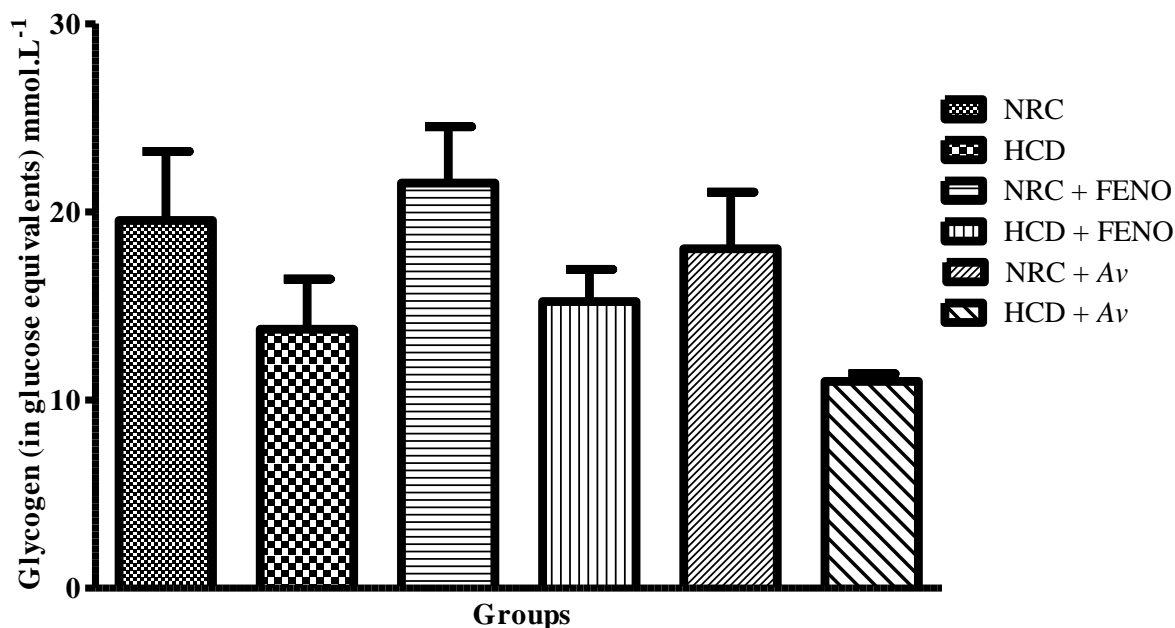
There were no significant ( $p>0.05$ ) differences observed in the hepatic lipid content (Figure 3.5) and in the hepatic glycogen content (Figure 3.6).





**Figure 3.5. Effect of *Aloe vera* leaf extract on hepatic lipid content of growing rats**

**Key:** NRC, normal rat chow; HCD, high carbohydrate diet; FENO, fenofibrate (100 mg.kg<sup>-1</sup>); Av, *Aloe vera* (300 mg.kg<sup>-1</sup>). The data in Figure 3.5 shows that there were no significant ( $p > 0.05$ ) differences observed in the hepatic lipid content of treated rats. Data is presented as mean  $\pm$  SEM. n=10 per group except NRC + FENO where n=9.



**Figure 3.6. Effect of *Aloe vera* leaf extract on hepatic glycogen content of growing rats**

**Key:** NRC, normal rat chow; HCD, high carbohydrate diet; FENO, fenofibrate (100 mg.kg<sup>-1</sup>); Av, *Aloe vera* (300 mg.kg<sup>-1</sup>). The data in Figure 3.6 shows that there were no significant ( $p > 0.05$ ) differences observed in the hepatic glycogen content of treated rats. Data is presented as mean  $\pm$  SEM. n=10 per group except NRC + FENO where n= 9

## **CHAPTER FOUR- DISCUSSION**

The present study investigated the effects of a crude whole leaf *Aloe vera* extract on a diet-induced metabolic dysfunction. The aim of this study was to establish an animal-based model of diet-induced metabolic dysfunction and explore whether administration of *Aloe vera* would delay the development of metabolic dysfunction as measured by some makers of metabolic dysfunction i.e. circulating metabolic substrates, insulin levels, and visceral obesity. The possible adverse effects of the extracts were also assessed by determining markers of liver function and histology. Fenofibrate was used as a positive control.

The high carbohydrate diet led to a significant increase in body mass gain and manifestation of central obesity i.e. increased visceral fat mass. The increase in body mass gain observed in rats fed a high carbohydrate diet in the present study is in line with a previous study by Majane *et al.*, (2009) who observed that adult rats assigned to a similar diet for five months showed an increased body mass gain in comparison to rats on a normal diet.

In the present study, *Aloe vera* did not prevent the high carbohydrate diet-induced increase in body mass, which fenofibrate administration was able to prevent. Studies have shown that fenofibrate significantly reduced body mass in animal models of genetic diet-induced increase in body mass (Carmona *et al.*, 2005).

There was a significant increase in the mass of visceral fat of rats fed a high carbohydrate diet in comparison with the control. Fenofibrate administration prevented the increase in visceral fat mass. However, *Aloe vera* administration did not significantly prevent the diet-induced increase in visceral fat mass. My findings with *Aloe vera* are in contrast to previous studies using other animal models of metabolic dysfunction which have shown that *Aloe vera*-derived

phytosterols prevented the increase in the visceral fat mass (Misawa *et al.*, 2008) in diabetic Zucker fat rats. The increase in visceral fat might have contributed to the increased body mass in rats fed a high carbohydrate diet. Excess consumption of carbohydrates is associated with an increased visceral obesity (Slyper, 2004). Dietary carbohydrates are stored as glycogen in the liver, however, when glycogen storage is at a maximum, the only pathway for storage of glucose is the conversion into fats. Excess fats then accumulate in the abdominal adipose tissue hence causing visceral obesity (Flatt, 1970).

Changes in body mass may be influenced by several factors such as hydration status and prandial state therefore body mass is unreliable measurement for growth (Yin *et al.*, 1982). The tibial length has been used in several studies as a more accurate indicator of linear growth (Eshet *et al.*, 2004). To further explore the effects of *Aloe vera* on growth, I investigated the effects of *Aloe vera* on tibial length and mass. The tibial masses and lengths were not significantly affected by the exposure to the different treatments and diets. However, this is in contrast to previous studies which have shown that oral administration of *Aloe vera* resulted in an increase in tibial length, which the authors suggested could have resulted from an increase in metaphyseal bone tissue (Cho *et al.*, 2001).

Several studies show that a high intake of carbohydrate plays a major role in the development of increased visceral fat and abdominal obesity, which can lead to the development of insulin resistance (Basciano *et al.*, 2005). I further investigated the adverse effect of exposure to the high carbohydrate diet and increased abdominal obesity by performing an oral glucose tolerance test, which is an index for insulin resistance (Loxman *et al.*, 2007; Muellenbach,

2009) and can reveal a pre-diabetic state. Despite the diet-induced increased visceral adiposity, there were no abnormalities observed in the oral glucose tolerance indicating that the rats were not in a pre-diabetic state. Plasma insulin levels, as well as the homeostasis model assessment of insulin resistance were not affected by the different treatments. The precise mechanism of the high carbohydrate diet in the induction of insulin resistance is not well understood, however many animal studies have examined the genetic modification in the context of diet-induced metabolic dysfunction (Buettner *et al.*, 2006).

The present study showed that long-term *Aloe vera* administration had no significant effect on fasting blood glucose levels. Previous studies in diabetic patients administration of *Aloe vera* decreased blood glucose levels (Agarwal, 1985). In addition Ghannam *et al.* (1986) found that there were hypoglycemic agents present in *Aloe vera* that lowered blood glucose in Alloxan-diabetic mice.

The results obtained from this study also showed no significant differences between the fasting levels of circulating triglycerides of the rats in the different treatment groups. Several studies have shown that diets rich in carbohydrates may cause elevated triglycerides levels (Parks, 2002). *Aloe vera* has been shown to lower fasting triglycerides levels in rat models of streptozotocin-induced diabetes (Rajasekaran, 2004). Fenofibrate which I used as a positive control agent also did not significantly affect fasting triglyceride concentrations in my study. Chaput *et al.* (2000) found that fenofibrate did not only reduce body weight but it also resulted in the reduction of circulating triglycerides in (*fa/fa*) fatty Zucker rats and *db/db* mice.

The liver is one of the largest organs in the body that serves as a metabolic powerhouse for the processing of nutrients, absorption of lipids and glycogen storage to maintain energy levels (Koeppen and Stanton, 2008). Several studies have shown that hepatic lipid and glycogen content are affected by dietary treatment (Weigand *et al.*, 1980). There were no significant differences observed in fasting hepatic lipid and glycogen storage of all the treatment groups. Research has shown that starvation may decrease lipid composition and glycogen (Weigand *et al.*, 1980). Therefore, it can be speculated that the non-significant differences in hepatic lipid content and glycogen content may have been due to fasting the animals which could have depleted the hepatic lipid and glycogen content in rats fed a high carbohydrate diet to control levels in my study. Thus, future studies should be done to assess the levels of the metabolic substrates in non-fasted animals.

In the present study, I observed a distinct liver enlargement in rats administered fenofibrate, but the hepatomegally was without any signs of hepatic steatosis. These observations were in line with previous studies where it was observed that long-term administration with the PPAR- $\alpha$  agonist induces hepatomegally (Hong *et al.*, 2007). So although in my study fenofibrate administration from an early age of the rats prevented the diet-induced increase in visceral adiposity, which might be medically beneficial, the side effects need to be taken into consideration.

To further investigate the potential hepatotoxic effects of the treatments, I investigated markers of liver function (ALP, ALT, TBIL and GGT). The liver has a number of functions,

including metabolism and detoxification of several substances in the body. Since the liver cells are exposed to toxins, they are therefore at risk of damage (Gaskill *et al.*, 2004). Alanine aminotransferase (ALT) is an enzyme present in hepatocytes. When hepatocytes are damaged, the cells leak this enzyme into the blood. ALT is therefore useful as a marker for liver damage. There are several isoenzymes of Alkaline phosphatase (ALP) found in different tissues. ALP is an enzyme in the cells lining the biliary ducts of the liver. ALP levels in plasma rise with large bile duct obstruction. ALP is also present in bone so it is higher in growing animals as their bones are being remodeled (Nyblom *et al.*, 2006). The GIT also produces ALP in rats (Zafar *et al.*, 2009). There were no significant differences in the circulating concentrations of ALT in different groups of rats; these results suggest that there was no liver damage. However, the levels of alkaline phosphatase were increased only in the group receiving a normal rat chow and fenofibrate, but not in the group receiving a high carbohydrate diet and fenofibrate. Previous studies suggest that the increase in circulating ALP concentrations following fenofibrate treatment is not considered to be clinically significant (Dohmen *et al.*, 2005). Some of the serum ALP may come from the duodenal mucosa which contain two isoforms of the enzyme (Iwao *et al.*, 1987; Koyama *et al.*, 1987). Concentrations of total bilirubin were reduced in the group fed with normal rat chow and *Aloe vera*. However, in previous studies, the total bilirubin levels of rats treated with *Aloe vera* were not affected when compared to the control group (Saritha and Anilakumar, 2010). Due to unavailability of equipment, it was not possible to identify the specific isoforms present in the rats in my study.



The principal role of the gastrointestinal tract (GIT) is to digest and absorb food, therefore apart from nutrients, the GIT is also exposed to ingested bacteria and other potentially harmful substances. Thus, the GIT has to adapt to various dietary changes (Yegani and Korver. 2008). The gastrointestinal tract therefore undergoes extensive structural and functional changes such as an alteration of the small intestinal villi and crypts (Traber and Silberg, 1996) and absorption capacity (Van Beers *et al.*, 1998). Hence, evaluation of morphological changes can be used in the diagnosis and assessment of intestinal pathology (Weser and Tawil. 1976).

In this present study, it was found that no significant changes occurred in the gross morphometry of the large intestine, caecum and the stomach other than the small intestine. However, the relative mass of the large intestine was reduced in rats on the high carbohydrate diet alone. This could be attributable to a possible lower level of fibre in the HCD. Fibre is important for the development of the large intestine (Eastwood, 1992). In a study in which suckling rats were administered *Aloe vera* extracts they found an increase in caecal mass (Beya *et al.*, 2012). The presence of osmotically active or fermentable substances that are not absorbed from the small intestine may affect the GIT flora and influence caecum weight (Baltrop and Brueton, 1990). The increased large intestine mass could thus have been due to the presence of complex carbohydrates in the *Aloe* extracts resulting in the development of the flora which affects the production of volatile fatty acids and improved digestibility in rats (Reddy, 1971). It is noteworthy as well that there was no reduction in mass of the large intestine in rats fed the HCD and fenofibrate. The mass of the small intestine of rats fed normal rat chow and fenofibrate was also significantly increased but not in the other groups. The mechanisms underlying these effects of fenofibrate require further investigation.

I further investigated the possibility of micropathology of the small intestines; the intestinal morphology appeared to be normal. There were no differences in the villus heights between the groups. Although the morphology of the small intestines was not affected, the function of the GIT could have been affected, hence further studies should investigate the function of the small intestine to evaluate its absorptive and secretory capacity.

# **CHAPTER FIVE- CONCLUSION AND RECOMENDATIONS**

*Aloe vera* has been used for many decades. The present study has shown that weaning rats onto a high carbohydrate diet and feeding them the diet for 20 weeks resulted in the development of visceral obesity without altering the glucose tolerance, metabolic substrates and morphology. The animal model used thus did not result in the full development of metabolic syndrome. Other studies have generally used adult animals at the commencement of their studies, a period at which the rats have past the rapid growth phase. My use of young growing animals could have resulted in most of the dietary nutrients being channeled into rapid growth and hence the lack of excessive obesity. A longer feeding period would be recommended for future studies. The findings from the present study showed that the administration of fenofibrate prevented the high carbohydrate diet-induced visceral obesity whereas treatment with the *Aloe vera* leaf preparation was ineffective. However, the treatment with fenofibrate from an early age resulted in hepatomegally, the long-term functional significance of which requires further investigation.

The present study involved the use of a crude leaf preparation; future studies should be conducted to compare the effect of a crude leaf and gel extract to evaluate their relative effectiveness. Future research should also be conducted to isolate the active constituents of the plant to provide a better understanding of its phytochemicals and the positive effects that have been noted by others.

Although the findings in this study may assist in filling gaps on the effect of *Aloe vera* on diet-induced metabolic dysfunction in growing children, the study has some limitations. My results suggest that *Aloe vera* administration at 300 mg.kg<sup>-1</sup> through gelatine cubes did not have a

significant effect, perhaps for future studies it would be a good idea to change the method of administration as the gelatine cubes may have also had an effect on the activity on the constituents of *Aloe vera*.

Understanding the liver metabolic gene profile as the liver plays a major role in metabolism would be interesting. Therefore, for future studies it would be worthwhile to measure gene and protein expression.

## **CHAPTER SIX-REFERENCES**

- Agarwal, O.P. (1985) Prevention of atheromatous heart disease. *Angiology*, 36: 485-492.
- Ashcroft, F.M. and Gribble, F.M. (1999) ATP-sensitive K1 channels in health and disease. *Diabetologia*, 42: 903–919.
- Atherton, P. (1998) *Aloe vera*: magic or medicine? *Nurs Stand*, 12: 49-52.
- Baltrop, D. and Brueton, T.M. (1990) The gastrointestinal tract and short-term toxicity test. In: P.J., Bordeau, Editor, short-term Toxicity test for non-genotoxic effects, John Wiley and Sons Ltd 99-110.
- Beya, W.B., Davidson, B. and Erlwanger, K.H. (2012) The effects of a crude aqueous and alcohol extracts of *Aloe vera* on the gastrointestinal tract and accessory organs of suckling rats. *Af J Tradit Comp Alt Med*, 9: 553-560.
- Buettner, R., Parhofer K.G., Woenckhaus, W., Wrede, C.E., Kunz-Schughart, L.A., Schölmerich, J. and Bollheimer, L.C. 2006. Defining high-fat-diet rat models: metabolic and molecular effects of different fat types. *J Mol Endocrinol*, 36: 485-501.
- Basciano, H., Federico, L. and Adeli, K. (2005) Fructose, insulin resistance and metabolic dyslipidemia. *Nutr Metab*, 2: 5.
- Burns, A.R., Bowden, R.A., Abe, Y., Walker, D.C., Simon, S.I. and Entman, M.L. (1999) P-selectin mediates neutrophil adhesion to endothelial cell borders. *J Leukoc Biol*, 65: 299–306.
- Bland, J. (1985) Effect of orally consumed *Aloe* juice on gastrointestinal function in normal humans. (Dissertation) PhD *Linus Pauling Institute of Science and Medicine, Palo Alto, Callifornia*.

- Bligh, E.G. and Dyer, W.J. (1959) A rapid method of total lipid extraction and purification. *J Biochem Physiol*, 37: 911-917.
- Can, A., Akev, N., Ozsoy, N., Bolkent, S., Arda, B.P., Yanardag, R. and Okyar, A. (2004) Effect of *Aloe vera* leaf gel and pulp extracts on the liver in type-II diabetic rat models. *Biol Pharm Bull*, 27: 694-8.
- Carmona, M.C., Louche, K., Nibbelink, M., Prunet, B., Bross, A., Desbazeille, M., Dacquet, C., Renard, P., Casteilla, L. and Pènicaud, L. (2005) Fenofibrate prevents rosiglitazone-induced body weight gain in ob/ob mice. *Int J Obes*, 29: 864-871.
- Chan, J.L. and Abrahamson, M.J. (2003) Pharmacological management of type 2 diabetes mellitus: rationale for rational use of insulin. *Mayo Clin Proc*, 78: 459-67.
- Chaput, E., Saladin, R., Silvestre, M. and Edgar, A.D. (2000) Fenofibrate and rosiglitazone lower serum triglycerides with opposing effects on body weight. *Biochem Biophys Res Commun*, 271: 445-50.
- Cho, I.H., Ahn, J.H., Chung, C.Y., Yoo, W.J. and Sung, H.Y. (2001) Expression of vasculoendothelial growth factor in distraction osteogenesis of rat tibia. *J Korean Orthop Res*, 4: 114-20.
- Davis, R.H., Stewart, G.J. and Bregman, P.J. (1992) *Aloe vera* and the inflamed synovial pouch model. *J Am Podiatr Med Assoc*, 82: 140-148.
- Dohmen, K., Wen, C.Y., Nagaoka, S., Yano, K., Abiru, S., Ueki, T., Komori, A., Daikoku, M., Yatsuhashi, H. and Ishibashi, H. (2005) Fenofibrate-induced liver injury. *World J Gastroenterol*, 11: 7702-7703.



- Du Toit, E.F., Smith, W., Muller, C., Strijdom, H., Stouthammer, B., Woodwiss, A.J., Norton, G.R. and Lochner, A. (2008) Myocardial susceptibility to ischemic-reperfusion injury in a pre-diabetic model of dietary-induced obesity. *Am J Physiol*, 294: H2336-H2343.
- Eastwood, M.A (1992) The physiological effects of dietary fibre: an update. *Annu Rev Nutr*, 12: 19-35.
- Eshet, R., Maor, G., Ari, B.T., Eliezer, B.M., Gatyablonski, G. and Phillip, M. (2004) The aromatase inhibitor letrozole increases epiphyseal growth plate height and tibial length in peripubertal male mice. *J Endocrinol*, 182: 165-172.
- Eshun, K. and He, Q. (2004) *Aloe vera*: a valuable ingredient for the food, pharmaceutical and cosmetic industries-a review. *Crit Rev Food Sci Nutr*. 44:91-6.
- Feily, A. and Namazi, M.R., (2009) *Aloe vera* in dermatology: a brief review. *G Ital Dermatol Venereol*. 144: 85-91.
- Fermentia, A., Sanchez, E.S., Simal, S. and Rosselo, C. (1999) Compositional features of polyssacharides from *Aloe vera* (*Aloe vera barbadensis* Miller) plant tissues. *Carbohydr Polym*, 39: 109-117.
- Flatt, J.P. (1970) Conversion of carbohydrates to fat in adipose tissue: an energy-yielding and therefore, self-limiting process. *J Lip Res*, 11: 131-143.
- Fong, D.S., Aiello, L.P., Ferris, F.L. and Klein, R. (2004) Diabetic retinopathy. *Diabetes Care*, 27: 2540–2553.
- Fowler, M.J. (2008) Microvascular and macrovascular complications of diabetes. *Clin Diabetes*, 26: 77-82.

- Gaskill, C.L., Hoffmann, W.E. and Cribb, A.E. (2004) Serum alkaline phosphatase isoenzyme profiles in Phenobarbital-treated epileptic dogs. *Vet Clin Pathol*, 33: 215-222.
- Ghannam, N., Kingston, M., Al-Meshaal, I.A., Tariq, M., Parman, N.S. and Woodhouse, N. (1986) The antidiabetic activity of aloes: Preliminary clinical and experimental observations. *Horm Res*, 24: 286-294.
- Green, P. (1996) Aloe Vera extracts in equine clinical practice. *Vet Times*, 26: 9.
- Groop, L.C. (1992) Sulfonylureas in NIDDM. *Diabetes Care*, 15: 737-754.
- Grover, J.K., Yadav, S.P. and Vats, V. (2003) Effect of feeding *Murraya koeingii* and *Brassica juncea* on kidney functions and glucose levels in streptozotocin diabetic mice. *J Ethnopharmacol*, 85: 1-5.
- Hamman, J.H. (2008) Composition and applications of *Aloe vera* leaf gel. *Molecules*, 13: 1599-1616.
- Hong, X.Z., Li, L.D. and Wu, L.M. (2007) Effects of fenofibrate and xuezhikang on high-fat diet-induced non-alcoholic fatty liver disease. *Clin Expe Pharmacol Physiol*, 34: 27-35.
- IDF (2012) Diabetes Atlas, 4<sup>th</sup> Edition.
- Ingelsson, E., Sundstrom, J., Arnlov, J., Zethelius, B. and Lind, L., (2005) Insulin resistance and risk of congestive heart failure. *J Am Med Assoc*, 294: 334-341.
- Iwao, K., Kyoko, A., Yoshikastu, S., Hiroh, I. and Tsugikazu, K. (1987) Blood appearance of rat alkaline phosphatase originating from duodenum in vitro. *J Chromatogr*, 420: 275-286.

- Joseph, B. and Raj, S.J. (2010) Phytopharmacological and phytochemical properties of *Ficus* species: An overview. *Int J Pharm Bio Sci*, 1: 246-253.
- Kamerman, P.R., Modisa, B.M.E. and Mphahlele, N.R. (2004) Artovastatin, a potent HMG-CoA reductase inhibitor, is not antipyretic in rats. *J Therm Biol*, 29: 431-435.
- Kaufman, T., Kalderon, N., Ullmann, Y. and Berger, J. (1988) *Aloe vera* gel hindered wound healing of experimental second-degree burns: a quantitative controlled study. *J Burn Care Rehabil*, 9: 156-159.
- Kemper, K.J. and Chiou, V. (1999) *Aloe vera*. *The Longwood Herbal Task Force*. 1-24.
- Ker, J., Rheeder, P. and Van Tonder, R. (2007) Frequency of the metabolic syndrome in screened South African corporate executives. *Cardiovasc J S Afr*, 18: 31-33.
- King, H., Aubert, R.E. and Herman, W.H. (1998) Global burden of diabetes, 1995-2025: prevalence, numerical estimates, and projections. *Diabetes Care*, 21: 1414-1431.
- Kim, K., Kim, H., Kwon, J., Lee, S. and Kong, H. (2009) Hypoglycemic and hypolipidemic effects of processed *Aloe vera* gel in a mouse model of noninsulin-dependent diabetes mellitus. *Phytomedicine*, 16: 856-863.
- Koeppen, B.M. and Stanton, B.A., (2008) *Berne & Lervy Physiology*. 6<sup>th</sup> ed. Elsevier, Canada.
- Koyama, I., Arai, K., Sakagishi, Y., Ikezawa, H. and Komoda, T (1987) Blood appearance of rat alkaline phosphatase originating from the duodenum in vitro. *J Chromatogr*, 420: 275-286.
- Kumar, P.J. and Clark, M. (2002) *Textbook of Clinical Medicine*. Pub: Saunders (London). 1099-1121p.

- Lairon, D., Play, B. and Jourdheuil-Rahmanni, D. (2007) Digestible and indigestible carbohydrates: interactions with postprandial lipid metabolism. *J Nutr Biochem*, 18: 217-227.
- Li, W.L., Zheng, H.C., Bukuru, J. and De Kimpe, N. (2004) Natural medicines used in the traditional Chinese medical system for therapy of diabetes mellitus. *J Ethnopharmacol*, 92: 1-21.
- Li, J.H., Wang, W., Huang, X.R., Oldfield, M., Schmidt, A.M., Cooper, M.E. and Lan, H.Y. (2004) Advanced glycation end products induce tubular epithelial- myofibroblast transition through the RAGE/ERK1/2 MAP kinase signaling pathway. *Am J Pathol*, 164:1389-97.
- Loxham, S.J., Teague, J., Poucher, S.M., De Schoolmeester, J., Turnbull, A.V. and Carey, F. (2007) Glucagon challenge in the rat: a robust method for the vivo assessment of glycogen phosphorylase inhibitor efficacy. *J Pharmacol Toxicol Methods*, 55: 717.
- McKeown, N.M., Meigs, J.B., Liu, S., Saltzman, E., Wilson, P.W.F. and Jacques, P.F. (2004) Carbohydrate nutrition, insulin resistance, and the prevalence of the metabolic syndrome in the framingham offspring cohort. *Diabetes Care*, 27: 538-546.
- Maenthaisong, R., Chaiyakunapruk, N., Niruntraporn, S. and Kongkaew, C. (2007) The efficacy of *Aloe vera* for burn wound healing: a systematic review. *Burns*, 33: 713–718.
- Majane, H.I.O., Vengethasamy, L., Du Toit, E.F., Makaula, S., Woodisiss, A.J. and Norton, G. (2009) Dietary-induced obesity hastens the progression from concentric cardiac

- hypertrophy to pump dysfunction in spontaneously hypertensive rats. *Hypertention*, 54: 1376-1383.
- Matthews, D.R., Hosker, J.P., Rudenski, A.S., Naylor, B.A., Treacher, D.F. and Turner, R.C. (1985) Homeostasis model assessment: insulin resistance and beta-cell function from fasting plasma glucose and insulin concentration in man. *Diabetol*, 28: 412-419.
- Misawa, E. (2008) Administration of phytosterols isolated from *Aloe vera* gel reduced visceral fat mass and improve hyperglycemia in Zucker diabetic fatty (ZDF) rats. *Obes Res Clin Pract*, 2: 239.
- Muellenbach, E.M., Diel, C.J., Teachey, M.K., Lindborg, K.A., Hasselwander, O., Matuschek, M. and Henriksen, E.J. (2009) Metabolic interactions of AGE inhibitor pyridoxamine and antioxidant alpha-lipoic acid following 22 weeks of treatment in obese Zucker rats. *Life Sci*, 84: 563-8.
- Nyblom, H., Björnsson, E., Simrén, M., Aldenborg, F., Almer, S. and Olsson, R. (2006) The AST/ALT Ratio as an Indicator of Cirrhosis in Patients with PBC. *Liver Int*, 26: 840–845.
- Obata, M., Ito, S., Beppu, H., Fujita, K. and Nagatsu, T. (1993) Mechanisms of anti-inflammatory and anti thermal burn action of carboxypeptidase from *Aloe aborescens miller*. *Natalensis berger in rats and mice. Physiotherapy research*, 7: 530-533.
- Pacha, J. (2000) Development of intestinal transport function in mammals. *Physiol Rev*, 80: 1633-1667.

- Parks, E.J. (2002) Dietary carbohydrate's effects on lipogenesis and the relationship of lipogenesis to blood insulin and glucose concentrations. *Bri J Nutr*, 87: S247–S253.
- Passoneau, J.V. and Lauderdale, V.R. (1974) A comparison of three methods of glycogen measurement in tissues. *Anal Biochem*, 60: 405-12.
- Pickavance, L., Tadayyon, M., Widdowson, P.S., Buckingham, R.E. and Wilding, J.P. (1999) Therapeutic index for rosiglitazone in dietary obese rats: separation of efficacy and haemodilution. *Br J Pharmacol*, 128: 1570-1576.
- Rajasekaran, S., Sivagnanam, K., Ravi, K. and Subramanian, S. (2004) Hypoglycemic effect of *Aloe vera* gel on streptozotocin-induced diabetes in rats. *J Med Food*, 7: 61-66.
- Rajasekaran, S., Sivagnanam, K., Ravi, K. and Subramanian, S. (2006) Beneficial effects of *Aloe vera* leaf gel extract on lipid profile status in rats with streptozotocin diabetes. *Clin Exp Pharmacol Physiol*, 33: 232-237.
- Reddy, B.S (1971) Calcium and magnesium absorption: role of intestinal microflora-feeding. *Federation Preceedings*, 30: 1815-1821.
- Reuter, J., Jocher, A., Stump, J., Grossjohann, B., Franke, G. and Schempp, C.M (2008) Investigation of the anti-inflammatory potential of *Aloe vera* Gel (97.5%) in the ultraviolet erythema test. *Skin Pharmacol Physiol*, 21: 106-110.
- Reusch, J.E.B. (2003) Diabetes, microvascular complications, and cardiovascular complications: what is it about glucose? *J Clin Invest*, 112: 986–988.
- Rheeder, P. (2006) Type 2 diabetes: the emerging epidemic. *SA Fam Pract*, 48: 20.
- Rossouw, H.A., Grant, C.C. and Viljoen, M. (2012) Overweight and obesity in children and Adolescents: The South African Problem. *S Afr J Sci*, 108: 1-7.

- Saritha, V. and Anilakumar K.R. (2010) Toxicological evaluation of methanol extract of *Aloe vera* in rats. *J Pharma Biomed Res*, 1: 142-149.
- Schmidt, J. and Greenspoon, J. (1991) *Aloe vera* dermal wound gel is associated with a delay in wound healing. *Obstet Gynecol*, 78: 115-117.
- Schneeman, B.O (2007) Carbohydrates and gastrointestinal tract function. In: C.G., Biliaderis and M.S., Izydorczyk, Editors, *Functional Food Carbohydrates*, Taylor and Francis. LLC . 471-477.
- Slyper, A.H. (2004) The Pediatric Obesity Epidemic: Causes and Controversies. *J Clin Endocrinol Metab*, 89: 2540-2547.
- Shelton, M.R. (1991) *Aloe vera* - its chemical and therapeutic properties. *Int. J. Dermatol*, 30: 679-83.
- Shepherd, P.R. and Kahn, B.B. (1999) Glucose transporters and insulin action: Implications for insulin resistance and diabetes mellitus. *N Engl J Med*, 341: 248-257.
- Sorensen, A., Mayntz, D., Simpson, S.J. and Raubenheimer, D. (2009) Dietary ration of protein to carbohydrate induces plastic responses in the gastrointestinal tract of mice. *J Physiol*, 180: 259-266.
- Staels, B., Dallongeville, J., Auwerx, J., Schoonjans, K., Leitersdorf, E. and Fruchart, J. (1998) Mechanism of Action of Fibrates on Lipid and Lipoprotein Metabolism. *Circulation*, 98: 2088-2093.
- Sumbul, S., Waseemuddin, A.S. and Iqbal, A. (2004) Antifungal activity of *Allium*, *Aloe*, and *Solanum* species. *Pharm Biol*, 42: 491-498.

- Sweetnam, D., Holmes, A., Tennant, K.A., Zamani, A., Walle, M., Jones, P., Wong, C. and Brown, C.E. (2012) Diabetes impairs cortical plasticity and functional recovery following ischemic stroke. *J Neurosci*, 32: 5132-5143.
- Tanaka, M., Misawa, E., Yousuke, I., Habara, N., Nomaguchi, K., Yamada, M., Toida, T., Hayasawa, H., Takase, M., Inagaki, M. and Higuchi, R. (2006) Identification of five phytosterols from *Aloe vera* gel as anti-diabetic compounds. *Biol Pharm bull*, 29: 1418-1422.
- Thorburn, A.W., Storlien, L.H., Jenkins, A.B., Khouri, S. and Kraegen, E.W. (1989) Fructose-induced in vivo insulin resistance and elevated plasma triglyceride levels in rats. *Am J Clin Nutr*, 49: 1155-63.
- Traber, P.G. and Silberg, D.G. (1996) Intestine-specific gene transcription. *Annu Rev Physiol*, 58:275–297.
- Van Beers Schreurs, H.M., Nabuurs, M.J., Vellenga, L., Kalsbeek Van Der Valk, H.J., Wensing, T. and Breukink, H.J. (1998) Weaning and the weanling diet influence the villous height and crypt depth in the small intestine of pigs and alter the concentrations of short-chain fatty acids in the large intestine and blood. *J Nutr*, 128: 947–953.
- Vazquez, B., Avila, G., Segura, D. and Escalante, B. (1996) Antiinflammatory activity of extracts from *Aloe vera* gel. *J Ethnopharmacol*, 55: 69–75.
- Vigueras, R.M., Rojas-Castaneda, J., Hernandez, R., Reyes, G. and Alvarez, C. (1999) Histological characteristics of intestinal mucosa of the rat during the first year of life. *Lab Anim*, 33: 393-400.



- Vogler, B.K. and Ernst, E. (1999) *Aloe vera*: A systematic review of its clinical effectiveness. *Br J Gen Pract*, 349: 823–828.
- Weigand, W., Hannappel, E. and Brand, K. (1980) Effect of starvation and refeeding a high-protein or high-carbohydrate diet on lipid composition and glycogen content of rat livers in relation to age. *J Nutri*, 110: 669-674.
- Wells, G.D., Noseworthy, M.D., Hamilton, J., Tamopolski, M. and Tein, I. (2008) Skeletal muscle metabolic dysfunction in obesity and metabolic syndrome. *Can J Neurol Sci*, 35: 31-40.
- Weser, E. and Tawil, T. (1976) Epithelial cell loss in remaining intestine after small bowel resection in the rat. *Gastroenterol*, 71: 412-15.
- Winters, W.D. (1993) Immuno-reactive lectins in leaf gel form from *Aloe barbadensis* Miler. *Phytotherapy Research*, 7: S23-25.
- WHO (World Health Organization) (1999) Diagnosis and Classification of Diabetes Mellitus. In *Definition, Diagnosis and Classification of Diabetes Mellitus and Its Complications*. Geneva: WHO.
- WHO (World Health Organization) (2008) Traditional medicine: WHO
- Wolf, G. (2004) New insights into the pathophysiology of diabetic nephropathy: from haemodynamics to molecular pathology. *Eur J Clin Invest*, 34: 785 –796.
- Yates, A. (2002) *Yates Garden Guide*. Harper Collins Australia.
- Yegani, M. and Korver D.R. (2008) Factors affecting intestinal health in poultry. *Poult. Sci*, 87: 2052-2063.

- Yin, F.C., Spurgeon H.A., Rakusan, K, Weisfeldt M.L. and Lakatta E.G. (1982) Use of tibial length to quantify cardiac hypertrophy: application in the aging rat. *Am J Physiol Heart Circ Physiol*, 243: H941-H947.
- Zabielski, R., Godlewski, M.M. and Guilloteau, P. (2008) Control of development of gastrointestinal system in neonates. *J Physiol Pharmacol*, 59: 35-35.
- Zafar, M., Naeem-ul-Hassan Naqvi, S., Ahmed, M. and Kaimkhani, Z.A (2009) Altered liver morphology and enzymes in streptozotocin-induced diabetic rats. *Int J Morphol*, 27: 719-725.
- Zhang, L. and Tizard, I.R. (1996) Activation of mouse macrophage cell line by Acemannan; the major carbohydrate fraction of *Aloe vera*. *Immunopharmacol*, 35:119-28.
- <[http://www.betacell.org/content/articleview/article\\_id/1/](http://www.betacell.org/content/articleview/article_id/1/)>: Beta Cell Biology Consortium, 2004. (Accessed 10.10.2011)
- <<http://mumbai.olx.in/Aloe-vera-products-id-4852352> (Accessed 24.04.2012)

x

# **APPENDIX**



UNIVERSITY OF THE WITWATERSRAND, JOHANNESBURG

STRICTLY CONFIDENTIAL

ANIMAL ETHICS SCREENING COMMITTEE (AESC)

CLEARANCE CERTIFICATE NO. 2010/45/2A

APPLICANT: Ms ZP Gasa

SCHOOL: Physiology

DEPARTMENT:

LOCATION:

PROJECT TITLE: **Effects of *Aloe vera* gel extracts on diet induced metabolic dysfunction in growing rats**


**Number and Species**

60 rats


Approval was given for the use of animals for the project described above at an AESC meeting held on 31 .08.2010. This approval remains valid until 31.08.2012

The use of these animals is subject to AESC guidelines for the use and care of animals, is limited to the procedures described in the application form and to the following additional conditions:

**A signature is to be provided by the applicant on the first page of the AESC application**

Signed:  Date: 23/09/2010  
(Chairperson, AESC)

I am satisfied that the persons listed in this application are competent to perform the procedures therein, in terms of Section 23 (1) (c) of the Veterinary and Para-Veterinary Professions Act (19 of 1982)

Signed:  Date: 23/09/2010  
(Registered Veterinarian)

cc: Supervisor:  
Director: CAS

Works 2000/In0015/AESCCert.wps