

MAXILLOFACIAL RADIOLOGY

Emergent panoramic artefact in dental radiology: Footprint of Covid-19 pandemic

SADJ SEPTEMBER 2024, Vol. 79 No.8 P450-451

K Tshite¹

CASE

The following patient was referred for a panoramic radiograph for post-operative assessment, following extractions, after which a foreign body was noted below the mandible.

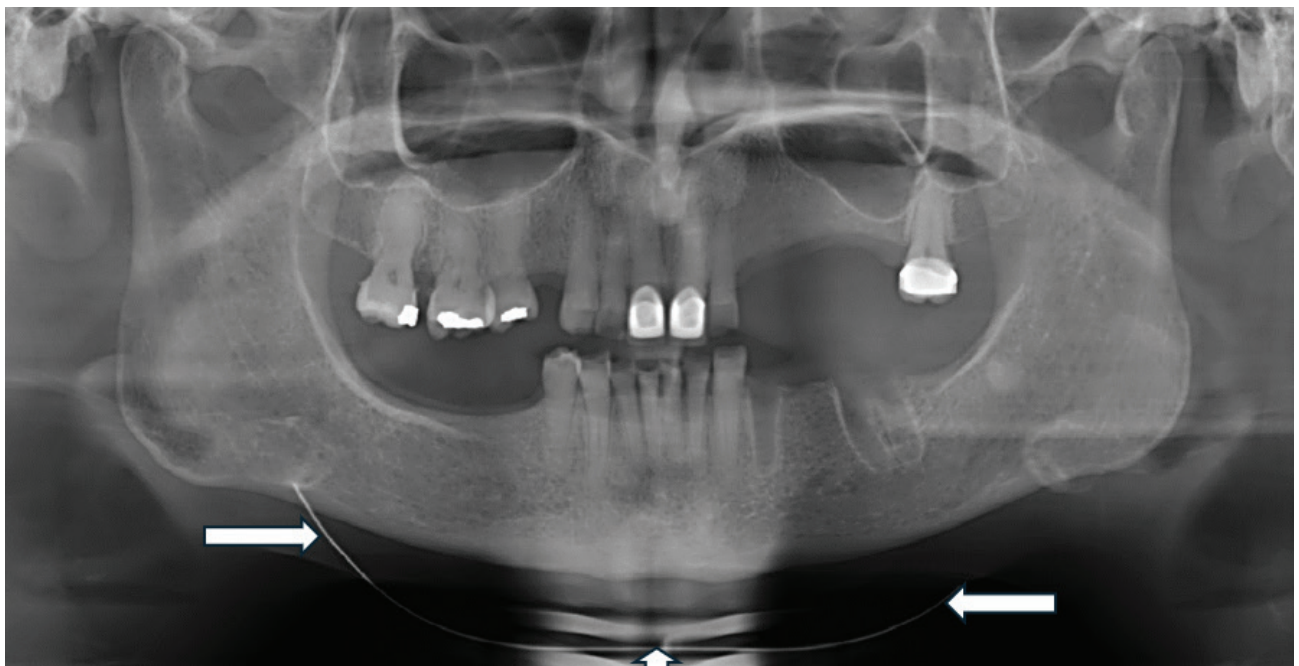


Figure 1: A panoramic radiograph taken of a patient wearing a face mask positioned below the mandible.

INTERPRETATION

The unprecedented educational challenges presented by the Covid-19 pandemic continue to offer opportunities to update, improve and strengthen the dental curriculum. Intra-oral radiographic methods were restricted during the Covid-19 pandemic due to their aerosol-generating nature, which resulted in extra-oral radiographs being predominantly used.¹ The strict usage of face masks during the pandemic, which continues to date, emerged a new patient preparation error in dental radiology.

As seen in figure 1, a panoramic radiograph taken on a patient who did not completely remove the face mask resulted in a thin radiopaque line below the body of the mandible.

Panoramic radiography is a complex projection of the jaws with multiple superimpositions and distortions of anatomical structures, which may be exacerbated by technical errors in image acquisition.² It forms part of the tools that are used for general assessment during dental examination.³ One of its key features is the ability to scan broader anatomical regions with a relatively low radiation dose, including several structures beyond the jaws.^{2,4} Panoramic radiography plays a vital role in diagnosis, decision-making and treatment planning; however, structures outside the jaws, incorporated in the final image, may create challenges in radiographic interpretation.^{2,4,5} Furthermore, like other imaging methods, a panoramic radiograph is also prone to have low resolution as a result of different factors and situations, such as patient-related issues.⁶ These factors are highlighted during clinical training because they may complicate image interpretation.

Dental students are taught about the principles of tomographic movement, emphasising the centre of rotation and all the structures within the focal trough, which appear in

Authors' information

1. Dr Koketso Tshite, UDOH, BDT, BDS, MSc Dentistry (Maxillofacial and Oral Radiology), Masters in Health Sciences Education, General Dental Practice Department (Radiology Unit), School of Oral Health Sciences, University of the Witwatersrand, Johannesburg, South Africa. ORCID: 0000-0002-6634-2957

Corresponding author

Name: Dr Koketso Tshite
Email: Koketso.tshite@wits.ac.za

Author's contribution

Dr Koketso Tshite Primary author – 100%

the final image.^{7,8} Although this is not the focus of the paper, students are also taught about the limitations of a panoramic radiograph, particularly its 2-dimensional (2D) representation of 3-dimensional (3D) structures.³ Due to this limitation, the bucco-lingual extensions of structures cannot be properly assessed. Therefore, a full understanding of image acquisition including its limitations is important.

There are general requirements that are common to all machines, which include *patient preparation, equipment preparation and patient positioning*.⁷ These requirements are mandatory to ensure quality radiographs of good diagnostic value. Dental radiology textbooks published before the Covid-19 pandemic only state that patients should remove jewellery such as earrings, hairpins, spectacles and dentures before taking panoramic radiographs. When asked to remove face masks before taking a panoramic radiograph, patients usually pull the masks down below the mandible, with the elastic loops still around the ears, resulting in a radiopaque artefact in the final image. These errors usually do not have major impacts on diagnosis, but for updated teaching and training, and to produce high-quality radiographs, students must be taught how to prevent them. Students depend mostly on prescribed textbooks for studying. If some elements or concepts are not covered in them, it unfortunately creates gaps in knowledge.

It is our duty as educators to update the modules in the curriculum to fill these gaps. The purpose of this paper is to revisit and update patient preparation protocols in dental radiology. The metal component in the face masks has been added to the list of patient preparation errors. To optimise learning, copies of radiographs of patients wearing face masks are kept in our radiology unit. They are used in teaching and training, as a supplement to the current prescribed textbooks.

AUTHORS' DECLARATION

Funding

This research did not receive any specific grant from funding agencies in the public, commercial or not-for-profit sectors.

Conflict of interest

The authors declare that they have no conflict of interest.

Ethics approval

This study was approved by the University of the Witwatersrand Human Research Ethics Committee (Reference no: M240764). All procedures followed the ethical standards of the Helsinki Declaration of 1975, as revised in 2008.

Acknowledgements

Dr IO Stemmer; Dr E Banda; Mrs B Walsh; Mrs N Mohapi; and Mrs A Asmal

REFERENCES

1. MacDonald D, Reitzik S. "New Normal" Radiology. *Int Dent J*. 2022 Aug;72(4):448-455. doi: 10.1016/j.identj.2022.05.002. Epub 2022 Jun 4. PMID: 35667883; PMCID: PMC9166288
2. Perschbacher S. Interpretation of panoramic radiographs. *Aust Dent J*. 2012 Mar;57 Suppl 1:40-5. doi: 10.1111/j.1834-7819.2011.01655.x. PMID: 22376096
3. Çelik B, Çelik ME. Automated detection of dental restorations using deep learning on panoramic radiographs. *Dentomaxillofac Radiol* (2022) 10.1259/dmfr.20220244
4. Arslan ZB, Demir H, Berker Yıldız D, Yasar F. Diagnostic accuracy of panoramic radiography and ultrasonography in detecting periapical lesions using periapical radiography as a gold standard. *Dentomaxillofac Radiol* 2020; 49: 20190290
5. Lingam AS, Koppolu P, Abdulsalam R, Reddy RL, Anwarullah A, Koppolu D. Assessment of common errors and subjective quality of digital panoramic radiographs in dental institution, Riyadh. *Ann Afr Med*. 2023 Jan-Mar;22(1):49-54. doi: 10.4103/aam.aam_213_21. PMID: 36695222; PMCID: PMC10064895
6. Çelik ME, Mikaeili M, Çelik B. Improving resolution of panoramic radiographs: super-resolution concept. *Dentomaxillofac Radiology*, Volume 53, Issue 4, May 2024, Pages 240-247. Whaites E, Drage N. *Essentials of dental radiography and radiology*, 5th ed. Churchill Livingstone Elsevier, 2013: 171-183. ISBN: 978-0702045998
7. White S, Pharoah M. *Oral Radiology: Principles and Interpretation*, 5th ed. United States: St. Louis, Mo, 2004. ISBN: 0323020011

Online CPD in 6 Easy Steps



The Continuing Professional Development (CPD) section provides for twenty general questions and five ethics questions. The section provides members with a valuable source of CPD points whilst also achieving the objective of CPD, to assure continuing education. The importance of continuing professional development should not be underestimated, it is a career-long obligation for practicing professionals.

