

The long term response to the treatment of an unusual periodontal lesion — a case report.

A. Volchansky and C.J. Dreyer

MRC/University of the Witwatersrand Dental Research Institute, 1 Jan Smuts Avenue, Johannesburg, 2001.

Keywords: *periodontitis*

SUMMARY

A misadventure with an orthodontic elastic band led to extensive damage to the periodontal structures surrounding the upper central incisor teeth of an otherwise healthy young person. Clinical and radiological examinations provided evidence of reattachment of the gingival tissue and regeneration of the alveolar bone over a period of twelve years.

OPSOMMING

'n Ongeluk met 'n ortodontiese rubberband het gr skade berokken aan die periodontale struktuur om boonste middel snytande van 'n andersins gesonde je persoon. Oor 'n periode van twaalf jaar het kliniese radiologiese ondersoek bewys van herverbinding van gingivale weefsel en vernuwing van die alveolêre b gelewer.

A mishap arising from the migration of an orthodontic rubber band led to extensive detachment of periodontal tissues in a child undergoing orthodontic treatment (Volchansky & Dreyer 1972). The accidental production of periodontal lesions by elastic bands appeared uncommon at that time. More recently Vandersall and Varble (1978) reviewed the literature on this subject and presented a case report. They explicitly pointed out that irreparable damage would be inflicted on periodontal tissues by bands that may accidentally slip subgingivally. Such bands should thus be used with special care during minor tooth movement. They particularly recommended that the elastic bands should be secured supragingivally to reduce the hazard of apical migration on teeth. In addition to this step patients should be given clear instructions and be warned of the potential danger of movement of these elastic bands. Patients should also be examined frequently by the administering dentist. A further suggestion made by these authors was the routine incorporation of a harmless radio-opaque medium into the elastic band, to facilitate clinical diagnosis, because of the difficulty in ascertaining the presence of elastic bands once they have migrated subgingivally.

CASE REPORT

In 1972 we reported on the successful treatment of a lesion produced by a subgingivally retained rubber

band. The presence of the band was only diagnosed after surgical exposure of the lesion. Fig. 1 shows the elastic band in place at the time of surgical intervention. The postoperative clinical appearance at 2 and 4 years after surgical intervention is shown in Figs. 2 and 3. The patient was not seen again for a further 7 years.

The present clinical examination revealed that the gingival tissue around the upper central incisor teeth was healthy with no clinical signs of inflammation. Further gingival recession had occurred on the labial aspect of these two teeth in the intervening period (Fig. 4) particularly the upper right central incisor. Both teeth showed grade I mobility and were in slight premature occlusal contact. No periodontal pockets could be probed.

RADIOGRAPHIC EXAMINATION

Intraoral radiographs of the upper central incisors were taken, using the same paralleling device used 12 years previously. Fig. 5 shows the original X-rays and Fig. 6 the present ones. Healing of the bony lesions had been maintained during this period. The apices of the teeth were rounded but the teeth were vital. Some widening of the periodontal spaces around both teeth had occurred in the period between the previous and current



Fig. 1 Photograph of the lesion after reflection of the soft tissue. The elastic band around the apices of the central incisors and the loss of bone on the distal and labial aspect of the incisors is seen.

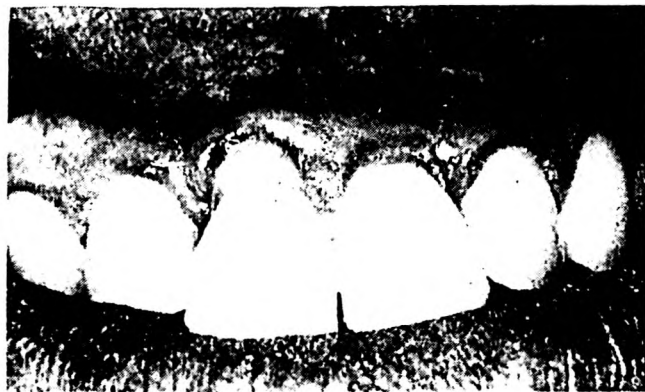


Fig. 2 Clinical photograph taken 2 years postoperatively, showing inflammation and recession of the labial gingiva of the upper right central incisor

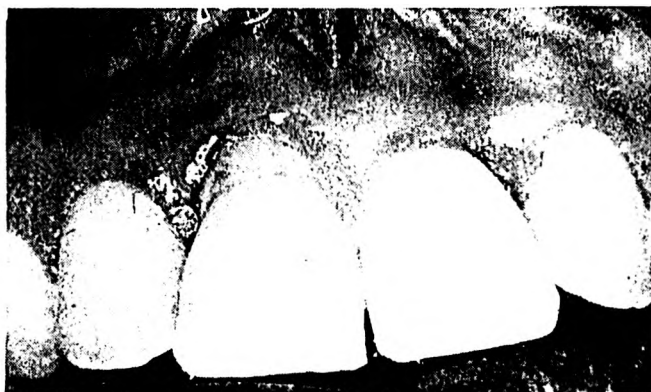

Fig. 3 Clinical photograph 4½ years postoperatively. Recession labial to the upper right central incisor persists, but gingival inflammation is minimal.

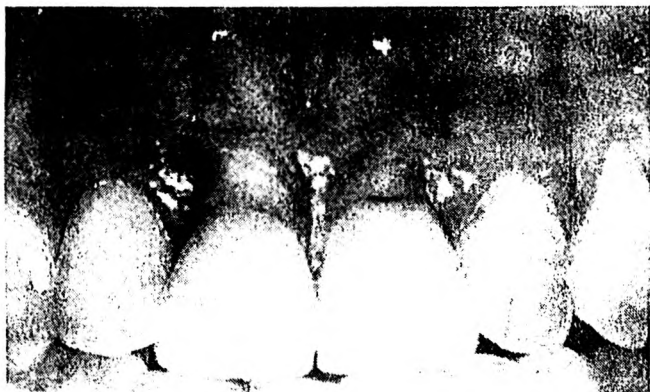


Fig. 4 Clinical photograph 12 years postoperatively. Recession has occurred on the labial aspect of both central incisors, but inflammation is minimal.

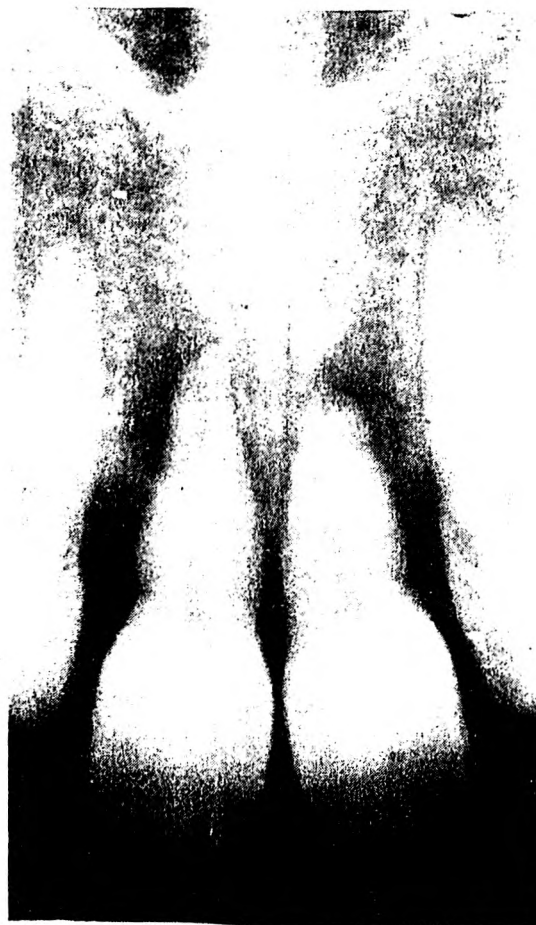

Fig. 5 Original intra-oral radiograph taken at the time of surgical intervention.

examinations. This may have been caused by the slight traumatic occlusion that was clinically evident.

DISCUSSION

In their review of the literature Vandersall and Varble (1978) refer to the observations of McQuillan (1870) and Brauer *et al* (1964) who described the mechanism of the apical migration of a rubber band placed around the maxillary central incisors. The destruction of the periodontium arising from this apical movement is facilitated by the tapered roots. On an experimental level Caton and Zander (1975) have successfully used orthodontic elastics to produce periodontal lesions in adult rhesus monkeys. The elastics were placed around the teeth at the gingival margin and migrated apically over a period of 4 weeks, resulting in detachment of the gingival tissue, pocket formation and alveolar bone loss. They found no evidence to suggest that the apical migration of the junctional epithelium or the alveolar bone loss was spontaneously reversible after the elastics had been removed. The suggestion that this type of damage is irreversible is not borne out by the experience in this case report. Timely surgical intervention did result in bony regeneration, reattachment of gingival tissue and a reduction in mobility. This has, in this case, effected a satisfactory retention of the two affected teeth for 12 years, with minimal further degenerative changes.

ACKNOWLEDGEMENTS

The authors wish to thank Miss E. Vieira for her preparation of the photographs and Professor P. Cleaton-Jones for advice.

REFERENCES

- Brauer, J.C., Higley, L.B., Lindahl, R.L., Massler, M. & Schour, I. (1964) *Dentistry for Children*, 5th ed. p 197. New York: McGraw-Hill.
- Caton, J.G. & Zander, H.A. (1975) Primate model for testing periodontal treatment procedures: 1. Histologic investigation of localised periodontal pockets produced by orthodontic elastics. *Journal of Periodontology*, **46**, 71-77.
- McQuillan, J.H. (1870) Care in the use of India-rubber rings, editorial. *Dental Cosmos*, **12**, 429.
- Vandersall, D.C. & Varble, D.L. (1978) The missing orthodontic elastic band, a periodontic-orthodontic dilemma. *Journal of the American Dental Association*, **97**, 661-663.
- Volchansky, A. & Dreyer, C.J. (1972) The treatment of an unusual periodontal lesion — A case report. *Journal of the Dental Association of South Africa*, **27**, 435-439.



Fig. 6 Present intra-oral radiograph, showing alveolar regeneration around the upper central incisors.