

DECLARATION

I, Michèle Kebert, declare that this research report is my own work.

It is being submitted for the degree of Master of Science in Dentistry to the University of the Witwatersrand, Johannesburg.

It has not been submitted before for any degree or examination at this or any other University.

_____ day of _____, 2007.

This work is dedicated to my loving family:

Karl, Elisabeth, and Dominique Kebert

And

Wayne van Biljon

ABSTRACT

MEASUREMENT OF SOFT TISSUE PROFILE CHANGES AS A RESULT OF PLACEMENT OF ORTHODONTIC BRACKETS

KEBERT, Michèle, BChD (Pretoria), 2007.

This research report quantifies the soft tissue profile changes that occur as a result of the placement of orthodontic brackets. It also assesses whether patients are able to perceive any changes in their own profiles immediately post bonding.

Using a standardised photographic technique, profile photographs were taken of a group of patients both before and immediately after the placement of orthodontic brackets. A series of angular and linear measurements were made each on the photographic images using a computer software program. The data obtained from the 'before' and 'after' photographs were then compared.

Patients were also asked several standard questions about their 'before' and 'after' photographs.

The results indicate that the placement of orthodontic brackets can cause changes in the soft tissue profile of patients. Statistically significant changes were found for four of the ten profile measurements that were investigated, namely the Nasolabial Angle, the Maxillo-Mandibular Contour, the Interlabial Angle and the Lower Lip Projection.

It was also found that patients are able to perceive changes in their profiles brought about by the placement of orthodontic brackets, and that most are able to correctly recognise which photograph was taken after bracket placement. The majority of patients prefer the photographs of their profiles taken before bracket placement.

This study was conducted using a standardised orthodontic bracket. Future research may be carried out to compare profile changes occurring with other bracket systems. This may assist manufacturers in designing brackets that are more comfortable and acceptable for patients.

ACKNOWLEDGEMENTS

I would like to express my gratitude to Dr Mark Jackson for his help and guidance throughout the research process.

I would also like to sincerely thank Dr Piet Becker of the Medical Research Council of South Africa, who helped with the statistical analysis and interpretation of the results.

My heartfelt thanks also go to Sarena Holtzhausen, who assisted in the collection of data.

I would also like to acknowledge and thank Yolanda Pfeiffer, who helped with photographic measurements in checking inter-operator accuracy.

TABLE OF CONTENTS

	Page
Declaration	i
Dedication	ii
Abstract	iii
Acknowledgements	v
Table of Contents	vi
List of Figures	vii
List of Tables	viii
Preface	1
Chapter 1: Literature review	3
Chapter 2: Materials and Methods	14
Chapter 3: Results and Statistical Analysis	30
Chapter 4: Discussion	44
Summary	49
Conclusions	50
Appendices	51
References	53

LIST OF FIGURES

	Page
<u>Figure 2.1:</u> Photographic set-up	18
<u>Figure 2.2:</u> Landmarks used in this photographic soft tissue profile analysis	21
<u>Figure 2.3:</u> Profile Angle	22
<u>Figure 2.4:</u> Nasolabial Angle	23
<u>Figure 2.5:</u> Maxillary Sulcus Contour	23
<u>Figure 2.6:</u> Mandibular Sulcus Contour	24
<u>Figure 2.7:</u> Labio-Mandibular Contour	24
<u>Figure 2.8:</u> Maxillo-Mandibular Contour	25
<u>Figure 2.9:</u> Interlabial Angle	25
<u>Figure 2.10:</u> Maxillo-Facial Angle	26
<u>Figure 2.11:</u> Upper Lip Projection	26
<u>Figure 2.12:</u> Lower Lip Projection	27
<u>Figure 3.1:</u> Scatter diagram of Profile Angle: First versus Second Observation	32
<u>Figure 3.2:</u> Scatter diagram of Nasolabial Angle: First versus Second Observation	32
<u>Figure 3.3:</u> Scatter diagram of Maxillary Sulcus Contour: First versus Second Observation	33
<u>Figure 3.4:</u> Scatter diagram of Mandibular Sulcus Contour: First versus Second Observation	33
<u>Figure 3.5:</u> Scatter diagram of Profile Angle: Operator 1 versus Operator 2	35

LIST OF TABLES

	Page
<u>Table 2.1:</u> Soft tissue points used in this profile analysis	20
<u>Table 3.1:</u> Intraclass Correlation Coefficients for profile measurements (Intra-observer)	31
<u>Table 3.2:</u> Intraclass Correlation Coefficients for profile measurements (Inter-observer)	34
<u>Table 3.3:</u> Comparison of profile measurements before and after banding for whole group	36
<u>Table 3.4:</u> Comparison of profile measurements before and after banding for female patients	38
<u>Table 3.5:</u> Comparison of profile measurements before and after banding for male patients	39
<u>Table 3.6:</u> Summary of resultant change in each profile measurement after banding	41
<u>Table 3.7:</u> Results of Patient Responses to Questionnaire	42

PREFACE

In today's world of mass marketing, media hype, extreme makeovers and patient demands, there has been a concerted drive by various parties to meet the challenge of designing an aesthetic orthodontic appliance. Growing public demand for so called "invisible orthodontics" has seen a dramatic rise in the use of more aesthetic appliances or systems. Invisalign®, lingual braces, ceramic or clear brackets are being offered to this growing group of discerning patients in an attempt to make orthodontic treatment more acceptable to them.

Some manufacturers have responded to this demand by producing brackets which they claim to be smaller, less visible, lower profile and more comfortable for the patient. However, no scientific literature exists to verify the claims made in advertisements that there are aesthetic benefits.

The soft tissue profile, and its contribution to overall facial aesthetics, has been extensively documented in the literature. Various factors are widely known to cause a change in the soft tissue profile. However, little attention has been directed in the literature at the possible influence that the appliances themselves may have on the soft tissue profile of patients.

Therefore, the purpose of this research is to investigate whether the placement of orthodontic brackets could be a further contributing factor to soft tissue profile changes.

This study will aim to quantify any changes in various angular and linear soft tissue profile measurements that may occur immediately after the placement of a predetermined type of orthodontic bracket of specific design, and to determine whether patients are able to perceive any changes in their own profile immediately post banding. With today's ever-increasing focus on appearance, any such changes may have bearing on psychological as well as sociological well-being.

Future studies may be done in order to comparatively examine profile changes with differing bracket systems to validate or repudiate claims of aesthetic benefits made by the various manufacturers.

CHAPTER 1: LITERATURE REVIEW

For years, orthodontists have studied the soft tissue contours of the faces of their patients and have recognised that, apart from creating a functional balanced occlusion, facial aesthetics should be an important outcome of orthodontic treatment. The soft tissue profile is an important factor to consider in its contribution to overall facial aesthetics.

However, the principles of what exactly defines an aesthetic profile have been the source of much debate throughout the literature.

Peck and Peck (1969, 1995) judged facial attractiveness to be the product of individual taste, shaped in part by cultural and popular trends, and influenced by racial and sex differences in facial form.

Ricketts (1982) saw beauty in mathematical terms, and suggested that aesthetics could be made scientific, rather than having to resort to subjective perceptions and philosophical ideas. He applied the divine proportion ($\sigma=1.618$) to describe optimal facial aesthetics, a view opposed by Peck and Peck (1995).

With the advent of the lateral cephalogram and cephalometric analysis, it became possible to assess the facial profile quantitatively. Lateral cephalometric head films became the cornerstone for diagnosis, treatment planning and prediction of hard and soft tissue responses to orthodontic treatment (Arnett and Bergman 1993).

Through the years, numerous authors have included soft tissue parameters in cephalometric analyses. Burstone (1958, 1967), Ricketts (1968), Lines, Lines and Lines (1978) and Holdaway (1983), amongst many others, have all contributed to the development of the various cephalometric soft tissue profile analyses commonly used today.

More recently, Bergman (1999) presented a cephalometrically-based soft tissue facial analysis, examining 18 soft tissue profile measurements. In addition to quantifying each soft tissue trait, he described the effects of growth, orthodontic tooth movement and orthognathic surgery on each of these soft tissue measurements.

However, reliance on cephalometric analysis alone for comprehensive orthodontic diagnosis and treatment planning can sometimes lead to certain shortcomings. Burstone (1958) recognised that the characteristics of soft tissue covering the teeth and bone can vary greatly. This can lead to problems in fully evaluating facial disharmony if the dento-skeletal pattern only is assessed, without consideration of the overlying soft tissue.

Arnett and Bergman (1993) maintained that by using Frankfort Horizontal as a reference line in order to assess the facial profile, true facial appearance would not be portrayed due to an incorrect positioning of the head. Instead, they showed that if Natural Head Position (NHP) (postural horizontal) is used when assessing facial balance, true antero-posterior facial relations are seen, facilitating more reliable orthodontic and surgical treatment decisions. They felt that, as an ideal, the soft tissue profile of the patient should therefore be assessed in Natural Head Position.

NHP is a standardised orientation of the head in an upright posture with the eyes focused on a distant point that is at eye level. It is the head position that the patient would assume naturally (Lundström et al. 1992).

As an adjunctive tool to cephalometrics, clinical photography has been incorporated into the evaluation and documentation of the soft tissue profile of the patient. Farkas, Bryson and Klotz (1980) assessed the reliability of photogrammetry of the face by evaluating 104 surface measurements taken directly from patients. Of these, 62 landmarks could be duplicated on photographs but only 26 were found to be reliable, more on the lateral than on the frontal photographs. The greatest number of reliable measurements was in the area of the lips and mouth.

In 1981, Farkas standardised the photographic technique and the taking of records in NHP. He developed a linear analysis of the soft tissue profile on photographic records, thereby facilitating the evaluation of variations in the facial profile of patients.

Bishara et al (1995) and Cummins, Bishara and Jakobsen (1995) used standardised facial photographs, taken with the head orientated to Frankfort Horizontal plane, to assess the reliability of the photogrammetric technique. Their findings indicated that while the measurement of profile changes from photographs was quite reliable, it was also technique and operator sensitive. Moreover, they found that the identification of certain landmarks, such as subnasale and gnathion, was less consistent than others.

Arnett and Bergman (1993) described an analysis of the soft tissue profile on photographic records taken with the patient in Natural Head Position (NHP). They used

19 facial traits in their examination of the facial profile, presenting a comprehensive approach to facial analysis.

Fernández-Riveiro et al (2002) digitally analysed the soft tissue facial profile of a sample of young white adults by means of linear measurements made on standardised photographic records taken in NHP. They showed sexual dimorphism of certain facial features, such as labial, nasal, and chin areas. In 2003, they extended their study to include angular measurements.

Nechala, Mahoney and Farkas (1999) compared three techniques of obtaining digital photographs, using direct anthropometry as a reference standard. They established that the accuracy achieved when using a digital camera, a 35-mm single lens reflex camera or a Polaroid camera (designed for medical documentation) was equivalent for angular and linear anthropometric measurements.

It has been recognized that some variation does exist in the reproducibility of NHP (Lundström et al. 1992). Cooke and Wei (1988) investigated the clinical reproducibility of NHP while recording lateral cephalometric radiographs. They concluded that NHP was more reproducible when the patient looked at his/her reflection in a mirror (method error 1.9°) than without the use of a mirror (method error 2.7°). They also found an average variation of 1.9° between repeat radiographs (taken after four to ten minutes, and again after one to two hours), when a mirror and stabilising ear-posts were used.

Üşümez and Orhan (2003) evaluated the reproducibility of sagittal (pitch) and transversal (roll) head positions in NHP, using an inclinometer. They found that the

error of the method after ten minutes for the sagittal measurement of NHP was 1.3°, and that the method error after ten minutes for the transversal measurement of NHP was 0.9°.

Other authors have strived to ensure a more repeatable head position orientated to the Frankfort Horizontal plane. Soncul and Bamber (2000) achieved a repeatable head position in their study which utilised a three-dimensional soft tissue laser scan. By incorporating a spirit-level into their technical set-up, they ensured that the Frankfort Horizontal plane was parallel to the ground and that the head of the patient was stabilised in the lateral view. To ensure that the position of the head of the patient could be stabilised in the frontal view, a narrow beam of a longitudinal laser light was projected onto the patient's facial midline. After digitisation of the scanned images, the co-ordinates of the landmarks were recorded, resulting in a highly reproducible head position.

A further method of analysing the profile is through the use of silhouettes. A silhouette is a simplified representation of a profile. It allows assessment of the profile without factors that may influence perceptions of aesthetics, such as hair or skin complexion. Lines, Lines and Lines (1978) used silhouettes to determine preferences for facial profiles for males and for females. In 1985, results published by Barrer and Ghafari supported the use of the silhouette in the assessment of profiles.

Overall, relying solely on one method of analysis in the assessment of the soft tissue profile can be problematic, as demonstrated by Fields, Vann and Vig in 1982. They investigated the clinical reliability of soft tissue profile analysis in children aged 8 and 12, using only profile photographs and soft tissue outlines taken from profile

radiographs. They found that correct assessment of the underlying skeletal pattern was unreliable in this manner, regardless of the speciality training of the evaluator, indicating the need for the concurrent use of radiographs to correctly diagnose skeletal aberrations.

Michiels and Sather (1994) compared the reliability of profile evaluations on lateral cephalograms and lateral photographs of an adult sample. Their results showed statistically significant differences in vertical and horizontal profile assessments based on these two methods. More subjects were considered by the judges to have an ideal Class I dento-skeletal relationship when the photographs were assessed than was shown in the cephalograms, indicating that soft tissue can camouflage an underlying dento-skeletal discrepancy.

Furthermore, it must also be recognised that these profile analyses are merely two-dimensional (2D) representations of three-dimensional (3D) structures. In light of this, Todd et al (2005) attempted to ascertain whether viewing two-dimensional or three-dimensional images would affect perceptions of facial aesthetics. Their study, however, yielded too great a variation of results to allow validation of any difference between the 2D and 3D images.

There are several factors that are widely known to cause a change in the soft tissue profile. These include tooth movement during orthodontic treatment (Yogosawa 1990, Valentim et al. 1994), tooth extractions (Kocadereli 2002, Bravo et al. 1997, Wholley and Woods 2003) and orthognathic surgery (Soncul and Bamber 2004).

Teitelbaum et al (2002) analysed the impact of dental and skeletal movements on soft tissue landmarks. They identified which soft tissue points would be displaced on moving each of the underlying dental or skeletal points, and were able to quantify the amount and direction of the resultant soft tissue displacement.

A further factor resulting in soft tissue profile changes is growth of the underlying cranio-facial skeleton.

Subtelny (1959) ascertained that the soft tissue nose continued to grow in a downward and forward direction from age 1 to 18 years. The bony and soft tissue chin also became more prominent in relation to the cranium, with growth continuing into late adolescence.

Bishara et al (1998) investigated the soft tissue profile changes that occur as a result of growth between the ages of 5 and 45. While focusing on five commonly used soft tissue parameters, they also concluded that the soft tissue profile changes were similar for both females and males in size and direction, except that the changes occurred earlier in females (10-15 years) than in males (15-25 years). They also found that the upper and lower lips became significantly more retruded in relation to the E-line between 15 and 25 years of age.

Prahl-Andersen et al (1995) described the development of the soft tissues of the nose, lips and chin. They demonstrated sexual dimorphism for the upper lip in the vertical dimension, whereas for the lower lip, the differences in growth relative to gender were mostly found in the horizontal dimension.

In a 3-dimensional study of the normal growth and development of the lips, Ferrario et al (2000) established a data base for the quantitative description of lip morphology from childhood to adulthood. Their results also showed that females had almost reached adult dimensions in their linear lip dimensions by age 13 to 14, whereas in males large increases were still expected to occur. Also, they found that the upper lip reached adult dimensions quicker than the lower lip, especially in females.

Genecov, Sinclair and Dechow (1989) found that antero-posterior growth, and thereby increase in the anterior projection of the nose, continued in both sexes after skeletal growth had diminished. While females had concluded a large portion of their nasal growth by age 12, males in contrast still exhibited anterior nasal growth until age 17, resulting in greater soft tissue dimensions.

Formby, Nanda and Currier (1994) showed that soft tissue changes in the lips, nose and chin continued in both males and females even after the age of 25 years.

In essence, any profile analysis is primarily an evaluation of the soft tissue adaptation to the underlying skeleton. Therefore, it must be recognised that skeletal characteristics, the soft tissue tone and the posture of the facial musculature are further factors that can affect the profile. However, Holdaway (1983) recognised that soft tissues vary in thickness over different parts of the facial skeleton. Consequently, the outline of the soft tissue profile does not necessarily correspond well with the underlying skeletal framework.

By studying radiographs periodically obtained from of a sample of patients from 3 months to 18 years of age, Subtelny (1959) established that the correlation between the

growth of hard and soft tissues is not strictly linear. Furthermore, soft tissue growth is quite independent of underlying skeletal tissues. While the convexity of the underlying skeletal profile tended to decrease with age, the convexity of the total soft tissue profile tended to increase.

Kasai (1998) found that all aspects of the soft tissue profile do not directly reflect changes in the underlying skeletal structure during orthodontic treatment. Some parts of the soft tissue profile (stomion, labiale inferius) show strong associations with the changes in the underlying skeletal structures, whereas other parts (labiale superius) tend to be more independent of the changes in the skeletal structures. He conceded that, in addition to variations caused by general imbalances of the dental and skeletal structures, there are also individual variations in the thickness and tension of the soft tissues.

Saxby and Freer (1985) investigated the correlations between hard and soft tissue reference points. They found a strong relationship between the angulation and horizontal position of the upper incisors and soft tissue variables, suggesting that they are very important determinants of the associated soft tissue morphology. They also found that the anteroposterior position of the lower incisors influenced the horizontal position of soft tissue B-point and the lower lip convexity. In contrast, they found that the angulation of the lower incisors seemed to bear very little relation to the overlying soft tissue morphology. Furthermore, they also found that the ANB angle and point-A convexity both strongly related to the overlying soft tissue outline.

The role of muscle forces on the soft tissue profile in response to changes must also not be overlooked. Oliver (1982) investigated the influence of upper lip strain and lip

thickness on the relationship between dental, skeletal and integumental profile changes in orthodontically treated patients. Significant correlations were found between incisor changes and lip vermilion changes in patients with high lip strain, but the relationships were found to be insignificant in those with low lip strain. He also concluded that patients with thin lips showed greater correlations between skeletal changes and soft tissue changes than those with thick lips.

The type of underlying malocclusion present also has a part to play in determining the pressures from the lips on the teeth. Thüer and Ingervall (1986) investigated the relationship between lip strength and lip pressure (pressure from the lips on the teeth) in children with various types of malocclusions. Using a dynamometer, they found that lip strength was lower in patients with an Angle Class II Division 1 malocclusion than in those with a Class I malocclusion. The lip pressure on the upper incisors was also higher in Class II Division 1 than in Class I malocclusions, and lowest in those with a Class II Division 2 malocclusion. Their findings therefore suggested that the pressure from the lips on the teeth is as a result of the incisor position.

In his Master's thesis in 1983, Lin evaluated the soft tissue profile changes that occurred as a result of the removal of orthodontic brackets. His study was comprised of a cephalometric comparison of the lip contour before and immediately after debonding at the end of orthodontic treatment. Lin found no significant changes in lip posture, which he attributed to the inherent yield of the soft tissues to the underlying appliance. While the sample as a whole demonstrated no statistically significant changes between lip postures with and without the presence of the brackets, a considerable variation in response was observed within the group. More than half of his patients showed a small increase in lip thickness after debonding. Considering that

the radiographs were taken with the patient's lips lightly touching, some initial lip strain may have been present, which was released with the removal of the brackets. According to Lin, this may have accounted for the thickening of the lips in these patients.

Facial appearance during orthodontic treatment is a consideration that may directly influence a patient's decision to commence with treatment. The presence of the appliance itself may have immediate aesthetic implications for the patient. While other factors that cause soft tissue profile changes have been extensively documented, minimal consideration has been given to the possible influence that the appliances themselves may have on the profile during treatment. This study will therefore quantify the soft tissue profile changes that may occur with the placement of orthodontic brackets.

CHAPTER 2: MATERIALS AND METHODS

OUTLINE OF EXPERIMENT:

The purpose of this study is to measure soft tissue profile changes that may be caused by the placement of orthodontic brackets.

The study will also assess whether patients are able to notice a difference in their profiles after the placement of these brackets, and questions which profile is preferred.

Right lateral photographs were taken of the subjects before and directly after the placement of orthodontic brackets, using a standardised photographic technique. These were then printed (15cm x 11cm in size), using a colour laser printer (HP 3800 dn), and shown to the patient. They were then asked several standard questions about their 'before' and 'after' profiles, and their responses were recorded on a data collection form (Appendix A).

The 'before' and 'after' photographs were also downloaded onto a computer, and analysed using Corel Draw X3[®] Graphics Suite. A series of angular and linear soft tissue measurements were performed on these photographs. The two sets of data thereby obtained were then compared.

SAMPLE:

The sample consisted of 33 consecutive patients, between the ages of 8 and 22 years, receiving full upper and lower arch bonding as part of their orthodontic treatment. No cognisance was taken of the type of malocclusion being treated, or of the race of the patient. Eleven male and 22 female patients were photographed for this study. The same orthodontic bracket system was used for all patients (Nu-Edge 0.018, TP Orthodontics).

Patients excluded from the study were:

- Those with beards or moustaches as it would not be possible to accurately identify some soft tissue points.
- Those receiving other bracket types, including ceramic brackets or lingually positioned brackets.
- Those wearing spectacles as it would not be possible to accurately identify some soft tissue points, such as Nasion.

The purpose and methods of the research was explained to each patient and their parent/ guardian, and informed consent was obtained. Each subject was made aware that participation was entirely voluntary and that they could withdraw at any time during the research process.

Ethical approval for this research was granted by the Human Research Ethics Committee, University of the Witwatersrand (Appendix B). The decision of the Committee was that this research was 'unconditionally approved'.

MATERIALS AND METHODS

Various studies that have made use of Natural Head Position have been presented in the literature. For the purposes of this study, it was deemed desirable to have a repeatable head position for the 'before' and 'after' photographs. Therefore, it was decided not to use Natural Head Position for patient posturing but to try to adhere to the same prescribed conditions before and after the banding. The technical set-up as described below provided a fixed and consistently repeatable positioning of the head, as has been statistically proven.

This study makes use of a non-invasive photographic technique to analyse profile changes.

Patients were informed of the purpose of the study and that photographs would be taken of their profiles before and after the placement of the orthodontic brackets. Patients were however not informed that they would be asked questions about their 'before' and 'after' profiles so as not to influence their possible responses. Once informed consent had been obtained, a small mark (dot) was drawn onto the patient's cheek with water soluble ink.

The photographic set-up employed the use of a Cephalostat (in this case an Asahi Auto III NCM X-Ray Unit), which is standard equipment in most orthodontic practices, to ensure consistency in repositioning the patient. The fixed ear pieces were placed into the patient's external auditory meatuses in order to stabilise the head in the transversal plane. In order to ensure repeatable sagittal positioning of the head between successive photographs, a red laser pointer was directed at the mark which

had been drawn onto the patient's cheek. This ensured that the patient's head was placed in the identical position for pre- and post-banding photographs. The patient was asked to close his/her eyes whenever the red laser light was used to eliminate the risk of any possible damage to the eyes.

A right lateral profile photograph was taken using a Minolta Dimage V digital camera at 1200 x 1600 d.p.i resolution, which was placed on the chin-rest of the Pan/Ceph machine at a fixed distance of 115 cm from the patient. This distance was measured from the lens of the camera to the midsagittal plane of the patient. Photographs were taken in an environment with good lighting to prevent shadow formation. The red laser light source was also placed on the chin rest, at a fixed position of 115 cm from the midsagittal plane of the patient. A ruler was fixed on the forehead support of the Cephalostat in the mid-sagittal plane, anterior to the patient's face, to facilitate standardisation of the magnification and to assist with any linear measurements on the photographs.

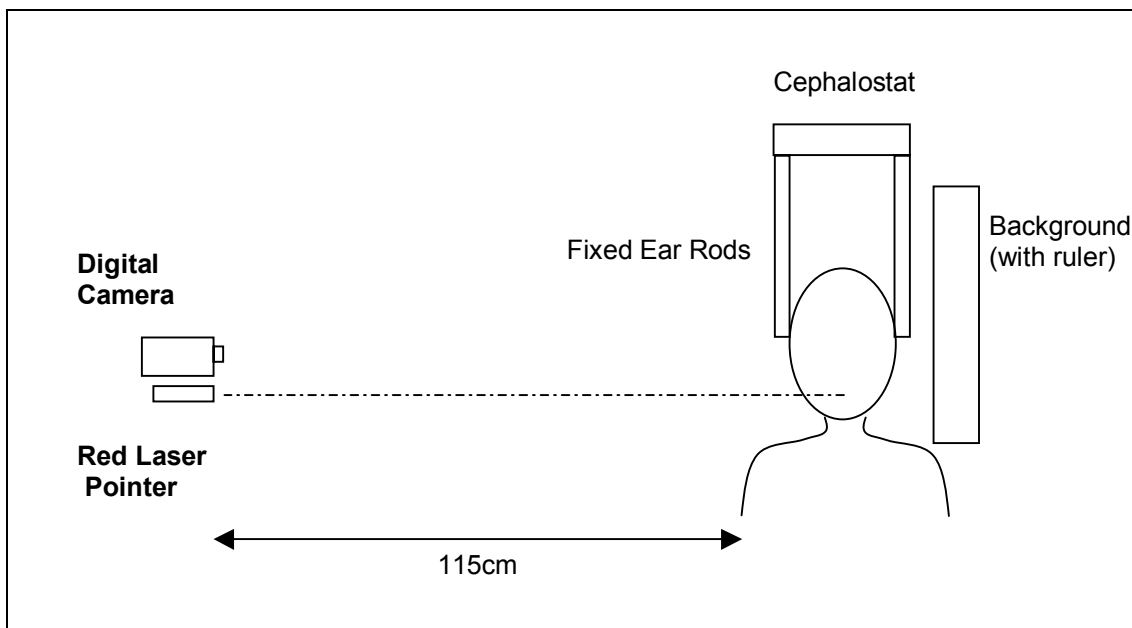


Figure 2.1: Photographic set-up

Photographs were taken with the patient's lips in repose and with the mandible at rest. A relaxed lip position can be obtained by asking the patient to relax whilst the operator gently strokes the lips (Arnett, Bergman 1993). Relaxed lip position is important in accurate evaluation of soft tissues, as it demonstrates the soft tissues relative to the hard tissues without muscular compensation. It was decided not to take photographs with the patient in centric occlusion due to the possible interference of the brackets or cement, which may have been placed on molars to open the bite, that could confound consistency of measurements were the patients placed in occlusion.

After the pre-bonding photograph had been taken, the patient was removed from the photographic set-up, and the full upper and lower fixed appliances were placed. The patient was then repositioned into the photographic set-up for the post-bonding photograph. The ear rods were placed into their external auditory meatuses in order to stabilise the head in the correct transversal plane. The red laser pointer was switched

on, and the patient's head orientated in the sagittal plane so that the red light shone directly onto the mark on the patient's cheek. A post-bonding photograph was then taken. For the post-bonding photographs, a small and unobtrusive marker was placed in the photographic field (on the ear-rod closest to the camera), which allowed the operator to correctly identify the 'before' and 'after' photographs. This marker was placed at such a time that it would not be brought to the patient's attention.

After the banding, the images were transferred from the digital camera onto a computer and printed for viewing by the patient. Patients were shown their two photographs, taken before and after the bonding, and their responses to a standard questionnaire were recorded. Considering that both sets of photographs were taken on the same day, the chances that the patient would be able to recognise the 'before' and 'after' photographs (e.g. due to different hairstyles or clothing) were eliminated.

All of the photographs collected in this manner were saved on the computer for later analysis.

ANALYSIS OF THE PHOTOS:

Measurements on both pre- and post-bonding photographs were performed using Corel Draw X3® Graphics Suite, a computer software program. On each photograph, the following standard soft tissue profile points were identified:

Table 2.1: Soft tissue points used in this profile analysis (Burstone 1958)

ABBREVIATION	SOFT TISSUE POINT	DESCRIPTION
G	Glabella	The most anterior point of the middle line of the forehead
N	Nasion	The most posterior point at the root of the soft tissue nose in the median plane
SN	Subnasale	The point at which the nasal septum merges with the upper cutaneous lip in the mid-sagittal plane
A'	Soft tissue A-point	The greatest concavity of the upper lip between Subnasale and Labiale Superius
B'	Soft tissue B-point	The point of greatest concavity of the lower lip, between Labiale Inferius and Soft tissue Pogonion
Ls	Labiale Superius	The point that indicates the mucocutaneous limit of the upper lip
Li	Labiale Inferius	The point that indicates the mucocutaneous limit of the lower lip
Pg'	Soft tissue Pogonion	The lowest and most anterior point on the soft tissue chin, in the mid-sagittal plane

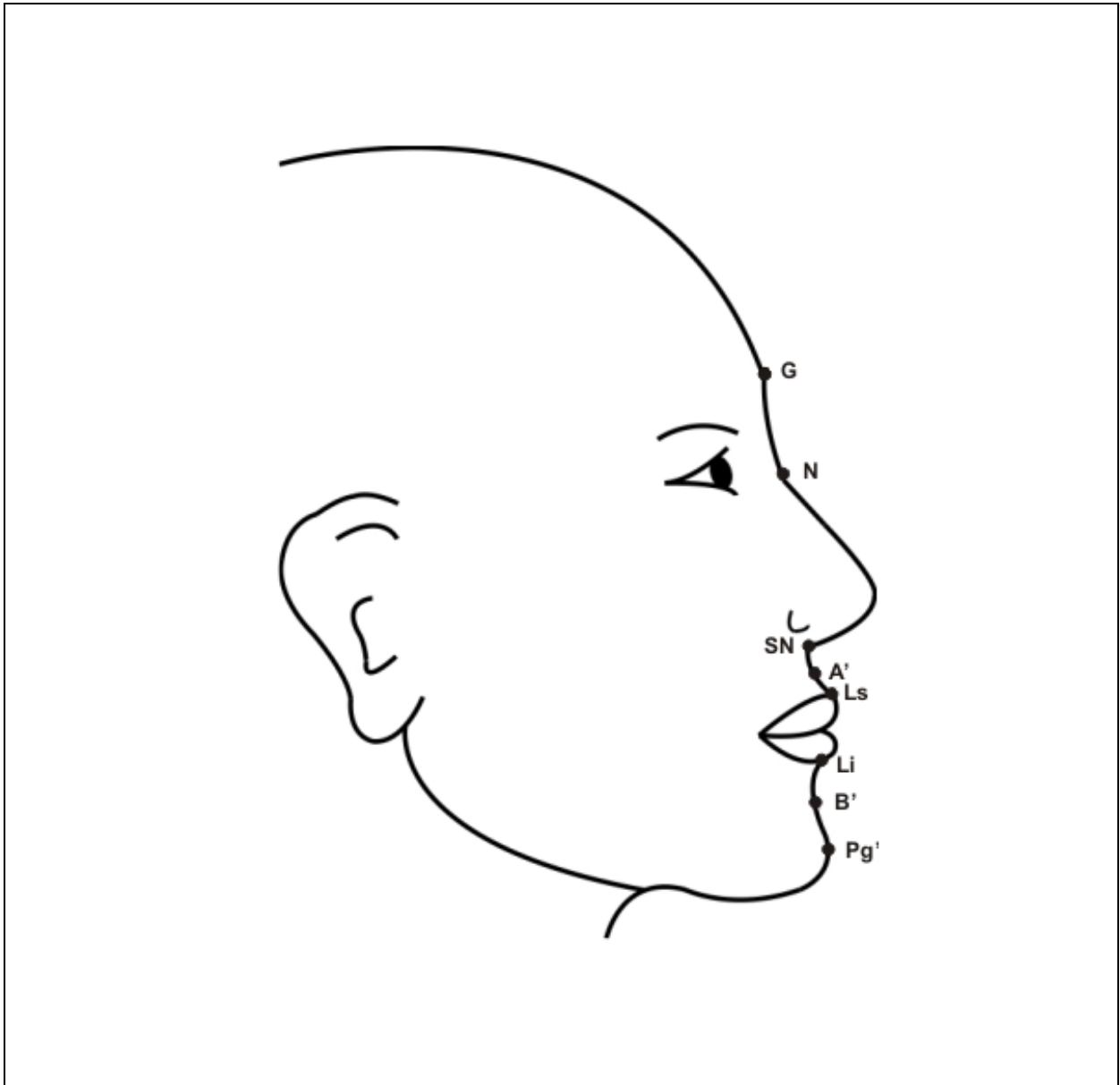


Figure 2.2: Landmarks used in this photographic soft tissue profile analysis

On each profile photograph, the following series of eight angular and two linear measurements were made and recorded, using the angular and horizontal dimension tools of Corel Draw X3® Graphics Suite:

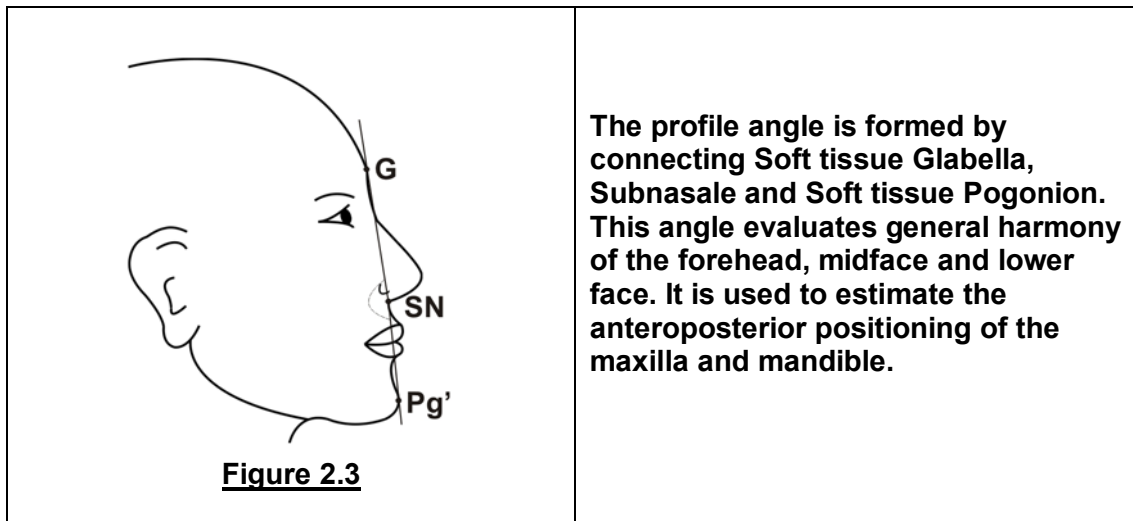
Angular measurements:

1. Profile Angle
2. Nasolabial Angle
3. Maxillary Sulcus Contour
4. Mandibular Sulcus Contour
5. Labio-Mandibular Contour
6. Maxillo-Mandibular Contour
7. Interlabial Angle
8. Maxillo-Facial Angle

Linear measurements:

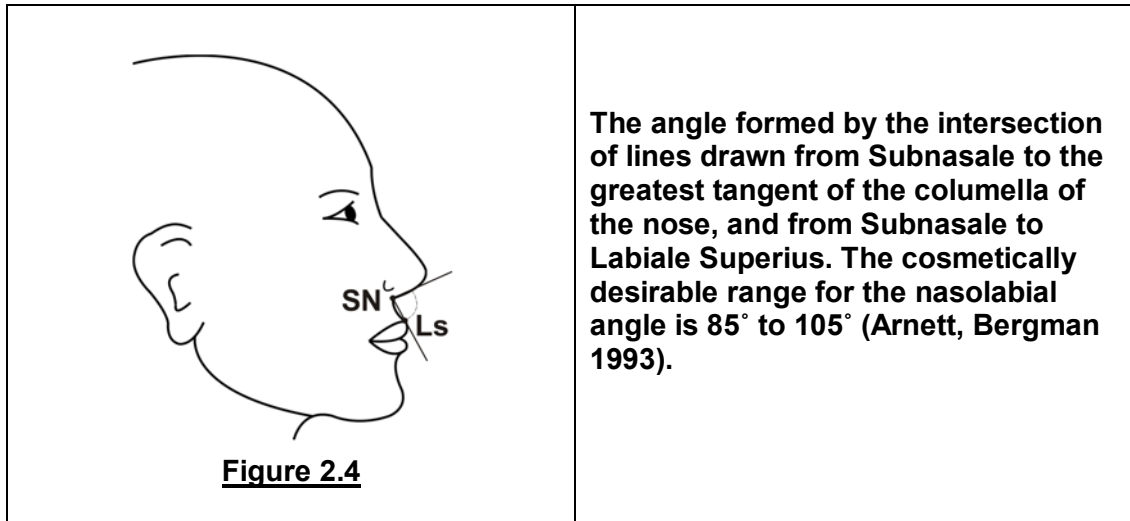
9. Upper lip projection
10. Lower lip projection

1. Profile Angle (G-SN-Pg')

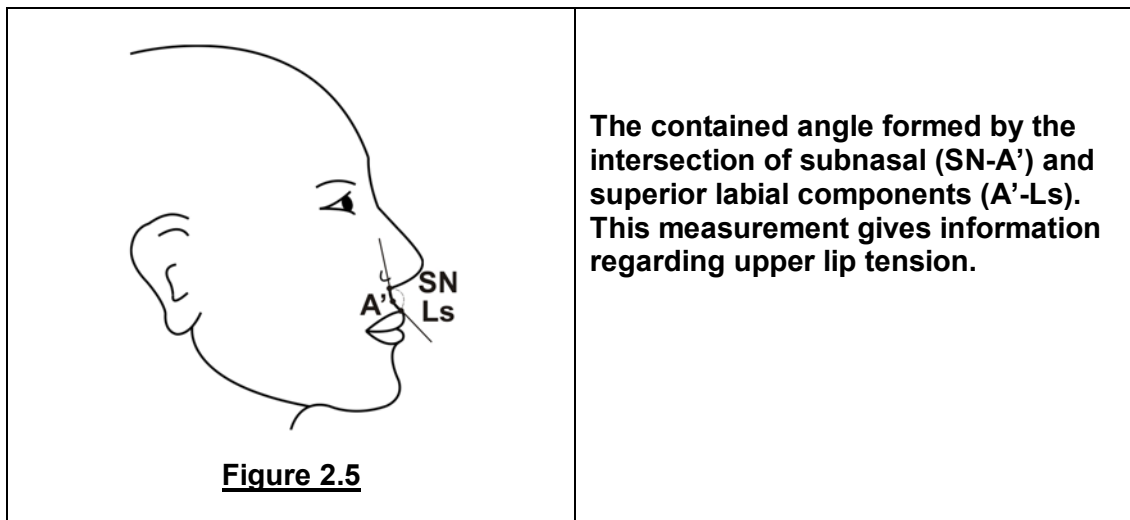


The profile angle is formed by connecting Soft tissue Glabella, Subnasale and Soft tissue Pogonion. This angle evaluates general harmony of the forehead, midface and lower face. It is used to estimate the anteroposterior positioning of the maxilla and mandible.

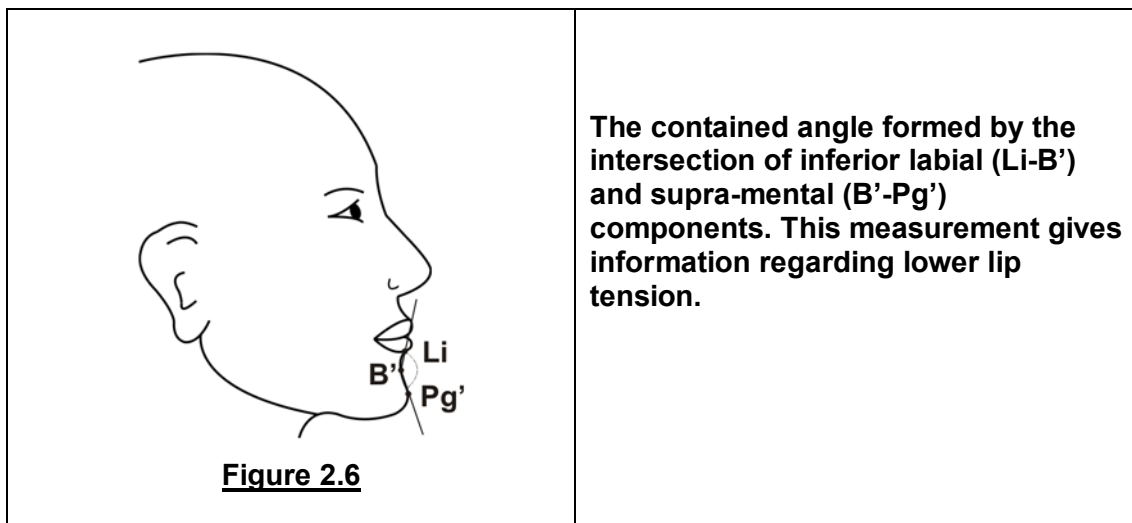
2. Nasolabial Angle



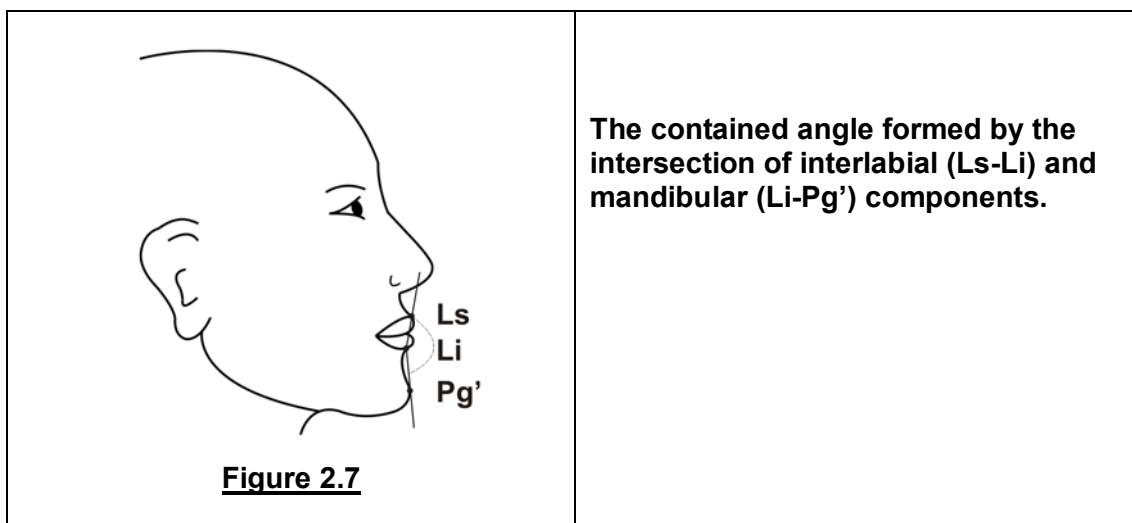
3. Maxillary Sulcus Contour (SN-A'-Ls)



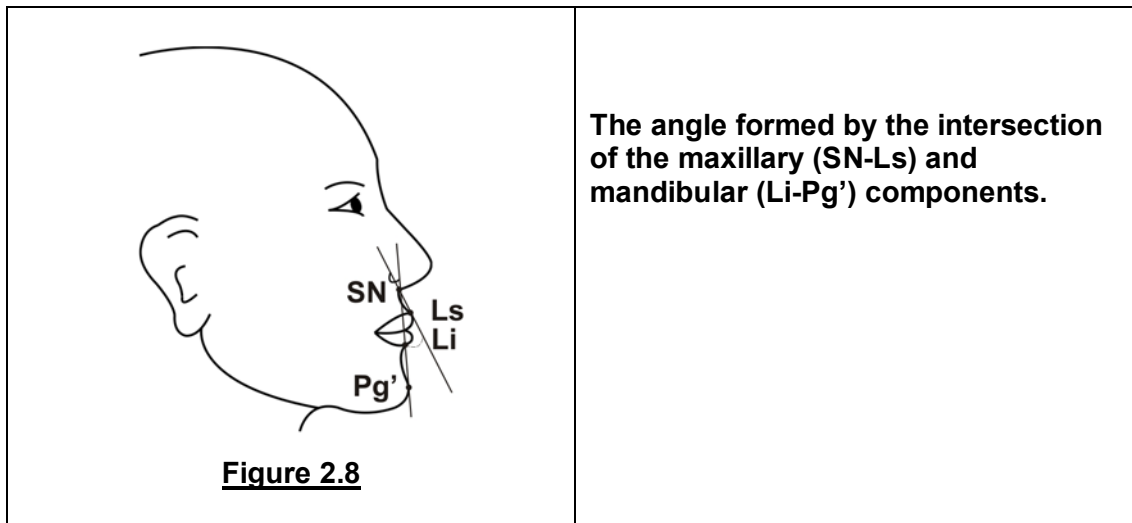
4. Mandibular Sulcus Contour (Li-B'-Pg')



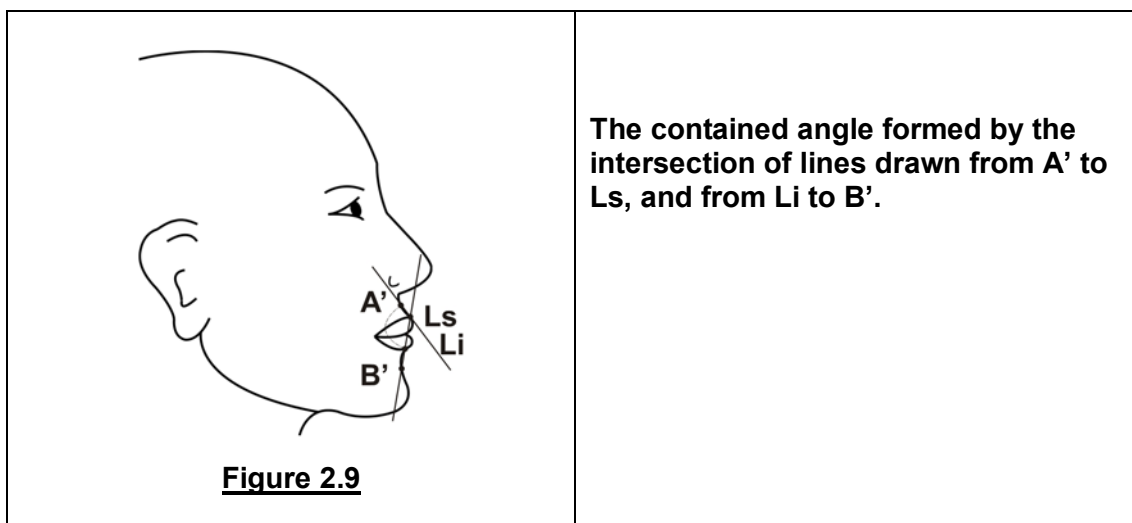
5. Labio-Mandibular Contour (Ls-Li-Pg)



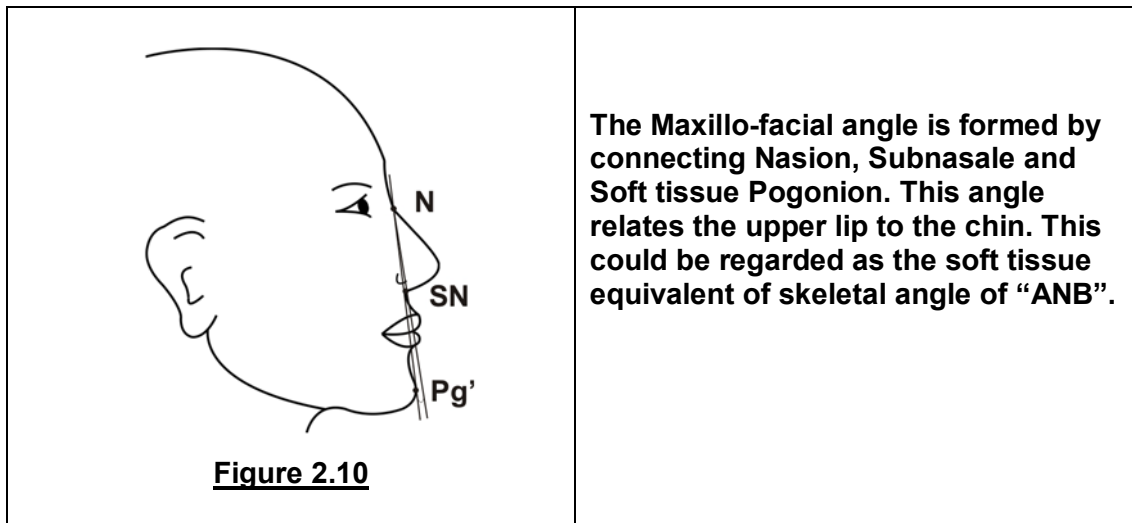
6. Maxillo-Mandibular Contour (SN-Ls-Li-Pg')



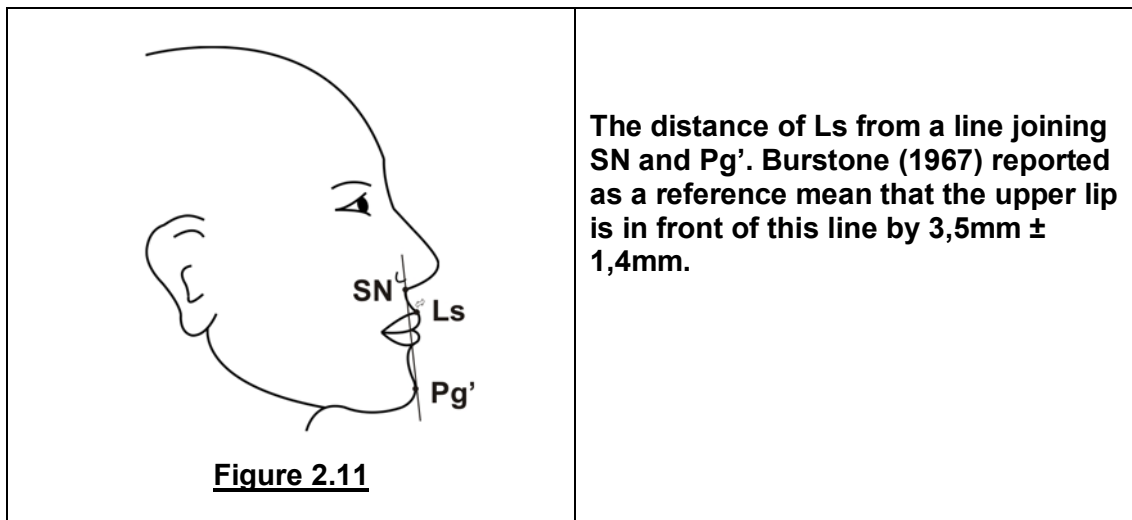
7. Interlabial Angle



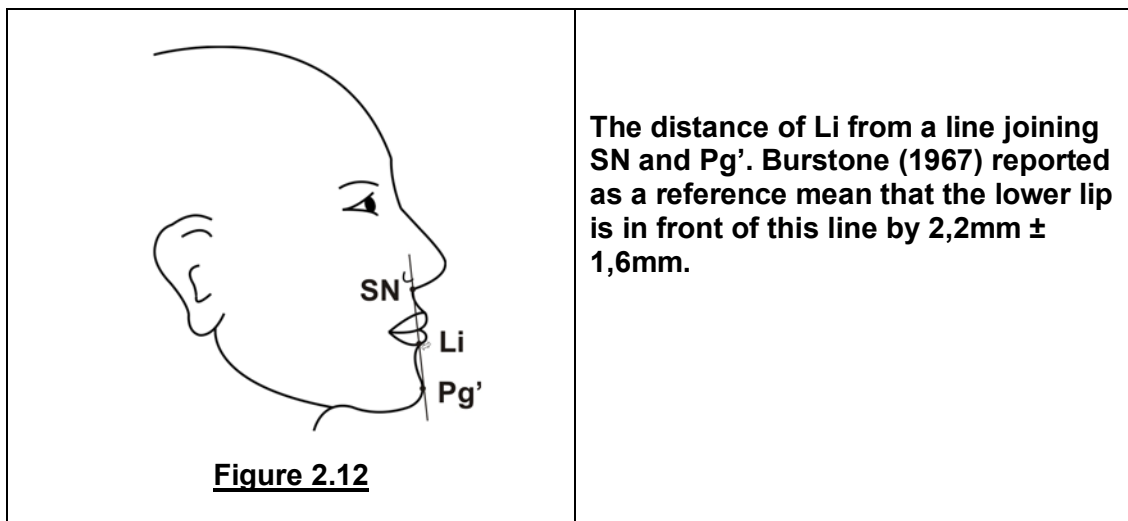
8. Maxillo-Facial Angle (SN-N-Pg')



9. Upper Lip Projection



10. Lower lip Projection



Figures 2.3 to 2.12: Profile measurements (Burstone 1958, Arnett and Bergman 1993)

Each of the above measurements was repeated twice for each pre-bonding and post-bonding photograph, with the second measurement being taken immediately after the first. Where there was a deviation of more than 0.3 degrees or 0.3 millimetres between the first and second measurements, a third measurement was taken in order to ensure accuracy of the results. This data was then saved for later statistical analysis, where an average of the two or three measurements would be used to calculate any differences between pre-bonding and post-bonding readings.

The level of precision for the measurements was set to the first decimal point, or 0.0 degrees or millimetres.

In order to standardise the size of the photographs, a magnification factor was computed so that each photograph was analysed at the same size.

Relative magnification of the image on the photographs was standardised to 0.85. This was done by measuring the one centimeter demarcation on the ruler in the background of the photograph (the apparent length of an object), and dividing it by one centimeter (the actual length of an object). The magnification was then calculated using the following formula:

$$\text{Magnification} = \frac{\text{Apparent length of an object (L)}}{\text{Actual length of an object (m)}}$$

Where the magnification of the photographs was not 0.85, the zoom level in the software program was adjusted until the magnification of 0.85 had been achieved for all photographs.

STATISTICAL CONSIDERATIONS:

1. Sample Size

The recommended sample size of 33 patients was calculated by a biostatistician, and was determined in order to meet with a desired and scientifically meaningful accuracy, set equal to one-third standard deviation. The 95% confidence interval was based on the large sample Z-statistic.

2. Data Analysis

Before quantifying the changes that take place, it was established whether these changes were related to the age of the patient. Should a relationship not exist, 95% confidence intervals would be calculated for the ten parameters being investigated. However, if a relationship with age did exist, 95% confidence bands around the regression lines of the parameters and age would be calculated. Sample size is such that accuracy is at least as good as desired.

CHAPTER 3: RESULTS AND STATISTICAL ANALYSIS

ERROR OF THE METHOD:

1. Repeatability of positioning of head

A pilot study was conducted to judge some of the possible outcomes and values, and to refine the technical set-up of equipment. Initially, three patients were photographed before and after banding, and it was noted on visual inspection that there appeared to be changes in the soft tissue profile.

However, some variation in head position was noted between the before and after photographs. Initially use had been made of only the ear pieces to stabilise the head in the transversal plane. This was not a repeatable head position, and the method was therefore refined, incorporating the facial marker and red laser light system into the technical set-up.

Subsequently, nine patients were sequentially positioned in the Cephalostat in the method as described above, including the use of the red laser light. After being photographed, each patient was removed from the Cephalostat, then repositioned and photographed again. Using Corel Draw X3[®] Graphics Suite, four of the ten profile measurements were performed twice on each of the photographs. These data were used to assess the repeatability of the positioning of the patient's head.

Repeatability can be evaluated by means of the Intraclass Correlation Coefficient (Lachin 2004). This is calculated following a One-way analysis of variance, with the nine patients being the nine levels of this single factor study design where two

observations are made for each patient. Using the One-way analysis, patients can also be viewed either as fixed or as random samples, with the latter being a more realistic reflection of repeatability.

Table 3.1 summarises the Intraclass Correlation Coefficients for the four profile measurements under study:

Table 3.1: Intraclass Correlation Coefficients for profile measurements (Intra-observer)

Profile measurement	Intraclass Correlation Coefficients	
	Fixed Effect Modelling	Random Effect Modelling
Profile Angle	0.99787	0.8866244
Nasolabial Angle	0.99840	0.8871845
Maxillary Sulcus Contour	0.99329	0.8817609
Mandibular Sulcus Contour	0.99959	0.8884571

Since the maximum value for the Intraclass Correlation Coefficient is 1, the values for fixed effect modelling reflect good repeatability of positioning of the patient's head. When the patients were viewed as random samples for the One-way analysis, the Intraclass Correlation Coefficient was slightly lower, but was still within highly acceptable ranges.

To put this data into further perspective, Figures 3.1 to 3.4 represent the agreement between first and second observations in relation to the 'line of perfect agreement' (45 degrees):

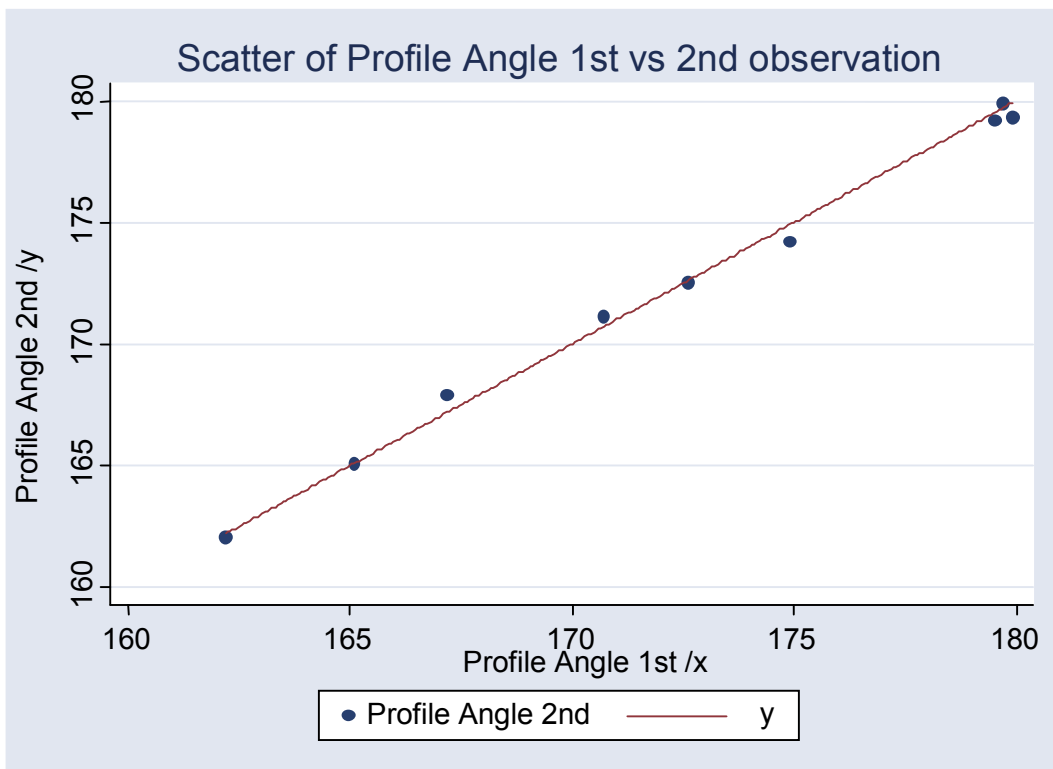


Figure 3.1: Scatter diagram of Profile Angle: First versus Second Observation

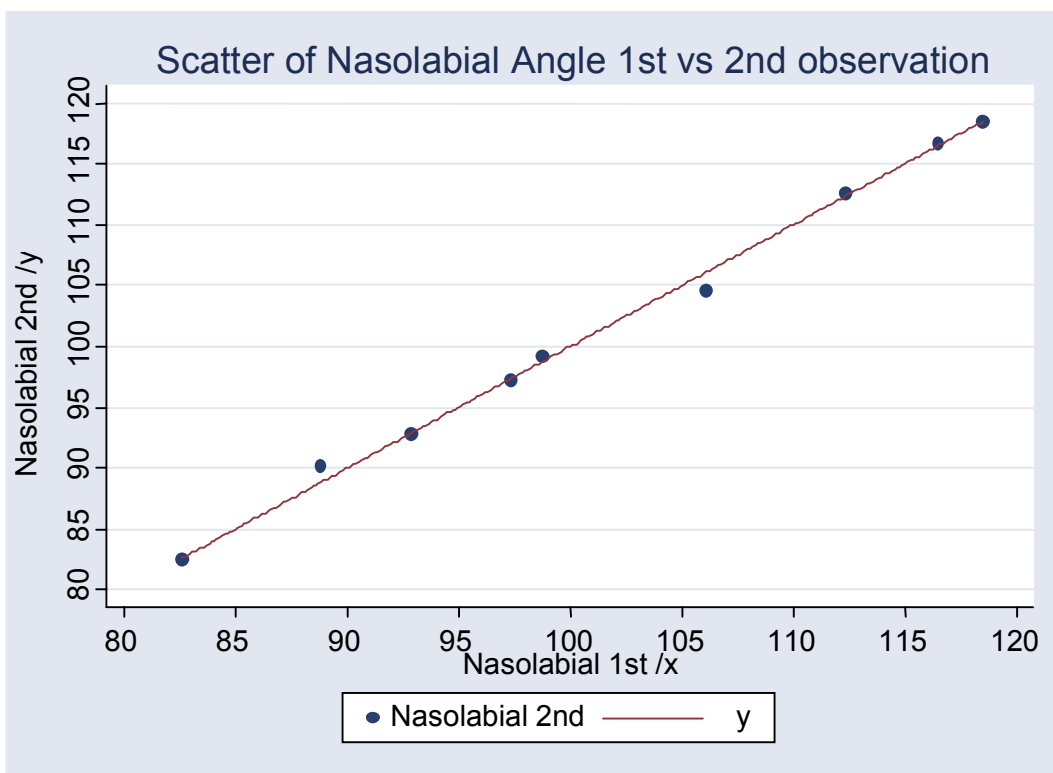


Figure 3.2: Scatter diagram of Nasolabial Angle: First versus Second Observation

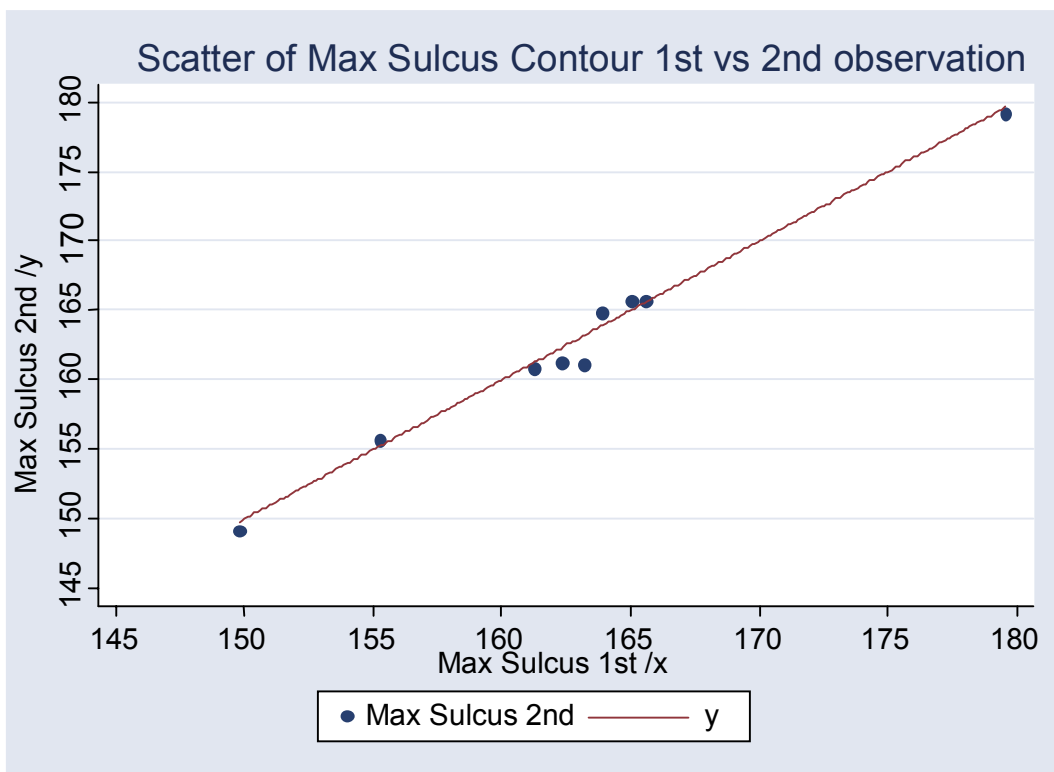


Figure 3.3: Scatter diagram of Max Sulcus Contour: First versus Second Observation

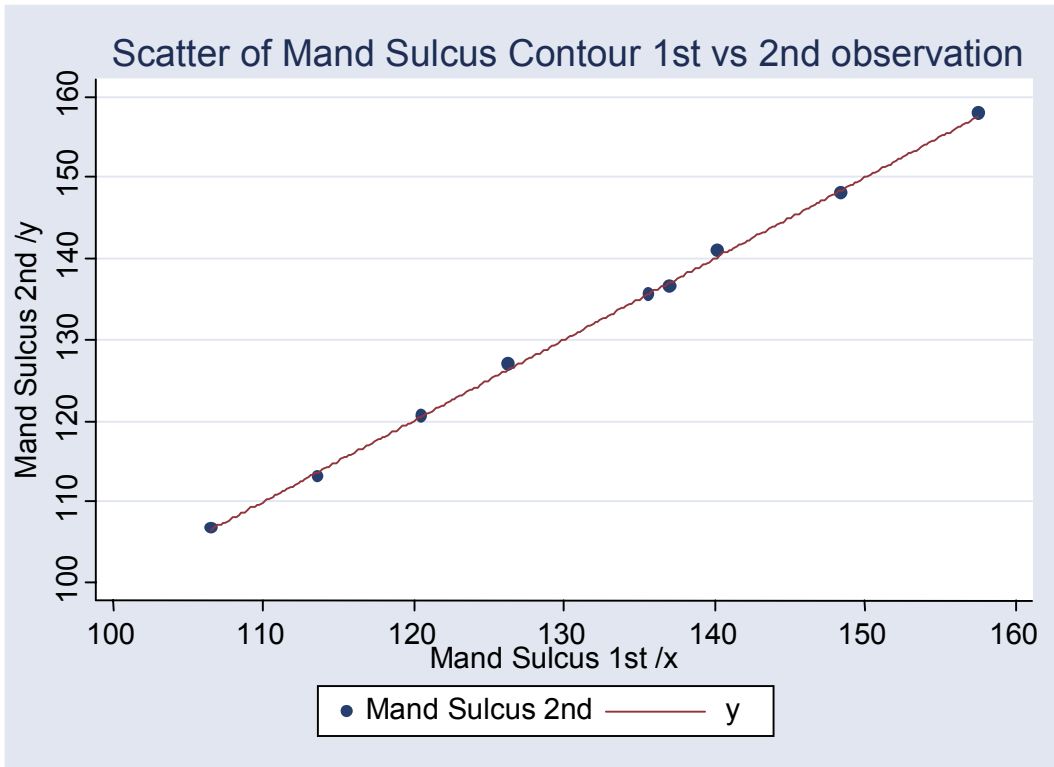


Figure 3.4: Scatter diagram of Mand Sulcus Contour: First versus Second Observation

2. Repeatability of measurements

Inter-observer agreement was also measured using the Intraclass Correlation Coefficient. Two independent operators measured the Profile Angle twice on a randomised sample of 15 photographs. High agreement was found, as demonstrated in Table 3.2, indicating that measurements were able to be accurately repeated.

Table 3.2: Intraclass Correlation Coefficients for profile measurements (Inter-observer)

Operator	Intraclass Correlation Coefficient	
	Fixed Effect Modelling	Random Effect Modelling
Operator 1	0.99944	0.932749
Operator 2	0.99922	0.9325294

The following scatter diagram (Figure 3.5) displays the measurements taken by Operator 1 versus the measurements by Operator 2:

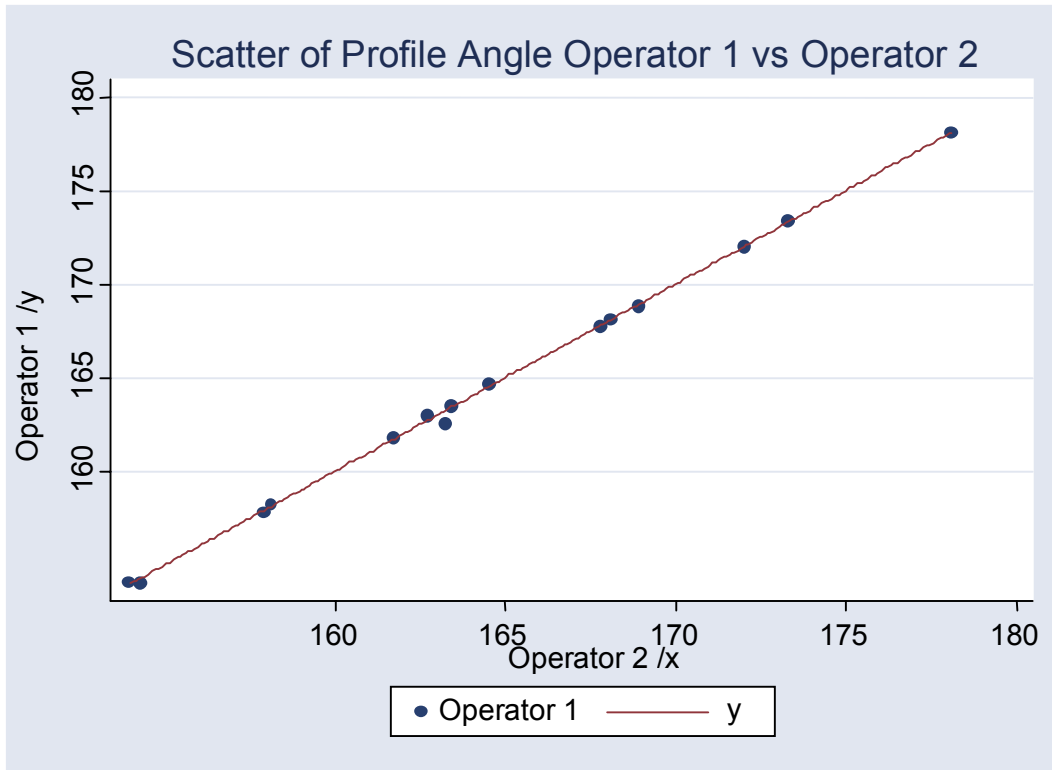


Figure 3.5: Scatter diagram of Profile Angle: Operator 1 versus Operator 2

STATISTICAL ANALYSIS OF PROFILE MEASUREMENTS

By comparing the 'before' and 'after' readings for the ten profile measurements, it was established that the changes were not associated with the ages of the patients.

Readings for each of the ten profile measurements taken before and after banding were therefore compared using the Student's paired t-test, the results of which are summarised in Table 3.3 below.

Table 3.3: Comparison of profile measurements before and after banding for whole group

Profile Measurement	Before banding Mean (SD)	After banding Mean (SD)	Change after banding		P-Value *
			Mean (SD)	95% Confidence Interval	
1. Profile Angle (°)	164.71 (5.25)	164.90 (5.14)	0.19 (1.63)	(-0.39; 0.76)	0.5142
2. Nasolabial Angle (°)	110.62 (11.54)	108.83 (11.55)	-1.79 (3.38)	(-2.99; -0.60)	0.0046*
3. Maxillary Sulcus Contour (°)	157.23 (12.50)	156.71 (14.17)	-0.52 (6.27)	(-2.74; 0.70)	0.6372
4. Mandibular Sulcus Contour (°)	122.06 (14.27)	123.12 (13.36)	1.06 (8.98)	(-2.13; 4.24)	0.5029
5. Labio-Mandibular Contour (°)	170.95 (6.22)	170.82 (7.76)	-0.14 (7.99)	(-2.97; 2.69)	0.9222
6. Maxillo-Mandibular Contour (°)	26.38 (12.14)	29.98 (13.51)	3.59 (6.47)	(1.30; 5.88)	0.0032*
7. Interlabial Angle (°)	107.20 (16.62)	103.10 (16.96)	-4.10 (7.84)	(-6.88; -1.32)	0.0052*
8. Maxillo-Facial Angle (°)	9.91 (2.99)	9.96 (2.82)	0.05 (1.06)	(-0.32; 0.43)	0.7703
9. Upper Lip Projection (mm)	8.78 (3.09)	9.07 (3.05)	0.29 (1.37)	(-0.19; 0.78)	0.2299
10. Lower Lip Projection (mm)	4.01 (4.42)	5.18 (4.73)	1.17 (1.90)	(0.49; 1.84)	0.0013*

* P < 0.05 denotes a statistically significant change

When the sample was viewed as a whole (male and female patients together), the results indicate that in this study the placement of orthodontic brackets caused statistically significant changes in the Nasolabial Angle, Maxillo-Mandibular Contour, Interlabial Angle and Lower Lip Projection. This is indicated by a P-value of less than 0.05.

The Nasolabial Angle showed an average decrease of 1.79 degrees after the placement of brackets, while the Maxillo-Mandibular Contour showed an average increase of 3.59 degrees. The Interlabial Angle decreased by a mean of 4.1 degrees after bracket placement. Lower Lip Projection demonstrated an average increase of 1.17 millimeters.

No statistically significant changes were found to occur for the remaining six parameters.

Statistical analysis was also undertaken to determine whether the sex of the patient had an influence on soft tissue changes. Readings for each of the ten profile measurements taken before and after banding were therefore also compared for male and female patients using the Student's paired t-test, the results of which are summarised in Tables 3.4 and 3.5 below.

Table 3.4: Comparison of profile measurements before and after banding for female patients

Profile Measurement	Before banding Mean (SD)	After banding Mean (SD)	Change after banding		P-Value *
			Mean (SD)	95% Confidence Interval	
1. Profile Angle (°)	165.73 (4.74)	165.60 (4.69)	-0.12 (1.63)	(-0.85; 0.60)	0.7238
2. Nasolabial Angle (°)	112.29 (7.81)	110.80 (7.26)	-1.49 (3.01)	(-2.83; -0.16)	0.0300*
3. Maxillary Sulcus Contour (°)	157.19 (9.39)	157.70 (12.01)	0.52 (6.57)	(-2.39; 3.43)	0.7151
4. Mandibular Sulcus Contour (°)	123.01 (14.71)	125.35 (14.05)	2.25 (10.04)	(-2.20; 6.70)	0.3050
5. Labio-Mandibular Contour (°)	171.32 (6.11)	170.45 (8.55)	-0.86 (7.36)	(-4.13; 2.40)	0.5873
6. Maxillo-Mandibular Contour (°)	24.71 (11.13)	29.14 (12.91)	4.43 (4.74)	(2.32; 6.53)	0.0003*
7. Interlabial Angle (°)	107.37 (17.45)	104.38 (16.95)	-2.99 (8.31)	(-6.68; 0.69)	0.1055
8. Maxillo-Facial Angle (°)	9.36 (2.68)	9.51 (2.45)	0.16 (1.03)	(-0.30; 0.61)	0.4830
9. Upper Lip Projection (mm)	7.97 (2.45)	8.70 (2.67)	0.74 (1.26)	(0.18; 1.30)	0.0122*
10. Lower Lip Projection (mm)	3.38 (4.21)	4.74 (4.85)	1.36 (1.51)	(0.69; 2.03)	0.0004*

* P< 0.05 denotes a statistically significant change

Table 3.5: Comparison of profile measurements before and after banding for male patients

Profile Measurement	Before banding Mean (SD)	After banding Mean (SD)	Change after banding		P-Value *
			Mean (SD)	95% Confidence Interval	
1. Profile Angle (°)	162.69 (5.86)	163.49 (5.93)	0.81 (1.51)	(-0.20; 1.82)	0.1056
2. Nasolabial Angle (°)	107.28 (16.71)	104.89 (17.05)	-2.40 (4.12)	(-5.16; 0.37)	0.0825
3. Maxillary Sulcus Contour (°)	157.33 (17.74)	154.74 (18.25)	-2.59 (5.29)	(-6.15; 0.96)	0.1351
4. Mandibular Sulcus Contour (°)	119.98 (13.78)	118.66 (11.11)	-1.32 (6.10)	(-5.42; 2.77)	0.4883
5. Labio-Mandibular Contour (°)	170.23 (6.69)	171.55 (6.19)	1.32 (9.32)	(-4.94; 7.58)	0.6488
6. Maxillo-Mandibular Contour (°)	29.73 (13.90)	31.65 (15.14)	1.92 (9.06)	(-4.16; 8.01)	0.4974
7. Interlabial Angle (°)	106.86 (15.62)	100.54 (17.50)	-6.31 (6.63)	(-10.77; -1.85)	0.0102*
8. Maxillo-Facial Angle (°)	11.02 (3.39)	10.87 (3.40)	-0.15 (1.15)	(-0.92; 0.62)	0.6748
9. Upper Lip Projection (mm)	10.40 (3.68)	9.80 (3.74)	-0.60 (1.17)	(-1.38; 0.19)	0.1211
10. Lower Lip Projection (mm)	5.27 (4.77)	6.05 (4.57)	0.78 (2.56)	(-0.94; 2.50)	0.3377

* P < 0.05 denotes a statistically significant change

When the profile measurements for female patients were analysed separately, the results indicate that the placement of orthodontic brackets cause statistically significant changes in the Nasolabial Angle, Maxillo-Mandibular Contour, Upper Lip Projection and Lower Lip Projection.

The Nasolabial Angle decreased by a mean of 1.49 degrees after the placement of orthodontic brackets in female patients, while the Maxillo-Mandibular Contour increased on average by 4.43 degrees. The mean Upper Lip Projection and mean Lower Lip Projection increased by 0.74 and 1.36 millimeters respectively.

When the profile measurements for male patients in this sample were analysed separately, the data indicate that the placement of orthodontic brackets result in statistically significant changes only in the Interlabial Angle.

The mean Interlabial Angle showed a decrease in 6.31 degrees in the male patients.

A summary of the resultant change in each of the profile measurements after the placement of orthodontic brackets for the group as a whole, for female patients and for male patients is illustrated in Table 3.6.

Table 3.6: Summary of resultant change in each profile measurement after banding

Profile Measurement	Whole Group	Female Patients	Male Patients
1. Profile Angle (°)	Increased	Decreased	Increased
2. Nasolabial Angle (°)	Decreased*	Decreased*	Decreased
3. Maxillary Sulcus Contour (°)	Decreased	Increased	Decreased
4. Mandibular Sulcus Contour (°)	Increased	Increased	Decreased
5. Labio-Mandibular Contour (°)	Decreased	Decreased	Increased
6. Maxillo-Mandibular Contour (°)	Increased*	Increased*	Increased
7. Interlabial Angle (°)	Decreased*	Decreased	Decreased*
8. Maxillo-Facial Angle (°)	Increased	Increased	Decreased
9. Upper Lip Projection (mm)	Increased	Increased*	Decreased
10. Lower Lip Projection (mm)	Increased*	Increased*	Increased

* denotes a statistically significant change

RESULTS OF PATIENT QUESTIONNAIRES

Patient responses to the standard questionnaire were also evaluated, the results of which are summarised in Table 3.7.

Table 3.7: Results of Patient Responses to Questionnaire

Which photograph did the patient prefer?	26 said Photograph A (79%)	6 said photograph B (18%)	1 said Neither (3%)
Could the patient see a difference between the two photographs?	30 said YES (91%)	3 said NO (9%)	
Could the patient see a difference in their profile?	26 said YES (79%)	7 said NO (21%)	
Which photograph did the patient think was taken AFTER the bands were placed?	11 said Photograph A (33%)	21 said Photograph B (64%)	1 was Not Sure (3%)

Photograph A = Taken before bracket placement

Photograph B = Taken after bracket placement

The results of the patients' responses to the questionnaire indicate that the majority of patients preferred the photograph taken before the placement of orthodontic brackets. Almost all the patients could notice a difference between the 'before' and 'after' photographs. Most could also notice a difference specifically in their profiles between the two photographs. The majority of patients were able to correctly recognise which photograph was taken after bracket placement.

When asked what differences, if any, they were able to notice in their profile between the two photographs, most patients focused on the lip, chin and cheek areas when answering this question. Many patients felt that their lips were 'fuller' or more 'swollen' in the photograph taken after banding. Another common response was that the cheek and chin areas were 'fuller' on this photograph. Others also felt that their profiles were more 'prominent' on the 'after' photograph.

CHAPTER 4: DISCUSSION

The results from this study have shown that the placement of orthodontic brackets is a contributing factor to soft tissue profile changes. Statistically significant changes were demonstrated for the sample as a whole in four of the ten profile measurements investigated, namely Nasolabial Angle, Maxillo-Mandibular Contour, Interlabial Angle and Lower Lip Projection.

A standardised orthodontic bracket type was used for all patients, namely the Nu-Edge 0.018 bracket (TP Orthodontics). Various reasons may be considered to explain the otherwise minimal influence that the presence of the appliance itself has had on the remaining six profile measurements.

Holdaway (1983) ascertained that soft tissues vary in thickness over different parts of the underlying skeletal framework. This is relevant in this study, as cognisance must be taken of the fact that patients with thicker soft tissues, such as the lips, may show less soft tissue profile changes after the placement of brackets than those with thinner tissues. The yield of the soft tissues as they 'mould' to the underlying appliance may be greater in patients with thicker tissues.

Muscle forces may have also played a role in determining the response of the soft tissues to the orthodontic brackets. Oliver (1982) demonstrated that the postural tone of soft tissues can cause a variation in the response to hard tissue changes. He found that greater changes in the lip area occurred in patients with high lip strain, but were found to be less significant in those with low lip strain. Patients with high lip strain

may for that reason have demonstrated more soft tissue changes as a result of the placement of the brackets.

It is recognised therefore that both individual soft tissue thickness and passive muscle tone are underlying factors that may have influenced the results of this current study. In order to eliminate active muscle tension, patients were asked to relax their lips while being photographed, which would hopefully have decreased the possible influence of further lip strain on the results.

Incisor position has also been shown to be an important factor in determining the pressures exerted by the lips on the teeth (Thüer, Ingervall 1986). Bearing this in mind, it may therefore be considered that patients with a Class II Division 1 discrepancy, whose upper lip pressure on the upper incisors is great, may show greater soft tissue profile changes to alterations in the underlying dento-skeletal framework. The type of malocclusion that the patient presented for was not recorded in this study.

Malocclusion type may have had direct influence on the overlying soft tissue changes.

The current study employed the use of a computer software program to measure soft tissue profile changes on photographic images of patients.

In 1995, Cummins, Bishara and Jakobsen identified various limitations of a computer assisted analysis of the soft tissue profile. They found that while the measurement of profile changes from photographs was reliable, it was also technique and operator sensitive. The limitations included problems with repeatable patient posturing and differential magnification, both of which were factors that influenced measurements taken from their photographs. Cognisance was taken of both of these aspects in the

current study. A repeatable head position was ensured by the use of the described technical set-up, allowing the head of the patient to be positioned in the identical sagittal and transversal position for successive photographs. The second factor that was addressed was the trend of differential magnification, where objects closer to the camera will tend to appear larger than those situated further away. Even though it is recognised that photographs are in essence two-dimensional representations of three-dimensional structures, the landmarks used in this study were all in the midsagittal plane, thus being essentially equidistant from the camera. This diminished any problems with differential magnification, which could have affected the accuracy of the results.

Another aspect of the Cummins, Bishara and Jakobsen (1995) study that is of relevance to this study is that the reliability of measurements may be affected by errors in landmark identification. By converting pixel measurements to millimeter measurements, it was found that an error of one pixel in locating a landmark on the screen would result in an error of 0.4 millimeters. Considering that linear measurements are defined by two landmarks, and angular measurements by three or four landmarks, the inherent error of the method would be greatly increased. Hence a detailed definition of the landmarks is essential, together with repeated assessment of accuracy in identification of landmarks on the photographs. The current study demonstrated that measurements were accurately repeated by two separate operators. Statistical evaluation of repeatability showed that accuracy of identification had been achieved.

While the changes in the four profile measurements may have been statistically significant, it is acknowledged that these changes may not necessarily have clinical

significance. For the group as a whole, the Nasolabial Angle and Interlabial Angle showed an average decrease of 1.79 and 4.1 degrees respectively after the placement of brackets, while the Maxillo-Mandibular Contour showed an average increase of 3.59 degrees. Lower Lip Projection demonstrated an average increase of 1.17 millimeters.

Even though these changes may not be clinically conspicuous, results from the patient questionnaire showed that the majority of patients were able to correctly identify which photograph was taken after bracket placement. As all possible factors were eliminated that might have assisted the patient in identifying the 'before' and 'after' photographs, the changes that the patients were able to perceive in their profiles can therefore be attributed to the influence of the brackets themselves.

It was also found that in general, males were better at correctly identifying the 'after' photograph (82% of males compared to 55% of females). However, as a general group, the female patients demonstrated more changes in their profile measurements than the male patients. While the Nasolabial Angle, the Maxillo-Mandibular Contour, the Upper Lip Projection and the Lower Lip Projection showed statistically significant changes with the placement of brackets in the female patients, the Interlabial Angle was the only profile measurement to demonstrate statistically significant change in the male patients. The sample size of male patients (11) was considerably lower than that of female patients (22). Perhaps a larger male sample would have demonstrated wider variation.

Several of the patients commented that their cheeks and lips appeared more "swollen" in the post-bonding photographs. It is possible that some tissue swelling may have

been caused by the cheek retractors, present for the duration of the application of the orthodontic appliances.

Several factors may therefore have affected the outcome of this research, which may be addressed in future studies. It may be advisable to standardise the malocclusion type, and thereby the associated soft tissue characteristics, when selecting patients for future studies. This may assist in limiting the possible influence that incisor position has had on the results, and ensure that all soft tissue profile changes can be directly attributed to the placement of the brackets themselves. A study measuring the effects of cheek retractors on the soft tissue profiles of patients may also be valuable. This study consisted of a predominantly female sample of patients. Future studies may attempt to ensure equal numbers of male and female patients in order to more accurately assess the possible influence that the sex of the patient may have had on the results.

This research was conducted using a single type of orthodontic bracket for all patients. Future research may be carried out in order to compare the profile changes occurring with various other bracket systems. This is of particular relevance to so-called 'low-profile' brackets as no scientific literature exists to validate or repudiate claims of aesthetic benefits that have been made by the various manufacturers in advertisements.

SUMMARY

This study was undertaken in order to quantify any soft tissue profile changes that may occur as a result of the placement of a specific type of orthodontic bracket. It also aimed at determining whether patients are able to perceive any changes in their own profile immediately post banding.

Right lateral photographs were taken of a group of patients before and immediately after the placement of orthodontic brackets, using a standardised photographic technique. The 'before' and 'after' photographs were analysed on a computer using the software program Corel Draw X3[®] Graphics Suite. On each profile photograph, standard soft tissue profile landmarks were identified and a series of eight angular and two linear measurements were made and recorded. The two sets of data thereby obtained were then compared with each other.

Patients were also asked several standard questions about their 'before' and 'after' profiles, and their responses were recorded.

Statistically significant changes were found for the group in four of the ten profile measurements that were investigated, namely the Nasolabial Angle, the Maxillo-Mandibular Contour, the Interlabial Angle and the Lower Lip Projection.

It was also found that the majority of patients preferred the photograph taken before the placement of the orthodontic brackets, and that most could notice a difference in their profiles between the two photographs. The majority of patients were also able to correctly recognise which photograph was taken after bracket placement.

CONCLUSIONS

The results of this study have shown the following:

1. The placement of orthodontic brackets can be associated with statistically significant changes in the soft tissue profile of patients.
2. Patients are able to perceive changes in their profiles after the placement of orthodontic brackets.
3. Patients prefer photographs of their profiles taken before the placement of orthodontic brackets.

APPENDIX A**Patient Response Collection Form**

Patient Code: _____

Date of Banding: _____

Question	Photograph A	Photograph B
1. Which photo do you prefer?		
2. Can you see a difference between the two? YES or NO.		
3. What differences, if any?		
4. Can you see a difference in your profile?		
5. What differences, if any?		
6. Which photo do you think was taken after the bands were placed?		

APPENDIX B**UNIVERSITY OF THE WITWATERSRAND, JOHANNESBURG**

Division of the Deputy Registrar (Research)

HUMAN RESEARCH ETHICS COMMITTEE (MEDICAL)

R14/49 Kebert

CLEARANCE CERTIFICATE**PROTOCOL NUMBER M050421****PROJECT**Measurement of Soft Tissue Profile
Changes as a Result of Orthodontic
Bracket Placement**INVESTIGATORS**

Dr M Kebert

DEPARTMENT


Wits Dental School

DATE CONSIDERED

05.04.29

DECISION OF THE COMMITTEE*

Approved unconditionally

Unless otherwise specified this ethical clearance is valid for 5 years and may be renewed upon application.**DATE** 05.05.29**CHAIRPERSON** 
P (Professor PE Cleaton-Jones)

*Guidelines for written 'informed consent' attached where applicable

cc: Supervisor : Dr M Jackson

DECLARATION OF INVESTIGATOR(S)To be completed in duplicate and **ONE COPY** returned to the Secretary at Room 10005, 10th Floor, Senate House, University.I/We fully understand the conditions under which I am/we are authorized to carry out the abovementioned research and I/we guarantee to ensure compliance with these conditions. Should any departure to be contemplated from the research procedure as approved I/we undertake to resubmit the protocol to the Committee. **I agree to a completion of a yearly progress report.**

PLEASE QUOTE THE PROTOCOL NUMBER IN ALL ENQUIRIES

REFERENCES

1. Arnett GW, Bergman RT. Facial keys to orthodontic diagnosis and treatment planning. Parts I and II. *American Journal of Orthodontics and Dentofacial Orthopedics* 1993; 103: 299-312, 395-411.
2. Barrer JG, Ghafari J. Silhouette profiles in the assessment of facial esthetics: A comparison of cases treated with various orthodontic appliances. *American Journal of Orthodontics* 1985; 87: 385-391.
3. Bergman RT. Cephalometric soft tissue profile analysis. *American Journal of Orthodontics and Dentofacial Orthopedics* 1999; 116: 373-389.
4. Bishara SE, Cummins DM, Jorgensen GJ, Jakobsen JR. A computer assisted photogrammetric analysis of soft tissue changes after orthodontic treatment. Part I: Methodology and reliability. *American Journal of Orthodontics and Dentofacial Orthopedics* 1995; 107: 633-639.
5. Bishara SE, Jakobsen JR, Hession TJ, Treder JE. Soft tissue profile changes from 5 to 45 years of age. *American Journal of Orthodontics and Dentofacial Orthopedics* 1998; 114: 698-706.
6. Bravo LA, Canut JA, Pascual A, Bravo B. Comparison of the changes in facial profile after orthodontic treatment, with and without extractions. *British Journal of Orthodontics* 1997; 24: 25-34.
7. Burstone CJ. The integumental profile. *American Journal of Orthodontics* 1958; 44: 1-25.
8. Burstone CJ. Lip posture and its significance in treatment planning. *American Journal of Orthodontics* 1967; 53: 262-284.
9. Cooke MS, Wei SHY. The reproducibility of natural head posture: A methodological study. *American Journal of Orthodontics and Dentofacial Orthopedics* 1988; 93: 280-288.
10. Cummins DM, Bishara SE, Jakobsen JR. A computer assisted photogrammetric analysis of soft tissue changes after orthodontic treatment. Part II: Results. *American Journal of Orthodontics and Dentofacial Orthopedics* 1995; 108: 38-47.
11. Farkas LG, Bryson W, Klotz J. Is photogrammetry of the face reliable? *Plastic and Reconstructive Surgery* 1980; 66: 346-355.
12. Farkas LG. Anthropometry of the head and face in medicine (1st Edition). p 285. New York: Elsevier North Holland Inc, 1981.

13. Fernández-Riveiro P, Suárez-Quintanilla D, Smyth-Chamosa E, Suárez-Cunqueiro M. Angular photogrammetric analysis of the soft tissue facial profile. *European Journal of Orthodontics* 2003; 25: 393-399.
14. Fernández-Riveiro P, Suárez-Quintanilla D, Smyth-Chamosa E, Suárez-Cunqueiro M. Linear photogrammetric analysis of the soft tissue facial profile. *American Journal of Orthodontics and Dentofacial Orthopedics* 2002; 122: 59-66.
15. Ferrario VF, Sforza C, Schmitz JH, Ciusa V, Colombo A. Normal growth and development of the lips: a 3-dimensional study from 6 years to adulthood using a geometric model. *Journal of Anatomy* 2000; 196: 415-423.
16. Fields HW, Vann WF, Vig KWL. Reliability of soft tissue profile analysis in children. *The Angle Orthodontist* 1982; 52: 159-165.
17. Formby WA, Nanda RS, Currier GF. Longitudinal changes in the adult facial profile. *American Journal of Orthodontics and Dentofacial Orthopedics* 1994; 105: 464-476.
18. Genecov JS, Sinclair PM, Dechow PC. Development of the nose and soft tissue profile. *The Angle Orthodontist* 1989; 60: 191-198.
19. Holdaway RA. A soft tissue cephalometric analysis and its use in orthodontic treatment planning. Part I. *American Journal of Orthodontics* 1983; 84: 1-28.
20. Kasai K. Soft tissue adaptability to hard tissues in facial profiles. *American Journal of Orthodontics and Dentofacial Orthopedics* 1998; 113: 674-684.
21. Kocadereli I. Changes in soft tissue profile after orthodontic treatment with and without extractions. *American Journal of Orthodontics and Dentofacial Orthopedics* 2002; 122: 67-72.
22. Lin J-S. An evaluation of soft tissue profile changes after removal of orthodontic brackets. Research report submitted for the degree MDent (Witwatersrand). 1983.
23. Lines PA, Lines RR, Lines CA. Profilemetrics and facial esthetics. *American Journal of Orthodontics* 1978; 73: 648-657.
24. Lundström A, Forsberg C-M, Peck S, McWilliam J. A proportional analysis of the soft tissue profile in young adults with normal occlusion. *The Angle Orthodontist* 1992; 62: 127-133.
25. Michiels G, Sather AH. Validity and reliability of facial profile evaluation in vertical and horizontal dimensions from lateral cephalograms and lateral photographs. *International Journal of Adult Orthodontics and Orthognathic Surgery* 1994; 9: 43-54.

26. Nechala P, Mahoney J, Farkas LG. Digital two-dimensional photogrammetry: A comparison of three techniques of obtaining digital photographs. *Plastic and Reconstructive Surgery* 1999; 103: 1819-1825.
27. Oliver BM. The influence of lip thickness and strain on upper lip response to incisor retraction. *American Journal of Orthodontics* 1982; 82: 141-149.
28. Peck H, Peck S. A concept of facial aesthetics. *The Angle Orthodontist* 1969; 40: 284-318.
29. Peck S, Peck L. Selected aspects of the art and science of Facial Esthetics. *Seminars in Orthodontics* 1995; 1: 105-126.
30. Prahli-Andersen B, Ligthelm-Bakker AS, Wattel E, Nanda R. Adolescent growth changes in soft tissue profile. *American Journal of Orthodontics and Dentofacial Orthopedics* 1995; 107: 476-483.
31. Ricketts RM. Esthetics, environment and the law of lip relation. *American Journal of Orthodontics* 1968; 52: 804-822.
32. Ricketts RM. The biologic significance of the divine proportion and Fibonacci series. *American Journal of Orthodontics* 1982; 81: 351-370.
33. Saxby PJ, Freer TJ. Dentoskeletal determinants of soft tissue morphology. *The Angle Orthodontist* 1985; 55: 147-154.
34. Soncul M, Bamber MA. Evaluation of facial soft tissue changes with optical surface scan after surgical correction of Class III deformities. *Journal of Oral and Maxillofacial Surgery* 2004; 62: 1331-1340.
35. Soncul M, Bamber MA. The reproducibility of the head position for a laser scan using a novel morphometric analysis for orthognathic surgery. *American Journal of Orthodontics and Dentofacial Orthopedics* 2000; 29: 86-90.
36. Subtelny JD. A longitudinal study of soft tissue facial structures and their profile characteristics defined in relation to underlying skeletal structures. *American Journal of Orthodontics* 1959; 45: 481-507.
37. Teitelbaum V, Balon-Perin A, De Maertelaer V, Daelemans P, Glineur R. Impact of dental and skeletal movements on the facial profile within the framework of orthodontic and surgical treatments. *International Journal of Adult Orthodontics and Orthognathic Surgery* 2002; 17: 82-88.
38. Thüer U, Ingervall B. Pressure from the lips on the teeth and malocclusion. *American Journal of Orthodontics and Dentofacial Orthopedics* 1986; 90: 234-242.
39. Todd SA, Hammond P, Hutton T, Cochrane S, Cunningham S. Perceptions of facial aesthetics in two and three dimensions. *European Journal of Orthodontics* 2005; 27: 363-369.

40. Üşümez S, Orhan M. Reproducibility of natural head position measured with an inclinometer. *American Journal of Orthodontics and Dentofacial Orthopedics* 2003; 123: 451-454.
41. Valentim ZL, Capelli Junior J, Almeida MA, Bailey LJ. Incisor retraction and profile changes in adult patients. *International Journal of Adult Orthodontics and Orthognathic Surgery* 1994; 9: 31-36.
42. Wholley CJ, Woods MG. The effects of commonly prescribed premolar extraction sequences on the curvature of the upper and lower lips. *The Angle Orthodontist* 2003; 73: 386-395.
43. Yogosawa F. Predicting soft tissue profile changes concurrent with orthodontic treatment. *The Angle Orthodontist* 1990; 90: 199-206.