

THE PROGNATHOUS MANDIBLE: ITS INVESTIGATION

C. J. DREYER, B.Sc. (SA), B.D.S., H.DIP.DENT. (RAND), F.O.S. (S.A.)

Joint University of the Witwatersrand and Council for Scientific and Industrial Research
Dental Research Unit, Milner Park, Johannesburg

THE contours of the face are largely dependent on the proportionate size and shape of the individual bones forming the skull. Thus a concave profile could be caused by an anterior position of the frontal region of the skull; a small maxillary complex; a large mandible; a forward position of the mandible; or a combination of these skeletal abnormalities.

The differential diagnosis between maxillary deficiency and mandibular overgrowth and certain aspects of the investigations prior to surgical treatment of mandibular overgrowths will be discussed.

The first phase of the investigation of a patient with a concave profile is inspection.

If the patient with a prognathous mandible is tall and has well developed mid-facial structures the prognathism can usually be attributed to an overgrowth of the mandible. On the other hand a lack of growth of the maxilla is usually responsible for the seemingly prognathous mandible seen in the small patient with the concave profile.

The intra-oral examination and dental history of the patient usually provides valuable information. Apart from such complicating factors as early extractions, habits, abnormal tooth material, incorrect incline plane relationship, altered axial inclinations and pathological processes, the arch form is indicative of the location of the skeletal dysplasia. Correct alignment of all the teeth in a well rounded maxillary arch is a sign that maxillary growth has been adequate and that the prognathism is thus mainly due to mandibular overgrowth. Under these circumstances the teeth in the lower arch are usually easily accommodated — often with spacing (Fig. 1).

The movements of an enlarged mandible may also aid in the diagnosis. The restriction of protrusive movement, often to less than 10 mm., and the predominance of a hinge movement in the temporomandibular joint during opening and closing are more often associated with overgrowth of the mandible than with a maxillary deficiency.

Cephalometric analysis is not only a valuable aid in diagnosis, but is essential for planning the surgical treatment.

The cephalometric analysis of a patient with a mandibular prognathism not only yields information about dental pattern but the skeletal appraisal is perhaps one of the most reliable methods of assessing the proportional growth of the maxillary complex and the mandible.

The Downs analysis of prognathism caused by a mandibular dysplasia shows the following features:

1. The facial plane angle is high or within normal limits.
2. Angle of convexity is usually lower than normal.
3. A-B plane is usually more positive than normal.
4. Mandibular plane angle is usually higher than normal.
5. Y axis is often within the normal range.

Even though the diagnosis of an excessive antero-posterior growth of the mandible can usually be made on the Downs analysis only, the presence of the so-called button on the chin and high gonial angles will lend further support to the diagnosis. The main differences between Class III's (Angle) caused by mandibular overgrowth and by maxillary deficiency are demonstrated in Fig. 2.

After clinical and cephalometric exami-

nations have established that an overgrowth of the mandible is responsible for the Class III appearance, the type and distribution of the overgrowth has to be investigated. Disproportionate growth of the mandible can be grouped into three categories.

First, excessive lateral growth of the mandible with minimal excessive antero-posterior growth. This skeletal dysplasia does not mar the facial appearance and the Downs' cephalometric analysis simulates the normal. Intra-oral examination often shows spacing in the lower arch and unilateral or bilateral posterior cross bite. This group is either uncommon or may only seem so because it causes so little aesthetic disturbance and is thus seldom referred for orthodontic or surgical treatment.

Secondly, excessive antero-posterior growth of the mandible with minimal excessive lateral growth. This group presents for treatment more commonly than the first group described and is easily recognized on clinical and cephalometric examination. As can be expected, this type of Class III gives a most satisfactory aesthetic and functional result after surgical treatment.

Thirdly, a mixture of excessive lateral and antero-posterior growth. This is the most common group. The aesthetic result of surgical treatment is usually excellent, but as the more excessive lateral growth predominates, so the more the chances of good occlusion of the posterior teeth diminish.

The degree to which the excessive growth of the mandible has affected the two halves of the mandible can be assessed by comparing the lower centre line to the mid-sagittal plane, the occlusion (Fig. 3), the shape of the dental arches and an X-ray view of the cranial base (Fig. 4).

The patient with unilateral hyperplasia has a distinctive swing of the mandible during opening and closing movements. Whereas the centre line of the lower deviates to the side opposite the condylar hyperplasia in the rest position, it generally approximates the mid-sagittal plane in the course of opening.

Excessive unilateral growth associated with an enlarged condyle should be re-

garded as a sign that condylar growth could still continue. Thus the prognosis of the prognathous mandible due to unilateral condylar hyperplasia is not as favourable as those due to excessive bilateral growth associated with condyles of normal dimensions.

NATURE OF THE TREATMENT

The treatment of a patient with a prognathous mandible may be achieved by orthodontic or surgical treatment or a combination of the two.

A favourable result can be achieved in the majority of patients with prognathous mandibles by means of orthodontic treatment only. However, as the skeletal deformity assumes greater proportions the best treatment may be orthodontic and surgical treatment, or surgical treatment only.

The validity of orthodontic treatment of a skeletal deformity may be challenged by those who believe that such treatment only affects the bone growth of the alveolar process and that the morphological pattern of an individual is constant.

It cannot be denied that the immediate bony changes resulting from tooth movement are mainly to be found in the alveolar processes; but the correlation between sinus formation and the degree of function of the teeth shows that functioning teeth affect bone resorption and deposition far beyond the alveolar processes.

The second indication that the position and perhaps the growth of the mandible can be affected by extrinsic factors is derived from the use of the chin strap. Clinical evidence suggests that use of the chin strap during the retention period of the orthodontic treatment of a (Angle) Class III malocclusion which is due to excessive mandibular growth, enhances the stability of the occlusion after the bands have been removed.

The third consideration is the part that subperiosteal bone growth plays in mandibular and maxillary growth. Since knowledge of all the factors stimulating this form of bone growth is not complete, it may be accepted that the repositioning of teeth and the subsequent alteration of function could to a greater or lesser degree affect this form of growth and therefore

the gross morphological characteristics of the jaws.

The above arguments are not presented as destructive criticism of the concept that the morphological pattern of the facial skeleton is genetically determined and retained from an early period of post-natal life to the adult stage, but to show that it can only be accepted with certain reservations. In the same way that metabolic disturbances caused by growth hormone or lack of thyroid hormone upset the inherited skeletal pattern, so alterations in the functional activity of the masticatory system may also affect bone growth.

Thus the growth in the condylar region of the mandible and the suture systems of the maxillary complex as well as all the other forms of appositional bone growth in the maxillary and mandibular could be affected by functioning teeth.

If one accepts that function can affect bone growth then such effects should be most noticeable while the bone growth is most active. It is therefore desirable to institute orthodontic treatment as soon as the prognathism is recognized. However, even if infants are brought for treatment during this period, so many practical difficulties and problems exist that orthodontic treatment is usually postponed until the early mixed dentition stage. It is impossible to assess how a particular skeletal abnormality would have progressed had it not been treated; but the satisfactory results achieved in many patients with this skeletal dysplasia more than justifies the treatment of all such patients during this phase of life.

During the next few years correction by orthodontic means should still be attempted in the majority of cases; but by the time the second molars have erupted it is usually possible to divide most of the patients with prognathous mandibles into two groups: those who may still benefit from orthodontic treatment, and those who could only be treated adequately by means of a combination of orthodontic and surgical procedures or by means of surgery only. When surgical treatment is complemented by orthodontic treatment, it is customary to complete the orthodontic treatment just prior to the surgical procedures.

AGE AT WHICH THE PROGNATHIC MANDIBLE SHOULD BE CORRECTED SURGICALLY

It has been customary to postpone this operative procedure until the late teens or early twenties after the analysis of two sets of headplates taken at six-monthly or one-yearly intervals have shown minimal or no growth changes in the jaws. However the operation could be done soon after the puberty growth spurt. Such early surgical treatment for this abnormality will have two major advantages over the present late operations. First the repair processes are so much more rapid and secondly the psychological advantages are obvious.

The fact that it has been shown that no fixed growth pattern exists for all facial types and that the growth of the jaws is not complete at the end of the puberty growth spurt, should not present any practical difficulties; since the bone growth which occurs in the mandible during the adolescent phase of life mainly increases the facial height, while only a minimal amount of the osteogenesis occurring in the mandible is translated into antero-posterior growth of the mandible.

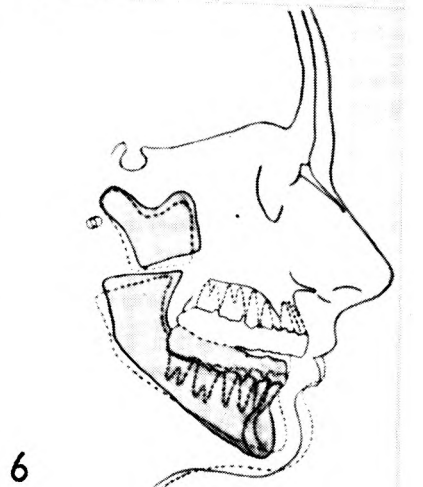
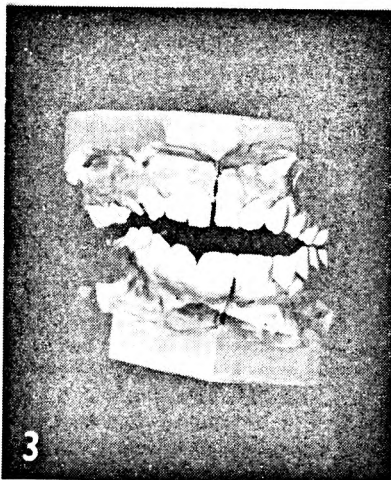
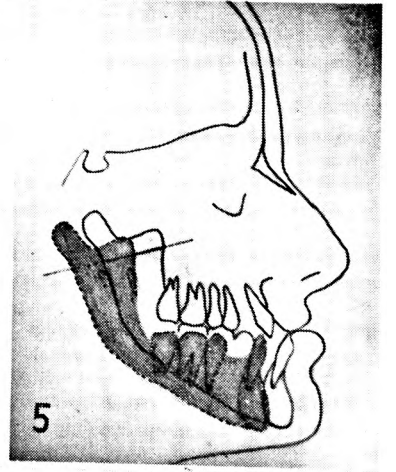
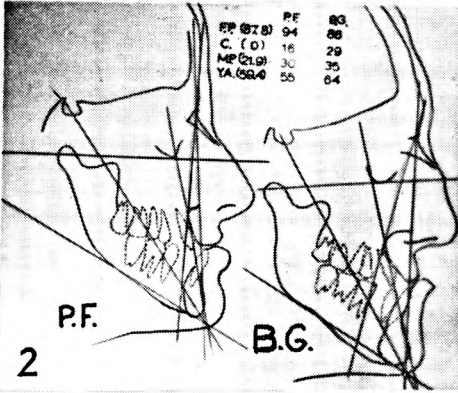
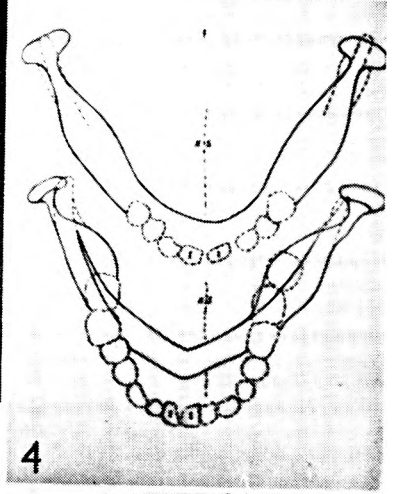
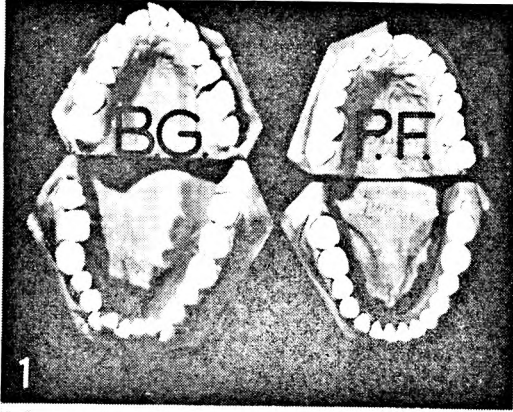
In the absence of varying intrinsic and extrinsic factors, the antero-posterior discrepancy between maxilla and mandible is due to disproportionate growth prior to adolescence. Therefore, even without making any provision for further disproportionate growth, it seems as if surgical correction could be carried out in the mid-teens in girls and slightly later in boys without fear of any relapses due to further antero-posterior growth of the mandible.

PREDETERMINATION OF MANDIBLE POSITION AFTER SURGICAL TREATMENT

Without utilizing the findings and making allowances for the known post-operative changes that occur, a satisfactory end result can hardly be achieved merely by articulation of the upper and lower models in what appears to be a satisfactory occlusion. The assessment of the new mandibular position can be made only after the following factors have been considered:

1. *Occlusal interference in the new position*

Marked occlusal interference may require extraction of certain teeth or if this is not indicated then the interferences may have to be corrected by means of ortho-



dontic treatment prior to the surgical procedures.

Moderate cuspal interference should be corrected by preliminary spot-grinding prior to the construction and fixation of the splints and then completed after the splints have been removed.

FIG. 1.—Occlusal view of models shows a deficiency of maxillary growth (B.G.) and mandibular overgrowth (P.F.).

FIG. 2.—Cephalometric analysis (after Downs) of a deficiency of maxillary growth (B.G.) and a mandibular overgrowth (P.F.).

FIG. 3.—Models of the jaw of a patient with a unilateral condylar hyperplasia showing the malocclusion and the typical deviation of the lower centre line to the side opposite the lesion.

FIG. 4.—Tracing of cranial base views of a bilateral and of a unilateral overgrowth of the mandible. The enlarged condyle and the deviation of the centre line is evident in the tracing of the unilateral lesion.

FIG. 5.—Composite tracing from a patient with a mandibular prognathism. The predetermined position of the mandible, as indicated by the shaded portion of the tracing, determined the angulation of the incision through the ramus.

FIG. 6.—Superimposition of the tracings from a patient after a bilateral osteotomy. The broken line tracing shows the relationship between the fragments and position of the body of the mandible, seven weeks after the operation, just prior to mobilization. The solid line tracing shows the changes that occurred 24 hours after mobilization but without removal of the splints.

2. Repositioning of the teeth

Any form of surgical treatment which reduces the mandibular prognathism must also disturb the balance of forces acting on the teeth. The changes that occur in arch form, after a bilateral osteotomy, are not pronounced in the buccal segments but the anterior segments usually undergo certain changes. The lower incisors tend to be uprighted if a lingual angulation exists prior to the operation. The upper incisors are not so markedly affected but may become more labially inclined.

Unless allowance is made for the uprighting of lingually inclined lower in-

cisors when predetermining the new mandibular position a relapse may occur. The relapse which is then primarily due to change in occlusion may be followed by a mandibular movement which exaggerates the deterioration.

3. Angulation of the incision through the rami

Correct angulation of the incision through the rami facilitates not only the posterior but also the inferior repositioning of the body of the mandible thus allowing an opening of the bite posteriorly as well as closure anteriorly if necessary. In this way contact between the fragments is maintained during the immediate post-operative period without noticeable anterior displacement of the condylar fragments due to the action of the lateral pterygoid muscle. The angle of the incision is calculated on the lateral head-plate with the jaws in the closed position. A tracing of the mandible is made and one point on the anterior margin of each ramus is marked on the film and tracing. The tracing of the mandible is then moved to a position where allowance is made for the uprighting of the incisors and the posterior opening of the bite. The two marked points on the anterior margin of each ramus are joined and this line indicates the angulation of the incision through the rami of the mandible (Fig. 5).

4. Development of an open bite

Post-operative changes which result in an anterior opening of the bite occur almost invariably after bilateral sectioning of the rami and reduction of the prognathism. The opening of the bite starts to take place as soon as immobilization is discontinued and generally reaches its peak after 48 hours. It is usually not accompanied by pain and seems to recur to the same extent even if the mandible is completely reimmobilized for further periods of one to three weeks.

The development of the open bite seems to be related to the amount of posterior and inferior repositioning of the mandible and the speed with which it occurs after immobilization is indicative of a repositioning of the condyles in the fossae or due to movement between the fragments.

Although certain alterations do occur

in the temporo-mandibular joints during the post-immobilization period, these changes are not of sufficient magnitude to produce the vertical divergence which occurs in the incisor region.

Movement between the condylar and ramus fragment of the resected mandible must thus be the major cause of the development of the anterior open bite (Fig. 6).

The mechanism and cause of the movement between the fragments is still a matter for further investigation but if the repair processes of an accidental fracture and a bilateral osteotomy are compared some light may be thrown on the problem.

The union which occurs after a three to eight week period of immobilization of a fracture of the mandible is characterized by a certain degree of springiness. If the mandible is mobilized after this type of union has occurred it is unusual to detect any further displacement of the fragments during the last phase of the repair process.

The callus formed during the early phase of repair in the mandible therefore has some elasticity but the displacing forces acting on the two fragments are not of sufficient magnitude and duration to alter the relationship of the two fragments permanently.

However, after bilateral osteotomy

where the position of the body of the mandible has been markedly altered, movement between the fragments may occur as a result of tension developed in the structures attached to the lower half of the rami and posterior portions of the body of the mandible. The only anatomical structures attached to this area in which appreciable tension could occur, are muscles and connective tissue bands. The nature of the opening is not indicative of muscular contraction as the source of tension. However, tension in the connective tissue bands attached to the mandible may be the source of the difficulty. The basis of this surmise is that occasionally after the rami are sectioned above the mandible foramen the body of the mandible becomes mobile but the desired amount of posterior and inferior movement cannot be achieved without the use of considerable force. Since muscle is unlikely to offer this type of resistance, the full movement of the major fragment is probably resisted by connective tissue structures such as the pterygo-mandibular raphe or the stylo-mandibular ligament.

From the practical point of view, it is immaterial how the open bite is caused; but when the models are articulated for constructing the splints, provision must be made to compensate for the open bite which occurs after this operation.