

https://dspace.org/

Location of Mandibular foramen on Mandibles of adult black South African population: a morphometric analysis and investigation into possible radiographic correlation

Tshite, Koketso

2017

http://hdl.handle.net/10539/23310

Downloaded from a DSpace repository. https://dspace.org/

LOCATION OF MANDIBULAR FORAMEN ON MANDIBLES OF ADULT BLACK SOUTH AFRICAN POPULATION: A MORPHOMETRIC ANALYSIS AND INVESTIGATION INTO POSSIBLE RADIOGRAPHIC CORRELATION.

Koketso Tshite



WITS
UNIVERSITY

A research report submitted to the Faculty of Health Sciences, University of the Witwatersrand, Johannesburg, in partial fulfilment of the requirements for the degree of Masters of Science in Dentistry.

Johannesburg, 2017

DECLARATION

I, Koketso Tshite, declare that this research report is my own work. It is being submitted for the degree of Masters of Science in Dentistry in the University of the Witwatersrand, Johannesburg. It has not been submitted before for any degree or examination at this or any other University.

……. Signature of candidate

……day of……..2017

DEDICATION

This dissertation is dedicated to:

The All Mighty God, my Lord Jesus Christ, for in Him I was chosen and have been enriched in every way.

My son and daughter: Lukhanyo and Khwezilomso Mbambo.

My husband Ntobeko Mbambo, for his ongoing support and immense patience.

My parents Moruakgomo and Matshidiso Tshite, for their constant solace during my studies.

My sisters Dr Felicia Tshite-Molamu and Ontiretse Tshite, my brothers Percy and Victor Tshite, whose affection, love, encouragement and prayers of day and night enabled me to get such triumph and prestige.

My helper Mahlaku Phokwane, for her absolute commitment.

PRESENTATIONS ARISING FROM THIS STUDY

Postal presentation at the International Association of Dental Research (IADR) 2016, Cape Town:

Morphometric analysis of the location of mandibular foramen in adult black South African population.

Abstract

The objective of the study was to determine the exact location of the mandibular foramen among black South African population using a possible correlation of radiographic and morphometric analysis. Sexual dimorphism in the position of the foramen was taken into consideration. This study was conducted on a total of 253 adult dry human mandible specimens and 24 adult radiographic data from the cone beam computed tomographic records of patients. Both male and female specimens of ages between 16-56 years old and above were examined for morphometric analysis. The age group for the radiographic analysis was between 21-25 years old. The length, height and distance of the mandibular foramen in relation to the anterior and posterior border of the ramus of the mandible; superior and inferior border of the mandible as well as the distance in relation to the coronoid & condyle were measured. All the measurements were taken using a mandibulometer and the Dental sliding digital callipers for the morphometric analysis. For both radiographic and morphometric analyses, the distance of the mandibular foramen (MF) to the posterior region of ramus was smaller than that of MF to anterior region. The same pattern of results were observed for both males and females in all age groups. Males generally showed greater readings than females in all parameters, except the MF-P measurement. The MF was situated more towards the superior part of the mandible in the morphometric study. In the radiographic study, the MF was situated more towards the inferior part of the mandible. No significant difference was noted amongst different age groups.

With regards to the antero-posterior dimensions of the mandible, the MF was found to be situated more towards the posterior region of the ramus for both radiographic and morphometric analyses in all age cohorts. With regards to infero-superior dimensions of the mandible, the MF was situated more towards the superior part of mandible in the

morphometric analysis, but more towards the inferior part of the mandible in the radiographic analysis. In conclusion, the position of the MF was constant with regards to the antero-posterior dimensions for both radiographic and morphometric analyses. Therefore, this suggests that the chances of finding the MF in the anterior border of ramus of mandible are limited hence the anterior border can be regarded as the "safety zone" in a South African population.

ACKNOWLEDGEMENTS

A successful project cannot be prepared and achieved by single efforts only or by whom the project is assigned, but it demands the guardianship of some conversant people who assist in the completion of a successful project. I therefore extend my sincere gratitude to my supervisors: Dr Olatunbosun Olaleye, Professor Ejikeme Mbajiorgu and Professor Brian Buch for all their assistance and guidance. Moreover Dr Olatunbosun Olaleye who at all times availed himself for indispensable advice and succour.

My gratitude is sincerely expressed further to the following people:

My spiritual parents: Apostle Dr Francis Hillary Sakufiwa and Pastor John and Jenny Rose, for their unceasing intercessions which reinforced my faith.

Mr Brendon Billings, Curator (Raymond Dart Collection of Human skeletons) in the School of Anatomical Sciences, University of the Witwatersrand, for his bright ideas and advice in morphological anatomy.

Mr Adedayo Tunde Ajidahun for his invaluable assistance with the statistical analysis.

Dr Tobias Houlton for his assistance with the project pictures.

My Head of Department, Dr Daisy Fidelis Kotsane and my departmental colleagues for their comprehension.

School of Anatomical Sciences and Wits School of Oral Health Sciences, University of the Witwatersrand, Johannesburg, South Africa for allowing me to conduct my project in their premises.

TABLE OF CONTENTS

DECLARATION II
DEDICATION III
PRESENTATIONS ARISING FROM THIS STUDY IV
Abstract V
ACKNOWLEDGEMENTS VII
TABLE OF CONTENTS VIII
LIST OF TABLES XI
LIST OF ABREVIATIONS XII
APPENDICES: XIV
1. Chapter one: Introduction 1
1.1. Background 1
1.2. Aim of the study 1
1.3. Objectives of the study 1
1.4. Type of study 2
1.5. Significance of study 2
1.6. Literature review 2
1.6.1. Anatomy and embryology of mandibular foramen 2
1.7. Population groups previously studied 3
1.8. Significance of the mandibular foramen 4
1.9. Limiting factors of a successful inferior alveolar nerve block 5
1.10. Complications associated with Orthognathic Surgery 6
1.11. Modalities used to determine the position of mandibular foramen 6
1.12. Conclusion of literature review 7
2. Chapter two: Materials and methods 8
2.1. The study has two components: Dry bone and CBCT radiographs. 8
Site of the study 8
2.2. Study population 8
2.3. Inclusion criteria for both dry bones and CBCT radiographs: 8
2.4. Exclusion criteria for both dry bones and CBCT radiographs: 8
2.5. Measuring instruments 9
2.6. Data collection for both dry bones and CBCT radiographs: 10

2.7. Data analysis for both dry bones and CBCT radiographs: 15
2.8. Ethical consideration 16
2.9. Study limitations 16
2.10. Source of bias 16
3. Chapter three: Results 17
3.1. Sample size, age and sex stratification 17
3.2. Test for normality 17
3.3. Distribution of the demographics 19
3.4. Morphology measurements of the samples 20
3.5. Sex distribution of samples 21
3.6. Age distribution of the samples 23
3.7. Mean difference in morphometric measurements 25
3.8. Distribution of radiographs measurement 26
3.9. Comparison between the mean measurements of the radiograph and the morphometric 27
4. Chapter four: Discussion 29
4.1. Morphometric study 29
4.2. Radiographic component 35
4.3. Comparison between morphometric and radiographic measurements 38
4.4. Summary of the discussion 39
5. Chapter five: Conclusion 40
REFERENCES 41

LIST OF FIGURES

Figure 2.1: Illustration of some of the measurements carried out in the morphometric study. 9
Figure 2.2: Illustration of some of the measurements carried out in the radiographic study. Internet accessed on 23 March, 2017. 10
Figure 2.3: Internal surface of ramus of mandible. MF-A; MF-P; A-P; MF-GO; MF-S. 11
Figure 2.4: Internal surface of ramus of mandible. MF-I; MF-H; MF-GO; H-GO. 12
Figure 3.1: Histogram showing normal distribution of the morphometric LMF-P data 18

LIST OF TABLES

Table 2.1: Various parameters on the ramus of mandible 13
Table 2.2: Additional parameters in the current study 14
Table 2.3: Age groups of dry mandibles 15
Table 3.1: Shapiro-Wilk test for normality 17
Table 3.2: Demographics of the morphometric samples 19
Table 3.3: Mean of morphology measurement of the total sample 20
Table 3.4: Gender distribution of samples 22
Table 3.5: Age distribution of the morphology 24
Table 3.6: One way analysis of variance (ANOVA) between the age groups 25
Table 3.7: Radiograph measurements of the 21-25 age cohort. 26
Table 3.8: Comparison between the mean measurements of the radiograph and the morphometric 28

LIST OF ABREVIATIONS

AMFs: Accessory mandibular foramina

ANOVA: Analysis of variance

CBCT: Cone beam computed tomography

GO-M: Distance from the most posterior border of the ramus of mandible to the most anterior point on the menton
H-GO: Distance from the highest point of condylar head to the most inferior point on the ramus of mandible
IAN: Inferior alveolar nerve

IANB: Inferior alveolar nerve block

IANVB: Inferior alveolar neurovascular bundle

L: Lingula of mandible

MF: Mandibular foramen

MF-A: Distance from the midpoint of the anterior margin of MF to the nearest point on the anterior border of ramus of mandible
MF-GO: Distance from the inferior point of the MF to the furthest point on the inferior border of ramus of mandible
MF-H: Distance from the most inferior point of the MF to the highest point on the condylar head
MF-I: Distance from the highest point of coronoid notch to the most inferior point on the MF
MF-P: Distance from the midpoint of the posterior margin of MF to the nearest point on the posterior border of ramus of mandible
MF-S: Distance from the lowest point of sigmoid notch to the inferior point of MF
P-A: Distance from the most posterior border of ramus of mandible to the most anterior point on the ramus of mandible
S-GO: Distance from the lowest point of sigmoid notch to the most inferior point of ramus of mandible

SSO: Sagittal split osteotomy

SSRO: Sagittal split ramus osteotomy

V_3: Third division of Trigeminal nerve

APPENDICES:

1. **Appendix 1:** Data collection sheet.
2. **Appendix 2:** Human Research Ethics Committee (Medical).
3. **Appendix 3:** Wits Oral Health Centre Research Committee.
4. **Appendix 4:** School of Anatomical Sciences tentative approval letter

1. Chapter one: Introduction

1.1. Background

The mandibular foramen (MF) is one of the openings found in human mandibles together with mental foramen. MF is located bilaterally and just above the centre of the internal surface of ramus of mandible (Samanta and Kharb, 2013; Thangavelu *et al.,* 2012). However, the exact position of MF varies amongst different population groups (Alves and Deana, 2014; Mbajiorgu, 2000; Olivier *et al.,* 2010; Thangavelu *et al.*, 2012).

MF is a very significant anatomical landmark in clinical dentistry because it serves as an entry point for inferior alveolar nerve (IAN) and its accompanying vascular structures known as inferior alveolar artery and vein, which navigate the mandibular canal to provide sensation and blood supply to mandibular teeth (Samanta and Kharb, 2013; Thangavelu *et al.,* 2012).

In clinical dentistry, inferior alveolar nerve block (IANB) is a common local anaesthetic given to patients that may require extractions and deep restorations of posterior mandibular teeth, thus, the variations in the position of MF may hinder dental clinicians to achieve a successful inferior alveolar nerve block, which in turn may result in local anaesthetic toxicity as well as damage to inferior alveolar neurovascular bundle (IANVB). Consequently, it is a prerequisite for dental clinicians to be familiar with the position of MF in order to avoid such complications.

1.2. Aim of the study

The aim of this study was to determine the location of mandibular foramen in mandibles of adult black South African population and to correlate bony morphometric data with radiographic data.

1.3. Objectives of the study

The objectives of this study are:

1. To determine the mean position of MF on radiographs using the cone beam computed tomography (CBCT) and on dry human mandibles of black South African cohort.
2. To determine the influence of sex and age specific differences in the position of mandibular foramen of black South African cohort.

3. To comparatively analyse data obtained from both radiographic and morphometric measurements by determining any possible correlation.

1.4. Type of study

Retrospective and cross-sectional study that included 253 dry human mandibles and 24 CBCT radiographs.

1.5. Significance of study

Numerous reports on the failure rate of inferior alveolar nerve block (IANB) as well as damage to inferior alveolar neurovascular bundle (O'Ryan and Araujo, 1999) led to morphometric and radiographic investigation into determining the position of MF in various population groups. Results showed differences, amongst males and females of different population and age groups and the conclusions were such that factors as ancestry, sex and age affect the location of MF.

There are no published studies thus far in the South African population; therefore, there are no records or data on the position of MF in relation to the different parameters of the ramus of mandible. Furthermore, the use of CBCT in clinical dentistry has become very popular because the images of CBCT are 3 dimensional and they give more precise visualization of the anatomical structures in the maxillofacial region. Thus, this study will provide the South African morphometric data obtained from both dry adult human mandibles and radiographic data obtained from the CBCT radiographs of patients with the purpose of investigating any possible correlation between the two analyses. The outcome of the investigation will therefore facilitate locating the MF in relation to the different borders of ramus of mandible, considering sex and age aspects. The information of which will provide the dental clinicians with the predictable indicators that will assist them to achieve a successful IANB and surgical procedures such as the sagittal split ramus osteotomies (SSRO) without inferior alveolar nerve bundle fatalities.

1.6. Literature review

1.6.1. Anatomy and embryology of mandibular foramen

Mandibular foramen lies in close proximity to the Lingula (L) of mandible. The lingula is described as a tongue-shaped bone projection on the medial aspect of ramus just anterior to MF, which further continues along the mandibular channel (Lopes *et al.*, 2010 ;Monnazzi *et*

al., 2012). Between the 4th and 8th week post fertilization, bilateral development of mandibular prominences together with frontonasal and maxillary prominences occur which together give rise to human face (Allan and Kramer, 2002). However, it is only during the 24th week of intrauterine life that the mandibular foramen and canal form. The mandibular foramen and canal both develop during the process of intramembranous ossification of the body and ramus of mandible, which occurs in the presence of inferior alveolar neurovascular bundle (IANVB) (Alves and Deana, 2014). The shapes of mandibular foramen and canal are completed as the process of ossification progresses (Park and Lee, 2015).

1.7. Population groups previously studied

The exact position of MF has been reported to vary amongst males and females of different population and age groups (Alves and Deana, 2014; Mbajiorgu, 2000; Olivier *et al.,* 2010; Thangavelu *et al.,* 2012). Nonetheless, MF has always been found in the posterior region of the ramus of the mandible (Samanta and Kharb, 2013).

The MF is always situated in the ventral and inferior two-thirds of ramus with no differences according to side, sex and age (Olivier *et al.,* 2010). Furthermore, other locations of MF were reported to be the middle part of the ramus, 3rd quadrant, level of occlusal plane, below the occlusal plane and at midpoint of the ramus of mandible (Mbajiorgu, 2000).

A study done in Kenya on the location of the MF showed that 4.7%, 64.6% and 30.7% of the mandibular foramen was located above, below and at the level of the occlusal planes respectively (Roberts and Sowray, 1979). These results were different from the ones discovered in the East Indian population which revealed 2.5%, 75% and 22.5% above the occlusal plane, below the occlusal plane and at the level of the occlusal plane respectively (Nicholson, 1985). It has been discovered that the position of the MF is affected by the degree of the mandibular angle (Gabriel, 1958). The more oblique the angle of the mandible is, the further forward and higher up the MF will be (Gabriel, 1958). A study carried out on 120 mandibles by Marzola *et al.,* (2005), noted that on average the mandible angle is 130 degrees.

In 2010, Trost and colleagues reported that the probability of the MF being located either in posterior or superior third of ramus of mandible is very low and they referred to those two regions as the safety zone. The main role of the safety zone is to allow the oral and maxillofacial surgeons to perform SSRO for correction of underlying skeletal abnormalities without damaging the IAN and its accompanying vascular structures (Olivier *et al.,* 2010).

MF is positioned at an equidistant anteroposterior point relative to ascending ramus; it is 18mm from the anterior border; 17 mm from the posterior border; 21 mm above from the mandibular foramen and 21 mm from the top of the condyle (Marzola, *et al.,* 2005). Since the MF lies in close proximity to the lingula of the mandible, the distance from the mandibular foramen to the upper point of lingula was also examined. Results showed that the average distance of the MF to lingula was 4.8 mm while it was 3.6mm to the midpoint of the line of the shortest distance between the anterior and posterior ramus of the mandible (Martone *et al.,* 1993).

1.8. Significance of the mandibular foramen

MF is a very significant anatomical landmark in clinical dentistry because it serves as an entry point for the inferior alveolar nerve (IAN) and its accompanying vascular structures known as inferior alveolar artery and vein (Thangavelu *et al.,* 2012). The inferior alveolar artery which is a branch of the maxillary artery directs downward and laterally in the pterigomandibular space, accompanied by the corresponding IAN and entering the mandibular foramen (Teixeira *et al.,* 2008). It is very important because as it runs through the mandibular canal, it sends branches to the pulp, bone, and gingiva, therefore, any injury will compromise vascularization of these tissues.

The mandibular nerve which is a third division (V_3) of the largest cranial nerve called Trigeminal nerve, gives rise to the IAN (Strini *et al.,* 2006). As soon as the inferior alveolar neurovascular bundle enters the mandibular foramen, it traverses the mandibular canal, supplying the mandibular teeth (Samanta and Kharb, 2013). The IAN exits the mandible through the mental foramen, giving sensory branches to the skin and mucosa of the lower lip as well as the gingivae of canine to 1st mandibular molar (Teixeira *et al.,* 2008).

In clinical dentistry, inferior alveolar nerve block (IANB) is a common local anaesthesia given to patients that may require extractions and deep restorations of posterior mandibular teeth (Padmavathi *et al.,* 2014). In order to achieve a successful anaesthesia, a dental clinician is supposed to inject the local anaesthesia around the IAN before it enters the MF. The technique which is used in IANB is called the Halsted technique and the success of this technique depends on placing the tip of the needle close to the mandibular foramen and injecting the local anaesthesia in the pterygomandibular space (Mbarjiorgu, 2000; Padmavathi *et al.,* 2014).

1.9. Limiting factors of a successful inferior alveolar nerve block

The variations in the position of MF may increase the risk of inferior alveolar nerve block (IANB) failure and damage to the inferior alveolar neurovascular bundle (Alves and Deana, 2014; Mbajiorgu, 2000; Olivier *et al.,* 2010; Samanta and Kharb, 2013; Thangavelu *et al.,* 2012). Therefore, if the dental clinicians are not familiar with the position of MF, it will be difficult to achieve a successful IANB and that could also lead to repeated injections which can result in local anaesthetic toxicity (Alves and Deana, 2014; Olivier *et al.,* 2010; Padmavathi *et al.,* 2014; Shuchardt, 1942; Witter et al., 2011; Wolford, 2000)

In addition to the variations in the position of MF, the presence of accessory mandibular foramina (AMF) is the other contributing factor even though reported cases on AMFs are very few (Samanta and Kharb, 2013). They can present as single or double and are situated either below or above the mandibular foramen (Padmavathi *et al.,* 2014; Samanta and Kharb, 2013). The IAN may have additional branches that are given off before the IAN enters the MF, therefore, these branches can be associated with the presence of AMFs (Samanta and Kharb, 2013).

A radiographic examination of AMFs was done by passing a metallic wire through them. The results showed that the neurovascular bundle passing through the examined AMF supplied the root of the third molar (Das and Suri, 2004). Consequently, the mandibular molar teeth can be supplied by the additional branches of IAN, which enter the mandible through the AMFs (Padmavathi et al., 2014; Samanta and Kharb, 2013). Hence, it is essential that the knowledge on the absence or the presence of the AMFs is in place and is understood.

High failure rates of IANB can be attributed to local anaesthesia given in the presence of AMFs, whereby nerves such as mylohyoid and buccal may enter through the AMFs and resulting in insufficient anaesthesia of the IAN; and can also be due to additional branches of IAN passing through the AMFs and escaping the local anaesthesia (Samanta and Kharb, 2013; Padmavathi *et al.,* 2014). AMFs can be a site for the spread of tumours following radiotherapy as well as providing a route for the spread of infection. The knowledge of AMFs can give important information on the branching pattern of IAN which can assist the dental clinicians with avoiding complications (Samanta and Kharb, 2013; Padmavathi *et al.,* 2014).

The manner in which the IAN divides may show several differences inside the mandibular canal (Samanta and Kharb, 2013). It can either traverse the mandibular canal as a single trunk providing branches to molar and premolar teeth or giving off a major and smaller trunk near

the MF. Subsequent to traversing through the mandibular canal, the major trunk exits the mandible through the mental foramen whereas the smaller trunk turns into the incisive nerve.

1.10. Complications associated with Orthognathic Surgery

Sagittal split osteotomy (SSO) or sagittal split ramus osteotomy (SSRO) is a popular dental surgical technique which is used to correct mandibular deformities such as prognathism and retrognathism (Alves and Deana, 2014; Shuchardt, 1942; Trost *et al.*, 2010; Witter *et al.*, 2011; Wolford, 2000). It was first introduced by Shuchardt in 1942 but was modified and improved by Trauner and Obwegeser in 1957 (Witter *et al.*, 2011). A similar surgical technique to the SSO is referred to as an intraoral vertical ramus osteotomy (IVRO) but was described as being less advantageous in correcting mandibular deformities as compared to the SSO (Wolford, 2000).

The advantages of SSO in conjunction with rigid fixation (RF) include simultaneous extraction of the impacted third molars with high levels of postoperative comfort. However, even though the SSO or SSRO was deemed advantageous, various complications and disadvantages associated with it, such as undesirable fractures, haemorrhage, injury to the neurovascular bundle, bone necrosis, infection and relapse can occur (Araujo, 1999; Dolce *et al.*, 2002; Fernandes *et al.*, 2009; Vansickels *et al.*, 1988; Wolford, 2000;).

The SSO is performed in close proximity to the IAN, therefore, if the IAN is injured post-operative neurosensory disturbances can occur; and 30-40% of such neurosensory disturbances develop in the lower lip and the mental skin (Witter *et al.*, 2011). This is because during the SSO the IAN can be cut by drill, a saw or chisel during the separation of the fragments, which leads to post-operative neurosensory complications. Furthermore, IAN could also be stretched or removed from its location at the time of medial displacement or injured by compression of the segments during fragment fixation (O ‘Ryan and Araujo, 1999).

1.11. Modalities used to determine the position of mandibular foramen

The importance of preoperative Cone Beam Computed Tomography (CBCT) scans has been emphasized since it offers the surgeon the opportunity to locate the neurovascular bundle in three dimensions (Agbaje *et al.*, 2013; Park and Lee, 2015). Those dimensions allow for individual modification of the approach of the lower border of ramus of mandible and the buccal plate, therefore, avoiding injury to the inferior alveolar neurovascular bundle. A panoramic radiograph is a 2 dimensional image which lacks the information in the bucco-

lingual dimension and also magnifies both the vertical and the horizontal directions (Agbaje *et al.,* 2013; Park and Lee, 2015). Thus, panoramic radiographs do not allow the clinician to predict whether the inferior alveolar nerve is close to the lingual or to the buccal cortex. With CBCT imaging, the course of the inferior alveolar nerve and its relationship to surrounding vital structures can be readily observed (Agbaje *et al.,* 2013; Farzaneh *et al.,* 2013).

CBCT images provide vital pre-operative information about the structures in and around the operating site as well as more precise visualization of the anatomical structures in the oral region (Agbaje *et al.,* 2013; Farzaneh *et al.,* 2013).

1.12. Conclusion of literature review

There are no records that the position of the MF has been studied in South Africa, however, published records are available for various countries. The position of MF has been recorded to vary amongst different people and the contributing factors to these variations have been reported to be race, sex, and age (Ennes *et al.,* 2009; Mbajiorgu, 2000; Oguz *et al.,* 2002).

Therefore, there is a possibility that different results will be achieved in South Africa and this study is very pertinent because of the diversity of racial groups in South Africa. The aim of this study is to radiographically and morphometrically determine the position of the MF using CBCT radiographs of patients and dry adult human mandibles, in Black South African cohort and also identify any possible link that has not been reported between both analyses.

2. Chapter two: Materials and methods

2.1. The study has two components: Dry bone and CBCT radiographs.

Site of the study

Dry bone component:

It was conducted in the Raymond A Dart Bone collection in the School of Anatomical Sciences, University of the Witwatersrand, Johannesburg, South Africa.

Radiographic component:

It was conducted in the Maxillofacial and Oral Radiology Department of Charlotte Maxeke Johannesburg Academic Hospital, South Africa.

2.2. Study population

Dry bones:

This was a retrospective, cross-sectional study carried out on a total of 253 Adult Black South African dry human mandibles. There were 120 female specimens and 133 male specimens. The female to male ratio was 0.9:1.

CBCT Radiographs:

This was a retrospective, cross-sectional study consisting of a total of 24 CBCT radiographic data of Adult Black South African patients. The records were from the year 2011 to 2016, which included 15 male records and 9 female records.

2.3. Inclusion criteria for both dry bones and CBCT radiographs:

a) Male and female dry mandible samples of ages ranging between 16-56 years old and above.
b) Fully or partially dentate (minimum of 6 teeth in the entire mandible) dry mandibles including the second molar (teeth 37 and 47).

2.4. Exclusion criteria for both dry bones and CBCT radiographs:

a) Completely edentulous mandibles
b) Mandibles with evident deformity or pathology
c) Mandibles that have undergone surgery
d) Damaged (e.g. fractured) mandibles

2.5. Measuring instruments

Dry bone component:

The height and length of mandible were measured using a mandibulometer, and for all linear measurements a dental sliding digital callipers (Mitutoyo, accuracy of 0.01mm was utilized). The measurements obtained were entered into a data collection sheet.



Figure 2.1: Illustration of some of the measurements carried out in the morphometric study

Radiographic component:

A Galaxis software measuring ruler was used for all the measurements. Linear measurements and the height were calculated on the tangential section and the length was calculated on the axial section. The CBCT images were obtained from the Sidexis data base on a Galileos 3D comfort by Sirona Dental systems. All radiographs were obtained from the same machine with the following information: model: Galileos GAX 5 (Compact); serial no: 3351.

Records of the field of view of the mandible were examined. All CBCT generated mandibular images were first increased to a thickness of 300% before measurements were undertaken and a U-jaw mandible shape was maintained in all the images.



Figure 2.2: Illustration of some of the measurements carried out in the radiographic study. Internet accessed 23 March, 2017.

2.6. Data collection for both dry bones and CBCT radiographs:

A repeatability/ intra-observer test was done at the beginning of the morphometric study. The rationale for the test was to make sure that the same methods and techniques are used with an intension of achieving significant results. However, no intra-observer test was done on the radiographic study.

Various osteological landmarks illustrated in Figure 2 & 3 were used to locate the MF. However, six additional landmarks were introduced in the current study.

The current study adopted the technique by Samanta and Kharb (2013). Bilateral measurements of the mandible were taken separately. MF was the point of reference in all the measurements. To precisely locate the MF, the following parameters were measured:

1) Distance from the midpoint of the anterior margin of MF to the nearest point on the anterior border of ramus of mandible (MF-A, table 1)
2) Distance from posterior margin of MF to the nearest point on the posterior border of ramus of mandible (MF-P, table 1)

3) Distance from the lowest point of sigmoid notch to the inferior point of MF (MF-S, table 1)
4) Distance from the inferior point of the MF to the furthest point on the inferior border of ramus of mandible (MF-GO, table 1)

In the current study six additional landmarks were measured:

1) Distance from the highest point of condylar head to the most inferior point on the ramus of mandible (H-GO, table 2)
2) Distance from the highest point of coronoid notch to the most inferior point on the MF (MF-I, table 2)
3) Distance from the most inferior point of the MF to the highest point on the condylar head (MF-H, table 2)
4) Distance from the most posterior border of the ramus of mandible to the most anterior point on the menton (GO-M, table 2)
5) Distance from the most posterior border of ramus of mandible to the most anterior point on the ramus of mandible (P-A, table 2)
6) Distance from the lowest point of sigmoid notch to the most inferior point of ramus of mandible (S-GO, table 2)

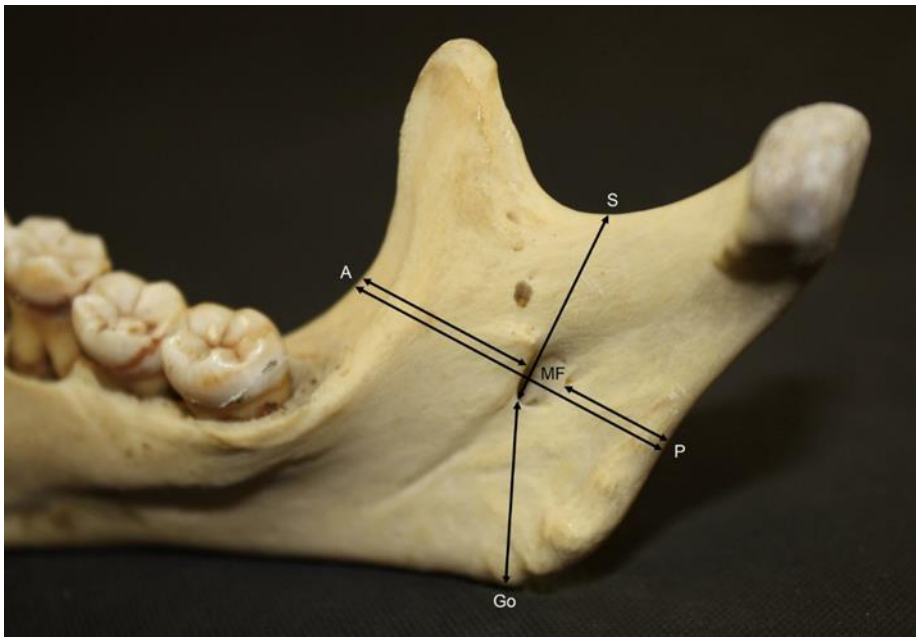

Figure 2.3: Internal surface of ramus of mandible. MF-A; MF-P; A-P; MF-GO; MF-S.

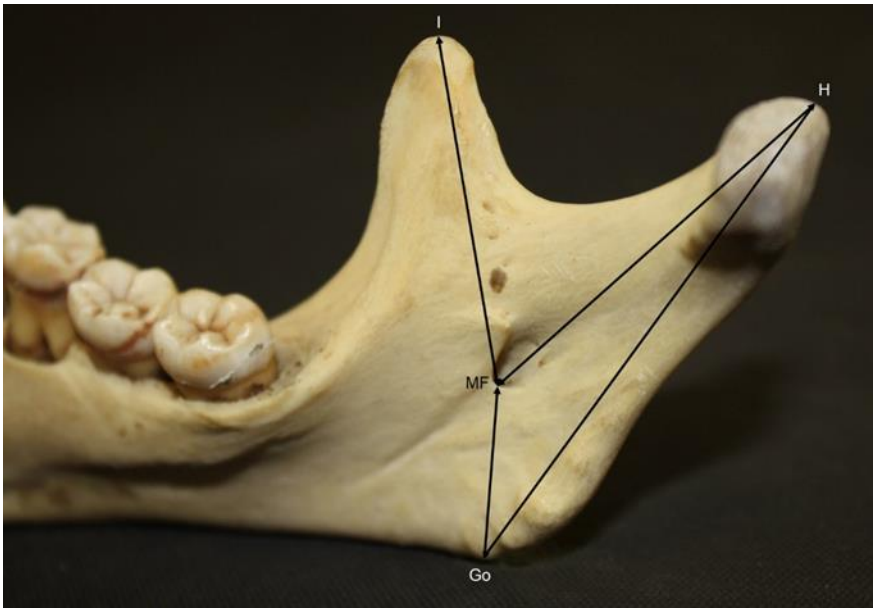

Figure 2.4: Internal surface of ramus of mandible. MF-I; MF-H; MF-GO; H-GO.

The dry bones were divided into age groups of 5 years apart (refer to table 3.2), with the purpose of identifying any evident morphological changes.

In the radiographic study only one age group of 21-25 years old was examined, and this was due to unavailability of CBCT radiographs that could not meet the inclusion criterion. The selected radiographs were also of Black South African cohort, however, not of the same ethnic groups as in the morphometric study. Classification of ethnicity in the radiographic study was biased. The first name of the patient was used to classify the ethnicity.

Table 2.1: Various parameters on the ramus of mandible

ANATOMICAL LANDMARK	DEFINITION	REFERENCE	INSTRUMENT
MF-P	Distance from the MF to posterior border of ramus	Nilton *et al.,* 2014	Dental sliding digital calliper
MF-A	Distance from the MF to anterior border of ramus	Nilton *et al.,* 2014	Dental sliding digital calliper
MF-S	Distance from the MF to sigmoid notch	Nilton *et al.,* 2014	Dental sliding digital calliper
MF-GO	Distance from MF to inferior border of ramus	Nilton *et al.,* 2014	Dental sliding digital calliper

Table 2.2: Additional parameters in the current study

ANATOMICAL LANDMARK	DEFINITION	REFERENCES	INSTRUMENT
S-GO	Distance from the sigmoid notch to inferior border of ramus	Park and Lee, 2015; Thangavelu *et al.*, 2012	Dental sliding digital calliper
MF-I	Distance from the MF to the highest point on the coronoid process	Current study	Dental sliding digital calliper
MF-H	Distance from the MF to the highest point on the condylar process	Thangavelu *et al.*, 2012	Dental sliding digital calliper
H-GO	Distance from the highest point on condylar head to the inferior border of ramus	Current study	Mandibulometer
GO-M	Length of mandible from the GO to the most anterior point on the menton	Current study	Mandibulometer
P-A	Distance from the posterior border of ramus to anterior border of ramus	Current study	Dental sliding digital calliper

Age groups:

All specimens were categorized into male and female and then divided into the following nine age groups with 5 years apart:

Table 2.3: Age groups of the dry mandibles

Variables	N
Age (years)	
16-20	25
21-25	30
26-30	30
31-35	30
36-40	31
41-45	29
46-50	29
51-55	19
>56	30
Gender	
Female	120
Male	133

The initial proposition of the current study was to have fifteen specimens in each age cohort, however, due to some of the specimens not meeting the inclusion criteria, some age cohorts ended with less subjects.

2.7. Data analysis for both dry bones and CBCT radiographs:

Descriptive statistics of mean, standard deviation and frequency was used to summarize the data. Paired t-test and one way Anova tests were used to compare group means of morphology measurements and total population, in the specific age cohorts. A Shapiro-Wilk test was used to check the normal distribution of data. The degree of magnification and distortion in the radiographic study was calculated. The difference between the two readings as a ratio of the true reading expressed as a percentage indicated the magnification for each parameter. The average magnification was taken as the standard error of all the magnifications. The percentages of either or both was set to be disregarded if less than 5% and therefore, level of significance for both radiographic and morphometric studies was set at $p<0.05$.Unfortunately the average magnification did not conform to the expected norm for the CBCT machine used.

2.8. Ethical consideration

Dry bones:

Ethical clearance was obtained in the year 2015 from the Ethics committee of the School of Anatomical Sciences as well as Human Research Ethics Committee of University of the Witwatersrand, Johannesburg, South Africa to utilize the human dry mandibles in the Raymond A Dart Bone collection.

CBCT radiographs:

Ethical clearance was obtained from the Wits Oral Health Centre Hospital Research committee, to use the CBCT radiographic data in Oral Radiology Department of Charlotte Maxeke Johannesburg Academic Hospital.

2.9. Study limitations

Dry bones:

Due to some specimens not meeting the inclusion criteria, some age cohorts ended up with fewer subjects than planned. Total sample sizes of 253 dry bones were examined.

CBCT radiographs:

Due to failure of most radiographs not meeting the requirements of the inclusion criteria, only 24 records were examined. The analysed sample size consisted of 9 female records and 15 male records, in the age cohort of 21-25 years old. Most of the patients that were referred for CBCT radiographs, had some form of oro-facial pathology, hence many radiographs were excluded.

2.10. Source of bias

Unlike the selection of specimens according to race and ethnicity in the Raymond A Dart Bone collection catalogue, selection of radiographic data was a bit biased. This was due to the fact that when patients first consulted Wits Oral Health Centre, they are registered into the Hospital system, and their ethnicity or race is classified according to their first language.

South Africa is a diverse country with many ethnicities and interracial marriages. That made it a little difficult to precisely classify some of the subjects.

3. Chapter three: Results

3.1. Sample size, age and sex stratification

A total sample size of 277 subjects was used in this study. This included 253 adult dry human mandibles and 24 CBCT radiographic records of patients. The samples were further stratified according to sex and sub age groups ranging from 16-56 years old and above in the morphometric study, however, in the radiographic study, only one age cohort of 21-25 years was used due to the unavailability of records that met the inclusion criteria

3.2. Test for normality

The Shapiro-Wilk test for normality was conducted and majority of the morphometric measurements showed normal distribution as shown in Table 3.1.

Table 3.1: Shapiro-Wilk test for normality

		Statistic	Sig.
LEFT	MF-P	0.99	0.22
	MF-A	0.99	0.2
	P-A	0.99	0.3
	MF-S	0.99	0.11
	MF-GO	1	0.96
	S-GO	0.99	0.21
	MF-I	0.99	0.12
	MF-H	0.99	0.47
	H-GO	0.99	0.09
	GO-M	0.99	0.1
RIGHT	MF-P	0.99	0.54
	MF-A	0.99	0.15
	P-A	0.99	0.06
	MF-S	0.99	0.26
	MF-GO	0.99	0.16
	S-GO	0.99	0.1
	MF-I	0.99	0.42
	MF-H	1	0.73
	H-GO	0.99	0.41
	GO-M	0.99	0.18

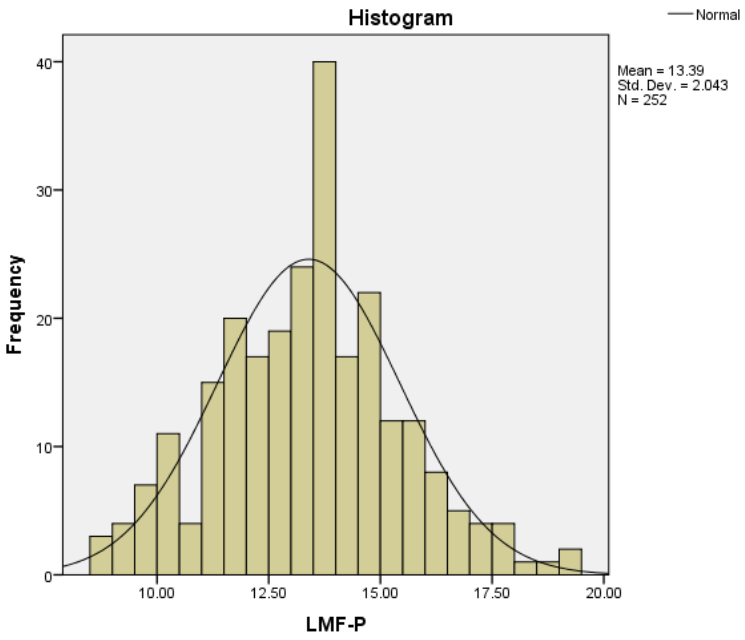

Figure 3.1: Histogram showing normal distribution of the morphometric MF-P data on the left side.

3.3. Distribution of the demographics

Table 3.2 outlines the demographic properties (sex and age cohorts) of the mandibles. In the morphometric study from a total sample size of 253, 120 were females (47.4%) and 133 males (52.6%). The age group (51-55 years) contained the least number of specimens making 7.5 % of the total population.

Table 3.2: Demographics of the morphometric samples

Variables	**N**	**%**
Age		
16-20	25	9.9
21-25	30	11.9
26-30	30	11.9
31-35	30	11.9
36-40	31	12.3
41-45	29	11.5
46-50	29	11.5
51-55	19	7.5
>56	30	11.9
Gender		
Female	120	47.4
Male	133	52.6

3.4. Morphology measurements of the samples

Table 3.3 shows the mean and standard deviation of the morphometric measurements on the right and left sides of the mandible. The mean of the MF-P; MF-I; and H-GO were significantly increased on the right hand side with the $p<0.001$. There was no significant difference on the rest of the measurements.

Table 3.3: Morphology measurement of cohort irrespective of sex

	Right		**Left**		
	Mean	**SD**	**Mean**	**SD**	**Sig**
MF-P	13.7	2	13.4	2.0	0.00**
MF-A	18.8	2.4	18.9	2.5	0.88
P-A	34.2	3.5	34.3	3.5	0.55
MF-S	20.1	3.0	20	3.1	0.25
MF-GO	22.9	3.7	22.7	3.7	0.09
S-GO	43.2	4.6	43	4.7	0.35
MF-I	35.3	3.6	35	3.6	0.00**
MF-H	39.3	3.4	39.1	3.4	0.08
H-GO	49.6	6.7	48.7	7.0	0.00**
GO-M	107.0	6.0	107.0	6.1	0.56

*p<0.05, **p<0.001

3.5. Sex distribution of samples

Table 3.4 outlines the means morphometric measurements according to gender distribution and the comparative analysis on the right and left sides. There was a significant difference between males and females in almost all the measurements except for the MF-P on the right and the MF-P and MF-S on the left ($p>0.05$). Males showed significantly higher readings than females on both the left and right side in all parameters except for the female MF-P on the right ($p>0.05$). In both males and females, the right side demonstrated higher readings than the left side.

Table 3.4: Parameter variations with sex

		Male		Female		
		Mean	**SD**	**Mean**	**SD**	**Sig**
Right	MF-P	13.5	2	13.8	2	0.24
Left		13.6	2.1	13.2	1.9	0.12
Right	MF-A	19.3	2.4	18.3	2.4	0.00
Left		19.2	2.5	18.5	2.3	0.03
Right	P-A	34.9	3.2	33.4	3.7	0.00
Left		34.9	3.5	33.6	3.3	0.00
Right	MF-S	20.5	3.4	19.7	2.5	0.03
Left		20.2	3.5	19.7	2.6	0.15
Right	MF-GO	24.3	3.5	21.4	3.3	0.00
Left		24.2	3.5	21	3.1	0.00
Right	S-GO	45.1	4.4	41	3.8	0.00
Left		45.1	4.5	40.7	3.7	0.00
Right	MF-I	36.5	3.7	34.1	3.1	0.00
Left		36.2	3.6	33.7	3.1	0.00
Right	MF-H	40	3.4	38.5	3.2	0.00
Left		39.9	3.4	38.2	3.3	0.00
Right	H-GO	52.6	6.3	46.2	5.4	0.00
Left		51.8	6.9	45.3	5.4	0.00
Right	GO-M	109	6	104.8	5.3	0.00
Left		108.9	6	104.7	5.4	0.00

*p<0.05, **p<0.001

3.6. Age distribution of the samples

Table 3.5 on page 24 outlines the age distribution of the morphometric measurements on both the left and the right sides. The left and right P-A distance was at its highest point at the age of 51-55 years and at its lowest point at the age of 21-25 years. MF-A reading was higher than the MF-P distance in all the samples irrespective of age. MF-S; MF-GO and S-GO increased significantly with increasing age in all the age cohorts on both left and right sides ($p<0.05$).

Table 3.5: Age distribution of the morphology

	16-20		21-25		26-30		31-35		36-40		41-45		46-50		51-55		>56	
Right	**Mean**	**SD**	**Mean**	**SD**	**Mean**	**SD**	**Mean**	**SD**	**Mean**	**SD**	**Mean**	**SD**	**Mean**	**SD**	**Mean**	**SD**	**Mean**	**SD**
MF-P	14.3	2.1	13.3	1.9	13.4	2.4	13.8	1.5	13.7	2.0	13.4	1.7	13.5	2.2	14.7	1.8	13.3	1.8
MF-A	18.4	2.0	18.4	2.7	19.4	2.1	18.6	2.4	18.5	2.9	19.4	2.5	19.2	2.1	19.7	2.4	18.2	2.6
P-A	34.5	2.9	32.4	4.6	34.6	3.3	33.8	3.0	33.9	4.1	35.2	3.1	35.0	3.3	35.7	3.0	33.4	3.2
MF-S	18.1	2.8	20.6	3.1	20.4	3.3	20.7	1.7	20.6	3.2	19.0	3.0	20.3	3.3	20.9	3.1	20.2	2.7
MF-GO	21.0	3.4	22.6	3.5	22.2	3.3	22.9	3.3	22.9	4.4	24.3	4.4	23.8	3.3	22.7	3.3	23.5	3.5
S-GO	41.3	4.3	43.2	4.9	42.6	4.1	43.5	3.4	43.3	5.2	43.3	4.8	43.9	4.7	43.7	5.6	43.5	4.5
MF-I	34.8	3.6	35.3	3.8	35.8	4.1	35.2	2.9	36.2	4.1	34.5	3.9	35.2	3.1	36.9	3.1	34.7	3.5
MF-H	38.5	3.0	39.5	4.1	38.8	3.5	38.9	3.0	39.6	3.4	38.9	2.8	39.7	3.9	40.4	3.9	39.4	2.9
H-GO	46.8	6.6	49.5	7.3	49.2	6.5	49.3	6.2	49.3	6.2	50.9	5.9	51.2	7.0	50.8	7.8	49.4	7.1
GO-M	105.1	4.8	106.5	5.2	106.4	6.1	106.3	6.1	107.2	6.5	107.3	5.0	109.0	7.4	107.4	4.5	107.9	7.2
	16-20		**21-25**		**26-30**		**31-35**		**36-40**		**41-45**		**46-50**		**51-55**		**>56**	
Left	**Mean**	**SD**	**Mean**	**SD**	**Mean**	**SD**	**Mean**	**SD**	**Mean**	**SD**	**Mean**	**SD**	**Mean**	**SD**	**Mean**	**SD**	**Mean**	**SD**
MF-P	14.0	2.2	13.3	2.1	13.6	2.1	13.2	1.6	13.2	2.4	13.1	1.6	13.3	2.2	14.0	2.5	13.3	1.8
MF-A	18.4	2.0	18.3	2.2	19.6	2.3	18.6	2.4	18.3	2.7	19.4	2.5	19.1	2.5	19.9	3.1	18.5	2.3
P-A	33.6	4.4	33.4	3.6	34.8	3.4	33.7	2.9	33.7	4.1	35.1	3.1	35.1	2.9	35.6	3.4	34.0	3.2
MF-S	17.6	3.1	20.5	3.3	20.3	3.4	20.3	2.0	20.6	3.3	19.6	2.8	20.5	3.3	20.3	3.2	19.8	2.7
MF-GO	21.2	3.5	21.8	3.7	22.8	3.7	21.7	3.8	22.7	3.9	24.0	4.3	23.8	2.6	22.9	3.0	23.3	3.7
S-GO	41.6	4.4	42.6	4.8	42.9	4.2	42.3	4.0	43.2	5.1	43.5	4.3	44.3	4.6	43.4	5.2	43.3	5.3
MF-I	34.8	4.1	35.0	4.0	34.6	3.7	35.0	3.3	35.6	3.7	34.7	3.6	35.2	3.5	36.3	3.3	34.5	3.4
MF-H	38.3	3.4	38.9	3.5	38.4	3.4	38.8	3.0	39.4	3.6	39.3	2.9	40.2	4.1	39.8	3.8	38.7	3.4
H-GO	47.0	6.5	47.6	7.2	47.5	9.0	47.8	6.5	48.9	6.1	49.9	5.7	51.3	6.9	50.2	7.6	48.9	7.2
GO-M	104.9	5.3	106.5	5.2	106.4	6.1	106.2	5.9	107.2	6.4	107.6	5.5	108.7	7.5	107.2	4.6	107.8	7.1

3.7. Mean difference in morphometric measurements

Table 3.6 shows the significant difference between the age cohorts for the morphometric measurements. There was a significant difference in the P-A measurement on both the right and left sides and MF-S measurements on both left and right sides ($p<0.05$).

Table 3.6: One way ANOVA between the age groups

	Right		**Left**	
	F	**Sig**	**F**	**Sig**
MF-P	1.49	0.16	0.66	0.72
MF-A	1.34	0.22	1.70	0.10
P-A	2.42	0.02*	1.37	0.21*
MF-S	2.53	0.01*	2.41	0.02*
MF-GO	1.83	0.07	1.93	0.06
S-GO	0.73	0.67	0.74	0.65
MF-I	1.12	0.35	0.58	0.79
MF-H	0.71	0.68	0.91	0.51
H-GO	0.99	0.44	1.20	0.30
GO-M	0.91	0.51	0.86	0.55

*$p<0.05$

3.8. Distribution of radiographs measurement

Table 3.7 shows the demographic distribution of the 21-25 years age cohort. Males showed significantly higher readings than females in all the parameters on both left and right sides except for the MF-P measurement. Radiographic measurements of the MF-GO, S-GO, MF-I and H-GO showed a significant difference between males and females on the right side ($p<0.05$). Except for the MF-A, the mean measurement of all other parameters showed no significant difference between males and females ($p>0.05$).

Table 3.7: Radiographic measurements of the 21-25 age cohort.

	Male		**Female**		
Right	**Mean**	**SD**	**Mean**	**SD**	**Sig**
MF-P	8.8	2.1	9.6	2.8	0.41
MF-A	11.5	1.2	10.9	2.8	0.46
P-A	22.5	2.9	21.8	2.7	0.6
MF-S	24.9	4.3	22	4.9	0.14
MF-GO	22.5	2.9	19.2	2.1	0.01*
S-GO	48.7	5.1	42.8	5.1	0.01*
MF-I	38.5	4.5	34.4	4.2	0.04*
MF-H	38.6	5	37.6	2.9	0.57
H-GO	64.7	5.6	60.1	4	0.04*
GO-M	45	2.1	43.7	2.6	0.22
Left	**Mean**	**SD**	**Mean**	**SD**	**Sig**
MF-P	7.9	1.4	8.5	2.4	0.45
MF-A	12.3	1.4	9.9	2.2	0.00*
P-A	22.7	3.4	21.4	3.6	0.39
MF-S	22.7	2.8	22.1	4.1	0.71
MF-GO	22.3	2.6	20.1	3.4	0.09
S-GO	47.2	5.6	43.5	3.7	0.09
MF-I	37	4.6	34.2	4	0.14
MF-H	35.8	3.7	34.7	4.9	0.56

H-GO	60.5	12.4	59.5	5.2	0.81
GO-M	44.6	2.3	43.7	2.6	0.4

3.9. Comparison between the mean measurements of the radiograph and the morphometric

Table 3.8 outlines the comparison between the means for the radiographic and morphometric measurements in the age cohort 21-25. There was a significant difference on the right side on almost all parameters except the MF-GO; S-GO; MF-I and MF-H ($p>0.05$). The left side also showed significant differences in all parameters except for the MF-S; MF-GO and MF-I ($p>0.05$).

Table 3.8: Comparison between the mean measurements of the radiograph and the morphometric

	Morphology		**Radiograph**		
Right	**Mean**	**SD**	**Mean**	**SD**	**Sig**
MF-P	13.3	1.9	9.1	2.4	0.00
MF-A	18.4	2.7	11.2	1.9	0.00
P-A	32.4	4.6	22.2	2.8	0.00
MF-S	20.6	3.1	23.8	4.7	0.01
MF-GO	22.6	3.5	21.3	3.1	0.51
S-GO	43.2	4.9	46.5	5.8	0.68
MF-I	35.3	3.8	36.9	4.7	0.24
MF-H	39.5	4.1	38.2	4.3	0.33
H-GO	49.5	7.3	63	5.4	0.00
GO-M	106.5	5.2	44.5	2.4	0.00
Left	**Mean**	**SD**	**Mean**	**SD**	**Sig**
MF-P	13.3	2.1	8.1	1.8	0.00
MF-A	18.3	2.2	11.4	2.1	0.00
P-A	33.4	3.6	22.2	3.5	0.00
MF-S	20.5	3.3	22.5	3.3	0.58
MF-GO	21.8	3.7	21.5	3.1	0.60
S-GO	42.6	4.8	45.8	5.2	0.02
MF-I	35	4	36	4.5	0.52
MF-H	38.9	3.5	35.4	4.1	0.02
H-GO	47.6	7.2	60.1	10.1	0.00
GO-M	106.5	5.2	44.3	2.4	0.00

4. Chapter four: Discussion

This present study aimed to determine the position of mandibular foramen in relation to mandibular osteological landmarks, using morphometric and radiographic measurements. It was conducted in the South African adult black population utilizing dry bony mandibles and CBCT radiographs, which were categorized into sex and age cohorts 16-56 years old and above, at five year intervals. The morphometric results of the current study corroborate with earlier reports on similar studies done in other populations of different countries (Alves and Deana, 2014; Mbajiorgu, 2000; Olivier *et al.,* 2010; Samanta and Kharb, 2013; Thangavelu *et al.,* 2012); however, the radiographic results did not show much of corroboration with other studies. The reason for such a discrepancy in the radiographic study could be attributed to a small sample size used in the current study because, due to unavailability of required radiographic records, only one age group of 21-25 years old was examined. Another possible reason could be due to limited reports on the study of this kind. Even though there was not enough radiographic data, the two current studies were compared using only one age group of 21-25 years old with the aim of determining any possible correlation. This is a first study of its kind; in that, no published studies are available on the South African population. The results of the two components were analysed and separately discussed below.

4.1. Morphometric study

In the morphometric study from a total sample size of 253, 120 were females (47.4%) and 133 males (52.6%). The age group (51-55 years) contained the least number of specimens making 7.5 % of the total population. Some of the reasons ascribed to so small a percentage in the 51-55 year- old age cohort were either because the second molars in that group (teeth 37 and 47) were missing or the mandibles were completely edentulous.

A comparison of the left and right sides of the total sample showed a statistically significant difference only in the MF-P; MF-I and H-GO with ($P<0.001$). The right side showed higher readings than the left in all parameters except in the MF-A and P-A measurements with no significant diffrence (refer to Table 3.3).

An analysis of the antero-posterior dimension of the mandible showed the mean of MF-P on both left and right sides to be significantly less than the mean of MF-A (refer to table 3.3). The mean of MF-A was 18.8mm on the right and 18.9mm on the left whereas the mean of MF-P was 13.7mm on the right and 13.4mm on the left. This suggests that the position of MF on dry bones was more towards the posterior border of the ramus of mandible than towards the anterior border.

The results of the current study aligned themselves with that of: Alves and Deana (2014); Marzola *et al.,* (2005); Mbajiorgu (2000); Shalini *et al.,* (2016); and Thangavelu *et al.,* (2012), but differed

slightly from the results of Samanta and Kharb (2013). Samanta and Kharb (2013) described MF to be at a mean distance of 15.72mm on the right and 16.23mm on the left from the anterior border of ramus of mandible; and at a mean distance of 13.29mm on the right and 12.73mm on the left from posterior border of ramus of mandible. Although there was a slight difference in Samanta and Kharb's study (2013), a similar pattern of MF being situated more towards the posterior border of ramus of mandible was still observed. One possible reason that could be attributed to such a difference might have been the small sample size of sixty mandibles that were utilized in their study.

Since two of the objectives in the current study were to determine age- and sex-specific differences, these categorical variables were important factors that were clearly described and considered. However, in earlier studies, these two factors were not always taken into consideration. In a study conducted by Alves and Deana (2014) on 185 macerated mandibles, age, sex and race were clearly described. In their study, the samples comprised both black and white individuals and a significant difference in MF-A and MF-P measurements was noted between the two races. However, the results of their black population group corroborated with the results of the current study on the same parameters. Considering ethnic groups, the results of their study confirmed that differences exist in the parameters studied, in that blacks showed higher values.

All specimens utilized by Mbajiorgu (2000) and belonging to the black Zimbabwean population group were all above 25 years old but sex was not taken into consideration. In the study done by Marzola *et al.,* (2005); Samanta and Kharb (2013), Shalini *et al.,* (2016) and Thangavelu *et al.,* (2012), both sex and age of the specimens were unknown. However, the results of the current corroborated with these studies.

In both the current study as well as those studies discussed above, the results of MF-A and MF-P parameters suggested that MF was located more towards the posterior border of the ramus of mandible3. However, these finding were contrary to the findings by Trost *et al.,* (2010) which considered the posterior border of the mandible as the "safety zone". One possible reason for the difference between the findings by Trost et al., (2010) and the current study may be due to the different methods used. Trost *et al.,* (2010) analysed the position of MF on panoramic radiographs compared to the morphometric methods used in the above discussed studies.

Two infero-superior dimensions of the mandible were considered in the current study. Both the sigmoid notch and the condyle constituted the superior part of the mandible. The study showed the mean of MF-GO on both left and right sides to be higher than the mean value of MF-S. The average MF-GO distance was recorded as 22.9mm on the right and 22.7mm on the left; the right side

demonstrating higher readings. MF-S was shown to be 20.1mm and 20mm on the right and left sides respectively. There was no statistically significant difference between the left and right side on both MF-S and MF-GO parameters.

The results of this current study show that MF is situated more towards the superior border of the ramus of the mandible than the inferior border. These results aligned themselves with the results by Mbajiorgu (2000); Mendoza *et al.,* (2004); and Shalini *et al.,* (2016) but differed from the results of Alves and Deana (2014); Ferreira *et al.,* (2005); and Samanta and Kharb, (2013) which described the position of MF to be more towards the inferior border of ramus of mandible.

In the study by Ferreira *et al.,* (2005) and Samanta and Kharb, (2013), a small sample size of thirty and sixty mandibles were used respectively, of which gender, race and age were not taken into account. This may be the reason attributed to the difference between the current and other studies. Although Alves and Deana (2014) used a larger sample size of 185 mandibles, of which age, sex and race were taken into consideration, the gonion was not as clearly defined. This may have affected the method used in taking the MF-GO measurement between various studies, which led to different results.

Singh *et al.,* (2015) reported on the location of the mandibular foramen with respect to the gonial angle. They concluded that the mandible undergoes substantial morphological and dimensional changes during the course of life; therefore, it varies with age and state of dentition. They also attributed these changes to the action of muscles of mastication. In their study they did not consider the sides of the mandible and neither sex nor ages were mentioned. Most of their specimens which accounted for 43.33% of the population showed that the distance of the mandibular foramen from the angle of the mandible was in the range of 21-25mm. The distance of the mandibular foramen to the sigmoid notch was not measured in their study; therefore a comparison between MF-GO and MF-S could not be made. The significance of the discussion carried out in the study by Singh *et al.,* (2015) about the substantial morphological changes that occur in the mandible could explain the difference noted in the position of MF in relation to the gonion.

Six additional anatomical landmarks were included in the current study, two of which were MF-I and the MF-H parameters, both demonstrating the distance of MF in relation to the upper part of the mandible. In this study, the average distance of MF-H was shown to be 39.3mm and 39.1mm on the right and left sides respectively. MF-I was recorded as 35.3mm and 35mm on the right and left sides respectively.

The results of the current study with regard to the MF-H distance were more or less similar to those of Thangavelu *et al.,* 2012, of which MF-H was recorded as 38.14mm on the right and 37.60mm on the left side. However, there was a significant difference between the left and right with P<0.01. MF in relation to the coronoid process was not measured in their study; therefore it was not possible to compare the two parameters within the same study as well as in other studies.

Marzola *et al.,* (2005) examined the position of MF in relation to the condyle and reported that MF was positioned at 21mm from the top of the condyle on both left and right sides. A small sample size of thirty mandibles was used in their study, of which sex and age were unknown. The fact that the study was conducted in a different population group could explain the discrepancies of MF-H parameter noted in their study as compared to other studies. MF-I was also not measured in their study; therefore a comparison could not be made.

In the current study, the total width of mandibular ramus which is described as a P-A distance, demonstrated no significant difference between the left and right sides. It was recorded as 34.2mm on the right and 34.3mm on the left side. However, the results demonstrated that the mean value of the P-A distance was significantly greater in males than in females (P<0.001) on both left and right sides. It was shown to be the same on both left and right sides in the male population with a mean value of 34.9mm. It was slightly higher on the left side of the female population with a mean value of 33.6mm as compared to 33.4mm on the right side but with no significant difference.

The results of Shalini *et al.,* (2016); Thangavelu *et al.,* (2012) and Padmavathi *et al., (*2014) were more or less similar to the results of the current study. Shalini *et al.,* (2016) reported that the P-A distance was 31.76mm on the right and 31.49mm on the left. It was recorded as 32.1mm and 31.6mm on the left and right sides respectively in a study by Padmavathi *et al., (*2014). Thangavelu *et al.,* (2012), reported it to be 33.33mm on the right and 33.20mm on the left. Again in both their studies, sex and age of mandibles were unknown and the right side showed slightly higher readings than the left.

In the current study, the length of the mandible (GO-M) in the total population was the same at an average distance of 107.0mm, with a standard deviation of 6.1. The average height of the mandible (H-GO) in the total population was seen to be 49.6mm on the right and 48.7mm on the left, and a statistically significant difference was noted between the left and right sides with P<0.001. Males demonstrated higher results than females on both the left and right sides. The GO-M distance was recorded as 109mm and 108.9mm on the right and left sides respectively for males as compared to 104.7mm and 104.8mm on the left and right sides for females. The height also demonstrated a

similar pattern with males showing larger readings than females. It was 52.6mm for males and 46.2mm for females on the right and 51.8mm for males and 45.3mm for females on the left side.

Thangavelu *et al.,* (2012), conducted a similar study and reported that the mean height of the mandible which he described as distance from the condyle to the inferior border of ramus of mandible was 64.82mm on the right and 64.22mm on the left. The right side showed higher readings than the left side. The results on the height of mandible in their study were a bit greater than the results of the current study which were 49.6mm and 48.7mm 0n the right and left side respectively, however, sex, age and race in their study were unknown. Therefore, that could be a reason for the difference noted.

The average distance from sigmoid notch to the inferior border of ramus of mandible in the current study was recoded to be almost the same on both the left and right side, at the average distance of 43.2mm on the right and 43mm on the left. There was no statistically significant difference noted between the left and right side (refer to table 3.3). However, results demonstrated significant difference cross-gender. The mean distance of S-GO was recorded to be 45.1mm on both the right and left side of males. It was recorded to be 41mm and 40.7mm on the right and left side respectively for females. Statistically significant difference was noted between males and females on both the right and left sides with a P value of 0.00. Furthermore, males showed higher readings than females on both left and right sides. The results of the current study were more or less similar to the results by Padmavathi *et al., (*2014) and Thangavelu *et al.,* (2012). Thangavelu *et al.,* (2012) reported that the mean distance from the sigmoid notch to inferior border of ramus of mandible was 48.49mm and 47.78mm on the right and left side respectively. Padmavathi *et al., (*2014) reported that the mean distance from the mandibular notch to the mandibular base was 47.1mm and 47.0mm on the left and right side respectively.

In the present study, both the left and right side demonstrated a decrease in the average distance of the MF-P with increasing age, however, the average distance increased again at the age of 51-55 years with a highest reading of 14.7mm and 14.0mm on the right and left side respectively. The shortest distance of the mandibular foramen from the posterior border of ramus of mandible was noted at age 41-45 years with the mean value of 13.1mm on the left side. These findings could suggest that as one grows, MF appears to be closer to the posterior border of ramus of mandible and moves further away from the anterior border of ramus of mandible. These findings are also aligned with the results reported by Singh *et al.,* (2015) on the morphological changes that occur in the mandible due to actions of muscles of mastication.

Alves and Deana, 2014 demonstrated conflicting results on both males and females. However, their study was conducted on both black and white individuals, with age ranging from 18- 61 years and above. Their results showed that with increasing age, the average distance of MF in relation to posterior border of ramus of mandible increases. It was recorded to be 13.14mm at the age of 18-30 years and 13.83 at the age of 61 years and above in males. Females in their study showed a similar pattern, whereby MF-P was 11.22mm at the age of 31-45 years and it was 12.03mm at the age of 61 years and above. The difference in the results between the current study and their study could be due to mixed racial groups examined in the study by Alves and Deana, 2014.

Similarly in the current study, as the MF-P distance decreased with increasing age, MF-A distance appeared to increase with increasing age on both left and right side. The highest reading was noted on the 51-55 years age cohort at a mean value of 19.7mm and 19.9mm on the right and left side respectively. This pattern was not observed in the study by Alves and Deana, 2014. On the contrary, the average distance of MF-A decreased with increasing age on both males and females.

The total width of ramus of mandible which is P-A distance also demonstrated slight fluctuating changes with increasing age on both left and right sides. It was at its smallest width at the age of 21-25 years with the mean value of 32.4mm and 33.4mm on the right and left side respectively. At the age of 51-55 years, the P-A seemed to have increased in width. It was recorded to be 35.7mm and 35.6mm on the right and left side respectively.

The distance of MF to the sigmoid notch also appeared to increase with increasing age on both left and right side. It was the shortest at the age of 16-20 years with the average of 18.1mm and 17.6 mm on the right and left respectively. It was recorded to be at its highest point at the age of 51-55 years with the average distance of 20.9mm on the right side and at the age of 36-40 years with the mean of 20.6mm on the left.

The male population in the study by Alves and Deana, 2014 demonstrated a similar sequence to the current study. It was noted to increase with increasing age, however, the female population in their study showed opposite results. MF-S was noted to decrease with increasing age. It was recorded to be 22.03mm at the age of 18-30 years and it was 19.56mm at the age of 61 years old and above. This is another finding that can be used to assert the difference in the position of MF between males and females.

MF-GO distance also appeared to increase with increasing age on both left and right side. The mandibular foramen was recorded to be at the shortest average distance of 21.0mm and 21.2mm from the sigmoid notch on the right and left side respectively at the age of 16-20 years old. The

highest reading of MF-GO was recorded to be 22.9mm on both left and right side; however, it was noticed to be at two different age groups of 31-35 years and 36-40 years on the right side; and on only one age group of 51-55 years on the left side.

The average distance of MF-GO in the study by Alves and Deana, 2014, showed a similar pattern in the male population only but it was opposite for the female counterpart, where it was decreasing with increasing age.

In conclusion of the morphometric discussion, we can assert that there is a variation in the location of MF in the studied distances between males and females. Males generally showed higher readings than females, however, the mandibular foramen was always situated towards the posterior border of ramus of mandible in all specimens. Furthermore, no significant difference was noted between the left and right sides of mandible in all parameters except for the MF-S distance. Thus, in the South African population, the anterior border of ramus of mandible can be regarded as the "safety zone" for the oral - maxillofacial surgeons, and that will minimize the risks of IANB injuries during surgical procedures.

Regarding age, there was an increase in the studied distances of all parameters with increasing age except for the MF-P distance; however, the increase was not statistically significant. Therefore, we can conclude that there is no significant change in the position of MF with increasing age from 16-56 years old and above.

4.2. Radiographic component

The right side showed significant difference between males and females in the MF-GO; S-GO; MF-I and H-GO parameters. Contrary to the left side, a significant difference was noted on MF-A parameter only. Males showed higher readings than females in all parameters except for the MF-P distance (refer to table 3.7); however, these findings could be biased because more male specimens than females were used.

In the current study the mean of MF-A distance on both left and right showed higher readings than the mean of MF-P distance in both males and females (see table 3.7). MF-A was recorded to be 11.5mm and 12.3mm on the right and left sides respectively in the male population. In females, it was recorded to be 10.9mm and 9.9 mm on the right and left side respectively. MF-P distance was recorded to be 8.8mm and 7.9mm on the right and left side respectively in the male population whereas in the female population, it was recorded to be 9.6mm and 8.5mm on the right and left side respectively. Again, the mandibular foramen was noted to be more towards the posterior border of

ramus of mandible. These results were aligned with the morphometric results of the current study; therefore, this could be used as an indication of possible correlation in the studied distance.

Park and Lee (2015) conducted a similar study, however, their sample size was much more than what was used in the current study. Similarly, their findings were significantly greater than the findings of the current study. The pattern of their MF-A findings aligned with those of the morphometric and radiographic analyses in the present study. Males showed higher readings than females; however, no statistically significant difference was noted between the two genders.

In the current study, the mean of MF-S distance on the left side was 22.7mm for males and it was 22.1mm for females. On the right side, it was recorded to be 24.9mm for males and 22mm for females. No statistically significant difference was noted between the males and females on both the left and right sides.

A study done by Park and Lee (2015) confirmed that the average radiographic distance of MF from mandibular notch differs with different occlusions. They examined both males and females with age range from 21.5 years to 22.2 years. They then looked at the male population alone and discovered that the mean of MF from mandibular notch is 22.29mm in the normal occlusion, 19.70 in skeletal class II malocclusion and 19.62mm in skeletal class III malocclusion. In the female population alone it was 21.05mm, 20.95mm and 18.31mm respectively. They further compared both males and females within the total study group and confirmed that the mean of MF from mandibular notch was the same in both males and females at the average of 20.28mm. They reported no statistically significant difference between the males and females and that was similar to that of the current study. Considering the three occlusions discussed in their study, the range of MF-S was between 18.77mm and 21.59mm. This range was less than the mean of MF-S distance in the current study and the two studies were a bit challenging to compare because occlusion was not taken into account in the current study.

In the current study, the mean of MF-GO on the left side was 22.3mm for males and 20.1mm for females. There was no significant difference between the males and females on the left side, however, on the right side the mean of MF-GO for males was 22.5mm and 19.2mm for females. Statistically significant difference was noted between males and females on the right side with P=0.01 Mean of MF-S showed slightly higher readings than that of MF-GO on both males and females, which suggests that the MF could be found situated more slightly towards the superior border of ramus of mandible radiographically. The results differed from our findings in the dry bone component. However, these were two different samples and that was highly expected.

The mean value of MF-H on both left and right side showed higher readings than that of MF-I for both males and females except on the male left side. Results showed that the mean distance of MF-H was 38.6mm and 35.8mm for males on the right and left side respectively. In females, it was recorded to be 37.6mm and 34.7mm on the right and left side respectively. There was a statistically significant difference of MF-I on the right side between the male and females, however, no significant difference was noted on the left side between the males and females. No statistically significant difference of MF-H was noted on both the left and right side of males and females. Furthermore, males showed higher readings than females on both parameters, and the right side also showed higher readings than the left side. There are no published records of the radiographic position of MF in relation to the coronoid process and condylar process; however, morphometric records of the studies discussed earlier on showed a similar pattern of results.

The width of ramus of mandible may affect the relative position of MF, the larger the width the more posterior the mandibular foramen is (Robertson, 1979).In the current study, the mean of P-A distance on the right side was 22.5mm for males and 21.8mm for females. It was 22.7mm on the left side for males and 21.4mm on the same side for females, however, the difference was not statistically significant.

Sagittal split ramus osteotomy is performed in close proximity to the inferior alveolar nerve. In a study by Wittwer *et al.,* (2012), the course of mandibular canal was determined in relation to the inner surface of the cortical bone. They discovered that the dimension of the mandible at the sagittal split ramus osteotomy was smaller than that of the males. They further observed that the mean bone thickness from mandibular canal to buccal plate at the second molar was smaller in females than in males. This could be linked to the findings of the present study that the total width of ramus of mandible was larger in males than in females.

The mean distance on the right side from the condylar head to the most inferior border of ramus of mandible was 64.7mm for males and 60.1mm for females. There was a statistically significant difference between the males and females on the right side, however, males still showed higher readings than females. On the left side, the mean distance was 60.5mm for males and 59.5mm for females. No statistically significant difference was noted on the left but males showed higher readings on the left side as well.

The mean distance on the right side was recorded to be 45mm for males and 43.7mm for females. There was no statistically significant difference noted between males and females at P=0.022 however, the right total length of the males appeared longer than that of the female counterpart. On the left side the mean distance of the length of mandible was 44.6mm for males and 43.7mm for

females. No statistically significant difference was noted between males and females, however, males showed higher readings than the females.

The mean distance from the sigmoid notch to most inferior point of mandible was recorded to be 48.7mm and 42.8mm for males and females respectively on the right. Statistically significant difference was noted between the males and females with at P =0.01. On the left side it was recorded to be 47.2mm and 43.5mm for males and females respectively, however, no statistically significant difference was noted on the left side between males and females.

Park and Lee's study (2015) confirmed that the mean distance from the mandibular foramen to inferior border of ramus of mandible was 52.64mm for males and 45.88mm for females. Statistically significant difference was noted between the males and females, with males showing even higher readings than females. These findings further suggested that the inferosuperior height of mandible is greater in males than in the female counterpart.

In conclusion of the radiographic study, it was a bit challenging to make a comparison between males and females because of the difference in the sample sizes used. More male samples than females were used; however, males still showed higher readings in all parameters except the MF-P distance on both left and right sides. MF-A distance was greater than the MF-P distance and that could be another indication that MF is situated more in the posterior region of mandible than the anterior region. This could also confirm that the anterior border of ramus of mandible can be regarded as the "safety zone" during surgical procedures in the South African Black population.

4.3. Comparison between morphometric and radiographic measurements

Two different samples were compared in order to investigate any possible correlation between morphometric measurements and radiographic measurements. The current morphometric study showed statistically significant difference in almost all parameters on the right side except for the MF-GO; S-GO; MF-I and MF-H; and similarly on the left side with inclusion of MF-S and exclusion of S-GO. When comparing the MF-A and MF-P dimensions of ramus of mandible, the same pattern was observed. The average distance of MF-P was significantly less than the average distance of MF-A in both morphometric and radiographic studies. This suggested that MF is situated more in the posterior border of ramus of mandible than the anterior border in both dry bones and radiographs. The infero-superior dimensions demonstrated inversely proportional results. The morphometric results suggested that MF was more situated in the superior part of mandible while radiographic results suggested that MF was more in the inferior border of ramus of mandible. This comparison has never been reported on hence a limited discussion on it.

4.4. Summary of the discussion

The current study proved more or less similar results with that of the literature in some parameters, however, based on the results of the current study and that of literature (Alves and Deana, 2014; Mbajiorgu, 2000; Olivier *et al.*, 2010; Thangavelu *et al.*, 2012; Samanta and Kharb, 2013), it was proven that the position of MF varies amongst males and females. Furthermore, even though the current study did not examine heterogeneous sample, those studied in the literature showed higher readings for blacks than whites. In both the morphometric and the radiographic analyses, the mean value of the MF-P was statistically less than the mean value of the MF-A distance, thus, the MF could be confirmed to be situated more in the posterior border of ramus of mandible, both morphometrically and radiographically. Hence the posterior region of the mandible was confirmed to be the "safety zone" in the South African population. There seemed to be variations in the position of MF in relation to the superior and inferior border of ramus of mandible. The morphometric results of the current study, results of Mendoza *et al.*, (2004) and of Mbajiorgu (2000) showed that the MF was situated more towards the superior border than the inferior border of ramus of mandible as compared to other studies which showed opposite results. In both morphometric and radiographic analyses, males generally showed higher readings than females in all parameters except for the MF-P distance.

5. Chapter five: Conclusion

Considering the results acquired in the morphometric analysis of the current study, all parameters increased with increasing age except the MF-A distance, however, the difference was not statistically significant. Regarding sex, males demonstrated greater readings than females, and 80-90% of parameters showed statistically significant difference between males and females.

MF was always found to be situated in the posterior border of ramus of mandible than in the anterior region on both males and females. MF was more situated in the superior part than the lower parts of mandible, more towards the sigmoid notch than the inferior border of ramus of mandible. The condylar head was deemed the most superior point of mandible than the coronoid process and that was confirmed by the average distance of MF-H which was always greater than the average distance of MF-I. The right side demonstrated higher readings than the left side in almost all parameters; however, more than 50% of the parameters showed no significant difference between the two sides.

The comparison between radiographic and morphometric analysis showed no significant difference in about four out of ten parameters. This outcome suggested that there might be a correlation between morphometric and radiographic measurements. However, the radiographic study may be reviewed and conducted prospectively involving patients instead of records. The outcome of this comparison partially suggested that preoperative CBCT scans may provide vital information of the position of the mandibular foramen in relation to various anatomical landmarks. This information may be used as a guide by maxillofacial and oral surgeons to minimise injury to the inferior alveolar neurovascular bundle during surgical procedures.

REFERENCES

1. Agbaje, J. O., Sun, Y., De Munter, S., Schepers, S., Vrielinck, L., Lambrichts, I. and Politis, C. (2013) 'CBCT-based predictability of attachment of the neurovascular bundle to the proximal segment of the mandible during sagittal split osteotomy', *International Journal of Oral and Maxillofacial Surgery*, 42(3), pp. 308–315
2. Alves, N. and Deana, N. F. (2014) 'Morphometric study of mandibular foramen in macerated skulls to contribute to the development of sagittal split ramus osteotomy (SSRO) technique', *Surgical and radiologic anatomy: SRA*, 36(9), pp. 839–845.
3. Bhalajhi S.I. Orthodontics, The art and Science. 4th Edition.2009
4. Farzaneh Afkhami., Afshin Haraji., Hamid Reza Boostani (2013) 'Radiographic Location of the Mental Foramen and Mandibular Canal'.
5. Hae-Seo Park and Jae-Hoon Lee (2015) 'Acompartive study on the location of the mandibular foramen in CBCT of normal occlusion and skeletal class II and III malocclusion'.
6. Leonard S. Fishman (1981) 'Radiographic evaluation of skeletal maturation. A clinically Oriented Method Based on Hand-Wrist Films'.
7. Lopes P T C., Pereira GAM., Santos AMPV (2010) 'Morphological analysis of the lingula in dry mandibles of individuals in Southern Brazil'.
8. Mark G. Hans., Donald H. Enlow., Regina Noachtar (1995) 'Age related difference in mandibular ramus growth: a histologic study'.
9. Martone, C. H., Ben-Josef, A. M., Wolf, S. M. and Mintz, S. M. (1993) 'Dimorphic study of surgical anatomic landmarks of the lateral ramus of the mandible', *Oral Surgery, Oral Medicine, Oral Pathology*, 75(4), pp. 436–438.
10. Marzola, C., Frare, P. H. B., and Toledo Filho, J. L. et al., (2005) 'Forame da mandíbulacontribuição sobre sua localização para as técnicas anestésicas', *Rev. Odontol (Eletrônica- Academia Tiradentes de Odontologia-ATO), Bauru, SP*, 2(6), pp. 235– 258.
11. Mbajiorgu, E. F. (2000) 'A study of the position of the mandibular foramen in adult black Zimbabwean mandibles', *The Central African Journal of Medicine*, 46(7), pp. 184–190.
12. O'ryan F. S. (1999) 'Rigid fixation in Orthognathic surgery', *Select. Read. oral Maxillofac. Surg.*, 8(2), pp. 1–3.
13. Padmavathi G., Suman Tiwara., Varalakshmi K L., Roopashree R (2014) 'An Anatomical Study of Mandibular and Accessory Mandibular Foramen in Dry Adult Human Mandibles of South Indian Origin', Journal of Dental and Medical Sciences.
14. Roberts DH, Swray JA. Local analgesia in dentistry. 2nd edition. Bristol. John Wright, 1979.

15. Samanta, 1. Prajna Paramita and Kharb, P. (2013) 'Morphometric analysis of mandibular foramen and incidence of accessory mandibular foramina adult human mandibles of an Indian population.' *Rev Arg de Anat Clin*, 5(2), pp. 60–66.
16. Shailendra Singh., Suniti Raj Mishra., Pramod Kumar., Priyanka Sinha., Sushobhana., Jigyasa Passey., Rahul Singh.(2015) 'Location of mandibular foramen in correlation with the gonila angle in Indian population: A morphometric study for surgical practices', International journal of Anatomy and Research.
17. Shalini, R., Ravi Varman, C., Manoranjitham, R., Veeramuthu, M. (2016) ' Morphometric study on mandibular foramen and incidence of accessory mandibular foramen in mandibles of South Indian population and its clinical implications in inferior alveolar nerve block',
18. Sicher H, Dubrul EL. Oral Anatomy. 8th edition. St Louis Ishiyaku Euro America Inc. 1988
19. Thangavelu, K., Kannan, R., Kumar, N. S., Rethish, E., Sabitha, S. and SayeeGanesh, N. (2012) 'Significance of localization of mandibular foramen in an inferior alveolar nerve block', *Journal of Natural Science, Biology, and Medicine*, 3(2), pp. 156–160.
20. Trost, O., Salignon, V., Cheynel, N., Malka, G. and Trouilloud, P. (2010) 'A simple method to locate mandibular foramen: preliminary radiological study', *Surgical and radiologic anatomy: SRA*, 32(10), pp. 927–931.
21. Wittwer, G., Adeyemo, W. L., Beinemann, J. and Juergens, P. (2012) 'Evaluation of risk of injury to the inferior alveolar nerve with classical sagittal split osteotomy technique and proposed alternative surgical techniques using computer-assisted surgery', *International Journal of Oral and Maxillofacial Surgery*, 41(1), pp. 79–86.
22. Wolford, L. M. (2000) 'The sagittal split ramus osteotomy as the preferred treatment for mandibular prognathism', *Journal of Oral and Maxillofacial Surgery*, 58(3), pp. 310–312.