

INTERNAL TAMPONADE BY SILICONE OIL IN THE TREATMENT OF
RETINAL DETACHMENT : A REVIEW AND A RETROSPECTIVE STUDY

Jaywant Ram

A Dissertation Submitted to the Faculty of Ophthalmology,
University of the Witwatersrand, Johannesburg for the
Degree of Master of Medicine (Ophthalmology).

February 1989

DECLARATION

I declare that this dissertation is my own, unaided work.
It is being submitted for the degree of Master of Medicine
(Ophthalmology) in the University of the Witwatersrand,
Johannesburg. It has not been submitted before for any
degree or examination in any other University.



JAYWANT RAM

28th day of February , 1989

Contents:

A:	A Review of the Literature : Silicone Oil
I	Introduction to Silicone Oil
II	Temporary Tamponading agents
III	Physical and Chemical Properties
IV	Mechanism of Action of Silicone Oil
V	Problems with Silicone Oil
VI	Indications for Silicone Oil
VII	Technique of injection of Silicone Oil
VIII	Should Silicone Oil be Removed?
IX	Indications for Remova. of Silicone Oil
X	Technique for Removing Silicone Oil
XI	Results of Treatment
XII	Complications of Intravitreal Silicone Oil
XIII	Histological studies of biological effects of Silicone Oil
XIV	Ultrasound finding following use of Intravitreal Silicone Oil
XV	Silicone Oil and its influence on Electrophysiologic Findings
B:	Retrospective Study - Silicone Oil
I	Subjects and Methods
II	Results
III	Discussion
IV	Summary

TABLES AND FIGURES

- Page 13 Figure 1 | Pre- and subretinal fibroblastic membranes contract and throw the retina into folds.
- Page 13 Figure 2 | Contracting pre - and subretinal glial membranes can cause retinal folding.
- Page 19 Figure 3 | Schematic drawing of air-fluid exchange. The silicone tube allows a continuous entry of sterile air into the eye while the Charles' flute needle removes the fluid. The eye will then be filled with air and the retina will flatten.
- Page 19 Figure 4 | Schematic drawing of silicone oil injection with the silicone - air exchange technique. When the silicone is injected the air escapes through the opening in the pars plana previously used for illumination.
- Page 25 Figure 5 | Refractive changes in non-aphakic and aphakic eyes.
- Page 32 Figure 6 | Clemens, Kroll and Rochels)
(Left) When the patient is upright, the sound waves strike diagonally at the border of the silicone bubble, producing small peaks.
(Right) When the patient bends forward, the silicone bubble is in direct contact with the retinal detachment.
- Page 35 Table 1 | Table reflecting details of patients who had vitrectomy and silicone oil
- Page 36 Table 2 | Results showing the vision, the [unclear] of the lens and intraocular pressure.

1 Introduction

Silicone Oil for the management of complicated retinal detachments was introduced by Cibis¹ and associates. Its clinical use was later prohibited in the United States because of significant post-operative complications. Experimental studies indicated that silicone oil might be retinotoxic. Scott² in Cambridge, for many years continued to advocate the use of Silicone Oil and he slowly convinced retinal surgeons that there might be a place for Silicone Oil in detachment surgery. Because of a better understanding of vitreoretinal abnormalities and improved surgical techniques, the use of Silicone Oil is now being re-evaluated in many centres including the United States.

II Temporary Tamponading Agents e.g. Air, sulphur
hexafluoride (SF6), hyaluronate (healon), Silicone
Oil

The effect of a temporary tamponading agent is to prevent fluid from the vitreous passing through a retinal break or hole, causing the subretinal fluid to reabsorb and the retina to flatten. It also flattens normal mobile retina which is detached. It does not flatten retina where there is proliferative vitreoretinopathy (PVR) which immobilizes the retina and causes puckering of the retina. The drawbacks of air are that it is short acting in the vitreous cavity, it can cause acute glaucoma and there is a marked inflammatory response due to the inflow of serum protein into the vitreous. Other gases have been used and include sulphur hexafluoride (SF6), octafluoro-cyclobutane (C4f8) and perfluoropentane (C₅F₁₂). These gases are inert, non polar, symmetric molecules of high molecular weight which cause them to be absorbed slowly in tissue. After intravitreal injection, the gas volume expands because some of the nitrogen, oxygen, carbon dioxide that is normally dissolved in adjacent tissue is attracted into the gas bubble. The problem of excessive volume increase of the gas bubble postoperatively is offset by injecting a mixture of air and high molecular weight gas. When mixed with air, these gases remain much longer in the vitreous than does air alone. Their disadvantages is that the more lasting the gas mixture, the more inflammation it causes. For this reason a well tolerated durable liquid of high viscosity is potentially superior to gas mixture e.g. silicone oil. The effect of non-absorbable liquids is longer lasting compared to gases or air.

Sodium hyaluronate has also been used as a temporary tamponade. In a series by Vatne and Syrdalen¹² only 50% of retinas were attached six months postoperatively. Silicone oil has also been used as a temporary tamponade and removed six weeks postoperatively¹⁸. The use of silicone oil as a temporary tamponade prevents the development of cataracts, glaucoma and retinal toxicity but is complicated by redetachment of the retina.

Dow Corning 360 medical fluid or Dimethyl-polysiloxane is a clear colourless silicone liquid characterised by the following properties ; chemical inertness, high water repellency, low volatility, resistance to decomposition by heat, and oxidation, good lubrication characteristics for plastics and rubber, low surface tension and a very low order of toxicity and skin sensitization. It is intended for use in a variety of medical applications such as lubricant for rubber and plastic devices and instruments, protective and water repellent films on skin, providing a hydrophobic surface on glass and ceramic surfaces, and as a versatile defoamer. There is little change in physical properties over a wide temperature span (-40°C to 204°C). This fluid also exhibits heat stability, oxidation resistance and very low water vapour pressures. It is insoluble in organic liquids other than active solvents and is non greasy, non-rancidifying and virtually odourless.

Silicone oil is available in given standard viscosity grades: 100, 350, 1000, 2000 and 12500 centistokes. Only silicone oil for viscosities greater than 2000 centistokes should be used. Studies revealed little tissue reaction with higher viscosities whereas adverse tissue reactions may be seen with lower viscosities. In a study by Champion et al silicone oil of various grades injected into the peritoneum of mice revealed that the least chronic inflammatory reaction was found with the lower viscosity silicone oil²⁷. In a study by Petersen et al, they recommended low density silicone oil for long term tamponade²⁸.

IV Mechanism of Action of Silicone Oil

- (a) Silicone oil can mechanically push the retina back into contact with the retinal pigment epithelium.
- (b) Silicone oil can function as a tamponading agent, occluding the retinal holes or breaks, causing reabsorption of the subretinal fluid and flattening of the retina.
- (c) Silicone oil of higher viscosities can actively unfold and flatten retinas which are complicated by PVR.
- (d) In some patients the tamponading and mechanical effects of silicone oil are insufficient to keep the retina in place in an active phase of proliferation. The retinal detachment will then progress.
- (e) Silicone oil provides increased optical conditions when vitrectomy is done for dissection and removal of epiretinal membranes²⁶.

V Problems with Silicone Oil

- (a) There are various viscosities of silicone oil which can be injected intravitreally. The higher the viscosity the more difficult it is to inject into the vitreous. For lower viscosities e.g. 2000 centistokes a 5cc syringe is adequate whereas a mechanical pump is required to inject silicone oil of higher viscosities e.g. 125000 centistokes. A recent study by Grisolano shows that 10ml of silicone oil can be injected through a 16 gauge needle of 0.8mm in only 5 minutes, thus doing away with mechanical pumps ²³.
- (b) Silicone oil is lighter than aqueous and tends to rise in the vitreous cavity. Because it is very difficult to get a complete fill of the vitreous cavity the inferior retina and especially holes in this area will require further treatment. To manage inferior detachments, external buckling e.g. by means of a tyre and, or cryotherapy can be used.
- (c) In aphakic patients with an intact iris diaphragm it is important to make an iridectomy at the 6 o'clock position. This will allow aqueous humour to pass via the iridectomy at the 6 o'clock position into the anterior chamber, preventing silicone oil from being pushed into the anterior chamber, thus preventing keratopathy and secondary glaucoma. A conventional iridectomy, in the upper 1/3 of the iris, may allow the silicone oil to enter the anterior chamber causing complications.

- (d) Silicone oil in the vitreous cavity can emulsify and find its way through the zonules and via the pupil into the anterior chamber, or in aphakic patients via the pupil into the angle causing an inverse hypopyon. This could lead to the development of complications such as keratopathy and glaucoma, but this is more commonly noted with large oil globules against the cornea.
- (e) Silicone oil of low viscosity e.g. 100 centistokes or less are not viscous enough to remain in the intravitreal cavity and pass via the retinal holes into the subretinal space. If this happens because of low viscosity after the surgery or at the time of the procedure the eye is lost.
- (f) Few cases of opacification of the silicone oil has occurred post-operatively. It is due to faulty purification of the product in the factory, which encourage secondary polymerization. Better purified silicone is now available.

VI Indications for Silicone Oil include:

- (A) Proliferative vitreoretinopathy.
- (B) Giant retinal tears.
- (C) Failed conventional surgery.
- (D) Macular hole retinal detachment.
- (E) Retinal detachment in diabetes requiring vitrectomy.
- (F) Peripapillary tears in myopes.

(A) Proliferative vitreoretinopathy (PVR)

There are several predisposing causes of PVR

- (i) Blood in the vitreous.
- (ii) Multiple detachment procedures.
- (iii) Vitreous loss e.g. occurring at the time of subretinal fluid release.
- (iv) Detachment of macula.

Machemer³ has classified the development and progress of PVR.

- Stage I a Tobacco dust
- Stage II b Pigment clumping in the vitreous
- Stage III c Membrane formation within the vitreous and on the retina (clinically the retina appears stiff and does not undulate freely).
- Stage IV d This stage is characterised by contraction of the membranes. The retina has a thickened yellow appearance and star folds are present.

Subgroups of IVth Stage

- (a) Single quadrant involved.
- (b) Two quadrants involved.
- (c) Three to four quadrants involved.
This is seen as a morning glory detachment.
- (d) Morning glory detachment with an extremely narrow funnel obscuring the disc.

Staging has significance as far as the surgical treatment is concerned.

Stages I to IV (b) are all amenable to standard extraocular detachment procedures.

Stage IV (c) - the morning glory detachment cannot be flattened without internal tamponade e.g. silicone oil.

Stage IV (d) is inoperable.

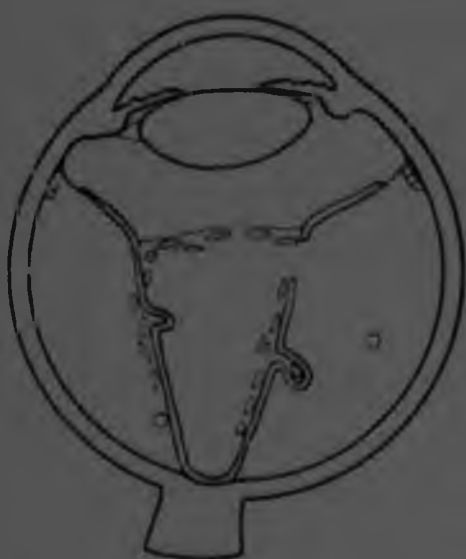

Fig 1 Peri- and subretinal fibroblastic membranes contract and throw the retina into folds. Posterior vitreous membrane is shortened, pulling the retina centrally. A tunnel-shaped detachment results.

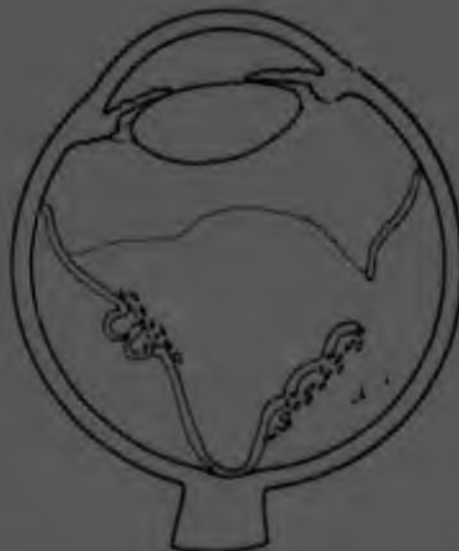

Fig 2 Contracting pre- and subretinal glial membranes can cause retinal folding.

KEY
 --- RGD
 --- FIBROBLAST
 --- VITREOUS

Machemer³ described the pathogenesis of proliferative vitreo-retinopathy. When the retina is detached, cells are liberated from the pigment epithelium and appear as pigmented macrophages. These cells multiply in the subretinal space and reach the retinal surface via a retinal hole. Some of the pigment epithelial macrophages undergo change and form fibroblast and fibrocytes. Other pigment epithelial macrophages develop cellular membranes. In addition to the pigment epithelial cells, retinal glial cells participate in the proliferation. There is sudden contraction of the membranes. Depending on the force and the size of the contracting membrane, different clinical pictures result that vary from superficial surface wrinkling to heavy folding of the retina. Membranes can also occur subretinally, leading to folding of the retina. See figure 1 and 2 page 11.

According to Scott⁴, PVR is a condition which complicates retinal detachment. It immobilizes the detached retina by fibrous membranes so that conventional surgery fails to restore the retina permanently to its normal position. The diagnosis can be made before fibrosis occurs so that prompt surgery by buckling technique may prevent the full development of massive retraction.

There are 4 major signs of the pre-fibrotic stage :

1. Peripheral retinal immobilisation.
2. Distortion of retinal tears.
3. Reduction of the mobility of normally mobile vitreous gel.
4. The presence of pigmented macrophages in the gel.

If the pre-fibrotic stage is untreated the stage of fibrosis results and the signs of fibrosis include:

- a visible membrane
- retinal puckering
- narrow posterior folds of detached retina.

Treatment of the fibrotic stage includes vitrectomy and silicone oil. The problem is to separate the membrane from the retina and, since it will be hazardous to remove via a vitrectomy, membrane separation can only be achieved by the injection of silicone oil.

(B) Giant Retinal Tears :

These tears are by definition greater than 90° . Gravity and membranes can produce flap positions which are exceedingly difficult to correct. These breaks are commonly complicated by massive vitreous retraction so that the permanent fixing of the posterior flap, together with the retinal detachment may not respond to conventional surgery using scleral buckling, intraocular gas and post-operative positioning.

For the above reasons and also that silicone oil has no disadvantage in the treatment of giant retinal tears, Scott uses silicone oil especially if there are pigment cells in the vitreous, rolling of the posterior edge of the break and surface features of the retina indicating early membrane formation. Most patients with giant breaks present with early signs of PVP, and in these

patients the presence of the early surface retinal membrane prevents the injected gas or air from exerting an effect for long enough to obtain a good adhesion. The result is retraction of the posterior flap and failure. Therefore, a vitrectomy is done followed by silicone oil to allow a more permanent fixation of the posterior flap and in many cases an elevation of the problem membrane. When silicone is used it is preferable to operate on patients in a prone position, for silicone moves more slowly in the eye and it is desirable to inject it into the correct position from the beginning. This will require the use of a special operating table.

(c) Failed Conventional Surgery :

When conventional surgery has failed to flatten the retinal detachment, especially when all visible holes are sealed and many detachment procedures have been performed, the only choice one is left with, is to do a vitrectomy and silicone oil, as a last resort.

(d) Macular hole retinal detachment

According to Haut⁵ et al a retinal detachment caused by a macular hole has three major disadvantages when classical methods are used:

- (i) One has to establish direct contact with the sclera in the macula region. This is not easy and has its own complications, necessitating removal of muscle and possibly damaging the nerves and short ciliary vessels, as shown by extensive choroidal changes revealed in angiography.
- (ii) External buckling in the macular region will result in distortion preventing maximum gain in visual acuity.
- (iii) With a macular hole there may be an associated peripheral tear, the treatment of which is difficult because of the need for complex episcleral buckling.

By contrast, the vitrectomy - silicone oil method eliminates :

- outer posterior damage to sclera
- deformation of the eyeball
- the risk of laceration of the staphylomatous sclera
- complications involved in puncturing the subretinal fluid (insofar as the macular hole permits endocular aspiration)
- peripheral buckling where there is an upper tear
- maximum visual acuity is retained

Some workers, however, have had success following simple vitrectomy, which would eliminate possible retinal traction, and subsequent injection of gas.

(E) Retinal Detachment in Diabetics requiring Vitrectomy:

In certain Diabetic eyes vitrectomy may be associated with retinal detachment. Retinal breaks may be the cause of the retinal detachment or may be caused by attempts to elevate membranes which may be very difficult to remove. Silicone oil is very useful in the treatment of these retinal complications of vitrectomy and may reduce the risk of subsequent rubeosis.

(F) Peripapillary Tears in Myopes:

Silicone oil can be used in high myopes with peripapillary tears whose posterior poles are inaccessible to conventional buckling surgery. The only modification to surgery is that one must be sure to completely replace the vitreous gel which is degenerate, and it is the only way to ensure an internal seal of the tear in all positions of the eye.

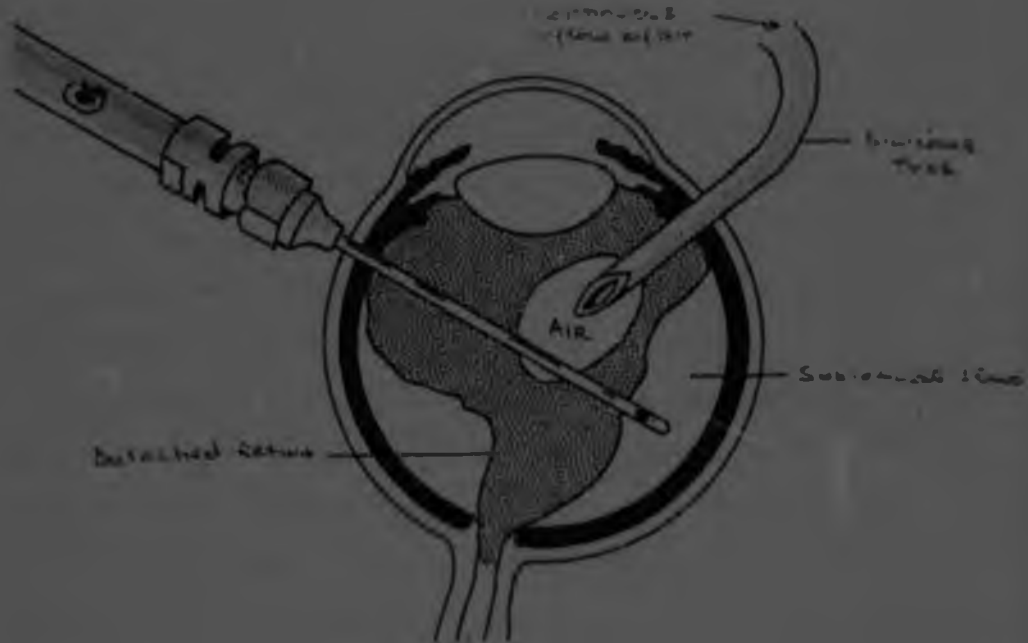


Fig. 3 | Schematic drawing of air-fluid exchange. The silicone tube allows a continuous entry of sterile air into the eye while the Charles' flute needle removes the fluid. The eye will then be filled with air and the retina will flatten.

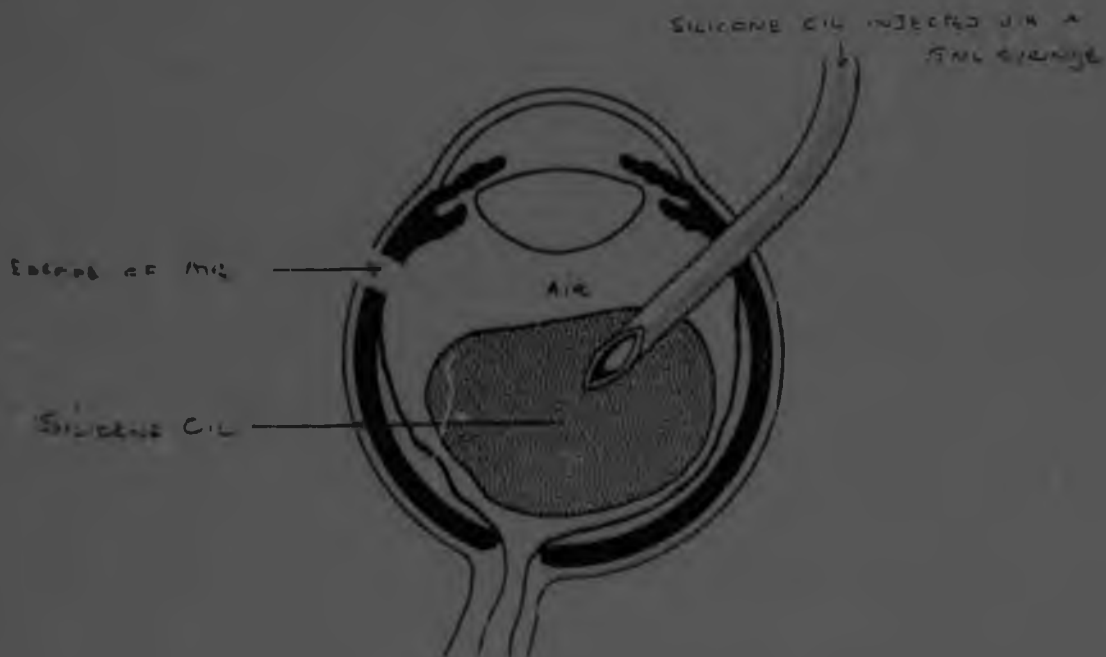


Fig. 4 Schematic drawing of silicone oil injection with the silicone-air exchange technique. When the silicone is injected the air escapes through the opening in the pars plana previously used for illumination.

VII Technique of injection of Silicone Oil

The method used at St John Eye Hospital is to inject the silicone oil via an infusion tube of 1mm diameter at the pars plana. (See figure 3). At the end of the vitrectomy, the balanced salt solution is exchanged for air, and the air is allowed through the silicone tube via a continuous flow into the vitreous cavity. The Charles' flute needle, which acts as a vacuum needle with finger tip control is inserted either into the retinal tear or if this is not technically possible, over the disc to drain the sub-retinal fluid and balanced salt solution. The eye is thus filled with sterile air. Care should be taken to visualise the tip of the Charles' flute needle so that retina does not adhere to the port of the needle. Silicone oil is then connected to the infusion tube and the eye is filled with the oil, replacing the air. (See figure 4). A preplaced suture can be tied when the infusion tube is removed, so as not to allow any oil to escape. Phakic and aphakic eyes can be done equally well with this procedure. A 5ml syringe is used to inject the silicone oil via the infusion tube. Silicone oil of 2000 centistokes is used at St John Eye Hospital. Another technique of injection of silicone oil is a mechanical pump especially for the highly viscous silicones.

VIII Should Silicone Oil be Removed?

There are two schools of thought.

- (a) Scott⁴ experiences few long term side effects and he does not remove the silicone oil.

In a series of 50 patients there were no corneal problems. Only 50 patients did not benefit from surgery

and there were no patients whose vision deteriorated as a result of optic atrophy or retinal atrophy. Cataracts occurred only in those 5 patients whose surgery failed completely. The follow-up in the 50 patients was for 5 years.

- (b) Gonvers⁽⁶⁾ feels that silicone oil causes long term complications including silicone retinopathy, cataract, glaucoma and keratopathy and tends to remove it 6 - 8 weeks following reattachment of the retina. He claimed a success rate of 62% using silicone oil as a temporary tamponade. Clinical complications directly related to silicone oil were rare and did not progress or develop after the removal of the silicone oil except for opacification of the lens in phakic patients. This occurred frequently (43 out of 55 eyes) and progressed many months after the withdrawal of silicone oil.

IX Indications for Removal of Silicone Oil

1. Acute glaucoma
2. Cataract formation
3. Keratopathy
4. Following reattachment of the retina

There is an increasing tendency to remove silicone oil once the retina is attached, 6 - 8 weeks after the surgery to prevent the above complications.

Silicone oil has the advantage that one can apply cryotherapy or laser to the retina as the media are clear. Following the

cryotherapy and or laser, (which will cause the retina to remain flat) the oil can be removed 6 - 8 weeks later.

X Technique for Removing Silicone Oil

(a) Phakic eyes

Two incisions are made in the pars plana. The site for release of silicone oil should be uppermost thus facilitating outflow of the silicone oil as it is lighter than balanced salt solution. The incision for the infusion can be most dependent. Infusion of balanced salt solution is via a silicone tube. Most of the silicone oil will flow out, but it is difficult to expect the last 0.2 to 0.5 ml of silicone oil from the vitreous cavity.

(b) Aphakic eyes

Two incisions are made : one in the cornea and one in the pars plana. The pars plana incision can be used for infusing the balanced salt solution and the corneal incision can be uppermost for drainage of silicone oil. An alternative method is to make two incisions in the cornea. The silicone tube can be inserted through the cornea via the dilated pupil into the vitreous cavity. Again the site for drainage of silicone oil must be uppermost.

XI Results of Treatment

(a) Scott² reviewed 160 cases, of which 25 were aphakic.

Follow-up was from 6 months to 4 years.

126 Cases were anatomically successful - 78%

12 Cases saw 6/36

37 Cases saw 6/60

5 Cases saw worse than 6/400

72 Cases saw 6/18 to 6/60

- (b) Gonvers⁶ achieved a 57 percent success rate, compared to 10 percent when he performed vitrectomy alone. A success rate of 62% was achieved by Gonvers when he used silicone oil as a temporary tamponade. This success rate of 52% was achieved 6 months after the silicone oil was removed.
- (c) Grey and Leaver⁷ had a successful early anatomical results in 66% of patients. Successful late anatomical result was achieved in 56%. (One month compared to one year following the operation). Visual results improved in 56% of patients after one month and 40% after one year.
- (d) Of 47 eyes operated on by Constable⁸ using very high viscosity silicone oil (12500), he achieved a 72% anatomical reattachment. All eyes in which complete or partial retinal reattachment was achieved showed improvement in vision but this was restricted to count fingers or 6/60.
- (e) The following results were published by Glaser⁹ from the Wilmer Ophthalmological Institute.
- The retina was completely reattached in 70% of eyes (16 of 23 eyes) with proliferative Diabetic retinopathy and 67% of eyes (20 of 30 eyes) with PVR. Follow-up averaged 11 months in the PDR group and 14.4 months in the PVR group. The visual result was significantly

different in the above two groups. Whereas it was better than 5/200 in only 5 cases of the PDF group the visual acuity was better than 200 in 53% of the PVR group.

XII Complications of Intravitreal Silicone Oil (9) (10)
can be divided into intra-operative and postoperative complications.

(a) Intraoperative complications include:

- (i) Subtotal filling of the vitreous cavity with silicone oil leads to a persistent detachment.
- (ii) Subretinal silicone oil secondary to improper placement of the infusion cannula or via the retinal hole. The operation should be abandoned at this stage.
- (iii) Central retinal artery occlusion which is rare
- (iv) Silicone oil in the anterior chamber resulting in postoperative complications.
- (v) Expulsive ocular haemorrhage occurs very rarely and has occurred even after cataract extraction, trabeculectomy

(b) Post-operative Complications

(i) Refractive changes

- Emmetropes become hypermetropic (+6.0D or +7.0D)
- Myopes tend to emmetropia with improvement in vision.
- Aphakes become emmetropic again,

Figure 5(a) shows an aphakic eye in which the convex surface of the silicone oil acts as a converging lens while a phakic eye (Figure 5(b)) has a concave surface of the silicone oil behind the lens acting as a divergent lens.




Fig. 5(a)

Fig. 5(b)

Refractive changes in phakic and aphakic eyes.

(ii) Secondary opacification of the silicone oil occurs in about 10 out of 350 cases, 24 - 48 hours after the operation. It is due to faulty purification of the product in the factory.

(iii) Retinal Complications

According to Sugar ¹⁰ et al, and Manschot ¹⁵ silicone oil causes degeneration and partial loss of ganglion cells or receptor cells or both.

Histochemical studies showed that large amounts of retinal phospholipids were attracted to the vitreo-retinal interface and surround the silicone particles. Electron microscopic findings suggest that silicone particles are able to pass into the retina through widened inter-cellular gaps between Müller cells and subsequent formation of openings in the internal limiting membrane. These findings are probably not significant as Scott ⁴, has no clinical evidence that silicone oil is toxic to retina or lens.

Scott ¹¹ concludes that previous bad experience with use of silicone oil is due to the inadequate volume used and the consequent inability to separate fibrotic membranes.

In a series of 99 eyes treated with intraocular silicone oil Ando ³¹ et al found retinal haemorrhages four times.

(iv) The Lens

In Scotts' ⁴ series of 160 patients, cataracts developed only in 5 patients. Also of note is that surgery in these 5 patients failed completely.

In a series by Dimopoulos, 85% of patients developed cataracts in the first year postoperatively²⁹. In another series by B Billington and P Leaver, poor acuities were attributed to cataract formation eighteen months after surgery³⁰.

I think that the review of the literature shows that cataracts develop in a high percentage of patients following intravitreal silicone oil injection and Scott is the only one who publishes results to the contrary. According to Haut¹² et al, the mechanical properties linked to the rising of the silicone oil due to its low gravity seems to be of prime importance. This may be responsible for cataracts due to the silicone oil pressing against the posterior capsule in decubitus. The opacities do in most cases start on the posterior surface of the lens. Haut has not seen any macrophages swollen with silicone oil on the anterior capsule of the lens, although these were described by Leaver and co-workers whose conclusion is that of a metabolic pathogenesis due to blocked transmission at the lens epithelium.

(v) Glaucoma can be either open or closed angle.

In Haut's¹² series 12 out of 23 cases had angle closure. In Scott's series open angle glaucoma developed in 2 cases out of 10. The effect appears to be a chemical emulsification in which bubbles break away from the main bubble months after surgery and pass into the anterior chamber. Both cases were not aphakic so that the silicone oil droplets passed through the zonules.

In the anterior chamber the droplets did not coalesce but infiltrated the iris and trabecular meshwork.

The incidence of the complication is very low but must be recognised and treated before damage is caused.

(vi) Keratopathy

Permanent contact of silicone oil with the cornea results in corneal changes of various degrees of severity.

A small bubble of silicone oil mobile in the anterior chamber will not result in any changes of the cornea.

A large bubble of silicone oil in the anterior chamber can cause a calcific band keratopathy. The calcium salt deposit in Bowman's layer and superficial stroma can be explained by a lower metabolic rate in the cornea, especially in the superficial layers. Less metabolic end products like lactic acid are produced, while the loss of carbon dioxide by evaporation remains unchanged. This results in an increase in pH in the superficial corneal layers, and precipitation of calcium salts occurs. The silicone oil blocks the transport of nutrients from the aqueous into the cornea.

Thinning of the cornea over silicone oil in the anterior chamber either with or without band keratopathy is seen frequently after oil injection. It is the result of evaporation at the corneal surface until the passive leak is being occluded by the oil bubble.

Permanent contact of oil with the endothelium of longer than 6 months results in metaplasia of endothelial cells to a posterior collagenous layer. Even when the endothelium is changed in a fibrous layer, the cornea may stay clear and of normal thickness so long as there is no aqueous leak into the stroma. If silicone oil is removed at this stage the cornea will decompensate due to the malfunctioning of the endothelium.

In Haut's ¹² series 37 out of 200 cases developed corneal changes. In 34 cases the silicone oil was in contact with the cornea whereas in 7 cases, although there was contact the cornea remained clear.

XIII Histological studies of biological effects of
 Silicone Oil

Mukai ⁹ and associates reported ganglion cell degeneration, swelling of the nerve fibre layer, and vacuolation of the ganglion cells, photoreceptor cells, and corneal endothelial cells in owl monkeys injected with liquid silicone.

Faulborn and Bowald found oil inclusions when examining two epiretinal membranes removed from silicone oil-filled eyes.

Bonfeld and Laqua ²⁴ in a study of pre-retinal membranes from human eyes filled with silicone oil found membrane - bound vacuoles that appear as empty spaces on transmission electron microscopy.

It is widely accepted that the spaces had been filled with silicone oil before tissue processing and that the silicone oil was lost during dehydration and embedding in plastic region.

Results concerning the possible effect of intraocular silicone oil on the retina are still controversial. Histologic studies on enucleated human eyes showed no toxic effect in attached retinas, but other cases reports on the histologic appearance of human eyes after long term silicone oil filling described severe sequelae in the retina and other ocular structures after silicone oil filling. V.C. Parmiley et al ²⁵ found a foreign body giant cell reaction in a human eye enucleated 20 months after silicone oil injection. In an experimental study Champion et al ²⁶ found abundant extracellular lipid - like droplets and a dense cellular infiltrate of macrophages, lymphocytes and multinucleated giant cells. Lipid - like inclusions were observed in macrophages and multinucleated giant cells.

Ultrasound Finding following use of Intravitreal Silicone
Oil ¹³

A - Scan Findings

The vitreous cavity measures 22 micro seconds without silicone oil but is greatly prolonged (40 micro seconds) after intravitreal silicone oil injection. The peak of the silicone bubble is narrow (1.5 micro seconds) symmetric and in direct contact with the retina, choroid and sclera. The orbital echoes are rarefied, in contrast to those obtained without silicone oil. The above occurs because the velocity of sound is delayed in silicone oil.

The velocity of sound in silicone oil at 20°C is 1.010 meters per second.

If the silicone does not completely fill the vitreous body it rises in the vitreous cavity leaving only a small unfilled area at the bottom. To avoid having the sound waves strike the 6 o'clock meridian diagonally, the patient should bend over so that the silicone bubble is in direct contact with the retina. (See Figure 6). Because the peak is widened to 2.5 micro seconds or more and asymmetric with steps, several adjustments in A-Scan are necessary.

The high double peak demonstrates a retina immersed in silicone oil.

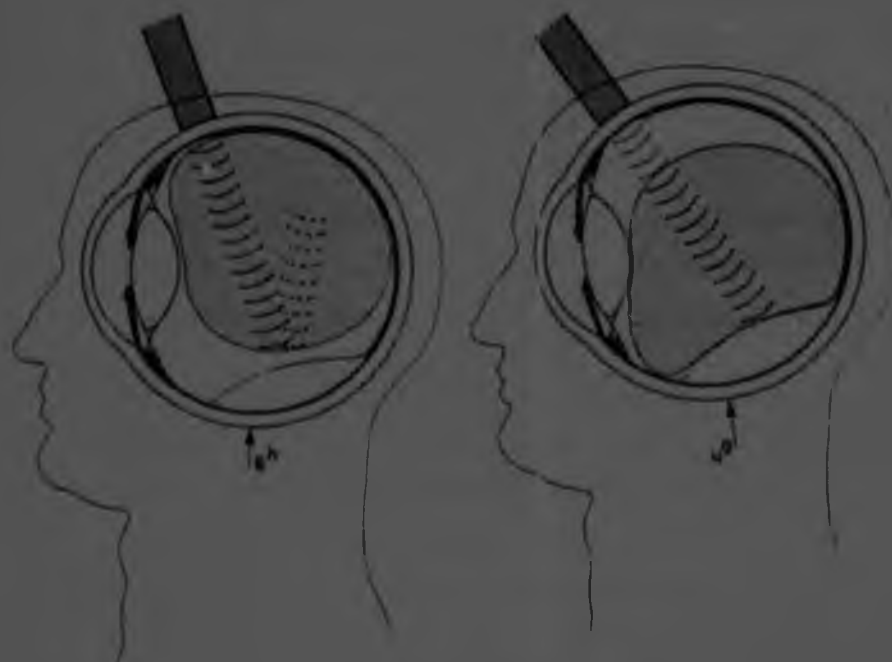

Fig 6 (Clemens, Kroll, and Rochels) Left, When the patient is upright, the sound wave strikes diagonally at the border of the silicone bubble, producing small peaks. Right, When the patient bends forward the silicone bubble is in direct contact with the retinal detachment.

XV Silicone Oil and its influence on Electro-physiologic Findings¹⁴

(a) Electroretinogram changes

The a and b waves are greatly reduced or are even unrecordable with silicone oil in situ. After removal of the silicone oil the electroretinographic a and b waves increase although the anatomic situations and visual functions remain unchanged.

The pre-existing retinal detachment seems to be the most important factor influencing the eventual a and b wave values. The time the silicone oil remains in the eye is apparently less important and does not affect the a and b wave amplitudes.

(b) Electro-oculogram changes

With silicone oil in the eye, the basic level of the corneo-retinal potential is low compared to that in normal subjects and in those with retinal detachments. After oil removal, the basic level increases even though it is still in the subnormal range.

The electro-retinogram and electro-oculographic findings indicate an electrical insulator effect on the conduction of retinal potentials but not retinal toxicity.

XV Silicone Oil and its influence on Electro-physiologic Findings¹⁴

(a) Electroretinogram changes

The a and b waves are greatly reduced or are even unrecordable with silicone oil in situ. After removal of the silicone oil the electroretinographic a and b waves increase although the anatomic situations and visual functions remain unchanged.

The pre-existing retinal detachment seems to be the most important factor influencing the eventual a and b wave values. The time the silicone oil remains in the eye is apparently less important and does not affect the a and b wave amplitudes.

(b) Electro-oculogram changes

With silicone oil in the eye, the basic level of the corneo-retinal potential is low compared to that in normal subjects and in those with retinal detachments. After oil removal, the basic level increases even though it is still in the subnormal range.

The electro-retinogram and electro-oculographic findings indicate an electrical insulator effect on the conduction of retinal potentials but not retinal toxicity.

Retrospective Study

1. Subjects and Methods

The records of all patients at the St John Eye Hospital, between February 84 and June 85, with retinal detachments requiring posterior vitrectomy and intraocular silicone oil injection were reviewed. There were 35 cases of which 29 had a satisfactory follow up. 30 of 29 patients were operated on. Follow-up ranged from 3 - 24 months with a mean of 10 months. All eyes had a complete pre-operative evaluation including visual acuity, slit-lamp examination and contact lens and binocular indirect ophthalmoscopy. Table I on page 35 shows details of patients who had vitrectomy and silicone oil exchange. The retina was graded according to Machemer's classification¹, 17 eyes operated on were left sided and 13 eyes were right sided. There were 20 males and 9 females. The causative factors included:

Trauma	-	18
Cataract Surgery	-	1
Marfans	-	1
Uveitis	-	2
High myopia	-	1
Giant retinal tear	-	1

10 Patients had conventional surgery prior to undergoing intraocular silicone injection.

The status of the lens prior to vitrectomy and intraocular silicone oil included:

Aphakic eyes	-	9
Cataractous lenses	-	5
Clear lenses	-	16

According to Machemer's classification the patients operated on fell into the following grades:

Grade I	-	11
II	-	7
III	-	3
IVa	-	3
IVb	-	3
IVc	-	3

The technique of vitrectomy and silicone oil injection was described on page 20.

II RESULTS

Of the 30 eyes operated on, 15 had attached retinas while the rest had totally detached retinas.

The table below shows results concerning vision, the state of the lens and the intraocular pressure.

TABLE 2	Vision	improved	unchanged	worse	Total
(Post-operatively)	11	17	-	-	30 eyes
Lens	Pre-operative	Post-operative			Total
	Aphakic	10	15		30 eyes
	Phakic	20	15		30 eyes
Intraocular Pressure	10mmHg	10-21mmHg	21mmHg	Total	
Pre-operative	15	12	3	30	
Post-operative	11	17	2	30	

Silicone oil was only removed in 2 patients.

III Discussion

The cases we see at St John Eye Hospital include long standing detachments, traumatic detachments and detachments with severe PVR. All these factors contribute to the poor prognosis following operation. The reattachment rate of 50% obtained at the St John Eye Hospital can be considered acceptable. Various reports in the literature of successful retinal detachment repair using silicone oil have varied between 40% and 75%.

Complications encountered post-operatively can be divided into immediate post-operatively and long term complications.

Immediate post-operative complications include:

- (a) Intraocular Hypertension which was controlled by using B-Blockers and Acetazolamide.
- (b) Incomplete fill of silicone oil noticed post-operatively.
- (c) Persistent detachment.

Long term post-operative complications include:

- (a) Lens opacities: In this series only 2 out of 15 patients developed posterior subcapsular lens opacities while the rest remained clear. This study does not reflect the literature which reveals a high percentage of cataracts develop following injection of intraocular silicone oil. This is contrary to results that Scott has published.
- (b) Corneal decomposition: No patients developed corneal decomposition in this series.

in.

- (c) Glaucoma: 5 patients continued to receive B-Blockers and Acetazolamide on a long term basis and their pressures were reasonably well controlled.
- (d) Removal of Silicone Oil: Silicone oil was removed in 2 patients in this series and both patients then developed total retinal detachments.

IV SUMMARY

With the experience at the St John Eye Hospital and in view of the experience overseas, referred to in this paper the following conclusions can be reached:-

- (a) Silicone oil injection, intravitreally, is the only way of attaining reattachment of chronic retinal detachments due to trauma, PVR, failed conventional surgery and giant retinal tears.
- (b) The visual acuity post-operatively is not good but the anatomical result obtained of 50% is reasonable.
- (c) The lens should be left in situ at the time of surgery. It should be removed if it is cataractous or if vitrectomy in the vitreous base area, is required. Our study revealed only two cataracts post-operatively but the incidence will increase the longer the silicone oil is left intraocularly.
- (d) Silicone oil should be left in situ post-operatively unless it causes uncontrolled glaucoma or corneal decompensation. If a cataract forms post-operatively, an extracapsular lens extraction can be formed leaving the silicone oil intravitreally.

In conclusion my findings at St John Eye Hospital emphasise the experience of Scott in Cambridge.

REFERENCES

1. Cibis P.A. et al : The use of liquid silicone in retinal detachment, Arch. Ophthalmology; 68 (500 - 599) Nov., 1962.
2. Scott J.D. : Treatment of the detached immobile retina, Trans. Ophthalmol. Soc. U.K.; 92 (351-7, 1972).
3. Machemer R : Pathogenesis and classification of massive periretinal proliferation, Br. J. Ophthalmol., 62 (737 - 747) 1978.
4. Scott J.D. : The treatment of proliferative vitreo-retinopathy by separation of periretinal membranes using liquid silicone, modern problems in Ophthalmology; Vol. 15 (285 - 290).
5. Haut et al : Treatment of macular hole retinal detachment with silicone oil, with or without Argon Laser Photocoagulation, Ophthalmologica 187 (25 - 28) 1983.
6. Gonvers M. : Temporary silicone oil tamponade in the management of retinal detachment with proliferative vitreoretinopathy, Am. J. Ophthalmol.; 100 (239 - 245) Aug. 1985.
7. Grey R.H.B. and Leaver P.K. : Silicone oil in the treatment of massive periretinal retraction I. Results in 105 eyes, Br. J. Ophthalmol.; 63 (355 - 360).
8. Constable I. et al : Super viscous silicone liquid in retinal surgery, Australian Journal of Ophthalmology; 1982; 10 : (5 - 11).

17. Fastenberg D.M. et al : Intraocular injection of silicone oil for experimental proliferative vitreoretinopathy, Am. J. Ophthalmol.; 95 (663 - 667) 1983.
18. Gonvers M. : Temporary use of intraocular silicone oil in treatment of detachment with proliferative vitreoretinopathy, ophthalmologica; 184 (210 - 218) 1982.
19. Beekhuis W.H. et al : Basal iridectomy at 6 o'clock in the aphakic eye treated with silicone oil, Br. J. Ophthalmol.; 71 (197 - 200) 1987.
20. Beekhuis G.R.I.J., Zivojnovic R. : Silicone oil keratopathy; indications for keratoplasty, Br. J. Ophthalmol.; 69 : 247 - 253 (1982).
21. Glaser M.B. et al : Silicone oil in treatment of complicated retinal detachment; Ophthalmology; 94 (9) 1109 to 1113 September 1987.
22. H.O. Vatne; P. Syrdalen : The use of sodium hyaluronate (healon) in the treatment of complicated cases of retinal detachment; Acta Ophthalmologica; 64 (1986) 169 - 172.
23. J. Grisolan, A. Peyman : Special short Needles to Inject and Aspirate High - viscosity Silicone Oil, Arch. Ophthalmol Vol. 104, April 1986 (page 608).
24. N. Bornfeld et al : Ultrastructural characteristics of Pre-retinal membranes from Human eyes Filled with Silicone Oil, Am. J. Ophthalmol.; 103 770 - 775 June 1987.
25. V.C. Parmley et al : Foreign - Body Giant cell Reaction to Liquid Silicone Am. J. Ophthalmol.; 101 680 - 683 June 1986.
26. D. Chavaud et al; Ophthalmologie Jan - Mar 1988 1.2. 13 - 15.
27. R. Champion et al : Peritoneal reaction to liquid silicone - an experimental study Graefes Archive Ophthalmology 1987 225 (141 - 145).

28. J. Petersen et al : Fluor Silikonöl Schwerer als Wasser : ein neues Hilfsmittel der vitreo-retinalen chirurgie; Klin Mbl Augentheil 189 (1986) 228 - 232.
29. St Dimopoulos, K. Heimann, Spatkomplikationen nach Silikonol injektion. Langzeitbeobachtungen an 100 Fällen; Klin. Mbl. Augenheilk 189 (1986) 223 - 227.
30. B.M. Billington & P.K. Leaver : Vitrectomy and fluid / silicone oil exchange for giant retinal tears results at 18 months Klin. Mbl. Augenheilk 189 (1986) 223 - 227.
31. F. Ando et al : Graefe's Arch Clin Exp Ophthal 224 32 - 33 January 1986.



Author Ram J

Name of thesis Internal Tamponade by silicone oil in the treatment of retinal detachment: a review and retrospective study
1989

PUBLISHER:

University of the Witwatersrand, Johannesburg

©2013

LEGAL NOTICES:

Copyright Notice: All materials on the University of the Witwatersrand, Johannesburg Library website are protected by South African copyright law and may not be distributed, transmitted, displayed, or otherwise published in any format, without the prior written permission of the copyright owner.

Disclaimer and Terms of Use: Provided that you maintain all copyright and other notices contained therein, you may download material (one machine readable copy and one print copy per page) for your personal and/or educational non-commercial use only.

The University of the Witwatersrand, Johannesburg, is not responsible for any errors or omissions and excludes any and all liability for any errors in or omissions from the information on the Library website.