

# Hard Tissue Barrier Formation in Pulpotomized Monkey Teeth Capped with Cyanoacrylate or Calcium Hydroxide for 10 and 60 Minutes

M. CVEK<sup>4</sup>, L. GRANATH<sup>1</sup>, P. CLEATON-JONES<sup>2</sup>, and J. AUSTIN<sup>3</sup>

Department of Pedodontics, Eastmaninstitutet, Dalagatan 11, S-113 24 Stockholm, Sweden; <sup>1</sup>Department of Pedodontics, University of Lund, School of Dentistry, Malmö, Sweden; <sup>2</sup>MRC/University of the Witwatersrand Dental Research Institute and <sup>3</sup>Central Animal Service, University of the Witwatersrand, Johannesburg, South Africa

Monkey incisor teeth were pulpotomized in groups of 10. After physiological hemostasis, the pulps of group I were covered with isobutyl cyanoacrylate, and those of groups II and III with calcium hydroxide for 10 and 60 minutes, respectively, whereafter this compound was washed away and the wound surfaces covered with Teflon. In group IV, calcium hydroxide was used as a positive control, and Teflon as a negative control in group V. The animals were killed after 12 weeks and the teeth removed in tissue blocks. The material was processed and evaluated histologically with respect to location and continuity of a hard tissue barrier, type of newly formed hard tissue, state of the pulp, and presence of stainable bacteria in the coronal cavity.

Seven of nine teeth in group I showed a hard tissue barrier. The corresponding figure for group II was eight out of 10 teeth. All teeth in groups III and IV had a barrier. The incidence of a continuous barrier increased from group I through group IV, as did the incidence of its location below the level of the original wound surface. The condition of the pulp was related to the presence of bacteria and the continuity of the barrier to the presence of inflammation. There was no bridging in group V.

The results support the theory that a low-grade irritation is responsible for the formation of a hard tissue barrier in exposed pulps.

J Dent Res 66(6):1166-1174, June, 1987

## Introduction.

In 1971, Schröder and Granath described the effects of calcium hydroxide on surgically treated human pulps and noted that the compound caused a multilayered necrosis, followed by subjacent mineralization. They postulated that the lowermost layer, a zone of firm necrosis, generates a low-grade irritation of the underlying tissue sufficient to produce a matrix that mineralizes. The mechanism is obscure, but it is unlikely that calcium ions released from calcium hydroxide would play a decisive role (for review, see Granath, 1982, and Schröder, 1985).

Support for this low-grade irritation theory comes from the claim that isobutyl cyanoacrylate induces hard tissue formation without an obvious zone of firm necrosis acting as an inducer (Berkman *et al.*, 1971). Agreement on this, however, is not complete. Nixon and Hannah (1972) have reported that n-butyl cyanoacrylate failed to produce satisfactory dentin barriers, while, with regard to calcium hydroxide, Holland *et al.* (1982) have speculated on whether calcium or other cations are involved.

Because of an incomplete understanding of the mechanism of barrier formation, we started to look for alternatives to hydroxides for pulpal wound dressings, one of which was cyanoacrylate. Isobutyl cyanoacrylate, a cyanoacrylic ester  $\{CH_2=C(C\equiv N)COOC_4H_9\}$ , is an odorless, colorless, or pale yellow liquid with a boiling point of 82°C at 6 mm Hg additional pressure and a density of 0.990 (The Merck Index, 1976). It polymerizes in the presence of water and is not soluble in water, but is degradable in a biological environment. Ther-

apeutically, it is used in surgery as a tissue adhesive.

The literature offers no explanation as to why pulp tissue might respond with formation of hard tissue to cyanoacrylate that lacks both calcium and hydroxyl ions. However, the following hypothesis has been suggested (Granath, 1982): "The material is apparently biocompatible as such. On degradation in contact with the pulp tissue, some substance(s) is released that either causes a low-grade degeneration in the nearest cellular layer or alters the physical state in the tissue layer which in turn changes the chemical equilibrium locally. In both instances calcium is attracted. Mineralization of newly formed collagenous substance is initiated from the calcified foci."

In this connection, it is interesting to note that hard tissue formation has been found directly against some calcium-hydroxide-containing hard-setting cements in experimentally exposed monkey pulps, *i.e.*, without a visible zone of necrosis in the light microscope (Tronstad, 1974; Heys *et al.*, 1980, 1981; Cox *et al.*, 1982). The mechanism can be assumed to be the same as with pure calcium hydroxide, while a lower pH and a varying release of hydroxyl ions might explain the lack of visible necrosis.

One way to elucidate the mechanism of hard tissue induction following application of calcium hydroxide would be to remove the compound from the surgically treated pulp tissue once an initial caustic effect has been established. This occurs soon after exposure to calcium hydroxide (Schröder and Granath, 1971). Such a treatment would minimize the effect of ionized calcium and would thus be a useful comparison with calcium-free cyanoacrylate.

The aim of this study, therefore, was to elucidate further the morphological appearance of a hard tissue barrier in pulpotomized teeth with calcium hydroxide and cyanoacrylate as wound dressings. Teflon was used as a control substance because it is biologically inert.

## Materials and methods.

*Operative technique.* — Fifty-two mature permanent incisor teeth from 14 monkeys (*Cercopithecus aethiops pygerythrus*) were used for the experiments. The animals were first tranquilized with Ketamine hydrochloride (Ketalar, Parke-Davis Laboratories, Ltd., Johannesburg) and then anesthetized with pentobarbitone sodium (Sagatal, Maybaker, Ltd., Johannesburg). A rubber dam was used to isolate the maxillary teeth, while the mandibular teeth were isolated with cotton rolls. The teeth were mechanically cleaned with a rubber cup containing water-mixed pumice and thereafter washed, together with the rubber dam or the surrounding mucosa, with 0.5% chlorhexidine in 70% ethanol.

The operative procedure was performed with diamond instruments according to the technique of Granath and Hagman (1971). In order to facilitate cavity preparation and cooling during pulpotomy, we removed incisal enamel for about one-third of the crown length. Subsequently, a round and then a cylindrical diamond instrument were used to cut a hole through dentin but without perforating the roof of the pulp chamber. The final cut was made with a cylindrical instrument with

Received for publication September 3, 1986

Accepted for publication December 18, 1986

<sup>4</sup>To whom correspondence and reprint requests should be addressed

TABLE 1

HARD TISSUE BARRIER FORMATION IN 49 PULPOTOMIZED MONKEY INCISORS CAPPED WITH ISOBUTYL CYANOACRYLATE OR CALCIUM HYDROXIDE FOR DIFFERENT TIME PERIODS OR LEFT WITHOUT AN ACTIVE WOUND DRESSING, IN RELATION TO STATE OF PULP AND PRESENCE OF BACTERIA; OBSERVATIONS AFTER 12 WEEKS

Group	No.	Wound Dressing		Hard Tissue Barrier*				State of Pulp**				Bacteria***
		Material	Time	d	c	lws	bws	sl	m	se	ne	
I	9	cyano- acrylate	12 weeks	6	1	7				4(4)		5
II	10	calcium hydroxide	10 min	5	3	4	4		5(3)	1(1)		4
III	10	calcium hydroxide	60 min	7	3	2	8	1		3(3)		3
IV	10	calcium hydroxide	12 weeks	1	9		10					4
V	10	no dressing								4(4)	2(2)	6

\*d = discontinuous barrier, characterized by a layer of bone-like and a subsequent layer of dentin-like tissue; c = continuous barrier, otherwise as in d; lws = at level and bws = below level of original wound surface.

\*\*sl = slight (scattered inflammatory cells), m = moderate and se = severe inflammation (accumulation of inflammatory cells, abscess); ne = necrosis; number of cases with stainable bacteria within parenthesis.

\*\*\*Presence of stainable bacteria in coronal activity or in dentin walls forming the cavity.

smooth sides and diamond particles only on its base and of a diameter that just exceeded the radius of the access cavity. The rotating instrument was gradually lowered into the tooth with circular movements until pulp tissue, surrounded by dentin, was removed to about the level of the largest cross-section of the pulp.

During all steps of the operative procedure, the tooth and cutting instruments were irrigated with physiological saline solution. A high-speed handpiece running at about 100,000 rpm was used, and the cutting was performed intermittently in order to keep the dentin moist and to avoid overheating the pulp. After completing the pulpotomy, we irrigated the wound surface continuously with saline until bleeding ceased. Thereafter,

each of the following procedures was performed in groups of 10 teeth, selected according to a randomized system:

I. Isobutyl cyanoacrylate (Ethicon Bucrylat, Ethicon GmbH, Nordestedt, W. Germany) was placed over the pulps. Thereafter, two or more sterilized Teflon discs, 2 mm in diameter and previously punched from a 0.08-mm-thick Teflon tape (USA standard BS 4375, 1978), were placed over the cyanoacrylate and molded against the surrounding dentin shelf with gentle pressure, by means of a small round instrument placed toward the cavity corner.

II-III. Calcium hydroxide paste (Calasept, Scania Dental AB, Knivsta, Sweden) was placed over the pulps and

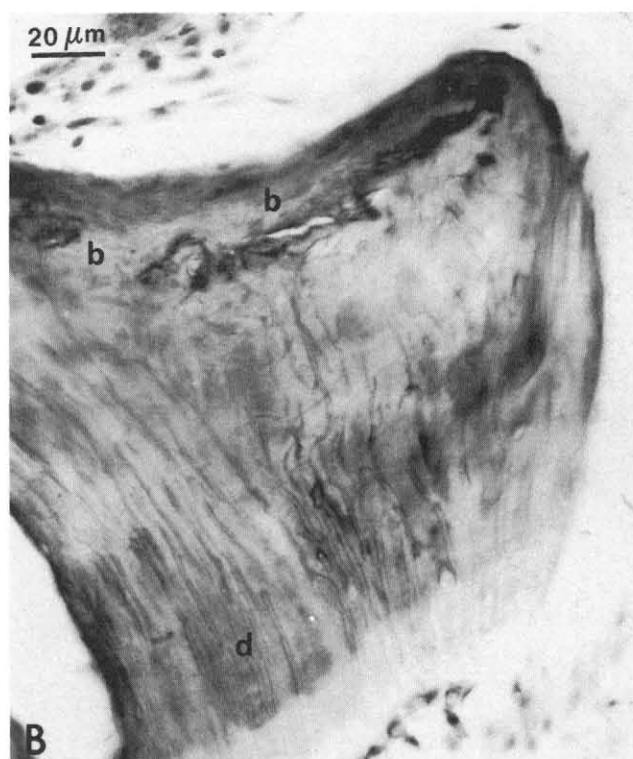
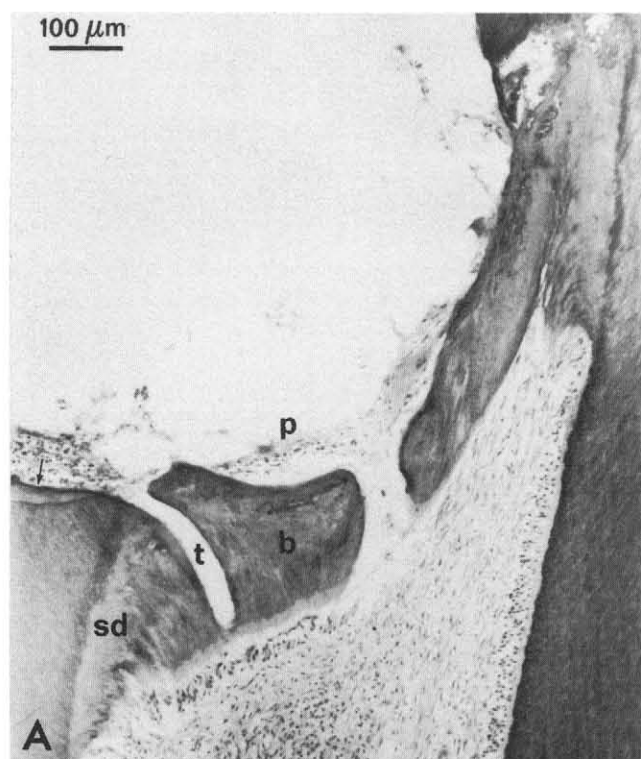


Fig. 1 — (A) Cyanoacrylate. Discontinuous barrier; inflamed pulp tissue (p); "tunnel" (t) between irritation (secondary) dentin (sd) and true barrier (b); hard tissue deposited on dental shelf (arrow).

(B) Layers of bone-like (b) and dentin-like (d) tissue.

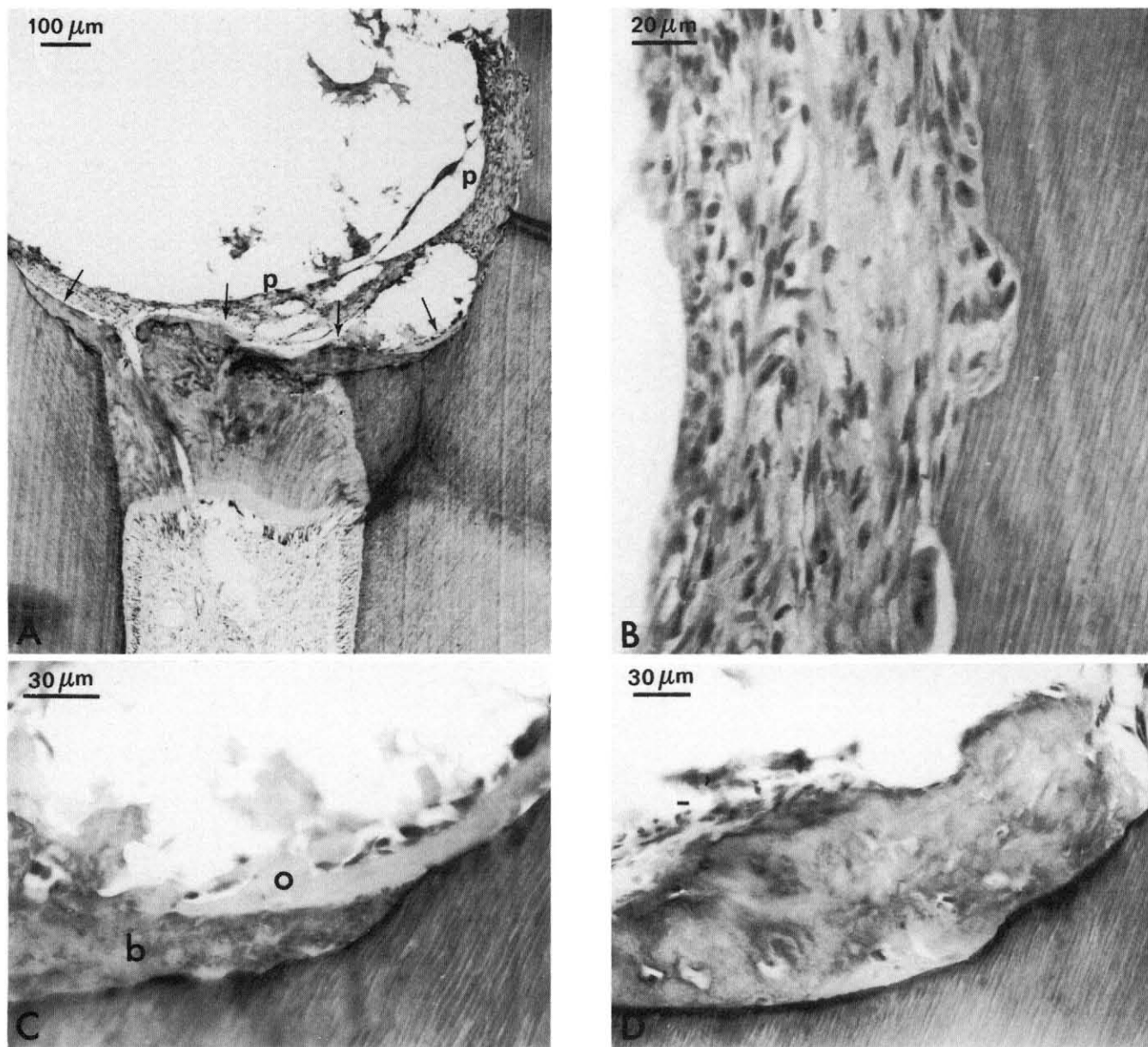


Fig. 2 — (A) Cyanoacrylate. Discontinuous barrier; inflamed tissue (p) in upper right corner adjacent to a resorption area magnified in (B); deposition of bone-like tissue on dentinal shelf and coronal surface of barrier (arrows).

(B) Resorption of dentinal cavity wall.

(C) Deposition of bone-like (b) and osteoid-like (o) tissue on dentinal shelf.

(D) Another section of the same tooth; more extensive apposition of bone-like tissue on dentinal shelf.

molded with light pressure by means of dry cotton pellets for either 10 or 60 minutes. Subsequently, the calcium hydroxide was washed away with a stream of physiological saline, and the pulps were covered with Teflon discs as described above.

- IV. As a positive control, calcium hydroxide paste was placed over the pulps and molded with light pressure by means of dry cotton pellets in such a way that a layer of compressed calcium hydroxide, approximately 2 mm in thickness, remained over the pulps. No Teflon was placed in these specimens.
- V. As a negative control, only Teflon discs were placed over the exposed pulps.

The remaining part of the cavity in each crown of all teeth was filled with a fortified zinc-oxide/eugenol cement (IRM,

L.D. Caulk, Milford, DE). Finally, two teeth were used as a control for determining the effects of the operative procedures. These were extracted immediately after pulpotomy and prepared histologically.

After 12 weeks, the monkeys were killed with an overdose of pentobarbitone sodium (Euthanaze, Centaur Laboratories, Ltd., Johannesburg) and the head and neck retrogradely perfused with physiological saline, followed by 10% neutral buffered formalin (Retief and Austin, 1973). The teeth were removed in tissue blocks, decalcified in 10% EDTA at pH 6.8, and embedded in celloidin-paraffin. The blocks were serially sectioned at 5  $\mu$ m. Every tenth section was stained with hematoxylin and eosin and every ninth or eleventh section with a modified Gram stain according to the method of Brown and Brenn (1931).

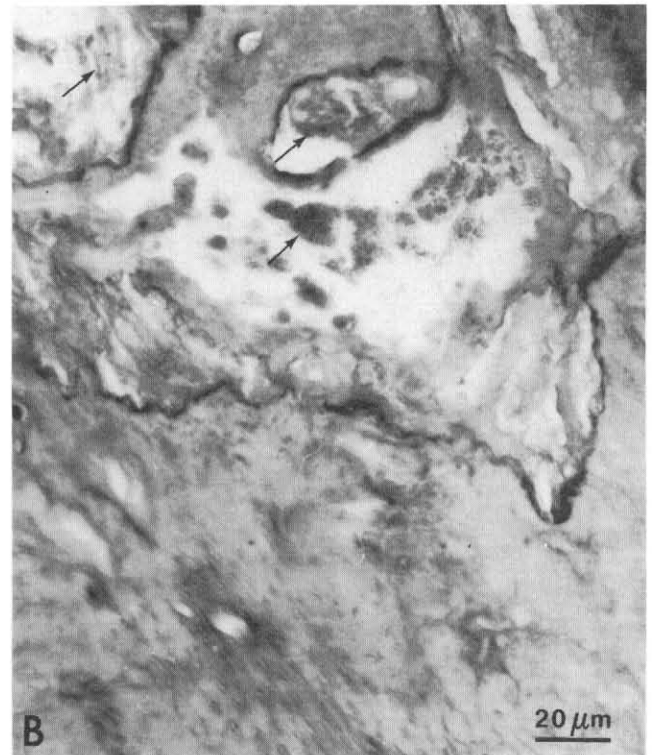
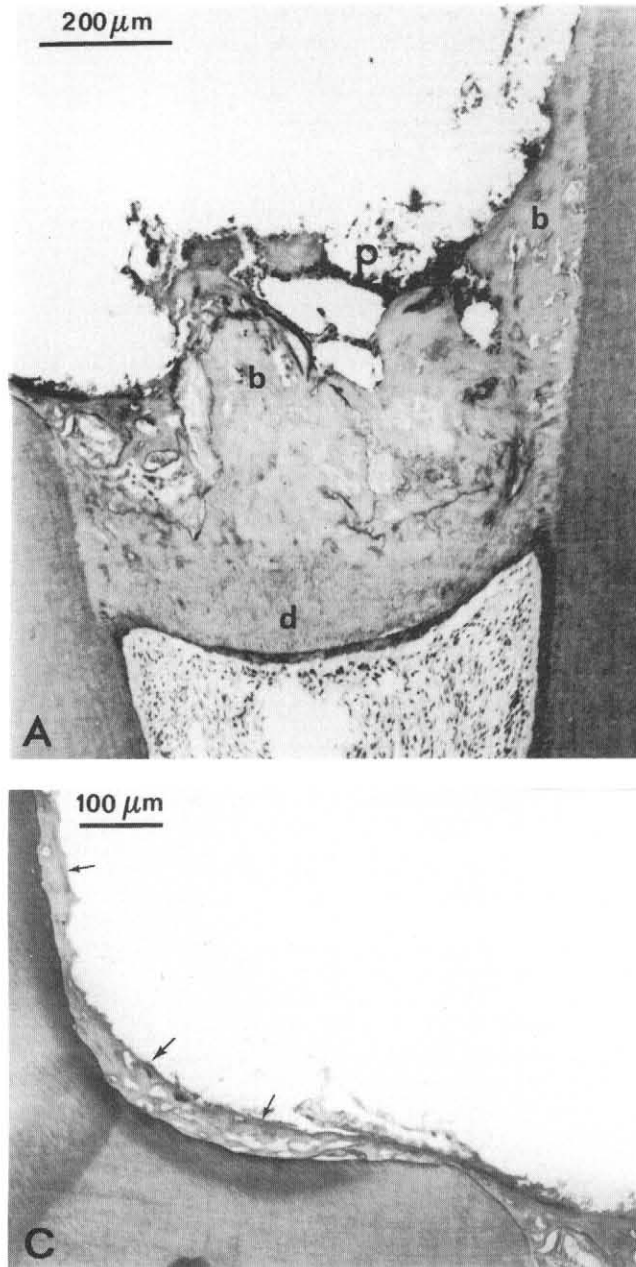


Fig. 3 — (A) Cyanoacrylate. Discontinuous barrier; inflamed pulp tissue (p); bone-like (b) and dentin-like (d) tissue.

(B) Unidentified foreign material, possibly trapped remnants of capping material (arrows).

(C) Deposition of bone-like tissue on the left-hand wall of coronal cavity (arrows).

The remaining 60 incisor teeth of the 14 monkeys were used for study of the effects of other pulp-capping materials not reported here.

**Histological assessment: Hard tissue barrier.** — Hard tissue barriers were classified as continuous or discontinuous. The criteria used to assess barrier formation were derived from the typical appearance of a barrier induced through the effect of calcium hydroxide. Characteristically, such a barrier consists of a layer of bone-like tissue and a subsequent layer of dentin-like tissue (Schröder and Granath, 1971) located at a certain distance (about 1 mm) from the original level of the wound surface. When the barrier was continuous through all sections and no vital tissue was seen above, it was classified as continuous; the barrier was termed discontinuous if these criteria were not met.

**Condition of the pulp.** — Pathologic changes in the pulp were denoted as slight (scattered inflammatory cells), moderate or severe (accumulation of cells, abscess) inflammation, or necrosis. The condition recorded was that seen in the section

with the most advanced degree of inflammation. The changes were noted separately for the pulp proper and for the tissue that had proliferated from the pulp into the coronal cavity.

**Bacteria.** — Specimens were examined for the presence or absence of stainable bacteria either in the coronal cavity or in the dentin forming this cavity.

## Results.

The results are listed in Table 1. Seven of the nine teeth capped with cyanoacrylate (group I; one tooth in this group was lost during preparation) showed formation of a hard tissue barrier (Figs. 1-3). The corresponding numbers for calcium hydroxide applied for 10 minutes (group II) were eight out of 10 teeth (Figs. 4 and 5), for 60 minutes (group III) 10 of 10 (Figs. 6 and 7), and for 12 weeks (group IV) 10 of 10. The incidence of continuous barrier formation increased from group I through group IV, as did the incidence of barrier formation below the original wound surface.

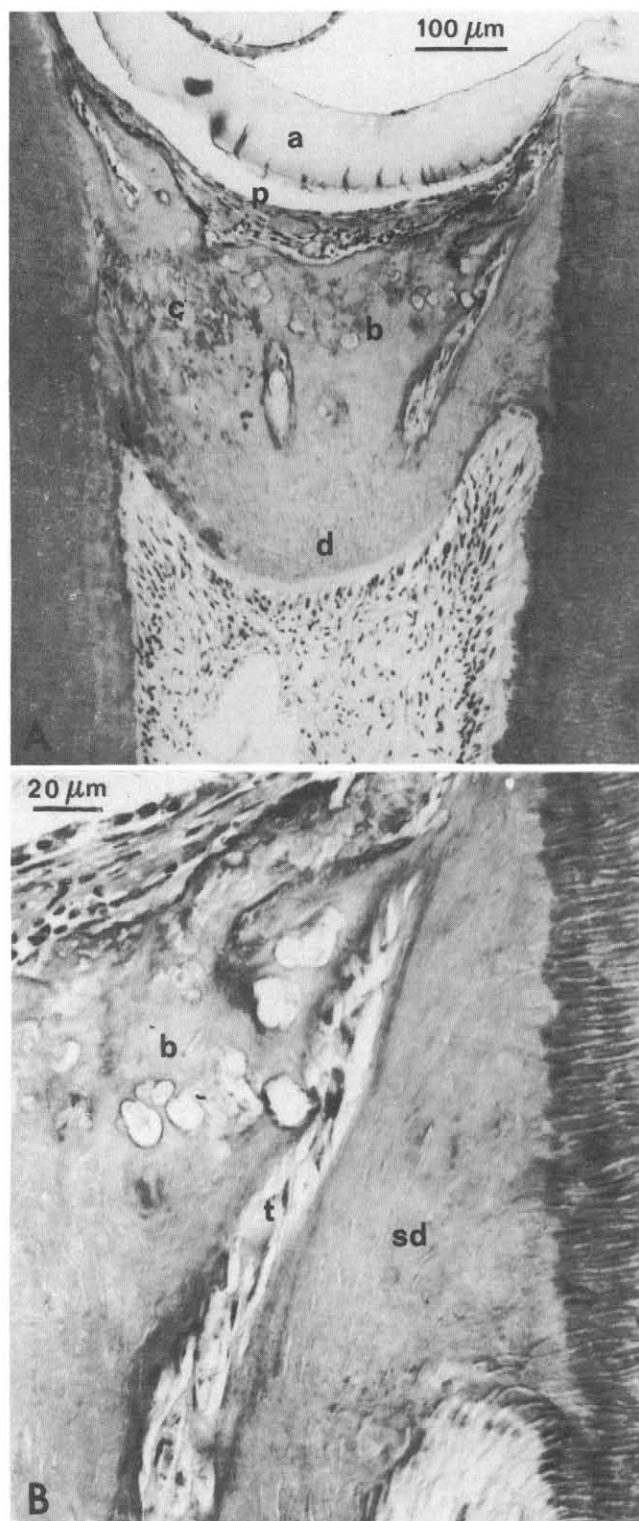


Fig. 4 — (A) Calcium hydroxide applied for 10 minutes. Discontinuous barrier located at the level of the original wound surface; Teflon (a); pulp tissue (p); diffusely calcified tissue (c); bone-like (b) and dentin-like (d) tissue.

(B) "Tunnel" (t) between bone-like tissue (b) and irritation dentin (sd).

A characteristic finding in group V (no dressing) was the apposition of hard tissue on the pulpal walls adjacent to dentinal tubules from the dentinal shelf of the coronal access cavity (Fig. 8). This was also seen in the two teeth from group II in

which formation of a true barrier was not seen. The amount was proportional to the size of the dentinal shelf and consisted mostly of two layers. One layer resembled bone, the other layer resembled dentin (Fig. 9). The pulpal surface in these teeth consisted of a dense, collagen-rich connective tissue with cells arranged longitudinally against the surface of the Teflon discs (Figs. 8 and 9).

In the teeth of groups I-III, with a barrier formed at the level of pulpal amputation, the barrier seemed, in most instances, to be a combination of hard tissue induced by the medicament and apposition of hard tissue on dentinal walls (Figs. 1,2,4, and 6). Discontinuities in the form of so-called "tunnels" (Cox *et al.*, 1985) were often found between the two types of hard tissue (Figs. 1,2, and 4). These tunnels contained pulp tissue with numerous fibroblast-like cells, probably original tissue that had proliferated into the space between the coronal surface of the barrier and the Teflon discs. In five teeth capped with cyanoacrylate, hard tissue was also deposited on the dentinal shelf and the vertical walls of the coronal cavity. In three of these teeth, hard tissue was deposited on the coronal surface of the barrier as well. This hard tissue on the shelf consisted primarily of a bone-like layer and a layer of osteoid-like tissue, surrounded by proliferated pulp tissue (Figs. 1-3). Furthermore, in two of these teeth, there was resorption of cavity walls adjacent to the proliferated and inflamed tissue (Fig. 2). None of the teeth with a barrier located at the level of pulpal amputation contained necrotic tissue between the barrier and the Teflon discs.

The proliferation of pulp tissue into the coronal cavity above the level of the original wound surface was also seen in most of the teeth in which the pulp was covered with Teflon alone (group V). In two of these teeth, hard tissue was deposited to a limited extent on the dentinal shelf (Fig. 8).

In teeth from groups II-IV, in which there was a barrier below the level of the original wound surface, none of the barriers included hard tissue deposited on the dentinal wall in the manner described above (Figs. 5 and 7). In two teeth from group II, such hard tissue was deposited on the dentinal walls below and separate from the barrier. It was found adjacent to the dentinal tubules which, at the site of the dentinal shelf of the coronal cavity, were covered with an amorphous, necrotic-like tissue (Fig. 5).

No dressing material was seen above the hard tissue barrier in any of the teeth. In some sections of one tooth in which the pulp had been capped with cyanoacrylate, however, the coronal, bone-like layer of the hard tissue included spaces that contained unidentified foreign material, possibly remnants of the capping material (Fig. 3).

The association between the presence of stainable bacteria and the status of the pulps is demonstrated in Table 1. In practically all teeth with necrosis or moderate-to-severe pulpal inflammation, bacteria were demonstrated. In Table 2, the relationship between the state of the pulp and presence of a hard tissue barrier is presented for groups I-IV. It can be seen that the pulps of all teeth without a barrier were inflamed. In teeth without inflammation, the proportion of those with a continuous barrier increased from group I through group IV.

The pulps of the two teeth extracted immediately after pulpotomy and hemostasis showed no signs of mechanical trauma or overheating.

## Discussion.

The pulps in the present study responded to all five experimental procedures with formation of hard tissue, though the medicaments and/or irritants used were different.

Thus, in teeth treated with cyanoacrylate and in six teeth treated with calcium hydroxide for 10 or 60 minutes, barriers

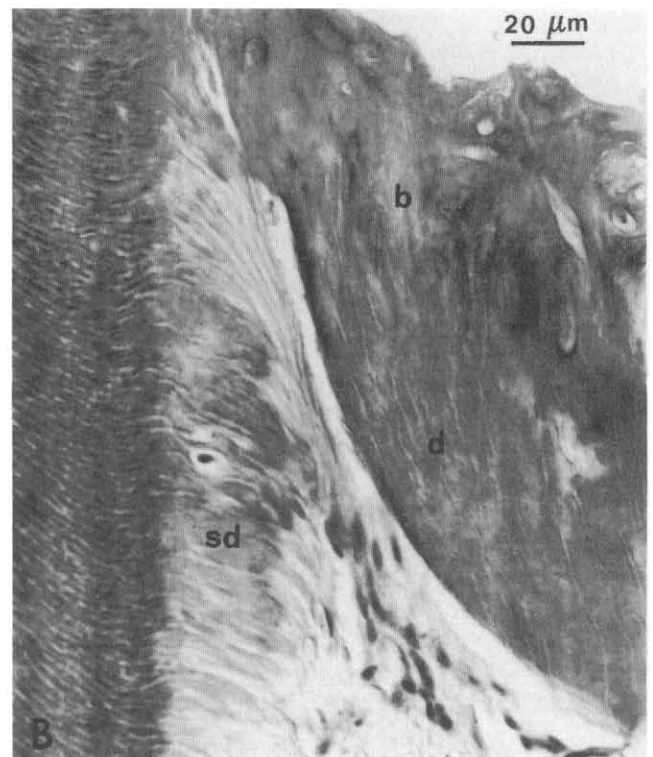
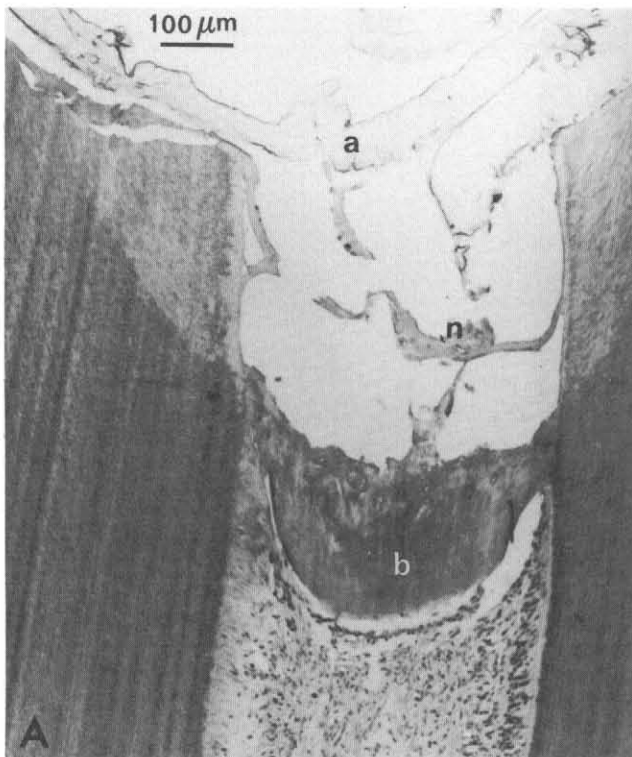



Fig. 5 — (A) Calcium hydroxide applied for 10 minutes. A continuous barrier (b), located about 1.5 mm below the level of the original wound surface; Teflon (a); necrotic tissue (n).

(B) Deposition of irritation dentin (sd) below and separate from the barrier; bone-like (b) and dentin-like (d) tissue.

(C) Necrotic tissue (arrows) on dentinal shelf, covering tubules corresponding to secondary dentin formation.



were formed at the surface of the original pulpal wound. These barriers consisted of hard tissue that formed in response to the medicament that was placed on the surface of the pulp. In addition, hard tissue deposited on the dentinal walls appeared to have been induced by the irritation from the dentinal shelf of the pulpotomy access cavity. Both types of tissue seem to have been formed simultaneously. In some cases, they were in contact with each other, and in others they were separated by "tunnels" containing soft tissue. With respect to the teeth treated with calcium hydroxide, presumably the caustic effect of the medicament was responsible for the formation of the hard tissue barrier at the level of the pulpal wound. It was not strong enough to destroy pulp tissue completely but was a stimulant sufficient to induce hard tissue formation.

Apposition of hard tissue to dentinal walls was a characteristic finding in teeth in which the pulps were covered only with Teflon. The source of irritation may have been the operational trauma together with debris and/or necrotic tissue, which was

seen covering the dentinal shelf in some cases. In these teeth, the pulp had formed a layer of dense, collagen-rich tissue that was in contact with the Teflon. This ability of the pulp to form a fibrous barrier in response to a foreign, biologically inert substance has been demonstrated previously by Granath and Hagman (1971). In two teeth treated with calcium hydroxide for 10 minutes, apposition of hard tissue to dentinal walls was seen below and separate from a continuous barrier. It could have been due to the wide dentinal shelf which was connected with deeper parts of the pulp and eventually the presence of bacteria in the coronal cavity.

The present findings concerning the ability of cyanoacrylate to induce hard tissue corroborate the results reported by Berkman *et al.* (1971). The barriers induced in this study were, however, discontinuous and permitted proliferation of pulp tissue into the coronal cavity. This clearly indicates that cyanoacrylates cannot be regarded as an adequate therapeutic alternative to calcium hydroxide.

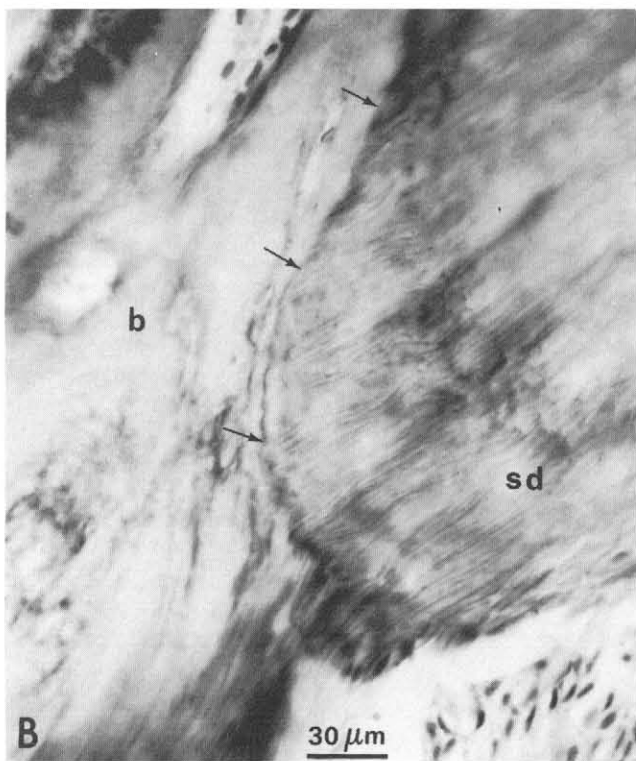
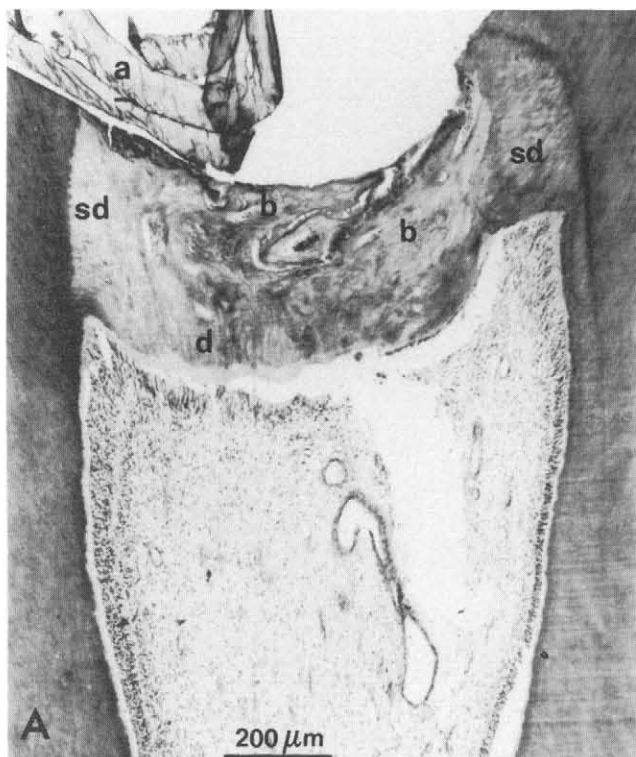


Fig. 6 — (A) Calcium hydroxide applied for 60 minutes. Discontinuous barrier, located at the level of the original wound surface; Teflon (a); irritation dentin (sd); bone-like (b) and dentin-like (d) tissue.

(B) Demarcation line (arrows) between bone-like tissue (b) and irritation dentin (sd).

In a number of cases, proliferation of pulp tissue was followed by the apposition of bone-like tissue on the walls of the coronal cavity. This finding is interesting from the standpoint of hard tissue induction. It has been shown that dentin, treated

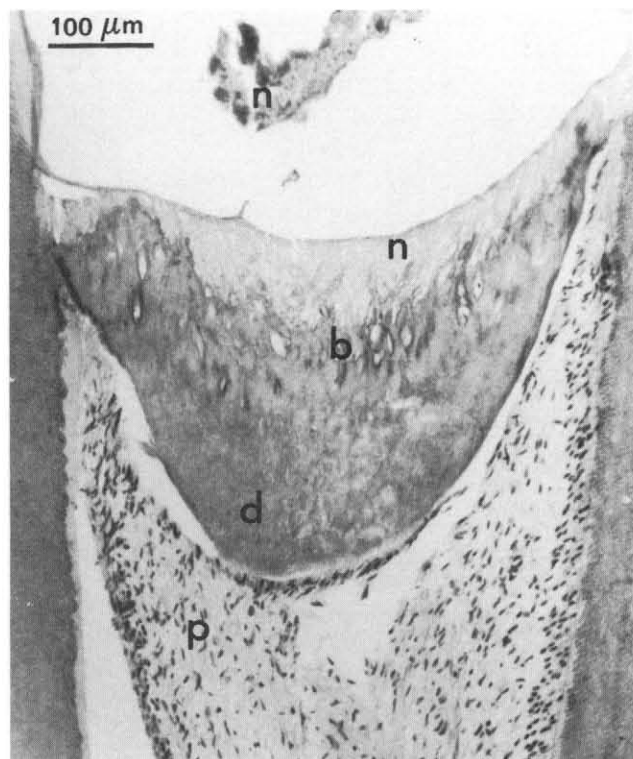

Fig. 7 — Calcium hydroxide applied for 60 minutes. Continuous barrier, located below the level of the original wound surface; layers of necrotic (n), bone-like (b) and dentin-like (d) tissue; inflammation-free pulp (p). This section is also typical of teeth with pulps covered with calcium hydroxide for 12 weeks.

in different ways, possesses a capacity to induce formation of ectopic bone (Urist *et al.*, 1968; Bang, 1973). Therefore, one may speculate that when in contact with vital tissue, non-vital dentin may induce the differentiation of odontoprogenitor cells which results in apposition of bone-like tissue on the dentinal cavity walls. A parallel can be drawn with apposition of hard tissue on the walls of the pulp chamber in re-implanted teeth, after the necrotic pulp has been replaced by ingrowing mesenchymal tissue (Ohman, 1965; Kling *et al.*, 1986).

After treatment with calcium hydroxide, the pulps responded with formation of a hard tissue barrier in all but two teeth, regardless of the treatment duration, *i.e.*, after 10 or 60 minutes, or after 12 weeks of pulpal contact. Most of the barriers were formed below the level of the original wound surface and were typical, with respect to hard tissue layers (Schröder and Granath, 1971). These results show, first, that a short treatment with calcium hydroxide is enough to induce formation of hard tissue, and second, that it is not necessary to place the compound over a pulpal wound for a longer interval in order to induce the formation of a complete hard tissue barrier. This observation supports the finding of Pisanti and Sciaky (1964) that calcium, which is needed for mineralization, is derived from tissue fluid. It is also probable that the beneficial effect of calcium hydroxide, which is left over the exposure site for a longer time, is due to its antibacterial property.

Although a particular inductive effect of calcium ions cannot be excluded, the short treatment experiments, together with those using cyanoacrylate as a wound dressing, support the theory that a low-grade irritation is responsible for the formation of the hard tissue barrier. Such a view is also supported by recent findings that the effects of calcium hydroxide are non-specific and highly pH-dependent (Gordon *et al.*, 1985). Moreover, our results support the concept that any low-grade

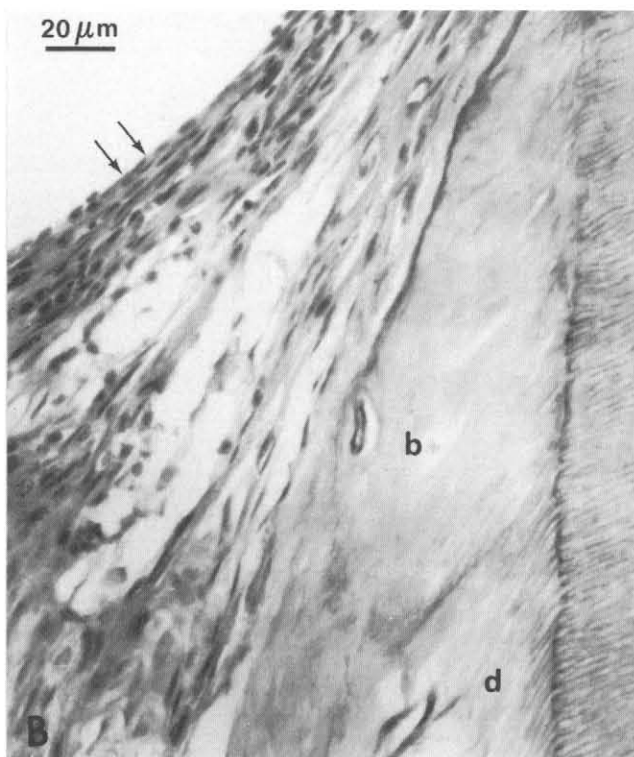
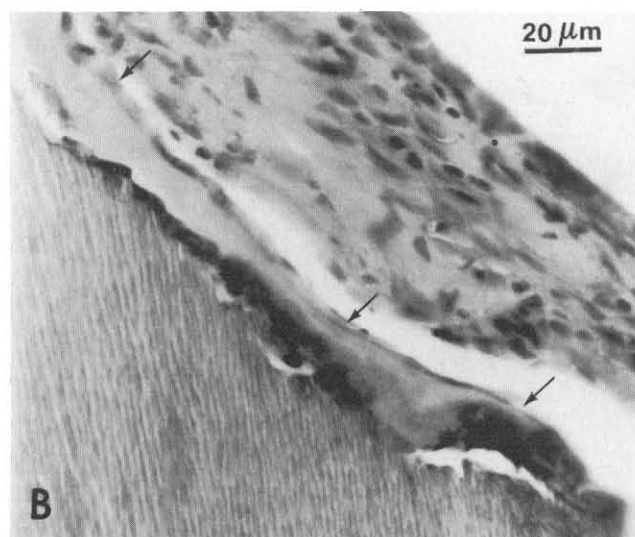
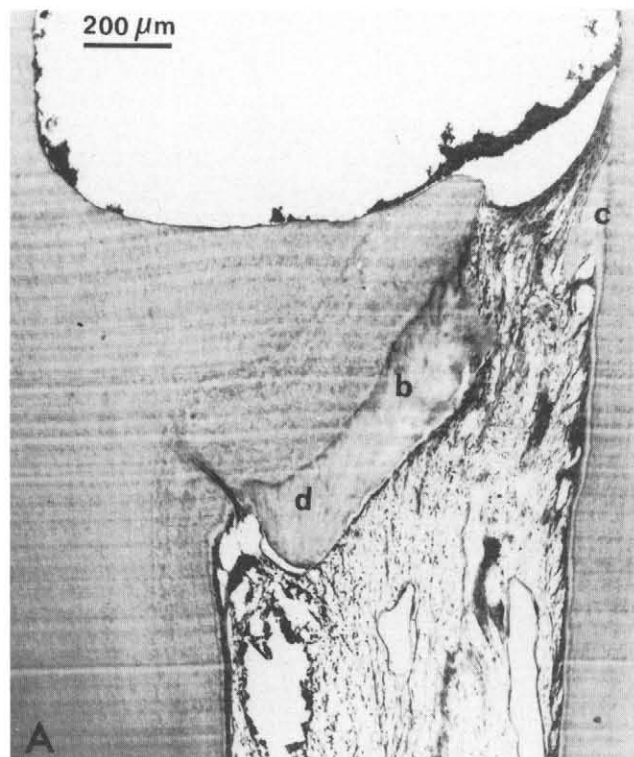
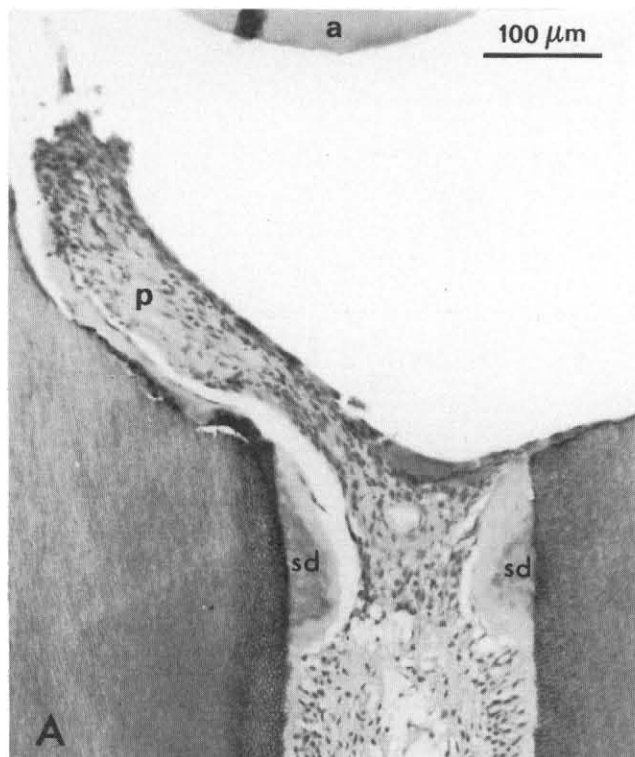


Fig. 8 — (A) Surgical wound covered only with Teflon (a); deposition of irritation dentin (sd); proliferation of collagen-rich pulp tissue (p).  
 (B) Deposition of bone-like tissue (arrows) on dentinal shelf.

Fig. 9 — (A) Calcium hydroxide applied for 10 minutes, peripheral section; no formation of a true barrier; note the relation between size of dentinal shelf and amount of irritation dentin, extensive to the left with bone-like (b) and dentin-like (d) tissue, and minimal to the right (c).

(B) Detail of the right side showing bone-like (b) and dentin-like (d) tissue; dense connective tissue at pulpal surface (arrows).

irritation should stimulate the pulp to form hard tissue (Schröder, 1985). Results with calcium hydroxide as an ectopic bone inducer have not been convincing (Rønning and Koski, 1966; Rasmussen and Mjör, 1971). As far as we know, cyanoacrylates do not induce ectopic bone when used as adhesives. This may imply that, in the absence of epithelium, the response to different, non-specific irritants — namely, formation of hard tissue — should be considered to be an inherent, defensive, and probably stereotypic reaction of the pulp. Veis (1985) proposed that a necrotic layer such as that produced by calcium hydroxide presents a surface to which the pulp cells attach, polarize, and then begin to express their odontoblastic potential. Schröder and Granath (1971) observed new collagen after only four days. With regard to mineralization, it is interesting

to note that Schröder and Sundström (1974) found matrix vesicles in the area of new collagen one week after application of

TABLE 2

CROSS-TABULATION OF HARD TISSUE BARRIER FORMATION AND PULP STATE IN 39 PULPOTOMIZED MONKEY INCISORS CAPPED WITH ISOBUTYL CYANOACRYLATE OR CALCIUM HYDROXIDE FOR DIFFERENT PERIODS OF TIME: OBSERVATIONS AFTER 12 WEEKS

Pulpal Inflammation	Hard Tissue Barrier								
	Group I n = 9			Groups II + III n = 20			Group IV n = 10		
	none	d	c	none	d	c	none	d	c
none	4	1		4	6		1	9*	
sl				1**					
m				1	4***				
sc	2	2		1	3				

\*Six cases, \*\*one case, and \*\*\*two cases with no stainable bacteria. For definitions see Table 1.

calcium hydroxide on the exposed pulp. Such vesicles are thought to play a role in the initial calcification process of dentin and other mineralizing tissues (Ten Cate and Torneck, 1982). The type of tissue to be formed may depend on the degree of irritation and on the genetic make-up of progenitor cells rather than on the irritant itself. Hence, Cvek and Sundström (1974) found the apical closure of immature roots of non-vital permanent incisors treated with calcium hydroxide to consist of a bone-like layer followed by cementum-like tissue.

In the present study, inflammatory changes in pulps were clearly related to the presence of bacteria in the coronal cavity, and the continuity of the barriers was in turn related to the condition of the pulp. This emphasizes the importance of bacteria in pulpal (Cox *et al.*, 1985) as well as periapical (Fabricius *et al.*, 1982) inflammatory reactions. The role in inflammatory pulp disease is currently receiving a great deal of attention in the dental literature.

## Acknowledgments.

The authors wish to express their sincere gratitude to Drs. Henry Trowbridge and Edward Sweeney, University of Pennsylvania School of Dental Medicine, Philadelphia, for their constructive comments in the preparation of this manuscript.

## REFERENCES

- BANG, G. (1973): Induction of Heterotopic Bone Formation by Demineralized Dentine: An Experimental Model in Guinea Pigs. *Scand J Dent Res* 81:240-250.
- BERKMAN, M.D.; CUCOLO, F.A.; LEVIN, M.P.; and BRUNELLE, L.J. (1971): Pulpal Response to Isobutyl Cyanoacrylate in Human Teeth. *J Am Dent Assoc* 83:140-145.
- BROWN, J. H. and BRENN, L.A. (1931): A Method for the Differential Staining of Gram-positive and Gram-negative Bacteria in Tissue Sections. *Bull Johns Hopkins Hosp* 48:69-73.
- COX, C.F.; BERGENHOLTZ, G.; FITZGERALD, M.; HEYS, D.R.; HEYS, R.J.; AVERY, J.K.; and BAKER, J.A. (1982): Capping of the Dental Pulp Mechanically Exposed to the Oral Microflora—A 5-week Observation of Wound Healing in the Monkey. *J Oral Pathol* 11:327-339.
- COX, C.F.; BERGENHOLTZ, G.; HEYS, D.R.; SYED, S.A.; FITZGERALD, M.; and HEYS, R.J. (1985): Pulp Capping of Dental Pulp Mechanically Exposed to Oral Microflora: A 1-2-year Ob-
- servation of Wound Healing in the Monkey. *J Oral Pathol* 14:156-168.
- CVEK, M. and SUNDSTRÖM, B. (1974): Treatment of Non-vital Permanent Incisors with Calcium Hydroxide. V. Histologic Appearance of Roentgenographically Demonstrable Apical Closure of Immature Roots. *Odont Revy* 25:379-391.
- FABRICIUS, L.; DAHLÉN, G.; HOLM, S.E.; and MÖLLER, Å.J.R. (1982): Influence of Combinations of Oral Bacteria on Periapical Tissues of Monkeys. *Scand J Dent Res* 90:200-206.
- GORDON, T.M.; RANLY, D.M.; and BOYAN, B.D. (1985): The Effects of Calcium Hydroxide on Bovine Pulp Tissue: Variations in pH and Calcium Concentration. *J Endodont* 11:156-160.
- GRANATH, L. (1982): Pulp Capping Materials. In: **Biocompatibility of Dental Materials**, Vol. II, D.C. Smith and D.F. Williams, Eds., Boca Raton, FL: C.R.C. Press, Inc., pp. 253-267.
- GRANATH, L.-E. and HAGMAN, G. (1971): Experimental Pulpotomy in Human Bicuspid with Reference to Cutting Technique. *Acta Odontol Scand* 29:155-163.
- HEYS, D.R.; COX, C.F.; HEYS, R.J.; and AVERY, J.K. (1981): Histological Considerations of Direct Pulp-capping Agents. *J Dent Res* 60:1371-1379.
- HEYS, D.R.; HEYS, R.J.; COX, C.F.; and AVERY, J.K. (1980): The Response of Four Calcium Hydroxides on Monkey Pulps. *J Oral Pathol* 9:372-379.
- HOLLAND, R.; PINHEIRO, C.E.; DE MELLO, W.; NERY, M.J.; and DE SOUZA, V. (1982): Histochemical Analysis of the Dog's Dental Pulp after Pulp Capping with Calcium, Barium, and Strontium Hydroxides. *J Endodont* 8:444-447.
- KLING, M.; CVEK, M.; and MEJÄRE, I. (1986): Rate and Predictability of Pulp Revascularization in Therapeutically Reimplanted Permanent Incisors. *Endodont Dent Traumatol* 2:83-89.
- NIXON, G.S. and HANNAH, C. M. (1972): N-butyl Cyanoacrylate as a Pulp Capping Agent. *Br Dent J* 133:14-18.
- ÖHMAN, A. (1965): Healing and Sensitivity to Pain in Young Replanted Human Teeth. An Experimental, Clinical and Histological Study. *Odont Tidskr* 73:165-228.
- PISANTI, S. and SCIACKY, I. (1964): Origin of Calcium in the Repair Wall after Pulp Exposure in the Dog. *J Dent Res* 43:641-644.
- RASMUSSEN, P. and MJÖR, I.A. (1971): Calcium Hydroxide as an Ectopic Bone Inductor in Rats. *Scand J Dent Res* 79:24-30.
- RETIEF, D.H. and AUSTIN, J.C. (1973): The Vervet Monkey (*Cercopithecus aethiops*) as an Experimental Model for Pulpal Studies. *J Dent Assoc S Afr* 28:98-103.
- RÖNNING, O. and KOSKI, K. (1966): The Fate of Anorganic Implants in the Subcutaneous Tissue of the Rat. *Plast Reconstr Surg* 37:121-124.
- SCHRÖDER, U. (1985): Effects of Calcium Hydroxide-containing Pulp-capping Agents on Cell Migration, Proliferation, and Differentiation. *J Dent Res* 64 (Sp. Iss.): 541-548.
- SCHRÖDER, U. and GRANATH, L.-E. (1971): Early Reaction of Intact Human Teeth to Calcium Hydroxide Following Experimental Pulpotomy and Its Significance to the Development of Hard Tissue Barrier. *Odont Revy* 22:379-396.
- SCHRÖDER, U. and SUNDSTRÖM, B. (1974): Transmission Electron Microscopy of Tissue Changes Following Experimental Pulpotomy of Intact Human Teeth and Capping with Calcium Hydroxide. *Odont Revy* 25:57-67.
- TEN CATE, A.R. and TORNECK, C.D. (1982): The Dentin-Pulp Complex: Development, Structure, and Repair. In: **Biocompatibility of Dental Materials**, Vol. I, D.C. Smith and D.F. Williams, Eds., Boca Raton, FL: C.R.C. Press, Inc., pp. 85-86.
- TRONSTAD, L. (1974): Reaction of the Exposed Pulp to Dycal Treatment. *Oral Surg* 38:945-953.
- URIST, M.R.; DOWELL, T.A.; HAY, P.H.; and STRATES, B.S. (1968): Inductive Substrates for Bone Formation. *Clin Orthop* 59:59-96.
- VEIS, A. (1985): The Role of Dental Pulp—Thoughts on the Session on Pulp Repair Processes. *J Dent Res* 64(Sp. Iss.): 552-554.