

REFERENCES

- JACOBSON, A. (1967) The Bantu Dentition. Unpublished Ph.D. thesis. University of the Witwatersrand, Johannesburg. pp 126-127.
- REDMAN, R. S., SHAPIRO, B. L., and GORLIN, R. J. (1965) Measurement of normal and reportedly malformed palatal vaults III. Down's Syndrome. *J. Pediat.* 67: 162-165.
- REDMAN, R. S., SHAPIRO, B. L., and GORLIN, R. J. (1966) Measurement of normal and reportedly malformed palatal vaults II. Normal juvenile measurements. *J. Dent. Res.* 45:266-269.
- SCHAMROTH, L., and SEGAL, F. An Introduction to Congenital Heart Disease. 1st Ed. p. 1. Blackwell Scientific Publications, Oxford.
- SHAPIRO, B. L., REDMAN, R. S., and GORLIN, R. J. (1963) Measurement of normal and reportedly malformed palatal vaults I: normal adult measurements. *J. dent. Res.* 42:1039.
- SHAPIRO, B. L. *et al* (1967) The palate and Down's syndrome. *New Eng. J. Med.* 276:1460-1463.

SPONTANEOUS FIBROADENOMA IN AN ALBINO RAT

S. M. SMIRIN

*Final Year Dental Student, Joint Dental Research Unit of the University of the Witwatersrand and South African Medical Research Council*

SPONTANEOUS tumours in laboratory animals frequently have been described. Those which occur subcutaneously include the fibrosarcoma, myofibrosarcoma, liposarcoma, sarcoma, adenocarcinoma and fibroadenoma (Stewart *et al* 1959).

During the past three years spontaneous subcutaneous tumours often have developed in Wistar strain albino rats in the animal colony of the Dental Research Unit; they comprise one fibrosarcoma and a number of fibroadenomas. This article is a description of the most recently found tumour: a fibroadenoma.

MATERIALS AND METHODS

An adult female albino rat developed a subcutaneous nodule in the right groin region along the nipple line. The mass was left *in situ* for several months and allowed to develop until it comprised about one-third of the size of the animal (Fig. 1). At this stage the tumour mass was firm with a discrete edge, mobile and unattached to the overlying healthy skin. No other tumours were evident and the rat's condition appeared good.

Under neurolept anaesthesia ("Hypnorm"—Philips Duphar—0.2ml/100gm body weight) the tumour was exposed *via* a paramedian abdominal incision. It

was demarcated by blunt dissection and found to be contained entirely subcutaneously with no apparent evidence of secondary metastatic spread (Fig. 2). It was easily elevated and enucleated after tying off a single small arterial vessel arising from the femoral artery. Excess skin was excised and the wound closed with silk sutures (Fig. 3). The animal was placed in a well-aired cage and given routine laboratory rations. Recovery was uneventful and after three months there has been no obvious recurrence of the tumour.

RESULTS

The tumour specimen was a spherical mass with a diameter of 9.0 cm. (Fig. 4) and the following weight figures were obtained:

Preoperative weight of rat—380 gms.

Resected tumour weight—162 gms.

The tumour therefore constituted 43 per cent of the animal's total preoperative weight.

Macroscopically the tumour appeared pink in colour, was well circumscribed with a thick capsule, and appeared lobulated.

Cryostat histological sections revealed a fibroadenoma predominantly of the pericanalicular type. The diagnosis was confirmed by examination of paraffin-em-



FIG. 1.—Preoperative appearance of rat and tumour.



FIG. 2.—Tumour exposed showing subcutaneous position.

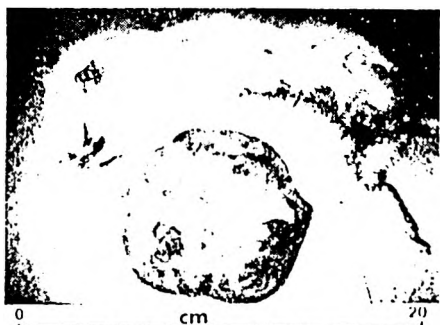

FIG. 3.—Postoperative appearance of rat and tumour.




FIG. 4.—Macroscopic appearance of tumour.

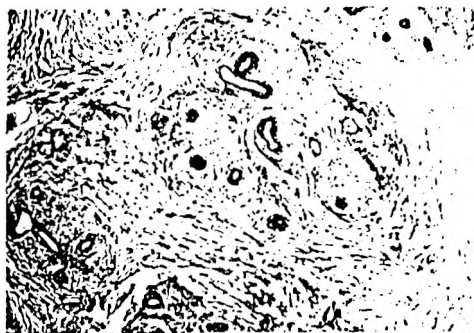

FIG. 5.—Low power view of histological section of tumour showing fibrous tissue whorls enclosing ducts and acini ( $\times 64$ ).

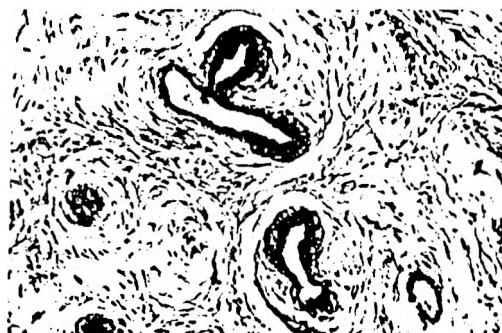

FIG. 6.—High power view of tumour showing ducts and acini with columnar and cuboidal cells ( $\times 200$ ).

bedded sections (Fig. 5). The histological sections revealed a capsule of dense collagen fibre bundles dividing the tumour into numerous lobules. It was relatively avascular with no evidence of necrosis.

Both epithelial and stromal elements participated in the neoplasm, the glandular elements of which consisted of small branching duct-like structures lined by a single layer of cuboidal or low columnar cells. The nuclei were basally situated, stained hyperchromatically and were round and distinct (Fig. 6). No evidence of pleomorphism or mitoses was found.

The stromal element of connective tissues was largely collagen fibre bundles with spindle-shaped fibroblasts arranged in whorls enclosing the glandular elements.

#### DISCUSSION

The fibroadenoma is the most commonly occurring benign neoplasm of the mammary gland of the rat. (Stewart *et al* 1959). Tumours of this type were described by Loeb in 1902. In 1929 Emge studied a mammary fibroadenoma that arose in a Wistar rat, and described its morphologic characteristics and biological behaviour. This appears identical to the tumour described in this study.

The formation of a fibroadenoma is believed to begin as an infiltration of subcutaneous adipose tissue by ductlike epithelial tissue and connective tissue. The adipose tissue is slowly replaced by infiltrating and proliferating glandular tissue. Regressive changes occur in some parts of the tumour leaving hyaline areas where there is atrophy of glandular tissue with subsequent replacement of these areas by collagenous fibrous tissue bundles. As a result of infiltration of glandular tissue and subsequent proliferation, hyalinisation and atrophy, the tumour becomes characterized by ducts surrounded by rings of connective tissue.

Two forms of the fibroadenoma are distinguished histologically: the pericanalicular and the intracanalicular (Cappell 1964). This division, however, is artificial; many tumours show both types of structure in different areas. In the former the epithelial arrangement roughly cor-

responds to that in the normal breast lobule with an investment of loose fibrous connective tissue. In the latter there are numerous curved and branching clefts lined by epithelium but indented by projections of fibrocellular tissue into the lumina of the ducts and acini. The pericanalicular type predominated in the tumour described.

The growth of the tumour is slow but steadily progressive and may reach enormous size: its weight actually can exceed that of the animal. If left unresected such cases are fatal after about one year.

The cause of the tumour is still unknown, but it is sensitive to oestrogens (Murphy 1938). In his extensive study in albino rats that author was unable to induce a fibroadenoma by means of oestrogens.

#### SUMMARY

A number of spontaneously occurring subcutaneous tumours have been observed in the rat colony of the Dental Research Unit. The macroscopic and microscopic appearance of the most recent tumour, a fibroadenoma, is described.

#### ACKNOWLEDGMENTS

The author wishes to thank Professor M. Shear for the histological diagnosis; Professor C. J. Dreyer for providing facilities for this study; and Dr. D. H. Retief and Dr. P. Cleaton-Jones for help with the preparation of the manuscript.

#### REFERENCES

- CAPPELL, D. F. (1964) *Muir's Textbook of Pathology*, 8th ed. pp 767-769. Edward Arnold Ltd., London.
- STEWART, F. W. (1950) *Atlas of Tumour Pathology*. Section IX—Facicle 34. *Tumours of the Breast*. pp 105-107. Armed Forces Institute of Pathology, Washington D.C.
- STEWART, H. L. *et al* (1959) *Atlas of Tumour Pathology*. Section XII—Facicle 40. *Transplantable and Transmissible Tumours of Animals* pp 57-76, 238-270. Armed Forces Institute of Pathology, Washington D.C.
- MURPHY, K. M., EMGE, L. A. (1938) The influence of long continued injections of oestrogens on mammary tissue. *Am. J. Obst. and Gynec.* 36:750-768 (Cited by Stewart *et al* 1959).
- LOEB, L., FLEISHER, M. S. (1916) Transplantation of benign tumours. *J. Cancer Research*. 1:427-459 (Cited by Stewart *et al* 1959).