

https://dspace.org/

Obstetric rectal buttonhole tear and a successful threelayer repair A case report

Nnabuike Ngene

https://hdl.handle.net/10539/39165
SCOPUS

Downloaded from a DSpace repository. https://dspace.org/

Case Reports in Women's Health 37 (2023) e00491

Contents lists available at ScienceDirect

Case Reports in Women's Health

journal homepage: www.elsevier.com/locate/crwh

Obstetric rectal buttonhole tear and a successful three-layer repair: A case report

Nnabuike Chibuoke Ngene [a,b,*]

[a] Department of Obstetrics and Gynecology, Leratong Hospital, Krugersdorp, Gauteng Province, South Africa
[b] Department of Obstetrics and Gynaecology, School of Clinical Medicine, Faculty of Health Sciences, University of the Witwatersrand, Johannesburg, South Africa

ARTICLE INFO

Keywords:
Anal sphincter
Obstetric anal sphincteric injury
Rectal buttonhole tear
Rectal mucosa
Third-degree perineal tear
Vagino-rectal fascia

ABSTRACT

An obstetric rectal buttonhole tear (ORBT) is a rare obstetric complication with only 21 cases reported in the literature. The choice of two- or three-layer repair of ORBT is controversial. In this case, the author describes (with high-quality images) an ORBT repaired in three layers in order to provide clinical lessons to healthcare professionals involved in obstetrical care. The patient was a 26-year-old pregnant woman with a previous vertex delivery and 4 previous first-trimester miscarriages. In the index pregnancy, she had a spontaneous vertex vaginal birth of a 3095 g male baby at 39 weeks of gestation. During childbirth, she sustained an ORBT and a third-degree perineal tear involving <50% of the external anal sphincter. The ORBT was repaired in three layers using continuous 2–0 Vicryl to the rectal mucosa, and interrupted polydioxanone (PDS) 3–0 to the adjoining vagino-rectal fascia. Subsequently, the external anal sphincter was repaired end-to-end with interrupted PDS 3–0. Thereafter, the vagina was repaired with continuous Vicryl 2–0. The wound healed with no complications over the 12 weeks of postnatal clinic visits. A three-layer repair is arguably preferable given that closure of the fascia between the rectal and vaginal mucosae (vagino-rectal fascia) may improve the tensile strength at the injury site. However, a two-layer repair may be undertaken in rare cases where the vagino-rectal fascia is not identifiable.

1. Introduction

Obstetric rectal buttonhole tear (ORBT) is a vaginal birth trauma that may not be readily identified at the time of the injury without a high index of suspicion and rectal examination after childbirth. It is rare: it complicates one per 7310 vaginal births, and only 21 cases have been reported in the literature, with a limited number of them occurring during a spontaneous vertex vaginal birth (in comparison with instrumental/operative vaginal birth) [1–4]. The tear involves the vaginal epithelium with an extension into the rectal mucosa. It may be isolated, without injury to the anal sphincter, but very rarely occurs concurrently with obstetric anal sphincteric injury (OASIS) [1]. The occurrence of ORBT with intact perineal skin increases the risk of missing identification of the injury immediately after childbirth.

There are mixed practices in the method of repairing ORBT among the limited number of cases reported in the literature. For instance, some clinicians use two-layer rather than three-layer repair [1–3]. The present case report describes a successful three-layer repair of ORBT following spontaneous vertex vaginal birth.

2. Case Presentation

The patient was a 26-year-old pregnant woman with a previous spontaneous vertex vaginal birth of a normal 2300 g male newborn at term, and 4 previous first-trimester miscarriages. The patient booked for antenatal care in a district hospital at 29 weeks of gestation and was successfully treated for vaginal discharge syndrome using ceftriaxone, metronidazole and azithromycin [5]. Her body mass index at booking was 20.7 kg/m^2. She had smoked four cigarettes per day throughout the pregnancy. At 39 weeks of gestation, she presented to the same district hospital in labour and had a spontaneous vertex vaginal birth of a normal male fetus weighing 3095 g with Apgar scores of 9 and 10 at one and five minutes respectively. The childbirth was not difficult, and neither episiotomy nor instrumental delivery was used. She sustained a longitudinal luminal vaginal tear and an external anal sphincteric injury which resulted in vaginal bleeding. A tampon was placed into the vagina to tamponade the bleeding before transfer to an obstetrician-led unit in a regional hospital for repair of the injury.

On arrival at the hospital, the patient confirmed that she had no

* Corresponding author: Department of Obstetrics and Gynaecology, Leratong Hospital, Krugersdorp, Gauteng Province, South Africa.
E-mail address: ngenenc@gmail.com.

https://doi.org/10.1016/j.crwh.2023.e00491
Received 16 February 2023; Received in revised form 25 February 2023; Accepted 27 February 2023
Available online 5 March 2023
2214-9112/© 2023 The Author. Published by Elsevier B.V. This is an open access article under the CC BY-NC-ND license (http://creativecommons.org/licenses/by-nc-nd/4.0/).

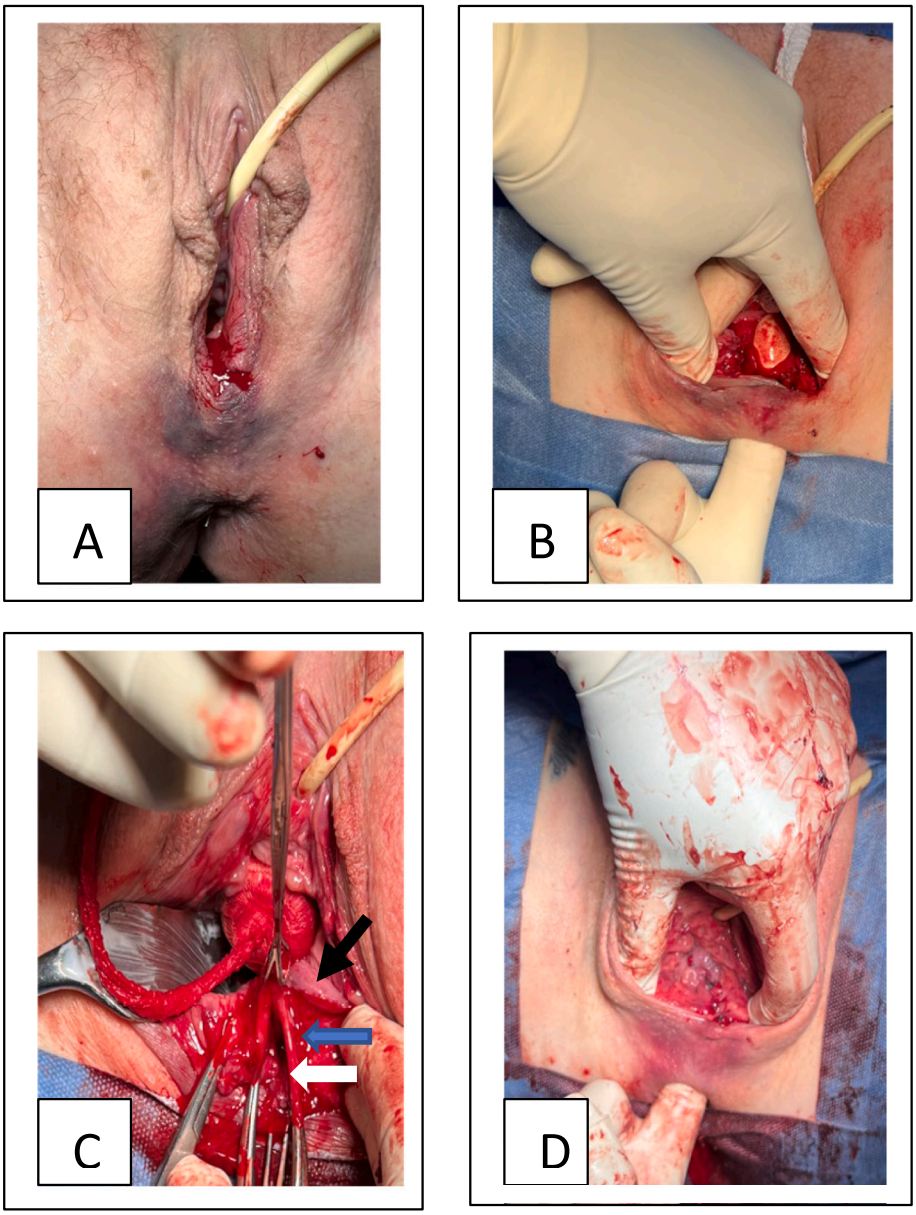

Fig. 1. Vaginal bleeding after childbirth suggestive of obstetric injury (A); obstetric rectal buttonhole tear without laceration of perineal skin (B); vaginal mucosa (black arrow), vagino-rectal septum (blue arrow), and rectal mucosa (white arrow) (C); and perineum after the repair (D). (For interpretation of the references to colour in this figure legend, the reader is referred to the web version of this article.)

personal nor family history of urogenital disorder or any connective tissue disease. She had minimal vaginal bleeding and was haemodynamically stable with a blood pressure of 124/67 mmHg, a pulse rate of 76 beats/min, and a haemoglobin concentration of 12.5 g/dl. Following physical examination, a diagnosis was made of a third-degree perineal tear involving <50% of the external anal sphincter (grade 3a) and a rectal button hole tear of 5 cm in length (3 cm proximal to the anal verge). There was no tear in the perineal skin (Fig. 1), and the rectum was empty. Consent was obtained from the patient, and she had a surgical repair of the injury in the operating room by a specialist obstetrician and gynaecologist. The surgical repair was done approximately 7 h 30 min after childbirth, and the tissues were viable. The rectal buttonhole tear was repaired in three layers using continuous 2–0 Vicryl to the rectal mucosa, and interrupted polydioxanone (PDS) 3–0 to the adjoining vagino-rectal fascia. Subsequently, the external anal sphincter was repaired end-to-end with PDS 3–0. Thereafter, the vagina was repaired with continuous Vicryl 2–0. A vaginal tampon was placed inside the vagina for six hours to tamponade bleeding. Oral co-amoxiclav for a week, lactulose for 10 days, and paracetamol for three days were prescribed postoperatively. She was subsequently counselled to have a sitz bath at least twice daily, and provided with advice to avoid constipation. The patient had no faecal incontinence after the surgery, and she was found to have fully recovered from the repair at the 6- and 12-week postnatal clinic visits.

3. Discussion

In the patient described, a three-layer repair was performed. During a primary three-layer repair of ORBT, closure of the fascial layer between the rectal and vaginal mucosae improves tensile strength at the injury site. This middle layer may maintain tissue apposition if there is a breakdown of either of the other two layers (vaginal or anal mucosa). In contrast, a two-layer primary repair involves the repair of the vaginal and rectal mucosae, and not the middle layer of tissue (vagino-rectal

facia); it is therefore quick and saves sutures. In 2021, Roper et al. recommended three-layer repair of rectal buttonhole tears [1]. In correspondence to the editor about Roper's publication, Habek and Luetić described the successful use of two-layer repair in four cases [3]. More recently, Tunney et al. reported successful three-layer repair in two cases [2].

Following the primary repair of ORBT, the complications associated with the injury are wound breakdown and development of rectovaginal fistula, and abnormal healing such as stenosis including acquired gynaetresia. In undiagnosed cases, ORBT manifests as a rectovaginal fistula with consequential health and socioeconomic consequences such as difficulty with social and sexual relationships. Therefore, clinicians and patients should be aware of these complications and take measures to prevent traumatic vaginal birth, which is a risk factor for ORBT; and to identify and repair the injury if it occurs. Women undergoing vaginal birth should be counselled about the possibility of sustaining perineal tears including ORBT.

The common risk factors for obstetric perineal injury are increasing maternal age, maternal diabetes, Asian ethnicity, primiparity, vaginal delivery after caesarean section, prolonged second stage of labour, midline episiotomy, instrumental delivery, fetal weight $>$ 4000 g, induction and augmentation of labour [6–9]. However, Groutz et al. showed, using multivariate logistic regression analysis, that primiparity, instrumental delivery, and fetal weight $>$ 4000 g were the only significant risk factors [10]. In another study, cardiovascular disease, as well as a previous caesarean birth and decreasing parity were the identified risk factors, while black race and tobacco use decreased the risk [11]. The patient is Caucasian and did not have any of the common risk factors for obstetric perineal injury. Therefore, the occurrence of ORBT and OASIS in the patient is difficult to explain. To prevent and detect perineal tears, the following care bundles are recommended: (i) obtaining antenatal information which may influence the choice of management, (ii) manual perineal support including fetal head control during vaginal birth, (iii) use of a mediolateral episiotomy (placed 60 ^{o} from vertical) at crowning when clinically indicated, and (iv) examination of the perineum including per rectal examination after vaginal birth [8,12].

4. Conclusion

Physical examination of the vagina and rectum should be performed after vaginal birth to exclude ORBT. An experienced clinician should undertake repair of ORBT, and a three-layer repair offers satisfactory wound healing and is recommended by the author. However, a two-layer repair may be undertaken in rare cases where the vagino-rectal fascia is not identifiable.

Contributors

Nnabuike Chibuoke Ngene was involved in patient care and is the sole author of this case report.

Funding

No funding was received from any individual or organization to support the writing or publication of this case report.

Patient consent

Written informed consent to publish the case report was obtained from the patient.

Provenance and peer review

This article was not commissioned. Peer review was directed by Professor Margaret Rees, Editor-in-Chief, independently of the author, Dr. Nnabuike Chibuoke Ngene, who is a senior editorial advisor of *Case Reports in Women's Health* and who was blinded to the process.

Acknowledgment

The author is thankful to the patient for giving a written informed consent for the case report to be published.

Conflict of interest statement

The author declares there is no conflict of interest regarding the publication of this case report.

References

[1] J.C. Roper, R. Thakar, A.H. Sultan, Isolated rectal buttonhole tears in obstetrics: case series and review of the literature, Int. Urogynecol. J. 37 (7) (2021) 1761–1769.
[2] E. Tunney, B. O'Leary, F. Malone, M. Geary, Obstetric rectal buttonhole tears: a case series and literature review, Int. J. Gynaecol. Obstet. (2022), https://doi.org/10.1002/ijgo.14513. Online ahead of print.
[3] D. Habek, A.T. Luetić, Primary identification and reparation of the "buttonhole" tears is necessary, Int. Urogynecol. J. 32 (1) (2021) 227–228.
[4] A. Awomolo, D. Hardman, A. Louis-Jacques, Obstetric rectal laceration in the absence of an anal sphincter injury, BMJ Case Rep 18 (8) (2021), e243296.
[5] N. Nkanyane, N.C. Ngene, Surgical excision of benign spindle cell neoplasm of the cervix predating miscarriage due to cervical insufficiency: a case report, Case Rep. Womens Health 35 (e00425) (2022).
[6] K. Perslev, E.-J. Mørch, H. Jangö, Increased risk of obstetric anal sphincter injury in women undergoing vaginal delivery after caesarean section: a systematic review and meta-analysis, BJOG 129 (129) (2022) 1961–1968.
[7] M. Gyhagen, M.E. Engh, H. Husslein, H. Koelbl, I.E.K. Nilsson, J. Schulz, A. Wagg, I. Milsom, Temporal trends in obstetric anal sphincter injury from the first vaginal delivery in Austria, Canada, Norway, and Sweden, Acta Obstet. Gynecol. Scand. 100 (11) (2021) 1969–1976.
[8] Society of Obstetricians and Gynaecology of Canada (SOGC), Obstetrical anal Sphincter Injuries (OASIS): prevention, recognition, and repair, J. Obstet. Gynaecol. Can. 37 (12) (2015) 1131–1148.
[9] Royal College of Obstetricians & Gynaecologists, The management of third- and fourth-degree perineal tears, Green-top Guideline No. 29 (2015). https://www.rcog.org.uk/media/5jeb5hzu/gtg-29.pdf (accessed 25 February 2023).
[10] A. Groutz, A. Cohen, R. Gold, J. Hasson, A. Wengier, J.B. Lessing, D. Gordon, Risk factors for severe perineal injury during childbirth: a case–control study of 60 consecutive cases, Color. Dis. 13 (8) (2011) e216–e219.
[11] D. Luchristt, A.R. Meekins, C. Zhao, C. Grotegut, N.Y. Siddiqui, B. Alhanti, J. E. Jelovsek, Risk of obstetric anal sphincter injuries at the time of admission for delivery: a clinical prediction model, BJOG 129 (2062–2069) (2022).
[12] J.G. Thorntona, H.G. Dahlen, The UK Obstetric Anal Sphincter Injury (OASI) Care Bundle: a critical review, Midwifery 90 (1020801) (2020).