

https://dspace.org/

The anatomical dimensions of the mandibular ramus and the presence of third molars: its effect on the sagittal split ramus osteotomy.

Beukes, Jacques

2012-04-17
http://hdl.handle.net/10539/11457

Downloaded from a DSpace repository. https://dspace.org/

Research report for MSc Dent

University of Witwatersrand

Faculty of health science

Dr J Beukes

Student number: 9507510h

Supervisor: Prof JP Reyneke

October 2011

The anatomical dimensions of the mandibular ramus and the presence of third molars: its effect on the Sagittal Split Ramus Osteotomy

1. Title
2. Aim
3. Introduction
4. Objectives
5. Materials and Methods
6. Statistical analysis
7. Results
8. Discussion
9. Management of unfavourable splits
10. Conclusion
11. References

Title

The variation of the anatomical dimensions of the mandibular ramus and the presence of third molars: its effect on the Sagittal Split Ramus Osteotomy

Aim

A Prospective study to evaluate the influence that the anatomical dimensions of the ramus of the mandible and the presence of lower third molars may have on the Sagittal Split Ramus Osteotomy.

Introduction

Since a report in 1907 by VP Blair[1] on surgical repositioning of the mandible for the correction of a prognathic mandible, the technique for the surgical correction of dentofacial deformities has since developed into, not only a well defined science, but also a fascinating art form.

In 1957 Trauner and Obwegeser[2] described a surgical procedure which involved repositioning the mandible by splitting the mandibular ramus in a sagittal plane. This technique enabled the surgeon to establish occlusal function and improved facial aesthetics by repositioning the mandible either anteriorly or posteriorly. The technique was later modified by Dal Pont[3] and further refined by Hunsuck in 1968[4] and Epker in 1977[5].

The Bilateral Sagittal Ramus Osteotomy is currently the most popular surgical procedure for the correction of dentofacial deformities involving the mandible[6]. The ingenuity of the procedure, development of specialised instruments and the improvement of the surgeons' experience and skills has made it possible to achieve surgical goals quick and atraumatically with predictable results[7,8].

However, as with any other surgical procedure, intra- and post-operative complications may occur. Complications associated with the surgical technique when performing the sagittal split osteotomy are well documented in the literature, the most common being unfavourable fractures of either the distal or proximal segment, damage to the inferior alveolar nerve, failure of fixation and condylar sag[7,8].

Although the anatomy of the posterior part of the mandible lends itself to the surgical design, it has become evident that the specific anatomy of each individual mandibular ramus plays a significant role at the time of splitting the ramus. Various technical factors could influence the successful completion of splitting the ramus and there are several important anatomical structures that should be considered when repositioning the mandible[9]. Maintaining the mandibular condyle/fossa relationship however, forms the basis for the achievement of the new planned occlusion. Correct positioning of the condyles in the fossae during surgery is therefore mandatory and is certainly challenging. The involvement of the Inferior alveolar nerve should be carefully considered

and the neurovascular bundle must be preserved at all cost during surgery to prevent post-operative neurosensory deficit of the lower lip and chin.

Experience has shown that the anatomical shape of the mandible, bone thickness, height of the ramus, the position of the lingula and presence of an impacted third molar tooth are all important factors which may influence the successful execution of the sagittal ramus split.

Fracture of the distal aspect of the proximal segment of the mandibular ramus or buccal plate usually occurs at the initial stage of the split. This complication may involve only part of the buccal plate (fig.1) however the fracture may extend further superiorly including the coronoid process of the mandible (fig.2).

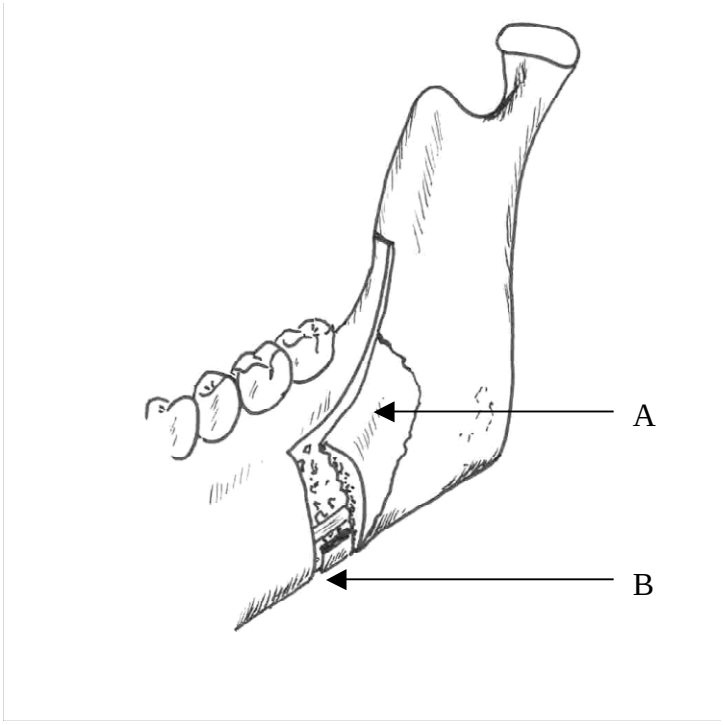

Fig.1 *A)Buccal plate fracture on distal aspect of the proximal segment. B)The inferior part of the proximal segment fails to separate from the distal segment*

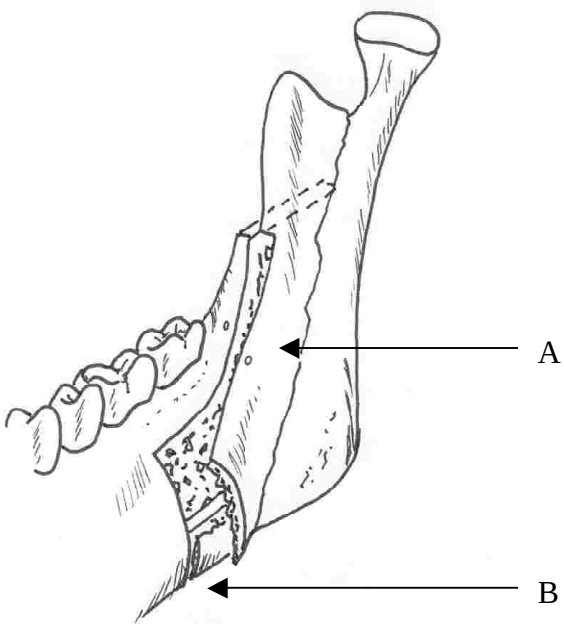

Fig.2 *A) Buccal plate fracture extending to the coronoid notch. B) The segment fails to separate from the lower border.*

Unfavourable fracture of the buccal plate usually occurs following failure to include the lingual cortex in the vertical part of the osteotomy (fig.3b). A wide and rounded mandibular lower border makes inclusion of the lingual cortex in the vertical osteotomy difficult.

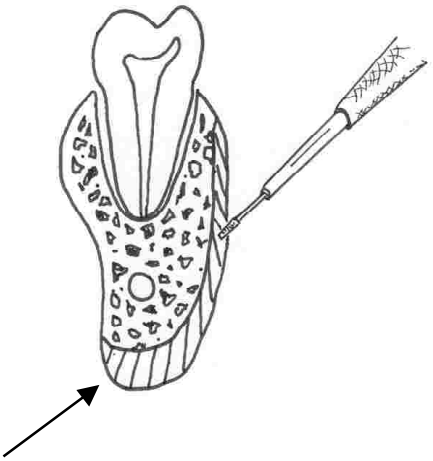

Fig.3a *The osteotomy should be carried medially to include the lingual cortex(Arrow).*

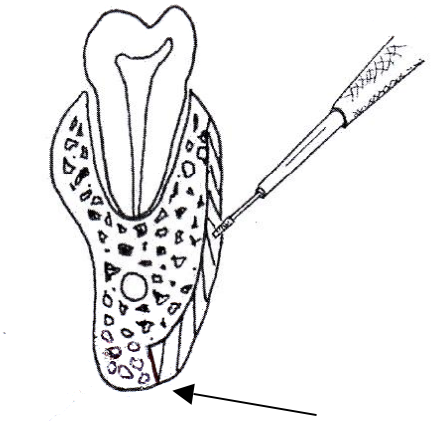

Fig.3b *The osteotomy is stopped short, not including the lingual cortex. This will lead to a fracture of the buccal cortex.*

The retromolar area of the distal segment of the mandible is often thin and fragile. The fragility of the bone may further be increased by the presence of an

impacted third molar tooth in the line of surgery (fig.4). The integrity of the bone in this segment plays an important role when fixating the segments and is essential for placement of bicortical screw rigid fixation. Fracture of this segment will limit placement of bicortical screws and increase the risk of fixation failure. An alternative fixation method such as the use of plate fixation should be considered. A rare complication of bilateral post-operative fracture of the lingual plates in the retromolar area leading to severe bilateral open bite malocclusion has been reported[10].

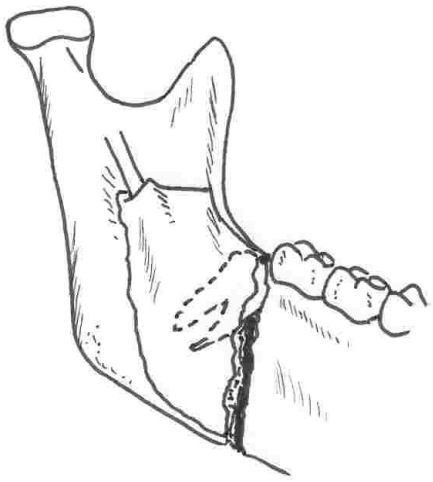

Fig.4 *The thin proximal aspect of the distal fragment will be further weakened by the presence of an impacted lower third molar.*

The position of the lingula, the mandibular foramen and the depth of the fossa posterior to the lingula are additional anatomical structures which demand consideration when planning and performing the sagittal split ramus osteotomy. The modification to the sagittal split osteotomy by Hunsuck[4] and Epker[5] allows

the surgeon to split the mandible anterior to the posterior border of the mandible. The osteotomy, according to this modification, runs from just posterior to the lingula, downwards on the lingual side of the ramus towards the lingual aspect of the vertical osteotomy (fig.5).

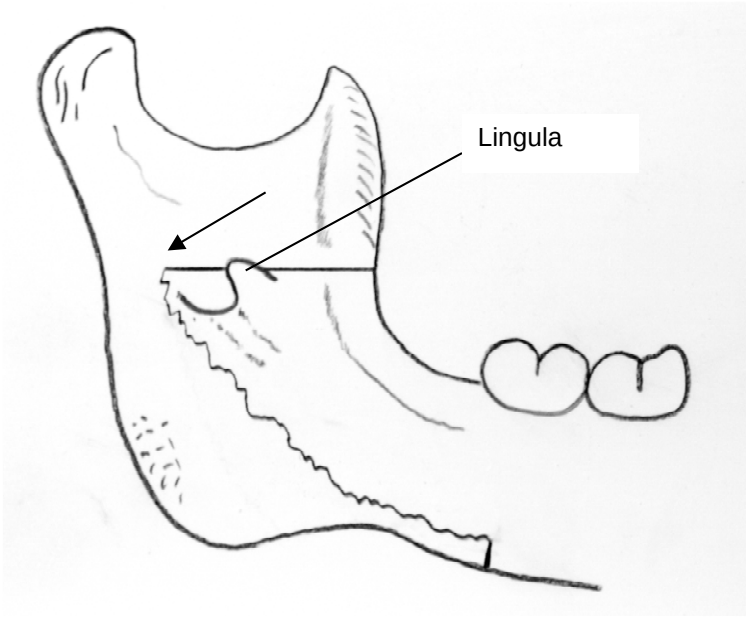

Fig.5 *The Hunsuck and Epker modification will result in the osteotomy extending from posterior to the lingula(arrow) to the lower border of the mandibular ramus.*

Failure to extend the horizontal osteotomy to just posterior to the lingula into the fossa, on the medial side of the ramus, will lead the osteotomy to fracture anterior to the lingula. The lingula, foramen and superior part of the inferior alveolar canal, will now remain attached to the proximal segment (fig.6). If this complication does occur, the attached bony canal, containing the neurovascular bundle, should be carefully dissected from the proximal segment. This may

unfortunatelly further jeopardise the neurosensory prognosis. Repositioning of the distal segment without releasing the inferior alveolar neurovascular bundle from the bone will stretch the nerve adding to the risk of neurosensory deficit of the lower lip and chin on the affected side.

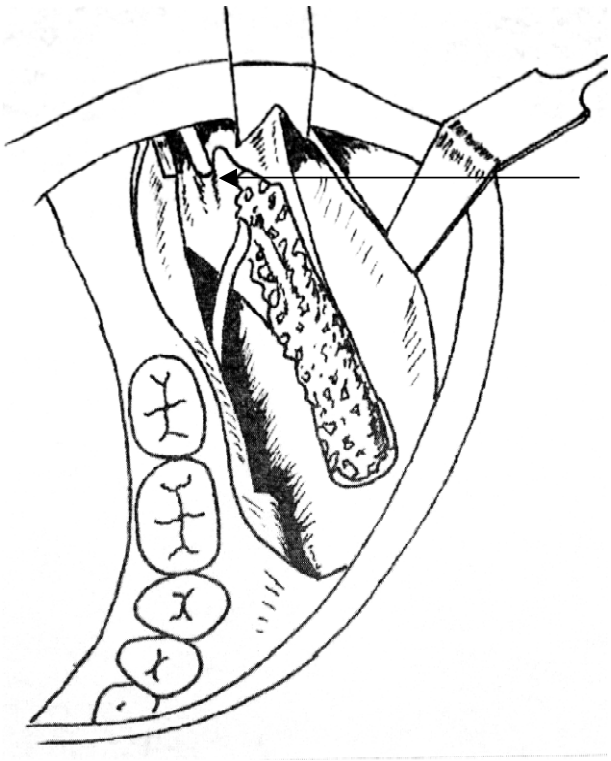

Fig.6 *Inadequate posterior extension of the horizontal osteotomy will result in the lingula, foramen and superior part of the canal remaining attached to the proximal segment. (Arrow)*

Objectives

This study measured the width of the anterior mandibular ramus, the height of the corpus posterior to the second mandibular molar as well as the antero-posterior anatomical position of the lingula and investigated the influence that

these dimensions of the mandible may have on the successful splitting of the mandibular ramus. The effect that the presence of wisdom teeth had on the difficulty of the procedure was also investigated.

Materials and Methods

Seventy four patients volunteered to take part in the study (Permission from the Human Medical Research Ethics Committee was obtained: M0050341). Data was captured over a period of eight months from consecutive patients who had received sagittal split osteotomies. The same surgeon performed 147 sagittal split osteotomies on 74 patients. Seventy four patients received bilateral osteotomies while a unilateral osteotomy was performed on one patient, (73 osteotomies were performed on the right side and 74 osteotomies on the left side).

Fifty-nine percent of the patients included in the study were females (44) and forty-two percent were males (30). The age of the patients ranged from thirteen(13) years to fifty-three(53) years (average age: 26) at the time of surgery.

Each patient's surgical treatment was comprehensively planned and included cephalometric surgical objectives and model surgery. A standard surgical routine allowed the surgical team to anticipate each step, prevent intra-operative uncertainty and helped to eliminate post-operative complications.

During surgery, a single experienced operator measured the width of the mandibular rami at the level of the horizontal osteotomy (the height of the lingula) while the width of the mandibular bodies were measured just posterior to the second molar tooth (fig.7). Measurements were performed using a calliper.

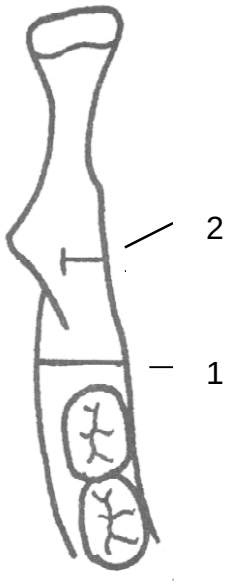

Fig.7 *Intraoperative measurements included (1) the width of the mandible 3mm posterior to the second lower molar and (2) the width of the ramus at the level of the lingula.*

Further measurements were performed on a standard panoramic radiograph taken on the same x-ray machine (Planmeca 2002 cc Prolive) by the same radiographer and included the following: the distance from the lower border of the mandible to the apex of the distal root of the lower second molar tooth, the height of the corpus of the mandible 3 millimetres posterior to the lower second

molar, the distance from the anterior border of the ramus to the anterior border of the lingula and the antero-posterior dimension of the ramus at the level of the lingula (fig.8).

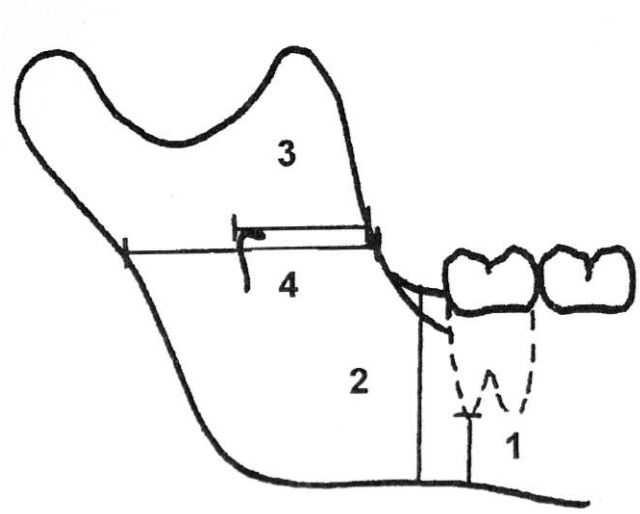

Fig.8 *Measurements on the panoramic radiograph. (1) The distance from the lower border to the apex of the distal root of the lower second molar, (2) height of the corpus of the mandible 3mm posterior to the lower second molar, (3) distance from the anterior border of the ramus to the anterior border of the lingula and, (4) antero-posterior dimension of the ramus of the mandible.*

The presence of an impacted/unerupted/erupted lower third molar tooth was noted.

Following each procedure the surgeon evaluated and graded the difficulty of splitting the mandibular ramus as follows;

Grade 1: Once the straight osteotome was placed into the osteotomy line at the superior border and the Reyneke splitter placed into the vertical osteotomy at the lower border and rotated the related segments split apart without difficulty.

Grade 2: A tendency to a greenstick and/or bad split and inferior alveolar nerve involvement, requiring dissection of the neurovascular bundle or canal. The split required redefining the osteotomies to ensure correct splitting.

Data analysis:

Six mandibular measurements were made on both the left and right side. These continuous measurements were summarized by difficulty grade using descriptive statistics mean and standard deviation. Group comparisons were done using Students' two couple t-test and p-values along with 95% confidence intervals for the mean difference between groups were reported. Groups were also compared with respect to the distribution of wisdom teeth (absent; erupted; unerupted; impacted), using Fischer's exact test. Testing was done at the 0.05 level of significance.

Results:

Grades of difficulty differed significantly (p=0.015) with respect to measurement 5-L and marginally significant (p=0.071) with respect to measurement 6-R (Table 1). However, these differences are clinically irrelevant and hence we have concluded that the grades of difficulty do not differ significantly with respect to any of the measurements.

Grades of difficulty differ significantly (p=0.003) with respect to wisdom teeth distribution; in particular for the difficult group (grade 2). This group has a high

proportion of unerupted (33.33%) and impacted (21.22%) wisdom teeth, while the not difficult group (Grade 1) only has 12.5% unerupted and 2,5% impacted wisdom teeth.

		Grade of difficulty					
		Grade 1		Grade 2			
Measurement		**Mean (Std-dev)**	**N**	**Mean (Std-dev)**	**N**	**P-value***	**95 % c.i. for difference**
1. Lower border of the body of the mandible to the apex of the distal root of the lower second molar.	R	12.97 (3.06)	45	13.78 (4.17)	28	0.34	(-2.5; 0.88)
	L	13.47 (3.22)	48	13.07 (3.41)	26	0.61	(-1.19; 1.99)
2. Height of the body of the mandible 3mm posterior to the lower second molar.	R	28.76 (4.10)	45	30.46 (4.81)	28	0.11	(-3.80; 0.41)
	L	28.57 (4.24)	48	28.96 (4.79)	26	0.71	(-2.54; 1.77)
3. Distance from the anterior border of the ramus to the anterior border of the lingula.	R	17.08 (3.34)	45	18.00 (3.07)	28	0.24	(-2.46; 0.64)
	L	16.07 (2.92)	48	16.59 (3.09)	26	0.47	(-1.97; 0.92)
4. Antero-posterior dimension of the ramus at the level of the lingula.	R	35.74 (3.90)	45	36.03 (4.85)	28	0.77	(-2.35; 1.76)
	L	33.83 (4.05)	48	32.92 (4.39)	26	0.37	(-1.11; 2.93)
5. Width of the mandible posterior to the lower second molar.	R	15.87 (2.22)	45	16.33 (1.91)	28	0.36	(-1.47; 0.55)
	L	15.96 (2.29)	48	17.28 (1.94)	26	0.01	(-2.37; 0.26)
6. Width of the mandibular ramus at the level of the lingula.	R	7.43 (1.61)	45	8.19 (1.74)	28	0.06	(-1.56; 0.03)
	L	8.01 (1.50)	48	8.69 (2.32)	26	0.15	(-1.57; 0.20)

Table. 1 Comparison of difficulty grade 1 and difficulty grade 2 treatment groups with respect to mean mandibular measurements (mm).
*p-Value associated with Student's two-sample t-test and $p<0.05$ denotes a statistically significant difference between difficulty groups.

Third molars	Grade of difficulty		Total
	Grade 1	Grade 2	
Absent	29 (70.73%)	12 (36.36%)	41 (55.41%)
Erupted	6 (14.63%)	3 (9.09%)	9 (12.16%)
Unerupted	5 (12.20%)	11 (33.33%)	16 21.62%)
Impacted	1 (2.44%)	7 (21.21%)	8 (10.81%)
Total	41 (100%)	33 (100%)	74 (100%)

Table 2: Comparison of Grade 1 and Grade 2 treatment groups with respect to the distribution of wisdom teeth.

Discussion

In the last four decades the Sagittal Split Osteotomy has evolved from a life threatening procedure to, in some cases, outpatient surgery.

In this prospective study no unfavourable splits of the mandible was reported. The surgeons' experience and skill may certainly be a factor in this result. Approaching each patient with a standard surgical technique that involves appropriate treatment planning, a consistent surgical routine and the use of modern well designed instrumentation assist in minimizing intra-operative and post operative complications.

Although no intra-operative or post-operative bad splits occurred in this study, there were a number of osteotomies that proved to be technically more difficult than others. The presence of lower third molars certainly influenced the level of

difficulty. We anticipated that other factors such as the height and the width of the corpus of the mandible and the width and thickness of the ramus
would influence the difficulty level but this study showed that no single measurement influenced the difficulty of the sagittal split. Experienced surgeons are often able to recognize anatomical limitations early, adjust their surgical technique appropriately and in doing so limit the possible complications associated with the above mentioned factors.

Reyneke et al, Precious et al and Mehra et al indicates increased risk of an unfavourable split with unerupted third molar teeth[11,12,13]. Previous studies have recommended the removal of unerupted lower third molar teeth at least six months prior to the surgical procedure[11]. The authors however feel that a period of nine months is more appropriate.

Conclusion

Even though there were no statistically significant differences between the dimensions of the mandible of difficult sagittal split osteotomies and easy osteotomies, experience have shown that cases with extreme anatomical variations e.g. an extremely narrow mandible or small mandibular height does contribute to the difficulty of the sagittal split osteotomy.

This study showed an increased risk of a difficult split if lower third molars were present but we could not establish if any single anatomical measurement contributed to the level of difficulty.

References

[1] Blair VP. Operations on the jaw bone and face. Surg Gynecol Obstet 1907; 4:67-8

[2] Trauner R, Obwegeser H. The surgical correction of mandibular prognathism and retrognathia with consideration of genioplasty. Oral Surg Oral Med Oral Path 1957; 10:677-689

[3] Dal Pont G. Retromolar osteotomy for the correction of prognathism. J Oral Surg 1961; 19:42-7

[4] Hunsuck EE. A modified intraoral sagittal splitting technique for correction of mandibular prognathism. J Oral Surg Anaesth 1968; 2:249-252

[5] Epker BN. Modifications in the sagittal osteotomy of the mandible. J Oral Surg 1977; 35:157-9

[6] Macintosh RB. Experience with the Sagittal split Osteotomy of the mandibular ramus: A 13 –year review. J Maxillofac surg 1981; 9:151-65

[7] Gaersey LH. De Champlain R.W. Sequelae and complications of the intra-oral sagittal osteotomy in the mandibular ramus. Oral Surg Oral Med Oral Path 1971; 32:176-92

[8] Behrman SJ. Complications of the sagittal osteotomy of the mandibular ramus. J Oral Surg 1972; 30:554-61

[9] Witherow H, Offord D, Eliahoo J, Stewart A. Postoperative fractures of the lingual plate after bilateral sagittal split osteotomies. Brit Journ of Oral Maxillofacial Surg 2006; 44:296-300

[10] Turvey TA. Intraoperative complications of sagittal split osteotomy of the mandibular ramus: Incidence and management. J Oral Maxillofac Surg 1985; 43:504-9

[11] Reyneke JP, Tsakiris P. Age as a factor in the complication rate after removal of unerupted/impacted third molars at the time of mandibular sagittal split osteotomy. J Oral Maxillofac Surg 2002; 60:654-9

[12] Precious DS, Lung KE, Pynn BR, GooddayRH. Presence of impacted teeth as a determining factor of unfavorable splits in 1256 sagittal osteotomies. Oral Surg Oral Med Oral Path 1998; 85:362-5

[13] Mehra P, Castro V, Freitas RZ, Wolford LM. Complications of the mandibular sagittal split osteotomy associated with the presence or absence of third molars. J Oral Maxillofac Surg 2001; 59: 854-8