

https://dspace.org/

Quality of Adult Chest Radiographs Using Slit Beam Radiography (LODOX) in the Trauma Setting

Du Toit, Maria Johanna

2014

https://hdl.handle.net/10539/28297

Du Toit, M. J. 2014. Quality of Adult Chest Radiographs Using Slit Beam Radiography (LODOX) in the Trauma Setting. University of the Witwatersrand, Johannesburg. Available on: http://wiredspace.wits.ac.za/handle/10539/28297

Downloaded from a DSpace repository. https://dspace.org/

Quality of Adult Chest Radiographs Using Slit Beam Radiography (LODOX) in the Trauma Setting

Dr Maria Johanna du Toit

A research report submitted to the Faculty of Health Sciences, University of the Witwatersrand, Johannesburg, in partial fulfilment of the requirements for the degree of Master of Medicine in Diagnostic Radiology

Johannesburg, 2014

Declaration

I, MJ du Toit, declare that this research report is my own work. It is being submitted for the degree of MMed (RadD) at the University of the Witwatersrand, Johannesburg. It has not been submitted before for any degree or examination at this or any other University.

DR MARIA JOHANNA DU TOIT

On this 26 the day of May 2014.

Publications and presentations

This work has never been published.

It has never been presented at a congress.

Abstract

LODOX Statscan images the entire body in 13 seconds. There is no information available regarding quality assurance (QA) of this diagnostic imaging modality. We performed QA of the chest component of LODOX images at one Emergency Unit.

AIM: To determine and score the prevalence and type of radiographic error of LODOX chest radiographs in the adult trauma setting. To develop a poster as visual aid to illustrate the advantages and disadvantages of the LODOX Stat scan and suggest methods to reduce errors that may influence the diagnostic quality of the image.

METHOD: A retrospective descriptive study on one hundred LODOX studies in adults (> 18 years of age) over a period of six weeks was done. The open source OSIRIX software was used to view DICOM files and QA evaluations were performed by three observers, using a pre-drafted tick-sheet and scoring system.

RESULTS: No perfect scores were achieved in our study with an average score of 3.79 out of a possible worst score of 10. The majority of points were scored due to positioning errors and poor planning such as un-removed clothing and other artefacts. Radiographic density, contrast and sharpness generally were of good quality contributing less to QA scores.

CONCLUSION: Operator dependent errors were the most frequently encountered in LODOX chest images. These were acquired without a trained radiographer in a trauma setting which posses its own challenges. There appears to be a leniency with regards to the quality of the images in this setting. The majority of the images were considered diagnostic, but many of the errors encountered are correctible through proper radiographic principles and this should be targeted when training staff.

Acknowledgements

Patience leads us to success

Even though it's not easy to cope

It is an art not performed by many

Constructed with wisdom and hope

To my supervisors Prof Savvas Andronikou and Dr Su Lucas, you have guided me with wisdom and hope; you have made this project possible through your patience and dedication to research.

To my mom, you have been my motivation, my rock in everything I have embarked upon. Thank you for supporting me through everything, every day.

To the registrars embarking on this great journey, success is within your reach.

Table of Contents

Declaration ii

Publications and presentations iii

Abstract iv

Acknowledgements v

List of Figures ix

List of Tables x

1. Introduction 1

1.1 Role of CXR (Chest X-ray) in Trauma 1

1.2 Imaging for Specific Chest Pathology in Trauma using CXR 2

1.3 Factors affecting interpretation of CXR in Trauma 5

1.4 QA in CXR 6

1.5 Criteria and Tick-sheets for QA 7

1.6 Factors affecting the quality of CXR in Trauma: 8

1.7 "LODOX Statscan": 9

1.8 QA in LODOX 12

1.9 Study objectives 13

2. Materials and Methods 13

2.1 Research paradigm 13

2.2 Inclusion and Exclusion criteria 14

2.3 Data collection 17

2.4 Data analysis 17

2.5 Statistics 18

2.6 LODOX Statscan QA Poster 19

3. Results 20

3.1. General Considerations 20

3.2. Patient demographics 21

3.3. Distribution of total scores achieved 21

3.4 Frequency of Radiographic Errors 22

3.5. Errors per category 23

3.5.1 Positioning 23

3.5.2 Density, contrast and sharpness 23

3.6. Fleiss Kappa Scores 23

3.7. Frequency of radiographic errors according to the observer's common decision .. 24

3.8. Films requiring repeating 25

3.9. Additional Results 25

4. Discussion 26

4.1 Results in context 26

4.1.1 Parts cut-off 28

4.1.2 Rotation 28

4.1.3 Scapula in the way 29

4.1.4 Patient motion 29

4.1.5 Under Inspiration 30

4.1.6 Artefacts 30

4.1.7 Central and peripheral vessels 30

4.1.8 Trachea and bronchi 31

4.1.9 Intervertebral discs spaces 31

4.1.10 Clavicle not on 4th rib 31

4.2 Fleiss' Kappa scoring 32

4.3 Current applications 32

4.4 Limitations of the current study 33

4.5 Future applications 33

5. Conclusion 35

Appendix A: Ethics Clearance Certificate 36

Appendix B: Quality Assessment Tick-sheet 37

Appendix C: Lodox Statscan Poster to improve QA 38

6. References 39

List of Figures

Figure 2.1 Examples of digital image manipulation to optimally demonstrate bony structures (A) and lung fields (B)..... 14

Figure 2.2. Examples or radiographic errors on LODOX in the trauma setting: Full body LODOX images A, B, C and chest images from LODOX D, E..... 16

List of Tables

Table 2.1 – QA Criteria 15

Table 2.2 – Fleiss Kappa Score interpretation 18

Table 3.1 Total Scores achieved 21

Table 3.2. Frequency of occurrence of radiographic errors 22

Table 3.3 Frequency of errors, Fleiss Kappa scores and total agreement between observers 24

Table 4.1 Radlex image quality rating scale 27

1. Introduction

LODOX is a relatively new slit beam technology, which is still finding its place in diagnostic imaging. It is favoured in trauma departments for whole body imaging because it offers advantages of reduced radiation within the trauma department environment, and because patients can be imaged on the resuscitation trolley, rather than being moved to the X-ray department. These inherent advantages have built–in disadvantages including the fact that radiographic positioning procedures are not always adhered to (radiographers are sometimes not employed for imaging procedures and patients are often not moved or correctly positioned). Equipment is under the trauma department control, where there may not be regular radiographic Quality Assurance (QA) procedures. Existing literature concentrates on the diagnostic capability of this technique against the standard, chest radiographs.

There is however limited information on QA parameters of the chest component of LODOX whole body images in the trauma setting, where detailed information of high quality chest radiographs may be lifesaving. Regular QA is essential for maintaining diagnostic imaging quality while maintaining reduced radiation doses to patients. This study will aim to identify the most common radiographic errors on the chest component of LODOX images in the trauma setting, so that appropriate quality improvement (QI) steps can be taken.

1.1 Role of CXR (Chest X-ray) in Trauma

Resuscitation according to the Advanced Trauma Life Support (ATLS) program is essential in the management of patients involved in major trauma. Radiographic evaluation is included in this program ranging from plain radiographs to Computed Tomography (CT).

Antero-posterior chest radiography is routinely performed as one of the first diagnostic tests for patients sustaining chest trauma, on first presentation to the Emergency Department. Patients are often unstable. Transportation to the radiology department may involve additional risks, thus necessitating the use of bedside / mobile radiography with its inherent limitations of poor positioning and artefacts due to overlying monitoring equipment (1). A lateral chest radiograph may be required which is further time consuming and often of poor quality.

Diagnosis of chest trauma is dependent on high quality radiographs in order to evaluate the chest wall (including the soft tissue and bones), the pleura, the diaphragm, the lungs and mediastinum (including the trachea, bronchi and oesophagus), the heart (including the pericardium) and the vasculature (including the aorta, great vessels and pulmonary arteries) (2). In those patients for whom an upright position is impossible, it may be helpful to obtain and AP chest radiograph with the patient in the reverse Trendelenburg position (3).

Chest computed tomography is a good alternative diagnostic tool in a trauma patient with suspected chest injury. However, financial implications as well as radiation exposure are restrictions that need to be considered. Careful review of the indication of a scan as well as the stability of the patient need to be evaluated in order to avoid delays in patient care (4).

1.2 Imaging for Specific Chest Pathology in Trauma using CXR

A significant amount of radiographic detail is necessary for accurately diagnosing specific pathologies after chest trauma.

Standard Chest X-ray (CXR) is a first line investigation for suspected **pneumothorax** after blunt or penetrating chest trauma where the edge of the lung is sought and an area of lucency containing no vascular or bronchial structures beyond this represents the pneumothorax. Significant radiographic detail is needed to avoid the use of CT scanning for detecting small pneumothoraces (5), which can be very subtle on plain radiographs.

Aortic injury is suggested in a few chest x-ray findings that are neither specific nor sensitive. These features include capping in the left apex, paraspinal line widening, mediastinal widening, a widened right paratracheal stripe (>5mm), right-sided deviation of the nasogastric tube and obscuration of the descending aortic line (6). Recommendations by Kuhlman indicate that with good quality chest radiographs with normal findings are adequate to exclude any significant pathology (6). The use of chest radiographs obtained with portable equipment in supine trauma patients to predict the presence of mediastinal haemorrhage is therefore considered inaccurate (6). Although a mediastinal width of more than 25% of the thoracic width is the most frequent finding in mediastinal haemorrhage, it is not a sensitive finding. An abnormal transverse aortic arch or obscuration of the aorto-pulmonary window could be evaluated as more reliable indication of such an injury. CT evaluation is often still recommended to confirm the diagnosis (7).

Findings in patients with a ruptured diaphragm are nonspecific. Injuries to the diaphragm are frequently not identified on initial evaluation with potential serious complications such as respiratory failure. Radiographic features that may suggest diaphragmatic rupture include mass effect on the contralateral hemithorax due to herniation of abdominal organs into the chest, more than two centimetres elevation of a hemidiaphragm compared to the opposite side

(the diaphragm may also appear to have an irregular contour) and a nasogastric tube that curves back up in the chest after initial normal descent (6).

Oesophageal rupture is suspected with the presence of significant pneumomediastinum (again not a specific sign). Pathology in the left hemithorax after trauma demonstrating effusion, lower lobe collapse and a pneumothorax should also raise the suspicion of oesophageal rupture (6).

Pulmonary contusions are expected after significant blunt chest trauma and are caused by haemorrhage into the alveoli. Features of air-space consolidation are typically seen during the initial radiographic evaluation. Pleural effusions that demonstrate significant enlargement over a short period of time should raise the suspicion of an injury to a vascular structure (causing a hemothorax) or the thoracic duct (causing a chylothorax) (6). Radiographs must therefore be of sufficiently high quality to demonstrate both air-space disease and pleural fluid and Hounsfield units are a useful adjunct on CT scans to differentiate between a hemothorax (red blood cell attenuation) and chylothorax (fat attenuation).

Trauma radiographs are often not adequate to identify fractures over the full extent of the thoracic spine. Thoracic spine fractures are often suspected in the chest trauma patient and accurate evaluation of the presence and extent will influence the time frame and extent of the orthopaedic and / or neurosurgical intervention (6).

Rib fractures occur in 60% of blunt trauma cases; however, only one in every five are detected with portable trauma chest radiography because of the quality and difficulty to obtain oblique

views (6). It is important to identify a flail chest and respiratory failure is a common complication. Flail chest is identified when five or more ribs in a row, or when three or more segmental fractures are present (6).

1.3 Factors affecting interpretation of CXR in Trauma

CXR abnormalities missed in the trauma setting have been reported, although their clinical significance has very rarely influenced patient management. The most commonly missed findings include fractures, dislocations, air-space disease, and pulmonary nodules (8).

Two-dimensional images superimpose all tissue densities of a three-dimensional structure. This poses a challenge to distinguish internal structures from the peripheral thoracic cage. Air–fluid levels in fluid containing air-filled structures are not identified in an x-ray taken when the patient is supine. Magnification of structures furthest from the film and on poorly inspired films create a false sense of the dimensions of the cardio-thoracic ratio and prominence of the vasculature (9)

Complicating the interpretation of chest radiographs of trauma patients are non-technical confounding factors. For example, mediastinal shift is caused by both lung collapse or tension pneumothorax while obliteration of the mediastinal outline may be due to pulmonary contusion, pleural effusion, or hemothorax and can make evaluation of the mediastinum difficult. It is often difficult to distinguish the mediastinal outline and extent in patients with a tortuous aorta. Atherosclerosis can also influence structure identification, obscuring possible pathology. Pre-existing pathology such as hilar lymphadenopathy, mediastinal soft tissue masses and increased vessel diameter can be confused for a mediastinal hematoma (3).

Pneumothorax occurs in 30%-40% of cases of blunt chest trauma. Small pneumothoraces may be difficult to detect on plain radiographs and CT has been shown to have a greater sensitivity, particularly in supine trauma patients (10).

1.4 QA in CXR

Quality of radiographs is paramount in diagnostic radiology and directly affects diagnostic capabilities further. Quality management forms an intricate part of any well-managed radiology practise. The American Board of Radiology now requires the practice quality improvement (PQI) into the maintenance of certification (11). However, the concepts of quality control (QC), quality assurance (QA), and quality improvement (QI) are incorrectly used as if apparently similar terms (11).

QC is defined as the implementation and constant auditing of pre-set guidelines and standards appropriate for practice. QC in chest radiography includes amongst others: interval testing and maintenance of radiology equipment and the quality of results submitted for interpretation (11). By doing regular QC and evaluating images obtained, unacceptable radiographic images can be used to educate and in time decrease these types of images (11). QA is a data collection process over time that aims to ensure patient care of an acceptable standard. QI is a philosophy or culture to continuously improve patient care.

1.5 Criteria and Tick-sheets for QA

Previous research has successfully quantified plain film abnormalities with the use of tick-sheets or data-entry forms. Limiting choices and decreasing confusion provide more reliable results by forcing participants to making a decision through the use of such tick-sheets (12).

Quality Criteria and quality scores have also been presented and revised by Lanhede and colleagues through a series of visualization criteria listed below (13):

(1) Reproduction of the vascular pattern in the whole lung, particularly the peripheral vessels.

(2) Visually sharp reproduction of the trachea and proximal bronchi and, the borders of the heart and aorta.

(3) Visually sharp reproduction of the diaphragm and costophrenic angles.

(4) Visualization of the retrocardiac lung and mediastinum.

(5) Thin linear structures (0.5–2 mm): fissures, peripheral vessels.

(6) Rounded structures (2–6 mm): vessels seen en face.

(7) The carina with main bronchi.

(8) The thoracic vertebrae.

(9) The lung mediastinal interface.

(10) Details to be sharply visualized in the costopleural junction

Another paper, by Chen-Yuan and colleagues, lists checkpoints for anatomical positioning and identification of quality chest radiography (14):

(1) Complete identification with name of patient, age, name of health facility, and date of examination

(2) Clear identification mark printed at the place on the upper-left/right side

(3) No defective lung fields from apices to lower edges

(4) Whole edges of the both diaphragms traced

(5) Sufficient inspiration: the posterior 10th rib should be visible above the diaphragm

(6) Symmetrical location of clavicles and scapulae

(7) No overlapping of scapulae in the lung fields

(8) Density of both lung fields visualized symmetrically

(9) Centrally located trachea and both main tracheal branches visible

(10) Pulmonary vessels clearly visible in the lung fields and traced to the lung periphery

(11) Lower vessels in the left lung visible through the heart

(12) Thoracic vertebrae visible behind the heart

(13) Artefacts and foreign substances must not be visualized

1.6 Factors affecting the quality of CXR in Trauma:

Imaging in the trauma setting often utilizes portable X-ray equipment. This type of portable X-ray examination has limitations. Proper positioning of the patient is often not possible and inability to breath hold on deep inspiration as well as artefacts from clothing or monitoring equipment affects the quality of the CXR (1), making QA vital to maintain diagnostic standards.

A portable CXR is currently often performed on digital computed radiography systems (DR). There are several benefits of the DR system such as faster acquisition and image post-processing compared to old CR systems. Software programs of DR systems also provide multiple features allowing brightness adjustment, measurement, rotation and zooming functions.

There are also inherent disadvantages. Radiation exposure is not reflected on the image when using digital imaging (15). The blackness or whiteness of the initial film does not act as a natural control for limiting machine settings as this can be adjusted through post processing by the operator through windowing.

Increased exposures due to repeat examinations are also a more frequent occurrence in the trauma setting due to uncooperative patient's motion or positioning. Operator dependent factors such as poor radiographic technique and film processing also may necessitate repeat examinations (16).

There are reports of medical facilities that are oblivious to the radiation levels they expose their patients to. Deficient QC practices should therefore be cause for concern in practices (16). Placement of radiographic X-ray equipment outside of imaging departments, for example in trauma departments may contribute to this phenomenon. QC is most often performed within radiology departments where constant supervision and management may be available, but are regularly deficient outside of this designated area.

1.7 "LODOX Statscan":

Lodox Statscan (LS) is a digital radiography (DR), low-radiation imaging device that provides head-to-toe antero-posterior (AP), oblique and lateral views in just over five minutes with additional advantages of not having to move the patient from the resuscitation trolley (18). LS is gaining wide acceptance and popularity with a report in 2010 documenting 25 trauma centres worldwide utilizing this imaging technique in their emergency treatment and evaluation protocols (19).

The X-ray tube is mounted on one end of a C-arm that is able to rotate 100°. Cranio-caudal oblique views are achieved through lifting or depressing either end of the table (20). Imaging parameters (kVp and mAs) are automatically calculated by simple patient physical attributes being entered prior to imaging, thereby eliminating a degree of operator error (21).

Traditional radiographic instruments dispense X-rays in a cone beam allowing x-rays to spread in width and length. The Statscan dispenses a targeted X-ray beam through a very narrow slot that penetrates the patient's body in 2mm slices, resulting in a fan shape of the x-rays in the direction of the detector (21). The slit beam technology results in less poor-quality, secondary photons being emitted from the X-ray beam. The C-arm travels at 13.8cm/s, allowing full body AP scanning in approximately 13 seconds (20). The only comparable full- body imaging is the ''scannogram'' or ''scout view'' used for CT scanning; this is at a much lower resolution. CT imaging provides a valuable three-dimensional multiplanar reconstruction (MPR) feature that provides a major advantage over the two-dimensional presentation of the image in LS (20). Software tools, including a module to obtain linear measurements such as in other DR systems, accompany the Statscan system. This software corrects for magnification on the basis of the distance between the X-ray detector and the central axis of the patient as part of the basic information entered by the operator (22).

LS offers some advantages that make it attractive in practice. Good quality images including low noise and high-resolution images (23) are achieved at a low dose. The simplicity of operation and the ability to obtain full-body views are advantageous in the trauma unit (21). The disadvantages of scatter radiation is not a contributing factor in LS, therefore a large surface scatter minimising grid is not required, and therefore decreased exposure parameters

can be utilized (21). The flat-panel detectors used in DR (Digital Radiography) machines have superior detective quantum efficiency than the phosphorus plates used in CR (Computed Radiography). This is not done at the cost of poorer image quality and still at a reduced patient radiation exposure (23). LS provides a powerful post-processing algorithm that sharpens contrast and improves the general image quality. Linear slit DR provides very good soft- tissue contrast while maintaining sharp delineation of bones. It also depicts anatomic structures better than CR in high-attenuation areas of the chest such as the mediastinum and the retrocardiac region (23). Image quality was evaluated to be equivalent to that of conventional X-rays in all categories in one study (20).

In a study by Pitcher where the paediatric population was evaluated using LODOX, it was noted that LODOX provides and ideal opportunity to decrease the radiation exposure especially where multiple radiographs are indicated (22).

The LS provides alternative opportunities for imaging obese patients. The weight capacity of the carbon-fibre bed accommodates patients up to 330 kilograms. The automated calculation for individual patient physical characteristic information adjusts exposure parameters to manage bariatric patients. Increased high-attenuation soft tissue penetration & bony detail appears better to conventional films (21).

Rib fractures, pneumothoraces and lung contusions are adequately evaluated in chest trauma with the use of linear slit DR as compared to CR (23). Multi-reader analyses are needed to evaluate linear slit DR to determine its role in chest trauma injuries (23). In a study by Schiemann (24), it was shown that LODOX allowed for exclusion of pneumothorax, pleural

effusion and free abdominal air in all cases investigated. The quality of LS images of the chest has not been evaluated in detail in the trauma setting.

1.8 QA in LODOX

QA procedures are routine for conventional chest radiographs but limited information is published specifically around the QA of LODOX images. Determination of the type of errors that are most common and what additional errors should be anticipated is important so that QI (quality improvement) can be instituted for every institution.

Motion artefact decreased the quality on the LODOX images in one study by Pitcher and colleagues (25). This was however not deemed to be of significance in the diagnostic and clinical setting (25). Femoral diaphyseal periosteal reaction that was identified was attributed to post processing errors and was rectified (25).

The resolution of LODOX images has been found to be similar to those of computed radiography (CR). LODOX allowed superior visualization of all major airways in one study (25). LODOX chest images in a non-trauma setting showed longitudinal rotation in only 17.4% of cases compared to 52% of the CR images (25). Foreign bodies were picked up at a higher frequency during linear slit DR imaging. This was the first imaging technique in all trauma patients, prior to any removal of clothing, intervention and monitoring equipment being present (23).

The LODOX also has associated image optimization software, which includes edge enhancement and histogram equalization. This affords superior visualization of the bony

skeleton, skeletal soft tissues and the major airways. Pulmonary vasculature and pulmonary parenchyma are best evaluated prior to any image modification (25).

1.9 Study objectives

To determine and score the prevalence and type of radiographic error of LODOX chest radiographs in the adult trauma setting. To developed a poster demonstrating advantageous and disadvantageous qualities of the LODOX Statscan, as well as examples of errors. Suggestions are made to correct some of these errors (Appendix C).

2. Materials and Methods

2.1 Research paradigm

One hundred LODOX Statscan full body digital images were retrospectively collected at the Charlotte Maxeke Johannesburg Academic Hospital (CMJAH) Trauma unit database, from the 12th of August 2011 to 1st of September 2011.

The study was approved by The University of the Witwatersrand Human Research Ethics Committee (clearance number: M120523).

Emergency Medicine physicians performed all LODOX imaging. A radiographer did not assist the physicians. Image acquisition parameters were manually set by predetermined factory setting from LODOX, determined by approximate weight: normal (220kg) or bariatric (330kg).

2.2 Inclusion and Exclusion criteria

All LODOX studies in that were performed in the time period were included. All the patients that are seen in this unit are adults (aged 18 years and older). Male and female patients were included. Studies that did not include the chest as part of the whole body assessment, and all corrupted digital files were excluded. Routine LODOX studies, at our institution, are performed as a whole body trauma studies.

These LODOX studies were saved on a digital storage device and transferred to a laptop. The open source OSIRIX software was used to view DICOM (Digital Imaging and Communications in Medicine) files and perform the evaluations. Each LODOX study was evaluated independently by the primary investigator (a senior registrar in radiology) and two consultant radiologists. A quality assurance tick-sheet was used for determining radiographic errors relating to the chest component of the examination. Image altering was open to all functions available on the Osirix program, including magnification, contrast, etc. Fig 2.1 shows an example of digital image manipulation to optimally demonstrate either the bony structures or the lung fields.

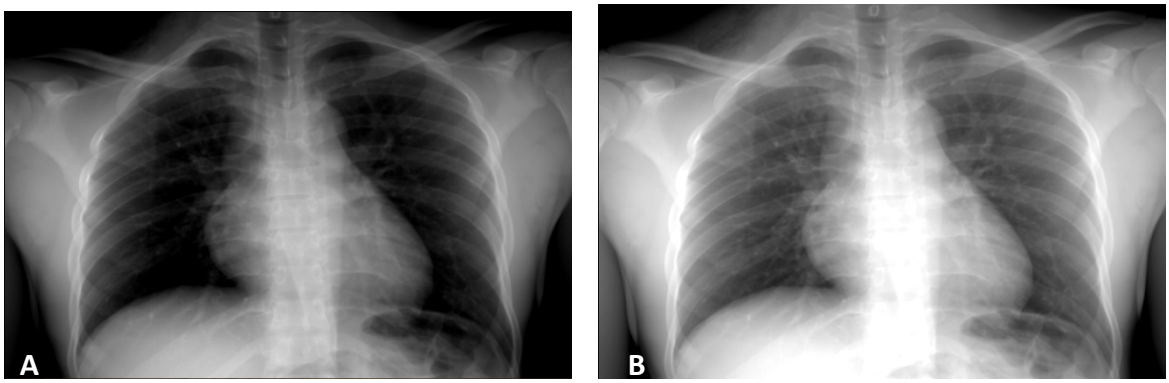

Fig 2.1. Examples of digital image manipulation to optimally demonstrate bony structures (A) and lung fields (B)

The tick-sheet provided annotated examples of images, indicating identification of various errors and normal references. Table 2.1 shows the 15 criteria used to determine the QA of the LODOX chest images.

Table 2.1 – QA Criteria

IDENTIFICATION	POSITIONING	DENSITY, CONTRAST, SHARPNESS	DOES THE FILM NEED REPEATING
No Name	Parts cut-off	Central vessels not well seen	Yes
No Hospital ID	Under-inspired	Peripheral vessels not well seen	
No age	Patient rotated	Trachea and Bronchi not well seen	
Wrong left and right marker	Scapula in the lung fields	Intervertebral disks not well seen	
	Clavicles not on the 4th rib		
	Artefacts or foreign bodies present		

Examples of these errors are shown in figure 2.2.

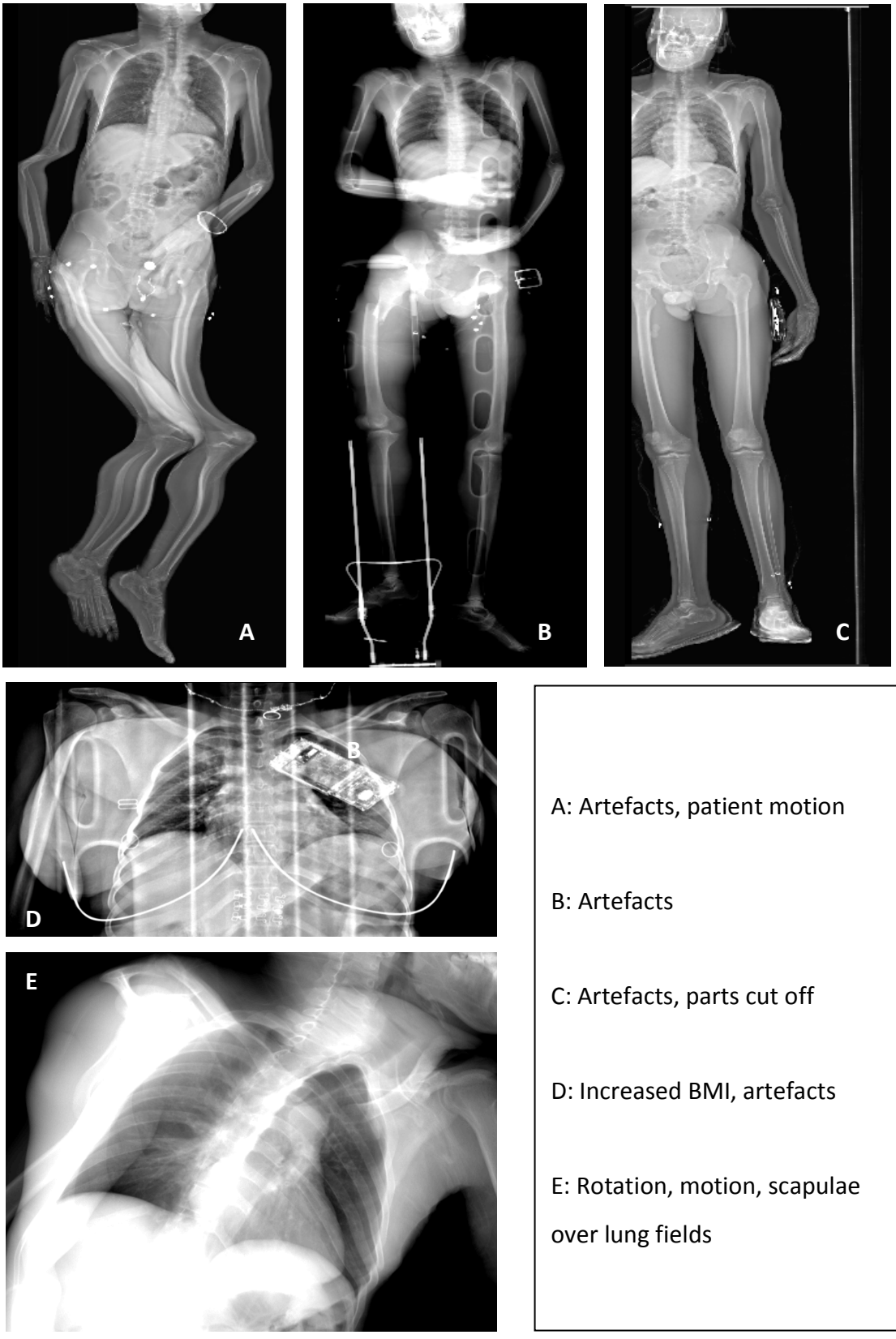

Figure 2.2. Examples or radiographic errors on LODOX in the trauma setting: Full body LODOX images A, B, C and chest images from LODOX D, E

2.3 Data collection

The data collection tick-sheet (Appendix B) was compiled from the European guidelines on quality criteria for diagnostic radiographic images (URL:http://www.sprmn.pt/legislacao/ficheiros/EuropeanGuidelineseur16260.pdf) and used in a scoring system, which is an accumulation of points for radiographic errors listed on the tick-sheet ranging from 0 (a perfect radiograph) to a maximum of 15 points (most number of errors). In addition, the categories of error allowed for recording of each type of error encountered

A common decision was determined for each radiographic error where two or three observers agreed on the presence of criteria for a specific image. The primary investigator made comments with regards to certain specifics that influenced the QA of images that appeared to be significant contributors to poor QA of the images.

Due to poor identification present on most of the cases, the identification criteria were removed for statistical analysis of the QA of the LODOX images. The reason for poor identification may be attributed to the fact that no radiographers were present to operate the LODOX imaging system. The question whether the study needed to be repeated was also omitted from the scoring system, as this didn't influence the LODOX image QA directly.

The total score was reduced to a maximum score of 10 for the worst performance image.

2.4 Data analysis

Data was entered into an excel spread sheet for Kappa analysis of the three investigators.

Categories that were scored are illustrated in Table 3.2.

2.5 Statistics

Descriptive statistics were utilized for distribution of scores achieved and frequencies of total scores achieved. Results were presented as frequencies and percentages. Fleiss Kappa values were calculated to give the reader a quantitative measure of the magnitude of agreement between observers where three or more observers were assessing the QA. Table 2.2 illustrates the interpretation of the Kappa scores.

Table 2.2 – Fleiss Kappa Score interpretation (27)

Kappa	Agreement
<0	Less than chance agreement
0.01-0.20	Slight agreement
0.21-0.40	Fair agreement
0.41-0.60	Moderate agreement
0.61-0.80	Substantial agreement
0.81-0.99	Almost perfect agreement

An inter-observer agreement was also determined where an observation was identified very rarely or very frequently, as Kappa scores are inaccurate at the extremes of the range.

2.6 LODOX Statscan QA Poster

A poster was developed to demonstrate advantageous and disadvantageous qualities of the LODOX Statscan, as well as examples of errors. Suggestions are made to correct some of these errors (Appendix C).

3. Results

3.1. General Considerations

A total of 100 LODOX images were evaluated. Patient identification on the LODOX images was very poor throughout, and was omitted for the quality assurance calculation. Results were calculated for the broad categories of a) bad positioning and b) poor density, contrast and sharpness. Comments indicating whether a study needed repeating were also omitted for score calculations but were used as a conclusive comment on quality.

Instances where Fleiss Kappa scores were not a reliable reflection of agreement between observers occurred when there was infrequent identification or high prevalence of an error. Fleiss Kappa scores depend on the proportions of subjects that have true values in each category. It is maximum when the probability of a true yes is 0.5 and as the probability gets closer to zero, the expected Fleiss Kappa becomes smaller (28). The same is true with regards to the Fleiss Kappa score when an error is recorded in almost all instances by all observers.

Because instructions in the QA sheet given to observers were not prescriptive, there appeared to be leniency with regards to radiographic errors for two of the observers. The scores indicated by the principal investigator are therefore reported in addition to the group majority decision for comparison. The principal investigator understood the restrictions of the tick-sheet, being involved in creating it.

3.2. Patient demographics

The capturing of patient identification and demographic data like age and gender was poor throughout. All patients included in this study were adults (over 18 years old) as the Charlotte Maxeke Johannesburg Academic Hospital images only adult patients on the LODOX Statscanner. It was not possible to calculate the mean and median for the ages of the patients in this study. The male to female ratio was not known.

3.3. Distribution of total scores achieved

There was no perfect score (of zero) achieved during this study. The distribution of scores is summarised in Table 3.1.

Table 3.1 Total Scores achieved

Number of errors recorded	Frequency
1	2
2	20
3	20
4	30
5	14
6	11
7	3

The scores ranged from one to seven errors out of a maximum of ten errors. The majority, 72% of cases, of images scored less than five. The best score achieved was one error, only in two

cases. The worst score was seven errors that were documented in three cases. The mean score was 3.79 and the median was 4.3.4.

3.4 Frequency of Radiographic Errors

The frequency of occurrence of the recorded radiographic errors recorded is shown in table 3.2

Table 3.2. Frequency of occurrence of radiographic errors

CRITERIA	PERCENTAGE	
	(Majority)	(Primary investigator)
SCAPULA IN THE WAY	98	89
ROTATED	78	80
UNDER INSPIRED	72	69
ARTEFACT / FOREIGN BODY	65	63
CLAVICLE NOT ON 4TH RIB (Kyphosis / Lordosis)	33	29
CENTRAL VESSELS NOT WELL SEEN	16	34
PERIPHERAL VESSELS NOT WELL SEEN	14	11
PARTS CUT-OFF	2	1
TRACHEA AND BRONCHI NOT CLEARLY SEEN	1	4
INTERVERTEBRAL DISC SPACE NOT VISIBLE	0	0

3.5. Errors per category

3.5.1 Positioning

The most frequent radiographic error, in 98% of cases, was the scapula overlying the lung fields. Two other common errors were rotation (78%) (Fig 2.2.E), under-inspiration (72%) and presence of artefacts or the presence of foreign bodies (65%) (Fig 2.2.B). Parts cut-off was identified in only two cases (2%) (Fig 2.2.C). The frequency of each type of the radiographic errors are summarised in Table 3.2.

3.5.2 Density, contrast and sharpness

The most frequent radiographic errors in this category were the central vessels not identified clearly in 16% of cases and the peripheral vessels not clearly identified in 14% of cases. Intervertebral discs and trachea / bronchi were well visualised on almost all LODOX images (99%) (Figures 2.2 A & B).

3.6. Fleiss Kappa Scores

Fleiss Kappa coefficients ranged from less than chance agreement (K = -0.01) to almost perfect (K = 0.82), but most commonly there was fair agreement (K = 0.3). An almost perfect agreement of K = 0.82 was seen with regards to the presence of "artefacts and foreign body". This was followed by "parts cut off" with a substantial agreement of K = 0.80. Slight agreement (K = 0.08) was achieved for the high frequency observation of "scapula in the way". Other areas where the Kappa scoring was low, included "trachea not visible" (K = 0.08) and "intervertebral disc spaces not visible" (K = -0.01). Fleiss Kappa scores are summarised in figure 3.3.

Table 3.3 Frequency of errors, Fleiss Kappa scores and total agreement between observers

	Frequency (%)	Fleiss Kappa	Total agreement between observers (%)
Scapula in the way	98%	0.08	86%
Rotated	78%	0.31	61%
Under-inspired	72%	0.59	74%
Artefact / Foreign Body	65%	0.82	88%
Clavicle not on 4th rib	33%	0.6	73%
Central vessels not well seen	16%	0.22	65%
Peripheral vessels not well seen	14%	0.22	61%
Parts cut-off	2%	0.8	99%
Trachea and bronchi not clearly seen	1%	0.08	92%
Intervertebral disc spaces not Well seen	0%	-0.01	98%

3.7. Frequency of radiographic errors according to the observer's common decision

Because of the low Fleiss Kappa scores for errors that occurred frequently (e.g. scapula in the way, K = 0.08) as well as errors that were very rare (e.g. trachea not visible, K = 0.08) the frequency of each radiographic error according to the common decision is also presented in Table 3.3. This shows good total agreement between observers for the abovementioned errors: scapula in the way, total agreement of 86% and trachea and bronchi not clearly seen, total agreement of 92%.

The best agreement between the three observers was for “parts cut-off” (99%) and “intervertebral discs not visible” (98%). Poor agreement between observers was achieved for “rotation” (61%) and “peripheral vessels not seen” (61%), as well as “central vessels not visualized” (65%).

3.8. Films requiring repeating

Seven LODOX images would have been rejected and would have to be repeated based on a majority reader consensus. Individual reader requests for repeat were 30 for reader one (primary investigator), eight for reader two and one for reader three.

3.9. Additional Results

An additional comment recorded that was not part of the prescribed options on the QA tick-sheet was with regards to obese patients. There were eight comments made with regards to patient obesity and in 100% of cases the film was documented to be under inspired.

4. Discussion

4.1 Results in context

Quality assurance of the LODOX chest radiographs showed no perfect radiographs and the best score documented was one error out of a possible ten (in 2% of cases). The reject rate was 7% in our study. In the context of QA this would not be a good QA score, where previous studies indicated retake rates of between 3-5% in digital imaging (29). In the context of a polytrauma patient that needs urgent imaging, this may be acceptable due to leniency with regards to the emergency setting. In the presence median score of 4 (4 errors per film) the 7% repeat rate it suggests that in our setting the observers are lenient with regards to chest radiograph quality. Gavelli showed a similar result with regards to tolerance (1).

Foos also indicated a reject rate of 9% (in-department) and 1% (portable) chest radiographs (31). This may be an indication of the degree of tolerance that is seen with regards to portable X-rays taken under suboptimal conditions in the ICU setting. In the setting of a trauma patient where the extent of the injuries is unknown and patient co-operation is limited there is a tendency to accept radiographs that would have scored poorly on the technical aspects of the study. Our reject rate of 7% may be related to increased tolerance for poor positioning in multi-trauma patients as these patients are moved as little as possible until the spine has been cleared of fractures. In a study by Whaley, et al. it was found that radiologists accepted limited quality studies and weighted their decision to accept an image more heavily on the diagnostic interpretability relative to the study indication, rather than technical quality (32).

A low Kappa score in light of a high percentage total agreement between observers was attributed to the fact that the error was recorded in almost all cases by all observers, or almost never. Kappa depends on the proportions of subjects that have true values in each category. Kappa is maximum when the probability of a true yes is 0.5; as the probability gets closer to zero, the expected kappa is smaller (28).

Previous QA evaluation (the RadLex Image Quality Rating Scale) (32) used qualitative parameters based on diagnostic and clinical descriptors (Table 4.1). Our scoring system was designed to quantify quality numerically, based on cumulative number of objective quality assurance criteria identified, unrelated to the diagnostic information available on the image. We did use one further independent criterion inquiring whether the reader would have requested a repeat radiograph for diagnostic purposes. The results of the error score vs. the repeat / reject rates show a contradicting pattern.

Table 4.1 Radlex image quality rating scale

Level	Title	Definition
1	Non-diagnostic	Little or no clinically usable diagnostic information, insufficient information to answer the primary clinical question
2	Limited	Not as much diagnostic information as is typical for an examination of this type, but likely sufficient to answer the primary clinical question
3	Diagnostic	Image quality that would be expected routinely when imaging cooperative patients
4	Exemplary	Image quality that can serve as an example

4.1.1 Parts cut-off

Studies that did not include the chest as part of the whole body assessment.

Foos demonstrated the most common reasons for rejection were due to poor positioning and parts being cut-off (31). In our study there were only two instances where parts were found to be cut-off. A 0.8 Kappa score indicating substantial agreement as well as 99% total agreement between observers. LODOX has a large field of view image capturing area that is standard. There is no option to collimate and therefore unless the patient is not positioned properly on the table, the chances of cutting of parts are limited.

4.1.2 Rotation

Rotation had a frequency of 78%. The kappa score of 0.31, indicated only fair agreement. We attribute the low Fleiss Kappa score to presumed tolerance in the trauma setting with two of readers not recording mild and moderate rotation. The primary investigator indicated rotation in 80% of cases imaged.

Images were provided on the QA tick sheet for observers, but there was still a variation in recording of errors that should not have been open to interpretation. Agreement amongst observers was low for the evaluation of rotation, despite an annotated picture clearly indicating equal distances of medial clavicle ends to the spinous process on the QA tick sheet. There was, however, no distinct training session or an additional instruction sheet for the observers.

No time is wasted to position a patient correctly or to remove overlying foreign bodies for LODOX in the trauma setting, as this investigation is typically performed as an entry point into

the trauma unit for polytrauma patients. These do not necessarily require repeat imaging but often may affect other factors such as quality visualisation of the central vessels. This appears to be the philosophy of the LODOX use at our institution where a clinician-run service aims to obtain full-body imaging without moving the patient. There is, however, no guideline restricting the reliance on uninterruptable parts of the imaging or any guideline for repeating imaging of important areas such as the chest.

4.1.3 Scapula in the way

This error was recorded in 98% of cases causing the Kappa score to reflect only slight agreement between observers. Scapulae are projected naturally over the lung field when a patient's arms are at their sides in the supine position. None of the patients in this study were imaged with the upper limbs elevated above the head. Furthermore, traumatologists are unwilling to move patient's limbs prior to evaluating for fractures - one of the main aims of the whole body imaging technique – making it an inherent quality issue in the trauma setting. This feature does not in itself result in a non-diagnostic film, despite of the possibility of disguising a pneumothorax. The primary investigator documented this error in 89% of cases.

4.1.4 Patient motion

Foos et al. reported on QA of chest radiographs that patient motion during capturing caused blurring (31). Our tick sheet recorded visibility of central and peripheral vasculature, which would incorporate motion blur. Vascularity was poorly visualized in 16% and 14% of cases in the central and peripheral vessels respectively.

4.1.5 Under Inspiration

There was moderate agreement between observers with regards to the chest being under inspired during imaging and this was recorded in 72% of cases. This was especially prevalent in patients that were obese.

4.1.6 Artefacts

Artefacts and foreign bodies were identified in 65% of cases with almost perfect agreement on the Kappa score of 0.82 and 88% total agreement. In unstable patients where bedside / mobile radiography is used there are inherent limitations of poor positioning and artefacts due to overlying monitoring equipment (1). This is an accepted part of practice that can be translated to LODOX imaging.

4.1.7 Central and peripheral vessels

Central vessels were not well visualized in 16% of cases and peripheral vessels in 14% of cases with Kappa scores of 0.22 (fair agreement) in both cases. The lower Fleiss Kappa score seen here is in correlation with the lower total agreement between observers of 65 and 61% respectively. The primary investigator indicated central vessels not clearly seen in 34% of cases and peripheral vessels not clearly seen in 11% of cases. In the majority of cases where the central vessels were not well seen, rotation was also documented. Rotation often obscures the hilar areas with an inability to clearly evaluate the central vessels i.e. a compounding effect of positional radiographic and technical errors.

4.1.8 Trachea and bronchi

The trachea and bronchi were not clearly visualized in only 1% of cases. In this particular case there was significant rotation that would account for the inability to clearly visualize the trachea and bronchi in their full extent. The Kappa score was 0.08 with an interobserver agreement of 92%. This result was also attributed to the low prevalence of the error being recorded. The primary investigator indicated poorly visualized trachea in 4% of cases. Our findings support those of Pitcher and colleagues in demonstrating that LODOX images are an excellent way of evaluating the trachea and bronchi for diagnostic purposes (22).

4.1.9 Intervertebral discs spaces

The intervertebral discs spaces were visualized in all cases evaluated with an interobserver agreement of 98%. The low Kappa score of -0.01 (less than chance agreement) is due to the error not being recorded. The primary investigator did not document any cases where the intervertebral discs spaces were not well visualized. The ability to manipulate the image contrast after capturing makes it possible to visualise the discs spaces adequately. This bodes well for using LODOX in evaluation of the spine on chest imaging.

4.1.10 Clavicle not on 4th rib

In 33% of cases this was recorded as an error. There was moderate agreement between observers (Kappa 0.6 and total agreement of 73%). There was variation between observers due to unclear guidelines with regards to the exact location of the clavicle with regards to the area of intersection with the 4th rib. The primary investigator documented this error in 29% of cases. The importance of this observation is in the evaluation of lordotic or kyphotic positioning

of the patient, which may explain specific appearances on the radiograph that may be mistaken as pathology (e.g. anterior rib deformity). This error is unlikely to be something that can be changed, as it is not recommended to flex or extend a polytrauma patient prior to excluding spinal injury.

4.2 Fleiss' Kappa scoring

The scores calculated according to the method of Viera were not reflective of the agreement amongst observers in instances where there was either a very high error-recording rate or in cases where it was a rare event (27). These included: "Scapula in the way", "Trachea visualized", "Intervertebral discs spaces visualized". For this reason, we opted to use observer agreement in these instances. Kappa depends on the proportions of subjects that have true values in each category.

4.3 Current applications

LODOX imaging is excellent in the context of Emergency Medicine as a quick screening tool to evaluate the extent of injuries in trauma patients. Studies done previously to evaluate and compare LODOX's ability to identify pathology with conventional imaging have indicated comparable and even superior image quality (21). LODOX makes it possible to acquire a full body radiograph quickly, enabling the clinician to evaluate different body segments on a digital image as indicated by the clinical setting (18). This optimizes the Golden Hour and stabilizing the patient in a goal directed fashion, having imaging available when the first review is done according to ATLS protocols (30). With regard to evaluation of the chest, whole body LODOX has significant limitations inherent to its use i.e. arms are not moved to displace the scapula

from the lung fields, spinal boards and clothing interfere as artefacts and patients are often rotated. This influences the technical quality because these factors are often not correctable prior to imaging due to fear of aggravating existing injury.

4.4 Limitations of the current study

There were some inconsistencies in the agreement between observers, especially with regards to the ability to visualize the central and peripheral vessels and the presence of rotation. These problems resulted from a combination of factors such as a lack of standard terminology and associated clarifications for QA limitations despite the use of a prescribed pictorial tick-sheet. Observer's tolerance also appeared to affect their evaluation of the presence of errors when the radiograph was still considered diagnostic. The observers with more clinical experience recorded fewer radiographic errors.

4.5 Future applications

LODOX imaging is in its infancy and according to our knowledge no previous studies have been done on this imaging modality with regards to QA of chest images. The study was limited in only including the chest component of the LODOX image. This should be extended to include the rest of the body, even though QA guidelines for other regions are not as well defined.

Quality assurance also needs to be done in the context of a qualified radiographer performing the imaging, instead of the clinician, as was the case in our study. We believe that this was a contributing factor contributing to basic QA problems such as recording of patient identification, which had to be excluded from this study. Evaluation of errors recorded through

radiographer driven QA should also be performed. Future studies with regards to QA need to include clear instructions in order to limit tolerance.

5. Conclusion

Operator dependent errors were the most frequently encountered in LODOX chest images. These were acquired without a trained radiographer in a trauma setting which posses its own challenges. There appears to be a leniency with regards to the quality of the images in this setting. The majority of the images were considered diagnostic, but many of the errors encountered are correctible through the use of proper radiographic principles and this should be targeted when training staff using LODOX equipment. Suggestions to improve QA have been created in the form of a poster for display in departments.

Appendix A: Ethics Clearance Certificate

UNIVERSITY OF THE WITWATERSRAND, JOHANNESBURG
Division of the Deputy Registrar (Research)

HUMAN RESEARCH ETHICS COMMITTEE (MEDICAL)
R14/49 Dr Maria J du Toit

CLEARANCE CERTIFICATE	**M120523**
PROJECT	Quality of Adult Chest Radiographs Using Slit Beam Radiography (LODOX) in the Trauma Setting
INVESTIGATORS	Dr Maria J du Toit.
DEPARTMENT	Department of Diagnostic Radiology
DATE CONSIDERED	25/05/2012
+DECISION OF THE COMMITTEE*	Approved unconditionally

Unless otherwise specified this ethical clearance is valid for 5 years and may be renewed upon application.

DATE 25/05/2012 **CHAIRPERSON** .....
(Professor PE Cleaton-Jones)

*Guidelines for written 'informed consent' attached where applicable
cc: Supervisor : Prof S Andronikou

DECLARATION OF INVESTIGATOR(S)
To be completed in duplicate and **ONE COPY** returned to the Secretary at Room 10004, 10th Floor, Senate House, University.
I/We fully understand the conditions under which I am/we are authorized to carry out the abovementioned research and I/we guarantee to ensure compliance with these conditions. Should any departure to be contemplated from the research procedure as approved I/we undertake to resubmit the protocol to the Committee. **I agree to a completion of a yearly progress report.**

PLEASE QUOTE THE PROTOCOL NUMBER IN ALL ENQUIRIES...

Appendix B: Quality Assessment Tick-sheet

Quality Assessment [QA] of Chest Radiographs - Adults

Date: **Name of Facility: CMJAH** **ID:** **Reviewer name:**

Please circle the "[1]" whenever a radiographic error is identified in sections A, B and C

For office use:

A] Identification: No name: **1** hospital ID**: 1** No Age**: 1** Wrong or no Left/Right marker **[1]** **/4**

B] Bad Positioning:

Parts Cut-off **[1]**

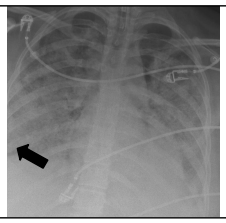

Under Inspired (< 6 ant ribs) **[1]**

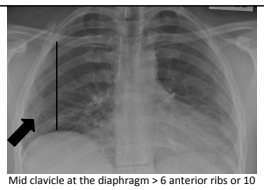

Mid clavicle at the diaphragm > 6 anterior ribs or 10 posterior ribs above the diaphragm

Rotated **[1]**

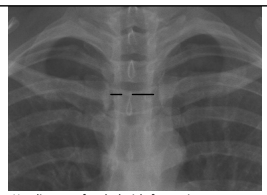

Use distance of each clavicle from spinous process

/3

Scapula in the way (> 1 cm) **[1]**

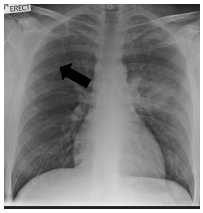

Clavicle **not** on 4th rib **[1]**

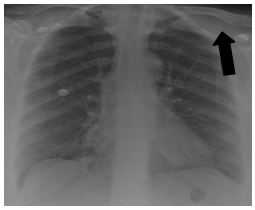

Artifact / Foreign body **[1]**

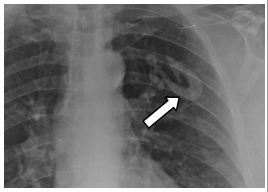

/3

C] Poor density, Contrast and Sharpness:

Central vessels not well seen **[1]**

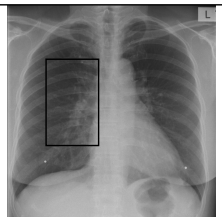

Peripheral vessels not well seen **[1]**

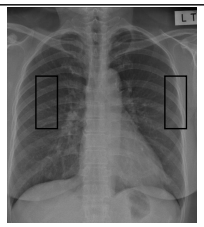

/2

Trachea and bronchi not clearly seen **[1]**

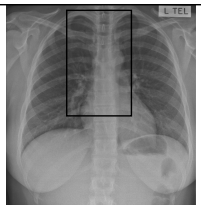

Intervertebral disk not visible **[1]**

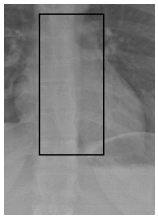

/2

Is the film un-acceptable and does it require repeating: Yes **[1]**

Any Comment:

_____

_____

Total: /15

Appendix C: Lodox Statscan Poster to improve QA

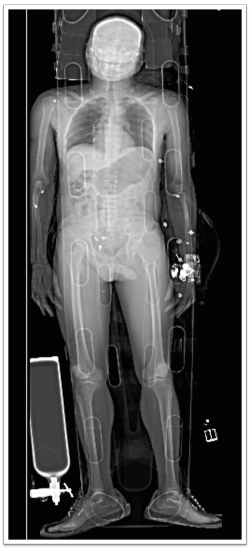

Paramedic / Ambulance Care

- Trauma patients are resuscitated, stabilized and restrained by paramedics on scene for transportation to the Emergency Unit

EU - LODOX

- Multi-trauma patients are imaged on the LODOX system, in 13 seconds, at the entry level of the EU. Patients remain on the back-board, clothes are not removed, no positioning done.

ACLS Golden Hour and beyond

- Patients are managed according to ACLS protocols, including first and second review.

Rotated

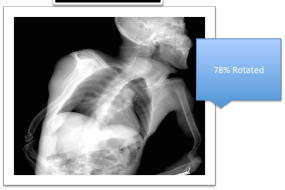

Scapula in the Way



Underinspired

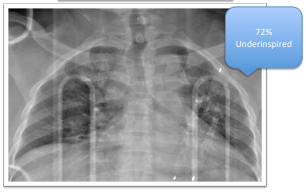

Disadvantages

- Rotated
- Scapula in the way
- Underinspired

Advantages

- Good Pulmonology Quality Image
- Good Skeletal Quality Image
- Quick Full body image
- Low Dose

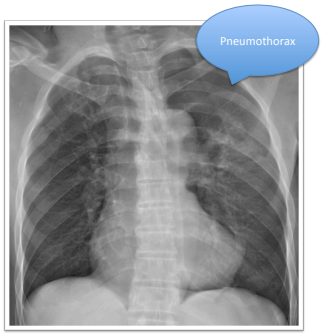

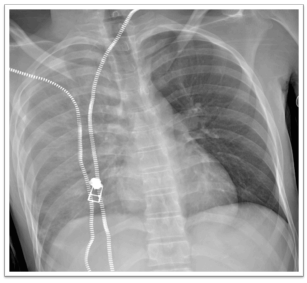

How do we improve the LODOX QA?

- Elevate the arms above the level of the head when possible
- Straighten patient of the table according to grid lines when possible
- Ask conscious patients to breath hold
- Make use of a qualified radiographer

6. References

1) Gavelli G, Canini R, Bertaccini P, Battista G, Bnà C, Fattori R. Imaging of Thoracic Injuries: Eur Radiol 2002;12:1273-94.

2) Ho M, Gutierrez FR. Chest Radiography in Thoracic Polytrauma . AJR Am J Roentgenol 2009;192:599-612.

3) Creasy JD, Chiles C, Routh WD, Dyer RB. Overview of Traumatic Injury of the Thoracic Aorta. Radiographics 1997;17:27-45.

4) Traub M, Stevenson M, McEvoy S, Briggs G, Lo SK, Leibman S, et al. The use of chest computed tomography versus chest X-ray in patients with major blunt trauma. Injury 2007; 38:43-7.

5) Surleti S, Fama F, Murabito LM, Villari SA, Bramanti CC, Gioffre Florio MA. Pneumothorax in the Emergency Room: personal caseload. G Chir 2011; 32:473-478.

6) Kuhlman JE, Pozniak MA, Collins J, Knisely BL. Radiographic and CT findings of blunt chest trauma: Aortic injuries and looking beyond them. Radiographics 1998;18:1085-1106.

7) Steenburg SD, Ravenel JG, Ikonomidis JS, Schönholz C, Reeves S. Acute Traumatic Aortic Injury: Imaging Evaluation and Management. Radiology 2008;248:748-62.

8) Petinaux B, Bhat R, Boniface K, Aristizabal J. Accuracy of radiographic readings in the emergency department. American Journal of Emergency Medicine 2011; 29:18–25.

9) Ho ML, Gutierrez FR. Chest radiography in thoracic polytrauma. AJR Am J Roentgenol 2009;192:599-612.

10) Van Hise ML, Primack SL, Israel RS, Müller NL. CT in Blunt Trauma: Indications and Limitations. Radiographics 1998;18:1071-84.

11) Kanne JP. Quality Management in Cardiopulmonary Imaging. Journal of Thoracic Imaging 2011;26:10-17

12) Cleveland RH, Schluchter M, Wood BP, Berdon WE, Boechat MI, Easley KA, et al. Chest Radiographic data acquisition and quality assurance in multi center studies. Pediatr Radiol 1997;27:880-7.

13) Lanhede B, Båth M, Kheddache S, Sund P, Björneld L, Widell M, et al. The influence of different technique factors on image quality of chest radiographs as evaluated by modified CEC image quality criteria. Br J Radiol 2002;75:38-49.

14) Chen-Yuan C, Van Cleeff M, Daley C, Date T, Enarson DA, Getahun H, et al. Handbook for district hospitals in Resource Constrained Settings on Quality Assurance of Chest Radiography: for better TB control and health system strengthening. 2008; p.8.

15) Cohen MD, Cooper ML, Piersall K and Apgar BK. Quality assurance: using the exposure index and the deviation index to monitor radiation exposure for portable chest radiographs in neonates. Pediatr Radiol 2011; 41:592–601.

16) Spelic DC, Kaczmarek RV, Hilohi MC, Moyal AE. Nationwide surveys of chest, abdomen, lumbosacral spine radiography, and upper gastrointestinal fluoroscopy: a summary of findings. Health Phys 2010;98:498-514.

17) Szucs-Farkas Z, Vock P. Image quality of supine chest radiographs: intra-individual comparison of computed radiography and low-dose linear-slit digital radiography. Eur Radiol 2009;19:2156-62.

18) Boffard KD, Goosen J, Plani F, Degiannis E Potgieter H. The Use of Low Dosage X-Ray (Lodox/Statscan) in Major Trauma: Comparison Between Low Dose X-Ray and Conventional X-Ray Techniques. J Trauma. 2006;60: 1175–1183

19) Evangelopoulos DS, von Tobel M, Cholewa D, Wolf R, Exadaktylos AK, Zachariou Z. Impact of Lodox Statscan on Radiation dose and screening time in Paediatric trauma patients. Eur J Pediatr Surg 2010;20: 382-6.

20) Beningfield S, Potgieter H, Nicol A, van As S, Bowie G, Hering E. Report on a new type of trauma full-body digital X-ray machine. Emerg Radiol 2003;10:23-9.

21) Amirlak B, Zakhary B, Weichman K, Ahluwalia H, Forse AR, Gaines RD. Novel use of LODOX Statscan in a level one-trauma center. Ulus Travma Acil Cerrahi Derg 2009; 15:521-8

22) Pitcher RD, Wilde JCH, Douglas TS, Van AS AB. The use of the Statscan digital X-ray unit in paediatric polytrauma. Pediatr Radiol 2009;39:433-437

23) Szucs-Farkas Z, Kaelin I, Flach PM, Rosskopf A, Ruder TD, Triantafyllou M, et al. Detection of chest trauma with whole-body low-dose linear slit digital radiography: A multireader study. AJR Am J Roentgenol 2010;194:388-395.

24) Schiemann U, Schaller B, Bonel H, Brunner HH, Zimmermann H, Exadaktylos AK. The use of full-body low-dosage X-ray (Lodox/Statscan) in acute medical emergencies: a preliminary experience. Intern Med J 2009;39:779-81

25) Pitcher RD, Van As AB, Sanders V, Douglas TS, Wieselthaler N, Vlok A, et al. A pilot study evaluating the “STATSCAN” digital X-ray machine in paediatric polytrauma. Emerg Radiol 2008;15:35–42.

26) Daya RB, Kibel MA, Pitcher RD, Workman L, Douglas TS, Sanders V. A pilot study evaluating erect chest imaging in children, using the Lodox Statscan digital X-ray machine. SAJR 2009;80-85

27) Viera AJ, Garrett JM. Understanding Interobserver Agreement: The Kappa Statistic. Family Medicine 2005;37:360-3.

28) Landis RJ, Koch GG. The measurement of observer agreement for categorical data. Biometrics 1977; 33:159-174

29) Waaler D, Hofmann B. Image rejects / retakes – radiographic challenges. Radiat Prot Dosimetry 2010; 139(1-3):375-9

30) Dinh MM, Bein K, Roncal S, et al. Redefining the golden hour for severe head injury in an urban setting: The effect of pre-hospital arrival times on patient outcomes. Injury, Int. J. Care Injured. 2012. doi:10.1016/j.injury.2012.01.011

31) Foos DH, Sehnert WJ, Reiner B, Siegel EL, Segal A, Waldman DL. Digital radiography reject analysis: data collection methodology, results, and recommendations from an in-depth investigation at two hospitals. J Digit Imaging 2009;22(1):89-98

32) Whaley JS, Pressman BD, Wilson JR, Bravo L, Sehnert WJ, Foos DH. Investigation of the Variability in the Assessment of Digital Chest X-ray Image Quality. J Digit Imaging 2012; 26(2):217-226