DSPACE

https://dspace.org/

Cyst wall ultrastructure of Sarcocystis (Protozoa: Coccidia) of Southern African mammals

Daly, Thomas Joseph Michael

2015-01-19
http://hdl.handle.net/10539/16606

Downloaded from a DSpace repository. https://dspace.org/

Namaqua rock mouse Aethomys namaquensis
Region: Transvaal (Eastern)
Cyst Wall Morphology: Simple, invaginated cyst wall.

SPECIMEN NUMBER(S): M79-20

C.	NO.	MIN.	MAX.	S.MN	S.S.D.	P.MN	P.S.D.
a	10	0,48	0,87	0,70	0,13	0,60 - 0,79	0,09 - 0,23
f	5	5,25	6,25	5,78	0,40	5,28 - 6,28	0,24 - 1,16
g	5	1,25	1,92	1,62	0,26	1,30 - 1,93	0,15 - 0,73
i	1			72,5			
j	1			70,0			

Red veld rat Aethomys chrysophilus
Region: Transvaal (Eastern)
Cyst Wall Morphology: Simple, invaginated cyst wall.

SPECIMEN NUMBER(S): DAS 4439

C.	NO.	MIN.	MAX.	C.MN	S.S.D.	P.MN	P.S.D.
a	12	0,22	0,57	0,40	0,11	0,33 - 0,47	0,08 - 0,18
i	1			65,0			
j	1			55,0			

ORDER: CARNIVORA
FAMILY: HYAENIDAE
SUBFAMILY: HYAENINAE
Spotted hyaena Crocuta crocuta
Region: Transvaal (Eastern)
Cyst Wall Morphology: Broad, short, palisade-like protrusions.

SPECIMEN NUMBER(S): M83-114

C.	NO.	MIN.	MAX.	S.MN	S.S.D.	P.MN	P.S.D.
a	10	0,60	1,24	0,94	0,20	0,78 - 1,09	0,15 - 0,40
b	10	1,27	1,90	1,58	0,20	1,44 - 1,73	0,14 - 0,37
c	10	0,77	1,33	1,08	0,19	0,94 - 1,21	0,13 - 0,35
f	1			9,50			
g	1			1,75			
i	1			37,5			
j	1			35,0			

Note: The merozoites were not cut in perfect section.

FAMILY: FELIDAE
SUBFAMILY: FELINAE
Lion Panthera leo
Region: Transvaal (Eastern)
Cyst Wall Morphology: Simple, invaginated cyst wall.

SPECIMEN NUMBER(S): M83-98

C.	NO.	MIN.	MAX.	S.MN	S.S.D.	P.MN	P.S.D.
a	16	0,60	1,30	0,72	0,21	0,61 - 0,83	0,16 - 0,33
f	4	2,50	4,06	2,90	0,77	1,68 - 4,13	0,44 - 2,87
g	4	0,69	0,92	0,79	0,10	0,64 - 0,95	0,06 - 0,37
i	1			187,5			
j	1			135,0			

Lioness Panthera leo
Region: Zimbabwe
Cyst Wall Morphology: Invaginated cyst wall with elongated protrusions which are circular in cross section.

SPECIMEN NUMBER(S): M86-110

C.	NO.	MIN.	MAX.	S.MN	S.S.D.	P.MN	P.S.D.
a	10	0,40	0,72	0,53	0,11	0,45 - 0,60	0,07 - 0,20
b	10	0,73	2,05	1,26	0,49	0,91 - 1,62	0,34 - 0,90
c	10	0,16	0,46	0,26	0,09	0,19 - 0,32	0,06 - 0,16
d	10	0,28	0,55	0,46	0,09	0,39 - 0,52	0,06 - 0,16
e	10	0,18	0,32	0,25	0,05	0,21 - 0,29	0,04 - 0,10
f	1			12,40			
g	1			1,50			

FAMILY: VIVERRIDAE
SUBFAMILY: VIVERRINAE
African civet Civettictis civetta
Region: Transvaal (Eastern)
Cyst Wall Morphology: Long, finger-like protrusions with fibrillar elements and smooth walls.

SPECIMEN NUMBER(S): M83-143

C.	NO.	MIN.	MAX.	S.MN	S.S.D.	P.MN	P.S.D.
a	10	0,60	0,97	0,80	0,11	0,73 - 0,88	0,08 - 0,20
b	10	3,83	4,25	4,04	0,11	3,97 - 4,12	0,08 - 0,20
c	10	0,85	1,20	1,00	0,12	0,91 - 1,08	0,08 - 0,21
f	1			7,67			
g	1			2,18			
i	1			52,5			
j	1			42,5			

Small-spotted genet Genetta genetta
Region: Transvaal (Eastern)
Cyst Wall Morphology: Simple cyst wall.

SPECIMEN NUMBER(S): TM 30568/30571/30575

C.	NO.	MIN.	MAX.	S.MN	S.S.D.	P.MN	P.S.D.
a	20	0,30	0,80	0,50	0,18	0,42 - 0,59	0,14 - 0,27
f	9	3,00	4,85	3,97	0,61	3,50 - 4,44	0,41 - 1,17
g	9	1,00	1,50	1,19	0,17	1,05 - 1,32	0,12 - 0,33

SPECIMEN NUMBER(S): TM 30568, TM 30571, TM 30575

C.	NO.	MIN.	MAX.	S.MN	S.S.D.	P.MN	P.S.D.
i	3	47,5	122,5	80,0	38,5	0,0 - 175,6	20,0 - 241,0
j	3	42,5	112,5	68,3	38,4	0,0 - 163,8	20,0 - 240,7

Large-spotted genet Genetta tigrina
Region: Transvaal (Eastern)
Cyst Wall Morphology: Simple cyst wall.

SPECIMEN NUMBER(S): TM 30518

C.	NO.	MIN.	MAX.	S.MN	S.S.D.	P.MN	P.S.D.
a	18	0,30	0,57	0,42	0,10	0,38 - 0,48	0,08 - 0,16
f	1			3,63			
g	1			1,13			
i	1			60,0			
j	1			50,0			

Note: Merozoites were not cut in perfect section. Micropores were seen in the trimembranal pellicles of merozoites.

SUBFAMILY: HERPESTINAE
Slender mongoose Galerella sanguinea
Region: Transvaal (Eastern)
Cyst Wall Morphology: Simple, invaginated cyst wall.

SPECIMEN NUMBER(S): TM 30565

C.	NO.	MIN.	MAX.	S.MN	S.S.D.	P.MN	P.S.D.
a	15	0,22	0,60	0,31	0,11	0,25 - 0,37	0,08 - 0,17
f	3	4,75	5,88	5,21	0,59	3,74 - 6,68	0,31 - 3,72
g	3	0,83	1,17	0,97	0,18	0,54 - 1,41	0,09 - 1,10
i	2	67,5	75,0	71,3	5,3	23,6 - 118,9	2,4 - 167,7
j	2	40,0	50,0	45,0	7,1	0,0 - 108,5	3,2 - 223,6

Slender mongoose Galerella sanguinea
Region: Transvaal (Eastern)
Cyst Wall Morphology: Long, slender protrusions with microtubular elements that extend into the ground substance. A thick osmiophilic layer is present beneath the invaginated cyst membrane.

SPECIMEN NUMBER(S): TM 30566

C.	NO.	MIN.	MAX.	S.MN	S.S.D.	P.MN	P.S.D.
a	12	0,80	1,20	1,00	0,12	0,92 - 1,07	0,09 - 0,21
b	2	5,80	7,53	6,67	1,22	0,00 - 17,65	0,55 - 38,68
c	2	0,67	0,67	0,67	0,00	0,67 - 0,67	0,00 - 0,00
d	10	0,84	1,64	1,08	0,29	0,88 - 1,29	0,20 - 0,52
e	10	0,44	0,72	0,60	0,09	0,53 - 0,66	0,06 - 0,16
f	2	7,75	8,00	7,88	0,18	6,29 - 9,46	0,08 - 5,59
g	2	2,00	2,50	2,25	0,35	0,00 - 5,43	0,16 - 11,18
i	1			135,0			
j	1			82,5			

ORDER: PERISSODACTYLA
FAMILY: EQUIDAE
Mountain zebra Equus zebra hartmannae
Region: Namibia
Cyst Wall Morphology: Long, slender protrusions adjacent to the cyst wall. The fibrillar elements extend into the ground substance.

SPECIMEN NUMBER(S): M82-78

C.	NO.	MIN.	MAX.	S.MN	S.S.D.	P.MN	P.S.D.
a	13	0,44	0,80	0,62	0,12	0,54 - 0,70	0,09 - 0,21
b	2	1,64	2,22	1,93	0,41	0,00 - 8,61	0,18 - 12,97
c	1			0,40			
d	4	1,27	1,60	1,51	0,16	1,25 - 1,77	0,09 - 0,60
e	4	0,40	0,48	0,43	0,03	0,38 - 0,49	0,02 - 0,13
i	1			90,0			
j	1			72,5			

Mountain zebra Equus zebra hartmannae
Region: Namibia
Cyst Wall Morphology: Long, slender protrusions adjacent to the cyst wall. The fibrillar elements extend into the ground substance.

SPECIMEN NUMBER(S): M80-164

C.	NO.	MIN.	MAX.	S.MN	S.S.D.	P.MN	P.S.D.
f	4	9,00	14,33	11,00	2,32	7,30 - 14,70	1,32 - 8,66
g	4	2,83	3,50	3,13	0,29	2,67 - 3,58	0,16 - 1,07
i	2	82,5	115,0	98,8	23,0	0,0 - 306,2	10,3 - 726,7
j	2	70,0	105,0	87,5	24,7	0,0 - 309,9	11,0 - 782,6

Mountain zebra Equus zebra hartmannae
Region: Namibia
Cyst Wall Morphology: Long, slender protrusions adjacent to the cyst wall. The fibrillar elements extend into the ground substance.

SPECIMEN NUMBER(S): M81-216

C.	NO.	MIN.	MAX.	S.MN	S.S.D.	P.MN	P.S.D.
a	3	0,73	1,22	0,90	0,28	0,21 - 1,59	0,14 - 1,74
d	5	1,13	2,00	1,45	0,37	0,99 - 1,92	0,22 - 1,08
e	5	0,50	0,67	0,57	0,07	0,48 - 0,66	0,04 - 0,21
f	3	7,40	10,20	8,98	1,43	5,42 - 12,54	0,75 - 8,97
g	3	2,20	2,80	2,50	0,30	1,75 - 3,25	0,16 - 1,88
i	3	47,5	72,5	62,5	13,2	29,6 - 95,4	6,9 - 82,8
j	3	45,0	67,5	55,8	11,3	27,8 - 83,8	5,9 - 70,6

Mountain zebra Equus zebra hartmannae
Region: Namibia
Cyst Wall Morphology: Long, slender protrusions adjacent to the cyst wall. The fibrillar elements extend into the ground substance.

SPECIMEN NUMBER(S): M82-202

C.	NO.	MIN.	MAX.	S.MN	S.S.D.	P.MN	P.S.D.
a	10	0,63	1,33	0,89	0,30	0,68 - 1,10	0,20 - 0,54
b	3	2,12	2,60	2,28	0,28	1,53 - 2,97	0,14 - 1,74
c	3	0,43	0,50	0,47	0,04	0,38 - 0,56	0,02 - 0,23
d	4	0,63	0,90	0,79	0,13	0,59 - 1,00	0,07 - 0,49
e	4	0,40	0,67	0,53	0,11	0,35 - 0,70	0,06 - 0,42
f	8	5,60	9,60	6,61	1,29	5,54 - 7,69	0,85 - 2,62
g	8	1,75	3,00	2,21	0,38	1,89 - 2,52	0,25 - 0,77
i	1			57,5			
j	1			55,0			

Mountain zebra *Equus zebra hartmannae*
Region: Namibia
Cyst Wall Morphology: Long, slender protrusions adjacent to the cyst wall. The fibrillar elements extend into the ground substance.

SPECIMEN NUMBER(S): M83-65

C.	NO.	MIN.	MAX.	S.MN	S.S.D.	P.MN	P.S.D.
a	13	0,63	1,12	0,86	0,14	0,77 - 0,94	0,10 - 0,24
d	9	0,74	2,00	1,15	0,37	0,86 - 1,44	0,25 - 0,72
e	9	0,33	0,62	0,51	0,10	0,43 - 0,58	0,07 - 0,19
f	1			10,63			
g	1			3,13			
i	1			72,5			
j	1			60,0			

Burchell's zebra *Equus burchelli*
Region: Namibia
Cyst Wall Morphology: Long, slender protrusions adjacent to the cyst wall. The fibrillar elements extend into the ground substance.

SPECIMEN NUMBER(S): M82-76

C.	NO.	MIN.	MAX.	S.MN	S.S.D.	P.MN	P.S.D.
a	18	0,60	1,56	0,95	0,21	0,84 - 1,06	0,15 - 0,31
b	7	1,46	3,33	2,51	0,67	1,89 - 3,13	0,43 - 1,47
c	7	0,40	0,55	0,47	0,04	0,43 - 0,51	0,03 - 0,10
d	7	0,75	1,24	0,92	0,17	0,76 - 1,08	0,11 - 0,38
e	7	0,63	0,75	0,68	0,04	0,64 - 0,72	0,02 - 0,08
i	1			82,5			
j	1			60,0			

ORDER: ARTIODACTYLA
FAMILY: SUIDAE
Warthog Phacochoerus aethiopicus
Region: Namibia
Cyst Wall Morphology: Short, broad, palisade-like protrusions with fibrillar elements grouped in the granular material.

SPECIMEN NUMBER(S): WART 4

C.	NO.	MIN.	MAX.	S.MN	S.S.D.	P.MN	P.S.D.
a	4	0,72	0,80	0,75	0,04	0,69 - 0,81	0,02 - 0,13
d	5	1,53	2,60	1,94	0,45	1,38 - 2,50	0,27 - 1,30
e	5	1,56	2,30	1,92	0,36	1,47 - 2,37	0,22 - 1,05
f	4	5,75	9,00	7,50	1,34	5,37 - 9,63	0,76 - 4,99
g	4	2,00	3,00	2,31	0,47	1,56 - 3,07	0,27 - 1,76
i	1			100,0			
j	1			95,0			

Warthog Phacochoerus aethiopicus
Region: Natal
Cyst Wall Morphology: Short, broad, palisade-like protrusions with fibrillar elements grouped in the granular material.

SPECIMEN NUMBER(S): M82-94

C.	NO.	MIN.	MAX.	S.MN	S.S.D.	P.MN	P.S.D.
a	6	0,58	0,75	0,67	0,06	0,61 - 0,74	0,04 - 0,14
b	3	2,17	2,40	2,27	0,12	1,98 - 2,56	0,06 - 0,73
c	3	1,07	1,20	1,14	0,07	0,98 - 1,31	0,03 - 0,42
d	5	1,70	1,95	1,85	0,09	1,73 - 1,97	0,06 - 0,27
e	5	1,25	1,55	1,41	0,13	1,25 - 1,57	0,08 - 0,37
i	1			45,0			
j	1			42,5			

Warthog Phacochoerus aethiopicus
Region: Transvaal (Eastern)
Cyst Wall Morphology: Macroscopic cyst. The protrusions are broad-based, with irregular outlines.

SPECIMEN NUMBER(S, [illegible]3-66

C.	NO.	MIN.	MAX.	S.MN	S.S.D.	P.MN	P.S.D.
a	10	0,56	2,80	[illegible]	0,62	1,23 - 2,11	0,42 - 1,12
b	4	3,25	4,30	[illegible]	0,53	2,98 - 4,67	0,30 - 1,97
c	3	4,85	8,25	6,12	1,86	1,50 - 10,73	0,97 - 11,54
f	2	9,40	11,80	10,60	1,70	0,00 - 25,85	0,76 - 53,67
g	2	2,20	2,50	2,35	0,21	0,44 - 4,26	0,09 - 8,71
i	2	970,2	1068,2	1019,2	69,3	396,5 - 1641,8	30,9 - 2191,4
j	2	588,0	852,6	720,3	187,1	0,0 - 2401,3	83,5 - 5916,6

Warthog Phacochoerus aethiopicus
Region: Zimbabwe
Cyst Wall Morphology: Short, broad, palisade-like protrusions with fibrillar elements grouped in the granular material.

SPECIMEN NUMBER(S): M83-2C

C.	NO.	MIN.	MAX.	S.MN	S.S.D.	P.MN	P.S.D.
a	5	0,47	0,73	0,62	0,10	0,49 - 0,75	0,06 - 0,29
b	7	2,53	3,06	2,87	0,19	2,59 - 3,04	0,12 - 0,41
c	7	1,00	1,40	1,14	0,15	1,00 - 1,28	0,09 - 0,32
i	1			90,0			
j	1			72,5			

FAMILY: HIPPOPOTAMIDAE
Hippopotamus Hippopotamus amphibius
Region: Transvaal (Eastern)
Cyst Wall Morphology: Long, finger-like protrusions with fibrillar elements that extend into the ground substance.

SPECIMEN NUMBER(S): M83-131

C.	NO.	MIN.	MAX.	S.MN	S.S.D.	P.MN	P.S.D.
a	9	0,80	2,12	1,21	0,46	0,86 - 1,57	0,31 - 0,[illegible]
b	12	3,80	6,20	5,09	0,72	4,[illegible] - 5,[illegible]	0,51 - 1,[illegible]
c	12	0,54	1,00	0,75	0,13	0,56 - [illegible]	0,09 - [illegible],2
f	3	8,33	11,75	10,53	1,91	5,79 - 16,26	[illegible],98 - 11,94
g	3	2,00	2,50	2,17	0,29	1,45 - 2,88	[illegible] - 1,81
i	2	60,0	62,5	61,3	1,8	45,4 - 77,1	[illegible] - 55,9
j	2	55,0	57,5	56,3	1,8	40,4 - 72,1	[illegible] - 55,9

FAMILY: GIRAFFIDAE
Giraffe Giraffa camelopardalis
Region: Namibia
Cyst Wall Morphology: Indented, flat, ribbon-like protrusions.

SPECIMEN NUMBER(S): M85-103

C.	NO.	MIN.	MAX.	S.MN	S.S.D.	P.MN	P.S.D.
a	5	0,50	0,90	0,67	0,15	0,49 - 0,86	0,09 - 0,43
b	6	1,00	1,40	1,26	0,15	1,10 - 1,42	0,09 - 0,37
c	6	0,20	0,35	0,23	0,06	0,17 - 0,29	0,04 - 0,15
h	2	0,97	1,05	1,01	0,06	0,50 - 1,52	0,03 - 1,79
i	1			100,0			
j	1			75,0			

Giraffe Giraffa camelopardalis
Region: Transvaal (Eastern)
Cyst Wall Morphology: Indented, flat, ribbon-like protrusions.

SPECIMEN NUMBER(S): M85-81

C.	NO.	MIN.	MAX.	S.MN	S.S.D.	P.MN	P.S.D.
a	5	0,27	0,45	0,35	0,07	0,26 - 0,44	0,04 - 0,21
b	5	1,30	2,80	1,76	0,60	1,02 - 2,50	0,36 - 1,72
c	5	0,10	0,45	0,19	0,15	0,01 - 0,37	0,09 - 0,42
d	5	0,87	1,47	1,09	0,24	0,79 - 1,40	0,15 - 0,70
e	5	0,40	0,60	0,53	0,08	0,43 - 0,63	0,05 - 0,22
h	5	1,07	1,70	1,26	0,26	0,94 - 1,58	0,15 - 0,74
i	1			85,0			
j	1			80,0			

FAMILY: BOVIDAE
SUBFAMILY: ALCELAPHINAE
TRIBE: CONNOCHAETINI
Blue wildebeest Connochaetes taurinus
Region: Natal
Cyst Wall Morphology: Mushroom-shaped protrusions.

SPECIMEN NUMBER(S): M82-88/204-207

C.	NO.	MIN.	MAX.	S.MN	S.S.D.	P.MN	P.S.D.
a	8	0,50	1,18	0,70	0,21	0,52 - 0,88	0,14 - 0,44
d(M)*	5	1,07	2,16	1,34	0,47	0,77 - 1,92	0,28 - 1,34
e(M)*	5	0,70	0,88	0,79	0,08	0,69 - 0,90	0,05 - 0,24
d(C)*	6	0,62	1,55	0,99	0,31	0,66 - 1,32	0,20 - 0,77
e(C)*	6	0,48	0,75	0,58	0,10	0,48 - 0,69	0,06 - 0,24
f	4	5,25	9,25	7,56	1,58	4,88 - 10,24	0,95 - 6,28
g	4	2,25	4,12	3,22	0,87	1,84 - 4,60	0,49 - 3,23

* See explanation at bottom of Table 2.

SPECIMEN NUMBER(S): M82-86, M82-204-207

C.	NO.	MIN.	MAX.	S.MN	S.S.D.	P.MN	P.S.D.
i	2	50,0	57,5	53,8	5,3	6,1 - 101,4	2,4 - 167,7
j	2	32,5	37,5	35,0	3,8	3,2 - 66,8	1,6 - 111,8

TRIBE: ALCELAPHINI

Tsessebe Damaliscus lunatus

Region: Transvaal (Northern)

Cyst Wall Morphology: Long, broad, flat, palisade-like protrusions.

SPECIMEN NUMBER(S): M85-72

C.	NO.	MIN.	MAX.	S.MN	S.S.D.	P.MN	P.S.D.
a	12	0,67	1,00	0,85	0,12	0,77 - 0,92	0,09 - 0,21
d	10	0,80	1,85	1,37	0,34	1,13 - 1,60	0,23 - 0,61
e	10	1,40	1,88	1,54	0,18	1,42 - 1,67	0,12 - 0,33
f	5	10,00	12,67	11,17	1,07	9,83 - 12,50	0,64 - 3,09
g	5	2,00	2,67	2,34	0,24	2,05 - 2,64	0,14 - 0,58
i	1			70,0			
j	1			70,0			

SUBFAMILY: ANTILOPINAE
TRIBE: ANTILOPINI
Springbuck Antidorcas marsupialis
Region: Namibia
Cyst Wall Morphology: Long, slender protrusions (tendril-like).

SPECIMEN NUMBER(S): MB3-58

C.	NO.	MIN.	MAX.	S.MN	S.S.D.	P.MN	P.S.D.
a	9	1,10	1,60	1,40	0,15	1,28 - 1,52	0,10 - 0,29
b	6	7,00	8,00	7,55	0,38	7,15 - 7,94	0,24 - 0,92
c	1			0,30			
f	3	7,67	9,67	8,67	1,00	6,19 - 11,15	0,52 - 6,26
g	3	2,33	3,00	2,67	0,34	1,83 - 3,50	0,17 - 2,10
i	1			185,0			
j	1			155,0			

SUBFAMILY: AEPYCEROTINAE
Impala Aepyceros melampus
Region: Transvaal (Eastern)
Cyst Wall Morphology: Mushroom-shaped protrusions.

SPECIMEN NUMBER(S): MB3-100/101

C.	NO.	MIN.	MAX.	S.MN	S.S.D.	P.MN	P.S.D.
a	13	0,40	1,37	0,80	0,30	0,61 - 0,98	0,21 - 0,49
d(M)*	8	1,97	3,25	2,40	0,44	2,03 - 2,77	0,29 - 0,90
e(M)*	8	0,53	0,90	0,76	0,13	0,65 - 0,87	0,09 - 0,25
d(C)*	4	1,06	1,25	1,17	0,10	1,01 - 1,32	0,06 - 0,37
e(C)*	4	0,50	0,87	0,61	0,18	0,32 - 0,89	0,10 - 0,66
f	2	8,60	8,87	8,74	0,19	7,02 - 10,45	0,09 - 6,04
g	2	2,00	2,62	2,31	0,44	0,00 - 6,25	0,20 - 13,86

* See explanation at bottom of Table 2.

SPECIMEN NUMBER(S): M83-100, M83-101

C.	NO.	MIN.	MAX.	S.MN	S.S.D.	P.MN	P.S.D.
i	2	70,0	82,5	76,3	8,8	0,0 - 155,7	3,9 - 279,5
j	2	47,5	80,0	63,8	23,0	0,0 - 270,2	10,3 - 726,7

Impala Aepyceros melampus
Region: Zimbabwe
Cyst Wall Morphology: Mushroom-shaped protrusions.

SPECIMEN NUMBER(S): M80-132/133/132+3X/135

C.	NO.	MIN.	MAX.	S.MN	S.S.D.	P.MN	P.S.D.
a	16	0,44	1,55	0,90	0,43	0,67 - 1,13	0,32 - 0,67
d(M)*	12	1,12	2,30	1,60	0,35	1,37 - 1,82	0,25 - 0,59
e(M)*	12	0,65	1,55	1,11	0,34	0,89 - 1,32	0,24 - 0,58
d(C)*	5	0,55	1,75	1,08	0,43	0,64 - 1,53	0,27 - 1,04
e(C)*	5	0,50	1,33	0,75	0,30	0,44 - 1,06	0,19 - 0,73
f	2	5,50	5,50	5,50	0,00	5,50 - 5,50	0,00 - 0,00
g	3	1,65	2,50	2,08	0,42	1,00 - 3,10	0,22 - 2,66

SPECIMEN NUMBER(S): M80-132, M80-133, M80-132+3X, M80-135

C.	NO.	MIN.	MAX.	S.MN	S.S.D.	P.MN	P.S.D.
i	5	37,5	120,0	68,5	33,8	26,5 - 110,5	20,3 - 97,2
j	5	32,5	55,0	45,0	8,3	34,7 - 55,3	5,0 - 23,8

* See explanation at bottom of Table 2.

Impala Aepyceros melampus
Region: Zimbabwe
Cyst Wall Morphology: Broad-based protrusions ("flower-shaped").

SPECIMEN NUMBER(S): M80-135X/M83-1A/4B

C.	NO.	MIN.	MAX.	S.MN	S.S.D.	P.MN	P.S.D.
a	5	0,35	0,80	0,58	0,19	0,35 - 0,82	0,11 - 0,55
b	5	0,90	3,27	1,66	0,97	0,35 - 2,77	0,58 - 2,80
c	5	0,87	2,20	1,52	0,48	0,92 - 2,12	0,29 - 1,39
f	7	6,50	8,75	7,64	0,73	6,96 - 8,32	0,47 - 1,62
g	7	1,75	3,75	2,46	0,65	1,86 - 3,07	0,42 - 1,44

SPECIMEN NUMBER(S): M80-135X, M83-1A, M83-4B(F)

C.	NO.	MIN.	MAX.	S.MN	S.S.D.	P.MN	P.S.D.
i	4	55,0	87,5	65,0	15,1	40,9 - 89,1	8,6 - 56,4
j	4	50,0	67,5	56,9	7,6	45,0 - 68,8	4,2 - 27,8
k	1			372,4			
l	1			68,6			

Impala Aepyceros melampus
Region: Zimbabwe
Cyst Wall Morphology: Long, slender, protrusions with smooth surfaces. Bean-shaped in cross section.

SPECIMEN NUMBER(S): M83-4B

C.	NO.	MIN.	MAX.	S.MN	S.S.D.	P.MN	P.S.D.
a	5	0,20	0,30	0,25	0,05	0,19 - 0,31	0,03 - 0,14
d	6	0,42	0,64	0,51	0,10	0,41 - 0,62	0,06 - 0,24
e	6	0,11	0,14	0,13	0,01	0,12 - 0,14	0,01 - 0,03
f	3	7,60	8,40	7,92	0,43	6,86 - 8,97	0,22 - 2,66
g	3	1,80	2,40	2,19	0,34	1,35 - 3,04	0,18 - 2,13

SPECIMEN NUMBER(S): MB3-48(8)

C.	NO.	MIN.	MAX.	S.MN	S.S.D.	P.MN	P.S.D.
f	1			85,0			
j	1			80,0			

SUBFAMILY: HIPPOTRAGINAE
Gemsbuck Oryx gazella
Region: Namibia
Cyst Wall Morphology: Long, slender, protrusions with smooth surfaces. Bean-shaped in cross section.

SPECIMEN NUMBER(S): MB3-43

C.	NO.	MIN.	MAX.	S.MN	S.S.D.	P.MN	
a	12	0,52	1,13	0,67	0,16	0,57 - 0,77	0,11 - 0,27
d	10	0,35	0,80	0,51	0,13	0,41 - 0,60	0,09 - 0,24
e	10	0,12	0,28	0,20	0,05	0,16 - 0,24	0,04 - 0,10
f	5	9,50	13,00	10,57	1,41	8,81 - 12,32	0,86 - 4,06
g	5	1,83	3,33	2,36	0,58	1,64 - 3,09	0,35 - 1.67
f	1			52,5			
j	1			42,5			

Note: Values for the shortest measurements of protrusions (e) were taken from the protrusions lying adjacent to the cyst wall.

SUBFAMILY: BOVINAE
TRIBE: .RAGELAPHINI
Kudu Tragelaphus strepsiceros
Region: Namibia
Cyst Wall Morphology: Long, slender, protrusions with smooth surfaces. Bean-shaped in cross section.

SPECIMEN NUMBER(S): M83-50

C.	NO.	MIN.	MAX.	S.MN	S.S.D.	P.MN	P.S.D.
a	5	0,30	0,73	0,48	0,21	0,22 - 0,75	0,13 - 0,61
d	4	0,30	0,38	0,33	0,04	0,27 - 0,40	0,02 - 0,15
e	4	0,23	0,28	0,25	0,02	0,22 - 0,29	0,01 - 0,08
f	3	8,75	13,00	10,67	2,16	5,31 - 16,02	1,12 - 13,50
g	3	2,50	4,13	3,13	0,88	0,95 - 5,51	0,46 - 5,50
i	1			55,0			
j	1			52,5			

Kudu Tragelaphus strepsiceros
Region: Transvaal (Eastern)
Cyst Wall Morphology: Long, slender, protrusions with smooth surfaces. Bean-shaped in cross section.
Cyst Location: Skeletal muscle

SPECIMEN NUMBER(S): M83-103

C.	NO.	MIN.	MAX.	S.MN	S.S.D.	P.MN	P.S.D.
a	8	0,17	0,30	0,22	0,05	0,17 - 0,26	0,04 - 0,11
d	9	0,22	0,40	0,33	0,07	0,28 - 0,38	0,05 - 0,14
e	9	0,13	0,20	0,17	0,02	0,16 - 0,19	0,01 - 0,04
f	3	7,40	10,70	8,73	1,74	4,41 - 13,05	0,91 - 10,89
g	3	1,70	2,40	2,17	0,40	1,16 - 3,17	0,21 - 2,53
i	1			52,5			
j	1			37,5			

Kudu Tragelaphus strepsiceros
Region: Transvaal (Eastern)
Cyst Wall Morphology: Long, slender, protrusions with smooth surfaces. Bean-shaped in cross section.
Cyst Location: Skeletal muscle

SPECIMEN NUMBER(S): M83-170A

C.	NO.	MIN.	MAX.	S.MN	S.S.D.	P.MN	P.S.D.
a	4	0,10	0,15	0,12	0,02	0,09 - 0,16	0,01 - 0,08
d	6	0,28	0,38	0,35	0,04	0,31 - 0,39	0,02 - 0,09
e	6	0,09	0,12	0,10	0,01	0,09 - 0,11	0,01 - 0,03
f	1			52,5			
j	1			37,5			

Kudu Tragelaphus strepsiceros
Region: Transvaal (Eastern)
Cyst Wall Morphology: Long, slender, protrusions with smooth surfaces. Bean-shaped in cross section.
Cyst Location: Cardiac muscle

SPECIMEN NUMBER(S): M83-170D

C.	NO.	MIN.	MAX.	S.MN	S.S.D.	P.MN	P.S.D.
a	4	0,23	0,37	0,27	0,07	0,16 - 0,38	0,04 - 0,26
d	6	0,27	0,38	0,33	0,04	0,28 - 0,37	0,02 - 0,09
e	6	0,13	0,23	0,16	0,04	0,12 - 0,20	0,02 - 0,09
f	1			60,0			
j	1			57,5			

Kudu Tragelaphus strepsiceros
Region: Zimbabwe
Cyst Wall Morphology: Long, finger-like protrusions with fine fibrillar elements. The protrusion surfaces are slightly indented.

SPECIMEN NUMBER(S): M83-3

C.	NO.	MIN.	MAX.	S.MN	S.S.D.	P.MN	P.S.D.
a	6	0,67	1,20	0,94	0,17	0,76 - 1,12	0,11 - 0,42
b	5	3,50	5,25	4,18	0,70	3,44 - 4,91	0,44 - 1,72
c	6	0,58	2,33	1,24	0,68	0,52 - 1,96	0,43 - 1,67
d	3	1,30	1,48	1,38	0,09	1,15 - 1,61	0,05 - 0,58
e	3	0,45	0,63	0,54	0,09	0,32 - 0,77	0,05 - 0,55
f	2	8,00	9,08	8,54	0,76	1,68 - 15,40	0,34 - 24,15
g	2	2,00	2,83	2,42	0,59	0,00 - 7,59	0,26 - 18,56
i	1			90,0			
j	1			85,0			

Bushbuck Tragelaphus scriptus
Region: Transvaal (Eastern)
Cyst Wall Morphology: Long, slender, protrusions with smooth surfaces. Circular in cross section.

SPECIMEN NUMBER(S): M83-159

C.	NO.	MIN.	MAX.	S.MN	S.S.D.	P.MN	P.S.D.
a	8	0,11	0,31	0,17	0,06	0,12 - 0,23	0,04 - 0,13
d	20	0,30	1,50	0,53	0,31	0,38 - 0,67	0,24 - 0,45
e	20	0,07	0,30	0,17	0,06	0,14 - 0,20	0,05 - 0,09
i	1			57,5			
j	1			52,5			

SUBFAMILY: REDUNCINAE

Waterbuck Kobus ellipsiprymnus

Region: Transvaal (Eastern)

Cyst Wall Morphology: Long, slender, protrusions with smooth surfaces. Bean-shaped in cross section.

SPECIMEN NUMBER(S): M83-112

C.	NO.	MIN.	MAX.	S.MN	S.S.D.	P.MN	P.S.D.
a	12	0,20	0,32	0,26	0,04	0,24 - 0,29	0,02 - 0,06
d	10	0,32	0,73	0,50	0,14	0,40 - 0,60	0,10 - 0,26
e	1			0,15			
f	2	6,67	7,17	6,92	0,35	3,74 - 10,10	0,16 - 11,18
g	2	1,56	2,33	1,95	0,53	0,00 - 6,72	0,24 - 16,77
i	1			52,5			
j	1			45,0			

Note: The merozoites were not cut in perfect section.

Lechwe Kobus leche

Region: Namibia

Cyst Wall Morphology: Mushroom-shaped protrusions.

SPECIMEN NUMBER(S): MB3-34

C.	NO.	MIN.	MAX.	S.MN	S.S.D.	P.MN	P.S.D.
a	13	0,33	0,88	0,52	0,17	0,42 - 0,62	0,12 - 0,28
d(M)*	11	0,92	1,64	1,19	0,22	1,04 - 1,34	0,16 - 0,39
e(M)*	11	0,40	0,72	0,56	0,11	0,48 - 0,63	0,08 - 0,19
d(C)*	10	0,64	1,32	0,88	0,21	0,73 - 1,03	0,14 - 0,38
e(C)*	10	0,42	0,72	0,60	0,12	0,51 - 0,68	0,08 - 0,22
f	1			8,10			
g	1			2,70			
i	1			40,0			
j	1			30,0			

* See explanation at bottom of Table 2.

Ox Bos taurus
Region: Natal
Cyst Wall Morphology: Macroscopic cat/bovine sarcocysts.
Protrusions with irregular outlines and narrow bases.
Microtubular elements radiate from the narrow bases.
Cyst Location: Skeletal muscle

SPECIMEN NUMBER(S): M82-203

C.	NO.	MIN.	MAX.	S.MN	S.S.D.	P.MN	P.S.D.
a	16	0,88	2,75	1,41	0,60	1,09 - 1,73	0,44 - 0,92
d	12	1,35	4,90	2,28	1,32	1,44 - 3,11	0,93 - 2,24
e	12	0,43	3,00	1,03	0,91	0,46 - 1,61	0,64 - 1,54
f	6	5,75	10,00	7,17	1,52	5,57 - 8,76	0,95 - 3,73
g	6	2,00	2,85	2,58	0,31	2,26 - 2,90	0,19 - 0,76
i	3	162,5	180,0	170,8	8,8	149,0 - 192,6	4,6 - 55,0
j	3	62,5	162,5	123,3	53,4	5,0 - 256,0	27,8 - 334,4

Note: The merozoites were not cut in perfect section.

Cow Bos taurus
Region: Transvaal
Cyst Wall Morphology: Microscopic dog/bovine sarcocyst.
Protrusions with smooth surfaces. Bean-shaped in cross section.
Cyst Location: Cardiac muscle

SPECIMEN NUMBER(S): M80-25

C.	NO.	MIN.	MAX.	S.MN	S.S.D.	P.MN	P.S.D.
a	15	0,18	0,41	0,31	0,07	0,27 - 0,35	0,05 - 0,11
d	4	0,20	0,48	0,32	0,12	0,12 - 0,52	0,07 - 0,46
e	4	0,10	0,20	0,13	0,05	0,05 - 0,20	0,03 - 0,19
f	1			45,0			
j	1			40,0			

Horse Equus caballus
Region: Transvaal
Cyst Wall Morphology: Long, slender, protrusions adjacent to the cyst wall. The microtubules extend into the ground substance.
Cyst Location: Oesophageal muscle

SPECIMEN NUMBER(S): M82-58

C.	NO.	MIN.	MAX.	S.MN	S.S.D.	P.MN	P.S.D.
a	8	0,60	1,40	0,91	0,32	0,64 - 1,17	0,21 - 0,64
b	4	2,10	4,20	3,46	0,93	1,98 - 4,93	0,53 - 3,46
c	4	0,50	1,00	0,77	0,23	0,41 - 1,13	0,13 - 0,84
d	5	1,20	2,20	1,57	0,41	1,06 - 2,08	0,25 - 1,19
e	5	0,37	0,67	0,45	0,13	0,29 - 0,61	0,08 - 0,36
i	2	97,5	150,0	123,8	37,1	0,0 - 457,3	16,6 - 1173,9
j	2	82,5	87,5	85,0	3,5	53,2 - 116,8	1,6 - 111,8

Pig Sus scrofa
Region: Transvaal
Cyst Wall Morphology: Long, flat, broad-based protrusions. Microtubular elements are circular in cross section.
Cyst Location: Oesophageal muscle

SPECIMEN NUMBER(S): M82-4

C.	NO.	MIN.	MAX.	S.MN	S.S.D.	P.MN	P.S.D.
c	1			2,80			
d	5	1,00	2,20	1,49	0,46	0,92 - 2,06	0,27 - 1,32
e	5	0,67	1,07	0,84	0,17	0,63 - 1,06	0,10 - 0,50
i	8	85,0	205,0	128,1	40,0	94,6 - 161,6	26,5 - 81,5
j	8	75,0	142,5	103,8	22,5	85,0 - 122,5	14,9 - 45,8

Sheep Ovis aries
Region: Natal
Cyst Wall Morphology: Microscopic sarcocysts. Wide, flat, ribbon-like protrusions.
Cyst Location: Cardiac muscle

SPECIMEN NUMBER(S): M83-190/191

C.	NO.	MIN.	MAX.	S.MN	S.S.D.	P.MN	P.S.D.
a	5	0,13	0,25	0,21	0,05	0,15 - 0,28	0,03 - 0,15
d	2	1,00	1,03	1,02	0,02	0,82 - 1,21	0,01 - 0,67
e	2	0,15	0,17	0,16	0,01	0,03 - 0,29	0,01 - 0,45
f	1			6,83			
g	1			2,50			

SPECIMEN NUMBER(S): M83-190, M83-191

C.	NO.	MIN.	MAX.	S.MN	S.S.D.	P.MN	P.S.D.
i	2	80,0	137,5	108,8	40,7	0,0 - 474,0	18,1 - 1285,7
j	2	57,5	112,5	85,0	38,9	0,0 - 434,4	17,4 - 1229,8

Note: The merozoites were not cut in perfect section. Measurements for the lengths (f) and widths (g) of the merozoites are for the longest, single merozoite found.

Sheep Ovis aries
Region: Transvaal
Cyst Wall Morphology: Microscopic sarcocyst. Wide, flat, ribbon-like protrusions.
Cyst Location: Oesophageal muscle

SPECIMEN NUMBER(S): M80-28

C.	NO.	MIN.	MAX.	S.MN	S.S.D.	P.MN	P.S.D.
a	3	0,20	0,22	0,21	0,01	0,18 - 0,24	0,01 - 0,07
d	3	0,64	0,90	0,76	0,13	0,44 - 1,09	0,07 - 0,82
e	3	0,22	0,35	0,27	0,07	0,10 - 0,44	0,04 - 0,44
i	5	40,0	140,0	73,0	38,9	24,6 - 121,4	13,3 - 112,0
j	5	40,0	95,0	60,0	21,8	32,9 - 87,1	13,1 - 62,7

Sheep Ovis aries
Region: Transvaal
Cyst Wall Morphology: Macroscopic sarcocysts. Cauliflower-like protrusions with microtubular elements.
Cyst Location: Oesophageal muscle

SPECIMEN NUMBER(S): M80-13-24

C.	NO.	MIN.	MAX.	S.MN	S.S.D.	P.MN	P.S.D.
a	5	1,57	8,75	3,26	3,08	0,00 - 7,08	1,84 - 8,84
f	6	8,00	12,00	10,52	1,63	8,80 - 12,23	1,02 - 4,00
g	6	2,20	3,00	2,58	0,35	2,22 - 2,95	0,22 - 0,86
i	1			1058,2			
j	1			862,4			

Black rat Rattus rattus
Region: Laboratory-bred (experimentally infected). Johannesburg, Transvaal.
Cyst Wall Morphology: Macroscopic rat/cat sarcocyst. Simple, invaginated cyst wall.
Cyst Location: Skeletal muscle

SPECIMEN NUMBER(S): M79-128

C.	NO.	MIN.	MAX.	S.MN	S.S.D.	P.MN	P.S.D.
a	12	0,48	0,73	0,60	0,09	0,54 - 0,66	0,06 - 0,15
i	1			150,0			
j	1			142,5			

Brown rat Rattus norvegicus albinus
Strain: Sprague-Dawley
Region: Laboratory-bred (experimentally infected). Johannesburg, Transvaal.
Cyst Wall Morphology: Macroscopic rat/cat sarcocyst. Simple, invaginated cyst wall.
Cyst Location: Skeletal muscle

SPECIMEN NUMBER(S): M79-112

C.	NO.	MIN.	MAX.	S.MN	S.S.D.	P.MN	P.S.D.
a	10	0,38	0,60	0,48	0,07	0,43 - 0,53	0,05 - 0,13
i	1			77,5			
j	1			55,0			

6. TRANSMISSION EXPERIMENTS

CAT SARCOCYSTIS TRANSMISSION EXPERIMENTS

EXPERIMENT 1

To establish a laboratory strain in order to determine the host specificity of a species of rodent Sarcocystis, two coccidia-free kittens were fed skeletal muscle from a naturally-infected black rat R. rattus on 23 February 1979. A faecal sample collected on 5 March was examined by centrifugal flotation (saturated NaCl solution, involving the bacteriological loop method*) and intact oocysts as well as free sporocysts were found. This was indicative of an early infection in the kittens. To determine the prepatent and patent periods for R. rattus/cat Sarcocystis, faecal samples which had been collected were examined retrospectively (again by centrifugal flotation) for the presence of sporocysts on the following days:

DATE OF SAMPLE	POS./NEG.	RESULT
23 February	neg.	-
24 February	neg.	-
25 February	neg.	-
26 February	neg.	-
27 February	neg.	-
28 February	neg.	-
1 March	neg.	-
2 March	pos.	oocysts
3 March	pos.	oocysts
4 March	pos.	oocysts
5 March	pos.	oocysts
9 March	neg.	-
15 March	neg.	-
9 April	pos.	sporocysts

* See materials and methods

11 April	pos.	sporocysts
5 May	pos.	sporocysts
14 May	pos.	sporocysts

Harvesting of sporocysts from faeces started from 13 March 1979. A lipid layer, resulting from the canned meat diet of the cats, obstructed the collecting of sporocysts from the centrifuge tubes. The diet was changed to tinned chicken and wet bran, which reduced the amount of fat in the faeces and allowed more efficient harvesting of sporocysts from 10 May to 3 June 1979. Cat pellets (available commercially), soaked in water or milk, were introduced into the diet between 4-25 July.

The oocysts from 2, 3 and 4 March faecal samples (which were examined retrospectively) appeared healthy and the thin oocyst walls were clearly visible. The sporozoites appeared long and thin, and the residual bodies were uncontracted, with large granules.

The prepatent period for the R. rattus/cat Sarcocystis species proved to be 7 days. To determine the patent period, selected, recently-collected faecal samples were examined for the presence of sporocysts:

DATE OF SAMPLE	POS./NEG.	RESULT
7 June	pos.	sporocysts
12 June	pos.	sporocysts
14 June	pos.	sporocysts
25 June	pos.	sporocysts
24 July	pos.	sporocyst
30 July	pos.	sporocyst
31 July	pos.	sporocyst
6 August	neg.	-
10 August	pos.	sporocyst
15 August	neg.	-
20 August	pos.	sporocyst
25 August	pos.	sporocyst
8 October	pos.	sporocyst

Bacteria were noted within sporocysts in the above samples. This

was attributed to a deterioration in the viability of sporocysts towards the end of the patent period. The s ngle sporocysts detected in the 20 August and 8 October samples appeared to have damaged or collapsed walls. A third examination of a faecal sample from 8 October revealed another defunct sporocyst. The last samples checked were examined two years after collection of the faeces; and were from 5 August (re-examination of this sample), 13 and 19 September and 1 October. They were all negative. The patent period for the R. rattus/cat Sarcocystis species is at least 7 months.

The dimensions of the sporocysts were 11,08 µm x 8,22 µm (range 9,65-11,75 µm x 7,63-8,86 µm).

EXPERIMENT 2

Two 6-week-old kittens were obtained privately, and subsequent faecal examinations for a period of 20 days revealed an absence of Isospora felis, I. rivolta, Sarcocystis or any other coccidia. The kittens were fed naturally-infected R. rattus skeletal muscle on 30 August 1979, after which faeces were collected daily for screening.

DATE OF SAMPLE	POS./NEG.	RESULT	
3 September	neg.	-	-
4 September	pos.	-	oocysts
5 September	pos.	sporocysts	oocysts
8 September	pos.	sporocysts	oocysts
9 September	pos.	sporocysts	oocysts
10 September	pos.	sporocysts	oocysts
11 September	pos.	sporocysts	-

Sarcocystis infection became patent on 4 September 1979, 5 days after the kittens had been fed infected rat muscle. Faecal samples from 6 and 7 September were kept for measurement of the sporocysts and oocysts.

Sporocysts were harvested from the faeces from 8 September to 28 November 1979, and were used to inoculate laboratory-bred R. rattus, white rats R. norvegicus and white mice M. musculus (see experiments 3, 4, 5 and 6).

was attributed to a deterioration in the viability of sporocysts towards the end of the patent period. The single sporocysts detected in the 20 August and 8 October samples appeared to have damaged or collapsed walls. A third examination of a faecal sample from 8 October revealed another defunct sporocyst. The last samples checked were examined two years after collection of the faeces; and were from 5 August (re-examination of this sample), 13 and 19 September and 1 October. They were all negative. The patent period for the R. rattus/cat Sarcocystis species is at least 7 months.

The dimensions of the sporocysts were 11,06 µm x 8,22 µm (range 9,65-11,75 µm x 7,63-8,86 µm).

EXPERIMENT 2

Two 6-week-old kittens were obtained privately, and subsequent faecal examinations for a period of 20 days revealed an absence of *Isospora felis*, *I. rivolta*, *Sarcocystis* or any other coccidia. The kittens were fed naturally-infected R. rattus skeletal muscle on 30 August 1979, after which faeces were collected daily for screening.

DATE OF SAMPLE	POS./NEG.	RESULT	
3 September	neg.	-	-
4 September	pos.	-	oocysts
5 September	pos.	sporocysts	oocysts
8 September	pos.	sporocysts	oocysts
9 September	pos.	sporocysts	oocysts
10 September	pos.	sporocysts	oocysts
11 September	pos.	sporocysts	-

Sarcocystis infection became patent on 4 September 1979, 5 days after the kittens had been fed infected rat muscle. Faecal samples from 6 and 7 September were kept for measurement of the sporocysts and oocysts.

Sporocysts were harvested from the faeces from 8 September to 28 November 1979, and were used to inoculate laboratory-bred R. rattus, white rats R. norvegicus and white mice M. musculus (see experiments 3, 4, 5 and 6).

To determine the patent period, faecal samples were examined at regular intervals from approximately 5 months after the kittens had been infected with R. rattus/cat sarcocysts:

DATE OF SAMPLE	POS./NEG.	RESULT
22 January	pos.	sporocyst (1)
23 January	pos.	sporocyst (1)
31 January	pos.	sporocyst (1)
9 February	pos.	sporocyst (1)
21 February	neg.	-
1 March	neg.	-
10 March	neg.	-
23 March	neg.	-
1 April	neg.	-
9 April	neg.	-
20 April	neg.	-

The single sporocysts located in the samples examined from January and February were difficult to find, indicating a decline in the number of sporocysts being shed at that time. The number of sporocysts seen in a single field by light microscopy is indicated in parentheses. This is the not the total number of sporocysts in a single drop of faecal/salt solution, as the slides were not fully examined. The faecal samples from 21 February to 9 April were examined 1,5 years later. Consequently, any sporocysts in the samples could have deteriorated making the result false-negative. The patent period was at least months.

EXPERIMENTS 3 AND 4

To determine the presence of Sarcocystis in and degree of invasion of the skeletal musculature of rodent hosts, six laboratory-bred R. rattus, 26 R. norvegicus and 24 M. musculus were inoculated in a controlled experiment with varying dosages of Sarcocystis sporocysts on 16 and 17 November 1979 (the details of dosages, etc., are given in the dissection results of rodent hosts to determine the presence of sarcocysts in muscle, Appendix 8).

sporocysts were less than 10 weeks old on the day of inoculation, and were administered by stomach tube. Sprague-Dawley R. norvegicus and Swiss-Webster M. musculus were used in the experiments.

The autopsies conducted 5 months later (April 1980), revealed sarcocysts in four of the inoculated black rats and in the one control animal. Sarcocysts were found in one inoculated white rat but were also found in three of 10 control animals which had been kept in the same room. Macroscopic examination for sarcocysts in skeletal muscle from the pectoral and thigh areas of 300 (three hundred) "control" R. norvegicus, which were of the same "stock" as those used in experiments 3 and 4 but had been maintained in a different animal house, was negative. All the white mice were negative for sarcocysts. It is thought that cockroaches probably transported sporocysts in the animal house, which would account for infections in control animals.

The reason why some inoculated animals did not become infected may have been because the inocula were too large (the optimum dosage for Sarcocystis muris is apparently 50 sporocysts - Blewaska, 1961). Furthermore, mouse host strain plays a role in S. muris infection in white mice (Erber, 1980 - personal communication to M. B. Markus).

Freeze-dried R. rattus/cat sarcocysts from experimentally infected rats were sent to Elizabeth Atkinson of the Department of Biochemistry, Kings College, London, for electrophoretic comparison with S. cymruensis and S. muris. However, she did not go ahead with the investigation.

EXPERIMENT 5

In an attempt to determine the distribution of Sarcocystis in the body organs of rodent hosts, two laboratory-bred R. ractus were inoculated with approximately 350 000 and 175 000 sporocysts, respectively, on 21 November 1979. Sporocysts were less than 10 weeks old on the day of inoculation and were administered by stomach tube (see dissection of R. rattus to determine the presence of Sarcocystis in body organs in Appendix 9).

Autopsies were carried out on the rats on days 13 (4 December) and 16 (7 December), respectively, after inoculation. Examination

of the tissues by light microscopy did not reveal infection in either animal in any of the following organs: mesenteric lymph nodes, spleen, kidney, heart, brain, adrenal gland, pancreas, skeletal muscle, lung or liver. Liver and lung specimens were fixed for electron microscopy but were not examined when light microscopic screening proved negative.

EXPERIMENT 6

Three laboratory-bred R. rattus were inoculated with 150 000 sporocysts by stomach tube on 3 December 1979 (there were three control rats). Sporocysts were less than 10 weeks old on the day of inoculation. One inoculated rat and one uninoculated control were dissected on 13 December (day 10 p.i.). The remaining two pairs of inoculated and control rats were examined on day 12 (15 December) and day 14 (17 December), respectively, after inoculation (see dissection of R. rattus to determine the presence of Sarcocystis in body organs in Appendix 9).

Light microscopic examination of impression smears and/or sections of mesenteric lymph node, liver, lung, adrenal gland, spleen, kidney, brain, peritoneal cavity and pancreas from the inoculated rats and the controls was negative for Sarcocystis. Liver tissue fixed for electron microscopy was not examined when light microscopic screening proved negative. An inoculated control rat killed in June 1980 (6 months p.i.), had sarcocysts in the skeletal musculature. Muscle specimens were processed for transmission electron microscopy to study the cyst wall ultrastructure.

Ruiz and Frenkel (1976) failed to transmit S. muris to rats. S. cymruensis, which has a similar cyst wall structure to that of S. muris, was infective to R. norvegicus but not to mice (Ashford, 1978). A Sarcocystis species originally located in wild R. norvegicus was infective to four out of 18 rats and one out of ten mice, when they were orally inoculated with sporozoites (Atkinson, 1978).

Sarcocystis found in black rats R. rattus in Tasmania by Munday et al. (1978), had the cat as a final host (Munday and Mason, 1981). Munday and Mason (1981) stated that sarcocysts from R.

rattus had thin walls similar to cysts found in wild mice and R. norvegicus in New Zealand (McKenna and Charleston, 1980; Collins and Charleston, 1979). In addition, the sporocysts shed by cats were of comparable size to those passed by cats after being fed infected R. norvegicus in New Zealand (Collins and Charleston, 1979). However, the Tasmanian organism was found to be moderately infective to R. norvegicus and poorly infective to mice M. musculus (Munday and Mason, 1981). McKenna and Charleston (1980) found that sporocysts from naturally infected cats produced sarcocysts morphologically similar to S. muris in mice, and not laboratory rats. The evidence suggested that this was an isolate of S. muris (McKenna and Charleston, 1980). The authors suggested that despite morphological similarities of the cysts found in wild mice and R. norvegicus (Collins and Charleston, 1979) to S. muris, and the fact that both S. muris and the organism in R. norvegicus have the cat as a definitive host, the failure to infect R. norvegicus with their isolate of S. muris makes it possible that distinct species of Sarcocystis are involved.

The species of Sarcocystis isolated in this study was found to be infective to R. rattus, moderately infective to R. norvegicus and not infective to mice. These findings agree with those of Munday and Mason (1981), for their Sarcocystis species located in R. rattus in Tasmania. The isolate used in the transmission study in my laboratory was originally derived from the skeletal muscles of wild-caught R. rattus.

Whether the high dosages given to R. norvegicus in the present study resulted in a marked immune reaction on the part of the host to Sarcocystis infection, is not known. Only one of the inoculated albino rats had sarcocysts present in its muscles. Some control rats, which must have ingested only a minimal number of sporocysts, became infected. As the rats and mice in the present study were not immunosuppresed in order to increase the intensity of infection (Blewaska, 1981), it is possible that the high dosages used drastically reduced both the number of patent infections in rodents and the number of muscle cysts in infected animals. Blewaska (1981) found that the administration of 500 or more sporocysts of S. muris in NMRI-mice resulted in reduced infection rates and grades of infection.

The contamination of the control rats was not surprising because they were housed in the same room as the inoculated rats, where there were numerous resident cockroaches (attempts to eliminate the cockroaches had been unsuccessful). The presence of sarcocysts in three of the control R. norvegicus, in spite of the low dosages they must have recieved, is interesting. Blewaska (1981) found that inocula of less than 50 sporocysts in NMRI-mice resulted in lower infection rates than in animals which recieved 50 sporocysts, but in equ.. grades of infection. In the present study, the intensity of infection based on the number of muscle cysts in the infected control animals varied from light to heavy, and may have been related to the number of sporocysts ingested.

EXPERIMENT 7

Four Sarcocystis-positive R. norvegicus that had been inoculated in the laboratory with sporocysts from kittens (infected with Sarcocystis on 30 August 1979), were fed to two pairs of kittens. This was the same species of Sarcocystis which was being passaged through the final host for the second time.

One pair of cats were fed their first meal of infected white rat (M79-47) on 10 April 1980. The second pair were fed infected white rat (M79-75, M79-114 and M79-112) on 17 April 1980. Selected faecal samples were subsequently examined for the presence of sporocysts.

DATE OF SAMPLE	POS./NEG.	RESULT
13 April)	neg.	(I. felis present)
15 April) 1st	neg.	- -
16 April) pair	neg.	- -
20 April)	neg.	- -
22 April)	pos.	sporocysts and oocysts of Sarcocystis
15 April)	neg.	(I. felis present)
22 April) 2nd	neg.	- -
24 April) pair	pos.	- oocysts of Sarcocystis

29 April)	both pairs	pos.	sporocysts and oocysts of Sarcocystis

The prepatent period for the rat/cat Sarcocystis infection was between 7 and 11 days. Sporocysts were harvested from faecal samples of both cat pairs from 29 April to 15 May 1980. Faecal examinations for samples from 13 April to 20 April for the first pair of cats and 15 and 24 April for the second pair of cats, were carried out in October 1981. Although the faeces were examined 1,5 years later, an intact oocyst was nevertheless found during a complete scan of the slide from 24 April 1980 sample.

During the period of Ph.D. registration, attempted transmission experiments involving Besnoitia sp. (from zebras), Isospora felis and Toxoplasma gondii were carried out. Details of the Besnoitia and Toxoplasma work are not given here because they are irrelevant to the subject of this thesis. However, some routine information on I. felis is included because a short paper is bound into the thesis as supplementary material. Collaborative research was involved. However, I carried out all electron microscopic work and was responsible for all faecal examinations and harvesting of oocysts.

ISOSPORA FELIS TRANSMISSION EXPERIMENTS

EXPERIMENT 8

Coccidia-free kittens kept in the laboratory from August 1979 produced a large number of I. felis oocysts on 25 January 1980, following oral inoculation with sporulated oocysts. Faeces were collected, and oocysts were harvested and concentrated for further transmission to cats. Faeces were screened by centrifugal flotation (with use of a saturated NaCl solution) on the following days:

DATE OF SAMPLE	POS./NEG.	RESULT
22 January	neg.	-
23 January	neg.	-
24 January	pos.	few oocysts

25 January	pos.	many oocysts
27 January	pos.	many oocysts
29 January	pos.	many oocysts
31 January	pos.	many oocysts
2 February	pos.	few oocysts
3 February	pos.	few oocysts
4 February	pos.	few oocysts
5 February	pos.	few oocysts
6 February	pos.	few oocysts
7 February	pos.	isolated oocysts
8 February	pos.	isolated oocysts
9 February	pos.	isolated oocysts
10 February	neg.	-
11 February	neg.	-

The patent period for the I. felis infection was 17 days. Oocysts were harvested from 24 January to 9 February 1980.

EXPERIMENT 9

Two kittens were inoculated with I. felis on 8 November 1980, after faecal screening had revealed an absence of both I. felis and I. rivolta. The following faecal examinations were carried out (direct examination, without concentrating oocysts):

DATE OF SAMPLE	POS./NEG.	RESULT
10 November	neg.	-
14 November	neg.	-
16 November	pos.	oocysts
17 November	pos.	oocysts
23 November	pos.	oocysts

Harvesting of oocysts started from 16 November 1980. A faecal flotation on 9 December revealed a single oocyst and harvesting then ceased, as this was effectively the end of the patent period (24 days). The prepatent period for the infection was 8 days.

A second pair of kittens, born on 29 September 1980, had numerous pre-inoculation faecal scans, some of these on the following widely-spaced dates:

DATE OF SAMPLE	POS./NEG.
8+10 November	neg.
22 November	neg.
23 November	neg.
29+30 November	neg.
6+7 December	neg.

One kitten was inoculated with 39 million sporulated I. felis oocysts on 15 December 1980; the other was kept as a control. The control kitten was housed in the same room as the experimental kitten, and contamination of the room occurred when the inoculated animal vomited. In view of this situation, the control was then also given a predetermined dose (of 13 million I. felis oocysts) on 16 December 1980.

Oocysts were counted by means of a haemocytometer:

Bottle 1: 7 500 000 oocysts per ml

Bottle 2: 5 345 000 oocysts per ml

The contents of each bottle were added together and the first cat (M80-141) recieved 6 ml of the concentrate (39 million oocysts), while the second cat (M80-142) recieved 2 ml of concentrate.

A faecal flotation from faeces passed soon after inoculation revealed damaged and undamaged oocysts. Sporulated oocysts were present which were not, therefore, from a patent infection. The regurgitate from the first inoculated cat was checked by direct examination, and many damaged and undamaged oocysts were found.

Autopsies were carried out on both cats on 19 December 1980; 100 hours after inoculation. The mesenteric lymph nodes (MLN) showed apparent oedema. Impression smears were made from MLN from each cat and pieces were placed in neutral-buffered formal-saline and Karnovsky's fixative, respectively, for subsequent examination (which has not yet been carried out).

The small intestine of each cat, from the end of the duodenum to the beginning of the caecum, was removed. Pieces of tissue from two

broadly-defined areas along this section were placed in Karnovsky's fixative (Table 6). The remaining intestine was placed in neutral-buffered formal-saline and pieces were later removed for light microscopy.

Formal-saline-fixed tissue from the jejenum was placed in glutaraldehyde briefly (not that this was necessary) on 17 February 1981 and thereafter processed and examined by transmission electron microscopy for enteric stages of I. felis. Endodyogeny was observed (Daly and Markus, 1981: see research abstract bound in this thesis as supplementary material in support of PhD candidature).

TABLE 6: *Fixation of mesenteric lymp node and intestine from kittens M80-141 and M80-142.*

	KARNOVSKY		NEUTRAL-BUFFERED FORMAL-SALINE	
	M80-141	M80-142	M80-141	M80-142
0°C	3,5 hrs	2,5 hrs	6 hrs	2,5 hrs
4°C	-	-	46 hrs	70 hrs
Room temp. (r.t.)	-	-	Then r.t.	Then r.t.
	Processing of tissue for transmission electron microscopy was according to routine schedule - see materials and methods		Processing of tissue for light microscopy was according to routine schedule - *see materials* and methods	

Note: r.t. = *room temperature.*

DOG SARCOCYSTIS TRANSMISSION EXPERIMENTS

EXPERIMENT 10

Fresh bovine hearts were obtained from the Johannesburg abattoir and checked (fresh tissue: squash technique) for the presence of sarcocysts. Positive hearts from a 1,5- and 3-year-old animal, respectively, were stripped of all connective tissue and minced (hand mincer). The meat was fed to four coccidia-free puppies on 16 March 1979. Harvesting techniques were subsequently tested on the faeces of the infected animals.

EXPERIMENT 11

Two cross dalmatian/pointer puppies, obtained privately, showed a high natural infection of Sarcocystis on examination of their faeces. On 14 May 1979, the intestine of one of the 12-week-old dogs was removed. The posterior two-thirds of the small intestine (i.e. jejunum and ileum) was cut into 4 cm lengths and scraped, with use of a glass microscope slide, in clean water. Some sections contained undigested food but these were washed in water before being scraped. Many sporocysts were present in the settled suspension (a mean of 600 sporocysts and 47 oocysts per drop was found, i.e. 42 000 sporocysts per ml).

To concentrate sporocysts from the scrapings, half of the material was placed in a Waring blender for 5 seconds before being sieved and the other half was sieved through gauze and allowed to settle. Four drops of a combined, diluted concentrate of the sieved material were examined microscopically and a mean of 52 sporocysts and 35 oocysts per drop was found. Two bottles of sporocysts from the gut scrapings contained 22 800 per ml and 13 300 per ml, respectively. These techniques proved to be suitable for the calf inoculation experiment reported below.

Sporocysts were harvested from the faeces of both dogs by centrifugal flotation. Two bottles of washed sporocysts contained 23 050 per ml and 11 600 per ml, respectively. A Swiss-Webster white mouse was inoculated by stomach tube with doses of up to 1ml of the combined concentrate, and recieved a total of 310 900

sporocysts over a period of 14 days. Five days after the last inoculation, the mouse was killed. Examination of Giemsa-stained impression smears and formal-saline-fixed mesenteric lymph node, spleen, liver, lung, kidney and brain did not reveal any hypnozoite-like stages of the parasite (cf. Isospora spp. - vide Markus, 1978b).

This was a joint experiment with M. B. Markus, which was supplementary to the subject of this thesis.

EXPERIMENT 12

Some Sarcocystis species infecting domestic animals are known to have a debilitating, and in acute infections, a fatal effect on their intermediate hosts. S. cruzi of cattle, as well as certain Sarcocystis species occurring in sheep, goats and pigs are responsible for reproductive losses due to abortion and reduced weight gain of the intermediate host (Herbert and Smith, 1987). The clinical effects of sarcocystosis on the intermediate host have been reported from various countries on different continents, including Canada, Europe, the United States, Australia and the United Kingdom (Markus, 1978a).

Experiment 12 was carried out in order to determine whether S. cruzi in South Africa is also pathogenic for the bovine intermediate host.

A bovine heart heavily infected with Sarcocystis was stripped of all connective tissue and minced in a hand mincer. This meat was fed, on 21 March 1980, to two, 6-week-old cross labrador/ridgeback puppies which had not been fed raw meat or dewormed. Faecal flotations from the dogs had shown them to be coccidia-free. Sporocysts, 16,05 µm x 10,71 µm in size and some oocysts, which measured 20,09 µm x 15,56 µm, were passed in the faeces 7-8 days after ingestion of the meat.

The two dogs were killed on 8 April 1980 (19 days p.i.). The posterior colon was removed and placed at 4°C together with the anterior duodenum. The ileum and jejunum of each gut was scraped, washed several times in distilled water, and sieved through gauze before being stored in the refrigerator.

On 23 April 1980, a single calf was given (per os) 2x300 ml of

blended dog gut scrapings containing over 1 million sporocysts. The 600 ml of inoculum was mixed with 400 ml of powdered milk and was administered in a bottle in two doses of 500 ml. A second calf was kept as a control animal.

On day 27 p.i., the inoculated calf became weak and it died on day 28 p.i. of acute sarcocystosis. Schizonts were found in the endothelial cells of blood vessels in various tissues. Schizonts in the brain (Figure 114) were examined by electron microscopy (Figure 115), involving a technique which is described in the materials and methods section of this thesis. Parasitized host cells possessed a broad basal lamina and were electron-pale. In some sections, the host cell nucleus was seen as a crescent-shaped structure at the periphery of the cell. Organisms identified as young second-generation schizonts had an irregularly-shaped nucleus and were surrounded by a double pellicular membrane. Intermediate-aged second-generation schizonts had an enlarged, lobed nucleus and an infolded, double pellicular membrane. Single unit membranes associated with the developing apical complex of each merozoite, appeared around the lobes of the enlarged parasite nucleus. However, intranuclear spindles at the outer edges of the nuclear lobes, each of which extend between two developing apical complexes (Dubey et al., 1980), could not be distinguished.

Endopolygeny in second-generation schizonts of S. cruzi involves the enlargement of the nucleus to form numerous lobes. All merozoites associated with the nuclear lobes bud from a central area within the schizont. Dubey et al. (1980) described the formation of first-generation merozoites from 2-4 residual bodies. Their presence indicated that mitotic division had taken place previously, and that each nucleus became part of a centrally-located residual body.

In the present study, mature second-generation schizonts were examined ultrastructurally (Figure 115) and, although the formation of merozoites was found to be similar to that described by Dubey et al. (1980) for first-generation merozoites, the development of second-generation merozoites from a single central area within the schizont is not known to occur. Unlike first-generation schizonts, very little residual cytoplasm was evident within the mature schizonts examined. This indicated that most of the cytoplasm of

the schizont had been incorporated into the merozoites. Schizonts examined in the present study were lying free within the host cell cytoplasm, and were not apparently surrounded by a parasitophorous vacuole.

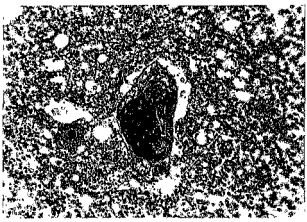

FIGURE 114: Light photomicrograph of a schizont in an endothelial cell in the brain of a calf Bos taurus which had died of acute sarcocystosis. x1000. Fixation: formal-saline; stain: toluidine blue (semi-thin section).

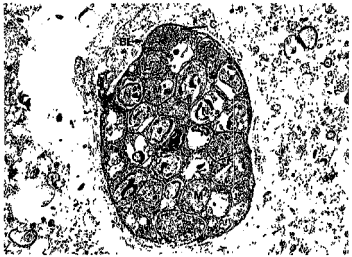

FIGURE 115: Transmission electron micrograph of a schizont in brain tissue of a calf Bos taurus which had died of acute sarcocystosis. x6000. Fixation: formal-saline.

ZEBRA-DOG SARCOCYSTIS TRANSMISSION EXPERIMENT

EXPERIMENT 13

Ultrastructurally, the cyst wall of a Sarcocystis species of the mountain zebra Equus zebra hartmannae was found to be morphologically similar to sarcocysts of the domestic horse (Figures 87 and 88). As the domestic dog was known to be a final host of horse Sarcocystis in Europe and the United States, it was decided to attempt transmission of zebra Sarcocystis to the dog. The transmission work involved collaborative research with M. B. Markus and H. C. Biggs. I participated in the feeding of meat to the dogs (and the post mortems on the dogs), examined the cysts in the meat ultrastructurally, and screened the faeces of the puppies.

Sarcocystis-infected mountain zebra meat (containing the same kind of sarcocyst as had been found previously), collected in the *vicinity of Windhoek, Namibia, was fed* to four coccidia-free puppies which had never eaten raw meat, namely two from each of two litters (8-week-old cross weimaraner/doberman pups and 6-week-old cross labrador/rottweiler *pups, respectively). A litter-mate puppy* from each litter was used as a control animal. The faeces of the control puppies were examined daily for seven weeks after commencement of the experiment. They remained coccidia-free throughout this time. Sporulated oocysts of Sarcocystis were present in the intestinal villi of two experimental puppies examined after 9,5 days, although stages of the parasite had not yet appeared in their faeces. The prepatent period in the other two experimental puppies was more than 9,5 but less than 10,5 days. Fifteen sporocysts measured 12,3 µm x 9,2 µm (range 10,9-13,1 µm x 8,9-9,5 µm).

Oocysts and sporocysts were harvested from the intestinal mucosa of the experimental puppies by a modification of the technique used by Heydorn et al. (1981). These sporocysts were to have been used *for attempted transmission of zebra* Sarcocystis to the domestic horse. However, experimental horses were not available; and the number of sporocysts obtained was in any case probably not large enough to *cause changes in temperature in experimentally infected* horses (as has been done with horse/dog sporocysts by recent

workers).

Although the most likely natural definitive host of the *Sarcocystis* species occurring in zebra is the black-backed jackal Canis mesomelas, the present investigation showed that the domestic dog may be "substituted" for a feral (probably canid) host. If the *Sarcocystis species in both wild and domestic equine* hosts is the same, then both the feral final host and the domestic dog are definitive hosts of this species.

IMPALA-VULTURE SARCOCYSTIS TRANSMISSION EXPERIMENT

EXPERIMENT 14

I screened faecal samples from vultures which had been infected with Sarcocystis of the impala Aepyceros melampus by M. B. Markus and P. J. Mundy (see Markus et al., 1985); and examined, by electron microscopy, the cyst types present in the infective material. The electron microscopic results are reported elsewhere in this thesis.

Thirty (30) sporocysts measured 13,0 µm x 10,1 µm (range 9,9-14,4 µm x 9,2-11,1 µm).

CAT-OVINE SARCOCYSTIS TRANSMISSION EXPERIMENT

EXPERIMENT 15

Twelve sheep oesophagi (M80-13 to 24) were obtained from the Johannesburg abattoir on 2 June 1980. Large Sarcocystis macrocysts of the sheep/cat type were present in some oesophagi (thick-walled microcysts of the sheep/dog type were also found in some of the oesophagi). Several macrocysts were fixed in glutaraldehyde for transmission electron microscopy. Other macrocysts were dissected out of infected sheep oesophagi (after storage, briefly, at 4°C) and were fed to two kittens on 5 June 1980, after examination of their faeces had revealed an absence of Sarcocystis. The kittens subsequently developed patent infections. The prepatent period was *approximately* 6 days and the patent period was at least 28 days.

6. REFERENCES

ASHFORD, R. W. 1977. The fox, Vulpes vulpes, as a final host for Sarcocystis of sheep. Annals of Tropical Medicine and Parasitology 71 : 29-34.

ASHFORD, R. W. 1978. Sarcocystis cymruensis n. sp., a parasite of rats Rattus norvegicus and cats Felis catus. Annals of Tropical Medicine and Parasitology 72 : 37-43.

ASHFORD, R. W. and BRITT, D. P. 1983. Nomenclature of Sarcocystis species infecting sheep. Veterinary Record 113 : 574-575.

ARYEETEY, M. E. 1979. Morphologische und serologische Untersuchungen an Sarkosporidien (Protozoa, Sporozoa). *Inaugural-Dissertation zur Erlangung des Doktorgrades der* Mathematisch-Naturwissenschaftlichen Fakultät der Universität Düsseldorf.

ARYEETEY, M., MEHLHORN, H. and HEYDORN, A. O. 1980. Electron microscopic studies on the development of Sarcocystis capracanis in experimentally infected goats. Zentralblatt für Bakteriologie, Mikrobiologie und Hygiene, I. Abteilung Originale A247 : 543-556.

ATKINSON, E. M. 1978. A Sarcocystis species of rats. Journal of Protozoology 25 : 138.

BEAVER, P. C. and MALECKAR, J. R. 1981. Sarcocystis singaporensis Zaman and Colley, (1975) 1976, Sarcocystis villivillosi sp. n., and Sarcocystis zamani sp. n.: development, morphology, and persistence in the laboratory rat, Rattus norvegicus. Journal of Parasitology 67 : 241-255.

BECKER, B., MEHLHORN, H. and HEYDORN, A. O. 1979. Light and electron microscopic studies on gamogony and sporogony of 5 Sarcocystis species in vivo and in tissue cultures. Zentralblatt für Bakteriologie, Mikrobiologie und Hygiene, I. Abteilung Originale A244 : 394-404.

BERGMANN, V. and KINDER, E. 1975. Unterschiede in der Struktur der Zystenwand bei Sarkozysten des Schafes. Monatshefte für Veterinärmedizin 30 : 772-774.

BLEDSOE, B. 1979. Sporogony of Sarcocystis idahoensis in the gopher snake, Pituophis melanoleucus (Daudin). Journal of Parasitology 65 : 875-879.

BLEDSOE, B. 1980a. Sarcocystis idahoensis sp. n. in deer mice Peromyscus maniculatus (Wagner) and gopher snakes Pituophis melanoleucus (Daudin). Journal of Parasitology 27 : 93-102.

BLEDSOE, B. 1980b. Transmission studies with Sarcocystis idahoensis of deer mice Peromyscus maniculatus and gopher snakes Pituophis melanoleucus. Journal of Wildlife Diseases 16 : 195-200.

BLEWASKA, S. 1981. Versuche zur Steigerung der Befallsextensität und -intensität der Sarcocystis muris-Infektion. Inaugural-Dissertation zur Erlangung des Grades eines Doctor Medicinae Veterinariae durch die Tierärztliche Hochschule Hannover.

BÖTTNER, A. 1984. Vorkommen sowie licht- und elektronenmikroskopische Differenzierung von Sarkosporidienarten bei Schlachtrindern auf der Nordinsel Neuseelands. Inaugural-Dissertation zur Erlangung des Grades eines Doctor Medicinae Veterinariae. Aus dem Institut für Parasitologie der Tierärztlichen Hochschule Hannover und dem Department of Pathology and Public Health der Massey University, Palmerston North.

BOTTNER, A., CHARLESTON, W. A. G. and HOPCROFT, D. 1987a. The structure and identity of macroscopically visible Sarcocystis cysts in cattle. Veterinary Parasitology 24 : 35-46.

BOTTNER, A., CHARLESTON, W. A. G., POMROY, W. E. and ROMMEL, M. 1987b. The prevalence and identity of Sarcocystis in beef cattle in New Zealand. Veterinary Parasitology 24 : 157-168.

BREHM, H. 1979. Untersuchungen über die Entwicklung von Sarcocystis singaporensis Zaman und Colley, 1976 in der Ratte (Rattus norvegicus Berkenhout, 1769) und in dem Netzpython (Python reticulatus Schneider, 1801). Inaugural-Dissertation zur Erlangung der tiermedizinischen Doktorwürde des Fachbereichs Tiermedizin der Ludwig-Maximilians-Universität München.

BREHM, H. and FRANK, W. 1980. Der Entwicklungskreislauf von Sarcocystis singaporensis Zaman und Colley, 1976 im End- und Zwischenwirt. Zeitschrift für Parasitenkunde 62 : 15-30.

BRITT, D. P. and BAKER, J. R. 1983. Cysts of Sarcocystis tenella in North Ronaldsay sheep. Veterinary Record 113 : 516.

CAWTHORN, R. J., WOBESER, G. A. and GAJADHAR, A. A. 1983. Description of Sarcocystis campestris sp. n. (Protozoa: Sarcocystidae): a parasite of the badger Taxidea taxus with experimental transmission to the Richardson's ground squirrel, Spermophilus richardsonii. Canadian Journal of Zoology 61 : 370-377.

CAWTHORN, R. J., GAJADHAR, A. A. and BROOKS, R. J. 1984. Description of Sarcocystis rauschorum sp. n. (Protozoa: Sarcocystidae) with experimental cyclic transmission between varying lemmings (Dicrostonyx richardsoni) and snowy owls (Nyctea scandiaca). Canadian Journal of Zoology 62 : 217-225.

ČERNÁ, Z. 1982. Laboratory models in the study of sarcosporidia. Journal of Protozoology 29 : 299.

ČERNÁ, Z. 1983. Multiplication of merozoites of Sarcocystis dispersa Cerna, Kolarova et Šulc, 1978 and Sarcocystis cernae Levine, 1977 in the blood stream of the intermediate host. Folia Parasitologica (Praha) 30 : 5-8.

ČERNÁ, Z. 1984. The role of birds as definitive hosts and intermediate hosts of heteroxenous coccidians. Journal of Protozoology 31 : 579-581.

ČERNÁ, Z. and LOUČKOVÁ, M. 1976. Microtus arvalis as the intermediate host of a coccidian from the kestrel (Falco tinnunculus). Folia Parasitologica (Praha) 23 : 110.

ČERNÁ, Z. and SENAUD, J. 1977. Sur un type nouveau de multiplication asexuée d'une sarcosporidie, dans le foie de la souris. Comptes rendus hebdomadaires des Séances de l'Académie des Sciences, Paris D285 : 347-349.

ČERNÁ, Z., KOLÁŘOVÁ, I. and ŠULC, P. 1978a. Contribution to the problem of cyst-producing coccidians. Folia Parasitologica (Praha) 25 : 9-16.

ČERNÁ, Z., KOLÁŘOVÁ, I. and ŠULC, P. 1978b. Sarcocystis cernae Levine, 1977, excystation, life-cycle and comparison with other heteroxenous coccidians from rodents and birds. Folia Parasitologica (Praha) 25 : 201-207.

ČERNÁ, Z. and ALLY, A. B. 1979. Two sarcosporidian species from Microtus arvalis. Journal of Protozoology 26 : 40A.

ČERNÁ, Z., KOLÁŘOVÁ, I. and KOLÁŘOVÁ, L. 1982. What we know about the sarcosporidia of carnivorous birds. Journal of Protozoology 29 : 505.

ČERNÁ, Z. and KVAŠŇOVSKÁ, Z. 1986. Life cycle involving bird-bird relation in Sarcocystis coccidia with the description of Sarcocystis accipitris sp. n. Folia Parasitologica (Praha) 33 : 305-309.

CERVÁ, L. and ČERNÁ, Z. 1982. Indirect haemagglutination reaction with Sarcocystis dispersa antigen. Folia Parasitologica (Praha) 29 : 219-226.

CHARLESTON, W. A. G. and BOTTNER, A. 1986. Structural features of macroscopic sarcocysts from cattle revealed by electron microscopy. Proceedings of the 6th International Congress of Parasitology (Brisbane, Australia) : 108.

COLLINS, G. H. 1981. Sarcocystis in rats from Stewart Island. New Zealand Journal of Zoology 8 : 129.

COLLINS, G. H. and CHARLESTON, W. A. G. 1979. Studies on Sarcocystis species II. Infection in wild and feral animals - prevalence and transmission. New Zealand Veterinary Journal 27 : 134-135.

COLLINS, G. H., ATKINSON, E. and CHARLESTON, W. A. G. 1979. Studies on Sarcocystis species III: The macrocystic species of sheep. New Zealand Veterinary Journal 27 : 204-206.

COLWELL, D. D. and MAHRT, J. L. 1981. Ultrastructure of the cyst wall and merozoites of Sarcocystis from moose (Alces alces) in Alberta, Canada. Zeitschrift für Parasitenkunde 65 : 317-329.

CORNAGLIA, E., GUARDA, F., GUARDA, F. and MISCIATELLI, M. E. 1980. Ricerca, frequenza, diagnosi, morfologia istopatologica ed ultrastrutturale della Sarcosporidiosi cardiaca nel Camosci e Stambecchi. Annali della Facolta di Medicina Veterinaria di Torino 27 : 1-20.

CROCKER, P. R., TOULSON, E. and LEVISON, D. A. 1982. Particles in paraffin sections demonstrated in the backscattered electron image (BEI). Micron 13 : 437-446.

DALY, T. J. M. and MARKUS, M. B. 1980. Separation of Sarcocystis species (Protozoa: Sporozoa, Coccidia) by means of cyst wall ultrastructure. Proceedings of the Electron Microscopy Society of Southern Africa 10 : 95-96.

DALY, T. J. M. and MARKUS, M. B. 1981. Enteric multiplication of Isospora felis by endodyogeny. Proceedings of the Electron Microscopy Society of Southern Africa 11 : 99-100.

DALY, T. J. M., MARKUS, M. B. and BIGGS, H. C. 1983. Sarcocystis of domestic and wild equine hosts. Proceedings of the Electron Microscopy Society of Southern Africa 13 : 71-72.

DISSANAIKE, A. S. and POOPALACHELVAM, M. 1975. Sarcocystis booliati n. sp. and a parasite of undetermined taxonomic position, Octoplasma garnhami n. gen. n. sp. from the moonrat, Echinosorex gymnurus. Southeast Asian Journal of Tropical Medicine and Public Health 6 : 175-185.

DISSANAIKE, A. S. and KAN, S. P. 1973. Studies on Sarcocystis in Malaysia: 1. Sarcocystis levinei n. sp. from the water buffalo Bubalus bubalis. Zeitschrift für Parasitenkunde 55 : 127-138.

DUBEY, J. P. 1982. Development of ox-coyote cycle of Sarcocystis cruzi. Journal of Protozoology 29 : 591-601.

DUBEY, J. P. 1983a. Sarcocystis peromysci n. sp. and S. idahoensis in deer mouse (Peromyscus maniculatus) in Montana. Canadian Journal of Zoology 61 : 1180-1182.

DUBEY, J. P. 1983b. Sarcocystis montanaensis and S. microti sp. n. from the meadow vole (Microtus pennsylvanicus). Proceedings of the Helminthological Society of Washington 50 : 318-324.

DUBEY, J. P. 1983c. Sarcocystis bovemanensis *sp. nov.* (*Protozoa:* Sarcocystidae) and S. campestris from the Richardson's ground squirrel (Spermophilus richardsonii), in Montana, U.S.A. Canadian Journal of Zoology 61 : 942-946.

DUBEY, J. P. 1983d. Sarcocystis fayeri *sp. n. from the bighorn* sheep (Ovis canadensis) and coyote (Canis latrans). Proceedings of the Helminthological Society of Washington 50 : 153-158.

DUBEY, J. P., SPEER, C. A. and DOUGLASS, T. G. 1980. Development and ultrastructure of *first-generation meronts* of Sarcocystis cruzi in calves fed sporocysts from coyote feces. Journal of Protozoology 27 : 380-387.

DUBEY, J. P., SPEER, C. A., CALLIS, G. and BLIXT, J. A. 1982. Development of the *sheep-canid cycle* of Sarcocystis tenella. Canadian Journal of Zoology 60 : 2464-2477.

DUBEY, J. P. and LOZIER, S. M. 1983. Sarcocystis infection in the white-tailed deer (Odocoileus virginianus) in Montana: intensity and description of *Sarcocystis odoi n .sp.* American Journal of Veterinary Research 44 : 1738-1743.

DUBEY, J. P., JOLLEY, W. R. and THORNE, E. T. 1983. Sarcocystis sybillensis sp. nov. from the North American elk (Cervus elaphus). *Canadian Journal of Zoology* 61 : 737-742.

DUBEY, J. P., SPEER, C. A., EPLING, G. P. and BLIXT, J. A. 1984. Sarcocystis capracanis: development in goats, dogs and coyotes. International Goat and Sheep Research 2 : 252-265.

DUBEY, J. P. and SPEER, C. A. 1985. Prevalence and ultrastructure of three types of Sarcocystis in mule deer, Odocoileus hemionus (Rafinesque), in Montana. Journal of Wildlife Diseases 21 : 219-228.

DUBEY, J. P. and SPEER, C. A. 1986. Sarcocystis infections in mule deer (Odocoileus hemionus) in Montana and the descriptions of three new species. American Journal of Veterinary Research 47 : 1052-1055.

EDWARDS, G. T. 1984. Prevalence of equine Sarcocystis in British horses and a comparison of two detection methods. Veterinary Record 115 : 265-267.

ELWASILA, M., ENTZEROTH, R., CHOBOTAR, B. and SCHOLTYSECK, E. 1984. Comparison of the structure of Sarcocystis cuniculi of the European rabbit (Oryctolagus cuniculus) and Sarcocystis leporum of the cottontail rabbit (Sylvilagus floridanus) by light and electron microscopy. Acta Veterinaria Hungarica 32 : 71-78.

ENTZEROTH, R. 1982. A comparative light and electron microscope study of the cysts of Sarcocystis species of roe deer (Capreolus capreolus). Zeitschrift für Parasitenkunde 66 : 281-292.

ENTZEROTH, R. 1984. Electron microscope study of host-parasite interactions of Sarcocystis muris (Protozoa, Coccidia) in tissue culture and in vivo. Zeitschrift für Paras'tenkunde 70 : 131-134.

ENTZEROTH, R. 1985. Light-, scanning-, and transmission electron microscope study of the cyst wall of Sarcocystis gracilis Ratz, 1909 (Sporozoa, Coccidia) from the roe deer (Capreolus capreolus L.). Archiv für Protistenkunde 129 : 183-186.

ENTZEROTH, R. and CHOBOTAR, B. 1982. Ultrastructure of macrogamonts, microgamonts, and oocysts of Sarcocystis muris in experimentally infected cats. Journal of Protozoology 29 : 528.

ENTZEROTH, R., CHOBOTAR, B. and SCHOLTYSECK, E. 1982. Ultrastructure of Sarcocystis sp. from the muscle of a white-tailed deer (Odocoileus virginianus). Zeitschrift für Parasitenkunde 68 : 33-38.

ENTZEROTH, R., NEMESERI, L. and SCHOLTYSECK, E. 1983a. Prevalence and ultrastructure of Sarcocystis sp. from the red deer (Cervus elaphus L.) in Hungary. Parasitologia Hungarica 16 : 47-52.

ENTZEROTH, R., SCHOLTYSECK, E. and CHOBOTAR, B. 1983b. Ultrastructure of Sarcocystis sp. n. from the eastern chipmunk (Tamias striatus). Zeitschrift für Parasitenkunde 69 : 823-826.

ENTZEROTH, R., CHOBOTAR, B. and SCHOLTYSECK, E. 1983c. Ultrastructure of a Sarcocystis species from the red squirrel (Tamiasciurus hudsonicus) in Michigan. Protistologica 19 : 91-94.

ENTZEROTH, R., CHOBOTAR, B. and SCHOLTYSECK, E. 1985a. Sarcocystis crotali sp. n. with the Mojave rattlesnake (Crotalus scutulatus scutulatus)-mouse (Mus musculus) cycle. Archiv für Protistenkunde 129 : 19-23.

ENTZEROTH, R., CHOBOTAR, B., SCHOLTYSECK, E. and NEMESERI, L. 1985b. Light and electron microscope study of Sarcocystis sp. from the fallow deer (Cervus dama). Zeitschrift für Parasitenkunde 71 : 33-39.

ERBER, M. 1982. Life cycle of Sarcocystis tenella in sheep and dog. Zeitschrift für Parasitenkunde 68 : 171-180.

ERBER, M. and GEISEL, O. 1981. Vorkommen und Entwicklung von 2 Sarkosporidienarten des Pferdes. Zeitschrift für Parasitenkunde 65 : 283-291.

FAYER, R. and FRENKEL, J. K. 1979. Comparative infectivity for calves of oocysts of feline coccidia: Besnoitia, Hammondia, Cystoisospora, Sarcocystis and Toxoplasma. Journal of Parasitology 65 : 756-762.

FEDERMAN, Q. and VALLESPIR, S. 1984. A new device and method for rapid processing of cytologic smears, histologic sections and cell cultures for electron microscopy. Acta Cytologica 28 : 509-513.

FEDOSEYENKO, V. M. and LEVIT, A. V. 1979. Elektronno-mikroskopicheskoe izuchenie tsist Sarcocystis muris v skeletnoi muskulature belykh myshei. Protozoologiya (Toksoplazmidy) 4 : 106-110.

FISCHER, G. 1979. Die Entwicklung von Sarcocystis capracanis n. spec. in der Ziege. Inaugural-Dissertation zur Erlangung der Würde eines Doctor Medicinae Veterinariae an der Freien Universität Berlin.

FORD, G. E. 1986. Biochemical characterization for identification of ovine sarcosporidia. Australian Journal of Biological Sciences 39 : 31-36.

FRANK, W. and HAFNER, U. 1981. Host range and host specificity of Sarcocystis. Zentralblatt für Bakteriologie, Mikrobiologie und Hygiene, I. Abteilung Originale A250 : 355-360.

GILL, H. S., MORIARTY, K. M. and CHARLESTON, W. A. G. 1986. Interaction between sporocysts of Sarcocystis muris and peritoneal macrophages. Proceedings of the 5th International Congress of Parasitology (Brisbane, Australia) : 139.

GJERDE, B. 1984a. A light microscopic comparison of the cysts of four species of Sarcocystis infecting the domestic reindeer (Rangifer tarandus) in northern Norway. Acta Veterinaria Scandinavica 25 : 195-204.

GJERDE, B. 1984b. Sarcocystis infection in wild reindeer (Rangifer tarandus) from Hardangervidda in southern Norway: with a description of the cysts of Sarcocystis hardangeri n. sp. Acta Veterinaria Scandinavica 25 : 205-212.

GJERDE, B. 1984c. The fox as definitive host for Sarcocystis sp. Gjerde, 1984 from skeletal muscle of reindeer (Rangifer tarandus), with a proposal for Sarcocystis tarandivulpes n. sp. as replacement name. Acta Veterinaria Scandinavica 25 : 403-410.

GJERDE, B. 1984d. Sarcocystis hardangeri and Sarcocystis rangi n. sp. from the domestic reindeer (Rangifer tarandus) in northern Norway. Acta Veterinaria Scandinavica 25 : 411-418.

GJERDE, B. 1985a. Ultrastructure of the cysts of Sarcocystis gruneri from cardiac muscle of reindeer (Rangifer tarandus tarandus). Zeitschrift für Parasitenkunde 71 : 189-198.

GJERDE, B. 1985b. Ultrastructure of the cysts of Sarcocystis tarandivulpes from skeletal muscle of reindeer (Rangifer tarandus tarandus). Acta Veterinaria Scandinavica 26 : 91-104.

GJERDE, B. 1985c. Ultrastructure of the cysts of Sarcocystis rangiferi from skeletal muscle of reindeer (Rangifer tarandus tarandus). Canadian Journal of Zoology 63 : 2669-2675.

GJERDE, B. 1985d. Ultrastructure of the cysts of Sarcocystis hardangeri from skeletal muscle of reindeer (Rangifer tarandus tarandus). Canadian Journal of Zoology 63 : 2676-2683.

GJERDE, B. 1985e. Ultrastructure of the cysts of Sarcocystis tarandi from skeletal muscle of reindeer (Rangifer tarandus tarandus). Canadian Journal of Zoology 63 : 2913-2918.

GJERDE, B. 1985f. Ultrastructure of the cysts of Sarcocystis rangi from skeletal muscle of reindeer (Rangifer tarandus tarandus). Rangifer 5 : 43-52.

GJERDE, B. and BRATBERG, B. 1984. The domestic reindeer (Rangifer tarandus) from northern Norway as intermediate host for three species of Sarcocystis. Acta Veterinaria Scandinavica 25 : 18 194.

GÖBEL, E., KATZ, M. and ERBER, M. 1978. Licht- und elektronenmikroskopische Untersuchungen zur Entwicklung von Muskelzysten von Sarcocystis suicanis in Haus-schweinen nach experimenteller Infektion. Zentralblatt für Bakteriologie, Mikrobiologie und Hygiene, I. Abteilung Originale A241 : 368-383.

GÖBEL, E. and ROMMEL, M. 1980. Licht- und elektronenmikroskopische Untersuchungen an Zysten von Sarcocystis equicanis in der Ösophagusmuskulatur von Pferden. Berliner und Münchener Tierärztliche Wochenschrift 93 : 41-47.

GUT, J. 1982. Infection of mice immunized with formolized cystozoites of Sarcocystis dispersa Černá, Kolářová et Šulc, 1978. Folia Parasitologica (Praha) 29 : 285-288.

HAFNER, U. and FRANK, W. 1984. Host specificity and host range of the genus Sarcocystis in three snake-rodent life cycles. Zentralblatt für Bakteriologie, Mikrobiologie und Hygiene, I. Abteilung Originale A256 : 296-299.

HAFNER, U. and MATUSCHKA, F.-R. 1984. Life cycle studies on Sarcocystis dirumpens sp. n. with regard to host specifi.ity. Zeitschrift für Parasitenkunde 70 : 715-720.

HAFNER, U. and FRANK, W. 1986. Morphological studies on the muscle cysts of Sarcocystis dirumpens (Hoare 1933) Häfner and Matuschka 1984 in several host species revealing endopolygeny in metrocytes. Zeitschrift für Parasitenkunde 72 : 453-461.

HERBERT, I. V. and SMITH, T. S. 1987. Sarcocystosis. Parasitology Today 3 : 16-21.

HERNÁNDEZ-RODRÍGUES, S., MARTÍNEZ-GÓMEZ, F., NAVARRETE, I. and ACOSTA-GARCÍA, I. 1981. Estudio al microscopio optico y electronico del quiste de Sarcocystis cervicanis. Revista Iberica de Parasitologia 41 : 351-361.

HEYDORN, A. O. 1985. Zur Entwicklung von Sarcocystis arieticanis n. sp. Berliner und Münchener Tierärztliche Wochenschrift 98 : 231-241.

HEYDORN, A. O., HARALAMBIDIS, S. and MATUSCHKA, F.-R. 1981. Zur Chemoprophylaxe und Therapie der akuten Sarkosporidiose. Berliner und Münchener Tierärztliche Wochenschrift 94 : 229-234.

HEYDORN, A. O. and UNTERHOLZNER, J. 1983. Zur Entwicklung von Sarcocystis hircicanis n. sp. Berliner und Münchener Tierärztliche Wochenschrift 96 : 275-282.

HINAIDY, H. K. and LOUPAL, G. 1982. Sarcocystis bertrami Doflein, 1901, ein Sarkosporid des Pferdes, Equus caballus. Zentralblatt für Veterinärmedizin B29 : 681-701.

HOFER, J., BOCH, J. and ERBER, M. 1982. Zelluläre und humorale Reaktion bei Mäusen nach experimenteller Sarcocystis muris- und S. dispersa-Infektion. Berliner und Münchener Tierärztliche Wochenschrift 95 : 169-175.

KAISER, I. A. and MARKUS, M. B. 1981. Sarcocystis in the avian intermediate host. Proceedings of the Electron Microscopy Society of Southern Africa 11 : 115-116.

KAISER, I. A. and MARKUS, M. B. 1983a. Species of Sarcocystis in wild South African birds. Proceedings of the Electron Microscopy Society of Southern Africa 13 : 103-104.

KAISER, I. A. and MARKUS, M. B. 1983b. Sarcocystis infection in wild southern African birds. *South African Journal of Science* 79 : 470-471.

KAN, S. P. 1979. Ultrastructure of the cyst wall of Sarcocystis spp. from some rodents in Malaysia. International Journal for Parasitology 9 : 475-480.

KAN, S. P. and DISSANAIKE, A. S. 1977. Ultrastructure of Sarcocystis sp. from the Malaysian house rat, Rattus rattus diardii. Zeitschrift für Parasitenkunde 52 : 219-227.

KAN, S. P. and DISSANAIKE, A. S. 1978. Studies on Sarcocystis in Malaysia II. Comparative ultrastructure of the cyst wall and zoites of Sarcocystis levinei and Sarcocystis fusiformis from the water buffalo, Bubalus bubalis. Zeitschrift für Parasitenkunde 57 : 107-115.

KAN, S. P., PRATHAP, K. and DISSANAIKE, A. S. 1979. Light and electron microstructure of a Sarcocystis sp. from the Malaysian long-tailed monkey, Macaca fascicularis. American Journal of Tropical Medicine and Hygiene 28 : 634-642.

KARNOVSKY, M. J. 1965. A formaldehyde-glutaraldehyde fixative of high osmolality for use in electron microscopy. Journal of Cell Biology 27 : 137A-138A.

KENNEDY, M. J. and FRELIER, P. F. 1986. Frenkelia sp. from the brain of a Porcupine (Erethizon dorsatum) from Alberta, Canada. Journal of Wildlife Diseases 22 : 112-114.

KIRKPATRICK, C. E., DUBEY, J. P., GOLDSCHMIDT, M. H., SAIK, J. E. and SCHMITZ, J. A. 1986. Sarcocystis sp. in muscles of domestic cats. Veterinary Pathology 23 : 88-90.

KOLÁŘOVÁ, L. 1986. Mouse (Mus musculus) as intermediate host of Sarcocystis sp. from the goshawk (Accipiter gentilis). Folia Parasitologica (Praha) 33 : 15-19.

LAI, P. F. 1977. Sarcocystis in Malaysian field rats. Southeast Asian Journal of Tropical Medicine and Public Health 8 : 417-419.

LEIER, H., BOCH J. and ERBER M. 1982. Möglichkeiten der Immunisierung von Mäusen gegen Sarcosporidien (Sarcocystis muris) mit abgeschwächten Sporozysten. Berliner und Münchener Tierärztliche Wochenschrift 95 : 231-235.

LEVINE, N. D. 1977. Sarcocystis cernae sp. n., replacement name for Sarcocystis sp. Černá and Loučková, 1976. Folia Parasitologica (Praha) 24 : 316.

LEVINE, N. D. 1979. What is "Sarcocystis" mucosa? Annals of Tropical Medicine and Parasitology 73 : 91-92.

LEVINE, N. D. 1986. The taxonomy of Sarcocystis (Protozoa, Apicomplexa) species. Journal of Parasitology 72 : 372-382.

LEVINE, N. D. and TADROS W. 1980. Named species and hosts of Sarcocystis (Protozoa: Apicomplexa: Sarcocystidae). Systematic Parasitology 2 : 41-59.

MARKUS, M. B. 1978a. Sarcocystis and sarcocystosis in domestic animals and man. Advances in Veterinary Science and Comparative Medicine 22 : 159-193.

MARKUS, M. B. 1978b. Terminology for invasive stages of protozoa of the subphylum Apicomplexa (Sporozoa). South African Journal of Science 74 : 105-106.

MARKUS, M. B. and DALY, T. J. M. 1980. Specificity of Sarcocystis in the intermediate host. Proceedings of the Third European Multicolloquium of Parasitology (Cambridge, England) : 141.

MARKUS, M. B., KAISER, I. A. and DALY, T. J. M. 1981. Sarcocystis of the vervet monkey Cercopithecus pygerythrus. Proceedings of the Electron Microscopy Society of Southern Africa 11 : 117-118.

MARKUS, M. B., DALY, T. J. M. and MUNDY, P. J. 1984. Host specificity of Sarcocystis species of wild African ungulates. Parasitology 89 : xliii-xliv.

MARKUS, M. B., MUNDY, P. J. and DALY, T. J. M. 1985. Vultures Gyps spp. as final hosts of Sarcocystis of the impala Aepyceros melamous. South African Journal of Science 81 : 43.

MATUSCHKA, F.-R. 1981. Life cycle of Sarcocystis between poikilothermic hosts. Lizards are intermediate hosts for S. podarcicolubris sp. nov, snakes function as definitive hosts. Zeitschrift für Naturforschung 36 : 1093-1096.

MATUSCHKA, F.-R. 1986. Sarcocystis clethrionomyelaphis n. sp. from snakes of the genus Elaphe and different voles of the family Arvicolidae. Journal of Parasitology 72 : 226-231.

MATUSCHKA, F.-R. and MEHLHORN, H. 1984. Sarcocysts of Sarcocystis podarcicolubris from experimentally infected Tyrrhenian wall lizards (Podarcis tiliguerta), S. gallotiae from naturally infected Canarian lizards (Gallotia gallotí) and S. dugesii from Madeirian lizards (Lacerta dugesii). Protistologica 20 : 133-139.

MATUSCHKA, F.-R., HEYDORN, A. O., MEHLHORN, H., ABD-AL-AAL, Z., DIESING, L. and BIEHLER, A. 1987. Experimental transmission of Sarcocystis muriviperae n. sp. to laboratory mice by sporocysts from the Palestinian viper (Vipera palaestinae): a light and electron microscope study. Parasitology Research 73 : 33-40.

McKENNA, P. B. and CHARLESTON, W. A. G. 1980. Coccidia (Protozoa: Sporozoasida) of cats and dogs. II. Experimental induction of Sarcocystis infections in mice. New Zealand Veterinary Journal 28 : 117-119.

MEHLHORN, H., HARTLEY, W. J. and HEYDORN, A. O. 1976. A comparative ultrastructural study of the cyst wall of 13 Sarcocystis species. Protistologica 12 : 461-467.

MEHLHORN, H. and HEYDORN, A. O. 1978. The Sarcosporidia (Protozoa, Sporozoa): Life cycle and fine structure. Advances in Parasitology 16 : 43-93.

MEHLHORN, H. and FRENKEL, J. K. 1980. Ultrastructural comparison of cysts and zoites of Toxoplasma gondii, Sarcocystis muris, and Hammondia hammondi in skeletal muscle of mice. Journal of Parasitology 66 : 59-67.

MUNDAY, B. L. 1983. An isosporan parasite of masked owls producing sarcocysts in rats. Journal of Wildlife Diseases 19 : 146-147.

MUNDAY, B. L., MASON, R. W., HARTLEY, W. J., PRESIDENTE, P. J. A. and OBENDORF, D. 1978. Sarcocystis and related organisms in Australian wildlife: I. Survey findings in mammals. Journal of Wildlife Diseases 14 : 417-433.

MUNDAY, B. L. and MASON, R. W. 1980. Sarcocystis and related organisms in Australian wildlife: III. Sarcocystis murinotechis sp. n.: life cycle in rats (Rattus, Pseudomys and Mastocomys spp.) and tiger snakes (Notechis ater). Journal of Wildlife Diseases 16 : 83-87.

MUNDAY, B. L. and MASON, R. W. 1981. Sarcocystis in rats from islands. New Zealand Journal of Zoology 8 : 563.

MUNDAY, B. L. and OBENDORF, D. L. 1984. Morphology of Sarcocystis gigantea in experimentally-infected sheep. Veterinary Parasitology 16 : 193-199.

OBENDORF, D. L. and MUNDAY, B. L. 1987. Experimental infection with Sarcocystis medusiformis in sheep. Veterinary Parasitology 24 : 59-66.

O'DONOGHUE, P. J., ADAMS, M., DIXON, B. R., FORD, G. E. and BAVERSTOCK, P. R. 1986. Morphological and biochemical correlates in the characterization of Sarcocystis spp. Journal of Protozoology 33 : 114-121.

O'DONOGHUE, P. J., OBENDORF, D. L., O'CALLAGHAN, M. G., MOORE, E. and DIXON, B. R. 1987a. Sarcocystis mucosa (Blanchard, 1885) Labbé, 1889 in unadorned rock wallabies (Petrogale assimilis) and Bennett's wallabies (Macropus rufogriseus). Parasitology Research 73 : 113-120.

O'DONOGHUE, P. J., WATTS, C. H. S. and DIXON, B. R. 1987b. Ultrastructure of Sarcocystis spp. (Protozoa: Apicomplexa) in rodents from North Sulawesi and West Java, Indonesia. Journal of Wildlife Diseases 23 : 225-232.

O'TOOLE, D., DUFFELL, S. J., UPCOTT, D. H. and FREWIN, D. 1986. Experimental microcyst Sarcocystis infection in lambs: pathology. Veterinary Record 119 : 525-531.

O'TOOLE, D. 1987. Experimental ovine sarcocystosis: sequential ultrastructural pathology in skeletal muscle. Journal of Comparative Pathology 97 : 51-60.

PACHECO, N. D., SHEFFIELD, H. G. and FAYER, R. 1978. Fine structure of immature cysts of Sarcocystis cruzi. Journal of Parasitology 64 : 320-325.

RIFAAT, M. A., SALEM, S. A., KHALIL, H. M., AZAB, M. E., ABDEL BAKI, M. H. and ABDEL GHAFFAR, F. M. 1978. A study on the life cycle of Sarcocystis muris. Journal of the Egyptian Public Health Association 53 : 341-357.

ROMMEL, M. 1979. Das Frettchen (Putorius putorius furo), ein zusätzlicher Endwirt für Sarcocystis muris. Zeitschrift für Parasitenkunde 58 : 187-188.

RUIZ, A. and FRENKEL, J. K. 1976. Recognition of cyclic transmission of Sarcocystis muris by cats. Journal of Infectious Diseases 133 : 409-418.

RZEPCZYK, C. M. 1974. Evidence of a rat-snake life cycle for Sarcocystis. International Journal for Parasitology 4 : 447-449.

RZEPCZYK, C. and SCHOLTYSECK, E. 1976. Light and electron microscope studies on the Sarcocystis of Rattus fuscipes, an Australian rat. Zeitschrift für Parasitenkunde 50 : 137-150.

SENAUD, J. and ČERNÁ, Z. 1978. Le cycle de développement asexué de Sarcocystis dispersa (Černá, Kolářová et Šulc, 1977) chez la souris: étude au microscope électronique. Protistologica 14 : 155-176.

SHEFFIELD, H. G., FRENKEL, J. K. and RUIZ, A. 1977. Ultrastructure of the cyst of Sarcocystis muris. Journal of Parasitology 63 : 629-641.

SMITHERS, R. H. N. 1983. The mammals of the southern African subregion. University of Pretoria, Pretoria.

SPEER, C. A. and DUBEY, J. P. 1982. Sarcocystis wapiti sp. nov. from the North American wapiti (Cervus elaphus). Canadian Journal of Zoology 60 : 881-888.

SPEER, C. A. and DUBEY, J. P. 1986. An unusual structure in the primary cyst wall of Sarcocystis hemionilatrantis. Journal of Protozoology 33 : 130-132.

TADROS, W. 1981. Studies on Sarcosporidia of rodents with birds of prey as definitive hosts. Pp. 248-259 in Canning, E. U. (ed.), *Parasitological topics: a presentation volume to P. C. C. Garnham, F.R.S., on the occasion of his 80th birthday, 1981.* Special Publication No. 1, Society of Protozoologists. Allen Press, Lawrence, Kansas.

TADROS, W. and LAARMAN, J. J. 1976. Sarcocystis and related coccidian parasites: a brief review, together with a discussion on some biological aspects of their life cycles and a new proposal for their classification. Acta Leidensia 44 : 1-107.

TADROS, W. and LAARMAN, J. J. 1976. A comparative study of the light and electron microscopic structure of the walls of the muscle cysts of several species of sarcocystid eimeriid coccidia. Proceedings of the Koninklijke Nederlandse Akademie van Wetenschappen C81 : 469-491.

TADROS, W. and LAARMAN, J. J. 1979. Successful rodent to rodent transmission of Sarcocystis sebeki by inoculation of precystic schizogonic stages. Transactions of the Royal Society of Tropical Medicine and Hygiene 73 : 350.

TADROS, W. and LAARMAN, J. J. 1982. Current concepts on the biology, evolution and taxonomy of tissue cyst-forming eimeriid coccidia. Advances in Parasitology 20 : 293-468.

TINLING, S. P., CARDINET, G. H., BLYTHE, L. L., COHEN, M. and VONDERFECHT, S. L. 1980. A light and electron microscopic study of sarcocysts in a horse. Journal of Parasitology 66 : 458-466.

VILES, J. M. and POWELL, E. C. 1976. The ultrastructure of the cyst wall of a murine Sarcocystis. Zeitschrift für Parasitenkunde 49 : 127-132.

WOODMANSEE, D. B. and POWELL, E. C. 1984. Cross-transmission and in vivo excystation experiments with Sarcocystis muris. Journal of Parasitology 70 : 182-183.

ZAMAN, V. and COLLEY, F. C. 1975. Light and electron microscopic observations of the life cycle of Sarcocystis orientalis sp. n. in the rat (Rattus norvegicus) and the Malaysian reticulated python (Python reticulatus). Zeitschrift für Parasitenkunde 47 : 169-185.

ZAMAN, V. and COLLEY, F. C. 1976. Replacement of Sarcocystis orientalis Zaman and Colley, 1975 by Sarcocystis singaporensis n. sp. Zeitschrift für Parasitenkunde 51 : 137.

APPENDIXES

ABBREVIATIONS USED IN APPENDIXES:

NO. EXAM.	Number of specimens examined histopathologically
NO. INFECT.	Number of specimens infected
% INFECT.	Percentage of animals infected from all regions - relative only to the numbers of specimens examined in the Department of Zoology at the University of the Witwatersrand
NO. EXAM. T.E.M.	Number of specimens examined by transmission electron microscopy
SPECIMEN NO.	Specimen laboratory number
SKELETAL M.	Skeletal muscle
CARDIAC M.	Cardiac muscle
INOC.	Number of laboratory rodents inoculated with Sarcocystis in transmission experiments
n.e.	Not examined

APPENDIX 1: SOUTHERN AFRICAN *WILD MAMMALS EXAMINED* HISTOPATHOLOGICALLY FOR MUSCULAR SARCOCYSTIS *INFECTION* - BREAKDOWN INTO LOCALITIES*

The numbers given in brackets refer *to the numbers of specimens examined* and/or the numbers of specimens *found to be infected* by other people working on Sarcocystis in the Department of Zoology at the University of the Witwatersrand. (Prevalence data which are not my own have been omitted for many host mammals, particularly those host species from which *I did not also screen muscle*).

SPECIES	LOCALITY	REGION	NO. EXAM.	NO. INFECT.
ORDER: INSECTIVORA				
FAMILY: CHRYSOCHLORIDAE				
Golden mole Eremitalpa granti		Namibia	5	0
FAMILY: MACROSCELIDIDAE				
SUBFAMILY: MACROSCELIDINAE				
Four-toed elephant shrew Petrodromus tetradactylis	Kruger Nat. Park	Transvaal(East.)	3	0

* Geographic co-ordinates have not been given as the raw data are *merely for* the information of the author (the *information of relevance* to the reader has been incorporated in Appendixes 1 and 2).



ORDER: CHIROPTERA				
SUBORDER: MEGACHIROPTERA				
FAMILY: PTEROPODIDAE				
SUBFAMILY: PTEROPODINAE				
Egyptian fruit bat Rousettus aegyptiacus	Kruger Nat. Park	Transvaal(East.)	1	0
ORDER: PRIMATES				
SUBORDER: ANTHROPOIDEA				
FAMILY: HOMINIDAE				
Man Homo sapiens	Johannesburg	Transvaal	44 (11)	0 (0)
FAMILY: CERCOPITHECIDAE				
SUBFAMILY: CERCOPITHECINAE				
Baboon Papio ursinus	Mkuzi	Natal	6	3
" " "	*Kruger Nat. Park*	*Transvaal*(East.)	0 (4)	0 (2)
" " "	Vaalwater	Transvaal(North.)	0 (33)	0 (2)
Vervet monkey Cercopithecus pygerythrus	Graaff-Reinet	Cape	0 (7)	0 (1)
Vervet monkey	Cradock	Cape	0 (6)	0 (3)
" "	Mkuzi	Natal	8 (1)	2 (0)
" "	Durban	Natal	0 (7)	0 (0)



Vervet monkey	Kruger Nat. Park	Transvaal(East.)	1	1
" "	Nelspruit	Transvaal(East.)	0 (1)	0 (0)
" "	Vaalwater	Transvaal(North.)	0 (16)	0 (3)
" "	Duiwelskloof	Transvaal(North.)	0 (11)	0 (0)
" "	Rustenburg	Transvaal(West.)	0 (12)	0 (2)
" "	Pretoria	Transvaal	0 (2)	0 (1)
" "	Johannesburg*	Transvaal	0 (41)	0 (1)
ORDER: LAGOMORPHA				
FAMILY: LEPORIDAE				
Scrub hare Lepus saxatilis	Kruger Nat. Park	Transvaal(East.)	3	0
ORDER: RODENTIA				
FAMILY: BATHYERGIDAE				
SUBFAMILY: GEORYCHINAE				
Cape mole rat Georychus capensis		Cape	4	0

* Includes specimens of unknown geographic origin.





FAMILY: HYSTRICIDAE				
Crested porcupine *Hystrix africaeaustralis*	Kruger Nat. Park	Transvaal(East.)	1	0
FAMILY: SCIURIDAE				
Tree squirrel *Paraxerus cepapi*	Kruger Nat. Park	Transvaal(East.)	0	0
FAMILY: MURIDAE				
SUBFAMILY: MURINAE				
Spiny mouse *Acomys spinosissimus*	Kruger Nat. Park	Transvaal(East.)	6	3
Single-striped mouse *Lemniscomys griselda*	Kruger Nat. Park	Transvaal(East.)	2	1
Striped mouse *Rhabdomys pumilio*			1	0
Water rat *Dasymys incomtus*		Natal	0 (2)	0 (2)
House mouse *Mus musculus* (Introduced)		Natal	0 (1)	0 (1)
" " " " "		Marion Island	119	17
Multimammate mouse *Praomys natalensis*	Kruger Nat. Park	Transvaal(East.)	3	1



Namaqua rock mouse Aethomys namaquensis	Kruger Nat. Park	Transvaal(East.)	8	3
Namaqua rock mouse		Natal	0 (2)	0 (2)
Red veld rat Aethomys chrysophilus	Kruger Nat. Park	Transvaal(East.)	3	1
FAMILY: CRICETIDAE				
SUBFAMILY: GERBILLINAE				
Bushveld gerbil Tatera leucogaster	Kruger Nat. Park	Transvaal(East.)	3	0
SUBFAMILY: CRICETOMYINAE				
Pouched mouse Saccostomus campestris	Kruger Nat. Park	Transvaal(East.)	1	0
SUBFAMILY: DENDROMURINAE				
Fat mouse Steatomys pratensis		Natal	0 (1)	0 (1)
ORDER: CARNIVORA				
FAMILY: HYAENIDAE				
SUBFAMILY: PROTELINAE				
Aardwolf Protelas cristatus		Cape	0 (1)	0 (0)
SUBFAMILY: HYAENINAE				
Spotted hyaena Crocuta crocuta	Kruger Nat. Park	Transvaal(East.)	1	1



FAMILY: FELIDAE				
SUBFAMILY: FELINAE				
Leopard Panthera pardus		Cape	0 (7)	0 (0)
" " "	Vrolijkheid	Cape	1	0
Lion Panthera leo	Kruger Nat. Park	Transvaal(East.)	6	4
" " "	Matetsi	Zimbabwe	3	2
Caracal Felis caracal		Cape	0 (15)	0 (0)
" " "	Vrolijkheid	Cape	1	0
" " "	Cradock	Cape	2	0
African wild cat Felis lybica		Cape	0 (1)	0 (0)
FAMILY: CANIDAE				
SUBFAMILY: CANINAE				
Cape fox Vulpes chama		Cape	0 (4)	0 (1)
Black-backed jackal Canis mesomelas		Cape	0 (4)	0 (0)
" " " " "	Kuruman	Cape	1	0
" " " " "	Kruger Nat. Park	Transvaal(East.)	1	1



FAMILY: MUSTELIDAE					
SUBFAMILY: MUSTELINAE					
Striped polecat Ictonyx striatus		Cape	2	0	
" " " "	Makapansgat	Transvaal(North.)	1	0	
FAMILY: VIVERRIDAE					
SUBFAMILY: VIVERRINAE					
African civet Civettictis (Viverra) civetta	Kruger Nat. Park	Transvaal(East.)	1	1	
Small-spotted genet Genetta genetta		Cape	0 (1)	0 (0)	
" " " " "	Kuruman	Cape	1	0	
" " " " "	Kruger Nat. Park	Transvaal(East.)	3	3	
Large-spotted genet Genetta tigrina		Cape	0 (1)	0 (0)	
" " " " "	Kruger Nat. Park	Transvaal(East.)	1	1	
SUBFAMILY: HERPESTINAE					
Suricate Suricata suricatta		Cape	0 (2)	0 (0)	
Yellow mongoose Cynictis penicillata		Namibia	1	0	





Slender mongoose Galerella (Herpestes) sanguinea		Cape	1	0
Slender mongoose	Kruger Nat. Park	Transvaal(East.)	2	2
Banded mongoose Mungos mungo	Vrolijkheid	Cape	1	0
ORDER: PROBOSCIDEA				
FAMILY: ELEPHANTIDAE				
Elephant Loxodonta africana	Kruger Nat. Park	Transvaal(East.)	2	0
" " "		Zimbabwe	33	0
ORDER: HYRACOIDEA				
FAMILY: PROCAVIIDAE				
Rock rabbit Procavia capensis		Namibia	10	1
ORDER: PERISSODACTYLA				
FAMILY: *EQUIDAE*				
Mtn zebra Equus zebra zebra	Cradock	Cape	3	0
" " " " "	Pilansberg	Transvaal	1	0
Mtn zebra Equus zebra hartmannae	Cradock	Cape	6	0
" " " " "	Etosha	Namibia	2	2





Mtn zebra *Equus zebra hartmannae*	Windhoek	Namibia	6	5
Burchell's zebra Equus burchelli	Etosha	Namibia	3	3
" " " "	Kruger Nat. Park	Transvaal(East.)	4	4
ORDER: ARTIODACTYLA				
FAMILY: SUIDAE				
Warthog Phacochoerus aethiopicus	Windhoek	Namibia	4 (5)	4 (3)
" " "	Mkuzi	Natal	13 (15)	8 (14)
" " "	Kruger Nat. Park	Transvaal(East.)	6	6
" " "	West Nicholson	Zimbabwe	1	1
FAMILY: HIPPOPOTAMIDAE				
Hippopotamus Hippopotamus amphibius	Kruger Nat. Park	Transvaal(East.)	10	3
FAMILY: GIRAFFIDAE				
Giraffe Giraffa camelopardalis	Etosha	Namibia	2	2
" " "	Kruger Nat. Park	Transvaal(East.)	1	1
FAMILY: BOVIDAE				
SUBFAMILY: ALCELAPHINAE				
TRIBE: CONNOCHAETINI				
Wildebeest Connochaetes taurinus	Mkuzi	Natal	9 (2)	7 (2)
" " "	Pongola	Natal	1	0





TRIBE: ALCELAPHINI				
Tsessebe Damaliscus lunatus	Kruger Nat. Park	Transvaal(East.)	1	0
" " "	Nylsvlei	Transvaal(North.)	6	2
SUBFAMILY: ANTILOPINAE				
TRIBE: ANTILOPINI				
Springbuck Antidorcas marsupialis		Namibia	19 (4)	13 (0)
TRIBE: NEOTRAGINI				
Steenbuck Raphicerus campestris	Kruger Nat. Park	Transvaal(East.)	1	0
SUBFAMILY: AEPYCEROTINAE				
Impala Aepyceros melampus	Kruger Nat. Park	Transvaal(East.)	6	5
" " "		Zimbabwe	8 (1)	5 (1)
SUBFAMILY: HIPPOTRAGINAE				
Gemsbuck Oryx gazella		Namibia	19	17
SUBFAMILY: BOVINAE				
TRIBE: BOVINI				
Buffalo Syncerus caffer	Kruger Nat. Park	Transvaal(East.)	1	0
" " "		Zimbabwe	0 (2)	0 (1)





TRIBE: TRAGELAPHINI				
Kudu *Tragelaphus strepsicerus*		Namibia	12	6
" " "	Kruger Nat. Park	Transvaal(East.)	38	33
" " "		Zimbabwe	2	1
Bushbuck *Tragelaphus scriptus*	Kruger Nat. Park	Transvaal(East.)	3	1
SUBFAMILY: REDUNCINAE				
Mtn. reedbuck *Redunca fulvorufula*	*Cradock*	Cape	1	0
Waterbuck *Kobus ellipsiprymnus*	Kruger Nat. Park	Transvaal(East.)	2	2
Lechwe *Kobus leche*		Namibia	1	1



APPENDIX 2: *SOUTHERN AFRICAN* WILD MAMMALS EXAMINED HISTOPATHOLOGICALLY FOR MUSCULAR SARCOCYSTIS *INFECTION*

The numbers given in brackets refer to the numbers of specimens *examined* and/or the number of specimens found to be infected by other people working on *Sarcocystis* in the Department of Zoology at the University of the *Witwatersrand*. (*Prevalence* data which are not my own have been omitted for many host mammals, particularly those host species from which I did not also screen muscle).

SPECIES	NO. EXAM.	NO. INFECT.	% INFECT.
ORDER: INSECTIVORA			
FAMILY: CHRYSOCHLORIDAE			
Golden mole *Eremitalpa granti*	5	0	0,00
FAMILY: MACROSCELIDIDAE			
SUBFAMILY: MACROSCELIDINAE			
Four-toed elephant shrew *Petrodromus tetradactylis*	3	0	0,00
ORDER: CHIROPTERA			
SUBORDER: MEGACHIROPTERA			
FAMILY: PTEROPODIDAE			



SUBFAMILY: PTEROPODINAE			
Egyptian fruit bat Rousettus aegyptiacus	1	0	0,00
ORDER: PRIMATES			
SUBORDER: ANTHROPOIDEA			
FAMILY: CERCOPITHECIDAE			
SUBFAMILY: CERCOPITHECINAE			
Baboon Papio ursinus	6 (37)	3 (4)	16,28
Vervet monkey Cercopithecus pygerythrus	9 (104)	3 (11)	12,39
ORDER: LAGOMORPHA			
FAMILY: LEPORIDAE			
Scrub hare Lepus saxatilis	3	0	0,00
ORDER: RODENTIA			
FAMILY: BATHYERGIDAE			
SUBFAMILY: GEORYCHINAE			
Cape mole rat Georychus capensis	4	0	0,00





FAMILY: HYSTRICIDAE			
Crested porcupine Hystrix africaeaustralis	1	0	0,00
FAMILY: SCIURIDAE			
Tree squirrel Paraxerus cepapi	8	0	0,00
FAMILY: MURIDAE			
SUBFAMILY: MURINAE			
Spiny mouse Acomys spinosissimus	6	3	50,00
Single-striped mouse Lemniscomys griselda	2	1	50,00
Striped mouse Rhabdomys pumilio	1	0	0,00
Water rat Dasymus incomtus	*0 (2)*	*0 (2)*	50,00
House mouse Mus musculus (Introduced)	0 (1)	0 (1)	*100,00*
" " " " " (Island)	119	1(?)	0,84(?)
Multimammate mouse Praomys *natalensis*	3	1	33,33
Namaqua rock mouse Aethomys namaquensis	*8 (2)*	3 (2)	50,00
Red veld rat Aethomys chrysophilus	3	1	33,33



FAMILY: CRICETIDAE			
SUBFAMILY: GERBILLINAE			
Bushveld gerbil Tatera leucogaster	3	0	0,00
SUBFAMILY: CRICETOMYINAE			
Pouched mouse Saccostomus campestris	1	0	0,00
SUBFAMILY: DENDROMURINAE			
Fat mouse Steatomys pratensis	0 (1)	0 (1)	100,00
ORDER: CARNIVORA			
FAMILY: HYAENIDAE			
SUBFAMILY: PROTELINAE			
Aardwolf Protelas cristatus	0 (1)	0 (0)	0,00
SUBFAMILY: HYAENINAE			
Spotted hyaena Crocuta crocuta	1	1	100,00
FAMILY: FELIDAE			
SUBFAMILY: FELINAE			
Leopard Panthera pardus	1 (7)	0 (0)	0,00
Lion Panthera leo	8	6	75,00



Caracal Felis caracal	3 (15)	0 (0)	0,00
African wild cat Felis lybica	0 (1)	0 (0)	0,00
FAMILY: CANIDAE			
SUBFAMILY: CANINAE			
Cape fox Vulpes chama	0 (4)	0 (1)	0,00
Black-backed jackal Canis mesomelas	2 (5)	1 (0)	25,00
FAMILY: MUSTELIDAE			
SUBFAMILY: MUSTELINAE			
Striped polecat Ictonyx striatus	3	0	0,00
FAMILY: VIVERRIDAE			
SUBFAMILY: VIVERRINAE			
African civet Civettictis (Viverra) civetta	1	1	100,00
Small-spotted genet Genetta genetta	4 (1)	3 (0)	60,00
Large-spotted genet Genetta tigrina	1 (1)	1 (0)	50,00
SUBFAMILY: HERPESTINAE			
Suricate Suricata suricatta	0 (2)	0 (0)	0,00



Yellow mongoose Cynictis penicillata	1	0	0,00
Slender mongoose Galerella (Herpestes) sanguinea	3	2	66,67
Banded mongoose Mungos mungo	1	0	0,00
ORDER: PROBOSCIDEA			
FAMILY: ELEPHANTIDAE			
Elephant Loxodonta africana	35	0	0,00
ORDER: HYRACOIDEA			
FAMILY: PROCAVIIDAE			
Rock rabbit Procavia capensis	10	1	10,00
ORDER: PERISSODACTYLA			
FAMILY: EQUIDAE			
Mtn zebra Equus zebra zebra	4	0	0,00
Mtn zebra Equus zebra hartmannae	14	7	50,00
Burchell's zebra Equus burchelli	7	7	100,00



ORDER: ARTIODACTYLA			
FAMILY: SUIDAE			
Warthog Phacochoerus aethiopicus	26 (20)	21 (17)	82,61
FAMILY: HIPPOPOTAMIDAE			
Hippopotamus Hippopotamus amphibius	10	3	30,00
FAMILY: GIRAFFIDAE			
Giraffe Giraffa camelopardalis	3	3	100,00
FAMILY: BOVIDAE			
SUBFAMILY: *ALCELAPHINAE*			
TRIBE: CONNOCHAETINI			
Wildebeest Connochaetes taurinus	10 (2)	7 (2)	75,00
TRIBE: ALCELAPHINI			
Tsessebe Damaliscus lunatus	7	2	28,57
SUBFAMILY: ANTILOPINAE			
TRIBE: ANTILOPINI			
Springbuck Antidorcas marsupialis	19 (4)	13 (0)	66,62
TRIBE: NEOTRAGINI			
Steenbuck Raphicerus campestris	1	0	0,00





SUBFAMILY: AEPYCEROTINAE			
Impala Aepyceros melampus	16 (1)	10 (1)	62,50
SUBFAMILY: HIPPOTRAGINAE			
Gemsbuck Oryx gazella	19	17	89,47
SUBFAMILY: BOVINAE			
TRIBE: BOVINI			
Buffalo Syncerus caffer	1 (2)	0 (1)	33,33
TRIBE: TRAGELAPHINI			
Kudu Tragelaphus strepsiceros	52	40	76,92
Bushbuck Tragelaphus scriptus	3	1	33,33
SUBFAMILY: REDUNCINAE			
Mtn. reedbuck Redunca fulvorufula	1	0	0,00
Waterbuck Kobus ellipsiprymnus	2	2	100,00
Lechwe Kobus leche	1	1	100,00



APPENDIX 3: HOSTS OF CYSTS EXAMINED BY TRANSMISSION ELECTRON MICROSCOPY

SPECIES	LOCALITY	REGION	NO. EXAM. T.E.M.
ORDER: PRIMATES			
SUBORDER: *ANTHROPOIDEA*			
FAMILY: CERCOPITHECIDAE			
SUBFAMILY: CERCOPITHECINAE			
Vervet monkey Cercopithecus pygerythrus	Cradock	Cape	2*
Vervet monkey	Vaalwater	Transvaal(North.)	1*
ORDER: RODENTIA			
FAMILY: MURIDAE			
SUBFAMILY: MURINAE			
Spiny mouse Acomys spinosissimus	Kruger Nat. Park	Transvaal(East.)	1
Multimammate mouse Praomys natalensis	Kruger Nat. Park	Transvaal(East.)	1

* The ultrastructural results are not discussed in this thesis (see Markus et al., 1981).



Namaqua rock mouse Aethomys namaquensis	Kruger Nat. Park	Transvaal(East.)	1
Red veld rat Aethomys chrysophilus	Kruger Nat. Park	Transvaal(East.)	1
ORDER: CARNIVORA			
FAMILY: HYAENIDAE			
SUBFAMILY: HYAENINAE			
Spotted hyaena Crocuta crocuta	Kruger Nat. Park	Transvaal(East.)	1
FAMILY: FELIDAE			
SUBFAMILY: FELINAE			
Lion Panthora leo	Kruger Nat. Park	Transvaal(East.)	1
" "	Matetsi	Zimbabwe	1
FAMILY: VIVERRIDAE			
SUBFAMILY: VIVERRINAE			
African civet Civettictis (Viverra) civetta	Kruger Nat. Park	Transvaal(East.)	1
Small-spotted genet Genetta genetta	Kruger Nat. Park	Transvaal(East.)	3
Large-spotted genet Genetta tigrina	Kruger Nat. Park	Transvaal(East.)	1



SUBFAMILY: HERPESTINAE			
Slender mongoose Galerella (Herpestes) sanguinea	Kruger Nat. Park	Transvaal(East.)	2
ORDER: PERISSODACTYLA			
FAMILY: EQUIDAE			
Mtn zebra Equus zebra hartmannae	Etosha	Namibia	1
" " " " "	Windhoek	Namibia	4
Burchell's zebra Equus burchelli	Etosha	Namibia	1
ORDER: ARTIODACTYLA			
FAMILY: SUIDAE			
Warthog Phacochoerus aethiopicus	Windhoek	Namibia	1
" " "	Mkuzi	Natal	1
" " "	Kruger Nat. Park	Transvaal(East.)	1 (macro.)
" " "	West Nicholson	Zimbabwe	1
FAMILY: HIPPOPOTAMIDAE			
Hippopotamus Hippopotamus amphibius	Kruger Nat. Park	Transvaal(East.)	1



FAMILY: GIRAFFIDAE			
Giraffe Giraffa camelopardalis	Etosha	Namibia	1
" " "	Kruger Nat. Park	Transvaal(East.)	1
FAMILY: BOVIDAE			
SUBFAMILY: ALCELAPHINAE			
TRIBE: CONNOCHAETINI			
Wildebeest Connochaetes taurinus	Mkuzi	Natal	4
TRIBE: ALCELAPHINI			
Tsessebe Damaliscus lunatus	Nylsvlei	Transvaal(North.)	1
SUBFAMILY: ANTILOPINAE			
TRIBE: ANTILOPINI			
Springbuck Antidorcas marsupialis		Namibia	1
SUBFAMILY: AEPYCEROTINAE			
Impala Aepyceros melampus	Kruger Nat. Park	Transvaal(East.)	2
" " "		Zimbabwe	6
SUBFAMILY: HIPPOTRAGINAE			
Gemsbuck Oryx gazella		Namibia	1



SUBFAMILY: BOVINAE			
TRIBE: TRAGELAPHINI			
Kudu Tragelaphus strepsiceros		Namibia	1
" " "	Kruger Nat. Park	Transvaal(East.)	2
" " "		Zimbabwe	1
Bushbuck Tragelaphus scriptus	Kruger Nat. Park	Transvaal(East.)	1
SUBFAMILY: REDUNCINAE			
Waterbuck Kobus ellipsiprymnus	Kruger Nat. Park	Transvaal(East.)	1
Lechwe Kobus leche		Namibia	1



APPENDIX 4: DOMESTIC ANIMALS IN SOUTHERN AFRICA EXAMINED HISTOPATHOLOGICALLY FOR MUSCULAR SARCOCYSTIS INFECTION - LOCATION OF SARCOCYSTS AND HOSTS OF CYSTS EXAMINED BY TRANSMISSION ELECTRON MICROSCOPY

SPECIES	LOCALITY	REGION	NO. EXAM.	NO. INFECT.	% INFECT.	NO. EXAM. T.E.M.
Ox Bos taurus	Melmoth[+]	Natal	1	1	100,00	1
" " "	Johannesburg[*]	Transvaal	10	10	100,00	1
" " "	Johannesburg[o]	Transvaal	12	7	58,33	0
Donkey Equus asinus	Springs[o]	Transvaal	10	1	10,00	0
Horse Equus caballus	Cradock[+]	Cape	2	0	0,00	0
" " "	Springs[o]	Transvaal	31	5	16,13	1
Pig Sus scrofa	Krugersdorp[o]	Transvaal	32	1	3,12	1
Sheep Ovis aries	Allerton[*]	Natal	2	2	100,00	2
" " "	Johannesburg[o]	Transvaal	14	13	92,86	12

[+] Ox - skeletal muscle; Horse - thigh and pectoral

[*] Heart

[o] Oesophagus (in sheep, 11 of 12 oesophagi had macrocysts)



APPENDIX 5: SOUTHERN AFRICAN WILD MAMMALS INFECTED WITH SARCOCYSTIS: LOCATION OF *SARCOCYSTS*[*]

The specimen (laboratory) numbers given *in bold type* indicate those specimens from which material was processed for *transmission* electron microscopy. The specimen numbers in brackets indicate which specimens have been examined for Sarcocystis by other workers in the Department of Zoology at the University of the Witwatersrand.

SPECIES	REGION	*SPECIMEN NO.*	SKELETAL M.	CARDIAC M.
ORDER: PRIMATES				
SUBORDER: ANTHROPOIDEA				
FAMILY: CERCOPITHECIDAE				
SUBFAMILY: CERCOPITHECINAE				
Baboon Papio ursinus	Natal	M82-82	pectoral, hindleg	n.e.
		M82-83	pectoral, hindleg	n.e.

[*] *Normally only* pectoral and hindleg muscle samples (and sometimes heart) from host animals were examined.

		M82-14	pectoral, hindleg	n.e.
Baboon *Papio ursinus*	Transvaal(East.)	M83-41	pectoral, leg	n.e.
		M83-63	pectoral, leg	n.e.
" " "	Transvaal(North.)	M80-33	pectoral	n.e.
		M80-49	pectoral	n.e.
Vervet monkey *Cercopithecus pygerythrus*	Cape	M81-59	pectoral, abdomen	n.e.
Vervet monkey	Cape	M81-47	pectoral, abdomen	neg.
		M81-54	pectoral, abdomen	neg.
		M81-49	pectoral, abdomen	n.e.
" "	Natal	M82-106	pectoral, hindleg	n.e.
		M82-107	pectoral, hindleg	n.e.
" "	Transvaal(East.)	M83-115	skeletal	n.e.
" "	Transvaal(North.)	M81-181	pectoral, abdomen	neg.
		M80-83	diaphragm, abdomen	n.e.



		M81-1	pectoral, abdomen	neg.
Vervet monkey	Transvaal(West.)	M80-81	diaphragm, abdomen	n.e.
		M81-33	pectoral, abdomen	n.e.
" "	Transvaal	M80-104	diaphragm, abdomen	n.e.
" "	Transvaal	M81-206	pectoral, abdomen	n.e.

ORDER: RODENTIA
FAMILY: MURIDAE
SUBFAMILY: MURINAE

Spiny mouse Acomys spinosissimus	Transvaal(East.)	TM 30578	leg	n.e.
		DAS 4441	leg	n.e.
		DAS 4443	leg	n.e.
Single-striped mouse Lemniscomys griselda	Transvaal(East.)	TM 30567	leg, abdomen	n.e.
Water rat Dasymus incomtus	Natal	(M80-186)	pectoral, abdomen	n.e.





		(M80-201)	pectoral, abdomen	n.e.
House mouse Mus musculus (Introduced)	Natal	(M80-187)	pectoral, abdomen	n.e.
" " " " "	Marion Island	M81-156	skeletal	n.e.
Multimammate mouse Praomys natalensis	Transvaal(East.)	TM 30557	leg	n.e.
Namaqua rock mouse Aethomys namaquensis	Transvaal(East.)	M79-20	leg	n.e.
		M79-21	abdomen	n.e.
		M79-16	leg	n.e.
Namaqua rock mouse	Natal	(M80-111)	pectoral, abdomen	n.e.
		(M80-213)	pectoral, abdomen	n.e.
Red veld rat Aethomys chrysophilus	Transvaal(East.)	DAS 4439	abdomen	n.e.
FAMILY: CRICETIDAE				
SUBFAMILY: DENDROMURINAE				
Fat mouse Steatomys pratensis	Natal	(M80-221)	pectoral, abdomen	n.e.





ORDER: CARNIVORA				
FAMILY: HYAENIDAE				
SUBFAMILY: HYAENINAE				
Spotted hyaena Crocuta crocuta	Transvaal(East.)	M83-114	skeletal	n.e.
FAMILY: FELIDAE				
SUBFAMILY: FELINAE				
Lion Panthera leo	Transvaal(East.)	M83-98	skeletal	n.e.
		M83-110	skeletal	pos.
		M83-113	skeletal	n.e.
		(M86-127)	skeletal	neg.
" " "	Zimbabwe	M86-110	pectoral, hindleg	neg.
		(M86-111)	pectoral, hindleg	n.e.
FAMILY: CANIDAE				
SUBFAMILY: CANINAE				
Cape fox Vulpes chama	Cape	(M80-169)	skeletal	n.e.
Black-backed jackal Canis mesomelas	Transvaal(East.)	M83-102	skeletal	n.e.





FAMILY: VIVERRIDAE				
SUBFAMILY: VIVERRINAE				
African civet Civettictis (Viverra) civetta	Transvaal(East.)	M83-143	abdomen, diaphragm, thorax, pelvic, hindleg	n.e.
Small-spotted genet Genetta genetta	Transvaal(East.)	TM 30558	leg	n.e.
		TM 30571	leg	n.e.
		TM 30575	leg	n.e.
Large-spotted genet Genetta tigrina	Transvaal(East.)	TM 30518	leg	n.e.
SUBFAMILY: HERPESTINAE				
Slender mongoose Galerella (Herpestes) sanguinea	Transvaal(East.)	TM 30565	leg	n.e.
		TM 30566	leg	n.e.
ORDER: HYRACOIDEA				
FAMILY: PROCAVIIDAE				
Rock rabbit Procavia capensis	Namibia	M82-150	pectoral, leg	n.e.



ORDER: PERISSODACTYLA

FAMILY: EQUIDAE

Mtn zebra Equus zebra hartmannae	Namibia	M82-78	pectoral, hindleg	neg.
		M82-77	pectoral, hindleg	neg.
" " " "	Namibia	M80-164	skeletal	n.e.
		M81-216	skeletal	n.e.
		M82-202	pectoral, thigh, shoulder	n.e.
		M83-65	pectoral, thigh, shoulder	n.e.
		M81-215	skeletal	neg.
Burchell's zebra Equus burchelli	Namibia	M82-76	pectoral, hindleg	neg.
		M82-74	pectoral, hindleg	neg.
		M82-75	pectoral, hindleg	neg.
" " " "	Transvaal(East.)	M85-83	pectoral, thigh	neg.
		M85-84	pectoral, thigh	neg.
		M85-85	pectoral, thigh	neg.
		M85-86	pectoral, thigh	neg.

ORDER: ARTIODACTYLA
FAMILY: SUIDAE

Warthog *Phacochoerus aethiopicus*	Namibia	WART 4	frontleg, neck hindleg	n.e.
		M82-79	frontleg, neck hindleg	n.e.
		M82-80	frontleg, neck hindleg	n.e.
		M82-81	frontleg, neck hindleg	n.e.
		M81-218	hindleg	n.e.
		M81-219	hindleg	n.e.
		M81-220	hindleg	n.e.
" " "	Natal	M82-94	pectoral, hindleg	n.e.
		M82-89	pectoral, hindleg	n.e.
		M82-91	pectoral, hindleg	n.e.
		M82-92	pectoral, hindleg	n.e.
		M82-95	pectoral, hindleg	n.e.



M82-96	pectoral, hindleg	n.e.
M82-99	pectoral, hindleg	n.e.
M82-192	pectoral, hindleg	n.e.
(M83-19)	pectoral, hindleg	n.e.
(M83-20)	pectoral, hindleg	n.e.
(M83-21)	pectoral, hindleg	n.e.
(M83-22)	pectoral, hindleg	n.e.
(M83-23)	pectoral, hindleg	n.e.
(M83-24)	pectoral, hindleg	n.e.
(M83-25)	pectoral, hindleg	n.e.
(M83-27)	pectoral, hindleg	n.e.
(M83-28)	pectoral, hindleg	n.e.



		(M83-29)	pectoral, hindleg	n.e.
		(M83-30)	pectoral, hindleg	n.e.
		(M83-31)	pectoral, hindleg	n.e.
		(M83-32)	pectoral, hindleg	n.e.
		(M83-33)	pectoral, hindleg	n.e.
Warthog Phacochoerus aethiopicus	Transvaal(East.)	M83-66 (macro.)	skeletal	neg.
		M83-92	skeletal	n.e.
		M83-105	pectoral, diaphragm	neg.
		M83-146	thorax, abdomen, pelvic, hindleg	n.e.
		M83-163	pectoral, pelvic	neg.
		M83-164	pectoral, pelvic	n.e.
		M83-185	pectoral, pelvic	n.e.





		M83-156	pectoral, pelvic	n.e.
Warthog Phacochoerus aethiopicus	Zimbabwe	M83-2C	skeletal	n.e.
FAMILY: HIPPOPOTAMIDAE				
Hippopotamus Hippopotamus amphibius	Transvaal(East.)	M83-131	pectoral, diaphragm, hindquarter	n.e.
		M83-132	thorax, abdomen, pelvic, hindleg	n.e.
		M83-144	diaphragm	n.e.
FAMILY: GIRAFFIDAE				
Giraffe Giraffa camelopardalis	Namibia	M85-103	pectoral, thigh	neg.
		M85-104	pectoral, thigh	neg.
" " "	Transvaal(East.)	M86-81	leg, masseter, occipital	n.e.

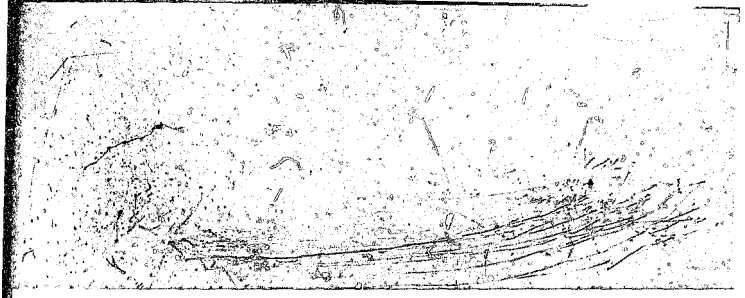

FAMILY: BOVIDAE
SUBFAMILY: ALCELAPHINAE
TRIBE: CONNOCHAETINI

Wildebeest Connochaetes taurinus	Natal	M82-88	pectoral, hindleg	n.e.
		M82-204	head	n.e.
		M82-206	head	n.e.
		M82-207	head	n.e.
		M82-84	pectoral, hindleg	n.e.
		M82-85	pectoral, hindleg	n.e.
		M82-87	pectoral, hindleg	n.e.
		(M83-17)	pectoral, hindleg	n.e.
		(M83-18)	pectoral, hindleg	n.e.

TRIBE: ALCELAPHINI

Tsessebe Damaliscus lunatus	Transvaal(North.)	M85-72	pectoral, thigh	neg.
		M85-87	pectoral, thigh	neg.

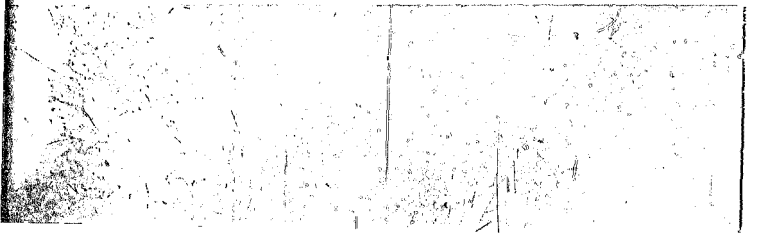



SUBFAMILY: ANTILOPINAE

TRIBE: ANTILOPINI

Springbuck Antidorcas marsupialis	Namibia	M83-58	neck, frontleg, hindleg	n.e.
		M83-54	neck, frontleg, hindleg	n.e.
		M83-55	neck, frontleg, hindleg	n.e.
		M85-59	neck, frontleg, hindleg	n.e.
		M85-60	neck, frontleg, hindleg	n.e.
		M85-79	neck, frontleg, hindleg	n.e.
		M83-178	neck, frontleg, hindleg	n.e.



		M83-179	neck, frontleg, hindleg	n.e.
		M83-180	neck, frontleg, hindleg	n.e.
		M83-182	neck, frontleg, hindleg	n.e.
		M83-183	neck, frontleg, hindleg	n.e.
		M83-184	neck, frontleg, hindleg	n.e.
		M83-186	neck, frontleg, hindleg	n.e.
SUBFAMILY: AEPYCEROTINAE				
Impala Aepyceros melampus	Transvaal(East.)	M83-100	skeletal	n.e.
		M83-101	skeletal	n.e.
		M83-108	skeletal	n.e.



		M83-141	thorax, abdomen, pelvic, hindleg	n.e.
		M83-157	pectoral, pelvic	n.e.
Impala Aepyceros melampus	Zimbabwe	M80-132	skeletal	neg.
		M80-133	skeletal	neg.
		M80-132+133X	skeletal	neg.
		M80-135	skeletal	neg.
		M80-135X	skeletal	neg.
		M83-1A	skeletal	neg.
		M83-4B	skeletal	neg.
		(M80-78)	skeletal	n.e.
SUBFAMILY: HIPPOTRAGINAE				
Gemsbuck Oryx gazella	Namibia	M83-43	neck, frontleg, hindleg	n.e.
		M83-42	neck, frontleg, hindleg	n.e.





M83-46	neck, frontleg, hindleg	n.e.
M83-47	neck, frontleg, hindleg	n.e.
M83-48	neck, frontleg, hindleg	n.e.
M83-49	neck, frontleg, hindleg	n.e.
M83-74	neck, frontleg, hindleg	n.e.
M83-75	neck, frontleg, hindleg	n.e.
M83-76	neck, frontleg, hindleg	n.e.
M83-77	neck, frontleg, hindleg	n.e.





M83-171	neck, frontleg, hindleg	n.e.
M83-172	neck, frontleg, hindleg	n.e.
M83-173	neck, frontleg, hindleg	n.e.
M83-174	neck, frontleg, hindleg	n.e.
M83-175	neck, *frontleg*, hindleg	n.e.
M83-176	neck, frontleg, hindleg	n.e.
M83-177	neck, frontleg, hindleg	n.e.



SUBFAMILY: BOVINAE				
TRIBE: BOVINI				
Buffalo Syncerus caffer	Zimbabwe	(M80-144)	skeletal	n.e.
TRIBE: TRAGELAPHINI				
Kudu Tragelaphus strepsiceros	Namibia	M83-50	neck, frontleg, hindleg	n.e.
		M83-51	neck, frontleg, hindleg	n.e.
		M83-82	neck, frontleg, hindleg	n.e.
		M83-85	neck, frontleg, hindleg	n.e.
		M83-186	neck, frontleg, hindleg	n.e.
		M83-189	neck, frontleg, hindleg	n.e.





Kudu Tragelaphus strepsiceros	Transvaal(East.)	M83-103	pectoral, diaphragm, hindquarter	n.e.
		M83-170	skeletal diaphragm	pos.
		M83-93	skeletal	n.e.
		M83-95	pectoral, hindleg	n.e.
		M83-96	skeletal	n.e.
		M83-97	skeletal	n.e.
		M83-104	pectoral, diaphragm, hindquarter	n.e.
		M83-106	pectoral, diaphragm, hindquarter	n.e.
		M83-116	pectoral, diaphragm	n.e.
		M83-117	pectoral, diaphragm, hindquarter	n.e.
		M83-118	pectoral, diaphragm, hindquarter	n.e.





M83-120	hindquarter	n.e.
M83-121	pectoral, diaphragm, hindquarter	n.e.
M83-122	pectoral, diaphragm, hindquarter	n.e.
M83-123	pectoral, diaphragm, hindquarter	n.e.
M83-124	pectoral, diaphragm, hindquarter	n.e.
M83-125	pectoral, diaphragm, hindquarter	n.e.
M83-126	pectoral, diaphragm, hindquarter	n.e.
M83-127	pectoral, diaphragm	n.e.
M83-128	pectoral, diaphragm, hindquarter	n.e.





M83-130	pectoral, thorax, abdomen, diaphragm, hindquarter, pelvic, hindleg	n.e.
M83-136	skeletal	n.e.
M83-151	pectoral, diaphragm, hindquarter	n.e.
M83-152	pectoral, diaphragm, hindquarter	n.e.
M83-160	pectoral, diaphragm, hindquarter	n.e.
M83-161	pectoral, diaphragm, hindquarter	n.e.
M83-162	pectoral, diaphragm, hindquarter	n.e.





		M83-163	pectoral, diaphragm	n.e.
		M83-164	pectoral, diaphragm, hindquarter	n.e.
		M83-165	pectoral, diaphragm, hindquarter	n.e.
		M83-166	pectoral, diaphragm, hindquarter	n.e.
		M83-167	pectoral, diaphragm, hindquarter	n.e.
		M83-169	skeletal, diaphragm	pos.
Kudu Tragelaphus strepsiceros	Zimbabwe	M83-3	skeletal	n.e.
Bushbuck Tragelaphus scriptus	Transvaal(East.)	M83-159	pectoral, pelvic	n.e.
SUBFAMILY: REDUNCINAE				
Waterbuck Kobus ellipsiprymnus	Transvaal(East.)	M83-112	pectoral, pelvic	n.e.



		M83-111	pectoral, pelvic	n.e.
Lechwe Kobus leche	Namibia	M83-34	skeletal	n.e.



APPENDIX 6: LABORATORY RODENTS USED IN SARCOCYSTIS TRANSMISSION EXPERIMENTS - HOSTS EXAMINED HISTOPATHOLOGICALLY AND BY TRANSMISSION ELECTRON MICROSCOPY

SPECIES	NO. EXAM.	CONTROL	INOC.	NO. INFECT.	% INFECT.	NO. EXAM. T.E.M.
Black rat Rattus rattus*	18	5	13	6	46,15	2
Brown rat Rattus norvegicus albinus+	36	10	26	4	15,38	1
House mouse Mus musculus+	33	9	24	0	0,00	0

Note: Macroscopic examination for sarcocysts in skeletal muscle from the pectoral and thigh areas of 300 (three hundred) "control" R. norvegicus, which were of the same "stock" as those mentioned above but had been maintained in a different animal house, was negative.

---

* Laboratory-bred, from parents trapped in Johannesburg

\+ Laboratory-bred: Brown rat - Sprague-Dawley strain
House mouse - Swiss-Webster strain



APPENDIX 7: INDIVIDUAL MEASUREMENTS OF SARCOCYST COMPONENTS FROM MICROGRAPHS OF VARIOUS MAGNIFICATIONS

In most cases, the measurements were taken from micrographs of a single cyst from a single animal.

Where more than one cyst of the same species of Sarcocystis was measured from the same animal, this is indicated by the number of measurements given for cyst diameters for that specimen in this Appendix.

In cases where more than one animal of the same species from a particular region had the same kind of sarcocyst (based on *morphological structure*), the measurements for the components were pooled - as indicated in this Apoendix, where more than one specimen number precedes a group of measurements.

Cysts were measured randomly and no selection was made on the basis of maturity and/or size. The number of measurements for each component varies, and was dependent on the number and suitability of the micrographs. It is assumed that the measurements follow an approximately "normal" distribution.

In this Appendix, the specimen (laboratory) number of each animal (or numbers, if the measurements from more than one animal have been pooled) from which cyst measurements were taken, is listed on the left. Letters in the first vertical column are codes for the individual components (see component code key: C.) of the cyst(s) in the animal, that were selected for measurement. The individual measurements follow, and are listed horizontally.

The components of the cysts were measured in millimeters, from which the equivalent dimensions in micrometers (μm) were calculated, according to the magnifications of the micrographs. All measurements for the cyst components in this Appendix are given in micrometers (μm).

In order to measure the sarcocyst diameters from semi-thick sections on microscope slides, a magnification factor for an ocular micrometer (graticule in eyepiece) was used. The magnification factor was determined by calibration of a SM-Lux Leitz microscope with the aid of a 0,01 interval stage scale.

COMPONENT CODE KEY (C.):

a Width of cyst wall including ground substance
b Length of protrusions (longitudinal section: L.S.)*
c Width of protrusions (L.S.)*
d Longest measurement for protrusions (cross section: X.S.)**
e Shortest measurement for protrusions (X.S.)**
f Length of merozoites (L.S.)
g Width of merozoites (L.S.)
h Distance between bases of protrusions at cyst wall
i Longest diameter of cyst in semi-thick sections (X.S.)**
j Shortest diameter of cyst in semi-thick sections (X.S.)**
k Length of cyst in semi-thick sections (L.S.)
l Width of cyst in semi-thick sections (L.S.)

---

* Complete longitudinal sections of the protrusions were not obtained in cases where they were convoluted and/or not lying perfectly in the plane of section (Figure 116). Measurements for b and c refer to the parts of the protrusions visibly attached to the cyst body in the micrographs. A longitudinal section of a protrusion which was not connected at its base to the body of the cyst, was never measured. The reader should refer to the appropriate Figures (micrographs) when consulting the data in this Appendix.

** In cases of perfectly circular cross sections of protrusions, measurements for d and e would be identical. Similarly, in cases of perfectly circular cross sections of cysts, measurements for i and j would be identical.

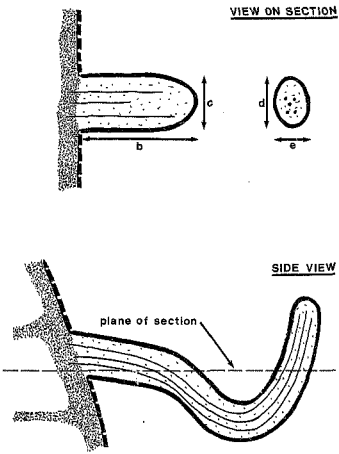

FIGURE 116: Diagram showing measurement codes for a protrusion not lying perfectly in the plane of section.

TM 30578: a 0,74; 0,70; 1,05; 0,92; 1,10
b 0,70; 0,68; 1,60; 1,90; 0,75; 3,20; 2,40
1,60; 1,40; 0,75
c 0,55; 0,52; 0,53; 0,47; 0,45
f 6,40; 6,25; 5,00
g 1,60; 1,50; 1,62
i 325,0
j 175,0

TM 30557: a 0,50; 0,48; 0,47; 0,47; 0,46
f 5,40; 4,80; 5,40; 4,67; 5,20
g 1,50; 1,60; 1,70; 2,00; 1,30
i 42,5
j 42,5

M79-20: a 0,60; 0,48; 0,62; 0,60; 0,63; 0,73; 0,87
0,79; 0,85; 0,78
f 5,50; 5,92; 5,25; 6,25; 6,00
g 1,92; 1,67; 1,75; 1,50; 1,25
i 72,5
j 70,0

DAS 4439: a 0,44; 0,45; 0,57; 0,46; 0,44; 0,47; 0,45
0,22; 0,25; 0,43; 0,23; 0,40
i 65,0
j 55,0

M83-114: a 1,13; 0,77; 0,60; 0,85; 0,87; 0,77; 0,80
1,13; 1,24; 1,20
b 1,45; 1,70; 1,50; 1,60; 1,33; 1,90; 1,80
1,73; 1,53; 1,27
c 1,33; 0,97; 1,20; 0,87; 1,15; 0,77; 0,93
1,33; 1,05; 1,15
f 9,50
g 1,75
i 37,5
j 35,0

M83-98: a 0,60; 0,68; 0,69; 0,94; 1,00; 0,72; 0,75
0,78; 0,67; 0,77; 1,30; 0,52; 0,50; 0,53
0,54; 0,54
f 4,06; 2,50; 2,50; 2,56
g 0,92; 0,81; 0,75; 0,69
i 187,5
j 135,0

M86-110: a 0,58; 0,43; 0,40; 0,50; 0,43; 0,60; 0,72
0,65; 0,52; 0,44
b 0,92; 0,80; 2,00; 0,87; 1,28; 2,05; 1,68
1,31; 1,00; 0,73
c 0,16; 0,23; 0,20; 0,20; 0,32; 0,20; 0,46
0,32; 0,25; 0,23
d 0,40; 0,42; 0,28; 0,55; 0,50; 0,54; 0,54
0,43; 0,38; 0,53
e 0,24; 0,32; 0,18; 0,30; 0,32; 0,28; 0,24
0,18; 0,22; 0,23
f 12,40
g 1,50

M83-143: a 0,60; 0,67; 0,80; 0,86; 0,85; 0,90; 0,87
0,97; 0,73; 0,80
b 4,00; 3,83; 4,00; 4,10; 3,97; 4,05; 4,06
4,12; 4,25; 4,06
c 1,00; 0,95; 0,86; 1,20; 1,09; 0,87; 1,03
1,12; 1,00; 0,87
f 7,67
g 2,18
i 82,5
j 42,

TM 30558/30571/30575:	a	0,43;	0,43;	0,30;	0,35;	0,40	
		0,68;	0,72;	0,72;	0,73;	0,80	
		0,33;	0,33;	0,37;	0,40;	0,30	
		0,37;	0,40;	0,48;	0,68;	0,80	
	f	4,50;	4,85;	3,75;	3,50;	3,00	
		4,50;	4,00;	3,38;	4,25		
	g	1,00;	1,06;	1,50;	1,13;	1,25	
		1,00;	1,38;	1,13;	1,28		
TM 30558:	i	70,0					
	j	50,0					
TM 30571:	i	122,5					
	j	112,5					
TM 30575:	i	47,5					
	j	42,5					

TM 30518:	a	0,55;	0,56;	0,52;	0,48;	0,54;	0,55;	0,57
		0,53;	0,35;	0,33;	0,30;	0,33;	0,33;	0,30
		0,37;	0,33;	0,40;	0,40			
	f	3,63						
	g	1,13						
	i	60,0						
	j	50,0						

TM 30565:	a	0,60;	0,47;	0,33;	0,23;	0,28;	0,23;	0,24
		0,27;	0,40;	0,22;	0,38;	0,27;	0,23;	0,28
		0,23						
	f	5,00;	4,75;	5,88				
	g	0,92;	1,17;	0,83				
	i	75,0;	67,5					
	j	40,0;	50,0					

TM 30566: a 0,80; 1,20; 1,00; 0,92; 0,92; 0,88; 1,08
1,05; 0,90; 0,97; 1,06; 1,20
b 5,80; 7,53
c 0,67; 0,67
d 1,56; 1,12; 0,88; 0,85; 0,92; 0,98; 1,00
1,64; 1,04; 0,84
e 0,72; 0,47; 0,60; 0,68; 0,56; 0,44; 0,68
0,60; 0,60; 0,64
f 8,00; 7,75
g 2,00; 2,50
i 135,0
j 82,5

M82-78: a 0,63; 0,50; 0,57; 0,47; 0,80; 0,62; 0,48
0,44; 0,72; 0,80; 0,63; 0,64; 0,76
b 2,22; 1,54
c 0,40
d 1,60; 1,27; 1,58; 1,60
e 0,43; 0,42; 0,48; 0,40
i 90,0
j 72,5

M80-164: f 10,00; 14,33; 9,00; 10,67
g 3,17; 2,83; 3,50; 3,00
i 115,0; 82,5
j 105,0; 70,0

M81-216: a 0,73; 0,75; 1,22
d 2,00; 1,15; 1,67; 1,32; 1,13
e 0,63; 0,54; 0,50; 0,67; 0,52
f 10,20; 9,33; 7,40
g 2,80; 2,50; 2,20
i 72,5; 67,5; 47,5
j 67,5; 55,0; 45,0

M82-202: a 0,63; 0,68; 0,77; 0,82; 0,67; 0,69; 0,70
1,32; 1,28; 1,33
b 2,12; 2,50; 2,12
c 0,50; 0,48; 0,43
d 0,63; 0,90; 0,90; 0,75
e 0,50; 0,53; 0,67; 0,40
f 6,25; 6,25; 6,50; 7,00; 9,60; 5,60; 5,70
6,00
g 2,25; 2,00; 1,75; 3,00; 2,33; 2,00; 2,00
2,33
i 57,5
j 55,0

M83-65: a 0,97; 0,78; 0,77; 1,12; 0,86; 1,02; 0,75
0,83; 0,63; 0,65; 0,90; 0,90; 0,97
d 0,74; 1,10; 0,93; 0,90; 1,20; 1,40; 1,17
0,93; 2,00
e 0,58; 0,57; 0,38; 0,62; 0,56; 0,33; 0,50
0,47; 0,57
f 10,63
g 3,13
i 72,5
j 60,0

M82-76: a 0,85; 1,00; 0,90; 0,87; 0,80; 1,08; 0,93
0,90; 0,80; 1,05; 1,20; 1,08; 0,60; 0,90
0,95; 0,77; 0,80; 1,55
b 3,00; 2,95; 2,60; 2,40; 3,33; 1,84; 1,46
c 0,45; 0,47; 0,40; 0,47; 0,56; 0,48; 0,45
d 0,88; 0,75; 1,05; 0,80; 1,24; 0,90; 0,80
e 0,63; 0,65; 0,70; 0,68; 0,58; 0,75; 0,67
i 82,5
j 60,0

WART 4:	a	0,80;	0,75;	0,72;	0,73		
	d	1,53;	2,20;	2,60;	1,70;	1,65	
	e	1,86;	2,30;	2,30;	1,60;	1,55	
	f	7,75;	7,50;	5,75;	9,00		
	g	2,00;	2,00;	2,25;	3,00		
	i	*100,0*					
	j	95,0					
M82-94:	a	0,75;	0,65;	0,72;	0,67;	0,58;	0,67
	b	2,40;	2,25;	2,17			
	c	1,07;	1,20;	1,16			
	d	1,85;	1,95;	1,90;	1,70;	1,85	
	e	1,45;	1,55;	1,50;	1,25;	1,30	
	i	45,0					
	j	42,5					
M83-66:	a	2,06;	0,56;	0,75;	1,75;	1,50;	2,06; 2,00
		1,60;	2,60;	1,81			
	b	3,50;	4,25;	4,30;	3,25		
	c	8,25;	5,25;	4,85			
	f	11,80;	9,40				
	g	2,20;	2,50				
	i	1068,2;	970,2				
	j	852,6;	588,0				
M83-2C:	a	0,73;	0,67;	0,67;	0,67;	0,67	
	b	3,06;	2,93;	2,80;	3,06;	2,76;	2,93; 2,53
	c	1,10;	1,06;	1,28;	1,16;	1,40;	1,00; 1,00
	i	90,0					
	j	72,5					

M83-131: a 0,89; 0,84; 0,80; 0,89; 0,88; 1,42; 1,50
1,56; 2,12
b 4,70; 4,00; 3,80; 4,40; 5,20; 5,50; 5,60
5,50; 5,50; 6,20; 5,17; 5,56
c 0,71; 0,64; 0,70; 0,54; 0,80; 0,70; 0,76
0,94; 1,00; 0,60; 0,83; 0,75
f 8,33; 11,50; 11,75
g 2,00; 2,50; 2,00
i 62,5; 60,0
j 55,0; 57,5

M85-103: a 0,50; 0,90; 0,70; 0,67; 0,60
b 1,40; 1,20; 1,30; 1,00; 1,27; 1,40
c 0,35; 0,20; 0,20; 0,20; 0,23; 0,20
h 0,97; 1,05
i 100,0
j 75,0

M85-61: a 0,45; 0,40; 0,35; 0,30; 0,27
b 2,80; 1,60; 1,30; 1,65; 1,45
c 0,45; 0,10; 0,15; 0,10; 0,16
d 1,47; 0,93; 1,20; 1,00; 0,87
e 0,60; 0,53; 0,40; 0,56; 0,57
h 1,70; 1,10; 1,07; 1,27; 1,15
i 85,0
j 80,0

MB2-88/204-207:	a	0,80;	0,56;	1,18;	0,60;	0,65;	0,72
		0,50;	0,58				
	d(M)*	1,30;	1,10;	2,16;	1,07;	1,09	
	e(M)*	0,70;	0,80;	0,72;	0,38;	0,87	
	d(C)*	0,88;	0,82;	0,62;	1,55;	1,05;	1,00
	e(C)*	0,56;	0,48;	0,50;	0,57;	0,75;	0,64
	f	7,62;	5,25;	9,25;	8,12		
	g	2,25;	2,75;	3,75;	4,12		
MB2-88:	i	57,5					
	j	32,5					
MB2-204-207:	i	50,0					
	j	37,5					

MB5-72:	a	0,75;	0,90;	0,57;	0,67;	1,00;	1,00;	0,77
		0,75;	1,00;	0,87;	0,88;	0,90		
	d	1,25;	1,45;	1,70;	1,17;	1,20;	1,50;	1,85
		1,00;	0,80;	1,63				
	e	1,50;	1,40;	1,40;	1,80;	1,47;	1,50;	1,40
		1,69;	1,40;	1,88				
	f	10,00;	11,83;	12,67;	10,50;	10,83		
	g	2,38;	2,33;	2,00;	2,33;	2,67		
	i	70,0						
	j	70,0						

MB3-58:	a	1,50;	1,50;	1,10;	1,37;	1,60;	1,50;	1,37
		1,40;	1,25					
	b	7,70;	7,37;	7,00;	7,33;	8,00;	7,87	
	c	0,30						
	f	8,67;	9,67;	7,67				
	g	3,00;	2,67;	2,33				
	i	185,0						
	j	155,0						

---

* See explanation at bottom of Table 2.

M83-100/101: a		0,77;	0,50;	0,40;	0,67;	0,40;	0,67
		0,53;	1,37;	1,10;	1,00;	1,03;	0,90
		1,00					
	d(M)*	3,25;	2,50;	2,83;	1,97;	2,30;	2,15
		2,20;	2,00				
	e(M)*	0,90;	0,63;	0,53;	0,70;	0,80;	0,90
		0,80;	0,80				
	d(C)*	[illegible];	1,10;	1,06;	1,25		
	e(C)*	0,55;	0,50;	0,87;	0,50		
	ŷ	8,87;	8,60				
	g	2,62;	2,00				
M83-100: i	70,0						
j	47,5						
M83-101: i	82,5						
j	80,0						

* See explanation at bottom of Table 2.

M80-132/13[illegible]/132+3X/135: a		0,47;	0,44;	0,49;	0,46;	0,50
		0,46;	0,60;	1,35;	0,92;	1,55
		1,50;	1,37;	0,87;	0,80;	1,40
		1,25				
	d(M)*	1,60;	1,32;	1,90;	2,30;	1,12
		1,20;	1,54;	1,57;	2,10;	1,50
		1,55;	1,45			
	e(M)*	0,66;	0,84;	0,70;	1,47;	1,04
		1,04;	1,12;	1,50;	0,65;	1,40
		1,55;	1,32			
	d(C)*	0,96;	1,40;	0,[illegible]	0,55;	0,87
		1,75				
	e(C)*	0,64;	0,60;	[illegible]	0,77;	1,[illegible]
		0,67				
	f	5,50;	5,50			
	g	1,66;	2,00;	2,50		
M80-132: i	50,0					
j	47,5					
M80-133: i	37,5					
j	32,5					
M80-132+3X: i	50,0					
j	42,5					
M80-135: i	85,0; 120,0					
j	47,5; 55,0					

* See explanation at bottom of Table 2.

M80-135X/M83-1A/48: a 0,80; 0,55; 0,35; 0,75; 0,46
b 1,05; 0,90; 3,27; 1,17; 1,40
c 1,60; 2,20; 0,87; 1,60; 1,33
f 7,75; 8,25; 7,25; 7,25; 7,75
8,75; 6,5
g 2,25; 3,75; 1,75; 2,00; 2,75
2,50; 2,25

M80-135X: i 60,0
j 55,0

M83-1A: i 87,5; 55,0
j 67,5; 50,0

M83-48(F): i 57,5
j 55,0
k 372,4
l 68,6

M83-48: a 0,20; 0,30; 0,26; 0,20; 0,30
d 0,42; 0,42; 0,46; 0,52; 0,62; 0,64
e 0,14; 0,12; 0,13; 0,13; 0,14; 0,11
f 7,75; 8,40; 7,60
g 2,38; 2,40; 1,80

M83-48(B): i 85,0
j 80,0

M83-43: a 0,64; 0,54; 0,62; 1,13; 0,67; 0,65; 0,55
0,67; 0,62; 0,52; 0,72; 0,56
d 0,37; 0,43; 0,35; 0,50; 0,47; 0,52; 0,47
0,80; 0,56; 0,60
e 0,12; 0,18; 0,20; 0,18; 0,23; 0,27; 0,23
0,13; 0,28; 0,16
f 9,50; 10,33; 10,33; 13,00; 9,67
g 2,33; 1,83; 3,3.; 2,00; 2,33
i 52,5
j 42,5

M83-50: a 0,73; 0,70; 0,30; 0,35; 0,33
d 0,38; 0,30; 0,35; 0,30
e 0,25; 0,25; 0,28; 0,23
f 13,00; 10,25; 8,75
g 2,50; 4,13; 2,76
i 55,0
j 52,5

M83-103: a 0,18; 0,30; 0,30; 0,17; 0,23; 0,22; 0,18
0,17
d 0,40; 0,33; 0,25; 0,40; 0,37; 0,35; 0,37
0,25; 0,22
e 0,13; 0,18; 0,20; 0,17; 0,17; 0,17; 0,17
0,18; 0,20
f 10,70; 8,10; 7,40
g 2,40; 1,70; 2,40
i 52,5
j 37,5

M83-170A: a 0,11; 0,13; 0,10; 0,15
d 0,36; 0,34; 0,37; 0,38; 0,38; 0,28
e 0,09; 0,10; 0,10; 0,12; 0,11; 0,09
i 52,5
j 37,5

M83-170D: a 0,23; 0,24; 0,23; 0,37
d 0,35; 0,32; 0,30; 0,38; 0,33; 0,27
e 0,13; 0,14; 0,17; 0,13; 0,23; 0,17
i 60,0
j 57,5

M83-3: a 0,67; 0,90; 0,95; 1,00; 1,20; 0,90
b 3,83; 4,83; 5,25; 4,00; 3,50; 3,65
c 0,92; 0,83; 0,58; 0,95; 1,83; 2,33
d 1,35; 1,30; 1,48
e 0,55; 0,63; 0,45
f 9,08; 8.00
g 2,00; 2,83
i 90,0
j 85,0

M83-159: a 0,12; 0,12; 0,17; 0,11; 0,31; 0,20; 0,19
0,16
d 0,41; 0,42; 0,36; 0,37; 0,42; 0,37; 0,50
0,50; 0,40; 0,84; 0,87; 0,45; 0,40; 0,30
0,35; 0,40; 0,32; 0,30; 1,10; 1,50
e 0,15; 0,19; 0,21; 0,20; 0,25; 0,30; 0,17
0,15; 0,10; 0,16; 0,07; 0,07; 0,17; 0,16
0,14; 0,15; 0,12; 0,14; 0,20; 0,30
i 57,5
j 52,5

M83-112: a 0,20; 0,28; 0,27; 0,27; 0,32; 0,31; 0,25
0,30; 0,24; 0,24; 0,25; 0,23
d 0,62; 0,47; 0,67; 0,32; 0,36; 0,38; 0,47
0,73; 0,40; 0,60
e 0,15
f 6,67; 7,17
g 2,33; 1,58
i 52,5
j 45,0

M83-34: a	0,60;	0,38;	0,33;	0,47;	0,52;	0,36;	0,48
	0,40;	0,72;	0,70;	0,40;	0,56;	0,88	
d(M)*	1,12;	0,96;	1,13;	1,64;	1,20;	0,92;	0,92
	1,46;	1,26;	1,26;	1,26			
e(M)*	0,46;	0,40;	0,47;	0,46;	0,64;	0,72;	0,70
	0,50;	0,56;	0,55;	0,66			
d(C)*	0,80;	0,64;	0,65;	0,88;	1,32;	0,80;	0,90
	0,95;	0,76;	1,12				
e(C)*	0,68;	0,42;	0,42;	0,68;	0,68;	0,72;	0,68
	0,65;	0,48;	0,54				
f	8,10						
g	2,70						
i	40,0						
j	30,0						

M82-203: a	1,23;	1,20;	1,12;	1,25;	1,16;	2,30;	2,75
	1,05;	1,13;	1,25;	1,10;	2,70;	1,03;	0,88
	1,23;	1,20					
d	1,58;	1,55;	1,45;	1,45;	1,75;	1,60;	4,90
	3,07;	4,90;	1,35;	1,44;	2,30		
e	0,44;	0,45;	0,55;	0,55;	0,75;	0,43;	2,65
	1,67;	3,00;	0,58;	0,52;	0,80		
f	10,00;	7,25;	6,75;	7,25;	6,00;	5,75	
g	2,63;	2,85;	2,75;	2,75;	2,00;	2,50	
i	170,0;	180,0;	162,5				
j	145,0;	162,5;	62,5				

M80-25: a	0,38;	0,30;	0,38;	0,30;	0,34;	0,33;	0,41
	0,19;	0,18;	0,20;	0,25;	0,33;	0,37;	0,30
	0,34						
d	0,25;	0,36;	0,20;	0,48			
e	0,10;	0,10;	0,10;	0,20			
i	45,0						
j	40,0						

---

* See explanation at bottom of Table 2.

M82-58: a 0,83; 1,04; 1,40; 0,63; 0,60; 0,80; 0,64
1,33
b 2,10; 4,20; 3,80; 3,73
c 0,50; 0,67; 0,90; 1,00
d 1,77; 1,38; 1,30; 1,20; 2,20
e 0,43; 0,37; 0,37; 0,40; 0,67
f 150,0; 97,5
j 87,5; 82,5

M82-4: c 2,80
d 1,47; 1,20; 1,00; * 1,60; 2,20
e 0,67; 1,07; 0,67; 0,93; 0,87
f 127,5; 92,5; 107,5; 105,0; 85,0; 205,0; 142,5
160,0
j 107,5; 75,0; 97,5; 100,0; 77,5; 142,5; 125,0
105,0

M83-190/191: a 0,20; 0,25; 0,24; 0,13; 0,25
d 1,00; 1,03
e 0,15; 0,17
f 6,83
g 2,50
M83-190: f 137,5
j 112,5
M83-191: f 80,0
j 57,5

M80-28: a 0,22; 0,22; 0,20
d 0,90; 0,7[illegible] 0,64
e 0,24; 0 35; 0,22
f 70,0; 57,5; 40,0; 140,0. 57,5
j 65,0; 45,0; 40,0; 95,0; 55,0

M80-13-24: a 1,80; 2,00; 1,57; 2,20; 8,75
f 12,00; 8,00; 11,00; 11,80; 9,00; 11,30
g 3,00; 3,00; 2,60; 2,40; 2,30; 2,20
i 1068,2
j 862,4

M79-128: a 0,50; 0,58; 0,50; 0,48; 0,52; 0,66; 0,64
0,68; 0,73; 0,70; 0,67; 0,54
f 150,0
ƒ 142,5

M79-112: a 0,38; 0,44; 0,60; 0,55; 0,50; 0,53; 0,44
0,42; 0,53; 0,40
f 77,5
ƒ 55,0

APPENDIX 8: DISSECTION OF RODENT HOSTS TO DETERMINE THE PRESENCE OF SARCOCYSTS IN MUSCLE FOR EXPERIMENTS 3 AND 4

The following procedure was adopted, unless otherwise stated, for all specimens examined.

The animal was killed by exposure to chloroform and then weighed. The skin covering the ventral surface of both the left and right hind legs was cut and pulled away. That overlying the ventral thoracic area was cut in a "V" shape, each cut extending to an axilla of the animal. This skin was folded back over the lower jaw. Macroscopic examinations were then carried out by two persons (T.J.M. Daly and M.B. Markus). Following this, two small pieces of skeletal muscle from the leg region and two pieces from the pectoral/shoulder area were examined microscopically (fresh preparations) for the presence of sarcocysts. Skeletal muscle from the left and right femoral regions, left and right pectoral areas and the left and right shoulder (scapula/humeral area) was removed and fixed in neutral-buffered formal-saline for subsequent light microscopic scrutiny.

Details are provided here only for "positive" animals (and animals which died prematurely). Details of negative animals are listed in summary form in Tables 7 and 8.

KEY

D.I. Day of inoculation
P.M. Day of autopsy (post-mortem)
D.P.I. Days post inoculation
Mass Weight at post-mortem
pos. "Positive" for Sarcocystis infection
neg. "Negative" for Sarcocystis infection

EXPERIMENT 3

Animals inoculated by stomach tube with Rattus rattus/cat Sarcocystis sporocysts.

R. rattus M79-31: male
Born: March 1979 (laboratory-bred)
D.I.: 16 November 1979 Dose: 122 500
P.M.: 1 April 1980 Mass: 258,20 g

Sarcocysts were seen both macroscopically and microscopically. As the infection was heavy, the cysts were easily visible to the naked eye. Measurements of ten cysts were taken from the pectoral muscles: mean 5,2 mm (range: 4,0-7,0 mm). Skeletal muscle was removed from the left and right hind legs, and placed in formal-saline together with three pieces of tongue muscle. Skeletal muscle from the diaphragm and pectoral and shoulder areas was placed together in a large bottle of fixative with three pieces of muscle from the ventricle of the heart and pieces of duodenum, removed from just below the pyloric sphincter.

R. rattus M79-38: male
Born: March 1979 (laboratory-bred)
D.I.: 16 November 1979 Dose: 12 250
P.M.: 1 April 1980 Mass: 289,01 g

Sarcocysts were seen macroscopically in the deeper muscles, close to the costal and intercostal muscles, and in the superficial muscles of the pectoral and shoulder regions. Measurements of ten cysts from these areas were: mean 7,0 mm (range: 5,0-9,0 mm). The dissection procedure was the same as that for M79-31 (above). This specimen was not as heavily infected as M79-31, but a lot more cysts could be seen in the deeper muscle layers.

R. rattus M79-46: male. CONTROL
Born: March 1979 (laboratory-bred)
P.M.: 1 April 1980 Mass: 274,03 g

This rat was heavily infected. Measurements of macroscopic cysts (10) were taken only from the pectoral and costal regions: mean 6,8 mm (range: 4,0-9,0 mm). Skeletal muscle from the left and right hind limbs was fixed immediately in formal-saline together with three pieces of tongue. Muscle from the pectoral and costal regions was removed and fixed, but no muscles from the shoulder region were taken; nor were the heart or duodenum removed.

R. norvegicus M79-47: female. CONTROL
Born: -*
P.M.: 9 April 1980 Mass: 235,30 g

A light Sarcocystis infection was detected in the musculature. In addition to skeletal muscle, heart, duodenum and tongue were fixed in formal-saline. The remainder of the fresh skeletal muscle was removed and fed to two cats on 10 April 1980 (see transmission experiment 7).

R. norvegicus M79-24: female
Born: -
D.I.: 16 November 1979 Dose: 50 000
Died: 17 November 1979 Mass: 220,10

Impression smears were made from the mesenteric lymph nodes and the peritoneal cavity. No stages of Sarcocystis were found.

---

* R. norvegicus were selected by weight rather than by age.

R. rattus M79-35: male

Born: March 1979 (laboratory-bred)

D.I.: 16 November 1979 Dose: 25 000

Died: 16 February 1981 Mass: -

Skeletal muscle from the abdominal (ventral), pelvic and pectoral regions were examined macroscopically for sarcocysts; none were found. Muscle from these regions was fixed in formal-saline for subsequent light microscopic examination (no cysts were detected).

TABLE 7: Rodents inoculated by stomach tube with Rattus rattus/cat Sarcocystis sporocysts on 16 November 1979.

- For experiment 3

SPECIMEN NO.	SPECIES	INOCULUM	P.M. D.P.I.	MASS	RESULT
M79-24	R. norvegicus	50 000	1	220,1	neg.
M79-31	R. rattus	122 500	137	258,2	pos.
M79-32	R. norvegicus	122 500	139	272,9	neg.
M79-33	M. musculus	122 500	139	31,3	neg.
M79-34	M. musculus	50 000	144	28,3	neg.
M79-35	R. rattus	25 000	-	?	neg.
M79-36	R. norvegicus	25 000	145	260,0	neg.
M79-37	M. musculus	25 000	144	36,6	neg.
M79-38	R. rattus	12 250	137	289,0	pos.
M79-39	R. norvegicus	12 250	139	240,1	neg.
M79-40	M. musculus	12 250	144	30,8	neg.
M79-41	R. norvegicus	12 250	144	232,0	neg.
M79-42	R. norvegicus	12 250	144	242,3	neg.
M79-43	R. norvegicus	12 250	144	230,0	neg.
M79-44	M. musculus	12 250	144	36,5	neg.
M79-45	M. musculus	12 250	139	29,5	neg.
M79-46	R. rattus	CONTROL	137	274,0	pos.
M79-47	R. norvegicus	CONTROL	145	235,3	pos.
M79-48	R. norvegicus	CONTROL	148	222,4	neg.
M79-49	R. norvegicus	CONTROL	148	262,0	neg.
M79-50	R. norvegicus	CONTROL	148	247,5	neg.
M79-51	R. norvegicus	CONTROL	148	253,7	neg.
M79-52	M. musculus	CONTROL	144	32 2	neg.
M79-53	M. musculus	CONTROL	149	28,3	neg.
M79-54	M. musculus	CONTROL	149	32,1	neg.
M79-55	M. musculus	CONTROL	149	25,9	neg.
M79-56	M. musculus	CONTROL	149	32,0	neg.

- see footnote to Table 8.

EXPERIMENT 4

Animals inoculated by stomach tube with Rattus rattus/cat Sarcocystis sporocysts.

R. rattus M79-57: female
Born: Probably 2nd generation (laboratory-bred)
D.I.: 17 November 1979 Dose: 18 000
P.M.: 19 April 1980 Mass: 179,05 g

Sarcocysts were found in this rat, but the infection was very light (lighter than that found in M79-90).

R. norvegicus M79-75: male
Born: -
D.I.: 17 November 1979 Dose: 18 000
P.M.: 17 April 1980 Mass: 459,01 g

The rat was heavily infected with Sarcocystis. Skeletal muscle from the pectoral and humeral regions was fixed in formal-saline in addition to duodenum, tongue, heart and brain. All remaining fresh muscle was removed and fed to each of four cats on 17 and 18 April 1980 (see transmission experiment 7).

R. rattus M79-90: female
Born: March 1979 (laboratory-bred)
D.I.: 17 November 1979 Dose: 10 000
P.M.: 19 April 1980 Mass: 158,50 g

This rat had a very light Sarcocystis infection, which was difficult to identify macroscopically. Macroscopic diagnosis was made from the thin muscle of the diaphragm. Muscle and tissue fixed in formal-saline included duodenum, tongue, heart and brain.

R. norvegicus M79-112: male. CONTROL

Born: -

P.M.: 16 April 1980 Mass: 400,20 g

A heavy infection of Sarcocystis was apparent. Ten sarcocysts in abdominal muscle measured: mean 7,95 mm (range: 6,0-12,5 mm). In addition to muscle from the pectoral and humeral regions, duodenum, tongue, heart and brain were fixed in formal-saline. All remaining fresh muscle was removed, and fed to each of four cats on 17 April 1980 (see transmission experiment 7).

R. norvegicus M79-114: male. CONTROL

Born: -

P.M.: 17 April 1980 Mass: 443,30 g

The animal was lightly infected with Sarcocystis. Prior to being killed the rat was seen to be lethargic. It had remained in the corner of the cage. Muscle from pectoral and humeral areas and duodenum, tongue, heart and brain were placed in formal-saline. All remaining muscle was stripped from the carcass, and fed to each of four cats on 17 and 18 April 1980 (see transmission experiment 7).

R. norvegicus M79-29: male

Born: -

D.I.: 17 November 1979 Dose: 18 000

P.M.: 1 December 1979 Mass: 195,02 g

This rat was killed only 14 days after inoculation, as it was sneezing and lethargic. Impression smears were made from the mesenteric lymph nodes, liver and lung. Pieces of mesenteric lymph node, spleen, liver, lung, kidney, heart, brain and adrenal gland were placed in formal-saline for light microscopy. Skeletal muscle was removed from the hind leg region and fixed for light microscopic examination. No stages of Sarcocystis were found.

R. rattus M79-64: female

Born: Laboratory-bred

O.I.: 17 November 1979 Dose: 18 000

P.M.: 24 November 1980 Mass: -

No sarcocysts were found, despite careful examination of the pectoral, pelvic, abdominal, intercostal and diaphragm muscles; both micro- and macroscopically. Tissue from the lung and diaphragm, intercostal, pectoral and pelvic muscles was placed in formal-saline for subsequent light microscopic screening.

TABLE B: Rodents inoculated by stomach tube with Rattus rattus/cat Sarcocystis sporocysts on 17 November 1979.

- For experiment 4

SPECIMEN NO.	SPECIES	INOCULUM	P.M. D.P.I.	MASS	RESULT
M79-29	R. norvegicus	18 000	14	195,0	neg.
M79-57	R. rattus	18 000	154	179,1	pos.
M79-64	R. rattus	18 000	374	?	neg.
M79-68	R. norvegicus	18 000	148	447,7	neg.
M79-69	R. norvegicus	18 000	148	429,7	neg.
M79-70	R. norvegicus	18 000	148	503,5	neg.
M79-71	R. norvegicus	18 000	148	418,0	neg.
M79-72	R. norvegicus	18 000	151	432,5	neg.
M79-73	R. norvegicus	18 000	152	426,7	neg.
M79-74	R. norvegicus	18 000	152	405,6	neg.
M79-75	R. norvegicus	18 000	152	459,0	pos.
M79-76	R. norvegicus	18 000	152	447,8	neg.
M79-78	M. musculus	18 000	148	33,6	neg.
M79-79	M. musculus	18 000	148	35,6	neg.
M79-80	M. musculus	18 000	148	31,4	neg.
M79-81	M. musculus	18 000	148	29,0	neg.
M79-82	M. musculus	18 000	150	32,7	neg.
M79-83	M. musculus	18 000	150	33,7	neg.
M79-84	M. musculus	18 000	150	33,3	neg.
M79-85	M. musculus	18 000	150	33,6	neg.
M79-86	M. musculus	18 000	150	33,4	neg.
M79-87	R. norvegicus	35 000	152	422,4	neg.
M79-88	M. musculus	35 000	150	37,9	neg.
M79-90	R. rattus	10 000	154	158,5	pos.
M79-93	R. norvegicus	10 000	152	413,8	neg.
M79-94	R. norvegicus	10 000	152	481,0	neg.
M79-95	R. norvegicus	10 000	153	397,7	neg.
M79-96	R. norvegicus	10 000	153	507,6	neg.
M79-97	R. norvegicus	10 000	153	454,1	neg.
M79-98	R. norvegicus	10 000	154	458,6	neg.

M79-99	R. norvegicus	10 000	154	477,1	neg.
M79-100	M. musculus	10 000	150	30,7	neg.
M79-101	M. musculus	10 000	150	38,7	neg.
M79-102	M. musculus	10 000	150	37,2	neg.
M79-103	M. musculus	10 000	150	35,7	neg.
M79-105	M. musculus	10 000	150	29,4	neg.
M79-106	M. musculus	10 000	150	34,1	neg.
M79-107	M. musculus	10 000	150	36,7	neg.
M79-108	M. musculus	10 000	150	34,8	neg.
M79-110	R. norvegicus	18 000	153	476,7	neg.
M79-111	R. norvegicus	CONTROL	151	432,5	neg.
M79-112	R. norvegicus	CONTROL	151	400,2	pos.
M79-113	R. norvegicus	CONTROL	151	427,5	neg.
M79-114	R. norvegicus	CONTROL	152	443,3	pos.
M79-115	R. norvegicus	CONTROL	152	485,2	neg.
M79-116	M. musculus	CONTROL	151	38,2	neg.
M79-117	M. musculus	CONTROL	151	34,9	neg.
M79-118	M. musculus	CONTROL	151	36,9	neg.
M79-119	M. musculus	CONTROL	151	34,7	neg.

Note: There were an additional 300 (three hundred) "control" R. norvegicus for experiments 3 and 4 together. They were of the same "stock" as those given sporocysts but were kept in a different animal house. The 300 additional "control" rats were used for anatomical dissection purposes in student practical classes and were inspected for macrocysts by T.J.M. Daly and M.B. Markus at the time that the dissections commenced.

APPENDIX 9: DISSECTION OF RATTUS RATTUS TO DETERMINE THE PRESENCE OF SARCOCYSTIS FOR EXPERIMENTS 5 AND 6

EXPERIMENT 5

Animals inoculated by stomach tube with Rattus rattus/cat Sarcocystis sporocysts.

R. rattus M79-28: male
Born: Young (laboratory-bred)
D.I.: 21 November 1979 Dose: 350 000
P.M.: 4 December 1979 Mass: 168,25 g

After 13 days p.i., impression smears were made from mesenteric lymph node, spleen, liver, lung, kidney, brain and adrenal gland. Blood smears were prepared from blood in the abdomen at the time of removal of the liver. Pieces of mesenteric lymph node, spleen, kidney, heart, brain, adrenal gland, pancreas and skeletal muscle were fixed in formal-saline. Lung and liver were also placed in formal-saline; as well as in glutaraldehyde and Karnovsky's fixatives, for subsequent processing for transmission electron microscopy. Formal-saline-fixed liver was processed for histological examination in January 1980; no stages of Sarcocystis infection were seen. (Skeletal muscle examined macroscopically for sarcocysts at the time of autopsy, was negative).

R. rattus M79-120: male
Born: Young (laboratory-bred)
D.I.: 21 November 1979 Dose: 175 000
P.M.: 7 December 1979 Mass: 210,01 g

After 16 days p.i., impression smears were made of the same tissues as for M79-28. In addition, tissue imprints were prepared from the pancreas and blood smears from the renal vein, 35-40 mins after death. Tissues were fixed in formal-saline as for M79-28. Liver was placed in glutaraldehyde and Karnovsky's fixatives for later processing for transmission electron microscopy. Formal-saline-fixed liver was processed in paraffin wax, and frozen

sections (cryostat) were cut for histological examination in January 1980; no stages of Sarcocystis were evident. (Skeletal muscle examined macroscopically for sarcocysts at the time of autopsy, was negative).

TABLE 9: Rodents inoculated by stomach tube with Rattus rattus/cat Sarcocystis sporocysts on 21 November 1979.

- For experiment 5

SPECIMEN NO.	SPECIES	INOCULUM	P.M. D.P.I.	MASS	RESULT
M79-28	R. rattus	350 000	13	168,5	neg.
M79-120	R. rattus	175 000	16	210,0	neg.

EXPERIMENT 6

Animals inoculated by stomach tube with Rattus rattus/cat Sarcocystis sporocysts.

R. rattus M79-122: male
Born: 5 weeks old (laboratory-bred)
D.I.: 3 December 1979 Dose: 150 000
P.M.: 13 December 1979 Mass: 86,01 g

After 10 days p.i., impression smears were made from mesenteric lymph node, spleen, liver, lung, kidney, brain, adrenal gland, peritoneal cavity and pancreas. Tissue imprints and blood smears were stained with Giemsa. Mesenteric lymph node, liver, lung and adrenal gland were fixed in formal-saline for light microscopy and pieces of liver were placed in glutaraldehyde and Karnovsky's fixative for subsequent processing for transmission electron microscopy. Liver tissue processed for histological examination in January 1980, showed no evidence of Sarcocystis infection. (Sarcocysts were not found in skeletal muscle examined macroscopically at the time of autopsy).

R. rattus M79-123: male. CONTROL
Born: 5 weeks old (laboratory-bred)
P.M.: 13 December 1979 Mass: 81,33 g

Impression smears and blood smears were made of the same tissues as for M79-122. Spleen, liver, lung, kidney, heart, brain, adrenal gland, pancreas and skeletal muscle were placed in formal-saline for subsequent light microscopic examination. Liver tissue processed for histological examination in January 1980, showed no evidence of Sarcocystis infection. Sarcocysts were not found in skeletal muscle checked macroscopically at the time of autopsy.

R. rattus M79-124: female
Born: 5 weeks old (laboratory-bred)
D.I.: 3 December 1979 Dose: 150 000
P.M.: 15 December 1979 Mass: 71,85 g

Impression smears and blood smears were made of the same tissues as for M79-122, after 12 days p.i. Spleen, liver, lung, kidney, heart, brain, adrenal gland, pancreas and skeletal muscle were placed in formal-saline for light microscopy. Liver tissue processed for histological examination in January 1980, contained no stages of Sarcocystis. Liver was fixed in glutaraldehyde for transmission electron microscopy at a later date. (Sarcocysts were not found in skeletal muscle examined macroscopically at the time of autopsy).

R. rattus M79-125: male. CONTROL
Born: 5 weeks old (laboratory-bred)
P.M.: 15 December 1979 Mass: 77,66 g

Impression smears and blood films were made of the same tissues as for M79-122. Spleen, liver, lung, kidney, heart, brain, adrenal gland, pancreas and skeletal muscle were placed in formal-saline for subsequent screening by light microscopy. Liver processed for histological examination in January 1980, was Sarcocystis-negative. (Sarcocysts were not seen in skeletal muscle examined macroscopically at the time of autopsy).

R. rattus M79-126: male
Born: [illegible] weeks old (laboratory-bred)
D.I.: [illegible]ecember 1979 Dose: 150 000
P.M.: 17 December 1979 Mass: 89,78 g

Impression smears and blood films were prepared from the same tissues as for M79-122, after 14 days p.i. Spleen, liver, lung, kidney, heart, brain, adrenal gland, pancreas and skeletal muscle were placed in formal-saline for light microscopy. Liver tissue processed for histological examination in January 1980 apparently did not contain Sarcocystis. Pieces of liver were fixed in

glutaraldehyde for subsequent transmission electron microscopy. (Sarcocysts were not observed in skeletal muscle examined macroscopically at the time the post-mortem was carried out.

R. rattus M79-127: female. CONTROL
Born: 6 weeks old (laboratory-bred)
P.M.: 17 December 1979 Mass: 87,31 g

Impression smears and blood smears were made of the same tissues as for M79-122. Spleen, liver, lung, kidney, heart, brain, adrenal gland, pancreas and skeletal muscle were placed in formal-saline for light microscopy. Sarcocystis was not seen in liver tissue processed for histological examination in January 1980. (Sarcocysts were not present in skeletal muscle examined macroscopically at the time of autopsy).

R. rattus M79-128: male
Born: 5 weeks old (laboratory-bred)
D.I.: 3 December 1979 Dose: <150 000
P.M.: 2 June 1980 Mass: 215,57 g

Sarcocysts were found on macroscopic examination of the skeletal muscles. Muscle was placed in glutaraldehyde fixative and processed for transmission electron microscopy, in order to examine the cyst wall ultrastructure.

TABLE 10: Rodents inoculated by stomach tube with Rattus rattus/cat Sarcocystis sporocysts on 3 December 1979.

- For experiment 6

SPECIMEN NO.	SPECIES	INOCULUM	P.M. D.P.I.	MASS	RESULT
M79-122	R. rattus	150 000	10	86,0	neg.
M79-123	R. rattus	CONTROL	10	81,3	neg.
M79-124	R. rattus	150 000	12	71,8	neg.
M79-125	R. rattus	CONTROL	12	77,6	neg.
M79-126	R. rattus	150 000	14	89,7	neg.
M79-127	R. rattus	CONTROL	14	87,3	neg.
M79-128	R. rattus	<150 000	182	215,6	*pos.*

SUPPLEMENTARY MATERIAL

The following publication, being the results of collaborative research while the candidate was registered for the Ph.D. degree, is submitted as subsidiary matter in support of his candidature: Daly, T. J. M. and Markus, M. B. 1981. Enteric multiplication of Isospora felis by endodyogeny. Proceedings of the Electron Microscopy Society of Southern Africa 11 : 99-100. Electron microscopy and faecal flotations were carried out by T. J. M. Daly, who also prepared the plate. The paper was drafted by M. B. Markus. The experimentation involved is described in that section of the thesis which gives details concerning transmission experiments.

Elektronmikroskopieverenigingen van Suidelike Afrika DURBAN (1981)

ENTERIC MULTIPLICATION OF *ISOSPORA FELIS* BY ENDODYOGENY

T.J.M. Daly and M.B. Markus

Department of Zoology, University of the Witwatersrand, Johannesburg

Endodyogeny[1] is a type of asexual reproduction seen in certain protozoan parasites belonging to the subphylum Sporozoa (Apicomplexa). It involves formation of two daughter organisms within a parent cell, the latter being destroyed in the process.

Ultrastructural evidence of enteric endodyogeny in *Isospora* is presented in Figures 1 to 3. These observations were made at an earlier stage of the gut infection (4 days after oral inoculation) than any reported on to date[2,3]. Crystalloid bodies[4], which may be homologous with the refractile bodies of eimerian sporozoites and early merozoites[5], were no longer present.

Ferguson *et al.*[3] regarded the occurrence of enteric endodyogeny in *Isospora felis* (previously found by electron microscopy in *I. canis*[2]) as support for the creation of the new genus "*Cystoisospora*" in the family Sarcocystidae[6] for species of *Isospora* (family Eimeriidae) having hypnozoites[4] in the life-cycle. Similarly, Box *et al.*[7] were in favour of placing "*Cystoisospora*" in the Sarcocystidae on the basis of fine structural details of the sporocyst.

At present there are reasons for retaining the genus "*Cystoisospora*" and for having it in the family Sarcocystidae. However, the biology of more *Isospora sens. str.* species needs to be studied; and further consideration should be given to whether the division process in species of *Eimeria* is, in fact, significantly different from endodyogeny[8].

This work was supported by the South African Medical Research Council, the S.A. Council for Scientific and Industrial Research and the University of the Witwatersrand.

References

1. Goldman, M., Carver, R.K., and Sulzer, A.J., 1958, J. Parasit. 44, 161.
2. Hilali, M., Ghaffar, F.A., and Scholtyseck, E., 1979, Acta Vet. Acad. Sci. Hung. 27, 233.
3. Ferguson, D.J.P., Birch-Andersen, A., Hutchison, W.M., and Siim, J. Chr., 1980, Z. Parasitenk. 63, 289.
4. Markus, M.B., 1978, S. Afr. J. Sci. 74, 105.
5. Scholtyseck, E., and Ghaffar, F.A., 1981, Z. Parasitenk. 65, 117.
6. Frenkel, J.K., 1977, J. Parasit. 63, 611.
7. Box, E.D., Marchiondo, A.A., Duszynski, D.W., and Davis, C.P., 1980, J. Parasit. 66, 68.
8. Scholtyseck, E., and Nemeséri, L., 1979, Parasit. Hung. 12, 11.

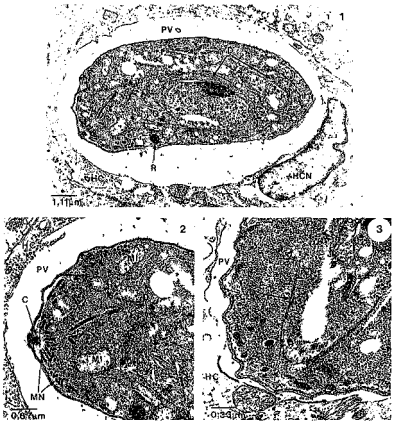

Figures 1-3. Stages of *Isospora felis* within epithelial cells of the cat intestine, at 4 days post inoculation. Developing daughter parasites can be seen inside the parent cells. Formal-saline fixation.

Key. C = conoid; D = daughter; G = Golgi body; HC = host cell (gut epithelial cell); HCN = host cell nucleus; MI = mitochondrion; MN = micronemes; N = parasite nucleus; PV = parasitophorous vacuole; R = rhoptry.

Author Daly Thomas Joseph Michael
Name of thesis Cyst wall ultrastructure of Sarcocystis (Protozoa: Coccidia) of Southern African mammals. 1987

PUBLISHER:
University of the Witwatersrand, Johannesburg
©2013

LEGAL NOTICES:

Copyright Notice: All materials on the University of the Witwatersrand, Johannesburg Library website are protected by South African copyright law and may not be distributed, transmitted, displayed, or otherwise published in any format, without the prior written permission of the copyright owner.

Disclaimer and Terms of Use: Provided that you maintain all copyright and other notices contained therein, you may download material (one machine readable copy and one print copy per page) for your personal and/or educational non-commercial use only.

The University of the Witwatersrand, Johannesburg, is not responsible for any errors or omissions and excludes any and all liability for any errors in or omissions from the information on the Library website.

Author Daly Thomas Joseph Michael
Name of thesis Cyst wall ultrastructure of Sarcocystis (Protozoa: Coccidia) of Southern African mammals. 1987

PUBLISHER:
University of the Witwatersrand, Johannesburg
©2013

LEGAL NOTICES:

Copyright Notice: All materials on the University of the Witwatersrand, Johannesburg Library website are protected by South African copyright law and may not be distributed, transmitted, displayed, or otherwise published in any format, without the prior written permission of the copyright owner.

Disclaimer and Terms of Use: Provided that you maintain all copyright and other notices contained therein, you may download material (one machine readable copy and one print copy per page) for your personal and/or educational non-commercial use only.

The University of the Witwatersrand, Johannesburg, is not responsible for any errors or omissions and excludes any and all liability for any errors in or omissions from the information on the Library website.