

https://dspace.org/

A comparative study of outcomes of two surgical procedures used to manage intracapsular ankylosis of the temporomandibular joint

Milad, Abdusalam A

2018
https://hdl.handle.net/10539/25259

Downloaded from a DSpace repository. https://dspace.org/

A comparative study of outcomes of two surgical procedures used to manage intracapsular ankylosis of the temporomandibular joint

MILAD ABDUSALAM A MILAD

1314864

A research report submitted to the Faculty of Health Sciences, University of the Witwatersrand, in partial fulfilment of the requirements for the degree of Master of Science in Dentistry in the department of Maxillo-Facial and Oral Surgery.

Johannesburg, 2018

DECLARATION

I, Milad Abdusalam A Milad, declare that this research report is my own work. It is being submitted for an MSc (Dent) degree in Maxillo-Facial and Oral Surgery at the University of the Witwatersrand, Johannesburg, South Africa. It has not been submitted before for any degree or examination at this or any other University, and all the sources I have used or quoted have been indicated and acknowledged by complete references.

M.MILAD

_____day of _____, 2018

.....

DEDICATION

To the spirit of my father, to my mother, to my dear wife, to the university of Sabha and all my colleagues.

ABSTRACT

Introduction: Temporomandibular joint (TMJ) ankylosis may be defined as the fusion of joint surfaces with bony or fibrous tissue which causes limitations on the functional activities of the oral cavity. Surgical treatment includes gap arthroplasty (GA), interpositional Arthroplasty (IA) and joint reconstruction using costochondral graft (CCG), iliac crest, clavicular, fibular, and metatarsal or alloplastic prosthesis and distraction osteogenesis.

Aim and objectives: The aim of this retrospective study was to compare outcomes of GA with CCG. The objectives were to identify factors that are associated with surgical outcomes, to identify the age group that is commonly affected and to compare the mean maximum interincisal opening (MIO) in two surgical procedures.

Materials and Methods: This retrospective study evaluated outcomes of 40 patients who were treated with GA and CCG between February 2007 and December 2016. The data were analysed and classified into pre-operative, intra-operative and post-operative stages. The outcomes were evaluated by calculating an achieved MIO (final MIO – preoperative MIO), and post-operative change in MIO (Op MIO - final MIO) and the final MIO, which refers to the last recorded MIO.

Results: Forty patients met the criteria for this study, twenty-seven were males and thirteen were females, the age range was 2 to 55 years. Trauma was the main cause of ankylosis with (62%) (n=26), followed by congenital defects with (27.5%) (n=11) and infection with (7.5%) (n=3). The mean of the final MIO of GA and with CCG was 30 mm (SD= 7.31) and 29.47 mm (SD= 6.79) respectively. The mean of A-MIO for GA and with CCG was 22.76 mm (SD= 8.61) and 24.1 mm (SD= 7.16) respectively, while the Pop-MIO for GA and with CCG was -3.85 mm (SD= 10.11) and -2.10 mm (SD= 7.49) respectively. The results showed no statistically significant difference ($P > 0.05$) in the mean MIO between two groups under GA

and CCG. In addition, it showed no association between the complications, age, gender and aetiology that were investigated by using logistic regression.

Conclusion: The findings of this study suggest that there is no difference in surgical outcomes between GA and IA with CCG, and the most common age groups that was affected was third stage 20-29 years (42.5%), with no association between factors and surgical outcomes.

ACKNOWLEDGEMENTS

I would like to express my deepest gratitude to my supervisor, Dr. Mzubanzi Mabongo who taught and guided me all the way. Thank you for your excellent guidance, caring, patience, monitoring and constant encouragement throughout the learning process. It was much appreciated.

I would also like to thank:

- The staff members of the Maxillo-Facial and Oral Surgery Department.
- To my family and colleagues who have made this thesis possible and because of whom my postgraduate experience has been one that I will appreciate forever.

TABLE OF CONTENT

	Page
DECLARATION	ii
DEDICATION	iii
ABSTRACT	iv
ACKNOWLEDGEMENTS	vi
TABLE OF CONTENT	vii
LIST OF FIGURES	ix
LIST OF TABLES	x
LIST OF ABBREVIATIONS	xi
CHAPTER1 - INTRODUCTION AND LITERATURE REVIEW	1
1.1 Introduction	1
1.2 Literature Review	3
CHAPTER 2 - AIM AND OBJECTIVES	32
CHAPTER 3 – METHODOLOGY	33
3.1 Study Design	33

3.2 Data Collection 34

3.3 Statistical Analysis 34

3.4 Inclusion Criteria 35

3.5 Exclusion Criteria 35

3.6 Ethical Issues 35

CHAPTER 4 – RESULTS 36

4.1 Maximum Interincisal Mouth Opening 39

4.2 Complication 42

4.3 Association 43

CHAPTER 5 – DISCUSSION 45

CHAPTER 6 - CONCLUSIONS AND RECOMMENDATIONS 56

REFERENCES 57

APPENDIXES 80

LIST OF FIGURES

Page

Figure 1: Sawhney classification of intra-capsular ankylosis according to anatomy of pathology. 8

Figure 2: 3D-reconstruction of unilateral ankylosis, from frontal, lateral and submento-vertex views. 12

Figure 3: Frontal view of left unilateral TMJ ankylosis 13

Figure 4: Lateral and frontal view of bilateral ankylosis. 14

Figure 5: Diagram depicting the grafting procedure using CCG 22

Figure 6: Age distribution of the particIAants.
36

LIST OF TABLES

Page

Table 1: Preoperative data and outcomes in the study of the patient after surgical treatment 38

Table 2: The distribution of aetiology per surgical method used and the prevalence under each age group. 39

Table 3: Analysis of the outcomes between two surgical methods 40

Table 4: Follow-up period with mean of outcomes. 41

Table 5: Affected side per surgical method used and the prevalence under each age group. 42

Table 6: Type of ankylosis per surgical method used and the prevalence under each age group. 42

Table 7: Analysis association between factors and complication. 43

Table 8: Analysis association between factors and complication (GA). 44

Table 9: Analysis association between factors and complication (CCG). 44

LIST OF ABBREVIATIONS

3D: Three Dimensional Reconstructed Images.

CAD/CAM: Computer-Aided Design/ Computer-Aided Manufacturing.

CCG: Costochondral Graft.

CMJAH: Charlotte Maxeke Johannesburg Academic Hospital.

CT: Computed Tomography.

F-Outcome: Final Outcome.

GA: GA.

HREC: Human Research Ethics Committee Medical.

IA: Interpositional Arthroplasty.

MIO: Maximum Interincisal Opening.

MMF: Maxillo-Mandibular Wire Fixation.

MRI: Magnetic Resonance Imaging.

Op-MIO: Maximum Interincisal Opening During Operation.

Pop-MIO: Post-Operative change in Maximum Interincisal Opening.

Pre-MIO: Pre-Operative Maximum Interincisal Opening.

Sx-T: Type of Surgical Treatment.

CHAPTER 1

INTRODUCTION AND LITERATURE REVIEW

1.1 Introduction

Temporomandibular joint (TMJ) ankylosis is an uncommon condition in which there is immobility of the joint. It is characterised by the formation of an osseous, fibrous or fibro-osseous mass fused to the base of the skull (Elgazzar *et al.,* 2010). This fusion results in a gradual decrease in mouth opening to 5 mm or less and the inability to open the mouth in the long term (Bayat *et al.,* 2009). This inability to open the mouth leads to serious problems for patients, which include feeding challenges, poor oral hygiene and facial asymmetry-especially in children, and psychological problems (Sanders, 1975). Trismus can also be caused by the limitation of the mouth opening (Tideman and Doddridge, 1987), which is described as clenching of the teeth in tonic spasm (Rowe, 1982). Trismus may be caused by trauma to the muscle of mastication (masseter and/or temporalis) with reactive spasm or subsequent hematoma formation and fibrosis or both (Walter *et al.,* 1976). In addition, infection in the pterygo-mandibular space also produces trismus, while ankylosis may be caused by extraction of the lower molar or other local surgery or hematoma from the inferior alveolar nerve block (Rowe, 1982).

The TMJ is one of the most sensitive joints in the human body and therefore injuries and infections to this joint can result in various complications for the patients (Ramezanian and Yavary, 2006). The anatomy of the condylar cartilage makes it vulnerable to environmental changes, as the TMJ, unlike the knee joint which has a growth plate and articular cartilage, has a single cartilage that is responsible for both growth and articulation. The proliferative layer of the condylar cartilage, where endochondral ossification takes place, lies immediately below the thin outer protective layer of cartilage (Mizoguchi *et al.,* 2013).

TMJ ankylosis is classified according to the site of fusion as intra-capsular and extra-capsular ankylosis, when it has developed; into a congenital or acquired, side involved; into unilateral or bilateral, and type of tissue; into fibrous or bony and fibro-osseous ankylosis. Kaban *et al.* (1990) considered ankylosis as complete when maximum interincisal opening MIO is ≤ 5 mm, and incomplete ankylosis is ≥ 5 mm.

The causes of acquired TMJ ankylosis are trauma, infection and systemic inflammatory disease such as ankylosing spondylitis, rheumatoid arthritis and psoriasis (Topazian, 1964).Other causes include irradiation, neoplasm, previous surgery and recurrence of TMJ ankylosis (Ware and Brown, 1981).

Currently, the surgical techniques used to manage TMJ ankylosis are GA (Rajgopal *et al.*, 1983), IA (Manganello-Souza and Mariani, 2003), and joint reconstruction using a variety of grafts including costochondral, iliac crest, clavicular, fibular, and metatarsal or alloplastic prosthesis (Munro *et al.*, 1986; Saeed *et al.*, 2002; Haung *et al.*, 2007), and distraction osteogenesis (Stucki-McCormick *et al.*, 1997; Nitzan *et al.*, 2012).

Management of TMJ ankylosis is further complicated by the fact that there is no consensus as to the optimal surgical treatment for TMJ ankylosis (Miyamoto *et al.*, 1999), and outcomes studies of current techniques present conflicting results (Saeed and Kent, 2003; Al-Moraissi *et al.*, 2015; Ma *et al.*, 2015; Liu *et al.*, 2015). Furthermore, the chosen technique is usually dependant on age, site, extent of ankylosis, injury location or type (Valentini *et al.*, 2002; Bayat *et al.*, 2009).

However, satisfactory results from GA have been reported (Rajgopal *et al.*, 1983; Roychoudhury *et al.*, 1999; Vasconceloes *et al.*, 2006; Temerek, 2013), while joint reconstruction with CCG is regarded the treatment of choice by some surgeons with favourable results (Ware and Brown, 1981; Wolford *et al.*, 1994; Ko *et al.*, 1999).

1.2 Literature Review

TMJ ankylosis is a joint disorder which is characterised by osseous, fibrous or fibro-osseous adhesion of the joint components and loss of joint function (Valentini *et al.*, 2002). It is an uncommon condition where fibrous or bony fusion partially or completely obliterates the articular spaces and leads to joint deformity (Kaban *et al.,* 1990). This bony fusion between fragment or large bone mass usually involves the condyle of the mandible, the temporal bone and the zygomatic process (Menon and Sinha, 2008), while fibrous adhesion is a result of fibrous change in capsular ligaments that cause restriction of movement (Meredith *et al.*, 2004).

TMJ ankylosis leads to limitations of the functional activities of the oral cavity such as speech and mastication and interferes with the maintenance of good oral hygiene. In growing individuals ankylosis can result in a retruded position of the mandible causing constriction of the airway, and impeded eruption of mandibular molars has also been reported (Roychoudhury *et al.*, 1999). Facial disfigurements in these patients exacerbate psychological stress as these children are often teased by their peers (Chidzonga, 1999).

1.2.1 Aetiology

TMJ ankylosis may either be acquired or congenital (Dingman, 1934). Acquired TMJ ankylosis may be caused by trauma and infection (Kazanjian, 1938; Topazian, 1964; El-Mofty, 1974). Systemic inflammatory disorders such as rheumatoid arthritis, psoriasis and ankylosing spondylitis may also result in TMJ ankylosis (Kaban *et al.,* 1990; Bayat *et al.,* 2009; Sidebottom and Salha, 2013). The incidence of trauma as etiological cause of the TMJ ankylosis ranges from 31-98%, infections in 10-49% and systemic disease in 10% of cases (Rowe, 1982; Miyamoto *et al.*, 2000; Sidebottom and Salha, 2013). It has also been reported that TMJ ankylosis may be secondary to a TMJ surgical procedure (Kaban *et al.*, 1990).

1.2.1.1 Trauma

The incidence of trauma as the most common cause of ankylosis ranges from 31% -98% (Rowe, 1982). Two studies with large sample sizes reported trauma as the main cause of TMJ ankylosis, as in 92.2% of 206 cases (Sarma and Dave, 1991), and 98% in 204 cases (El-Sheikh, 1999).

The pathogenesis of TMJ ankylosis of traumatic origin is that traumatic injury results in an intra-articular haematoma leading to fibrosis, excessive bone formation and hypomobility of the joint (El-Mofty, 1972; Tauras *et al.,* 1972; Kaban *et al.,* 1990). Haematoma formation within joint space and subsequent fibrosis may occur in trauma without fracture (Walter *et al.,* 1975). Guilhem and Cadenat (1955) reported that injuries leading to TMJ ankylosis may occur during forceps delivery at birth. In children, the pathogenesis of TMJ ankylosis may be due to trismus of the mandible following intra-capsular fracture; this may result in prolonged immobilisation of the jaw allowing excessive mineralization and bone formation (Roychoundhury *et al.,* 1998). Bellinger (1940) reported that crushing blows to the joint are more likely to cause ankylosis than fractures of the neck of the condyle due to trauma to the mandible, while other authors showed that the point of impact of trauma was the mandibular symphysis or body region (Topazian, 1964; El-Mofty, 1972). Trauma to the condyle of the mandible may cause condylar fracture that can result in ankylosis secondary to bony fusion of the condyle to the zygomatic process of temporal bone or the base of the skull (Freedus *et al.,* 1975; Walter *et al.,* 1976). When a condylar fracture comes into close contact with the zygomatic arch it may cause a juxta-articular type of ankylosis (ankylosis that occur lateral to the articulation itself) (Ferretti *et al.,* 2005). In addition, trauma may lead to limitation of movement when there is a dislocated condylar fragment (Freedus *et al.,* 1975).

The pathophysiology of ankylosis may represent fibrosis of the soft tissue surrounding the joint, bony prominence causing mechanical obstruction, fusion of bony elements, or degeneration of the joint space leading to limited movement (Montalva *et al.,* 2008).

1.2.1.2 Inflammation and Infection

Inflammatory processes that occur within the joints usually result in the formation of granulation tissue which destroys the joint cartilage (Bellinger, 1940), followed by formation of a fibrous tissue that undergoes metaplasia into fibro-cartilage which is directly transformed into bone (Walker, 1973). Straith and Lewis (1948) classified joint inflammation into primary inflammation of the joint and secondary due to local inflammatory processes and bloodstream infection.

I. Primary Inflammation

Primary inflammation is most commonly seen in rheumatoid arthritis which involves the mandibular articulation in half of all cases (Blackwood, 1957). Rheumatoid arthritis, which is an inflammatory joint disease may involve both TMJ especially the fibrous variety, it is usually occurs in middle age female (Walker, 1973; Nitzan *et al.,* 2012), while rheumatoid spondylitis rarely involves TMJ, and is characterised by a gradual stiffening of the joint, which ultimately may result in joint ankylosis (Topazian, 1964). However, temporomandibular joint inflammation may occur secondary to other disease processes (Sarma and Dave, 1991). Primary joint inflammation has been reported in ankylosing spondylitis and in Still's disease (Tideman and Doddridge, 1987), while psoriatic arthritis associated with TMJ ankylosis has also been reported (Paterson and Shephered, 1992).

II. Secondary Infection

Some African studies have reported infection as the main cause of ankylosis in children (Nwoku, 1979; Adekeye, 1983). Infection of the TMJ may be a direct extension from other sites as occurring in otitis media, mumps, osteomyelitis of the zygomatic temporal bone, mastoditis and soft tissue abscesses (El-Mofty, 1972). Scarlet fever and typhoid may also be able to attack the joint directly through the bloodstream or cause otitis media or mastoiditis and affect the joint secondarily by direct extension (Miller *et al.,* 1975).

The spread of infection from middle ear to the TMJ is one of the complications of otitis media, resulting in septic arthritis, malocclusion and ankylosis (Rowe, 1982). TMJ ankylosis in this condition occurs due to the reactive formation of fibrous or bone tissue within intra-capsular abscesses (Valentini *et al.,* 2002), and complete filling of the articulation with fibrous connective or bone tissue, frequently causes the destruction of the articular disc or obliteration of the joint space (Souchere *et al.,* 1994). Direct spread from the ear to the TMJ can be via three routes: congenital dehiscence of the cartilaginous canal, dehiscent squamo-tympanic fissure or failure of closure of Huschke's foramen before the fifth year of life (Bast *et al.,* 2015).

1.2.1.3 Congenital

Congenital ankylosis refers to an ankylosis that is diagnosed at birth or soon after birth (Rajgopal *et al.,* 1983). Some of these patients may be reported as syngnathia rather than intracapsular or extracapsular TMJ ankylosis (Burket, 1938).

The exact pathogenesis of congenital ankylosis is unknown (Ajike *et al.,* 2006), but various proposed hypotheses have been reported which include: anomalous fusion of embryonal mesenchyme during embryogenesis (Nwoku and Kekere-Eknn, 1986), an abnormality of the stapedial artery in the fetus (Poswillo, 1973), early loss of neural crest cells (Hegtvedt, 1992), and hyper-vitaminosis A (Nada, 1970).

However, the term congenital ankylosis is used to describe limitation of jaw movement that occurs in infancy (Topazian, 1964), while other authors believe that congenital ankylosis is probably due to neonatal infection or obstetric trauma (forceps delivery) (Burket, 1938; Salleh, 1965). According to Allori *et al.* (2010) 85.7% of intracapsular ankylosis of the TMJ are acquired, and 64% of extracapsular ankylosis of the TMJ are congenital.

1.2.2 Classification of TMJ Ankylosis

Kazanjian (1938) classified TMJ ankylosis as intra-capsular ankylosis (true ankylosis) and extra-capsular ankylosis (false ankylosis).

1.2.2.1 Intra-capsular Ankylosis

Ankylosis is described as intra-capsular that occurs between the condyle head of the mandible and the mandibular fossa of the temporal bone (Kazanjian, 1938). Hugh *et al.* (2011) reported that trauma, especially intracapsular and subcondylar fractures in children are the most frequent cause of TMJ ankylosis. The excessive mineralization and bone formation in children with comminuted intracapsular fracture due to prolonged immobilization, mainly explains the pathogenesis (Roychoundhury *et al.,* 1997). Trauma can also result in an intra-articular haematoma leading to fibrosis, excessive bone formation and ultimately hypo - mobility of the joint (Kaban *et al.,* 1990). The pathological changes that occur in intra-capsular ankylosis as reported by several authors (Thoma *et al.,* 1945; Straith and Lewis, 1948; Shafer *et al.,* 1963) are: -

- Deterioration of the meniscus
- Flattening of the mandibular fossa
- Increased thickness of the condyle resulting in obliteration of capsular space
- Calcification or ossification of the attached fibrous tissue that leads to continuity between the mandible and the base of the skull
- Hyperostosis extending to the coronoid process, ramus and zygomatic arch

Topazian (1964) classified intra-capsular ankylosis according to the severity or extent of the ankylotic mass, into: -

- Class I- ankylosis involving the mandibular condyle and the mandibular fossa
- Class II- ankylosis extending to the mandibular notch
- Class III- ankylosis extending to the coronoid process

Sawhney (1986) classified intra-capsular ankylosis according to the anatomy of pathology into four types (Fig. 1): -

- Type I- reduction of joint space, flattened head of the condyle and with fibrous adhesion formed in and around joint
- Type II- bony spicules from the condylar surface to the mandibular fossa of the temporal bone
- Type III- proximal segment is lying free or fused to the antero-medial aspect of the condylar stump
- Type IV- wide and deep block between the ramus and upper articulating surface

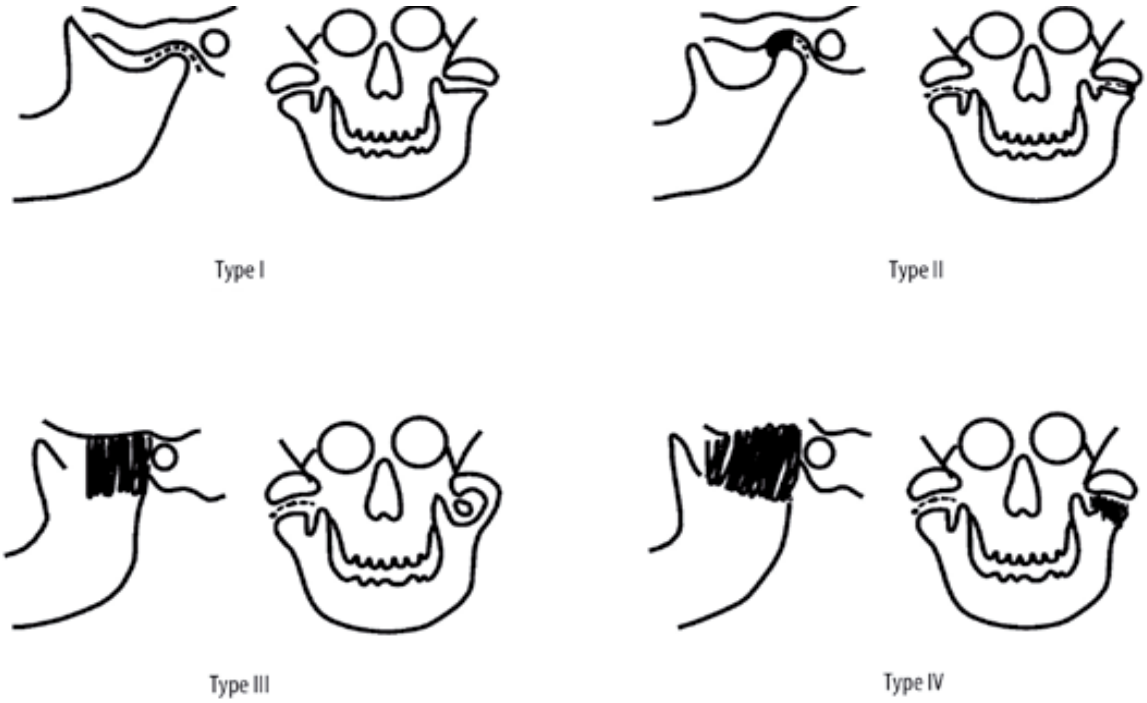

Figure 1: Sawhney classification of intra-capsular ankylosis according to anatomy of pathology. [Source: Reza and Mercurri, 2015].

Durr and Turlington (1993) graded heterotopic bone formation within the ankylotic mass into 4 grades based on the CT- scan findings: -

- Grade 0: No bone islands visible
- Grade 1: Islands of bone visible within the soft tissue around the joint
- Grade 2: Periarticular bone formation
- Grade 3: Apparent bony ankylosis.

Grades 1, 2 and 3 are further classified as symptomatic (S) and asymptomatic (A). The symptomatic ossification includes: severe pain, decreased interincisal opening (15 mm or less), closed locking of the jaw, or decreased lateral or protrusive movement.

1.2.2.2 Extracapsular Ankylosis

Extra capsular ankylosis is defined as the restriction of the mandibular movement that occurs outside the TMJ capsule (Kazanjian, 1938). It is a pathological condition not directly related to the joint and may result from muscular, neurological and psychiatric disorder (Manganello-Sauza and Mariani, 2003). Myogenic disorder may cause restricted mouth opening of muscle origin. In this condition the fibrosis is produced from an intramuscular haematoma and ultimately undergoes calcification (Beck, 1969; Silagi and Schow, 1970), myositis ossifications that affect the masticatory muscle can result in a limitation of the mouth opening (Parkash and Goyal, 1992). Neurogenic disorders that lead to mandibular dysfunction include bulbar paralysis, brain tumour, cerebrovascular accident and epilepsy (Miller *et al.,* 1975). These conditions may be due to a flaccid paralysis of the muscle resulting in restricted mouth opening (Beck, 1969). A psychoneurosis, also known as hysterical trismus, can produce a clinical picture of complete extra-capsular bony ankylosis. In this condition the patient cannot separate the jaw (Thoma, 1946). Other causes are tumours such as chondroma, osteochondroma, condylar hyperplasia (Miller *et al.,* 1975), coronoid process and zygomatic

arch fractures which have been reported to cause extra capsular ankylosis (Kaban *et al.,* 1990; Vanhove and Dom, 1999). Although these are fibrous or bony adhesions between the coronoid process and the zygomatic arch, they are uncommon causes of extra capsular ankylosis (Paolino and Murphy, 1987). The coronoid process may be displaced inward and attached to the base of the skull, or outward and attached to the inner surface of the zygoma (Vanhove and Dom, 1999). The mechanisms by which the ankylosis develops are unclear, but could result from heterotopic bone ossification (Vanhove and Dom, 1999; TIApu and Rahman, 2011). Zygomatico-coronoid ankylosis tends to follow fracture of the coronoid process or both zygoma and coronoid process (Hugh *et al.,* 2011). In this situation, if fibrous healing between the two bones occurs, the patient may develop an extracapsular fibrous ankylosis (Paolino, 1987). Ossifications of this fibrous tissue result in bony ankylosis (Paolino and Murphy, 1987), which is extracapsular between coronoid process and zygoma (Vanhove and Dom, 1999).

Extracapsular ankylosis is classified as simple extracapsular ankylosis when there are no radiographic changes on the articular surface, while complex extracapsular ankylosis occurs with secondary intra-capsular degenerative changes (Spijkevert *et al.,* 1994).

1.2.3 Clinical Findings

Limited mouth opening is the common clinical feature of patients with TMJ ankylosis (Chidzonga, 1999). The severity of this limitation depends on whether the ankylosis is fibrous or bony (Munro *et al.,* 1986). Severity of facial deformities resulting from TMJ ankylosis depends on the joint involvement, age of onset and duration (Miller *et al.,* 1975). The ankylosis that occurs during early age (childhood), in patients still growing and over a long duration, results in severe facial deformities (Munro *et al.,* 1986). This is due to the progressive nature of the condition during the growth of the children (Rowe, 1982).

TMJ ankylosis that occurs in adulthood, when the growth of the mandible has ceased presents with restricted mouth opening with either deviation or a retruded mandibles (El-Sheikh, 1999).

Clinical findings may provide insight as to the time of onset and duration of TMJ ankylosis, in a unilateral case of early onset, there will be a cross bite (Chidzonga, 1999; El-Sheikh, 1999), while in bilateral involvement, there will be a class II malocclusion and anterior open bite (Bellinger, 1940; Rowe, 1982). The coronoid process of the mandible tends to be elongated, with extent depending on the duration of ankylosis (Nwoku, 1979). This is believed to be secondary growth in response to limited function of the temporalis muscle (MacIntoch and Henny, 1977; Posswillo *et al.*, 1987).

The clinical features and challenges encountered by patients with TMJ ankylosis adversely affect facial morphology, aesthetics and function, as well as psychological well-being of the patient. The challenges encountered by patients with TMJ ankylosis are:

- Restricted movement of the mandible, due to the condyle fusion in the TMJ
- Inadequate chewing function
- Restricted mouth opening
- Poor maintenance of oral hygiene
- Problems with speech in severe cases
- Reduced growth of the mandible with bilateral joint involvement resulting in "bird face" (Fig 4)
- Facial asymmetry in unilateral involvement
- Misaligned teeth, due to lack of space (Khan *et al.*, 2005; Shetty *et al.*, 2014)

1.2.3.1 Unilateral Ankylosis

In a unilateral case of early onset, there will be asymmetrical face, which is characterised by deviation of the mandible towards the affected side (Xiao *et al.*, 2012). In long standing TMJ

ankylosis that occurred early in life, the face is flattened on the affected side and full on the unaffected side (Fig 2), with malocclusion that is characterised by a cross-bite and canting of the occlusion- up on the affected side (El-Sheikh, 1999; Chizdonga, 1999). This occlusal cant is caused by compensatory growth of the maxilla on the unaffected side (Kaban *et al.,* 1990). In unilateral joint involvement, regardless of the extent, there is slight movement when the patient attempts to open the jaw (Bellinger, 1940). The motion is caused by a slight gliding movement on the unaffected side (Thoma *et al.,* 1945). The vertical height of the ramus may be reduced on the affected side when measured from the angle of the mandible to the lower border of the zygomatic arch (Fig 3) (Dingman, 1946).

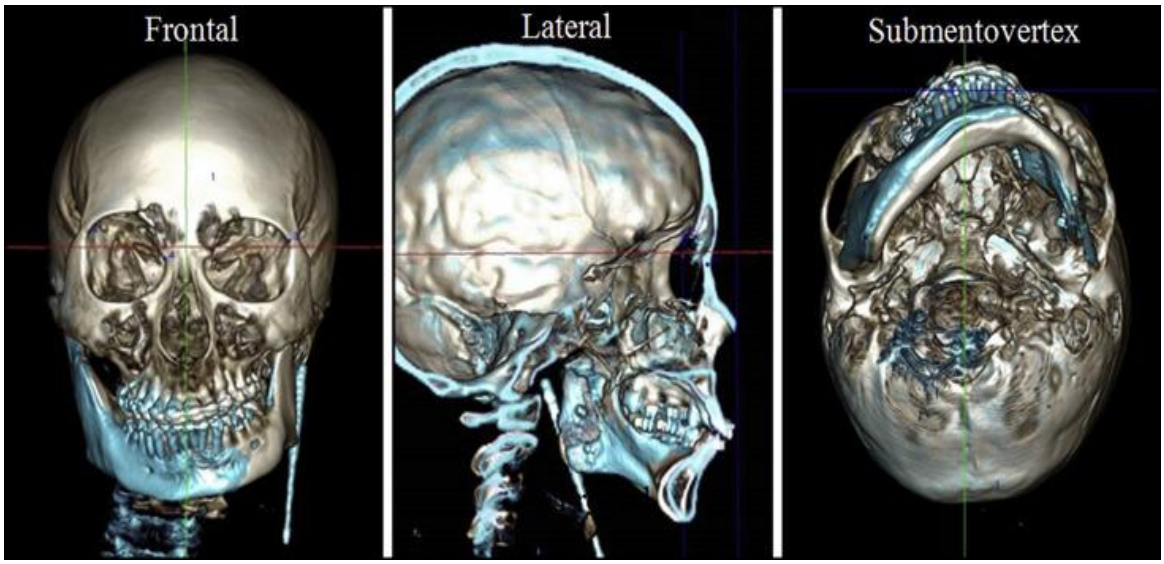

Figure 2: 3D-reconstruction of left TMJ ankylosis, from frontal, lateral and submento-vertex views. [Source: Xiao *et al.*, 2012].



a b c

Figure 3: Left TMJ ankylosis from frontal view and panolipse [Source: Behnia *et al.*, 2015]

1.2.3.2 Bilateral Ankylosis

Bilateral TMJ ankylosis of childhood result in a symmetrical face, but the mandible is micrognathic (Rowe, 1982), giving rise to what is described as “bird face deformity” (Khan *et al.*, 2005) (Fig 4). The limitation of mouth opening with a class II malocclusion and crowding of teeth results in rampant caries, due to the inability to maintain good oral hygiene (Nwoku, 1979). Furthermore, in bilateral bony ankylosis, there is minimal motion. A mouth opening of 5 mm or less is considered to indicate full bony union (Thoma, 1946).

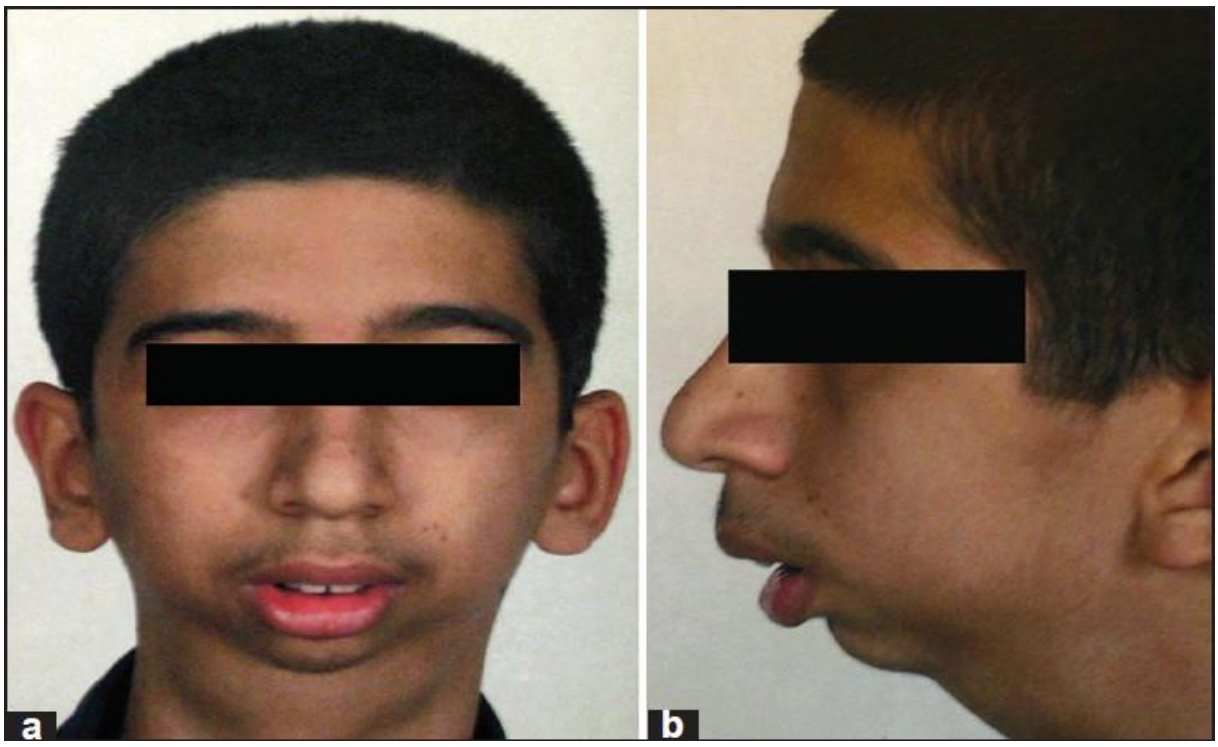

Figure 4: Frontal (a) and lateral view (b) of bilateral ankylosis [Source: Shirani *et al.,* 2014]

1.2.4 Diagnosis of TMJ Ankylosis

The diagnosis of TMJ ankylosis is based on clinical and radiographic features (Shetty *et al.*, 2014). Since 1930, radiographic images have been used in diagnosis of TMJ ankylosis (EL-Hakim and Metwalli, 2002; White and Pharoah, 2004), and provide invaluable information with regard to the extent and type of ankylosis (Silagi and Schow, 1970).

Diagnostic imaging currently includes: -

- Plain radiographs such as orthopantograms and posterior-anterior views of the mandible
- Computed tomography (CT) scan
- Magnetic resonance imaging (MRI)
- Three dimensional (3D) reconstructed images (Spijkevrtet *et al.*, 1994)

El-Hakim and Metwalli (2002) described radiographic features associated with TMJ ankylosis: -

- Reduced or complete obliteration of joint space
- Elongated coronoid processes
- Medial extent of the ankylotic mass is demonstrated
- Marked antegonial notching
- Flattening of the condylar head
- Reduced vertical height of the mandible

1.2.5 Management of TMJ Ankylosis

Management of TMJ ankylosis may be either by surgical intervention and or physiotherapy. Surgical intervention allows the excision of the ankylotic mass from the joint (Bellinger, 1940; Su-Gwan, 2001). Various authors recommended that the release of ankylosis should be done as soon as it is diagnosed to prevent severe deformities and dental compensation (Freedus *et al.*, 1975; Tideman and Doddridge, 1987; Kaban *et al.*, 1990; Chossegros *et al.*, 1997).

The main objectives of treatment for TMJ ankylosis are to restore joint function, to improve the patient's aesthetic appearance and quality of life (Rowe, 1982; Chizdonga, 1999), to avoid re-ankylosis (Adekeye, 1983), to facilitate the maintenance of good oral hygiene (Freedus *et al.*, 1975), and to relieve airway problems if these occur (El-Sheikh, 1999).

1.2.5.1 Non-Surgical Treatment of Ankylosis

Fibrous ankylosis of the TMJ may be managed by either surgical intervention or physiotherapy. Mechanical devices to improve range of motion are useful in cases of mild fibrous ankylosis and early rheumatoid arthritis, but cannot be used in chronic intra-articular ankylosis (Kazanjian, 1938).

Brisement force which refers to the forceful opening of the jaws is usually performed on the patient under general anaesthesia (Miller *et al.*, 1975). In this condition, the jaw is forced open by means of a mouth gag and mobilized as much as possible by forceful manipulation (Prakasam *et al.,* 2012). After the jaw has been mobilized, the patient may benefit further from exercise with a rubber block inserted between the teeth on the affected side (Thoma, 1969). Blair (1928) reported that this technique is potentially dangerous and that the only definitive treatment of ankylosis is surgical intervention (Munro *et al.,* 1986). Reported complications associated with brisement force are low with possibility of pain, bleeding, and infection and a risk of tendon damage (Prakasam *et al.,* 2012). Fractures of the mandible, aggravation of the condition with possibility of formation of complete bony ankylosis are more serious risk (Kazanjian, 1938; Sawhney, 1985).

1.2.5.2 Surgical Treatment

Historically, Esmarch was the first to perform an osteotomy for TMJ ankylosis in 1851 when patients suffering from ankylosis were considered to be incurable (Dingman, 1946). This was followed by Humphry who performed the first condylectomy in 1854 (Kaban *et al.,* 1990). Surgical intervention is regarded as the only effective method for treatment of true TMJ ankylosis (Bellinger, 1949).

Many surgical techniques have been described for TMJ ankylosis including osteotomy, ostoearthroectomy, angle osteotomy and ramus osteotomy (Parker, 1948; Rowe, 1982). Furthermore, various methods were used including GA, IA and joint reconstruction, using costochondral, iliac crest, clavicular, fibular, a metatarsal head grafts or alloplastic prostheses (Freedus *et al.,* 1975; Munro *et al.,* 1986). More recently, distraction osteogenesis has been described (Stucki-McCormic *et al.,* 1997). The selection of one or more of the surgical modalities for a particular case depends on the patient's age, the type and severity of the joint ankylosis, growth potential, patient preference and compliance, and availability of the

techniques and expertise at the time of treatment (Adekeye *et al.,* 1983; Bayat *et al.,* 2009; Al-Moraissi *et al.,* 2015). Some reports have recommended correcting secondary deformities such as facial asymmetry, micrognathic mandible and occlusal canting concomitantly with the release of the TMJ ankylosis (Munro *et al.,* 1986; El-Shiekh, 1999; Young long *et al.,* 2002).

1.2.6.1 Gap Arthroplasty (GA)

GA was first described by Abbe in 1880 (Miller *et al.,* 1975) It is considered to be the oldest technique for treating TMJ ankylosis, and is done by creating a gap between the mandibular fossa and ramus or condyle of the mandible (Babu *et al.,* 2013) or the excision of ankylotic mass (Topazian, 1966). The advantages of this technique are very simple, surgeons spend less surgical operation time leaving the TMJ joint region empty by resecting the ankylotic bone and the cost is low compared to other methods that use additional materials (Kaban *et al.,* 1990). Disadvantages reported include pseudo-articulation, shortened ramus and re-ankylosis (Chugh *et al.,* 2011). These disadvantages are probably due to extensive resection of the bone without reconstruction of the ramus-joint complex (Qudah *et al.,* 1992; Roychoudhury *et al.,* 1999). A gap wider than 10 mm is recommended to avoid re-ankylosis during the treatment by GA (Elgazzar *et al.,* 2010). Topazian (1964) reported that GA is associated with a high recurrence rate, hence a gap of 1- 2 cm is recommended to prevent re-ankylosis (Topazian, 1966; Rowe, 1986). However, the creation of a big gap tends to cause a shortened mandibular ramus, which probably leads to mandibular deviation in unilateral cases, posterior premature contact and open bite (El-Sheikh, 1999). Complications of GA reported in unilateral cases are posterior premature occlusion, open bite on the affected side and contralateral side, while in bilateral cases, severe anterior open bite may develop preventing mastication and causing aesthetic and respiratory issues (Kaban *et al.,* 1990; El-Sheikh, 1999; Vasconcelos *et al.,* 2008). Some authors have reported improvements in appearance in patients treated with GA at an early age (El-Mofty, 1974; Sarma and Dane, 1991). However, some clinicians prefer

using GA as a primary procedure followed by reconstruction with CCG as a secondary procedure (MacIntosh, 2000; Salin, 2000).

1.2.6.2 Interpositional Arthroplasty (IA)

IA refers to minimal resection of bone between the ramus of the mandible and mandibular fossa (Qudah *et al.,* 2005), and the placing of an interpositional material between the two bone segments (Manganello-Souza and Mariana, 2003).

In IA autogenous materials are placed in the area between two bone segments to prevent recurrence of ankylosis (Topazian, 1966), by preventing adhesion between the two bony cut surfaces (MacIntosh, 2000), and maintain the length of the condylar and ramus area of the mandible (Ramezanian and Yavary, 2006). Huang *et al.* (2007) suggested that making a gap of correct size, choosing the proper interpositional material and diligent postoperative physical therapy are all important factors in preventing re-ankylosis and in contributing to the success of the treatment. Various interpositional materials have been used, such as temporal fascia, auricular cartilage and dermis (Chossegros *et al.,* 1997; Karaca *et al.,* 2004; Güven, 2004). IA with alloplastic material such as polyethene (Bromberg *et al.,* 1969), silastic sheet and acrylic spacer marbles (Erdem and Alkan, 2000), and gold foil and silicon prostheses (Chossegros *et al.*, 1997; Danda *et al.*, 2009) have also been described.

Autogenous interpositional materials have benefits but are not without complications (Kaban *et al.,* 1990). Temporalis fascia is commonly used tissue because of it is close proximity to the surgical area, which can be used from the same incision, good blood supply, easy preparation and harvesting, minimal cosmetic and functional morbidity (Pogrel and Kaban, 1990). Güven (2004) reported that the treatment using temporalis fascia as autogenous material and GA with active mouth opening exercises, provides an effective functional outcome and also assists in the prevention of re-ankylosis. Dimtroulis (2004) reported fibrosis and scar contracture following the use of temporalis fascia which may cause trismus and chronic headache.

Placement of autogenous fat graft around articulation surfaces after TMJ reconstruction has been reported to decrease heterotopic bone formation, which possibly causes re-ankylosis (Wolford and Karac, 1997). Advantages of auricular cartilage are growth ability, ease of harvesting and placement, and biologic compatibility (Kaban *et al.,* 1990; Link *et al.,* 1993). Advantages of dermis are minimal donor site morbidity, and hidden scar, which is situated in the groin below the belt line (Dimitroulis, 2004). The possibility of epidermoid cyst formation and atrophy of the dermis under pressure have been reported as potential complications (Chossegros *et al.*, 1997).

This growth may relate to the functional growth theory, in which the skeletal unit (mandible) grows in response to function (Moss and Salentijn, 1969). The tissue grafts referred to are most likely to be the condylar replacement grafts where success in dependent on a rich vascular supply to sustain the graft (Mercuri, 2012).

A disadvantage of alloplastic materials is failure of the material (Mercuri, 2012), usually due to infection and fragmentation of the material under functional load leading to a foreign body reaction to wear debris (Kent *et al.,* 1986; Saeed *et al.,* 2001; Mercuri and Anspach, 2003). This usually leads to failure and loss of the material (Mercuri, 2012). Extrusions of the material, bone resorption and development of abnormalities and pathological lesions have been reported (Reza and Mercuri, 2015).

1.2.6.3 Reconstruction of TMJ

Reconstruction of the joint is done in children to transplant the condylar growth centre, and in children and adults to restore the vertical height of the ramus and thereby restore mandibular symmetry (Ware and Brown, 1981). Autogenous bone and alloplastic materials have been used (Ruddlesdin *et al.,* 1986; Wolford *et al.,* 1994).

Autogenous bones that have been used as grafts in the management of TMJ ankylosis are metatarsal head, costochondral, sternoclavicular joint, fibular head, iliac crest and coronoid processes (Dingman and Grabb, 1946; MacIntosh and Henny, 1977; Khadka and Hu, 2012).

I. Costochondral Graft (CCG)

Among the autogenous grafts, CCG is the material of choice because some authors believe that its cartilaginous part acts as a primary growth centre, especially in children (Ware and Tylor, 1966; Obied *et al.,* 1988; Ko *et al.,* 1999; Wolford *et al.,* 1999). Furthermore, growth may also be adaptive in response to the functional theory (Samman *et al.,* 1995). Some studies suggest that CCG is the best choice for reconstruction of TMJ ankylosis in children (Bowerman, 1987; Guyuron and Lasa, 1992; Ko *et al.,* 1999; Wolford *et al.,* 1999; He *et al.,* 2008). In adults, reconstructions with CCGs are used to restore the height of the ramus of the mandible (Poswillo, 1987), but may be applied only to a limited number of patients due to the histomorphology of the rib of the fully-grown patient (Mercuri, 1998).

The CCG is usually obtained from the 5th, 6th, or 7th rib and this requires a harvesting of a minimum length of 3 cm of the rib bone and 0.5-1 cm of the cartilaginous part to ensure a successful graft (Lindqvist *et al.,* 1988; Link *et al.,* 1993; Karaca *et al.,* 2004; He *et al.,* 2008) (Fig. 3). CCG offers three functional parts, the bony portion restores the vertical height of the ramus and fixation of the graft to the mandible (Kennett, 1973), the cartilaginous part of about 0.5-1 cm is needed which acts as interpositional material (Kennett, 1973; Karaca *et al.,* 2004) and the junction between the bony portion and the cartilaginous portion acts as a growth centre (Ware and Brown, 1981).

Advantages of the CCG: -

- Biological compatibility (Kaban *et al.,* 1990)
- Functional workability and adaptability (Lindqvist *et al.,* 1988; Link *et al.,* 1993)
- Usually easy to harvest (Poswillo, 1987)

- Long grafts can be obtained (Kennett, 1973)
- Reformed new rib if periosteum is reconstituted at the donor site (Kennett, 1973)

The main objective of using CCGs in children is to act as a transplanted growth centre (Ware and Brown, 1981; MacIntosh, 2000). Some authors suggest that the mandible is no longer growing when growth of the rib graft during normal pubertal growth has stopped (Tauras *et al.*, 1972; Obied *et al.*, 1988). On the other hand, this normal pubertal growth may be the cause of unpredictable growth of the mandible at the graft site (Guyuron and Lasa, 1992; Chossegros *et al.,* 1997; Mercuri, 1998; MacIntosh, 2000). Perrott *et al,* (1994) reported the lateral contour overgrowth in the region of the CCG junction but without linear dimensional change especially in adults (Perrott *et al.*, 1994). The authors believe that this case supports the suggestion that the CCG exhibits features of a primary growth centre (MacIntosh, 1992; Perrott *et al.*, 1994; Samman *et al.*, 1995).

The disadvantages of CCG are a second operation site with donor site morbidity (Kaban *et al.*, 1990), fracture of the graft, especially at the junction site (Mercuri, 1998; Smith *et al.*, 1999; Karaca *et al.*, 2004). The growth of the transplanted rib is unpredictable as its growth may be proportional to the rest of the mandible or may overgrow or may undergo resorption (El-Sheikh and Medra, 1997).

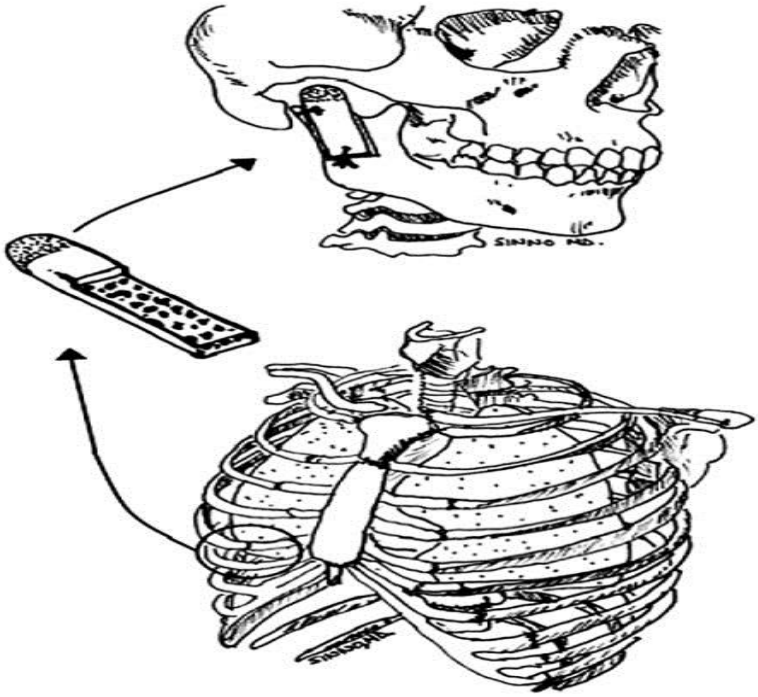

Figure 5: Harvested rib for grafting site and placement of graft on the mandible between the ramus and glenoid fossa [Source: Saeed and Kent, 2003].

II. Alloplastic Joints

A comprehensive and well documented systematic review of the history of alloplastic TMJ prosthesis has recently been published (De Meurechy and Mommaerts, 2018).Alloplastic materials are used to maintain the height of the condyle-ramus region and to reduce recurrence rate of the ankylosis due to osteoblastic growth (Chossegros et al., 1997; Ramezanian and Yavary, 2006).

Alloplastic joint prostheses have been developed for use in the reconstruction of TMJ ankylosis to avoid the complications associated with CCG treatment (Link *et al.,* 1993). An alloplastic total joint prosthesis provides a biomechanical rather than a biological solution in the treatment of TMJ ankylosis (Blunn *et al.,* 1991). Currently, CAD/CAM is being used to prepare the model of a joint prosthesis for custom made alloplastic joints (Mercuri *et al.,* 2007). Although these custom made alloplastic joints show promising results, high cost is

prohibitive. Their use in growing children is controversial and the life span of these joints still is unknown (Mercuri, 2012).

Factors associated with failure of the total joint prostheses are metal hypersensitivity (Wolford *et al.,* 2000), prosthesis micro-movement (Henry and Wolford, 1993), loosening of prosthetic components (Chase *et al.,* 1995), and bacterial contamination (Henry *et al.,* 2000). Another complication is foreign body giant cell reaction to wear particles of the polyethylene fossa and also titanium alloy causing pain and swelling (Chase, 1995; Mercuri and Anspach, 2003).

Advantage of Alloplastic Joint Prosthesis: -

- Restoration of vertical dimension
- Avoidance of donor site morbidity
- Reduction in operation time
- Low re-ankylosis rate due to surgical resection. An autogenous fat graft is packed around the articulation of the TMJ replacement device to decrease heterotopic bone formation that may cause decreased joint mobility and pain (Mercuri *et al.,* 2008)

Disadvantage of Alloplastic Joint Prosthesis: -

- Wear of the materials (Saeed *et al.,* 2002)
- Failure of prosthesis as mentioned before (Chase *et al.,* 1995; Saeed *et al.,* 2002)
- Lack of growth in children (Mercuri, 2000)
- More costly (Mercuri *et al.,* 1995)

1.2.7 Surgical Procedures

The surgical technique for release of TMJ ankylosis has been described by Rowe (1982); Kaban *et al.* (1990); El-Shiekh and Medra (1997). The main steps are as follows: -

- Incision through the skin is limited to the preauricular and submandibular approaches, so several approaches to the mandibular condyle have been described, and these incisions provide adequate exposure without injury to the facial nerve.
- These incision include the hockey stick (Bromberg *et al.*, 1969), T-shaped (El-Moftey, 1974), L-shaped, horizontal or / and vertical incision (Dingman, 1964; El-Moftey, 1974) and Al kayat and Bramley (1979). The submandibular approach is used for access to the lateral aspect of the ramus for fixation of the CCG or alloplastic joint;
- Stripping of any attachment such as muscles and ligaments that attach the mandible to the cranium (masseter, medial pterygoid, stylo-mandibular and pterygo-mandibular ligaments);
- Aggressive excision of the fibrous and/or bony ankylotic mass, coronoidectomy on the affected and possibly unaffected side if coronoid processes are elongated. The unaffected side is treated if a maximal incisal mouth opening of 35 mm is not achieved during ankylosis release;
- Lining of the joint with a temporalis myofascial flap as an interpositional material;
- CCG is harvested from 5th, 6th, 7th rib, and reconstruction of the ramus condyle unit (RCU);
- Rigid fixation with early mobilisation of the jaw if CCG is used, with minimal inter-maxillary fixation (not > 10 days);
- Prefabricated occlusal splint is used to improve the malocclusion after release of maxillo-mandibular wire fixation (MMF), it remains in place for approximately three months, without adjustment. The splint creates an open bite on the affected side to permit setting of the bone graft, and to allow over-eruption of the maxillary segment to improve the occlusal cant;
- Aggressive physiotherapy

A satisfactory and intensive post-operative physical therapy program is as essential as surgical intervention. It plays a vital role in the success of the treatment, improvement of MIO, and prevention of re-ankylosis.

Some surgeons, who perform GA, use the preauricular approach only or with temporal extension and do not release the pterygomassetric sling (El-Mofty, 1974; Roychoudhury *et al.,* 1999). The use of a prefabricated splint to establish occlusion during the period of immobilisation (Tauras *et al.,* 1972; El-Sheikh, 1999) has been documented.

In children, management of TMJ ankylosis seems to be influenced by the theories of growth of the mandible. The surgeons who believe that the condyle is the primary growth centre prefer the use of CCG, while those who subscribe to the functional matrix theory of growth, in which the condyle is regarded as a secondary growth centre, prefer GA and immediate postoperative exercise (Mabongo and Karriem, 2014).

1.2.7.1 Airway Management

Patients with TMJ ankylosis always present with challenges of management of airway before surgery (Sanchez, 1995). The three techniques of intubation that have been reported include blind nasal intubation, tracheostomy and fibre optic intubation (Rowe, 1982; Adekeye, 1983). Lately blind nasal intubation has been replaced with glidescope assisted intubation (Gupta *et al.,* 2015). Previously, blind nasal intubation was reported as the most commonly used intubation technique (Adekeye, 1983; Chidzonga, 1999), while latterly the fibre-optic techniques are the most commonly used (Lakshmi and Pradnya, 2011; Mabongo, 2014). However, tracheostomy should be avoided if possible as complications with this technique may be severe, especially in patients who suffered previous head injury or had an altered mental status (Mahafza *et al.,* 2012). The intubation process in TMJ ankylosis is difficult because of the possibility of failure, trauma and bleeding from the upper airway due to the distorted soft tissue anatomy (Sanchez, 1995). Furthermore, severe complications associated with blind nasal intubation includes death due to laryngospasm, oedema of the glottis and

injury to the lateral pharyngeal wall which results in pharyngo-mediastinal fistula (Rowe, 1982; Adekeye, 1983). The intubation challenge in children results from unequal growth of the two halves of the mandible and reduced mandibular space with overcrowding of soft tissue (Lakshmi and Pradnya, 2011).

1.2.8 Physiotherapy

Aggressive physiotherapy is considered equally as important as surgery (Chossegros *et al.,* 1997). Previous studies highlighted immediate postoperative physiotherapy as an important key in the success of TMJ ankylosis management (Kaban *et al.,* 1999; Miyamoto *et al.,* 2000; Su-Gwan, 2001; Elgazzar *et al.,* 2010). Post-operative physiotherapy allows for the restoration of normal mandibular movement and activates growth of the bone as described in "Moss's theory of growth" (Mercuri, 2008). It is also used to restore physiological mass of the masticatory muscle and prevents the need for further surgery (Maki and Al-Assaf, 2008). Devices used to mobilise the joint are acrylic screws, wooden spatulas, and functional appliances. Exercises under general anaesthesia as well as the use of the professional skills of physiotherapists are also valuable (Nwoku, 1979; Kaban *et al.,* 1990; Posnick and Goldstein, 1993; Chossegros *et al.,* 1997). Wooden tongue spatulas are used on the occlusal surfaces of teeth in gradually increasing numbers according to the patient's tolerance (El-Sheikh, 1999). This is done under strict supervision for 15 minutes five times a day, bi-weekly for 3 months, then monthly for one year (Sawhney, 1985). This active exercise is started early and continued regularly for at least one year to produce cortication of the bone ends at the newly created joint, thereby preventing neo-osteogenesis and subsequently preventing re-ankylosis (Adekeye, 1983). This also helps in stretching scar tissue to maintain the mouth opening and prevent fibrous adhesion (Su-Gwan, 2001). Furthermore, it is essential to rehabilitate and to encourage restoration of muscle function because muscle function has been compromised over time in such cases (Straith and Lewis, 1948; Bromberg *et al.*, 1969; El-Mofty, 1974; Mercuri, 2012).

In bilateral cases, post-operative immobilisation of the jaw for 1- 10 weeks is recommended (Kaban *et al.,* 1990; Posnick and Goldstein, 1997), while in unilateral cases some authors recommend early mobilisation of the jaw, within 24-48 hours after the release of TMJ ankylosis (Topazian, 1966; Chossegros *et al.,* 1997; Roychoudhury *et al.,* 1999). However, some clinicians do not immobilise the mandible, but active exercises are not begun for at least a week after operation (Rowe, 1982).

1.2.9 Complications

Re-ankylosis is universally accepted as the main complication following surgical release (Kaban *et al.,* 1990; Khan *et al.,* 2005). Topazian (1966) reported that re-ankylosis results from incomplete removal of the ankylotic mass, while inappropriate or inadequate post-operative exercise or physiotherapy has also been implicated (Chizdonga, 1999). However, a limited mandibular movement and re-ankylosis usually occurs within six months after surgery (Miller *et al.,* 1975; Freedus *et al.,* 1975; Bayat *et al.,* 2009).

Facial nerve injury in TMJ surgery is higher than in other types of surgery in the same region (Bayat *et al.,* 2009). Facial palsy is due to excessive intra-operative retraction of tissues (Weinberg and Kryshtalskyi, 1992; Roychoudhury *et al.,* 1999). Other complications, such as severe bleeding can be as a result of laceration of branches of the external carotid artery and maxillary artery that require ligation. Sepsis (El-Mofty, 1974) and light paraesthesia in the region supplied by the inferior alveolar nerve (MacIntosh and Henny, 1977) have also been reported.

Complications associated with CCG are unpredictable growth, which include the overgrowth of graft (Chossegros *et al.,* 1997; MacIntosh, 2000), resorption of the graft (El-Sheikh and Medra, 1997), and fracture at the costochondral junction (Smith *et al.,* 1999; Karaca *et al.,* 2004).

Complications associated with bilateral GA are malocclusion (Matsuura *et al.,* 2001), characterised by anterior open bite and posterior premature contact, and deviation of the jaw towards the affected side in unilateral cases (Kaban *et al.,* 1990).

1.2.10 Growth of the Mandible

There are two main theories on the growth of the mandible. The traditional concept is that growth takes place at various sutural interfaces in the skull, since the intrinsic potential of various growth centres facilitate development of the face (Dingman, 1971; Rowe, 1982). The cartilaginous cap of the condyle acts as a primary growth centre of the mandible and its removal affects the subsequent growth of the mandible (Ware and Tylor, 1965; Roychoudhury *et al.,* 1998). Furthermore, injury to this region may interfere with normal development of the mandible, therefore ankylosis that occurs would be responsible for cessation of function of the cartilaginous cells (Sawhney, 1985; Tideman and Doddridge, 1987; Sada, 1988). Bowerman (1987) reported that failure of growth in unilateral TMJ ankylosed cases where on the normal side, growth still occurs despite limited jaw motion, is a proof that the condyle plays an important role in the growth of the mandible.

The "functional matrix theory of growth" states that the condyle acts as a secondary growth centre (Moss and Salentjn, 1969; MacIntoch and Henny, 1977; Posswillo *et al.,* 1987) which is not responsible for growth of any other skeletal structure of the mandible except the condyle itself and considers the condyle an adaptive centre (Moss and Rankow, 1968). Petrovic *et al,* (1981) reported that the CCG junction has an almost unique intrinsic growth potential (cell-derived) combined with extrinsic factors (environment-modified) to adapt and remodel (Petrovic *et al.,* 1981). Furthermore, this theory suggested that the musculature matrix around the mandible will lead to growth once function is established and facial remodelling will occur subsequently (Roychoudhury *et al.,* 1998). Growth is mediated by extrinsic influences, which are morpho-genetic in primary form, such as size and shape of the

mandibular angle, while the coronoid process of the mandible is secondary and compensatory for primary change in the functional demands of the masseter, medial pterygoid and temporalis muscle respectively (Matukas *et al.,* 1980; Ware and Brown, 1981).

1.2.11 Studies on Outcomes

To our knowledge, various studies have used several variables to evaluate outcomes for the release of TMJ ankylosis, such as measuring the postoperative MIO, recurrence rate and follow-up period, irrespective of the surgical procedure (Abdel-Haleem *et al.,* 2011; Mehrotra *et al.,* 2012; Al-Moraissi *et al.,* 2014; Ma *et al.,* 2015; Liu *et al.,* 2015). De Roo *et al.* (2015) focused on improvement of MIO as the primary outcome parameter of the surgical treatment of TMJ ankylosis and other factors were rarely reported. However, the major flaw of outcome studies in TMJ ankylosis is that the final MIO is usually taken as an achieved mouth opening without considering the preoperative MIO. Mabongo (2013) addressed this discrepancy by mathematically calculating an achieved MIO using this formula: Achieved MIO = (final MIO – preoperative MIO). This formula makes it easy to objectively compare the outcomes of TMJ ankylosis (Mabongo, 2013). Current meta-analysis studies have also evaluated outcome by the mean change between the pre-to postoperative maximum interincisal opening (MIO) (Al-Moraissi *et al.,* 2014; Liu *et al.,* 2015).

However, Topazian (1964) reported a high recurrence rate in eight patients treated with GA and he advised that the IA should be performed as the preferred treatment for TMJ ankylosis. Roychoudhury *et al.* (1999) reviewed 50 cases, with good results for GA. They reported a MIO of 30 mm for a group aged 13- 30 years with anterior open bite in only three patients with 2% recurrence rate.

In a retrospective study of 34 patients by Bayat *et al,* (2009) the interpositional graft proved to be an effective method in the treatment of TMJ ankylosis. This study showed that the mean preoperative MIO and final MIO were 3.45 mm and 30.8 mm respectively. Re-ankylosis

occurred in two patients (5.9%), while facial nerve injuries were noted in 12 sides (28.5%) (Bayat *et al.,* 2009). Karthigeyan *et al.* (2012) compared outcomes of eight cases which were treated with GA and nine cases with IA. The study revealed that the final MIO was wider in patients operated with IA than the cases operated by GA (Karthigeyan *et al.,* 2012). Danda *et al.* (2008), however, did not find any significant difference in the maximum interincisal opening and the incidence of re-ankylosis between patients treated by GA and IA. They concluded that success of treatment depended on patient cooperation with active physiotherapy and regular follow-up. Bhatt *et al.* (2014) studied the recurrence rate on 207 patients treated by GA (group I) and 55 patients treated by IA (group II). They found that the recurrence rate in group I and group II were 14.6% and 4.8% respectively. The difference in the recurrence rate was not statistically significant with $P = 0.08$.

In South Africa, Mabongo (2013) documented a study of children involving 21 ankylosed joints treated by GA and CCG. A positive correlation between Op MIO and the outcome, with Pop MIO of 4 mm was reported. The study supported the view of Karthigeyan *et al,* (2012) that two important variables for a good outcome are good Op MIO and post-operative physiotherapy.

Long-term reports of the mandibular growth in children treated with CCG show that excessive growth on the treated side occurred in 54% of the 72 cases and growth equal to that on the opposite side occurred in only 38% of cases (Guyuron and Lasa, 1992; Ko *et al.,* 1999).

A meta-analysis on TMJ ankylosis observed that IA provided the most satisfactory outcome followed by joint reconstruction with a CCG followed by GA, recurrence rate for IA, CCG, GA were 0.01, 0.03, 0.06 respectively (Liu *et al.,* 2015). This study recommended that IA was treatment of choice for management of TMJ ankylosis, followed by CCG as the second choice and GA as the third choice (Liu *et al.,* 2015).

However, other meta-analysis studies have reported less definitive findings (Shaikh *et al.*, 2013; Lui *et al.*, 2015; Ma *et al.*, 2015). The meta-analysis study by Ma *et al.* (2015) showed that IA produced better MIO than GA, but the recurrence rate was the same. In contrast, Shaikh *et al.* (2013) found no significant difference for patients treated with IA and GA. De Roo *et al*. (2015) reported that the IA was superior to GA and reconstruction joints with CCG in terms of MIO and superior to GA in recurrence rate, while alloplastic joints were superior to a CCG in reducing pain, but provided a smaller MIO.

CHAPTER 2

AIM AND OBJECTIVES

2.1. Rationale and Significance of the Study

GA and joint reconstruction with CCG are commonly used surgical techniques for the management of TMJ ankylosis. This study reports the experience in the department of maxillofacial and oral surgery at the Charlotte Maxeke Johannesburg Academic Hospital (CMJAH) in an attempt to contribute to this controversial subject, with the hope of adding value in the management of patients with TMJ ankylosis.

2.2. Aim

- To compare outcomes of GA with CCG in patients treated for TMJ ankylosis

2.3. Objectives

- To identify factors associated with good surgical outcomes
- To identify the age group that is commonly affected by TMJ ankylosis
- To compare the mean MIO in the two surgical procedures

CHAPTER 3

METHODOLOGY

3.1 Study Design

This is a retrospective study of the records of 40 patients treated for TMJ ankylosis in the Maxillo-Facial and Oral Surgery unit at the Charlotte Maxeke Johannesburg Academic Hospital (CMJAH). All patients operated for TMJ ankylosis from January 2007 to December 2016 were included in this study. All patients were surgically operated under general anaesthesia. All patients were operated under a consultant and a registrar. The patients were treated according to the following the protocol:

- Preauricular incision with/without extension
- Aggressive excision of fibrous and/ or bony ankylotic mass
- Coronoidectomy on the affected side when necessary
- Contralateral coronoidectomy to improve maximum interincisal opening (where necessary)

When reconstruction with CCG was performed:

- Submandibular incision was made to expose the lateral aspect of the ramus for fixation of the graft
- Stripping of any attachment of muscles and ligaments
- Harvest of CCG from 5th or 6th or 7th rib
- Rigid fixation with early mobilisation of jaw
- Exercise was done 24 hours after surgery

In all patients, clinical examination and radiographs (plain X-rays and computed tomography - CT-scan), confirmed the diagnosis of TMJ ankylosis. The measuring devices used included

a gauge, calliper and ruler (rigid or flexible). Almost all of the measurements were obtained by use of a ruler.

3.2 Data Collection

The data was separated into pre-operative, intra-operative and post-operative stages. Pre-operative data was analysed for age of the patient as recorded, sex, aetiology, side involved (unilateral or bilateral), and measurement of the mouth opening. Operation data included type of ankylosis (fibrous or bony ankylosis), surgical technique and measurement mouth opening. Post-operative data were analysed for final outcome, maximum interincisal opening (MIO), post-operative change in mouth opening, measurement mouth opening, complications and follow-up periods with outcomes.

The outcomes were evaluated as previously described by Mabongo (2013). The outcomes were evaluated by calculating an achieved MIO (final MIO – preoperative MIO), and post-operative change in MIO (Op MIO - final MIO) (formulae below). Final MIO refers to the last recorded MIO.

When achieved MIO (A-MIO) was 10 mm or more, this was regarded as a good outcome, while an achieved MIO less than 10 mm was regarded as a bad result (re-ankylosis).

From these three parameters, outcomes are determined by using two variables, postoperative change in MIO (Pop-MIO) and Achieved MIO (A-MIO). The formulae below are used to calculate these variables:

- Pop MIO = Op MIO – Final MIO.
- A-MIO = Final MIO – pre-op MIO.

3.3 Statistical Analysis

The measures of central tendencies (mean, standard deviation, frequencies and percentages) were used to summarise the data. Descriptive statistics were used to calculate means and

standard deviations for the various measurements. Bar charts were drawn to clearly represent the data. The t-test was used to measure significant differences between the surgical methods at various stages while logistic regression was used to determine the association between socio-demographic variables and complications associated with the surgical methods.

3.4 Inclusion Criteria

- Patients with intra-capsular ankylosis of the TMJ
- Patients followed up for at least 3 months
- Patients with TMJ ankylosis treated with either GA or reconstruction with a CCG

3.5 Exclusion Criteria

- Patients treated with other surgical methods apart from GA and CCG.
- Loss of patient details or inadequate documentation
- Patients without follow-up
- Patients with pseudo-ankylosis of the TMJ

3.6 Ethical Issues

The ethical clearance for the study was obtained from the Human Research Ethics Committee Medical (HREC) (Appendix I). Permission for use of Hospital Records (medical records) was granted by the CEO of Charlotte Maxeke Johannesburg Academic Hospital (CMJAH) (Appendix IV), and the Hospital Research Risk Committee of the School of Oral Health Sciences (Appendix III).

CHAPTER 4

RESULTS

During this period of 10 years, records of forty patients with ankylosed TMJ met the inclusion criteria. Twenty-seven of these patients were male and 13 were female. The mean age of the participants was 21.78±11.73 years. The age range at presentation was from 2 to 55 years and five of these patients were above 30 years of age.

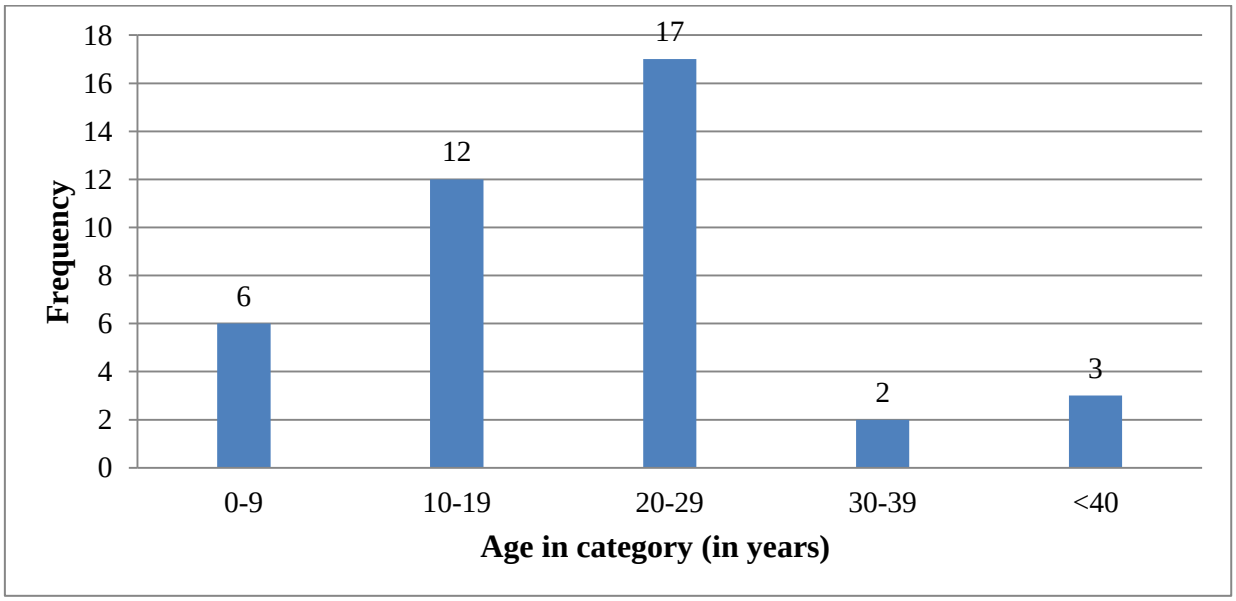

Figure 6: Age distribution of the particIAants

The aetiology of ankylosis was trauma 26 (62%), congenital 11 (27.5%), and infection 3 (7.5%) (Table 1). Twenty-one patients (16 males and 5 females) were treated by GA, while nineteen (11 males and 8 females) were treated by CCG.

Trauma was the cause of ankylosis in 16 patients treated by GA and 10 patients treated by CCG (Table 2). The TMJ ankylosis was unilateral in 23 patients and bilateral in 17 patients. Clinical and radiographic examination confirmed bony ankylosis to be present in 32 patients, fibrous in 5 patients and osseo-fibrous in 3 patients. Of the 32 patients that had bony

ankylosis, 17 patients were managed by GA and 15 patients were managed by CCG (Table 1). Of 5 patients with fibrous ankylosis, 4 were managed by GA and one by CCG. Furthermore, two of the 3 patients with fibrous ankylosis were treated by CCG, while other one was treated by GA.

Table 1: Preoperative data and outcomes in the study of the patient after surgical treatment

No	Age (yrs)	Sex	Etiology	Side	Ankylosis type	Sx-T	Pre-MIO (mm)	Op-MIO (mm)	Follow-up (Months)	Final –MIO (mm)	A-MIO (mm)	Pop-MIO (mm)	Complication
1	7	M	Trauma	U/L	Bony	GA	12	30	7	28	16	-2	None
2	6	M	Congenital	BIL	Bony	GA	10	30	12	32	22	2	None
3	27	F	Trauma	BIL	Bony	GA	10	40	6	40	30	0	Deviation
4	14	M	Trauma	U/R	Fibrous	GA	10	35	3	25	15	-10	Anterior open bite
5	17	M	Trauma	BIL	Bony	GA	5	30	6	25	20	-5	None
6	33	F	Trauma	U/R	Bony	GA	5	33	12	30	25	-3	None
7	8	M	Congenital	U/R	Fibro-osseus	GA	5	35	6	26	21	-9	Sepsis
8	24	M	Trauma	BIL	Fibrosis	GA	10	35	6	35	25	0	Anterior open bite/ sepsis
9	23	M	Congenital	BIL	Bony	GA	0	35	3	28	28	-7	None
10	28	F	Trauma	BIL	Bony	GA	5	40	6	30	25	-10	None
11	27	F	Trauma	BIL	Bony	GA	5	50	6	38	33	-12	None
12	55	M	Trauma	BIL	Fibrous	GA	5	30	7	30	25	0	None
13	18	M	Trauma	U/L	Bony	GA	3	30	6	36	33	6	Nerve injury VII
14	26	M	Trauma	BIL	Bony	GA	5	45	3	27	22	18	None
15	13	M	Trauma	U/R	Bony	GA	10	30	7	38	28	8	None
16	27	M	Congenital	U/L	Fibrous	GA	10	40	6	15	5	-25	Re-ankylosis
17	9	M	Trauma	U/L	Bony	GA	5	30	3	27	22	-3	Sepsis
18	22	M	Trauma	BIL	Bony	GA	10	40	6	28	18	-12	Sepsis
19	35	M	Trauma	U/R	Bony	GA	5	35	6	45	40	10	Deviation
20	23	M	Congenital	BIL	Bony	GA	12	35	8	15	3	-20	Re-ankylosis
21	28	F	Trauma	U/L	Bony	GA	10	30	12	32	22	2	None
22	28	F	Trauma	BIL	Bony	CCG	10	35	6	15	5	-20	Re-ankylosis
23	45	M	Trauma	U/R	Bony	CCG	12	40	6	37	25	-3	None
24	27	M	Congenital	U/R	Bony	CCG	5	35	6	33	28	-2	Nerve injury VII
25	25	M	Trauma	BIL	Bony	CCG	10	40	5	30	20	-10	None
26	12	F	Congenital	U/L	Bony	CCG	2	30	3	25	23	-5	Sepsis
27	28	M	Trauma	BIL	Fibro-osseus	CCG	7	40	3	30	23	-10	None
28	43	M	Trauma	U/L	Bony	CCG	4	40	6	40	36	0	None
29	29	F	Trauma	U/R	Bony	CCG	3	40	6	33	30	-7	None
30	2	M	Congenital	U/R	Fibrous	CCG	5	25	6	25	20	0	Hearing Problem
31	14	M	Congenital	BIL	Bony	CCG	7	25	8	31	24	6	None
32	17	M	Trauma	BIL	Bony	CCG	10	30	6	15	5	-15	Re-ankylosis
33	29	F	Trauma	U/R	Bony	CCG	5	35	3	28	23	-7	None
34	18	F	Trauma	U/L	Fibr-osseus	CCG	5	25	12	38	33	13	Deviation
35	15	F	Trauma	BIL	Bony	CCG	10	35	6	30	20	-5	None
36	9	M	Infection	U/L	Bony	CCG	0	30	12	30	30	0	None
37	10	F	Congenital	U/R	Bony	CCG	0	25	3	22	22	-3	Sepsis
38	12	M	Infection	U/L	Bony	CCG	2	25	6	30	28	5	None
39	23	F	Congenital	U/R	Fibrous	CCG	0	20	12	33	33	13	None
40	15	M	Infection	U/L	Bony	CCG	5	25	6	35	30	10	Deviation

In GA group, the most common cause for TMJ ankylosis was trauma (16 cases), with five cases reported as congenital and none due to infection (Table 2). One of the reported congenital cases was a previously treated ankylosis that re-ankylosed.

Table 2: The distribution of aetiology per surgical method used and the prevalence under each age group.

Aetiology	Age in years	GA	CCG
Trauma	0-9	2	-
	10-19	4	3
	20-29	7	5
	30-39	2	-
	≥40	1	2
Congenital	0-9	2	1
	10-19	-	3
	20-29	3	2
	30-39	-	-
	≥40	-	-
Infection	0-9	-	1
	10-19	-	2
	20-29	-	-
	30-39	-	-
	≥40	-	-

Trauma was also the most common cause of TMJ ankylosis among the patients treated by CCG (10 cases) followed by congenital (6 cases) and then infection (3 cases). Two of the reported congenital cases were previously treated TMJ ankylosis that re-ankylosed (Table 2).

4.1 MAXIMAL INTERINCISAL OPENING (MIO)

The mean preoperative MIO (pre MIO) of all the patients (40 patients) was 6.30 ± 3.54 mm. The mean pre MIO for GA was 7.24 mm and for CCG it was 5.37 mm with a range of 0-12 mm for both GA and CCG groups.

The Op MIO for patients treated with GA ranged between 30 and 50 mm with a mean of (35.14), while OP MIO ranged between 20 and 40 mm with a mean of (31.58) for those treated with CCG. The mean A MIO were (22.76) and (24.11) in GA and CCG cases, respectively (Table 3).

Table 3: Analysis of the outcomes between two surgical methods used in treating the patients.

Variable	Surgical method	N	Minimum	Maximum	Mean	Std. Deviation	P-value
Pre MIO	GA	21	0.0	12.0	7.24	3.35	0.10
	CCG	19	0.0	12.0	5.37	3.74	
Op MIO	GA	21	30.0	50.0	35.14	5.61	0.07
	CCG	19	20.0	40.0	31.58	6.68	
Follow-up	GA	21	3.0	24.0	8.24	6.74	0.86
	CCG	19	3.0	24.0	8.263	7.13	
F MIO	GA	21	15.0	45.0	30.00	7.31	0.82
	CCG	19	15.0	40.0	29.47	6.79	
A MIO	GA	21	3.0	40.0	22.76	8.61	0.62
	CCG	19	5.0	36.0	24.11	7.16	
Pop MIO	GA	21	-25.0	18.0	-3.43	10.11	0.66
	CCG	19	-15.0	13.0	-2.11	7.49	

Among the patients operated with GA in the study, 14 had a negative postoperative change thereby suggesting that the Op MIO was reduced, while seven patients had a positive Pop MIO with the mean Pop MIO -3.43 mm.

Among the nineteen patients operated by CCG in the study, 11 had a negative postoperative change thereby suggesting that the Op MIO was reduced, while eight patients had a positive

Pop MIO with the mean Pop MIO -2.11 mm, and their Pop MIO was negative with -10 mm and -20 mm (Table 3).

The mean follow-up for the whole sample ranged from 3 months to 24 months. Thirty-one patients had follow-up of more than 6 months and 9 patients had follow-up of less than 6 months. For patients who were followed up for more than 6 months, the mean final MIO was 30.55 mm while those followed up less than 6 months, the mean final MIO was 26.87 mm (Table 4).

There were no significant differences ($p > 0.05$) in the mean MIO between the groups of patients treated with GA and CCG.

Table 4: Follow-up period with mean of outcomes.

Surgical treatment	Follow-up			
	≥ 6 months N	MIO	< 6 months N	MIO
GA	17	30.76	4	26.75
CCG	14	30.35	5	27
Mean	-	30.55	-	26.87

Table 5: Affected side per surgical method used and the prevalence under each age group.

Side	**Age in years**	**GA**	**CCG**
Unilateral	0-9	3	2
	10-19	3	5
	20-29	2	4
	30-39	2	
	≥40	-	2
Bilateral	0-9	1	-
	10-19	1	3
	20-29	8	3
	30-39	-	-
	≥40	1	-

There were almost equal proportions of patients (11 GA vs 13 CCG) between the two surgical methods that had unilateral ankylosis. However, there were 10 patients that had bilateral ankylosis that were treated by GA while six patients were treated by CCG. Most affected patients were in the 11-20 (11 patients) and 21-30 (17 patients) age groups (Table 5).

Table 6: Type of ankylosis per surgical method used and the prevalence under each age group.

Type of ankylosis	Gender	GA	CCG
Bony	Male	12	9
	Female	5	6
Fibrous	Male	3	1
	Female	-	1
Bony & Fibrous	Male	1	1
	Female	-	1

4.2 Complications

Eighteen (45%) patients had various complications. Four (10%) patients developed re-ankylosis, two were treated with GA and other two treated by CCG. Facial nerve injury was recorded in two (5%) patients, one treated by GA and other treated by CCG. Two patients who were treated with GA developed anterior open bite, one patient had bilateral involvement and the other had unilateral involvement. Four patients developed deviation of the mandible of which two were treated by CCG and the other two by GA. Six patients (15%) developed sepsis, four (19%) of these were treated by GA and the other two (10.5%) with CCG. One patient developed hearing problem was treated by CCG.

4.3 Associations

The associations between the complication and age, gender or aetiology was investigated using logistic regression. There was no statistically significant association (*P > 0.05*) between the three factors and complications as shown in the STATA outputs below, whether done for all the cases or based on the surgical method.

4.3.1 Logistic Regression Output for all the 40 cases

Multiple logistical regression was performed to estimate the relationship between complication and an individual's age, gender and aetiology (Table 7). All three factors: age (*P = 0.150*), gender (*P = 0.596*) and aetiology (*P = 0.895*) were found not to be significant predictors of the complication in each individual.

Table 7: Analysis of association between factors and complication for all 40 cases.

Complication	Coef	Std. err	Z	P>z	(95%CI)	
Age	-.0523488	. 0363536	-1.44	0.150	-.1236005	.018903
Gender	-.3762841	. 7102591	-0.53	0.596	-1.768366	1.015798
Aetiology	-.0762528	.5802485	-0.13	0.895	-1.213519	1.061013
Cons	1.526779	1.74626	0.87	0.382	-1.895828	4.949385

Level of significance P < 0.05.

4.3.2 Logistic Regression Output for 21 cases (GA)

MultIAle logistical regression was performed to estimate the relationshIA between complication and an individuals' age, gender and aetiology (Table 8). All the three factors: age (*P = 0.705*), gender (*P = 0.200*) and etiology (*P = 0.632*) were found not to be significant predictors of the complication in each individual.

Table 8: Analysis of association between factors and complication for 21 cases (GA).

Complication	Coef	Std. err	Z	P>z	(95% CI)	
Age	-.0159586	.0421875	-0.38	0.705	-.0986446	.0667275
Gender	-1.589491	1.239739	-1.28	0.200	-4.019335	.8403538
Aetiology	.5426588	1.133726	0.48	0.632	-1.679402	2.76472
Cons	1.516943	2.312964	0.66	0.512	-3.016384	6.05027

Level of significance P < 0.05.

4.3.3 Logistic Regression Output for 19 cases (CCG)

Multiple logistical regression was performed to estimate the relationship between complication and an individuals' age, gender and aetiology (Table 9). All the three factors: age (*P = 0.139*), gender (*P = 0.662*) and aetiology (*P = 0.675*) were found not to be significant predictors of the complication in each individual.

Table 9: Analysis of association between factors and complication for 19 cases (19).

Complication	Coef	Std. err	Z	P>z	(95% CI)	
Age	-.1112144	.0750887	-1.48	0.139	-.2583856	.0359568
Gender	.4942002	1.129991	0.44	0.662	-1.720541	2.708941
Aetiology	-.3793697	.9037974	-0.42	0.675	-2.15078	1.392041
Cons	1.814737	3.506343	0.52	0.605	-5.057569	8.687043

Level of significance P < 0.05.

CHAPTER 5

DISCUSSION

5.1 Aetiology

Trauma was the cause of ankylosis in 65% (n=26) of patients. Twenty-one patients were involved in vehicle accidents and falling off a bicycle, while three cases occurred as a result of birth trauma and the other two cases following an assault. Congenital and infective causes accounted for 27.5% (n=11) and 7.5% (n=3) of patients respectively (Table 4). Trauma and congenital seem to be the most common causes of TMJ ankylosis. Trauma was the most common cause of ankylosis which concurs with the findings of other authors (Chidzonga, 1999; Roychoudhury *et al.,* 1999; Su-Gwan, 2001; Danda *et al.,* 2009; Elgazzar *et al.,* 2010; Mabongo, 2013). Other studies reported infection as the most common cause of ankylosis among children (Nwoku, 1979; Adekeye, 1983). Improved understanding and management of infection and a decrease in the incidence of otitis media since the advent of antibiotics has led to a lower incidence of ankylosis due to infections (Kennett, 1973). Another possible factor could be that Noma (Cancrum oris) is rare in South Africa and more common in Nigeria (Mabongo, 2013).

Congenital ankylosis is relatively rare, but in this study TMJ ankylosis was reported as congenital in 27.5% (n= 11) (Table 4). This finding concurs with other studies that consider congenital causes as the next most common aetiological factor (El-Shiekh, 1999; Ramezanian and Yavary, 2006). The challenge with recording the aetiological factors is that clinicians often depend on an inaccurate history provided by the mother of paediatric patients regarding their childhood experience. Accurately documented clinical records are often unavailable which prevents more reliable reporting. Hence some authors define “congenital ankylosis” as

the term applied to patients who had limitation of mouth opening in infancy which might have been caused by obstetric trauma during delivery (Topazian, 1964; Rajgopal *et al.*, 1983). This was also supported by Mabongo (2013), who reported a condylar head that was found lying medial to the ankylotic mass in a patient that was reported to have a congenital ankylosis.

El-Sheikh (1999) uses the term "congenital ankylosis" in a situation where there is complete bony fusion between mandibular condyle and temporal bone, with absence of any trace of intra-capsular disc and lateral pterygoid muscle. However, ankylosis that was associated with atrophy of the left side of the mandible and maxilla at birth was reported by Burket (1936). Another reason that could lead to the apparently low incidence of congenital cases might be that these cases are also reported as syngnathia or synchiae. In this study, the high number of congenital cases is probably related to the failure to diagnosis the problem at an in early stage.

5.2 Age

Although ankylosis can occur in any age group, it usually develops before the age of 10 years (Malik, 2002). In this study, the most commonly affected age group was the third decade of life (42.5%) (Fig 4). This finding concurs with other authors who reported a high incidence of TMJ ankylosis in patients aged 20-29 years (Bello *et al.*, 2012; Babu *et al.*, 2013). In contrast, other studies reported patients in the first decade of life as the most commonly affected age group (Topazian, 1964; El-Mofty, 1972). The explanation for this difference could be the availability of expertise for treating mandibular fracture and the rarity of facial fracture in children compared to adults (Bamjee *et al.*, 1990).

5.3 Gender

Since environmental factors seem to be the cause of TMJ ankylosis, both genders should be equally affected. However, this study showed that males are more commonly affected (67.5 %) (n=27), then females 32.5% (n=13) (Table 1). This difference is probably associated with the greater physical activity of boys (Dingman, 1946). This compares favourably with most of the studies which reported TMJ ankylosis to be more common in males (Dingman, 1964; El-Mofty, 1972; Valentini *et al.,* 2002; Bayat *et al.,* 2009). Risdon (1934) found that both sexes were equally affected. Conversely other studies reported a slightly higher number of females than males (El-Sheikh, 1999; Roychoudhury *et al.,* 1999). This higher number of females with TMJ ankylosis may be due to some countries that are characterised by a higher number of females compared with males (Hossain *et al.,* 2012).

5.4 Outcomes

5.4.1 Final Outcomes (F-MIO)

A literature review reveals that the outcomes are measured by using final MIO. However, there is no agreement on what constitutes a good outcome. Some studies regard an MIO of at least 30 mm as a good result (Chossegros *et al.,* 1997; Roychoudhury *et al.,* 1999; Bhatt *et al.,* 2014), while others regard a MIO of 20 mm as adequate for function and aesthetics (Topazian, 1966). This study evaluates outcomes of release of TMJ ankylosis with a fairly unique method where A-MIO of more than 10 mm is regarded as a good result, while A-MIO less than 10 mm is considered as re-ankylosis.

Four patients had a final MIO between 0-19 mm, twelve had a MIO between 20-29 mm and twenty-four patients had a final MIO of 30 mm and above (Table 2). These outcomes differ from the study by Kaban *et al,* (1990) in which all patients achieved final MIO of 30 mm and above.

The mean final MIO of this study was 29.73 mm (SD= 14.1) which compares favourably with that of other studies (El-Mofty, 1974; Roychoudhury *et al.,* 1999), but is less than the 37.5 mm in the study by Kaban *et al.* (1990). An in-depth comparison of the outcomes between this study and Kaban *et al.* (1990) suggests that the difference lies in the mean pre-op MIO, which was 16.5 mm (SD= 13.87) in the series by Kaban *et al.* (1990), while in this study, it was 6.29 mm (SD= 7.9).

In this series, final MIO of GA with a mean of 30 mm (SD=7.31) was regarded as a satisfactory result with a low recurrence rate of 9.5% (n=2), from 21 cases (Table 2). This compares favourably with other studies (Rajgopal *et al.,* 1983; Roychoudhury *et al.,* 1999), but differs from Topazian's (1966) series in which GA showed a recurrence rate of 53.3% (8 cases) from 15 cases.

The OP MIO ranged between 20 and 40 mm with a mean of 31.58mm (SD = 6.68), and the mean A MIO was 24.11mm (SD = 7.16) for those treated with CCG. These outcomes with CCG concur with some studies that have reported good results with CCG (Raveh *et al.,* 1989; Wolford *et al.,* 1994; Ko *et al.,* 1999); while other studies have reported bad results (Guyuron and Lasa, 1992; Saeed and Kent, 2003).

In this study, there was no statistically significant difference ($P > 0.05$) in the mean F MIO between the patients treated with GA and CCG was 30 mm (SD = 7.31) and 29.47 (SD = 6.79) respectively) (Table 2).

5.4.2. Post- Operative Change in MIO (Pop-MIO)

The patients progress after surgery were assessed by a parameter called post- operative change (Pop-MIO), which was calculated by subtracting Op-MIO from the final MIO (Mabongo and Karriem, 2014). A positive pop MIO indicates an increase in mouth opening

from what was obtained intra-operatively, while a negative value reveals a decrease in mouth opening. A zero value indicates that intra-operative mouth opening has been maintained.

Utilising Mabongo's outcomes formula, 12 patients operated by GA had negative post-operative changes, while 6 patients had a positive Pop- MIO and 3 patients maintained the intra-operative mouth opening (Table 2). Some studies also reported reduction of Pop MIO in some patients (Adekeye, 1983) while in others reduction Pop MIO was reported in all patients (Salins, 2000). This reduction in post-operative changes in mouth opening could possibly be associated with lack of compliance with the post-operative physiotherapy protocol and/or failure to strip the medial pterygoid and the ligaments that attach the mandible to the base of the skull (El-Sheikh, 1999).

On the other hand, 10 patients had a negative Pop-MIO after being operated with CCG and 6 patients had a positive post-operative change, while 3 patients maintained the intra-operative mouth opening. Two patients with high negative value had a re-ankylosis.

Overall, pop-MIO in patients treated with GA had a mean of -3.43 mm (SD= 10.11), while in CCG the mean was -2.11 mm (SD= 7.49). The mean Op MIO for GA and CCG about 35.14 mm (SD= 5.61) and 31.58 mm (SD= 6.68) respectively (Table 2). An intraoperative MIO of 30-35 mm should be the goal for every surgeon as suggested by Kaban *et al.,* (1990). The Pop MIO for GA and CCG was -3.43 (SD= 10.11) and -2.11 (SD= 7.49) respectively, and the overall Pop MIO was 2.77 (SD=17.6). This Pop MIO compares favourable with that of -6.5 mm reported by Mabongo and Karriem, 2014.

Patients who had congenital ankylosis of TMJ had a mean Pop MIO of -4.5 mm (SD= 11.50) which was higher than other etiology of ankylosis due to trauma and infection with means of -2.5 mm (SD= 7.29) and 7.2 mm (SD= 3.35) respectively. This reduction could be due to the

longstanding nature of the problem characterised by poorly developed or hypoplastic musculature due to lack of functional (Mitarashi *et al.,* 2002).

According to Mabongo and Karriem, (2014) this parameter, Pop MIO, could be of help in the following ways: -

- Evaluating post-surgical improvement in TMJ ankylosis patients
- Motivating the patients
- Can also be used as a research tool

The main disadvantage of this variable is that it cannot be worked out if intra-operative mouth opening was not recorded.

5.4.3. Achieved Mouth Opening (A-MIO)

The mean A-MIO for this sample was 23.44 mm (SD= 15.7), where the pre-operative MIO was 6.30 mm (SD= 7.8) and the final MIO 29.74 mm (SD= 14.1). There are studies that reported improvement in mouth opening A-MIO of more than 23 mm (Manganello-Souza and Mariani, 2003; Güven *et al.,* 2008; Danda *et al.,* 2009; Bhatt *et al.,* 2014), while other studies reported improvement of mouth opening A-MIO of less than 23 mm (Zhi *et al.,* 2009; Vasconcelos *et al.,* 2008; Holmlund *et al.,* 2013).

In this series, the patients treated with GA had a mean pre MIO of 7.24 mm (SD= 3.35), F MIO of 30 mm (SD= 7.31) and A-MIO of 22.77 mm (SD= 8.61), while for CCG the mean pre MIO was 5.37 mm (SD= 3.74), F MIO 29.47 mm (SD= 6.79) and A-MIO of 24.11 mm (SD= 7.16) (Table 2). The results of this study suggest that CCG produced better outcomes than GA, which is in line with Elgazzar *et al,* (2010) and Liu *et al,* (2015). However, no statistically significant difference ($P > 0.05$) in the mean MIO was found between the two groups of patients in this study.

5.5 Sides Involved

Unilateral TMJ ankylosis was found in 57.5% (n=23) cases, and bilateral cases 42.5% (n=17) (Table 5). Ten patients with unilateral TMJ ankylosis were treated by GA and 13 patients were treated with CCG with the mean final MIO 30.2 mm and 30.6 mm respectively. This finding concurs with a study that reported that patients with unilateral cases have final MIO more than 30 mm (Roychoudhury *et al.,* 1998) while in bilateral ankylosis, 11 patients were treated with GA and six patients were treated under CCG with the mean final MIO 29.8 mm and 22.3 mm respectively (Table 2). Overall, the mean final MIO of unilateral cases was 30.47 mm, while in bilateral cases it was 27.2 mm. When outcomes of unilateral cases were clinically compared with those of bilateral cases, unilateral cases tend to show better outcomes than in bilateral cases. This supports the findings of other studies that reported more improvement of MIO in unilateral cases than bilateral cases (Sarma and Dave, 1991; Roychoudhury et *al.,* 1999; Guven, 2008; Bansal *et al.,* 2011; Yang *et al.,* 2011). This suggests that the bilateral cases have a higher tendency for post-operative reduction of MIO than unilateral cases. This difference in post-operative change in MIO between bilateral and unilateral cases can be explained by the fact that during ankylosis the muscles on the normal side were using more force to open the mouth, while after release of TMJ ankylosis the workload for these muscles is reduced (Guyol *et al.,* 1995; Guven, 2008; Mabongo, 2013). Abdel-Haleem *et al.* (2011) reported that improvement of aesthetic deformity and facial asymmetry was noted in all patients especially in young patients with unilateral ankylosis.

5.6 Type of Ankylosis

Bony ankylosis was present in 31 patients (77.5%), fibrous ankylosis in 6 patients (15%) and fibro-osseous ankylosis in 4 patients (7.5%) where the mean final MIO was 30 mm, 27 mm, and 30 mm respectively (Table 2&5). Some authors have documented similar trends, Elgazzar *et al,* (2010) reported bony ankylosis in 71% (n=77) with the mean final MIO 32.7

mm and fibrous ankylosis in 6% (n=6) with a mean final MIO of 32.8 mm and fibro-osseous in 24% (n=26) with a mean final MIO of 33.5 mm. Mishra *et al,* (2012) found bony ankylosis in 24 patients (82.3%) and fibrous ankylosis in 9 patients (17.7%).

5.7 Complications

5.7.1 Re-ankylosis

Re-ankylosis is the most common complication of surgical release of TMJ ankylosis (Guyuron and Lasa, 1992; Chidzonga, 1999; Mabongo, 2013). Re-ankylosis usually occurs within the first six months (Miller *et al.,* 1975; Freedus *et al.,* 1975), and some clinicians regard patients as being re-ankylosis free after six months (Kaban *et al.,* 1990; Lello, 1990).

In this study, four patients (10%) suffered from re-ankylosis, two cases treated with GA and two cases treated by CCG (Table 1). Some authors believe that recurrence rate is higher with paediatric cases (Raveh *et al.,* 1989; Posnick and Goldstein, 1993). In this series, re-ankylosis occurred in the third decade of life with mean age 23.75, with a follow-up period of more than six months. Re-ankylosis occurred in the patients released from bony and fibrous ankylosis (Table 1), further suggesting that re-ankylosis occurs with both types of ankylosis. This concurs with finding of other authors (Kaban *et al.,* 1990; Ramezanian and Yavary, 2006).

Intra-operative or iatrogenic causes of re-ankylosis are failure to remove enough bone, the medial extent of the ankylotic mass (Kaban *et al.,* 1990; Posnick and Goldstein, 1993), failure to expose and remove the coronoid processes when indicated (El-Sheikh, 1999), and failure to strip the contracted muscles of mastication that pull the ramus directly to the base of the skull (El-Sheikh and Medra, 1997). Post-operative causes could include lack of compliance with the exercises (Kaban *et al.,* 1990; Chidzonga, 1999; El-Sheikh, 1999). In this study, the

most likely cause for re-ankylosis occurring post-operative in three patients was probably lack of proper physiotherapy and adequate exercise time.

The re-ankylosis rate was 9.5% in patients treated by GA and 10.5% for patients treated with CCG. This rate compares favourably with outcomes reported by other authors (El-Mofty, 1974; Kaban *et al.*, 1990). This suggests that re-ankylosis does not depend on the type of procedures used to release the ankylosis, but confirms the assertion that adequacy of intra-operative mouth opening (Kaban *et al.,* 1990), and compliance with post-operative physiotherapy (El-Sheikh, 1999; Chidzonga, 1999) are the most likely causes of re-ankylosis.

5.7.2 Sepsis

Sepsis occurred in six patients (15%), four patients treated with GA and the other two treated with CCG (Table 1). Sepsis is a rare complication, but has been reported, especially in patients who had profuse intraoperative bleeding. It is believed that packing with haemostatic materials, provides a good nidus for bacterial growth (Rowe, 1982). All patients that developed sepsis had severe bleeding intra-operatively, and were treated by debridement and antibiotics.

5.7.3 Facial Nerve Injury

In this series, transient weakness of branches of the facial nerve was reported in two patients (5%) which compares favourably with other studies (El-Mofty, 1974; Rajgopal *et al.*, 1983). The injury to the facial nerve is usually as a result of excessive flap traction during surgery and excessive bone removal (Rowe, 1982; Elgazzar *et al.*, 2010). The incidence of transient injury of the facial nerve is very low and the nerve usually regains function within six months (Weinberg and Kryshtalskyj, 1992; Sidebottom and Salla, 2012). Permanent facial nerve damage was not reported in this study.

5.7.4 Anterior Open Bite

This complication is usually associated with GA (Lello, 1990; Roychoudhuy *et al.,* 1999). In this series, the 2 patients that developed an anterior open bite were treated with GA. This concurs with Elgazzar *et al,* (2010) who further noted that most of the patients who developed an anterior open bite had an open bite before surgery, possible as a result of attempts to force food between the anterior teeth.

5.7.5 Other Complications

Deviation of the mandible occurred in four patients- two patients in each treatment group. Three of the four patients who had deviation of the mandible had unilateral TMJ ankylosis, while the other case had bilateral TMJ ankylosis. Some studies suggested that deviation and malocclusion may be due to shortening of the mandibular ramus as a consequence of creating two wide a gap (El-Shiekh, 1999; Vasconcelos *et al.,* 2008). Creating a gap of approximately 5 mm during GA is recommended by some authors as a method of preventing this from occurring (Topazian, 1966; Rowe, 1982). Kazanjian (1938) reported that when arthroplasty is performed close to the TMJ, it seems that the involved bones and muscles have an impressive ability to adapt to the alteration in anatomic relationship and that reconstruction of the condyle is not important for obtaining satisfactory restoration of function. Another rare complication reported was post-operative loss of hearing, probably due to extensive flap surgery.

5.8 Follow-up Period

The follow-up period ranged from 3-24 months with a mean of eight months (Table 3). This follow-up period does not compare favourably with a mean of 22.3 months in a study by Zhi

et al, (2009), and 24.4 months by El-Mofty (1972). Other studies had cases with a minimum follow-up period of one year or more (Kaban *et al.,* 1990; Lello, 1990).

Chossegros *et al*, (1999) reported that 90% of patients with a follow-up period of more than one year had a final MIO 30 mm and above. In follow-up periods of less than a year only 64% of cases reported a final MIO of 30 mm and above. It was proposed that this was related to the high degree of patient motivation by compliance treatment and sufficient physiotherapy. In this series, six patients had follow-up periods more than a year with a mean final MIO of 32.49 mm. Eight patients had a follow-up of three months and their reported final MIO was 26.5 mm. this was also proposed to be as a result of adequate post-operative physiotherapy and treatment compliance.

The shorter follow up period reported in this study was most likely as a result of an inability to comply with the post-operative treatment recommendations. As the institution is a public referral hospital, a number of the patients lived considerable distances away from the treating facility making attendance for follow-up management very challenging. In younger patients, the fear of painful post-operative visits often results in non-compliance with treatment.

5.9. Association Factor with Outcomes

According to the results in this series, there is no significant association between factors such as aetiology, age, gender, type of ankyloses, and complication with outcomes (Table 4&5&6). This is in agreement with some authors who reported no meaningful correlation between outcomes and aetiology, side, gender, and complication (Kaban *et al.*, 1990; Ramezanian and Yavary, 2006). In contrast, other studies reported that variables such as age, gender and race had an effect on the outcome of MIO (Ying *et al.,* 2013; Voiner *et al.,* 2011; De Roo *et al.,* 2015).

CHAPTER 6

CONCLUSIONS AND RECOMMENDATIONS

6.1 Conclusion

No statistically significant difference ($P > 0.05$) between groups treated with GA and CCG was found in this study supporting the hypothesis that there is no difference in outcome between the two surgical procedures. The most commonly affected age group was the third decade (42.5%). The role of adequate patient compliance and physiotherapy is regarded as essential for satisfactory outcome. There was no significant association between factors such as aetiology, age, gender, type of ankyloses, and complication developed with outcomes.

6.2 Recommendations

The follow up period for TMJ ankylosis patients should not be less than a year. A clear post-operative physiotherapy protocol that is followed for a year should be developed.

6.3 Limitations

A major limitation of the study is that lateral excursions of the jaws were not recorded and therefore could not be studied. The other limitations of the study are the short follow- up period and the lack of post-operative physiotherapy protocol.

REFERENCES

Abdel-Haleem, A.K., Nouby, R. and Taghian, M., 2011. The use of the rib grafts in head and neck reconstruction. *Egyptian Journal of Ear, Nose, Throat and Allied Sciences*, *12*(2), pp.89-98.

Adekeye, E.O., 1983. Ankylosis of the mandible: analysis of 76 cases. *Journal of Oral and Maxillofacial Surgery*, 41(7), pp.442-449.

Ajike, S.O., Chom, N.D., Amanyeiwe, U.E., Adebayo, E.T., Ononiwu, C.N., Anyiam, J.O. and Ogala, W.N., 2006. Non-syndromal, true congenital ankylosis of the temporomandibular joint: a case report. *West indian medical journal*, *55*(6), pp.444-446.

Al-Kayat, A. and Bramley, P., 1979. A modified pre-auricular approach to the temporomandibular joint and malar arch. *British Journal of Oral Surgery*, *17*(2), pp.91-103.

Allori, A.C., Chang, C.C., Fariña, R., Grayson, B.H., Warren, S.M. and McCarthy, J.G., 2010. Current concepts in pediatric temporomandibular joint disorders: Part 1. Etiology, epidemiology, and classification. *Plastic and Reconstructive Surgery*, 126(4), pp.1263-1275.

Al-Moraissi, E.A., El-Sharkawy, T.M., Mounair, R.M. and El-Ghareeb, T.I., 2015. A systematic review and meta-analysis of the clinical outcomes for various surgical modalities in the management of temporomandibular joint ankylosis. *International journal of oral and maxillofacial surgery*, *44*(4), pp.470-482.

Babu, L., Jain, M.K., Ramesh, C. and Vinayaka, N., 2013. Is aggressive gap arthroplasty essential in the management of temporomandibular joint ankylosis? A prospective clinical study of 15 cases. *British Journal of Oral and Maxillofacial Surgery*, 51(6), pp.473-478.

Bamjee, Y., Lownie, J.F., Cleaton-Jones, P.E. and Lownie, M.A., 1996. Maxillofacial injuries in a group of South Africans under 18 years of age. *British Journal of Oral and Maxillofacial Surgery*, 34(4), pp.298-302.

Bansal, A., Jain, S., Arora, S., Gupta, S., Singh, V.A. and Prashar, D., 2011. Costochondral grafts in the treatment of temporomandibular joint ankylosis: a Clinical Study.

Bast, F., Collier, S., Chadha, P. and Collier, J., 2015. Septic arthritis of the temporomandibular joint as a complication of acute otitis media in a child: a rare case and the importance of real-time PCR for diagnosis. *International Journal of Pediatric Otorhinolaryngology*, 79(11), pp.1942-1945.

Bayat, M., Badri, A. and Moharamnejad, N., 2009. Treatment of temporomandibular joint ankylosis: gap arthroplasty and interpositional arthroplasty with temporalis muscle flap. *Oral and Maxillofacial Surgery*, 13(4), pp.207-212.

Behnia, H., Tehranchi, A. and Younessian, F., 2015. Comprehensive Management of Temporomandibular Joint Ankylosis—State of the Art. In *A Textbook of Advanced Oral and Maxillofacial Surgery Volume 2*. InTech.

Bellinger, D.H., 1940. Temporomandibular ankylosis and its surgical correction. *The Journal of the American Dental Association*, 27(10), pp.1563-1568.

Bello, S.A., Olokun, B.A., Olaitan, A.A. and Ajike, S.O., 2012. Aetiology and presentation of ankylosis of the temporomandibular joint: report of 23 cases from Abuja, Nigeria. *British Journal of Oral and Maxillofacial Surgery*, 50(1), pp.80-84.

Bhatt, K., Roychoudhury, A., Bhutia, O. and Pandey, R.M., 2014. Functional outcomes of gap and interposition arthroplasty in the treatment of temporomandibular joint ankylosis. *Journal of Oral and Maxillofacial Surgery*, 72(12), pp.2434-2439.

Blackwood, H.J.J., 1957. Intra-articular fibrous ankylosis of the temporomandibular joint. *Oral Surgery, Oral Medicine, Oral Pathology*, 10(6), pp.634-642.

Blunn, G.W., Walker, P.S., Joshi, A. and Hardinge, K., 1991. The dominance of cyclic sliding in producing wear in total knee replacements. *Clinical Orthopaedics and Related Research*, 273, pp.253-260.

Bowerman, J., 1987. Reconstruction of the temporomandibular joint for acquired deformity and congenital malformation. *British Journal of Oral and Maxillofacial Surgery*, 25(2), pp.149-160.

Bromberg, B.E., Song, I.C. and Radlauer, C.B., 1969. Surgical treatment of massive bony ankylosis of the temporomandibular joint. *Plastic and Reconstructive Surgery*, 43(1), pp.66-70.

Burket, L.W., 1936. Congenital bony temporomandibular ankylosis and facial hemi-atrophy: review of the literature and report of a case. *Journal of the American Medical Association*, 106(20), pp.1719-1722.

Chase, D.C., Hudson, J.W., Gerard, D.A., Russell, R., Chambers, K., Curry, J.R., Latta, J.E. and Christensen, R.W., 1995. The Christensen prosthesis: a retrospective clinical study. *Oral Surgery, Oral Medicine, Oral Pathology, Oral Radiology, and Endodontology*, 80(3), pp.273-278.

Chidzonga, M.M., 1999. Temporomandibular joint ankylosis: review of thirty-two cases. *British Journal of Oral and Maxillofacial Surgery*, 37(2), pp.123-126.

Chossegros, C., Guyot, L., Cheynet, F., Blanc, J.L. and Cannoni, P., 1999. Full-thickness skin graft interposition after temporomandibular joint ankylosis surgery: A study of 31 cases. *International Journal of Oral and Maxillofacial Surgery*, 28(5), pp.330-334.

Chossegros, C., Guyot, L., Cheynet, F., Blanc, J.L., Gola, R., Bourezak, Z. and Conrath, J., 1997. Comparison of different materials for interposition arthroplasty in treatment of temporomandibular joint ankylosis surgery: long-term follow-up in 25 cases. *British Journal of Oral and Maxillofacial Surgery*, 35(3), pp.157-160.

Chugh, A., Pasricha, N., Bedi, R.S. and Pandey, P., 2011. Management of temporomandibular joint ankylosis in children: Current perspective. *Asian Journal of Oral Health & Allied Sciences*, 1(2), p.161.

Danda, A.K., Ramkumar, S. and Chinnaswami, R., 2009. Comparison of gap arthroplasty with and without a temporalis muscle flap for the treatment of ankylosis. *Journal of Oral and Maxillofacial Surgery*, 67(7), pp.1425-1431.

De Meurechy, N. and Mommaerts, M.Y., 2018. Alloplastic temporomandibular joint replacement systems: a systematic review of their history. *International journal of oral and maxillofacial surgery*.

De Roo, N., Van Doorne, L., Troch, A., Vermeersch, H. and Brusselaers, N., 2016. Quantifying the outcome of surgical treatment of temporomandibular joint ankylosis: A systematic review and meta-analysis. *Journal of Cranio-Maxillofacial Surgery*, 44(1), pp.6-15.

Dimitroulis, G., 2004. The interpositional dermis-fat graft in the management of temporomandibular joint ankylosis. *International journal of oral and maxillofacial surgery*, *33*(8), pp.755-760.

Dingman, R.O. and Grabb, W.C., 1964. Reconstruction of both mandibular condyles with metatarsal bone grafts. *Plastic and Reconstructive Surgery*, 34(5), pp.441-451.

Dingman, R.O., 1946. Ankylosis of the temporomandibular joint. *American Journal of Orthodontics and Oral Surgery*, 32(2), pp. A120-A125.

Dingman, R.O., 1971. Reconstruction of both mandibular condyles with metatarsal bone grafts. *Plastic and reconstructive surgery*, *47*(6), p.594.

Durr, E.D., Turlington, E.G. and Foote, R.L., 1993. Radiation treatment of heterotopic bone formation in the temporomandibular joint articulation. *International Journal of Radiation Oncology, Biology, Physics*, 27(4), pp.863-869.

Elgazzar, R.F., Abdelhady, A.I., Saad, K.A., Elshaal, M.A., Hussain, M.M., Abdelal, S.E., and Sadakah, A.A., 2010. Treatment modalities of TMJ ankylosis: experience in Delta Nile, Egypt. *International Journal of Oral and Maxillofacial Surgery*, 39(4), pp.333-342.

El-Hakim, I.E. and Metwalli, S.A., 2002. Imaging of temporomandibular joint ankylosis: A new radiographic classification. *Dentomaxillofacial Radiology*, 31(1), pp.19-23.

El-Mofty, S., 1972. Ankylosis of the temporomandibular joint. *Oral Surgery, Oral Medicine, Oral Pathology*, 33(4), pp.650-660.

El-Mofty, S., 1974. Surgical treatment of ankylosis of the temporomandibular joint. *Journal of Oral Surgery*, 32(3), p.202.

El-Sheikh, M.M. and Medra, A.M., 1997. Management of unilateral temporomandibular ankylosis associated with facial asymmetry. *Journal of Cranio-Maxillofacial Surgery*, 25(3), pp.109-115.

El-Sheikh, M.M., 1999. Temporomandibular joint ankylosis: the Egyptian experience. *Annals of the Royal College of Surgeons of England*, 81(1), p.12.

Erdem, E. and Alkan, A., 2001. The use of acrylic marbles for interposition arthroplasty in the treatment of temporomandibular joint ankylosis: follow-up of 47 cases. *International Journal of Oral and Maxillofacial Surgery*, 30(1), pp.32-36.

Ferretti, C., Bryant, R., Becker, P. and Lawrence, C., 2005. Temporomandibular joint morphology following post-traumatic ankylosis in 26 patients. *International journal of oral and maxillofacial surgery*, *34*(4), pp.376-381.

Freedus, M.S., Ziter, W.D. and Doyle, P.K., 1975. Principles of treatment for temporomandibular joint ankylosis. *Journal of Oral Surgery*, 33(10), pp.757-765.

Guilhem, P. and Cadenat, E., 1955. The etiology of the so-called congenital temporo-mandibular joint ankylosis. *Oral Surgery, Oral Medicine, Oral Pathology*, 8(4), pp.449-450.

Gupta, A., Kapoor, D., Awana, M. and Lehl, G., 2015. Fiberscope assisted videolaryngoscope intubation in the surgical treatment of TMJ ankylosis. *Journal of maxillofacial and oral surgery*, *14*(2), pp.484-486.

Güven, O., 2004. Treatment of temporomandibular joint ankylosis by a modified fossa prosthesis. *Journal of Cranio-Maxillofacial Surgery*, 32(4), pp.236-242.

Guyuron, B. and Lasa, J.R, C.I., 1992. Unpredictable growth pattern of costochondral graft. *Plastic and Reconstructive Surgery*, 90(5), pp.880-886.

He, D., Ellis, E. and Zhang, Y., 2008. Etiology of temporomandibular joint ankylosis secondary to condylar fractures: the role of concomitant mandibular fractures. *Journal of Oral and Maxillofacial Surgery*, 66(1), pp.77-84.

Hegtvedt, A.K., 1992. Diagnosis and management of facial asymmetry. *Principles of oral and maxillofacial surgery*, pp.1400-1401.

Henry, C.H. and Wolford, L.M., 1993. Treatment outcomes for temporomandibular joint reconstruction after Proplast-Teflon implant failure. *Journal of oral and maxillofacial surgery*, 51(4), pp.352-358.

Henry, C.H., Hughes, C.V., Gérard, H.C., Hudson, A.P. and Wolford, L.M., 2000. Reactive arthritis: preliminary microbiologic analysis of the human temporomandibular joint. *Journal of Oral and Maxillofacial Surgery*, 58(10), pp.1137-1142.

Holmlund, A., Lund, B. and Weiner, C.K., 2013. Mandibular condylectomy with osteoarthrectomy with and without transfer of the temporalis muscle. *British Journal of Oral and Maxillofacial Surgery*, 51(3), pp.206-210.

Hossain, M.A., Shah, S.A.A. and Biswas, R.S.R., 2014. Frequency of Temporomandibular Joint Ankylosis in Various Age Groups with Reference to Etiology. *Chattagram Maa-O-Shishu Hospital Medical College Journal*, 13(2), pp.17-20.

Huang, I.Y., Lai, S.T., Shen, Y.H. and Worthington, P., 2007. Interpositional Arthrplasty using autogenous costal cartilage graft for temporomandibular joint ankylosis in adults. *International Journal of Oral and Maxillofacial Surgery*, 36(10), pp.909-915.

Kaban, L.B., Perrott, D.H. and Fisher, K., 1990. A protocol for management of temporomandibular joint ankylosis. *Journal of Oral and Maxillofacial Surgery*, 48(11), pp.1145-1151.

Karaca, C., Barutcu, A., Baytekin, C., Yılmaz, M., Menderes, A. and Tan, O., 2004. Modifications of the inverted T-shaped silicone implant for treatment of temporomandibular joint ankylosis. *Journal of Cranio-Maxillofacial Surgery*, 32(4), pp.243-246.

Karthigeyan, R. Sathyanarayanan, R. and Balatandayondam, A., 2012. Management of Temporomandibular joint ankylosis, gap arthroplasty versus interpositional arthrplasty. *Journal of Indian Academy of Dental Specialists*, 3(1), pp.57-61.

Kazanjian, V.H., 1938. Ankylosis of temporomandibular joint. *American Journal of Orthodontic and Oral Surgery*, 24(12), pp.1181-1206.

Kennett, S., 1973. Temporomandibular joint ankylosis: the rationale for grafting in the young patient. *Journal of Oral Surgery*, 31(10), p.744.

Kent, J.N., Misiek, D.J., Akin, R.K., Hinds, E.C. and Homsy, C.A., 1983. Temporomandibular joint condylar prosthesis: a ten-year report. *Journal of Oral and Maxillofacial Surgery*, 41(4), pp.245-254.

Khadka, A. and Hu, J., 2012. Autogenous grafts for condylar reconstruction in treatment of TMJ ankylosis: current concepts and considerations for the future. *International Journal of Oral and Maxillofacial Surgery*, 41(1), pp.94-102.

Khan, Z., Frcs, S. and Fredecs, F., 2005. Management of Temporomandibular joint ankylosis: literature review. *Pakistan Oral and Dental Journal*; 25(2), pp.151-155.

Ko, E.W.C., Huang, C.S. and Chen, Y.R., 1999. Temporomandibular joint reconstruction in children using costochondral grafts. *Journal of Oral and Maxillofacial Surgery*, 57(7), pp.789-798.

Komorowska, A., 1997. Congenital temporomandibular joint ankylosis—a case report. *European Journal of Orthodontics*, 19(3), pp.243-248.

Lakshmi, V. and Pradnya, S., 2001. A review of anaesthetic technique in 15 paediatric patients with temporomandibular joint ankylosis. *Pediatric Anesthesia*, *11*(2), pp.237-244.

Lei, Z., 2002. Auricular cartilage graft interposition after temporomandibular joint ankylosis surgery in children. *Journal of Oral and Maxillofacial Surgery*, 60(9), pp.985-987.

Lello, G.E., 1990. Surgical correction of temporomandibular joint ankylosis. *Journal of Cranio-Maxillofacial Surgery*, 18(1), pp.19-26.

Lindqvist, C., Jokinen, J., Paukku, P. and Tasanen, A., 1988. Adaptation of autogenous costochondral grafts used for temporomandibular joint reconstruction: a long-term clinical and radiologic follow-up. *Journal of Oral and Maxillofacial Surgery*, 46(6), pp.465-470.

Link, J.O., Hoffman, D.C. and Laskin, D.M., 1993. Hyperplasia of a costochondral graft in an adult. *Journal of Oral and Maxillofacial Surgery*, 51(12), pp.1392-1394.

Liu, X., Shen, P., Zhang, S., Yang, C. and Wang, Y., 2015. Effectiveness of different surgical modalities in the management of temporomandibular joint ankylosis: a meta-analysis. *International Journal of Clinical and Experimental Medicine*, 8(11), p.19831.

Ma, J., Liang, L., Jiang, H. and Gu, B., 2015. Gap arthroplasty versus interpositional arthroplasty for temporomandibular joint ankylosis: a meta-analysis. *PloS One*, 10(5), p. e0127652.

Mabongo, M. and Karriem, G., 2014. Temporomandibular Joint Ankylosis: Evaluation of surgical outcomes. *Journal of Dental and Medical Sciences*, 13(8), pp.60-66.

Mabongo, M., 2013. Temporomandibular joint ankylosis in Children. *Journal of Dental and Medical Sciences*, 12*(5)*, pp.35-41.

MacIntosh, R.B. and Henny, F.A., 1977. A spectrum of application of autogenous costochondral grafts. *Journal of Maxillofacial Surgery*, 5*(1)*, pp.257-267.

MacIntosh, R.B., 2000. The use of autogenous tissues for temporomandibular joint reconstruction. *Journal of Oral and Maxillofacial Surgery*, 58(1), pp.63-69.

Mahafza, T., Batarseh, S., Bsoul, N., Massad, E., Qudaisat, I. and Al-Layla, A.E.E., 2012. Early vs. late tracheostomy for the ICU patients: Experience in a referral hospital. *Saudi journal of anaesthesia*, *6*(2), p.152.

Maki, M.H. and Al-Assaf, D.A., 2008. Surgical management of temporomandibular joint ankylosis. *Journal of Craniofacial Surgery*, 19(6), pp.1583-1588.

Malik, N.A., 2002. Ankylosis of temporomandibular joint & its management. *Textbook of Oral and Maxillofacial Surgery. 1st edition. New Delhi: Jaypee Brother Medical Publisher*, pp.202-218.

Manganello-Souza, L.C. and Mariani, P.B., 2003. Temporomandibular joint ankylosis: report of 14 cases. *International Journal of Oral and Maxillofacial Surgery*, 32(1), pp.24-29.

Marx, R.E., 1992. The science and art of reconstructing the jaws and temporomandibular joints. *Modern Practice in Orthognathic and Reconstructive Surgery*, 2, p.1448.

Matsuura, H., Miyamoto, H., Ogi, N., Kurita, K. and Goss, A.N., 2001. The effect of GA on temporomandibular joint ankylosis: an experimental study. *International Journal of Oral and Maxillofacial Surgery*, 30(5), pp.431-437.

Matukas, V.J., Szymela, V.F. and Schmidt, J.F., 1980. Surgical treatment of bony ankylosis in a child using a composite cartilage-bone iliac crest graft. *Journal of oral surgery American Dental Association*, *38*(12), pp.903-905.

Mehrotra, D., Kumar, S. and Dhasmana, S., 2012. Hydroxyapatite/collagen block with platelet rich plasma in temporomandibular joint ankylosis: a pilot study in children and adolescents. *British Journal of Oral and Maxillofacial Surgery*, *50*(8), pp.774-778.

Mehrotra, D., Vishwakarma, K., Chellapa, A.L. and Mahajan, N., 2016. Pre-arthroplasty simultaneous maxillomandibular distraction osteogenesis for the correction of post-ankylotic dentofacial deformities. *International Journal of Oral and Maxillofacial Surgery*, 45(7), pp.820-827.

Menon, S. and Sinha, R., 2008. Gap arthroplasty for mandibular condyle dislocation and impaction into the middle cranial fossa. *Journal of Oral and Maxillofacial Surgery*, 66(11), pp.2390-2393.

Mercuri, L.G., 1998. Alloplastic temporomandibular joint reconstruction. *Oral Surgery, Oral Medicine, Oral Pathology, Oral Radiology, and Endodontology*, 85(6), pp.631-637.

Mercuri, L.G., 2000. The use of alloplastic prostheses for temporomandibular joint reconstruction. *Journal of Oral and Maxillofacial Surgery*, 58(1), pp.70-75.

Mercuri, L.G., Ali, F.A. and Woolson, R., 2008. Outcomes of total alloplastic replacement with periarticular autogenous fat grafting for management of reankylosis of the temporomandibular joint. *Journal of Oral and Maxillofacial Surgery*, 66(9), pp.1794-1803.

Mercuri, L.G., Edibam, N.R. and Giobbie-Hurder, A., 2007. Fourteen-year follow-up of a patient-fitted total temporomandibular joint reconstruction system. *Journal of Oral and Maxillofacial Surgery*, 65(6), pp.1140-1148.

Mercuri, L.G., Wolford, L.M., Sanders, B., White, R.D., Hurder, A. and Henderson, W., 1995. Custom CAD/CAM total temporomandibular joint reconstruction system: preliminary multicenter report. *Journal of Oral and Maxillofacial Surgery*, 53(2), pp.106-115.

Mercuri, L.G., 2012. Alloplastic temporomandibular joint replacement: rationale for the use of custom devices. *International journal of oral and maxillofacial surgery*, *41*(9), pp.1033-1040.

Mercuri, L.G. and Anspach Iii, W.E., 2003. Principles for the revision of total alloplastic TMJ prostheses. *International journal of oral and maxillofacial surgery*, *32*(4), pp.353-359.

Meredith, A., Troulis, M.J. and Kaban, L.B., 2004. Hypomobility and hypermobility disorders of the temporomandibular joint. In *Peterson's Principles of Oral and Maxillofacial Surgery*, pp.1033-1047. BC Decker, London.

Miller, G.A., Page, J.R, H.L. and Griffith, C.R., 1975. Temporomandibular joint ankylosis: review of the literature and report of two cases of bilateral involvement. *Journal of Oral Surgery*, 33(10), pp.792-803.

Mishra, S., Tripathy, R., Sabhlok, S. and Roy, R., 2012. Management of adult unilateral TMJ ankylosis with temporalis muscle and fascia flap: Review of 51 Cases. *International Journal of Head and Neck Surgery*, 3(3), pp.133-36.

Mitarashi, S., Abe, S., Watanabe, H., Yoshii, M., Hashimoto, M. and Ide, Y., 2002. Temporomandibular joint ankylosis: a case report. *Journal of Cranio-Mandibular Practise*, 20(1), pp.67-71.

Miyamoto, H., Kurita, K., Ishimaru, J.I. and Goss, A.N., 1999. A sheep model for temporomandibular joint ankylosis. *Journal of Oral and Maxillofacial Surgery*, 57(7), pp.812-817.

Mizoguchi, I., Toriya, N. and Nakao, Y., 2013. Growth of the mandible and biological characteristics of the mandibular condylar cartilage. *Japanese Dental Science Review*, 49(4), pp.139-150.

Montalva, F.M., Sosa, F.F., Aguilar, L.O. and Taylor, J.A., 2008. Videofluoroscopic analysis of temporomandibular joint ankylosis. *Journal of Craniofacial Surgery*, *19*(3), pp.726-731.

Moss, M.L. and Rankow, R.M., 1968. The role of the functional matrix in mandibular growth. *The Angle Orthodontist*, 38(2), pp.95-103.

Moss, M.L. and Salentijn, L., 1969. The primary role of functional matrices in facial growth. *American Journal of Orthodontics*, 55(6), pp.566-577.

Munro, I.R., Chen, Y.R. and Park, B.Y., 1986. Simultaneous total correction of temporomandibular ankylosis and facial asymmetry. *Plastic and Reconstructive Surgery*, 77(4), pp.517-527.

Nanda, R., 1970. Maxillomandibular ankylosis and cleft palate in rat embryos. *Journal of dental research*, *49*(5), pp.1086-1090.

Nitzan, D.W., Bar-Ziv, J. and Shteyer, A., 1998. Surgical management of temporomandibular joint ankylosis type III by retaining the displaced condyle and disc. *Journal of Oral and Maxillofacial Surgery*, 56(10), pp.1133-1138.

Nwoku, A.L., 1979. Rehabilitating children with temporomandibular joint ankylosis. *International Journal of Oral Surgery*, 8(4), pp.271-275.

Nwoku, A.L. and Kekere-Ekun, T.A., 1986. Congenital ankylosis of the mandible: Report of a case noted at birth. *Journal of maxillofacial surgery*, *14*, pp.150-152.

Obeid, G., Guttenberg, S.A. and Connole, P.W., 1988. costochondral grafting in condylar replacement and mandibular reconstruction. *Journal of Oral and Maxillofacial Surgery*, 46(3), pp.177-182.

Parkash, H. and Goyal, M., 1992. Myositis ossificans of medial pterygoid muscle: a cause for temporomandibular joint ankylosis. *Oral Surgery, Oral Medicine, Oral Pathology*, 73(1), pp.27-28.

Parker, D.B., 1948. Ankylosis of the temporomandibular joint. *Journal of Oral Surgery*, 6(1), p.42.

Paolino, R.M. and Murphy, J.B., 1987. Surgical correction of longstanding bilateral extracapsular ankylosis of the mandible: Report of a case. *Journal of Oral and Maxillofacial Surgery*, *45*(7), pp.638-641.

Paterson, A.W. and Shepherd, J.P., 1992. Fascia lata interpositional arthroplasty in the treatment of temporomandibular joint ankylosis caused by psoriatic arthritis. *International Journal of Oral and Maxillofacial Surgery*, 21(3), pp.137-139.

Petrovic, A., Stutzmann, J. and Oudet, C., 1981. Condylectomy and mandibular growth in young rats. A quantitative study. *Proceedings of the Finnish Dental Society. Suomen Hammaslaakariseuran toimituksia*, *77*(1-3), pp.139-150.

Pogrel, M.A. and Kaban, L.B., 1990. The role of a temporalis fascia and muscle flap in temporomandibular joint surgery. *Journal of oral and maxillofacial surgery*, *48*(1), pp.14-19.

Posnick, J.C. and Goldstein, J.A., 1993. Surgical management of temporomandibular joint ankylosis in the pediatric population. *Plastic and Reconstructive Surgery*, 91(5), pp.791-798.

Poswillo, D.E., 1987. Biological reconstruction of the mandibular condyle. *British Journal of Oral and Maxillofacial Surgery*, 25(2), pp.100-104.

Poswillo, D.E., 1987. Biological reconstruction of the mandibular condyle. *British Journal of Oral and Maxillofacial Surgery*, *25*(2), pp.100-104.

Prakasam, M., Managutti, A. and Jain, N., 2012. Brisement force for the fibrous ankylosis: An obsolete technique revisited. *Clinical Dentistry*, *6*(5), p.14.

Qudah, M.A., Qudeimat, M.A. and Al-Maaita, J., 2005. Treatment of TMJ ankylosis in Jordanian children–a comparison of two surgical techniques. *Journal of Cranio-Maxillofacial Surgery*, 33(1), pp.30-36.

Rajgopal, A., Banerji, P.K., Batura, V. and Sural, A., 1983. Temporomandibular ankylosis: A report of 15 cases. *Journal of Maxillofacial Surgery*, 11(1), pp.37-41.

Ramezanian, M. and Yavary, T., 2006. Comparion of gap arthroplasty and interpositional arthroplasty on the temporomandibular joint. *Acta Medica Iranica*, 44(6), pp.391-394.

Raveh, J., Vuillemin, T., Lädrach, K. and Sutter, F., 1989. Temporomandibular joint ankylosis: surgical treatment and long-term results. *Journal of Oral and Maxillofacial Surgery*, 47(9), pp.900-906.

Reza, M. and Mercuri, L.G., 2015. Management of temporomandibular joint ankylosis. *Oral and Maxillofacial Surgery Clinics*, 27(1), pp.27-35.

Risdon, F., 1934. Ankylosis of the Temporo maxillary Joint. *The Journal of the American Dental Association*, 21(11), pp.1933-1937.

Rowe, N.L., 1982. Ankylosis of the temporomandibular joint. *Journal of the Royal College of Surgeons of Edinburgh*, 27(2), pp.67-79.

Roychoudhury, A., Parkash, H. and Trikha, A., 1999. Functional restoration by gap arthroplasty in temporomandibular joint ankylosis: a report of 50 cases. *Oral Surgery, Oral Medicine, Oral Pathology, Oral Radiology, and Endodontology*, 87(2), pp.166-169.

Ruddlesdin, G. Ansell, B.M, Ardem, G.P. and Swann, M., 1986. Total hip replacement in children with juvenile chronic arthritis. *British Editorial Society of Bone and Joint Surgery*, 68 (2), pp.218-22.

Sada, V.M., 1968. A technique for treatment of TMJ ankylosis. *Transaction of Third International Conference on Oral Surgery London*: E and S Livingstone.

Saeed, N.R., McLeod, N.M.H. and Hensher, R., 2001. Temporomandibular joint replacement in rheumatoid-induced disease. *British Journal of Oral and Maxillofacial Surgery*, *39*(1), pp.71-75.

Saeed, N.R. and Kent, J.N., 2003. A retrospective study of the costochondral graft in TMJ reconstruction. *International Journal of Oral and Maxillofacial Surgery*, 32(6), pp.606-609.

Saeed, N.R., Hensher, R., McLeod, N.M.H. and Kent, J.N., 2002. Reconstruction of the temporomandibular joint autogenous compared with alloplastic. *British Journal of Oral and Maxillofacial Surgery*, 40(4), pp.296-299.

Salleh, N.B.M., 1965. Congenital partial fusion of the mandible and maxilla: report of a case. *Oral Surgery, Oral Medicine, Oral Pathology*, *20*(1), pp.74-76.

Salins, P.C., 2000. New perspectives in the management of cranio-mandibular ankylosis. *International Journal of Oral and Maxillofacial Surgery*, 29(5), pp.337-340.

Samman, N., Shen, G.F., Cheung, L.K., Tong, A.C.K. and Tideman, H., 1994. Scintigraphic correlations with age, sex and radiographic measurements in mandibular asymmetry.

Sanders, B., 1975. Temporomandibular joint ankylosis secondary to Marie-Strümpell disease. *Journal of Oral Surgery*, 33(10), pp.784-786.

Sanches, A.F., 1995, Retrograde intubation. Diffcult intubation, *Anesthesiology Clinics of North America*, 13, pp.427-447.

Sarma, U.C. and Dave, P.K., 1991. Temporamandibular joint ankylosis: An Indian experience. *Oral Surgery, Oral Medicine, Oral Pathology*, 72(6), pp.660-664.

Sawhney, C.P., 1986. Bony ankylosis of the temporomandibular joint: follow-up of 70 patients treated with arthroplasty and acrylic spacer interposition. *Plastic and Reconstructive Surgery*, 77(1), p.29.

Shaikh, S.K., Mishra, M., Tiwari, A.K., Chander, M., Gaur, A. and Singh, H., 2013. Comparative evaluation of gap arthroplasty and interpositional arthroplasty using temporalis fascia in the management of temporomandibular joint ankylosis. *Journal of Orofacial Research*, 3(3), p.170.

Shetty, P., Thomas, A. and Sowmya, B., 2014. Diagnosis of temporomandibular joint (TMJ) ankylosis in children. *Journal of Indian Society of Pedodontics and Preventive Dentistry*, 32(3), p.266.

Shirani, G., Mohammadi, F., Arshad, M. and Shirazi, M., 2014. Temporomandibular joint ankylosis: Case-series of two different surgical procedures. *Dental Hypotheses*, *5*(3), p.103.

Sidebottom, A.J. and Salha, R., 2013. Management of the temporomandibular joint in rheumatoid disorders. *British Journal of Oral and Maxillofacial Surgery*, 51(3), pp.191-198.

Silagi, J.L. and Schow Jr, C.E., 1970. Temporomandibular joint arthroplasty: review of literature and report of case. *Journal of Oral Surgery*, 28(12), p.920.

Smith, J.A., Sandler, N.A., Ozaki, W.H. and Braun, T.W., 1999. Subjective and objective assessment of the temporalis myofascial flap in previously operated temporomandibular joints. *Journal of Oral and Maxillofacial Surgery*, 57(9), pp.1058-1065.

Souchere, B., Paulus, C.H., Duclos, P., Breton, P. and Freidel, M., 1994. Articulation temporomandibularie. Revue De Stomatologie De Chirurgie Maxillo-Faciale, (95),pp.156-160.

Spijkervet, F.K., de Bont, L.G. and Boering, G., 1994. Management of pseudoankylosis of the temporomandibular joint: report of cases. *Journal of Oral and Maxillofacial Surgery*, 52(11), pp.1211-1217.

Straith, C.L. and Lewis, J.R., 1948. Ankylosis of the temporo-mandibular joint. *Plastic and Reconstructive Surgery*, 3(4), pp.464-477.

Stucki-McCormick, S.U., Winick, R. and Winick, A., 1998. Distraction osteogenesis for the reconstruction of the temporomandibular joint. *The New York state Dental Journal*, 64(3), pp.36-41.

Su-Gwan, K., 2001. Treatment of temporomandibular joint ankylosis with temporalis muscle and fascia flap. *International Journal of Oral and Maxillofacial Surgery*, 30(3), pp.189-193.

Tauras, S.P., Jordan, J.E. and Keen, R.R., 1972. Temporomandibular joint ankylosis corrected with a gold prosthesis. *Journal of Oral Surgery*, 30(10), pp.767-773.

Temerek, A.T., 2016. Conservative gap arthroplasty in temporomandibular ankylosis not involving the sigmoid notch: a selected age group study. *British Journal of Oral and Maxillofacial Surgery*, 54(5), pp.38-43.

Thoma, K.H., Howe, H.D. and Wenig, M., 1945. Ankylosis of the Jaw. *American Journal of Orthodontics and Oral Surgery*, 31(4), pp.244-248.

Tideman, H. and Doddridge, M., 1987. Temporomandibular joint ankylosis. *Australian Dental Journal*, 32(3), pp.171-177.

Tippu, S.R. and Rahman, F., 2011. Heterotopic calcification: A cause for zygomatico-coronoid ankylosis. *Biomedical Research*, *22*(2).

Topazian, R.G., 1964. Etiology of ankylosis of temporomandibular joint: Ankylosis of 44 cases. *Journal of Oral Surgery, Anesthesia, and Hospital Dental Service*, 22(1), pp.227-233.

Topazian, R.G., 1966. Comparison of gap and interposition arthroplasty in the treatment of temporomandibular joint ankylosis. *Journal of Oral Surgery*, 24(5), p.405.

Topazian, R.G., 2001. Gap arthroplasty versus Interpositional arthroplasty for ankylosis of Temporomandibular joint. *Oral Surgery Oral Medicine Oral Pathology Oral Radiology Endodontology*, 91(4), pp.388-389.

Valentini, V., Vetrano, S., Agrillo, A., Torroni, A., Fabiani, F. and Iannetti, G., 2002. Surgical treatment of TMJ ankylosis: our experience (60 cases). *Journal of Craniofacial Surgery*, 13(1), pp.59-67.

Vanhove, F. and Dom, M., 1999. Zygomatico-coronoid ankylosis: a case report. *International Journal of Oral and Maxillofacial Surgery*, 28(4), pp.258-259.

Vasconcelos, B.C., Porto, G.G., Bessa-Nogueira, R.V., Do Nascimento, M. and Marques, M., 2009. Surgical treatment of temporomandibular joint ankylosis: follow-up of 15 cases and literature review. *Medicina Oral, Patologia Oral, Cirugia Bucal*, 14(1), pp. E34-E38.

Voiner, J., Yu, J., Deitrich, P., Chafin, C. and Giannakopoulos, H., 2011. Analysis of mandibular motion following unilateral and bilateral alloplastic TMJ reconstruction. *International Journal of Oral and Maxillofacial Surgery*, 40(6), pp.569-571.

Walker, R.V., 1973. Arthroplasty of the ankylosed temporomandibular joint. *In Transactions of the International Conference on Oral Surgery*, 4, p.279.

Walter, C.G. and Kaban, L.B., 1976. Surgical treatment of mandibular hypomobility. *Journal of oral surgery, 34*(4), pp.343-348.

Ware, W.H. and Brown, S.L., 1981. Growth centre transplantation to replace mandibular condyles. *Journal of Maxillofacial Surgery*, 9(1), pp.50-58.

Ware, W.H. and Taylor, R.C., 1965. Replantation of growing mandibular condyles in rhesus monkeys. *Oral Surgery, Oral Medicine, Oral Pathology*, 19(5), pp.669-677.

Ware, W.H. and Taylor, R.C., 1966. Growth center transplantation to replace damaged mandibular condyles. *The Journal of the American Dental Association*, 73(1), pp.128-137.

Weinberg, S. and Kryshtalskyj, B., 1992. Facial nerve function following temporomandibular joint surgery using the preauricular approach. *Journal of Oral and Maxillofacial Surgery*, 50(10), pp.1048-1051.

White, S.C. and Pharaoh, M.J., 2004. Oral radiology: Principles and Interpretation. 5th edition. *St Louis: Mosby*, pp.581-582.

Wolford, L.M., Cottrell, D.A. and Henry, C.H., 1994. Temporomandibular joint reconstruction of the complex patient with the Techmedica custom-made total joint prosthesis. *Journal of Oral and Maxillofacial Surgery*, 52(1), pp.2-10.

Wolford, L.M. and Karras, S.C., 1997. Autologous fat transplantation around temporomandibular joint total joint prostheses: preliminary treatment outcomes. *Journal of oral and maxillofacial surgery*, *55*(3), pp.245-251.

Wolford, L.M., Mehra, P. and Rea, W., 2000. Metal hypersensitivity in patients with total joint prosthesis. *Journal of Oral and Maxillofacial Surgery*, *58*(1), p.29.

Xiao, E., Zhang, Y., An, J., Li, J. and Yan, Y., 2012. Long-term evaluation of the stability of reconstructed condyles by transport distraction osteogenesis. *International Journal of Oral and Maxillofacial Surgery*, 41(12), pp.1490-1494.

Yan, Y.B., Li, J.M., Xiao, E., An, J.G., Gan, Y.H. and Zhang, Y., 2014. A pilot trial on the molecular pathophysiology of traumatic temporomandibular joint bony ankylosis in a sheep model. Part I: Expression of WNT signaling. *Journal of Cranio-Maxillofacial Surgery*, 42(2), pp.e15-e22.

Ying, Q.V., Bacic, J., Abramowicz, S. and Sonis, A., 2013. Cross sectional: normal maximal incisal opening and associations with physical variables in children. *Pediatric Dentistry*, 35(1), pp.61-66.

YongLong, H., Xiaoming, G., Xinhua, F. and Yilin, W., 2002. Modified coronoid process grafts combined with sagittal split osteotomy for treatment of bilateral temporomandibular joint ankylosis. *Journal of Oral and Maxillofacial Surgery*, 60(1), pp.11-18.

Zhi, K., Ren, W., Zhou, H., Gao, L., Zhao, L., Hou, C. and Zhang, Y., 2009. Management of temporomandibular joint ankylosis: 11 years' clinical experience. *Oral Surgery, Oral Medicine, Oral Pathology, Oral Radiology, and Endodontology*, 108(5), pp.687-692.

APPENDIXES

Appendix I: Ethical Clearance

R14/49 Dr Milad Abdusalam A Milad

HUMAN RESEARCH ETHICS COMMITTEE (MEDICAL)

CLEARANCE CERTIFICATE NO. M170607

NAME: (Principal Investigator)	Dr Milad Abdusalam A Milad
DEPARTMENT:	School of Oral Health Sciences/Maxillo-Facial and Oral Surgery Charlotte Maxeke Johannesburg Academic Hospital
PROJECT TITLE:	A Comparative Study of Outcomes of Two Surgical Procedures Used to Manage Intracapsular Ankylosis of the Temporomandibular Joint
DATE CONSIDERED:	30/06/2017
DECISION:	Approved unconditionally
CONDITIONS:	
SUPERVISOR:	Dr Mzubanzi Mabongo
APPROVED BY:	Professor P Cleaton-Jones, Chairperson, HREC (Medical)
DATE OF APPROVAL:	03/07/2017

This clearance certificate is valid for 5 years from date of approval. Extension may be applied for.

DECLARATION OF INVESTIGATORS

To be completed in duplicate and **ONE COPY** returned to the Research Office Secretary in Room 301, Third Floor, Faculty of Health Sciences, Phillip Tobias Building, 29 Princess of Wales Terrace, Parktown, 2193, University of the Witwatersrand. I/we fully understand the conditions under which I am/we are authorized to carry out the above-mentioned research and I/we undertake to ensure compliance with these conditions. Should any departure be contemplated, from the research protocol as approved, I/we undertake to resubmit the application to the Committee. **I agree to submit a yearly progress report**. The date for annual re-certification will be one year after the date of convened meeting where the study was initially reviewed. In this case, the study was initially reviewed in June and will therefore be due in the month of June each year. Unreported changes to the application may invalidate the clearance given by the HREC (Medical).

Principal Investigator Signature Date

PLEASE QUOTE THE PROTOCOL NUMBER IN ALL ENQUIRIES

Appendix II: Title Approval

UNIVERSITY OF THE
WITWATERSRAND,
JOHANNESBURG

Private Bag 3 Wits, 2050
Fax: 027117172119
Tel: 02711 7172076

Reference: Mrs Sandra Benn
E-mail: sandra.benn@wits.ac.za

14 August 2017
Person No: 1314864
PAG

Dr MA Milad
306 Mostyn Hall 7 Princess Place
Parktown
2001
South Africa

Dear Dr Milad

Master of Science in Dentistry: Approval of Title

We have pleasure in advising that your proposal entitled *A comparative study of outcomes of two surgical procedures used to manage intracapsular ankylosis of the temporomandibular joint* has been approved. Please note that any amendments to this title have to be endorsed by the Faculty's higher degrees committee and formally approved.

Yours sincerely

Mrs Sandra Benn
Faculty Registrar
Faculty of Health Sciences

Appendix III: Permission from CEO of Wits Oral Health Centre

GAUTENG PROVINCE
HEALTH
REPUBLIC OF SOUTH AFRICA

WITS ORAL HEALTH CENTRE

Private Bag X15 Braamfontein, Johannesburg, 2017
Enquiries: Ms Tumelo Marule
Tel: (011)488-4893, Fax 086 406 3196
E-mail: Tumelo.Marule@wits.ac.za

26 April 2017

Dr M Milad
MSc Dent Student
Maxillo-Facial and Oral Surgery
Faculty of Health Sciences
University of the Witwatersrand
Johannesburg

REGARDING: REQUEST FOR PERMISSION TO ACCESS THE WITS ORAL HEALTH CENTRE PATIENT RECORDS FOR MY POSTGRADUATE RESEARCH

REFERENCE :HRRC/APR/03/2017

It is my pleasure to grant final approval to utilize resources at Wits Oral Health Centre in order to conduct your research.
The Hospital Research and Risk Committee allocated a unique reference number to this application – Kindly quote this reference number in all future correspondence regarding this research.

Please note that the Hospital Research and Risk Committee should be informed of the estimated date the research will commence, as well as regular status reports until the research has been concluded. Within a month after conclusion of the research project, a written report must be submitted to the Head of School/CEO, summarizing the final result/outcome as well as the recommendations made based on the research concluded.

Regards,

Prof MS Nemutandani 26/04/17
CEO/Head of School

Appendix IV: Permission from CEO of CMJAH

GAUTENG PROVINCE
HEALTH
REPUBLIC OF SOUTH AFRICA

CHARLOTTE MAXEKE JOHANNESBURG ACADEMIC HOSPITAL (CMJAH)
OFFICE OF THE CEO

Enquiries: Mr. J. Maepa
Tell: 011 488 3365 Fax: 011 488 3753
Email: Johannes.Maepa@gauteng.gov.za
DATE: 12th July 2017

Dr. Milad Abdusalam
MScDent Student
Department of Maxillo-Facial and Oral Surgery
School of Oral Health Science

Dear Dr. Milad

RE: A Comparative study of Outcomes of Two Surgical Procedures Used to Manage Intracapsular Ankylosis of the Temporomandibular Joint.

Permission is hereby granted for you to access the requested patient files from patient records. The files should not be removed from patient affairs offices.

You will be given space to sit and review the files there.

Please produce this letter and give to Mr. Molefe. He can be contacted at 011 488 3862.

Regards

DR. M. MOFOKENG
CLINICAL DIRECTOR.
DATE:

Cc: Mrs. M. Bodibe
Director Finance

Mr. J. Molefe
Assistant Director: Patient Affairs

Appendix V: Data Capture Sheet

Patient No	Age	Gender	Aetiology	Side	Type	SRx	Pre MIO (mm)	I-p MIO (mm)	Pp-MIO (mm)	F-outcome (mm)	F/up	Complication

SRx = Type of surgical treatment (GP=GA / CCG= CCG)

Pre- MIO = Preoperative maximum interincisal opening

IA- MIO = Intraoperative maximum interincisal opening

Pp -MIO = Postoperative maximum interincisal opening

F-outcome = Final outcome at last visit

F/up = follow- up.

Appendix VI: Plagiarism Report

1314864:Dr_Milad_-_thesis_changes_accepted.docx

by Milad Milad

Submission date: 04-Jun-2018 01:50PM (UTC+0200)
Submission ID: 930763477
File name: 6-4dfe-b4c3-015a238f2758_Dr_Milad_-_thesis_changes_accepted.docx (2.21M)
Word count: 19987
Character count: 112514

1314864:Dr_Milad_-_thesis_changes_accepted.docx

ORIGINALITY REPORT

5%	3%	3%	1%
SIMILARITY INDEX	INTERNET SOURCES	PUBLICATIONS	STUDENT PAPERS

PRIMARY SOURCES

1	www.iosrjournals.org Internet Source	2%
2	De Roo, Noëmi, Luc Van Doorne, Aline Troch, Hubert Vermeersch, and Nele Brusselaers. "Quantifying the outcome of surgical treatment of temporomandibular joint ankylosis: A systematic review and meta-analysis", Journal of Cranio-Maxillofacial Surgery, 2016. Publication	1%
3	"42 Annual Congress of AOMSI Nagpur 16–18 Nov 2017", Journal of Maxillofacial and Oral Surgery, 2017 Publication	1%
4	Mohammad Bayat. "Treatment of temporomandibular joint ankylosis: gap and interpositional arthroplasty with temporalis muscle flap", Oral and Maxillofacial Surgery, 10/06/2009 Publication	1%
5	Submitted to University of Witwatersrand Student Paper	

1%

Exclude quotes	On	Exclude matches	< 1%
Exclude bibliography	On		