

https://dspace.org/

The occurrence of sarcocystis (protozoa: coccida) in wild Southern African birds

Kaiser, Ingrid Anne

2015-04-22
http://hdl.handle.net/10539/17507

Downloaded from a DSpace repository. https://dspace.org/

THE OCCURRENCE OF SARCOCYSTIS [illegible] IN WILD SOUTHERN AFRICAN BIRDS

I.A. KAISER

THE OCCURRENCE OF *SARCOCYSTIS* (PROTOZOA : COCCIDIA) IN WILD SOUTHERN AFRICAN BIRDS

Ingrid Anne Kaiser

A dissertation submitted to the Faculty of Science,
University of the Witwatersrand, Johannesburg,
in fulfilment of the requirements
for the degree of Master of Science

Johannesburg 1983

THE OCCURRENCE OF *SARCOCYSTIS* (PROTOZOA : COCCIDIA) IN WILD SOUTHERN AFRICAN BIRDS

Ingrid Anne Kaiser

A dissertation submitted to the Faculty of Science,
University of the Witwatersrand, Johannesburg,
in fulfilment of the requirements
for the degree of Master of Science

Johannesburg 1983

ABSTRACT

THE OCCURRENCE OF SARCOCYSTIS (PROTOZOA : COCCIDIA) IN WILD SOUTHERN AFRICAN BIRDS

KAISER, Ingrid Anne: M.Sc., University of the Witwatersrand, 1983.

Little is known about host specificity of avian Sarcocystis species; and nothing was previously known about the prevalence of the parasite in African birds.

Skeletal muscle from 1512 individuals of 280 species (representing 64 families) was examined histologically. Sarcocystis was found in 40 individuals of 25 species (representing 20 avian families). Cardiac muscle from a number of the infected birds was subsequently screened, but in no case was the parasite detected in the heart as well.

At least seven different species of Sarcocystis could be distinguished by means of electron microscopy. The ultrastructural findings indicate, therefore, that a number of avian Sarcocystis species have evolved. Morphologically similar cysts of a particular type occurred in unrelated hosts. Thus, evidence that species of avian Sarcocystis may have a loose host specificity, is provided.

It was found, furthermore, that freezing and prolonged fixation did not affect the gross morphology of the cyst wall.

DECLARATION

I declare that this dissertation is my own, unaided work. It is being submitted for the degree of Master of Science in the University of the Witwatersrand, Johannesburg. It has not been submitted before for any degree or examination in any other university.

Gilmour

23 day of December, 1983.

ACKNOWLEDGEMENTS

I thank my supervisor, Prof. M.B. Markus, for all the help given and the interest shown in this study.

I am grateful to the following people (and organizations) for donating and, in some cases, identifying material:-
Dr F.W. Huchzermeyer; Dr H.C. Biggs; Dr J.C. Dobbs; Dr J.H. Oosthuizen; Dr P.C. Benson; Dr P.J. Mundy; Mark Longridge; Prof. M.B. Markus; Richard and Chris Watson; Stuart Halse; Willem Ferguson; Barberspan Ornithological Research Station (in particular, Mr H.K. Morgan); Bird Section of the Transvaal Museum, Pretoria; and the S.P.C.A. Bird Hospital, Johannesburg.

I am also grateful to Joseph Daly for assistance with techniques, and to Walli Maier for the photographs.

My thanks to Hilary Kaiser and Malcolm Keeping for proof-reading this project; and to Irma and Ian Lowe for assistance with the typing of the thesis, and the use of their computer for this purpose.

This research was supported by the South African Council for Scientific and Industrial Research and the University of the Witwatersrand.

ACKNOWLEDGEMENTS

I thank my supervisor, Prof. M.B. Markus, for all the help given and the interest shown in this study.

I am grateful to the following people (and organizations) for donating and, in some cases, identifying material:-
Dr F.W. Huchzermeyer; Dr H.C. Biggs; Dr J.C. Dobbs; Dr J.H. Oosthuizen; Dr P.C. Benson; Dr P.J. Mundy; Mark Longridge; Prof. M.B. Markus; Richard and Chris Watson; Stuart Halse; Willem Ferguson; Barberspan Ornithological Research Station (in particular, Mr H.K. Morgan); Bird Section of the Transvaal Museum, Pretoria; and the S.P.C.A. Bird Hospital, Johannesburg.

I am also grateful to Joseph Daly for assistance with techniques, and to Walli Maier for the photographs.

My thanks to Hilary Kaiser and Malcolm Keeping for proof-reading this project; and to Irma and Ian Lowe for assistance with the typing of the thesis, and the use of their computer for this purpose.

This research was supported by the South African Council for Scientific and Industrial Research and the University of the Witwatersrand.

ABBREVIATIONS USED FOR ELECTRON MICROGRAPHS

A - polysaccharide granules (amylopectin)

C - conoid

CW - cyst wall

F - fibrillar elements

GS - ground substance

HC - host cell

LM - limiting membrane

M - cystozoic merozoite

MI - mitochondrion

MN - micronemes

N - nucleus

OL - osmiophilic layer of primary cyst wall

PA - parasite

PR - cyst wall protrusions

S - septum

VE - vesicle

X - curved bases of fibrillar elements

CONTENTS

	Page
ABSTRACT	ii
DECLARATION	iv
ACKNOWLEDGEMENTS	v
ABBREVIATIONS USED FOR ELECTRON MICROGRAPHS	vi
LIST OF TABLES	ix
LIST OF FIGURES	x
INTRODUCTION	1
HISTORICAL REVIEW	5
MATERIALS AND METHODS	22
RESULTS	
Prevalence of *Sarcocystis* infection	25
Site specificity	43
Electron microscopy	44
Effects of freezing and prolonged fixation	51
Pathogenicity	52
DISCUSSION	74
Source of infection	75
Predatory intermediate hosts	78
Site specificity	79
Final hosts	81
Electron microscopy	82
Number of avian *Sarcocystis* species	86
Host specificity	86
Effects of freezing and prolonged fixation on cyst wall ultrastructure	88

Page

Pathogenicity

Acute infection..... 89

Chronic infection..... 89

APPENDIXES

I. Specific names of non-southern African hosts of Sarcocystis mentioned in the text..... 92

II. Common and scientific names of southern African birds mentioned in the text..... 94

III. Fixation and processing of tissue for light microscopy..... 109

IV. Staining of sections for light microscopy... 110

V. Fixation and processing of tissue for electron microscopy..... 112

VI. Staining of sections for electron microscopy..... 114

REFERENCES..... 115

LIST OF TABLES

Page

1. Species or birds examined microscopically for *Sarcocystis* infection..... 26

2. Summary of species of birds found to have *Sarcocystis* infections..... 40

3. Waterfowl examined macroscopically (but not microscopically) for obvious macroscopic sarcocysts..... 42

4. Site specificity of *Sarcocystis* in some infected birds..... 43

5. Measurements of cysts and cystozoic merozoites which were examined by electron microscopy..... 46

LIST OF FIGURES

Page

1. Life-cycle of *Sarcocystis*..... 2

2-7. *Sarcocystis* from a whiterumped swift *Apus caffer*..... 53

8-11. Ultrastructural details of *Sarcocystis* of a night heron *Nycticorax nycticorax*..... 54

12-15. *Sarcocystis* sp. from a little egret *Egretta garzetta*..... 55

16-21. *Sarcocystis* from a Natal robin *Cossypha natalensis*..... 56

22-25. Ultrastructure of *Sarcocystis* of the spotted dikkop *Burhinus capensis*..... 57

26-29. *Sarcocystis* in the lilacbreasted roller *Coracias caudata*..... 58

30-35. *Sarcocystis* in the yellowbilled hornbill *Tockus flavirostris*..... 59

36-39. Sections through the periphery of a cyst in skeletal muscle of a redbilled hornbill *Tockus erythrorhynchus*..... 60

40-43. Sarcocyst in the laughing dove *Streptopelia senegalensis*..... 61

Page

44-49.Sections through a sarcocyst of a purple gallinule Porphyrio porphyrio..... 62

50-55.Sarcocystis from a cattle egret Bubulcus ibis..... 63

56-61.Sections through a sarcocyst of Swainson's francolin Francolinus swainsonii..... 64

62-65.Sections through a sarcocyst of Swainson's francolin Francolinus swainsonii..... 65

66-67.Macroscopic cysts in the skeletal muscle of a redbilled teal Anas erythrorhyncha..... 66

68-71.Ultrastructural details of Sarcocystis of a redbilled teal Anas erythrorhyncha..... 67

72-75.Electron micrographs of Sarcocystis in the Cape glossy starling Lamprotornis nitens..... 68

76-79.Sections through the periphery of Sarcocystis from Burchell's glossy starling Lamprotornis australis..... 69

80-83.Sarcocystis from a yellowbilled egret Egretta intermedia..... 70

84-87.Sarcocystis from a subantarctic skua Catharacta antarctica..... 71

Page

88. Section through an elongated nodule located in the skeletal muscle of an immature speckled mousebird Colius striatus..... 72

89. Section through skeletal muscle of a juvenile masked weaver Ploceus velatus..... 73

INTRODUCTION

The protozoan organism Sarcocystis is a coccidian parasite belonging to the Phylum Apicomplexa (Levine et al., 1980). For basic information concerning the Coccidia, the reader is referred to Long (1982). Species of Sarcocystis typically occur intracellularly in the skeletal and/or cardiac musculature of vertebrates and have an intestinal phase in meat-eating animals or man.

The life-cycle of Sarcocystis was elucidated only recently (Markus, 1978). It is now known to involve two vertebrate hosts which have become evolutionarily adapted to the predator-prey relationship existing between them (Figure 1). The cysts in muscle (A), containing cystozoic merozoites (B), are ingested by the predator. Macrogametocytes and microgametocytes usually develop at the base of the intestinal epithelium. Fertilisation of the macrogametes results in development of oocysts containing two sporocysts, each having four sporozoites after the oocysts have sporulated. Oocysts and sporocysts are shed in the faeces (D). If the intermediate host swallows a sporocyst, at least two generations of schizogony take place (E), primarily in the vascular endothelium,

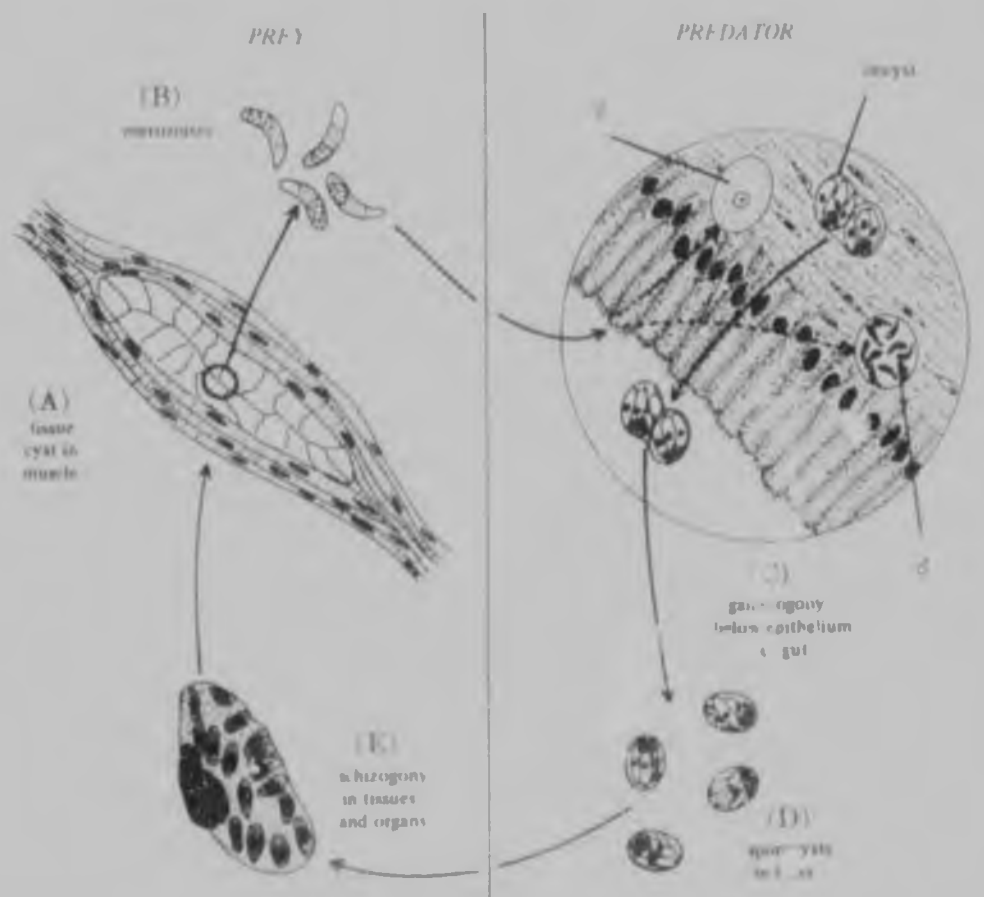

FIGURE 1. Life-cycle of Sarcocystis. Tissue cysts (A) containing merozoites (B) are ingested by the predator. These merozoites grow directly to sexual stages (C) in the intestine of the predator (the parasites in diagram C have been enlarged in relation to the epithelial cells). Oocysts sporulate in situ in the subepithelial tissue and are released into the lumen of the gut; forms in the faeces are mainly free sporocysts (D), which have broken out of the fragile oocysts. When ingested by the prey, the sporozoites from sporocysts initiate cycles of asexual multiplication (E) in reticulo-endothelial cells in most tissues. Merozoites from schizonts give rise to the cysts in muscle. (Different stages not drawn to scale). (After Markus et al., 1974; reproduced by permission from the Journal of Tropical Medicine and Hygiene.) From Markus (1978).

before invasion of muscle cells occurs.

The sarcocysts are limited by a primary cyst wall which consists of a unit membrane and underlying osmiophilic material (Mehlhorn et al., 1976). A layer of amorphous ground substance is present beneath the primary cyst wall. Septa, which divide the cyst into compartments, are formed in many species when the ground substance traverses the interior of the cyst. Each species of Sarcocystis possesses a characteristic primary cyst wall. Species of Sarcocystis which are indistinguishable at the light microscope level can differ in terms of their fine structure; electron microscopic study of cysts is often required to distinguish between the different types of cyst wall.

Sarcocystis is worthy of study not only because it is of basic protozoological interest, but also because it has recently been shown to cause previously unrecognised disease in domestic animals and in man (Markus, 1978). There is little published information on the prevalence and host specificity of this parasite in birds. Nothing was previously known about the occurrence of Sarcocystis in African birds.

The aims of the present study were primarily to determine:-

1). the prevalence of Sarcocystis infection in a

sample of African birds.

2). whether Sarcocystis also occurs extra-intestinally in predatory African birds (which are final hosts of Sarcocystis).

3). the diversity or otherwise of species of Sarcocystis which infect birds.

4). the degree of host specificity (as far as can be judged by cyst wall types).

5). the site specificity of Sarcocystis in birds.

6). obvious deleterious effects (if any) which avian Sarcocystis species may have on their hosts.

7). the effects of deep-freezing and prolonged fixation on cyst wall morphology.

The purpose of this preliminary report is to consider the points listed in the previous paragraph (and not to describe in detail the fine structure of cysts and their contents).

HISTORICAL REVIEW

Included in this review are summaries of the more important publications on avian Sarcocystis which have appeared since the life-cycle of the organism was eluidated; and summaries of those papers which are considered to be relevant, for one reason or another, to the present study. Additional relevant papers are referred to in the discussion.

Sarcocystis was recorded in an African bird for the first time by Fantham (1913), who found it in the *redfaced mousebird Colius indicus. The sarcocysts were macroscopically visible as elongate, white, opaque streaks in the muscles. The most heavily parasitised region of the body was the pectoral area, and cardiac muscle also contained sarcocysts. In section, the cysts were seen to be chambered. In view of the polymorphism and small size of the merozoites, the apparent absence of marked metachromatic granules and the presence of a definite polar vesicle, Fantham (1913) decided to give the parasite the new specific name Sarcocystis colii.

---

* The modern practice of omitting hyphens in common names of birds has been followed (Southern African Ornithological Society List Committee, 1980).

Sarcocystis was reported in a predatory bird by Darling (1915), who saw microscopic cysts in the skeletal and heart muscle fibres of a **hawk Leucopternis sp. The cyst was divided into compartments by septa and its wall was 6µm thick.

Levine et al. (1970) described Sarcocystis-like cysts in the skeletal and heart muscle of domestic chickens Gallus gallus. Infected birds developed diarrhoea and a peculiar gait, and several of them died. The cysts were not considered by these authors to belong to the genus Sarcocystis because: (1) the cysts had a single-layered wall which lacked cytophaneres; (2) septa divided the cysts into compartments; (3) the merozoites were rounded rather than elongate; and (4) extensive tissue damage was associated with cysts. Cysts of Arthrocystis galli n. gen., n. sp. (Levine et al., 1970) are one millimetre or more in length, with one to four or more compartments; the latter contain spherical merozoites about 1µm in diameter. The validity or otherwise of the genus Arthrocystis has not been considered in this dissertation.

Fayer (1970) observed the development of Sarcocystis sp. from wild grackles Quiscalus quiscula in avian and mammalian cell cultures. "Multinucleate" and "cyst-

---

** Both the common and scientific names of non-southern African birds and mammals are given in Appendix I.

like" stages were formed.

Fayer and Kocan (1971) found a high prevalence of Sarcocystis in wild grackles in Maryland in the United States of America. Adult female grackles were more often infected with Sarcocystis than were adult males, but the number of cysts per bird was greater in males than in females. In both males and females the leg and thigh muscles contained more cysts than the pectoral muscles. Neither heart nor tongue muscle was infected.

Merozoites from sarcocysts in the leg and thigh muscles of wild grackles were inoculated into cultured embryonic bovine kidney cells (Fayer, 1972). Thirty hours after inoculation, mature microgametes and macrogametes were observed. Cyst-like forms were found after 42 hours.

A raptor-passerine cycle for Sarcocystis was suggested by the results of Ashford (1975). Sporocysts resembling those of Isospora buteonis Henry, 1932, obtained from faeces collected below the nest of a European sparrowhawk Accipiter nisus, infected one of two canaries Serinus canarius.

Dabbling ducks were found to contain macroscopic cysts of Sarcocystis, whereas no diving ducks were infected (Hoppe, 1976). This may be explained by the fact that dabbling ducks feeding in shallower wetlands are more

likely to ingest faecal material of other animals than are divers. No significant difference in the number of cysts present was found between the sexes, and the lower numbers of cysts in juvenile dabbling ducks was possibly attributable to the time needed for the maturation of the cysts.

Mehlhorn et al. (1976) used electron microscopy to show the structure of the cyst wall of 13 Sarcocystis species, including those from a domestic fowl and a wild grackle. The macroscopic cysts in the domestic fowl contained fibrillar elements which extended into palisade-like protrusions of the cyst wall. Invaginations were found on and between the protrusions and septa from the ground substance compartmentalised the cyst. The sarcocysts from the grackle were also macroscopic, and the primary cyst wall was folded into wave-like protrusions into which bundles of microtubules extended. There were invaginations of the surfaces of the protrusions and septa were present in the cysts. The study showed that the parasite (as opposed to the host) determines the structure of the cyst wall, but that the primary wall morphology cannot be used exclusively as a criterion for species identification; this is because a similar type of primary wall can be present in several different Sarcocystis species, particularly those having thin-walled cysts. Transmission experiments would be

required in order to differentiate between these species.

Free-ranging chickens in Papua New Guinea were found to have a 4[illegible] per cent overall frequency of infection with *Sarcocystis* (Munday *et al.*, 1977). The body weight and body condition of the infected birds were not noticeably different [illegible] those of the uninfected birds. Clinically, however, infected birds showed signs of muscular weakness. In these cases, a granulomatous type of myositis was seen histologically, together with numerous sarcocysts in the muscle; cysts were not found in the myocardium. A dog-fowl life-cycle seems possible since sporocysts were detected in the faeces of a dog *Canis familiaris* which was fed infected chicken. However, attempts to produce experimental infections in chickens were not successful. The authors suggested that the sporocyst inoculum used may have been too small.

Tim and Duszynski (1977) surveyed the occurrence of *Sarcocystis* in adult brownheaded cowbirds *Molothrus ater* by comparing three different methods for detection of sarcocysts. Macroscopically negative birds were shown to be positive using two techniques other than macroscopic examination of muscle, with pepsin digestion being more sensitive than microscopic examination of abdominal muscle. Sarcocysts were most common in the upper and lower leg and back muscles. No

cysts were seen in cardiac muscle.

Duszynski and Box (1978) showed that the opossum Didelphis virginiana was a good definitive host for Sarcocystis of three species of icterid birds. Their results also indicated that the opossum was a possible final host for one species of duck Sarcocystis. Cats Felis domesticus, rats Rattus norvegicus and a dog failed to act as final hosts for the last-mentioned species of Sarcocystis.

Box and Duszynski (1978) have shown that Sarcocystis is not necessarily host specific, as had previously been thought. The authors obtained sporocysts by feeding opossums muscle cysts from infected brownheaded cowbirds and great-tailed grackles Cuiscalus mexicanus, which belong to the same passerine family, the Icteridae. The sporocysts were infective for house sparrows Passer domesticus and canaries which represent two other families (Ploceidae and Fringillidae, respectively) of the order Passeriformes. The sporocysts were not, however, infective for mallards Anas platyrhynchos (Family Anatidae).

The light and electron microscopic structure of the cyst wall of Sarcocystis in the plush-crested jay Cyanocorax chrysops was compared in a paper by Tadros and Laarman (1978). The cyst wall as seen under the

light microscope appeared fairly smooth with only slight ridges, whilst electron microscopy revealed a cyst wall with a deeply fjorded outline. Long bundles of fibrils extended into irregular cyst wall projections, and the relatively thick ground substance underlying the primary cyst wall was granular and contained vesicles. This study, which included work on Sarcocystis in mammals and a reptile, confirmed the earlier conclusions of Mehlhorn et al. (1976): the fine structure of the cyst wall should not be used exclusively to distinguish between different species of Sarcocystis, since there can be similarities in the fine structure of the cyst wall of different species as well as differences in the cyst wall structure of some species during different stages of development.

Golubkov (1978) was unable to infect chicks and goslings with "Sarcocystis fusiformis" in minced beef. However, it was stated that "S. fusiformis" sporocysts in the faeces of cats and dogs successfully infected "experimental birds". One bird died and the others became thin and their muscles were pale in colour. There is some doubt as to the validity of the results given in this paper (personal communication in 1983 to M.B. Markus from T.V. Beyer, who did not consider it worth providing a copy of the paper).

Golubkov (1979) reported the successful transmission of S. horvati from chickens and S. rilevi from geese to

dogs and cats. The prepatent period for dog and cat was 10 and 11 days, respectively, with the infection lasting 21 to 23 days in dogs and 19 days in cats. The sporocysts from cat and dog faeces were morphologically similar and endogenous stages of developing sporocysts were present in the mucosa of the small intestine of both final hosts. There are some questions arising from this paper (N.D. Levine, personal communication to M.B. Markus, 1982) and the results need to be confirmed.

Garnham et al. (1979) described a new species, Sarcocystis kirmsei, from the brains of two tropical birds, a Siamese firebacked pheasant Lophura diardi from Thailand and an unidentified bird from Panama, respectively. The sizes of the cysts from the two birds differed, but they were structurally similar, both containing merozoites and the remnants of sept Electron micrographs of the cyst wall of the Siamese firebacked pheasant, showed projecting spines with an apparently simple structure, having longitudinal strands along the spines. Polar rings and micronemes were present in the merozoites. The material used for electron microscopy was in the form of sections lifted from microscope slides which had been prepared for light microscopy and, consequently, the results of the fine structural examination leave something to be desired. Whether this organism was, in fact,

Sarcocystis, is not certain; nor, in the absence of transmission experiments, is it certain whether only one parasite species was involved.

The deaths of captive blue and yellow tanagers Thraupis bonariensis in the Memphis zoo in the United States of America was considered to be due to sarcocystosis, as no other significant lesions were found and invasion of the musculature was particularly severe (Douglass and Hansen, 1979). Compartmentalised cysts were present in both cardiac and skeletal muscles.

Sarcocystis was found by histological examination of muscle in 25 of 43 families of Australian birds (Munday et al., 1979). Muscle from a total of 832 birds of 129 species was screened. The organism was prevalent in certain carnivorous birds (cormorants, herons, kookaburras, pelicans, hawks and falcons) and omnivorous or insectivorous birds (honeyeaters, coots, native hens, grass finches, gulls and swallows). In other carnivorous birds (magpies, currowongs and ravens), ground-feeding omnivores (wrens, scrub-wrens, shrike thrushes, parrots, ibis and spoonbills) and insectivorous species (pardalotes, silvereyes and robins), Sarcocystis was less common. The differences in the frequency of Sarcocystis infection in these birds are possibly due to their different feeding habits. Two morphological types of sarcocysts were found by light microscopy (the fine structure of cysts

was not examined): thin-walled cysts, which were the most common type; and thick-walled cysts, which were found in cormorants, grebes and pelicans. Cysts were not found in the myocardium except in the case of a southern skua Catharacta skua, two white-backed magpies Gymnorhina hypoleuca and one hoary-headed grebe Podiceps poliocephalus; in all of which sarcocysts were found in the myocardium only and not in skeletal muscle. Munday et al. (1979) commented that the absence of macroscopic cysts in Australian birds was probably related to the absence of a suitable definitive host on that continent. Only predatory birds contained sporocysts in intestinal mucosal scrapings.

A survey by Markus and Munday (1979) indicated that vultures are probably final hosts of more than one species of Sarcocystis of large game animals, since sporocysts have been found in white-backed vultures Gyps africanus which were thought not to have fed on domestic animals; or if so, only on rare occasions. Other than the report by Fantham (1913), discussed earlier, this appears to have been the only work carried out on Sarcocystis of African birds prior to commencement of the present study.

The frequency of Sarcocystis infection in the musculature of certain birds in western Canada was

established by Drouin and Mahrt (1979). Nine hundred and thirty individuals of 58 species were examined. Macrocysts and microcysts were found in some host species (mallards, pintails Anas acuta and wild shovelers Anas clypeata), although not concurrently in the same individual. Sarcocysts were recorded in skeletal muscle from the great horned owl Bubo virginianus and the snowy owl Nyctea scandiaca. The method of checking for cysts in histological sections of one muscle sample proved to be reliable, as duplicate samples yielded the same result in most cases. Microcysts in a red-winged blackbird Agelaius phoeniceus and a yellow-headed blackbird Xanthocephalus xanthocephalus were evenly distributed throughout the body, and cysts were not found in the cardiac muscle of any of 112 individuals examined. Attempts to transmit sarcocysts from ducks to various carnivores were unsuccessful, which probably means that the parasite is transmitted by a different host(s) in a different area(s).

Drouin and Mahrt (1980) described, by light microscopy, five kinds of Sarcocystis microcysts from birds in western Canada on the basis of the thickness of the cyst wall, and on the length of the radial spines and their proximity to each other. Different host species harboured similar cyst types and different cyst types were found in the same host species, as well as concurrently in the same individual. The authors

speculated that differences in cyst type may be a function of the host species infected. It is possible that protrusions of the primary cyst wall are a function of the age of the cyst; "cauliflower-like" structures were found on the primary cyst wall in wild shovelers and a gadwall Anas strepera collected in spring, but were absent from a wild shoveler and several mallards collected in autumn. The authors suggested that the projections may be resorbed into the wall as the cyst ages. Young and old ducks harboured macrocysts with different cyst walls.

Box and Duszynski (1980) studied the sexual stages of Sarcocystis in opossums after feeding them muscle cysts from brownheaded cowbirds and great-tailed grackles. Macrogametocytes and microgametocytes were observed throughout the small intestine, as were, at a later stage, sporocysts containing sporozoites. The sporocysts were examined by Box et al. (1980) using phase contrast microscopy and scanning and transmission electron microscopy. Cowbird and grackle-infected opossums, respectively, showed sporocysts with similar patterns of ridges on the surfaces.

The striped skunk Mephitis mephitis served as a final host for macroscopic cysts of Sarcocystis rileyi from wild shovelers (Wicht, 1981). The skunk shed both sporulated oocysts and free sporocysts in the faeces;

the prepatent period was 15 days and the patent period was 50 days. The oocysts were fully sporulated when shed, with each of the two sporocysts containing four sporozoites and a granular residuum.

Experimental transmission of macroscopic cysts of Sarcocystis sp. from naturally infected wild shovelers to striped skunks was also achieved by Cawthorn et al. (1981). Sporocysts from the skunk were administered orally to laboratory-reared shovelers and gave rise to microscopic cysts in a shoveler examined at 85 days post infection; and macroscopic cysts in a shoveler examined at 154 days post infection. A skunk fed subsequently on muscle containing the macroscopic cysts, passed faeces containing sporocysts. The sarcocysts from both the natural and experimental infections had a primary cyst wall with "cauliflower-like" projections. However, the cyst wall projections of the microscopic cysts of the experimentally infected duck were shorter and less elaborate than those of the macroscopic cysts. The cysts probably belonged to the same species, since their walls were similar.

Wobeser et al. (1981) examined cardiac and skeletal muscle from snow geese Anser caerulescens, Ross's geese Anser rossi and Canada geese Branta canadensis by means of light microscopy. Two morphological Sarcocystis types were found in the skeletal muscle of the three species of geese. The type occurring more

commonly had finger-like protrusions (containing numerous fibrils) of the primary cyst wall, arranged in palisade fashion. The primary cyst wall was invaginated and septa extended from the peripheral ground substance into the cyst. The cyst type found in both cardiac and skeletal muscle had a relatively smooth primary cyst wall, with only a few small invaginations; septa were present. One snow goose had both cyst types concurrently in its skeletal muscle.

Wobeser and Cawthorn (1981) found macroscopic and microscopic cysts in wild ducks, with focal granulomatous myositis present only in association with macroscopic cysts. Yellowish-white nodules which were at first thought to be cysts were seen in the muscle fibers, but histological examination showed that many of these nodules were granulomas. A series of degenerative changes and a subsequent inflammatory response to the degeneration could be seen in cysts in the wild shoveler and the mallard.

Kaiser and Markus (1981) showed that the gross structure of the cyst wall of the spotted dikkop Burhinus capensis was not affected by freezing at -20°C. Protrusions of the cyst wall contained fibrillar elements, and infoldings of the primary wall gave the cyst an irregular outline.

Wenzel (1981) examined 873 individuals of 14 different bird species in south-western Germany for the presence of Sarcocystis. The identity of the parasite in the neck and thigh muscles of chickens was probably S. horvathi; cysts were weakly chambered and cyst wall protrusions were present. These cysts were not experimentally infective to cats, dogs or northern goshawks Accipiter gentilis. A clearly-chambered cyst with cyst wall projections was recovered from pectoral, neck and thigh muscles. This species of Sarcocystis was successfully transmitted to a cat and a dog, with prepatent periods of six and nine days respectively, and patent periods of 23 and 32 days respectively. Sporocysts obtained from these infections were successfully transmitted to chickens. A ring-necked pheasant Phasianus colchicus contained distinctly-chambered cysts with large cyst wall protrusions. Although this species of Sarcocystis was morphologically similar to the one found in chickens, it could not be transmitted to the latter host by means of sporocysts from a dog infected with the pheasant cysts. Cysts found in a common coot Fulica atra were distinctly chambered and the cyst walls were smooth. Neither the cat nor the dog proved to be the final host.

Sarcocysts were recorded in the myocardium of a raptor, namely a bald eagle Haliaeetus leucocephalus (Crawley et al., 1982). The cysts had thin walls and were non-

septate. Smooth-walled cysts were also found in the pectoral muscles, but these cysts had not yet been positively identified as Sarcocystis. It is possible that the eagle was infected with two types of cysts.

Box and Smith (1982) fed naturally-infected brownheaded cowbirds and great-tailed grackles (Family Icteridae) to opossums, and the sporocysts thus obtained were used to infect sparrows. The latter, in turn, infected opossums. To determine the intermediate host range, sporocysts from these opossums were given orally to six species of birds representing four orders, namely Passeriformes (canary, zebra finch Poephila guttata), Psittaciformes (budgerigar Melopsittacus undulatus), Columbiformes (domestic pigeon Columba livia) and Galliformes (chicken, helmeted guineafowl Numida meleagris). Schizogony occurred in the lungs in all birds but the Galliformes. Muscular cysts developed in both the Passeriformes and the Psittaciformes, but the Columbiformes were not susceptible to development of cysts in muscle cells. This indicates that four avian species of two additional* orders are susceptible to infection with Sarcocystis. The cysts were divided into compartments by septa and their walls had similar

---

* Sporocysts of the same species of Sarcocystis had previously been found to give rise to muscular cysts in various passeriform hosts (Box and Duszynski, 1978). In the subsequent study (Box and Smith, 1982) stages were located in experimental psittaciform and in the columbiform hosts as well.

protrusions in all the experimentally infected birds. The results of this work indicate that at least one species of avian Sarcocystis is not completely host specific; and that this parasite can develop to varying degrees in a number of potential intermediate host species.

MATERIALS AND METHODS

Two hundred and eighty species of wild southern African birds, representing 64 families, were examined histologically for the presence of *Sarcocystis*: the total sample size was 1512 individuals. However, 21 additional birds were checked for macroscopic sarcocysts. Most of the material came from the Republic of South Africa. A number of muscle samples were collected in South West Africa (Namibia) and Zimbabwe. Muscle from 10 species of exotic birds was also screened, but the results have not been included in this dissertation. Muscle samples were obtained mainly from road casualties; fixed specimens; birds which had died in the Bird Hospital at the Johannesburg branch of the Society for the Prevention of Cruelty to Animals; and deep-frozen birds at the Transvaal Museum, Pretoria. No birds were killed specially for this study.

Fresh material was fixed whenever possible, but many muscle specimens were from birds which had been frozen at -20°C. Several pieces of pectoral muscle and several pieces of leg muscle (each $5mm^3$) were dissected from

the birds and fixed in neutral-buffered formal-saline[1] for at least 24 hours. Two pieces of pectoral muscle and one piece of leg muscle (each $5mm^3$) were used for initial screening and were embedded in the same paraplast block. In some cases, muscle samples from birds that had been fixed in formalin, injected with glycerine and kept in 70 per cent alcohol, were used. All samples were dehydrated in a graded series of alcohols, cleared in chloroform and embedded in paraplast[1]. Sections 6µm thick were cut with a metal knife on a Leitz Wetzlar 1512 microtome and stained by means of a modified Mayer's haematoxylin and eosin Y[2] method. Sections were examined for cysts using a compound light microscope. Approximately 30 sections from each bird were normally screened by light microscopy. The above procedure was repeated, as a double check, for birds with moderate to heavy infections. Some of the remaining muscle samples from birds which were found to contain cysts, were utilized for electron microscopy. Small pieces of tissue (cross-sections less than $1mm^2$) were post-fixed in osmium tetroxide, dehydrated in a graded acetone series and embedded in araldite[3]. Semi-thin sections (1µm

---

1. See Appendix III.
2. See Appendix IV.
3. See Appendix V.

thick) were cut on a Porter-Blum ultramicrotome and stained with a toluidine blue and pyronin Y solution[4], to locate the sarcocysts. Ultrathin sections (60 - 90nm thick) of the cysts were then prepared on a Reichert OMU 3 ultramicrotome and mounted on copper grids. Sections were stained with uranyl acetate and lead citrate[4], and examined under a JEM-100S transmission electron microscope. Images were recorded on a Kodak CAT film.

If the carcasses of birds in which sarcocysts were found were still available, three tissue samples (each approximately $5mm^3$) were cut from each of the following body regions:- abdomen, back, breast, brain, heart, oesophagus, thigh and wing. The material was examined histologically, and the total number of cysts located in approximately 30 sections of tissue from each region was recorded to give an indication of the site specificity of Sarcocystis.

---

4. See Appendix VI.

RESULTS

Prevalence of Sarcocystis infection

Of the 1512 birds that were microscopically examined (Table 1), 40 individuals of 25 species (representing 20 families) were found to be infected with *Sarcocystis* (Table 2). Except where otherwise indicated, the birds examined were adults. Species are classified according to *S.A.O.S. Checklist of Southern African Birds* (Southern African Ornithological Society List Committee, 1980). Some birds which were not collected by the author were not identified to the specific level by the collectors, and these birds have been listed in Table 1 as *Francolinus* sp., *Coturnix* sp., *Camaroptera* sp., *Anthus* sp. and *Lagonosticta* sp., respectively. Scientific names of birds only have been used in Tables 1 to 4. For the sake of clarity, both scientific and common names are given on first mention of a species in the text; thereafter, only common names are used. See Appendix II for a list of both the common and scientific names of the southern African birds mentioned in this dissertation.

TABLE 1: Species of birds examined microscopically for *Sarcocystis* infection.

KEY:

+/- : + indicates that *Sarcocystis* was present (the number of individuals found to be infected is given in brackets behind the + sign).
- indicates that *Sarcocystis* was not seen.

No. : number of individuals of a particular species examined.

juv.: juvenile - birds still in the nest or recently fledged.

imm.: immature - birds older than juveniles (usually as judged by the plumage) but not yet adult.

sub. : subadult - birds which are almost mature.

FAMILY	SPECIES	No.	+/-
Diomedeidae	*Diomedea exulans*	1	-
	Phoebetria fusca	1	-
	Phoebetria palpebrata	1	-
Procellariidae	*Macronectes halli*	1	+(1)
	Pterodroma macroptera	1	-
	Pterodroma mollis	9	-
	Pterodroma incerta	4	-
	Pterodroma brevirostris	9	-
	Halobaena caerulea	10	-
	Pachyptila vittata	2	-

TABLE 1 (cont.)

	Pachyptila desolata	1	-
	Pachyptila turtur	1	-
	Puffinus gravis	1	-
	Puffinus assimilis	6	-
Oceanitidae	*Fregetta grallaria*	1	-
Phalacrocoracidae	*Phalacrocorax carbo*	1	-
	Phalacrocorax africanus	2	-
Ardeidae	*Ardea cinerea*	2	-
	Ardea melanocephala (imm.)	2	-
	Ardea melanocephala	5	-
	Ardea purpurea	2	-
	Egretta garzetta	2	+(1)
	Egretta intermedia	2	+(1)
	Bubulcus ibis	22	+(4)
	Nycticorax nycticorax	1	+(1)
	Ixobrychus sturmii	1	-
Scopidae	*Scopus umbretta*	1	-
Ciconiidae	*Ciconia ciconia*	1	-
Plataleidae	*Threskiornis aethiopicus*	6	-
	Plegadis falcinellus	1	-
	Bostrychia hagedash	6	+(1)
	Platalea alba	2	-

TABLE 1 (cont.)

Anatidae	Dendrocygna viduata	3	-
	Alopochen aegyptiacus	8	-
	Anas erythrorhyncha	1	+(1)
	Anas acuta	1	-
	Plectropterus gambensis (imm.)	6	-
	Plectropterus gambensis	16	-
	Oxyura maccoa	1	-
Sagittariidae	Sagittarius serpentarius	2	-
Accipitridae	Gyps africanus	1	-
	Milvus migrans (imm.)	1	-
	Milvus migrans	38	-
	Elanus caeruleus (sub.)	1	-
	Elanus caeruleus	23	-
	Aquila rapax	1	-
	Hieraaetus ayresii	1	-
	Circaetus gallicus	1	-
	Butec buteo	4	-
	Buteo rufofuscus	1	-
	Accipiter rufiventris	1	-
	Accipiter minullus	1	-
	Accipiter tachiro	1	-
	Melierax canorus	5	-
	Circus ranivorus	2	-
Falconidae	Falco biarmicus	1	-
	Falco amurensis	1	-

TABLE 1 (cont.)

	Falco tinnunculus	2	-
	Falco rupicoloides	1	-
	Falco naumanni	4	-
Phasianidae	Francolinus sp.	1	-
	Francolinus coqui	2	-
	Francolinus sephaena	3	-
	Francolinus shelleyi (juv.)	3	-
	Francolinus levaillantoides	2	-
	Francolinus adspersus	1	-
	Francolinus capensis	1	-
	Francolinus natalensis	3	-
	Francolinus swainsonii	8	+(3)
	Coturnix sp.	1	-
	Coturnix coturnix	2	-
	Coturnix delegorguei	2	-
Numididae	Numida meleagris	1	-
Turnicidae	Turnix sylvatica	7	-
Gruidae	Anthropoides paradisea	3	-
Rallidae	Crex crex	1	-
	Crex egregia	1	-
	Amaurornis flavirostris	1	-
	Porphyrio porphyrio	3	+(1)
	Gallinula chloropus	3	-

TABLE 1 (cont.)

	Fulica cristata	4	-
Charadriidae	Charadrius tricollaris	1	-
	Vanellus coronatus (imm.)	3	-
	Vanellus coronatus	11	-
	Vanellus armatus	2	-
	Vanellus senegallus	2	-
Scolopacidae	Tringa glareola	1	-
	Calidris ferruginea	2	-
	Philomachus pugnax	1	-
	Gallinago nigripennis	1	-
Burhinidae	Burhinus capensis (juv.)	1	-
	Burhinus capensis	10	+(4)
Glareolidae	Rhinoptilus chalcopterus	4	-
	Glareola pratincola	1	-
Laridae	Stercorarius parasiticus	2	-
	Catharacta antarctica	2	+(1)
	Larus cirrocephalus	1	-
Columbidae	Columba guinea (juv.)	3	-
	Columba guinea (imm.)	3	-
	Columba guinea	12	-
	Columba arquatrix	2	-
	Streptopelia semitorquata	4	-
	Streptopelia capicola	7	-

TABLE 1 (cont.)

	Streptopelia senegalensis (imm.)	22	-
	Streptopelia senegalensis	70	+(3)
	Oena capensis	3	-
	Turtur chalcospilos	1	-
Psittacidae	Psittacula krameri	1	-
	Agapornis roseicollis	1	-
Musophagidae	Corythaixoides concolor	4	-
Cuculidae	Cuculus solitarius	1	-
	Clamator levaillantii	1	-
	Chrysococcyx caprius (juv.)	2	-
	Chrysococcyx caprius (imm.)	2	-
	Chrysococcyx caprius	4	+(1)
	Centropus superciliosus (juv.)	1	-
	Centropus superciliosus	7	-
Tytonidae	Tyto alba	13	+(1)
	Tyto capensis	1	-
Strigidae	Asio capensis	13	-
	Otus leucotis	1	-
	Glaucidium perlatum	2	-
	Bubo africanus	14	+(1)
Caprimulgidae	Caprimulgus natalensis	1	-

TABLE 1 (cont.)

Apodidae	Apus barbatus	3	-
	Apus caffer (imm.)	4	-
	Apus caffer	31	+(2)
	Apus horus	1	-
	Apus affinis (juv.)	3	-
	Apus affinis	29	-
Coliidae	Colius striatus (juv.)	2	-
	Colius striatus (imm.)	5	-
	Colius striatus	46	-
	Colius colius (imm.)	1	-
	Colius colius	2	-
	Colius indicus (imm.)	6	-
	Colius indicus	20	-
Halcyonidae	Ceryle maxima	2	-
	Alcedo semitorquata	1	-
	Halcyon senegalensis	1	-
	Halcyon albiventris	8	+(1)
	Halcyon chelicuti	3	-
Meropidae	Merops apiaster	5	-
	Merops pusillus	2	-
Coraciidae	Coracias garrulus	1	-
	Coracias caudata	4	+(2)
Upupidae	Upupa epops	8	-

TABLE 1 (cont.)

Phoeniculidae	Phoeniculus purpureus	2	-
Bucerotidae	Tockus nasutus	4	-
	Tockus erythrorhynchus	14	+(3)
	Tochus flavirostris	4	+(2)
Capitonidae	Lybius torquatus	5	-
	Pogoniulus chrysoconus	1	-
	Trachyphonus vaillantii	22	-
Indicatoridae	Indicator minor	1	-
Picidae	Dendropicos fuscescens	2	-
	Mesopicos griseocephalus	1	-
Eurylaimidae	Smithornis capensis	1	-
Alaudidae	Mirafra africana	1	-
	Mirafra sabota	3	-
	Eremopterix leucotis	3	-
Hirundinidae	Hirundo rustica	9	-
	Hirundo albigularis	1	-
	Hirundo semirufa	1	-
	Hirundo cucullata (imm.)	2	-
	Hirundo cucullata	7	-
	Hirundo abyssinica	2	-
	Delichon urbica	4	-
	Riparia paludicola	2	-

TABLE 1 (cont.)

Dicruridae	Dicrurus adsimilis (juv.	1	-
	Dicrurus adsimilis	-	-
	Dicrurus ludwigii	1	-
Oriolidae	Oriolus oriolus	2	-
	Oriolus larvatus	3	-
Corvidae	Corvus capensis	3	-
	Corvus albus (juv.)	1	-
	Corvus albus	2	-
Paridae	Parus niger	2	-
	Anthoscopus caroli	1	-
Timaliidae	Turdoides jardineii (imm.	1	-
	Turdoides jardineii	3	-
	Turdoides bicolor	2	-
Pycnonotidae	Pycnonotus barbatus (imm.	2	-
	Pycnonotus barbatus	11	-
	Phyllastrephus flavostriatus	1	-
	Andropadus importunus	1	-
	Chlorocichla flaviventris	3	-
Turdidae	Turdus libonyana	4	-
	Turdus olivaceus (juv.)	6	-
	Turdus olivaceus (imm.)	15	-

TABLE 1 (cont.)

	Turdus olivaceus	19	-
	Turdus litsitsirupa	3	-
	Oenanthe monticola	2	-
	Oenanthe bifasciata	1	-
	Cercomela familiaris	2	-
	Thamnolaea cinnamomeiventris	2	-
	Myrmecocichla formicivora	1	-
	Cossypha dichroa	1	-
	Cossypha natalensis	1	+(1)
	Cossypha caffra (imm.)	3	-
	Cossypha caffra	7	-
	Cossypha humeralis	5	-
	Pogonocichla stellata	1	-
	Erythropygia leucophrys	5	-
	Erythropygia paena	3	-
Sylviidae	Parisoma subcaeruleum	2	-
	Acrocephalus baeticatus	7	-
	Acrocephalus palustris	2	-
	Acrocephalus schoenobaenus	2	-
	Acrocephalus gracilirostris	1	-
	Chloropeta natalensis	1	-
	Bradypterus baboecala	1	-
	Phylloscopus trochilus	2	-
	Apalis thoracica	1	-
	Sylvietta rufescens	3	-
	Eremomela usticollis	1	-
	Camaroptera sp.	1	-
	Sphenoeacus afer	1	-

TABLE 1 (cont.)

	Cisticola juncidis	2	-
	Cisticola textrix	1	-
	Cisticola lais	1	-
	Cisticola chiniana	2	-
	Cisticola tinniens	1	-
	Cisticola natalensis	1	-
	Cisticola fulvicapilla	5	-
	Prinia subflava	1	-
	Prinia flavicans	1	-
	Prinia maculosa	2	-
Muscicapidae	Muscicapa striata	3	-
	Muscicapa caerulescens	1	-
	Myioparus plumbeus	1	-
	Melaenornis pammelaina	2	-
	Melaenornis mariquensis	2	-
	Melaenornis pallidus	1	-
	Sigelus silens	3	-
	Batis capensis	1	-
	Terpsiphone viridis	1	-
Motacillidae	Motacilla capensis	6	-
	Anthus sp.	2	-
	Anthus similis	1	-
	Anthus leucophrys	1	-
	Macronyx capensis (imm.)	1	-
Laniidae	Lanius minor	1	-

TABLE 1 (cont.)

	Lanius collaris (juv.)	7	-
	Lanius collaris (imm.)	10	-
	Lanius collaris (sub.)	8	-
	Lanius collaris	12	-
	Lanius collurio	1	-
	Corvinella melanoleuca	9	+(1)
Malaconotidae	Laniarius ferrugineus	2	-
	Laniarius atrococcineus (sub.)	1	-
	Laniarius atrococcineus	3	-
	Dryoscopus cubla	4	-
	Tchagra australis	3	-
	Tchagra senegala	1	-
	Telophorus zeylonus (juv.)	2	-
	Telophorus zeylonus (imm.)	1	-
	Telophorus zeylonus	5	+(1)
Prionopidae	Prionops plumatus	1	-
Sturnidae	Acridotheres tristis (juv.)	2	-
	Acridotheres tristis (imm.)	5	-
	Acridotheres tristis	12	-
	Spreo bicolor (juv.)	1	-
	Spreo bicolor	3	-
	Creatophora cinerea	1	-
	Cinnyricinclus leucogaster (imm.)	1	-
	Cinnyricinclus leucogaster (sub.)	1	-
	Cinnyricinclus leucogaster	6	-
	Lamprotornis australis	10	+(1)

TABLE 1 (cont.)

	Lamprotornis nitens (imm.)	1	-
	Lamprotornis nitens	9	+(1)
	Onychognathus morio (juv.)	1	-
Promeropidae	Promerops cafer	2	-
	Promerops gurneyi	1	-
Nectariniidae	Nectarinia famosa	2	-
	Nectarinia afra	1	-
	Nectarinia talatala	4	-
	Nectarinia amethystina	3	-
Zosteropidae	Zosterops pallidus	12	-
Ploceidae	Bubalornis niger	3	-
	Plocepasser mahali	69	-
	Philetairus socius	23	-
	Passer domesticus (imm.)	1	-
	Passer domesticus (sub.)	1	-
	Passer domesticus	10	-
	Passer melanurus (juv.)	3	-
	Passer melanurus (imm.)	6	-
	Passer melanurus	35	-
	Passer griseus	1	-
	Petronia superciliaris	1	-
	Sporopipes squamifrons	2	-
	Ploceus cucullatus	2	-
	Ploceus capensis	1	-

TABLE 1 (cont.)

	Ploceus velatus (juv.)	1	-
	Ploceus velatus (imm.)	9	-
	Ploceus velatus	16	-
	Quelea quelea	8	-
	Euplectes orix (imm.)	1	-
	Euplectes orix	8	-
	Euplectes afer	1	-
	Euplectes capensis	1	-
	Euplectes albonotatus	1	-
	Euplectes progne	1	-
Estrildidae	Pytilia melba	2	-
	Lagonosticta sp.	1	-
	Uraeginthus angolensis	3	-
	Uraeginthus granatinus	1	-
	Estrilda astrild	2	-
	Estrilda melanotis	1	-
	Spermaegithus subflavus	1	-
	Amadina erythrocephala	9	-
Viduidae	Vidua macroura	8	-
	Vidua regia	2	-
	Vidua paradisaea	2	-
Fringillidae	Serinus mozambicus	4	-
	Serinus striogularis	12	-
	Serinus tottus	2	-
	Serinus flaviventris	2	-
	Serinus gularis	5	-

TABLE 1 (cont.)

	Ploceus velatus (juv.)	1	-
	Ploceus velatus (imm.)	9	-
	Ploceus velatus	16	-
	Quelea quelea	8	-
	Euplectes orix (imm.)	1	-
	Euplectes orix	8	-
	Euplectes afer	1	-
	Euplectes capensis	1	-
	Euplectes albonotatus	1	-
	Euplectes progne	1	-
Estrildidae	Pytilia melba	2	-
	Lagonosticta sp.	1	-
	Uraeginthus angolensis	3	-
	Uraeginthus granatinus	1	-
	Estrilda astrild	2	-
	Estrilda melanotis	1	-
	Sporaeginthus subflavus	1	-
	Amadina erythrocephala	9	-
Viduidae	Vidua macroura	8	-
	Vidua regia	2	-
	Vidua paradisaea	2	-
Fringillidae	Serinus mozambicus	4	-
	Serinus atrogularis	12	-
	Serinus tottus	2	-
	Serinus flaviventris	2	-
	Serinus gularis	5	-

TABLE 1 (cont.)

	Emberiza flaviventris	3	-
HYPOTHETICAL LIST*	Pelagodroma marina	3	-
	Garrodia nereis	3	-
	Pelecanoides urinatrix	11	-
	Columba livia (juv.)	1	-
	Columba livia (imm.)	2	-
	Columba livia	72	-

* There was a prima facie case for inclusion of these species in the South African list when each was first recorded in the literature. However, their inclusion is now unacceptable for a reason stated in each case in the S.A.O.S. Checklist of Southern African Birds (Southern African Ornithological Society List Committee, 1980).

A summary of host species found to be infected with Sarcocystis is given in Table 2.

TABLE 2: Summary of species of birds found to have Sarcocystis infections.

FAMILY	SPECIES	NUMBER EXAMINED	NUMBER INFECTED
Procellariidae	Macronectes halli	1	1
Ardeidae	Egretta garzetta	2	1
	Egretta intermedia	2	1
	Bubulcus ibis	22	4

TABLE 2 (cont.)

	Nycticorax nycticorax	1	1
Plataleidae	Bostrychia hagedash	6	1
Anatidae	Anas erythrorhyncha	1	1
Phasianidae	Francolinus swainsonii	8	3
Rallidae	Porphyrio porphyrio	3	1
Burhinidae	Burhinus capensis	10	4
Laridae	Catharacta antarctica	2	1
Columbidae	Streptopelia senegalensis	70	3
Cuculidae	Chrysococcyx caprius	4	1
Tytonidae	Tyto alba	13	1
Strigidae	Bubo africanus	14	1
Apodidae	Apus caffer	31	2
Halcyonidae	Halcyon albiventris	8	1
Coraciidae	Coracias caudata	4	2

TABLE 2 (cont.)

Bucerotidae	Tockus erythrorhynchus	14	3
	Tockus flavirostris	4	2
Turdidae	Cossypha natalensis	1	1
Laniidae	Corvinella melanoleuca	9	1
Malaconotidae	Telophorus zeylonus	5	1
Sturnidae	Lamprotornis australis	10	1
	Lamprotornis nitens	9	1

Twenty-one waterfowl were examined macroscopically only, for obvious macroscopic sarcocysts; no cysts were seen (Table 3).

TABLE 3: Waterfowl examined macroscopically (but not microscopically) for obvious macroscopic sarcocysts*.

FAMILY		NUMBER EXAMINED	NUMBER INFECTED
Anatidae	Anas undulata	9	-
	Anas erythrorhyncha	11	-
Rallidae	Fulica cristata	1	-

* Information provided by Mr H.K. Morgan of Baberspan Ornithological Research Station, at the request of the author.

TABLE 2 (cont.)

Bucerotidae	Tockus erythrorhynchus	14	3
	Tockus flavirostris	4	2
Turdidae	Cossypha natalensis	1	1
Laniidae	Corvinella melanoleuca	9	1
Malaconotidae	Telophorus zeylonus	5	1
Sturnidae	Lamprotornis australis	10	1
	Lamprotornis nitens	9	1

Twenty-one waterfowl were examined macroscopically only, for obvious macroscopic sarcocysts; no cysts were seen (Table 3).

TABLE 3: Waterfowl examined macroscopically (but not microscopically) for obvious macroscopic sarcocysts*.

FAMILY		NUMBER EXAMINED	NUMBER INFECTED
Anatidae	Anas undulata	9	-
	Anas erythrorhyncha	11	-
Rallidae	Fulica cristata	1	-

* Information provided by Mr H.K. Morgan of Baberspan Ornithological Research Station, at the request of the author.

Site specificity

Tissue from 15 of the birds found to harbour cysts was examined further to give an indication of the site specificity of Sarcocystis (Table 4).

TABLE 4: Site specificity of Sarcocystis* in some infected birds.

KEY:

\- : no cysts found in this region.

\+ : 1 - 4 cysts found in this region.

++ : 5 - 8 cysts found in this region.

+++ : 9 - 12 cysts found in this region.

++++ : 13 or more cysts found in this region.

AM : abdominal muscle

BM : back muscle

Br : brain

H : heart

Oe : oesophagus

PM : pectoral muscle

TM : thigh muscle

W : wing muscle

---

* See Discussion.

TABLE 4 (cont.)

	Ab	Ba	Er	H	Oe	Pe	Th	W
Egretta garzetta	-	+	-	-	++	++	++	-
E. intermedia	-	-	-	-	-	+	-	-
Bubulcus ibis	-	+	-	-	-	++++	++	+
B. ibis	-	-	-	-	-	+	-	-
B. ibis	++++	++++	-	-	-	++++	++++	++++
Nycticorax nycticorax	-	++	-	-	-	+	+	-
Burhinus capensis	-	++	-	-	-	+	+	+++
B. capensis	+	+	-	-	-	++	++	++++
Streptopelia senegalensis	-	-	-	-	-	+	-	-
Chrysococcyx caprius	-	-	-	-	-	+	-	-
Bubo africanus	-	+	+*	-	-	+	-	-
Apus caffer	-	-	-	-	-	++	-	-
A. caffer	-	++++	-	-	-	++++	+++	++++
Coracias caudata	-	+	-	-	-	+	+	+
Telophorus zeylonus	-	-	-	-	-	+	-	-

* See Discussion.

Electron microscopy

Sarcocysts from 19 individual birds (17 species) representing 12 families were examined by electron microscopy (Figures 2 - 65; 68 - 87). Abbreviations used for structures shown in the electron micrographs have been listed on page v.

The measurements of sectioned cysts as well as the dimensions of cystozoic merozoites are given in Table

5. Because of poor fixation of the contents of cysts found in the redbilled hornbill Tockus erythrorhynchus (discussed later), it was not possible to obtain measurements of the merozoites.

The morphology of the cyst walls of a type of sarcocyst found in two whiterumped swifts Apus caffer (Apodidae) and Sarcocystis in a night heron Nycticorax nycticorax (Ardeidae) was similar (Figures 2 - 6; 8 - 11). The undulating primary cyst wall had many small invaginations of the outer limiting membrane, which resulted in the formation of vesicular pockets (Figures 5 and 11). The ground substance beneath the primary cyst wall (Figures 3 and 8) traversed the interior of the cysts, forming septa which gave rise to chambers. Typical apicomplexan conoids were seen in cystozoic merozoites of the whiterumped swift (Figures 6 and 7).

The cyst found in the little egret Egretta garzetta (Ardeidae) had irregularly shaped protrusions of the primary cyst wall of varying diameter and length (Figures 12 - 15). In some places the outer membrane was seen to be invaginated through the osmiophilic layer (Figure 13). Septa compartmentalised the cyst (Figure 14).

TABLE 5: Measurements of sections of cysts which were examined by electron microscopy; and of cystozoic merozoites.

Species	Size (in semi-thin section) of individual cyst (µm)*	Merozoite size (µm)**
Egretta garzetta	90 - 94,5	5,9 - 7 x 1 - 1,5 (n=7)
E. intermedia	53,2 - 64,4	7,7 - 10,7 x 2 (n=8)
Bubulcus ibis	33,6 - 35	3 - 4 x 1,5 - 1,7 (n=4)
Nycticorax nycticorax	103,5 - 135	4 - 5,8 x 1,1 - 1,6 (n=4)
Anas erythrorhyncha	358,4 - 425,6	1,6 x 4,67 (n=3)
Francolinus swainsonii	84 - 95,2	1,67 x 8,3 (n=7)
Porphyrio porphyrio	117,6 - 131,6	6,3 - 7 x 2,1 - 2,3 (n=5)
Burhinus capensis	61,6 - 75,6	9 x 1 (n=3)
Catharacta antarctica	70 - 92,4	1,7 x 6,3 (n=7)
Streptopelia senegalensis	36,4 - 50,4	6,5 - 7 x 1,7 (n=5)
Apus caffer	64,4 - 57,4	3 - 3,6 x 1,1 - 1,3 (n=5)
A. caffer	36,4 - 44,8	4 - 5,6 x 1,3 - 1,5 (n=4)
Coracias caudata	40,5	4,5 - 6,5 x 1 - 1,2 (n=4)
Tockus erythrorhynchus	28 - 33,6	?
T. erythrorhynchus	19,6	?
T. flavirostris	53,2 - 64,4	7,7 - 10,7 x 2 (n=3)
Cossypha natalensis	36,4 - 47,6	2 x 6,5 (n=3)
Lamprotornis australis	78,4 - 86,8	6,7 - 13 x 1,5- 2 (n=4)
L. nitens	28	1,7 x 1,5 (n=5)

* These measurements are for single sections of individual cysts. Because of the angle at which cysts were cut, they were not usually circular when seen in section. Consequently, measurements have normally been given for both the smaller and the larger "diameter" of the cyst.

**The numbers of sectioned organisms used to determine the merozoite size are given in brackets. Estimates of merozoite size were based on electron micrographs.

The cyst wall of Sarcocystis was morphologically similar in members of five families of birds, namely Turdidae (Natal rob'n Cossypha natalensis), Burhinidae (spotted dikkop Burhinus capensis), Coraciidae (lilacbreasted roller Coracias caudata), Bucerotidae (yellowbilled hornbill Tockus flavirostris and two redbilled hornbills) and Columbidae (laughing dove Streptopelia senegalensis) (Figures 16 - 43). Infoldings of the primary wall gave the cyst an irregular outline. Fibrillar elements with a diameter of up to 25nm could be seen within palisade-like protrusions of the cyst wall. In the laughing dove, the fibrillar elements were seen to extend into the ground substance beneath the protrusions (Figures 41 and 43). The fibrillar elements were curved at their bases (Figure 43). Protrusions of the cyst wall in the Natal robin were up to 1,5µm in length, with a diameter of approximately 0,5µm. Protuberances in the laughing dove were up to 1,1µm in length, with a diameter of 0,5µm. In the spotted dikkop, lilacbreasted roller, yellowbilled hornbill and redbilled hornbills, the protrusions were 0,4 to 0,8µm long, with diameters of between 0,5 and 0,9µm. Sections through the protuberances of cysts from these four host species were oblique rather than completely longitudinal, and their actual lengths were probably closer to those of cysts from the Natal robin and the laughing dove. Septa, formed by the ground substance, were present in

all cases.

The cyst wall of Sarcocystis in the purple gallinule Porphyrio porphyrio (Rallidae) had palisade-like projections into which fibrillar elements with a diameter of approximately 29nm extended (Figures 44 - 49). The protuberances were up to 3,5µm in length, with a diameter of 1,5µm. An osmiophilic layer was not visible and, when viewed in cross-section, invaginations of the outer limiting membrane appeared to be circular, with a spot of darkly-staining material inside them (Figures 46 and 49). Septa were present (Figure 45).

The cyst walls of an immature (Figures 50 - 53) and a mature (Figures 54 and 55) sarcocyst found in a cattle egret Bubulcus ibis (Ardeidae) both appeared to be smooth; no protuberances were present on the primary cyst wall. Infoldings of the limiting membrane formed pockets. An osmiophilic layer was present (Figures 53 and 54). The ground substance traversed the cysts, forming septa (Figures 51, 53, and 54).

A Swainson's francolin Francolinus swainsonii (Phasianidae) harboured cysts in which the primary cyst wall, which consisted of an outer limiting membrane and a thicker underlying osmiophilic layer, was composed of villus-like protrusions (Figures 56 - 65). These

protrusions were up to 6µm long, with the diameter of the widest region up to 0,9µm and having a narrower base with a diameter of approximately 0,45µm. Filamentous elements up to 30nm in cross-section extended from the ground substance into the cyst wall protrusions. Invaginations of the outer membrane formed pore-like structures which appeared circular in cross-section, with a spot of darkly staining material in the centre (Figures 56, 57and 60). Septa were formed by the ground substance.

Macroscopic cysts in the redbilled teal Anas erythrorhyncha (Anatidae) measured up to 8mm in length and had a diameter of 1mm (Figures 66 and 67). The primary cyst wall had palisade-like protrusions (up to 1,6µm in length, with a diameter of 0,7µm) at irregular intervals (Figures 68 - 71). Indentations of the outer limiting membrane formed pockets (Figure 71). The cyst was compartmentalised by septa formed by the ground substance (Figure 69).

Some birds contained cysts which were difficult to categorise. The wall of a cyst in a Cape glossy starling Lamprotornis nitens (Sturnidae) (Figures 72 - 75) had protrusions of approximately 0,67µm in length, with a diameter of 0,3µm. These protrusions occurred at irregular intervals, as was the case with the macroscopic cysts from the redbilled teal. However, cysts in the Cape glossy starling were microscopic.

They were possibly immature cysts of the type seen in the Natal robin group. The organisms within the cyst were apparently in a state of deterioration and it was not, therefore, possible to judge what the age of the cyst might be. Septa, formed by the ground substance, were present.

Burchell's glossy starling Lamprotornis australis (Sturnidae) and a yellowbilled egret Egretta intermedia (Ardeidae) harboured cysts with similar cyst walls (Figures 76 - 83). The outer limiting membrane was irregular in both cases. Palisade-like protrusions of the primary cyst wall, which were up to 1,2µm in length, with a diameter of 0,5µm, were similar to the type seen in the Natal robin group. However, whether any fibrillar elements are present within these protrusions, is not clear. Cysts were compartmentalised by septa (Figures 76 and 80).

A subantarctic skua Catharacta antarctica (Laridae) contained cysts with an irregular primary cyst wall (Figures 84 - 87). An osmiophilic layer was present beneath the outer limiting membrane. Portions of the cyst wall were similar to that seen in the little egret, but no definite protrusions of varying length were visible as in the little egret cyst. Septa were present.

White streaks seen in the skeletal musculature of an immature speckled mousebird Colius striatus and a juvenile masked weaver Ploceus velatus were Sarcocystis-like when viewed under the light microscope. Electron microscopy later showed that these were not Sarcocystis infections (Figures 88 and 89).

Effects of freezing and prolonged fixation

Muscle from the Burchell's glossy starling, the laughing dove and Swainson's francolin was freshly fixed, whilst all the other birds had been frozen at -20°C and thawed prior to use. The gross structure of the cyst wall was not affected by freezing (Figures 2 - 39; 44 - 55; 68 - 75; 80 - 87). The general morphology of walls of cysts in two redbilled hornbills that had been fixed in formalin, injected with glycerine and subsequently kept in 70 per cent alcohol (for longer than five years) was still discernible, even though the contents of the cysts and the surrounding host tissue were either in a state of degeneration or had not been fixed properly (Figures 36 - 39). This was also true for the yellowbilled hornbill and the Cape glossy starling (Figures 30 - 35; 72 - 75), the entire carcasses of which had been immersed in formalin for a period of about 15 years.

Pathogenicity

The light and electron microscopic studies would seem to indicate that the chronic Sarcocystis infections had little or no effect on the infected hosts. Often the host cytoplasm surrounding the cyst wall was devoid of myofibrils, and numerous vesicles, vacuoles and mitochondria were present (Figures 2 - 4, 10, 11, 20, 29, 34, 41, 42, 44, 48, 56, 58, 60, 62). The degree of myositis and necrosis of the muscle fibres was not severe enough to account for the death of the birds.

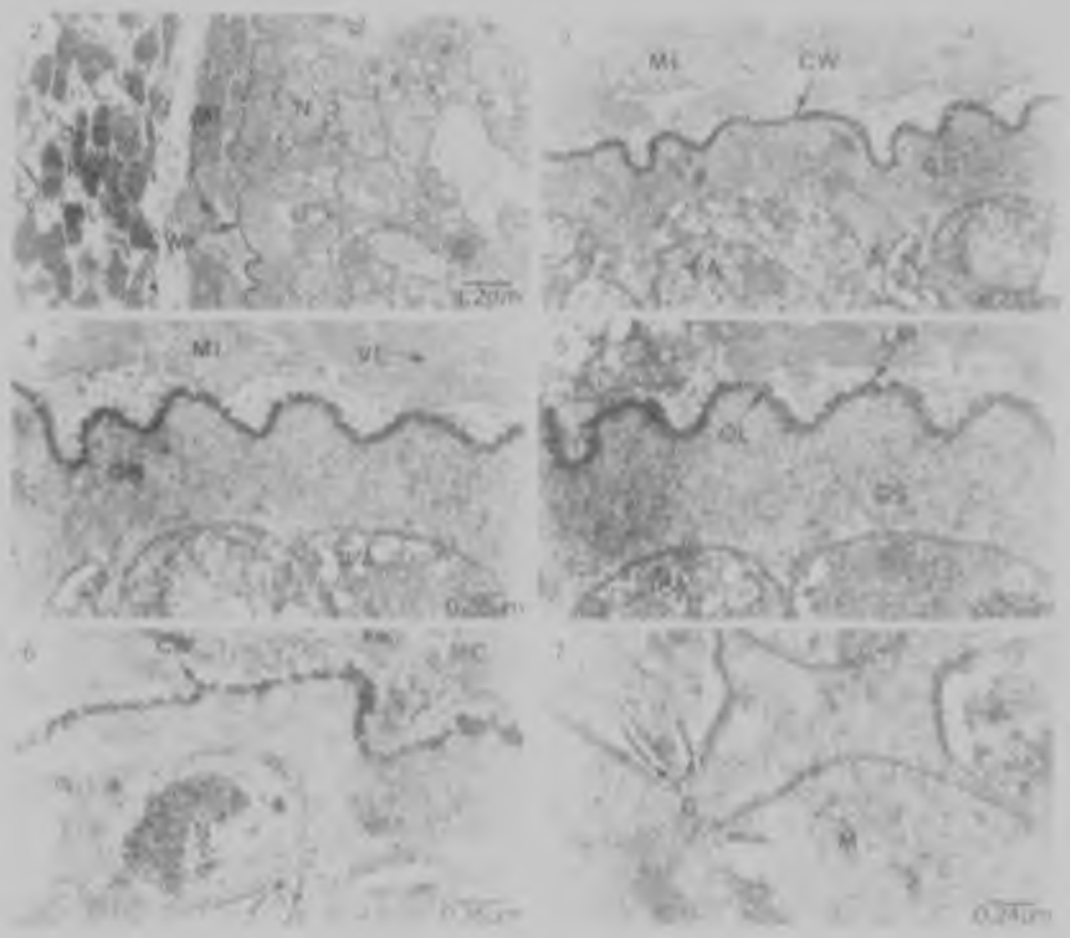

FIGURES 2 to 7. Sarcocystis from a whiterumped swift Apus caffer. Note the wavy appearance of the primary cyst wall (CW). The li- ting membrane (LM) forms vesicular pockets. A septum (S), which compartmentalises the cyst, can be seen as an inward extension of the ground substance. Conoids (C) are visible in the anterior regions of cystozoic merozoites (M). Fixation: formal-saline after freezing and thawing. Stain: uranyl acetate and lead citrate.

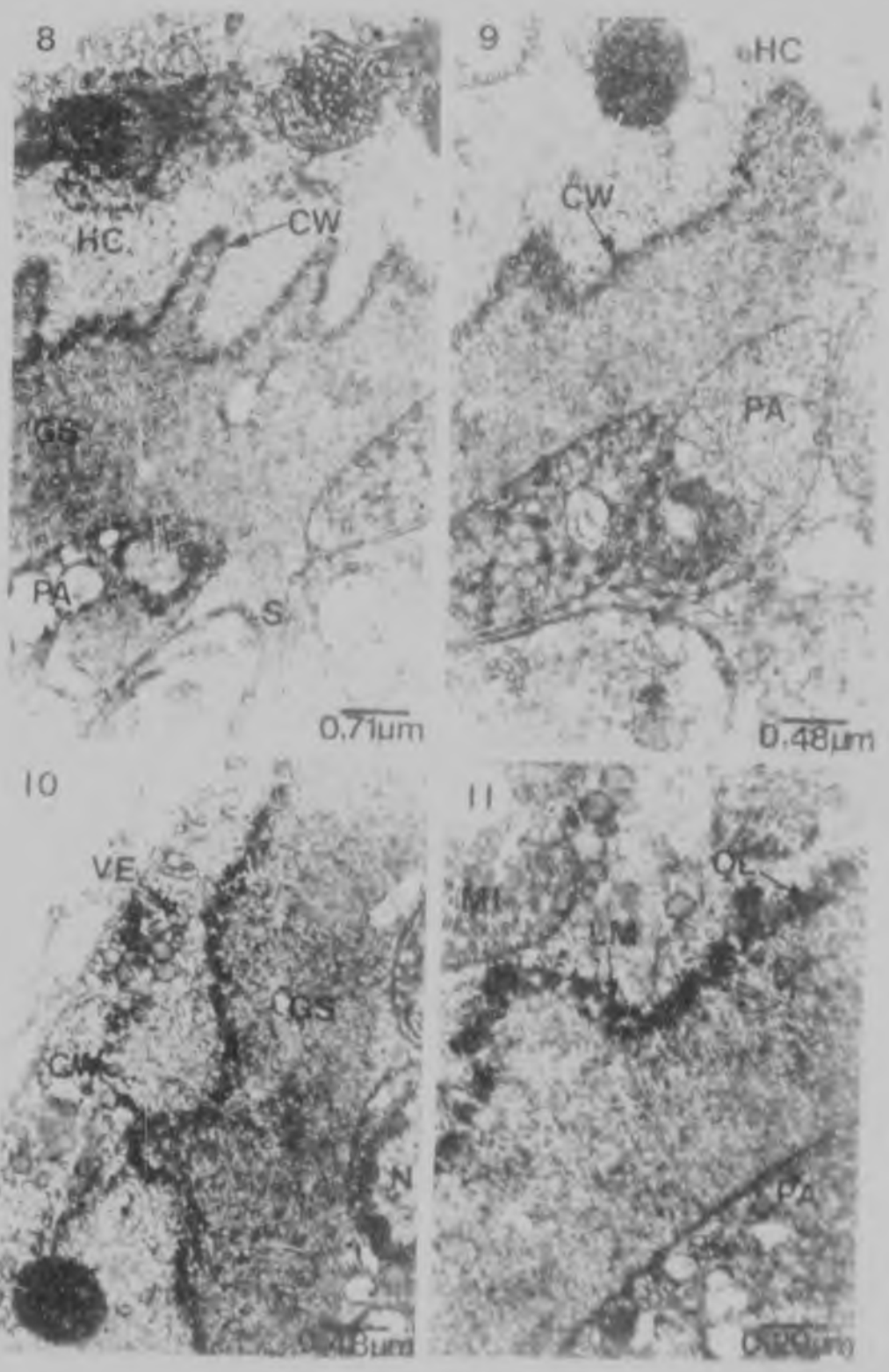

FIGURES 8 to 11. Ultrastructural details of Sarcocystis of a night heron Nycticorax nycticorax, showing the undulating cyst wall (CW). Small pockets are formed by the limiting membrane (LM). Vesicles (VE) occur in the host cell (HC) as a response to the presence of the cyst. Fixation: formal-saline after freezing and thawing. Stain: uranyl acetate and lead citrate.

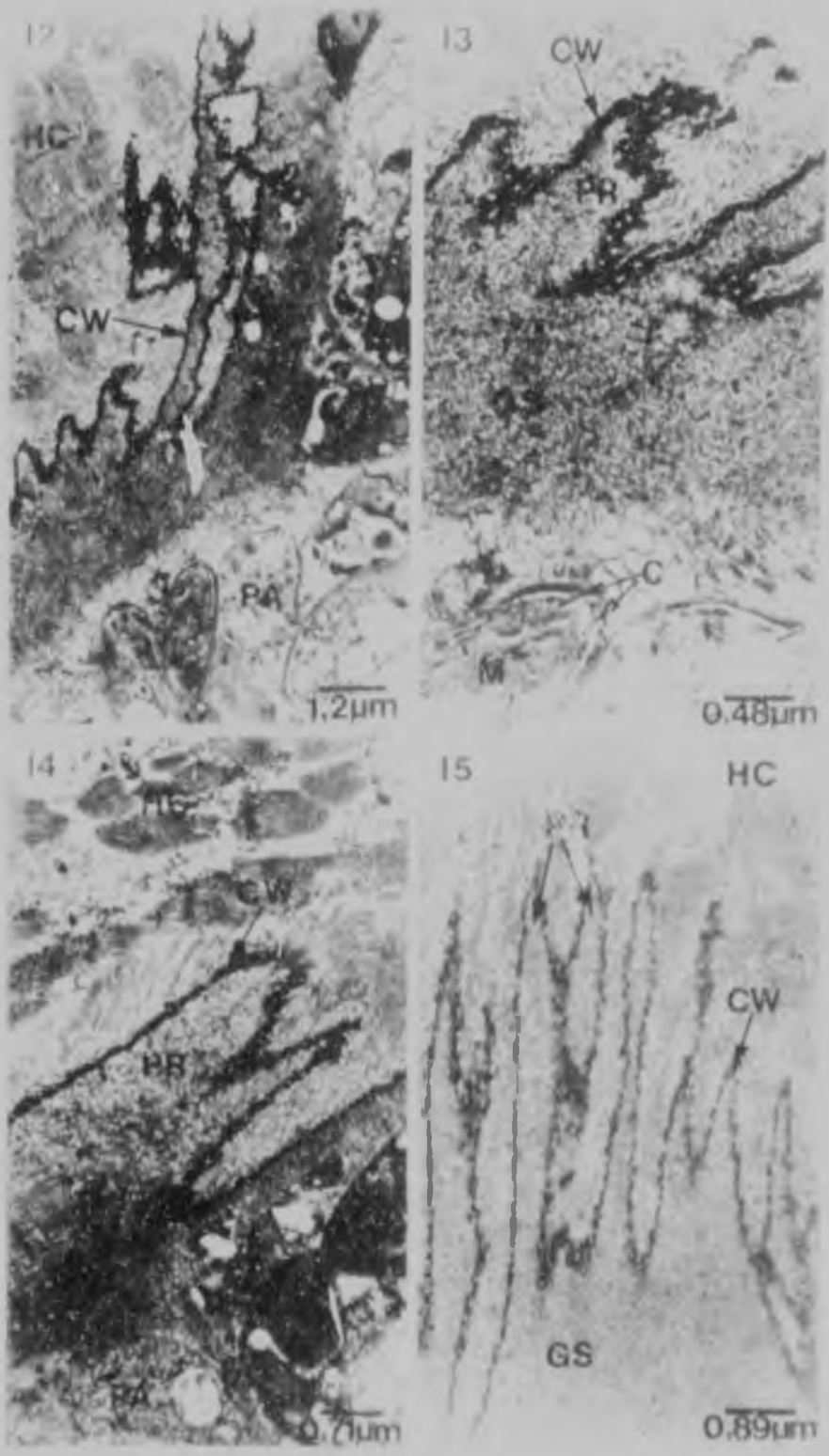

FIGURES 12 to 15. *Sarcocystis* sp., showing irregular cyst wall protrusions (PR), from a little egret *Egretta garzetta*. The ground substance (GS) extends into the cyst to form septa (S). Conoids (C) are apparent anteriorly in cystozoic merozoites (M). Fixation: formol-saline after freezing and thawing. Stain: uranyl acetate and lead citrate.

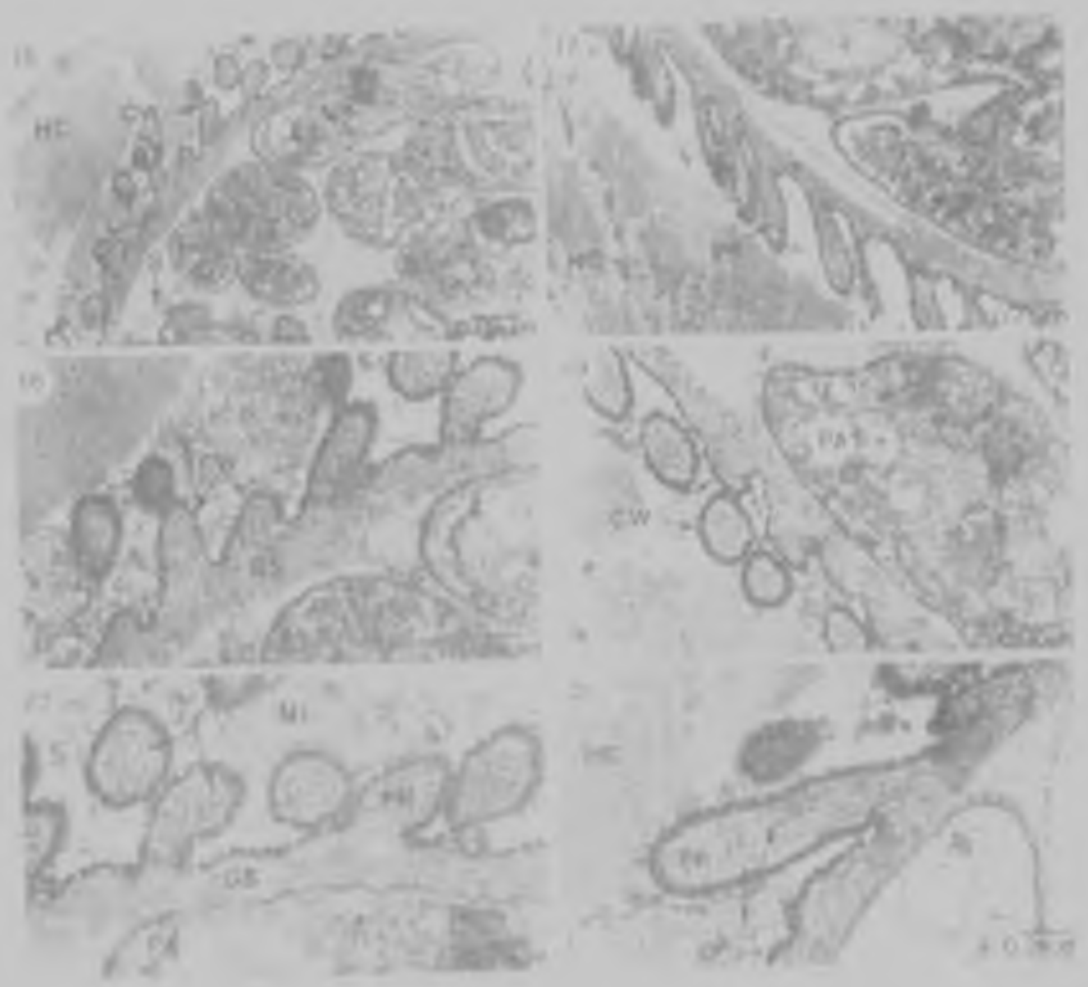

FIGURES 16 to 21. Sarcocystis from a Natal robin Cossypha natalensis. There are fibrillar elements (F) within the cyst wall protrusions (PR). The primary cyst wall (CW) is invaginated. Septa (S) extend from the ground substance (GS) into the cyst. Fixation: formal-saline after freezing and thawing. Stain: uranyl acetate and lead citrate.

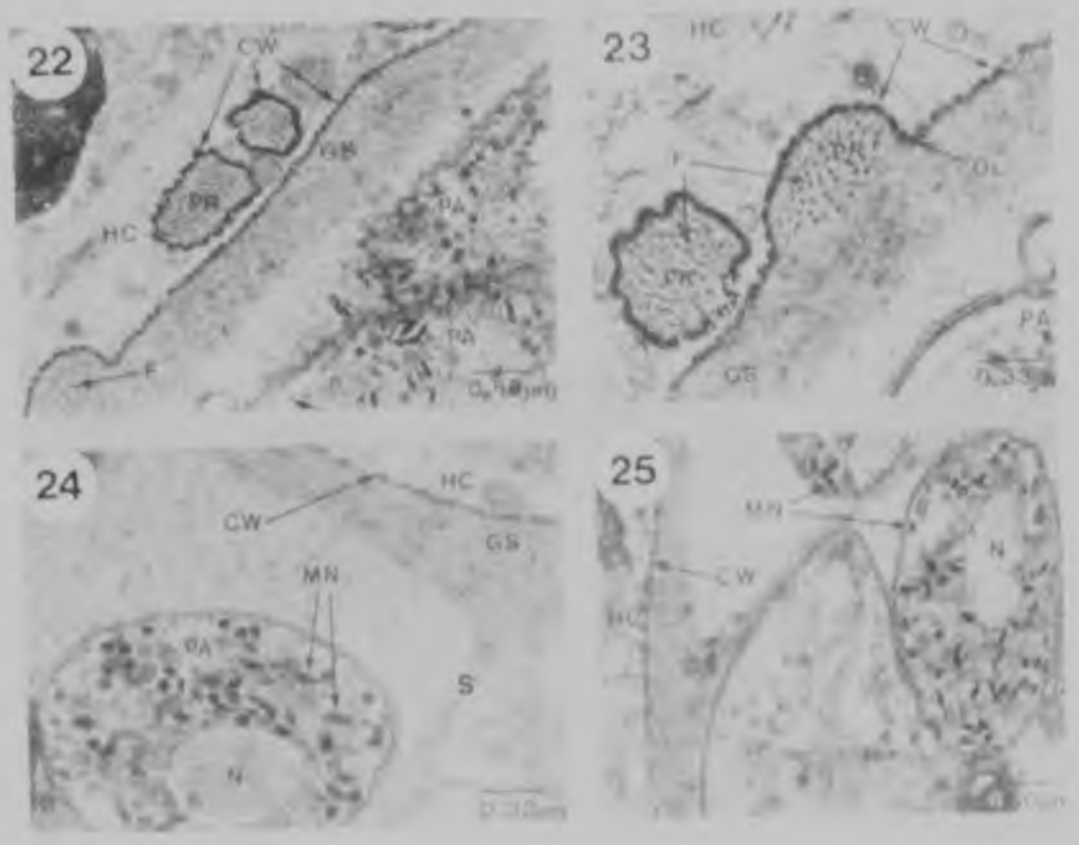

FIGURES 22 to 25. Ultrastructure of Sarcocystis of the spotted dikkop Burhinus capensis. Fibrillar elements (F) can be seen within the cyst wall protrusions (FR). The cyst has an irregular outline because of infoldings of the primary wall (CW). Fixation: formal-saline after freezing and thawing. Stain: uranyl acetate and lead citrate.

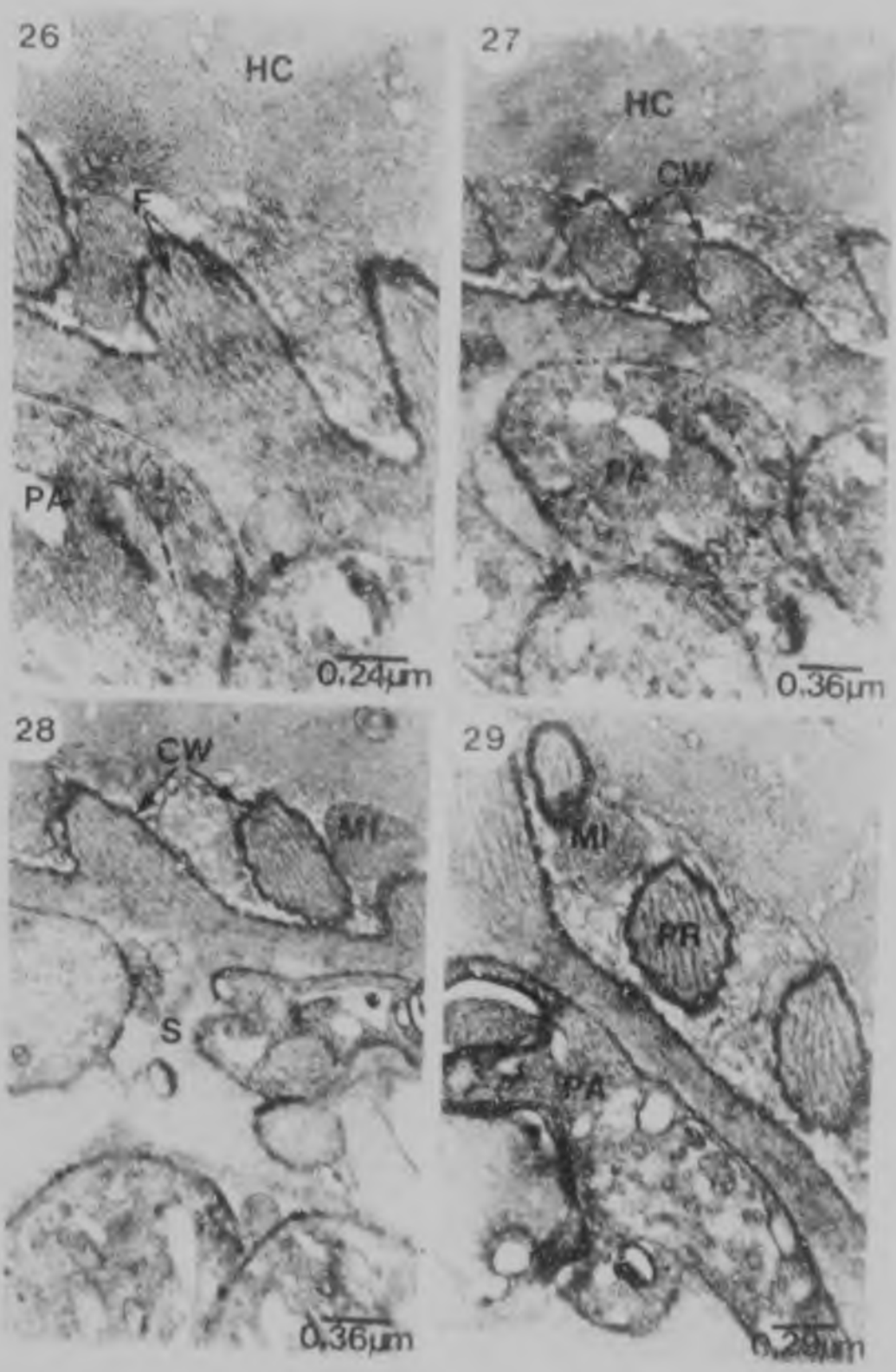

FIGURES 26 to 29. *Sarcocystis* in the lilacbreasted roller *Coracias caudata*; the cysts wall protrusions (PR) contain filamentous elements (F). The primary cyst wall (CW) shows invaginations of the limiting membrane and septa (S) traverse the cyst. Fixation: formal-saline after freezing and thawing. Stain: uranyl acetate and lead citrate.

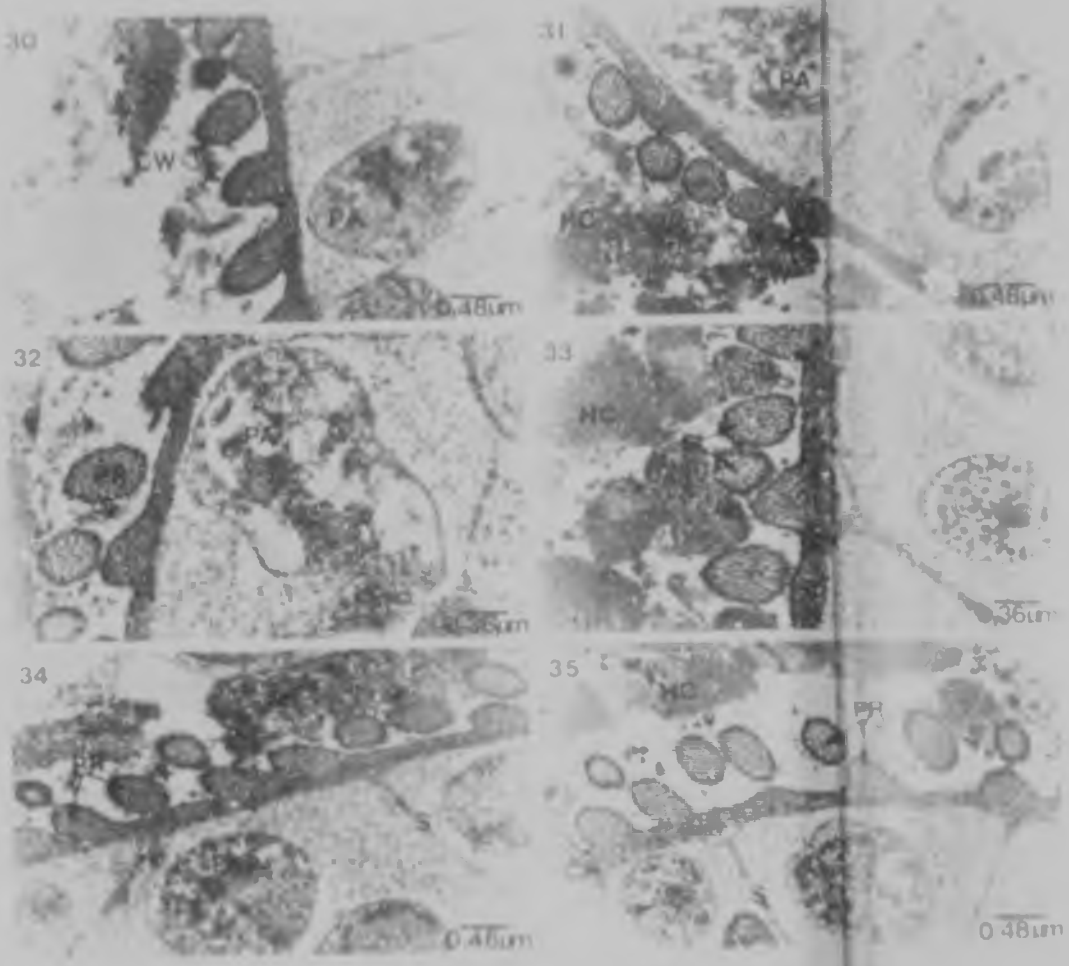

FIGURES 30 to 35. Sarcocystis in the yellowbilled hornbill Tockus flavirostris, showing palisade-like protrusions (PR) of the cyst wall (CW). Septa (S) form chambers which contain the parasites (PA). Fixation: formaldehyde after freezing and thawing. Stain: uranyl acetate and lead citrate. (Examined after storage for more than fifteen years in formalin).

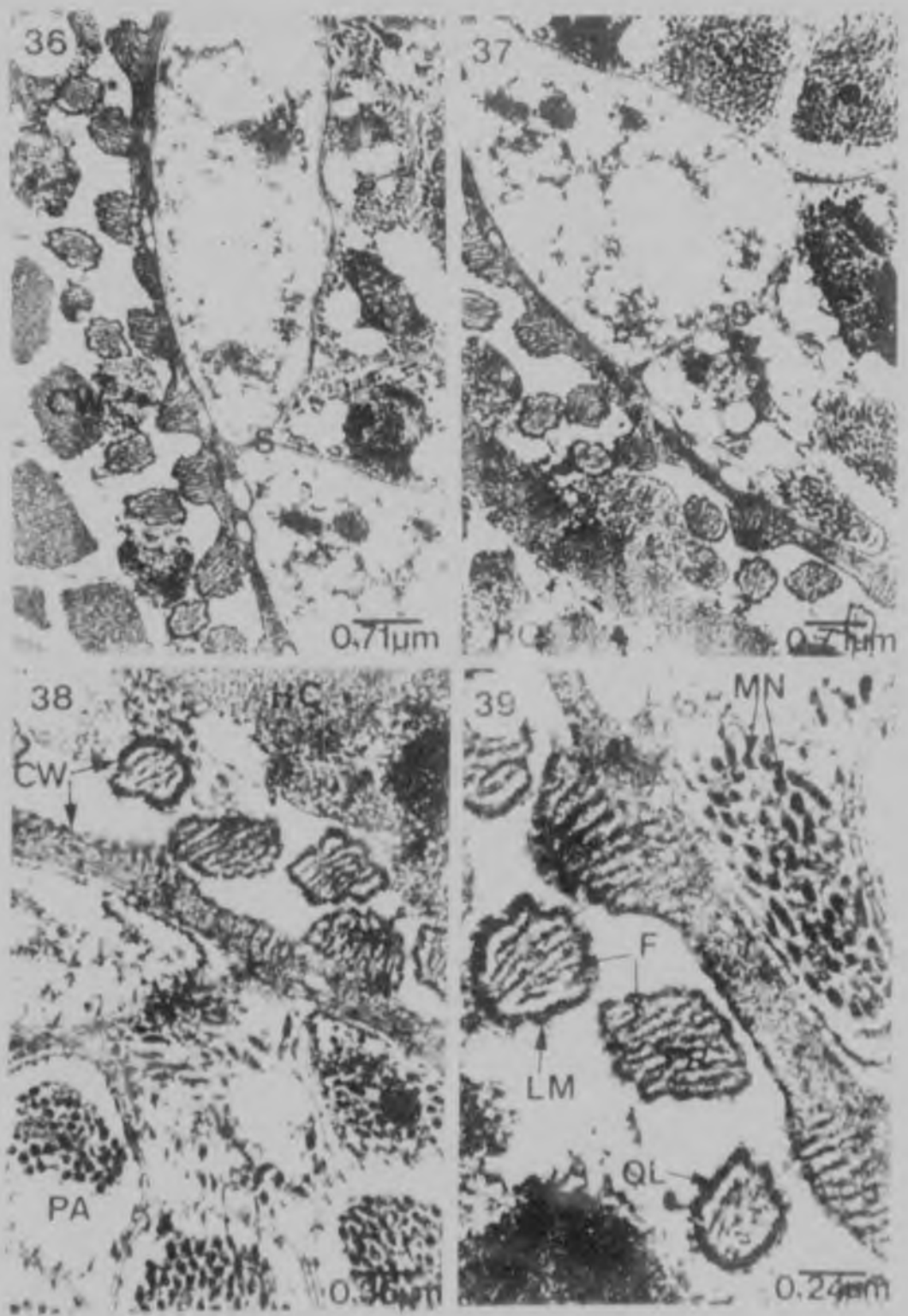

FIGURES 36 to 39. Sections through the periphery of a cyst in skeletal muscle of a redbilled hornbill Tockus erythrorhynchus. The primary cyst wall (CW) has protrusions (PR) into which fibrils (F) extend. Septa (S) traverse the cyst. Fixation: formal-saline after freezing and thawing. Stain: uranyl acetate and lead citrate. (Examined after storage for more than five years in 70 per cent alcohol after fixation in formalin and subsequent injection of glycerine).

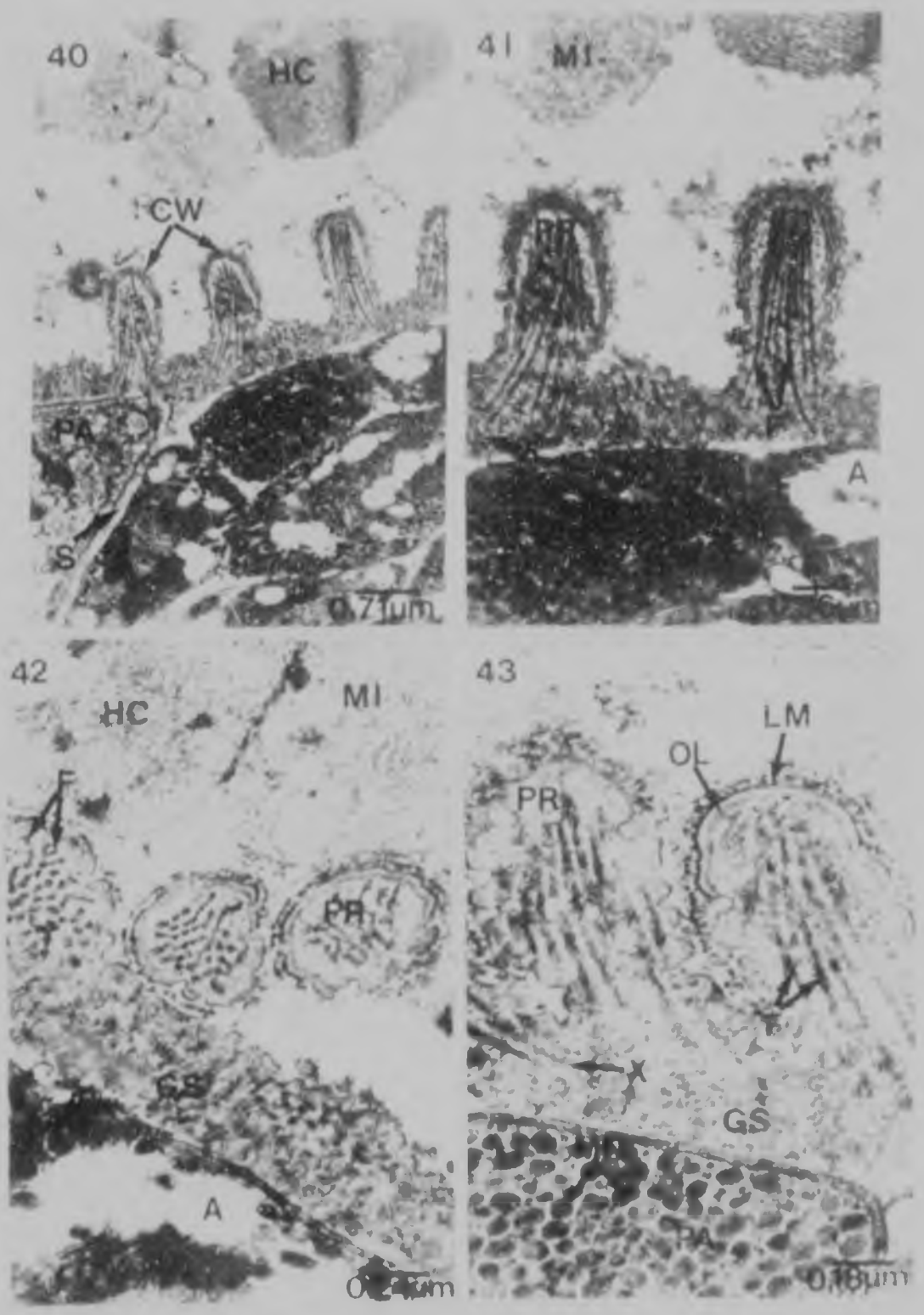

FIGURES 40 to 43. A sarcocyst in the laughing dove Streptopelia senegalensis, located intracellularly in a skeletal muscle fibre (HC). Fibrillar elements (F) within palisade-like protrusions (PR) of the cyst wall are curved at their bases (X). The osmiophilic layer (OL) is apparent between invaginations of the limiting membrane (LM). Fixation: formal-saline (freshly fixed). Stain: uranyl acetate and lead citrate.

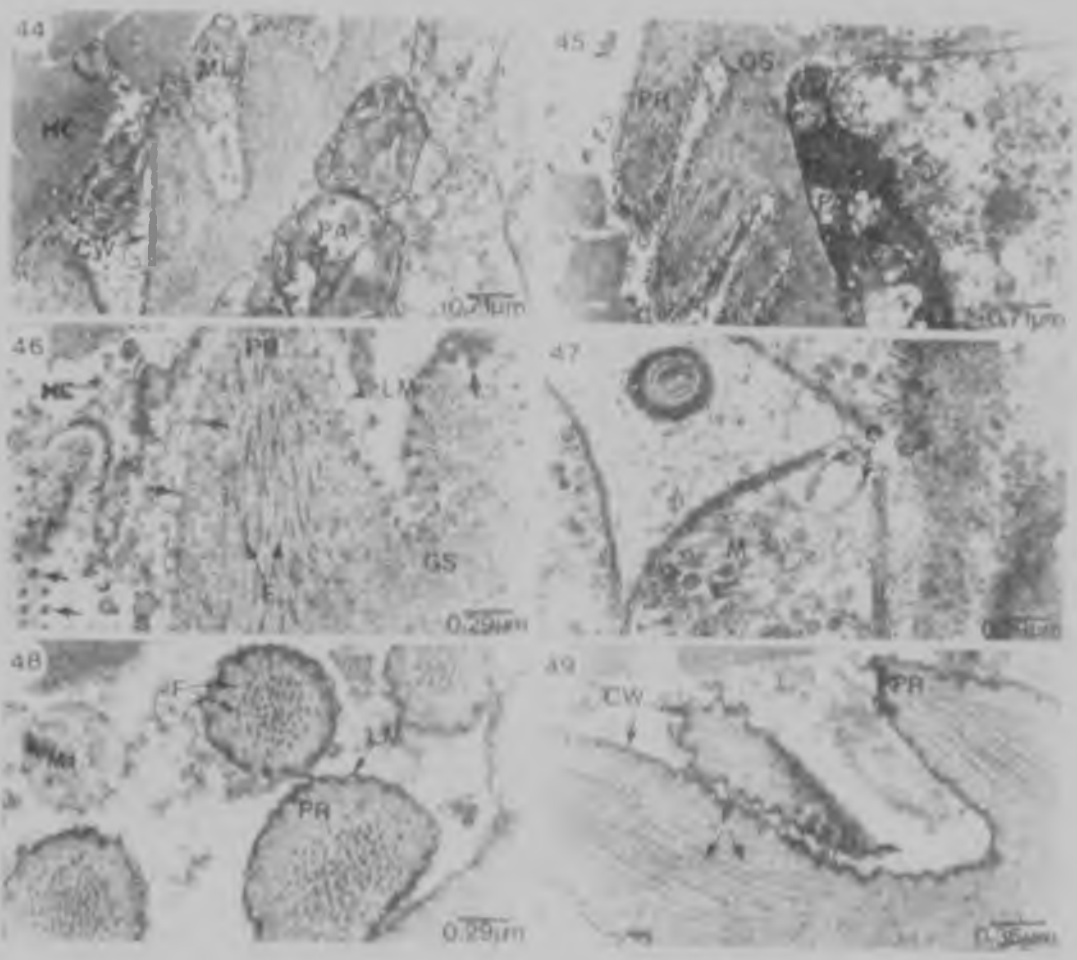

FIGURES 44 to 49. Sections through a sarcocyst in a purple gallinule Porphyrio porphyrio, showing palisade-like projections (PR) of the primary cyst wall (CW), containing fibrillar elements (F). Invaginations (short arrows) of the limiting membrane (LM) appear circular in cross section, with a spot of darkly-staining material in the centre. Fixation: formal-saline after freezing and thawing. Stain: uranyl acetate and lead citrate.

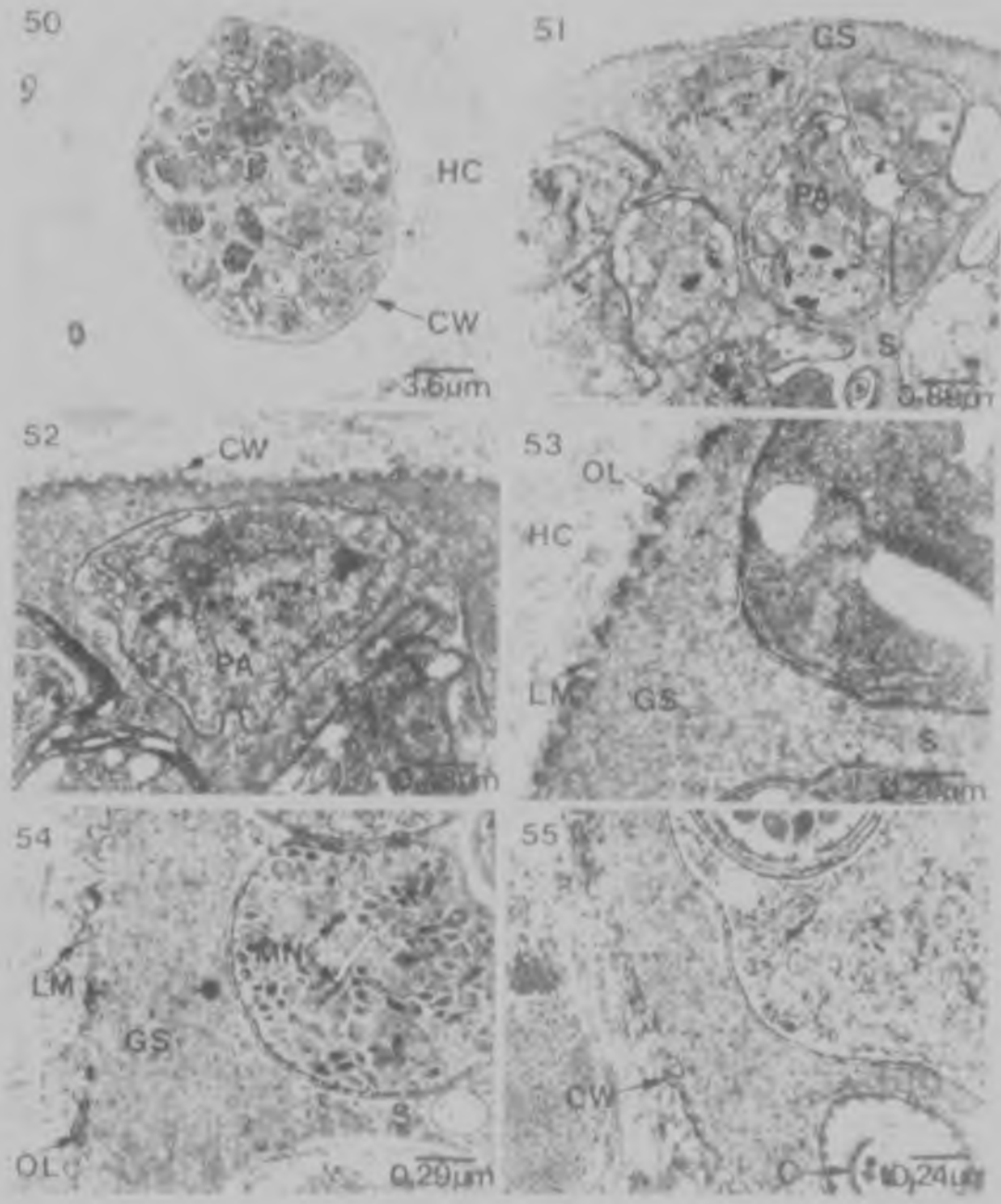

FIGURES 50 to 55. Sarcocystis from a cattle egret Bubulcus ibis. Both the immature cyst (Figures 50 - 53) and the mature cyst (Figures 54 and 55) have a relatively smooth cyst wall (CW). An osmiophilic layer (OL) is present. The limiting membrane (LM) forms vesicular pockets. Parasites (PA) are present in compartments formed by septa (S). Fixation: formal-saline after freezing and thawing. Stain: uranyl acetate and lead citrate.

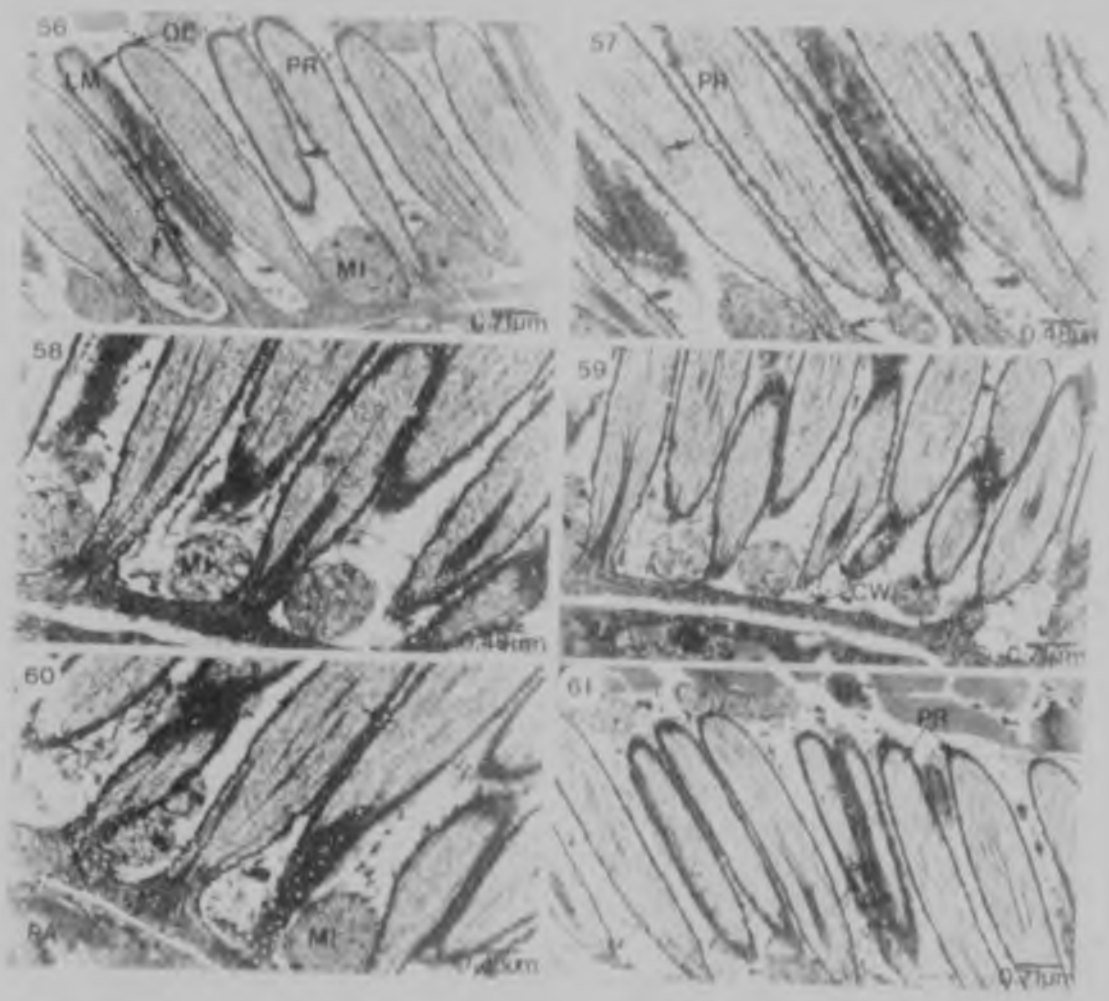

FIGURES 56 to 61. Sections through a sarcocyst of Swainson's francolin Francolinus swainsonii. (For explanation, see caption to Figures 62 to 65).

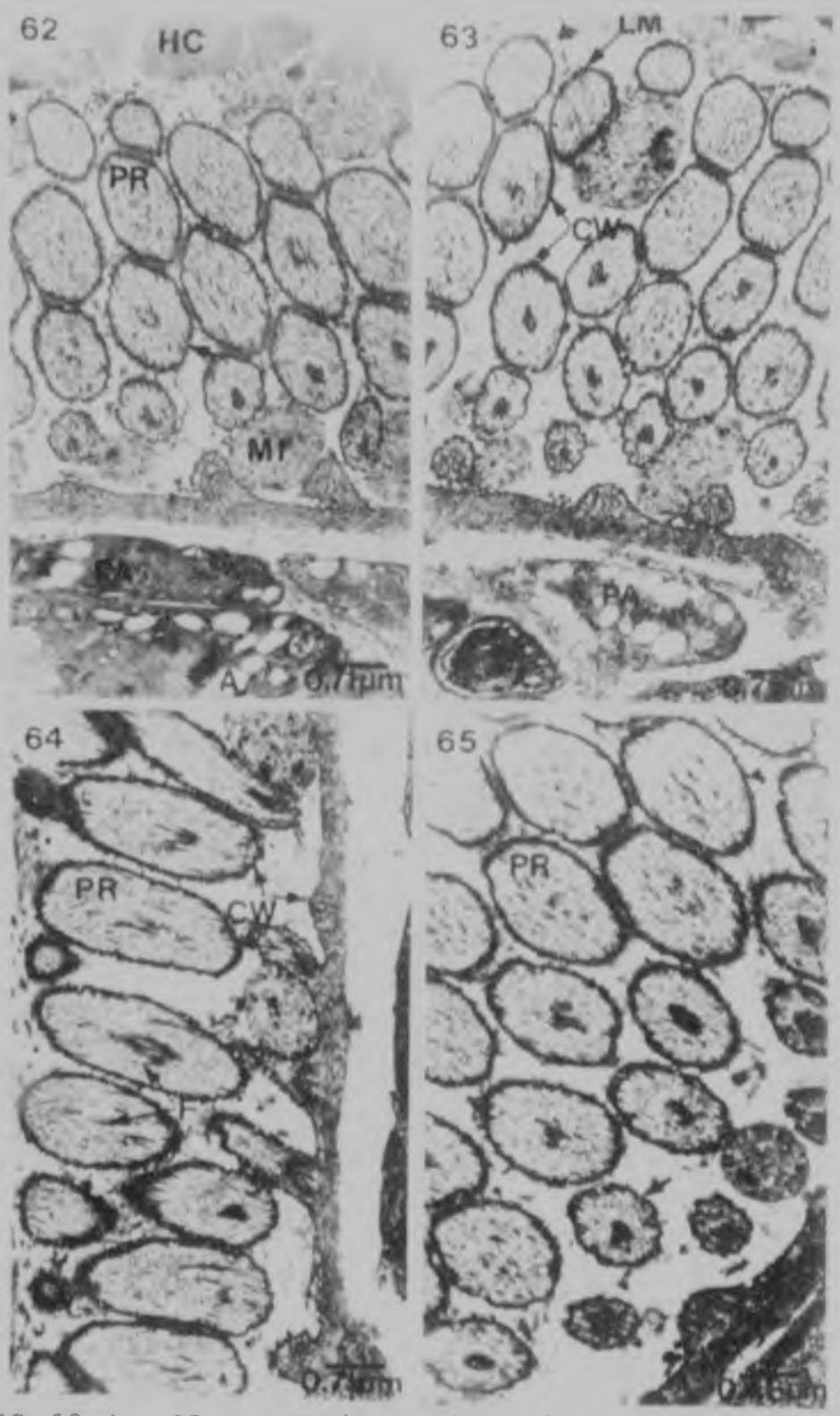

FIGURES 62 to 65. Sections through a sarcocyst of Swainson's francolin Francolinus swainsonii, showing villus-like protrusions (PR) of the primary cyst wall (CW). Filamentous elements (F) extend from the ground substance (GS) into the cyst wall protrusions. Invaginations (short arrows) of the limiting membrane (LM) appear circular in cross section, with a spot of darkly-staining material in the centre. Fixation: forma -saline (freshly fixed). Stain: uranyl acetate and lead citrate.



FIGURE 66. Macroscopic cysts (white arrows) in the skeletal muscle of a redbilled teal Anas erythrorhyncha.



FIGURE 67. Macroscopic cyst (white arrow) in the skeletal muscle of a redbilled teal Anas erythrorhyncha.

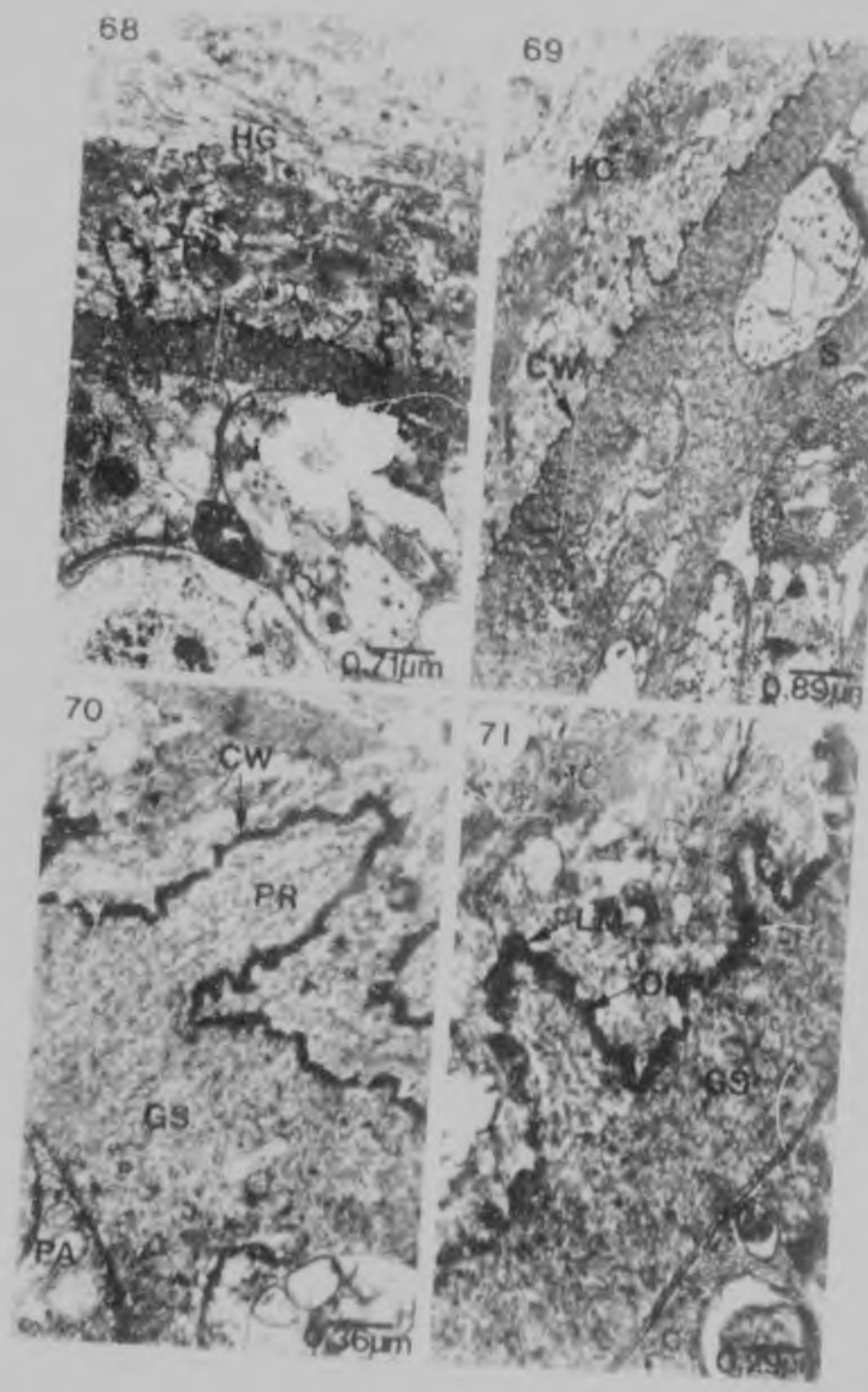

FIGURES 68 to 71. Ultrastructural details of Sarcocystis of a redbilled teal Anas erythrorhyncha. The primary cyst wall (CW) has palisade-like protrusions (PR) at irregular intervals. Septa (S) compartmentalise the cyst. Fixation: glutaraldehyde after freezing and thawing. Stain: uranyl acetate and lead citrate.

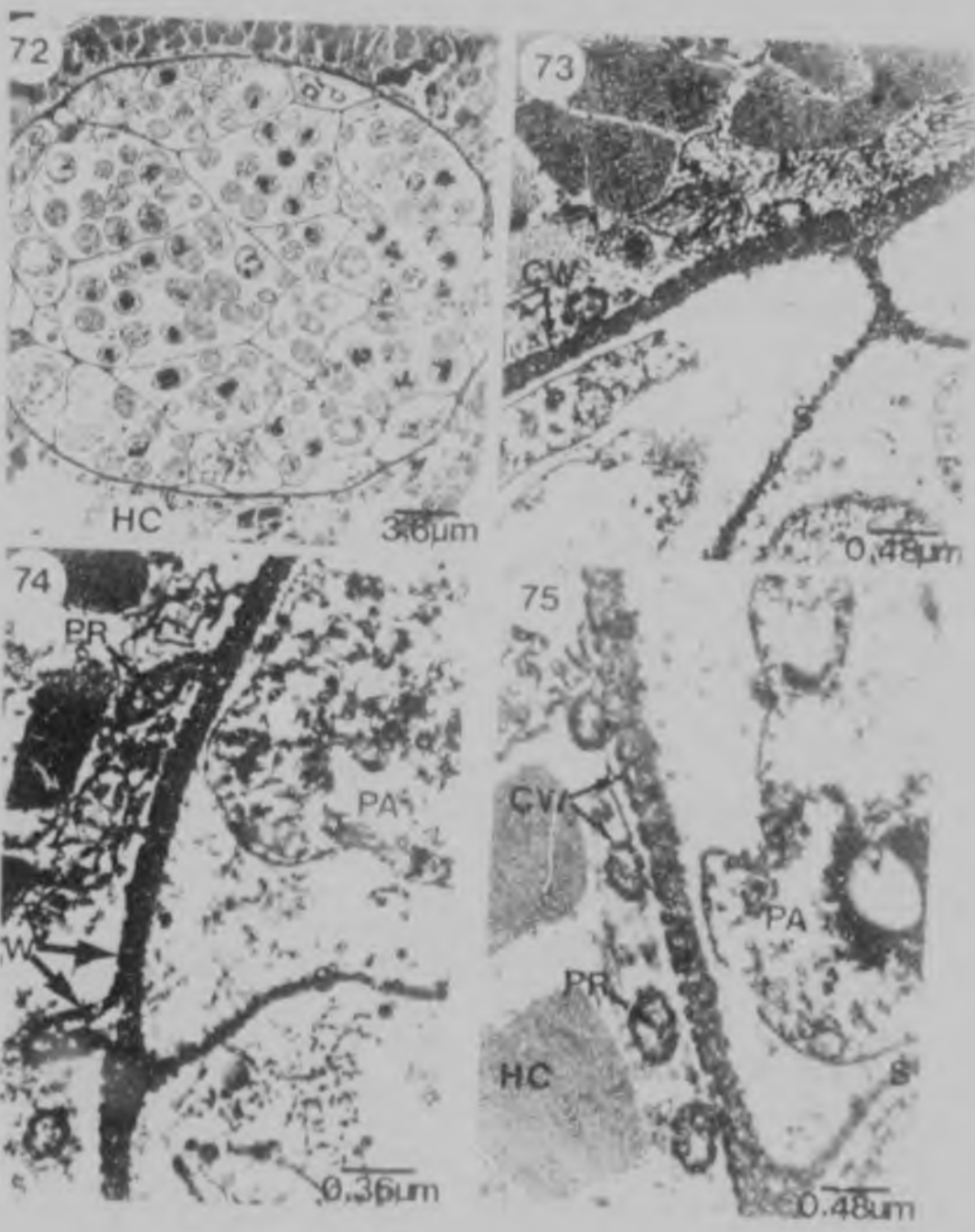

FIGURES 72 to 75. Electron micrographs of Sarcocystis in the Cape glossy starling Lamprotornis nitens. Protrusions (PR) extend from the cyst wall (CW) and septa (S) are visible. Fixation: formaldehyde after freezing and thawing. Stain: uranyl acetate and lead citrate. (Examined after storage for more than fifteen years in formalin).

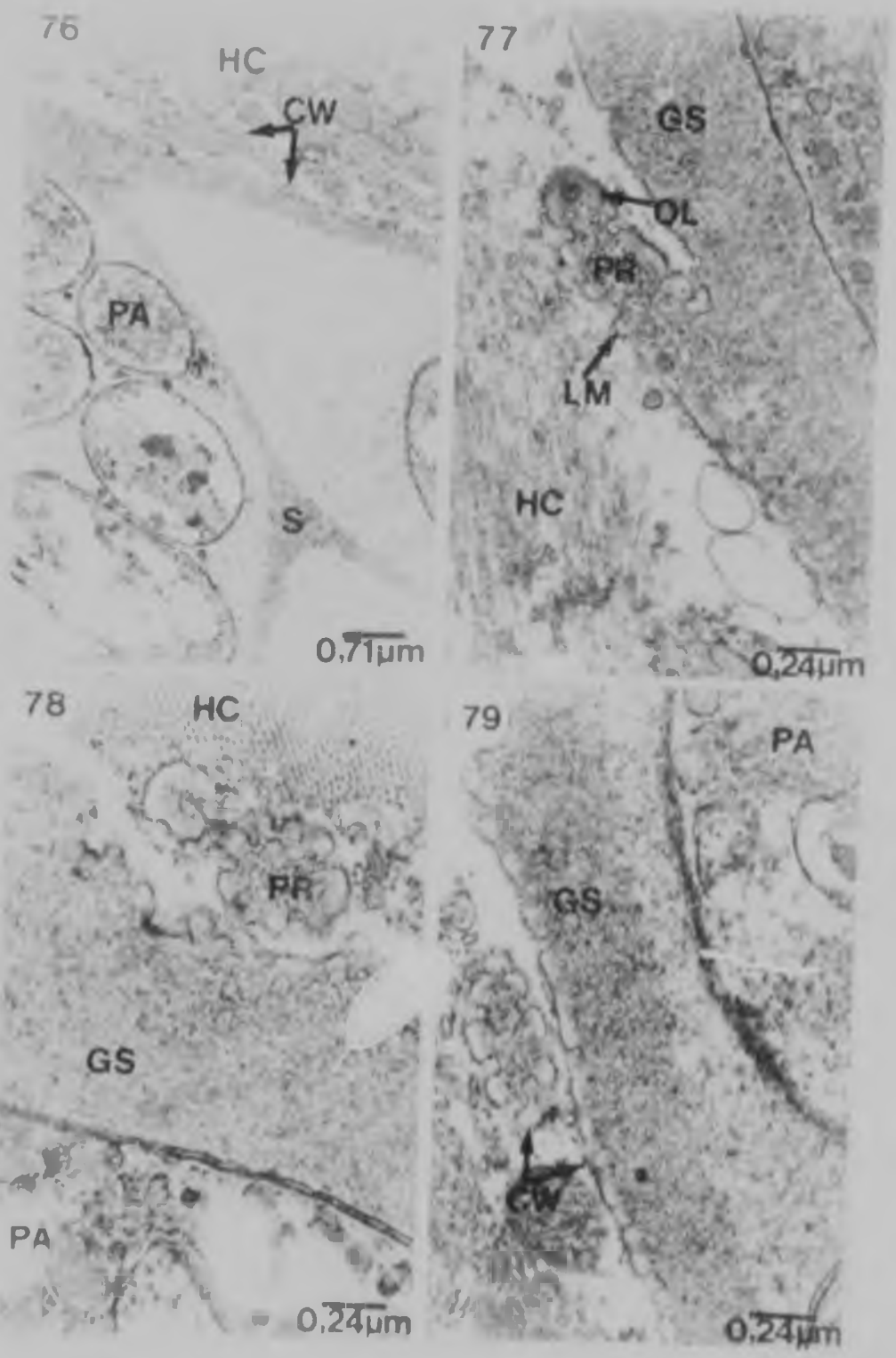

FIGURES 76 to 79. Sections through the periphery of a sarcocyst from Burchell's glossy starling Lamprotornis australis. Protrusions (PR) occur along the cyst wall and invaginations of the outer membrane (LM) form vesicular pockets. Fixation: formal-saline (freshly fixed). Stain: uranyl acetate and lead citrate.

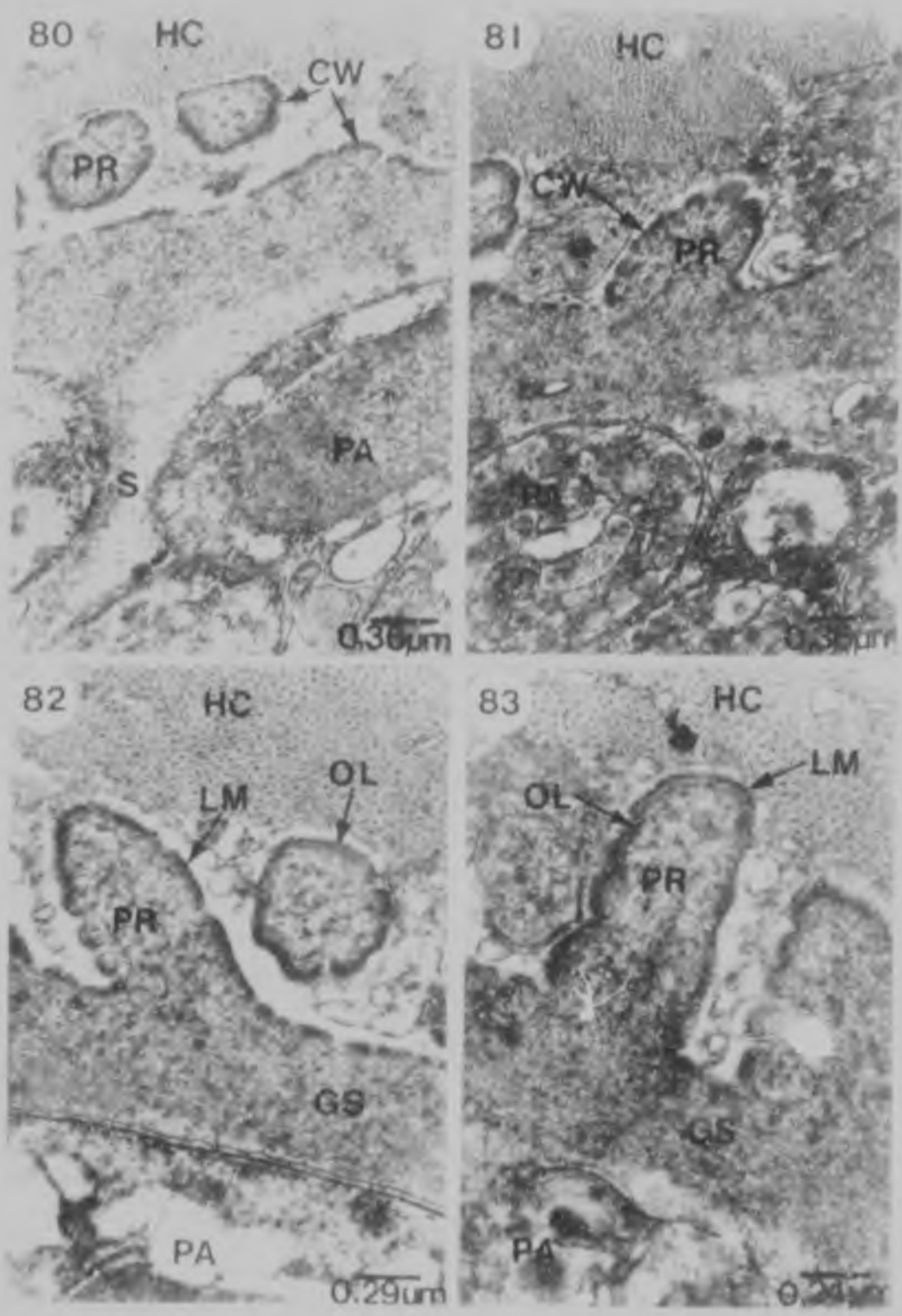

FIGURES 80 to 83. *Sarcocystis* from a yellowbilled egret *Egretta intermedia*. Protrusions (PR) of the cyst wall are evident, and an osmiophilic layer (OL) is found. Fixation: formal-saline after freezing and thawing. Stain: uranyl acetate and lead citrate.

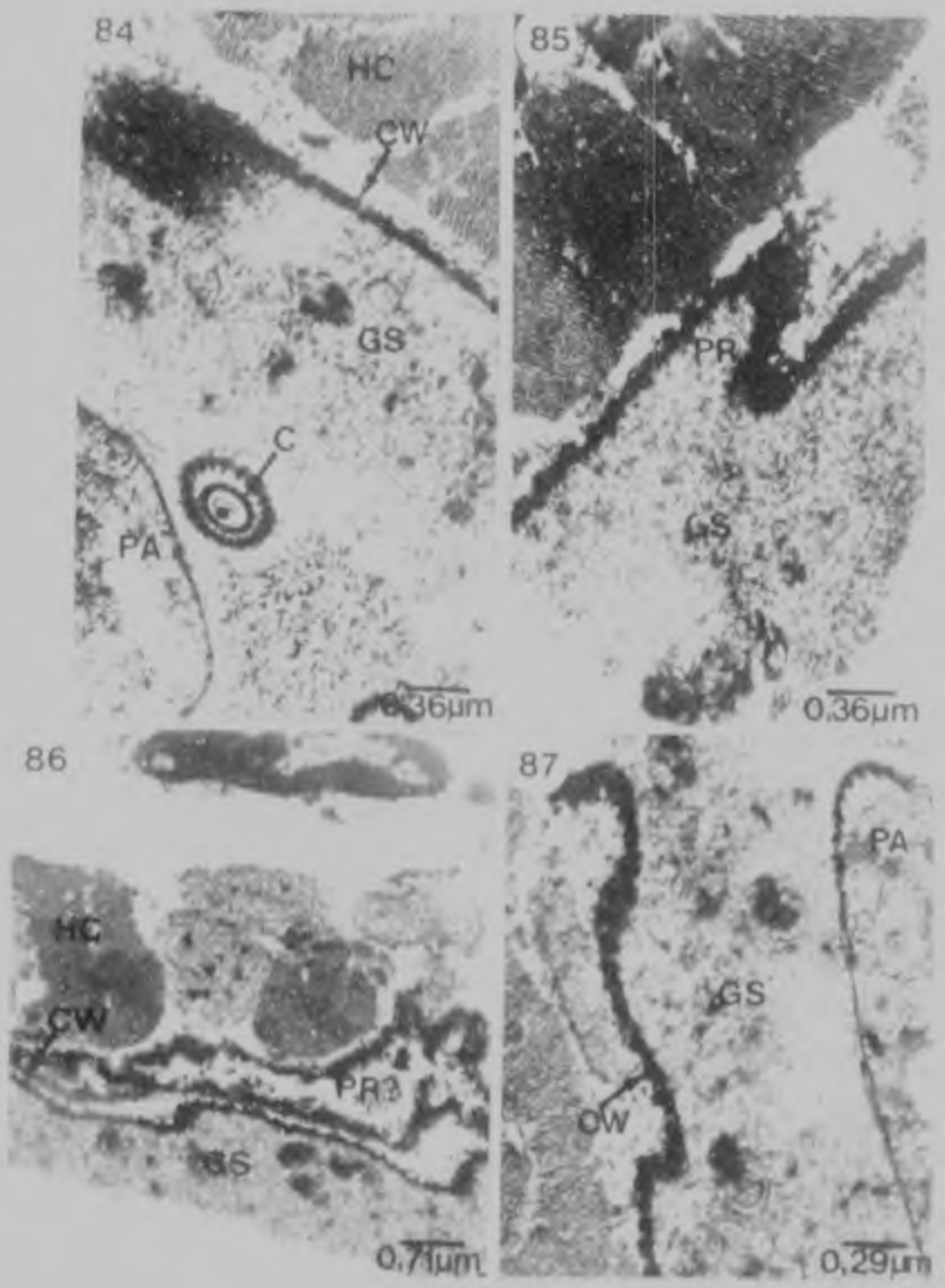

FIGURES 84 to 87. *Sarcocystis* from a subantarctic skua *Catharacta antarctica*. It is not clear whether the structure seen in Figure 86 (PR?) is a section through a protrusion. Fixation: formal-saline after freezing and thawing. Stain: uranyl acetate and lead citrate.

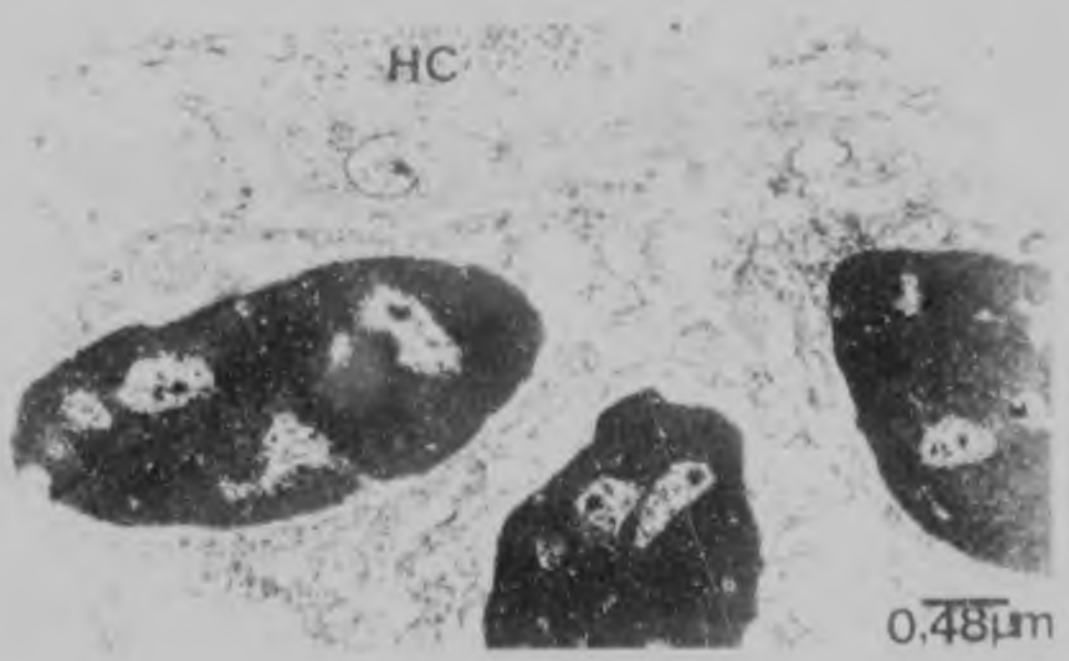

FIGURE 88. Section through an elongated nodule located in the skeletal muscle of an immature speckled mousebird Colius striatus. (Macroscopically, the structure looked like a cyst of Sarcocystis). Fixation: glutaraldehyde after freezing and thawing. Stain: uranyl acetate and lead citiate.



FIGURE 89. Section through skeletal muscle of a juvenile masked weaver Ploceus velatus, showing the Sarcocystis-like appearance of certain muscle fibres at low magnification. Fixation: formal-saline after freezing and thawing. Stain: uranyl acetate and lead citrate.

DISCUSSION

Sarcocystis has not hitherto been reported from 10 of the 20 families in which it was found during the course of the present investigation. These 10 families are the Procellariidae, Burhinidae, Tytonidae, Apodidae, Halcyonidae, Coraciidae, Bucerotidae, Laniidae, Malaconotidae and Sturnidae. Cysts have previously been recorded from 10 of the 20 families in which they were found in the present study, namely the Ardeidae, Plataleidae, Anatidae, Phasianidae, Rallidae, Laridae, Columbidae, Cuculidae, Strigidae and Turdidae (Kalyakin and Zasukhin, 1975; Drouin and Mahrt, 1979; Munday et al., 1979; Wenzel, 1981). Sarcocystis has been observed in the musculature of birds belonging to a number of other families in which it was not found by the present author, namely the Phalacrocoracidae, Accipitridae, Falconidae, Charadriidae, Scolopacidae, Psittacidae, Upupidae, Coliidae, Picidae, Hirundinidae, Oriolidae, Corvidae, Sylviidae, Muscicapidae, Zosteropidae, Ploceidae and Fringillidae (Kalyakin and Zasukhin, 1975; Drouin and Mahrt, 1979; Munday et al., 1979; Wenzel, 1981).

Judging from the results of Drouin and Mahrt (1979), it appears that a fairly reliable diagnosis of Sarcocystis

infection can be made on the basis of examination of three muscle samples from each bird, this being the procedure adopted here for southern African birds. Drouin and Mahrt (1979) screened 125 duplicate muscle samples histologically; 121 of these samples gave the same result as for the original muscle specimens.

In the present study, heart muscle was not initially screened in addition to skeletal muscle from each bird as too many individuals were due to be examined for this to have been feasible in terms of time. Furthermore, many of the birds obtained as road kills were decomposing; and this would have made the task of opening the body cavity unpleasant.

Source of infection

Birds belonging to most of the families in which Sarcocystis has been found, feed to a greater or a lesser extent on insects; exceptions being the Procellariidae and the Laridae, which are mainly scavengers, and the Tytonidae which capture, inter alia, rodents (McLachlan and Liversidge, 1978). Most of the birds concerned also spend a certain amount of time on the ground. Faecal contamination from infected carnivores must cause widespread dissemination of Sarcocystis sporocysts in the environment, making them available to birds which feed on the ground.

Arthropods congregating at sites of faecal deposition might attract ground-feeding birds which could perhaps become infected by accidentally ingesting sporocysts in the vicinity or by feeding on insects to which sporocysts are adhering. Temporary transport hosts such as flies, beetles, other arthropods and earthworms may convey sporocysts to other sites (Markus, 1974). It has been shown experimentally that cockroaches can carry sporocysts of Sarcocystis muris in the laboratory (Smith and Frenkel, 1978). Markus (1980) has found that flies transport sporocysts under natural conditions after visiting carrier dog faeces and disperse these infective stages in the vicinity of cattle and elsewhere.

Further evidence that insects may be natural transport hosts of Sarcocystis was provided by the finding of sarcocysts in the whiterumped swift. Swifts feed exclusively on insects caught on the wing. If flies, for example, carrying sporocysts from carnivore faeces were to be ingested, the parasite could be transmitted. The alternative source of infection for swifts is the water they drink by skimming the surface; however, depending on the quantities of dissolved salts present, this might only be likely to occur if the water was disturbed, since the sporocysts would normally sink to the bottom.

Arboreal species may acquire infection while collecting

nesting material. The higher frequency of Sarcocystis infection in female wild grackles compared to that in males could perhaps be explained by the fact that females are often responsible for nest building (Fayer and Kocan, 1971).

Sarcocystis has been reported a number of times from the Anatidae (Kalyakin and Zasukhin, 1975; Drouin and Mahrt, 1979). Hoppe (1976) recorded a high frequency of macroscopic sarcocysts from dabbling ducks, whilst no diving ducks were infected. This suggests that faecal transmission of Sarcocystis of waterfowl occurs, because dabbling ducks feed in shallower wetlands and even upland regions, and would be more likely to ingest faecal material of other animals than would divers. This suggestion is perhaps supported by the present study in which a redbilled teal, which favours shallow temporary water and flooded grasslands (McLachlan and Liversidge, 1978), was found to harbour macroscopic cysts. It is surprising that no cysts were found in the other dabbling waterfowl, comprising mainly spurwing geese Plectropterus gambensis and Egyptian geese Alopochen aegyptiacus. However, this may be explained by the fact that these geese feed to a large extent away from water in open fields, where there is less chance of a concentration of viable sporocysts occurring than in shallow water. Also, the sample of dabbling ducks examined by the present author

(whitefaced duck Dendrocygna viduata, Egyptian geese, redbilled teal, pintail, spurwing geese and maccoa duck Oxyura maccoa) was small. A further 21 waterfowl did not contain macroscopic sarcocysts when they were examined, but since these birds were not checked microscopically, it cannot be stated with certainty that cysts were not present.

The absence of cysts in juvenile and immature southern African birds is a finding similar to that of Chabreck (1965) who reported that only 0,4 per cent of immature ducks were infected with Sarcocystis. None of the juvenile birds examined by Fayer and Kocan (1971) and Drouin and Mahrt (1979) harboured muscular cysts. Munday et al. (1979) did not distinguish between immature and adult birds in their prevalence data, but they explain the low percentage of infection of waterfowl by the fact that many of the birds examined were very young. The absence of muscular cysts in juvenile and immature birds may be explained by the shorter period which these birds have had to come in contact with sporocysts; and the time required for sarcocysts to develop in muscle cells following ingestion of sporocysts.

Predatory intermediate hosts

It has been thought that carnivores, which are final hosts of many species of Sarcocystis, rarely harbour

sarcocysts in their muscles. However, Markus and Daly (1980) found that muscular sarcocystosis is common in various carnivorous mammals in South Africa. Similarly, there have been several reports of Sarcocystis in the musculature of predatory birds (Kalyakin and Zasukhin, 1975; Munday et al., 1979; Crawley et al., 1982). Sarcocysts were, likewise, found in the present study in the barn owl and in the spotted eagle owl. This is further evidence that extra-intestinal Sarcocystis infection is not unusual in the avian final host. Fundamental revision of our current concept of the life-cycle of Sarcocystis would be required should it be shown that both intestinal and extra-intestinal infection can be caused in the same host species by a particular species of Sarcocystis (Markus and Daly, 1980).

Site specificity

The distribution of muscle cysts in birds has been found to vary between species. Fayer and Kocan (1971) found that in 91 great-tailed grackles infected with Sarcocystis, both males and females had heavier infections in the leg and thigh muscle than in breast muscle; tongue and heart muscle did not contain Sarcocystis. Sarcocystis infection occurred only in pectoral muscle of a blue and yellow macaw Ara ararauna, whilst a Tovi-parakeet Brotogeris jugularis contained large numbers of cysts in all cross-striated

muscle; muscle of the tongue, myocardium and connective tissue around the origin of the aorta also harboured cysts (Borst and Zwart, 1973). Box and Duszynski (1977) reported that in b[illegible]nhead[illegible]d cowbirds, cysts were more common in the upper and lower leg and back muscle, and no cysts were seen in heart muscle. Drouin and Mahrt (1979) found that seven out of 112 birds had sarcocysts in skeletal muscle but no cysts were present in the myocardium. Site specificity tests on a red-[illegible]nged blackbird and a yellow-headed blackbird showed [illegible]t sarcocysts were evenly distributed throughout the skeletal musculature, with no cysts pre[illegible]nt in the myocardium (Drouin and Mahrt, 1979). Garnham et al. (1979) described a new species of Sarcocystis (although it is not certain that this is the generic identity of the organism) from the brains of two presumably unrelated tropical birds (one was not identified). Munday et al. (1979) found that sarcocysts in a southern skua, two white-backed magpies and a hoary-headed grebe occurred only in the myocardium, and Crawley et al. (1982) reported numerous sarcocysts in the myocardium of a bald eagle. Sarcocysts have also been reported in the myocardium of a redfaced mousebird (Fantham, 1913), a hawk (Darling, 1915), a pintail (Erickson, 1940), a great blue heron Ardea herodias (Clark, 1958), snow geese and Ross's geese (Wobeser et al., 1981). In all instances in the present study, cysts were located in the [illegible]ectural

muscle, and this was usually the preferred site. However, Sarcocystis in both spotted dikkops examined for the site specificity of Sarcocystis showed a distinct preference for wing muscle. Cysts were not located in the heart or the brain in the present investigation, except in the case of a spotted eagle owl, which had at least one cyst in the brain. However, the low intensity of infection in the brain of the spotted eagle owl did not make identification by means of electron microscopy possible. Consequently, the generic identity of the cyst remains in doubt.

Final hosts

Levine and Tadros (1980) listed 12 named species of Sarcocystis of birds but the definitive hosts of most are unknown. Muscle cells of canaries became infected when the birds were fed sporocysts from faeces of naturally infected European sparrowhawks (Ashford, 1975). Experiments carried out by Duszynski and Box (1978) with various carnivores and omnivores showed that only the opossum was a suitable definitive host for sarcocysts obtained from cowbirds and grackles. Sarcocystis horvati was successfully transmitted from chickens to dogs and cats (Golubkov, 1979; Wenzel, 1981; Wenzel et al., 1982) and S. rileyi from geese to dogs and cats (Golubkov, 1979). Cysts from a ring-necked pheasant were successfully transmitted to a dog (Wenzel, 1981). Cawthorn et al. (1981) and Wicht

(1981) reported transmission of S. rileyi to the striped skunk when the latter was fed infected muscle from the wild shoveler. The skunk, therefore, served as a definitive host for S. rileyi. Sporocyst production was good: this suggests that the striped skunk is a main host for waterfowl Sarcocystis. Sporocysts collected from masked owls Tyto novaehollandiae produced sarcocysts in rats, but not mice (Munday, 1983). Birds could be the intermediate hosts of sporocysts from masked owls which are not infective to rats or mice.

Transmission experiments were not carried out during the course of the present study because no intermediate hosts which were consistently infected with Sarcocystis were available for experimental work. Attempts to use a spotted dikkop were unsuccessful as none of the fresh birds obtained from the S.P.C.A. bird hospital proved to be infected. The redbilled teal which had macroscopic sarcocysts could have served as a source of material for experimental use but the bird concerned had unfortunately been accidentally deep-frozen by the donor.

Electron microscopy

The ultrastructure of the cyst wall is characteristic for each species of Sarcocystis and frequently provides the only means of distinguishing between them (Daly and

Markus, 1980). However, morphology alone cannot be used conclusively for specific identification since similar types of primary wall can be present in different Sarcocystis species (Mehlhorn et al., 1976). It is clear from light microscopic studies that a given bird species may sometimes harbour more than one cyst type concurrently (Drouin and Mahrt, 1980; Wobeser et al., 1981). Electron microscopy is necessary to determine the ultrastructural characteristics of a cyst wall, since species which look identical by light microscopy may, in fact, be found to differ at the fin_ structural level.

Only six species of avian Sarcocystis have previously been studied under the electron microscope (although the organism(s) examined by Garnham et al. (1979) may have been Sarcocystis). Mehlhorn et al. (1976) published details of Sarcocystis in a domestic fowl and a wild grackle; Tadros and Laarman (1978) examined the wall of Sarcocystis of a plush-crested jay; Kaiser and Markus (1981) described the morphology of the wall of Sarcocystis from a spotted dikkop and Wobeser et al. (1981) examined the walls of two types of Sarcocystis occurring in a snow goose.

Electron microscopy proved useful in establishing that

structures seen macroscopically as white streaks*, and appearing Sarcocystis-like under the light microscope, were not, in fact, Sarcocystis (Figures 88 and 89).

The walls of sarcocysts in the Natal robin, spotted dikkop, lilacbreasted roller, yellowbilled hornbill, redbilled hornbill and laughing dove (Figures 16 - 43) were all similar to that of the cyst from the domestic fowl examined by Mehlhorn et al. (1976). Fibrillar elements occurred within palisade-like protrusions of the primary cyst wall. Wobeser et al. (1981) illustrated a morphologically similar cyst wall, having protrusions of similar dimensions, from a snow goose.

The walls of cysts from the whiterumped swift and the night heron (Figures 2 - 11) were similar to that in a snow goose (Wobeser et al., 1981). Wobeser et al. (1981) apparently included the ground substance in the measurement of the cyst wall, which they gave as being 0,5µm thick. If the ground substance is included in the measurements of the cyst walls of the whiterumped swift and night heron parasites, then the latter walls are of similar thickness to that in the snow goose (0,64µm and 0,4µm, respectively, in a cyst chosen at random from each of the two infected whiterumped

---

* in skeletal muscle of a masked weaver and a speckled mousebird.

swifts; and 0,88µm in the night heron).

The irregularly-shaped cyst wall protrusions in the little egret (Figures 12 - 15) were similar to those found in a plush-crested jay (Tadros and Laarman, 1978). However, the wall projections in the plush-crested jay contained bundles of fibrils; the latter did not occur in the little egret. In both cases the ground substance was coarsely granular, but scattered vesicles which occurred in the ground substance of the plush-crested jay parasite were not seen in the little egret. It is not certain whether the cyst from a subantarctic skua (Figures 84 - 87) can be included in this category.

The types of cyst walls found in the purple gallinule (Figures 44 - 49), cattle egret (Figures 50 - 55), Swainson's francolin (Figures 56 - 65) and redbilled teal (Figures 68 - 71) have not previously been seen by electron microscopy in any avian species.

The cyst type found in Burchell's glossy starling (Figures 76 - 79) and the yellowbilled egret (Figures 80 - 83) could belong to a separate category, but if fibrillar elements are present (no firm conclusion was reached on the basis of the material studied), these cysts would be similar to those found in the Natal robin group. Since the age of the cyst from the Cape glossy starling (Figures 72 - 75) cannot be determined

because of degeneration of the contents of the cyst, it is not certain what type of cyst was present in the infected bird.

The type of cyst wall seen in the wild grackle (Mehlhorn et al., 1976) was not seen by electron microscopy in any avian species in the present study. The ends of protrusions of the primary wall in the grackle were bubble-like swellings into which microtubules extended.

Number of avian Sarcocystis species

In the present study, the seven different cyst types distinguished by electron microscopy on the basis of their cyst wall morphology indicate that a number of avian Sarcocystis species have evolved. Further evidence is provided by Kalyakin and Zasukhin (1975), who distinguished approximately 11 species of avian Sarcocystis by light microscopy on the basis of the size of merozoites.

Host specificity

The type of Sarcocystis occurring in the Natal robin has been found in seven families of birds (i.e. including the families to which the domestic hen and snow goose belong) and that found in the whiterumped swift was present in three families of birds (if the

one snow goose cyst described by Wobeser et al. (1981) is included). Although the cyst wall morphology of different species of Sarcocystis may prove to be similar, the findings as regards southern African birds would nevertheless seem to support previous work which showed (experimentally) that at least one species of avian Sarcocystis has a broad intermediate host spectrum (Box and Duszynski, 1978; Box and Smith, 1982).

Many avian host species may be physiologically susceptible to infection with a given species of Sarcocystis since the same cyst type, as judged by the fine structure (and, therefore, possibly the same parasite species), was found in different bird species. Ecological factors may provide a partial explanation for which host species are susceptible: that is, due to differences in feeding ecology, some species may have had more opportunity than others to ingest infective sporocysts and become evolutionarily adapted to particular species of Sarcocystis (if they were not initially susceptible to infection with the parasite species concerned). Box and Duszynski (1978) suggest that a light infection of Sarcocystis may lead to adaptation of a given predator-prey relationship in an "abnormal" host when the infection is sustained over a period of time. Intensification of this relationship between a partially susceptible prey species and the predatory host could widen the spectrum of intermediate

hosts in nature and select for parasites more fully adapted to the prey species in question (Box and Smith, 1982).

Effects of freezing and prolonged fixation on cyst wall ultrastructure

Broad categories of cyst wall types can be distinguished after freezing of dead birds at -20°C; the gross structure of the cyst wall is not affected by this process. This means that muscle samples can be taken at museums from deep-frozen specimens awaiting skinning. The gross features of the cyst wall were also distinguishable even after birds containing cysts had been kept in formalin for a period of more than 15 years - as was the case with the yellowbilled hornbill (Figures 30 - 35) and the Cape glossy starling (Figures 72 - 75). The same comment applies to the redbilled hornbills (Figures 36 - 39): they had been frozen and thawed before being fixed in formalin and were then injected with glycerine and subsequently kept in 70 per cent alcohol for an unknown period but for more than five years.

Preliminary screening of frozen or preserved material by light and electron microscopy identifies host species suitable for more detailed study.

Pathogenicity

Acute infection

Markus (1981) believes there is a possibility that severe mortality due to a respiratory condition in muscovy ducks Cairina moschata in Canada was caused by schizonts of Sarcocystis and not Haemoproteus, as was thought by Julian and Galt (1980). In peninsular Malaysia, Opitz et al. (1982) found a myopathy associated with protozoan schizonts in chickens, which they thought could have been Sarcocystis. However, whether most of the stages they described were, in fact, schizonts rather than cysts of the "chronic infection", is not clear.

Chronic infection

Munday et al. (1977) found that sarcocystosis caused severe myositis in five fowls. The authors considered that the relatively high prevalence of clinical sarcocystosis in fowls makes it a major consideration in the differential diagnosis of leg or muscle weakness in these birds in Papua New Guinea and perhaps elsewhere. Douglass and Hansen (1979) believed that sarcocystosis played a major role in the death of blue and yellow tanagers which they studied. Other reports, however, indicated that Sarcocystis had little or no effect on the avian host (Fantham, 1913; Riley, 1931;

Beaudette, 1941; Salt, 1958; Chabreck, 1965). Quortrup and Shillinger (1941) found that most birds with muscular sarcocystosis had died from some other cause. Quortrup and Shillinger (1941) believe, however, that they have ample proof that this parasite can and frequently does kill its host, as was the case with a green-winged teal Anas crecca. Chabreck (1965) showed that there was no significant difference in body weight between parasitised and non-parasitised ducks.

Stewart and Giannini (1982) stated that a young cyst causes little or no disruption to the highly ordered sarcoplasm but that displacement of myofibrils with loss of register is frequently seen as the cyst enlarges. The present study confirms that the host cytoplasm surrounding the cyst wall is often devoid of myofibrils, although numerous vesicles, vacuoles and mitochondria may be present in spaces between projections of the cyst wall (Stewart and Giannini, 1982).

The death of the infected birds examined by the present author cannot be ascribed to Sarcocystis infection as the birds had, in many cases, been killed by accident (cars, cats, etc.) or they had been shot and taken to the S.P.C.A. bird hospital for that reason. However, it is not impossible that Sarcocystis may sometimes cause weakening of muscle, with the result that the

movements of the birds become slower, making them more susceptible to capture by cats.

As the cyst becomes older, the muscle cell undergoes further degenerative changes, i.e. thinning and separation of myofibrils (Stewart and Giannini, 1982). Wobeser and Cawthorn (1981) found that a progression of changes was evident in the degeneration of the cyst, beginning with degeneration of the cyst wall and ending with granuloma formation. Inflammation of the host tissue was proportional to the amount of degeneration which had taken place within the cyst (Mathews, 1930; Wobeser and Cawthorn, 1981).

APPENDIX I

Specific names of non-southern African hosts of Sarcocystis mentioned in the text

Birds

Bald eagle - Haliaeetus leucocephalus

Blue and yellow macaw - Ara ararauna

Blue and yellow tanager - Thraupis bonariensis

Brownheaded cowbird - Molothrus ater

Budgerigar - Melopsittacus undulatus

Canada goose - Branta canadensis

Canary - Serinus canarius

Common coot - Fulica atr

Domestic fowl - Gallus gallus

European sparrowhawk - Accipiter nisus

Gadwall - Anas strepera

Great blue heron - Ardea herodias

Great horned owl - Bubo virginianus

Great-tailed grackle - Quiscalus mexicanus

Green-winged teal - Anas crecca

Hawk - Leucopternis sp.

Hoary-headed grebe - Podiceps poliocephalus

House sparrow - Passer domesticus

Mallard - Anas platyrhyncho

Masked owl - Tyto novaehollandiae

Muscovy duck - Cairina moschata

Northern goshawk - Accipiter gentilis

Plush-crested jay - Cyanocorax chrysops

Red-winged blackbird - Agelaius phoeniceus

Ring-necked pheasant - Phasianus colchicus

Ross's goose - Anser rossi

Siamese firebacked pheasant - Lophura diardi

Snow goose - Anser caerulescens

Snowy owl - Nyctea scandiaca

Southern skua - Catharacta skua

Tovi-parakeet - Brotogeris jugularis

White-backed magpie - Gymnorhina hypoleuca

Wild grackle - Quiscalus quiscula

Wild shoveler - Anas clypeata

Yellow-headed blackbird - Xanthocephalus xanthocephalus

Zebra finch - Poephila guttata

Mammals

Cat - Felis domestica

Dog - Canis familiaris

Opossum - Didelphis virginiana

Rat - Rattus norvegicus

Striped skunk - Mephitis mephitis

APPENDIX II

Common and scientific names of Southern African birds mentioned in the text

DIOMEDEIDAE

Wandering albatross - Diomedea exulans

Sooty albatross - Phoebetria fusca

Lightmantled sooty albatross - Phoebetria palpebrata

PROCELLARIIDAE

Northern giant petrel - Macronectes halli

Greatwinged petrel - Pterodroma macroptera

Softplumaged petrel - Pterodroma mollis

Atlantic petrel - Pterodroma incerta

Kerguelen petrel - Pterodroma brevirostris

Blue petrel - Halobaena caerulea

Broadbilled prion - Pachyptila vittata

Antarctic prion - Pachyptila desolata

Fairy prion - Pachyptila turtur

Great shearwater - Puffinus gravis

Little shearwater - Puffinus assimilis

OCEANITIDAE

Whitebellied storm petrel - Fregetta grallaria

PHALACROCORACIDAE

Whitebreasted cormorant - Phalacrocorax carbo

Reed cormorant - Phalacrocorax africanus

APPENDIX II

Common and scientific names of southern African birds mentioned in the text

DIOMEDEIDAE

Wandering albatross - *Diomedea exulans*

Sooty albatross - *Phoebetria fusca*

Lightmantled sooty albatross - *Phoebetria palpebrata*

PROCELLARIIDAE

Northern giant petrel - *Macronectes halli*

Greatwinged petrel - *Pterodroma macroptera*

Softplumaged petrel - *Pterodroma mollis*

Atlantic petrel - *Pterodroma incerta*

Kerguelen petrel - *Pterodroma brevirostris*

Blue petrel - *Halobaena caerulea*

Broadbilled prion - *Pachyptila vittata*

Antarctic prion - *Pachyptila desolata*

Fairy prion - *Pachyptila turtur*

Great shearwater - *Puffinus gravis*

Little shearwater - *Puffinus assimilis*

OCEANITIDAE

Whitebellied storm petrel - *Fregetta grallaria*

PHALACROCORACIDAE

Whitebreasted cormorant - *Phalacrocorax carbo*

Reed cormorant - *Phalacrocorax africanus*

APPENDIX II

Common and scientific names of southern African birds mentioned in the text

DIOMEDEIDAE

Wandering albatross - *Diomedea exulans*

Sooty albatross - *Phoebetria fusca*

Lightmantled sooty albatross - *Phoebetria palpebrata*

PROCELLARIIDAE

Northern giant petrel - *Macronectes halli*

Greatwinged petrel - *Pterodroma macroptera*

Softplumaged petrel - *Pterodroma mollis*

Atlantic petrel - *Pterodroma incerta*

Kerguelen petrel - *Pterodroma brevirostris*

Blue petrel - *Halobaena caerulea*

Broadbilled prion - *Pachyptila vittata*

Antarctic prion - *Pachyptila desolata*

Fairy prion - *Pachyptila turtur*

Great shearwater - *Puffinus gravis*

Little shearwater - *Puffinus assimilis*

OCEANITIDAE

Whitebellied storm petrel - *Fregetta grallaria*

PHALACROCORACIDAE

Whitebreasted cormorant - *Phalacrocorax carbo*

Reed cormorant - *Phalacrocorax africanus*

ARDEIDAE

Grey heron - Ardea cinerea

Blackheaded heron - Ardea melanocephala

Purple heron - Ardea purpurea

Little egret - Egretta garzetta

Yellowbilled egret - Egretta intermedia

Cattle egret - Bubulcus ibis

Blackcrowned night heron - Nycticorax nycticorax

Rail heron - Ixobrychus sturmii

SCOPIDAE

Hamerkop - Scopus umbretta

CICONIIDAE

White stork - Ciconia ciconia

PLATALEIDAE

Sacred ibis - Threskiornis aethiopicus

Glossy ibis - Plegadis falcinellus

Hadeda - Bostrychia hagedash

African spoonbill - Platalea alba

ANATIDAE

Whitefaced duck - Dendrocygna viduata

Egyptian goose - Alopochen aegyptiacus

Redbilled teal - Anas erythrorhyncha

Pintail - Anas acuta

Spurwinged goose - Plectropterus gambensis

Maccoa duck - Oxyura maccoa

SAGITTARIIDAE

Secretarybird - Sagittarius serpentarius

ACCIPITRIDAE

Whitebacked vulture - Gyps africanus

Black kite - Milvus migrans

Blackshouldered kite - Elanus caeruleus

Tawny eagle - Aquila rapax

Ayres' eagle - Hieraaetus ayresii

Blackbreasted snake eagle - Circaetus gallicus

Steppe buzzard - Buteo buteo

Jackal buzzard - Buteo rufofuscus

Redbreasted sparrowhawk - Accipiter rufiventris

Little sparrowhawk - Accipiter minullus

African goshawk - Accipiter tachiro

Pale chanting goshawk - Melierax canorus

African marsh harrier - Circus ranivorus

FALCONIDAE

Lanner - Falco biarmicus

Eastern redfooted kestrel - Falco amurensis

Common kestrel - Falco tinnunculus

Greater kestrel - Falco rupicoloides

Lesser kestrel - Falco naumanni

PHASIANIDAE

Francolin - Francolinus sp.

Coqui francolin - Francolinus coqui

Crested francolir - Francolinus sephaena

Shelley's francolin - Francolinus shelleyi

Orange river francolin - Francolinus levaillantoides

Redbilled francolin - Francolinus adspersus

Cape francolin - Francolinus capensis

Natal francolin - Francolinus natalensis

Swainson's francolin - Francolinus swainsonii

Quail - Coturnix sp.

African quail - Coturnix coturnix

Harlequin quail - Corurnix delegorguei

NUMIDIDAE

Helmeted guineafowl - Numida meleagris

TURNICIDAE

Kurrichane buttonquail - Turnix sylvatica

GRUIDAE

Blue crane - Anthropoides paradisea

RALLIDAE

Corncrake - Crex crex

African crake - Crex egregia

Black crake - Amaurornis flavirostris

Purple gallinule - Porphyrio porphyrio

Moorhen - Gallinula chloropus

Redknobbed coot - Fulica cristata

CHARADRIIDAE

Threebanded sandplover - Charadrius tricollaris

Crowned plover - Vanellus coronatus

Blacksmith plover - Vanellus armatus

Wattled plover - Vanellus senegallus

SCOLOPACIDAE

Wood sandpiper - Tringa glareola

Curlew sandpiper - Calidris ferruginea

Ruff - Philomachus pugnax

Ethiopian snipe - Gallinago nigripennis

BURHINIDAE

Spotted dikkop - Burhinus capensis

GLAREOLIDAE

Bronzewinged courser - Rhinoptilus chalcopterus

Collared pratincole - Glareola pratincola

LARIDAE

Arctic skua - Stercorarius parasiticus

Subantarctic skua - Catharacta antarctica

Greyheaded gull - Larus cirrocephalus

COLUMBIDAE

Speckled pigeon - Columba guinea

Rameron pigeon - Columba arquatrix

Redeyed dove - Streptopelia semitorquata

Cape turtle dove - Streptopelia capicola

Laughing dove - Streptopelia senegalensis

Namaqua dove - Oena capensis

Emeraldspotted dove - Turtur chalcospilos

PSITTACIDAE

Roseringed parakeet - Psittacula krameri

Rosyfaced lovebird - Agapornis roseicollis

MUSOPHAGIDAE

Grey loerie - Corythaixoides concolor

CUCULIDAE

Redchested cuckoo - Cuculus solitarius

Striped crested cuckoo - Clamator levaillantii

Didric cuckoo - Chrysococcyx caprius

Whitebrowed coucal - Centropus superciliosus

TYTONIDAE

Barn owl - Tyto alba

Grass owl - Tyto capensis

STRIGIDAE

Marsh owl - Asio capensis

Whitefaced owl - Otus leucotis

Pearlspotted owl - Glaucidium perlatum

Spotted eagle owl - Bubo africanus

CAPRIMULGIDAE

Natal nightjar - Caprimulgus natalensis

APODIDAE

African black swift - Apus barbatus

Whiterumped swift - Apus caffer

Horus swift - Apus horus

Little swift - Apus affinis

COLIIDAE

Speckled mousebird - Colius striatus

Whitebacked mousebird - Colius colius

Redfaced mousebird - Colius indicus

HALCYONIDAE

Giant kingfisher - Ceryle maxima

Halfcollared kingfisher - Alcedo semitorquata

Woodland kingfisher - Halcyon senegalensis

Brownhooded kingfisher - Halcyon albiventris

Striped kingfisher - Halcyon chelicuti

MEROPIDAE

European bee-eater - Merops apiaster

Little bee-eater - Merops pusillus

CORACIIDAE

European roller - Coracias garrulus

Lilacbreasted roller - Coracias caudata

UPUPIDAE

Hoopoe - Upupa epops

PHOENICULIDAE

Redbilled woodhoopoe - Phoeniculus purpureus

BUCEROTIDAE

Grey hornbill - Tockus nasutus

Redbilled hornbill - Tockus erythrorhynchus

Yellowbilled hornbill - Tockus flavirostris

CAPITONIDAE

Blackcollared barbet - Lybius torquatus

Yellowfronted tinkerbird - Pogoniulus chrysoconus

Crested barbet - Trachyphonus vaillantii

INDICATORIDAE

Lesser honeyguide - Indicator minor

PICIDAE

Cardinal woodpecker - Dendropicos fuscescens

Olive woodpecker - Mesopicos griseocephalus

EURYLAIMIDAE

African broadbill - Smithornis capensis

ALAUDIDAE

Rufousnaped lark - Mirafra africana

Subota lark - Mirafra [illegible]

Chestnutbacked finchlark - Eremopterix leucotis

HIRUNDINIDAE

European swallow - Hirundo rustica

Whitethroated swallow - Hirundo albigularis

Redbreasted swallow - Hirundo semirufa

Greater striped swallow - Hirundo cucullata

Lesser striped swallow - Hirundo abyssinica

House martin - Delichon urbica

Brownthroated sand martin - Riparia paludicola

DICRURIDAE

Forktailed drongo - Dicrurus adsimilis

Squaretailed drongo - Dicrurus ludwigii

ORIOLIDAE

Golden oriole - Oriolus oriolus

Blackheaded oriole - Oriolus larvatus

CORVIDAE

Black crow - Corvus capensis

Pied crow - Corvus albus

PARIDAE

Southern black tit - Parus niger

Grey penduline tit - Anthoscopus caroli

TIMALIIDAE

Arrowmarked babbler - Turdoides jardineii

Pied babbler - Turdoides bicolor

PYCNONOTIDAE

Blackeyed bulbul - Pycnonotus barbatus

Yellowstreaked bulbul - Phyllastrephus flavostriatus

Sombre bulbul - Andropadus importunus

Yellowbellied bulbul - Chlorocichla flaviventris

TURDIDAE

Kurrichane thrush - Turdus libonyana

Olive thrush - Turdus olivaceus

Groundscraper thrush - Turdus litsitsirupa

Mountain chat - Oenanthe monticola

Buffstreaked chat - Oenanthe bifasciata

Familiar chat - Cercomela familiaris

Mocking chat - Thamnolaea cinnamomeiventris

Anteating chat - Myrmecocichla formicivora

Chorister robin - Cossypha dichroa

Natal robin - Cossypha natalensis

Cape robin - Cossypha caffra

Whitethroated robin - Cossypha humeralis

Starred robin - Pogonocichla stellata

Whitebrowed scrub robin - Erythropygia leucophrys

Kalahari scrub robin - Erythropygia paena

SYLVIIDAE

Chestnutvented titbabbler - Parisoma subcaeruleum

African reed warbler - Acrocephalus baeticatus

Marsh warbler - Acrocephalus palustris

Sedge warbler - Acrocephalus schoenobaenus

Lesser swamp warbler - Acrocephalus gracilirostris

Luteous warbler - Chloropeta natalensis

Little rush warbler - Bradypterus baboecala

Willow warbler - Phylloscopus trochilus

Barthroated warbler - Apalis thoracica

Crombec - Sylvietta rufescens

Burntnecked eremomela - Eremomela usticollis

Warbler - Camaroptera sp.

Grassbird - Sphenoeacus afer

Fantailed cisticola - Cisticola juncidis

Cloud cisticola - Cisticola textrix

Wailing cisticola - Cisticola lais

Rattling cisticola - Cisticola chiniana

Levaillant's cisticola - Cisticola tinniens

Croaking cisticola - Cisticola natalensis

Neddicky - Cisticola fulvicapilla

Tawnyflanked prinia - Prinia subflava

Blackchested prinia - Prinia flavicans

Karoo prinia - Prinia maculosa

MUSCICAPIDAE

Spotted flycatcher - Muscicapa striata

Bluegrey flycatcher - Muscicapa caerulescens

Leadcoloured flycatcher - Myioparus plumbeus

Black flycatcher - Melaenornis pammelaina

Marico flycatcher - Melaenornis mariquensis

Mousecoloured flycatcher - Melaenornis pallidus

Fiscal flycatcher - Sigelus silens

Cape batis - Batis capensis

Paradise flycatcher - Terpsiphone viridis

MOTACILLIDAE

Cape wagtail - Motacilla capensis

Pipit - Anthus sp.

Longbilled pipit - Anthus similis

Plainbacked pipit - Anthus leucophrys

Orangethroated longclaw - Macronyx capensis

LANIIDAE

Lesser grey shrike - Lanius minor

Fiscal shrike - Lanius collaris

Redbacked shrike - Lanius collurio

Longtailed shrike - Corvinella melanoleuca

MALACONOTIDAE

Southern boubou - Laniarius ferrugineus

Crimsonbreasted shrike - Laniarius atrococcineus

Puffback - Dryoscopus cubla

Threestreaked tchagra - Tchagra australis

Blackcrowned tchagra - Tchagra senegala

Bokmakierie - Telophorus zeylonus

PRIONOPIDAE

White helmetshrike - Prionops plumatus

STURNIDAE

Indian myna - Acridotheres tristis

Pied starling - Spreo bicolor

Wattled starling - Creatophora cinerea

Plumcoloured starling - Cinnyricinclus leucogaster

Burchell's glossy starling - Lamprotornis australis

Cape glossy starling - Lamprotornis nitens

Redwinged starling - Onychognathus morio

PROMEROPIDAE

Cape sugarbird - Promerops cafer

Gurney's sugarbird - Promerops gurneyi

NECTARINIIDAE

Malachite sunbird - Nectarinia famosa

Greater doublecollared sunbird - Nectarinia afra

Whitebellied sunbird - Nectarinia talatala

Black sunbird - Nectarinia amethystina

ZOSTEROPIDAE

Green white-eye - Zosterops pallidus

PLOCEIDAE

Redbilled buffalo weaver - Bubalornis niger

Whitebrowed sparrow-weaver - Plocepasser mahali

Sociable weaver - Philetairus socius

House sparrow - Passer domesticus

Cape sparrow - Passer melanurus

Greyheaded sparrow - Passer griseus

Yellowthroated sparrow - Petronia superciliaris

Scalyfeathered finch - Sporopipes squamifrons

Spottedbacked weaver - Ploceus cucullatus

Cape weaver - Ploceus capensis

Masked weaver - Ploceus velatus

Redbilled quelea - Quelea quelea

Red bishop - Euplectes orix

Golden bishop - Euplectes afer

Yellowrumped bishop - Euplectes capensis

Whitewinged widow - Euplectes albonotatus

Longtailed widow - Euplectes progne

ESTRILDIDAE

Melba finch - Pytilia melba

Firefinch - Lagonosticta sp.

Blue waxbill - Uraeginthus angolensis

Violeteared waxbill - Uraeginthus granatinus

Common waxbill - Estrilda astrild

Blackfaced swee - Estrilda melanotis

Orangebreasted waxbill - Sporaeginthus subflavus

Redheaded finch - Amadina erythrocephala

VIDUIDAE

Pintailed whydah - Vidua macroura

Shaft-tailed whydah - Vidua regia

Paradise whydah - Vidua paradisaea

FRINGILLIDAE

Yelloweye canary - Serinus mozambicus

Blackthroated canary - Serinus atrogularis

Cape siskin - Serinus tottus

Yellow canary - Serinus flaviventris

Streakyheaded seedeater - Serinus gularis

Goldenbreasted buntin; - Emberiza flaviventris

HYPOTHETICAL LIST*

Whitefaced storm petrel - Pelagodroma marina

Greybacked storm petrel - Garrodia nereis

Diving petrel - Pelecanoides urinatrix

Domestic pigeon - Columba livia

---

* There was a prima facie case for inclusion of these species in the South African list when each was first recorded in the literature. However, their inclusion is now unacceptable for a reason stated in each case in the S.A.O.S. Checklist of Southern African Birds (Southern African Ornithological Society List Committee, 1980).

APPENDIX III

Fixation and processing of tissue for light microscopy

1) Neutral-buffered formal-saline (A) for at least 24 hours.
2) 70% alcohol for 1 hour.
3) 95% alcohol for 2 x 30 minutes.
4) 100% alcohol for 3 x 30 minutes.
5) Chloroform for 2 x 30 minutes.
6) Paraplast 1 for 1 hour.
7) Paraplast 2 overnight.
8) Embed in paraplast.
9) Cut sections at 6µm.
10) Place sections on to 30% alcohol, and float them on to water heated in waterbath to 40°C.
11) Place sections on slide which has been coated with albumen.
12) Allow to dry.

A) Formal-saline fixative (pH near neutral)

Formalin	250ml
Distilled water	1750ml
NaCl	19,13g
NaH_2PO_4	9g
Na_2HPO_4	14,6g

APPENDIX IV

Staining of sections for light microscopy

1) Xylene for 10 minutes.
2) 100% alcohol for 2 x 1 minute.
3) 95% alcohol for 1 minute.
4) Water for 1 minute.
5) Mayer's haematoxylin (A) for 5 minutes.
6) 1% acid alcohol (B) for 5 seconds.
7) Water for 10 minutes.
8) Eosin Y (C) for 15 seconds.
9) Water for 1 minute.
10) 95% alcohol for 1 minute.
11) 100% alcohol for 2 x 1 minute.
12) Xylene for 1 minute.
13) Mount in Entellan.

A) Modified Mayer's Haematoxylin

Haematoxylin	4,0g
Distilled water	1000ml
Sodium iodate	0,3g
Ammonium or potassium alum	50,0g
Citric acid	1,5g
Chloral hydrate	75,0g

Dissolve alum in water (heat not used); add haematoxylin, iodate, citric acid and chloral hydrate, in that order. Filter haematoxylin solution through coarse filter paper.

B) 1% Acid Alcohol

1% HCl in 70% alcohol.

C) Eosin Y

5g eosin in 500ml distilled water

2,5g phloxine in 250ml distilled water

Add 750ml distilled water.

APPENDIX V

Fixation and processing of tissue for electron microscopy

1) Glutaraldehyde (A) for 3 hours at 0°C.
2) Wash in 0,2M cacodylate buffer (B) for 2 x 15 minutes at 4°C.
3) 1% OsO_4 (C) in 0,2M cacodylate buffer for 1 hour at 4°C.
4) Rinse in 0,1M sodium acetate (D) for 2 x 10 minutes at 4°C.
5) 0,25% aqueous uranyl acetate (E) for 1 hour at 4°C.
6) Rinse in 0,1M sodium acetate (D) for 2 x 10 minutes at 4°C.
7) 35% acetone for 5 minutes at 4°C.
8) 50% acetone for 5 minutes at 4°C.
9) 70% acetone/1% uranyl acetate for 1 - 3 hours or overnight at 4°C.
10) 90% acetone for 10 minutes at room temperature.
11) 100% acetone for 3 x 15 minutes at room temperature.
12) Araldite (F)/acetone (25:75) for 2 hours at room temperature.
13) Araldite/acetone (50:50) for 2 hours at room temperature.
14) Araldite/acetone (75:25) for 2 hours at room temperature.
15) Araldite for 24 hours at room temperature.
16) Allow to polymerise for 2 days at 60°C.

A Glutaraldehyde fixative

Glutaraldehyde 25%	5ml
Cacodylate buffer (as in B)	15ml
Water	20ml

Use within 24 hours.

B 0,2M Cacodylate Buffer

Sodium Cacodylate ($Na\ CH_3)_2AsO_2.3H_2O$)	42,8g
N.HCl	6,9ml
Water to	1000ml

C 2% OsO_4

Osmium tetroxide	2ml
Cacodylate buffer	6ml

D 0,1M Sodium acetate is 1,3608g/100ml water.

E 1,25g Uranyl acetate in 100ml water.

F Araldite

1) Thoroughly mix 500g araldite resin and 500g DDSA hardener.
2) Add 15ml accelerator (DMP 30) and 50ml dibutyl phthalate.
3) Mix for at least 6 hours, avoiding excess air bubbles.

APPENDIX VI

Staining of sections for electron microscopy

Staining of semi-thin sections for electron microscopy

1) 1% pyronin in distilled water (Solution A .
2) 1% toluidine blue in 1% borax (Solution B .
3) Mix 1 part of Solution A and 4 parts of Solution B well and filter before use.

Staining of ultrathin sections for electron microscopy

1) Saturated uranyl acetate (Solution A : [illegible] spatula uranyl acetate + 50% ethanol.
2) Lead citrate (Solution B): 1,33g lead nitrate 1,76g sodium citrate placed in 30ml water dissolve. After 30 minutes add 8,0ml N.NaOH make up to 50ml.
3) Centrifuge both (1) and (2) at 3650 rpm minutes.
4) Stain grids in Solution A for 10 minutes.
5) Rinse grids in 3 beakers of 50% ethanol.
6) Stain grids in Solution B for 10 minutes dish contains NaOH pellets).
7) Rinse grids 3 times with distilled water. first container of distilled water contains of N.NaOH.

REFERENCES

Ashford, R.W. 1975. Preliminary observations on the life cycle of *Isospora buteonis*. *Journal of Protozoology* 22: 48A.

Beaudette, F.R. 1941. Sarcosporidiosis in a black duck. *Journal of the American Veterinary and Medical Association* 99: 52-53.

Borst, G.H.A. and Zwart, P. 1973. Sarcosporidiosis in Psittaciformes. *Zeitschrift für Parasitenkunde* 42: 293-298.

Box, E.D. and Duszynski, D.W. 1977. Survey for *Sarcocystis* in the brown-headed cowbird (*Molothrus ater*): a comparison of macroscopic, microscopic and digestion techniques. *Journal of Wildlife Diseases* 13: 356-359.

Box, E.D. and Duszynski, D.W. 1978. Experimental transmission of *Sarcocystis* from icterid birds to sparrows and canaries by sporocysts from the opossum. *Journal of Parasitology* 64: 682-688.

Box, E.D. and Duszynski, D.W. 1980. *Sarcocystis* of passerine birds: sexual stages in the opossum (*Didelphis virginiana*). *Journal of Wildlife Diseases* 16: 209-215.

REFERENCES

Ashford, R.W. 1975. Preliminary observations on the life cycle of *Isospora buteonis*. *Journal of Protozoology* 22: 48A.

Beaudette, F.R. 1941. Sarcosporidiosis in a black duck. *Journal of the American Veterinary and Medical Association* 99: 52-53.

Borst, G.H.A. and Zwart, P. 1973. Sarcosporidiosis in Psittaciformes. *Zeitschrift für Parasitenkunde* 42: 293-298.

Box, E.D. and Duszynski, D.W. 1977. Survey for *Sarcocystis* in the brown-headed cowbird (*Molothrus ater*): a comparison of macroscopic, microscopic and digestion techniques. *Journal of Wildlife Diseases* 13: 356-359.

Box, E.D. and Duszynski, D.W. 1978. Experimental transmission of *Sarcocystis* from icterid birds to sparrows and canaries by sporocysts from the opossum. *Journal of Parasitology* 64: 682-688.

Box, E.D. and Duszynski, D.W. 1980. *Sarcocystis* of passerine birds: sexual stages in the opossum (*Didelphis virginiana*). *Journal of Wildlife Diseases* 16: 209-215.

Box, E.D. and Smith, J.H. 1982. The intermediate host spectrum in a Sarcocystis species of birds. Journal of Parasitology 68: 668-673.

Box, E.D., Marchiondo, A.A., Duszynski, D.W. and Davis, C.P. 1980. Ultrastructure of Sarcocystis sporocysts from passerine birds and opossums: comments on classification of the genus Isospora. Journal of Parasitology 66: 68-74.

Cawthorn, R.J., Rainnie, D. and Wobeser, G. 1981. Experimental transmission of Sarcocystis sp. (Protozoa: Sarcocystidae) between the shoveler (Anas clypeata) duck and the striped skunk (Mephitis mephitis). Journal of Wildlife Diseases 17: 389-394.

Chabreck, R.H. 1965. Sarcosporidiosis in ducks in Louisiana. Transactions of the North American Wildlife Conference 30: 174-184.

Clark, G.M. 1958. Sarcocystis in certain birds. Journal of Parasitology 44, Suppl.: 41.

Crawley, R.R., Ernst, J.V. and Milton, J.L. 1982. Sarcocystis in a bald eagle (Haliaeetus leucocephalus). Journal of Wildlife Diseases 18: 253-255.

Daly, T.J.M. and Markus, M.B. 1980. Separation of Sarcocystis species (Protozoa: Sporozoa,

Coccidia) by means of cyst wall ultrastructure. Proceedings of the Electron Microscopy Society of Southern Africa 10: 95-96.

Darling, S.T. 1915. Sarcosporidia encountered in Panama. Journal of Parasitology 1: 113-120.

Douglass, E.M. and Hansen, B. 1979. Sarcosporidiosis in blue and yellow tanagers. Veterinary Medicine and Small Animal Clinician 74: 1534-1535.

Drouin, T.E. and Mahrt, J.L. 1979. The prevalence of Sarcocystis Lankester, 1882, in some bird species in western Canada, with notes on its life cycle. Canadian Journal of Zoology 57: 1915-1921.

Drouin, T.E. and Mahrt, J.L. 1980. The morphology of cysts of Sarcocystis infecting birds in western Canada. Canadian Journal of Zoology 58: 1477-1482.

Duszynski, D.W. and Box, E.D. 1978. The opossum (Didelphis virginiana) as a host for Sarcocystis debonei from cowbirds (Molothrus ater) and grackles (Cassidix mexicanus, Quiscalus quiscula). Journal of Parasitology 64: 326-329.

Erickson, A.B. 1940. Sarcocystis in birds. Auk 57: 514-519.

Fantham, H.B. 1913. Sarcocystis colii, n.sp., a sarcosporidian occurring in the red-faced African mouse bird, Colius erythromelon. Proceedings of the Philosophical Society, Cambridge 17: 221-224.

Fayer, R. 1970. Sarcocystis: development in cultured avian and mammalian cells. Science 168: 1104-1105.

Fayer, R. 1972. Gametogony of Sarcocystis sp. in cell culture. Science 175: 65-67.

Fayer, R. and Kocan, R.M. 1971. Prevalence of Sarcocystis in grackles in Maryland. Journal of Protozoology 18: 547-548.

Garnham, P.C.C., Duggan, A.J. and Sinden, R.E. 1979. A new species of Sarcocystis in the brain of two exotic birds. Annales de parasitologie humaine et comparée 54: 393-400.

Golubkov, V.I. 1978. Sarcocystis infection in birds (in Russian). Ptitsevodstvo 10: 44-45; abstract 1111 in Protozoological Abstracts 4: 122 (1980).

Golubkov, V.I. 1979. Infection of dogs and cats with Sarcocystis from chicken and geese (in Russian). Veterinariya 1: 55-56.

Hoppe, D.M. 1976. Prevalence of macroscopically detectable Sarcocystis in North Dakota ducks.

Journal of Wildlife Diseases 12: 27-29.

Julian, R.J. and Galt, D.E. 1980. Mortality in muscovy ducks (Cairina moschata) caused by Haemoproteus infection. Journal of Wildlife Diseases 16: 39-44.

Kaiser, I.A. and Markus, M.B. 1981. Sarcocystis in the avian intermediate host. Proceedings of the Electron Microscopy Society of Southern Africa 11: 115-116.

Kalyakin, V.N. and Zasukhin, D.N. 1975. Distribution of Sarcocystis (Protozoa: Sporozoa) in vertebrates. Folia Parasitologica (Prahal 22: 289-307.

Levine, N.D., Beamer, P.D. and Simon, J. 1970. A disease of chickens associated with Arthrocystis galli n.g., n.sp., an organism of uncertain taxonomic position. H.D. Srivastava Commemoration Volume, India: 429-434.

Levine, N.D., Corliss, J.O., Cox, F.E.G., Deroux, G., Grain, J., Honigberg, B.M., Leedale, G.F., Loeblich, A.R., Lom, J., Lynn, D., Merinfeld, E.G., Page, F.C., Poljansky, G., Sprague, V., Vavra, J. and Wallace, F.G. 1980. A newly revised classification of Protozoa. Journal of Protozoology 27: 37-58.

Levine, N.D. and Tadros, W. 1980. Named species and hosts of Sarcocystis (Protozoa: Apicomplexa: Sarcocystidae). Systematic Parasitology 2: 41-59.

Long, P.L. 1982. The Biology of the Coccidia. Edward Arnold, London.

Markus, M.B. 1974. Birds, coprophagous arthropods and coccidian oocysts. Proceedings of the 3rd International Congress of Parasitology (Munich) 1: 98-99.

Markus, M.B. 1978. Sarcocystis and sarcocystosis in domestic animals and man. Advances in Veterinary Science and Comparative Medicine 22: 159-193.

Markus, M.B. 1980. Flies as natural transport hosts of Sarcocystis and other coccidia. Journal of Parasitology 66: 361-362.

Markus, M.B. 1981. Arthropod-borne disease as a possible factor limiting the distribution of birds. South African Journal of Science 77: 574-575.

Markus, M.B. and Daly, T.J.M. 1980. Specificity of Sarcocystis for the intermediate host. Proceedings of the 3rd European Multicolloquium of Parasitology (Cambridge, England) : 141.

Markus, M.B., Killick-Kendrick, R. and Garnham, P.C.C. 1974. The coccidial nature and life-cycle of Sarcocystis. Journal of Tropical Medicine and Hygiene 77: 248-259.

Markus, M.B. and Mundy, P.J. 1979. Intestinal Sarcocystis infection in vultures and its significance. Parasitology 79: xxxix.

Mathews, F.P. 1930. Sarcosporidiosis in a duck. Journal of the American Veterinary Medical Association 76: 705-707.

McLachlan, G.R. and Liversidge, R. 1978. Roberts Birds of South Africa (4th ed.). The John Voelcker Bird Book Fund, Cape Town.

Mehlhorn, H., Hartley, W.J. and Heydorn, A.O. 1976. A comparative ultrastructural study of the cyst wall of 13 Sarcocystis species. Protistologica 12: 451-467.

Munday, B.L. 1983. An isosporan parasite of masked owls producing sarcocysts in rats. Journal of Wildlife Diseases 19: 146-147.

Munday, B.L., Hartley, W.J., Harrigan, K.E., Presidente, P.J.A. and Obendorf, D.L. 1979. Sarcocystis and related organisms in Australian wildlife: II. Survey findings in birds, reptiles, amphibians and fish. Journal of Wildlife Diseases 15: 57-73.

Munday, B.L., Humphrey, J.D. and Kila, V. 1977. Pathology produced by, prevalence of, and probable life-cycle of a species of Sarcocystis in the domestic fowl. Avian Diseases 21: 697-703.

Opitz, H.M., Jakob, H.J., Wiesenhuetter, E. and Devi, V.V. 1982. A myopathy associated with protozoan schizonts in chickens in commercial farms in peninsular Malaysia. Avian Pathology 11: 527-534.

Quortrup, E.R. and Shillinger, J.E. 1941. 3000 wild bird autopsies on western lake areas. Journal of the American Veterinary Medical Association 99: 382-387.

Riley, W.A. 1931. Sarcosporidicsis in ducks. Parasitology 23: 282-285.

Salt, W.R. 1958. Sarcocystis rileyi in sage grouse. Journal of Parasitology 44: 511.

Smith, D.D. and Frenkel, J.K. 1978. Cockroaches as vectors of Sarcocystis muris and of other coccidia in the laboratory. Journal of Parasitology 64: 315-319.

Southern African Ornithological Society List Committee. 1980. S.A.O.S. Checklist of Southern African Birds. Southern African Ornithological Society,

Johannesburg.

Stewart, G.L. and Giannini, S.H. 1982. Sarcocystis, Trypanosoma, Toxoplasma, Brugia, Ancylostoma, and Trichinella spp.: a review of the intracellular parasites of striated muscle. Experimental Parasitology 53: 406-447.

Tadrcs, W. and Laarman, J.J. 1978. A comparative study of the light and electron microscopic structure of the walls of the muscle cysts of several species of sarcocystid eimeriid Coccidia (1). Proceedings of the Koninklijke Nederlandse Akademie van Wetenschappen C81: 469-491.

Wenzel, R. 1981. Untersuchungen über Sarkosporidien-Infektionen bei Haus- und Wildgeflügel. Inaugural-Dissertation der Universität München, 41pp.

Wenzel, R., Erber, M., Boch, J. and Schellner, H.P. 1982. Sarkosporidien-Infektion bei Haushuhn, Fasan und Blesshuhn. Berliner und Münchener Tierärtzliche Wochenschrift 95: 188-193.

Wicht, R.J. 1981. Transmission of Sarcocystis rilevi to the striped skunk (Mephitis mephitis). Journal of Wildlife Diseases 17: 387-394.

Wobeser, G and Cawthorn, R.J. 1981. Granulomatous myositis in association with Sarcocystis sp.

infection in wild ducks. Avian Diseases 26: 412-418.

Wobeser, G., Leighton, F.A. and Cawthorn, R.J. 1981. Occurrence of Sarcocystis Lankester, 1882, in geese in Saskatchewan. Canadian Journal of Zoology 59: 1621-1624.

Author Kaiser I A
Name of thesis The occurrence of Sarcocystis (Protozoa: Coccidia) in wild Southern African birds 1983

PUBLISHER:
University of the Witwatersrand, Johannesburg
©2013

LEGAL NOTICES:

Copyright Notice: All materials on the University of the Witwatersrand, Johannesburg Library website are protected by South African copyright law and may not be distributed, transmitted, displayed, or otherwise published in any format, without the prior written permission of the copyright owner.

Disclaimer and Terms of Use: Provided that you maintain all copyright and other notices contained therein, you may download material (one machine readable copy and one print copy per page) for your personal and/or educational non-commercial use only.

The University of the Witwatersrand, Johannesburg, is not responsible for any errors or omissions and excludes any and all liability for any errors in or omissions from the information on the Library website.