

https://dspace.org/

Schwannoma and neurofibroma of the posterior tibial nerve presenting as tarsal tunnel syndrome review of the literature with two case reports

MJ Tladi; Nikiforos Saragas; Paulo Ferrao; Andrew Strydom

https://hdl.handle.net/10539/24272
SCOPUS 2017

Downloaded from a DSpace repository. https://dspace.org/

The Foot 32 (2017) 22–26

Contents lists available at ScienceDirect

The Foot

journal homepage: www.elsevier.com/locate/foot

Review

Schwannoma and neurofibroma of the posterior tibial nerve presenting as tarsal tunnel syndrome: review of the literature with two case reports

Makgabo John Tladi[a,*], Nikiforos Pandelis Saragas[b], Paulo Norberto Ferrao[b], Andrew Strydom[c]

[a] Dr George Mukhari Academic Hospital Ga-Rankuwa, and Orthopaedic Department, Sefako Makgatho Health University, Pretoria, South Africa
[b] Netcare Linksfield Orthopaedic Sports & Rehabilitation Centre (Clinic), and Orthopaedic Department, University of the Witwatersrand, Johannesburg, South Africa
[c] Charlotte Maxeke Academic Hospital, and Orthopaedic Department, University of the Witwatersrand, Johannesburg, South Africa

HIGHLIGHTS

- Long delay in diagnosing of tarsal tunnel syndrome due to peripheral nerve tumours.
- No literature with multiple neurofibroma of posterior tibial nerve presenting as a tarsal syndrome.
- Ultrasonography done in good hands can diagnosis peripheral nerve tumours.
- Good surgical outcomes with excision of both tumours.

ARTICLE INFO

Article history:
Received 23 August 2016
Received in revised form 6 March 2017
Accepted 14 March 2017

Keywords:
Schwannoma
Neurofibroma
Peripheral nerve tumours
Neurofibromatosis

ABSTRACT

We present two case reports of peripheral nerve tumors (schwannoma and neurofibroma) that presented as tarsal tunnel syndrome for many years. There has never been a report of multiple neurofibroma of the posterior tibial nerve presenting as a tarsal tunnel syndrome. Both patients were treated surgically with good outcomes.

© 2017 Elsevier Ltd. All rights reserved.

1. Introduction

Peripheral nerve tumours account for 10.2% of all foot and ankle tumours including schwannoma (57%), neurofibroma (29%) and malignant peripheral nerve tumours (14%). Schwannomas and neurofibromas are benign with a slow growth rate. Although found in any nerve, they are most commonly found in the head, neck and brachial plexus. In the lower limb, the posterior tibia nerve (PTN) is commonly involved [1].

Tarsal tunnel syndrome (TTS) arises from compression of the PTN within the tarsal tunnel and its multiple causes may be intrinsic or extrinsic to the tarsal tunnel. One intrinsic cause is compression of the PTN within the tarsal tunnel by a peripheral nerve tumour [2]. Due to the slow growth rate of these tumours, a TTS diagnosis can be missed or delayed, resulting in a prolonged period of analgesia administration with no improvement and the impairment of daily activities [2–5]. Two cases of TTS secondary to peripheral nerve tumours (schwannoma and neurofibroma) of the PTN are presented.

2. Case 1

2.1. Clinical history

A 46-year-old man was referred by his physiotherapist with a 15-year history of medial ankle and foot pain, which radiated to the lateral aspect of the sole. The patient had consulted numerous physicians with no resolution of his symptoms, was

* Corresponding author at: PO Box 591, MEDUNSA 0204. Tel.: +27 835297395.
E-mail addresses: mjtladi.ortho@gmail.com (M.J. Tladi), saragas@global.co.za (N.P. Saragas), paulo@cybersmart.co.za (P.N. Ferrao), drewstrydom@hotmail.com (A. Strydom).

http://dx.doi.org/10.1016/j.foot.2017.03.005
0958-2592/© 2017 Elsevier Ltd. All rights reserved.

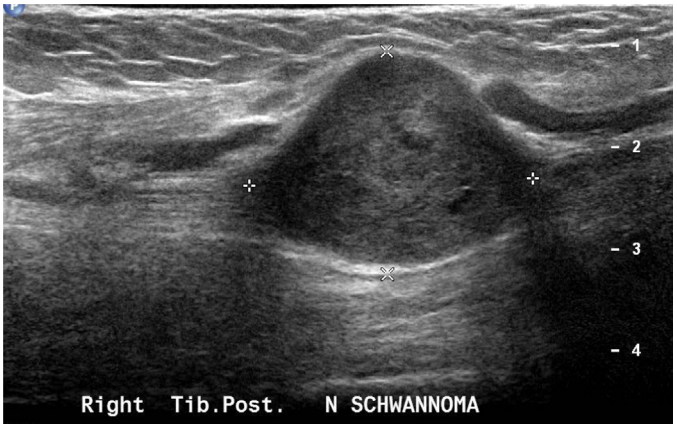

Fig. 1. Ultrasound scan showing schwannoma of the posterior tibial nerve.

repeatedly diagnosed with Achilles tendon pathology and referred for physiotherapy. His most recent physiotherapist disagreed that his symptoms were related to the Achilles tendon and referred him for an ultrasound. On presentation he reported continuous medial ankle and foot pain (worse at night) which was affecting his normal activities.

2.2. Examination

On examination, the Achilles tendon appeared normal. The patient had pin-point tenderness 2 cm above medial malleolus, midway between the tibia and the Achilles tendon with no palpable mass. He had a positive Tinel test over the PTN. The foot was sensory and motor intact with good palpable pulses. Clinically he had no features of neurofibromatosis.

2.3. Investigation

The patient ultrasound scan (Fig. 1) reported a $28 \times 20 \times 18\,mm^3$ hypoechoic mass in continuity with the PTN, suggestive of a schwannoma.

2.4. Management

Treatment options were discussed and he was advised to have the mass surgically excised for symptomatic relief and, more importantly, get a histological diagnosis. The patient was counselled regarding the surgical risks and complications, including damage to the PTN. Surgical excision was performed under general anaesthesia with no peripheral nerve block. The posterior tibial nerve was carefully exposed and a $2 \times 1.5\,cm^2$ mass was found within the neural sheath of the PTN (Figs. 2 and 3).

The mass was carefully dissected out and removed without damaging the nerve. The wound was closed and a below-knee slab applied. The mass was sent for histology and reported as being a schwannoma based on the presence of Antoni type A and type B cells and histochemistry stained positive for S-100 (Fig. 4). The slab was removed at three weeks. The wound had healed well and the foot was sensory and motor intact. He was instructed to start weight bearing as tolerated. At the eight-week follow-up, his symptoms had completely resolved with no complaints of pain or neurological symptoms. He returned to all normal activities at 12 weeks.

3. Case 2

3.1. Clinical history

A neurologist referred a 24-year-old woman with a 10-year history of left medial ankle pain radiating up the leg (Valleix phenomenon) and with electric shock-like sensations aggravated by walking and cold weather [6]. With no benefit from analgesia or physiotherapy she had undergone a tarsal tunnel release on two occasions elsewhere in 1997 and 2002 on the affected leg.

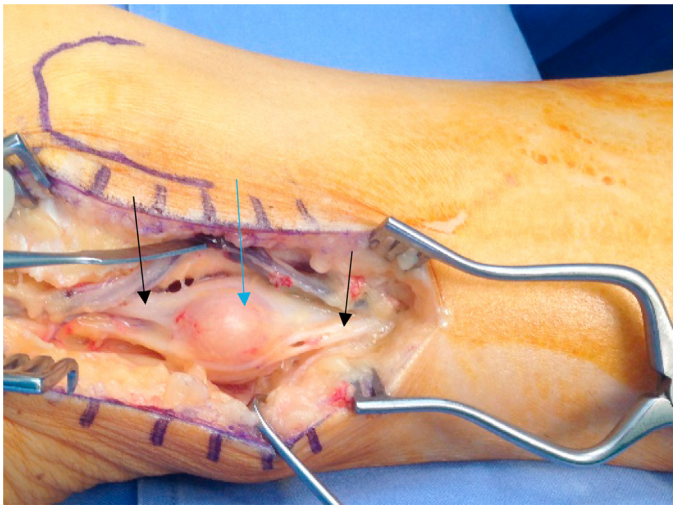

Fig. 2. Intraoperative schwannoma of the posterior tibial nerve. The black arrows indicate posterior tibial nerve and blue shows schwannoma.



Fig. 3. Schwannoma completely removed and the posterior tibial nerve is still intact.

3.2. Examination

The patient presented with an antalgic gait, a large surgical scar over the tarsal tunnel and swelling around the medial aspect of the left ankle. She had a 5° equinus deformity and decreased sensation over the lateral plantar nerve distribution with a positive Tinel test. No positive findings suggested neurofibromatosis.

3.3. Investigation

The patient presented with ultrasound and MRI reports. Ultrasound reported a cystic mass measuring $25 \times 10.5\,mm^2$ adjacent to the tibialis posterior and flexor digitorium tendons, suggestive of a ganglion cyst. The MRI showed two well-circumscribed septate cysts on the medial aspect of her left ankle (Fig. 5). The proximal cyst was 2 cm proximal to the ankle measuring $19 \times 12\,mm^2$ on the medial aspect of the flexor hallucis muscle at its musculo-

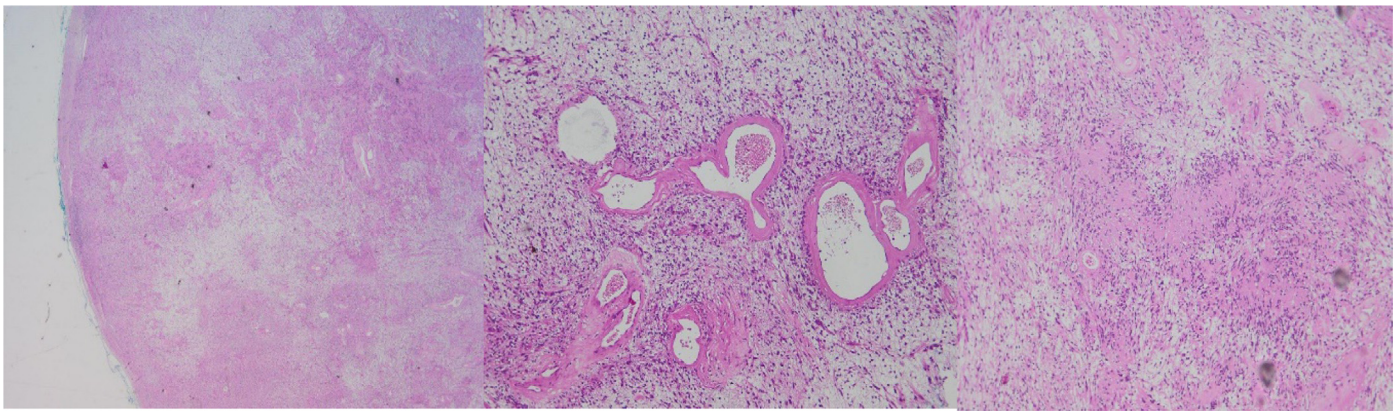

Fig. 4. Histological slides of schwannoma.

tendinous junction, posterior to the tibialis posterior and flexor digitorium tendons. The second cyst was within the tarsal tunnel, measuring $25 \times 11.3\,mm^2$, compressing the posterior tibial nerve and suggestive of a ganglion cyst. Nerve conduction studies showed an increased distal latency of both medial and lateral plantar nerves with reduction in amplitude of the compound motor unit. A diagnosis of recurrent TTS secondary to ganglion cysts together with a shortened Achilles tendon due to chronicity of TTS was made.

3.4. Management

The patient was informed that she should be managed surgically with a tarsal tunnel release and neurolysis, excision of the two cysts, and lengthening of the Achilles tendon. Surgical risks, including nerve damage, were discussed. An incision was made over the old medial scar. Extensive and dense scar tissue was identified overlying the posterior tibial nerve. The healthy posterior tibial nerve was identified distally where it bifurcates and dissected proximally from the scar tissue. A complete neurolysis of the nerve was performed and a 3 cm mass within the nerve, removed. Because the mass was part of the nerve, it was difficult to remove without injuring the nerve. Proximally the nerve was found to be normal. The mass contained brown "putty-like" material. The second mass was beside the flexor hallucis longus and excised without compromising any structures. The wound was closed and a below-knee back slab was applied. The two masses were sent for histology which reported both masses as neurofibromas (Fig. 6). Achilles tendon lengthening was not done because the surgeon awaited histology results indicating the pathology.



Fig. 5. MRI indicating multiple neurofibroma of posterior tibial nerve.

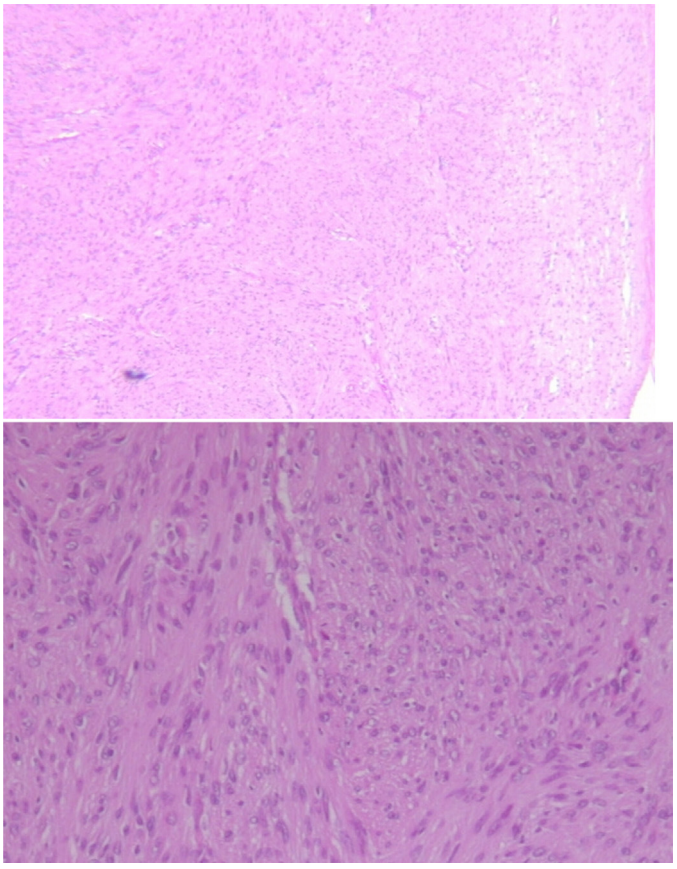

Fig. 6. Histological slides showing neurofibroma.

Table 1
Conditions causing delayed in diagnosing TTS.

Trauma
Ligaments injury
Arthritis
Heel fat pad bruising
Neuropathies
Peripheral neuropathy (Diabetes)
Plantar neurofibromatosis
Morton's neuroma
Radiculopathy
Disc herniation
Inflammatory conditions
Tenosynovitis
Plantar fasciitis
Insertional Achilles tendonitis
Gout
Others
Peripheral vascular disease
Restless leg syndrome
Medial arch strain

The patient was followed-up 10 days postoperatively for review reporting numbness along the medial plantar nerve distribution. The back slab was removed at three weeks and she was referred to physiotherapy. At seven weeks, she reported no pain but still had hypoesthesia along the distribution of the medial plantar nerve. She fully recovered at 20 weeks.

4. Discussion

The tarsal tunnel is a fibro-osseous structure containing tendons and the neurovascular bundle. Either the PTN or its branches can be compressed within the tunnel resulting in TTS [2]. TTS is often misdiagnosed because the pain and proximity mimic various conditions resulting in a delayed diagnosis (Table 1) [7]. In 1962, Keck reported that TTS is often misdiagnosed as plantar fasciitis due to the proximity of symptoms [8]. Management of extrinsic causes such as adjacent arthritis (compressive osteophytes) or tenosynovitis (rheumatoid arthritis) result in a delayed diagnosis. TTS may be overlooked in chronic conditions, such as diabetes mellitus, peripheral neuropathy or gout. Tumours at the level of the tarsal tunnel are reported to be rare [9].

A schwannoma is a benign peripheral nerve tumour arising from the Schwan cells of the nerve sheath [10–12]. Other terms for schwannoma include neurilemoma, neurocytoma, peripheral glioma or perineurial fibroblastoma [13]. Schwannomas of the PTN are usually isolated but reports of multiple schwannomas within the same nerve exist and these cases require evaluation for neurofibromatosis [14,15]. There is no difference in incidence with regards to race or gender [16]. Schwannomas are known to be slow growing and asymptomatic for months to years, as in our case. Nawabi et al. reported 25 cases of schwannoma of PTN with the mean duration of symptoms before diagnosis being 86.5 months (seven years) [17]. The diagnosis may be missed or ascribed to other conditions, e.g. psychogenic pain [3].

Neurofibromas contain multiple cell types including Schwan cells, fibroblast, mast cells, perineurial cells and axons [10–12]. As with schwannomas, a neurofibroma diagnosis is often delayed [18,19]. Although a neurofibroma may be found in isolation, it mostly occurs with other features of neurofibromatosis (von Recklinghausen's disease) [19]. However, Levi et al. reported that 12 of 34 patients with neurofibromas had no association with von Recklinghausen's disease [20]. We found only one case report of TTS secondary to a single neurofibroma in a patient diagnosed with von Recklinghausen's disease [19]. There is no report in the English literature of multiple neurofibromas of the PTN causing TTS.

Space-occupying lesions causing TTS can present with pain, with or without a palpable mass around the medial malleolus. The pain often radiates distally to the heel and proximally up the leg (Valleix phenomenon) [6,8]. Neural compressive symptoms in TTS include paraesthesia, dysesthesia or hyperesthesia along the distribution of the PTN. The Tinel test is the most reliable clinical test for diagnosing TTS even if a mass is not palpable [2,3,10].

Standard radiographs are done to exclude other pathologies [3,4,13]. Once TTS is suspected further imaging should be routinely done. An experienced ultra-sonographer/radiologist will be helpful in diagnosing a peripheral nerve tumour which is reported as a well-circumscribed, oval, heterogeneous mass in conjunction with cystic degeneration, eccentric location and posterior acoustic enhancement [22]. Hence, we recommend that patients be referred to a radiologist or ultrasonographer with a special interest in musculo-skeletal radiology, as ultrasound is a safe, inexpensive and non-invasive method of identifying these tumours. Reporting of normal nerve conduction studies does not exclude TTS. Saragas et al. reported that nine out of 28 patients with TTS had normal nerve conduction studies [23]. MRI is the investigation of choice for identifying these tumours within the PTN and differentiating between schwannoma, neurofibroma and other soft tissue tumours. A schwannoma originates and grows at the periphery of the nerve, causing compression and lateral or medial displacement of the nerve. By contrast, neurofibromas originate within the neural tissue with nerve fibres trapped within the tumour. The characteristic signal intensity pattern, called a target sign, is seen on T2 weighted images for a benign peripheral nerve tumour. This target sign is characterised by a low-density centre and hyperintense rim of the mass on the T2 weighted images. Malignant tumours do not demonstrate this target pattern [4,15,24,25]. MRI also helps with locating and determining the size of the mass and extent of nerve infiltration by the tumour, crucial to preoperative planning.

Histopathological diagnosis of a schwannoma is based upon the presence of Antoni type A and type B cells. Antoni type A tissue forms a relatively orderly arrangement of cells with elongated nuclei and Verocay bodies, whilst Antoni type B tissue is made up of cells with no orientation or arrangement. Neurofibromas consist of several cells which include Schwann cells with elongated nuclei, large multipolar fibrotic cells, mast cells and the presence of axons [1,10,12,26]. Murărescu et al. reported on a hybrid type of peripheral nerve tumour consisting of a neurofibroma and schwannoma occurring together in a single tumour but this occurrence is rare [8]. While histochemically schwannomas always stain positive for S-100, not all neurofibromas do so [10,20].

Management of TTS due to schwannoma, neurofibroma or any space-occupying lesion is surgical decompression and excision of the lesion [4,5,21]. The clinical outcome for surgical excision of any space-occupying lesion causing TTS is good [23]. Sung et al. reported on 13 cases of TTS due to space-occupying lesions, which were treated surgically, with improvement of the visual analogue score from 6.4 to 2.2 and the American Orthopaedic and Ankle Society score from 77.8 to 92.7 [21]. Schwannomas are well-circumscribed, encapsulated tumours with a good surgical outcome compared to neurofibromas which have variable outcomes due to extensive nerve infiltration. Excision of a schwannoma may be performed safely without damaging the nerve [3,4,14,19,26–28]. However, safe excision of the latter is difficult to achieve, [24,29]. Levi et al. reported that 23.5% of patients with neurofibroma excision had neurological deficit following surgical excision [22]. Consequently, patients should always be warned of the possibility of nerve damage when excising these neurofibromas [24,29]. Pain relief post-surgery occurs over a variable time period [3,4].

Sammarco et al. reported that the average time to maximum improvement post-tarsal tunnel release is 9 months [30]. Recurrence is rare for schwannomas, but can occur with neurofibromas due to the inability to completely excise the tumour [4,20,25]. The author can only predict the reason why the second patient had recurrent TTS, despite two previous tarsal tunnel releases, was that the neurofibromas were either missed or not completely resected. Although malignant transformation is rare for a schwannoma, it can occur with a neurofibroma [1,14,15].

5. Conclusion

Schwannoma or neurofibroma of the PTN should be considered in the differential diagnosis for TTS. These tumours can be asymptomatic while small but will present with compressive neuropathy symptoms as they become larger. Proper history-taking, a high index of suspicion and a positive Tinel test over the PTN form the basis of diagnosing TTS. Further imaging is of importance. An experienced ultrasonographer/radiologist can identify the presence of a mass in the tarsal tunnel. If a mass is identified, a MRI is advised preoperatively to locate the tumour (within or around the nerve) and differentiate a schwannoma or a neurofibroma from other soft tissue tumours. Excisional biopsy and neurolysis is the treatment of choice.

References

[1] Carvajal J, Cuartas E, Qadir R, Levi A, Temple T. Peripheral nerve sheath tumors of the foot and ankle. Foot Ankle Int 2011;32:163–7.
[2] Gould J. Tarsal tunnel syndrome. Foot Ankle Clin N Am 2011;16:275–86.
[3] Ghaly R. A posterior tibial nerve neurilemoma unrecognised for 10 years: case report. Neurosurgery 2001;48(3):668–72.
[4] Boya H, Ozcan O, Oztekin H. Tarsal tunnel syndrome associated with a neurilemoma in the posterior tibial nerve: a case report. Foot 2008;18:174–7.
[5] Hallahan K, Vinokur J, Demski S, Faulkner-Jones B. Tarsal tunnel syndrome secondary to the posterior tibial nerve. J Foot Ankle Surg 2014;53:79–82.
[6] Lau J, Daniels T. Tarsal tunnel syndrome: a review of the literature. Foot Ankle Int 1999;20(3):201–9.
[7] Kusher S, Reid D. Medial tarsal tunnel syndrome: a review. JOSPT 1984;6(1):39–45.
[8] Keck C. The tarsal-tunnel syndrome. J Bone Joint Surg 1962;44A:180–2.
[9] Oh S, Meyer R. Entrapment neuropathies of the tibial nerve. Neurol Clinic 1999;17:593–615.
[10] Wippold IIF, Lubner M, Perrin R, Lämmle M, Perry A. Neuropathology for the neuroradiologist: Antoni A and Antoni B tissue patterns. AJNR 2007;28:1633–8.
[11] Murărescu E, Ivan L, Mihailovici M. Neurofibroma, schwannoma or a hybrid tumor of the peripheral nerve sheath? Rom J Morphol Embryol 2005;46(2):113–6.
[12] Ferner R, Doherty M. Neuroma and schwannoma. Curr Opin Neurol 2002;15:679–84.
[13] Milnes H, Pavier J. Schwannoma of the tibial nerve sheath as a cause of tarsal tunnel syndrome–a case study. Foot 2012;22:243–6.
[14] Schweitzer K, Adams Jr S, Nunley J. Multiple schwannomas of the posterior tibial nerve: a case series. Foot Ankle Int 2013;34(4):607–11.
[15] Ogase A, Hotta T, Morita T, Otsuka H. Multiple schwannomas in the peripheral nerves. JBJS 1998;80(4):657–61.
[16] Spiegl P, Cullivan T, Remiain H, Johnson K. Neurilemoma of the lower extremity. Foot Ankle 1986;6(4):194–8.
[17] Nawabi D, Sinisi M. Schwannoma of the posterior tibial nerve: the problem of delay in diagnosis. JBJS 2007;89:814–6.
[18] Mirick A, Bornestein G, Bancroft L. Radiologic case study. Neurofibroma causing tarsal tunnel syndrome. Orthopedics 2013;36(2):154–7.
[19] D'Orazi V, Venditto T, Panunzi A, Anichini S, Manzini G, Tallarico A, Bernrtti A, Paoloni M. Misdiagnosis of plexiform neurofibroma of the medial plantar nerve: case report. Foot 2014;24:143–5.
[20] Levi A, Ross A, Cuartas E, Qadir R, Temple H. The surgical management of symptomatic peripheral nerve sheath tumors. Neurosurgery 2010;66(4):1–9.
[21] Sung K, Park S. Short term operative outcome of tarsal tunnel syndrome due to benign space–occupying lesions. Foot Ankle Int 2009;30(8):741–5.
[22] Pino C, Ghazle H, Bhatt S, Dogra V. Schwannoma of the tibial nerve. J Diagn Med Sonogr 2010;26(4):205–8.
[23] Saragas N, O'Brien G. Is a positive nerve conduction study a predictor of a satisfactory result after tarsal tunnel release? SAOJ 2008;(Spring):54–5.
[24] Chang L, Shieh S. Neurofibroma derived from the deep peroneal nerve: a case report. Kaohsiung J Med Sci 2006;22:290–6.
[25] Marui T, Yamamoto T, Akisue T, Hitora T, Kawamoto T, Nagira K, Yoshiya S, Kurosaka M. Neurilemmoma in the foot as a cause of hell pain: a report of two cases. Foot Ankle Int 2004;25(2):107–11.
[26] Gosk J, Gutkowska O, Urban M, Wnukiewicz, Reichert P, Ziólkowski. Results of surgical treatment of schwannomas arising from extremities. Bio Med Res Int 2015;2015:1–8.
[27] Arabi H, Bakzaza O, El Fikri A, Elktaibai A, Saidi H, EL Alaoui M. Compression of the peroneal nerve by a neurofibroma originating from collaterals of the peroneal nerve: a case report. J Med Case Rep 2016;10:1–5.
[28] Mendeszoon M, Cunningham N, Crockett R, Kushner D. Schwannoma: case report. Foot Ankle Online J 2009;2(10):1–4.
[29] Li-Ren C, Shyh-Jou S. Neurofibroma derived from the deep peroneal nerve: a case report. Kaohsiung J Med Sci 2006;22:290–5.
[30] Sammarco G, Chang L. Outcome of surgical treatment of tarsal tunnel syndrome. Foot Ankle Int 2003;24(2):125–31.