

https://dspace.org/

Contributions to an understanding of community-acquired pneumonia

Feldman, Charles

2010-09-03
http://hdl.handle.net/10539/8612

Downloaded from a DSpace repository. https://dspace.org/

The Southern African Journal of Epidemiology and Infection 1988; 3 (4): 3-4

Mycoplasma pneumoniae pneumonia requiring intensive care unit admission

Deborah R Baum, Charles Feldman, Clifford Smith and Phillip Ginsburg

A severe case of pneumonia due to** Mycoplasma pneumoniae **infection in an adult black man is presented. This report highlights the need to consider investigation and empiric treatment of** M. pneumoniae **in patients with severe pneumonia not responding to usual antimicrobial therapy.

Introduction

Mycoplasma pneumoniae infection is a well recognised entity, usually responsible for mild, self-limiting, febrile upper respiratory tract infections, pharyngitis, and/or bronchitis.[1] Hospital admission for pneumonia, and more particularly, the need for Intensive Care Unit (ICU) admission is very rarely required, although isolated case reports do appear in the literature.[2,3,4,5,6] We report *M. pneumoniae* pneumonia in a previously healthy, 48 year old black male with a fulminant clinical course, whose condition rapidly deteriorated, requiring his admission to ICU. The aim of this case report is to highlight the need to consider *M. pneumoniae* as a possible aetiological agent in critically ill patients with pneumonia, particularly in those cases unresponsive to usual empiric antimicrobial therapy.

Case report

A 48 year old, previously well, black male security guard was admitted to Hillbrow Hospital on 1st February, 1988, with a 2-day history of progressively worsening left-sided pleuritic chest pain and cough productive of yellow sputum. There was no haemoptysis. He further complained of decreasing effort tolerance over the previous 2 days which limited him to a few footsteps only. There was no previous history of tuberculosis or tuberculosis contact, night sweats or loss of weight.

On examination he was anxious, tachypnoeic and cyanosed on room air. His blood pressure was 110/70 mmHg, his pulse rate was 100 beats/min and regular, and his temperature was 39 °C. On auscultation of the lungs, bronchial breathing and crepitations were heard in the left lower lobe and left axilla. The cardiovascular, gastrointestinal and central nervous system examinations were normal.

The initial blood gas on a polymask ($FiO_2 \pm 60$-80%) showed: pH of 7.379; pCO_2 of 26.7 mmHg; pO_2 of 44.0 mmHg; HCO_3 of 15.5mmol/l; base excess of -8.0; and a saturation of 78.7%. In view of the hypoxaemia, poor PaO_2/FiO_2 ratio and negative base excess in spite of a blood pressure of 110/70 mmHg, the decision was made to admit the patient to the ICU. Blood investigations on admission revealed a haemoglobin of 9.7 g/dl and a white cell count of 7.3 x 10^9/l. The platelet count was 247 x 10^9/l. The Westergren erythrocyte sedimentation rate (ESR) was 5 mm/hour. The serum sodium level was 137mmol/l, serum potassium 3.9 mmol/l, serum chloride 103 mmol/l, urea 7.7mmol/l and creatinine 166μmol/l. The serum calcium was 1.68mmol/l, the serum magnesium 0.36mmol/l and the serum phosphate 1.22mmol/l. Liver function tests were normal and serum albumin measured 34 g/l. The admission chest radiograph revealed a patchy bibasilar bronchopneumonic pattern involving the left lower lobe more extensively than the right (Figure 1).

Cephradine, 1 g 6 hourly IVI, and amikacin 500 mg 12 hourly IVI, were commenced, consistent with a presumptive diagnosis of bacterial pneumonia based on a history of the acute onset of symptoms, clinical picture, and Gram stain of the sputum which displayed predominantly Gram-positive cocci and some Gram-positive and Gram-negative bacilli.

The patient's condition initially continued to deteriorate, necessitating ventilation. This was undertaken using a nasal endotracheal tube and Ohmeda CPU flow generated, pressure/time cycle ventilator. A maximum positive end expiratory pressure (PEEP) of 10 cm water for maximum dynamic compliance, and a maximal FiO_2 of 0.8 were utilised.

Infusions of inotropic doses of isoprenaline, adrenaline (3.81 μg/l/kg/min and 0.17 μg/kg/min respectively) and of renal doses of dopamine (5 μg/kg/min) were given. A Swan-Ganz catheter was inserted into the left pulmonary artery 15 hours following admission to ICU, in the face of the continuing deterioration in the patient's condition, and lability of the blood pressure. A pulmonary artery wedge pressure of 5 mmHg, systemic vascular resistance of 575 dynes.sec.cm^{-5} and pulmonary vascular resistance of 224 dynes.sec.cm^{-5} were recorded. The poor arterial blood gas and low pulmonary artery wedge pressure, together with the rapid spread of the pulmonary infiltrate on serial chest radiographs to involve both lung fields diffusely, were compatible with clinical and radiological evidence of adult respiratory distress syndrome (ARDS).

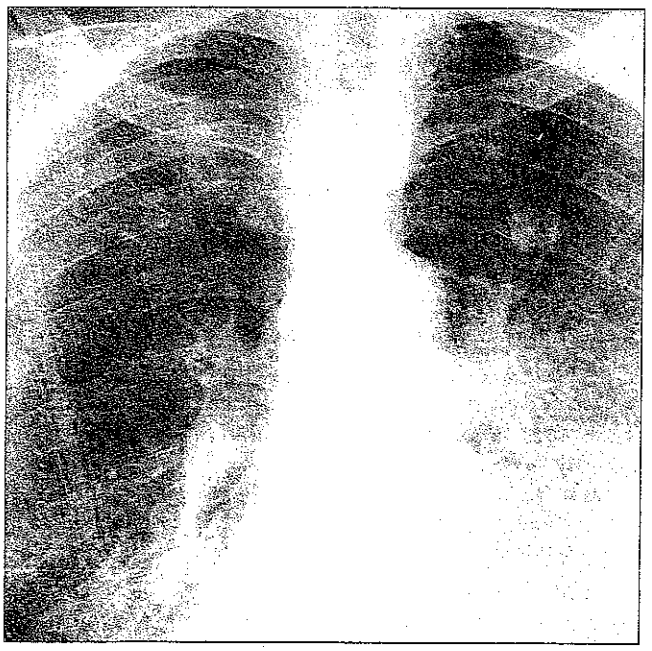

Figure 1: **Chest radiograph of the patient, on admission to hospital, demonstrating bibasilar pulmonary consolidation predominantly affecting the left lower lobe**

Department of Medicine, University of the Witwatersrand, York Road, Parktown 2193. Correspondence to Dr Feldman.

With continuing deterioration in the clinical condition, antibiotics were empirically changed to cefotaxime (1 mg IVI 6 hourly) and clindamycin (600 mg IVI 6 hourly), and erythromycin (1 g IVI 6 hourly) was added in staggered doses. Additional blood specimens were submitted for bacterial and fungal culture, and for testing for the presence of cold agglutinins[7] and for serology for *M. pneumoniae* (immunofluorescence antibody test, Zeus Technologics Incorporated, New Jersey) and *Legionella pneumophila* (indirect fluorescent antibody test).[8]

Packed red blood cell transfusions were required to maintain the falling haemoglobin which was, in retrospect, most probably a function of the cold agglutinin, autoimmune haemolytic anaemia associated with *M. pneumoniae* infection.[7] Despite the low legionella antibody titre which was not diagnostic on its own but was unfortunately not followed up for evidence of a 4-fold rise in titre, it is felt that the overwhelming evidence pointed towards the diagnosis of a mycoplasmal infection. No pathogenic organisms were isolated on sputum culture. The Legionella serology showed a titre of 1/64. Cold agglutinins were detected and on serological testing positive *Mycoplasma pneumoniae* IgM antibodies were present.

The patient began to improve slowly from day two. PEEP and FiO_2 were weaned slowly, together with the adrenaline, isoprenaline and dopamine infusions.

Extubation was possible on day 10 and erythromycin, clindamycin and cefotaxime were continued for a further day following discharge from ICU (10 day course of antibiotics). The patient's further recovery was uneventful and he was discharged well from hospital.

Discussion

Mycoplasma pneumoniae is a well-known cause of community-acquired pneumonia, particularly in patients not requiring hospitalisation[9,10] and usually affects children and young adults, although no age group is immune.[11] Both respiratory and non-respiratory syndromes may result.[9,10] Fatal cases of *M. pneumoniae* pneumonia are rare, although isolated case reports do appear in the literature.[12,13,14,15,16,17,18]

Patients with respiratory tract involvement usually present with rhinorrhoea, pharyngitis and otalgia. Clinically apparent pneumonia occurs in less than 10% of patients infected with *M.pneumoniae*, while the majority of ill patients develop only pharyngitis or bronchitis.[19] Fever ($T° > 38.9$ °C), followed by chills, headache and non-productive cough are the most common symptoms.[9] Purulent sputum, haemoptysis and pleuritic chest pain are less commonly found. Characteristically, radiological evidence of consolidation on chest radiograph is not matched by as extensive physical signs. Acquisition of the disease is via inhalation of infected material on exposure to infected individuals, with an incubation period of 2 weeks.[9]

In the vast majority of patients who develop clinically apparent *M. pneumoniae* pneumonia, should abrupt deterioration occur in their clinical status, such deterioration is reported to occur only 7-14 days following the onset of illness.[1] This is in contrast to the short duration (2 days) prior to deterioration experienced in our case, a feature more in keeping with the more common bacterial pneumonias.

The best discriminating variables between the more common bacterial pneumonias and *M. pneumoniae* infection are usually the presence or absence of predisposing disease or previous antibiotic treatment, the ESR rate (ESR was 5 mm in our case), the presence of lymphocytes and the band neutrophils count.[10] The common bacterial pneumonias are favoured by predisposing disease, a short duration of illness before hospitalisation, the presence of alcoholism, the absence of signs of an upper respiratory tract infection, high C-reactive protein determinations and ESR, total leukocyte counts greater than 15.0 x 10^9/l, abnormal auscultatory findings and the presence of lobar consolidation on chest radiograph. *M. pneumoniae* pneumonia, however, usually presents with symptoms before hospitalisation for a long period of time, and patients are often more likely to have received antibiotic treatment before such hospitalisation.[10] Neither of these factors pertained in our case. Lobar consolidation also occurs in mycoplasma pneumonia and no distinction between it and the usual bacterial pneumonias can be made on the basis of radiological changes alone. However, radiological resolution is usually most rapid in *M. pneumoniae* infections.

Appropriate diagnostic investigations for the detection of *M. pneumoniae*, such as sputum and blood cultures, are mandatory, although more commonly mycoplasma infection is diagnosed on positive serology and by the demonstration of the presence of cold agglutinins.

Although mycoplasma pneumonia is very seldom the cause of life-threatening illness, such cases are being reported in the literature. The need to consider *M. pneumoniae* as the infecting agent in acutely ill patients with progressive pneumonias requiring ICU admission is stressed. In critically ill patients with pneumonia, particularly those unresponsive to usual empiric antimicrobial therapy, therapy with agents effective against *M. pneumoniae* should be considered early. This treatment should be instituted even before a positive diagnosis has been established. Failure to consider *M. pneumoniae* as the cause of infection may lead to death from an illness, usually eminently treatable with antibiotics such as erythromycin or tetracycline.

References

1. Koletsky RJ, Weinstein AJ. Fulminant *Mycoplasma pneumoniae* infection: Report of a fatal case, and a review of the literature. *Am Rev Resp Dis* 1980; **122:** 491-496.
2. Kaufman JM, Cuvelier CA, van der Straeten M. *Mycoplasma* pneumonia with fulminant evolution into diffuse interstitial fibrosis. *Thorax* 1980; **35:** 140-144.
3. Jastremski MS. Adult respiratory distress syndrome due to *Mycoplasma pneumoniae*. *Chest* 1979; **75:** 529.
4. Levine DP, Lemer AM. The clinical spectrum of *Mycoplasma pneumoniae* infections. *Med Clin North Am* 1978; **62:** 961-978.
5. Linz DH, Tolle SW, Elliot DL. *Mycoplasma pneumoniae* pneumonia. Experience at a referral centre. *Western J Med* 1984; **140:** 895-900.
6. McGonigle R, Wagstaff JK. Life threatening *Mycoplasma pneumoniae* infection. *Postgrad Med J* 1980; **56:** 675-676.
7. Knight V. *Mycoplasma pneumoniae* infections. In: Petersdorf RG, Adams RD, Braunwald E, Isselbacher KJ, Martin JB, Wilson JD. Harrison's principles of internal medicine. 10th ed. McGraw Hill Book Co, New York, 1983: 1078-1079.
8. Wilkinson HN, Fikis BJ, Cruce DD. Indirect immunofluorescence test for serodiagnosis of Legionnaire's disease: evidence for serodiversity of Legionnaire's disease bacterial antigens and for multiple specificity of human antibodies. *J Clin Microbiol* 1979; **9:** 379-383.
9. Pennington JE. Respiratory infections: diagnosis and management. Raven Press, New York, 1983: 251-267.
10. Luby JP. Southwestern Internal Medicine Conference. Pneumonias in adults due to mycoplasma, chlamydiae and viruses. *Am J Med* 1987; **294:** 45-64.
11. White RJ, Blainey AD, Harrison JK, Clarke SKR. Causes of pneumonia presenting to a district general hospital. *Thorax* 1981; **36:** 566-570.
12. DeVos M, Van Nimmen L, Baele G. Disseminated intravascular coagulation during a fatal *Mycoplasma pneumoniae* infection. *Acta haematol* (Basel) 1974; **52:** 120-125.
13. Maisel JC, Babbitt LH, John TJ. Fatal *Mycoplasma pneumoniae* infection with isolation of organisms from lung. *JAMA* 1967; **202:** 287-290.
14. Sterner G, Biberfeld G. Central nervous system complication of *Mycoplasma pneumoniae* infection. *Scand J Infect Dis* 1969; **1:** 203-208.
15. Nilsson IM, Rausing A, Denneberg T, Christensson P. Intravascular coagulation and acute renal failure in a child with mycoplasma infection. *Acta Med Scand* 1971; **189:** 359-365.
16. Meyers BR, Hirschman SZ. Fatal infections associated with *Mycoplasma pneumoniae:* discussion of three cases with necropsy findings. *Mt Sinai J Med NY* 1972: **39:** 258-264
17. Naftalin JM, Wellisch G, Kahana Z, Diengott D. *Mycoplasma pneumoniae* septicemia. *JAMA* 1974; **228:** 565.
18. Dorff B, Lind K. Two fatal cases of meningoencephalitis associated with *Mycoplasma pneumoniae* infection. *Scand J Infect Dis* 1976; **8:** 49-51.
19. Forsyth BR, Chaneck RM. Mycoplasma pneumonia. *Annu Rev Med* 1966; **17:** 371-382.