

https://dspace.org/

Balloon valvuloplasty for valvar pulmonary stenosis A 34year experience at a large tertiarylevel hospital Southern Africa

Phophi Raphulu (nee Manenzhe); M Mamaila Lebea; Antoinette Cilliers

https://hdl.handle.net/10539/44781
DOAJ

Downloaded from a DSpace repository. https://dspace.org/

Balloon valvuloplasty for valvar pulmonary stenosis: A 34-year experience at a large tertiary-level hospital, Southern Africa

Phophi Raphulu[1,2], Mamaila Martha Lebea[3] and Antoinette Cilliers[1,2]

[1]Division of Paediatric Cardiology, Chris Hani Baragwanath Academic Hospital, Soweto, South Africa
[2]Faculty of Health Sciences, University of the Witwatersrand, Division of Paediatric Cardiology, Johannesburg, South Africa
[3]Netcare Sunninghill Hospital, Johannesburg, South Africa

Address for correspondence:
Dr Phophi Raphulu
Chris Hani Baragwanath Academic Hospital
26 Chris Hani Road
Diepkloof extension
Soweto
Johannesburg
1864
South Africa

Email:
Phophi.Manenzhe@wits.ac.za

ABSTRACT

Background: Congenital pulmonary valve stenosis (PS) is one of the most common congenital cardiac defects, accounting for 8% - 12% of all congenital cardiac defects. Percutaneous balloon pulmonary valvuloplasty (PBPV) has been the preferred treatment since its introduction in 1982.
Aim: To evaluate the efficacy and safety of PBPV over the last 3 decades at a single institution.
Method: A retrospective, descriptive analysis was conducted at a tertiary-level hospital in Southern Africa to evaluate patients who underwent PBPV between 1985 and 2019.
Results: During the study period, 68 patients underwent balloon valvuloplasty for moderate to severe pulmonary stenosis. Patients were selected using echocardiographic criteria. The mean pulmonary valve annulus measured on angiography was 11.2mm (SD 3.9) with a mean balloon size of 13.1mm (SD 4.4). The balloon size to pulmonary valve annulus ratio was 1.169:1. The median peak instantaneous gradient (PIG) before balloon valvuloplasty was 79mmHg (IQR 64 - 102mmHg) which decreased to 33mmHg (IQR 23 - 40mmHg) after balloon valvuloplasty (p<0.001). There was an 88% success rate. Complications occurred in 8/68 (11.7%) patients, with 1 procedural death reported.
Conclusion: Our study shows that PBPV is a safe and effective treatment of moderate and severe PS with a good outcome. Complications are rare if the procedure is well planned and managed promptly if they arise.
SA Heart® 2024;21:258-263

INTRODUCTION

Congenital pulmonary valve stenosis (PS) is one of the most common congenital cardiac defects, accounting for 8% - 12% of all defects.[1] PS can occur as an isolated defect or in association with other cardiac defects.[1] The associated cardiac defects include atrial septal defect (ASD), ventricular septal defect (VSD) and patent ductus arteriosus (PDA).[1] Congenital PS may be found in association with genetic syndromes including Noonan, Holt-Oram, Leopard, William, and Allagile Syndromes.[1] Acquired PS is rare in the paediatric population.[1] The pathologic features of the stenotic pulmonary valve vary, with the most common variety being a dome-shaped pulmonary valve.[2] The fused pulmonary valve leaflets protrude from their attachment into the pulmonary artery as a conical, windsock-like structure.[2] Pulmonary valve ring hypoplasia and dysplastic pulmonary valves where the leaflets are not fused but are thickened, may be present in a small percentage of patients.[2] The diagnosis can be made on clinical cardiac examination by the presence of a murmur and confirmed by echocardiography.[3]

The severity of the PS is classified as mild to severe using an echocardiographically derived Doppler flow gradient.[1,3] Critical PS is associated with very poor pulmonary blood flow and may be confused with cyanotic heart disease because there is usually right-to-left shunting through the patent foramen ovale (PFO) or an atrial septal defect (ASD) and survival is dependent on the patency of a ductus arteriosus.[1,3]

Surgery was the treatment of choice for valvar pulmonary stenosis in the past.[4] However, percutaneous balloon pulmonary valvuloplasty (PBPV) has become the preferred alternative treatment since its introduction in 1982 by Kan, et al.[4] Success rates of approximately 75% - 88% have been reported with PBPV.[4,5] The first attempt to relieve pulmonary valve obstruction by transcatheter methodology was in the early 1950s by Rubio-Alverez, et al.[2,6,7] where they used a ureteral

catheter percutaneously with a wire to cut open a stenotic pulmonary valve.[2,6,7] More recently, Kan and associates applied the technique of Gruentzig, et al. to relieve pulmonary valve obstruction by using an inflated balloon catheter positioned across the pulmonary valve.[2] Initial recommendations were to use balloon sizes 20% - 40% larger than the pulmonary valve annulus, with a balloon to pulmonary valve annulus ratio of 1.2 – 1.4.[4] The use of balloon sizes 20% - 40% larger than the pulmonary valve annulus was associated with the development of pulmonary insufficiency at late follow up.[4] In subsequent years, the use of balloon size 1.1-1.2 larger than the pulmonary valve annulus has been recommended to prevent the development of significant pulmonary insufficiency at late follow-up.[4] A good response is achieved using PBPV in patients with moderate to severe pulmonary valve stenosis, however, dysplastic pulmonary valves may not respond to balloon dilatation and frequently require surgical treatment.[8]

Immediate-, short-, and mid-term outcomes of balloon pulmonary valvuloplasty are well documented, but there is limited information on long-term results.[9,10,11,12] Pulmonary oedema complicating balloon dilatation of the pulmonary valve is rare and usually associated with treatment of severe stenosis.[13] This complication was described by Shrivastava, et al. where they reported 2 children who developed pulmonary oedema following PBPV.[13] Management includes administration of diuretics, inotropes, and ventilatory support. One of the 2 cases of pulmonary oedema reported by Shrivastava, et al. proved to be fatal despite treatment.[13] Right ventricular outflow tract obstruction or hypercontractile infundibular obstruction, otherwise known as "suicide right ventricle", may appear after balloon valvuloplasty, particularly in those patients with severe pulmonary valve obstruction.[14] Relief of the infundibular obstruction can be treated with administration of b-blockers.[14, 15] Additional treatments include fluid administration combined with beta-blockers or calcium channel blockers.[15] A sudden decompensation of the patient post BPV or surgery, therefore, should alert one to the possibility of infundibular obstruction particularly in patients with supra-systemic right ventricular pressure.[15] Pre-procedure administration of a beta-blocker may be helpful as a prevention strategy.[15]

A successful PBPV is labelled as successful if the peak-to-peak angiographic pressure gradient (PG) is reduced to less than 50% of its initial value.[16] A suboptimal result is regarded as a PG reduced by 25% - 49% and unsuccessful result if the PG is reduced by less than 25%.[16] Restenosis has been described in 10% of children who undergo PBPV particularly in instances where a balloon / annulus ratio <1.2 was used.[17,18] Redilatation of the pulmonary valve in patients who develop restenosis following previous PBPV has been associated with good results and is the procedure of choice in this group of patients.[17,18] Results of late follow up of PBPV are excellent, with some patients having mild residual pulmonary regurgitation.[18,19] The use of large balloon sizes, complex valvular morphology due to a previous surgical valvotomy, or the presence of dysplastic valves have been associated with the development of significant pulmonary regurgitation following PBPV.[20,21,23,24]

METHODS AND MATERIALS

Study design

We conducted a retrospective, descriptive analysis at a tertiary-level hospital in Southern Africa to evaluate patients who underwent percutaneous balloon pulmonary valvuloplasty (PBPV) between February 1985 - May 2019.

Statistical analysis

Data was extracted from the electronic paediatric cardiology database at CHBAH, and hospital records were interrogated.

Descriptive statistics presented continuous variables as means and standard deviations (SD) for normally distributed data, and as medians with interquartile ranges (IQR) for skewed data. The Shapiro-Wilk test was used to test for normality of the pressure gradients. The Mann-Whitney U test was used to compare medians. P-values <0.05 were considered significant. Data were analysed using Stata.

Definitions

Severity of PS based on echocardiographic derived Doppler gradients.[1]

- **Mild PS** is defined as a Doppler flow gradient less than 36mmHg.[1]
- **Moderate PS** is defined as a Doppler flow gradient between 36 and 64mmHg.[1]
- **Severe PS** is defined as a Doppler gradient greater than 64mmHg.[1]
- **Successful PBPV** is defined as a reduction of the pressure gradient across the pulmonary valve to less than 50% of its initial value.[16]
- A **suboptimal result** is defined as a reduction of the pressure gradient by 25% - 49%.[16]
- **Unsuccessful PBPV** is defined as a reduction of the pressure gradient by less than 25%.[16]

RESULTS

During the study period from February 1985 - May 2019, 68 patients underwent balloon valvuloplasty at CHBAH. Patients were selected using echocardiographic derived Doppler gradients.

Echocardiographic derived Doppler gradients before PBPV, balloon sizes, pulmonary valve annulus, patient demographics, and complications were documented for all 68 patients. Patient selection for balloon valvuloplasty was based on echocardiographic derived Doppler gradients and not symptomatology. When record review was conducted, immediate pressure gradients after PBPV were documented for 60/68 patients; however the echocardiographically derived Doppler gradients at 3 month follow-up were documented for all 68/68 patients. Descriptive analysis (Median, IQR) to assess the statistical significance in the reduction of the pressure gradients after PBPV was done on the 60/68 patients who had documentation of the immediate post-PBPV pressure gradients. On analysis of the outcome of patients who underwent PBPV, the 3 month follow-up echocardiographically derived Doppler gradients were included.

Characteristics of patients

Of the 68 patients, 5/68 (7%) were less than 1 month of age, and 63/68 (93%) were older than 1 month of age. There was a male:female ratio of 1.1:1. The indication for PBPV was moderate PS in 14/68 (21%) patients and severe PS in 54/68 (79%) patients (Table I).

Echocardiography and catheterisation data

The mean pulmonary valve annulus measured on angiography (Figure IA) was 11.2mm (SD 3.9) and the mean balloon size was 13.1mm (SD 4.4). The balloon size (Figure IB) to pulmonary valve annulus ratio was 1.169:1 (SD 1.1) (Table II).

TABLE I: Characteristics of patients (n=68).

Age stratification	
<1 month	5/68 (7.4%)
>1 month	63/68 (93%)
Gender	
Male	35/68 (51%)
Female	33/68 (49%)
Indications	
Moderate PS	
(PIG 36 – 64mmHg)	14/68 (21%)
Severe PS	
(PIG >64mmHg)	54/68 (79%)

PS: Pulmonary stenosis, PIG: Peak instantaneous gradient.

Outcomes

There was an 88% success rate. A suboptimal reduction was found in 5/68 (7.4%) of patients due to the presence of dysplastic valves. One of the patients had a co-morbid sinus venosus ASD which required surgery (Table III).

TABLE II: Echocardiography and catheterisation data.

Parameter	Mean (SD)
Pulmonary valve annulus (mm)	11.2 (3.9)
Balloon size (mm)	13.1 (4.4)
Balloon / PV size ratio	1.169:1

SD: Standard deviation, PIG: Peak instantaneous gradient, PV: Pulmonary valve, BV: Balloon valvuloplasty.

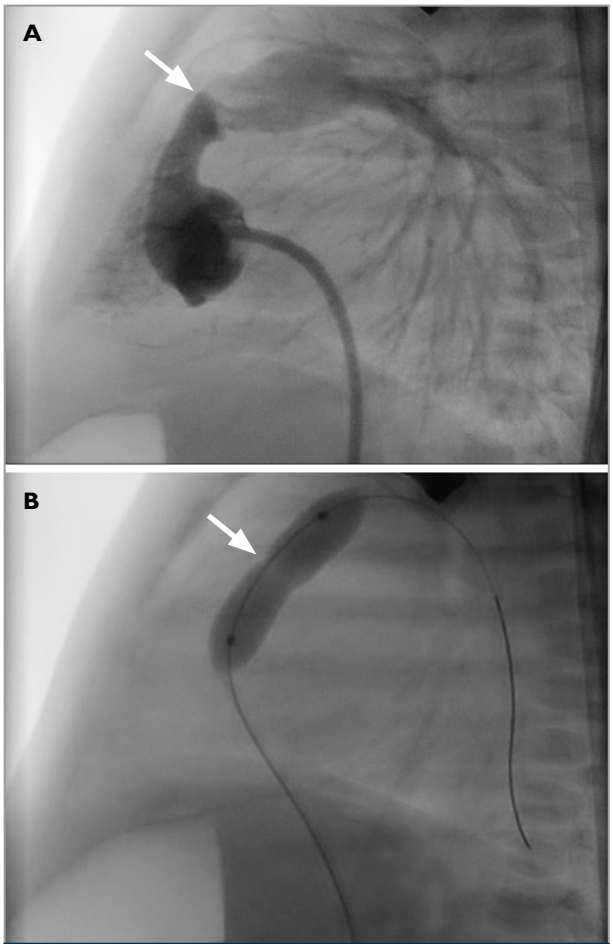

FIGURE 1: Angiography and fluoroscopy during PBPV.
A: RV angiogram in lateral view showing a doming pulmonary valve (arrow).
B: Balloon catheter with wire and inflated balloon showing a "waist" caused by the stenotic pulmonary valve (arrow).
RV: Right ventricle, PBPV: Percutaneous balloon pulmonary valvuloplasty.

Descriptive and analytical statistics for pre- and post-balloon dilatation gradients

We tested for normality of the peak instantaneous gradient (PIG) pre- and post-balloon dilatation (BD) using the Shapiro-Wilk test (p-value=0.015 and 0.016, respectively). Both were not normally distributed hence the medians and inter-quartile ranges (IQR) are reported. The median pre-BD PIG was higher than the post-BD PIG (79mmHg vs. 33mmHg). We tested whether there was a statistically significant difference pre-BD PIG and post-BD PIG using the Wilcoxon signed-rank test and found strong evidence that the pre- and post-PIG were significantly different (Table IV).

Complications

Complications occurred in 8/68 (11.7%) patients, with 1 death reported. An iatrogenic "suicide right ventricle" or hyper-contractile infundibular obstruction was observed in 2 patients, while 1 patient developed reperfusion pulmonary oedema. One patient developed sudden severe tricuspid regurgitation during the procedure caused by ruptured tricuspid valve chordae due to a sudden downward movement of the balloon across the tricuspid valve during balloon inflation, and 2 patients developed severe pulmonary regurgitation. Both patients who developed severe pulmonary regurgitation had dysplastic pulmonary valves. One of the patients who developed severe pulmonary regurgitation required serial balloon dilatations; however, the balloon / PV ratio of the biggest balloon used was 1.1:1, which is acceptable. The other patient who developed severe pulmonary regurgitation also had appropriate balloon sizing, with a balloon / PV ratio of 1.2:1. One patient had a cardiac arrest during the procedure during cannulation of the PV with the balloon and developed cerebral palsy. One patient had perforation of the right ventricular outflow tract with a wire, and subsequently died. The patient who had perforation of the right ventricular outflow tract was a neonate with critical pulmonary stenosis. This happened during the first decade of the study (Table V).

TABLE III: Immediate outcomes.

Outcome (n=68)	
Good outcome	60/68 (88.2%)
Suboptimal pressure reduction	5/68 (7.4%)
Procedure not undertaken due to complications	3/68 (4.4%)
Reasons for suboptimal reduction (n=5)	
Dysplastic pulmonary valve	5/5 (100%)

ASD:Atrial septal defect, PV: Pulmonary valve, RVOT: Right ventricular outflow tract.

TABLE IV: Descriptive and analytical statistics for pre- and post-balloon dilatation gradients.

	Shapiro-Wilk test for normality p-value	Median (IQR) PIG, mmHg	Wilcoxon signed rank test p-value
PIG pre-BD, n=60	0.015	79 (64 - 102)	<0.001
PIG post-BD, n=60	0.016	33 (23 - 40)	<0.001

TABLE V: Complications.

Complications (n=68)	
Suicide right ventricle	2/68 (2.9%)
Reperfusion pulmonary oedema	1/68 (1.5%)
Severe pulmonary regurgitation	2/68 (2.9%)
Ruptured TV chordae	1/68 (1.5%)
Cerebral palsy	1/68 (1.5%)
RVOT perforation with a wire	1/68 (1.5%)
Mortality	1/68 (1.5%)

TV: Tricuspid valve, RVOT: Right ventricular outflow tract.

Follow up at 3 months

Patients with dysplastic pulmonary valves

Three out of the 5 patients who had dysplastic valves had no change in the immediate post-balloon dilatation gradient; however, they were monitored clinically and were noted to have a further reduction in the pulmonary valve gradient at 3 months, which required no further intervention. One out of the 5 patients went on to have a surgery in the form of a transannular patch. One out of the 5 patients was unfortunately lost to follow-up.

Patients with severe pulmonary regurgitation

The 2 patients who developed severe pulmonary regurgitation are currently asymptomatic and being monitored clinically.

DISCUSSION

Congenital pulmonary valve stenosis (PS) is one of the most common congenital cardiac defects with a good outcome if treated correctly.[1,4] PS can occur in isolation or in association with other cardiac defects or syndromes, most commonly Noonan Syndrome.[1] The pathologic features of PS vary, with the dome-shaped pulmonary valve being the most common type.[2] In our cohort of patients, the majority of patients, 92.6% (60/68), had the fused pulmonary valve leaflet and a doming pulmonary valve variety with a minority of patients having dysplastic leaflets, 7.4% (5/68).[2] The findings of majority of patients having fused pulmonary valve leaflets with a doming

pulmonary valve and a minority with dysplastic valves in our study is similar to the findings of a study done by Rao PS.[2]

The indications for PBPV in our cohort were moderate PS (21%) and severe PS (79%), based on the echocardiographically derived Doppler gradient, similar to other studies where PBPV was done in patients with moderate and severe PS.[2,8,11,18]

The mean pulmonary valve annulus measured on angiography was 11.2mm (SD 3.9) and the mean balloon size was 13.1mm (SD 4.4), with a balloon to PVA ratio of 1.169:1. A slightly smaller balloon / PVA of 1.125 ratio was documented by Maostafa, et al. where the mean pulmonary valve annulus was 14.23mm (SD2.7) and the mean balloon size was 16.02mm (SD 3.00).[4] The majority of the patients in the latter study were infants and older children, with no reference made to neonates. Smaller balloon / PVA ratios of 1.1 were used in neonates in a study conducted by Loureiro P, et al. and the recommendation is to use balloon sizes not exceeding a balloon / PVA ratio of 1.1 in this age group.[23]

The success rate of PBPV in our cohort was 88%, which is similar to what has been reported by studies done in Iran and Spain, with reported success rates ranging from 75% - 88%.[4,5] The median peak instantaneous (PIG) before balloon valvuloplasty was 79mmHg (IQR 64 - 102mmHg) which decreased to 33mmHg (IQR 23 - 40mmgHg) after balloon valvuloplasty. There was a poor response to PBPV in the minority of the study patients (7.4%, n=5) due to the presence of dysplastic valves which are poorly responsive to balloon valvuloplasty. Similarly, 6.7% (n=4) of the cohort reported by Maostafa, et al. had dysplastic pulmonary valves.[4]

Although PBPV has a good success rate a small number have complications that the interventionalist needs to be aware of, in particular pulmonary oedema and infundibular obstruction.[13,14] Shrivastava, et al. from Escorts Heart Institute and Research Centre, New Delhi, India, described 2 cases of pulmonary oedema soon after balloon dilatation of the pulmonary valve.[13] These patients were treated with diuretics, inotropes, and ventilatory support.(13) Only 1/68 (1.47%) patients in our study developed pulmonary oedema following PBPV. This patient showed a good response to diuretics and ventilatory support. Although our patient who developed pulmonary oedema responded to treatment, some cases have been reported to be fatal despite treatment, as reported by Shrivastava, et al.[13] Due to the risk of fatality associated with pulmonary oedema following PBPV, this complication needs to be anticipated prior to starting the procedure.

Infundibular obstruction after PBPV, also referred to as a "suicide right ventricle", may be related to the severity of pulmonary valve obstruction and a hypercontractile infundibulum.[14,15] This complication is rare, and normally results in cases where the RV pressure is suprasystemic before the procedure.[15] Chinawa, et al. did a systematic review from 1987 - 2016, published in the Nigerian Journal of Cardiology, looking at suicidal right ventricle in children and adults following PBPV.[15] The review showed that this complication is rare, which is similar to the findings from our study where this complication was seen in 2/68 (2.9%) patients. Relief of the infundibular obstruction can be treated with administration of b-blockers.[14,15] The patients in our cohort were treated with beta-blockers, with both showing a good response. Suicide right ventricle should be anticipated particularly in patients who have suprasystemic RV pressure prior to the procedure, and pre-procedure administration of a beta-blocker may be helpful as a prevention strategy.[15]

Another complication described is the development of pulmonary regurgitation. Most studies report a low incidence of significant pulmonary regurgitation following PBPV in the paediatric population.[4,20,21] Studies done by Maostafa, et al. in Iran and Al Balushi, et al. in Muscat reported a low incidence of significant pulmonary regurgitation.[4,21] Maostafa, et al. reported an incidence of 18% for moderate pulmonary regurgitation and 6% for severe regurgitation.[4] Al Balushi reported an incidence of 3.8% for moderate pulmonary regurgitation. The low incidence of significant pulmonary regurgitation reported was similar to the findings in our study, with only 2/68 (2.9%) developing severe pulmonary regurgitation in our study. The use of large balloon sizes, complex valvular morphology due to a previous surgical valvotomy or the presence of dysplastic valves have been associated with the development of significant pulmonary regurgitation following PBPV.[24]

The 2 patients who developed severe pulmonary regurgitation in our cohort had balloon to PVA ratios of 1.1 and 1.2 respectively used, which is within the recommended range. One patient had serial balloon dilatations done; however, the biggest balloon used had a balloon to PVA ratio of 1.2. Both patients who developed severe pulmonary regurgitation had dysplastic valves. It appears that in our cohort the development of pulmonary regurgitation was observed in some patients with dysplastic valves and was not related to the balloon sizing as both patients had adequate balloon sizing. The presence of complex valvular morphology, which includes dysplastic valves has also been associated with the development of significant pulmonary regurgitation as reported in a study done by Hatem, et al. which may have been the risk factor associated with severe pulmonary regurgitation in our patients.[24] In addition

to adequate balloon sizing as a precaution to prevent the development of severe pulmonary regurgitation, patients with complex valvular morphology should be monitored closely for the development of this complication. The 2 patients who developed severe pulmonary regurgitation in our study have remained asymptomatic and are currently being monitored clinically.

In our cohort, 1 patient died during PBPV following perforation of the RVOT with a wire. The patient who died was a neonate with critical pulmonary stenosis. This complication of RVOT perforation has been described by Maostafa, et al. where they also encountered a death in a neonate with critical pulmonary stenosis following perforation of the RVOT.[4]

Over the 3 decades of our study, the procedure of PBPV has evolved. During the first decade of the study, a balloon to PVA ratio of 1.3 was used, which changed over the years to a ratio of 1.2, with more research done around the procedure. The technique of PBPV and patient selection have remained the same over the 3 decades of the study. Furthermore, there has been an increase in awareness and anticipation of immediate complications described, such as pulmonary oedema and suicidal right ventricle, resulting in prompt treatment of such complications when they arise.

CONCLUSION

PBPV is a safe and effective treatment of moderate and severe PS with a good outcome and should continue to be the treatment of choice for moderate and severe PS. Complications are infrequent if procedural guidelines are followed. Rare complications such as infundibular obstruction and pulmonary oedema following PBPV should be anticipated and managed quickly. Appropriate sizing of the balloon is important to avoid the development of significant pulmonary regurgitation.

LIMITATIONS

The retrospective nature of the study and the small sample size are limitations of our study.

FUTURE RESEARCH

Most studies have looked at short- and medium-term complications of PBPV, but there are few studies that focus on the long-term complications. An area for future research would be to look at the long-term complications of PBPV.

Conflict of interest: none declared.

REFERENCES

1. Mitchell B, Mhlongo M. The diagnosis and management of congenital pulmonary valve stenosis. SA Heart® 2018;15(1):36-45.
2. Rao PS. Balloon pulmonary valvuloplasty in children. JIC 2005.
3. Amoozgar H, Salehi M, Borzoee M, et al. Balloon valvuloplasty for pulmonary stenosis in children: Immediate outcome and cardiac remodelling during mid-term follow-up. Iran J Paediatr 2017;27(6):e10058.doi:10.5812/ijp.10058.
4. Maostafa BA, Seyed-Hossien M, Shahrokh R. Long-term results of balloon pulmonary valvuloplasty in children with congenital pulmonary valve stenosis. Iran J Paediatr 2013;23(1):32-36.
5. Merino-Ingelmo R, Santos-de Soto J, Coserria-Sanchez F, Descalzo-Senoran A, Valverde-Perez I. Long-term results of percutaneous balloon valvuloplasty in pulmonary valve stenosis in the paediatric population. Rev Esp Cardiol 2014;67(5):374-379.
6. Rubio-Alvarez V, Limon-Lason R, Soni J. Intracardiac valvulotomy by means of a catheter. Arch Inst Cordiol Mexico 1953;23:183.
7. Rubio V, Limon-Lason R. Treatment of pulmonary valvular stenosis and tricuspid stenosis using a modified catheter. 2nd World Congress of Cardiology, Washington DC, Programme Abstract 1954; II:205.
8. Balfour IC, Rao PS. Pulmonary stenosis. Curr Treat Options Cardio Med 2000;489-498.
9. Akcurin G, Kahramanyol O, Atakan C. Intermediate-term follow-up results of pulmonary balloon valvuloplasty in children. Turk J Paediatr 2000;42(2): 126-31.
10. Luo F, Xu WZ, Xia CS, et al. Percutaneous balloon pulmonary valvuloplasty for critical pulmonary stenosis in infants under 6 months of age and short- and medium-term follow-up. Zhonghua Er Ke Za Zhi 2011;49(1):17-20.
11. Hernadez Cobeno MA, Bermudez-Canete R, Herraiz I, et al. Percutaneous balloon valvuloplasty in pulmonary valve stenosis. Arq Bras Cardiol 2004; 82(3):221-227.
12. Cheragh H, ul Hassan M, Hafizullah M, Gul AM. Outcome of balloon pulmonic valvuloplasty with 18 months follow up. J Ayub Med Coll Abbottabad 2009;2(3):95-99.
13. Shrivastava S, Tomar M, Radhakrishnan S. Acute pulmonary oedema following percutaneous balloon pulmonary valvuloplasty in children. Cardiology in the Young 2003;13(6):576-578.
14. Ben-Shachar G, Cohen M, Sivakoff M, et al. Development of infundibular obstruction after percutaneous pulmonary balloon valvuloplasty. J AM Coll Cardiol 1985;5(3):754 -756.
15. Chinawa JM, Chinawa AT, Chukwu BF, Duru CO, Eze JC, Nwafor AI. Suicidal right ventricle in children and adults: Trends, triggers, and treatment: A systematic review of a rare but catastrophic event. Nig J Cardiol 2020; 17:87-91.
16. Mughal AR, Saeed MH, Ahmad M, Sadiq M. Early outcome of balloon pulmonary valvuloplasty for pulmonary valve stenosis in adolescents and adults: Experience at a tertiary care cardiac institute. APMC 2020;14(3):200-204.
17. Rao PS. Percutaneous balloon pulmonary valvuloplasty: State of the art. Catheter Cardiovasc Interv 2007;69(5):747-63. doi: 10.1002/ccd.20982. PMID: 17330270.
18. Rao PS, Galal O, Patnana M, Buck SH, Wilson AD. Results of 3 - 10 year follow-up of balloon dilatation of the pulmonary valve. Heart 1998; 80: 591-595.
19. O'Connor BK, Beekman RH, Lindauer A, Rocchini A. Intermediate-term outcome after pulmonary balloon valvuloplasty: Comparison with a matched surgical control group. J Am Coll Cardiol 1992;20:169-173.
20. Poon LK, Menahem S. Pulmonary regurgitation after percutaneous balloon valvuloplasty for isolated pulmonary valvar stenosis in childhood. Cardiol Young 2003;13:444-450.
21. Al Balushi AY, Al Shuaili H, Al Khabori M, Al Maskri S. Pulmonary valve regurgitation following balloon valvuloplasty for pulmonary valve stenosis: Single centre experience. Ann Paediatr Card 2013;6:141-4.
22. Ring JC, Kulik TJ, Burke BA, Lock JE. Morphologic changes induced by dilation of the pulmonary valve anulus with overlarge balloons in normal new-born lambs. Am J Cardiol 1985;55:210-214.
23. Loureiro P, Cardoso B, Gomes I, Martins J, Pinto F. Long-term results of percutaneous balloon valvuloplasty in neonatal critical pulmonary valve stenosis: A 20-year, single-centre experience. Cardiology in the Young 2017;27(7):1314-1322.
24. Hatem DM, Castro I, Haertel JC, et al. Short- and long-term results of percutaneous balloon valvuloplasty in pulmonary valve stenosis. Arq Bras Cardiol 2004;82(3):228-234.