

https://dspace.org/

A comparison between bone grafting and non-grafting of immediately placed implants in the molar area

Van der Linden, Wynand Johan

2024
https://hdl.handle.net/10539/37615

Downloaded from a DSpace repository. https://dspace.org/

A COMPARISON BETWEEN BONE GRAFTING AND NON-GRAFTING OF IMMEDIATELY PLACED IMPLANTS IN THE MOLAR AREA.

Author: Dr. Wynand Johan van der Linden BDS (Wits)

Student number 353106

Supervisor: Prof. E. Rikhotso, BDS (Wits), M.DENT, FCMFOS (SA)
Department of Maxillofacial and Oral Surgery
University of the Witwatersrand
Johannesburg

A research report submitted to the Faculty of Health Sciences, University of the Witwatersrand, Johannesburg, in partial fulfilment of the requirements for the degree of Master of Science in Dentistry

Johannesburg 2022

Declaration: Student's contribution to article(s) and agreement of co-author(s)

I, Wynand Johan van der Linden, student number 353106, declare that this Research Report is my own work and that I contributed adequately towards research findings published in the article(s) stated below which are included in my Research Report.

Signature of Student…….....Date…….....…

Name of Primary Supervisor…….....……

Signature of Primary Supervisor ……Date……...…….....…

DEDICATION

To my parents, thank you for all your guidance and inspiration.

ABSTRACT

Aim: This study aims to investigate the outcome of placing a bone graft material into the residual socket space of a fresh molar extraction socket, treated flapless after an implant has been placed compared with a control group at three months.

Methodology: This prospective, randomized, control, double-blind clinical trial will evaluate the difference in ridge width between a control and intervention (grafting) group at baseline and three months postoperatively. All cases were evaluated using pre-operative (T_0) and three months postoperative (T_1) impression models. Horizontal measurements were taken at 3 levels (2, 4, and 6mm). Vertical point measurements were done at 3 points (A, B, and, C) and compared between the two groups.

Results: The study consisted of 22 participants, 11 in the control and 11 in the grafting group with a mean age of 49.5 years. Majority of the cases presented in the mandible (64%) with one case of implant failure. Bone loss was perceived to be greater in the control group after 3 months compared to the loss observed in the grafting group. The difference in the loss of ridge width between the control and grafting groups was insignificant (p-value>0.05).

Conclusion: The difference in the loss of ridge width between the control and grafting group was insignificant (p-value>0.05), owing to the study's small sample size. Less bone resorption was observed in the grafting group at 3 months post–implant placement, however, the long-term follow-up would be required to determine the effectiveness of the bone graft.

Further studies with larger population samples and increased follow-up time (6 months, 12 months, and 24 months) should be considered to determine the long-term benefit of bone grafting done simultaneously with tooth extraction and immediate implant placement.

Acknowledgements

Thank you to Dr W van der Linden for agreeing to participate in this study and for providing the patients to make this study possible. Thank you to Prof. E Rikhotso for supervising the project and for advice and guidance over the period of the MSc Dent course. Thank you to Dr R. Reed for his assistance with the statistical analysis.

Contents

1. LIST OF FIGURES 6

2. INTRODUCTION 7

3. STUDY OBJECIVES 14

4. MATERIALS AND METHODS 15

5. RESULTS 21

6. DISCUSSION 26

7. CONCLUSION 32

8. REFERENCES 33

9. APPENDIX 42

1. LIST OF FIGURES

FIGURE 1 17

FIGURE 2 18

FIGURE 3 19

FIGURE 4 25

FIGURE 5 25

2. INTRODUCTION

Primary stability has been highlighted as the critical element required for successful long-term immediate implant placement, irrespective of the presence of septal bone, the residual space between the implant and the wall of the socket, and the use of grafting material. The presence of the “gap junction” between the walls of the socket and the implant has created disputes among researchers over the need of filling the space after immediate implant placement. Authors have suggested that placing a grafting material is necessary if the gap junction is greater than 2mm with a freeze-dried bone allograft and enamel matrix derivate and may allow “selective cell colonization and tissue repopulation” to aid in restoring the alveolar process without the use of a membrane. In contrast, other practitioners demonstrated successful outcomes by leaving the residual spaces to heal spontaneously without raising a surgical flap, reaching primary closure, or placing a grafting material. (Cucchi et al, 2017, Elaskary et al ,2022).

The literature states that immediate placement of implants into infected sites can be a suitable treatment option provided adequate clinical protocols were followed, these include antimicrobial prophylaxis and concurrent therapy, thorough debridement of the inner aspect of the alveolus and cleaning of the site, to avoid infection and possible implant failure (Perelman-Karmon et al, 2012., Serrano Méndez et al, 2017).

Healing of a tooth extraction socket follows a cascade of events that result in three-dimensional changes in the alveolar process. This process of physiological healing occurs in five different stages as described by Otha (1993). These include:

- The granulation stage (lasting up to five days): Early granulation tissue is seen covering the walls of the extraction socket. Initially starting at the bottom of the socket and spreading up the walls.
- Initial angiogenic stage (occurring within the first week with the granulation stage): The blood clot formed inside the socket starts to reduce in size from its center and new bone trabeculae appear at the base of the socket.
- New bone formation stage: (Commences 2 weeks post extraction): Sinusoid formations, which have formed in the earlier phases, yield bone trabeculae

and osteoid can be detected at this point. Bone which is formed follows the pattern of the sinusoid formations which is predominantly formed vertically originating from the apical region.

- Bone-growth stage (occurs 4-5 weeks after extraction): Characterized by well-developed, thickened trabeculae filling two-thirds of the socket. This bone is known as primary spongiosa. The coronal aspect of the socket shows sinusoid formations compared to the apical portion displaying mature bone with fewer sinusoids.
- Bone re-organisation stage (evident at 6 weeks following extraction): Maturation of the primary spongiosa changes, causing it to change into more mature lamellar bone. The percentages of the lamellar bone are higher towards the apex of the residual socket.

Primary blood clot is a prerequisite for the uneventful healing of the extraction socket.

This healing causes a nominal loss of vertical height with a potentially substantial loss of alveolar bone width in the buccolingual dimension. Schropp et al., (2003) reported alveolar ridge width reduction of up to 50% (corresponding to a buccolingual dimension change of 4.5 to 6.1 mm) for the duration of the 12-month period after the extraction. Two-thirds of this reduction occurs within the first three months. Shropp et al (2003) observed that the reduction of alveolar bone was greater at molar sites than at premolar sites. At 12 months post-extraction, 0.5 to 0.9 mm average vertical bone resorption can be expected in these sites. Previously reported data also confirm that remodelling following tooth extraction is more pronounced in the buccal than the lingual bone (Botticelli et al., 2004; Araujo & Lindhe, 2005). These authors reported that these differences between the buccal and lingual bone walls were related to the following:

a. The early disappearance of the bundle bone, that in the presence of a tooth, occupies a larger fraction of the marginal portion of the bone wall in the buccal than in the lingual aspect of the socket.
b. The additional surface resorption has a more pronounced effect on the delicate buccal than on the wider lingual bone wall of the socket.

Misch et al., (1999) also proposed that the constriction of the blood clot in the alveolus causes loss of crestal bone height and width of the buccal plate after tooth extraction. This may be further compounded by the remodelling of the labial cortical plates in response to a reduction in blood supply post-extraction.

The most significant amount of bone loss which will result in hard and soft tissue deformation, potentially compromising the ability to predictably restore the site with a dental implant occurs within the first three months after extraction (Tomlin et al, 2014).

In modern dentistry, a very predictable treatment for the unrestorable molar tooth is the placement of a dental implant followed by an implant-supported prosthesis. Immediate implant placement following a tooth extraction is well documented in the literature and is a predictable treatment modality and shortens the treatment time (Gelb 1993, Rosenquist et al.,1996).

The rationale for utilising dental implants rather than the more traditional fixed or fixed removable prostheses previously employed is to provide a more conservative form of treatment (Jiyrai and Chee 2006). Dental implants do not rely on adjacent teeth for anchorage, making them a suitable alternative to bridges especially if the adjacent teeth are virgin teeth.

Implants are manufactured from titanium and possess the ability to fuse with the bone, allowing for very stable support for a prosthesis. Their presence also preserves alveolar bone from physiologic resorption (American Academy of Implant Dentistry 2018). Implants can provide support for removable or fixed prostheses. Prosthetic implant crowns serve to restore the occlusion and function where teeth were lost and because of osseointegration, rehabilitate patients to a point where they report a 94.2% return to normal function (Annibali et al., 2010).

Implants replace teeth damaged due to trauma, dental caries, failed root canal therapy, or where root canal therapy cannot be completed. The presence of bone loss due to periodontal disease can be managed with implants provided there are no purulent exudates and adequate soft tissue health to provide for primary wound closure (Hassan et al., 2011).

Immediate implant placement results in decreased surgical trauma which lowers the risk of bone necrosis occurring and potentially reduces resorption of the alveolar process. This allows for faster healing of the socket by speeding up the rate at which woven bone is transformed into lamellar bone. This process is facilitated by the natural socket being rich in periodontal cells and bony matrix (Ebenezer et al., 2015). Additional advantages include fewer surgical interventions with a concomitant reduction in cost and postoperative morbidity resulting in a more positive psychological impact on the patient.

Paolantonio et al., (2001) also suggested that re-modelling could be prevented by implant placement in fresh extraction sites and concurrently maintain the original shape of the ridge. They stated that “Early implantation may preserve the alveolar anatomy and that the placement of a fixture in a fresh extraction socket may help to maintain the bony crest structure”. Most available studies have described the use of implants in fresh extraction sites in the anterior area for aesthetic reasons

Healing at the implant-bone interface:

The healing that occurs at implant surfaces adjacent to the bone is a specific form of healing. Implants are either placed level to the surrounding bone or sub-crestal to the surface of the bone. A cover screw is placed to overlay the soft tissues and heals without excessive granulation tissue formation. Healing of the bone occurs between the edge of the osteotomy site and the surface of the titanium implant (Cardarapoli et al, 2003, Politis et al, 2015).

At the inner sides of the threads on the implant, blood clots are formed. These are then infiltrated by macrophages and granulocytes. Fibroblastic progenitor cells migrate into the provisional matrix, allowing for the formation of granulation tissue and vascularisation by endothelial cells. The granulation tissue cells differentiate into osteoblasts, which lay down new bone. The new bone formation can be seen 4 days after implant placement, with the highest bone-implant integration occurring 3 months post-surgery. Remodeling around the dental implant can persist for at least 1 year, dependant on mechanical loading from the occlusal forces directed on the final restoration (Politis et al, 2016).

Immediate placement of Implants

When a tooth is scheduled for extraction and subsequent restoration, consideration needs to be given to when the implant will be placed. Hupp et al., (2006) states that the implant can be immediately placed (at the time of surgery) or delayed placement at either 2 months (early) or 6 months (late). The advantage of placing an implant immediately is that it allows for the shortest healing time and the implant is positioned at the time of extraction removing the need for a secondary procedure. Additionally, a provisional restoration could be placed which will allow for ideal tissue repositioning and maintenance to provide good aesthetic outcomes.

The chief disadvantage of immediately placed implants is related to the root shape left in the bone compared to the shape of the implant placed. This is highly evident in the case of multi-rooted teeth as well as in the anterior teeth with very oval-shaped roots. Another disadvantage is related to excessive early loading from occlusal forces on provisional restorations, which affects the immediate and long-term stability of the implant. In isolated cases, provisional restorations may be considered at the time of placement. Firm contact points with the adjacent teeth and the provisional restoration are essential as the teeth will act as a splint in conjunction with the restoration and prevent unwanted loading or torquing of the implant until such a time that it is fully osseointegrated (Hupp et al 2006).

A study done by Kim et al., (2017) showed that immediate implant placement in the molar and premolar regions had better clinical and radiographic outcomes than delayed implant placement. Zhou et al., (2018) stated that inorganic bone grafts with or without barrier membranes combined with immediately placed implants could decrease horizontal alveolar resorption by up to 15%. In a six-month, randomized, controlled clinical study performed by Iasella et al., (2003), it was established that ridge preservation with tetracycline hydrated freeze-dried bone allografts decreased the amount of post-extraction resorptive change. However, no immediate implants were placed.

Other studies have however failed to support the hypothesis that immediate implant placement significantly reduces bone resorption. Botticelli et al., (2004) reported that in extraction sites where implants were placed (following single tooth extraction),

both lingual and buccal walls underwent clear remodeling and resorption. The distance between the implant surface to the outer surface of the buccal and lingual bone walls was markedly diminished (buccal aspect: - 50%; lingual aspect: -25%) at the 4-month interval between implant insertion and re-entry surgery. Araujo et al., (2005) also reported in their study that the placement of implants in fresh extraction sites failed to prevent the remodeling that occurred in the walls of the extraction sockets in the premolar regions in dogs.

Ridge preservation using grafting material (autografts, allografts, xenografts, alloplasts, or synthetic material) placed in thoroughly debrided, fresh extraction sockets has been postulated to decrease early alveolar ridge width loss (Allegrini et al., 2008).

In 2009, Tarnow described bone fill of the residual space between the immediately placed implant and the socket wall of the fresh extraction, known as the “jump gap” (“gap between the implant and socket wall or any buccal dehiscence or fenestrations”), when flapless surgery was performed on maxillary anterior teeth. He postulated that by performing the exodontia flapless the blood supply to the buccal plate was preserved allowing for less buccolingual bone resorption to occur.

Bone grafting is reserved for cases where implants are to be placed where insufficient bone is available. “The insufficiency may be because of the previous extraction with resultant bone atrophy, traumatic extraction, trauma, sinus pneumatisation, congenital abnormalities/defects and from the removal of pathological lesions” (Hupp et al 2006). In these scenarios, to provide enough support, the remaining bone would need to be modified for implant placement. Multiple sources of graft material can be utilized, dependent on the amount and configuration of the bone required. The methods available include autogenous grafts, allografts, and xenografts (Hupp et al 2006).

“Allografts as described by Oryan et al., (2014) are used in a morselized form (bone fragments) and structural forms are provided as cortical, cancellous, or cortico-cancellous grafts.” They can also be processed as mineralized or demineralized, fresh, fresh-frozen, or freeze-dried forms”. These grafts can be presented in various shapes such as powder, cortical chips, and cancellous cubes. The bone can be

harvested from cadavers or from living donors and the cadaveric bone is commercially available. Grafts harvested from fresh cadavers with preservation of the cellular and organic contents are minimally processed. The advantages of using an allograft include that they are readily available, avoid the need to sacrifice host tissue, and do not contribute to donor site morbidity.

Allografts have variable osteoinductive and osteoconductive properties but have lower osteogenic potential compared to autografts as they lack viable cells.

Fresh bone allografts carry the risk of transmitting bacterial contaminants and viruses such as HIV and hepatitis B and C and may initiate an immunological reaction than can interfere with the healing of the bone graft and rejection by the host. The rate of healing of allografts is slower than that of autografts.

Due to the risk of creating an immunological reaction, fresh bone allografts are used infrequently. The use of frozen or freeze-dried bone allografts decreased the potential for an immunological reaction while preserving biological and biomechanical properties (Oryan et al., 2014).

This study aims to evaluate the benefit of placing a bone graft (allograft) into the residual space around an implant placed into a fresh molar extraction site extraction utilizing flapless surgery.

The investigators hypothesized that bone grafting placed in the jump gap would decrease the amount of resorption occurring at three months. The specific aim of the study was to compare alveolar ridge width bone loss between a control and grafting group.

3. STUDY OBJECTIVES

AIM:

To assess the necessity for bone grafting of the “jump–gap” in patients undergoing immediate implant placement in the molar region to preserve alveolar bone width.

OBJECTIVES:

To determine alveolar ridge width in cases grafted with an allograft

To determine alveolar ridge width in non-grafted cases.

To compare the measurements of alveolar ridge width at baseline (T_0) and after 3 months (T_3).

4. MATERIALS AND METHODS:

Study design and sample

This prospective, randomized control clinical trial study consisted of two groups (grafted vs non-grafted) with a minimum of 10 subjects, comprising males and females that met the inclusion criteria.

The subjects were sourced from private surgical practice at the Sunninghill Hospital. Patients were invited to partake in the study and given informed consent to qualify and thus selected in a non-probability sampling method by means of convenience sampling.

Inclusion and exclusion criteria were based on those described by Spinato et al., (2012) (Table 1).

Inclusion criteria required that participants be above 18 years of age, had good oral hygiene, and have sufficient bone volume for implant placement in the molar region.

Table 1: Exclusion criteria:

Mental illness	**No adjacent premolar or molar to extraction site**
Pregnancy	Tobacco Smoking (>10 per day)
Immunocompromised patients	Poor oral hygiene
Received Bisphosphonate or radiation therapy in the past to the head or neck	Active infection (abscess) Periodontitis
Uncontrolled Diabetes Mellitus (Type I/II)	Haemophilia

Grouping, Randomization, Allocation, Concealment, and Blinding

Patients were randomly assigned to either the control or grafting groups until a minimum of 10 patients were treated in each group.

The grafted group consisted of patients that underwent flapless atraumatic molar tooth extraction and immediate implant placement. An allograft consisting of a demineralized, mineralized bone matrix was placed into the jump gap around the implant.

The control group (non-grafted) comprised patients in whom flapless atraumatic molar tooth extraction with immediate implant placement without any grafting was done.

Study Variables

Sample demographics were defined as patient age in years, sex, and race. The alveolar ridge width was assessed by the primary investigator at 9 repeatable points on the gypsum models.

Data collection methods

Prior to surgery, alginate impressions were taken and poured immediately in gypsum to minimize potential shrinkage or warping of the impressions.

At the three-month post-operative re-evaluation (integration check), a second impression was taken and poured immediately in gypsum. These study models were then used to determine baseline (T_0) and three-month post-operative (T_3) models to compare ridge widths.

Surgical Protocol

Patients underwent atraumatic tooth removal without raising a mucoperiosteal flap. The tooth socket was thoroughly debrided, curetted, and irrigated using distilled water. Osteotomy preparation was performed for implant placement following the manufacturers drilling instructions. The implant position was verified using a direction indicator and the implant was inserted to minimum primary stability of 25 Ncm.

In the non-grafting protocol, a blood clot was allowed to form around the implant and the site was sutured using 5.0 plain resorbable sutures.

In the grafting protocol, bone chips (MDM Bone SA®) were carefully packed around the implant filling the socket, and the soft tissue was sutured using 5.0 plain resorbable sutures.

The implant position was confirmed radiographically.

All patients received analgesics and the grafting patients received a 5 day course of antibiotics. Antibiotics consisted of amoxicillin 875 mg and clavulanic acid 125 mg. If allergic the alternative antibiotic was clindamycin 150mg prescribed as per the manufacturer's instructions for 5 days.

Straumann Bone Level Tapered ® of 4.8mm diameter (Fig.1) were placed into the fresh extraction sockets. An allograft bone graft material (MDM 300mg) sourced from BoneSA® was packed firmly into the jump gap of the grafted cases. No grafting material was placed into the control group. The mucosal edges were drawn towards the implant and each other with resorbable 5 "0" plain catgut sutures in both groups.



Figure 1: Straumann Bone Level Tapered ® 4.8mm diameter implant – Courtesy of Dr W van der Linden

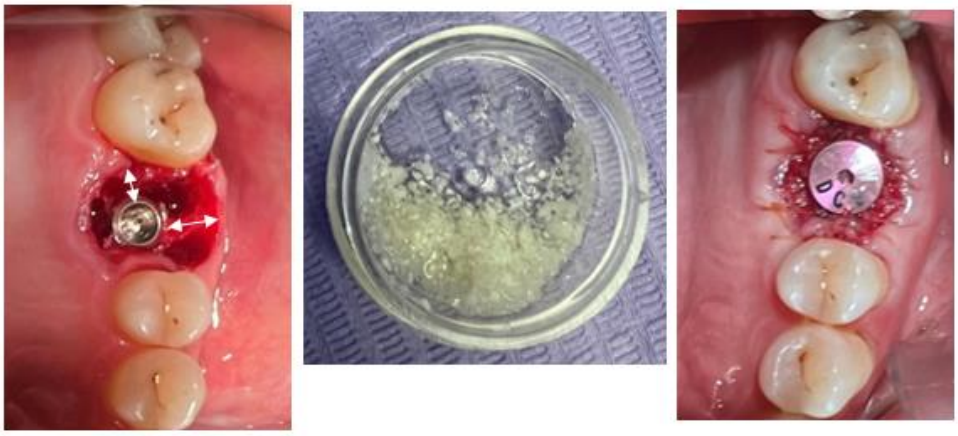

(A) (B) (C)

Figure 2. Images demonstrating immediate implant placement into the fresh molar extraction socket. Image (A) shows the implant placed centrally in the socket with the jump gap visible circumferentially as demonstrated by the white arrows. Image (B) shows the allograft used to graft the jump gap. Image (C) shows the final result with the bone graft, healing abutment, and sutures in place. Courtesy of Dr W van der Linden.

Impressions were taken in alginate and poured in gypsum at baseline and at three months when the patients returned to confirm integration of the implant prior to fabrication of the prosthetic crown. The gypsum models provided stable and accurate 3-dimensional records of the alveolar anatomy. The width of the alveolar ridge was measured on the gypsum models in three different sites at 9 points.

All surgeries were performed by the same surgeon. The impressions taken were poured with Gypsum immediately to minimize dimensional changes in the materials.

Variables and Measurements

Primary predictor – Treatment with allograft or without allograft

Outcomes – Alveolar ridge bone loss

Alveolar ridge width was measured at baseline (T_0) and three months (T_3) at 9 repeatable points on the plaster models ~ at 2 mm (A, B, C) and 4 mm and 6 mm below the gingival margin (Figure 2). Calipers were used to measure the ridge width and the measurements were repeated 3 times. An average of the three

measurements taken was recorded as the representative figure at T_0 and T_1 to minimize researcher error.

Horizontal ridge width was calculated as a mean value of the summation of the three mesial to distal horizontal measurements (A, B, and C) at 2, 4 and 6 mm in a buccolingual direction, each interval being accounted for separately from the coronal portion to the sulcus.

The vertical point width was calculated as the mean of the summation of the 3 vertical measurements at points A, B, and C respectively. Representing the width of the ridge at points A, B, and C in a buccolingual direction.

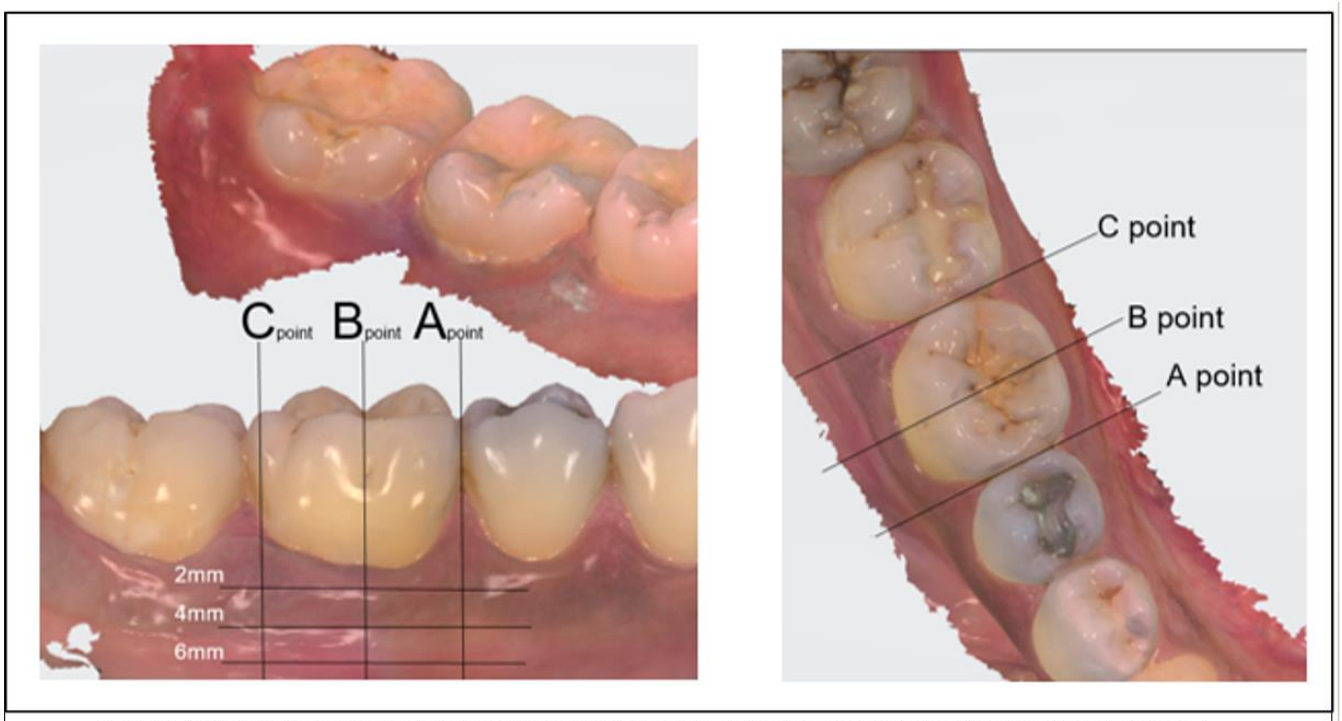

Figure 3: 9 Points on the model where measurements were taken: A, B, and C from a mesial to the distal direction and at 2 mm, 4 mm, and 6 mm from the coronal portion towards the sulcus.

Data analyses

The sample size was calculated assuming a 5% alpha error (p=0.05) and 80% study power.

Data for each individual case was captured by the principal investigator and the values entered in STATISTICA. t-Tests was used to compare the difference in ridge width at T_0 and T_3 between the control and grafting groups. These measurements were used to determine if significance difference in the ridge width at three months between the control and grafting groups exists.

Data analysis was analysed using STATISTICA. t-Tests will be done to find the *p* values. The level of significance was set at 0.05

5. RESULTS

The final study consisted of 22 participants (11 in the control and 11 in the intervention group). The sample consisted of 12 male and 10 female participants. The average age of the participants was 49.9 years (28 – 71) with 64% (14) of the cases presenting in the mandible and 36% (8) in the maxilla. Of the 22 participants, one case in the grafting group failed at three months (4.5%) (Tables 2a and b).

The average horizontal width of bone loss in the control group at 3 months was 1.38 mm (0.43 – 2.6 mm), 1.07 mm (0.45 – 2.12 mm), and 0.84 mm (0.42 – 1.70) at 2, 4 and 6 mm respectively (Fig.3) (Table 3).

In the grafting group at 3 months, bone loss was 1.07 mm (0.12 – 2.63 mm), 0.91 mm (0.3 – 2.48 mm), and 1.37 mm (0.28 – 2.38 mm) at 2, 4, and 6 mm respectively (Fig.3) (Table 4).

Table 3. Average Horizontal Bone Width loss

Average horizontal bone width loss				
	Non-Grafting		Grafting	Non-grafting - grafting
2mm	1,38		1,07	0,31
4mm	1,07		0,91	0,16
6mm	0,84		1,37	-0,53

The average vertical buccolingual bone loss at points A, B, and C at three months in the control group was 1.08 mm (0.33 – 2.88 mm), 1.27 mm (0.23 – 2.12 mm), and 0.97 mm (0.42 – 1.7 mm) respectively (Fig.4).

In the grafting group at three months vertical buccolingual bone loss was 0.74 mm (0.12 – 1.93 mm), 1.4 mm (0.43 – 3.37 mm), and 0.84 mm (0.25 – 2.37 mm) respectively (Fig.5) (Table 3).

t-test revealed that the difference between the grafting and control group were insignificant as the p value > 0.05 (Table 5 a, 5b).

Table 4: Mean vertical point loss

Mean Vertical point loss			
	A	B	C
Non - Grafting	1,08	1,27	0,97
Graft	0,74	1,4	0,84
Non- graft - graft	0,34	-0,13	0,13

Table 5 a: P values at 2, 4, and 6mm representing horizontal bone loss

Horizontal bone loss		P Value
	2mm	0,511
	4mm	0,780
	6mm	0,330

Table 5 b: P values at points A, B and C representing buccolingual bone loss

Vertical Bucco-lingual bone loss		P Value
	A point	0,301
	B point	0,727
	C Point	0,638

Table 2a: Data sheet: Non-Grafting group.

					Before			After		
Control Group					**2mm**	**4mm**	**6mm**	**2mm**	**4mm**	**6mm**
1	58	Male	Caucasian	Mandible	9,22	10,5	12,32	8,78	9,9	11,7
2	59	Male	Caucasian	Mandible	12,72	13,67	14,68	10,67	12,95	14,25
3	44	Female	Caucasian	Mandible	11,23	12,17	12,75	9,98	11,18	12,03
4	35	Male	Asian	Mandible	12,27	12,23	12,6	10,78	11,78	12
5	32	Female	Caucasian	Mandible	11,68	12,45	13,9	9,55	11,37	12,2
6	61	Female	African	Maxilla	11,42	12,82	14,23	10,9	12,12	13,82
7	71	Female	Caucasian	Maxilla	12,2	15,32	15,75	11,38	13,78	14,55
8	61	Male	Caucasian	Mandible	12,3	12,65	13,7	10,8	11,37	12,95
9	67	Female	Caucasian	Mandible	10,78	12,75	14,35	9,95	11,9	13,57
10	28	Male	Caucasian	Maxilla	12,9	13,75	14,58	10,95	12,37	14
11	59	Female	Caucasian	Mandible	11,37	13,18	14,17	9,13	11,03	12,67

Table 2b: Data Sheet: Grafting Group

					Before			After		
Bone Grafting group					**2mm**	**4mm**	**6mm**	**2mm**	**4mm**	**6mm**
1	59	Female	Caucasian	Maxilla	14,1	15,03	15,85	13,27	14,52	15,43
2	45	Male	Caucasian	Mandible	11,32	12,97	13,68	10,77	12,48	13,4
3	41	Male	Caucasian	Maxilla	12,02	12,93	14,13	10,08	12,13	13,8
4	45	Female	Caucasian	Mandible	11,37	11,83	12,05	10,55	10,78	11,33
5	47	Male	Caucasian	Mandible	12,25	14,35	16,22	11,43	13,65	15,35
6	50	Male	Caucasian	Maxilla	15,7	17,33	19,02	13,07	14,85	16,63
7	54	Female	Caucasian	Mandible	10,65	12,22	19,97	10,53	11,92	12,58
8	51	Male	Caucasian	Maxilla	14,63	16,23	17,22	13,47	15,35	16,33
9	33	Female	Caucasian	Mandible	11,87	12,47	13,12	9,85	10,75	11,65
10	46	Male	Caucasian	Mandible	11,37	12,4	13,17	10,52	11,37	12,83
11	51	Male	Caucasian	Mandible	NA	NA	NA	NA	NA	NA

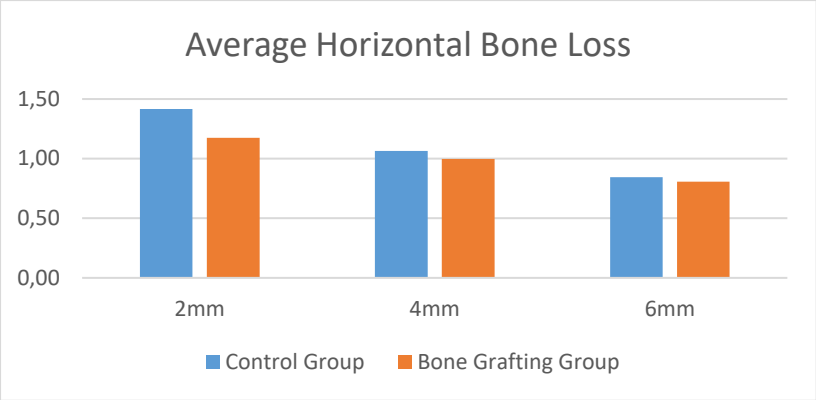

Figure 4. Average horizonal bone loss at points 2, 4, and 6 mm.

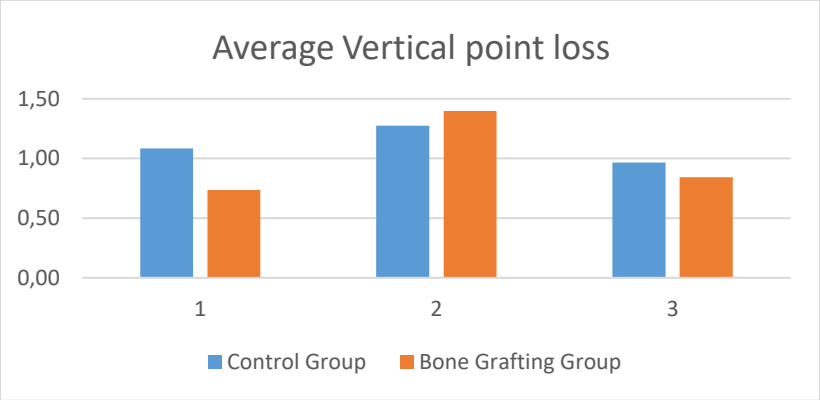

Figure 5. Average buccolingual vertical point loss at points A, B, and C annotated as 1, 2, and 3 respectively.

6. DISCUSSION

The goal of this study was to determine if the placement of a bone grafting material with immediately placed implants provided a significant difference in the amount of bone resorption three months post-operatively. It was hypothesized that the placement of a bone grafting material would show a decreased amount of bone width loss three months post-operatively as compared to that of the control/non-grafting group. The specific aims were to investigate the influence of jump gap grafting on alveolar bone loss.

The results of the study showed that bone width loss was less in the grafting group compared to the non-grafting group at three months post-operatively. Placement of a bone grafting material in the jump-gap does appear to affect the amount of bone width loss in the posterior region at three months post-operatively. This difference however was not statistically significant.

Alveolar socket healing follows a cascade of events in three-dimensional changes in the alveolar process. These dimensional changes are more pronounced during the first 3 months after extraction, and reduction of between 25% and 50% in width, and between 11% and 22% in height (Araujo et al, 2000; Horowitz et al, 2012; Iocca et al, 2017; Iasella et al, 2004). Immediate implant placement is advocated by most clinicians as it circumvents the need for a secondary surgical procedure and allows for shorter healing and treatment periods (Lang et al, 2012). It is also hypothesized that placing an implant into a fresh extraction site may counteract the physiological resorption of the hard tissues that occurs after tooth extraction. Studies have however failed to support the hypothesis that immediate implant placement significantly reduces bone resorption (Sanz et al, 2010, Chen et al, 2007, Botticelli et al, 2004). Animal studies that have evaluated the effect on healing dynamics of immediate implants in the alveolar bone ridge have concluded that reduction in the buccal bone wall was partially related to the bundle bone loss and the pre-surgical thickness of buccal bone tissue, without any consistent positive influence provided by implants placed immediately in extraction sockets (Araujo et al. 2005, 2006, Blanco et al. 2008, Vignoletti et al. 2009, 2012, Caneva et al. 2010). Bakkali et al (2021) also stated that implant placement into a fresh extraction socket alone does

not prevent the physiological remodeling of the alveolar bone contrary to initial suggestions. Clinical studies have also reported that at immediate implant sites, there is a high percentage of spontaneous fill of this marginal gap; >90% of gaps wider than 2mm were filled (Botticelli et al. 2004). Notwithstanding these observations, it was recently suggested that marginal gaps be filled with a bone graft to achieve improved clinical aesthetic outcomes (Chen and Buser 2014).

Numerous treatment modalities have been introduced in an effort to reduce dimensional changes following extractions, mostly the combination of immediate implant placement and a concomitant alveolar ridge preservation technique (Clementini et al, 2015). Chen et al (2007) suggested that inorganic bone grafts with or without barrier membranes combined with immediately placed implants could decrease horizontal alveolar resorption by 15% - 20%. There is however a paucity of studies that have reported on whether there are clinical benefits (i.e., reduction of horizontal and vertical bone loss) when the resultant jump gap is grafted following immediate implant placement, especially in the molar region. Some studies appear to suggest that only jump gaps of 2 mm should be considered for grafting (Zeren, 2006, Chu et al, 2012; Grunder ,2011). In a randomised clinical trial carried out by Chen et al. (2007) it was described that the treatment group receiving bovine bone mineral (DBBM) grafting in the gap, demonstrated a significant reduction in the extent of horizontal bone resorption compared with that of the control group, where the gap was left unfilled. Controversy however persists about the need and clinical benefits of jump gap grafting in immediately placed implants in fresh extracti0on sockets (Schropp & Isidor 2008).

The systematic review and meta-analysis by Clementini et al (2015) investigated dimensional changes in the alveolar ridges after immediate implant placement with or without simultaneous regenerative procedures. They determined that immediate implant placement does not counteract alveolar ridge modeling post-tooth extraction. In agreement with our findings, the efficacy of a concomitant regenerative technique in preventing alveolar reduction was inconclusive. Despite this, the overall body of evidence seems to indicate a trend towards a better outcome with the combined immediate implant placement and use of regenerative techniques.

Bakkali et al (2021) stated that the use of bone replacement grafts in gaps decreased the horizontal resorption of buccal bone but does not influence bone changes in the vertical dimension. The authors however were not able to determine bone grafts' effects on the resorption of the buccal bone plate based on the size of the gap. The prospective randomised-controlled study by Sanz et al (2012) demonstrated that placing a DBBM-C bone replacement graft significantly reduced horizontal bone resorptive changes occurring in the buccal bone after the immediate implantation in fresh extraction sockets. Both these studies, however, only evaluated implants placed in the maxillary aesthetic zone (including incisors, canines, and premolars).

Our findings of no significant difference between grafting and non-grating of the jump gap contradicts that reported by Elaskary et al (2022). Elaskary et al (2022) concluded that grafting the jump gap with a particulate bone graft (deproteinized bovine bone mineral, DBBM) with immediately placed implants in the aesthetic zone improved the labial bone thickness at 12 months post-implant placement. They observed a significantly thicker labial bone thickness in the grafted group than in the non-grafted group (2.95 (0.97) mm and 1.98 (0.56) mm, respectively). This study, however, focused on the anterior portion of the maxilla with a longer follow-up period and used non–resorbable bovine bone. Unlike in the present study, Elaskary et al (2022) used CBCTs to evaluate regenerated facial bone thickness in this study.

The experimental study by Novaes also concluded that jump gap filling by bovine bone showed better outcomes than non-filled jump gaps. However, only lower bi-cuspid teeth were included in this study.

To determine the significance and sustainability of volumetric maintenance of ridge width, measurements should be taken at 6, 12, and 24 months. Determining the degree of resorption occurring over longer periods of time will provide a more realistic appraisal of the suggested benefits of grafting intervention. A longer follow-up beyond the 3 months could have yielded different results from our study. A retrospective study conducted by Solakoğlu et al (2022) showed a significant reduction in resorption rates in sockets that had been treated with bone grafting and delayed implant placement after 3 years.

Consideration should be given to the use of Cone beam scanning to measure ridge widths before and after implant placement. This method will provide a more accurate representation of the data set when observing the hard tissues. The present study relied on the soft tissues to represent the underlying hard tissues, and patients with thick gingival biotypes may have affected the final outcomes of bone resorption measured at three months. Ethical considerations may preclude this advantage due to exposing patients to additional radiation.

Three variables are involved in this study – the healing of the extraction site, the integration of the implant in the site, and finally the incorporation of the bone graft into the extraction socket around the implant.

The healing of the extraction site follows that of normal wound healing (Otha,.1993), and the main concern after implant placement is the re-apposition of the soft tissues in such a manner as to minimize soft tissue down growth into the socket and to establish a good contour to the healing abutment.

The natural healing process is directly affected by the individual's own physiological, nutritional, and immunological states. Individuals heal at different rates and factors such as oral hygiene and proper post-operative care can affect the outcome of any surgical intervention. Other factors that may affect the outcome of wound healing include the reason for tooth removal, the immunological response of the host, the chronicity of the infection, the virulence of the bacteria, and the amount of bone destruction in the socket (Politis et al 2016).

The host's immune response can greatly affect the outcome of healing, as an insufficient response may result in delayed clearance of necrotic debris and bacteria as well as necessary inflammatory cytokines which activate and attract cells needed for the healing process.

Post-operative infection will delay any tissue healing or integration as the host's primary defense will be directed toward eliminating the active infection. Highly virulent bacteria which can evade host immune defenses will delay and ultimately cause the failure of the procedure if left unchecked.

Large peri-apical areas where there is destruction of bone will result in implants not being eligible for placement. Unless the inter-radicular bone is intact, primary stability will not be achieved, especially in multi-rooted sockets where the size and shape of the socket are not compatible with the round shape of the implant body. In this instance, once the socket has been thoroughly debrided and implant stability could be created, a bone grafting material can be placed into the residual space surrounding the implant, to serve as a space maintainer and act as a scaffold for new bone formation (Cucchi et al, 2017).

After the evaluation of the models between the two groups for the study, there was no obvious difference between the control and grafting groups with respect to the final soft tissue positioning. There was no specific evidence of gross soft tissue change or deformation between the groups after healing of the soft tissue had occurred. If insufficient bone is available, ridge preservation which has been shown to be a viable long-term method of maintaining bone levels can be utilized to allow for delayed implant placement (Solakoğlu et al, 2022).

Integration of the implant in the site is determined by primary stability, immobility during healing with minimal exposure to occlusal forces, and incorporation of bone onto the titanium surface of the implant. This is promoted by not placing a provisional restoration and by selecting the correct size healing abutment. The healing abutment also allows for soft tissue remodeling around the crest of the implant to access the implant later when doing the final restoration, as well as eliminating the need for a second surgical procedure. Integration of the implant occurs in the presence of the bone grafting material, provided that primary stability is achieved, and no unnecessary movement or post-operative infection occurs during the healing phase (Politis et al, 2016). All patients in the present study received healing abutments.

The incorporation of bone grafting material is aptly described by Oryan et at., (2014), and requires five stages of processing: inflammation, revascularization, osteoconduction, osteoinduction, and lastly remodeling. The time period of each stage is variable according to the graft placed. Delayed or interrupted vascularization, infection, as well as micromovements at the site, will delay the incorporation of the graft

The slower rate of resorption in the grafting group is possibly due to the presence of foreign material in the socket which requires an additional immune response to remove or incorporate the material in the healing process. This would slow down the rate at which the body is able to heal and remodel a tooth socket thereby prolonging but not reducing the resorptive process in the longer term.

Bone resorption cannot be prevented as it is a natural physiological process that occurs. Thus, remodeling or resorption of the graft will occur over time and will have a final impact on the actual impact of the protocol. Therefore, increase monitoring time is required for more validated results.

The validity of this study is limited by the small sample size, the relatively short follow-up time, and the measurement technique of the healing ridge.

This study had a statistical power of 80%. The power could be strengthened by increasing the number of participants in the study owing to the reason why the p-value is greater than 0.05. This would warrant for additional studies with larger sample sizes in both the grafting and control groups.

There are several limitations associated with our study. Our sample size may not have been large enough to detect the differences in resorption rates necessary to reach statistical significance. The outcomes of this study should thus be interpreted with caution due to the small sample size.

Other confounding factors such as smoking, the size of the defect, and reasons for the extraction were not investigated. Notwithstanding its limitations, this study has added valuable information to the ongoing debate on whether to graft or not graft jump gaps in the molar regions.

7. Conclusion:

The addition of bone grafting material into the residual space between an implant immediately placed into a fresh molar extraction site and the socket walls resulted in less bone resorption at the alveolar crest at the 3-month measurement period compared to the control group. However, the difference in measurements was statistically insignificant ($p>0.05$).

A larger sample size monitored over a longer period of time, and with a more sophisticated measuring device would strengthen the conclusions drawn from this study.

From the findings of the present study, revealing no difference between grafted and non-grafted cases, we conclude that grafting of the jump gap in the molar region offers no additional benefit. Future prospective randomised-controlled studies, involving a larger number of patients, as well as longer follow-up period that will include data on the size of the defect, and CBCT measurements at baseline and each follow-up period are recommended to further strengthen the findings of this study

8. REFERENCES:

1. Allegrini, S Jr. Koening, B Jr. Allegrini, MR et al., (2008). Alveolar Ridge Socket Preservation with Bone Grafting—Review, *Annales Academiae Medicae Stetinensis,* 2008; 54(1): 70-81.

2. Annibali, S. Vestri AR. et al., (2010). Patient Satisfaction with Oral Rehabilitation: Evaluation of Responses to a Questionnaire. *Annaldi Di Stomatologia (Roma)*. 2010; 1(3-4): 2-8.

3. Araújo, MG. Lindhe J., (2005). Dimensional Ridge Alterations Following Tooth Extraction. An Experimental Study in the Dog. *Journal of Clinical Periodontology, 2005;* 32(2): 212–18.

4. Bakkali S, Rizo-Gorrita M, et al. (2021). Efficacy of Different Surgical Techniques for Peri-Implant Tissue Preservation in Immediate Implant Placement: A Systematic Review and Meta-Analysis. *Clinical Oral Investigations,* 2021; 25: 1655-1675.

5. Blanco, J. Nunez, V et al., (2008). Ridge alterations following immediate implant placement in the dog: flap versus flapless surgery. *Journal of Clinical Periodontology*, 2008; 35(7): 640-648.

6. Botticelli, D. Berglundh, T. Lindhe, J., (2004). Hard-tissue Alterations Following Immediate Implant Placement in Extraction Sites. *Journal of Clinical Periodontology,* 2004; 31(10): 820–28.

7. Caneva M, Boticelli D, et al., (2010). Flap Vs “Flapless” Surgical Approach at Immediate Implants: A Histomorphometric Study In Dogs. *Clinical Oral Implants Research,* 2010; 21(12): 1314-1319.

8. Caneva M, Salata LA. et al ., (2010). Hard Tissue Formation Adjacent to Implants of Various Size and Configuration Immediately Placed into Extraction Sockets: An Experimental Study in Dogs. *Clinical Oral Implants Research*, 2010; 21(9): 885-890.

9. Cardarapoli G, Araujo M, Lindhe J, (2003). Dynamics of Bone Tissue Formation in Tooth Extraction Sites. An Experimental Study in Dogs. *Journal of Clinical Periodontology* 2003; 30: 809– 818.

10. Chen, ST,. Darby, IB , et al, (2007). A Prospective Clinical Study of Non-Submerged Immediate Implants: Clinical Outcomes and Esthetic Results. *Clinical Oral Implants Research*, 2007; 18(5): 552-562.

11. Chen, ST, Buser D., (2014). Esthetic outcomes following immediate and early implant placement in the anterior maxilla – a systematic review: Int Journal of Oral and Maxillofacial Implants, 2014; 29: 186-215.

12. Chu S, Salama M, et al,. (2012).The Dual-Zone Therapeutic Concept of Managing Immediate Implant Placement and Provisional restoration in Anterior Extraction Sockets. *Compendium of Continuing Education in Dentistry,* 2012; 33(7).

13. Clementini, De Risi, V,. (2015). Alveolar ridge preservation techniques: a systematic review and meta-analysis of historical and histomorphometrical data. *Clinical Oral Implants Research*, 2015; 26: 50-68.

14. Cucchi, A., Vignudelli, et al., (2017). Tapered, Double-Lead Threads Single Implants Placed in Fresh Extraction Sockets and Healed Sites of the Posterior Jaws: A Multicentre Randomized Controlled Trial with 1 to 3 Years of Follow-Up. *BioMed research international*, *2017*; 8017175. https://0-doi-org.innopac.wits.ac.za/10.1155/2017/8017175

15. Ebenezer, V. Balakrishnan, K. et al. (2015). Immediate Placement of Endosseous Implants into the Extraction Sockets. *Journal of Pharmacy and BioAllied Sciences,* 2015; 7: 234-237.

16. Elaskary, A. Abdelraham, H. et al ., (2022). Does Grafting the Jumping Gap in Immediately Placed Anterior Implants Using Vestibular Socket Therapy Influence the Labial Bone Thickness? *American Association of Oral and Maxillofacial Surgeons*. 2022;80(8):1398-1407.

17. Gelb, D. (1993). Immediate implant surgery: Three-year retrospective evaluation of 50 consecutive cases. *International Journal of Oral and Maxillofacial Implants*, 1993; 8(4): 388-99.

18. Grunder U. (2011). Crestal Ridge Width Changes When Placing Implants at the Time of Tooth Extraction With and Without Soft Tissue Augmentation After a

Healing Period of 6 Months: Report of 24 Consecutive Cases. *International journal of Periodontics and Restorative Dentistry*, 2011; 31(1): 9 – 17.

19. Hassan, K. Alagl, A., (2011). Implant Dentistry – The most Promising Discipline of Dentistry. 1st ed. London: *IntechOpen*, 2011; 173-177.

20. Hupp, J., Ellis, E. and Tucker, M., (2006). Contemporary Oral and Maxillofacial Surgery. *6th ed. Elsevier*, 2006; 43-50.

21. Hupp, J., Ellis, E. and Tucker, M., (2006). Contemporary Oral and Maxillofacial Surgery. *6th ed. Elsevier*, 2006; 234-238.

22. Iasella, JM. Greenwell, H. Miller, RL., et al. (2003). Ridge preservation with freeze-dried bone allograft and a collagen membrane compared to extraction alone for implant site development: a clinical and histologic study in humans. *Journal of Periodontology*, 2003; 74(7), pp.990–9.

23. Jivrai, S. Chee, W. (2006). Rationale for Dental Implants. *British Dental Journal*, 2006; (200): 61-665.

24. Jun, SH. Park, C. Hwang, S. et al., (2018). The Influence of Bone Graft Procedures on Primary Stability and Bone Change of Implants Placed in Fresh Extraction Sockets. *Maxillofacial plastic and Oral surgery, 2018* ;40(1):8. Published 2018 Apr 25. doi:10.1186/s40902-018-0148-2.

25. Kim, JK. Yoon, AJ. (2017). Clinical and Radiographic Outcomes of Immediate and Delayed Placement of Dental Implants in Molar and Premolar Regions. *Clinical Implant Dentistry Related Research*, 2017; 19(4): 703-709.

26. Lazzara, R. (1989). Immediate Implant Placement into Extraction Sites: Surgical and Restorative Advantages. *International Journal of Periodontics and Restorative Dentistry*, 1989; 9(5): 332-43.

27. Lee, W. Choi, J. et al., (2019). *Novel Use of Silicon Sheets for Immediate Implant Placement in Fresh Molar Extraction Sockets. Case Rep Dent*, 2019;2019:3501671. Published 2019 Feb 28. doi:10.1155/2019/3501671 [Accessed 12 July 2022]

28. Maiorana, C. Pier, PP. Matteo, D. et al., (2017). Alveolar Socket Preservation with Demineralised Bovine Bone Mineral and a Collagen Matrix. *Journal of Periodontal & Implant Science,* 2017; 47(4): 194.

29. Misch, CE. Dietsh-Misch, F. Misch, CM., (1999). A Modified Socket Seal Surgery with Composite Graft Approach. *Journal of Oral Implantology,* 1999; 25(4): 244–50.

30. Novaes, B. Papalexiou, V. Luczyszyn, SM., (2002). Immediate Implant in Extraction Socket with Acelular Dermal Matrix Graft and Bioactive Glass: A Case Report. *Implant Dentistry,* 2002; 11(4): 343-348.

31. Oryan, A., Alidadi, S., Moshiri, A. and Mafulli, N. (2014). Bone Regenerative Medicine: Classic Options, Novels Strategies, and Future Directions. *Journal of Orthopaedic Surgery and Research*, 2014; 9(1): 18.

32. Otha, Y., (1993). Comparative changes in microvasculature and bone during healing of implant and extraction sites. *Journal of Oral Implantology*, 1993; 19(3): 309-18.

33. Paolantonio, M. Dolci, M. Scarano, A. et al., (2001). Immediate Implant placement in fresh extraction sockets. A Controlled Clinical and Histological study in Man. *Journal of Periodontology, American Academy of Periodontology,* 2001; 72(11):1560-71

34. Perelman-Karmon M, Kozlovsky A, Liloy R, Artzi Z. (2012). Socket site preservation using bovine bone mineral with and without a bioresorbable collagen membrane. *Int J Periodontics Restorative Dent*, 2012; 32(4): 459–65.

35. Politis, C. Schoenaers, J. Jacobs, R. Agbaje, JO. (2016). Wound Healing Problems in the Mouth. *Front Physiol*. 7:507. Published 2016 Nov 2. doi:10.3389/fphys.2016.00507/fphys.2016.00507

36. Rosenquist, B. Grenthe. B., (1996). Immediate placement of implants into extraction sockets: implant survival. *International Journal of Oral and Maxillofacial Implants*, 1996; 11(2): 205-209.

37. Santos, PL. Guilinelli, JL. Tella, CS, et al., (2013). Bone Substitutes for Peri-Implant Defects Of Post-extraction Implants. *International Journal of Biomater*. 2013; 2013: 307136. doi: 10.1155/2013/307136.

38. Sanz M, Ferrus J, et al. (2010). Factors influencing ridge alterations following immediate implant placement into extraction sockets. *Clinical Oral Implants Research,* 2010; 21(1); 22 – 29.

39. Sanz M, Lindhe J, et al. (2012). The effect of placing a bone replacement graft in the gap at immediately placed implants: a randomized clinical trial. *Clinical Oral Implants Research,* 2012; 28(8): 902 – 910.

40. Schropp, L Wenzel, A. Kostopoulous, T., (2003). Bone Healing and Soft Tissue Contour changes following Single-Tooth Extraction: A Clinical and Radiographic 12-month prospective Study. I*nternational Journal of Periodontics Restorative Dentistry*, 2003; 23(3):313-323

41. Schropp L, Isidor F,. (2008). Clinical Outcome and Patient Satisfaction Following Full Flap Elevation for Early and Delayed Placement of Single – Tooth Implants: A 5-year Randomized Study. *International Journal of Oral and Maxillofacial Implants,* 2008; 23(4): 733-743.

42. Sepinato, S. Agninni, A. Chiesi, M. et al., (2012). Comparison Between Graft and No-Graft in an Immediate Placed and Immediate Nonfunctional Loaded Implant. *Implant Dentistry*, 2012; 21(2): 97-103.

43. Solakoğlu, O. Ofluoğlu, D. Schwarzenbach, H. et al., 2022. A 3-Year Prospective Randomized Clinical Trial of Alveolar Bone Crest Response and Clinical Parameters Through 1, 2, And 3 Years of Clinical Function of Implants Placed 4 Months After Alveolar Ridge Preservation Using Two Different Allogeneic Bone-Grafting Materials. *International Journal of Implant Dentistry*, 2022; 8(5):1-16

44. Serrano Méndez CA, Lang NP, Caneva M, Ramírez Lemus G, Mora Solano G, Botticelli D. Comparison of Allografts and Xenografts Used For Alveolar Ridge Preservation. A Clinical and Histomorphometric RCT in Humans. *Clin Implant Dent Relat Res*, 2017; 19(4): 608-615.

45. Tarnow, D., Chu, S., Salama, M., et al., (2014). Flapless Post extraction Socket Implant Placement in the Esthetic Zone: Part 1. The Effect of Bone Grafting and/or Provisional Restoration on Facial-Palatal Ridge Dimensional Change—A Retrospective Cohort Study. *International Journal of Periodontics & Restorative Dentistry*, 2014; 34(3):323-331.

46. Tomlin, EM. Shelby, JN. Rossmann, JN., (2014). Ridge Preservation for Implant Therapy: A Review of the Literature. *The Open Dentistry Journal,* 2014; 8: 66–76.

47. Vignoletti F. De Sancti, M. et al., (2009). Early Healing of Implants Placed into Fresh Extraction Sockets: An Experimental Study in the Beagle Dog. II: Ridge Alterations. *Journal of Clinical Periodontology*, 2009; 35(8): 688-697.

48. Zeren, KJ,. (2006). Minimally Invasive Extraction and Immediate Implant Placement: The Preservation of Esthetics. *International Joural of periodontics and restorative dentistry*, 2006; 26(2): 171-181.

49. Zhou, J. Li, X. et al., 2018. Bone Regeneration around Immediate Placed Implant of Molar Teeth with Autologous Platelet-Rich Fibrin. *Pubmed*, 2018; 97(44): PMID: 30383681.

10. APPENDIX

11. Ethics clearance

UNIVERSITY OF THE WITWATERSRAND, JOHANNESBURG

R14/49 Dr Wynand Johan van der Linden

HUMAN RESEARCH ETHICS COMMITTEE (MEDICAL)

CLEARANCE CERTIFICATE NO. M190826

NAME: (Principal Investigator)	Dr Wynand Johan van der Linden
DEPARTMENT:	Oral Health Sunninghil Hospital (Private Practise)
PROJECT TITLE:	A comparison of ridge width following immediately placed implants in the molar area with and bone grafting
DATE CONSIDERED:	30/08/2019
DECISION:	Approved unconditionally
CONDITIONS:	
SUPERVISOR:	Prof E Rikhotso
APPROVED BY:	Dr CB Penny, Chairperson, HREC (Medical)
DATE OF APPROVAL:	23/09/2020

This clearance certificate is valid for 5 years from date of approval. Extension may be applied for.

DECLARATION OF INVESTIGATORS

To be completed in duplicate and **ONE COPY** returned to the Research Office Secretary on the Third Floor, Faculty of Health Sciences, Phillip Tobias Building, 29 Princess of Wales Terrace, Parktown, 2193, University of the Witwatersrand. I/we fully understand the conditions under which I am/we are authorized to carry out the above-mentioned research and I/we undertake to ensure compliance with these conditions.Should any departure be contemplated, from the research protocol as approved, I/we undertake to resubmit the application to the Committee. I agree to submit a yearly progress report. The date for annual re-certification will be one year after the date of convened meeting where the study was initially reviewed. In this case, the study was initially reviewed in August and will therefore be due in the month of August each year. Unreported changes to the application may invalidate the clearance given by the HREC (Medical).

Principal Investigator Signature

15/12/2022
Date

PLEASE QUOTE THE PROTOCOL NUMBER IN ALL ENQUIRIES

Research consent form:

A Comparison of ridge width between bone grafting and non-grafting with Immediate implant placement.

Dr. WJ van der Linden

I …….. hereby agree to participate in this research project conducted by Dr WJ van der Linden through the University of the Witwatersrand. The research has been explained to me and I understand what my participation will involve.

I agree that my participation will remain anonymous YES NO (please circle)

I agree that the researcher may use anonymous. information such as age, gender and race in his research report for statistical purposes YES NO

I agree that the researcher may take photos of me YES NO

(but not of my face)

I agree that the information I provide may be used YES NO

anonymously by other researchers following this study

I agree that if I do participate I am allowed to leave YES NO

the study provided sufficient notice is given

…… (Signature)

…… (Name of participant)

…… (Date)

Information Sheet

I, Dr WJ van der Linden, am a Post Graduate student currently reading towards my MSc (Dent) degree at the University of the Witwatersrand.

My research involves comparing the width of the jaw where molar teeth are removed and replaced with a dental implant, this will be done before tooth removal and after implant placement.

If you agree to participate in the study I am conducting please be aware that all information is kept confidential. No photographs revealing your face will be used and all medical information will be kept private.

The data that will be recorded includes your age, sex, race and the measurements that I will obtain will be taken from Plaster of Paris models.

The only requirement for you to join the study is to agree to have 2 impressions taken in order to replicate the anatomy of your jaws. These will be done at the initial appointment and again at your follow up appointment 3 months later.

Thank you for agreeing to participate in the study.

Yours sincerely

Dr WJ van der Linden

BDS(Wits)

<u>Consent form from Private Practice</u> – Courtesy of Dr. W van der Linden

PATIENT INFORMED CONSENT FORM

1. I, the undersigned _____

   (Full names), hereby give my consent for the performance of the following:

   _____

   _____

   operation/procedure/treatment/process, upon myself/my spouse/ my dependant

   _____ ***(insert name)***

2. My physician has provided me with a general explanation of the nature of this operation/procedure/treatment/process and the reasons for its indication for my particular medical condition.

3. My physician has also discussed with me the risks and benefits of the operation/procedure/treatment/process. Some of these risks include, but are not limited to, the following
   [describe risks and benefits]

   <u>As per leaflets</u>

4. My physician has also explained that I can generally expect the following consequences and complications as a natural result of the undergoing intervention (some of which are attendant to an invasive procedure). Although some of these may not occur, including but not limited to, the following:
   [describe consequences and/or complications]

   <u>As per leaflets</u>

5. My physician has explained alternatives to undergoing this operation/treatment/procedure/process including alternative operative measures that may be deemed necessary or desirable during the course of this operation/procedure/treatment/process, also inclusive of:
   [describe alternatives]

   _____

6. I furthermore grant consent to the administration of a general or other anaesthetic for the purposes of the said operation/procedure/ treatment/process or alternative operative procedures. I moreover hereby grant consent to any radiological or diagnostic examination/laboratory tests/hospital services that are medically indicated or that the doctors may prescribe.

Blood transfusion
I hereby consent/do not consent to a blood/blood product transfusion to myself/the patient upon the instruction of the said medical practitioner (delete non-applicable).

7. My physician has also explained to me that other physicians and health care providers will participate in my care. I therefore extend this authorisation to these other physicians and health care providers. Although unlikely, in the event that my physician is not available to perform the above operation/procedure/treatment/process, I understand that this authorisation is extended to them. If possible, however, I will be notified of the substitution.
[this clause is optional]

8. I acknowledge that I have been informed of my/ the patient's health status, the range of diagnostic procedures and treatments generally available to myself / the patient, the benefits, risks, costs and consequences generally associated with each option, my / the patient's right to refuse health services and the implications, risks and obligations of such refusal.
[this clause is included in compliance with section 6 of Act 61 of 2003]

9. After discussing all of the above, my physician gave me an opportunity to ask questions and seek further information regarding to above items. I believe that I do not require further information at this time, and I am prepared to proceed with the recommended operation/treatment/ procedure/process. I believe that my physician has honoured my/ the patient's right to make my/the patient's own informed health care decision, give my consent voluntarily and freely, and certify that I can give valid consent. I understand that I can revoke this consent at any time up until the time the operation/treatment/procedure/process is started.

10. I acknowledge that I/the patient has been informed of all the above in a language understood by me/the patient

SIGNED AT _____ THIS ____ DAY OF _____20 ____

SIGNATURE OF PATIENT .....
Signature of patient/parent/spouse/guardian
Curator/mandated person/ grandparent/adult child/
Brother/sister (Specify capacity of signatory)
(See section 7 of Act 61 of 2003)

WITNESS 1 ..... **WITNESS 2** .....