

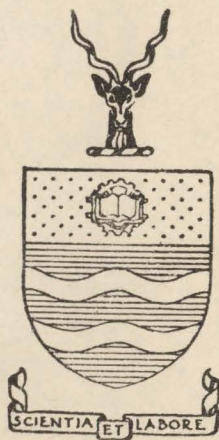
THE THALAMUS OF ELEPHANTULUS

by
A. C. ALLISON

PLATES

The
QL
937
ALL

The University
of
The Witwatersrand
Medical Library.



The
Class No. *Q1937* Accession No. *19664*
AH
H.W.V. 85972:10746.

THE THALAMUS OF ELEPHANTULUS.

PART II - PLATES.

The
QL
937
ALL



19664.

ABBREVIATIONS USED IN ALL FIGURES.

A.CO. - Anterior commissure.
A.COL. - Anterior colliculus.
A.HYP.A. - Anterior hypothalamic area.
AMYG. - Amygdala.
ANSA.L. - Ansa lenticularis.
B.OLF. - Olfactory bulb.
BR.CONJ.- Brachium conjunctivum.
C.CALL. - corpus callosum.
CER.AQ. - Cerebral aqueduct.
CO.I.AD. - Interanterodorsal commissure.
CO.HAB. - Habenular commissure.
CO. HIPP. - Hippocampal commissure.
DEC.G. - Decussation of Ganser.
DEC.M. - Decussation of Meynertz.
DEC.S.MAM. - Supramammillary decussation.
D.L.B. - Dorsal longitudinal bundle.
E.M.L. - External medullary lamina.
FIM. - Fimbria hippocampi.
F.LENT. - Fasciculus lenticularis.
FOR, MON. - Foramen of Monro.
FORN. - Fornix.
HAB. - Habenula.
HIP. - Hippocampus.
HYP. - Hypothalamus.
HYP.R.- Hypophysial recess of third ventricle.
HYP.ST. - Hypophysial stalk.
I.CAPS. - Internal capsule.
I.M.L. - Internal medullary lamina.
LEMN.M. - Medial lemniscus.
L. GEN. - Lateral geniculate body.
L. HYP.A. - Lateral hypothalamic area.
L. PR.R. - Lateral preoptic region.
MAM.B. - Mammillary body.
M.FOR.B. - Medial forebrain bundle.
M. GEN. - Medial geniculate body.
M. INT. - Massa intermedia.
M.L.B. - Medial longitudinal bundle.
M.PR.R. - Medial preoptic region.
N.A.D., - Anterodorsal nucleus.
N.A.M. - Anteromedial nucleus.
N.A.V. - Anteroventral nucleus.
N. CENT. - Central nucleus.
N. CENT. L. - Central lateral nucleus.
N.C.M. - Centrum medianum.
N.D.M. - Dorsomedial nucleus.
N. GEN.L.D. - Dorsal nucleus of the lateral geniculate body.

N.GEN.L.V. - Ventral nucleus of the lateral geniculate body.
 N.GEN.M. - Medial geniculate nucleus.
 N.HAB.L. - Lateral habenular nucleus.
 N.HAB.M. - Medial habenular nucleus.
 N.I.A.D. - Interanterodorsal nucleus.
 N.I.A.M. - Interanteromedial nucleus.
 N.I.M.D. - Intermediodorsal nucleus.
 N.I.PAF. - Interparafascicular nucleus.
 N.I.V. - Interventral nucleus.
 N.L. - Lateral nucleus.
 N.L.P. - Lateral posterior nucleus.
 N.L.O.T. - Large celled nucleus of the optic tract.
 N.M.D. - Medial dorsal nucleus.
 N.MAM.M. - Medial mammillary nucleus.
 N.MAM.L. - Lateral mammillary nucleus.
 N.ME.PR. - Median preoptic nucleus.
 N.M.V. - Medial ventral nucleus.
 N.O.P. - Optic nerve.
 N.PAC. - Paracentral nucleus.
 N.PAF. - Parafascicular nucleus.
 N.PAT. - Parataenial nucleus.
 N.PAV. - Paraventricular nucleus.
 N.PAV.A. - Anterior Paraventricular nucleus.
 N.PAV.P. - Posterior paraventricular nucleus.
 N.P.CO. - Nucleus of the posterior commissure.
 N.PRET. - Pretectal nucleus.
 N.RET. - Reticular nucleus.
 N.REUN. - Nucleus reuniens.
 N.RH. - Rhomboid nucleus.
 N.SCH. - Suprachiasmatic nucleus.
 N.S.GEN. - Suprageniculate nucleus.
 N.SOP. - Supraoptic nucleus.
 N.S.PAF. - Subparafascicular nucleus.
 N.STR.TERM. - Nucleus of the stria terminalis.
 N.SVB. - Subthalamic nucleus.
 N.SUBM. - Submedial nucleus.
 N.V. - Ventral nucleus. *N.TR.OP. - Nucleus of the optic tract.*
 O.CH. - Optic chiasma.
 PED.CER. - Cerebral peduncle.
 PED.MAM. - Mammillary peduncle.
 PEV.S. - Periventricular system.
 PIN. - Pineal body.
 P.CO. - Posterior commissure.
 P.COL. - Posterior colliculus.
 PR.R. - Preoptic region.

S.G.C.- Substantia grisea centralis.
STR.MED. - Stria medullaris.
STR. TERM. - Stria terminalis.
SUBC.O. - Subcommissural organ.
T.CIN. - Tuber cinereum.
TH. RAD. - Thalamic radiations.
T.OLF. - Olfactory tubercle.
TR.AM.HAB., - Amygdalo-habenular tract.
TR.C.HAB.L. - Lateral cortico-habenular tract.
TR.C.HAB.M. - Medial cortico-habenular tract.
TR.H.P. - Habenulo-peduncular tract.
TR.HYP. - Hypophysial tract.
TR.M.TEG. - Mammillo-tegmental tract.
TR.M.TH. - Mammillo-thalamic tract.
TR.OLF.L. - Lateral olfactory tract.
TR.OP. - Optic tract.
TR.OP.ACC.P. - Posterior accessory optic tract.
TR.PR.HAB.L. - Lateral preoptico-habenular tract.
TR.PR.HAB.M. - Medial preoptico-habenular tract.
V.III - Third ventricle.
Z.INC. - Zona incerta.

EXPLANATION OF PLATES.

- Plate 1 : Fig. 1.- median saggital section of the brain of *Elephantulus*, X3.
Fig. 2.- ventral aspect of the diencephalon, X10.
Fig. 3.- dorsal aspect of the diencephalon, X10.
- Plates 2 and 3 : Figs. 4 - 15 - Transverse sections through the diencephalon, showing the arrangement of the cell masses, X25.
- Plate 4 : Figs. 16 - 23 - Horizontal sections through the diencephalon, showing the arrangement of cell masses, X20.
- Plates 5 and 6 : Figs. 24 - 34 - Transverse sections through the diencephalon, showing the arrangement of the main fibre connections, X25.

PLATE I

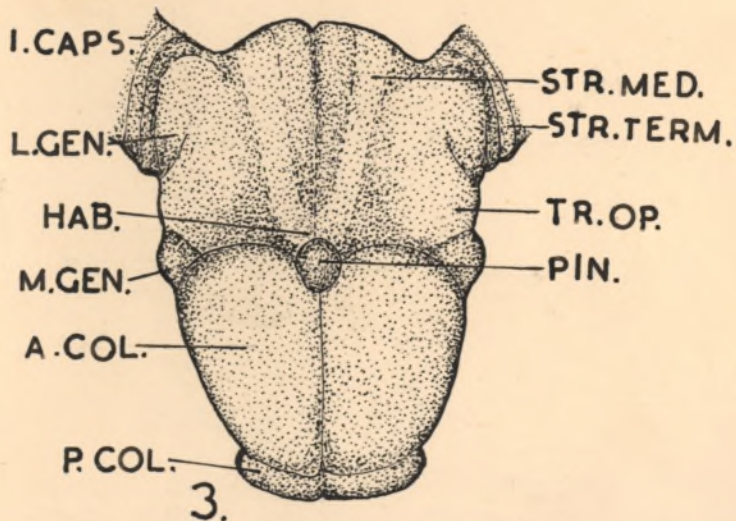
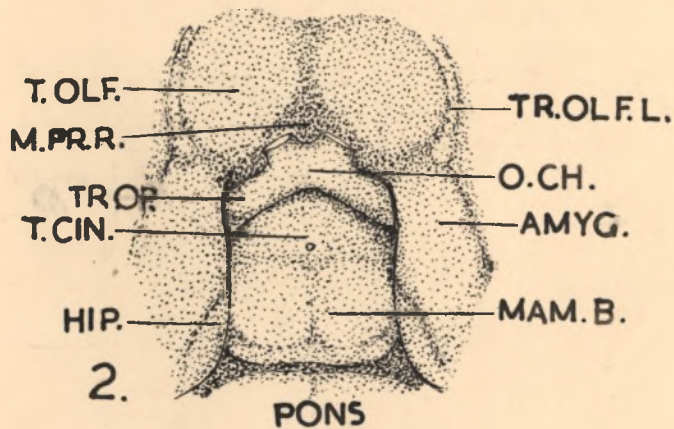
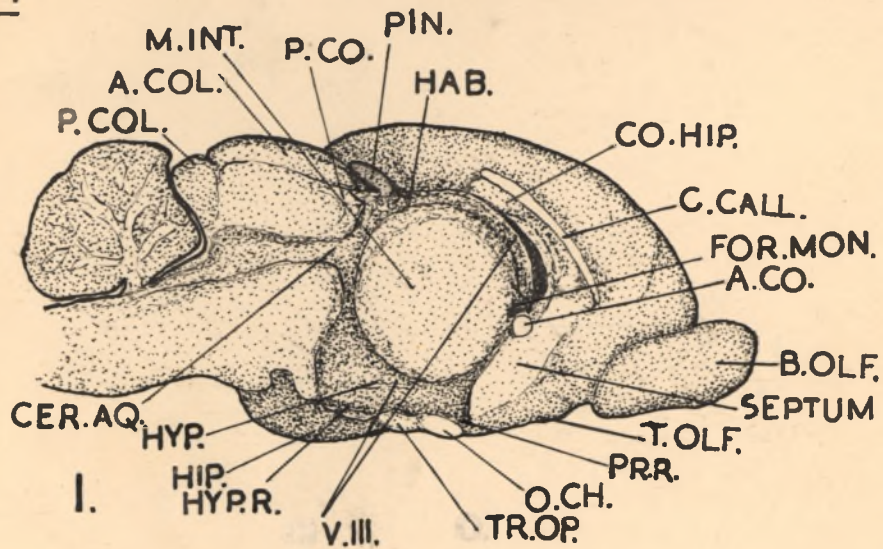
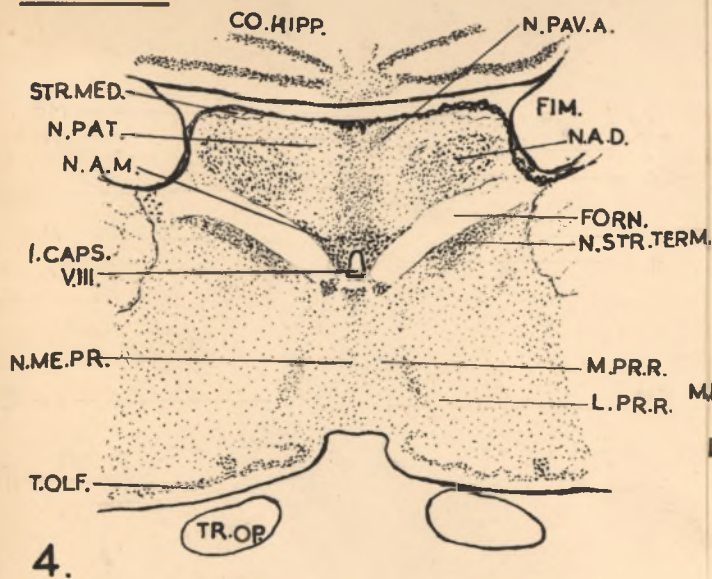
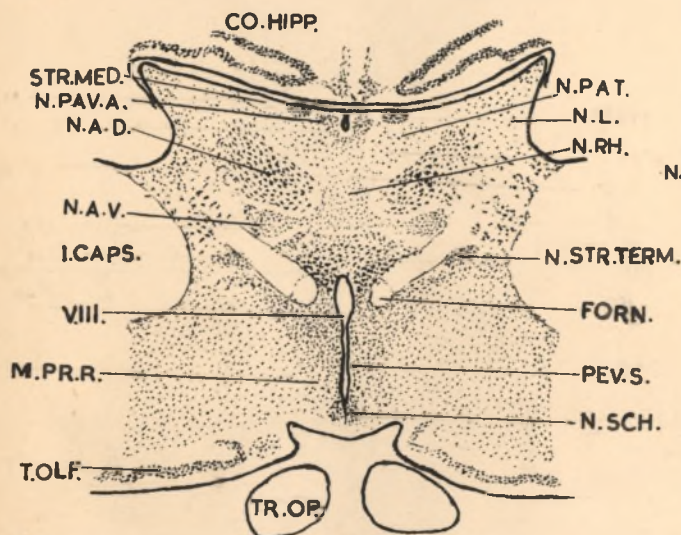


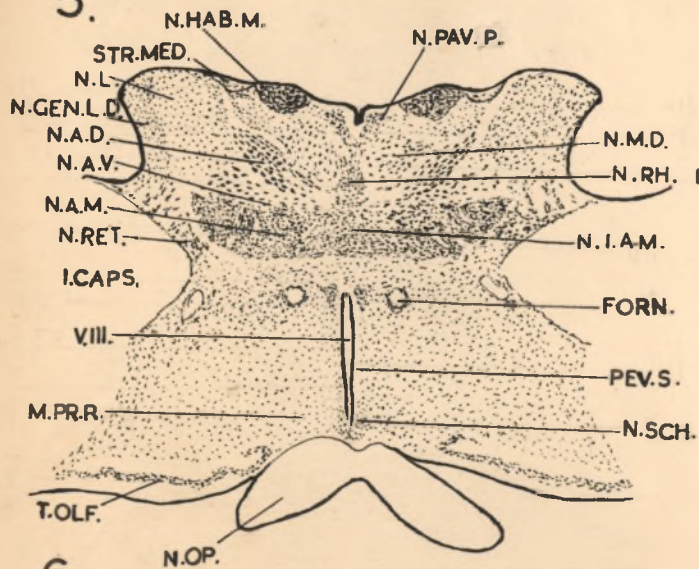
PLATE 2



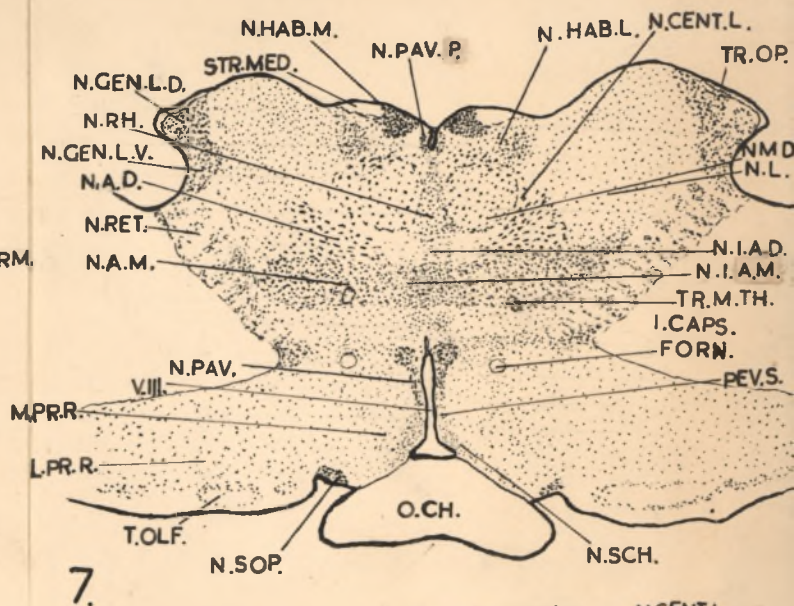
4.



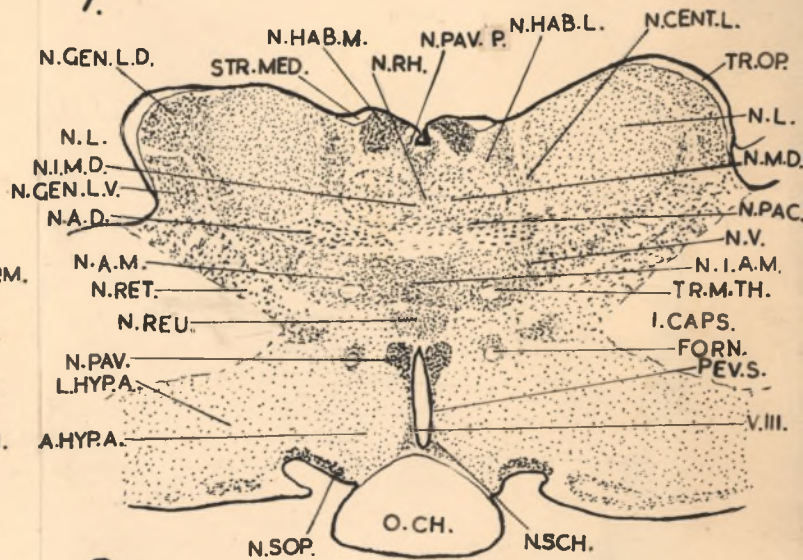
5.



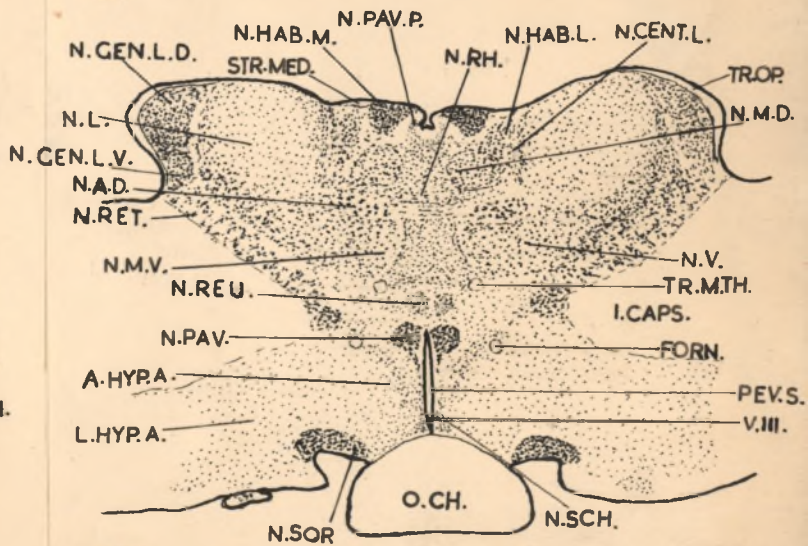
6.



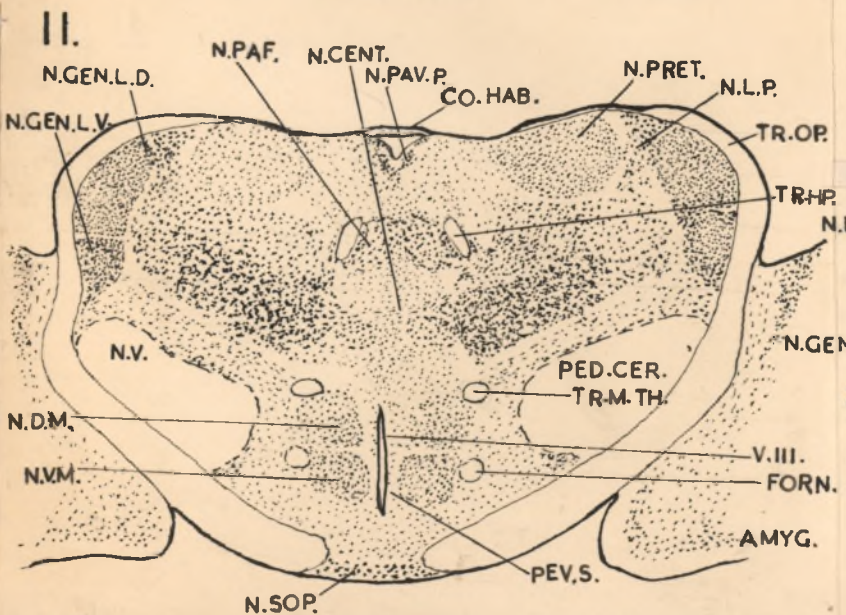
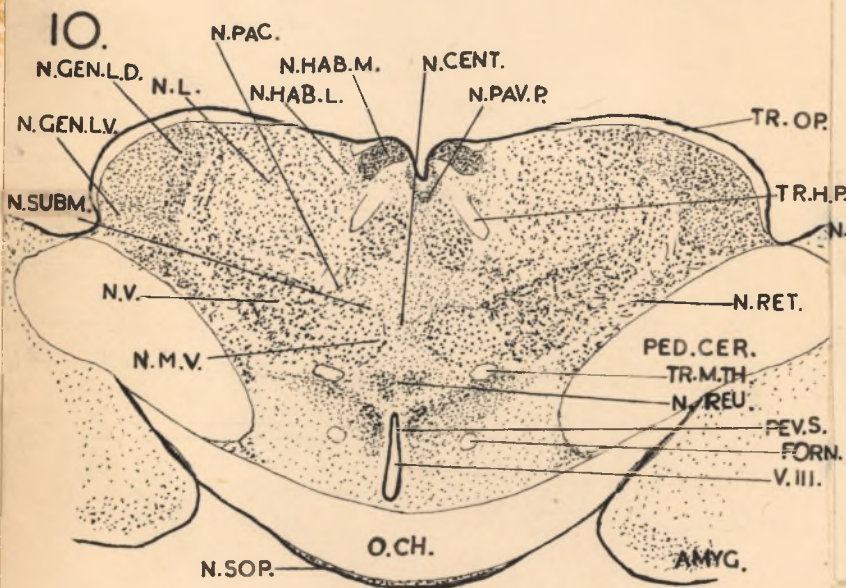
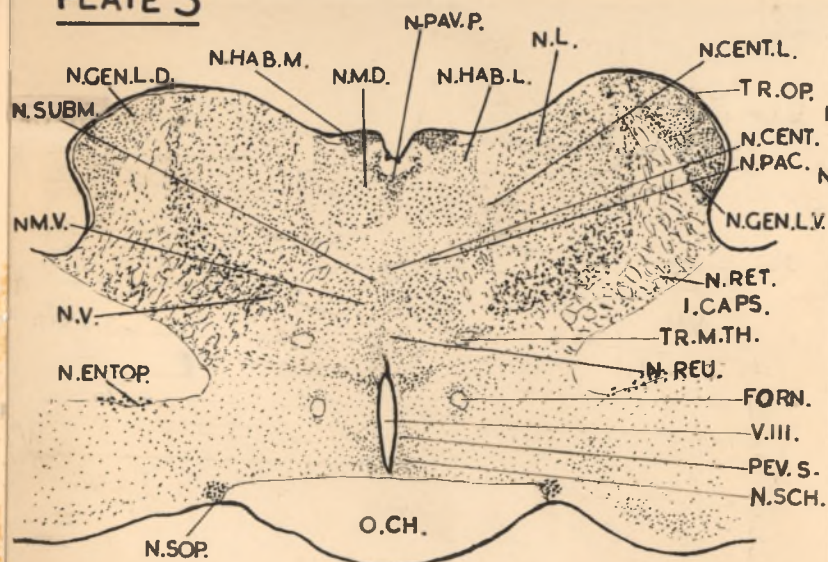
7.



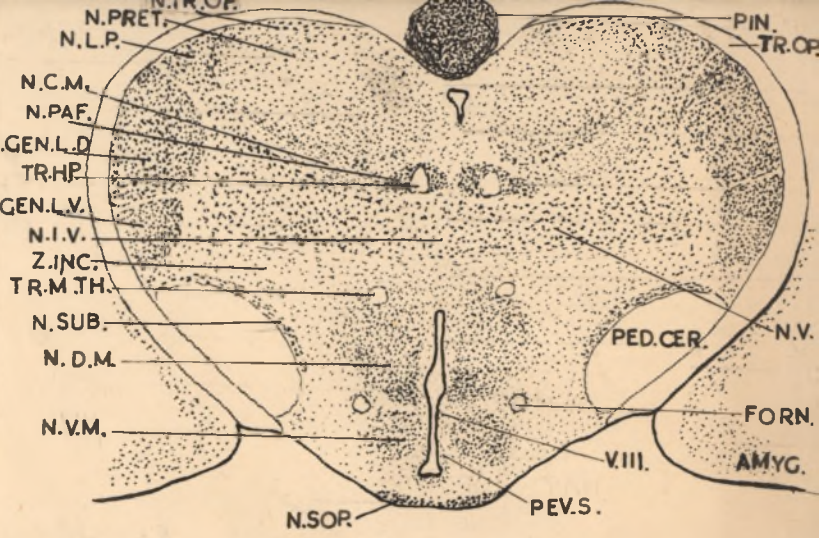
8.



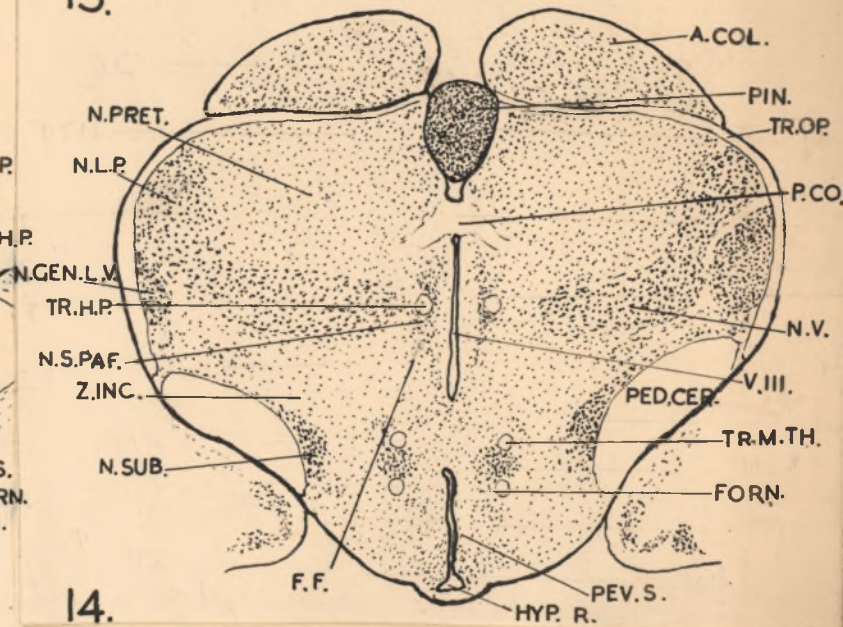
9.



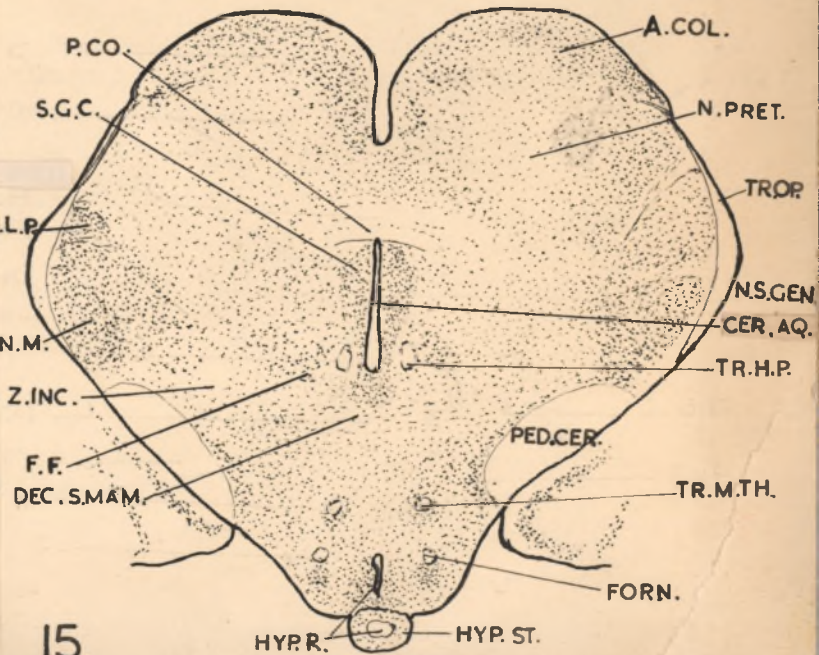
12.



13.

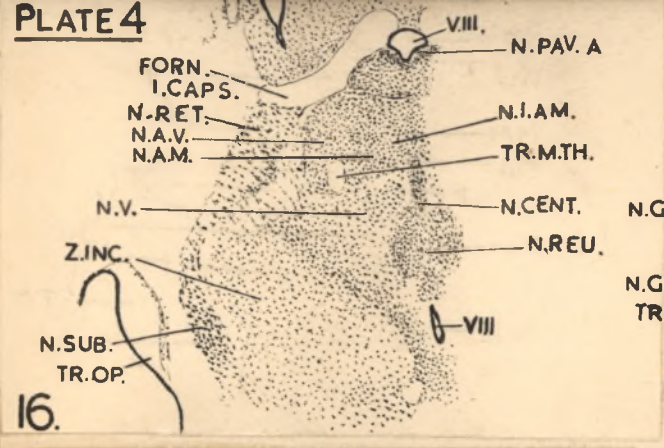


14.

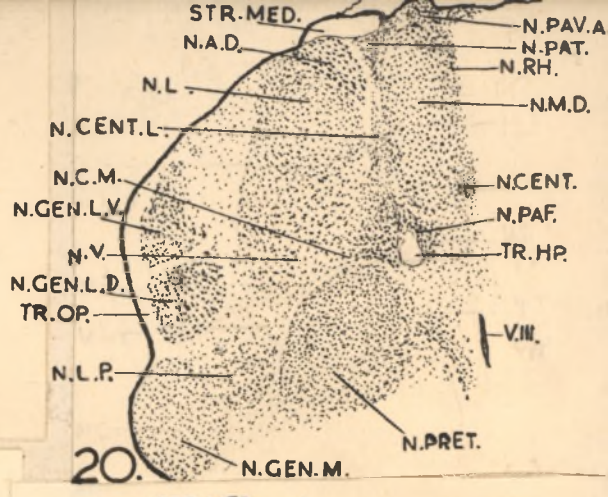


15.

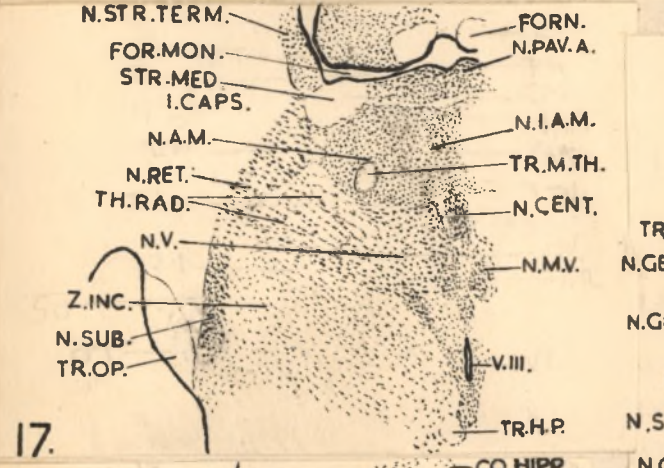
PLATE 4



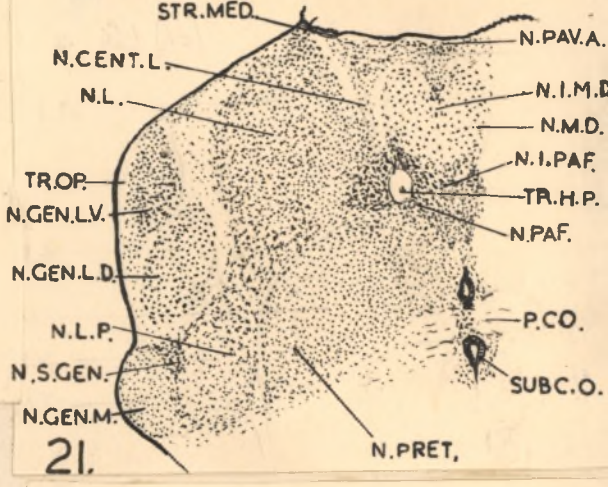
16.



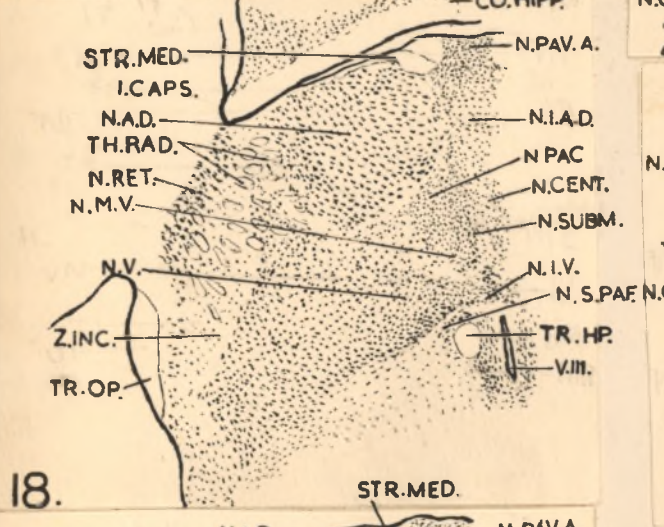
20.



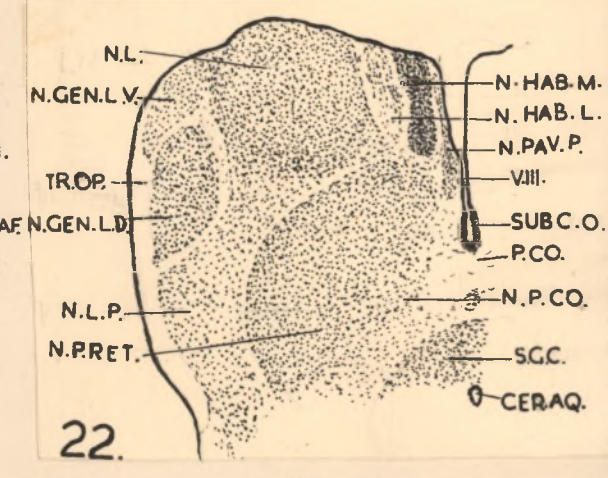
17.



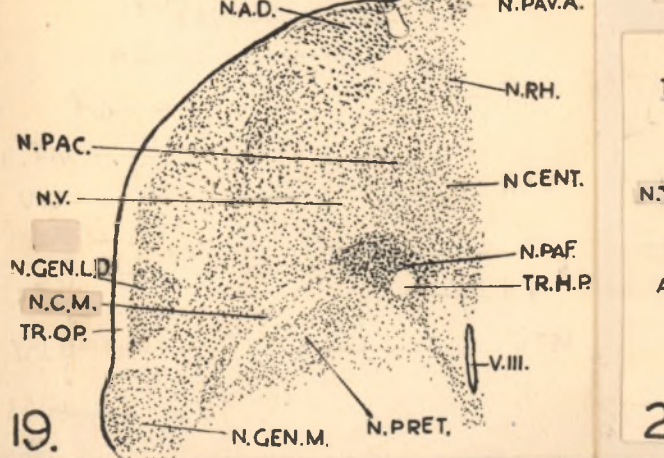
21.



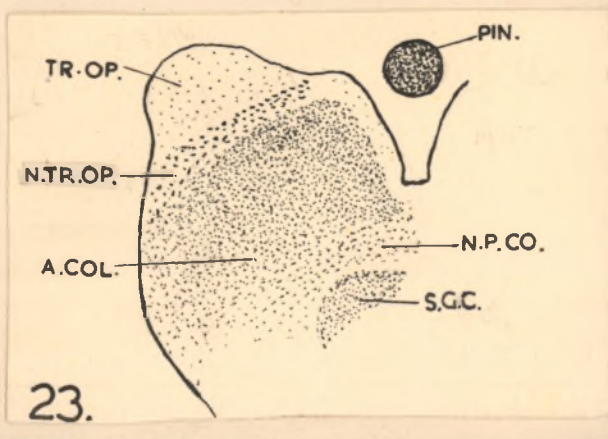
18.



22.

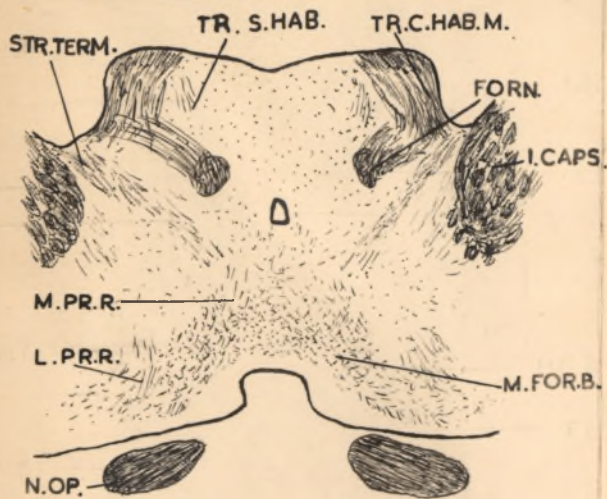


19.

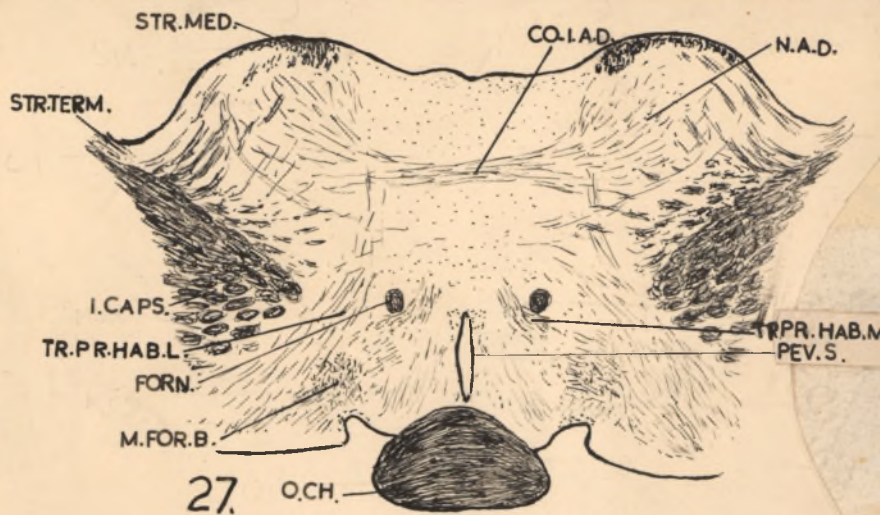


23.

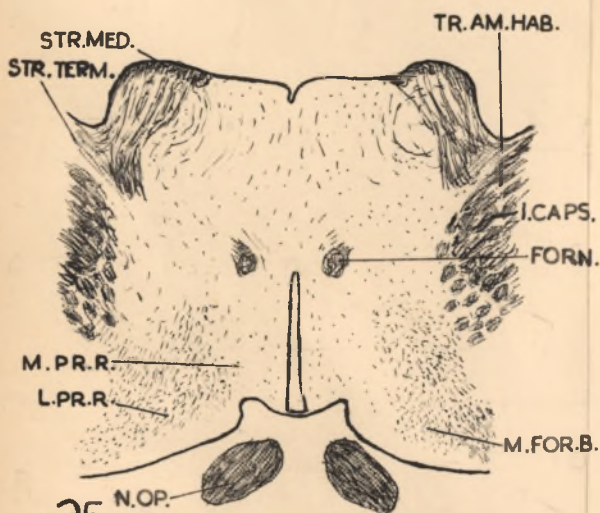
PLATE 5



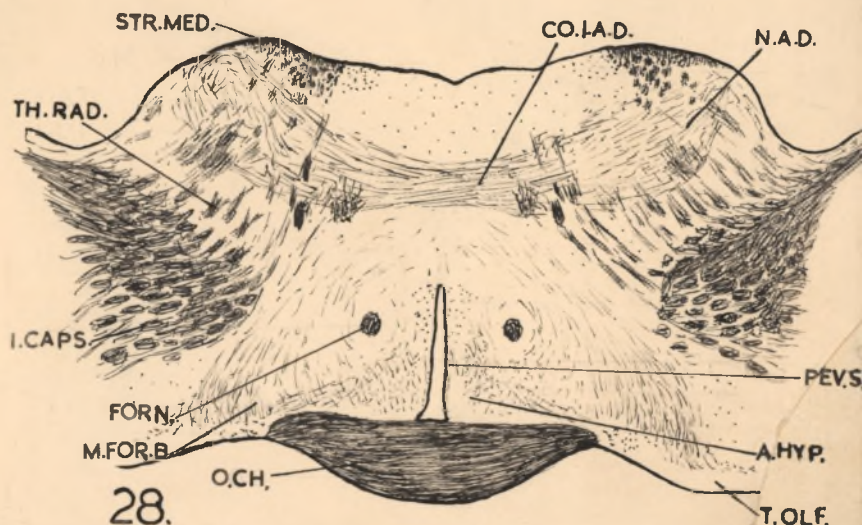
24.



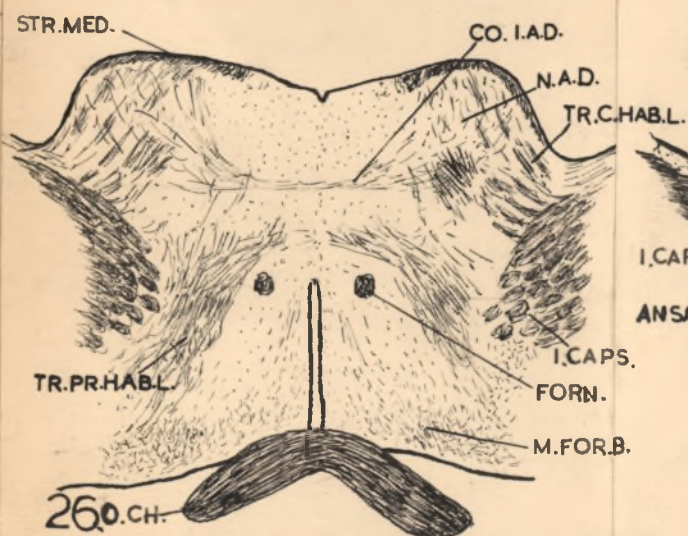
27.



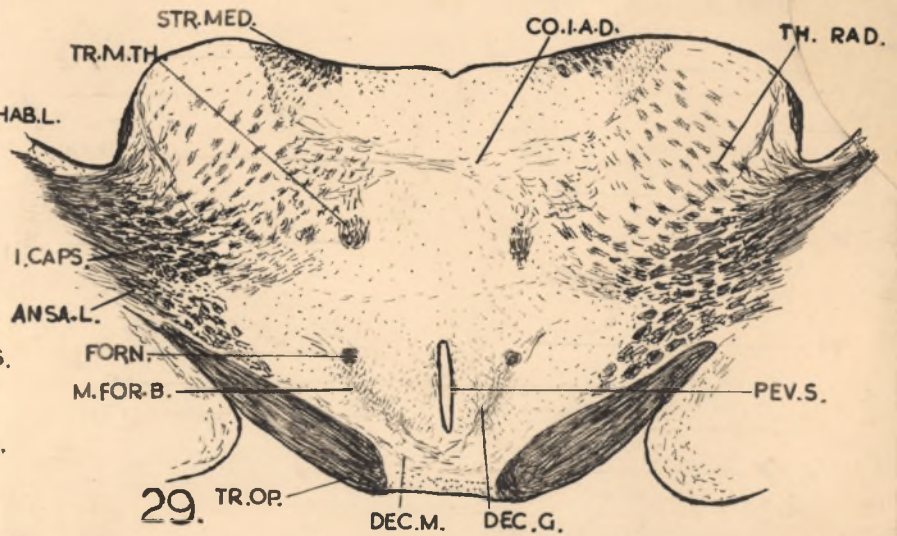
25.



28.

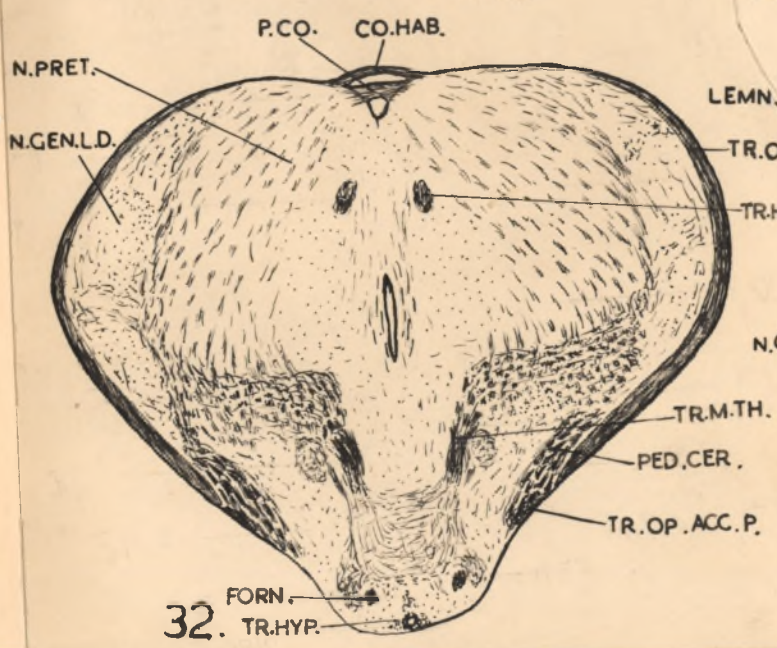
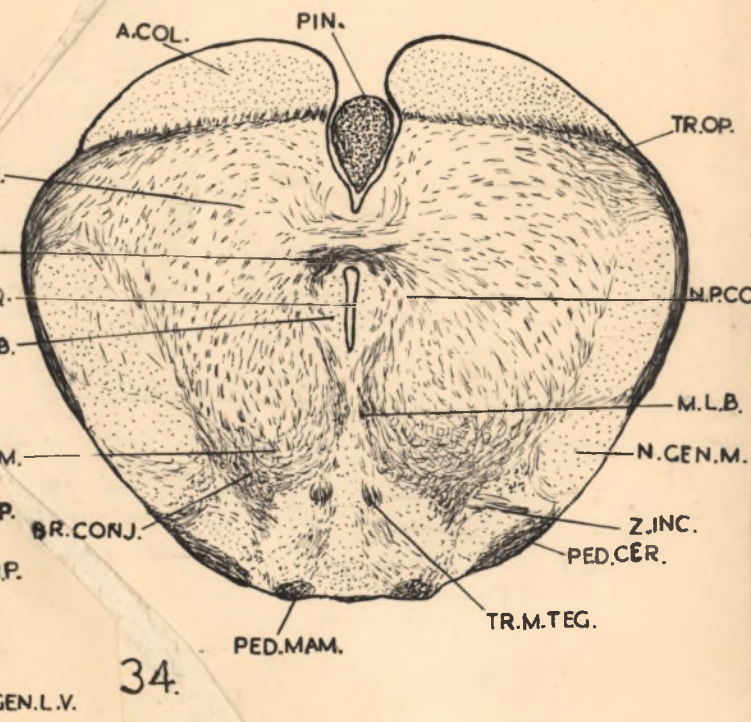
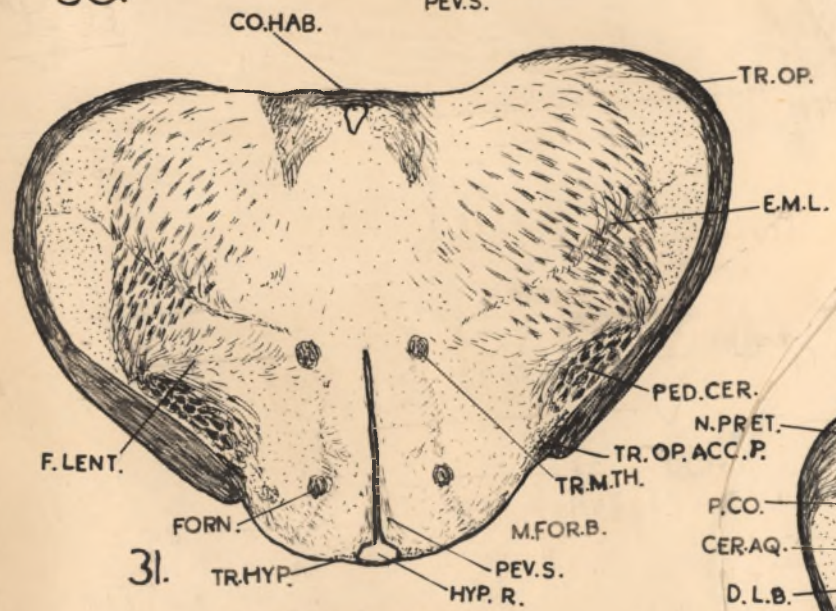
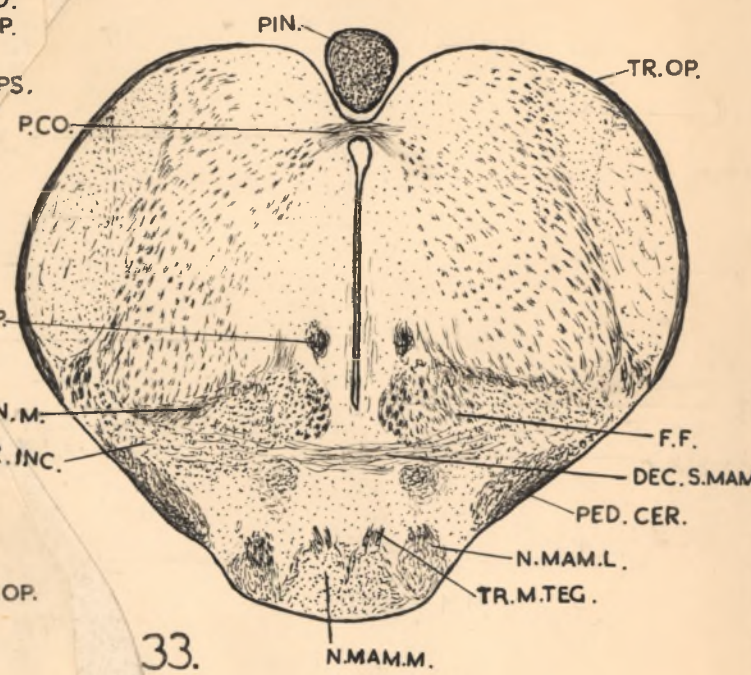
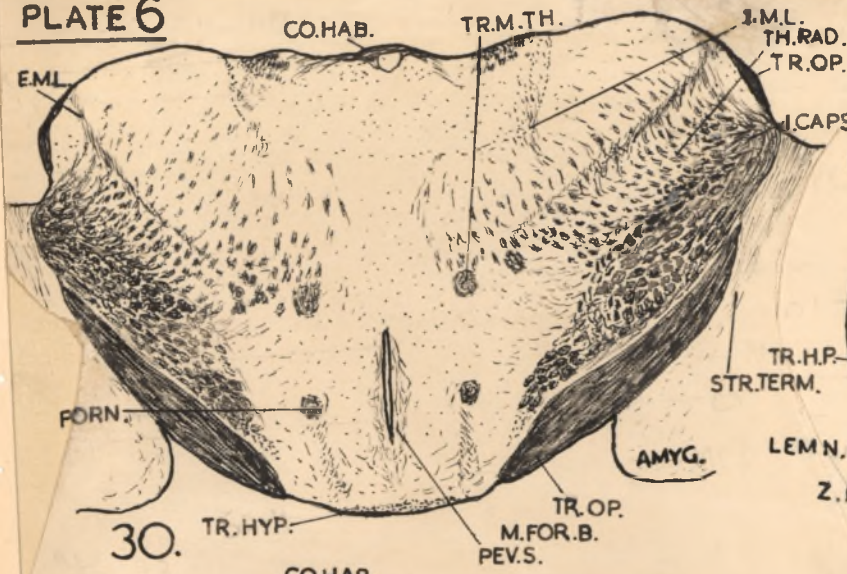


26.



29.

PLATE 6



SELECTED BIBLIOGRAPHY.

- ARIENS KAPPERS, C.V., G.C. HUBER and E.C. CROSEY 1936
The comparative anatomy of the nervous system of
vertebrates, including man. 2 Macmillan, New York.
- BODIAN, D. 1937 An experimental study of the optic tracts
and retinal projection of the Virginia opossum.
J. Comp. Neur. 66, 113.
- 1939 Studies on the diencephalon of the Virginia
opossum. The nuclear pattern in the adult. 71, 259.
 - 1940 Idem II. The fibre connections in normal
and experimental material. Ibid. 72, 207.
 - 1942 Idem III. The thalamo-cortical projection.
Ibid. 77, 525.
- BRENNER, S. 1946 The chromosome complement of Elephantulus.
S. Afr. J. Med. Sci., 11, Biol. Suppl., 71.
- CLARK, W.E. LE GROS. 1928 On the brain of the Macrosceli-
didae. J. Anat. 62, 245.
- 1929 The thalamus of the Tupaia minor.
Ibid. 63, 177.
 - 1929a Studies on the optic thalamus of the
Insectivora - the anterior nuclei, Brain. 55, 406.
 - 1930 The thalamus of Tarsius. J. Anat. 64, 371.
 - 1934 Early forerunners of man. Ballière, Tindall and
Cox, London.
 - 1942 The visual centres of the brain and their
connections. Physiol. Rev. 22, 205.
- ELLIOT-SMITH, G.H. 1910 The Arris and Gale Lectures.
Lancet. 1, 1.
- GILBERT, C. 1944 The development of the post-renal vena
cava in Elephantulus. S. Afr. J. Med. Sci., 9,
Biol. Suppl., 63.

- GOLDBY, F. 1941 The normal histology of the thalamus of the phalanger, *Trichosurus vulpecula*. *J. Anat.* 75, 197.
- GURDJIAN, E.S. 1925 Olfactory connections in the albino rat, with special reference to the stria medullaris and anterior commissure. *J. Comp. Neur.* 38, 127.
- 1927 The diencephalon of the albino rat. *J. Comp. Neur.* 43, 1.
- HORST, C.J. van der, and J. GILLMAN. 1941 The menstrual cycle in *Elephantulus*. *S. Afr. J. Med. Sci.*, 7 Biol. Suppl. 73.
- HUXLEY, J.S. 1941 *Evolution, etc.* Allen and Unwin, London.
- JOHNSTON, J.B. 1923. Further contributions to the study of the evolution of the forebrain. *J. Comp. Neur.* 35, 337.
- LOO, Y.T. 1931 The forebrain of the opossum, *Didelphys virginiana*, 11. Histology. *J. Comp. Neur.* 52, 1.
- MARBURG, O. 1944 The structure and fibre connections of the human habenula. *J. Comp. Neur.* 80, 211.
- PAPEZ, J.W. 1932 The thalamic nuclei of the nine-banded armadillo (*Tatusia novemcinctata*) *J. Comp. Neur.* 56, 49.
- RIOCH, D.Mc.K. 1929 Studies on the diencephalon of carnivora Part I. The nuclear configuration of the thalamus, epithalamus and hypothalamus of the dog and cat. *J. Comp. Neur.* 49, 1.
- 1929a Idem Part II. Certain nuclear configurations and fiber connections of the subthalamus of the dog and cat. *Ibid.* 49, 121.
- 1931 Idem Part III. Certain myelinated fiber connections of the diencephalon of the dog (*Canis familiaris*), cat (*Felis domestica*), and weasels (*Procyon lotor*) *Ibid.* 53, 319.

- SOLMITZKY, O. 1938 The thalamic nuclei of *Sus scrofa*.
J. Comp. Neur. 69, 121.
- WALKER, A.E. 1938 The primate thalamus. The University of
Chicago Press, Chicago, Ill.
- 1940 The medial thalamic nucleus. A comparative
anatomical, physiological and clinical study of
the nucleus medialis dorsalis thalami.
J. Comp. Neur. 73, 87.
- WRIGHT, M.K. 1945 The cell masses in the forebrain of the
Elephant shrew. S. Afr. J. Med. Sci., 10,
Biol. Suppl., 19.
- 1947 Personal communication.
-

File No.

Name

Address

Date

19

FILE No.	NAME	ADDRESS	DATE
			From _____ 19
			To _____ 19
			Reference _____

YePatax

'Falinge' File

No. 2 S.S. F'cap size.

