

https://dspace.org/

Airway status in civilian maxillofacial gunshot injuries in Johannesburg, South Africa

Tsakiris, P.; Cleaton-Jones, P. E.; Lownie, M. A.

2002

http://hdl.handle.net/10539/20437

Tsakiris,P., Cleaton-Jones,P.E., Lownie,M.A.2002. Airway status in civilian maxillofacial gunshot injuries in Johannesburg, South Africa.South African medical journal;92(10):803-806

Downloaded from a DSpace repository. https://dspace.org/

AIRWAY STATUS IN CIVILIAN MAXILLOFACIAL GUNSHOT INJURIES IN JOHANNESBURG, SOUTH AFRICA

P Tsakiris, P E Cleaton-Jones, M A Lownie

Background. Airway management of the maxillofacial gunshot injury constitutes a critical decision and an area that requires review in the context of civilian injuries. Most of our knowledge is extrapolated from military experience, which constitutes a different trauma patient group. This paper reports a retrospective survey of airway status in relation to maxillofacial gunshot injuries. The objective is to correlate clinical findings with treatment decisions.

Methods. A survey was done of 11 622 archived maxillofacial surgery records (1987 - 1992) in the three academic hospitals in Johannesburg.

Results. There were 211 maxillofacial gunshot injuries, for which 92 patient records had sufficient detail for inclusion in the analysis. The typical patient was a black male aged 20 - 29 years, shot with a low-velocity bullet of 0.38 calibre, admitted to hospital the day of the injury, operated on within 4 days, and discharged 4 days later. The airway was threatened in 20/92 cases at admission; 12/20 cases were treated with oro- or nasotracheal intubation, and 9/12 later had elective tracheostomies; 8/20 needed immediate surgical airways, 5 tracheostomies and 3 cricothyroidotomies (all later converted to tracheostomies). Three of thirty-seven patients with normal airways on admission later required emergency tracheostomy.

Conclusions. An abnormal airway was significantly more likely after a high-velocity injury, and when the tongue, floor of mouth, midline or bilateral facial skeletal bones were involved.

S Afr Med J 2002; **92:** 803-806.

Division of Maxillofacial and Oral Surgery, Faculty of Health Sciences, University of the Witwatersrand, Johannesburg

P Tsakiris, Dip Dent (Athens), MSc (Dent), MDent, FCD, FCD (CMSA-MFOS)

Medical Research Council/University of the Witwatersrand Dental Research Institute, Johannesburg

P E Cleaton-Jones, BDS, MB BCh, PhD, DSc (Dent)

Division of Maxillofacial and Oral Surgery, Faculty of Health Sciences, University of the Witwatersrand, Johannesburg

M A Lownie, BDS, Dip MFOS, FCMFOS, BA Hons

Gunshot wounds are now common in many countries but, in contrast to other parts of the body, little has been written on gunshot wounds of the face.[1] Most of the reports on facial gunshot wounds have dealt with military injuries, probably owing to the importance that the military attaches to logistics and strategic planning. Information on civilian injuries is scanty, and Demitriades *et al.*[1] have noted that only six series of the early management of gunshot injuries to the face had been published in the English language literature between 1986 and 1998.

Maxillofacial gunshot injuries threaten the airway.[2,3] The degree of threat is influenced by the position of the injury as well as the calibre and velocity of the weapon that inflicted it. In some circumstances management of the threatened airway is obvious. Airway obstruction due to high-velocity and shotgun injuries of the floor of the mouth, tongue and anterior mandible is treated with endotracheal intubation or replacement of a surgical airway.[4,5] There is also general agreement about the management of airway problems in military maxillofacial gunshot injuries, in which high-velocity weaponry predominates;[6,7] the recommended treatment is emergency tracheostomy, with scant mention of cricothyroidotomy as an alternative procedure. This omission may be semantic, with the term 'tracheostomy' intended to mean a surgical airway either via an incision into the cricoid membrane or through the lower tracheal rings.

In contrast to the clear military policy, there are differences in airway management of civilian maxillofacial gunshot injuries.[5,8-12] There is a perception that low-velocity, low-calibre maxillofacial gunshot injuries rarely pose a threat to life from airway obstruction.[8] It is common knowledge that anatomical disruption of the maxillofacial complex can threaten the airway, irrespective of energy transfer.[4,8] The prevalence of surgical airways in military maxillofacial missile injuries ranges from 17% to 41%.[13,14] The rates of airway management in civilian maxillofacial gunshot injuries have been reported as 33% for endotracheal intubation and from 2% to 30% for surgical airways.[5,10-12] The more conservative approach (endotracheal intubation, infrequent surgical airway[4,9]) has been reported from maxillofacial departments[10] compared with a higher frequency of surgical airways in studies from general surgical and ear, nose and throat (ENT) departments,[11,12] owing to the presence of concomitant neck injuries in patients treated in the latter. There is scant published information on the predominant type of injuries that would be seen by maxillofacial surgeons, and specific clinical information on airway status is even less common. Too much is left to the attending clinician in quantifying 'significant' injuries[14,15] and in predicting resultant oedema, based on personal experience and departmental protocols of treatment. Correlating clinical signs to expectant airway problems is usually the challenge posed to the individual treating such injuires.

The current paper describes a retrospective survey of airway status and management in relation to maxillofacial gunshot injuries in Johannesburg, South Africa. The objective is to provide the attending clinician with information pertaining to the appropriate management of the maxillofacial gunshot injury.

MATERIALS AND METHODS

Ethics clearance for the retrospective survey was granted by the Committee for Research on Human Subjects (Medical) of the University of the Witwatersrand. The study period was January 1987 - December 1992. All records in the archives of the three academic hospitals served by the Division of Maxillofacial and Oral Surgery of the University of the Witwatersrand were examined. These were Johannesburg Hospital, Hillbrow Hospital and Baragwanath Hospital. For inclusion in the study, records had to contain clear, specific information on gunshot wounds of the maxillofacial region. There were 211 cases available, of which 92 had clear information. Details of patient demography, airway status, extent of injury, location of injury, and type of weapon velocity were recorded for analysis with the Statistical Analysis System (SAS Institute Inc., Cary, NC, USA) and Instat 3 (GraphPad Software, San Diego, Calif., USA) using Fisher's exact test, the chi-square test or the Mantel-Haenszel chi-square test for trend (M-H χ^2) with statistical significance set at $P < 0.05$. Choice of test depended on numbers in the cross-tabulation cells and on whether a variable was ordinal or not. Unless otherwise stated the degree of freedom was 1.

RESULTS

During the study period there were 11 622 maxillofacial surgical cases treated at the three academic hospitals, so the 211 gunshot injuries were a small proportion (1.8%) of the work-load. There was an increase in the prevalence within the 211 gunshot injury cases from 9% to 37% over the period 1987 - 1992. Only 92 patients (46.3%) had sufficient detail in the case notes to be included in the study.

The demographic characteristics of the 92 patients in the study sample showed the typical gunshot victim to be a black male aged 20 - 29 years who had been shot with a low-velocity bullet of 0.38 calibre (Fig. 1). He was admitted to hospital the day of the injury and underwent a maxillofacial procedure within 4 days of admission. Generally the mandible was affected and the bullet was still in the tissues. Discharge was within 4 days of the surgical procedure.

As depicted in Table I, the characteristic injury was a predominantly transverse injury (i.e. crossing the midline) with localised comminution of the fracture site. The entry wound was predominantly located in the lower third of the facial



Fig. 1. Clinical presentation of civilian low-velocity maxillofacial gunshot wound on admission. The entry wound is in the left parasymphysis and the exit wound is on the right. The patient could maintain an airway by posturing and is a high-risk airway problem (floor of mouth, bilateral fracture mandible, loss of anterior tongue support).

Table I. Details of injury characteristics in descending prevalence (*N* = 92)

Bullet trajectory	Transverse 63%, sagittal 25%, tangential 12%
Injury site[8]	Mandible 61%, maxilla 21%, both jaws 10%, zygoma/orbit 3%, others 5%
Injury extent[3]	Type III 61%, neural 53%, major lacerations 37%, type II 25%, type IV 19%, ocular 8%, type I 9%
Entrance wound	Lower 1/3 (mandible region) 58%, mid 1/3 (maxilla/zygoma/orbit region) 36%, neck 6%, upper 1/3 (forehead region) 1%
Exit wound	None (penetrating injury) 46%, lower 1/3 32%, mid 1/3 10%, intra-oral 8%, neck 3%, upper 1/3 1%

Type I = soft-tissue injury alone; type II = single fracture without comminution; type III = single fracture with localised comminution of fracture site; type IV = severe comminution of a large area of bone.

skeleton (region of the mandible) and an exit wound was present in more than half the cases (i.e. perforating injuries) that infrequently involved the neck. The airway was threatened in 20 cases (22%) at admission with only 1 patient having arrived with an endotracheal tube already inserted by paramedics. At admission 12/20 cases (60%) were treated with oro- or nasotracheal intubation (Fig. 2); 9 of these later had elective tracheostomies. Eight of the 20 patients (40%) needed immediate surgical airways — five tracheostomies and 3 cricothyroidotomies. All the cricothryroidotomies were later converted to tracheostomies. Of the 37 airways recorded as normal on admission, three later required emergency tracheostomy.

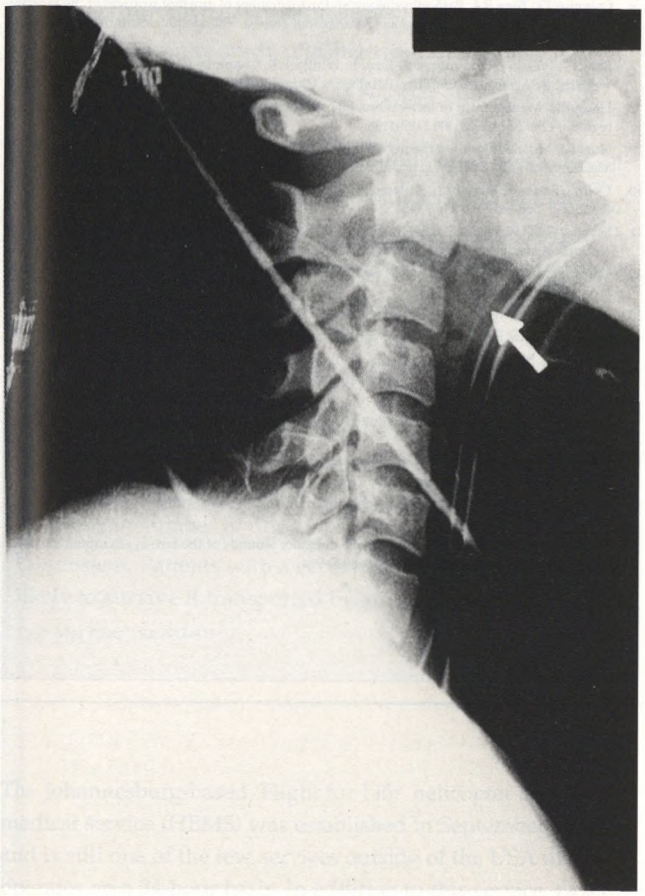

Fig. 2. Lateral cervical spine radiograph showing prevertebral soft-tissue oedema that required airway management with an endotracheal tube. Note the bullet in the ramus region and the fractured condyle.

For statistical analysis two classes of airway status were used; abnormal ($N = 20$) and normal ($N = 37$) as recorded at admission. Although it is likely that the airway was normal when nothing was recorded, such cases were not included in the analysis.

An abnormal airway was significantly more likely after a high-velocity injury (6/7 cases, 86%, Fisher's test $P = 0.003$) (Fig. 3) — these were accompanied by avulsion damage, if the



Fig. 3. High-velocity maxillofacial gunshot injury with tracheostomy in situ.

tongue ($\chi^2 = 3.80$, $P = 0.05$) or floor of the mouth ($\chi^2 = 5.24$, $P = 0.05$) were involved and if the injury was in the midline ($\chi^2 = 8.91$, df = 2, $P = 0.05$).

Abnormal airways, although not statistically significant, were seen in 9/14 (64%) of midline, 3/9 (33%) of bilateral and 2/30 (7%) of unilateral skeletal maxillofacial gunshot injuries. Of the patients who had an injury to the floor of the mouth 13/27 (48%) had an abnormal airway on admission; for the tongue the proportion was 9/19 (47%) .

Linked to the need for a patent airway in maxillofacial gunshot injuries is the cardiovascular status of the patient. In this study patients were considered haemodynamically stable if their systolic blood pressure at admission was 100 mmHg or higher — this was the situation in 94% of patients.

Regarding haemoglobin levels 77% had values above 10 g/dl; the remainder were between 8.8 and 9.9 g/dl. Eleven patients (11%) had tachycardia (>100 beats/min). All the patients were conscious, but 4 had a serious vascular injury requiring immediate attention. Tachycardia (>100/min) was noted in 12/64 of same-day admissions and in none of the 25 patients admitted > 1 day after the injury, a trend that was statistically significant (M-H $\chi^2 = 27.06$, $P < 0.0001$). With regard to systolic blood pressure 11/64 were hypotensive (< 100 mmHg) in the group admitted on the same day, compared with 17/25 admitted more than 1 day after the injury (M-H $\chi^2 = 18.04$, $P < 0.0001$). Patients with abnormal airways had more problems in the postoperative period ($\chi^2 = 11.15$, $P = 0.008$); these were infections, neural deficit and death.

Discussion

The typical maxillofacial gunshot injury patient in Johannesburg has a similar demographic profile to one in Cape Town,[3] but the frequency of such injuries in Johannesburg is higher — 211 in 6 years compared with 311 in 15 years in Cape Town. Airway status is the central concern of the casualty

officer and maxillofacial surgeon treating gunshot injuries. Airway patency is threatened by the disruption of the oral and nasal structures, the potential soft-tissue swelling around the trachea regions and the presence of blood in the air passages.[4-6,12-16] Dolin *et al.*[10] found that anatomical location of injury affected airway status, with 48% of mandibular and 36% of maxillary injuries requiring airway control.

From this study it was shown that floor of mouth injury, tongue injury, location of fracture (midline and bilateral) and high-velocity missile significantly affected the airway status. Neurological and haemodynamic status did not significantly affect airway status underlying the localised nature of the effects of injury. Tao Yao *et al.*[12] reported that isolated floor of mouth gunshot injuries presented with a compromised airway. In our study, such isolated floor of mouth injuries without concomitant fractures were not reported. The current study showed that 22% of the patients had a protected airway on admission; this was rarely done by paramedics of the ambulance service at the site of the injury and more commonly done at the admitting casualty department. Of those with protected airways approximately 60% were intubated and 40% had a surgical airway. An interesting finding is that of those patients who were evaluated as having a normal airway on admission, 11% required some form of emergency airway management. This underlines what has been stated in the literature concerning the importance of early protection of the airway.[10,11,17-19] The frequency of tracheostomy of 22% in the current study is similar to that reported by Tao Yao *et al.*[12] but lower than reported by Dolin *et al.*[10] and May *et al.*[11] There was an increase in the rate of tracheostomy between this study and that of the similar South African study in the same hospitals by Cohen *et al.*[5] some 10 years earlier. This difference is probably due to a more aggressive assault pattern seen in our study, resulting in greater tissue destruction (i.e. closer range injury). There are no studies to date that have compared endotracheal intubation and tracheotomies in maxillofacial gunshot wounds. The early endotracheal intubation in some of the patients did not prevent the need for later surgical airway protection in two-thirds of the intubated patients. However, early non-urgent intubation could be provided under less stressful and more controlled conditions, to the benefit of both patient and clinician.

Conclusions

Airway compromise in civilian maxillofacial gunshot injuries is not rare. Airways considered normal initially can deteriorate. The clinical factors that could affect correct decision in pre-emptive airway protection of low-velocity injuries are floor of mouth, tongue, and midline and bilateral skeletal maxillofacial injury. High-velocity injuries usually present with equivocal signs of airway obstruction.The increased stress related to performing emergency surgical airway and urgent intubation could be minimised if a pre-emptive controlled airway protection protocol based on clinical findings is applied. This philosophy could also be applied in the field in relation to other factors such as transport, distance and time.

References

1. Demetriades D, Chahwan S, Gomez H, Velmahos G, Yamashita D. Initial evaluation and management of gunshot wounds to the face. *J Trauma* 1998; **39:** 39-41.
2. Al-Shawi A. Experiences in the treatment of missile injuries of the maxillofacial region in Iraq. *Br J Oral Maxillofac Surg* 1986; **24:** 244-250.
3. Kassan AH, Kariem G, Lalloo R. A retrospective analysis of gunshot injuries to the maxillofacial region. *SADJ* 2000; **55:** 359-363.
4. Kwapis BW. Early management of maxillofacial war injuries. *J Oral Surg* 1954; **12:** 293-309.
5. Cohen MA, Skakenovsky BN, Smith I. Low-velocity hand-gun injuries of the maxillofacial region. *J Maxillofac Surg* 1986; **14:** 26-33.
6. Osborne TE, Bays RA. Pathophysiology and management of gunshot wounds to the face. In: Fonseca RJ, Walker RV, eds. *Oral and Maxillofacial Trauma.* Philadelphia: Saunders, 1991: 672-701.
7. Banks P, Wilson JSP, Saunders R, Terry B, Whitlock R, Chapman CW, Williams JL. Gunshot wounds. In: *Maxillofacial Injuries.* Edinburgh: Churchill Livingstone, 1985: 561-694.
8. Haug RH. Management of low-calibre, low-velocity gunshot wounds in the maxillofacial region. *J Oral Surg* 1989; **47:** 1192-1196.
9. Nunes J. Missile injuries to the maxillofacial region. Dental student project report, Division of Maxillofacial and Oral Surgery, University of the Witwatersrand, Johannesburg, 1992: 1-21.
10. Dolin J, Scalea T, Mannor L, Scalafani S, Trooskin S. The management of gunshot wounds of the face. *J Trauma* 1992; **33:** 508-515.
11. May M, Cuchavaree A, Chaderatana P, West J. Mandibular fractures from civilian gunshot wounds: A study of 20 cases. *Laryngoscope* 1973; **83:** 969-973.
12. Tao Yao S, Vaneko RM, Corley RD, Stuteville OH, Shoemaker WC. Gunshot wounds of the face. *J Trauma* 1972; **12:** 523-528.
13. Phillips RM. Early management of maxillofacial war injuries. *J Oral Surg* 1970; **28:** 808-813.
14. Terry BC. Facial injuries in military combat: definitive care. *J Oral Surg* 1969; **27:** 551-556.
15. Coppe DL, Balmer HGR, Dundee JW. Civil disturbance and anaesthetic workload in the Royal Victoria Hospital, Part II: The respiratory and intensive care unit. *Anesth Analg* 1973; **52:** 147-155.
16. Saletta JD, Lowe RJ, Lim LT, Thornton J, Delk S, Moss GS. Penetrating trauma to the neck. *J Trauma* 1976; **16:** 579-587.
17. Stiernberg CM, Jahrdoefer RA, Gillenwater A, Joe SA, Alcalen SV. Gunshot wounds to the head and neck. *Arch Otolaryngol Head Neck Surg* 1992; **118:** 592-597.
18. Grant TD, Epstein LI. Low velocity gunshot to the maxillofacial complex. *J Trauma* 1979; 19: 674-677.
19. Alper M, Total S, Cankayali R, Songur E. Gunshot wounds of the face in attempted suicide patients. *J Oral Maxillofac Surg* 1998; **56:** 930-934.

Accepted 6 September 2002.