

https://dspace.org/

A five year review of orbital biopsies at two Johannesburg hospitals

Naidu, Natasha

2018
https://hdl.handle.net/10539/27019

Downloaded from a DSpace repository. https://dspace.org/

A FIVE YEAR REVIEW OF ORBITAL BIOPSIES AT TWO JOHANNESBURG HOSPITALS

Natasha Naidu

A research report submitted to the Faculty of Health Sciences, University of the Witwatersrand, Johannesburg, in partial fulfilment of the requirements for the degree of Master of Medicine in the branch of Ophthalmology

Johannesburg

August 2018

DEPARTMENT OF NEUROSCIENCES

Neurology, Neurological Surgery, Ophthalmology,
Otorhinolaryngology, Psychiatry
School of Clinical Medicine, Faculty of Health Sciences,
7 York Road, Johannesburg 2193, South Africa
Tel: +27 11 717-2774 · Fax: +27 11 717 2775

Plagiarism declaration for written work

I Natasha Naidu as a postgraduate student registered for a MMed at the University of the Witwatersrand declare the following:

- I am aware that plagiarism is the use of someone else's work without their permission and or without acknowledging the original source.
- I am aware plagiarism is wrong.
- I confirm that this written work is my own work except where I have stated otherwise.
- I have followed the required conventions in referencing the thoughts and ideas of others.
- I understand that the University of the Witwatersrand may take disciplinary action against me if there is a belief that this is not my own unaided work or if I have failed to acknowledge the ideas or writing of others.

Signature …… Date: ……

ABSTRACT

Purpose: The objectives of this study were to report on the histological diagnosis of orbital biopsies and to describe the associated demographic data .

Methods: A clinical audit of orbital biopsies was undertaken at Chris Hani Baragwanath Academic Hospital and Charlotte Maxeke Johannesburg Academic Hospitals. The study period was from January 2011 to December 2015. Patient information was captured from theatre registers and the laboratory database.

Results: The largest group of orbital lesions biopsied were cystic lesions (17.3%) followed by lacrimal gland lesions (16%). The patients' ages ranged from 1-82 years. The majority of patients were African (85.3%) and female (52%)..

Conclusion: The results of this clinical audit differ slightly from international reports. It is the first report of orbital biopsies in a South African, tertiary hospital setting.

To God,

for your infinite blessings.

To mum,

for your sacrifice and motivation.

To Yegz,

for your love and support.

ACKNOWLEDGEMENTS

A special thank you to Professor Grant McLaren for his supervision and encouragement with my MMed. I would also like to thank the theatre staff at the hospitals involved for keeping detailed records. Much gratitude to the National Health Laboratory Service staff for aiding with my data collection.

CONTENTS **PAGE**

DECLARATION ii

ABSTRACT iii

DEDICATION iv

ACKNOWLEDGEMENTS v

TABLE OF CONTENTS vi

LIST OF TABLES viii

LIST OF FIGURES ix

CHAPTER ONE - INTRODUCTION **1**

1.1. Background and Literature Review **1**

1.2. Aim **4**

1.3. Hypothesis **5**

1.4. Objectives **5**

CHAPTER TWO - MATERIAL AND METHODS **6**

2.1. Study Design **6**

2.2. Ethics **6**

2.3. Sample Population 6

2.4. Inclusion Criteria 6

2.5. Exclusion Criteria 6

2.6. Data Capture 7

2.7. Statistical Analysis 7

CHAPTER THREE - RESULTS 8

3.1. Histology Results 8

3.2. Demographic Results 14

CHAPTER FOUR - DISCUSSION 19

CHAPTER FIVE - CONCLUSION 23

APPENDICES 24

Appendix A : Ethics Clearance Certificate 24

Appendix B: Data Capture Form 25

Appendix C: Summary of Cases 26

REFERENCES 30

LIST OF TABLES **PAGE**

Table 1. : Summary of Literature 4

Table 2.1. : Major Categories of Histological Results 8

Table 2.2. : Breakdown of Cystic Lesions 9

Table 2.3. : Breakdown of Lacrimal Gland Lesions 9

Table 2.4. : Breakdown of Vascular Lesions 10

Table 2.5. : Breakdown of Secondary Orbital Tumors from Adjacent Spread 10

Table 2.6. : Breakdown of Inflammatory Lesions 11

Table 2.7. : Breakdown of Metastatic Lesions 11

Table 2.8. : Breakdown of Lymphoid Tumor and Leukemias 12

Table 2.9. : Breakdown of Other Lesions 12

Table 2.10.: Distribution of Malignant Lesions 13

Table 3. 1 : Diagnosis by Gender 15

Table 3.2 : Paediatric Diagnosis Distribution (1- 12 years) 16

Table 3.3 :Young Adult Diagnosis Distribution (13 -20 years) 17

Table 3.4. : Adult Diagnosis Distribution (21 - 60 years) 17

Table 3.5. : Elderly Diagnosis Distribution (>61 years) 18

LIST OF FIGURES **PAGE**

Figure 1.1. : Sample delineated by gender and race 14

Figure 1.2. : Sample delineated by age and gender 14

CHAPTER ONE - INTRODUCTION

1.1. Background and Literature Review

The orbit is a compartment which is formed by four bony walls and contains the globe, extra ocular muscles and neuromuscular structures. It is directly related to the anterior and middle cranial fossa as well as the sinuses.[1] Orbital masses in this compartment can lead to sight and life threatening complications[1].

Orbital masses can be broadly classified as either neoplastic or non-neoplastic.[2] The neoplastic causes include vascular, mesenchymal, neural, lacrimal gland and metastatic tumors.[2-5] Secondary tumors which are due to direct spread to the orbit from adjacent structures can also cause neoplastic masses. Non-neoplastic causes are related to cysts, inflammation and vascular malformations.[2-5]

When diagnostic dilemmas with these orbital masses arise, orbital biopsy facilitates a definitive diagnosis versus the presumptive diagnosis obtained via clinical examination and neurological imaging alone. Orbital biopsy is thus the gold standard for tissue diagnosis in orbital masses. [6,7]

A study by Shields et al. reviewed 645 orbital biopsies conducted in Philadelphia in the United States.[8] Histology showed the majority of lesions to be cystic (30%) and of these, most were dermoid cysts. Lacrimal gland lesions were found in 11% of cases and more than half of these were due to chronic dacyroadenitis. Orbital lymphoma was detected in 5% of cases. Secondary orbital tumors were found in 11% of cases, mainly due to basal cell carcinoma of the eyelid. Breast carcinoma was the most frequent cause of metastatic orbital tumors.[8]

The same authors investigated the histology of orbital biopsies conducted in a paediatric population in a second review.[9] This population included 250 children under the age of 18 years. Orbital cysts comprised 52% of the lesions. Vascular

tumors comprised 6.8% and were mainly capillary haemangiomas, while rhabdomyosarcoma was present in 4% of cases. Secondary orbital tumors were present in 3.6% of cases and these were all from direct invasion of the optic nerve and orbit by retinoblastoma.[9]

A Swedish review of 300 orbital biopsy patients with space occupying orbital lesions revealed that lacrimal lesions comprised the largest group and in this group, dacyroadenitis was the most common cause.[6] This was followed by pleomorphic adenoma. Cavernous haemangiomas were found to be the most common vascular lesion. Solid tumors constituted 54% of cases, and over half of these were malignant. The primary malignancy was orbital lymphoma. Secondary tumors comprised 11.3% of malignant lesions and these were mainly conjunctival in origin (melanoma or squamous cell carcinoma).[6]

Simon et al. reported on a series of 369 cases of orbital masses in Los Angeles, United States. The majority of cases were inflammatory and vasculogenic, commonly cysts and cavernous haemangiomas. Malignant tumors comprised 19% of the total masses. These were mainly lacrimal gland tumors. In children, capillary haemangiomas were the most frequent orbital masses, followed by lymphangiomas.[10]

A review of 367 malignant orbital tumors in the Netherlands was conducted.[11] The most common cause was found to be lymphoma (67%), followed by rhabdomyosarcoma (12%) and lacrimal gland adenocarcinoma.[11]

Johansen et al. reported on orbital biopsies conducted in Denmark over a 33 year period. They reviewed 964 biopsies and found optic nerve lesions (32.3%) and secondary orbital tumors (20.9%) to be the two commonest groups. Their malignancy rate was 41.2%.[12]

Ting et al. audited 166 orbital biopsies conducted in London. Non-specific inflammatory disease and lymphoproliferative disorders were the two largest groups documented (38.3% and 24.7% respectively).[13]

A report on 119 orbital biopsies in children was done in India. Rhabdomyosarcomas were the most common (24%). This was followed by metastatic and secondary orbital tumors (17%). [14]

A study of sixty orbital tumors in children in Uganda revealed lymphoma to be the cause in the majority of cases (48%). Chloroma's due to acute myeloid leukaemia (AML) were noted in 13% of cases.[15]

The Human Science Research Council report on HIV in 2012 showed a steady increase in the overall prevalence of HIV in South Africa from 10.8% in 2008 to 12.2% in 2012.[16] In the 0-14 year age group the prevalence of HIV was 2.4 %. The 15-24 year group showed a prevalence of 7.1%. The highest HIV prevalence was in the 25- 49 year age group and was 25.2%. The over fifty years group had a prevalence of 7.6%.[16] It has previously been reported that HIV is associated with ocular tumors. Orbital lymphoma and Ocular Surface Squamous Neoplasia (OSSN) have been documented to occur in patients with HIV.[17,18] Secondary orbital tumors could result from direct spread of OSSN into the orbit.[17,18]

Literature regarding the causes of orbital masses varies according to location, population, hospital and speciality involved. The current data available has been derived from internationally conducted studies. A literature search found that no data regarding the South African population had been published. The prevalence of the Human Immunodeficiency Virus (HIV) in South Africa is high and on the rise.[16] HIV is known to be associated with specific orbital tumors such as lymphoma.[17]

With this in mind, a retrospective analysis of orbital biopsies, done at two tertiary hospitals in Johannesburg, South Africa was undertaken.

Table 1. Summary of Literatue				
Author	Year	Location	Population	Results
Seregard et al.[6]	1999	Sweden, Europe	n = 300 All ages	Lacrimal gland lesions in 17% Lymphoid lesions in 12% Cystic lesions in 11%
Shields et al.[8]	1984	Philadelphia, America	n = 354 Adults	Cystic lesions in 30% Lacrimal gland lesions in 11% Metastasic lesions in 11%
Shields et al.[9]	1986	Philadelphia, America	n = 250 Children	Cystic lesions in 52% Vascular lesions in 6.8% Rhabdomyosarcoma in 4%
Simon et al.[10]	2006	Los Angeles,America	n = 369 All ages	Inflammatory lesions in 22% Malignant tumors 19% Vascular lesions in 10%
Koopman et al.[11]	2011	Netherlands, Europe	n = 367 All ages	Lymphoma in 67% Rhabdomyosarcoma in 12%
Johansen et al.[12]	2000	Denmark, Europe	n = 965 All ages	Optic nerve lesions (32.3%) Secondary tumors (20.9%)
Ting et al.[13]	2015	London, United Kingdom	n = 166 All ages	Non-specific inflammatory disease (38.3%) Lymphoproliferative disease (24.7%)
Baja et al.[14]	2007	Delhi, India	n = 119 Children	Rhabdomyosarcoma (24%) Metastatic and secondary orbital tumors (17%)
Templeton[15]	1971	Uganda, Africa	n = 60 Children	Lymphoma in 48% Chloromas in 13%

1.2. Aim

To analyse orbital biopsies done at Chris Hani Baragwanath Academic Hospital (CHBAH) and Charlotte Maxeke Johannesburg Academic Hospital (CMJAH) over a 5 year period. The purpose of the analysis was to ascertain the histological diagnosis of the biopsies as well as associated demographic data.

1.3. Hypothesis

The spectrum of orbital masses in South Africa is different to those reported in other countries.

1.4. Objectives

The primary objective was to determine the histological diagnosis of orbital biopsies over a five year period. The secondary objective was to describe the patient demographics for this population in terms of age, sex and race.

CHAPTER TWO - MATERIALS AND METHODS

2.1. Study Design

This was a descriptive, retrospective record review.

2.2. Ethics

This protocol was approved by the University of the Witwatersrand Human Research Ethics Committee - clearance certificate no. M160212. (Appendix A.)
To maintain confidentiality each patient was allocated a study number in place of their name on the data capture form which was used for the study analysis. The data was password protected.

2.3. Sample Population

The sample population comprised all patients who underwent orbital biopsies at CHBAH and CMJAH during the period 1 January 2011 to 31 December 2015. This included all ages, genders and ethnic groups in this population. A total of 101 orbital biopsies were done for this period, histological data was recovered for 75 of these biopsies.

2.4. Inclusion Criteria

All patients regardless of sex, age or ethnic origin, who underwent orbital biopsies at SJEH and CMJAH between the period 1 January 2011 and 31 December 2015, whose records included histological data.

2.5. Exclusion Criteria

Any patient whose records did not contain histological diagnosis was excluded from the study.

2.6. Data Capture

Theatre registers were used to obtain details for patients who underwent orbital biopsies in the study period. These registers had manual entries of every patient undergoing a surgical procedure at the respective hospitals. Data for patients whose procedure included the term orbital biopsy was captured for the study. These patients' demographic data and hospital numbers were recorded on a spreadsheet. This was used to acquire histological data from the laboratory.

The National Health Laboratory Service (NHLS) was provided with a copy of the aforementioned spreadsheet. The patients' hospital number was used to access histology results. Once these results were provided by the NHLS, it was captured on a data capture sheet. (Appendix B.)

The information was also entered onto a spreadsheet for statistical analysis. (Appendix C.)

2.7. Statistical Analysis

The data was analysed with the objectives in mind.

The primary objective was to ascertain the histological diagnosis for the series. This was a categorical variable and expressed as frequencies and percentages.

The secondary objective was to describe the population demographics. Age, gender and ethnic origin were also categorical variables and were expressed as frequencies, percentages and medians.

CHAPTER THREE - RESULTS

The study period started in January 2011 and ended in December 2015. During this period 75 of a possible 101 patients met the inclusion criteria. The reason for exclusion in the remainder was a lack of histological data.

3.1. Histology Results

27 different diagnostic entities were documented. These were grouped into 9 major categories. In these categories, the overall majority lesion encountered was cystic lesions (17%), followed closely by lacrimal gland (16%) and vascular lesions (15%).

Table 2.1. Major Categories of Histological Results

	Frequency (n)	Percentage (%)
Cystic Lesions	13	17.3
Lacrimal Gland Lesions	12	16.0
Vascular Lesions	11	14.7
Other (breakdown specified later)	11	14.7
Secondary Orbital Tumors from Adjacent Structures	11	14.7
Inconclusive Specimens	5	6.7
Inflammatory Lesions	4	5.3
Lymphoid Tumors and Leukaemias	4	5.3
Metastatic Tumor to the Orbit	4	5.3
Total	75	100

*Percents are rounded.

Cystic lesions were the largest group, and accounted for 17% (n=13) of biopsy results. The most common cystic lesions were dermoid cysts (85%).

Table 2.2. Breakdown of Cystic Lesions			
	Frequency (n)	**Percentage of Category (%)**	**Percentage of Total (%)**
Dermoid Cyst	11	84.6	14.7
Eccrine Hydrocystoma	1	7.7	1.3
Epithelial Inclusion Cyst	1	7.7	1.3
Total	13	100	17.3

*Percents are rounded.

Lacrimal gland lesions comprised 16% (n=12). Pleomorphic adenoma accounted for 50 % of these diagnoses.

Table 2.3. Breakdown of Lacrimal Gland Lesions			
	Frequency (n)	**Percentage of Category (%)**	**Percentage of Total (%)**
Pleomorphic Adenoma	6	50	8
Dacyroadenitis	3	25	4
Sarcoidosis	1	8.3	1.3
Oncocytoma	1	8.3	1.3
Mucoepidermoid Carcinoma	1	8.3	1.3
Total	12	100	16

*Percents are rounded.

Vascular lesions comprised 15% (n=11) and included cavernous haemangiomas (54.5%) and lymphangiomas (45.5%).

Table 2.4. Breakdown of Vascular Lesions			
	Frequency (n)	**Percentage of Category (%)**	**Percentage of Total (%)**
Cavernous Haemangioma	6	54.5	8
Lymphangioma	5	45.5	6.7
Total	11	100	14.7

*Percents are rounded.

Secondary orbital tumors from adjacent structures made up 15% (n=11) of the diagnosis. These were all from carcinomatous spread. Conjunctival squamous cell carcinoma accounted for 73% of these secondary lesions.

Table 2.5. Breakdown of Secondary Orbital Tumors from Adjacent Structures			
	Frequency (n)	**Percentage of Category (%)**	**Percentage of Total (%)**
Conjunctival Squamous Cell Carcinoma	8	72.7	10.7
Recurrent Retinoblastoma	1	9.1	1.3
Ethmoid Sinus Squamous Cell Carcinoma	1	9.1	1.3
Eyelid Merkel Cell Carcinoma	1	9.1	1.3
Total	11	100	14.7

*Percents are rounded.

Inflammatory lesions accounted for 5% (n=4) of the sample and were due to Idiopathic Orbital Inflammatory Disease (IOID) in 3 of the 4 cases.

Table 2.6. Breakdown of Inflammatory Lesions			
	Frequency (n)	**Percentage of Category (%)**	**Percentage of Total (%)**
IOID	3	75	4
Inflammatory Myofibroblastic Tumor	1	25	1.3
Total	4	100	5.3

*Percents are rounded.

Metastatic tumors to the orbit were found in 5% (n=4) of cases. Breast carcinoma was found to be the primary site in 3 of the 4 cases.

Table 2.7. Breakdown of Metastatic Lesions			
	Frequency (n)	**Percentage of Category (%)**	**Percentage of Total (%)**
Breast Carcinoma	3	75	4
Gastrointestinal Adenocarinoma	1	25	1.3
Total	4	100	5.3

*Percents are rounded.

Lymphoid tumors and leukemias comprised 5% (n=4) of the lesions.

Table 2.8. Breakdown of Lymphoid Tumor and Leukaemia Lesions			
	Frequency (n)	**Percentage of Category (%)**	**Percentage of Total (%)**
Chloroma	2	50	2.65
B Cell Lymphoma	2	50	2.65
Total	4	100	5.3

*Percents are rounded.

The less frequent cases were arranged into a group headed “Other” and accounted for 15% (n=11) of the lesions encountered. These included three cases of benign fibroadipose tissue which were documented following socket biopsy after previous enucleation. Two cases each of rhabdomyosarcomas, meningiomas and neurofibrommas were documented. The rhabdomyosarcomas were embryonal in origin and both meningiomas were secondary tumors. One case each of a lipoma, and Juvenile Xanthogranuloma (JXG) were documented.

Table 2.9. Breakdown of Other Lesions			
	Frequency (n)	**Percentage of Category (%)**	**Percentage of Total (%)**
Benign Fibroadipose Tissue	3	27.2	4
Rhabdomyosarcoma	2	18.2	2.7
Meningioma	2	18.2	2.7
Neurofibroma	2	18.2	2.7
JXG	1	9.1	1.3
Lipoma	1	9.1	1.3
Total	11	100	14.7

*Percents are rounded.

Malignant lesions were found as the diagnosis in 23 cases (30.7%). Secondary tumors from adjacent orbital tissues were the largest contributor to malignant lesions with eight cases being secondary to conjunctival squamous cell carcinoma.

Table 2.10. Distribution of Malignant Lesions (n=23)			
		Frequency (n)	Percentage (%)
Secondary Orbital Tumors from Adjacent Structures (47.8%)	Conjunctival Squamous Cell Carcinoma	8	34.9
	Ethmoid Sinus Squamous Cell Carcinoma	1	4.3
	Merkel Cell Carcinoma	1	4.3
	Recurrent Retinoblastoma	1	4.3
Orbital Metastasis (17.4%)	Breast Carcinoma	3	13
	GIT adenocarcinoma	1	4.4
Lymphoid Tumors and Leukaemias (17.4%)	B Cell Lymphoma	2	8.7
	Chloromas	2	8.7
Lacrimal Gland Lesions (8.7%)	Mucoepidermoid Carcinoma	1	4.35
	Oncocytoma	1	4.35
Other (8.7%)	Rhabdomyosarcoma	2	8.7

*Percents are rounded.

3.2. Demographic Results

3.2.1 Race

The majority of patients were African (85%, n=64). This was followed by Whites, Coloureds and Indians (9%, 4%, and 1% respectively). The majority of males were found in the African population (83.3%, n=30), as were the majority of females (87.2%, n=34).

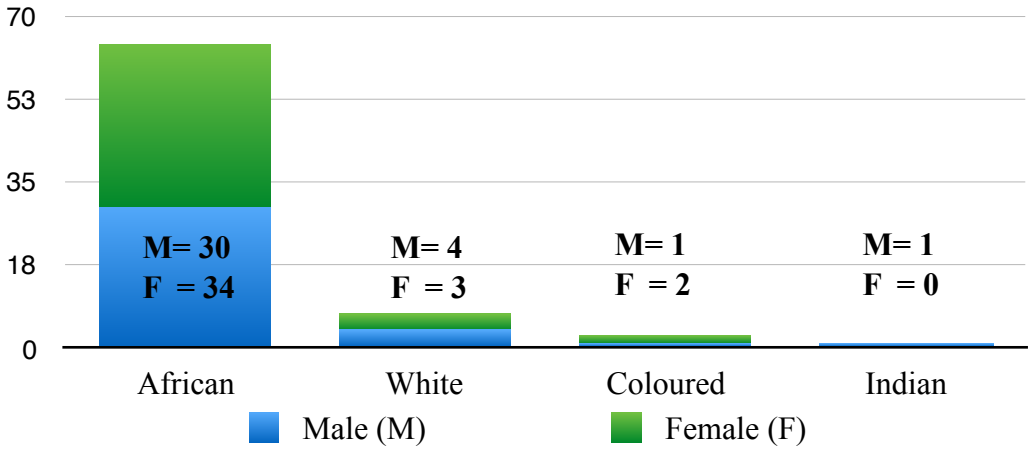

Figure **1.1 Sample delineated by gender and race (n = 75)**

3.2.2. Gender

Of the 75 patients sampled, 48% (n=36) were male and 52% (n=39) were female.

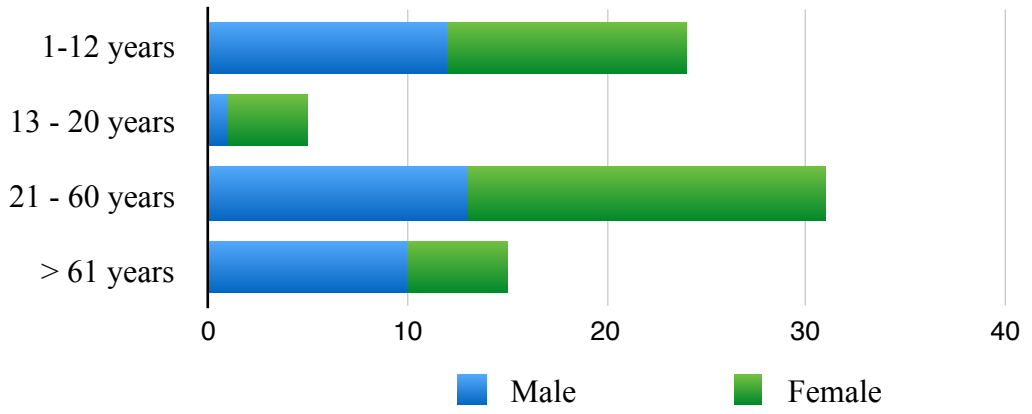

Figure 1.2. Sample delineated by age and gender

The most frequent histological diagnoses in the male group was cystic lesions (19.4%) and secondary orbital tumors from adjacent structures (19.4%). Lacrimal gland and vascular lesions dominated the female sub-sample (20.5% and 17.9% respectively).

Table 3.1. Diagnosis by Gender				
	Male		Female	
	Frequency (n)	Percentage (%)	Frequency (n)	Percentage (%)
Cystic Lesions	6	15,4	7	19.4
Lacrimal Gland Lesions	8	20.5	4	11.1
Vascular Lesions	7	17.9	4	11.1
Other	6	15.4	5	13.9
Secondary Orbital Tumors from Adjacent Structures	4	10.3	7	19.4
Inconclusive Specimens	3	7.7	2	5.6
Inflammatory Lesions	2	5.1	2	5.6
Lymphoid Tumors and Leukaemias	1	2.6	3	8.3
Metastatic Tumors to the Orbit	2	5.1	2	5.6
Total	39	100	36	100

*Percents are rounded.

3.2.3. Age

The ages in the study population ranged from 1 to 82 years. The mean was 34.4 years and the median 37 years. The most frequently cited age groups were the paediatric age group (1-12years) and the middle-aged group (41-60 years). These accounted for 32% and 25% of the study population respectively.

In the paediatric age group (1-12yrs), the most common lesions were cystic (37.5%), followed by vascular (16.6%).

Table 3.2. Paediatric Diagnosis Distribution (1-12 years)

	Frequency (n)	Percentage (%)
Cystic Lesions	9	37.5
Vascular Lesions	4	16.6
Other (Benign Fibroadipose Tissue)	3	12.5
Lymphoid Tumors and Leukaemias	2	8.3
Other (Rhabdomyosarcoma)	2	8.3
Other (Inconclusive Specimen)	1	4.2
Lacrimal Gland Lesions	1	4.2
Secondary Orbital Tumors from Adjacent Structures	1	4.2
Other (JXG)	1	4.2
Total	24	100

*Percents are rounded.

The most frequent diagnosis in young adults was vascular lesions (40%).

Table 3.3. Young Adult Diagnosis Distribution (13-20 years)		
	Frequency (n)	**Percentage (%)**
Vascular Lesions	2	40
Cystic Lesions	1	20
Inflammatory Lesions	1	20
Other (Meningioma)	1	20
Total	5	100

*Percents are rounded.

Secondary tumors predominated in the adult groups (23%). This was followed closely by lacrimal gland lesions (19%).

Table 3.4. Adult Diagnosis Distribution (21 - 60 years)		
	Frequency (n)	**Percentage (%)**
Secondary Orbital Tumors from Adjacent Structures	7	22.5
Lacrimal Gland Lesions	6	19.4
Vascular Lesions	4	12.9
Cystic Lesions	3	9.7
Inconclusive Specimen	3	9.7
Metastatic Tumors	3	9.7
Inflammatory Lesions	2	6.5
Lymphoid Tumors and Leukaemias	1	3.2
Other (Neurofibromma)	1	3.2
Other (Meningioma)	1	3.2
Total	31	100

*Percents are rounded.

In the elderly population (>61years) the majority of lesions were lacrimal gland lesions (33%), followed by secondary tumors (20%)

Table 3.5 Elderly Diagnosis Distribution (>61 years)		
	Frequency (n)	**Percentage (%)**
Lacrimal Gland Lesions	5	33.3
Secondary Orbital Tumors from Adjacent Structures	3	20.0
Vascular Lesions	1	6.7
Lymphoid Tumors and Leukaemias	1	6.7
Inconclusive Specimen	1	6.7
Metastatic Tumors	1	6.7
Inflammatory Lesions	1	6.7
Other (Lipoma)	1	6.7
Other (Schwanomma)	1	6.7
Total	15	100

*Percents are rounded.

CHAPTER FOUR - DISCUSSION

This study reported on the orbital biopsy results over a five-year period at two Johannesburg hospitals. All ages, genders and races were included. A total of 75 biopsies met the inclusion criteria and were analysed. The study population included ages from 1- 82years.

Seregard et al. reviewed a Swedish population group. They included both adults and children in their study. They found lacrimal gland lesions (17%), lymphoproliferative lesions (12%) and cystic lesions (11%) to be there top three diagnosis overall.[6] The current study found a similar percentage of lacrimal gland lesions (16%) and a higher incidence of cystic lesions (17%). The age distribution for Seregard's sample was not specified in their article. It is possible that a smaller paediatric population in their sample could have accounted for their lower percentage of cystic lesions.

Simon et al. reviewed orbital tumors in an American based study. Their study included paediatric patients and adults. These authors found the most common lesions to be inflammatory lesions (22%), malignant tumors (19%) and vascular lesions (10%).[10] This varies from our findings. The difference may be attributed to the fact that Simon et al. also included orbital tumors which were diagnosed on clinical grounds in their study.

Koopman et al. analysed malignant orbital tumors in the Netherlands. They found lymphoma (67%) and rhabdomyosarcoma(12%) to be the two largest groups.[11]
In our study the malignant lesions comprised 30.7% of our diagnosis. Of these secondary orbital tumors from conjunctival squamous cell carcinoma was the

largest (34.8%). This could reflect the burden of the HIV pandemic in South Africa as well as the delay in testing and treatment thereof.

Johansen et al found a malignancy rate higher than in our study (40.1% vs. 30.2%).[12] The paediatric population in their study was only 16% compared to the higher constitution in our group (32%).[12] This difference could have shifted their results in favour of diseases associated with adulthood and advanced age including metastatic disease.

Ting et al. found non-specific inflammatory disease and lymphoproliferative disorders to be their two largest groups(38.3% and 24.7% respectively).[13] Our study did not reveal similar findings. In fact inflammatory and lymphoproliferative diseases featured in our bottom three diagnosis.

Shields et al. reviewed biopsy results in a paediatric population in America. They found the commonest lesions to be cystic (52%), followed by vascular lesions and rhabdomyosarcoma (11% each).[9] The paediatric population in our study had similar lesions amongst its top two diagnoses. Cystic lesions were the majority (38%), followed by vascular lesions (17%). The current study showed a 15% frequency of benign fibroadipose tissue which was not seen in the Shields group. These biopsies were done for suspected tumor recurrences after enucleations. Rhabdomyosarcoma was the fourth most common diagnosis in this study (8%).

The Indian study group looked at paediatric orbital biopsies. They found that rhabdomyosarcomas (24%) were the most common lesion identified, followed by metastatic and secondary tumors (17%).[14] Our study differed and found cystic and vascular lesions to be the most common groups in its paediatric population.

It is important to note that the European, American, United Kingdom and Indian studies referenced above all have less African ancestry in their populations than

our study did. This racial difference could have contributed to the difference in disease entities seen in our study population.

In 1971, Templeton reported on orbital biopsies in Ugandan children. Templeton found Burkitt's lymphoma in almost half their sample (48%). Chloromas (13%) were the second most common diagnosis.[15] Chloromas were seen in only 8% of the paediatric population in our study. Burkitt's lymphoma is an aggressive B cell lymphoma. It is usually seen in Africa in the context of plasmodium falciparum malaria and Ebstein Barr Virus infections (EBV).[19] EBV and malaria are not endemic to Johannesburg, South Africa and this could account for the lack of Burkitt's lymphoma in our study. The differences in incidences could also be a reflection of the improved paediatric oncology services in the 21st century.

A total of five (6.7%) inconclusive specimens were documented. Since this study was conducted at a tertiary academic hospitals, it is possible that the biopsies were done by surgeons with different levels of experience. This could make inadequate biopsy technique a factor to consider. Biopsy of peri-lesional tissue may have occurred whilst trying to biopsy deep orbital tumors. Diffuse, ill defined orbital tumors may also have proven challenging to biopsy.

This study has limitations. Firstly, it was a retrospective clinical audit, which was dependant on staff to capture data. The theatre register is completed manually, as are the histology laboratory forms. Any incorrect entry would result in incomplete data for retrieval. Secondly, the two hospitals in the study were tertiary, academic referral centres. As such they may not reflect the general population since a larger percentage of patients at the facilities represent complicated orbital cases referred specifically for biopsy or for specialist assessment. Furthermore, CHBAH and CMJAH are tertiary referral hospitals and prevalence figures may be skewed due to the patient demographic.

HIV co - infection rates was not covered by this project due to the lack of availability of results on the data base. Had this been available, it would have been important in assessing the impact of HIV on the spectrum of orbital lesions encountered in the South African population.

CHAPTER FIVE - CONCLUSION

This series described 75 orbital biopsies from 27 different histological diagnoses. The major lesions found were cystic and lacrimal gland lesions. This differs from previously reported international data. The series also describes a larger proportion of secondary orbital tumors, mainly from conjunctival squamous cell carcinoma. This has not been highlighted in previous literature. This finding could be a reflection of the prevalence of HIV in South Africa as well as its association with this disease entity. To our knowledge, this is the first report on orbital biopsies in the South African setting. Prospective analyses would be useful in obtaining more data on the association of HIV co-infection in patients with orbital tumors.

APPENDICES

Appendix A. Ethics Clearance Certificate



RT4/4U Dr Natasha Naidu

HUMAN RESEARCH ETHICS COMMITTEE (MEDICAL)

CLEARANCE CERTIFICATE NO. M160212

NAME: (Principal Investigator)	Dr Natasha Naidu
DEPARTMENT:	Ophthalmology Chris Hani Baragwanath Academic Hospital Charlotte Maxeke Johannesburg Academic Hospital
PROJECT TITLE:	Five Year Review of Orbital Biopsies at Two Johannesburg Hospitals
DATE CONSIDERED:	26/02/2016
DECISION:	Approved unconditionally
CONDITIONS:	
SUPERVISOR:	
APPROVED BY:	Professor P Cleaton-Jones, Chairperson, HREC (Medical)
DATE OF APPROVAL:	10/02/2017

This clearance certificate is valid for 5 years from date of approval. Extension may be applied for.

DECLARATION OF INVESTIGATORS

To be completed in duplicate and **ONE COPY** returned to the Research Office Secretary n Room 301, Third Floor, Faculty of Health Sciences, Phillip Tobias Building, 29 Princess of Wales Terrace, Parktown, 2193, University of the Witwatersrand. I/we fully understand the conditions under which I am/we are authorized to carry out the above-mentioned research and I/we undertake to ensure compliance with these conditions. Should any departure be contemplated from the research protocol as approved, I/we undertake to resubmit the application to the Committee. **I agree to submit a yearly progress report.** The date for annual re-certification will be one year after the date of convened meeting where the study was initially reviewed. In this case the study was initially renewed in February and will therefore be due in the month of February each year. Unreported changes to the application may invalidate the clearance given by the HREC (Medical).

Principal Investigator Signature Date

PLEASE QUOTE THE PROTOCOL NUMBER IN ALL ENQUIRES

Appendix B. Data Capture Form

Study Number				
Age				
Sex	**M**	**F**		
Race	**B**	**W**	**C**	**I**
Histology Result				

Appendix C. Cases Summary

Stud.No.	Age	Sex	Race	Hospital	Histology Cat. 1	Histology Cat. 2
1	38	F	A	CHBAH	lacrimal gland lesions	dacyroadenitis
2	14	F	A	CHBAH	vascular lesions	cavernous haemangioma
3	23	F	A	CHBAH	vascular lesions	cavernous haemangioma
4	4	M	A	CHBAH	other	benign fibroadipose tissue
5	63	M	A	CHBAH	other	lipoma
6	45	F	A	CHBAH	secondary tumors	conjunctival SCC
7	71	M	I	CHBAH	metastatic tumors	breast carcinoma
8	2	F	C	CHBAH	vascular lesions	lymphangioma
9	23	M	W	CHBAH	other	neurofibromma
10	39	F	A	CHBAH	secondary tumors	conjunctival SCC
11	41	F	A	CHBAH	lymphoid tumors and leukaemias	B cell lymphoma
12	9	F	W	CHBAH	vascular lesions	lymphangioma
13	29	M	A	CHBAH	lacrimal gland lesions	oncocytoma
14	13	F	A	CHBAH	cystic lesions	dermoid cyst
15	48	F	A	CHBAH	vascular lesions	cavernous haemangioma
16	49	M	A	CHBAH	lacrimal gland lesions	pleomorphic adenoma
17	47	M	A	CHBAH	inflammatory lesions	inflammatory myofibroblastic tumor
18	43	F	A	CHBAH	lacrimal gland lesions	mucoepidermoid carcinoma
19	3	M	C	CHBAH	cystic lesions	dermoid cyst
20	28	F	A	CHBAH	secondary tumors	conjunctival SCC
21	78	F	A	CHBAH	lacrimal gland lesions	pleomorphic adenoma
22	3	F	A	CHBAH	other	benign fibroadipose tissue

Stud.No.	Age	Sex	Race	Hospital	Histology Cat. 1	Histology Cat. 2
23	5	F	A	CHBAH	other	embryonal rhabdomyosar-coma
24	9	F	A	CHBAH	lacrimal gland lesions	sarcoidosis
25	3	F	A	CHBAH	other	benign fibroadipose tissue
26	49	F	A	CHBAH	lacrimal gland lesions	dacyroadenitis
27	13	M	A	CHBAH	vascular lesions	cavernous haemangioma
28	59	F	A	CHBAH	inflammatory lesions	IOID
29	52	F	A	CHBAH	metastatic tumors	breast carcinoma
30	2	M	A	CHBAH	secondary tumors	recurrent retinoblastoma
31	75	M	A	CHBAH	lacrimal gland lesions	pleomorphic adenoma
32	37	M	A	CHBAH	cystic lesions	dermoid cyst
33	83	M	A	CHBAH	lacrimal gland lesions	dacyroadenitis
34	38	M	A	CHBAH	cystic lesions	eccrine hydrocystoma
35	6	M	A	CHBAH	vascular lesions	lymphangioma
36	47	M	A	CHBAH	secondary tumors	conjunctival SCC
37	16	F	A	CHBAH	inflammatory lesions	IOID
38	25	F	A	CHBAH	vascular lesions	lymphangioma
39	2	F	A	CHBAH	cystic lesions	dermoid cyst
40	70	M	A	CHBAH	vascular lesions	cavernous haemangioma
41	3	F	A	CHBAH	cystic lesions	dermoid cyst
42	2	M	A	CHBAH	lymphoid tumors and leukaemias	chloroma (AML)
43	1	M	A	CHBAH	cystic lesions	epithelial inclusion cyst
44	2	F	A	CHBAH	cystic lesions	dermoid cyst

Stud.No.	Age	Sex	Race	Hospital	Histology Cat. 1	Histology Cat. 2
45	46	F	A	CHBAH	inconclusive specimens	inconclusive
46	5	M	A	CHBAH	cystic lesions	dermoid cyst
47	50	F	A	CHBAH	other	secondary meningioma
48	33	M	A	CMJAH	cystic lesions	dermoid cyst
49	80	M	A	CMJAH	secondary tumors	conjunctival SCC
50	10	M	A	CMJAH	lymphoid tumors and leukaemias	chloroma (AML)
51	42	F	A	CMJAH	metastatic tumors	breast carcinoma
52	1	M	A	CMJAH	cystic lesions	dermoid cyst
53	4	F	A	CMJAH	vascular lesions	lymphangioma
54	56	M	A	CMJAH	secondary tumors	conjunctival SCC
55	3	F	A	CMJAH	cystic lesions	dermoid cyst
56	9	M	A	CMJAH	inconclusive specimens	inconclusive
57	3	M	A	CMJAH	other	juvenile xanthogranuloma
58	73	F	A	CMJAH	lacrimal gland lesions	pleomorphic adenoma
59	15	F	A	CMJAH	other	secondary meningioma
60	32	M	A	CMJAH	secondary tumors	conjunctival SCC
61	68	M	W	CMJAH	secondary tumors	ethmoid sinus squamous cell carcinoma
62	81	M	A	CMJAH	inconclusive specimens	inconclusive
63	81	M	A	CMJAH	inflammatory lesions	IOID
64	50	M	W	CMJAH	metastatic tumors	GIT adenocarcinoma
65	56	F	W	CMJAH	inconclusive specimens	inconclusive
66	55	M	A	CMJAH	secondary tumors	conjunctival SCC
67	69	F	A	CMJAH	secondary tumors	eyelid merkel cell carcinoma

Stud.No.	Age	Sex	Race	Hospital	Histology Cat. 1	Histology Cat. 2
68	62	F	A	CMJAH	lacrimal gland lesions	pleomorphic adenoma
69	57	F	C	CMJAH	lacrimal gland lesions	pleomorphic adenoma
70	67	F	W	CMJAH	other	neurofibromma
71	27	M	A	CMJAH	vascular lesions	cavernous haemangioma
72	45	F	A	CMJAH	inconclusive specimens	inconclusive
73	82	M	W	CMJAH	lymphoid tumors and leukaemias	B Cell lymphoma
74	2	F	A	CMJAH	cystic lesions	dermoid cyst
75	4	M	A	CMJAH	other	embryonal rhabdomyosar-coma

REFERENCES

1. Rene C. Update on orbital anatomy. *Eye* 2006;20:1119-1129.

2. Wolfgang EL. Orbital tumors. *Curr Opin Ophthalmol* 1992;3:342-346.

3. Goldberg S, Cantore WA. Tumors of the orbit. *Curr Opin Ophthalmol* 1997;8:51-56.

4. Kanksi JJ, Bowling B. Orbits. In: *Kanski's Clinical Ophthalmology - A Systematic Approach.* Elsvier;2016:77-117.

5. Holds JB, Chang WJ, Durairaj VD et al. Orbital neoplasms and malformations. In: *Basic Clinical Science Course, Section 7.* San Francisco; American Academy of Ophthalmology:2011:63-93.

6. Seregard S, Sahlin S. Panorama of orbital space-occupying lesions. The 24 year experience of a tertiary referral centre. *Acta Ophthalmol Scand* 1999;*77:91-98.*

7. Shields JA. Introduction to orbital diagnostic techniques. In: Shields JA. *Diagnosis and Management of Orbital Tumors.* Philadelphia;Saunders: 1989:36-46

8. Shields JA, Bakewell B, Augsberger J et al. Classification and incidence of space occupying lesions of the orbit. *Arch Ophthalmol* 1984;102:1606-1611.

9. Shields JA, Bakewell B, AugsbergerJ et al. Space occupying orbital masses in children. *Ophthalmology 1986;*93:379-384.

10. Simon GJB, Yoon MK, Jane A et al. Clinical manifestations of orbital lesions at the Jules Stein Eye Institute, 1999-2003. *Ophthalmic Surgery, Lasers and Imaging* 2006;37:25-32. *Acta Ophthalmol. Scand.* 2000;78:547-552.

11. Koopman JH, Van Heiden-van der Loo M, Van Dijk MR et al. Incidence of primary malignant orbital tumors in the Netherlands. *Eye* 2011;25:461-465.

12. Johansen S, Heegaard S, Bogeskov L et al. Orbital space-occupying lesions in Denmark 1974–1997.

13. Ting DS, Perez-Lopez M, Chew NJ, et al. A 10-year review of orbital biopsy: the Newcastle Eye Centre study. *Eye* 2015;29:1162-1166.

14. Bajaj MS, Pushker N, Chaturvedi A, et al. Orbital space-occupying lesions in Indian children. *J Paediatr Ophthalmol Strabismus* 2007;44:106-111.

15. Templeton AC. Orbital tumors in African children. Brit J Ophthalmol 1971;55:254-261.

16. Shisana O, Rehle T, Simbayi LC et al. HIV prevalence. In: *South African National HIV Prevalence, Incidence and Behaviour Survey 2012*. Cape Town:HSRC Press;2014:108-111.

17. Visser L. The eye and HIV/AIDS. *CME* 2007;25:493-495.

18. Cunningham ET, Margolis TP. Ocular manifestations of HIV infection. *The New Engl J Med* 1998;339:236-243.

19. Emmanuel B, Kawira E, Ogwang M et al. African Burkitt Lymphoma: Age-Specific Risk and Correlations with Malaria Biomarkers. *Am J Trop Med Hyg* 2011;84:397-401