

https://dspace.org/

Bacterial keratitis at St. John Eye Hospital with emphasis on causation and management

Cockinos, Chrissanthie

2014-03-14
http://hdl.handle.net10539/14160

Downloaded from a DSpace repository. https://dspace.org/

BACTERIAL KERATITIS AT ST JOHN EYE HOSPITAL WITH EMPHASIS ON CAUSATION AND MANAGEMENT

Chrissanthie Cockinos

A dissertation submitted to the Faculty of Health Sciences,
University of the Witwatersrand, Johannesburg
in partial fulfillment of the requirements for the degree
of Master of Medicine in Ophthalmology.

Johannesburg, 1998

Declaration

I declare that this dissertation is my own unaided work. It is being submitted for the degree of Master of Medicine in Ophthalmology at the University of the Witwatersrand, Johannesburg. It has not been submitted before for any degree or examination at this or any other university.



Chrissanthie Cockinos

26th day of June 1998

The work reported in this dissertation was carried out in the Department of Ophthalmology, St John Eye Hospital, Baragwanath, Johannesburg, South Africa.

The project was approved by the committee for research on human subjects, University of the Witwatersrand.

Dedication

This dissertation is dedicated to the people who work at St John Eye Hospital and all the patients.

Abstract

This dissertation describes the causation and management of bacterial keratitis at St John Eye Hospital.

Ninety three episodes of bacterial keratitis in 94 patients over a 12 month period from St John Eye Hospital were reviewed retrospectively.

Major predisposing factors were ocular trauma (25%), blepharitis (14%), malnutrition (5%), and alcoholism (4%).

Positive cultures of corneal ulcer samples were obtained in 63% of patients. The commonest organisms isolated were *Streptococcus pneumoniae* (21%), *Staphylococcus epidermidis* (21%), *Corynebacteriae* (13%), *Staphylococcus aureus* (11%) and *Pseudomonas aeruginosa* (11%). Of the single isolates, 79% were gram-positive bacteria and 21% were gram negative bacteria.

There were 16 children aged 16 years or younger in this study and corneal trauma was the major predisposing factor.

A high percentage (65%) of eyes had poor vision at the time of presentation (Counting Fingers or worse) and one third of patients presented to the out patient clinic after they had symptoms for more than one week. The occurrence of hypopyon ulcers was high (28%).

Therapy was mostly with intensive topical commercially available ciprofloxacin 0,3% ophthalmic solution either alone or in combination with topical chloramphenicol ointment or drops. There was a similar satisfactory response to treatment in both these groups of patients.

Papers arising from this dissertation:

Causation and Management of Microbial Keratitis at St John Eye Hospital.

1.O.S.S.A. Congress (Victoria Falls)

March 1998

2. Peninsula Eye Hospital (Cape Town)

May 1998

Acknowledgements

It is with deep appreciation that the following persons are acknowledged:

Professor N.H Welsh, my initial supervisor for suggesting the subject of this dissertation and his advice.

Dr Grant McLaren for his advice in preparation of the study.

Mrs Des Livingston for performing the statistical analysis of the data.

Dr Rodney Blumenfeld for helping to gather outstanding microbiology results.

Dr Andrew Jacovides for his constant support and encouragement and assistance with the computer.

Mrs Sharon Seftel for proof-reading the dissertation.

My colleagues at St John, in particular Dr Ismail Mayet and Dr Sarya Saks for their support and input.

Professor T.R. Carmichael, my supervisor and mentor, whose continual guidance, encouragement and advice were paramount to the completion of this dissertation.

Contents

	page
Declaration	2
Dedication	3
Abstract	4
Acknowledgements	5
List of Tables	7
List of Figures	8
Chapter 1 Introduction	9
1.1 Background	9
1.2 Aim of study	9
1.3 Pathogenesis of corneal ulcers	10
1.4 Bacterial pathogens	13
1.5 Current therapy for bacterial keratitis	15
1.6 Route of antibiotic administration	17
1.7 Initial antibiotic therapy	18
1.8 Adjunctive therapy	21
Chapter 2 Methods and materials	22
Chapter 3 Results	27
3.1 Demographic results	27
3.2 Predisposing factors	31
3.3 Microorganisms isolated from corneal ulcers	33
3.4 Bilateral corneal ulcers	35
3.5 Childhood microbial keratitis	35
3.6 Hypopyon and Keratitis	36
3.7 Treatment failures and complications	38
Chapter 4 Discussion	44
Chapter 5 Conclusions	51
Bibliography	54

List of Tables

Table	page
1.1 Normal conjunctival flora	10
1.2 Common compromising conditions associated with bacterial keratitis	12
1.3 Commonest bacterial pathogens cultured from corneal ulcers worldwide	14
1.4 Clinical differences between gram positive and gram negative ulcers	16
1.5 Adjunctive therapy	21
2.1 Ciprofloxacin dosing regimen	25
2.2 Antibiotic treatment regimens	26
3.1 Duration of symptoms prior to presentation	30
3.2 Predisposing Factors	32
3.3 Recorded visual acuity on presentation	32
3.4 Microorganisms isolated from corneal ulcers	34
3.5 Analysis of hypopyon ulcers	37
3.6 Predisposing factors in hypopyon ulcers	38
3.7 Analysis of treatment response to ciprofloxacin alone or in combination with chloramphenicol	39

List of Figures

Figure	page
1.1 Algorhythm for initial shotgun therapy of bacterial corneal ulcers	20
2.1 Culture technique	24
3.1 Age distribution of male patients presenting with corneal ulcers	28
3.2 Age distribution of female patients presenting with corneal ulcers	29

CHAPTER 1

1. INTRODUCTION

1.1 Background

Bacterial infection of the cornea is a threat to vision. Even less severe forms require urgent treatment, whereas the more severe forms constitute ocular emergencies.

Bacterial pathogens responsible for keratitis vary according to climate, region and nutritional status of patient populations[1].

Optimal empirical treatment of choice in a certain region should therefore be based on the expected isolates. Causative organisms are not static, thus frequent epidemiologic surveys are important[2].

1.2 Aim of Study

Objectives of this study were to :

1. Assess retrospectively demographic data related to corneal ulcers.
2. Assess the causative organisms of corneal ulceration at St John Eye Hospital (St John) but placing the emphasis on bacterial corneal ulcers.
3. Establish if a new commercially available topical antibiotic ciprofloxacin 0.3% solution was effective in the management of corneal ulcers in our patient population.

1.3 Pathogenesis

The conjunctivae and adnexae are usually sterile at birth and quickly become colonised by saprophytic bacteria [3]. Table 1.1 shows normal conjunctival flora.These organisms rarely infect the cornea.The normal tearfilm and intact epithelium enable the cornea to withstand invasion by most bacteria.

In the presence of the following factors, infective corneal ulceration may develop:

- Virulent microorganisms
- Local factors which provide a portal of entry for those organisms incapable of producing primary infection
- Compromised host health status which enables the organism to thrive.

Table 1.1
Normal conjunctival flora [3]

Staphylococcus epidermidis
S. aureus
Diphtheroids
**Streptococcus viridans*
**Streptococcus hemolyticus*
*Pneumococci

* Infrequent organisms found in conjunctival flora

If the host defences break down, virtually any bacterial strain, even those of low virulence can cause keratitis. In the compromised cornea, normal commensals become opportunistic pathogens and can cause keratitis for example *S.epidermidis* secondarily infecting a cornea with herpes simplex keratitis [4].

In some cases, virulent organisms like Neisseria gonorrhoea, may invade intact epithelium after adhering to the epithelial surface causing keratitis [5].

For most bacteria, a breach in the integrity of the epithelium is required.The glycocalyx of injured epithelium, or the glycocalyx of some bacteria such as *Pseudomonas* and gonococcus, play a role in initial adherence [6]. The adhesion is then followed by diffusion of toxins and bacterial byproducts.This facilitates the entry of bacteria into the stroma [7].

Once invasion has taken place, polymorphonuclear leukocytes enter the cornea in response to chemotactic factors (bacterial and endogenous), phagocytose bacteria, and with the help of lysosomes destroy the organism. The enzymes which destroy the bacteria may result in release of toxic metabolites which may cause corneal destruction [7].

Compromising conditions associated with an increased incidence of bacterial keratitis are listed in Table 1.2 .

TABLE 1.2
Common Compromising conditions associated with bacterial keratitis

ADULTS
Local Factors [8-11]
1) Eyelid and tear dysfunction
a) misdirected lashes (distichiasis)
b) tear insufficiency (Keratoconjunctivitis sicca)

2) External Factors
a) contact lens wear causing trauma
b) ocular trauma
c) Staphylococcal blepharitis

3) Corneal abnormalities
a) exposure keratopathy
b) bullous keratopathy
c) viral keratitis
d) corneal scarring / surgery
e) contact lens overuse or abuse causing corneal oedema
f) corneal dystrophies and degenerations eg lattice, climatic droplet keratopathy

General Factors [8-11]
1) Debilitating chronic disease
2) Malnutrition
3) Alcoholism
4) Advanced age
5) Diabetes mellitus
6) Drugs affecting the immune mechanism
7) AIDS

CHILDREN [10,12]

Local Factors
1) Ocular Trauma
2) Contact lens use
3) Exposure Keratopathy
4) Previous ocular surgery

General Factors
1) Severe systemic illness
2) Malignant disease of the orbit causing proptosis and exposure keratopathy

1.4 Bacterial Pathogens

There are relatively few species of bacteria which commonly cause keratitis, but a wide range of organisms has been reported [13].

Different bacterial pathogens have been reported from different climatic areas [2,9,10,11,13-17]. The prior state of the cornea, namely preexisting disease or injury, and severity of other comp mising factors, influences the spectrum of microorganisms that produce bacterial keratitis.

Knowledge of the commonest organisms in each region is of practical concern because of the difference in therapeutic approach. *Streptococcus pneumoniae* has been shown to be the commonest organism in many developing countries [2,9,11], and the use of gentamicin as first line therapy is not appropriate [2].
In many first world countries, *Pseudomonas aeruginosa* has been shown to be the most common isolate from corneal ulcers and in these cases aminoglycosides are indicated [8,14].
Table 1.3 shows the most common bacterial pathogens cultured from corneal ulcers in various studies worldwide.

TABLE 1.3

COMMONEST BACTERIAL PATHOGENS CULTURED FROM CORNEAL ULCERS WORLDWIDE

COUNTRY	INCIDENCE (%)	COUNTRY	INCIDENCE (%)
South Africa (9)		**India (17)**	
S. pneumoniae	42	*S. epidermidis*	26
P. aeruginosa	17	*S. aureus*	23
S. aureus	10	*P. aeruginosa*	7
S. epidermidis	8	*S. pneumoniae*	3
		coliforms	1
South Africa (11)			
S. epidermidis	32	**U.K. (16)**	
S. aureus	29	Mixed flora (diphtheroids,	
S. pneumoniae	16	*Neisseria, S. viridans*)	41
S. viridans	9	*S. aureus*	26
beta hemolytic streptococci	8	*S. epidermidis*	18
P. aeruginosa	6	*S. pneumoniae*	3
		Enterococci	3
South Africa (15)			
S. epidermidis	31	**U.S.A. (13)**	
S. pneumoniae	20	**New York**	
S. aureus	14	*S. aureus*	33
P. aeruginosa	10	*S. epidermidis*	16
S. viridans	3	*P. aeruginosa*	6
Nepal (2)		**Florida (14)**	
S. pneumoniae	31	*P. aeruginosa*	31
S. epidermidis	12	*S. aureus*	21
S. aureus	11	*S. epidermidis*	8
P. aeruginosa	11	*S. pneumoniae*	8

1.5 Current Therapy for Bacterial Keratitis

It is often helpful to try to predict clinically the most likely pathogen causing the ulcer. Infections caused by virulent organisms require a more vigilant approach by the physician, as they may deteriorate very rapidly .

A history of contact lens use often indicates a *Pseudomonas* infection [18]. *Moraxella* ulcers are frequently seen in malnourished, alcoholic patients [13,19-21].

Table 1.4 shows clinical differences between ulcers caused by Gram positive and Gram negative bacteria

Table 1.4

CLINICAL DIFFERENCES BETWEEN ULCERS CAUSED BY GRAM POSITIVE AND GRAM NEGATIVE BACTERIA [19]

ORGANISM	CLINICAL CHARACTERISTICS
Gram Positive Cocci *eg S. aureus , S. pneumoniae*	Round, oval, whitish-gray dry ulcers with distinct borders. Severe anterior chamber reaction.
Gram Negative Rods *eg P. aeruginosa*	More extensive, wet or soupy infiltrate that progresses quickly to involve the whole cornea. Typically a greenish yellow discharge sticking to the ulcer surface.

1.6 Routes of Antibiotic administration

There are three main routes of administration: systemic, subconjunctival and topical.

Systemic treatment

Systemic antibiotic administration has been shown to be less effective in treating bacterial keratitis, because a lower concentration of drug reaches the cornea than when given topically or subconjunctivally [22].

Systemic toxicity would be substantially higher with parenteral treatment than the other two methods. Systemic antibiotics may be indicated if there is scleral extension, if there is perforation of the cornea and always if the causative organism is *Neisseria gonorrhoea* [23].

Subconjunctival versus Topical therapy

Recent studies indicate that topical therapy compares favourably with subconjunctival therapy. This therapy also decreases the morbidity associated with subconjunctival injections [22-24].

Subconjunctival injections are painful, may cause perforation of the globe, and need to be administered by a physician or trained ophthalmic nurse. In the case of a child, it may be necessary to place the child under general anaesthesia to give the injection daily for four to five days with consequent risk. Ketamine may be a reasonable alternative to general anaesthesia, but also requires an anaesthetist [10].

Topical drops, on the other hand, may pose a compliance problem. It may be necessary to have the patient, their family or busy nursing staff instill the antibiotic as regularly as every 15-30 minutes during the first few days of treatment.

1.7 Initial Antibiotic Therapy

There are two schools of thought regarding the initial therapy of suspected bacterial corneal ulcers.

a)The specific therapy advocated by Jones [25], is based on the examination of corneal scrapings with culture identification of the offending organism on gram stain, and treatment of the keratitis with respect to the antibiotic sensitivity.

b)The "shotgun" approach of Baum [26], on the other hand, uses broad spectrum therapy based on the prevalence of organisms known to produce keratitis in a particular geographic area.

At St John, initial broad spectrum treatment with antibiotics was started after corneal scrapings were obtained. This treatment was not based on the gram stain, which may according to Baum, be misleading. Figure 1.1 shows an algorhythm for initial "shotgun" therapy of bacterial corneal ulcers which is based on Baum's approach.

In this retrospective review, antibiotic treatment included either topical ciprofloxacin (Ciloxan^{R}), with or without topical chloramphenicol in most cases.The treatment was modified only if the pathogen was reported to be resistant to the initial treatment, AND/OR if the ulcer continued to worsen. This approach was in keeping with Baum's broad spectrum therapy, rather than Jones's specific therapy.

Figure 1.1

Algorhythm for initial "shotgun" therapy of bacterial corneal ulcers (after Baum 1979) [25]

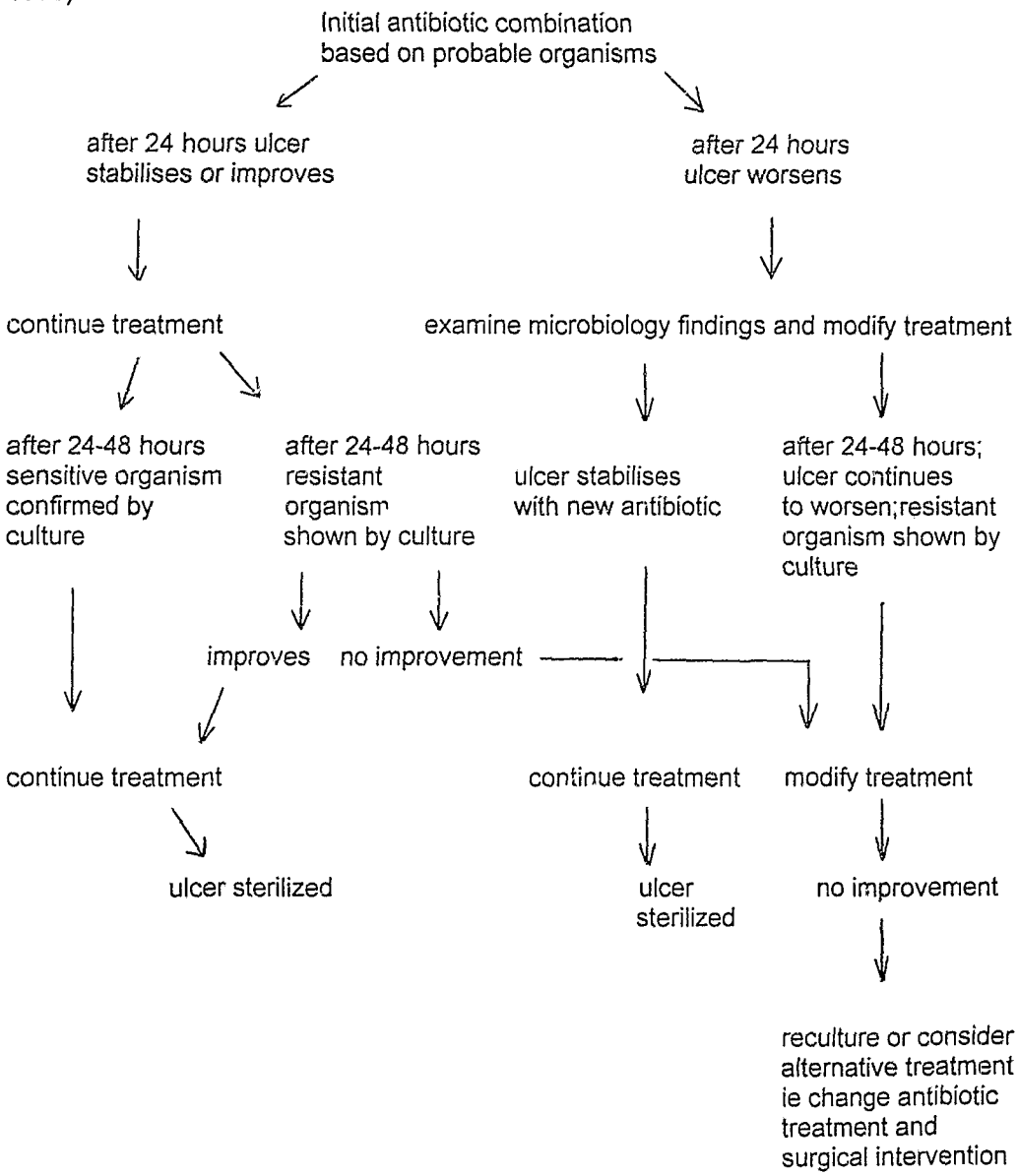

1.8 Adjunctive Therapy

Table 1.5 summarises the available forms of adjunctive treatment in bacterial keratitis.

Table 1.5 [27]

Cycloplegia	Routinely used, relieves ciliary spasm and discomfort and prevents posterior synechiae.
Debridement	Automatic on obtaining cultures. Removes debris and bacteria, improving antibiotic penetration.
Corticosteroids	Suppress host inflammatory response via inhibition of phospholipase A2. Used once keratitis responding well to antibiotics but best avoided or wait at least 3 days for favourable response to antibiotics in Pseudomonal ulcers.
Collagenase Inhibitors	Control inflammation and minimise corneal damage. Shown to reduce perforation for example Galardin.
Corneal Biopsy	Consider when cultures negative or ulcer fails to respond to initial therapy
Tissue Adhesives	eg cyanoacrylate in treatment and prevention of perforation and with descemetocoeles. Probably works via leukocyte inhibition and is bacteriostatic as well as mechanically sealing the perforation.
Conjunctival Flaps	When ulcers are unresponsive to medical therapy. Reserved for large, deep, slow-healing ulcers in a blind eye or descemetocoeles or peripheral thinned areas.
Penetrating Keratoplasty	When cornea has perforated or there is deep indolent ulceration in the acute stage [28].
Excimer Laser	Limited role; has been used to sterilize *Candida* keratitis experimentally after antifungals failed. Risk of perforation.

CHAPTER 2

2.1 METHODS AND MATERIALS

A retrospective study of 97 consecutive patients treated for suppurative keratitis was undertaken at St John over a one year period (1 June 1994 to 31 May 1995). There were 91 files available, and therefore the following analysis is of these 91 patients. The criterion for inclusion in the study was a diagnosis on discharge of bacterial or fungal keratitis based on clinical findings and response to treatment.

Conjunctival swabs and corneal scrapings were taken according to standard protocol [29]. Figure 2.1 shows the culture technique recommended to the physicians taking specimens from patients with corneal ulcers.

The patients were examined and managed by the ophthalmology registrars and consultants at St John who used the following antibiotic regimens:

1) Topical ciprofloxacin administered according to standard regimen shown in Table 2.1.
2) Topical ciprofloxacin and chloramphenicol drops 5mg/ml qid
3) Topical ciprofloxacin and chloramphenicol ointment nocte
4) Subconjunctival cefazolin 125mg and gentamicin 20mg
5) Various other combinations of topical antibiotics eg fortified cefazolin 33mg/ml, fortified gentamicin 14mg/ml and antiviral or antifungal drugs.

Table 2.2 shows the number of patients treated with the various antibiotic regimens.

Demographic analysis and information regarding age, sex, visual acuity, time lapsed before presentation to St John, predisposing factors, laboratory cultures, and type of medical treatment were recorded.

Therapy was mostly with intensive topical commercially available ciprofloxacin 0,3% ophthalmic solution, either alone or in combination with topical chloramphenicol ointment or drops. A retrospective analysis was made to see if the response to treatment was satisfactory in both these groups of patients.

Complications and treatment failures were recorded.

FIGURE 2.1

CULTURE TECHNIQUE [29]

	method	culture medium
conjunctival specimens	calgiswab moistened in serum broth	blood agar + serum broth
conjunctival specimens	calgiswab moistened in chopped meat broth	chopped meat broth
cornea anaesthetised		
multiple corneal scrapings	platinum spatula	blood agar
		chocolate agar
		thioglycolate broth
		brain heart infusion broth
		2 glass slides

Table 2.1
Ciprofloxacin Dosing Regimen [30]

Day 1 (Day patient was first seen)	a) 1-2 drops every 15 minutes for 6 hours, then b) 1-2 drops every 30 minutes for the remainder of the day
Day 2	1-2 drops every hour
Days 3 to 7	1-2 drops every 4 hours
After Day 7	At the discretion of the treating physician

TABLE 2.2

Antibiotic Treatment Regimens

Antibiotic	Number of patients
Ciprofloxacin only	24
Ciprofloxacin and chloramphenicol ointment nocte	37
Ciprofloxacin and chloramphenicol drops qid	10
Ciprofloxacin and subconjunctival gentamicin 20mg and subconjunctival cefazolin 125mg daily for 3-5 days	3
Ciprofloxacin and subconjunctival gentamicin 20mg and subconjunctival cefazolin 125mg for 3-5 days and chloramphenicol ointment nocte	4
Ciprofloxacin and subconjunctival gentamicin 20mg daily for 3-5 days and chloramphenicol ointment nocte	1
Subconjunctival cefazolin 125mg and subconjunctival gentamicin 20mg daily for 3-5 days	3
Combinations of other antibiotics/antivirals/antifungals	11
TOTAL EYES	93

Note:
In all cases patients received Atropine 1% cycloplegic drops at least once daily

CHAPTER 3

3.0 RESULTS

3.1 DEMOGRAPHIC ANALYSIS

There were 91 patients (93 eyes). Of these, 67 (73,6%) were male and 24 (26,4%) were female. Patients' ages ranged from 12 months to 88 years and the mean overall age was 42,4 years (Figures 3.1 and 3.2).

Seasonal occurrence rates varied from 55,9% in summer to 44,1% in winter. In South Africa the summer months are from October to March, and winter is from April to September.

Twenty six eyes (27,9%) presented with hypopyon and four of these (4,3%) had a blood stained hypopyon.

Forty nine left eyes and 44 right eyes had corneal ulcers. There were two patients with bilateral keratitis.

There were 16 children aged 16 years and under with bacterial keratitis. The mean age was 5,8 years.

The average duration of symptoms namely pain, decreased vision and ocular discharge prior to presentation, was calculated after excluding those patients who claimed a duration longer than two months and those of unspecified duration. The average duration of symptoms was found to be 10 days (Table 3.1). Thirty percent of patients had symptoms for more than one week before presentation.

FIGURE 3.1 AGE DISTRIBUTION OF MALE PATIENTS PRESENTING WITH CORNEAL ULCERS

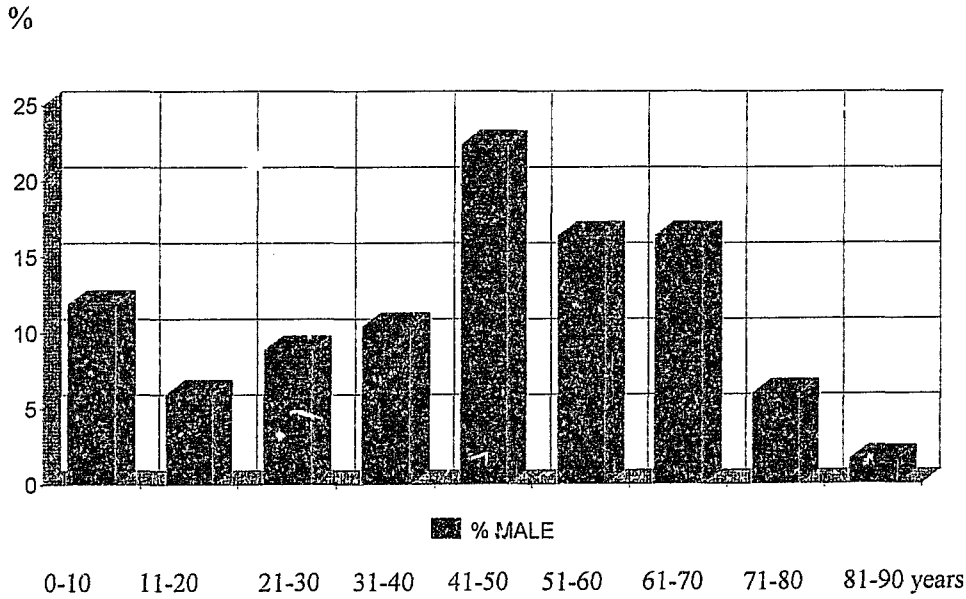

FIGURE 3.2 AGE DISTRIBUTION OF FEMALE PATIENTS PRESENTING WITH CORNEAL ULCERS

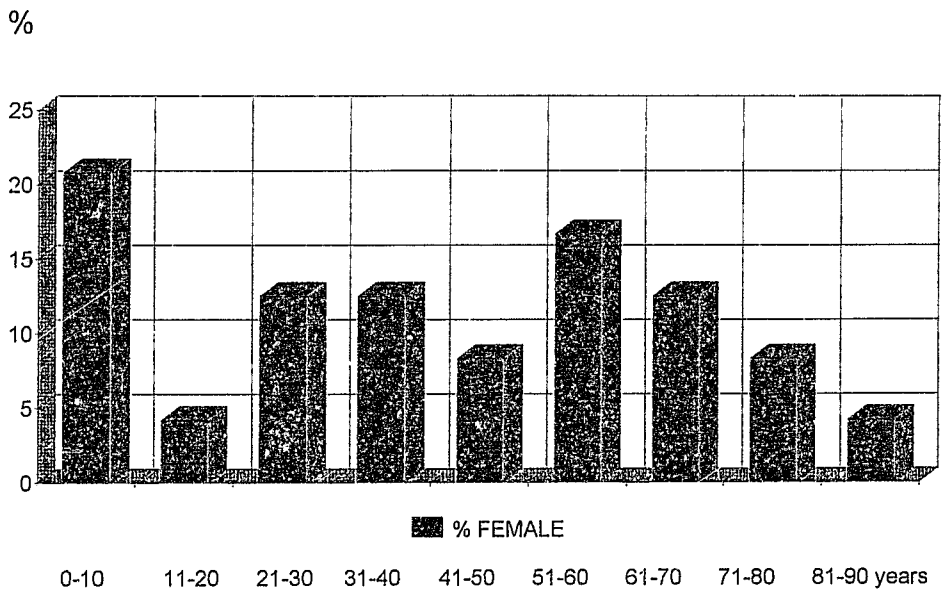

TABLE 3.1 Duration of symptoms prior to presentation

Duration of Illness	Number of eyes
1-7 days	47
8-14 days	12
15-29 days	4
1-2 months	4
>2 months	6
unspecified	20
Total number of eyes	93

3.2 PREDISPOSING FACTORS

Potential predisposing factors were recorded in 62 of 93 eyes (66,7%). Table 3.2 shows the local and systemic predisposing factors.

Local Factors

In twenty three corneal ulcers (25%) there was a history of ocular trauma and 14 eyes (15%) had blepharitis as a predisposing factor. Two eyes (3,3%) were noted to have climatic droplet keratopathy. One eye had a chronic lid deformity (ectropion) and two had previous corneal scarring.
Previous viral keratitis was recorded as a predisposing factor in four patients and Stevens Johnson syndrome in both eyes in one patient. Dry eye was recorded in three patients.

Systemic Factors

Four (4.3%) patients gave a history of alcoholism and one patient had diabetes mellitus. One patient had pulmonary tuberculosis, and five (5.4%) were clinically malnourished.

Contact lenses were not worn by any of the patients.
The visual acuity of the patients recorded at the first clinical examination is presented in Table 3.3 .

Fifty three eyes had a visual acuity of worse than 6/60 on presentation. This is 65% of eyes in which an initial visual acuity was measured.

TABLE 3.2
Predisposing factors

PREDISPOSING FACTOR	NUMBER OF PATIENTS
LOCAL	
Trauma	23
Blepharitis	14
Previous viral keratitis	4
Dry Eye	3
Corneal scarring	2
Stevens Johnson Syndrome	2
Climatic Droplet Keratopathy	2
Chronic Lid Deformities	1
SYSTEMIC	
Malnutrition	5
Alcoholism	4
Pulmonary Tuberculosis (active)	1
Diabetes Mellitus	1
	TOTAL 62 PATIENTS

Table 3.3 Recorded visual acuity on presentation

VA on presentation	Number of Eyes
No Light Perception	7
Light Perception	22
Hand Movements	12
Counting Fingers	12
6/60-6/36	10
6/24-6/18	8
6/12-6/5	10
Total eyes with recorded VA	81

3.3 Microorganisms isolated from corneal ulcers

Culture results were obtainable in 82 of the 93 eyes (88,2%), of which 52 (63.4%) had positive culture results. Of the negative culture results, five eyes (17%) had received prior treatment with antibiotics.

Of the 52 eyes with positive culture results:

- 38 eyes had a single bacterial isolate. Of these, 30 eyes (79%) had gram positive bacteria and 8 eyes (21%) had gram negative bacteria
- 12 eyes had mixed organisms
- Two eyes had only fungal isolates.

Table 3.4 shows the microorganisms and the number of cases isolated.

A total of 19 different strains of bacteria were isolated from the 82 eyes that were cultured.

The five most frequently isolated bacterial types were:

- *Streptococcus pneumoniae*
- *Staphylococcus epidermidis*
- *Pseudomonas aeruginosa*
- *Staphylococcus aureus*
- *Corynebacteriae.*

Table 3.4 Microorganisms isolated from corneal ulcers

Microorganisms	Number of eyes
Single Isolates	38
Gram Positive Bacteria	30
Streptococcus pneumoniae	8
Staphylococcus epidermidis	8
Corynebacteriae	5
Staphylococcus aureus	4
Streptococcus viridans	1
Staphylococcus spp	1
micrococcus spp	1
Streptococcus pyogenes	1
Enterococcus faecalis	1
Gram negative Bacteria	8
Pseudomonas aeruginosa	4
Neisseria gonorrhoea	1
Moraxella	1
Serratia marcescens	1
Proteus mirabilis	1
Mixed Isolates	12
Corynebacteriae + S.epidermidis	2
C.albicans - S.aureus	1
Corynebacteriae + S.aureus	1
S. epidermidis - N.gonorrhoea	1
S.epidermidis - S.pneumoniae	1
Corynebacteriae - S.aureus - Moraxella - S. milleri	1
P.aeruginosa - S.epidermidis	1
Haemophilus - S.epidermidis	1
Klebsiella - Enterobacter	1
Corynebacteriae - S.viridans	1
Acinetobacter + Corynebacteriae	1
FUNGI	2
Muco spp	1
Fusarium	1
Total Number of Eyes with Positive Cultures	52

3.4 Bilateral corneal ulcers

One patient had simultaneous bilateral corneal ulcers. She was 11 years old and had a history of Stevens Johnson syndrome and presented with bilateral staphylococcal blepharitis.

One female patient aged 59 years, presented with corneal ulcers in each eye on two separate occasions, 6 months apart. She had staphylococcal blepharitis and exposure keratopathy secondary to ectropion.

3.5 Childhood microbial keratitis

There were 16 children ranging in age from 12 months to 15 years (Mean 5,8 years). Seven children had a history of trauma. One child had bilateral disease, while another child had severe blepharitis.There was one child who went on to have a corneal graft. Predisposing factors were recorded in 62.5% of the children and trauma accounted for 60% of these.

Cultures were not obtained in 37.5% of the children because of the difficulty in obtaining cultures from uncooperative children. Of the eyes that had cultures taken, half showed a positive culture and half were negative.

Two *S. pneumoniae*, one *S. viridans*, one *S.aureus* and one *Fusarium* species were cultured.

Thirteen of the children were treated with ciprofloxacin with or without chloramphenicol, to which Natamycin was added when *Fusarium* was cultured in one eye. One child received subconjunctival injections of cefazolin and gentamicin.

One child developed a descemetocoele he went on to receive a corneal graft.

3.6 Hypopyon and keratitis

Twenty eight percent of the study patients had a hypopyon on admission. Calculation of the average duration of symptoms prior to presentation did not include a duration of longer than two months or symptoms of unspecified duration. In patients with hypopyon ulcers the average duration of symptoms prior to presentation was 8,9 days versus 10,6 days in the non-hypopyon ulcer patients.The quicker presentation of this group of patients may be related to the greater severity of disease compared with the group with non-hypopyon ulcers. This difference was however not statistically significant using the student t-test.

The presenting visual acuity was Counting Fingers or worse in 77% of the patients with hypopyon ulcers compared with 57% of patients with non-hypopyon ulcers.
The organisms cultured, visual acuity and duration of symptoms in patients with hypopyon are shown in Table 3.5.
Predisposing factors were recorded in 17 eyes. Trauma was the predisposing factor in four patients, alcoholism in three, previous viral keratitis in three, and malnutrition in two patients.
Table 3.6 shows the recorded predisposing factors in hypopyon ulcers.

Table 3.5
Analysis of Hypopyon Ulcers

	visual acuity on presentation	duration of symptoms (days)	organism cultured
1	HM	4	no growth
2	HM	10	*C. albicans* + *S. aureus*
3	6/36	5	no growth
4	NLP	-	no growth
5	LP	5	*P. aeruginosa*
6	HM	60	*P. aeruginosa*
7	LP	21	no growth
8	NLP	-	not done
9	NLP	4	*Corynebacteriae* + *S.epidermidis*
10	CF	-	lost
11	6/18	2	no growth
12	not recorded	1	*P. aeruginosa*
13	LP	-	no growth
14	LP	-	no growth
15	LP	7	*Corynebacteriae*
16	HM	7	*S. pneumoniae*
17	6/24	3	*S. pneumoniae*
18	LP	-	*Corynebacteriae* + *S.epidermidis*
19	NLP	5	*S. pneumoniae*
20	CF	-	*S. pneumoniae*
21	NLP	7	*S. marcescens*
22	NLP	7	not done
23	6/60	4	*S. viridans* + *Corynebacteriae*
24	HM	4	*S. aureus*
25	LP	-	no growth
26	6/18	5	no growth

- = unspecified or not recorded
Duration of >2 months was excluded from this analysis

TABLE 3.6

Predisposing factors in hypopyon ulcers	number of patients
TRAUMA	4
ALCOHOLISM	3
PREVIOUS VIRAL KERATITIS	3
MALNUTRITION	2
DIABETES	1
CLIMATIC DROPLET KERATOPATHY	1
EXPOSURE KERATOPATHY	1
BLEPHARITIS	1
PREVIOUS CORNEAL GRAFT	1

3.7 TREATMENT FAILURES AND COMPLICATIONS

Treatment failures were defined as:

- ulcers developing a complication such as descemetocoele or perforation that may or may not have required surgical intervention
- worsening of the ulcer on initial antibiotic treatment relative to day 1 (day of presentation and commencement of antibiotic treatment) requiring the modification of antibiotic treatment

Table 3.7 shows the treatment failures in the three groups of patients who received either topical ciprofloxacin alone, or in combination with topical chloramphenicol ointment or drops.

Table 3.7 Analysis of treatment response to ciprofloxacin alone and in combination with chloramphenicol

	number of patients	improved	failure
ciprofloxacin alone	24	22	2
ciprofloxacin plus chloramphenicol ointment at night	37	32	5
ciprofloxacin plus chloramphenicol drops four times daily	10	10	0

TREATMENT FAILURES

There were seven treatment failures (9,9 %) in 71 patients treated with ciprofloxacin with or without chloramphenicol drops or ointment.

Ciprofloxacin only

A 78 year old man presented with a long history of more than two months of pain and decreased vision. He had vision of counting fingers and a large hypopyon ulcer and descemetocoele in his only eye. *Staphylococcus aureus* and *Corynebacteriae* were cultured which were both sensitive to ciprofloxacin and chloramphenicol.
He was treated with ciprofloxacin but developed an impending perforation and the ulcer did not respond to treatment. He received an urgent corneal graft.

A 27 year old female presented with pain and decreased vision for one day after corneal trauma. *Pseudomonas* was cultured, which was sensitive to ciprofloxacin and gentamicin, but resistant to chloramphenicol. She was treated with ciprofloxacin, but showed no clinical improvement after three days. After this period, subconjunctival cefazolin and gentamicin were added. She developed a descemetocoele and was discharged five weeks later with a scarred vascularised cornea and anterior staphyloma.

Ciprofloxacin and chloramphenicol ointment at night

A 75 year old man presented with a one month history of pain and decreased vision. He had light perception vision on presentation. *Staphylococcus epidermidis* and *Neisseria gonorrhoea* were cultured which were both sensitive to ciprofloxacin and chloramphenicol *in vitro*. The patient was clinically malnourished. He did not respond to treatment for five days and Natamycin was added. One week later, the ulcer began to improve and the patient was discharged after two more weeks of treatment.

One 65 year old man presented with a three week history of pain and decreased vision. He had Light Perception vision and a large hypopyon ulcer. The underlying predisposing factor was proptosis with exposure keratopathy. There was no growth on culture, and he was treated with ciprofloxacin and chloramphenicol ointment to which he did not respond. One week later Natamycin was added still without improvement for one week. Thereafter Acyclovir ointment was added, and there was a slow improvement over a two week period. He was discharged from hospital with Light Perception vision. In retrospect this was probably a case of chronic herpetic keratouveitis but a diagnosis of bacterial keratitis was made.

A 58 year old man presented with a one week history of pain and decreased vision. He had already received antibiotic treatment before presenting to the hospital. The ulcer did not respond to ciprofloxacin and chloramphenicol for two days, and the patient then received subconjunctival cefazolin and gentamicin for five days plus pressure bandaging for an impending perforation. There was slow improvement over a further two week period, and he was discharged with Hand Movements vision.

A 37 year old female patient presented complaining of a painful eye over a one week period. She had a visual acuity of 6/12. A micrococcus species was cultured which was sensitive to ciprofloxacin and chloramphenicol *in vitro*. She was treated with ciprofloxacin and chloramphenicol ointment but deteriorated, thus subconjunctival cefazolin and gentamicin were added. She subsequently improved and was discharged with 6/36 vision.

A 67 year old man presented with a one week history of pain and decreased vision. He had Light Perception vision and a large hypopyon ulcer with a descemetocoele. The patient was clinically malnourished, and *Moraxella* was isolated from his cornea. He was given ciprofloxacin and chloramphenicol ointment to which the organism was sensitive *in vitro*, but the ulcer continued to deteriorate and perforated after one week. He developed endophthalmitis and had an evisceration.

Complications on other treatment regimens

Five patients developed complications on other treatment regimens. Three patients developed perforations and, of these, one went on to have an evisceration, and one had an anterior chamber reformation. One patient had a Gunderson conjunctival flap for a blind painful eye. One patient developed a descemetocoele and received an urgent corneal graft.

CHAPTER 4

4.0 DISCUSSION

In South Africa corneal trauma and ulceration is an important cause of blindness and occurs in all age groups. This pattern is consistent with studies from developing countries [2,9,10,11]. Microbial keratitis was previously found to be the cause of five percent of St John Eye Hospital admissions [11].

There was a marked male predominance (74%) and this is in accordance with other studies [9,13], and is partly related to the high occurrence of trauma as a predisposing factor.

In this study trauma is reported as being the most frequently found predisposing cause of corneal ulceration in children and adults.The incidence of trauma overall was 25%. In children, this incidence was 38%, and in adults 22%.This incidence in children was higher than previously reported at St John, as well as other developing countries and first world countries [2,9-12,31].

It has been suggested that microbial keratitis occurs less frequently in children of developed countries than in developing countries [10]. Childhood keratitis made up 17% of the cases seen during this study.This incidence is higher than in one study in the United Kingdom and another study in Los Angeles (11-12%) [10] but lower than previous reports from South Africa (18-22%) [9,10].

The occurrence of climatic droplet keratopathy (CDK) as a predisposing factor in this study was low (2,1%) compared with two previous studies from this hospital [9,11]. CDK is commonly seen in Southern Africa among elderly male individuals who have a history of chronic ultra violet light exposure [32,33]. In CDK, the degenerative corneal changes form superficial plaques that can ulcerate and become secondarily infected.

Absent in this group of patients were contact lens wearers. This is probably one of the reasons for the relatively low incidence of Pseudomonas keratitis. This is in keeping with the low incidence of Pseudomonas keratitis in developing countries [2,9,10].

In this study, 70% of patients came to the outpatient clinic for consultation after they had symptoms for up to one week, 18% came to the clinic after they had symptoms for 1-2 weeks, and 12% came after more than 2 weeks of symptoms.
As a result, a large proportion of the ulcers were advanced at presentation.
This is also shown by the high percentage (65%) of eyes with poor vision (Counting Fingers or worse) at presentation.

Microorganisms were isolated from 63% of the 82 corneas that were cultured.This rate of recovery compares favourably with other studies [1,9,11,15].

The negative culture results were partly due to prior treatment of the disease with topical antibiotics (17% of eyes). This percentage is probably underestimated since previous studies from this hospital have concurred that up to 50% of patients received suspected or definite antibiotic treatment prior to sampling [9,11].

Also the use of topical anaesthetic containing preservative (Novesin) prior to cultures may be another cause for the negative culture results [34]. An additional cause could be that different doctors may have performed different culture techniques despite trying to standardise the methods used.

The incidence of hypopyon occurring with bacterial keratitis in this study was high (28%), and compares with the 30% incidence of hypopyon ulcers found by Ormerod in California[10] and 43% of ulcers seen by Carmichael at St John Eye Hospital [31] . This incidence is probably due to the advanced nature of the keratitis on presentation and the virulence of the organisms. Patients with hypopyon ulcers presented earlier than those with non-hypopyon ulcers (the average duration of symptoms was 9 days compared with 11days) and this may be due to the greater severity of disease. The microorganisms cultured from ulcers presenting with hypopyon were different from non-hypopyon ulcers. Of the positive single isolates, *Streptococcus pneumoniae* occurred in 40%, and *Pseudomonas aeruginosa* occurred in 30% of hypopyon ulcers compared with 21% *S. pneumoniae* isolates and 10,5% *Pseudomonas* isolates in non-hypopyon ulcers. Hypopyon thus appeared to be associated with the more virulent organisms.

Of the seven treatment failures treated with ciprofloxacin alone or in combination with chloramphenicol, *Moraxella* was isolated from one patient who was malnourished. The poor outcome in *Moraxella* ulcers namely perforation and loss of the eye, is not an unexpected occurrence and has been reported previously [20,21].

In this study, of the patients with single isolates, the most common bacteria were *Streptococcus pneumoniae* (21%), *S.epidermidis* (21%), *Corynebacteriae* (13%), *S.aureus* (11%) and *Pseudomonas* (11%). Although *Corynebacteriae* have been considered non-pathogenic for the cornea, their presence in chronic bacterial keratitis that is otherwise sterile has led to the assumption that they are indolent pathogens [35].

In developed countries, the incidence of *S.pneumoniae* as a corneal pathogen has fallen to as low as 3% [14,16] whereas *Pseudomonas* has been the most frequently isolated organism in many series [14,36-38].

S.pneumonia has been found to be the commonest organism in patients with corneal ulceration by Pahalkar and associates in India, by Upadyay in Nepal and Carmichael and Ormerod in South Africa [2,9,11,31,39]. Since *S.pneumoniae* is generally not sensitive to aminoglycosides, the use of these drugs as first line antibiotics for treating corneal ulcers in an area where *S.pneumoniae* is the primary pathogen is not appropriate [2].
The three commonest isolates worldwide have consistently been found to be *S.epidermidis*, *S. pneumoniae* and *S.aureus* [2,9,11,14-17].

Fungal keratitis was uncommon in this study.Only two eyes had positive single fungal isolates, and one other was part of a mixed bacterial culture.This low incidence of fungal keratitis in South Africa has been previously reported by Carmichael [31] and Ormerod [11]. In Nepal where half of the 405 patients were farmers, 68 had fungal isolates so it can be deduced that climatic differences and work conditions may be responsible for the difference in incidence of fungal keratitis [2].

The pattern of childhood microbial keratitis was similar to that described by Ormerod in California [11] and previously at St John [10] with *S. pneumoniae, S. viridans, S. aureus* cultured, except that there was no *Pseudomonas* found at St John.

The management of childhood corneal ulceration is challenging. This is due to the difficulty in obtaining cultures as evidenced by more than one third of children in this study in whom corneal cultures were not obtained, as compared with 12% of adults. Some of the reasons the adults did not have cultures taken could be time constraints felt by the doctor or lack of availability of culture materials in the outpatient clinic at the time. In a study by Clinch in Louisiana [12], 24% of children's ulcers had a negative growth on culture, and he postulates the reason is that some of the referring practitioners did not adhere to the standard protocol of obtaining cultures before starting antibiotic therapy. This was based on the assumption that it would be difficult to obtain cultures from children. Management protocols should apply as strictly to children as to adults.

It has been suggested that topical antibiotic treatment in crying, uncooperative children often fails to reach the eye and that subconjunctival injections with topical supplementation may be the preferred method of treatment [11,40].

Only one child in this study developed a complication (a descemetocoele) and went on to receive a corneal graft, thus the rate of surgical intervention was low compared with other studies[10,12].

For the last two decades, one of the most widely accepted approaches to the management of corneal ulcers has been based on Baum's recommendation of topical administration of two fortified antibiotics, one effective against gram positive, and one against gram negative organisms [26].

Recent evidence has shown that commercially available topical ciprofloxacin 0.3% is as effective as conventional therapy for the treatment of most pathogens causing bacterial keratitis [41-44].

Some authorities augment topical treatment with subconjunctival injections [29] .The disadvantages of subconjunctival injections are that they are painful, they bear the risk of perforation of the globe, are more expensive and need to be administered by a physician or ophthalmic nurse. In the case of children, a general anaesthetic may be necessary for four to five days and this too has its risks.The use of fortified antibiotics also has limitations: possible contamination during preparation,incorrect dosage calculation, and washout of one of the agents on application of the second agent are among these [41].

In this study, 24 patients were treated with ciprofloxacin alone (22 successfully), 37 were treated with ciprofloxacin and chloramphenicol ointment at night (32 successfully) and 10 with ciprofloxacin and chloramphenicol drops four times daily (all successfully). The reason that chloramphenicol was added to ciprofloxacin in the initial phase of the study was that none of the fluoroquinolones is believed to be particularly active against streptococci (Minimum Inhibitory Concentration (MIC) 90 values are 4-8 times higher than for *Pseudomonas* and *S. epidermidis*) [45].

Clinical results in the United States of America have been encouraging, and suggest that ciprofloxacin can be used as an empirical monotherapy for suspected bacterial keratitis [41,44-46].

In this study, the treatment of bacterial keratitis using ciprofloxacin with or without chloramphenicol was successful. Three of the corneal ulcers with positive *S.pneumoniae* cultures (two being single isolates and one a mixed culture), were treated with ciprofloxacin alone, and all three responded well to treatment.

There were two *S. pneumoniae* single isolates treated with ciprofloxacin and chloramphenicol ointment at night, and both responded well to treatment. It is unlikely that the ointment form of chloramphenicol applied once daily had any significant impact on the eradication of infection.

Comparison of the three groups of patients, namely those treated with ciprofloxacin alone, and those treated with ciprofloxacin with chloramphenicol ointment or drops showed no statistically significant difference in successful outcome using the chi square test.

CHAPTER 5

5.0 CONCLUSIONS

This study confirms that corneal ulceration is an important cause of visual loss at St John Eye Hospital in Soweto.

Major local predisposing factors were ocular trauma (25%) and blepharitis (14%). The occurrence of trauma in children was 38% and this incidence was higher than previously reported from this hospital, and higher than reports from developed countries [2,9-12,31].

Important general predisposing factors were malnutrition (5%) and alcoholism (4%). The marked male predominance (77%) has previously been reported [9,10].

Positive cultures of corneal ulcer samples were obtained in 63% of patients. The commonest isolates were *Streptococcus pneumoniae* (21%), *Staphylococcus epidermidis* (21%), *Corynebacteriae* (13%), *Staphylococcus aureus* (11%) and *Pseudomonas aeruginosa* (11%). *S. pneumoniae* was the most frequently isolated organism by Carmichael at St John previously [9] and *S. epidermidis* was found by Ormerod to be most frequent [11]. The occurrence of fungal isolates was low (only two patients) in keeping with previous studies from St John [9,10]. Thus, the spectrum of frequent isolates in our area does not appear to have changed over the past two decades.

Of the single bacterial isolates, 79% were gram positive organisms and 21% were gram negative.

More than one third of the corneal ulcers showed no growth, and this was partly attributed to pretreatment with antibiotics.

Hypopyons were present in 28% of ulcers and these patients were found to present earlier (9 days) than non-hypopyon ulcers (11days). This difference was not found to be statistically significant. The incidence of *S. pneumoniae* and *Pseudomonas aeruginosa* was higher than in the non-hypopyon ulcer group. Presenting visual acuity was also worse in the hypopyon ulcer patients and this can probably be attributed to the greater severity of disease.

More than one third of children did not have cultures taken. The reason for this was probably the assumption that crying, uncooperative children are difficult to culture. Management protocols should apply as strictly to children as adults, and it is recommended that children are sedated where necessary [12].

Up until the time that this study began, the standard method of treating bacterial keratitis at St John was according to Baum's [26] broad spectrum "shotgun" therapy using two antibiotics, one effective against gram positive and one effective against gram negative organisms. There was initial reluctance to use ciprofloxacin topical commercially available drops as monotherapy in our third world environment where *S. pneumoniae* has been the most common causative organism.

Patients treated with ciprofloxacin alone, including those with *S. pneumoniae* ulcers, showed a similar successful outcome to the treatment as did the groups with chloramphenicol combined with ciprofloxacin. This successful outcome is probably due to the very high corneal penetration and concentration of the ciprofloxacin which offsets the higher MIC 90 values for streptococci [45].

It can be concluded from this study that ciprofloxacin topical 0,3% commercially available ophthalmic solution was effective in the management of bacterial keratitis as monotherapy in our developing country with its spectrum of microorganisms.
It is clear that this antibiotic is close to being ideal from an economic point of view and that of the physician and patient.

Bibliography

1. Limberg MB. A review of bacterial keratitis and bacterial conjunctivitis. *Am J Ophthalmol* 1991; **112**:2S-9S

2. Upadhyay MP, Karmacharya PCD, Koirala S, Tuladhar NR, Bryan LE, Smolin G, Whitcher JP. Epidemiological characteristics, predisposing factors and etiologic diagnosis of corneal ulceration in Nepal. *Am J Ophthalmol* 1991; **111**:92-9

3. Locatcher-Khorazo D, Seegal BC. *Microbiology of the eye*. St Louis: Mosby, 1972

4. Arffa RC. Infectious ulcerative keratitis. In *Grayson's Diseases of the Cornea*, 3rd ed. pp163-98. St Louis, CV Mosby 1991

5. Reed WP, Williams RC. Bacterial adherence: first step in the pathogenesis of certain infections. *J Chron Dis* 1978; **31**:67-72

6. Ramphal R, McNiece MT, Polack FM. Adherence of *Pseudomonas aeruginosa* to the injured cornea: A step in the pathogenesis of corneal infections. *Ann Ophthalmol* 1981; **13**:421-5

7. Hyndiuk RA. Experimental *Pseudomonas* keratitis - comparative therapy trials. *Trans Am Ophthalmol Soc* 1981; **79**:540-624

8. Musch DC, Sugar A, Meyer RF. Demographic and predisposing factors in corneal ulceration. *Arch Ophthalmol* 1983; **101**:1545-8

9. Carmichael TR, Wolpert M, Koornhof HJ. Corneal ulceration at an urban African hospital. *Br J Ophthalmol* 1985; **69**:920-6

10. Ormerod LD, Murphree AL, Gomez DS, et al. Microbial keratitis in children. *Ophthalmology* 1986; **93**:449-55

11. Ormerod LD: Causation and management of microbial keratitis in subtropical Africa. *Ophthalmology* 1987; **94**:1662-8

12. Clinch TE, Palmon FE, Robinson MJ, Cohen EJ, Barron BA, Liabson PR. Microbial keratitis in children. *Am J Ophthalmol* 1994; **117**:65-71

13. Asbell P, Stenson S. Ulcerative keratitis. Survey of 30 years' laboratory experience. *Arch Ophthalmol* 1982; **100**:77-80

14. Liesegang TJ, Forster RK. Spectrum of microbial keratitis in South Florida *Am J Ophthalmol* 1980 ; **90**:38-47

15. Maske R, Hill JC, Oliver SP . Management of bacterial corneal ulcers. *Br J Ophthalmol* 1986; **70**:199-201

16. Seal DV, Barrett SP, McGill JI. Etiology and treatment of acute bacterial infection of the external eye. *Br J Ophthalmol* 1982; **66**:357-60

17. Mahajan VM. Acute bacterial infections of the eye: their etiology and treatment. *Br J Ophthalmol* 1983; **67**:191-4

18. Wilson LA, Schlitzer RL, Ahern DG: *Pseudomonas* corneal ulcers associated with soft contact lens wear. *Am J Ophthalmol* 1981: **92**:546-54

19. Abbott RL, Kremer PA, Abrams MA. Bacterial Corneal Ulcers. In Duane TD (ed): Clinical Ophthalmology, vol 4, chap 18, Hagerstown, Harper and Row, 1997

20. Stern GA. *Moraxella* corneal ulcers: poor response to medical treatment. *Ann Ophthalmol* 1982; **14**:295-8

21. Marioneaux SJ, Cohen EJ, Arentsen JJ, Liabson PR. *Moraxella* keratitis. *Cornea* 1991; **10**:21-4

22. Davis SD, Sarff LD, Hyndiuk RA. Comparison of therapeutic routes in experimental *Pseudomonas* keratitis. *Am J Ophthalmol* 1979; **87**:710-14

23. Baum J. Treatment of bacterial ulcers of the cornea in the rabbitt: A comparison of administration by eye drops and subconjunctival injections. *Trans Am Ophth Soc* .1982; **vol** LXXX; 369-90

24. Leibowitz HM, Ryan WJ, Kupferman A. Route of antibiotic administration in bacterial keratitis. *Arch Ophthalmol* 1981; **99**:1420-3

25. Jones DB. Initial therapy of suspected microbial corneal ulcers. Specific antibiotic therapy based on corneal smears. *Surv Ophthalmol* 1979; **24**:105-16

26. Baum JL: Initial therapy of suspected microbial corneal ulcers. Broad antibiotic therapy based on prevalence of organisms. *Surv Ophthalmol* 1979; **24**:97-105

27. Pineda R, Dohlman CH. Adjunctive therapy and surgical considerations in the management of bacterial ulcerative keratitis. *Int Ophthalmol Clin* 1996; **Summer**: 37-47

28. Hill JC. Use of penetrating keratoplasty in acute bacterial keratitis. *Br J Ophthalmol* 1986; **70** :502-6

29. Jones DB. Early diagnosis and therapy of bacterial corneal ulcers. *Int Ophthalmol Clin* 1973; **13**:1-29

30. Alcon Laboratories, Inc. Ciprofloxacin hydrochloride 0.3% solution- new drug application no. 19-1992. Washington DC: Food and Drug Administration 1990

31. Carmichael TR. Ulcerative keratitis in the South African black with particular emphasis on the management of suppurative keratitis (Thesis). University of the Witwatersrand, 1991

32. Hill JC. The prevalence of corneal disease in the coloured community of a Karoo town. *S Afr Med J* 1985; **67**:723-7

33. Hill JC, Maske R, van der Walt S, Coetzer P. Corneal disease in rural Transkei. *S Afr Med J* 1989; **75** :469-72

34. Badenoch PR, Coster DJ. Antimicrobial activity of topical anaesthetic preparations. *Br J Ophthalmol* 1982; **66**:364-7

35. Rubinfeld RS, Cohen EJ, Arentsen JJ, Liabson PR. Diphtheroids as ocular pathogens. *Am J Ophthalmol* 1989; **108**:251-4

36.Cohen EJ, Fulton JC, Hoffman CJ, Rapuano CJ, Laibson PR. Trends in contact lens-associated corneal ulcers. *Cornea* 1996; **15**:566-70

37. Tan DT, Lee CP, Lim AS. Corneal ulcers in two institutions in Singapore: analysis of causative factors, organisms and antibiotic resistance. *Ann Acad Med Singapore* 1995; **24**:823-9

38. Chatterjee A, Kwartz J, Ridgway AE, Storey JK. Disposable soft contact lens ulcers: a study of 43 cases seen at Manchester Royal Eye Hospital. *Cornea* 1995;**14**:138-41

39. Pahalkar S, Thomas A, Alexander TA and Koshi G: Bacterial and mycotic agents of corneal ulcers in Velore. *Indian J Ophthalmol* 1985; **3**:289-92

40. Baum J, Barza M. Topical versus subconjunctival treatment of bacterial corneal ulcers. *Ophthalmology* 1983; **90**:162-8

41. Liebowitz HM. Clinical evaluation of ciprofloxacin 0.3% ophthalmic solution for treatment of bacterial keratitis. *Am J Ophthalmol* 1991;**112**:34-47

42. Callegan MC, Engel LS, Hill JM, O' Callaghan. Ciprofloxacin versus tobramycin for the treatment of *Staphylococcal* keratitis. *Invest Ophthalmol Vis Sci* 1994; **35**:1033-7

43. Guzek JP, Chacko D, Kettering JD, Wessels IF, Aprecio RM. Comparison of topical ciprofloxacin to conventional antibiotic therapy in the treatment of experimental *Pseudomonas aeruginosa* keratitis. *Cornea* 1994;**13**:500-4

44. Hyndiuk RA, Eiferman RA, et al. Comparison of ciprofloxacin ophthalmic solution 0.3% to fortified tobramycin-cefazolin in treating bacterial corneal ulcers. *Ophthalmology* 1996; **103**:1854-63

45. Diamond JP, White L, Leeming JP, Hoh HB, Easty DL. Topical 0.3% ciprofloxacin, norfloxacin and ofloxacin in treatment of bacterial keratitis: a new method for comparative evaluation of ocular drug penetration. *Br J Ophthalmol* 1995; **79**:606-9

46. Knauf HP, Silvany R, Southern PM, Risser RC, Wison SE. Susceptibility of corneal and conjunctival pathogens to ciprofloxacin. *Cornea* 1996, **15**:66-71

Author Cockinos C
Name of thesis Bacterial Keratitis At St John Eye Hospital With Emphasis On Causation And Management Cockinos C 1998

PUBLISHER:
University of the Witwatersrand, Johannesburg
©2013

LEGAL NOTICES:

Copyright Notice: All materials on the University of the Witwatersrand, Johannesburg Library website are protected by South African copyright law and may not be distributed, transmitted, displayed, or otherwise published in any format, without the prior written permission of the copyright owner.

Disclaimer and Terms of Use: Provided that you maintain all copyright and other notices contained therein, you may download material (one machine readable copy and one print copy per page) for your personal and/or educational non-commercial use only.

The University of the Witwatersrand, Johannesburg, is not responsible for any errors or omissions and excludes any and all liability for any errors in or omissions from the information on the Library website.