

https://dspace.org/

Subtypes of Endocervical Carcinoma: A Retrospective, Observational Study at Charlotte Maxeke Johannesburg Academic Hospital (2017–2019)

Bulane, Seipati

2024
University of the Witwatersrand, Johannesburg
https://hdl.handle.net/10539/46698
Bulane, Seipati. (2024). Subtypes of Endocervical Carcinoma: A Retrospective, Observational Study at Charlotte Maxeke Johannesburg Academic Hospital (2017–2019) [Master`s dissertation, University of the Witwatersrand, Johannesburg]. WIReDSpace. https://hdl.handle.net/10539/46698

Downloaded from a DSpace repository. https://dspace.org/

SUBTYPES OF ENDOCERVICAL CARCINOMA: A RETROSPECTIVE, OBSERVATIONAL STUDY AT CHARLOTTE MAXEKE JOHANNESBURG ACADEMIC HOSPITAL

(2017-2019)

SEIPATI BULANE

STUDENT NUMBER: 0700457H

SUPERVISOR: Prof. R. Wadee

A research report submitted to the Faculty of Medicine, University of the Witwatersrand, in partial fulfilment for the Degree of Master of Medicine (MMed Anatomical Pathology).



DECLARATION

I, Seipati Bulane (student number 0700457H), declare that this research report is my work. It is being submitted in fulfilment for the Degree of Master of Medicine (MMed Anatomical Pathology) at the University of the Witwatersrand. It has not been submitted for any degree or examination at this or other university.



30/08/2024

DEDICATION

I dedicate this MMed research report to my loving husband, Tshepo Morapeli, for his unwavering support, my precious daughter, Okhanya Mpho-Entle Morapeli and my dear parents for their encouragement and prayers.

ACKNOWLEDGEMENTS

I would like to thank the following people who played a role in this research project.

My supervisor, Prof. R. Wadee, for the conception of the topic and dedicated support throughout this process.

Ms. Fadila Ebrahim and Mr. Abel Ndlovu for assisting with sourcing patient pathology reports and slides.

ABSTRACT

Background:

The second most common cancer among women, especially in developing countries, is cervical cancer. Though less frequent than cervical squamous cell carcinoma (SCC), endocervical adenocarcinoma (ECA) is becoming more common worldwide, especially in young women. The decline in SCC is attributed to effective screening initiatives.

Objectives:

We aimed to assess the prevalence of ECA and its subtypes and to describe the clinicopathological characteristics of patients with these tumours at a tertiary South African institute between 2017-2019.

Methods:

This was a cross-sectional, descriptive study on 156 ECA patients. Following ethical clearance, demographic data, clinical information, and disease characteristics were obtained from departmental histopathological reports. Descriptive statistics were used to calculate the prevalence of ECA. We interrogated the association between age, Papanicolaou (Pap) smear results, Human Papillomavirus (HPV) status, and Human immunodeficiency virus (HIV) status with ECA.

Results:

The prevalence of ECA in all malignant cervix carcinoma cases was 6.8% and was more common in younger women. HPV-associated subtypes were the most common variants. The usual type of ECA accounted for 24.4% of cases. HIV status was documented in 64.0% of cases, of which 34.0% were positive. There were no statistically significant associations between ECA subtype and HIV status (p=0.81) or between ECA subtype and Pap smear results.

Conclusion:

The prevalence of ECA in South Africa is lower compared to Western countries, which may be due to different HPV subtypes or alternate risk factors to those in developed countries HPV prevails as a cause of endocervical carcinoma. HPV morphologic hallmarks serve as a practical guide in classifying ECAs according to their HPV status.

TABLE OF CONTENTS

Declaration

Dedication……iii

Acknowledgements……iv

Abstract……...v

Table of contents……vi-vii

List of abbreviations……...viii

CHAPTER 1: INTRODUCTION OF THE STUDY……1

1.1 Significance of the study 1

1.2 Aims……2

1.3 Objectives……2

CHAPTER 2: LITERATURE REVIEW……3

2.1 Anatomy of the cervix……3

2.2 Cervical cancer: Introduction……..3

2.3 Cervical cancer: Epidemiology……...4

2.4 Cervical cancer: Aetiology……5

2.5 Cervical cancer: Screening……6

2.6 Presentation, diagnosis, and spread……6

2.7 Cervical cancer: Morphological subtypes……..7

2.7.1 Endocervical Adenocarcinoma……7

2.7.1.1 HPV-associated subtypes……..8

2.7.1.2 HPV-independent subtypes……..10

2.7.2 Other subtypes……12

2.8 Cervical cancer: Staging……13

2.9 Treatment and survival……...13

3.0 References……..15

CHAPTER 3: SUBMISSIBLE JOURNAL ARTICLE……..22

3.1 Abstract……..24

3.2 Manuscript……25

3.2 .1 Introduction……...25

3.2.2 Materials and methods……...25

3.2.3 Results……26
3.2.4 Discussion……...28
3.2.5 Study limitations and recommendations…….30
3.2.6 Conclusion……..31
3.2.7 Acknowledgements…….....32
3.3 Tables…….33
3.3.1 Table I (Demographic and clinical data)…….33
3.3.2 Table II (P-values) ….…….34
3.4 Figures……35
3.4.1 Figure 1 (Histological of ECA)……...35
3.4.2 Figure 2 (ECA classification) …….36
3.4.3 Figure 3 (ECA frequency) ……..36
3.5 References……..36
APPENDICES……43
APPENDIX 1: Data collection sheet……43
APPENDIX 2: Ethics approval……44
APPENDIX 3: Turn it in report……45

LIST OF ABBREVIATIONS

AGC	- Atypical glandular cells
AIS	- Endocervical carcinoma in-situ
ASC-H	- Atypical squamous cells, cannot rule out high-grade squamous intraepithelial lesion
ASCUS	- Atypical squamous cells of undetermined significance
CIN	- Cervical intraepithelial neoplasia
CMJAH	- Charlotte Maxeke Johannesburg Academic Hospital
DES	- Diethylstilboestrol
ECA	- Endocervical adenocarcinoma
FIGO	- International Federation of Gynaecology and Obstetrics
HIV	- Human Immunodeficiency Virus
HPV	- Human papilloma virus
HSIL	- High-grade squamous intraepithelial lesion
H&E	- Haematoxylin and eosin
IECC	- International Endocervical Adenocarcinoma Criteria and Classification System
ISMC	- Invasive stratified mucin-producing carcinoma
ISMC	- Invasive stratified mucin-producing carcinoma
LSIL	- Low-grade squamous intraepithelial lesion
LLETZ	- Large loop excision of the transformation zone
NDoH	- National department of health
NHLS	- National Health Laboratory Services
NILM	- Negative for intraepithelial lesion and malignancy
NOS	- No special type
Pap smear	- Papanicolaou smear
PAS	- Periodic Acid-Schiff
SAJOG	- South African Journal of Obstetrics and Gynaecology
SC	- Serous carcinoma
SCC	- Squamous cell carcinoma
SCJ	- Squamocolumnar junction
SMILE	- Stratified mucin-producing intraepithelial lesion
SNOMED	- Systemized Nomenclature of Medicine
UICC	- Union for International Cancer Control
WHO	- World Health Organization

CHAPTER 1: INTRODUCTION OF THE STUDY

1.1 SIGNIFICANCE OF RESEARCH

Cervical carcinoma impacts negatively on the health burden of any population. Cervical cancer prevails as a significant contributor to and cause of cancer-related mortality in females worldwide. The incidence of cervical cancer increases annually worldwide, more so in African countries.[2,3] In 2018, an estimated 570 000 new cases and 311 000 deaths due to cervical carcinoma were recorded worldwide, while 528,000 new cases and 266,000 deaths were reported in 2012.[4–6] Globally, cervical carcinoma ranks second worldwide in the list of most common malignancies affecting women, particularly having a great disease burden and negative health impact in the lives of females in developing countries.[1] In developing countries, most cases of cervical carcinoma present at an advanced stage of the disease, impacting negatively on cure rates. [7] This may be due to ineffective screening programs.

Multiple risk factors have been found to increase the risk of cervical cancer. These include long-term oral contraceptive use, concurrent infection with Human Immunodeficiency Virus (HIV), and cigarette smoking.[8] The most significant of these is the association of high-risk human papillomavirus infections (HPV 16 & 18).[3]

Screening programs utilizing the Papanicolaou smear (Pap smear) have increased pre-cancerous and cancerous disease detection. They have contributed to the decline in cervical cancer-associated deaths in developed western countries.[8] In developed countries, the incidence of SCC of the cervix is on the decline due to the rollout of effective screening programs and prophylactic HPV vaccines in sexually naïve females. [3,9] The incidence of endocervical adenocarcinoma (ECA) and its precursor lesions is rising overall. Improved recognition of endocervical lesions on histopathological assessment and the high prevalence of HPV infection may explain the increase in the incidence of ECA cases.[9]

Research in western countries has shown that squamous cell carcinoma is declining, while endocervical cancer is on the rise. Most literature studies have been focused on squamous cell carcinoma and its associations. There is a lack of research and knowledge on endocervical cancer in the African population. Given the current increase in ECA incidence, it is

imperative to better understand endocervical cancer and provide more insight into the Southern African cohort.

1.2 AIM OF THE RESEARCH

The aim of this study is to describe the histopathological subtypes of endocervical carcinoma diagnosed at CMJAH (Charlotte Maxeke Johannesburg Academic Hospital) - National Health Laboratory Services (NHLS) during the time period 01/01/2017 to 31/10/2019.

1.3 OBJECTIVES OF THE RESEARCH

- To identify the various subtypes of endocervical carcinoma.
- To determine the prevalence of endocervical adenocarcinoma.
- To classify endocervical carcinoma subtypes into World Health Organization (WHO) categories of HPV related and non-HPV related endocervical carcinomas.
- To determine the epidemiological parameters and HIV status of patients with endocervical carcinoma.

CHAPTER 2: LITERATURE REVIEW ON SUBTYPES OF CERVICAL CANCER

2.1 ANATOMY OF THE CERVIX

The cervix is a cylinder-shaped fibromuscular tissue located in the lowermost part of the uterus. It is an essential part of the female genital tract system and is divided into two, distinct parts: the ectocervix and the endocervix.[1,2] The endocervical canal opens into the vagina through the external cervical os. The ectocervix and endocervical mucosa have different epithelium. The ectocervix is lined by mature stratified squamous epithelium, whereas the endocervix is surfaced by tall columnar, mucin-producing cells.[3,4] At the squamocolumnar junction (SCJ), where the epithelial linings of both the ectocervix and endocervix merge, is an area of high cell turnover wherein columnar epithelium initially lines the area but undergoes squamous metaplasia due to irritation.[1] Squamous cell carcinoma(SCC) of the cervix originates almost exclusively at the SCJ, while endocervical adenocarcinoma (ECA) originates from the endocervical glands.[1]

2.2 INTRODUCTION TO CERVICAL CANCER

Cervical carcinoma negatively impacts on the health burden of any population. Cervical carcinoma prevails as a significant contributor to and cause of cancer-related deaths in women worldwide.[5] Its incidence increases annually globally, especially in African countries.[3,4] In 2018, an estimated 570 000 new cases and 311 000 cervical cancer deaths were recorded worldwide, while 528,000 new cases and 266,000 deaths were reported in 2012.[6–8] Globally, cervical carcinoma ranks second in the list of most common malignancies affecting women, particularly having a negative health impact in the lives of females in developing countries[1] where the majority of cases present at an advanced stage of the disease, negatively impacting cure rates. [9] Ineffective screening programs could be the cause of this.[10]

Cervical cancer risk has been demonstrated to be increased by multiple risk factors. These include using oral contraceptives for an extended period of time, smoking cigarettes, and having concurrent Human Immunodeficiency Virus infection (HIV).[11] The most significant of these is the association of high-risk human papillomavirus (HPV) infections, especially subtypes 16 and 18.[4]

Screening programs utilizing the Pap smear have increased pre-cancerous and cancerous disease detection. They have played a role in the reduction of mortality linked to cervical cancer in developed Western nations.[11] In developing nations, the prevalence of SCC of the

cervix is declining as a result of the introduction of efficient screening programs and preventative HPV vaccines in sexually naïve females. [4,12] The incidence of ECA however, and its precursor lesions is rising overall.[1] Improved recognition of endocervical lesions on histopathological assessment and the high prevalence of HPV infection may explain the increased incidence of ECA cases.[12]

2.3 CERVICAL CANCER EPIDEMIOLOGY

Cervical carcinoma remains one of the leading causes of cancer-related mortality worldwide, despite it being a preventable disease. This is particularly true in Africa, where cervical carcinoma is the leading cause of morbidity and mortality among females. [6,13,14] In 2018, there was an increase in the number of cases reported compared to those reported in 2012 (deaths increased by 47 000, while new cases increased by 42 000).[7,8] The highest prevalence of cervical carcinoma is seen in women aged between 30 and 40.[1]

It is well documented that HPV infection plays an essential role in developing and progressing pre-cancerous lesions to cervical cancer and, particularly, incessant infection with high-risk HPV subtypes (HPV 16 and 18).[15] Studies have demonstrated that the disease burden attributed to cervical carcinoma varies greatly with geographic location.[13] In first-world countries, the disease burden has decreased, and this has been attributed to the development of effective programs, including early screening, diagnosis, and treatment.[14] The highest prevalence is in developing, low-income and low-resourced regions, where 80-83% of cases are found.[4,16] High mortality rates prevail in Southern Africa and Western Africa. Cervical carcinoma makes up 15% of all female malignancies in these areas. [3,4,8,16] The disparity in cervical cancer incidence between the developed and developing nations can be attributed to various factors, including inadequate knowledge and challenges in implementing cytology-based screening initiatives.[3] Among South African women, cervical malignancies constitute a significant cause of cancer-related deaths, with 70% of deaths occurring in women over 50.[13] The disease is, however, most aggressive in women diagnosed at a younger age.[11]

2.4 AETIOLOGY OF CERVICAL CANCER

Both SCC and ECA have similar identifiable risk factors.[17] Unremitting HPV infection by high-risk oncogenic subtypes is critical for progressing high-grade squamous intraepithelial lesions (HSIL) to invasive carcinoma.[6] However, exposure to multiple risk factors plays a role in acquiring persistent HPV infection.[13] These factors include the oncogenic potential related to the HPV subtype, a compromised immune system, concurrent infection with other sexually transmitted infections such as *Chlamydia trachomatis*, early onset of sexual activity, an increasing number of lifetime sexual partners, cigarette smoking and the long-term use of oral contraceptives.[14] In addition, women who are known to have/have been diagnosed with Peutz-Jeghers syndrome have a hereditary disposition for developing gastric-type adenocarcinoma of the cervix (HPV-independent).[13,14,17]

HIV infection is highly prevalent in Africa, with incidence rates exceeding 70%.[13] Because of their compromised immune systems, HIV-positive women are 2-5 times more likely than HIV-negative women to develop precursor lesions, persistent HPV infection, and cervical cancer at a younger age.[13,14,18]

The most significant contributing factor to the development of cervical cancer is persistent HPV infection.[6,19] The HPV subtypes commonly infecting mucosal keratinocytes are subdivided into those with high oncogenic potential (high-risk subtypes) and those with low oncogenic potential (low-risk subtypes).[20,21] High-risk subtypes (HPV 16/18) cause at least two-thirds (70%) of cervical carcinomas globally.[6,19,22,23] The high-risk subtypes have been found to cause the majority of cervical cancer in South Africa.[24] HPV 16 causes a majority of SCC and cervical intraepithelial lesions, while HPV 18 is more common in endocervical adenocarcinomas.[19,22]

Infection of basal cells in the squamous epithelial cell layer is preceded by acquiring HPV virions through micro-abrasions and epithelial trauma. The longevity of these infected cells underlies the persistence of HPV infection.[25] Genital HPV can have different morphological presentations ranging from normal cytology to different stages of pre-cancerous lesions (low-grade and high-grade squamous intraepithelial lesions) and invasive carcinoma.[26] The time frame for developing a pre-cancerous lesion with progression to invasive carcinoma is estimated at 15 years from the initial HPV infection.[27] The natural history of HPV infection in immunocompetent persons is spontaneous resolution, with 10% of HPV infections persisting and progressing to malignancy.[28]

2.5 CERVICAL CANCER SCREENING

Through effective cervical screening, many cases of invasive cervical carcinoma may be prevented.[29] However, there is a general lack of organized and efficient screening programs in developing countries.[30] In high-risk countries and regions, the aim is to ensure adequate screening and vaccination programs are implemented to transform the situation.[29] A Pap smear can identify early cervical epithelial changes and has a 70% sensitivity of detecting high-grade squamous intraepithelial lesions.[3]

Several countries have introduced HPV vaccination programs in an effort to lower the long-term global burden of cervical cancer and possibly eradicate it altogether.[8] The World Health Organization (WHO) recommends immunizing sexually naïve girls aged 9 to 13 years against HPV infection. Women between the ages of 30 to 49 years are advised to present themselves for a Pap smear test every 3 to 5 years. [29] Clinical trials have demonstrated that HPV vaccination effectively prevents cervical disease linked to HPV 16 and 18. Immunization is most beneficial in HPV naïve women.[29] The three commercially available HPV vaccines are the quadrivalent vaccine targeting both low and high risk HPV subtypes (HPV 6, 11, 16 and 18), the bivalent vaccine with efficacy against high risk subtypes only, and lastly the 9-valent vaccine, which confers protection against five additional oncogenic HPV subtypes.[31,32]

The sensitivity for early detection of precancerous lesions is increased when a Pap smear test and HPV DNA test are combined.[3] The incidence of cervical carcinoma is high in developing African countries, where prevention programs are non-existent or poorly implemented.[3] A study conducted in India among female health professionals revealed that although study participants had good knowledge and attitudes towards the use of the Pap smear in cervical screening, the delay in the appearance of disease symptoms created hesitancy in study participants to undergo a Pap smear test, which may contribute in some patients presenting with advanced disease.[9]

2.6 CLINICAL PRESENTATION, DIAGNOSIS, AND SPREAD

The symptomatology of cervical carcinoma depends on the tumour size and clinical stage. [24] Early-stage cervical cancer is usually asymptomatic, and late-stage tumours can present with a cervical mass associated with nonspecific symptoms of vaginal bleeding, especially post-coital bleeding.[16,28] The diagnosis is made on the cytological evaluation of an abnormal Pap smear, and the histological evaluation of a colposcopically directed biopsy or endocervical

curettage specimen.[14,28,33] Cervical cancer spreads by three main routes: direct spread to nearby organs such as the vagina, bladder, and uterus; lymphatic spread to regional lymph nodes; and haematogenous spread to distant metastatic sites (lungs, brain, and liver).[14,16]

2.7 CERVICAL CANCER MORPHOLOGICAL SUBTYPES

The WHO describes several histopathologic variants of cervical cancer. SCC is the most prevalent, accounting for 70-80% of cases. Other subtypes include but are not limited to adenocarcinoma, carcinosarcoma, adenosquamous carcinoma and carcinoma unclassifiable.[34] SCC is the most prevalent and accounts for 70-80% of cervical carcinoma cases.[14,19]

2.7.1 Endocervical adenocarcinoma (ECA)

The glandular epithelium of the endocervical canal is the source of cervical adenocarcinomas, which make up 20% to 25% of all cervical carcinomas worldwide.[1,19] Clinically, they present later and are asymptomatic due to their high endocervical origin, resulting in a poor prognosis.[1] The incidence of ECA and its subtypes has increased relative to squamous cell carcinoma, with more cases being diagnosed in recent years than several decades ago.[26,35] The ECA group comprises tumours with distinct and different morphological subtypes. These include endocervical, endometrioid, mucinous, gastric, serous, clear cell, and mesonephric tumours. The most prevalent subtype among all ECAs is the usual subtype.[36] High-risk HPV (18) driven ECAs make up about 85% of all ECAs.[36] According to An et al., 90% of cervical adenocarcinomas were HPV driven, with HPV 16 and 18 accounting for more than 70% of these cases.[30] Hence the sub-classification of ECA into HPV-related and HPV-unrelated subtypes as per the 2020 WHO classification.[35]

ECA's were primarily classified based on their characteristic histological features in the 2014 World Health Organisation classification system, which had minimal aetiological, clinical and management significance. [17] This classification system was difficult to use in daily practice because it lacked sufficient reproducibility clinically and similarly lacked pathogenetic significance, which limited its use in patient care management.[17]

A more reproducible classification named The International Endocervical Adenocarcinoma Criteria and Classification (IECC) system was developed in 2017-2018 to address the shortcomings of the WHO system.[17] This system classifies endocervical adenocarcinoma into two main categories; HPV-dependent and HPV-independent groups based on morphological grounds, precluding the need for immunohistochemical tests.[17] The IECC system recognises

the following hallmarks of HPV infection: identification of apical mitoses and apoptotic bodies at low power magnification (40x magnification). The absence of these morphological features correlates with HPV-independent tumours.[37]

The WHO implemented the IECC classification system in 2020, to provide clinicians with an improved means to diagnose and classify ECAs, which would ultimately allow for more individualized care for these patients.[17]

2.7.1.1 HPV-associated ECA

HPV-associated precursor lesions which progress to HPV-related ECA include usual-type endocervical carcinoma in-situ (AIS) and stratified mucin-producing intraepithelial lesion (SMILE).[37] HPV-related ECA subtypes comprise usual type including villoglandular variant, mucinous (non–gastric-type) type and HPV-dependent adenocarcinoma NOS.[34]

Usual type (including villoglandular variant)

This invasive endocervical tumour showing glandular differentiation is caused by high-risk HPV and is the most common subtype of ECA, accounting for approximately 75-80% of all ECA cases.[35,38] It usually presents in the 4th and 5th decades of life, with potential symptoms including vaginal bleeding and a clinically identifiable tumour, or the patient being asymptomatic but having an abnormal Pap smear.[35] The proportion of glandular differentiation is used to grade usual type ECA, though its prognostic value is debatable.[35] Usual subtype is defined by the presence of tumour cells with intracytoplasmic mucin, apical mitotic figures and apoptotic bodies in 50% of the entire tumour. The tumour consistently exhibits diffuse p16 block-like positivity immunohistochemically.[37] The variant shows different growth patterns, including villoglandular, papillary, cribriform, cystic glands, and micropapillary.[37]

For human papillomavirus-associated invasive adenocarcinoma, the Silva pattern-based classification has shown to be a reliable method for predicting the risk of lymph node metastasis and recurrences.[39] It is crucial to remember that this system is applicable to usual type HPV-associated ECAs; it does not apply to other variants. To appropriately categorize the tumour, the tumour needs to be entirely examined histologically, in the absence of destructive stromal invasion.[40] Three patterns are recognized, based on the degree of lymphovascular and destructive stromal invasion, regardless of the depth of invasion.[41]

Pattern A endocervical adenocarcinomas (non-destructive) are characterized by highly differentiated, well-formed glands with a lobular architecture, and the absence of destructive stromal invasion and lymphovascular invasion.[39] Distinguishing Pattern A ECA from adenocarcinoma in-situ may pose diagnostic difficulty.[34] Destructive patterns (Pattern B and C) exhibit poorly formed, angulated glands that infiltrate the stroma.[34] Pattern B (early/focally destructive) tumours show individual or small clusters of tumour cells surrounded by focally desmoplastic or inflamed stroma, admixed with pattern A glands.[39–41] Pattern B may show lymphovascular invasion.[34] Pattern C tumours show diffusely destructive, angulated glands within a marked desmoplastic stromal response.[34] Lymphovascular invasion may be present or absent and is not crucial for the diagnosis of pattern C.[39–41]

Mucinous type (Mucinous NOS adenocarcinoma, intestinal adenocarcinoma, signet-ring cell adenocarcinoma, and Invasive Stratified Mucin-producing Carcinoma (ISMC))

About 10% of all ECAs are of the mucinous.[34] As a rule, these tumours have more than 50% mucin-rich cells readily identifiable on H&E sections.[30] The mucinous carcinomas that are HPV-driven include intestinal type, signet-ring cell type, ISMC, and mucinous carcinoma NOS.[34]

Mucinous carcinoma NOS is an adenocarcinoma characterized by mucin production that cannot be classified into known specific subtypes of ECA.[30] More than 50% of tumour cells have mucinous cytoplasm resembling normal endocervix in a usual type background.[34,37]

About 10% of all ECA's are intestinal in nature, affecting women in their fourth and fifth decades.[30] The tumour goblet or enteroendocrine cell (Paneth-like cells) differentiation is of more than 50% of the tumour, in a mucinous NOS background.[34,37]

Signet-ring cell adenocarcinoma comprises loose, non-cohesive round cells with eccentrically placed nuclei and a mucinous vacuole, representing >50% of tumour cells in a usual-type background.[34,37]

Stratified mucin-producing intraepithelial lesion is a precursor to ISMC. ISMC is characterized by peripherally palisaded, nested and invasive clusters of columnar mucin-producing cells.[34,37]

The grading and prognosis of these tumours is similar to that of endocervical adenocarcinoma usual type.

Adenocarcinoma NOS, HPV-dependant

Although it does not fit morphologically into any of the established categories of HPV-dependent ECA's, this unusual tumour is HPV-associated.[17,39] It exhibits all the histological hallmarks of HPV infection, including apical mitoses and karyorrhexis at 40x magnification on the H&E tissue section. This tumour exhibits block-type positivity for p16 on immunohistochemical stains.[37]

2.7.1.2 HPV-independent ECA

There are several subtypes of HPV-independent ECA, such as HPV-independent adenocarcinoma gastric type, endometrioid type, mesonephric type, clear cell type, and HPV-independent adenocarcinoma NOS.[34] About 15% of cases of endocervical adenocarcinoma are HPV-independent.[37] For both mesonephric carcinoma and gastric-type adenocarcinomas, there are HPV-independent precursor lesions that are identified: mesonephric hyperplasia for the former, and atypical lobular endocervical glandular hyperplasia, gastric AIS for the latter.[37]

HPV-independent Adenocarcinoma, Gastric type

This group of HPV-independent ECAs is identified by cells that exhibit gastric differentiation with abundant clear cytoplasm and distinct cytoplasmic borders.[34,35] This subtype accounts for 10-15% of all cervical adenocarcinomas worldwide and 20-25% of the Japanese population.[34] It is the second-most common subtype of ECA and presents in the fifth decade.[34,38] The majority of cases are sporadic. A minor component is seen in Peutz Jeghers syndrome; a heritable cancer predisposition syndrome that is characterized by germline *STK11* mutations.[34,42] Apical mitotic figures and apoptosis are present but are typically inconspicuous and not detected easily at 40 to 100× magnification.[34,37] This tumour is HPV negative and is often aggressive compared to usual type ECA.[34] MUC-6 and HIK1083 immunohistochemical tests are characteristically positive.[34,42] A metastasis, especially one from the pancreaticobiliary tree, should be clinically excluded. The identification of PAX8 immunohistochemically (a marker of Mullerian origin) favours a primary cervical tumour.[37]

Endometrioid-type adenocarcinoma

With an estimated incidence of 1% of all endocervical carcinomas, primary endometrioid carcinomas of the cervix are exceedingly rare malignant.[30] These tumours resemble endometrial carcinomas of the uterus.[34] These neoplasms must be differentiated from direct

extension from the uterine corpus.[30] They frequently arise in the background of endometriosis.[37]

Adenocarcinoma, HPV-independent, mesonephric type

Less than 1% of all endocervical tumours are classified as mesonephric adenocarcinomas.[26,30] This subtype primarily affects females in their fifth decade of life and is characterised by *KRAS* mutations.[26,30,34] The tumour shows mesonephric differentiation and arises from mesonephric remnants in the background of mesonephric hyperplasia.[34] Various morphological growth patterns are recognized, including ductal, tubular, papillary, sex cord-like, solid, spindled, and retiform.[30] The tumour cells typically contain scant cytoplasm, and many of their nuclei may be oval, optically clear, grooved, and overlapping, resembling papillary thyroid carcinoma.[37] The tubular pattern, which is particularly distinctive, is characterized by cells containing intraluminal PAS (Periodic Acid Schiff)-positive eosinophilic material.[37] These tumours are negative for HPV.[34,37]

Adenocarcinoma, HPV-independent, clear cell type

These rare malignant neoplasms account for 3-4% of cervical adenocarcinomas.[34,43] Sporadic cases occur in the fifth decade and usually affect the endocervix. Previously this tumour was common in young women had been exposed to diethylstilboestrol (DES) in utero.[26,34] These tumours demonstrate a tubulocystic, papillary, and solid architecture in which hobnailed cells with clear or eosinophilic cytoplasm and prominent cytoplasmic borders are seen.[34,38] Mitotic activity is often low.[37]

HPV-independent Adenocarcinoma NOS

The term HPV-independent adenocarcinoma NOS is used when immunohistochemistry cannot be performed, or is unavailable to further subtype the tumour.[34] These are HPV-independent tumours that cannot be classified into one of the other HPV-independent subtypes.[34] They are poorly differentiated tumours with a solid architecture, atypical nuclei, and scant intracytoplasmic mucin.[37]

Serous carcinoma

Primary serous carcinoma of the cervix is a diagnosis of exclusion made after the exclusion of spread from either SC of the ovary, fallopian tube, or endometrium.[26] Aberrant p53 staining pattern without HPV infection must be present to consider a primary serous cervical

carcinoma.[34] However, there is now a consensus that most, if not all, cases of serous carcinoma in the cervix represent metastasis or direct extension from adnexal or endometrial serous carcinomas.[34]

2.7.2 Other subtypes of cervical cancer

Squamous cell carcinoma is the most predominant type of all cervical cancer types, and most originate in the SCJ. On speculum examination, they can be visualized as an exophytic or ulceration tumour mass.[1] The primary aetiological agent is high-risk HPV infection.[26] All squamous cell carcinomas arise from a pre-cancerous lesion of high-grade intraepithelial dysplasia known as cervical intraepithelial neoplasia 3 or squamous cell carcinoma in situ.

Adenosquamous carcinoma commonly arises from both squamous intraepithelial lesions and adenocarcinoma in-situ; hence, it comprises both malignant glandular and squamous epithelial components. High-risk HPV infection is linked aetiologically to adenosquamous carcinoma.[26,35]

The rarer subtypes of cervical cancer include neuroendocrine tumours, lymphomas, and sarcomas. Neuroendocrine tumours can arise independently or in conjunction with squamous cell carcinoma or endocervical adenocarcinoma.[38] These tumours are HPV driven and are categorized into high-grade and low-grade carcinomas, with the former being more common.[44,45] High-grade neuroendocrine carcinomas are classified into small-cell and large-cell varieties.[42] These are aggressive tumours that usually present at an advanced stage and therefore have a poor prognosis.[38]

In the female genital tract, lymphomas are exceedingly rare tumours that are challenging to diagnose on Pap smear or endocervical brushings. These malignancies may be primary or metastatic; however, distinguishing between primary extranodal origin and metastatic extranodal disease is challenging.[1] Lymphoma of the female genital tract may occur in the setting of systemic haematolymphoid disease. Diffuse large B-cell lymphoma is this site's most prevalent subtype.[23]

Carcinosarcomas of the cervix are extremely rare, and make up less than 3% of all uterine carcinosarcomas.[1] These tumours comprise both malignant epithelial and mesenchymal components.[46] They primarily affect postmenopausal women and present with vaginal bleeding and a protruding cervical mass.[1,46]

2.8 CERVICAL CANCER STAGING

The process of staging involves determining the extent of cancer spread, which informs patient care. Cervical tumours are staged according to the Union for International Cancer Control (UICC) TNM staging and the International Federation of Gynaecology and Obstetrics (FIGO) classifications.[16,19] Both classifications have been utilized to describe the anatomical extent of disease and prognosticate patients.[6] The TNM classification has been used to assess the extent of nodal and metastatic disease. The FIGO classification has been revised to include nodal status to correspond with the TNM staging system.[6] In the FIGO staging, treatment for cervical adenocarcinoma is guided by the tumour size >2cm, the percentage of cervical wall thickness involved by tumour, and the presence or absence of lymphovascular invasion.[41]

Tumour staging involves clinical and pathologic examination of the tumour, with clinically visible tumours staged as IB neoplasms.[41] In early-stage microscopic cervical carcinoma, the tumour is staged based on its depth of invasion. [41] The current staging system has several issues; one being the lack of precise guidelines for measuring invasive carcinoma.[40] Assessment of this parameter can be challenging, especially when the invasive tumour is adjacent to adenocarcinoma in-situ.[39]

A pattern-based risk stratification system (Silva-based pattern) was developed in response to the challenges in staging cervical adenocarcinoma. This system identifies tumours that, despite being invasive, may be treated more conservatively.[40] The application of this morphology-based classification may help to identify patients who will benefit from conservative treatment and have good clinical outcomes. [40] These patients would otherwise undergo radical surgery based on FIGO staging alone. The histopathologic pattern classification system for endocervical adenocarcinoma strongly correlates with nodal metastases and recurrence risk.[41]

2.9 TREATMENT AND SURVIVAL

Cervical cancer is managed using staging systems, which offer a basis for therapeutic methods based on the different stages of the disease.[38] Patient factors such age, fertility wishes, and health status also influence treatment options.[16] Currently, similar treatment approaches apply for squamous cell carcinoma and adenocarcinoma.[4] The treatment of an early-stage disease may involve radical hysterectomy and pelvic lymphadenectomy. For

locally advanced disease (stages IIB to IVA), adjuvant chemotherapy and radiation therapy are utilized.[36] Palliative chemotherapy is recommended for advanced disease and recurrent disease.[47]

Prognostic factors influencing the survival rate include the disease stage, parametrial involvement, and histological subtype.[12] Patients with cervical cancer in stage IA have a nearly 100% 5-year survival rate, whereas patients in stage IV have survival rates of 5 % to 15%.[12] Other factors that affect prognosis and survival are age at diagnosis and comorbidities such as coinfection with HIV.[28] The presence of lymph node metastases and lymphovascular invasion on histological assessment has a considerable impact on overall survival and is a good predictor of recurrence.[16]

3.0 REFERENCES

1. Sahdev A. Cervical Tumors. Semin Ultrasound CT MRI [Internet]. 2010 Oct [cited 2019 May 16];31(5):399–413. Available from: https://linkinghub.elsevier.com/retrieve/pii/S0887217110000624

2. Bhatla N, Aoki D, Sharma DN, Sankaranarayanan R. Cancer of the cervix uteri. Int J Gynecol Obstet [Internet]. 2018 Oct [cited 2019 Jun 26];143:22–36. Available from: http://doi.wiley.com/10.1002/ijgo.12611

3. Sachan P, Singh M, Patel M, Sachan R. A Study on Cervical Cancer Screening Using Pap Smear Test and Clinical Correlation. Asia-Pac J Oncol Nurs [Internet]. 2018 [cited 2021 Oct 22];5(3):337. Available from: http://www.apjon.org/text.asp?2018/5/3/337/233625

4. Simcock B, Shafi M. Invasive cancer of the cervix. Obstetrics, Gynaecology and Reproductive Medicine. 2007;17(6):181-187. Available from https://doi.org/10.1016/j.ogrm.2013.08.00

5. Small W, Bacon MA, Bajaj A, Chuang LT, Fisher BJ, Harkenrider MM, et al. Cervical cancer: A global health crisis. Cancer [Internet]. 2017 [cited 2019 Jun 25];123(13):2404–12. Available from: https://onlinelibrary.wiley.com/doi/abs/10.1002/cncr.30667

6. Bhatla N, Berek JS, Cuello Fredes M, Denny LA, Grenman S, Karunaratne K, et al. Revised FIGO staging for carcinoma of the cervix uteri. Int J Gynecol Obstet [Internet]. 2019 Apr [cited 2019 Jun 2];145(1):129–35. Available from: https://onlinelibrary.wiley.com/doi/abs/10.1002/ijgo.12749

7. Kanthiya K, Khunnarong J, Tangjitgamol S, Tanvanich S. Expression of the p16 and Ki67 in Cervical Squamous Intraepithelial Lesions and Cancer. Asian Pac J Can Prev, 17(7):3201-3206. Available from https://journal.waocp.org/article_32497_5c3683eef3090fe38e38ab1ac782957c.pdf

8. Bray F, Ferlay J, Soerjomataram I, Siegel RL, Torre LA, Jemal A. Global cancer statistics 2018: GLOBOCAN estimates of incidence and mortality worldwide for 36 cancers in 185 countries. CA Cancer J Clin [Internet]. 2018 Nov 1 [cited 2019 May

30];68(6):394–424. Available from: https://onlinelibrary.wiley.com/doi/abs/10.3322/caac.21492

9. Swapnajaswanth M, Suman G, Suryanarayana SP, Murthy NS. Perception and Practices on Screening and Vaccination for Carcinoma Cervix among Female Healthcare Professional in Tertiary Care Hospitals in Bangalore, India. Asian Pac J Cancer Prev [Internet]. 2014 Aug 15 [cited 2021 Oct 22];15(15):6095–8. Available from: http://koreascience.or.kr/journal/view.jsp?kj=POCPA9&py=2014&vnc=v15n15&sp=6095

10. Moodley J, Kawonga M, Bradley J, Hoffman M. Challenges in implementing a cervical screening program in South Africa. Cancer Detect Prev [Internet]. 2006 Jan [cited 2022 Feb 26];30(4):361–8. Available from: https://linkinghub.elsevier.com/retrieve/pii/S0361090X06001103

11. Pelkofski E, Stine J, Wages NA, Gehrig PA, Kim KH, Cantrell LA. Cervical Cancer in Women Aged 35 Years and Younger. Clin Ther [Internet]. 2016 Mar [cited 2019 May 16];38(3):459–66. Available from: https://linkinghub.elsevier.com/retrieve/pii/S0149291816300510

12. Ganesan R. HPV-related cervical glandular lesions. Diagn Histopathol [Internet]. 2018 Jan [cited 2019 May 16];24(1):18–25. Available from: https://linkinghub.elsevier.com/retrieve/pii/S1756231717301846

13. Cohen PA, Jhingran A, Oaknin A, Denny L. Cervical cancer. The Lancet [Internet]. 2019 Jan [cited 2019 May 16];393(10167):169–82. Available from: https://linkinghub.elsevier.com/retrieve/pii/S014067361832470X

14. World Health Organization, World Health Organization, Reproductive Health and Research. Comprehensive cervical cancer control: a guide to essential practice. [Internet]. 2014 [cited 2019 May 30]. Available from: http://apps.who.int/iris/bitstream/10665/144785/1/9789241548953_eng.pdf?ua=1

15. Goodman A. HPV testing as a screen for cervical cancer. BMJ [Internet]. 2015 Jun 30 [cited 2019 Aug 9];350:h2372. Available from: https://0-www-bmj-com.innopac.wits.ac.za/content/350/bmj.h2372

16. Kyrgiou M, Shafi MI. Invasive cancer of the cervix. Obstetrics, Gynaecology and Reproductive Medicine. 2010;20(5):147-154. Available from https://api.semanticscholar.org/CorpusID:44646928

17. Stolnicu S, Hoang L, Soslow RA. Recent advances in invasive adenocarcinoma of the cervix. Virchows Arch [Internet]. 2019 Nov [cited 2021 Jul 26];475(5):537–49. Available from: http://link.springer.com/10.1007/s00428-019-02601-0

18. Chakravarty J, Chourasia A, Thakur M, Singh A, Sundar S, Agrawal N. Prevalence of human papillomavirus infection & cervical abnormalities in HIV-positive women in eastern India. Indian J Med Res [Internet]. 2016 [cited 2021 Oct 22];143(1):79. Available from: http://www.ijmr.org.in/text.asp?2016/143/1/79/178614

19. Marth C, Landoni F, Mahner S, McCormack M, Gonzalez-Martin A, Colombo N. Cervical cancer: ESMO Clinical Practice Guidelines for diagnosis, treatment and follow-up†. Ann Oncol [Internet]. 2017 Jul [cited 2019 Jul 24];28(suppl_4):iv72–83. Available from: https://academic.oup.com/annonc/article-lookup/doi/10.1093/annonc/mdx220

20. Choi YJ, Park JS. Clinical significance of human papillomavirus genotyping. J Gynecol Oncol [Internet]. 2016 Mar [cited 2019 Jul 6];27(2). Available from: https://www.ncbi.nlm.nih.gov/pmc/articles/PMC4717226/

21. Biryukov J, Meyers C. Papillomavirus Infectious Pathways: A Comparison of Systems. Viruses [Internet]. 2015 Aug 4 [cited 2019 Aug 28];7(8):4303–25. Available from: http://www.mdpi.com/1999-4915/7/8/2823

22. Chen AA, Gheit T, Franceschi S, Tommasino M, Clifford GM. Human Papillomavirus 18 Genetic Variation and Cervical Cancer Risk Worldwide. Banks L, editor. J Virol [Internet]. 2015 Oct 15 [cited 2019 Jul 14];89(20):10680–7. Available from: http://jvi.asm.org/lookup/doi/10.1128/JVI.01747-15

23. Khorasanizadeh F, Hassanloo J, Khaksar N, Mohammad Taheri S, Marzaban M, H. Rashidi B, et al. Epidemiology of cervical cancer and human papilloma virus infection among Iranian women — Analyses of national data and systematic review of the

literature. Gynecol Oncol [Internet]. 2013 Feb [cited 2019 May 31];128(2):277–81. Available from: https://linkinghub.elsevier.com/retrieve/pii/S0090825812008980

24. Botha MH, Dochez C. Introducing human papillomavirus vaccines into the health system in South Africa. Vaccine [Internet]. 2012 Sep [cited 2019 May 31];30:C28–34. Available from: https://linkinghub.elsevier.com/retrieve/pii/S0264410X12004082

25. Doorbar J, Egawa N, Griffin H, Kranjec C, Murakami I. Human papillomavirus molecular biology and disease association: Human papillomavirus. Rev Med Virol [Internet]. 2015 Mar [cited 2019 Jul 14];25:2–23. Available from: http://doi.wiley.com/10.1002/rmv.1822

26. Park KJ. Neoplastic Lesions of the Cervix. Surg Pathol Clin [Internet]. 2011 Mar [cited 2019 May 31];4(1):17–86. Available from: https://linkinghub.elsevier.com/retrieve/pii/S1875918110002564

27. Burd EM. Human Papillomavirus Laboratory Testing: the Changing Paradigm. Clin Microbiol Rev [Internet]. 2016 Apr [cited 2019 Jul 6];29(2):291–319. Available from: https://www.ncbi.nlm.nih.gov/pmc/articles/PMC4786885/

28. Blair AR, Casas CM. Gynecologic Cancers. Prim Care Clin Off Pract [Internet]. 2009 Mar [cited 2019 May 31];36(1):115–30. Available from: https://linkinghub.elsevier.com/retrieve/pii/S0095454308000961

29. Brusselaers N, Shrestha S, van de Wijgert J, Verstraelen H. Vaginal dysbiosis and the risk of human papillomavirus and cervical cancer: systematic review and meta-analysis. Am J Obstet Gynecol [Internet]. 2018 Dec [cited 2019 May 31];S000293781832221X. Available from: https://linkinghub.elsevier.com/retrieve/pii/S000293781832221X

30. An HJ, Kim KR, Kim IS, Kim DW, Park MH, Park IA, et al. Prevalence of human papillomavirus DNA in various histological subtypes of cervical adenocarcinoma: a population-based study. Mod Pathol [Internet]. 2005 Apr [cited 2019 Jun 11];18(4):528–34. Available from: http://www.nature.com/articles/3800316

31. Bloem P, Ogbuanu I. Vaccination to prevent human papillomavirus infections: From promise to practice. PLOS Med [Internet]. 2017 Jun 27 [cited 2021 Oct 22];14(6):e1002325. Available from: https://dx.plos.org/10.1371/journal.pmed.1002325

32. Sundström K, Elfström KM. Advances in cervical cancer prevention: Efficacy, effectiveness, elimination? PLOS Med [Internet]. 2020 Jan 28 [cited 2021 Oct 22];17(1):e1003035. Available from: https://dx.plos.org/10.1371/journal.pmed.1003035

33. La Russa M, Jeyarajah AR. Invasive cervical cancer in pregnancy. Best Pract Res Clin Obstet Gynaecol [Internet]. 2016 May [cited 2019 May 16];33:44–57. Available from: https://linkinghub.elsevier.com/retrieve/pii/S1521693415001844

34. World Health Organization, International Agency for Research on Cancer. Female genital tumours. 5th ed. Vol. 4. Lyon, France: WHO Press; 2020.

35. Young RH, Clement PB. Endocervical adenocarcinoma and its variants: their morphology and differential diagnosis. Histopathology [Internet]. 2002 Sep [cited 2019 May 16];41(3):185–207. Available from: http://doi.wiley.com/10.1046/j.1365-2559.2002.01462.x

36. Human papillomavirus (HPV) and cervical cancer [Internet]. [cited 2019 May 30]. Available from: https://www.who.int/news-room/fact-sheets/detail/human-papillomavirus-(hpv)-and-cervical-cancer

37. Stolnicu S, Park KJ, Kiyokawa T, Oliva E, McCluggage WG, Soslow RA. Tumor Typing of Endocervical Adenocarcinoma: Contemporary Review and Recommendations From the International Society of Gynecological Pathologists. Int J Gynecol Pathol [Internet]. 2021 Mar [cited 2021 Nov 30];40(Supplement 1):S75–91. Available from: https://journals.lww.com/10.1097/PGP.0000000000000751

38. Turashvili G, Park KJ. Cervical Glandular Neoplasia. Surg Pathol Clin [Internet]. 2019 Jun [cited 2019 May 16];12(2):281–313. Available from: https://linkinghub.elsevier.com/retrieve/pii/S1875918119300042

39. Alvarado-Cabrero I, Parra-Herran C, Stolnicu S, Roma A, Oliva E, Malpica A. The Silva Pattern-based Classification for HPV-associated Invasive Endocervical Adenocarcinoma and the Distinction Between In Situ and Invasive Adenocarcinoma: Relevant Issues and Recommendations From the International Society of Gynecological Pathologists. Int J Gynecol Pathol [Internet]. 2021 Mar [cited 2021 Nov

30];40(Supplement 1):S48–65. Available from: https://journals.lww.com/10.1097/PGP.0000000000000735

40. Park KJ, Roma AA. Pattern based classification of endocervical adenocarcinoma: a review. Pathology (Phila) [Internet]. 2018 Feb [cited 2019 May 16];50(2):134–40. Available from: https://linkinghub.elsevier.com/retrieve/pii/S0031302517303859

41. Joanne K.L. Rutgers, MD1, Andres Roma, MD2, Kay Park, MD3, Richard J. Zaino, MD4, Abbey Johnson, MD5, Isabel Alvarado, MD, PhD6, Dean Daya, MD7, Golnar Rasty, MD8, Teri, Longacre, MD9, Brigitte Ronnett, MD10, and Elvio Silva, MD11. Pattern Classification of Endocervical Adenocarcinoma: Reproducibility and Review of Criteria. Mod Pathol. 2016 Sep;29(9):1083–94.

42. Pirog EC. Cervical Adenocarcinoma: Diagnosis of Human Papillomavirus–Positive and Human Papillomavirus–Negative Tumors. Arch Pathol Lab Med [Internet]. 2017 Jun 23 [cited 2019 Jun 26];141(12):1653–67. Available from: https://www.archivesofpathology.org/doi/10.5858/arpa.2016-0356-RA

43. Wang D, Zhao C, Fu L, Liu Y, Zhang W, Xu T. Primary Clear Cell Adenocarcinoma of the Cervix: A Clinical Analysis of 18 Cases without Exposure to Diethylstilbestrol. Obstet Gynecol Int [Internet]. 2019 Mar 26 [cited 2019 Jun 25];2019. Available from: https://www.ncbi.nlm.nih.gov/pmc/articles/PMC6458873/

44. Castle PE, Pierz A, Stoler MH. A systematic review and meta-analysis on the attribution of human papillomavirus (HPV) in neuroendocrine cancers of the cervix. Gynecol Oncol [Internet]. 2018 Feb [cited 2019 May 31];148(2):422–9. Available from: https://linkinghub.elsevier.com/retrieve/pii/S0090825817315482

45. Howitt BE, Kelly P, McCluggage WG. Pathology of Neuroendocrine Tumours of the Female Genital Tract. Curr Oncol Rep [Internet]. 2017 Sep 1 [cited 2019 Jun 25];19(9):59. Available from: https://0-link-springer-com.innopac.wits.ac.za/article/10.1007/s11912-017-0617-2

46. Kim M, Lee C, Choi H, Ko JK, Kang G, Chun K chul. Carcinosarcoma of the uterine cervix arising from Müllerian ducts. Obstet Gynecol Sci [Internet]. 2015 May [cited

2019 Jun 25];58(3):251–5. Available from: https://www.ncbi.nlm.nih.gov/pmc/articles/PMC4444523/

47. Kamura T, Ushijima K. Chemotherapy for advanced or recurrent cervical cancer. Taiwan J Obstet Gynecol [Internet]. 2013 Jun [cited 2019 May 31];52(2):161–4. Available from: https://linkinghub.elsevier.com/retrieve/pii/S1028455913000594

CHAPTER 3: South African Journal of Obstetrics and Gynaecology (SAJOG) SUBMISSABLE JOURNAL ARTICLE

SUBTYPES OF ENDOCERVICAL CANCER: A RETROSPECTIVE, OBSERVATIONAL STUDY AT CHARLOTTE MAXEKE JOHANNESBURG ACADEMIC HOSPITAL.

Seipati Bulane[1,] MBChB

Reubina Wadee[2], MBBCh (WITS), PhD

[1,2]Department of Anatomical Pathology, Faculty of Health Sciences, University of the Witwatersrand and National Health Laboratory Services, Johannesburg, South Africa.

*Corresponding authors

Full name: Seipati Bulane

Department: Anatomical Pathology

University of the Witwatersrand

7 York Road, Parktown

Johannesburg, 2193, South Africa

Tel: 011 489 8469 & +27 83 539 5134

Fax: 011 489 9493

Email: seipatibulane112@gmail.com, seipati.bulane@nhls.ac.za

Full name: Reubina Wadee

Department: Anatomical Pathology

University of the Witwatersrand

7 York Road, Parktown

Johannesburg, 2193, South Africa

Tel: 011 489 8544

Email: reubinawadee@gmail.com, reubina.wadee@nhls.ac.za

Number of Tables: 2

Number of Illustrations: 3

Abstract word count: 260

Text word count: 2216

Keywords: Endocervical adenocarcinoma, HPV, HIV, Pap smear, South Africa

3.1 ABSTRACT

Background:

The second most common cancer among women, especially in developing countries, is cervical cancer. Though less frequent than cervical squamous cell carcinoma (SCC), endocervical adenocarcinoma (ECA) is becoming more common worldwide, especially in young women. The decline in SCC is attributed to effective screening initiatives.

Objectives:

We aimed to assess the prevalence of ECA and its subtypes and to describe the clinicopathological characteristics of patients with these tumours at a tertiary South African institute between 2017-2019.

Methods:

This was a cross-sectional, descriptive study on 156 ECA patients. Following ethical clearance, demographic data, clinical information, and disease characteristics were obtained from departmental histopathological reports. Descriptive statistics were used to calculate the prevalence of ECA. We interrogated the association between age, Papanicolaou (Pap) smear results, Human Papillomavirus (HPV) status, and Human immunodeficiency virus (HIV) status with ECA.

Results:

The prevalence of ECA in all malignant cervix carcinoma cases was 6.8% and was more common in younger women. HPV-associated subtypes were the most common variants. The usual type of ECA accounted for 24.4% of cases. HIV status was documented in 64.0% of cases, of which 34.0% were positive. There were no statistically significant associations between ECA subtype and HIV status (p=0.81) or between ECA subtype and Pap smear results.

Conclusion:

The prevalence of ECA in South Africa is lower compared to Western countries, which may reflect the inadequacies in screening modalities of endocervical carcinoma at primary healthcare facilities. HPV prevails as a cause of endocervical carcinoma. HPV morphologic hallmarks serve as a practical guide in classifying ECAs according to their HPV status.

3.2 MANUSCRIPT

3.2.1 Introduction:

Endocervical adenocarcinoma (EAC) is less common in contrast to squamous cell carcinoma (SCC) of the cervix. However, global estimates indicate that the rates of endocervical adenocarcinoma relative to those of squamous cell carcinoma are rising in developed countries, particularly in young women.[17] Adenocarcinoma accounts for 10–25% of all cervical cancers.[48] Persistent infection with high-risk human papillomavirus subtypes is the most important causative factor in preinvasive lesions and most SCCs and adenocarcinomas. Therefore, surveillance of precancerous lesions, which are at present more frequent than invasive cancers, is one of the indicators of cancer screening evaluation.[49] In developed countries the decline in cervical SCC is attributed to the early introduction of effective cytologic screening programs and implementation of HPV vaccination.[17] Cytologic screening effectively detects SCCs in the early stages, whereas adenocarcinomas have been reported to be less detectable by screening.[50] The changing prevalence of oncogenic types of HPV may also contribute to the increase in adenocarcinoma. Both cervical cancer subtypes have been linked to persistent viral infection with high-risk HPV strains.[50]

To date, there have not been studies to assess if similar trends apply to sub-Saharan countries, and South Africa in particular. Owing to the enormous HIV burden in southern African countries, most studies have assessed cervical squamous cell carcinoma in HIV-positive women. Our retrospective study aimed to determine the prevalence of endocervical adenocarcinoma and its varied subtypes and to describe the age distribution and HIV status of patients diagnosed at Charlotte Maxeke Johannesburg Academic Hospital (CMJAH) in Johannesburg, South Africa over a 3-year period (2017-2019).

3.2.2 Material and methods:

This retrospective study was performed following approval from the University of the Witwatersrand's Human Research Ethics Committee (Clearance number: M191161) and the National Health Laboratory Service. A Systemized Nomenclature of Medicine (SNOMED) search yielded a cohort of 156 cases. Haematoxylin and eosin-stained slides of non-usual subtypes of ECA were retrieved and reviewed to confirm diagnoses. In addition, where HPV subtyping was not done, the authors (SB and RW) used HPV histologic hallmarks (apical mitoses and basal karyorrhexis) to subtype cases on microscopy.[34] Inclusion criteria

encompassed all primary cases of endocervical carcinoma diagnosed between 2017-2019 and included mostly cervical biopsies rather than resection specimens. Tumour recurrences, metastases, and endometrial biopsies were excluded from the data set. Histopathology report review included extraction of demographic data (age and primary hospital), clinical information (Pap smear result, HIV status, and CD4 count), and disease characteristics (type of biopsy, histological subtype, and HPV association). Where the HIV and CD4 count results were unavailable on the histopathology report, data was sought from the laboratory information system (TrakCare) (following approval from the Department of Microbiology and Infectious Diseases).

Descriptive statistics were performed. The data was abnormally distributed, and age groups were defined as medians with interquartile ranges. ECAs overall, and yearly prevalence was calculated, and the results were expressed as percentages. The histological subtypes and HPV associations were recorded and classified according to the World Health Organisation (WHO) classification of cervical adenocarcinoma 5th ed. Categorical data were summarized as frequencies and percentages. Associations of endocervical carcinoma subtype with HIV status and Pap smear result were assessed using the Chi-Square test, and statistically significant p-values were set at p-values ≤ 0.05.

3.2.3 Results:

A total of 156 endocervical carcinoma cases were diagnosed during the study period. The youngest patient was 26 years old, and the oldest was 88. Biopsies were submitted from 15 hospitals and clinics that the Department of Anatomical Pathology provides a pathology service to. The Department of Obstetrics and Gynaecology at Charlotte Maxeke Johannesburg Academic Hospital referred the bulk of the cases (19.0%).

Demographic and clinical characteristics are summarized in Table 1. The median age of the patients whose tumours were assessed was 49-years, and the interquartile range was 41.25 - 62. The majority (30.13%) of patients were between 40 and 50 years of age at presentation. The remainder (28.6%) of patients, were above 60 years of age. The most frequently examined specimens were cervical punch biopsies which constituted 88.5% of cases. In contrast, cervical curettings and large loop excision of the transformation zone (LLETZ) biopsies comprised 1.9% and 6.4% of patient cases, respectively. In only 3.2% of cases, total

abdominal hysterectomy specimen results were assessed as previous cervical biopsies demonstrated adenocarcinoma in-situ or the previous biopsy results were unavailable.

The overall prevalence of ECAs in all malignant cervix carcinoma cases was 6.8%. Most (39.1%) cases were diagnosed in 2017, with a yearly prevalence of 2.7%. The least number of patients (26.3%) were diagnosed in 2019, and the prevalence rate in that year was only 1.8%.

Assessment of HPV subtyping was performed at the time of initial histological examination, using p16 immunohistochemistry, a known surrogate marker for HPV infection. In 49% of the cases, there was diffuse block-type positive staining (Figure 1). HPV in-situ hybridization (ISH) was performed in 1 case of adenocarcinoma Not Otherwise Specified (NOS), and HPV-ISH (HPV 16) was positive. In the remainder of cases (51%), where the HPV status remained undetermined as neither p16 nor in-situ hybridization was performed, the authors used HPV histologic hallmarks (apical mitoses and basal karyorrhexis) to subtype cases microscopically). Using this WHO-recommended method, in the absence of ancillary studies, most (90.3%) ECAs were determined to be HPV-associated (Figure 2).

HPV-associated Adenocarcinoma NOS histology dominated overall (59.0%), compared to the Usual-type (including villoglandular subtype) accounting for 24.4% of cases. There were 11 (7.1%) cases of mucinous carcinoma, of which mucinous NOS was predominant in 6 (54.5%) cases. The remainder of mucinous carcinomas included 4 intestinal type (36.4%) cases and 1 (0.6%) case of signet-ring cell type. Fifteen cases (7.7%) were classified as non-HPV-associated carcinoma, of which clear cell carcinoma accounted for 8 (5.1%) cases, while HPV-independent gastric type was seen in only 1 (0.6%) case (Supplementary data, Figure 3).

Patient HIV results were documented in 64.1% of cases. Of these, 34.0% of patients were HIV positive, and 30.1% were HIV negative (Table 1). The CD4 count was available in 38% of the HIV-positive cases. The CD4 count ranged from 76-1333 cells/mm3, with the average CD4 count of 507.68 ± 278.9 cells/mm3.

The Pap smear results were undocumented in 71.2% of cases (Table 1). High-grade squamous intraepithelial neoplasia (HSIL) was recorded in 13.5% of cases that had a Pap smear result. Only 1.2% of patients had adenocarcinoma in-situ as the precursor lesion, with 0.6% occurring in conjunction with HSIL. Malignancy was confirmed in 9 Pap smears.

There was no statistically significant association between the endocervical carcinoma histopathological subtype and the Pap smear result (p=0.81). Similarly, no correlation existed between the histological subtype and the HIV status (p=0.80). There was no statistically significant association between HPV association and HIV status (p=0.16) (Table 1).

3.2.4 Discussion:

Our patient cohort comprised predominantly women aged 40-50 (30.1%), comparable to Pirog et al.'s study.[42] In contrast to studies conducted in developed countries, our study showed an approximately 4% lower prevalence of endocervical carcinoma.[35,48] The basis for this may be the reduced detection of endocervical adenocarcinoma on Pap smears, given their high endocervical origin, which influences the number of patients referred for colposcopically-directed biopsies.[1,49,51] The lower number of cases that develop in our patient population may be due to different HPV subtypes or alternate risk factors to those in developed countries. Of the recorded Pap smear results, the cytological detection of endocervical adenocarcinoma was low at 5.1%, raising the possibility of similar challenges in our setting in diagnosing ECA. Furthermore, unlike women in developed countries, developing countries generally lack access to screening programs.[51] In addition, the low literacy levels and lack of funding for screening programs create further hindrances in diagnosing and combating ECA.[52,53] In our study, Atypical Squamous Cells of Undetermined Significance (ASCUS) was found in 1.3% of screened women, Low-grade squamous intraepithelial lesion (LSIL) in 2.6%, and HSIL in 13.5%. Our LSIL and ASCUS results are comparable to those documented by Sachan et al., who reported ASCUS in 2.9%, LSIL in 5.1%, and HSIL in 0.5% of their screened women.[3] The higher number of HSIL lesions in our study may be attributed to the low turnout for voluntary screening. Therefore, most women present later with high-grade dysplasia.[3] The implementation of the 2001 national cervical screening program in South Africa by the National Department of Health (NDoH) has been challenging and has thus seen the incidences and mortality rates of cervix carcinoma persist, not only in South Africa, but in the majority of other Sub-Saharan African countries.[54,55]

Most cases in our study lacked characteristic morphological features to group them into a specific subtype such as usual type, mucinous, or many others under the current WHO classification of ECA. As a result, most cases were grouped into adenocarcinoma NOS, comprising 59.0% of the study population. Usual-type adenocarcinoma was the next most

common subtype, but was much lower than that quoted in previous research which showed that the usual-type comprises up to 80% of cases of ECA.[17,35] This disparity may be seen because of the varied histological patterns of ECA.[35] This creates diagnostic difficulties, especially in small biopsies such as cervical punch biopsies, which were this study's most frequently examined specimens (88.5%). The hesitancy of pathologists to commit to a final diagnosis or a specific histological subtype on cervical biopsies may explain this outcome. In many cases, the definite classification was deferred to the excision specimen. However, in light of the WHO's recently recommended HPV histologic hallmarks (apical mitoses and basal karyorrhexis) it is hoped that pathologists may be able to commit to a definitive diagnosis on biopsy specimens which will help guide further patient management.

In our study, the least reported subtypes were HPV-independent tumours. These included clear cell carcinoma (5.1%) and serous cell carcinoma (1.3%), which are rarely diagnosed in the literature.[43] In the current WHO classification of ECA, primary serous carcinoma of the cervix is a diagnosis made based on an aberrant p53 immunohistochemical staining pattern without HPV infection, after excluding extension from the uterus and ovary.[34]

Overall, HPV-associated ECA subtypes were the most diagnosed (90.3%) in our study, and their prognosis is known to be better than HPV-independent adenocarcinomas.[56] HPV in-situ hybridization was rarely performed, due to resource limitations and a lack of in-situ hybridization facilities. HPV subtyping using p16 immunohistochemistry demonstrated diffuse block-type positivity in 49.0% of the cases. HPV histologic hallmarks (apical mitoses and basal karyorrhexis), as referenced in the World Health Organisation (WHO) classification of cervical adenocarcinoma 5th ed were used to subtype the remainder of 51.0% cases on microscopy. Despite HPV status playing a role in prognosis, it is of no importance in treatment. There is no specific treatment strategy based on histologic type or relation to HPV, as all ECA tumour subtypes are treated similarly.[17,48,4,16]

HIV infection remains rampant in South Africa, increasing the risk for cervical carcinoma six-fold.[52] This positive association between HIV and cervical carcinoma has been reported in Western countries such as Italy, France, and Spain.[57] Similar findings were noted in studies from Uganda and Tanzania.[58] A slightly higher number of our ECA cases were co-infected with HIV, suggesting that a synergistic relationship may exist between HPV infection and HIV. However, these findings were not statistically significant. Despite some studies

reporting positive associations, studies in Africa, notably Tanzania and Uganda, performed at the beginning of the Acquired Immunodeficiency Disease Syndrome (AIDS) pandemic, and in 2011, showed no association between HIV and cervical carcinoma.[59] This negative association is attributed to the fact that the progression of dysplasia to malignancy is multifactorial and not only dependent on immune status. [59,60]

Silverberg et al. found that cervical neoplasia risk and thus, cancer risk for both squamous and endocervical cancers is increased in women with CD4 count < 500 cells/mm^3.[61] The average CD4 count recorded in HIV-positive cases in our study was on average 507 cells/mm^3. Hence, no significant associations were apparent in our cohort. Similar results regarding low CD4 count and its associated increased risk of HPV infection were found in a study by Chakravarty.[18]

3.2.5 Study limitations and recommendations:

While the majority of patient results were anticipated to be available on the NHLS LabTrack system, it is acknowledged that a subset of patients may have had their HIV and CD4 count tests conducted in private laboratories, to which we lack access.

Upon reviewing clinical request forms and searching the NHLS data system, only 64% of HIV results could be documented. Among those with positive HIV results, only 38% had an accompanying recorded CD4 count. Data collection was compromised by several factors:

1. **Incomplete Clinical Data**: The inadequacy and partiality with which clinical data and results are filled out by clinical colleagues, on the patient request forms contributed to missing information.
2. **Data Entry Errors**: Upon receipt and registration of specimens, multiple variables require entry such as patient name, hospital number, and date of birth amongst other identifiers, and errors in this process can compromise data retrieval from the NHLS TrakCare system.
3. **System Migration Issues**: CMJAH's migration to a new patient identification and registration system resulted in changes to patient identification numbers. In many cases, the previous numbers were not adequately registered, complicating the retrieval of historical data and thus limiting our access to patient results.

Our ethical clearance did not permit us to directly contact patients whose HIV results were not found on the NHLS LabTrack system.
The limitations highlighted above significantly impacted on our ability to obtain HIV results and CD4 counts for each of our patient cases. Our assessment and statistical analyses for HIV results and CD4 counts are thus only reflective of the cases in which these results were obtained. Thus, we cannot extrapolate these results to the entire cohort in our study.

The Pap smear results were not documented in many cases (71.2%). Therefore, ECA's low detection rates on Pap smear results should be interpreted cautiously. Limited data may have influenced this result, and a larger cohort of cases with available Pap smear results may give more accurate results with implications in the interpretation thereof.

Confirmatory HPV subtyping using genotyping, p16 immunohistochemistry or HPV-ISH was not assessed in this study. Further, HPV subtyping and a more complete data set on HIV and CD4 count can be used in future studies to investigate the association between endocervical carcinoma, HPV subtypes, and HIV status, as well as CD4 count.

The correlation between biopsy results and the final diagnosis made on excision specimens can be assessed in future studies.

Further research is needed to investigate the impact of HPV vaccination and screening programs on the incidence of ECA in southern Africa.

3.2.6 Conclusion:

The overall prevalence of endocervical carcinoma (ECA) in South Africa is lower compared to Western countries, which may reflect inadequacies in the screening modalities available in our primary healthcare facilities. Despite this, HPV remains a predominant cause of ECA. Our study emphasizes that strict adherence to the WHO guidelines for the morphological classification of ECA is essential. In the absence of ancillary studies, identifying HPV-associated histological features serves as a practical approach for classifying ECAs according to their HPV status.

3.2.7 Acknowledgements:

We thank the NHLS for providing the data.

We thank Ms Fadila Ebrahim and Mr. Abel Ndlovu for retrieving the slides efficiently.

3.3 TABLES:

3.3.1 Table I. Demographic and clinical data (N=156)

CHARACTERISTIC	VALUE
MEDIAN AGE AT DIAGNOSIS, years	49 (41.25-62)
AGE INTERVAL FOR ECA SUBTYPES, years	
HPV-associated Adeno NOS **Usual-type including Villoglandular and Mucinous**	36-46
Serous Ca **HPV-independent gastric type** **HPV-independent Adeno NOS**	58-68
Clear cell Ca	69-79
HIV STATUS	**N (%)**
Positive	53 **(34.0)**
Negative	47 **(30.1)**
Unknown/No result (NR)	56 **(35.9)**
PAP SMEAR	**N (%)**
Unknown/No result (NR)	111 **(71.2)**
NILM	1 **(0.6)**
LSIL	4 **(2.6)**
HSIL	21 **(13.5)**
ASCUS	2 **(1.3)**
ASCH	3 **(1.9)**
AGC	2 **(1.3)**
Adenocarcinoma in-situ	2 **(1.3)**
Adenocarcinoma in-situ & HSIL	1 **(0.6)**
Adenocarcinoma	8 **(5.1)**
Carcinoma	1 **(0.6)**

P16 IMMUNOHISTOCHEMICAL STAIN	**%**
Positive	**47.1**
Negative	**1.9**
Not performed/No result (NR)	**51.0**

3.3.2 Table II. Chi-square P values to analyse significant associations

VARIABLES	P-value (0.05)
ECA subtype association to HIV status	0.88
ECA subtype association to Pap smear result	0.82
HPV association to HIV status	0.29

3.4 FIGURES:

3.4.1 Figure 1. Histological subtypes of endocervical adenocarcinoma.

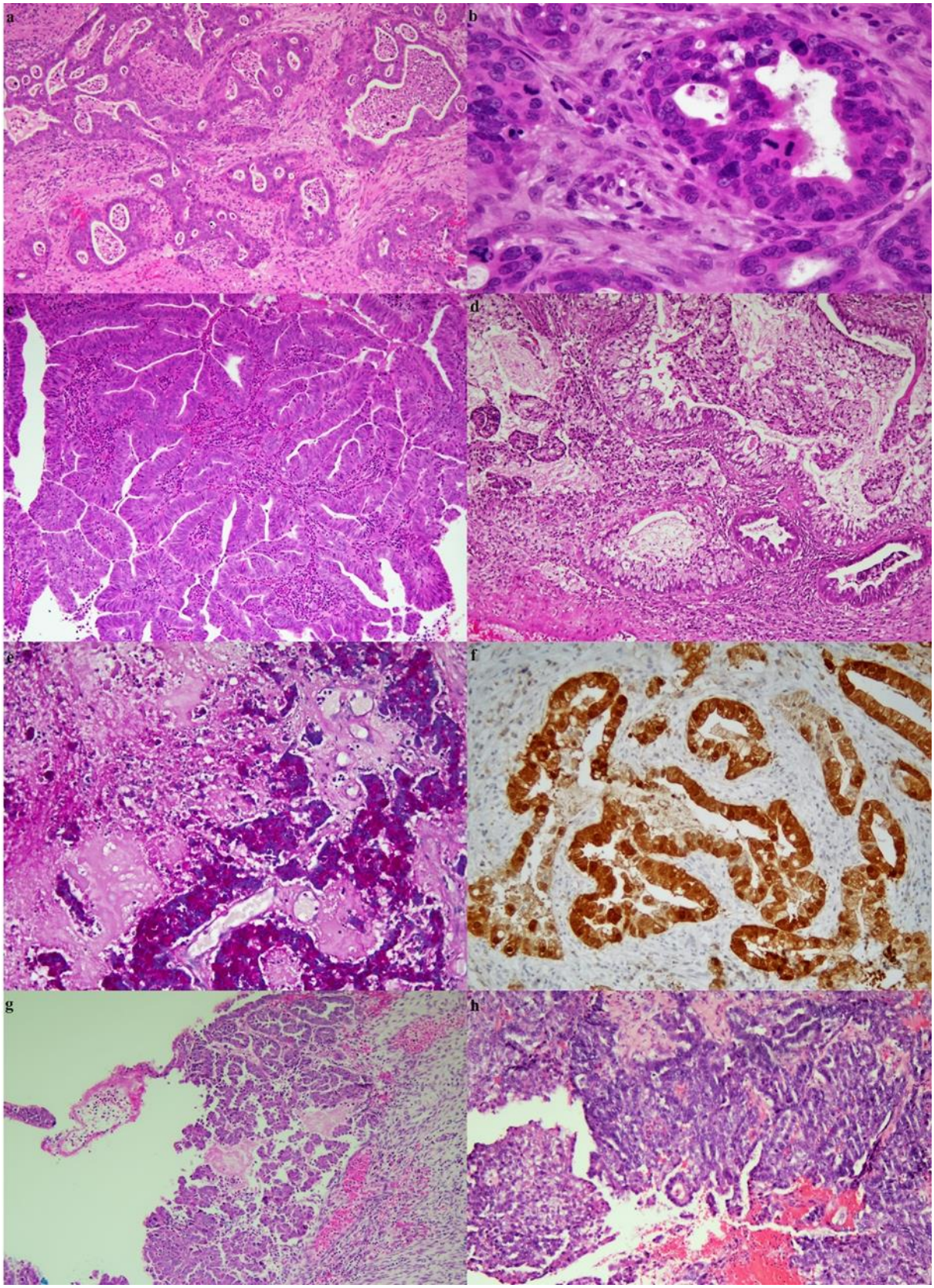

HPV related endocervical adenocarcinoma (a-d): (a, b) usual type endocervical adenocarcinoma, (c) villoglandular, (d) mucinous carcinoma of no special type (NOS), (e) Periodic acid–Schiff–diastase (D-PAS) stain in mucinous carcinoma, and (f) p16 immunohistochemical stain showing diffuse block-like positivity in tumour cells. HVP unrelated carcinomas (g-h): (g) serous carcinoma, and (h) clear cell carcinoma. Original magnification: 100x (a, c, d, g and h), 200x (e and f) 400x magnification (b).

3.4.2 Figure 2. Column chart illustrating the classification of ECA according to HPV status

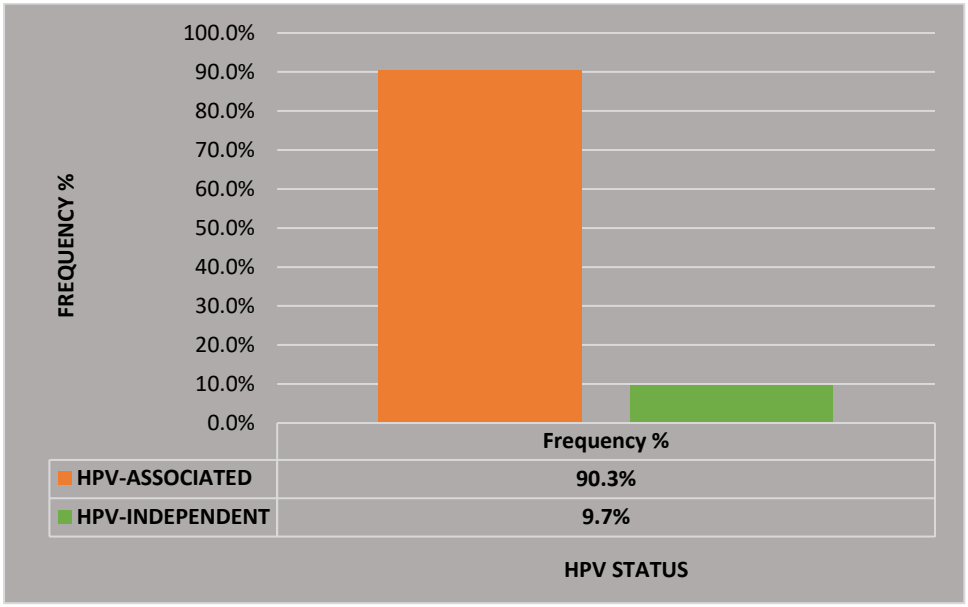

3.4.3 Figure 3. Bar chart illustrating the frequency of endocervical carcinoma subtypes

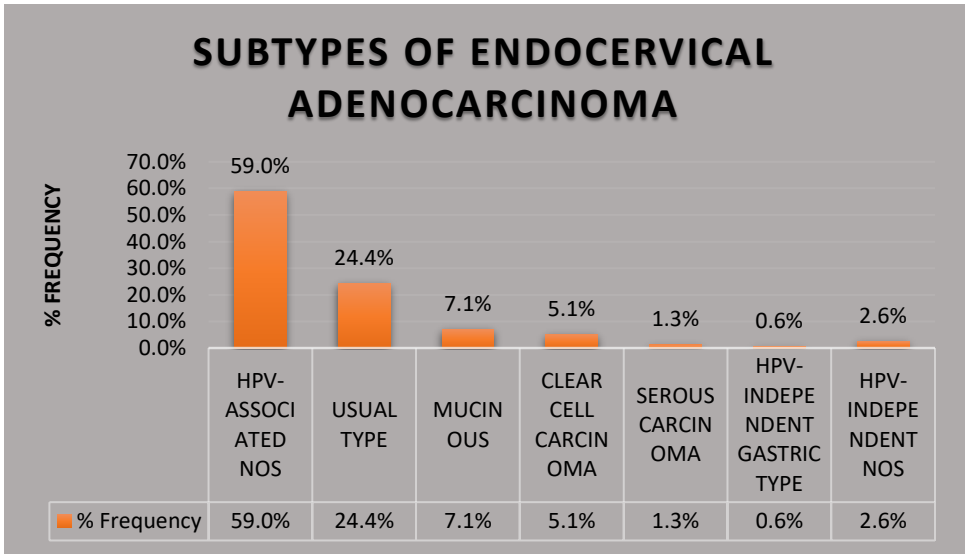

***Usual type including villoglandular.**

***Mucinous including mucinous nos, signet ring cell type, and intestinal type.**

3.5 REFERENCES

1. Sahdev A. Cervical Tumors. Semin Ultrasound CT MRI [Internet]. 2010 Oct [cited 2019 May 16];31(5):399–413. Available from: https://linkinghub.elsevier.com/retrieve/pii/S0887217110000624

2. Bhatla N, Aoki D, Sharma DN, Sankaranarayanan R. Cancer of the cervix uteri. Int J Gynecol Obstet [Internet]. 2018 Oct [cited 2019 Jun 26]; 143:22–36. Available from: http://doi.wiley.com/10.1002/ijgo.12611

3. Sachan P, Singh M, Patel M, Sachan R. A Study on Cervical Cancer Screening Using Pap Smear Test and Clinical Correlation. Asia-Pac J Oncol Nurs [Internet]. 2018 [cited 2021 Oct 22];5(3):337. Available from: http://www.apjon.org/text.asp?2018/5/3/337/233625

4. Simcock B, Shafi M. Invasive cancer of the cervix. Obstetrics, Gynaecology and Reproductive Medicine. 2007;17(6):181-187. Available from https://doi.org/10.1016/j.ogrm.2013.08.005

5. Small W, Bacon MA, Bajaj A, Chuang LT, Fisher BJ, Harkenrider MM, et al. Cervical cancer: A global health crisis. Cancer [Internet]. 2017 [cited 2019 Jun 25];123(13):2404–12. Available from: https://onlinelibrary.wiley.com/doi/abs/10.1002/cncr.30667

6. Bhatla N, Berek JS, Cuello Fredes M, Denny LA, Grenman S, Karunaratne K, et al. Revised FIGO staging for carcinoma of the cervix uteri. Int J Gynecol Obstet [Internet]. 2019 Apr [cited 2019 Jun 2];145(1):129–35. Available from: https://onlinelibrary.wiley.com/doi/abs/10.1002/ijgo.12749

7. Kanthiya K, Khunnarong J, Tangjitgamol S, Tanvanich S. Expression of the p16 and Ki67 in Cervical Squamous Intraepithelial Lesions and Cancer. Asian Pac J Can Prev, 17(7):3201-3206. Available from https://journal.waocp.org/article_32497_5c3683eef3090fe38e38ab1ac782957c.pdf

8. Bray F, Ferlay J, Soerjomataram I, Siegel RL, Torre LA, Jemal A. Global cancer statistics 2018: GLOBOCAN estimates of incidence and mortality worldwide for 36 cancers in 185 countries. CA Cancer J Clin [Internet]. 2018 Nov 1 [cited 2019 May 30];68(6):394–424. Available from: https://onlinelibrary.wiley.com/doi/abs/10.3322/caac.21492

9. Swapnajaswanth M, Suman G, Suryanarayana SP, Murthy NS. Perception and Practices on Screening and Vaccination for Carcinoma Cervix among Female Healthcare Professional in Tertiary Care Hospitals in Bangalore, India. Asian Pac J Cancer Prev [Internet]. 2014 Aug 15 [cited 2021 Oct 22];15(15):6095–8. Available from: http://koreascience.or.kr/journal/view.jsp?kj=POCPA9&py=2014&vnc=v15n15&sp=6095

10. Moodley J, Kawonga M, Bradley J, Hoffman M. Challenges in implementing a cervical screening program in South Africa. Cancer Detect Prev [Internet]. 2006 Jan [cited 2022

Feb 26];30(4):361–8. Available from: https://linkinghub.elsevier.com/retrieve/pii/S0361090X06001103

11. Pelkofski E, Stine J, Wages NA, Gehrig PA, Kim KH, Cantrell LA. Cervical Cancer in Women Aged 35 Years and Younger. Clin Ther [Internet]. 2016 Mar [cited 2019 May 16];38(3):459–66. Available from: https://linkinghub.elsevier.com/retrieve/pii/S0149291816300510

12. Ganesan R. HPV-related cervical glandular lesions. Diagn Histopathol [Internet]. 2018 Jan [cited 2019 May 16];24(1):18–25. Available from: https://linkinghub.elsevier.com/retrieve/pii/S1756231717301846

13. Cohen PA, Jhingran A, Oaknin A, Denny L. Cervical cancer. The Lancet [Internet]. 2019 Jan [cited 2019 May 16];393(10167):169–82. Available from: https://linkinghub.elsevier.com/retrieve/pii/S014067361832470X

14. World Health Organization, World Health Organization, Reproductive Health and Research. Comprehensive cervical cancer control: a guide to essential practice. [Internet]. 2014 [cited 2019 May 30]. Available from: http://apps.who.int/iris/bitstream/10665/144785/1/9789241548953_eng.pdf?ua=1

15. Goodman A. HPV testing as a screen for cervical cancer. BMJ [Internet]. 2015 Jun 30 [cited 2019 Aug 9];350:h2372. Available from: https://0-www-bmj-com.innopac.wits.ac.za/content/350/bmj.h2372

16. Kyrgiou M, Shafi MI. Invasive cancer of the cervix. Obstetrics, Gynaecology and Reproductive Medicine. 2010;20(5):147-154. Available from https://api.semanticscholar.org/CorpusID:44646928

17. Stolnicu S, Hoang L, Soslow RA. Recent advances in invasive adenocarcinoma of the cervix. Virchows Arch [Internet]. 2019 Nov [cited 2021 Jul 26];475(5):537–49. Available from: http://link.springer.com/10.1007/s00428-019-02601-0

18. Chakravarty J, Chourasia A, Thakur M, Singh A, Sundar S, Agrawal N. Prevalence of human papillomavirus infection & cervical abnormalities in HIV-positive women in eastern India. Indian J Med Res [Internet]. 2016 [cited 2021 Oct 22];143(1):79. Available from: http://www.ijmr.org.in/text.asp?2016/143/1/79/178614

19. Marth C, Landoni F, Mahner S, McCormack M, Gonzalez-Martin A, Colombo N. Cervical cancer: ESMO Clinical Practice Guidelines for diagnosis, treatment and follow-up†. Ann Oncol [Internet]. 2017 Jul [cited 2019 Jul 24];28(suppl_4):iv72–83. Available from: https://academic.oup.com/annonc/article-lookup/doi/10.1093/annonc/mdx220

20. Choi YJ, Park JS. Clinical significance of human papillomavirus genotyping. J Gynecol Oncol [Internet]. 2016 Mar [cited 2019 Jul 6];27(2). Available from: https://www.ncbi.nlm.nih.gov/pmc/articles/PMC4717226/

21. Biryukov J, Meyers C. Papillomavirus Infectious Pathways: A Comparison of Systems. Viruses [Internet]. 2015 Aug 4 [cited 2019 Aug 28];7(8):4303–25. Available from: http://www.mdpi.com/1999-4915/7/8/2823

22. Chen AA, Gheit T, Franceschi S, Tommasino M, Clifford GM. Human Papillomavirus 18 Genetic Variation and Cervical Cancer Risk Worldwide. Banks L, editor. J Virol [Internet]. 2015 Oct 15 [cited 2019 Jul 14];89(20):10680–7. Available from: http://jvi.asm.org/lookup/doi/10.1128/JVI.01747-15

23. Khorasanizadeh F, Hassanloo J, Khaksar N, Mohammad Taheri S, Marzaban M, H. Rashidi B, et al. Epidemiology of cervical cancer and human papilloma virus infection among Iranian women — Analyses of national data and systematic review of the literature. Gynecol Oncol [Internet]. 2013 Feb [cited 2019 May 31];128(2):277–81. Available from: https://linkinghub.elsevier.com/retrieve/pii/S0090825812008980

24. Botha MH, Dochez C. Introducing human papillomavirus vaccines into the health system in South Africa. Vaccine [Internet]. 2012 Sep [cited 2019 May 31];30:C28–34. Available from: https://linkinghub.elsevier.com/retrieve/pii/S0264410X12004082

25. Doorbar J, Egawa N, Griffin H, Kranjec C, Murakami I. Human papillomavirus molecular biology and disease association: Human papillomavirus. Rev Med Virol [Internet]. 2015 Mar [cited 2019 Jul 14];25:2–23. Available from: http://doi.wiley.com/10.1002/rmv.1822

26. Park KJ. Neoplastic Lesions of the Cervix. Surg Pathol Clin [Internet]. 2011 Mar [cited 2019 May 31];4(1):17–86. Available from: https://linkinghub.elsevier.com/retrieve/pii/S1875918110002564

27. Burd EM. Human Papillomavirus Laboratory Testing: the Changing Paradigm. Clin Microbiol Rev [Internet]. 2016 Apr [cited 2019 Jul 6];29(2):291–319. Available from: https://www.ncbi.nlm.nih.gov/pmc/articles/PMC4786885/

28. Blair AR, Casas CM. Gynecologic Cancers. Prim Care Clin Off Pract [Internet]. 2009 Mar [cited 2019 May 31];36(1):115–30. Available from: https://linkinghub.elsevier.com/retrieve/pii/S0095454308000961

29. Brusselaers N, Shrestha S, van de Wijgert J, Verstraelen H. Vaginal dysbiosis and the risk of human papillomavirus and cervical cancer: systematic review and meta-analysis. Am J Obstet Gynecol [Internet]. 2018 Dec [cited 2019 May 31];S000293781832221X. Available from: https://linkinghub.elsevier.com/retrieve/pii/S000293781832221X

30. An HJ, Kim KR, Kim IS, Kim DW, Park MH, Park IA, et al. Prevalence of human papillomavirus DNA in various histological subtypes of cervical adenocarcinoma: a population-based study. Mod Pathol [Internet]. 2005 Apr [cited 2019 Jun 11];18(4):528–34. Available from: http://www.nature.com/articles/3800316

31. Bloem P, Ogbuanu I. Vaccination to prevent human papillomavirus infections: From promise to practice. PLOS Med [Internet]. 2017 Jun 27 [cited 2021 Oct 22];14(6):e1002325. Available from: https://dx.plos.org/10.1371/journal.pmed.1002325

32. Sundström K, Elfström KM. Advances in cervical cancer prevention: Efficacy, effectiveness, elimination? PLOS Med [Internet]. 2020 Jan 28 [cited 2021 Oct 22];17(1):e1003035. Available from: https://dx.plos.org/10.1371/journal.pmed.1003035

33. La Russa M, Jeyarajah AR. Invasive cervical cancer in pregnancy. Best Pract Res Clin Obstet Gynaecol [Internet]. 2016 May [cited 2019 May 16];33:44–57. Available from: https://linkinghub.elsevier.com/retrieve/pii/S1521693415001844

34. World Health Organization, International Agency for Research on Cancer. Female genital tumours. 5th ed. Vol. 4. Lyon, France: WHO Press; 2020.

35. Young RH, Clement PB. Endocervical adenocarcinoma and its variants: their morphology and differential diagnosis. Histopathology [Internet]. 2002 Sep [cited 2019 May 16];41(3):185–207. Available from: http://doi.wiley.com/10.1046/j.1365-2559.2002.01462.x

36. Human papillomavirus (HPV) and cervical cancer [Internet]. [cited 2019 May 30]. Available from: https://www.who.int/news-room/fact-sheets/detail/human-papillomavirus-(hpv)-and-cervical-cancer

37. Stolnicu S, Park KJ, Kiyokawa T, Oliva E, McCluggage WG, Soslow RA. Tumor Typing of Endocervical Adenocarcinoma: Contemporary Review and Recommendations From the International Society of Gynecological Pathologists. Int J Gynecol Pathol [Internet]. 2021 Mar [cited 2021 Nov 30];40(Supplement 1):S75–91. Available from: https://journals.lww.com/10.1097/PGP.0000000000000751

38. Turashvili G, Park KJ. Cervical Glandular Neoplasia. Surg Pathol Clin [Internet]. 2019 Jun [cited 2019 May 16];12(2):281–313. Available from: https://linkinghub.elsevier.com/retrieve/pii/S1875918119300042

39. Alvarado-Cabrero I, Parra-Herran C, Stolnicu S, Roma A, Oliva E, Malpica A. The Silva Pattern-based Classification for HPV-associated Invasive Endocervical Adenocarcinoma and the Distinction Between In Situ and Invasive Adenocarcinoma: Relevant Issues and Recommendations From the International Society of Gynecological Pathologists. Int J Gynecol Pathol [Internet]. 2021 Mar [cited 2021 Nov 30];40(Supplement 1):S48–65. Available from: https://journals.lww.com/10.1097/PGP.0000000000000735

40. Park KJ, Roma AA. Pattern based classification of endocervical adenocarcinoma: a review. Pathology (Phila) [Internet]. 2018 Feb [cited 2019 May 16];50(2):134–40. Available from: https://linkinghub.elsevier.com/retrieve/pii/S0031302517303859

41. Rutgers JK, Roma AA, Park KJ, Zaino RJ, Johnson A, Alvarado I, Daya D, Rasty G, Longacre TA, Ronnett BM, Silva EG. Pattern classification of endocervical adenocarcinoma: reproducibility and review of criteria. Mod Pathol. 2016 Sep;29(9):1083-94. Available from: doi: 10.1038/modpathol.2016.94. Epub 2016 Jun 3. PMID: 27255163; PMCID: PMC5506840.

42. Pirog EC. Cervical Adenocarcinoma: Diagnosis of Human Papillomavirus–Positive and Human Papillomavirus–Negative Tumors. Arch Pathol Lab Med [Internet]. 2017 Jun 23 [cited 2019 Jun 26];141(12):1653–67. Available from: https://www.archivesofpathology.org/doi/10.5858/arpa.2016-0356-RA

43. Wang D, Zhao C, Fu L, Liu Y, Zhang W, Xu T. Primary Clear Cell Adenocarcinoma of the Cervix: A Clinical Analysis of 18 Cases without Exposure to Diethylstilbestrol.

Obstet Gynecol Int [Internet]. 2019 Mar 26 [cited 2019 Jun 25];2019. Available from: https://www.ncbi.nlm.nih.gov/pmc/articles/PMC6458873/

44. Castle PE, Pierz A, Stoler MH. A systematic review and meta-analysis on the attribution of human papillomavirus (HPV) in neuroendocrine cancers of the cervix. Gynecol Oncol [Internet]. 2018 Feb [cited 2019 May 31];148(2):422–9. Available from: https://linkinghub.elsevier.com/retrieve/pii/S0090825817315482

45. Howitt BE, Kelly P, McCluggage WG. Pathology of Neuroendocrine Tumours of the Female Genital Tract. Curr Oncol Rep [Internet]. 2017 Sep 1 [cited 2019 Jun 25];19(9):59. Available from: https://0-link-springer-com.innopac.wits.ac.za/article/10.1007/s11912-017-0617-2

46. Kim M, Lee C, Choi H, Ko JK, Kang G, Chun K chul. Carcinosarcoma of the uterine cervix arising from Müllerian ducts. Obstet Gynecol Sci [Internet]. 2015 May [cited 2019 Jun 25];58(3):251–5. Available from: https://www.ncbi.nlm.nih.gov/pmc/articles/PMC4444523/

47. Kamura T, Ushijima K. Chemotherapy for advanced or recurrent cervical cancer. Taiwan J Obstet Gynecol [Internet]. 2013 Jun [cited 2019 May 31];52(2):161–4. Available from: https://linkinghub.elsevier.com/retrieve/pii/S1028455913000594

48. Gadducci A, Guerrieri ME, Cosio S. Adenocarcinoma of the uterine cervix: Pathologic features, treatment options, clinical outcome and prognostic variables. Crit Rev Oncol Hematol [Internet]. 2019 Mar [cited 2019 May 16];135:103–14. Available from: https://linkinghub.elsevier.com/retrieve/pii/S1040842818304177

49. Missaoui N, Trabelsi A, Landolsi H, Jaidaine L, Korbi S, Hmissa S. Cervical Adenocarcinoma and Squamous Cell Carcinoma Incidence Trends among Tunisian Women. Asian Pacific J Cancer Prev 2010;11:777-780. Available from article_25281_2f97b8a6c75bed2bc3ba1b6515700f47.pdf (waocp.org)

50. Bray F. Incidence Trends of Adenocarcinoma of the Cervix in 13 European Countries. Cancer Epidemiol Biomarkers Prev [Internet]. 2005 Sep 1 [cited 2021 Jul 26];14(9):2191–9. Available from: http://cebp.aacrjournals.org/cgi/doi/10.1158/1055-9965.EPI-05-0231

51. Knegt Y. Audit of Cervical Cancer Screening and Colposcopy Attendance in Rural South Africa. African Journal of Reproductive Health December 2014; 18(4):70-78. Available from https://typeset.io/papers/audit-of-cervical-cancer-screening-and-colposcopy-attendance-2wkoz7h2wv

52. Moodley M. Cervical cancer in Southern Africa: The challenges. South Afr J Gynaecol Oncol [Internet]. 2009 Jan [cited 2021 Jul 26];1(1):11–3. Available from: https://www.tandfonline.com/doi/full/10.1080/20742835.2009.11441128

53. J. Moodley MH. Cervical cancer in South Africa: challenges and opportunities. Cancer Detect Prev. 2006;30:361–368. Available from https://doi.org/10.1016/j.cdp.2006.07.005

54. Dreyer G, Maske C, Stander M. Clinical evaluation and budget impact analysis of cervical cancer screening using cobas 4800 HPV screening technology in the public

sector of South Africa. Shankar EM, editor. PLOS ONE [Internet]. 2019 Sep 11 [cited 2021 Jul 29];14(9):e0221495. Available from: https://dx.plos.org/10.1371/journal.pone.0221495

55. Ports KA, Haffejee F, Mosavel M, Rameshbabu A. Integrating cervical cancer prevention initiatives with HIV care in resource-constrained settings: A formative study in Durban, South Africa. Glob Public Health [Internet]. 2015 Nov 26 [cited 2021 Jul 29];10(10):1238–51. Available from: http://www.tandfonline.com/doi/full/10.1080/17441692.2015.1008021

56. Uchiyama M, Iwasaka T, Matsuo N, Hachisuga T, Mori M, Sugimori H. Correlation between Human Papillomavirus Positivity and p53 Gene Overexpression in Adenocarcinoma of the Uterine Cervix. Gynecol Oncol [Internet]. 1997 Apr 1 [cited 2021 Aug 1];65(1):23–9. Available from: https://doi.org/10.1006/gyno.1997.4613

57. Sekirime WK, Gray R. HIV infection among Uganda women with cervical cancer: a retrospective study. Gynecol Obstet Invest. 2007;(63):222–8. Available from http://dx.doi.org/10.1159/000098197

58. Kahesa C, Mwaiselage J, Wabinga HR. Association between invasive cancer of the cervix and HIV-1 infection in Tanzania: the need for dual screening. BMC Public Health. 2008 Jul;(30;8):262. Available from: doi: 10.1186/1471-2458-8-262. PMID: 18664298; PMCID: PMC2527006.

59. Odida M, Sandin S, Mirembe F, Kleter B, Quint W, Weiderpass E. HPV types, HIV and invasive cervical carcinoma risk in Kampala, Uganda: a case-control study. Infect Agent Cancer [Internet]. 2011 [cited 2021 Aug 1];6(1):8. Available from: http://infectagentscancer.biomedcentral.com/articles/10.1186/1750-9378-6-8

60. Palefsky J. Biology of HPV in HIV infection. Adv Dent Res. 2006 Apr;1(19(1)):99-105. Available from: doi: 10.1177/154407370601900120. PMID: 16672559.

61. Silverberg MJ, Leyden WA, Chi A, Gregorich S, Huchko MJ, Kulasingam S, et al. Human Immunodeficiency Virus (HIV)– and Non-HIV–Associated Immunosuppression and Risk of Cervical Neoplasia. Obstet Gynecol [Internet]. 2018 Jan [cited 2021 Aug 1];131(1):47–55. Available from: https://journals.lww.com/00006250-201801000-00007

APPENDIX 1: DATA COLLECTION SHEET

Study no	Age	Sex	HIV P/N/UN	CD4 Count	Pap smear L-SIL/H-SIL/GPIN	ECC HS	HPV R/NR

KEYS:

P = Positive

N = Negative

UN = Unknown

L-SIL = Low grade squamous intraepithelial lesion

H-SIL =High grade squamous intraepithelial lesion

EGPIN= Endocervical glandular intraepithelial neoplasia

ECC = Endocervical cancer

HS = Histological subtype

HPV = Human papilloma virus

R = Related

NR = Non-related

APPENDIX 2: ETHICS APPROVAL

UNIVERSITY OF THE WITWATERSRAND, JOHANNESBURG

R14/49 Dr Seipati Bulane

HUMAN RESEARCH ETHICS COMMITTEE (MEDICAL)

CLEARANCE CERTIFICATE NO. M191161

NAME: (Principal Investigator)	Dr Seipati Bulane
DEPARTMENT:	Anatomical Pathology Charlotte Maxeke Johannesburg Academic Hospital National Health Laboratory Services
PROJECT TITLE:	Subtypes of endocervical carcinoma: A retrospective, observational study at Charlotte Maxeke Johannesburg Academic Hospital (2017-2019)
DATE CONSIDERED:	29/11/2019
DECISION:	Approved unconditionally
CONDITIONS:	
SUPERVISOR:	Dr Reubina Wadee
APPROVED BY:	Dr CB Penny, Chairperson, HREC (Medical)
DATE OF APPROVAL:	29/11/2019

This clearance certificate is valid for 5 years from date of approval. Extension may be applied for.

DECLARATION OF INVESTIGATORS

To be completed in duplicate and **ONE COPY** returned to the Research Office Secretary on the Third Floor, Faculty of Health Sciences, Phillip Tobias Building, 29 Princess of Wales Terrace, Parktown, 2193, University of the Witwatersrand. I/we fully understand the conditions under which I am/we are authorized to carry out the above-mentioned research and I/we undertake to ensure compliance with these conditions. Should any departure be contemplated, from the research protocol as approved, I/we undertake to resubmit the application to the Committee. **I agree to submit a yearly progress report**. The date for annual re-certification will be one year after the date of convened meeting where the study was initially reviewed. In this case, the study was initially reviewed in **November** and will therefore be due in the month of **November** each year. Unreported changes to the application may invalidate the clearance given by the HREC (Medical).

Principal Investigator Signature

Date 01/12/2019

PLEASE QUOTE THE PROTOCOL NUMBER IN ALL ENQUIRIES

APPENDIX 3: TURN IT IN ORIGINALITY REPORT

0700457H MMED-1.docx

ORIGINALITY REPORT

13% 8% 11% %

SIMILARITY INDEX INTERNET SOURCES PUBLICATIONS STUDENT PAPERS

PRIMARY SOURCES

1	www.ncbi.nlm.nih.gov Internet Source	2%
2	"Gynecologic Pathology", Springer Science and Business Media LLC, 2023 Publication	1%
3	Pushp L Sachan, Meenakshi Singh, Munna L Patel, Rekha Sachan. "A Study on Cervical Cancer Screening Using Pap Smear Test and Clinical Correlation", Asia-Pacific Journal of Oncology Nursing, 2018 Publication	1%

4 Rutgers, Joanne K L, Andres A Roma, Kay J Park, Richard J Zaino, Abbey Johnson, Isabel Alvarado, Dean Daya, Golnar Rasty, Teri A Longacre, Brigitte M Ronnett, and Elvio G Silva. "Pattern classification of endocervical adenocarcinoma: reproducibility and review of criteria", Modern Pathology, 2016. Publication	1%
5 journals.lww.com Internet Source	1%
6 F. Bray. "Incidence Trends of Adenocarcinoma of the Cervix in 13 European Countries", Cancer Epidemiology Biomarkers & Prevention, 2005 Publication	1%
7 wiredspace.wits.ac.za Internet Source	<1%
8 documents.cap.org Internet Source	<1%
9 W Glenn McCluggage, Naveena Singh, C Blake Gilks. " Key changes to the world health organisation (who) classification of female genital tumours introduced in the 5 edition (2020) ", Histopathology, 2022 Publication	<1%

10 Essentials of Anatomic Pathology, 2016. Publication	<1%
11 Kay J. Park, Andres A. Roma. "Pattern based classification of endocervical adenocarcinoma: a review", Pathology, 2018 Publication	<1%
12 Simona Stolnicu, Lien Hoang, Robert A. Soslow. "Recent advances in invasive adenocarcinoma of the cervix", Virchows Archiv, 2019 Publication	<1%
medicinesfakianakis.blogspot.com 13 Internet Source	<1%
14 Maria Arafah, Sameera Rashid, Asma Tulbah, Mohammed Akhtar. "Carcinomas of the Uterine Cervix: Comprehensive Review With An Update on Pathogenesis, Nomenclature of Precursor and Invasive Lesions, and Differential Diagnostic Considerations", Advances in Anatomic Pathology, 2021 Publication	<1%
15 dspace.unza.zm Internet Source	<1%

16	www.frontiersin.orgInternet Source	<1%
17	www.mskcc.orgInternet Source	<1%
18	Raji Ganesan. "HPV-related cervical glandular lesions", Diagnostic Histopathology, 2018 Publication	<1%
19	d.docksci.comInternet Source	<1%
20	mdpi-res.comInternet Source	<1%
21	Burcak Cakir Pekoz, Okan Dilek, Tolga Koseci,Zeynel Abidin Tas, Oktay Irkorucu, Bozkurt Gulek. "Can peritumoral edema evaluated by Magnetic Resonance Imaging before neoadjuvant chemotherapy predict complete pathological response in breast cancer?", Scottish Medical Journal, 2023 Publication	<1%
22	docshare.tipsInternet Source	<1%
23	www.duo.uio.noInternet Source	<1%

24	www.globalgiving.orgInternet Source	<1%
25	www.wits.ac.zaInternet Source	<1%
26	actascientific.comInternet Source	<1%
27	www.minervamedica.itInternet Source	<1%
28	scholar.sun.ac.zaInternet Source	<1%
29	enar.orgInternet Source	<1%
30	ijgc.bmj.comInternet Source	<1%
31	www.tjogonline.comInternet Source	<1%
32	"Gynecologic and Obstetric Pathology", Modern Pathology, 2017 Publication	<1%
33	hdl.handle.netInternet Source	<1%
34	link.springer.comInternet Source	<1%

35 www.researchgate.net Internet Source	<1%
36 Karen L. Talia, Richard Wing-Cheuk Wong, W. Glenn McCluggage. "Expression of Markers of Müllerian Clear Cell Carcinoma in Primary Cervical and Vaginal Gastric-type Adenocarcinomas", International Journal of Gynecological Pathology, 2019 Publication	<1%
37 Pier Selenica, Barbara Alemar, Cathleen Matrai, Karen L. Talia et al. "Massively parallel sequencing analysis of 68 gastric-type cervical adenocarcinomas reveals mutations in cell cycle-related genes and potentially targetable mutations", Modern Pathology, 2020 Publication	<1%
38 Pinar Bulutay, Nihan Haberal, Özlem Özen,Özlem Erdem et al. "Reproducibility of Morphologic Parameters of the International Endocervical Adenocarcinoma Criteria and Classification System and Correlation With Clinicopathologic Parameters: A MultiInstitutional Study", International Journal of Gynecological Pathology, 2022 Publication	<1%

39 Pirog, E.C.. "Diverse facets of cervical adenocarcinoma: comprehensive review of clinicopathologic features and diagnostic criteria", Diagnostic Histopathology, 201010 Publication	<1%
40 slideplayer.com Internet Source	<1%
41 vdoc.pub Internet Source	<1%
42 www.dovepress.com Internet Source	<1%
43 www.scielo.br Internet Source	<1%

Exclude quotes On

Exclude matches < 8 words

Exclude bibliography On