

https://dspace.org/

Pemphigus in black South Africans in the Johannesburg area

Bue, Eric Charan

2014-03-12
http://hdl.handle.net10539/14105

Downloaded from a DSpace repository. https://dspace.org/

PEMPHIGUS IN BLACK SOUTH AFRICANS IN THE JOHANNESBURG AREA

ERIC CHARAN BUE

PEMPHIGUS IN BLACK SOUTH AFRICANS IN THE JOHANNESBURG AREA

Eric Charan Bue

A research report submitted to the Faculty of Health Sciences, University of the Witwatersrand, in partial fulfilment of the requirements for the degree of Master of Medicine in Dermatology

Johannesburg, 1997

I, Eric Charan Bue declare that this research report is my my own work. It is being submitted for the Degree of Master of Medicine to the University of Witwatersrand, Johannesburg. It has not been submitted before for any degree or examination at this or any other University.

E.C. BUE

30th day of MARCH 1998 .

This research report is dedicated to my wife Tracy.

ABSTRACT

The purpose of this study was to investigate the prevalence of pemphigus in the black population in the Johannesburg area. Over a period of 8 years (1987-1995) 35 cases of pemphigus were diagnosed at the Baragwanath Hospital. They constituted approximately 0,3% of new dermatological patients seen during this time.

In each patient the diagnosis of pemphigus was confirmed by skin biopsies taken for both histological and immunofluorescence studies. Of the 35 cases, pemphigus foliaceus was diagnosed in 17 (48,6 %) and pemphigus vulgaris in 15 (42,9%). Pemphigus erythematosus was diagnosed in two cases (5,7%) and pemphigus vegetans in one (2,8%). The histological findings were diagnostic in 21 (60%) but equivocal in 14 (40%) cases. All cases had positive immunofluorescence. Direct immunofluorescence with IgG was positive in 91,4 % and C3 in 60%. In 14,7% of patients IgG alone was positive and in 20,6% both IgG andd C3 were positive. Indirect immunofluorescence was positive in 60% of patients.

ACKNOWLEDGMENTS

The assistance and guidance of my supervisor Prof. E.J. Schulz is greatly appreciated. The staff members of the Department of Anatomical Pathology of the University of the Witwatersrand and the South African Institute for Medical Research Johannesburg and Baragwanath Hospital assisted me with the collection of data from patient records. Ms Kirsten Rechenberg prepared the specimens of skin biopsies for immuno-fluorescence.

TABLE OF CONTENTS **Page**

DECLARATION ii

DEDICATION iii

ABSTRACT iv

ACKNOWLEDGEMENTS v

TABLE OF CONTENTS vi

LIST OF FIGURES viii

LIST OF TABLES ix

PREFACE x

INTRODUCTION 1

1. Definition and classification of pemphigus 1
2. History of pemphigus 2
3. Epidemiology of pemphigus 3
4. Clinical picture of pemphigus 5
5. Course, prognosis and treatment 9
6. Pathology, pathophysiology and diagnosis of pemphigus 11

Histopathology 11

Immunopathology 12

Pathophysiology 13

8. Associated diseases 15

PRESENT STUDY 16

1. Materials and Methods 16

2. Results 18

Clinical features and histopathology 20

Immunofluorescence 27

DISCUSSION 30

CONCLUSIONS 36

REFERENCES 38

LIST OF FIGURES

Figure	Page
1. Age of onset of pemphigus	19
2. Superficial blisters and scaling in a patient with pemphigus foliaceus	21
3. Deeper bullae in a patient with pemphigus vulgaris	22
4. Oral erosions in pemphigus vulgaris	23
5. Skin biopsy in pemphigus vulgaris: suprabasal acantholysis and bulla formation	25
6. Skin biopsy in pemphigus foliaceus: acntholysis in the granular layer and subcorneal bulla formation	26
7. Direct immunofluorescence : intercellular deposition of IgG throughout the epidermis	29

LIST OF TABLES

Table	Page
1. Type of pemphigus and sex ratio	18
2 .Age of onset of pemphigus	19
3. Positive immunofluorescence in pemphigus cases	28
5. Pemphigus : comparative data from other countries	32
6. Pemphigus in Africa - percentage of dermatological outpatients	33.

PREFACE

All types of pemphigus are rare and there are distinct racial and geographic differences in the occurrence of the various forms. For instance pemphigus vulgaris is most commonly seen in Ashkenazi Jews (1) while a form of pemphigus foliaceus is highly endemic in certain parts of Brazil (2).

There is little information about the occurrence of pemphigus in Africa in general and in South Africa in particular. In some African countries pemphigus foliaceus is the most common form (3) (4). South African data consists mainly of brief mention in reports on surveys of dermatological outpatients with little mention of the types of pemphigus encountered (5) (6). In particular there have been no previous reports from South Africa on immunofluorescnce findings which are essential for the accurate diagnosis and classification of pemphigus.

INTRODUCTION

1. Definition and classification of pemphigus

The term pemphigus refers to a group of intraepidermal diseases involving the skin and mucous membranes, characterized by disruption of the normal cell to cell adhesion. It is an autoimmune disease in which autoantibodies are produced against cell- surface proteins of stratified squaumous epithelium (7).

Pemphigus can be divided into two major types which differ in the level of cleavage within the epidermis. In pemphigus vulgaris the bullae develop just above the basal layer and in pemphigus foliaceus the bullae develop just below the stratum corneum in the granular layer (8). These two types have a number of variants as outlined in Table 1. A new type of pemphigus called paraneoplastic pemphigus, with unique clinical and immunopathologic features, has recently been described (9).

Table 1. Classification of pemphigus

PEMPHIGUS VULGARIS
Pemphigus vegetans
Drug induced pemphigus

PEMPHIGUS FOLIACEUS
Pemphigus erythematosus (Senear -Usher)
Fogo selvagem (Brazilian pemphigus)
Drug induced pemphigus foliaceus

PARANEOPLASTIC PEMPHIGUS

2. History of pemphigus

The word pemphigus is derived from the Greek "pemphix", meaning bubble. Hippocrates used the term "pemphigoides pyretoi" to describe a disease which was not characterized by blisters and thus probably did not represent true pemphigus (10) (11).

De Sauvages in 1760 was the first to apply the term pemphigus to describe a febrile disorder accompanied by an eruption of bullae. (11). The eruption lasted only two weeks and was probably not pemphigus but erythema multiforme. In 1791 Wichmann gave the name pemphigus to a chronic blistering disease that corresponds to what is today recognised as *pemphigus vulgaris* (11). In 1844 Cazenave described an exfoliative form of the disease recognized today as *pemphigus foliaceus* (9). In 1876 pemphigus vegetans was first described by Neumann (12). In 1889 Hallopeau described a patient with pustules and plaques which he called 'pyodermite vegetante", suggesting that it was a variant of pemphigus vegetans of Neumann (12).

In 1903 an epidemic form of blistering disease was described in the state of Sao Paolo, Brazil but these patients were misdiagnosed as having "tokelau" or tinea imbricata (2). The disease was later called "fogo selvagem", meaning "wild fire" in Portuguese (13). It was first regarded as a form of pemphigus foliaceus in 1905 (14).

Pemphigus erythematosus, also known as Senear- Usher sybdrome, was first reported in 1926 by Senear and Usher who described 11 cases which combined the features of pemphigus and lupus erythematosus (11).

Previously diseases such as bullous pemphigoid and benign mucous membrane pemphigoid, in which the bullae are sudepidermal, were included as types of pemphigus. However in 1953 Lever characterized pemphigus vulgaris as a distinct entity based on histopathologic features, clinical aspects and natural course (11).

In 1964 Beutner and Jordon provided the first clue to the pathogenesis of pemphigus by demonstrating that serum from patients with pemphigus contains autoantibodies that bind to an intercellular substance present in skin and mucosa (15).

3. Epidemiology of pemphigus

All types of pemphigus are rare. There is marked geographical and racial variation. The incidence of pemphigus in general varies from 0.76 per 1 000 000 in Finland (16) to 1.7 per 1 000 000 in France (17) and 4.2 per 1 000 000 in North America (18).

Pemphigus has been reported in many races (19). An increased prevalence has been observed in the Jewish population (18) (20), particularly in the Ashkenazi Jews (1).

In Africa pemphigus in the black population appears to be rare (21)

The incidence of ***pemphigus vulgaris*** is highest in the Jewish population. In Jerusalem it is reported as 1.62 per 100 000 (1) and in the Jewish population of Hartford County Connecticut as 3.2 per 100 000 (18). The incidence is higher in the

Ashkenazian (2.7 per 100 000) than in the non-Ashkenazian group (0.61 per 100000) (1). Pemphigus vulgaris is also the common type found in North America (84.1%), France (73%) (17), Thailand (62%) (23) and China (42.2%) (24). Pemphigus vulgaris is a disease that affects persons in middle and old age . The age of onset ranges between 12 and 88 years . The mean age of onset is in the sixth decade. The disease affects men and women equally (25).

In pemphigus vegetans, the mean age of onset for the Neumann type is 44 years and for the Hallopeau type is 45 years. The male to female ratio is 1 : 1.3 (26).

In some countries an endemic form of ***pemphigus foliaceus*** results in unusually high incidences. The incidence of endemic pemphigus foliaceus (fogo selvagem) in the whole of Brazil is 4.6 to 6.4 per 1000 000.(14) However in the rural areas, for example in Goias, the incidence of fogo selvagem in 1985 was reported as high as 50 per 1000 000 (14). Clusters of cases have been reported in Colombia (27), El Salvador (28), Peru and Paraquay (2). The population at risk for fogo selvagem includes young peasant children of either sex or any race who are exposed to the local ecology of the endemic region (13). In Brazil the mean age of onset is 30 years.(14) and in San Salvador it is 33.3 years (28).

Another endemic focus of pemphigus foliaceus was found in the Sousse area in Tunisia (3). The incidence initially was reported to be as high as 4 per 1 000 000

(3). A subsequent Tunisian study however found a much higher incidence of 6.7 per 1 000 000 per year (17). The general female to male ratio was 4 : 1, however among people aged beween 25 and 34, the female to male ratio was 52: 1.

4. Clinical picture and course of pemphigus

PEMPHIGUS VULGARIS

The primary lesion is a flaccid blister that may arise on normal or erythematous skin. The bullae are fragile and break easily leaving denuded areas that enlarge at the periphery. Frequently the denuded areas show at their periphery a collar of detached epidermis (11). A characteristic, but not diagnostic sign of pemphigus is Nikolsky's sign, produced when lateral pressure is applied to the edge of a blister or to normal appearing skin at the periphery of active lesions, resulting in shearing away of the epidermis (29). This sign is not specific for pemphigus vulgaris or pemphigus foliaceus, but is found in other active blistering diseases such as bullous pemphigoid, erythema multiforme, and certain variants of epidermolysis bullosa. The Asboe-Hansen sign is also frequently seen in pemphigus and is produced by applying pressure directly over an intact blister producing lateral spread of the lesion.(10) The skin lesions are rarely pruritic, except perhaps at times when crops of new bullae erupt (11). Pain caused by extensive denuded areas is severe and is similar to patients suffering thermal burns. Healing occurs without scar formation. Transient hyperpigmentation is common. Areas of prediction are the head and neck, trunk and intertriginous areas, for example, the axillae and groin.

Oral lesions are present in about 80% to 90% of all pemphigus vulgaris patients (1) (30). About 50% to 60% of patients initially present with oral lesions (1) (30). The interval between the onset of oral lesions and dissemination to glabrous skin is about 5 months (25). Blisters in the oral cavity are usually multiple, painful, persistent and superficial. Intact bullae are rarely seen because they break soon after formation. The resulting denuded areas enlarge with peripheral extension to involve large areas in the mouth. The denuded areas are often covered with a whitish exudate and bleed easily. The lesions also extend onto the vermilion border of the lips and are of particular diagnostic significance (11). The oral mucosa is often the site of recalcitrant lesions persisting even though the cutaneous disease has been successfully controlled (31). It is rare to see pemphigus in the oral cavity without subsequent skin involvement. Involvment of other mucous membranes may be seen in the pharynx, oesophagus, conjuctiva, larynx, urethra, vulva, cervix and rectal mucosa (29).

Pemphigus vegetans accounts for 1% to 2% of all cases of pemphigus.(26) Pemphigus vegetans has two clinical subtypes. the Neumann and Hallopeau type. The Newmann type has the more aggressive course. The lesions in the Newmann type begin as bullae and erosions like pemphigus vulgaris. However, whereas in pemphigus vulgaris the denuded areas heal with normal epidermis. the denuded areas in pemphigus vegetans heals with hypertrophic granulation tissue referred to as vegetations (11). The vegetations exude serum, bleed easily and are often studded with small pustules. The vegetations them become dry, verrucous and hyperkeratotic. Oral involvement is reported in 92% of cases (26). The vermilion border of the lips is frequently involved. Involvement of the tongue which has been termed the

cerebriform tongue, is characterized by a pattern of sulci and gyri on the dorsum of the tongue (10). The tongue is involved in 50% of cases of the Neumann type of pemphigus vegetans. The lesions in the Hallopeau type begin as pustules and not as bullae. The pustules rapidly develop into verrucous vegetations studded with pustules. The most common sites of involvement are the intertriginous areas especially the axillae and groin. Patients with the Hallopeau type have few relapses and usually remain in remission.

PEMPHIGUS FOLIACEUS

In pemphigus foliaceus, the bullae are small, flaccid, fragile and produce shallow erosions (29) This is accompanied by areas of erythema, scaling and crusting. The lesions develop first on the face, scalp and upper trunk. In the early stages, pemphigus foliaceus may mimic seborrheic dermatitis (10). In advance stages of the disease, sever exfoliation may occur resulting in an exfoliative erythroderma. Oral lesions are uncommon.

Fogo selvagem, or endemic pemphigus foliaceus may present as a localized or generalized form. The lesions of the localized form are distributed on seborrheic areas ot the face and trunk. It is characterized by superficial blisters and erosions. Lesions occur on the head and neck then spread acrally (2). They may resemble discoid lupus erythematosus, however the plaques lack follicular plugging, atrophy and hypopigmentation observed in the lesions of discoid lupus erythematosus. Patients with generalized fogo selvagem present with exfoliative erythroderma or with keratotic plaques and nodular lesions. Rarely are cases acute and fulminant with bullae erupting over a period of 1 to 3 weeks. Mucosal lesions are rarely observed.

PEMPHIGUS ERYTHEMATOSUS

The cutaneous lesions consist of well marginated erythematous, scaly hyperkeratotic, crusted plaques. The lesions develop in the seborrheic areas especially on the upper back and sternal region. The lesions often extend over the nose and malar area in a butterfly pattern (26). Mucous membrane involvement is rare as in pemphigus foliaceus.

OTHER, RARER FORMS OF PEMPHIGUS

Drug induced pemphigus

The causative drugs most commonly contain true thiol or sulphur groups that may be converted to thiols, for example, d-penicillamine, captopril and piroxicam (32). The development of pemphigus lesions is often preceded by a prodromal, non-specific, morbilliform, urticarial, annular or toxic erythematous eruptions. The clinical picture most frequently mimics pemphigus foliaceus but may resemble pemphigus erythematosus or pemphigus vulgaris (32).

Paraneoplastic pemphigus

The patients present with painful oral lesions refractory to standard therapies. Cutaneous lesions are pruritic and characteristically polymorphous. Erythematous papules forming target lesions with central blister formation and resembeling erythema multiforme is present on the trunk and extremities. In severe cases the patients may resemble toxic epidermal necrolysis (9).

5. Course, prognosis and treatment

Several prognistic indicators are important in determining the outcome of patients with pemphigus such as older age at onset, extent of diaease and progression of disease before onset of treatment (33) (10) (34). The dose of glucorticosteriods required to control the disease is another important indicator. Patients who require doses higher than 180 mg per day of prednisone have a poor prognosis (10). The clinical variant of pemphigus is important, pemphigus vulgaris has the worst prognosis and the highest mortality. Pemphigus foliaceus, fogo selvagem, pemphigus erythematosus and pemphigus vegetans generally run a more benign course (10). If the patient survives four years, the prognosis is better. (34).

The course of pemphigus is unpredictable. In a study published by Lever in 1977, 9,5% of patients died from complications of treatment and 7,9% died due to causes unrelated to the disease or treatment (35). Ultimately 38.1% achieved remission with no need for treatment. Fifteen percent required low dose maintenance treatment with glucocorticoids and/or immunosuppresants. Twenty seven percent had moderately active disease with continued relapses and remissions.

The prognosis of pemphigus was significantly altered by the introduction of glucocorticoids by Thorn and co-workers in 1950 (36). Since then they have become the mainstay of treatment for all forms of pemphigus (37).). Prior to the use of steroids the mortality of pemphigus was in the order of 60-90% (10) and most patients died within the first year (38). Since the introduction of steroids the mortality has dropped from 60-90% to between 15 and 45% (30) (39). Various treatment regimens are used, usually oral steroids in high initial doses. There is a marked difference in response between pemphigus vulgaris and pemphigus foliaceus, the latter being much easier to control (10) . When response to oral steroids is not adequate, pulse therapy with megadoses of steroids given intravenously may be tried (40).. High initial doses of steriods and long term treatment are needed and steroid side effects are a major cause of morbity and mortality. For this reason steroid sparing drugs are used in addition.

Adjuvant drugs used in pemphigus include the immunosuppressive agents cyclophosphamide, azathioprine, methotrexate and cyclosporin. (40). Cyclophoshamide appears to be the most efficacious immunosuppressive drug (40). Pasricha and co-workers induced remission in 37% of cases with a combination of pulsed corticosteroids and cyclophosphamide (41). Cyclosporin is useful for inducing rapid remission and for treating steroid resistant disease (42). Plasmapharesis is used for severe unresponsive cases (38). Other drugs such as dapsone (43) and antimalarials (32) may be useful in some cases of pemphigus foliaceus.

6. Pathology, pathophysiology and diagnosis of pemphigus

HISTOPATHOLOGY

Pemphigus vulgaris

The earliest histologic changes include oedema and disapperance of epidermal intercellular bridges. The histopathological hallmark of the disease is a process known as known as acantholysis, in which the cells of the lower epidermis just above the basal cell layer lose their normal cell-to-cell adhesion, resulting in the formation of a suprabasal intraepidermal bulla. The basal epidermal cells remain attached to the basement membrane, but lose the contact with their neighbours, resulting in a pattern likened to a "row of tombstones". A few acantholytic keratinocytes present in the blister cavity show degenerative changes, including a homogeneous cytoplasm with round, swollen hyperchromatic nuclei. Acantholysis may also extend to the epidermis of adnexal structures. Focal collections of eosinophils within the epidermis may be seen in some cases of early pemphigus vulgaris. The dermal infiltrated is generally minimal and when present often includes eosinophils (8).

Pemphigus vegetans

Suprabasal acantholysis as seen in pemphigus vulgaris is present, however in pemphigus vegetans lesions, there is epidermal hyperplasia, papillomatosis and prominent tissue eosinophilia. In addition, pemphigus vegetans lesions may show intraepidermal abscesses composed of eosinophils (8).

Pemphigus foliaceus

The cardinal histologic feature of pemphigus foliaceus is the presence of acantholysis just below the statum corneum and in the granular layer, resulting in the formation of a subcorneal intraepidermal vesicle. The blister may be filled with neutrophils and eosinophilic spongiosis may be present. (8)

Paraneoplastic pemphigus

Three features predominate in paraneoplastic pemphigus; suprabasilar intraepithelial acantholysis similar to pemphigus vulgaris, necrosis of individual keratinocytes that may resemble erythema multiforme, and a vacuolar interface dermatitis (9).

IMMUNOPATHOLOGY

Immunofluorescence microscopy

Immunofluorescence is a fluorescent laboratory technique for demonstrating the presence of antibodies in tissue or body fluids. There are two types of immunoflourescence used in dermatology : direct and indirect. Direct immunofluorescence is a technique used for demonstrating antibodies in tissue biopsy specimens. Indirect immunofluorescence is a technique used for demonstrating antibodies in serum. plasma and blister fluids.

Immunofluorescence plays an important role in the diagnosis of all forms of

pemphigus. The hallmark of pemphigus is the finding of IgG autoantibodies against the cell surface of keratinocytes (8). The demonstartion of linear IgG deposits in the intecellular spaces by direct immunofluorescence is considered to be a prerequisite for the diagnosis of pemphigus (10). The diagnosis of pemphigus should be seriously questioned if the direct immunofluorescence is negative. Deposition of IgG in the intercellular space is found in virtually 100 % of patients with active disease. In addition intercellular deposition of IgM, IgA and complement may also be present.

Eighty to ninety percent of patients with pemphigus manifest circulating antiepithelial cell surface IgG antibodies directed against the intercellular cement substance as demonstrated by indirect immunofluorescence (10). The intercellular immunofluorescence pattern is identical for all forms of pemphigus. In pemphigus erythematosus, in addition to the intercellular fluorescence there are also immunoreactants along the basement membrane zone, usually IgG and C3.

PATHOPHYSIOLOGY

Immunofluorescence is not only an important diagnostic test, but it also provided the first clue in establishing the mechanism for the disease. Beutner and Jordan provided the first evidence that autoimmune mechanisms played an important role in this disease (15). They demonstrated that patients with pemphigus vulgaris had circulating antibodies directed against the intercellular cement substance of skin and mucosa.. Pemphigus antibodies from both pemphigus vulgaris and pemphigus foliaceus are pathogenic. The pathophysiological role of pemphigus immunoglobulin

in the evolution of the disease was confirmed by Anhalt and co-workers. (44). They injected immunoglobulin fractions from 5 pemphigus patients into 36 neonatal Balb/c mice, 15 of which developed blisters which histologically and ultrastructurally resembled pemphigus vulgaris. The circulating antibodies bind to pemphigus antigens on the cell surrface, inducing acantholysis. Two pathways for acantholysis formation are proposed. In the first, acantholysis is induced by local stimulation of the plasminogen-plasmin system, which occurs independently of complement. The binding of pemphigus autoantibody to specific antigens on the surface of human epidermal cell stimulates production of plasminogen activator. The increase levels of plasminogen activator result in enhanced conversion of plasminogen to plasmin. Plasmin is responsible for degradation of cell adhesion molecules which causes breakdown of intercellular cement substance resulting in acantholysis (45). The second pathway, proposed by Kawana and co-workers, maintains that the pemphigus antibodies can fix complement, leading to altered cell membrane integrity that may then evoke acantholysis.(46)

Pemphigus antigens

The pemphigus antigens are complexes of adhering-junction molecules that belong to the family of adhesion glycoproteins called cadherins (32). These glycoproteins play a critical role in cell to cell adhesion in many cells. In pemphigus vulgaris, the target antigen is desmoglein 3, a 130 kDa transmembrane glycoprotein (32). In pemphigus foliaceus the target antigen is desmoglein 1, a 160 kDa transmembrane glycoprotein. Current data indicate that in paraneoplastic pemphigus there are a number of target antigens including desmoplakins I and II and a 230 kD bullous pemphigoid antigen(9).

Associated diseases

Pemphigus may be associated with a number of diseases, most frequently autoimmune disorders. These include rheumotoid arthritis (47), pernicious anaemia (48), Sjogrens syndrome (47), systemic lupus erythematosus (49) and Grave's disease (10) (50). The association of pemphigus with thymoma and/or myasthenia gravis has been reported in over thirty patients (51). About half are associated with pemphigus vulgaris and the other half are associated with pemphigus foliaceus or pemphigus erythematosus. Thymic abnormalities include benign or malignant thymoma or thymic hyperplasia and may precede or follow the onset of pemphigus.

In the past, pemphigus was thought to be associated with an increased risk of internal malignancy. In 1974 Krain reported that 54% of patients with pemphigus had a malignancy of the lymphoid or reticuloendothelial system (20). Several large studies have failed to confirm this observation, showing that only 2 - 3% of patients with pemphigus have an associated internal malignancy (30) (39). This is less than the expected incidence of malignancy for aged-matched controls. However, in a recent review of 60 cases of pemphigus and neoplasia, over half had a neoplasm of the immune system, with lymphoreticular malignancies predominating (52).

PRESENT STUDY

1. Materials and methods

The medical records of patients attending the Dermatology Outpatient Department at Baragwanath Hospital from January 1987 to January 1995 were reviewed. Patients were included in the study if the clinical diagnosis of pemphigus was confirmed by histopathological and immunofluorescence (IF) studies.

Skin biopsies were done under local anaesthesia using either a 3mm or 4mm punch. Two biopsies were done, one for routine paraffin embedding and haematoxylin and eosin (H&E) staining, and one for frozen section and immunofluorescence. Involved skin, preferrably an intact blister, was selected for H&E examination. Perilesional skin was biopsied for direct IF. At the same time blood was drawn into a plain red topped tube for indirect IF. . The skin for IF was placed into immunofluorescence transport medium containing Zeus fixative for a minimum time of one hour to a maximum time of 5 days in the refrigerator.

Specimens for frozen section were processed as follows: In the laboratory the tissue is transferred into a Zeus buffer wash solution and washed for a half an hour. The tissue core is then placed on the bottom of an embedding capsule and filled with an embedding medium, OCT compound. This is snap frozen in liquid nitrogen. The specimen is removed from the embedding capsule and attached to a cryostat chuck with a small amount of OCT compound. The specimen is cut into eight sectionseach of which is approxiamately 2 mm thick. Six of the specimens are placed into wells in a labelled slide for the direct IF.. Two skin sections are placed onto separate slides for

indirect IF. The slides are washed in phoshate buffered saline (PH 7.2) and placed on a magnetic stirrer for 15 minutes. This is repeated three times. Antisera, produced by Dako laboratories, consisting of fluorescein isothiocyanate conjugated rabbbit antihuman IgG, IgM, IgA C3 and fibrinogen are then prepared in the following dilutions: 1 : 40 dilution of albumin, IgG and fibrinogen and a 1 : 20 dilution of IgM, IgA and C3. The antisera are then pipetted onto the specimens and the slide is put into a moisture chamber for half an hour. The slide is then washed twice in phoshate buffered saline solution. A counterstain, Evans blue is applied and left on for 2 minutes.The Evans solution enhances the staining of tissue and prevents autofluorescence. The slide is washed in phoshate bufferes saline . A glycerine /buffer mixture is applied to a cover slip and this is mounted onto the slide. This mixture provides the correct refractive index for viewing the specimen with a fluorecent microscope.

The patient's blood and skin are used for indirect IF. The two sections of skin are washed in phosphate buffered saline and placed on a magnetic stirrer for 15 minutes. This is done three times. The patient's serum is diluted with phoshate buffered solution to a 1 : 10 dilution. The diluted serum is then applied to the skin sections for 30 minutes. The sections are then washed in buffer for 10 minutes This is done twice. A polyvalent fluorescein labelled antiserum diluted 1 : 10 is placed onto the sections for 30 minutes. It is then washed twice for 10 minutes in buffer. Evans blue counterstain is applied for 2 minutes then washed of with buffer. A cover slip with glycerine/buffer mixture is mounted onto the slide. If the slide is not viewed immediately it must be stored in a deep freeze..

The slides were examined using a Leitz fluorescent microscope.

RESULTS

During the 8 year period 1987-1995 a total of 35 cases fulfilled the necessary criteria for the diagnosis of pemphigus. A mean of 4.4 cases was seen per year. Of the cases 15 were diagnosed as pemphigus vulgaris, 17 as pemphigus foliaceus, 2 as pemphigus erythematosus and one as pemphigus vegetans. . Twenty six patients were female and 9 male. The type of pemphigus and sex ratio are shown in Table 1.

Table 1. Type of pemphigus and sex ratio

TYPE OF PEMPHIGUS	NUMBER OF PATIENTS	PERCENTAGE	SEX RATIO M:F
Pemphigus vulgaris	15	42.9	2 : 13
Pemphigus vegetans	1	2.8	1 : 0
Pemphigus foliaceus	17	48.6	6 : 11
Pemphigus erythematosus	2	5.7	0 : 2
TOTAL	35	100	9: 26 (1 : 2.9)

The age of onset ranged from 20 - 76 years with a mean age of onset of 46 years. Most patients presented in the third, fourth and fifth decade. (Fig. 1). The age range and mean age of onset for each type of pemphigus is shown in Table 2.

Table 2. Age of onset of pemphigus

TYPE OF PEMPHIGUS	AGE RANGE (YEARS)	MEAN (YEARS)
Pemphigus vulgaris	20-75	45
Pemphigus vegetans	21	21
Pemphigus foliaceus	26-76	51
Pemphigus erythematosus	24-43	29
TOTAL	20-76	46

The number of patients in each age group at onset of the disease is shown in Figure 1.

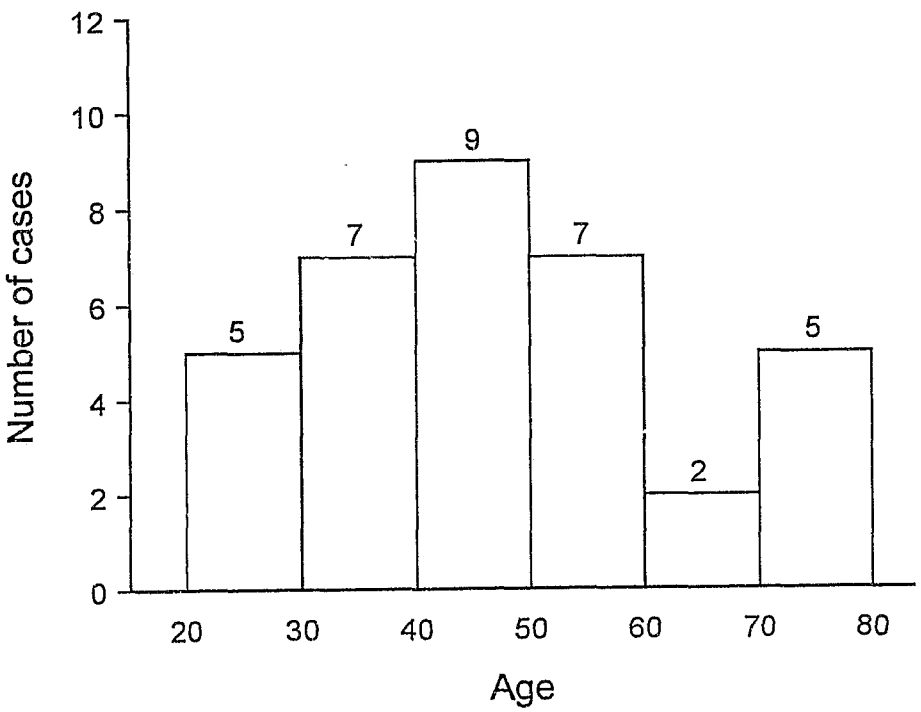

Figure 1. Age of onset of pemphigus

The time which elapsed between clinical onset of the disease and diagnosis varied from one week to 48 months, with a mean of 5 months.

Clinical features and histopathology

Four types of pemphigus were diagnosed on clinical grounds and confirmed by light microscopy and immunofluorescence. Of the 35 cases, 17 (48,6%) had pemphigus foliaceus, 15 (42,9%) pemphigus vulgaris, 2 (5,7%) pemphigus erythematosus and one (2,8%) pemphigus vegetans. (See Table 1).

The 17 patients with pemphigus foliaceus had superficial flaccid bullae surrounded by normal or erythematous skin, with erosions, scaling and crusting (see Fig. 2). The patients with pemphigus vulgaris tended to have visibly deeper bullae and erosions (see fig 3) although the distinction between the two types was somtimes not clinically obvious and required histological confirmation.

The most common sites of involvement for all types of pemphigus were the trunk (83%), face (35%) and scalp (30%). Figure 2 shows involvement of these sites in a patient with pemphigus foliaceus. Figure 3 illustrates involvement of the trunk in a patient with pemphigus vulgaris. Oral lesions, similar to those in Figure 3, occurred in 6 patients with pemphigus vulgaris (40%) and the one patient with pemphigus vegetans but were absent in the patients with pemphigus foliaceus and erythematosus.



Figure 2. Superficial blisters in a patient with pemphigus foliaceus



Figure 2. Superficial blisters in a patient with pemphigus foliaceus

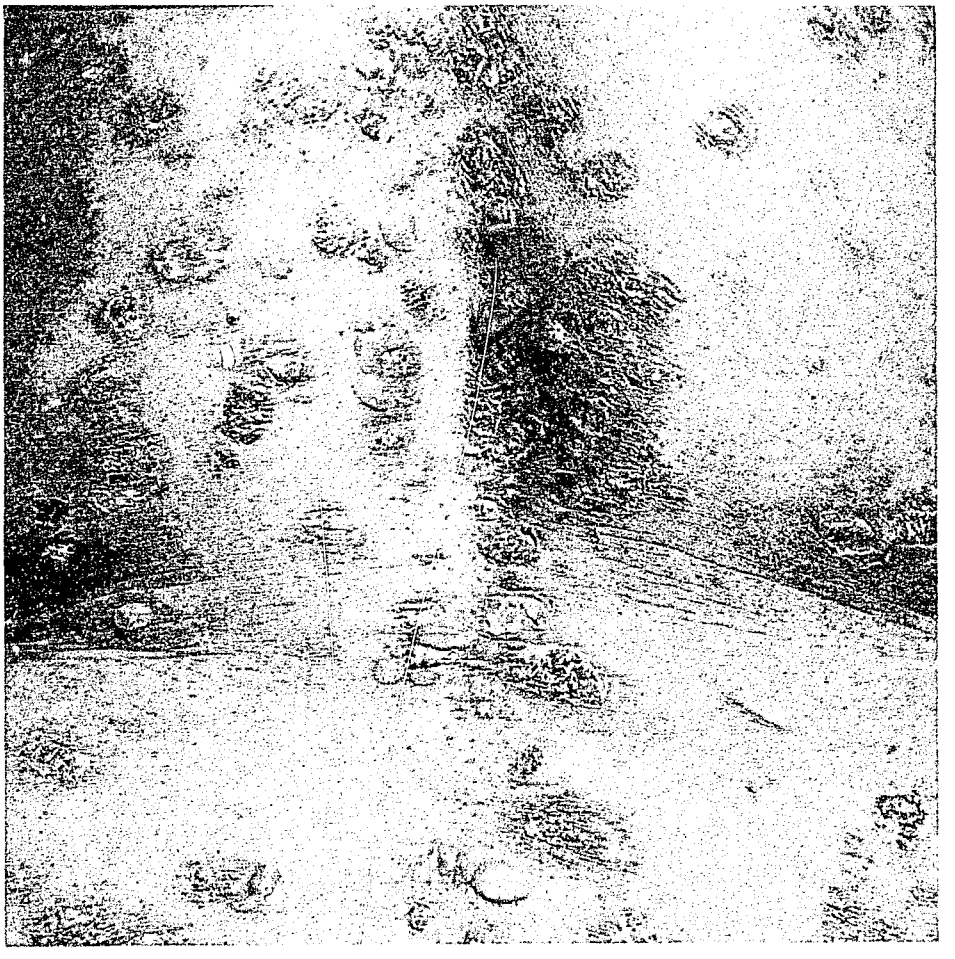

Figure 3. Deeper bullae in a patient with pemphigus vulgaris



Figure 4. Oral erosions in pemphigus vulgaris

Two patients were identified as having pemphigus erythematosus. The clinical features in one consisted of erythematous, crusted, scaling plaques in a seborrhoeic distribution. The second patient had erythematous plaques with post-inflammatory hyperpigmentation over the malar area of the face which resembled lesions of cutaneous lupus erythematosus. The patient also had symmetrical distal arthritis of the hands and alopecia of the scalp, both of which resmbled lupus erythematosus.

A patient diagnosed as pemphigus vegetans had verrucous crusted lesions on the face and trunk. He also had several oral ersions and ulcers, in keeping with pemphigus vegetans.

Histological features of pemphigus vulgaris consisting of suprabasal acantholysis and bulla formation was seen in 11 cases (73%) (See fig. 5). Subcorneal bullae and acantholysis in the granular layer was seen in 8 cases (47%) diagnosed as pemphigus foliaceus.(See Fig 6.)

In one of the two cases of pemphigus erythematosus a subcorneal bulla similar to that found in pemphigus foliaceus was seen. The diagnosis of pemphigus erythematosus was made on the presence of serum anti- nuclear antibodies and positive IF.

The one case of pemphigus vegetans showed a suprabasal bulla with acantholytic cells in the blister cavity and numerous eosinophils scattered throughout the hyperplastic epidermis.

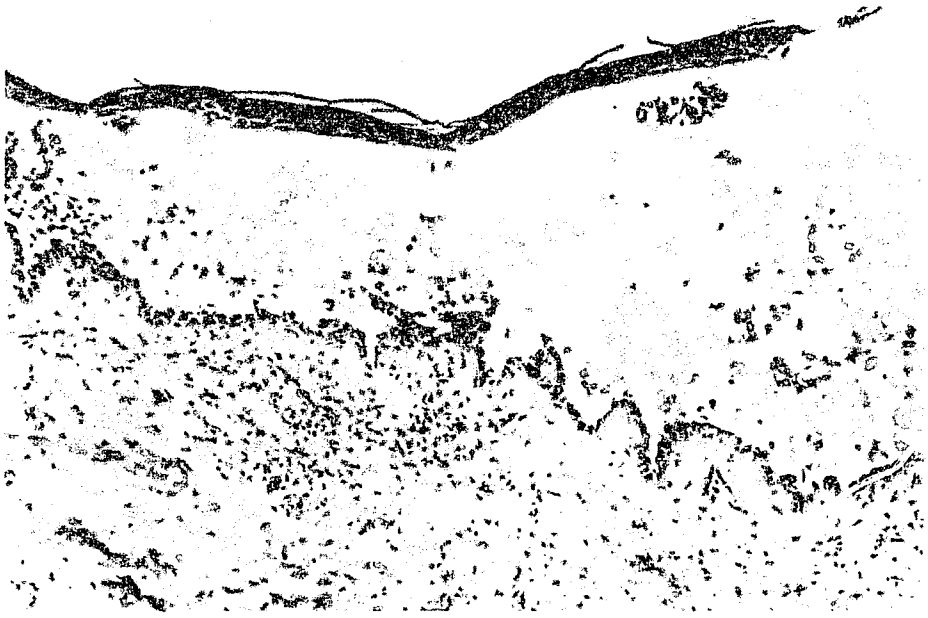

Figure 5. Skin biopsy in pemphigus vulgaris: suprabasal acantholysis and bulla formation



Figure 6. Skin biopsy in pemphigus foliaceus: acantholysis in the granular layer and subcorneal bulla formation

IMMUNOFLUORESCENCE

Either direct immunofluorescence or indirect immunofluorescence or both were positive in all 35 cases.

Direct IF, showing intercellular deposits throughout the epidermis (Fig. 4) was positive in 33 (94,3%). Deposits of IgG were present in 30 (85,7%), C3 in 21 (60%) and IgM in one patient (2,8%). No deposits of IgA were found in this study.

Intercellular deposits of IgG only were seen in 5 patients (14,2 %). Two patients (5,7%) demonstrated intercellular fluorescence with C3 alone. Both IgG and C3 were positive in 7 patients (20%)..

Indirect IF (patients serum on own skin) showed positive intercellualar fluorescence in 21 patients (60%). In two patients (one with pemphigus foliaceus, one with pemphigus erythematosus) i.e. 5,7% of cases, all direct IF tests were negative and intercellular fluorescence was seen only with indirect IF.

In addition to intercellular fluorescence, 3 patients (one with pemphigus vulgaris, 2 with pemphigus erythematosus) also demonstrated basement membrane zone fluorescence with direct and indirect IIF.

Direct IF in the two cases of pemphigus erythematosus demonstrated intercellular fluorescence as well as granular basement membrane fluorescence. Indirect IF

showed specled nuclear fluorescence in the epidermis in one of the cases.

The results of immunofluorescent studies are summarized in Table 3..

Table 3. Positive immunofluorescence in pemphigus cases

TYPE OF PEMPHIGUS	IgG	IgG + C3	C3	Indirect IF	IIF + IgG	IIF + C3	IIF + IgG + C3
Vulgaris n = 15	2	4	1		4	1	3
Vegetans n = 1							1
Foliaceus n = 17	3	3	1	1	1		8
Erythematosus n = 2				1	1		
TOTAL n = 35	5 14.3 %	7 20 %	2 5..7%	2 5.7 %	6 17.1 %	1 2.9 %	12 34.3 %

IF = mmunofluuoescence
IIF = indirect immunofluorescence

Iintercelluar fluorescence due to deposits of IgG on cell membranes throughout the epidermis is illustrated in Fig. 7

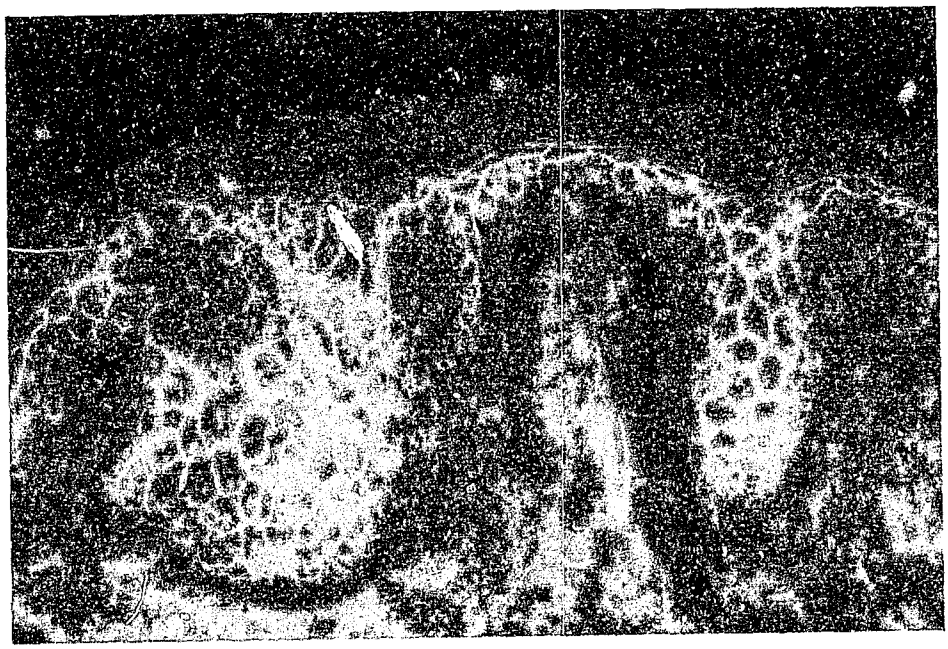

Figure 7. Direct immunofluorescence: intercellular deposition of IgG throughout the epidermis

DISCUSSION

Two major variants of pemphigus are recognized according to the level of acantholysis in the epidermis (8). Suprabasal clefting and bulla formation are characteristic features of pemphigus vulgaris. Pemphigus foliaceus and its variant pemphigus erythematosus are characterized by superficial subcorneal blister formation (8)..

All types of pemphigus are relatively rare, but there are marked geographical and racial variations. The incidence of pemphigus in general is 0.076 per 100 000 in Finland (16) and 0.42 per 100 000 in North America.(18). There is a particularly high incidence of 2.7 per 100 000 in Ashkenazi Jews, all cases being pemphigus vulgaris (1). Pemphigus vulgaris is also the most common type seen in North America (84.1%) (30) and Thailand (62%) (23). In our study pemphigus vulgaris accounted for 42.9% of cases.

In certain regions of South America. particularly Brazil (14) and Colombia (27) an endemic form of pemphigus foliaceus results in an unusually high prevalence of pemphigus in general. In Brazil the incidence of pemphigus foliaceus is 46 - 64 cases per 100 000, a prevalence at least five times higher than in North America (14). A similarly high incidence of pemphigus foliaceus of at least 40 cases per 100 000 is reported from Tunisia (3). Pemphigus foliaceus accounted for 48.6% of cases in our study, a relative incidence far less than that of the endemic type seen in San Salvador (78%) (28), Brazil (95,1%) (53) and in Tunisia (87%) (3)

Pemphigus erythematosus, the least common type also shows marked regional variations. In North American studies it is reported as occurring in 1.7% (20), 10.3% (30) and 30% of cases (39). In Thailand it is found in 4.1% of cases (23). It is unusually high in Finland where it accounts for 50% of cases (16). .In our study pemphigus erythematosus accounted for 5.6% of cases.

The prevalence of the various types of pemphigus in different countries is shown in Table 4 (page 32).

Table 4. Pemphigus:comparative data from other countries

COUNTRY	SEX RATIO	AGE		PEMPHIGUS	
	M : F	Range	Mean	Type	%
North America (30) n = 107	1 : 1	14 - 88		PV PF PE	84,1 5,6 10,3
South America (28) n = 23	1 : 4,7	16 - 70	33,3	PV PF PE	21,7 78,3
Europe (16) n = 82	0,9 : 1	9 - 85	57,5	PV PF PE	22,7 20,5 50
Asia (23) n = 98	1 : 1,3		42,95	PV PF PE	63,3 33,6 4,1
North Africa (3) n = 23		21 - 37	28	PV PF	13 87
South Africa [present study] n = 35	1 : 2.9	20 - 76	46	PV PF PE	42.9 48.6 5.7

PV = pemphigus vulgaris
PF = pemphigus foliaceus
PE = pemphigus erythematosus

There are few reports in the literature of the occurrence of pemphigus of any type in the Negroid race. In the United States only one out of 49 cases of pemphigus vulgaris reported by Krain was black (20). Only two out of 224 cases of pemphigus foliaceus and vulgaris from western Parana, Brazil, were black.(3). Reports of skin diseases in black patients in central and north Africa indicate that pemphigus in general is rare. These are shown in Table 5.

Table 5. Pemphigus in Africa- percentage of dermatological outpatients

Country	Total number of cases	Cases of pemphigus	%
Zambia (21)	12 610	1 (PE)	0,008
Uganda (54)	3 097	12 (2 PV, 10 PF)	0,39
Kenya (55)	3 168	18 (1 PV, 15 PF, 2 PE)	0,57

PE = pemphigus erythematosus
PV = pemphigus vulgaris
PF = pemphigus foliaceus

Pemphigus is also uncommon in black South Africans. In a series of 5 000 dermatological outpatients seen at Ga-Rankuwa Hospital near Pretoria, pemphigus was diagnosed in 9 (0.18%) cases (6). A similar result was reported from Baragwanath Hospital, where pemphigus accounted for 4 out of 2 000 outpatients (0.2%) (5).

To obtain the relative frequency of pemphigus in black patients in the Johannesburg area, Baragwanath Hospital statistics for the year 1992 were used. A total of 7030 dermatological outpatients were seen of which 2235 were new cases. Six new cases of pemphigus were seen, representing 0.27% of new cases.

During the period of this study a mean of 4,3 cases per year were seen and the estimated population served by the Baragwanath Hospital was 3 million people per year. The incidence was therefore in the region of 0,14 per 100 000. This is less than North America, and much lower than the incidence in South America and North Africa. This study confirms that pemphigus is a rare disease in black south Africans.

In most large series dealing with pemphigus in general, the male to female ratio is equal (Table 4) (14) (16) (20) (23)(30) (39). However in El Salvador the male to female ratio is 1:4.7 for pemphigus in general (28), a finding similar to ours of 1:3. It is important to note that in both these studies the sample sizes were small.

In Europe and North America pemphigus vulgaris affects mainly persons in middle and old age. Although the age of onset ranges from 12 - 79 years, the mean age of onset is in the sixth decade (20). Most cases of Brazilian pemphigus in South America occur in the second and third decade (2) with a mean age of onset of 30 years in Brazil (14) and 33.3 years in San Salvador (28). In Tunisia the mean age of onset of pemphigus foliaceus is 28 years (3), similar to that of endemic Brazilian pemphigus. In our series of black South Africans, pemphigus in general affected mainly persons in the third to fifth decade. The mean age of onset was 46 years, similar to the age of onset of 43

years in Thailand (23) and about a decade lower than in Finland (16). (Table 4). We found the mean age of onset for pemphigus vulgaris to be 45 years, approximately 20 years lower than in North America (63.3 yrs) (18), and of pemphigus foliaceus to be 51 years, approximatly 20 years higher than in Brazilian pemphigus (30 yrs) (14).

Immunofluorescence is used in confirming the diagnosis of pemphigus. An intercellular pattern of fluorescence is seen throughout the epidermis in all forms of pemphigus and the different types cannot be distinguished by immunofluorescence studies (56).

Indirect immunofluorescence detects circulating antibodies in the patients serum directed against the intercellular cement substance. The most commonly used substrates are normal human skin (56), guinea pig and monkey oesophagus (57), Monkey oesophagus yields the best results for pemphigus vulgaris, and guinea pig oesophagus for pemphigus foliaceus (57). The use of both is recommended for the diagnosis of all forms of pemphigus (57). The use of normal human skin is often preferred because of the expense and relative lack of availability of the other two tissue substrates. The indirect immunofluorescence is positive in 77 - 100% of patients (58) (59) (60). In our study the indirect immunofluorescence tests was positive in 67% of cases. Our low positivity may be due to the fact that we used the patients uninvolved skin as substrate. Furthermore whereas we used polyvalent antiserum, monovalent IgG was used in other studies (59) (61).

With direct immunofluorescence there is intercellular deposition of immunoglobulins, mainly IgG and C3.(8). Intercellular deposition of IgG is seen in 90 - 100% of cases, IgM and IgA in 40 - 60% of cases and C3 in 50 - 100% of cases (58) (60) (62). Maurice and coworkers found that IgG alone was positive in 21% of cases and IgG and C3 were positive in 79% of cases (59). In our study positive fluorescence with IgG (85,7%) and C3 (60%) was similar to that reported in the literature. Only 14,3% of cases showed fluorescence with IgG alone, 20% with IgG and C3 and 5,7% of cases with C3 alone. Positive fluorescence with IgM was found in 4% of patients and none with IgA. Similar results with IgM and IgA were reported by de Messias et al in patients with Brazilian pemphigus foliaceus.27 (61).

CONCLUSIONS

In this study it was possible to classify the type of pemphigus by routine microscopy in sixty per cent of cases. In the remaining forty per cent, although the clinical picture was that of pemphigus, pathological confirmation was only possible by means of immunofluorescence. Immunofluorescence is an essential aid to diagnosis in pemphigus as the characteristic histological features are not always seen..

It is important to establish the diagnosis of pemphigus as well as the type, in order to predict prognosis and to plan therapy. Pemphigus vulgaris is more difficult to control than pemphigus foliaceus.

Pemphigus vulgaris and pemphigus foliaceus occur with equal frequency in our black population. Impressions that there are transitional forms, and that patients with pemphigus foliaceus are easier to treat than the pemphigus vulgaris are not dealt with in this study and need further investigation.

REFERENCES

1. Pisanti S, Sharav Y, Kaufman E, Posner LN. Pemphigus vulgaris : incidence in Jews of different ethnic groups, according to age, sex, and initial lesion. Oral Surg 1974; 38 : 382-387.

2. Diaz LA, Sampaio SA, Rivitti EA et al. Endemic pemphigus foliaceus(fogo selvagem . Current and historic epidemiological studies. J Invest Dermatol 1989; 92 : 4-12.

3. Morini JP, Jomaa B, Gorgi Y, Saguem MH, Nouira R, Roujeau JC, Revuz J. Pemphigus foliaceus in young women. An endemic focus in the Sousse area of Tunisia. Arch Dermatol 1993; 129 : 69-73.

4. Mahe A, Flaguel B, Cisse I, Keita S, Bobin P. Pemphigus in Mali: a study of 30 cases. Brit J Dermatol 1996; 134: 114-119.

5. Dogliotti M. Skin disorders in the Bantu : A survey of 2 000 cases from Baragwanath Hospital. S Afr Med J 1970; 44 : 670-674.

6. Schulz EJ. Skin disorders in Black South Africans. A survey of 5 000 patients seen at Ga-Rankuwa Hospital, Pretoria. S Afr Med J 1982; 62 :864-867.

7. Beutner EH, Jordon RE, Chorzelski TP. The immunopathology of pemphigus and bullous pemphigoid. J Invest Dermatol 1968; 51 : 64-75.

8. Cohen LM, Skopicki, DK, Harrist TJ, Clark WH. Noninfectious vesiculobullous and vesiculopustular diseases. In: Elder DH, Elinitsas R, Jaworsky C, Johnson B, editors. Lever's histopathology of the skin. 8th ed. Philadelphia: Lippencott- Raven, 1997: 209-252

9. Anhalt GJ, Kim S, Stanley JR et al. Paraneoplastic pemphigus. An autoimmune mucocutaneous disease associated with neoplasia. N Eng J Med 1990; 323:1729-1735.

10. Korman N. Pemphigus. J Am Acad Dermatol 1988; 18 : 1219-1238.

11. Lever W. Pemphigus. Medicine 1953; 32 : 1-123.

12. Bastiaens MT, Zwan NV, Verschueren GLA, Stoof TJ, Nieboer C Three cases of pemphigus vegetans. Induction by enalapril - association with internal malignancy. Int J Dermatol 1994; 33 : 168-171.

13. Sampaio SAP, Rivitti EA, Aoki V, Diaz LA. Brazilian pemphigus foliaceus or fogo selvagem (wild fire). Derm Clinics 1994; 12 : 765-776.

14. Sevadjian C. Nosology of Brazilian pemphigus foliaceus. Int J Dermatol 1979; 18 : 781-786.

15. Beutner EH, Jordan RE. Demonstration of skin antibodies in sera of pemphigus vulgaris patients by indirect immunofluorescence staining. Proc Soc Exp Biol Med 1964; **117** : 505-510.

16. Hietanen J, Salo OP. Pemphigus : An epidemiological study of patients treated in Finnish hospitals between 1969 and 1978. Acta Dermatovener (Stockholm) 1982; **62** : 491-496.

17. Garin SB, Souissi R, Blum L. Comparative epidemiology of pemphigus in Tunisia and France. Unusual incidence of pemphigus foliaceus in young Tunisian women. J Invest Dermatol 1995 ; **104** : 302-305.

18. Simon DG, Krutchkoff D, Kaslow RA, Zarbo R. Pemphigus in Hartford County, Connecticut, from 1972 to 1977. Arch Dermatol 1980; **116** : 1035-1037.

19. Feinstein A, Yorav S, Movshovitz M, Schenwach-Millet M. Pemphigus in families. Int J Dermatol 1991; **5** : 347-351

20.. Krain LS. Pemphigus. Epidemiologic and survival characteristics of 59 patients, 1955 - 1973. Arch Dermatol 1974; **110** : 862-865.

21. Ratnam AV, Jayaraju K. Skin disease in Zambia. Brit J Dermatol 1979; **101** : 449-453.

22. Kubeyinje EP. Pemphigus vulgaris : Case report in a Nigerian Negro. East Afr Med J 1991; **68** : 582-584.

23. Piamphongsant T, Ophaswongse S. Treatment of pemphigus. Int J Dermatol 1991; **30** : 139-145.

24. Peiying JIN, Changgeng S, Ganyun YE. Chronic bullous dermatoses in China. Int J Dermatol 1993; **32** : 89-92.

25. Ahmed AR. Pemphigus: cirrent concepts. Ann Int Med 1980; **92** : 396-405.

26. Ahmed AR, Blose DA. Pemphigus vegetans. Int J Dermatol 1984 ; **23** : 135-141.

27. Robledo MA, Prada De CS, Jaramillo D, Leon W. South American pemphigus foliaceus: study of an epidemic in El Bagre and Nechi, Colombia 1982 to 1986. Brit J Dermatol 1988; **118** : 737-744.

28. Hernández-Pérez EH. Pemphigus in El Salvador. An eight-year study (1970-1977). Int J Dermatol 1979; **18** :645-648.

29. Pye RJ. Bullous eruptions. In: Champion RH, Burton JL, Ebling FJG, editors. Rook/Wilkinson/Ebling: textbook of dermatology. 5th ed. Oxford:Blackwell, 1992: 1623-1673.

30. Rosenberg FR, Sanders S, Nelson CT. Pemphigus. A 20-year review of 107 patients treated with corticosteroids. Arch Dermatol 1976; **112** : 962-970.

31. Meurer M, Millns JL, Rogers RS, Jordan RE. Oral pemphigus vulgaris. Arch Dermatol 1977; **113**: 1520-1524.

32. Huilgol SC, Black MM. Management of the immunobullous disorders. Clin Exp Dermatol 1995; **20** : 283-293.

33. Ahmed AR. Clinical features of pemphigus. Clin Dermatol 1983; **1(2)** :13-21.

34. Seidenbaum M, David M, Sandbank M. The course and prognosis of pemphigus. Int J Dermatol 1988; **27** :580-584.

35. Lever WF, Schaumberg-Lever G. Immunosuppressants and prednisone in pemphigus. Arch Dermatol 1977; **113** : 1236-1241.

36. Thorn GW, Forsham PH, Frawley TF, Hill SR et al. The clinical usefulness of ACTH and cortisone. N Eng J Med 1950; **242** : 865-872.

37. Lever WF, White H. Treatment of pemphigus with corticosteroids. Results obtained over a period of 11 years. Arch Dermatol 1963; **87** : 12-26.

38. Bystryn JC. Adjuvant therapy of pemphigus. Arch Dermatol 1984; **120** : 941-951.

39. Ryan JG. Pemphigus. A 20-year survey of experience with 70 cases. Arch Dermatol 1971; **104** : 14-20.

40. Bystryn JC, Steinman NM. The adjuvant therapy of pemphigus. Arch Dermatol 1996; **132** : 203-212.

41. Pasricha JS, Thazama J, Khan UK. Intermittent high dose dexamethasone - cyclophosphamide therapy for pemphigus. Brit J Dermatol 1988; **119** : 73-77.

42. Barthelemy H, Frappaz A, Cambazard MD et al. Treatment of nine cases of pemphigus vulgaris with cyclosporine. J Am Acad Dermatol 1988; **18** : 1262 - 1266.

43. Piamphongsant T. Pemphigus controlled by dapsone. Brit J Dermatol 1976; **94** : 681-686.

44. Anhalt JG, Labib RS, Voorhees JJ, Beals TF, Diaz LA. Induction of pemphigus in neonatal mice by passive transfer of IgG from patients with the disease. N Engl J Med 1982; **306** : 1189-1196

45. Morioko S, Lazaris GS, Jensen PJ. Involvement of urokinase - type plasminogen activator in acantholysis induced by pemphigus IgG. J Invest Dermatol 1987; 89 : 474-477.

46. Kawana S, Geoghegan WD, Jordan RE. Complement fixation by pemphigus antibody. III. Altered epidermal cell membrane integrity mediated by pemphigus antibody and complement. J Invest Dermatol 1986; 86 :29-33.

47. Falk ES. Pemphigus foliaceus in a patient with rheumatoid arthritis and Sjogren's syndrome. Dermatologica 1979; 158 :348-354.

48 MacKie RM, Saika NK, Morley WN. A case of pemphigus vulgaris associated with Addisonian pernicious anaemia. Brit J Dermatol 1973; 88 : 139-141.

49. Cruz PD, Coldiron BM, Sontheimer RD. Concurrent features of cutaneous lupus erythematosus and pemphigus erythematosus following myasthenia. gravis and thymoma. J Am Acad Dermatol 1987: 16 : 472-480.

50. Levine L, Bernstein JE, Soltani K et al. Coexisting childhood pemphigus foliaceus and Grave's disease. Arch Dermatol 1982; 118 : 602-604.

51. Kaplan RP, Callen JP. Pemphigus associated diseases and induced pemphigus. Clin Dermatol 1983; 1(2) : 42-71.

52. Younis J, Ahmed AR. The relationship of pemphigus to neoplasia. J Am Acad Dermatol 1990; 23 : 498- 502

53. Empinotti JC, Diaz LA, Martins CR, Rivitti EA, Sampaio SAP, Lombardi C, Sanches JA. Endemic pemphigus foliaceus in western Parana, Brazil (1976 - 1988). Brit J Dermatol 1990; 123 : 431-437.

54. Vollum DI. An impression of dermatology in Uganda. Trans St. John's Hosp Derm Soc 1973; 59 : 120-128.

55. Verhagen ARHB, Koten JW, Chaddah VK, Patel RI. Skin diseases in Kenya. A clinical and histopathological study of 3,168 patients. Arch Derm 1968; 98 : 577-586.

56. Kirtschig G, Wojnarowska F. Autoimmune blistering disease : an up-date of diagnostic methods and investigation. Clin Exper Dermatol 1994; 19 : 97-112.

57. Sabolinski ML, Beutner EH, Krasny S, Kumar V, Huang J, Chorzelski TP et al. Substrate specificity of anti-epithelial antibodies of pemphigus vulgaris and pemphigus foliaceus sera in immunofluorescence tests on monkey and guinea pig esophagus sections. J Invest Dermatol 1987; 88 : 545-549.

58. Tuffanelli DL. Cutaneous immunopathology : Recent observations. J Invest Dermatol 1975; **65** : 143-153.

59. Maurice PDL, Allen BR, Marriott DW, Powell RJ, Reeves WG. Skin immunofluorescence in the diagnosis of primary bullous diseases - a review of 279 cases. *Clin Exper Dermatol 1986; 11 : 352-364.*

60. Judd KP, Lever WF. Correlation of antibodies in skin and serum with disease severity in pemphigus. Arch Dermatol 1979; **115** : 428-432.

61. de Messias IT, von Kuster LC, Santamaria J, Kajdacsy-Balla A. Complement and antibody deposition in Brazilian pemphigus foliaceus and correlation of disease activity with circulating antibodies. Arch Dermatol 1988; **124** : 1664-1668

62. Jordon RE, Schroeter AL, Rogers RS, Perry HO. Abstract. Classical and alternate pathway activation of complement in pemphigus vulgaris lesions. J Invest Dermatol 1974; **63** : 256-259.

Author Bue EC
Name of thesis Pemphigus In Blach South Africans In The Johannesburg Area Bue Ec 1998

PUBLISHER:
University of the Witwatersrand, Johannesburg
©2013

LEGAL NOTICES:

Copyright Notice: All materials on the University of the Witwatersrand, Johannesburg Library website are protected by South African copyright law and may not be distributed, transmitted, displayed, or otherwise published in any format, without the prior written permission of the copyright owner.

Disclaimer and Terms of Use: Provided that you maintain all copyright and other notices contained therein, you may download material (one machine readable copy and one print copy per page) for your personal and/or educational non-commercial use only.

The University of the Witwatersrand, Johannesburg, is not responsible for any errors or omissions and excludes any and all liability for any errors in or omissions from the information on the Library website.