

https://dspace.org/

Healing patterns of transplanted roots coated with an allogeneic fibrin-fibronectin concentrate

Sing-Rambiritch, Simitha

2013-03-18
http://hdl.handle.net/10539/12541

Downloaded from a DSpace repository. https://dspace.org/

1 INTRODUCTION

The treatment of destructive periodontal disease, due to specific periodontopathic bacteria, aims at the regeneration of a periodontal attachment composed of new cementum, alveolar bone and a functional periodontal ligament uniting bone and cementum.

To reach that aim, previous clinical studies have shown the need to reduce the bacterial load and the inflammatory process by decontaminating the root surface. Stahl (1977) reported that, following periodontal surgery, there is rapid apical migration of the gingival epithelium onto the root surfaces impeding the formation of new connective tissue attachment. The subsequent recurrence of periodontal pockets was attributed to the re-colonisation of the radicular surfaces by subgingival plaque. Aukhil *et al.* (1983) confirmed that surgical and non-surgical conventional periodontal therapy results frequently in healing with a long junctional epithelium, thus preventing the deposition of a new cementum with inserted collagen fibres. To facilitate cementogenesis following surgical debridement of diseased roots in beagle dogs, Aukhil *et al.* (1983) interposed millipore filters between root surfaces and the closed muco-periosteal flaps to allow the periodontal ligament cells to migrate coronally and to prevent the down growth of the junctional epithelium onto the root surfaces. This experiment showed the potential for obtaining a new connective tissue attachment if the surgical procedure allows the re-population of the root planed surfaces by cells arising from the periodontal ligament with

the potential to differentiate into osteoblasts and form new bone.

Ripamonti (1985) described that the gingival unit regenerates with a junctional epithelium of varying height following any periodontal therapy provided that the root surface has been adequately decontaminated. Ripamonti *et al.* (1987) stated that healing by attachment regeneration, i.e. new cementum with inserted connective tissue fibres, following periodontal surgery can be unpredictable because healing patterns are influenced by certain factors such as the phenotypic and kinetic expression of the repopulating fibroblasts as well as the social behavioural patterns of the subject during the post-operative care period. Healing of a treated region primarily depends on the selective cellular repopulation by various cells from the surrounding regions, mainly endosteal cells, periodontal ligament cells, gingival connective tissue cells and epithelial cells.

However, the affected periodontium does not always heal satisfactorily mainly in instances of aggressive periodontitis and, consequently, many teeth are lost as the above-mentioned treatment is not predicatively successful. Therefore, surgical techniques and application of biochemicals devices onto root surfaces are in constant development.

1.1 Review of the literature

Periodontal tissue regeneration process entails a radicular treatment composed of scaling to remove the hard and soft accretions, root planing to remove the cementum infiltrated by bacteria and their toxins, and the demineralisation of the exposed dentine with citric

acid (Ririe *et al.*, 1980).

To better understand the steps of the healing process following surgical periodontal treatment, researchers have undertaken some innovative investigations and therapies which are described below.

Several authors (Register, 1973; Register *et al.*, 1975, 1976) have reported that radicular surface demineralisation enhanced cementogenesis which is an essential step to regenerate a new periodontal attachment. Garrett *et al.* (1978) examined by scanning and transmission electron microscopy the effect of the application of citric acid on diseased root surfaces. The demineralisation process of the root-planed surface of freshly extracted human teeth exposed to periodontitis resulted in the exposure of collagen fibrils within the dentine matrix providing a suitable nidus for splicing with newly deposited fibril during the healing process.

Proye *et al.* (1982), in a companion study on periodontal healing in monkeys, extracted and replanted teeth after denuding the coronal root surface of alveolar ligament fibres and cementum. Citric acid conditioning was not done. Histological examination at 1, 3, 7 and 21 days revealed that the gingival epithelium had proliferated rapidly on the root surface to the apical limit of the root instrumentation corresponding to the level of the non-denuded root surface with remaining periodontal ligament fibres. A new periodontal attachment was not observed on the denuded root surfaces as the absence of fibres resulted in apical migration of the epithelium and precluded the formation of a new

connective tissue attachment. However in the above companion study by Polson *et al.* (1982), when the experiment was modified by citric acid conditioning of the denuded coronal radicular surfaces, both extensive root resorption and a new connective tissue attachment had developed at day 21 as there was no apical migration of the gingival epithelium which remained coronal to the crestal bone. It appeared that the new connective tissue attachment was dependent upon early establishment of a fibrin linkage with the root surface. In another similar tooth replantation study, Polson *et al.* (1983) used histological techniques to differentiate between fibrin and collagen during healing at the root surface interface. The epithelium did not migrate apically along denuded root surfaces, but it was confirmed that the collagen fibre attachment to the root surface was preceded by fibrin linkage and that the linkage process occurred as an initial event in the wound healing process.

Caton *et al.* (1986) followed into the steps of Proye and Polson (1982) and used the same replantation animal model. The coronal third of roots planed free of fibres and cementum, and coated with a fibrin-fibronectin tissue adhesive, exhibited an enhanced fibre attachment to the planed root surfaces when compared to control root surfaces that were not demineralised. But long-term clinical studies over several years reveal that replanted teeth in humans almost invariably undergo ankylosis and resorption (Chen *et al*., 1986).

Other experiments have confirmed that root planing with subsequent demineralisation and coating with attachment glycoproteins enhanced periodontal regeneration (Wennström *et al*., 1986; Nasjleti *et al*., 1987; Ripamonti *et al.*, 1987, 1989).

In a model of non-human primates of the species *Papio ursinus*, Ripamonti *et al.* (1987) demonstrated that an allogeneic fibrin-fibronectin protein concentrate (AFFP), applied on surgically exposed, planed and demineralised root surfaces, enhanced new cementum deposition and alveolar bone regeneration with a regenerated and functional periodontal ligament when compared to control root surfaces without AFFP coating. Furthermore, coating surgically exposed root surfaces with AFFP also prevented ankylosis and root resorption on the experimental teeth during healing.

In the same primate model, Ripamonti *et al.* (1989) extracted mandibular incisors for subsequent replantation. On each tooth, the periodontal ligament fibres and the cementum were detached by root planing the coronal two thirds while the cementum and the attached remaining periodontal ligament fibres were left on the apical third. Following citric acid demineralisation of the root-planed surfaces, experimental roots were coated with AFFP prepared from pooled fresh frozen baboon plasma. When compared to control root surfaces without AFFP coating, results showed that biochemical treatment with AFFP of surgically exposed and demineralised root surfaces neither enhanced connective tissue regeneration and attachment nor prevented dento-alveolar ankylosis after replantation of mandibular incisors. The experimentations of Proye *et al.* (1982), Caton *et al.* (1986), Ripamonti *et al.* (1989) and others revealed that tooth replantation in their own alveoli may result in an initial clinical success demonstrated by clinical and radiographic examinations, but with long term failure due to root resorption and ankylosis as revealed by histological evaluation.

1.2 Historical background

As tooth replantation usually results in a failure to regenerate a complete and functional periodontal ligament in the long term, researchers have focused on tooth transplantation using the factors known for stimulating periodontal radicular re-integration, namely, root planing, citric acid demineralization, exclusion of epithelial cells by a microporous membrane (Karring *et al.*, 1980; Nyman *et al.*, 1980) and application of a fibrin-fibronectin adhesive (Ripamonti *et al.*, 1989). Karring *et al.* (1980) and Nyman *et al.* (1980) developed an animal model whereby roots affected with induced periodontitis were autotransplanted into grooves or beds prepared in the buccal surface of the body of the mandible. The coronal portion of the roots were planed and separated from the non-planed apical portion by a groove. Transplanted roots were embedded to half of their circumference into bone tissue while the remaining part was covered by a flap containing gingival connective tissue (Fig. 1). Healing in the apical portion resulted in the formation of a new attachment and in ankylosis, root resorption and the formation of non-functional connective tissue fibres aligned parallel to the root surface in the coronal portion.

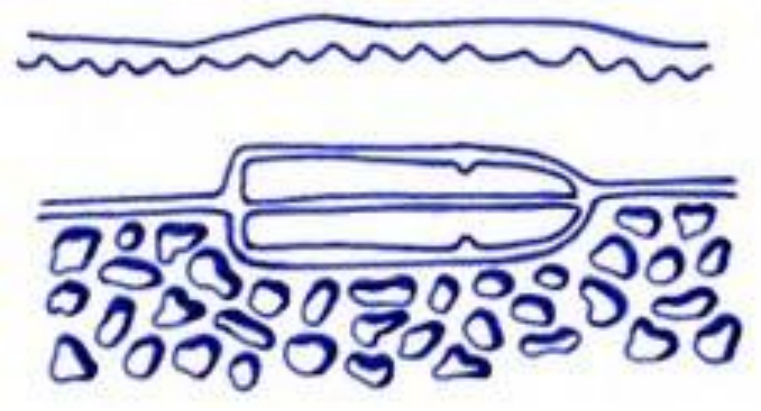

Figure 1 Schematic representation of the experimental procedure

Ripamonti *et al.* (1989) further evaluated the role of attachment factors (i.e. fibrin-fibronectin) in periodontal regeneration by conducting procedures related to the above-mentioned experiments on roots of mandibular molars autotransplanted in the alveolar and basal bone of the mandible of baboons. So far, the effectiveness of pre-treatment of those autotransplanted roots coated with AFFP has not been evaluated histologically and was the object of this study.

This study, which is a partial replication of Nyman's study (1980), was designed to evaluate histologically whether ankylosis and root resorption could be prevented on transplanted roots coated with AFFP. The intention was to verify whether tooth transplantation as done for orthodontic, oral surgical or periodontal purposes may have a biologically satisfactory long-term prognosis.

1.3 Fibrin-fibronectin protein concentrate

Yamada *et al.* (1978) identified a class of adhesive, high molecular weight glycoproteins (fibronectins) present on the surface of cells in connective tissue matrices and in extracellular fluids. The authors reported that fibronectins may have important roles in cellular adhesion, malignant transformation, reticulo-endothelial system function and embryonic differentiation.

Federgreen *et al.* (1980) investigated epithelial cell spreading on fibronectin-containing media. They found that no significant spread occurred in media enriched only with

fibronectin. However, appreciable spread occurred in media containing whole plasma and plasma deficient in fibronectin. Therefore, fibronectin could limit the migration of epithelial cells during the early stages of healing.

According to Kurkinen *et al.* (1980), fibronectin functions as a primary matrix during tissue repair for the organisation of the collagen by creating a tractional field for the migrating fibroblasts.

Bevilacqua *et al.* (1981) identified monocyte membrane receptors for fibronectin. The expression of the receptors was markedly enhanced by the interaction with fibronectin. The authors concluded that the binding of fibronectin at the surgical sites could promote the retention of monocytes and enhance their phagocytic capacity due to their affinity for fibrin and collagen.