

https://dspace.org/

Taking shape A geometric morphometric analysis of the immature human palate in relation to dental eruption and growth

Nkemakonam Onwochei-Bolum; Beverley Kramer; Erin Hutchinson

https://hdl.handle.net/10539/42466
SCOPUS

Downloaded from a DSpace repository. https://dspace.org/

Morphologie 108 (2024) 100722

Disponible en ligne sur
ScienceDirect
www.sciencedirect.com

Elsevier Masson France
EM|consulte
www.em-consulte.com

ORIGINAL ARTICLE

Taking shape: A geometric morphometric analysis of the immature human palate in relation to dental eruption and growth

N.V. Onwochei-bolum, B. Kramer, E.F. Hutchinson*

School of Anatomical Sciences, Faculty of Health Sciences, University of the Witwatersrand, 7, York Road, Parktown, 2193 Johannesburg, South Africa

KEYWORDS
Dental eruption ;
Immature palate ;
Palatal dimensions ;
Palatal shape

Summary
Background. — The immature human palate functions in suckling and swallowing but transitions to participate in mastication and sound production as the individual grows and matures. Functional alterations manifest as changes in the morphology of the palate and may result from dental eruption. The aim of this study was to analyse the effect of dental eruption on morphological changes of the palate in immature individuals using geometric morphometrics.
Methods. — Crania from 72 individuals were sourced from the Raymond A. Dart Collection of Human Skeletons, University of the Witwatersrand. Age groups corresponding to the eruption of the deciduous (birth — 5 years), mixed (6—12 years) and permanent dentition (13—20 years) respectively were used. Fourteen osteological landmarks were digitised across the oral surface of the palate and were converted into linear distances and 3D wireframes. Data analysis focused on alterations in shape and size relative to the state of the dentition.
Results. — A significant increase in the geometric mean, length and width was observed between the different states of the dentition. The palate shape was long and narrow in the permanent dentition group, resulting in a more acute angle anteriorly and a protruded orale. A protrusion of the staphylion and deeper palatal dome and change in the horizontal alignment of the alveolar region were also observed in the permanent dentition group.
Conclusion. — The subtle changes identified in the growing palate during different stages of the dentition may assist forensic scientists during detailed case analysis.
© 2023 L'Auteur(s). Publié par Elsevier Masson SAS. Cet article est publié en Open Access sous licence CC BY-NC-ND (http://creativecommons.org/licenses/by-nc-nd/4.0/).

Introduction

Anatomical structures involved in feeding have evolved over time to aid the mechanisms of prehension, mastication and deglutition in different organisms [1]. As human development proceeds, the increase in the functional activities of

* Corresponding author.
Adresse e-mail : Erin.hutchinson@wits.ac.za (E.F. Hutchinson).

https://doi.org/10.1016/j.morpho.2023.100722
1286-0115/© 2023 The Author(s). Published by Elsevier Masson SAS. This is an open access article under the CC BY-NC-ND license (http://creativecommons.org/licenses/by-nc-nd/4.0/).

the oral cavity and the changes which occur in the bones and muscles of the palate drives maturation and further structural development and growth [2—5]. The maxilla is characterised by numerous morphological changes during the juvenile stage of growth as the deciduous dentition exfoliates, the permanent dentition erupts and a relative increase in the mass of the maxillary alveolar bone and growth of inter-alveolar width occurs [3—6].

Forces associated with the functional activities of the oral cavity such as mastication, occlusion, swallowing and dental eruption are said to cause osteogenic loading of the associated bones [6]. These weight bearing activities stimulate the building of bone and lead to an increase in bone mass and also to bone remodelling of the palate [7]. A general change in the shape of the dental arch of the maxilla due to an increase in its length and width has been observed during the stages of eruption and emergence of the dentition [8]. Changes in both the anterior and posterior dentition and hence bone remodelling of the maxilla in those regions occur from childhood into adulthood [6,9]. Thus, the relationship between growth of the alveolar process and changes to the palate may be age-related. Geometric morphometrics (GM) offers the opportunity to explore the influences of subtle changes in size and shape across the growth of the palate relative to the different dental eruption patterns.

The current study thus analysed changes in the shape and dimensions of the human palate from birth through the stages of dental eruption to the complete emergence of the permanent dentition in the sub-adult stages of life using geometric morphometrics.

Materials and methods

Sample

Ethics clearance to use skeletonized human maxillae was obtained from the University of the Witwatersrand's Human Research Ethics Committee (HREC - Medical) (W-CBP-210401-01).

Crania from 72 South African individuals were sourced from the Raymond A. Dart Collection of Human Skeletons. The demographics of the sample is displayed in Table 1. The sample from each of the population affinities in relation to the stages of dental eruption is limited by the small cohort of sub-adult skeletal remains available in human collections [10,11]. As there is known to be a large amount of genetic admixture in the southern African populations [12,13], the sample was not assessed in relation to specific population affinities [14,15]. Age estimation was based on the stages of dental eruption and emergence of the teeth of each individual [16]. The age and sex of the individuals were obtained from the database of the collection.

As the eruption and emergence of the dentition is associated with the modelling and remodelling of the alveolar bone [17], and as alveolar bone is closely associated with the postnatal development of the palate [18], dental eruption and the emergence of the teeth were considered in the grouping of individuals for analysis. Thus, the sample was divided into three age groups: group 1 (birth — 5 years) to correspond with the eruption of the deciduous dentition, group 2 (6—12 years) corresponding with the eruption of the mixed dentition and group 3 (13—20 years) corresponding with the eruption of the permanent dentition (Table 1). Maxillae with any congenital abnormalities, atypical dental patterns (e.g. supernumerary teeth), trauma, pathology or surgical interventions and general damage were excluded from this study. Individuals were also excluded in cases where sutures could not be visualised or landmarks were not present.

Methods

Digitising of landmarks

A series of 14 osteological landmarks [19] (Fig. 1) were digitised across the oral surface of each palate using an Immersion MicroScribe G2 unit (Solution technologies Oella, MD, USA), with an accuracy of 0.38 mm. The landmarks were recorded from LM1 towards LM14 (Fig. 1) to better visualise their position in three-dimensional space (Supplementary Table 1).

Subsequent to digitising the landmarks using MicroScribe utility software (MUS) 7 (Revware inc. Raleigh, NC, USA), the 3D coordinates were imported into a Microsoft Excel worksheet. Each digitised landmark consisted of three coordinates (X, Y, and Z), which represented the horizontal, vertical and depth planes respectively. A Pythagorean formula was used to convert the recorded landmarks to distances [20].

Linear measurements

The length of the palate was measured between the orale (LM9) and staphylion (LM3) (Fig. 1). The width of the palate was measured at its widest point between the left and right

Table 1 Age, sex and population affinity distribution of the study sample.

Group	Age range (*n*=)	Sex (*n*=)		Population affinity (*n*=)		
Dentition type		Female	Male	[a]SA Coloured	SA White	SA Black
Deciduous	Birth — 5 years (*n* = 14)	9	5	1	1	12
Mixed	6—12 years (*n* = 8)	2	6	—	2	6
Permanent	13—20 years (*n* = 50)	17	33	2	3	45
	Total	28	44	3	6	63

[a] The South African coloured population group is a self-identified group who possesses a rich and diverse history within South Africa, which extends into their genetic make-up. Parental populations may include an admixture of Africans such as Khoesan individuals, African Bantu speaking population groups and non-Africans including Malaysians, Indonesians, Indians and Europeans [14,15].

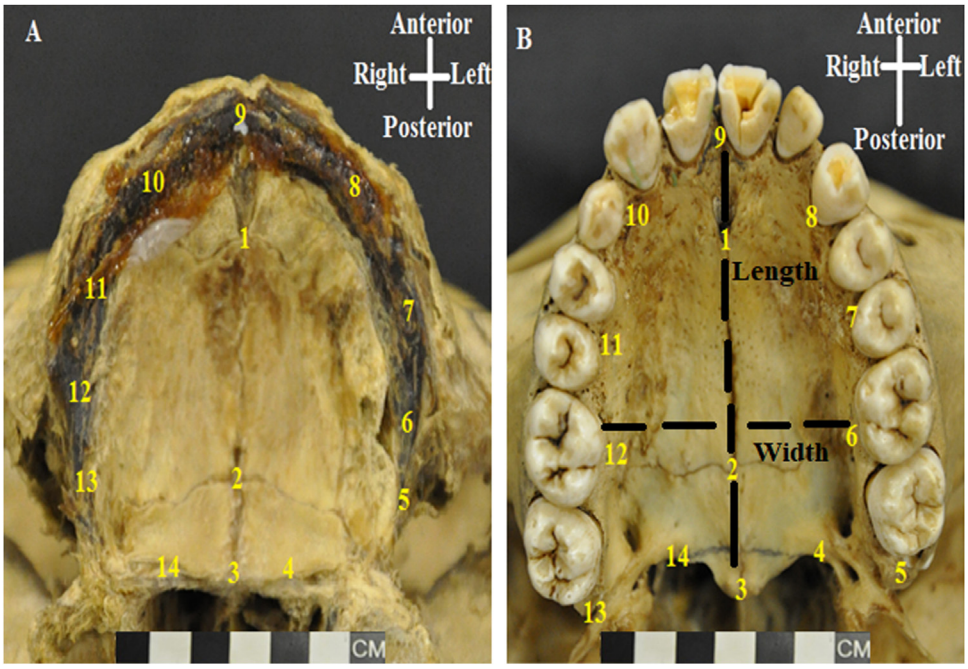

Figure 1 Oral surface of the human immature palate indicating the location of the 14 osteological landmarks. A. Birth. B. Twelve years of age. The 14 landmarks, include 10 fixed (FX) and four floating landmarks (FL) (Supplementary Table 1) selected for the purpose of calculating the linear measurements and defining the shape of the palate.

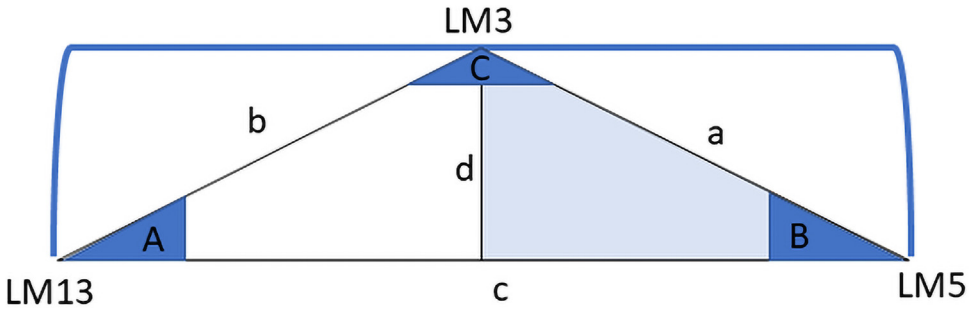

Figure 2 Schematic diagram illustrating the posterior view of the bony palate. The staphylion and left and right postalverions (landmarks LM3, LM5 and LM13) were used to calculate the elevation of the palatal dome. The calculation made use of the cosine rule (CosB = [c2 + a2−b2]/[2ac]) as the triangle created by landmarks LM3, LM5 and LM13 was not a right-angled triangle.

endomolare (LM6 and LM12) (Fig. 1). The elevation of the palatal dome was calculated (Fig. 2).

Shape analysis

In order to visualise the spatial relationships of digitised osteological landmarks, a wireframe model was constructed with MORPHOLOGIKA 2 v. 2.5 (University College London, UK, 2007) by connecting the digitised osteological landmarks in 3D space. The relationship between landmarks was further investigated using Generalized Procrustes Analysis (GPA).

Data analysis

The 3D landmark measurement data were subjected to a principal component analysis (PCA) using PAST statistical software to analyse the size and MORPHOLOGIKA 2 v. 2.5 (University College London, UK, 2007) to assess variations in shape. All quantitative data analysis was conducted using Microsoft Excel for Windows and SPSS V20 (IBM, Armonk, NY, USA, 2021).

A Shapiro—Wilk's test was conducted to assess the distribution of the data across the entire sample. Descriptive statistics were calculated. A multivariate analysis of variance (MANOVA) was conducted to assess variations in the calculated size (geometric mean) and shape (Mosimann shape) variables relative to dental eruption and age [17,21]. A *P*-value of less than 0.05 was considered significant.

The multivariate nature of shape as captured by the Procrustes shape coordinate was analysed using a principal component analysis (PCA) to show and compare shape variation between individuals within the study sample [22].

Inter- and intra-observer errors were determined by two researchers on ten individuals and tested using Lin's concordance correlation coefficient of reproducibility. The measure of repeatability included redigitising all linear mea-

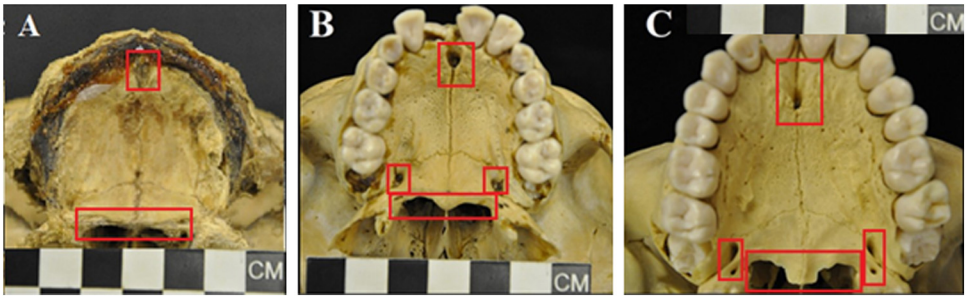

Figure 3 Oral surface of the immature human palate showing the general morphology. A. At birth (deciduous dentition group). B. Ten years of age (mixed dentition group). C. Sixteen years of age (permanent dentition group). Red rectangles indicate areas of the palate with marked morphological changes.

Table 2 Measurements (mean and standard deviation) of the palate according to the state of the dentition.

	Group 1 — Deciduous dentition: birth — 5 years ($n = 14$)	Group 2 — Mixed dentition: 6—12 years ($n = 8$)	Group 3 — Permanent dentition: 13—20 years ($n = 50$)	Scheffe Post Hoc (P)	
Measurements	Mean (SD)	Mean (SD)	Mean (SD)	Group 1 vs. 2	Group 2 vs. 3
Width	26.26 (3.30)	31.70 (2.17)	38.83 (3.33)	0.001[a]	0.001[a]
Height	3.02 (1.03)	4.60 (1.46)	7.75 (2.86)	0.366	0.006
Length	31.79 (3.24)	41.16 (2.71)	51.23 (4.37)	0.001[a]	0.001[a]
Geo_Mean	13.43 (2.38)	17.98 (1.87)	24.46 (4.22)	0.029	0.001[a]
MSV_W	1.99 (0.27)	1.78 (0.17)	1.64 (0.33)	0.303	0.495
MSV_H	0.22 (0.05)	0.25 (0.06)	0.31 (0.08)	0.571	0.146
MSV_L	2.42 (0.39)	2.31 (0.27)	2.16 (0.45)	0.846	0.640

Length: the length of the palate; Width: the width of the palate; Height: the height of the palate; Geo_Mean: geometric mean; MSV_L: Mosimann shape variable of the length of the palate; MSV_W: Mosimann shape variable of the width of the palate; MSV_H: Mosimann shape variable of the height of the palate. Scheffe Post Hoc P is significant at $P \leq 0.05$.

[a] All indicated values of P were less than 0.001.

surements across the 14 specified landmarks across all ten selected individuals. Values ranging between 0.8 and 1 were considered acceptable levels of repeatability.

Results

On macroscopic observation the palate was horseshoe-shaped in individuals of the deciduous dentition group (Fig. 3A) compared to a more oval-shape in the mixed and permanent dentition groups (Fig. 3B and C). In the posterior region of the palate in the mixed and permanent dentition groups (Fig. 3B and C), bilateral indentations (curvatures) and a formed palatal spine were observed when compared to the deciduous dentition group (Fig. 3B and C). The incisive foramen was more posteriorly situated in the permanent dentition group compared to its position in the deciduous and mixed dentition groups (Fig. 3).

Quantitative analysis of the palate

A high level of repeatability was observed across all measurements (height: 84%, width: 95.8%, length: 97.1%).

A significant increase in the geometric mean, length and width was observed between the different states of the dentition. However, no statistically significant changes in the shape parameters were noted (Table 2).

Size of the palate

The length ($P \leq 0.001$), width ($P \leq 0.001$) and height ($P \leq 0.006$) measurements of the palate of the permanent dentition group were significantly larger than that of the mixed and deciduous dentition groups respectively (Table 2) as evident in the high degree of separation observed in the PCA between these groups (Fig. 4). The geometric mean of the palate (geo_mean) was significantly greater when comparing the permanent dentition group to the mixed ($P \leq 0.029$) and deciduous ($P \leq 0.001$) dentition groups respectively (Table 2). However, no significant level of variance was noted in the PCA as indicated by the degree of overlap observed between these groups.

Qualitative analysis of palatal shape

When comparing the 3D wireframes, the oral view of the palate showed that the left and right posterior alveolar regions (at LM6 and LM12 respectively) were oriented towards the midline of the palate in the mixed dentition and permanent dentition groups (Fig. 5A). This change in

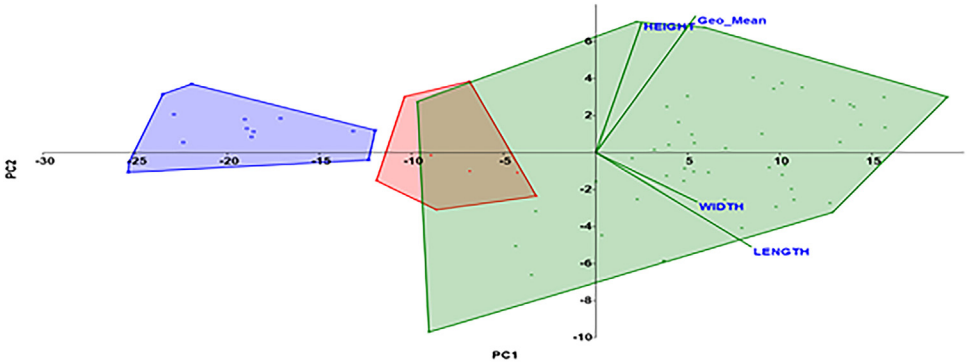

Figure 4 Principal component analysis (PCA) assessing the degree of variance in the size of the palate between the three states of the dentition: group 1 (blue: deciduous dentition), group 2 (red: mixed dentition), group 3 (green: permanent dentition). Box plots illustrate the influence of each measurement and the geometric mean (Geo_Mean) on PC1 and PC2. In the PCA, an overlap of the group distribution map (coloured areas) indicates little to no variation between the represented groups, while a separation between groups indicates a high to moderate degree of variation between the represented groups.

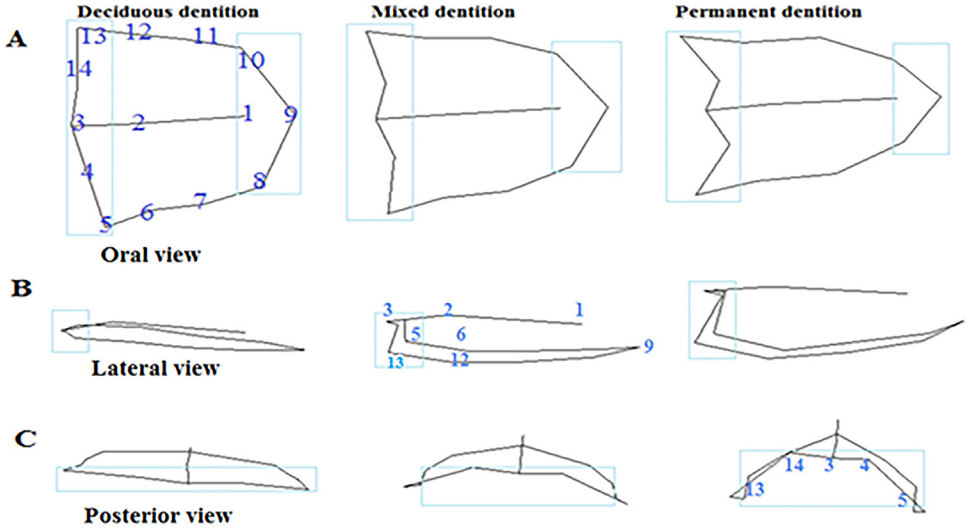

Figure 5 Wireframes illustrating the changes in the palatal shape between the varying stages of dental eruption and emergence. Oral view (A), illustrating the oral surface; lateral view (B), illustrating the right alveolar region and an overlapping of the left alveolar region; posterior view (C), illustrating the posterior region of the palate. Blue rectangles indicate areas of the palate with marked morphological changes. Numbers 1—14 indicate specific landmarks.

orientation resulted in a narrower appearance of the wireframe of the palate in the permanent dentition group when compared to the other groups as indicated by the distances between LM12-LM6 and LM10-LM8 (Fig. 5A). The palate was also longer along the median plane (distance between LM3-LM9) in the permanent dentition group compared to the deciduous and mixed dentition groups respectively (Fig. 5A). The long and narrow palate observed in the permanent dentition group, resulted in a more acute angle anteriorly (LM8-LM9-LM10) and a protruded orale (LM9) compared to the palate of the deciduous dentition group (Fig. 5A). An outward protrusion of the left and right postalverions (LM5 and LM13) was observed in the permanent dentition group (Fig. 5A).

Shape changes in the posterior region of the palate such as the protrusion of the staphylion (LM3) were observed across the different states of the dentition (Fig. 5A). A broad obtuse angle was observed relative to LM13-LM14-LM3 and LM3-LM4-LM5 on either side of the palatal spine in the deciduous dentition group compared to the mixed and permanent dentition groups (Fig. 5A). The formation of bilateral indentations of the posterior region of the palate in the mixed dentition group was observed at LM4 and LM14 respectively. The bilateral indenting was deeper in the permanent dentition group in comparison to the mixed dentition, and absent in the deciduous dentition group. Thus, a change in the obtuse angle of the bilateral indentations to an acute angle and a well-defined ''W'' shape (LM13-LM14-LM3-LM4-LM5) was observed at the posterior border of the palate in the permanent dentition group (Fig. 5A). The increase in the height of the alveolar region (LM13-LM3-LM5 and LM12-LM2-LM6) of the permanent dentition was associated with the more elevated roof of the palate compared to the mixed and deciduous dentition groups respectively (Fig. 5B).

In the posterior view of the wireframes (Fig. 5C), the roof of the palate changed from being flat in the deciduous den-

tition group (see line across the three groups indicated by: LM13-LM14-LM3-LM4-LM5) (Fig. 5C) to being deeper and forming a dome in the mixed and permanent dentition groups (Fig. 5C). The landmarks LM13-LM14 and LM4-LM5 respectively indicate a reorientation of the left and right alveolar regions from a horizontal orientation in the deciduous dentition group to a vertical orientation with a lateral inclination in the mixed and permanent dentition groups (Fig. 5C). The lateral divergence of the vertically oriented alveolar regions was associated with a statistically significant increase in the width of the palate in the later dentition groups.

Discussion

Significant 3D changes in the shape and size of the palate were observed in the current study by means of geometric morphometry, relative to the emergence and eruption of the maxillary dentition in immature individuals. The 3D-constructed wireframes demonstrated subtle and important differences in the palatal shape (in the anterior and posterior areas, and the dome of the palate) across the different stages of the dentition that have been overlooked by quantitative analysis and 2D methods making use of callipers. These differences included the horizontal orientation of the alveolar region in the deciduous group compared to a vertical orientation in the permanent dentition group (deepening of the palatal dome), angulation of the orale in the anterior alveolar region and the posterior ''W'' shape of the palate in permanent dentition group.

The variation in the shape of the palate in different states of the dentition in the current study, particularly those associated with the posterior palatal and alveolon regions, are supported by significant increases across all assessed dimensions. The transition in shape is particularly evident when comparing palatal shape between the deciduous and mixed dentition groups, where the alveolar arch increased in length and width. This increase in dimensions is thought to be the result of the alveolar arch accommodating the development, eruption and transition between dentition sets, which has been previously explored, particularly with reference to dental crowding [6,23—25]. Dental arch length is one of the most important factors when diagnosing and treating dental crowding issues [25]. Children with delayed eruption of the permanent teeth demonstrate shorter palatal lengths [24].

In addition to the significant lengthening of the palate, morphological shape variations such as lateral divergence of the alveolar region in the more advanced dentition groups compared to the deciduous dentition group indicated increased widening of the palate with the transition across the states of the dentition as has also been demonstrated by Knott [26] and Amirabadi et al. [27].

While the role of the dentition in the expansion of the palate anteriorly may account for the change in the angulation of the alveolon region of the palate in the current study, changes in the posterior palatal region were seen to have a greater effect on the transition of the overall shape of the palate. The palate appeared narrower in the endomolare region in the permanent dentition group compared to the other two groups which may be explained by a realignment of the maxillary molars with growth [6,28]. Maxillary molars become more upright as their crowns expand laterally with age and also undergo a degree of rotation in the coronal plane to increase the degree of molar torque needed with the adoption of more complex functions such as chewing [6,28]. The changes in the positioning and alignment of the molars may also account for the increase in the height of the palatal dome observed in the current study. Thilander [29] attributed the increase in the height of the palate across the different states of the dentition to the eruption of the dentition, which resulted in the inferior growth of the alveolar bone in the maxilla. The increase in height of the alveolar region in the permanent dentition of individuals in the current study better accommodates the bigger teeth and creates a larger surface area for the increased tongue activity associated with the demands of an evolved diet.

The palatal spine and posterior arches in the current study were significantly more defined in the permanent dentition group. The shape of the posterior palatal region transitioned from a broad obtuse angle on either side of the staphylion in the deciduous dentition group to a well-defined ''W'' shape in the posterior dentition, resulting in distinct posterior palatal arches on either side of the spine of the palate. This may be attributed to the significant increase in the length of the palate of individuals in the permanent dentition. The staphylion and posterior palatal arches also serve as an attachment point for the palatal aponeurosis, which forms a platform for the attachment of the soft palate musculature [30]. Owing to the attachment and functioning of the soft palate musculature, the posterior palatal spine and associated arches become more morphologically distinct with age [7] due to increased biomechanical stimulation associated with deglutition.

A significant increase in the definition and height of the roof of the palate, commencing from a flattened palatal shelf in individuals of the deciduous dentition group to a dome-like appearance in the permanent dentition group, was observed in the current study. Pressure of the soft palate musculature on the posterior aspect of the palate in a superior direction influences the height of the palate [31] and stimulates posterior appositional growth of the palate. With deposits of new bone being accrued on the oral surface of the palate, there is corresponding removal of bone from the nasal surface resulting in an increase in the depth of the palatal dome and thus an increase in height of the palate [8]. Abnormally high palatal domes occur in individuals with nasal obstruction and a reduced nasal cavity [32] indicating that breathing through the nose may also be important in palatal growth [33].

The tongue also creates a distortional force during suckling which coincides with the appearance of cartilage in the median palatal suture and ultimately growth in the width and height of the palate [7]. In addition, the mechanical action of the tongue against the dome of the palate is important during the oral phase of deglutition. Dysmorphologies of the palate occur in cases of aglossia, hypoglossia and soft plate dysmorphology, where absence of the pressure created by the mechanical activity of the tongue and soft palate have been implicated [34—40].

The influence of the biomechanical force generated by the tongue is further demonstrated by the formation of a more acute angle at the orale in the mixed and permanent dentition groups. The shape reorientation of the

maxillary incisor region from a lingual to a more labial direction is influenced by lingual forces on the anterior (incisor region) region of the palate [33]. Additionally, increased bone mass due to bone remodelling occurs in the anterior (incisor region) region of the palate in the immature stages of growth [9] suggesting that mechanical pressure from the tongue on the anterior region of the palate may have influenced the shape difference observed anteriorly between the three dentition groups.

In addition to the factors cited above, the growth of the components of the maxilla may also influence growth in the length of the palate. As the nasal region grows anteriorly, growth of the viscerocranium is directed anteriorly. In order to achieve equilibrium in craniofacial growth, the sphenoid bone grows posteriorly and apposition of new bone accrues in the posterior region of the maxillary tuberosity [8]. There is thus an increase in the anterior-posterior dimension of the maxillary alveolar region directly influencing the length of the palate [8,41], as indicated in the current study by a protruding staphylion in the posterior region of the palate in the mixed and permanent dentition groups.

Subtle changes in the growth of the maxilla as determined with geometric morphometrics have implications for forensic scientists and orthodontists. With respect to forensic scientists, the subtle changes in the orientation of the alveolar regions and the positioning of the orale may assist in refining age assessments of an immature individual. Orthodontists may find value understanding the impact of the realignment of the alveolar region and the change in the angulation of the orale when planning long-term orthodontic treatment, particularly in cases of dental crowding.

Limitations of the study

The sample size of the deciduous and mixed dentitions of the population studied was considerably smaller than the permanent dentition as is expected in a general skeletal collections where juvenile remains are relatively uncommon. This applies too to the mixed dentition where the sample could not be separated into an early, intermediate and late group. In addition, the cross-sectional nature of the study is a limitation and access to live patients would enhance knowledge as a longitudinal study could be undertaken.

Conclusion

The morphological changes observed in the current study occur concomitantly with the increased functional activities of the dentition and the oral soft tissues (including the tongue and soft palate), as well as the development and eruption of the dentition and the growth of the viscerocranium [18,42,43].

With the use of geometric morphometrics, the more subtle size and shape changes of the palate across the different states of the dentition are reflective of a progressive change due to dental eruption and development of the roof of the oral cavity. Multifactorial influences resulting from activities of the musculoskeletal structures of the oral cavity on the palate manifest as bone remodelling and appositional growth across the different states of the dentition.

Ethics approval

Ethics clearance to utilize the cadavers and skeletonized specimens for this study was obtained from the University of the Witwatersrand's Human Research Ethics Committee (HREC medical, W-CBP-210401-01).

Availability of data and material

Data related to the project is available in accordance with the terms and conditions as outlined by the Human Research Ethics Committee (medical) and the Collections Committee of the School of Anatomical Sciences, University of the Witwatersrand.

Disclosure of interest

The authors declare that they have no competing interest.

Funding

This work is based on research supported in part by the National Research Foundation of South Africa (Grant no. TTK180501325183).

Author contribution

N.O.: data collection, data analysis, manuscript writing/editing. B.K.: conceptualisation, data analysis, manuscript writing/editing. E.H.: conceptualisation, data analysis, manuscript writing/editing.

Acknowledgements

The authors wish to acknowledge the individuals who generously donated their bodies for teaching and research in our institution.

Appendix A. Supplementary data

Supplementary data associated with this article can be found, in the online version, at doi:10.1016/j.morpho.2023.100722.

Références

[1] Fish JL. Evolvability of the vertebrate craniofacial skeleton. Seminars in cell & developmental biology. Academic Press 2019;91:13—22.
[2] Humprey TA. Development of oral and facial motor mechanism in human fetuses and their relationship to craniofacial growth. Fetal Act Craniofac Growth 1971;50:1428—41.
[3] Herring SW. The ontogeny of mammalian mastication. Am J Zool 1985;25:339—49.
[4] Le Reverend GJD, Edelson LR, Loret C. Anatomical, functional, physiological and behavioural aspects of the development of mastication in early childhood. Br J Nutr 2014;111:403—14.
[5] Setiawati R, Rahardjo P. Osteogenesis and bone regeneration. In: Yang H, editor. Bone development and growth. London: Intechopen; 2018. p. 1—20.

[6] Hesby RM, Marshall SD, Dawson DV, Southard KA, Casco JS, Franciscus RG, et al. Transverse skeletal and dentoalveolar changes during growth. Am J Orthod Dentofacial Orthop 2006;130:721—31.
[7] Li J, Johnson CA, Smith AA, Hunter DJ, Singh G, Brunski JB, et al. Linking suckling biomechanics to the development of the palate. Sci Rep 2016;6:20419.
[8] Enlow DH, Bang S. Growth and remodeling of the human maxilla. Am J Orthod Dentofacial Orthop 1965;51:446—64.
[9] Martinez-Maza C, Rosas A, Nieto-Diaz M. Postnatal changes in the growth dynamics of the human face revealed from bone modelling patterns. J Anat 2013;223:228—41.
[10] Shapiro D, Richtsmeier JT. Brief communication: a sample of pediatric skulls available for study. Am J Phys Anthropol 1997;103:415—6.
[11] Walters C, Jansen JD. A troubled body of knowledge: the durability of racial science in human anatomy research in South Africa. Comp Educ Rev 2022;66:1—18.
[12] Petersen DC, Libiger O, Tondall EA, Hardie RA, Hannick LI, et al. Complex patterns of genomic admixture within southern Africa. PLoS Genet 2013;9:e1003309, http://dx.doi.org/10.1371/journal.pgen.1003309.
[13] Bajic V, Barbieri C, Hubner A, Guldemann T, Naumann C, et al. Genetic structure and sex-biased gene flow in the history of southern African populations. Am J Phys Anthropol 2018;167:656—71.
[14] Mokoena P, Billings BK, Gibbon V, Bidmos MA, Mazengenya P. Development of discriminant functions to estimate sex in upper limb bones for mixed ancestry South Africans. Sci Just 2019;59:660—6.
[15] Department of Statistics South Africa Census 2022. https://www.statssa.gov.za (accessed 28 July 2023).
[16] Alqahtani SJ, Hector MP, Liversidge HM. Brief communication: the London atlas of human tooth development and eruption. Am J Phys Anthropol 2010;142:481—90.
[17] Hutchinson EF, Farella M, Hoffman J, Kramer B. Variations in bone density across the body of the immature human mandible. J Anat 2017;230:679—88.
[18] Wise GE, He H, Gutierrez DL, Ring S, Yao S. Requirement of alveolar bone formation for eruption of rat molars. Eur J Oral Sci 2012;119:333—8.
[19] Bass WM. Human osteology: a laboratory and field manual. 5th edn. Springfield: Missouri Archaeological Society, Inc; 2005.
[20] Hutchinson EF, Farella M, Kramer B. Importance of teeth in maintaining the morphology of the adult mandible in humans. Eur J Oral Sci 2015;123:341—9.
[21] Mosimann JE. Size allometry: size and shape variables with characterizations of the lognormal and generalized gamma distributions. J Am Stat 1970;65:930—45.
[22] Klingenberg CP. Size, shape, and form: concepts of allometry in geometric morphometrics. Dev Genes Evol 2016;226:113—37.
[23] Bishara SE, Cummins DM, Jakobsen JR, Zaher AR. Dentofacial and soft tissue changes in Class II, division 1 cases treated with and without extractions. Am J Orthod Dentofacial Orthop 1995;107:28—37.
[24] Suda N, Hiyama S, Kuroda T. Relationship between formation/eruption of maxillary teeth and skeletal pattern of maxilla. Am J Orthod Dentofacial Orthop 2002;121:46—52.
[25] Bernabé E, del Castillo CE, Flores-Mir C. Intra-arch occlusal indicators of crowding in the permanent dentition. Am J Orthod Dentofacial Orthop 2005;128:220—5.
[26] Knott VB, Johnson R. Height and shape of the palate in girls. A longitudinal study. Arch Oral Biol 1970;15:849—60.
[27] Amirabadi GE, Golsha A, Derakhshn S, Khandan S, Saeidipour M, Nikkerdar N. Palatal dimensions at different stages of dentition in 5 to 18-year-old Iranian children and adolescent with normal occlusion. BMC Oral Health 2018;18:87.
[28] Marshall S, Dawson D, Southard KA, Lee AN, Casko JS, Southard TE. Transverse molar movements during growth. Am J Orthod Dentofacial Orthop 2003;124:615—24.
[29] Thilander B. Dentoalveolar development in subjects with normal occlusion. A longitudinal study between the ages of 5 and 31 years. Eur J Orthod 2009;31:109—20.
[30] Schönmeyr B, Sadhu P. A review of the tensor veli palatine function and its relevance to palatoplasty. J Plast Surg Hand Surery 2014;48:5—9.
[31] Swartz ME, Sheehan-Rooney K, Michael J, Dixon MJ, Eberhart JK. Examination of a palatogenic gene program in zebrafish. Dev Dyn 2011;240:2204—20.
[32] Baccetti T, Franch L, Cameron CG, McNamara Jr JA. Treatment timing for rapid maxillary expansion. Angle Orthod 2001;71:343.
[33] Moss-Salentijn L, Melvin L. Moss and the functional matrix. J Dent Res 1997;76:1814—7.
[34] Rachmiel A, Jackson IT, Sabapathy SR, Forte RA. Severe congenital hypoplasia of tongue and abnormal shape of soft palate and tonsillar pillars. Eur J Plast Surg 1993;16:149—53.
[35] Mandai H, Kinouchi K. Perioperative management of a neonate with aglossia-adactylia syndrome. Masui 2001;50:773—5.
[36] Salles F, Anchieta M, Bezerra PC, Lucia M, Torres ML, Queiroz E, et al. Complete and isolated congenital aglossia: case report and treatment of sequelae using rapid prototyping models. Oral Surg Oral Med Oral Pathol Oral Radiol Endod 2008;105:41—77.
[37] Rasool A, Zaroo MI, Wani AH, Darzi MA, Bashir SA, Bijli AH, et al. Isolated aglossia in a six year old child presenting with impaired speech: a case report. Cases J 2009;2:7926.
[38] Monroy PLC, Grefte S, Kuijpers-Jagtman AM, Wagener FA, Von den Hoff JW. Strategies to improve regeneration of the soft palate muscles after cleft palate repair. Tissue Eng Part B Rev 2012;18:468—77.
[39] Bommarito S, Zanato LE, Viera MM, Angelieri F. Aglossia: case report. Int Arch Otorhinolaryngol 2016;20:87—92.
[40] McMiken B, Vento-Wilson M, Warden M, Hall M, Rogers K. A child with congenital aglossia: a narrative review and descriptive case study. SAGE Open 2016;9:1—11.
[41] Wei X, Thomas N, Hatch NE, Hu M, Liu F. Postnatal craniofacial skeletal development of female C57BL/6NCrl mice. Front Physiol 2017;8:697.
[42] Yu SK, Lee MH, Park BS, Jeon YH, Chung YY, Kim HJ. Topographical relationship of the greater palatine artery and the palatal spine. Significance for periodontal surgery. J Clin Periodontol 2014;41:908—13.
[43] Bhushan R, Kumar S, Chauhan AK, Mohan S, Shekhar M, Naronly A. Assessment of the relationship between maxillary rotation and nasal morphology in males. Contemp Clin Dent 2015;6:12—7.