

https://dspace.org/

Large discs with large cups a diagnostic challenge in Black African patients

D Soma; Grant McLaren; Trevor Carmichael

https://hdl.handle.net/10539/35626
DHET

Downloaded from a DSpace repository. https://dspace.org/

Vol 15 | No 2 • Autumn 2020
SA Ophthalmology Journal

Large discs with large cups: a diagnostic challenge in Black African patients

D Soma MBChB, FC Ophth(SA), MMed(Wits); *Senior lecturer and Clinical Unit Head of Ophthalmology at the University of Pretoria, Steve Biko Academic Hospital, Pretoria, South Africa*
ORCID: http://orcid.org/0000-0001-6604-1815

GD McLaren MBBCh, FCS(SA)Ophth, FRC Ophth(UK); *Head of Department of Ophthalmology, Chris Hani Baragwanath Hospital (retired); Emeritus Professor, Division of Ophthalmology, Department of Neurosciences, University of the Witwatersrand, Johannesburg, South Africa*

TR Carmichael MBBCh(Wits), FC Ophth(SA), PhD(Med), MSc(Med); *Emeritus Professor, Division of Ophthalmology, Department of Neurosciences, University of the Witwatersrand, Johannesburg, South Africa*
ORCID: http://orcid.org/0000-0002-0659-6664

Corresponding author: Dr Darshana Soma, PO Box 13921, Laudium, 0037; tel: 0824892820; email: darshana.soma@gmail.com

Abstract

Background: The study was undertaken in order to determine in patients with large optic discs and large optic cups, the proportion with physiologic cupping (normal eyes) misdiagnosed as glaucomatous; and further, to evaluate the possible relationship between optic disc size and central corneal thickness.

Method and design: A case series of 69 Black African patients with large discs (vertical disc height measuring >1.8 mm) and large cups (vertical cup to disc ratio ≥0.6) was evaluated to determine what proportion had glaucoma. Patients categorised as normal were further evaluated to determine what proportion were previously misdiagnosed and treated for glaucoma. Patients with a suspected diagnosis of glaucoma, normal tension glaucoma or primary open angle glaucoma were recruited from the glaucoma clinic at St John's Eye Hospital, Soweto, South Africa.

Outcome measures included corrected vertical disc height (VDH), vertical cup to disc ratio (CDR), intraocular pressure (IOP), central corneal thickness (CCT), retinal nerve fibre layer (RNFL) analysis and visual fields.

Results: Sixty-nine Black African patients (138 eyes) with large discs and large cups were evaluated. Forty-one patients (59%) were females and 28 (41%) were males. The mean age was 56 years. Of the 69 patients, 51 (74%) had physiologic cupping (normal eyes) and 18 (26%) patients were glaucomatous. Of the group of 51 patients with physiologic cupping, there were nine patients who were previously misdiagnosed with glaucoma and who had received treatment.

VDH ranged between 1.9 and 3.2 mm (mean±SD, 2.3±0.26 mm). The distribution analysis of VDH measurements noted the largest cluster around 2.3 mm. CCT ranged between 454 µm and 618 µm (mean±SD, 516±37µm). Of the 138 eyes, 107 (77.5%) had CCT<544 µm.

Conclusion: Large CDR in relation to large disc size may be normal physiological cupping. It can be misdiagnosed as glaucomatous if objective RNFL analysis is not carried out. In this study, nine (18%) patients from a group of 51 patients with physiologic cupping were misdiagnosed as glaucomatous. There was no linear correlation between CCT and VDH in this study (Pearson's correlation coefficient was 0.13). The majority of eyes (77.5%) had thin corneas (CCT<544 µm).

Keywords: large discs, large cups, physiologic cupping, central corneal thickness, glaucoma, Black African

Funding: The authors received no funding towards this research.

Conflict of interest: The authors have no conflict of interest to disclose.

Introduction

Glaucoma is a disease that results in optic neuropathy. This manifests as increased cupping of the optic disc which is a typical feature of glaucomatous optic nerve damage. The vertical cup to disc ratio (CDR) has been used in the evaluation of glaucoma. The cup size is related physiologically to the disc size and pathologically to glaucomatous damage. Glaucomatous optic nerve damage leads to visual field changes. In addition, retinal nerve fibre layer (RNFL) atrophy occurs in glaucoma.

Diagnosing pathological changes based on CDR alone is of limited value. It is important to take into account the disc size.[1] There are different methods to measure disc size and each with its own strength and limitations. It is possible to measure the optic nerve head at the slit lamp with different types of lenses.[2] By using a slit lamp and a high magnification fundus lens (Volk 60D) a vertical slit is placed over the optic disc to measure the vertical disc diameter. Correction factors may be needed depending on the power of the lens used.[3] A 60 dioptre Volk lens has a correction factor of 0.92.[3]

Racial differences in optic disc size exist. Studies have shown that Black Africans have larger discs compared to Whites.[4,5]

Healey *et al.* showed in the Blue Mountain Eye Study that an increase in CDR occurs with an increased vertical disc size.[6] This is significant enough to warrant measurement of optic disc size. Large discs are defined as optic discs measuring 1.8 mm or more.[7] The importance of assessing CDR in relation to disc size was extensively studied by Jonas and co-workers[8] as well as Garway-Heath and associates.[9] They showed that the CDR for disc size has the highest diagnostic power compared to other optic disc parameters for separating normal subjects from pre-perimetric glaucoma patients.

It is clinically difficult to distinguish physiologic cupping from glaucomatous changes. Large CDR are sometimes misdiagnosed as glaucomatous. This can be prevented if disc size is measured because we know that large discs generally have large CDR.[6,8,9] In this way, the distinction between physiologic cupping and glaucomatous cupping can be made with greater confidence.

There is controversy about whether there is a positive correlation between disc size and RNFL thickness. A cross-section study by Budenz *et al.*[10] showed that for every mm^2 increase in cup disc area, the mean RNFL increased by 3.3 µm.

Central corneal thickness (CCT) plays an important role in the diagnosis of glaucoma. CCT influences intraocular pressure (IOP). In a cross-section study by Brandt *et al.*,[11] a total of 1 301 patients with ocular hypertension were studied to determine if CCT influences IOP measurements and if CCT is related to race. They found that CCT for Black Africans was 555.7 µm and CCT for Whites was 573 µm. They showed that Black Africans had thinner corneas than Whites and concluded that CCT may influence the accuracy of IOP measurements. Thin corneas underestimate IOP measurements and thick corneas overestimate IOP measurements.[1,12]

Objectives

The objectives of this study were to determine, in a cohort of 69 Black African patients with large optic discs and large optic cups, the proportion of patients with physiologic cupping misdiagnosed as glaucomatous; and secondarily to evaluate the possible relationship between optic disc size and CCT in these patients.

Study design

A case series consisting of 69 Black African patients with large optic discs and large optic cups was evaluated to determine what proportion had glaucoma and what proportion was normal. Patients categorised as normal were further evaluated to determine what proportion was misdiagnosed and treated as glaucoma. The relationship between disc size and CCT was also evaluated.

Glaucoma patients in this project are defined as patients who are diagnosed as glaucoma suspects, primary open angle glaucoma or normal tension glaucoma, and who attend the glaucoma clinic at St John's Eye Hospital, Soweto, South Africa.

Method

This was a convenience sampling of glaucoma patients with large optic discs and large optic cups, attending the glaucoma clinic at St John's Eye Hospital, who were invited to participate in the study. Informed consent was obtained from those patients willing to participate in the study and this research study was approved by the Human Research Ethics Committee (medical) at the University of the Witwatersrand, clearance certificate (M070435).

Large discs were defined as optic discs having a corrected vertical disc height (VDH) measuring more than 1.8 mm. Large cups are defined as CDR≥0.6.

Clinical examination included history, slit-lamp biomicroscopy findings which included IOP, gonioscopy and fundus examination that concentrated on the qualitative and quantitative measurements of the optic nerve head.

A Haag Streit biomicroscope was used to examine the eye. A 60D lens was used to examine and measure the optic disc head. A vertical slit beam was placed over the optic disc and the beam was adjusted to measure the vertical disc diameter. The measurement was read off the calibrated knob on the biomicroscope. A correction factor was needed for the lens (×1.02 for the Nikon 60D lens).[3]

A calibrated Goldmann tonometer was used to measure the IOP.

Gonioscopy was performed using a Volk three-mirror lens. The Shaffer-Etienne classification system was used in this study, which defines the following grades:

Grade 0 - No structures are visible and represents a closed angle

Grade 1 - Schwalbe line is visible and represents possible angle closure

Grade 2 - Schwalbe line and trabecular meshwork are visible but scleral spur not visible in a narrow angle

Grade 3 - Scleral spur is visible and angle closure is impossible

Grade 4 - All structures are visible from Schwalbe line to the ciliary band

Special investigations included refraction, visual fields, CCT measurements and RNFL analysis.

Refraction was carried out with a Nikon handheld autorefractor and refined subjectively. Patients who were more myopic than −8 dioptres or more hyperopic than +4 dioptres were excluded from the study. Children were excluded from the study. High myopes were excluded because they have markedly different appearance of the optic nerve head in normal and glaucomatous patients.[13,14] Also, the VDH is influenced by axial length (high myopia) and not by the distance of the lens from the cornea or by the refractive errors up to −8 dioptres.[15]

Four criteria were used to diagnose patients in the 'glaucoma' subgroup. A subgroup of patients with normal tension glaucoma was not included and remains a weakness in the study. The criteria were as follows:

1. A glaucoma suspect, defined as a patient with one of the following three features: an optic nerve or RNFL defect; or visual field abnormality consistent with glaucoma; or a consistently high IOP (>23 mmHg).[16]
2. Primary open angle glaucoma, defined as a triad of increased IOP, optic nerve head changes and changes on the visual field or RNFL analysis.[16]
3. Normal tension glaucoma, defined as IOP<21 mmHg with visual field defects and RNFL defects.[16]
4. Ocular hypertension, defined as IOP>23 mmHg and no changes on visual fields or the RNFL analysis.[16]

Visual fields were performed using the Oculus automated perimeter. This documented any functional loss or progression of function loss by the nerve over time. This was followed up for at least five years in order to exclude any progression to glaucoma in patients who were classified as having physiologic cupping.

The oculus automated perimeter was used to measure and document visual fields in all 138 eyes. Although the study was carried out over four months, visual fields done before the four months were also assessed and followed up for five years to ensure the absence of glaucomatous progression in patients diagnosed with physiologic cupping. The visual fields were compared to

ascertain if there were glaucomatous field losses or if there was any progression of field loss. Fields were categorised as having glaucomatous change, normal, unreliable or unsuccessful. In this study, fields with glaucomatous change were defined as one of the following: a glaucoma hemifield test outside normal limits on at least two consecutive occasions or a cluster of three or more non-edge points in a location typical for glaucoma or a corrected pattern standard deviation in less than 5% of normal individuals on two 26 consecutive fields.[16] Normal fields were defined as visual fields with no glaucomatous changes. Unreliable fields were defined as visual fields where glaucomatous changes were difficult to assess. Unsuccessful visual fields were due to profound visual loss. If the visual field did not assist in making the diagnosis of glaucoma then the clinical picture with the RNFL thickness was used to determine the diagnosis, and vice versa.

CCT was measured using the Heidelberg Engineering IOPac Advanced Pachymeter. In this study, CCT<544 µm was defined as a thin cornea.

The GDxVCC (Carl Zeiss Meditec Inc., Dublin CA, USA) is an RNFL analyser that uses scanning laser polarimetry to quantify nerve fibre layer thickness in order to detect early glaucomatous changes.[3] A retinal nerve fibre analysis was done with a scanning laser polarimeter to confirm the presence or absence of glaucomatous RNFL defect. This was based on the nerve fibre index TSNIT (temporal, superior, nasal, inferior, temporal) graph and parameters, and the deviation map.[17]

The parameters that were considered for the diagnosis of glaucoma or unclear were based on:

1. The nerve fibre index (NFI). This is the best parameter to differentiate glaucomatous and healthy eyes.[17] The NFI ranges from 0 to 100. The more advanced the glaucoma, the higher the NFI. Glaucoma eyes have NFI values of 35 and above and healthy eyes have NFI values of 44 and below. An NFI value of between 35 and 44 is considered borderline and therefore other data in the GDxVCC printout may be used to make the diagnosis of glaucoma.
2. The TSNIT graph. This shows RNFL values of each of the eyes on the expected age-related normal range.[17]
3. The deviation map. This map plots the RNFL values that deviate from the normal range. The colour-coded p-values indicate the extent of the deviation.[17]

Outcome measures

- Central corneal thickness (CCT)
- Intraocular pressure (IOP)
- Corrected vertical disc height (VDH)
- Vertical cup to disc ratio (CDR)
- Relationship between VDH and vertical cup height
- Relationship between VDH and CCT
- Retinal nerve fibre layer (RNFL) analysis
- Visual fields

The Excel database was used for data summary. Statistics were performed using the statistical software Stata version 8 (Stata Corporation, College station, Texas, USA).

Results

A total of 138 eyes of 69 Black African patients were evaluated. Forty-one (59%) were females and 28 (41%) were males. Patient ages ranged between 18 and 87 years with a mean of 56 years. Visual acuity ranged from 6/6 to light perception. Refractive errors extended from myopia of −6.5 D to hyperopia of +4 D.

Of the 69 patients with large discs and large cups, 51/69 (74%) had normal eyes and 18/69 (26%) had pathologic cupping. The group of 51 patients with normal eyes was further evaluated and 9/51 (18%) were previously misdiagnosed and treated with anti-glaucoma medications. The main reason for the misdiagnosis was an increased CDR in the presence of a large disc.

Central corneal thickness (CCT)

CCT ranged between 454 µm and 618 µm. The mean CCT was 516 µm±37.5 µm. (*Figure 1*). Out of a total of 138 eyes, 107 eyes (77.5%) had CCT<544 µm (thin corneas).

Intraocular pressure (IOP)

The IOPs measured with the Goldmann applanation tonometer ranged between 6 mmHg and 23 mmHg, and the mean IOP was 13±3.5 mmHg.

Corrected vertical disc height (VDH)

Vertical and horizontal disc diameters were measured. The VDH ranged between 1.9 mm and 3.2 mm (mean±SD, 2.3±0.26 mm). The horizontal disc diameters (HDD) ranged between 1.7 mm and 2.9 mm (mean±SD, 2.1 mm±0.21 mm) (*Figure 2*).

Vertical cup to disc ratio (CDR)

The vertical CDR was measured relative to VDH. CDR ranged from 0.6 to 1 (mean±SD, 0.7±0.08).

Relationship between VDH and vertical cup height

The vertical cup height was calculated by taking the CDR and multiplying it by the

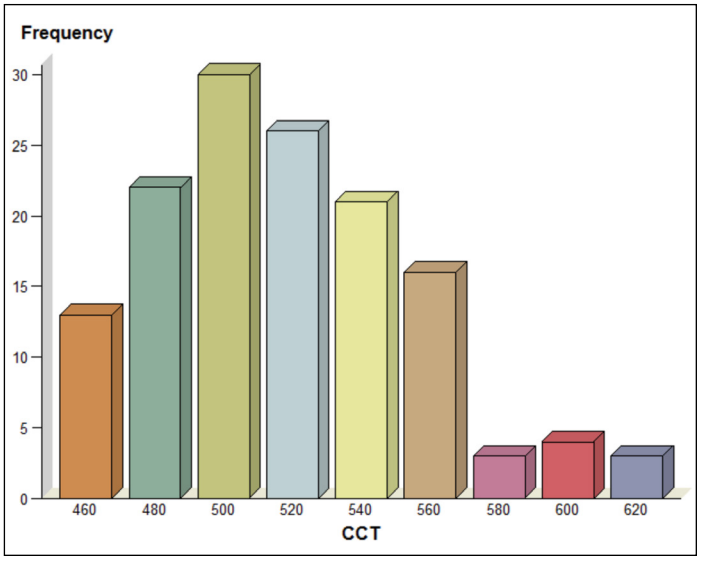

Figure 1. Distribution of central corneal thickness

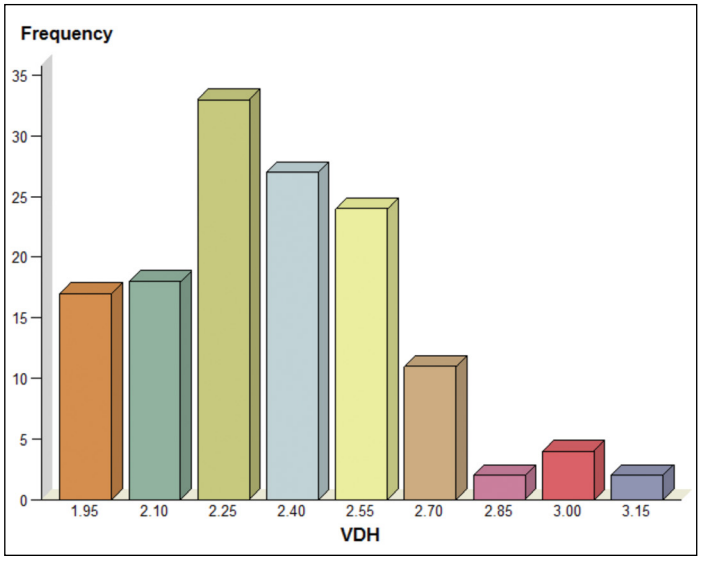

Figure 2. Distribution of vertical disc height

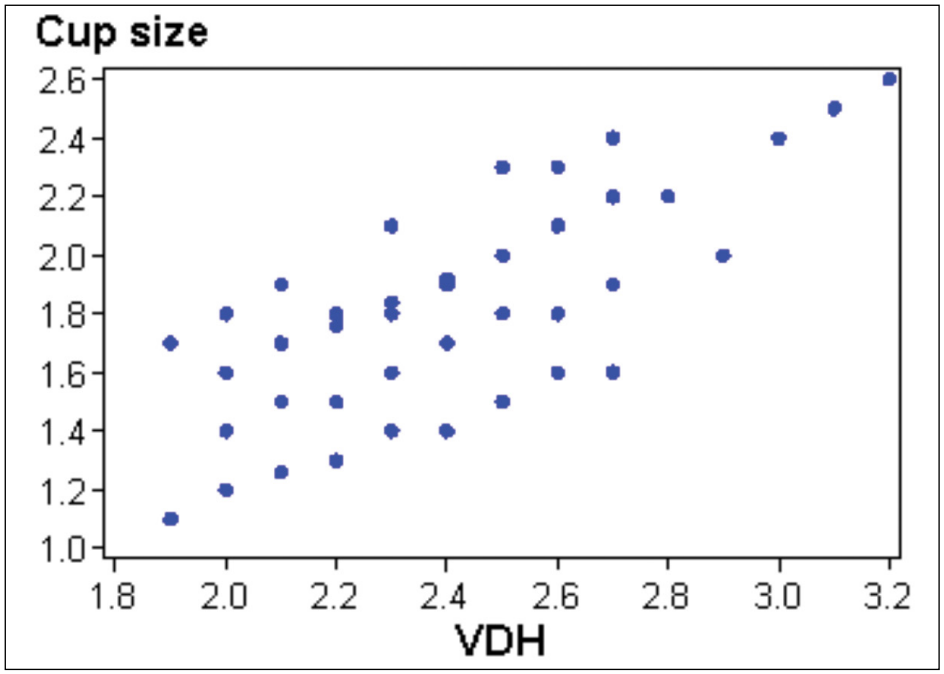

Figure 3. The relationship between VDH and vertical cup height

VDH. The vertical cup height increased with an increase in VDH. There was a positive linear relationship between the vertical cup height and the VDH (*Figure 3*).

Relationship between VDH and CCT

VDH ranged between 1.9 mm and 3.2 mm. The CCT ranged from 454 µm to 618 µm. There was no linear correlation between VDH and CCT. The Pearson correlation co-efficient was 0.13.

Retinal nerve fibre layer (RNFL) analysis

The nerve fibre index (NFI) for normal eyes ranged between 3 and 44. The mean NFI for all normal eyes was 38. The NFI for glaucoma eyes ranged between 35 and 98. The mean NFI for glaucoma eyes was 49.6. In eyes that had borderline NFI values, i.e. NFI values between 35 and 44, other parameters on the GDxVCC together with the visual fields were used to determine if the eye had glaucoma. The GDxVCC evaluation was unsuccessful in eight eyes because of poor visualisation of the fundi due to cataract formation.

Visual fields

Of the 69 patients, 51 patients had physiologic cupping and 18 patients had pathologic cupping based on clinical examination and visual fields alone. In the group with physiologic cupping, nine patients (13%) had unreliable visual fields and were misdiagnosed as glaucoma. The misdiagnosis was made because these patients did not have RNFL thickness done at their initial diagnosis. Forty-two patients (61%) were correctly diagnosed as having physiologic cupping of the optic discs and had normal visual fields over a period of five years.

Discussion

Examination of the optic nerve head in glaucoma commonly involves the evaluation of the optic cup, the neuroretinal rim contour and the RNFL. An important but overlooked component of the optic nerve head evaluation is measurement of the optic disc size.

In healthy subjects, small discs can have small cups and large discs can have large cups.[15] Large discs with large cups can therefore be misdiagnosed as glaucoma. Sometimes the visual fields obtained may be unreliable and therefore the diagnosis of glaucoma becomes a challenge to the ophthalmologist.

This study was limited to Black African patients. There were several reasons for this. First, there is an increased prevalence of glaucoma in Black African patients. This was shown in the Baltimore Eye Study which showed that African-Americans have a higher prevalence of glaucoma across all age groups when compared to Whites in the same city.[18,19] A study done by Rotchford *et al.*[20] also showed that glaucoma was one of the leading causes of blindness in people of Black African origin in rural Zululand (South Africa). Secondly, the optic disc head characteristics in Black African patients differ from their White counterparts.[4,5,20] Black African patients have larger optic disc sizes when compared to their White counterparts.[4,5] Thirdly, Black African patients have thin CCT when compared to their White counterparts.[1,11,12,21,22] By limiting the data to Black African patients, it was hoped that consistent results, not confounded by findings from other racial groups, would be obtained.

Optic disc size is influenced by a number of demographic factors that include race, age and sex. In addition, variation in anatomical structures of the optic nerve head and the RNFL is associated with variation in disc size. Due to the small number of cases, a limitation of this study is that no comparisons could be drawn about disc size related to age and sex.

Black Africans have larger discs when compared to their White counterparts.[12,16] The mean vertical and HDDs as measured by Quigley *et al.* for the disc of a normal human eye is a vertical disc diameter of 1.88 mm and a horizontal diameter of 1.77 mm.[23] In this study, large discs were defined as discs with a vertical height measuring more than 1.8 mm. The VDH ranged between 1.9 and 3.2 mm (mean±SD, 2.3±0.26) and the HDD ranged from 1.7 to 2.9 mm (mean±SD, 2.1±0.22). Studies conducted by Quigley *et al.* also demonstrated large VDH in Black Africans (1.96±0.16) compared to the VDH of Whites (1.82±0.15).[23] This study showed much larger disc sizes, possibly due to genetic variation. There was a normal Gaussian distribution for VDH (*Figure 2*). Large cups were defined as a cup-disc ratio greater than 0.6. The Blue Mountains Eye Study showed that that for each 0.1 mm increase in disc diameter there was an increase in CDR of 0.27.[6,7] Beck *et al.* reported that large discs have proportionately large CDRs in the normal eyes of Black African subjects.[24] The data from our study showed that there was a direct linear relationship between VDH and vertical cup height (*Figure 3*).

CCT influences IOP measurements. The mean CCT in the normal human eye is 545 µm.[22] In this study, the CCT ranged from 457 µm to 616 µm (mean±SD, 516±37 µm) and 77.5% of patients had thin corneas (CCT<544 µm). Thick corneas overestimate actual IOP measurements and thin corneas underestimate IOP measurements.[12] In this study, no correlation could be found between disc size and CCT. The Pearson correlation co-efficient was 0.12667. Pakravan *et al.* showed that there was an inverse relationship between disc size and CCT in African-American patients, but that this was not statistically significant. [12]

To diagnose glaucoma, the following criteria were used: an increased IOP; structural changes of the optic nerve head; visual field changes and corresponding RNFL damage on the scanning laser polarimeter (GDxVCC). In this study, unreliable visual

fields sometimes made it difficult to make a diagnosis of glaucoma and the researchers therefore had to rely on the RNFL analysis to assist with the diagnosis. It is important to bear in mind that during early glaucoma, there may not be visual field defects and patients therefore needed to be followed up for at least five years to ensure that patients categorised as having physiologic cupping did not progress to glaucoma.

Of the 69 patients studied, 51 patients (74%) had physiologic cupping and 18 patients (26%) had pathologic cupping. Of the 51 patients with physiologic cupping, nine (18%) were previously misdiagnosed as glaucoma and had received unnecessary treatment while the other 42 (82%) patients were correctly diagnosed as physiologic cupping.

A significant number of patients in the group of patients with large discs (51/69) had physiological cupping. The researchers concluded that although Black Africans are more susceptible to glaucoma and have large discs, large discs on their own are not a risk factor for the development of glaucoma. The researchers further concluded that large discs that have proportionately larger cups are more likely to be misdiagnosed as glaucoma than be diagnosed as physiologic cupping. Nine of the 51 patients were erroneously misdiagnosed and treated for glaucoma. The reason for the misdiagnosis was a large cup size in a large disc. Studies conducted by Heijl and Mölder showed that larger discs were more likely to be misdiagnosed with glaucoma than were smaller discs.[25] It is logical therefore that disc size may affect the diagnosis.

Of the nine patients misdiagnosed and treated for glaucoma, one patient had undergone surgery unnecessarily. The patient who had undergone surgery did not disclose that she had been taking allergy medication (comprising topical steroids). On examination, she was found to have large cups, an increased IOP and unreliable visual fields. At that point in time ophthalmologists at the hospital did not have access to a scanning laser polarimeter such as the GDxVCC. A trabeculectomy was carried out. Post-trabeculectomy, her IOP increased and it was then discovered that she was a steroid responder. She was found to have large discs with large cups. Years later when the scanning laser polarimeter (GDxVCC) became available, the RNFL of this patient showed no RNFL defects.

Although the literature reports an increased incidence of glaucoma in Black African patients, one has to be very careful in diagnosing a patient with glaucoma, because the possibility of physiological cupping in Black African patients with large discs must be considered.

Conclusion

Black Africans have large discs and patients with large discs have corresponding large cups. Large cups do not necessarily imply that the patient has glaucoma. In this study, the majority – 51 of the 69 patients (74%) – with large discs and large cups had physiologic cupping. Nine of the 51 patients were misdiagnosed as having glaucoma. The main reason for misdiagnosis was a large cup in relation to a large disc. Measuring these parameters may aid in preventing the misdiagnosis of glaucoma, unnecessary treatment and morbidity to these patients.

Black Africans have thin corneas and may have large discs. The CCT may influence IOP. In this study, 77.5% of patients had thin corneas (CCT<544 µm) but the researchers found no inverse correlation between CCT and disc size.

References

1. LaRosa F, Gross R, Orengo-Nania S. Central corneal thickness of Caucasians and African-Americans in glaucomatous and non-glaucomatous populations. *Arch Ophthalmol.* 2001;**119**:23-27.
2. Ansari-Shahrezaei S, Maar N, Biowski R, *et al*. Biomicroscopic measurement of the optic disc with a high-power positive lens. *Invest Ophthalmol Vis Sci.* 2001;**42**:153-57.
3. Hitchings RA, Migdal C, Bechetoille A, *et al*. *Terminology and guidelines for glaucoma*. 2nd ed. Italy: Editrice DOGMA s.r.l, 2003:1-13,1-19,1-20.
4. Chi T, Ritch R, Stickler D, *et al*. Racial differences in optic nerve head parameters. *Arch Ophthalmol.* 1989;**107**:836-39.
5. Varma R, Tielsch JM, Quigley HA, *et al*. Race, age, gender and refractive error related differences in the normal optic disc. *Arch Ophthalmol.* 1994;**112**:1068-76.
6. Healey PR, Mitchell P, Smith W, *et al*. Relationship between cup-disc ratio and optic disc diameter: The Blue Mountains Eye Study. *Aust N Z J Ophthalmol.* 1997;**25**:S99-101.
7. Crowston JG, Hopley CR, Healey PR, *et al*. The effect of optic disc diameter on vertical cup to disc ratio percentiles in a population-based cohort: The Blue Mountains Eye Study. *Br J Ophthalmol.* 2004;**88**:766-70.
8. Jonas JB, Bergua A, Schmitz-Valckenberg P, *et al*. Ranking of optic disc variables for detection of glaucomatous optic nerve damage. *Invest Ophthalmol Vis Sci.* 2000;**41**:1764-73.
9. Garway-Heath DF, Ruben ST, Viswanathan A, *et al*. Vertical cup/disc ratio in relation to optic disc size: Its value in the assessment of the glaucoma suspect. *Br J Ophthalmol.* 1998;**82**:1118-24.
10. Bedenz DL, Anderson DR, Varma R, *et al*. Determinants of normal retinal nerve fibre layer thickness measured by Stratus OCT. *Ophthalmology.* 2007;**5**:1-5.
11. Brandt JD, Beisser JA, Kass MA, *et al*. Central corneal thickness in Ocular Hypertension Treatment Study (OHTS). *Ophthalmology.* 2001;**108**:1779-88.
12. Pakravan M, Parsa A, Sanagou M, *et al*. Central corneal thickness and correlation to optic disc size: A potential link for susceptibility to glaucoma. *Br J Ophthalmol.* 2007;**91**:26-28.
13. Jonas JB, Gusek GC, Naumann GOH. Optic disc morphology in high myopia. *Graefes Arch Clin Exp Ophthalmol.* 1988;**226**:587-90.
14. Jonas JB, Dichtl A. Optic disc morphology in myopic primary open-angle glaucoma. *Graefes Arch Clin Exp Ophthalmol.* 1997;**235**:627-33.
15. Susanna R Jr, Vessani RM. New findings in the evaluation of the optic disc in glaucoma diagnosis. *Curr Opin Ophthalmol.* 2007;**18**:122-28.
16. Salmon J. *Kanski's Clinical Ophthalmology. A Systematic Approach*. 9th ed. Butterworth-Heinemann. Elsevier. 2021.
17. Lester M, Garway-Heath D, Leimj H. Optic nerve head and retinal nerve fiber analysis. Italy: Editrice DOGMA s.r.l, 2003:101-102.
18. Tielsch JM, Sommer A, Katz J, *et al*. Racial variations in the prevalence of primary open angle glaucoma: Baltimore Eye Survey. *JAMA.* 1991;**266**:369-74.
19. Kyari F, Abdull MM, Bastawrous *et al*. Epidemiology of glaucoma in Sub-Saharan Africa: prevalence, incidence and risk factors. *Middle East Afr J Ophthalmol.* 2013;**20**(2):111-25.
20. Rotchford AP, Johnson GJ. Glaucoma in Zulus: A population-based cross-sectional survey in a rural district in South Africa. *Arch Ophthalmol.* 2002;**120**:471-78.
21. Doughty MJ, Zaman ML. Human corneal thickness and its impact on intraocular pressure measures: a review and meta-analysis approach. *Surv Ophthalmol.* 2000;**44**:367-408.
22. Baboolal SO and Smit DP. South African Eye Study (SAES): ethnic differences in central corneal thickness and intraocular pressure. *Eye.* 2018;**32**:749-56.
23. Quigley HA, Brown AE, Morrison JD, *et al*. The size and shape of the optic disc in normal human eyes. *Arch Ophthalmol.* 1990;**108**:51-57.
24. Beck RW, Messner DK, Musch DC, *et al*. Is there a racial difference in physiologic cup size? *Ophthalmology.* 1985;**92**:873-76.
25. Heijl A, Mölder H. Optic disc diameter influences the ability to detect glaucomatous disc damage. *Acta Ophthalmol.* 1993;**71**:122-29.