

https://dspace.org/

Herpes zoster ophthalmicus in human immunodeficiency virus positive patients presenting to St John Eye Hospital: clinical presentation and ocular complications

Botha, Andre F

2014-03-31
http://hdl.handle.net10539/14421

Downloaded from a DSpace repository. https://dspace.org/

HERPES ZOSTER OPHTHALMICUS IN HUMAN IMMUNODEFICIENCY VIRUS POSITIVE PATIENTS PRESENTING TO ST JOHN EYE HOSPITAL: CLINICAL PRESENTATION AND OCULAR COMPLICATIONS

Andre F Botha

A research report submitted to the Faculty of Health Sciences, University of the Witwatersrand, Johannesburg, in partial fulfillment of the requirements of the degree of Master of Medicine Ophthalmology.

Johannesburg, 2013

DECLARATION

I, Andre Botha, declare that this research report is my own work. It has been submitted for the degree of Master of Medicine in Ophthalmology at the University of the Witwatersrand, Johannesburg. It has not been submitted before for any degree or examination at this or any other university.

_____

29th day of October 2013

The work reported in this dissertation was carried out at the St. John Eye Hospital, Johannesburg, South Africa.

DEDICATION

To my parents, Johan and Suzanne, for their love and encouragement.

To my wife, Barbara, for her love and patience.

To my daughter, Charlotte, for filling every day with smiles.

ETHICS APPROVAL

This project was approved by the Human Research Ethics Committee (Medical) at the University of the Witwatersrand.

Clearance certificate number: M080924

PRESENTATIONS ARISING FROM THIS STUDY

An abstract was submitted for consideration for presentation at the annual congress of the Ophthalmological Society of South Africa (OSSA) at the Sun City Resort, February 2010. The abstract was accepted and the paper was presented as an oral presentation at the above congress. Abstracts dealing with specific aspects of this study will be prepared for submission for publication

ABSTRACT

Purpose: To describe the clinical presentation, ocular complications and clinical implications of acute HZO in HIV positive patients.

Method: Prospective descriptive clinical case series of 54 individuals aged 18 – 50 years with confirmed HIV infection and acute presentation of HZO.

Results: A female preponderance (1.7:1) and mean age of 36.6 years (range 18 – 49 years) was recorded. The majority of patients were referred from CHC and only 28% of referred patients received appropriate antiviral treatment at the referral site. Mean duration of rash at presentation was 4.7 days (range 1 – 12 days) with 31% of patients presenting within 3 days of rash eruption. Patients attended a mean of 2.7 clinical visits. Equal proportions had known and unknown HIV serostatus at presentation. Mean $CD4^+$ was 276 cells/mm^3 (range 44 - 859 cells/mm^3). 67% of patients had a $CD4^+$ count < 350 cells/mm^3. Periocular discomfort was the most common presenting symptom (70%); decreased VA (2%) was an uncommon presenting symptom. Multidermatomal involvement was uncommon (7%). At presentation normal VA was seen in 69% of patients and 94% had no global visual impairment. Corneal complications (89%) and intraocular inflammation (46%) were the most common ocular complications. Ocular complications at presentation and multiple complications were the rule (70% and 61%). Hutchinson sign was found to be of little clinical value. Visual outcome was fair, 22% of patients having residual visual impairment. Post-herpetic neuralgia was common (74%).

Conclusion: HZO is a common HIV marker condition with ocular complications. It may have an application as an indication for the initiation of ARV treatment.

ACKNOWLEDGEMENTS

Many thanks to:

My supervisor, Prof Ismael Mayet, for his encouragement and suggestions for this study.

Prof Trevor Carmichael, the head and research coordinator of our department, for advice, assistance with the preparation of this research report and accompanying presentation and statistical analysis of study data.

Prof E Frohlich, of the Helen Joseph Hospital Anaesthetics Department, for advice in matters of pain management.

Mr. ML Perold, for proofreading the manuscript.

Mr. S Pimenta for digitization of study materials.

The participants in this study for their involvement in this study.

My fellow registrars at St John Eye Hospital for their assistance in identifying suitable participants for this study.

The nursing staff at St John Eye Hospital for their assistance as translators, counselors and in taking observations.

CONTENTS

Page

DECLARATION…….ii

DEDICATION……iii

ETHICS APPROVAL……....iv

PRESENTATIONS ARISING FROM THIS STUDY……v

ABSTRACT……...vi

ACKNOWLEDGEMENTS……..vii

CONTENTS……...……..…ix

LIST OF FIGURES……..…x

LIST OF TABLES……..xi

PREFACE……..……...xii

CHAPTER 1.0 INTRODUCTION……...……...1

CHAPTER 2.0 LITERATURE REVIEW……...7

CHAPTER 3.0 RESEARCH OBJECTIVES…...……..…21

CHAPTER 4.0 PARTICIPANT SELECTION AND METHODS……...22

CHAPTER 5.0 RESULTS…….…27

CHAPTER 6.0 DISCUSSION……...49

CHAPTER 7.0 CONCLUSION……57

CHAPTER 8.0 REFERENCES…….58

LIST OF FIGURES

Page

Figure 1 – Age distribution by gender……...28

Figure 2 - Knowledge of HIV status by site of referral…….31

Figure 3 - Average duration of rash to referral……..31

Figure 4 - Appropriate treatment at referral site……32

Figure 5 – Appropriate referral within 3 days of start of rash……...32

Figure 6 – Distribution of $CD4^+$ count (cells/mm^3)…….. ……..33

Figure 7 – Percentage of $CD4^+$ counts below 200 and 350 cells/mm^3 by gender…….34

Figure 8 – Distribution of $CD4^+$ counts (cells/mm^3) by knowledge of HIV status……...35

Figure 9 – Percentage of $CD4^+$ counts below 200 and 350 cells/mm^3 by knowledge of HIV status……...….35

Figure 10 – Scatter plot of body mass index (BMI)……..38

Figure 11 – Presenting visual acuity (VA) and visual impairment……39

Figure 12 – Encountered specific ocular complications of HZO…….…41

Figure 13 – VA and visual impairment on study exit……46

Figure 14 – Change in VA from presentation to study exit……...…47

LIST OF TABLES

Page

Table 1 – Key HIV statistics……2

Table 2 - Participant and treatment characteristics by site of referral……...30

Table 3 – Analysis of number of individual complications/participant by gender…..…41

Table 4 – Analysis of number of individual complications/participant by age…….....42

Table 5 – Analysis of number of individual complications/participant by $CD4^+$ count..43

Table 6 – Analysis of number of individual complications/participant by body mass index (BMI)……..…44

Table 7 – Sensitivity, specificity and predictive values of Hutchinson's sign……..45

PREFACE

I first became interested in herpes zoster ophthalmicus (HZO) as a common and often devastating ocular complication of human immune deficiency virus (HIV) infection whilst an ophthalmology medical officer at a secondary level hospitals in the Eastern Cape and Gauteng provinces of South Africa.

It was my observation that patients with this condition were commonly not referred for assessment by an ophthalmologist in the acute phase of disease and often presented with late and sight threatening complications.

I am particularly interested in establishing the role of this condition as a marker condition for the diagnosis of HIV infection in South Africa, rates of ocular complications in the acute phase of illness and rates of post-herpetic neuralgia. I am also interested in determining the role of this condition as an indication for initiation of highly active antiretroviral treatment (HAART).

Furthermore, there is limited recent literature dealing with this condition in an African setting where there is access to HAART.

1.0 INTRODUCTION

Since the emergence of acquired immune deficiency syndrome (AIDS) and the identification of HIV as the causative agent for this syndrome it has had an immense impact on pubic health care systems globally. Sub-Saharan Africa has emerged as the epicenter of the global pandemic.

In a review by Evans (1) certain aspects of an UNAIDS estimate from 2004 are highlighted. These include that, of the 38 million people living with HIV globally, 25 million are in Sub-Saharan Africa and that of an estimated 4.8 million people that acquired HIV in 2003, 3 million were in Sub-Saharan Africa. The author also remarked that syphilis has re-emerged as a cofactor for heterosexual spread of HIV infection and that the interaction between HIV and tuberculosis (TB) has resulted in an increase in TB infection. The impact of HIV infection has been less in countries where HAART has become available and the lack of HAART therapy in many Sub-Saharan African countries has led to the premature death of economically active members of the population (1).This in combination with the impact on the healthcare and education workforce and breakdown of the family unit has compounded the already great socioeconomic impact in resource poor countries (1).

Table1 - Key HIV statistics (compiled from Treatment Action Campaign website) (2)

Statistic	Value	Date and source
HIV prevalence	5.4 million	Department of Health (DOH) (2007)
People over age of 2 years with HIV	10.8% Males 8.2% Females 13.3%	Human Sciences Research Council (HSRC) (2005)
Pregnant women with HIV	29.1%	DOH
Annual AIDS deaths	400 000	Actuarial Society of South Africa (ASSA) 2003 (2011)
Cumulative AIDS deaths	2.5 million	ASSA 2003 (June 2008)
People enrolled in public sector antiretroviral program	488 739	South African report to United Nations General Assembly Special Session (UNGASS)

		(End November 2007)
People that initiated antiretroviral treatment in public health system	371 731	South African report to UNGASS (End November 2007)
People enrolled in private sector antiretroviral program	100 000	Joint Civil Society Monitoring Forum (2007)
People requiring antiretroviral therapy but not receiving it	524 000	ASSA 2003 (2008)

The HIV pandemic has been accompanied by increased rates of specific infectious and neoplastic conditions. It has been reported that 85% of opportunistic infections occur at $CD4^+$ counts of < 200 cells/mm^3 (3). The ocular complications of HIV infection first came to prominence in 1982 and a wide spectrum of disease has been described (4). The eye and ocular adnexa are commonly affected during the course of HIV infection with an estimated 52 – 100% of HIV infected individuals having an HIV-associated ocular manifestation during the course of their illness (5). Conditions affecting 1 eye, such as HZO and conjunctival squamous carcinoma, are relatively more common in developing

countries (6). Corneal and anterior segment pathology occurs in > 50% of patients, whilst adnexal pathology, that may indicate severe immunosuppression, occurs in 25% (7). In the African setting anterior segment disorders and adnexal pathology, notably conjunctival squamous carcinoma predominate (7). Up to 53% of HIV infected individuals have additional anterior segment disorders such as conjunctivitis, blepharitis and corneal ulcers (6). Different manifestations are seen in patients categorized by World Health Organization (WHO) stage (6):

1. Stage 1 ($CD4^+ > 1000$ cells/mm^3)

   Dry eye and conjunctival injection are most common.

2. Stage 2 ($CD4^+$ 500 – 1000 cells/mm^3)

   Allergic conjunctivitis, intermediate conjunctivitis, retinal vasculitis, HIV retinopathy and optic neuritis are most common.

3. Stage 3 ($CD4^+$ 200 – 500 cells/mm^3)

   Dry eye, blepharitis, bacterial and follicular conjunctivitis, Kaposi's sarcoma, molluscum contagiosum, HZO, herpes simplex (HSV), HIV retinopathy and aspergillosis are most common.

4. Stage 4 ($CD4^+ < 200$ cells/mm^3)

   Opportunistic infections predominate

The majority of ocular manifestations occur in patients with stage 3 disease (6).

HAART therapy has decreased the rate of blinding posterior segment disease as well as anterior segment pathology and adnexal disease (7). With the advent of HAART therapy, immune reconstitution inflammatory syndrome (IRIS) has assumed great importance (7).

Hodge, Seiff and Margolis (5) studied the incidence of ocular opportunistic infections in HIV positive and HIV negative subgroups. The conditions studied were cytomegalovirus (CMV) retinitis, HZO, pneumocystis carinii choroidopathy, herpes simplex keratitis, toxoplasma retinitis, fungal retinitis, ocular syphilis and ocular lymphoma. Only CMV retinitis, HZO and to a lesser extent toxoplasma retinitis showed an elevated risk ratio and rate difference between the 2 groups. All ocular infections in HIV seropositive patients should therefore not be considered opportunistic.

Historically CMV retinitis has been the most important HIV-associated ocular manifestation occurring at $CD4^+$ counts < 50 cells/mm^3 with the cumulative lifetime incidence being 25-40% in HIV positive patients (5). In contrast HZO occurs at greater $CD4^+$ counts, usually 200 – 400 cells/mm^3 at time of 1st episode, and therefore HAART is expected to have less of an impact on its incidence (4). The relative incidence risk ratio relative to HIV negative patients is 6.6/1 (5). The effect of HAART on HIV-associated ocular manifestations still needs to be elucidated. In the African setting it is thought that CMV retinitis is relatively less common due to higher mortality rates associated with systemic opportunistic infections that occur earlier in the course of the disease (8). The most common of these infections are TB, bacteraemia, cerebral toxoplasmosis, cryptococcosis, invasive salmonellosis and recurrent bacterial pneumonia with TB being the most common cause of death in Sub-Saharan Africa (8). The incidence of ocular manifestations of HIV infection is difficult to study in the African setting because only patients that can afford to attend hospital can participate in studies, the rate of mortality amongst hospitalized patients is high and patients that discharge themselves from hospital

often die at home without returning to hospital (8). In a study conducted in Burundi (8), 21% of patients studied had ocular abnormalities with many of them being asymptomatic. CMV retinitis and HZO was less common, the latter as it occurs earlier in the course of HIV infection. Kaposi's sarcoma was found to be less common but conjunctival squamous cell carcinoma to be more common. Anterior uveitis was found to be due to a variety of infectious agents. The most common abnormality encountered was HIV-associated microangiopathy (HIVAM) that was found in 10% of patients and was found increasingly in later stages of disease.

2.0 LITERATURE REVIEW

Varicella zoster virus (VZV), a human herpes virus, causes childhood varicella or chickenpox and later in life, zoster or shingles. Zoster develops when the virus, that has remained latent in the sensory ganglia, reactivates (3). Latent viral reactivation leads to viral replication with resulting necrosis and inflammation in the affected sensory ganglia (9).

The most common dermatomes affected are thoracic, lumbar and cervical (3). HZO is the most common specific form of zoster that results from the reactivation of latent trigeminal ganglionic VZV (9, 10, 11). The first division of this nerve is involved 20 times more commonly than the other 2 divisions (12). Involvement of the trigeminal nerve, and of other cranial nerves, notably, the facial and vestibulocochlear nerve is found in 20% of zoster cases (9). The ophthalmic division of the trigeminal nerve is involved in 10 – 17% of zoster cases (3).

The major risk factors for the development of this condition are advancing age and conditions causing depressed cell mediated immunity (CMI) such as HIV infection, malignancy and iatrogenic immunosuppression (10). A search for underlying malignancy is not warranted in healthy patients that present with zoster but risk factors for HIV infection should be sought in all patients (9, 13). It is recommended that all patients under the age of 50 years should have serological testing for HIV infection (4, 9, 13). In addition it has been suggested that protease inhibitors, as part of HAART, may

predispose AIDS patients to VZV infection (3). This increased risk was found to be independent of age, gender, type of protease inhibitor and $CD4^+$ count and viral load (VL) at baseline (7). An increase of CD8+ > 5% at 1 month may confer risk and may be useful in prophylactic decision making (7). HZO may be associated with improved immune status in those receiving HAART and has become more common with the advent of the HAART era (7). The peak incidence is between the ages of 40 and 70 years with equal gender distribution (10). In the setting of conditions causing decreased CMI, HZO is seen in younger age groups. Zoster is not considered to be an AIDS-defining illness, but is considered to be a strong predictor of HIV infection in young African adults and may be the sentinel event in the diagnosis of HIV (3, 14, 15). In a study conducted by Palexas et al (15), a HIV seropositivity rate of 40% was found with the majority of individuals being less than 40 years of age. This condition may precede other signs of immunosuppression in up to 3/4 of patients. This correlation has been shown to be greater in younger patients by Adio et al (16). In AIDS, recurrent episodes are seen in 19 – 27% of patients in contrast with 1 – 4% in immunocompetent hosts (3).

More than 90% of adults in the United States of America have serological evidence of past VZV infection and are therefore at risk of developing zoster (13). The lifetime risk of developing zoster is 10 – 20% and the condition occurs in 8 – 11% of patients with AIDS (3, 14). The significance of VZV infection in terms of mortality and the rate of progression to AIDS are unclear (3).

The acute illness initially presents with headache, fever, malaise and chills that are usually followed by unilateral pain or hypoaesthesia of the forehead and top of head (10). This prodromal stage is found in 80% of patients (9). Within 2 – 3 days there is eruption of crops of vesicles that crust and scar over a period of 2 – 4 weeks (10). Both haemorrhagic (*zoster haemorrhagicus*) and gangrenous (*zoster gangraenosus*) forms have been described (9). There may also be superadded infection (9). Classically the lesions do not cross the midline (3). Rarely, the lesions can cross the midline, a condition known as *zoster duplex* (9). In immunocompromised hosts, multiple dermatomes may become involved and vesicles may continue to appear for a longer period and may take longer to resolve (3). The pattern of lesion development can even appear varicelliform. Skin lesions can also become chronic and ulcerative. This suggests that prolonged therapy may be required (3, 13). In these patients complications occur with increased frequency and may present atypically (3). Yau et al (17) reported a case of simultaneous bilateral HZO in an HIV positive patient, highlighting the need for careful examination of the fellow eye in these patients. The mechanism of bilateral involvement is not understood but may occur as a result of haematogenous dissemination (18). Disseminated zoster is defined as extension over > 3 contiguous dermatomes or the presence of > 20 vesicles outside the initial dermatome (3). The disseminated form of this condition is associated with mortality rates of as great as 26% in these patients (3). Dissemination occurs in 1-2% of immunocompetent patients, but is more common in immunocompromised individuals (6-26%) (9, 13). Dissemination is most commonly limited to the skin but 10 – 50% of patients exhibit evidence of visceral involvement (13). With visceral involvement, mortality rates as high as 15% have been described in patients

receiving antivirals (13). VZV reactivation can occur in the absence of skin eruption, a condition known as *zoster sine herpete* (3).

The diagnosis of zoster is a clinical one and but may be confirmed definitively by isolation of the virus (3).

In acute HZO the rate of direct ocular involvement is estimated at 50-72% (10). The rate and severity of ocular involvement in HIV positive patients is known to be greater (19). No correlation between $CD4^+$ count and specific ocular manifestations has been demonstrated (20). The frontal branch of the trigeminal nerve is most commonly involved, and via the supraorbital, supratrochlear and nasociliary branches virtually all ocular and periocular structures can be involved (10). The involvement of the skin of the tip, side or root of the nose (Hutchinson's sign) is considered to be a strong predictor of ocular inflammation and corneal denervation, especially if both branches of the nasociliary nerve are involved (11, 14). Focus on lesions of the tip of the nose alone, a dermatome supplied by the external branch of the nasociliary nerve, ignores the rest of the dermatome supplied by this nerve, namely the skin at the corner of the eye, root and side of the nose (11). It is therefore advocated that all patients with a red eye or severe upper lid involvement be referred for an ophthalmologist to review, and not only those patients in which the tip of the nose is involved. Other factors that should be considered when deciding whether to refer a patient to an ophthalmologist are: stage and severity of disease, age and mobility of the patient, presence of immunosuppression and motivation of the patient (11). The presence of Hutchinson's sign is estimated to double the risk of

ocular involvement but it must be remembered that up to 1/3 of patients without this sign develop ocular complications (12).

The ocular and periocular complications of HZO include: (10)

1. Adnexa

   These include paralytic ptosis and cicatricial lid retraction/loss.

2. Anterior segment

   i) Sclera, episclera and conjunctiva

   These include scleritis, episcleritis and conjunctivitis. Episcleritis and scleritis are sectoral and may be flat or nodular.

   ii) Cornea (10,14)

   Various forms of corneal involvement have been described. The mechanisms of involvement include direct viral invasion, antigen-antibody reactions, delayed cell mediated hypersensitivity reactions and neurotrophic damage (12). In 2/3 of cases corneal hypoaesthesia is found. Infectious manifestations such as dendritiform keratitis may appear acutely or months later and immune mediated manifestations including anterior stromal infiltrates, punctate epitheliopathy, delayed mucous plaque keratopathy, necrotic stromal keratitis, nummular keratitis, endotheliitis and diffuse corneal oedema may appear weeks to months later (21). The chronological sequence of the development of corneal lesion from earliest to latest is as follows: punctate epithelial keratitis, pseudodendrites, anterior stromal infiltrates, sclerokeratitis,

keratouveitis/endotheliitis, serpiginous ulceration, delayed corneal mucous plaques, disciform keratitis, neurotrophic keratitis and lastly exposure keratitis (21). Stromal keratitis is less common than in HIV seronegative individuals but other forms of corneal involvement appear to be more prevalent (7). Stromal immune recovery keratitis has been described in HIV seropositive patients receiving HAART and this and other forms of immune recovery inflammatory syndrome (IRIS) may become more prevalent as HAART becomes more widely available (7, 22). Peripheral ulcerative keratitis associated with HZV infection has also been described in HIV seropositive patients (23). The exact pathogenesis is poorly understood but may be related to: the presence of actively replicating virus, a cell mediated immune phenomenon, focal occlusive vasculitis, neurogenic dysfunction or a combination of these mechanisms (23). In AIDS patients with severe immunodeficiency, humoral immune mechanisms may remain intact and may be non-specifically activated with increased serum IgA levels, hypergammaglobulinaemia and hypocomplementaemia (23). This may explain why this condition is found in the setting of AIDS, where the presence of intact humoral immunity even late in the clinical course may allow for immune-complex deposition, complement fixation, chemotaxis and neutrophil infiltration into the peripheral cornea (23). Chronic dendritiform keratitis is seen almost exclusively in the setting of HIV infection (20). Corneal hypoaesthesia results in neurotrophic keratitis with the adherent risk of corneal thinning

and perforation. Immune mediated lesions may become chronic and lead to corneal neovascularization. This is thought to be less common in patients that have received systemic antiviral therapy (20). Dendritiform and punctate epithelial lesions were not reported by Lewallen in a series of patients in Malawi, possibly due to later presentation (24).

iii) Iridocyclitis (10, 14)

This occurs in 40% of patients and may occur due to the loss or absence of virus specific delayed hypersensitivity (18). It may be complicated by chronic iris vasculitis, sectoral iris atrophy and irregular, poorly reactive pupils. Secondary ocular hypertension and glaucoma can develop as a result of trabeculitis, the development of peripheral anterior synechiae, clogging of the trabecular meshwork by inflammatory debris or as a result of steroid response invoked by the use of topical corticosteroids used in management. Up to 15% of patients require surgical intervention (18). The course is generally uniphasic and of short duration (18). Visual loss is generally not related to uveitis or glaucoma but rather due to other complications of HZO (18).

3. Posterior segment

Posterior segment manifestations include choroiditis and retinitis. These manifestations are seen more commonly associated with HIV infection. Three forms of retinitis, comprising a spectrum of disease, have been described. These are acute retinal necrosis (ARN), the more common progressive outer retinal necrosis (PORN) and rapidly progressive herpetic retinal necrosis (RPHRN)

(3, 14). ARN is seen in healthy individuals and in HIV positive individuals with $CD4^+$ counts < 200 cells/mm^3 and is preceded by the eruption of vesicles in 60 - 90% of cases (3). Blindness in 1 eye is seen in 76 – 85% of cases with bilateral blindness resulting in 60% of cases (3). PORN/RPHRN is more commonly seen in advanced HIV infection with $CD4^+$ counts < 50 cells/mm^3 (3). This condition is preceded by vesicular eruption in 73% of cases, is commonly bilateral and is associated with a poor treatment response, even in patients on HAART, and has a poor prognosis (3, 14). The propensity for posterior pole involvement may be due to HIVAM creating a portal of entry at this site (25). RPHRN may be associated with central nervous system disease (3). Different forms of herpetic retinitis have been seen simultaneously in fellow eyes of HIV seropositive patients (25). Central retinal venous occlusion due to HZV infection has been described as a presenting sign of AIDS (26).

4. Neuro-ophthalmological

   These manifestations include Argyll-Robertson pupil, retrobulbar optic neuritis, papillitis, optic atrophy and extraocular muscle palsies (cranial nerves III, IV and VI). Optic neuritis occurs more frequently in HIV positive patients and should be considered to be a possible precursor to PORN (27). It may occur in isolation associated with cutaneous manifestations and may be the initial manifestation of HIV infection (27).

5. CNS (3)

   VZV accounts for 2 – 4% of neurological disease in HIV positive individuals.

Described patterns of involvement include: multifocal leukoencephalopathy, ventriculitis, acute haemorrhagic meningomyeloradiculitis, focal necrotizing myelitis and vasculopathy of the leptomenigeal arteries associated with stroke. These features may occur in the presence of or in the absence of skin lesions. They may precede, accompany or follow skin lesions. Vasculopathy is often associated with meningitis. Myelitis is relatively rare. HIV-associated encephalitis and AIDS dementia complex may also be associated with VZV infection. Other rarer neurological associations are Guillain-Barré syndrome, fulminant necrotizing encephalitis with concomitant Epstein-Barr virus-related lymphoma and CMV ventriculitis. Description of individual conditions is beyond the scope of this review.

6. Other organ systems (3, 10)

   Other described systemic manifestations of VZV infection include arthritis, myocarditis, hepatitis, acute pancreatitis, gastric infections, pneumonia, oral lesions, Ramsey-Hunt syndrome (*herpes zoster oticus*), skin lesions resembling basal cell carcinoma, and co-infection with Leishamania species that has been described in AIDS patients.

7. Other

   Post-herpetic neuralgia (PHN) is characterized by hyperaesthesia or pain over the affected dermatome. It is defined as the persistence of pain > 4 – 6 weeks after the resolution of the skin rash depending on the specific definition used (3, 28). It is thought to be due to disordered fiber input in the diseased sensory ganglion, damaged spinal pain pathways with ectopic firing to the cerebral cortex,

abnormally heightened skin nociceptor sensitivity and reactivated ganglionitis (28). This occurs in 8 - 15% of patients and is more common in patients older than 60 years of age, those with greater prodromal symptoms and acute pain, those with marked rash severity, those with rash involving the head and neck (particularly ophthalmic), those with clinical depression and adverse psychosocial factors, failure to receive antiviral medication and viraemia (3, 28). Similar rates of this condition have been reported in HIV positive patients but may be more chronic in nature in these patients (3, 7). A wide range of treatment modalities are available to manage this complication and their description is beyond the scope of this discussion.

The aims of treatment of zoster infection are: (9)

1. Relieve pain in the acute phase.
2. Limit the spread and duration and spread of zosteric skin lesions.
3. Prevent and alleviate PHN and other acute and chronic complications.

The mainstay of treatment is systemic antiviral therapy (10). There is a very limited role for topical antiviral medications in this condition (9, 10). Parenteral therapy is advocated in immunodeficient patients, but this is not always practically possible in our setting. (9)

The indications for systemic antiviral treatment are: (9)

1. Urgent
    i) All patients over the age of 50 years

ii) All cases of zoster in the head and neck region

iii) Severe zoster on the trunk or extremities

iv) All cases in immunocompromised patients

v) Zoster in patients with co-morbid severe atopic dermatitis and eczema

2. Relative

i) Zoster on trunk or extremities in patients less the 50 years of age

Treatment with acyclovir reduces healing time, the appearance of new vesicles, the duration of pain and viral shedding (3). Treatment should ideally be initiated within the first 72 hours after the development of the skin lesions (9). Early treatment, within the first 7 days of the illness, is more efficacious as treatment inhibits viral DNA replication (3). Initiation of treatment after 72 hours is specifically recommended in the following situations: (9)

1. Immunodeficient patients
2. Visceral involvement
3. Persistent HZO
4. Zoster oticus

In the treatment of HZO, the rate of ocular complications in reduced from 50% to 20-30% in patients receiving systemic antivirals (14). This observation is illustrated by the contrasting findings of Margolis et al in San Francisco in the United States of America, where all patients received antiviral medication, and Lewallen in Malawi where no

antiviral medication was available (20, 24). Margolis et al found a low rate of poor visual outcomes, with 81% of patients having a final VA of ≥ 6/12. Most patients in this series with a poor visual outcome were complicated by retinitis or CNS disease. In contrast Lewallen found that 66% of patients had a final VA < 6/18 with 40% having light perception or no light perception. The most common causes of poor visual outcome in this series were severe keratouveitis and corneal perforation. Undisclosed used of traditional medication may be contributory. The rate of reported visual loss associated with this condition ranges from 14 – 56% (29). Risk factors for visual loss determined by Nithyanandam et al were the presence of Hutchinson's sign and the presence of uveitis (29). In this series the most common causes of visual loss were neurotrophic keratitis, uveitis and cataract. No significant difference in outcome was found between HIV seropositive and seronegative patients where early antiviral therapy is instituted (30). With the use of antiviral medication, the incidence and severity of acute dendritiform keratitis is reduced, and the incidence but not severity of immune stromal keratitis and late onset ocular inflammatory conditions, such as episcleritis, scleritis and iritis, are reduced (10). The use of antiviral medication however does not prevent PHN but valacyclovir and famciclovir may decrease the incidence and severity (10). Valacyclovir is also effective but fatal thrombocytopenic purpura/haemolytic uraemic syndrome has been described in severely immunocompromised HIV seropositive patients and this agent should therefore be avoided in these cases (28). In immunocompetent individuals all 3 agents are safe and well tolerated. Dose correction has to be made for renal insufficiency (9). There is no role for topical antivirals in non-ophthalmic zoster and only a limited role in HZO (9). Treatment resistance, to acyclovir, has been described with greater frequency

in HIV positive patients and cannot be bypassed with greater doses of antiviral therapy (9, 28). Prolonged treatment may be required in HIV seropositive patients due to prolonged viral shedding (9). Both medical and surgical modalities are employed in the management of ocular and periocular complications of HZO and their description is beyond the scope of this discussion (10).

Note on risk factors for early mortality in adults initiating HAART and pre-HAART initiation

95% of HIV seropositive individuals live in low and middle income countries and more than 20% of these individuals have advanced disease requiring HAART (31). HAART has been observed to reduce morbidity and mortality worldwide but a 3 fold increase in early mortality (within 12 months) in those starting HAART has been observed in low and middle income versus high income countries (31). This corresponds to an 8 – 26% mortality rate within the 1st year in Sub-Saharan Africa, the worst outcome region in the meta-analysis (31). The greatest proportion of deaths are observed within the 1st 3 months of treatment and the following risk factors for mortality have been identified in a meta-analysis by Gupta et al (31):

1. BMI < 18.5 kg/m^2
2. CD4$^+$ count < 50 cells/mm^3
3. WHO stage 4 disease
4. Haemoglobin (Hb) < 8 g/dL (nutritional marker)
5. Age > 40 years

6. VL > 5 log copies/ml
7. Male gender

Older age has been associated with delayed presentation and diagnosis, immune senescence and poor $CD4^+$ reconstitution. The authors explained observed difference by possible differences in healthcare seeking behavior, treatment adherence, and differing biological response to HAART. A study by Oliveira et al (32) studied risk factors for early mortality in HAART-naïve patients. Risk factors for early mortality identified in this study were:

1. BMI < 18.5 kg/m^2
2. Mid-upper-arm-circumference (MUAC) < 250 mm
3. CD4+ count < 350 $cells/mm^3$
4. suPAR (soluble urokinase-type plasminogen activator receptor) (inflammatory marker) plasma levels > 5.3 ng/ml

These risk factors were independent risk factors and used in combination were more sensitive and specific predictors of outcome. High suPAR plasma levels were also associated with increased risk of TB related mortality, important as TB is the most common cause of HIV-associated mortality in Sub-Saharan Africa.

3.0 RESEARCH OBJECTIVES

On embarking on this research project the following research questions were set to be answered during the course of the research:

1. To describe the demographic and clinical profile of participants in the study group.
2. To describe the ocular complications present in participants in the study group.
3. To determine the rate of post-herpetic neuralgia in the study group

4.0 PARTICIPANT SELECTION AND METHODS

Prior to embarking on the preparation of a protocol for this study, a pilot study was conducted to determine magnitude of the clinical problem at St John Eye Hospital. In the period 08/04/2008 – 18/04/2008, 21 patients were identified that met the criteria for inclusion in the proposed study group.

This prospective cross-sectional study enrolled HIV patients between the ages of 18 and 50 years with acute presentation of herpes zoster ophthalmicus. Acute presentation was defined as the onset of typical vesicular rash in the past 14 days.

All patients were enrolled after written informed consent was taken. Informed consent was taken by signature or right thumb print in the case of illiterate patients. The aid of a member of nursing staff was obtained in cases were a language barrier existed. Each patient received a patient information sheet including study information and contact number of the study doctor in case of any questions or concerns. Each patient was allocated a study number HZO- followed by sequential 3 digit number from 001.

Patients were requested to attend 2 further follow-up visits, 2 weeks and 4 weeks after initial presentation.

Patients unable to attend follow-up or with previous history of cicatricial lid disease, ocular surface disease, uveitis or previous intraocular surgery of the affected eye were excluded from this study.

At the initial visit date of birth and gender were recorded.

Patients with unknown retroviral disease status had serological testing by enzyme linked immunosorbent assay (ELISA) after pre-test counseling, as per departmental standard procedure, by a trained member of nursing staff.
Patients found to be HIV positive had their retroviral disease status confirmed by a second serological test by ELISA at the 2 week follow-up visit.
Patients found to be HIV negative had their retroviral disease status confirmed by a second serological test by ELISA at the 4 week follow-up visit.
All patients had post-test counseling irrespective of outcome of serological testing, as per departmental standard, by a trained member of nursing staff.

All patients enrolled in the study had luetic serology by rapid plasmin regain (RPR) and treponemal pallidum haemagglutination assay (TPHA), serum album determination (g/dl) and chest x-ray for exclusion of tuberculosis in cases were suggestive history was present. Suggestive symptoms enquired about included history of cough > 2 weeks, fever, night sweats and unintended weight loss. All enrolled patients were asked about previous herpes zoster infection with date and distribution being recorded.

Patients known to be HIV positive on enrollment in the study had determination of CD4+ count (cells/mm3) and viral load (copies/ml) at the presentation, whilst patients with unknown retroviral disease status with subsequent confirmation of positive HIV serology had the above laboratory tests at the 2 week-follow up visit.

Patients known to be HIV positive on enrollment in the study were asked regarding prior enrollment in an antiretroviral treatment program. Date of enrollment and current regimen were recorded. Location, date and precipitating event for initial diagnosis were recorded.

History of duration and distribution of rash and associated symptoms experienced by the patient were recorded.

The source of the referral and treatment prescribed at the source of referral were recorded.

Past medical history (especially previous or current tuberculosis), current medication, allergies and past ocular history were recorded.

At the initial presentation all patients had both a general examination, including a neurological examination, as well as a full ocular and adnexal examination. Corneal sensation was tested in all patients using a piece of cotton and relative subjective differences recorded. Rash distribution was illustrated on standardized data collection sheet. All examinations were conducted by the principal investigator. Visual acuities

were performed using a standard Snellen light box and intra-ocular pressure measurements were performed using a Goldman applanation tonometer. Gonioscopy was performed using a Volk 3-mirror gonioscopy lens and dilated fundoscopy using a Volk superfield lens.

General examination included general condition of patient, observation of vitals (blood pressure, pulse rate and character and oral body temperature measurement), fingerpick glucose measurement (mmol/l), weight (kg) measurement by electronic scale, height (m) measurement, BMI determination by the formula BMI = weight/height^2, examination of hands (especially clubbing of the digits), presence of lymphadenopathy and presence of oral candidiasis. Blood pressure, glucose and temperature measurements were performed by a member of the nursing staff. Examination of chest and heart included observation, palpation, percussion and auscultation. The abdomen was examined by observation, palpation, percussion and auscultation and any masses or hepatomegaly/splenomegaly was noted. Any scars were noted.

Neurological examination included assessment of level of consciousness, orientation, presence/absence of meningism, cranial nerve examination, upper and lower limb tone, power and reflexes and plantar responses, cerebellar examination, examination of gait and sensation.

Clinical assessment and treatment plan was recorded for each patient at every visit.

Patients with confirmed retroviral disease status and at least 1 clinical examination for analysis were included in the study. All included patients were included in the analysis of initial presentation. Patients that attended follow-up visit(s) were included in the analysis of clinical course of acute disease. Only patients that remained in the study group until the 4 week follow-up visit could be assessed for the presence of PHN as a time interval of 4 weeks was used in the definition of PHN for analysis in this study. This was done with the aid of an interpreter and the participant was asked to grade the pain on a scale of 1 – 10.

All patients received oral acyclovir 800 mg PO 5 times daily for 1 week. In the event of treatment being started elsewhere, the balance of 1 week of treatment was completed. Specific ocular complications were treated as per institutional standard of care. PHN was treated initially with oral paracetamol 1 g PO QDS, to which oral amytrypline 10 mg nocte as a starting dose would be added if required. Patients with an inadequate response to this regimen were referred for further management at the pain management clinic at Chris Hani Baragwanath Hospital.

All data was collected using a standardized data collection form and collated using Microsoft Excel 2010®.

All documentation and data collection sheets will be kept in hardcopy and digital formats. Statistical analysis of data was performed using Stata® v12.0. During analysis of study data, numerical variables were analysed using the Student t-test and categorical variables using the Chi-square test.

5.0 RESULTS

Data collection commenced on 12/11/2008 and was completed on 21/10/2009. All patients were assessed at the outpatients department of St John Eye Hospital by the principal investigator in this study.

During data collection 82 patients were assessed for inclusion as participants in the study group. Of these patients 28 were excluded from the study group as per protocol.
At study completion, 54 participants met the criteria for inclusion in the study group for analysis.

Patients excluded form study population

During data collection, 28 patients that met the clinical inclusion criteria for this study were excluded from the final study group. Of these patients, 11 patients were lost to follow-up, 3 were found to be HIV seronegative and a further 14 patients declined participation in the study. Reasons given for declining participation in this study included, being unable to attend follow-up (7 patients) and declining serological testing for HIV (7 patients).

Demographics of study population

The study population included 20 male (37%) and 34 female (63%) patients. The average age of participants in this study was 36.6 years, with a range of 18 – 49 years. The average age of male participants in this study was 38.3 years, with a range of 28 – 47 years. The average age of female participants in this study was 35.6 years, with a range of 18 – 49 years.

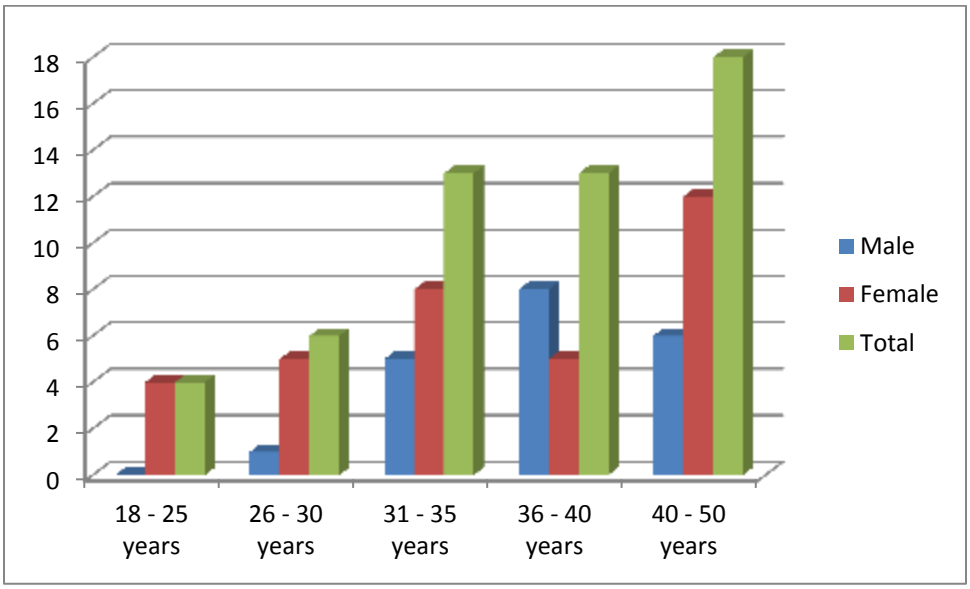

Figure 1 - Age distribution by gender

Source of referral for ophthalmic assessment, time to presentation and treatment given at referring institution

Of the patient's referred for assessment, 13 (24%) were hospital inpatients, 2 (4%) were attending hospital outpatient clinics, 25 (46%) were seen at community health clinics, 13

(24%) by private sector general practitioners and 1 patient (2%) was self-referred. All hospital inpatient referrals where from within our institution. Of the outpatient clinic referrals, 1 was from a local district hospital and 1 from the ARV clinic within our institution. Only 15 (28%) of study participants received an antiviral agent at appropriate dose and frequency before presenting to our institution for assessment and further management. Of these participants, 11 (73%) received oral acyclovir and 4 (27%) received parenteral acyclovir at the referring institution. The remaining 39 participants (72%) receiving either no or inappropriate treatment at the referring institution. Of these participants, 2 patients were prescribed an antiviral at an incorrect dose and frequency, 1 had appropriate treatment charted but did not receive it and 1 participant received an appropriate prescription but it was not filled. Of the participants in the study 25 (46%) received treatment with antiviral medication within 3 days of rash onset, either at referring institution or on presentation for ophthalmic assessment. The mean period from start of rash to presentation was 4.7 days with a range of 1 – 12 days. Of the participants in the study, 17 (31%) presented within 3 days of the start of the rash, which may be therapeutically important.

Table 2 – Participant and treatment characteristics by site of referral

Source of referral	Gender (M:F)	HIV status known	Duration of rash	Appropriate treatment prescribed at source
CHC n = 25	2:3	44%	4.3 days (range 1-7) 40% within 3 days or less	16%
Inpatient n = 13	1:5.6	62%	5.5 days (range 3-12) 31% within 3 days or less	85%
Outpatient n = 2	All male	50%	6.5 days (range 5-8) 0% within 3 days or less	0%
Self-referral n = 1	All male	100%	4 days 0% within 3 days or less	0%
GP n = 13	1:1.6	32%	4.5 (1-7) 23% within 3 days or less	0%

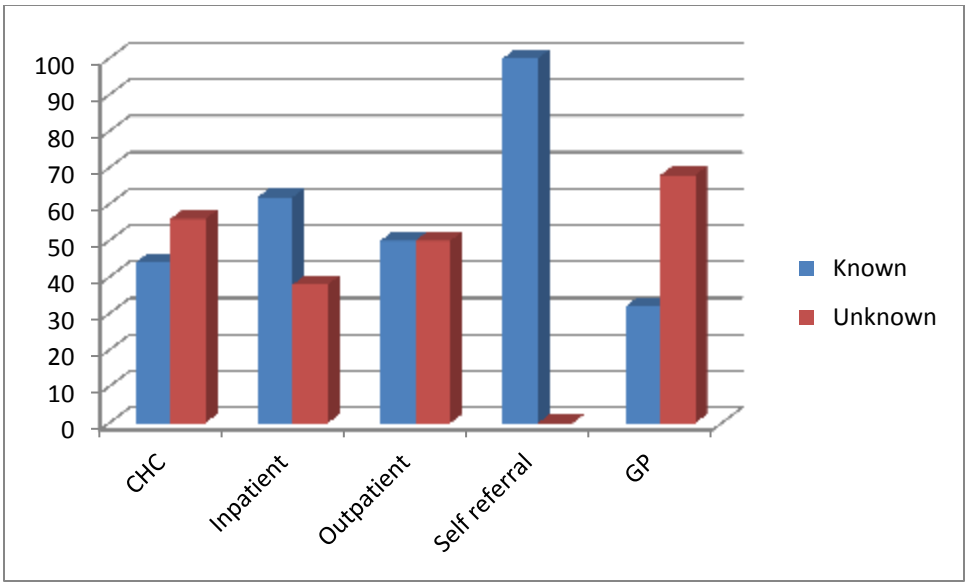

Figure 2 – Knowledge of HIV status by site of referral

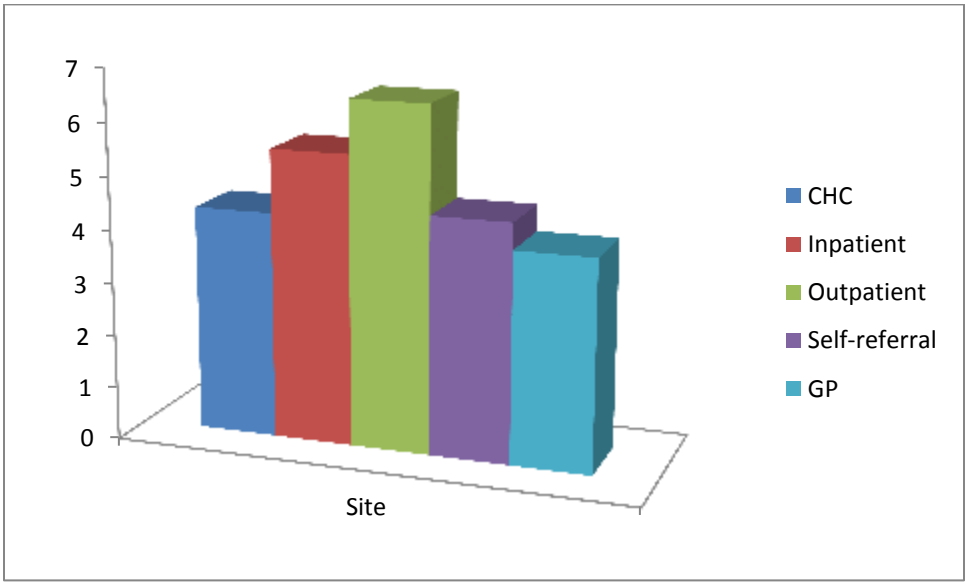

Figure 3 – Average duration of rash to referral

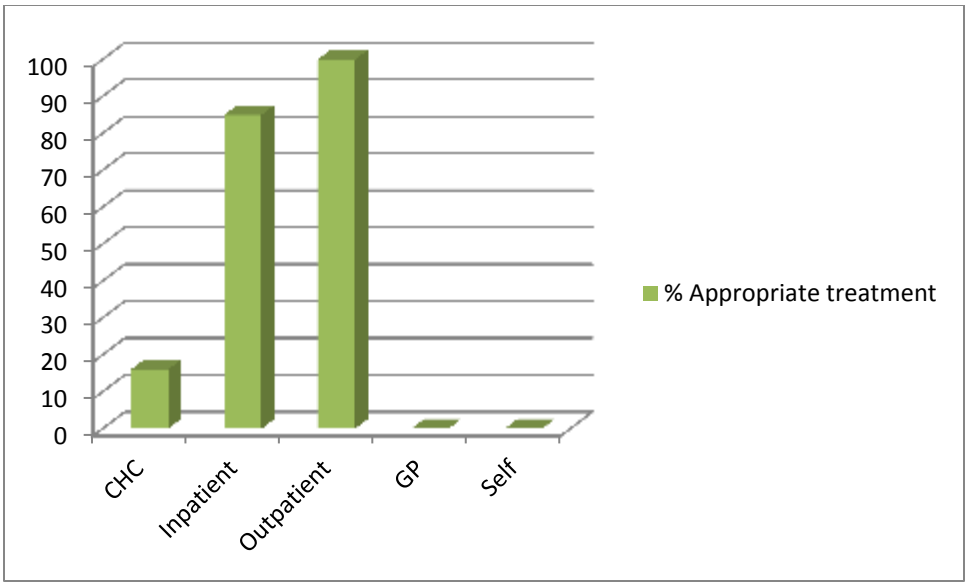

Figure 4 - Percentage treatment at referral site

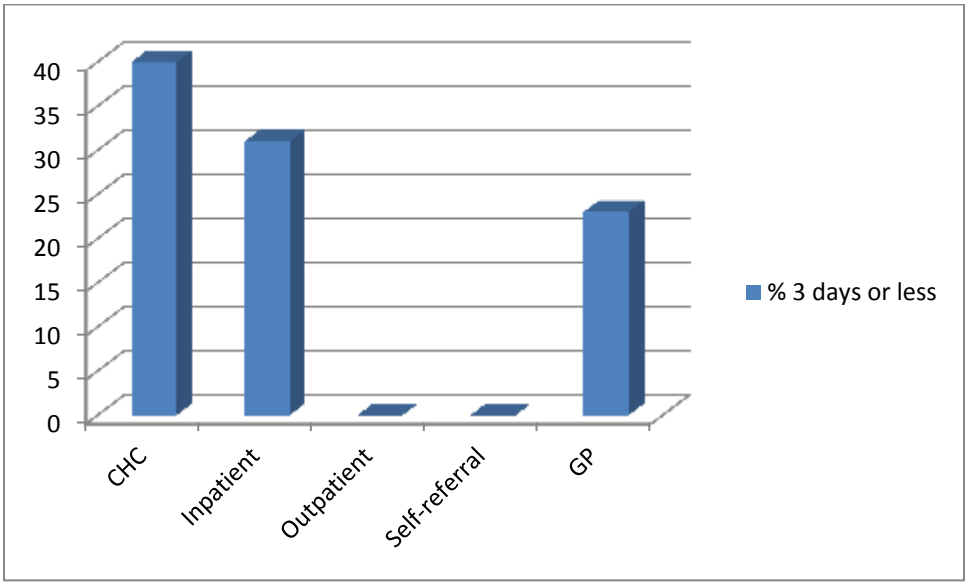

Figure 5 – Percentage referral within 3 days of start of rash

Attendance of clinical visits and follow-up of study participants

There were a total of 144 recorded clinical visits by participants in this study. Of the patients, 4 attended the initial assessment only, 10 attended 1 clinical follow-up visit at 2

weeks and 40 attended clinical follow-up visits at 2 and 4 weeks. The mean number of clinical visits by participants in this study was 2.7 with a range of 1 – 3 visits.

Immune characteristics of study population

Of the 54 participants in this study, 27 (50%) were known to be HIV seropositive and 27 (50%) were found to be HIV seropositive on entry into the study. The mean $CD4^+$ count of participants in the study was 276 cells/mm^3, with a range of 44 – 859 cells/mm^3. The CD4+ was not available for 2 patients in the study population. The mean CD4+ count of male participants in this study was 240 cells/mm^3, range 44 – 859 cells/mm^3, and for female participants in this study was 287 cells/mm^3, range 56 – 650 cells/mm^3.

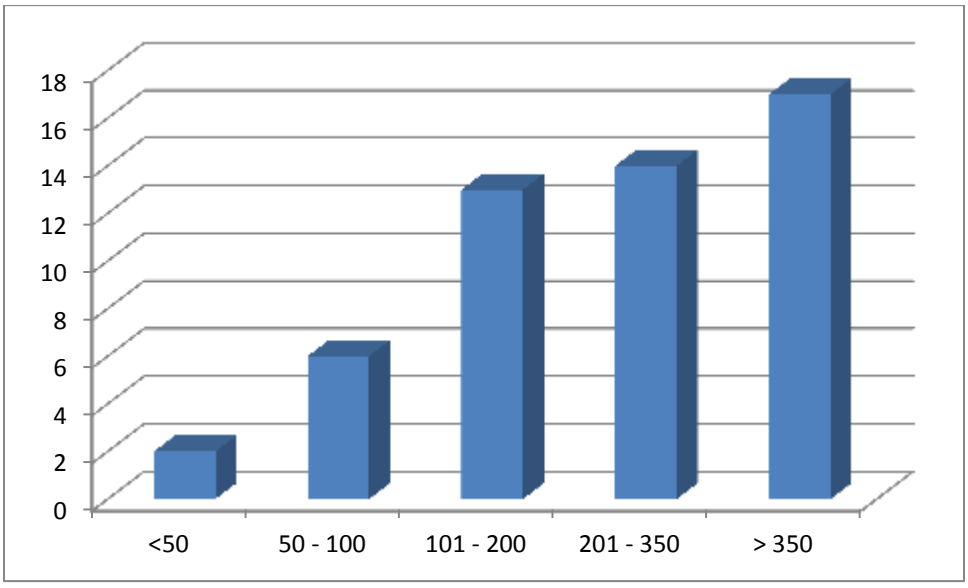

Figure 6 – Distribution of $CD4^+$ count (cells/mm^3)

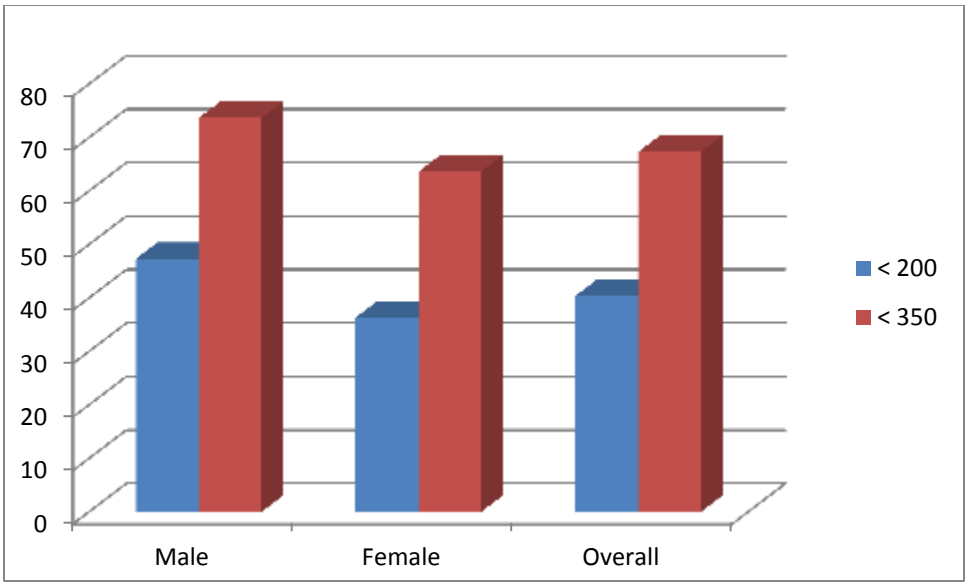

Figure 7 – Percentage of $CD4^{+}$ counts below 200 and 350 cells/mm^3 by gender

The proportion of participants with CD4+ counts < 200 and 350 cells/mm3 were 40 and 67% respectively. Corresponding values per gender were 47 and 74% for males and 40 and 67% for females. Corresponding values for participants in whom HIV serostatus was known and unknown were 43 and 73% and 35 and 65% respectively.

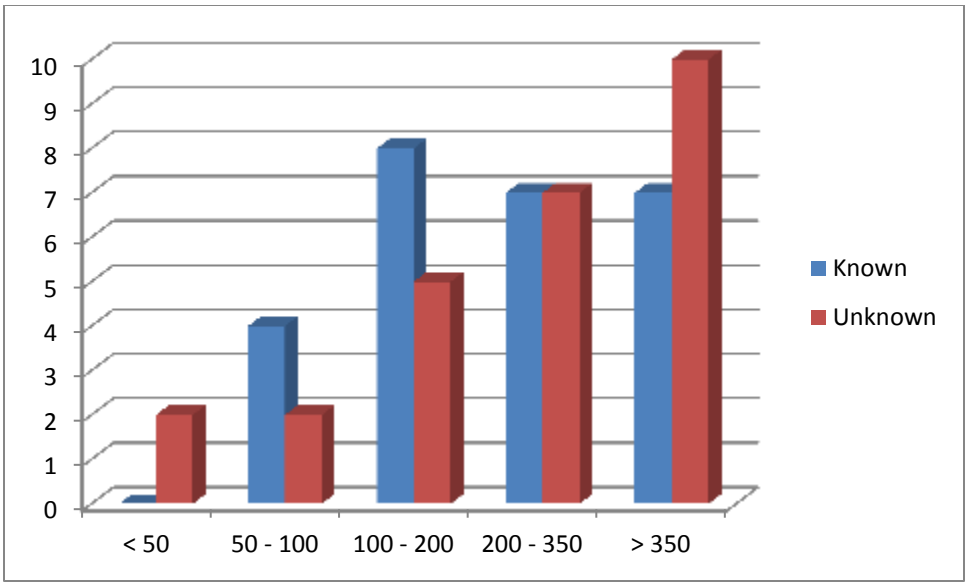

Figure 8 – Distribution of $CD4^{+}$ counts (cells/mm^3) by knowledge of HIV status

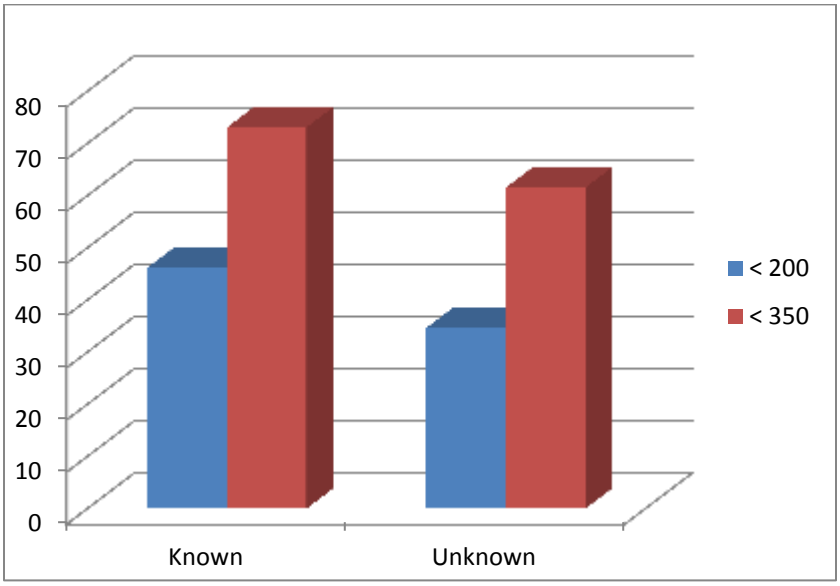

Figure 9 - Percentage of $CD4^{+}$ counts below 200 and 350 cells/mm^3 by knowledge of HIV status

Viral load results were recorded as baseline values for referral for initiation of HAART. Of the study participants, 9 of the 27 patients known to be HIV seropositive (33%) were currently on HAART and 1 patient was awaiting initiation of HAART therapy. The

following HAART regimens were encountered: efavirenz + stavudine + lamivudine (6 participants) and efavirenz + lamivudine + zidovudine (2 patients). In 1 case the current regimen was unknown by the participant. No participant was currently on a protease inhibitor containing regimen.

Physical characteristics, opportunistic infections and co-morbidity in the study population

Of the 54 participants in the study, there were 8 participants that were clinically suspected as having pulmonary TB. Of these patients, none were sputum positive for TB. There were 3 participants currently receiving TB treatment and 7 participants with a history of past pulmonary TB. That is 10 (19%) of participants either has a past history of treated pulmonary TB or is currently receiving TB treatment. Of the 54 participants in the study, there were 5 (9%) participants with a history or clinical signs of previous herpes zoster infection. Of these participants, 2 had previous contralateral HZO, 1 had recurrent ipsilateral HZO and 2 had non-ophthalmic herpes zoster. There were no participants with simultaneous bilateral HZO. Both participants with previous non-ophthalmic herpes zoster had involvement of thoracic dermatomes. Of the participants in this study, 6 (11%) had serological evidence of previous or current luetic disease with 1 having active luetic disease. There was 1 participant with diabetes mellitus, 1 with a history of genital herpes and 1 patient with a conjunctival lesion clinically suspicious for squamous cell carcinoma. There were 5 participants (19%) with unknown HIV status at the 1st consultation that revealed clinical events during history taking that should have prompted

serological diagnosis of HIV infection, 4 cases of past TB and 1 of past contralateral HZO. In patients known to be HIV seropositive, the diagnosis of HIV infection was made at the CHC (30%), the antenatal clinic (ANC) (30%), during hospital admission (37%) (1 following sexual assault) and during a visit to a private GP (3%).

Clinical characteristics at presentation

The presenting symptoms of participants in the study included: rash (100%), periocular pain, burning, itching or swelling (70%), headache (4%), ocular discomfort, redness or photophobia (56%) and decreased VA (2%). Of the participants in the study, 28 (52%) had a right and 26 (48%) left sided typical rash in the distribution of the ophthalmic division of the trigeminal nerve. Of these participants, 51 (93%) had only the ophthalmic dermatome involved and 4 (7%) had multi-dermatomal involvement with the V2 dermatome being involved in all these cases. No V3 dermatomal involvement was encountered.

General and neurological examination at presentation

Clinical signs and conditions not related to HZO encountered during this study included melanonychia, Mercke's lines, vitiligo, tinea corporis, tribal scarification, keloid, unidentified violaceous pedal rash, pallor, pulmonary consolidation and cardiac failure. Clinical stigmata of HIV infection encountered during the study included widespread follicular rash, old zoster scar, generalized lymphadenopathy, oral candidiasis and

hepatosplenomegaly. Neurological abnormalities encountered during the study included meningism and left hemiplegia.

Nutritional status of participants in study population

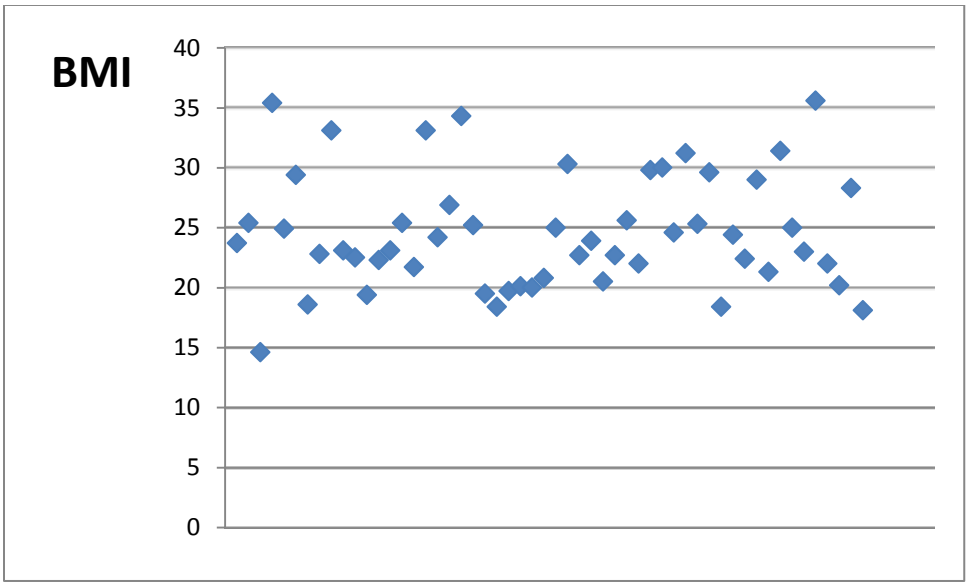

Figure 10 – Scatter plot of BMI

There were 3 participants (6%) in the study group with a BMI of < 18.5.

Ophthalmic examination at presentation

Analysis of ophthalmic examination at presentation included, presenting VA and visual impairment. Presenting visual acuities were classified as per the WHO definition of visual impairment and these definitions were applied to the affected eye and to the participant's binocular visual function. At presentation 29 participants (54%) were

classified as having normal VA (better than 6/18), 21 (39%) had some level of impairment (6/18 – 6/60) and 4 (7%) were either severe visual impairment or blind (< 6/60) in the affected eye. The global visual impairment analysis at presentation revealed 51 participants (94%) classified as not impaired, 2 (4%) with some impairment and 1 (2%) with severe impairment or blindness. This analysis was conducted in recognition of the fact that ocular involvement during the course of HIV infection is almost universal.

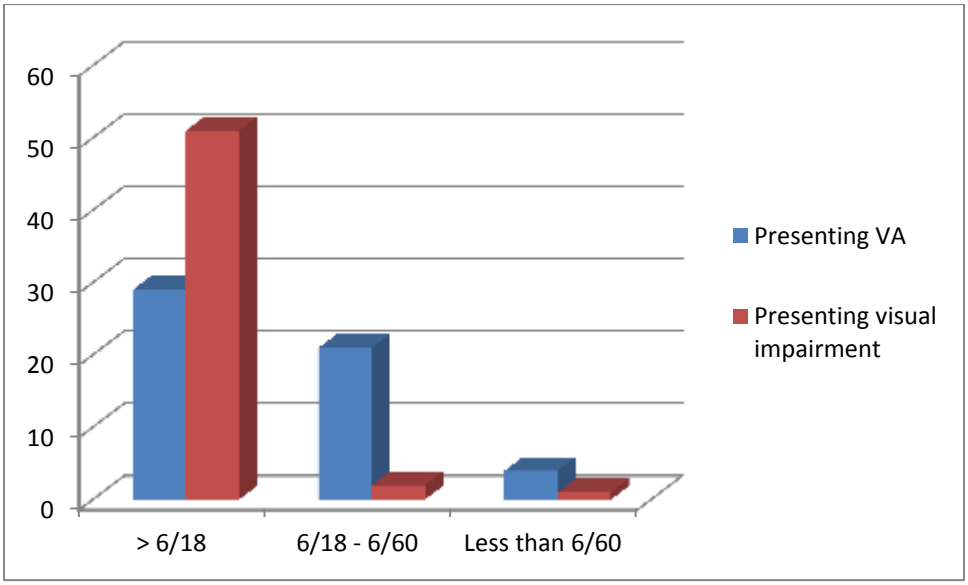

Figure 11 – Presenting VA and visual impairment

Ocular co-morbidity unrelated to HZO encountered during the course of the study included pterygium, presumed conjunctival squamous cell carcinoma, corneal stromal scarring, presumed corneal foreign body scar, traumatic angle recession, HIVAM, flecked retina, chorioretinal scarring, presumed traumatic macular hole, optic atrophy, periocular molluscum contagiosum, presumed lower motor neuron facial nerve palsy and presumed infantile esotropia.

Ocular complications in study population

The occurrence of specific ocular complications encountered during the study involvement was as follows: dendritic keratitis 6 (11%), geographic corneal ulceration 1 (2%), nummular keratitis 15 (23%), stromal keratitis 4 (7%), endotheliitis 4 (7%), neurotrophic keratitis 45 (83%), corneal perforation 1 (2%), iridocyclitis 25 (46%), cicatricial lid disease 2 (4%) and cranial nerve palsy 1 (2%). The cornea was the most common anatomical site affected by complications during the course of this study. The occurrence of blepharoconjunctivitis was excluded from analysis. No posterior segment involvement was encountered. Of the 25 participants with iridocyclitis, 4 (16%) had raised IOP recorded. The range of IOP encountered was 24 – 28 mmHg, with all raised IOP encountered at the 2 week follow-up visit. Only 1 of these participants had an intraocular pressure that remained raised on exit from the study. A single participant had iridocyclitis complicated by blood stained hypopyon. The only cranial nerve palsy encountered was oculomotor nerve palsy.

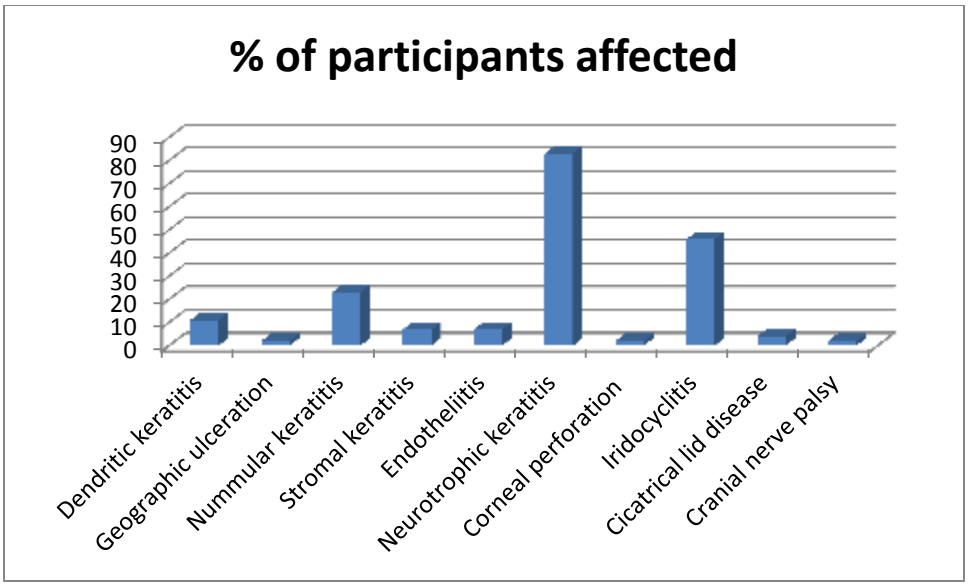

Figure 12 – Encountered specific ocular complications of HZO

The mean number of individual ocular complications encountered/patient in the study population was 1.9 (range 0 – 4) with 61% having multiple ocular complications and 9% having no ocular complications.

Table 3 – Analysis of number of individual complications/participant by gender

		Mean	Range	% multiple	% none
Gender	Male (n = 20)	1.9	0 – 4	55	5
	Female (n = 34)	2	0 - 4	68	12

Table 4 – Analysis of number of individual complications/participant by age

		Mean	Range	% multiple	% none
Age	18 – 30 years (n = 10)	2.1	0 - 4	70	10
	31 – 40 years (n = 26)	1.8	0 - 3	65	12
	41 – 50 years (n = 18)	2	0 - 4	56	6

Table 5 – Analysis of number of individual complications/participant by $CD4^+$ count

		Mean	Range	% multiple	% none
$CD4^+$ count ($cells/mm^3$)	< 50	2	None	100	0
	50 - 100	2.3	0 - 3	83	17
	101 - 200	1.4	0 - 3	31	15
	201 - 350	1.9	0 - 4	64	7
	>350	2.2	0 - 4	76	6

Table 6 – Analysis of the number of individual ocular complications/participant by BMI

		Mean	Range	% multiple	% none
BMI	< 18.5 (n = 3)	2.3	1 – 3	67	0
	>18.5 (n = 51)	1.9	0 - 4	60	10

The sensitivity, specificity, positive predictive value (PPV) and negative predictive value (NPV) of Hutchinson's sign in predicting ocular involvement was determined. These values were determined using the definition of a positive result as the involvement of the tip of the nose by the rash and again using a broader definition including the entire dermatome of the nasociliary nerve (corner of eye, root and side of bridge of nose.

Table 7 – Sensitivity, specificity and predictive value of Hutchinson's sign

Definition	Sensitivity	Specificity	PPV	NPV
Tip of nose	35%	100%	100%	86%
Extended	94%	40%	96%	50%

Ophthalmic examination at exit from study

The final VA on the affected side and visual impairment on exit from the study were analyzed. Of the participants, 38 (70%) to had a VA classified as normal as per definition and 16 (30%) had some degree of impairment or were severely impaired or blind in the affected eye. The distribution of participant's global visual impairment was identical to that on presentation.

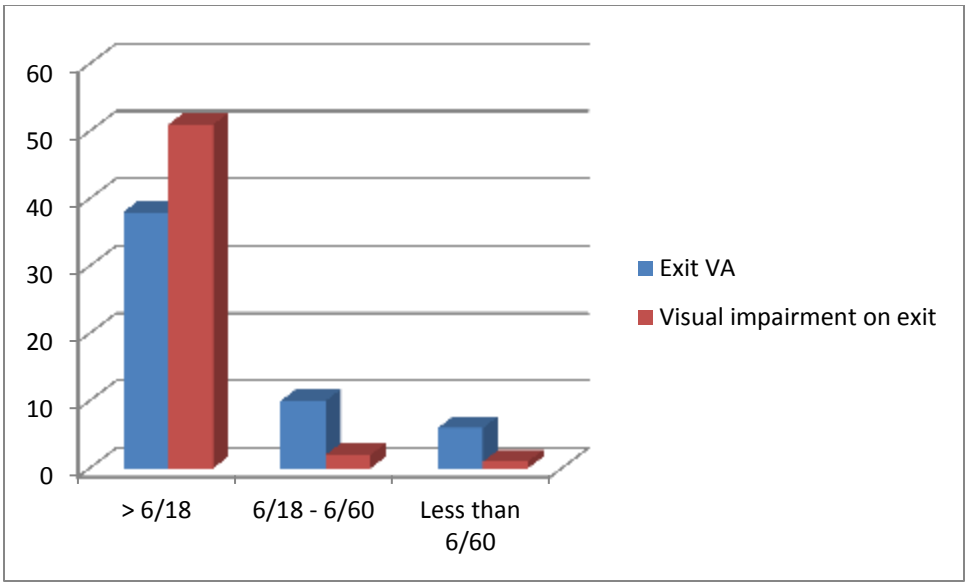

Figure 13 – VA and visual impairment on study exit

Furthermore, the change in VA in the affected eye during the course of the study was analyzed. Significant improvement was defined as an improvement of 2 or more Snellen lines and significant decline was defined as decline of 2 or more Snellen lines. Of the participants, 22 (41%) demonstrated significant improvement of VA, 26 (48%) remained unchanged and 6 (11%) demonstrated significant decline.

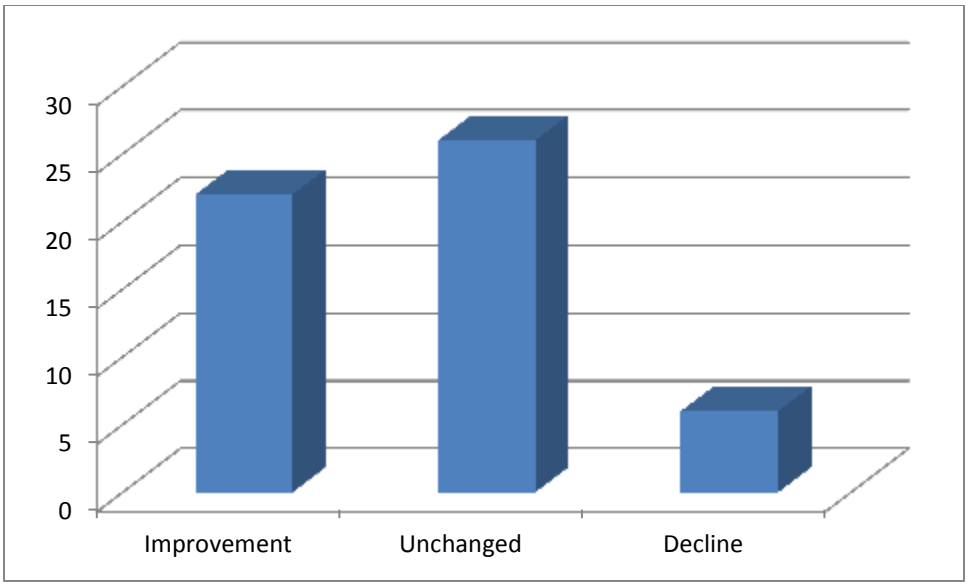

Figure 14 – Change in VA from presentation to study exit

Of the 6 patients with severe visual impairment or blindness in the affected eye, 1 suffered corneal perforation requiring evisceration, 1 had severe vascularized stromal scarring, 3 had persistent intraocular inflammation and 1 had presumed pre-existing optic atrophy. Of the 42 participants attending the 1 month follow-up, 32 (76%) had evidence of neurotrophic keratitis and 8 (19%) persistent intraocular inflammation.

Post-herpetic neuralgia

The prevalence of post-herpetic neuralgia in the study group was 74%. Only 42 of the participants were included in this analysis as participation until the last follow-up visit at 4 weeks was required for inclusion in this analysis as per the definition of PHN employed in this study. Of those participants receiving appropriate treatment with antivirals, 83%

developed PHN whereas 67% of participants that did not receive appropriate antiviral treatment developed PHN.

6.0 DISCUSSION

HZO is a common complication of co-infection with HIV in young Africans. It is known be associated with high rates of ocular complications and morbidity (10). It is considered a marker for HIV seropositivity (15).

HZO was an important marker for HIV seropositivity in the study group as 95% of eligible patients considered for inclusion in the study group were either known to be seropositive for HIV or tested positive for HIV on serological testing. Also of great importance was the fact that 7 patients declined HIV serological testing despite the known association between these 2 conditions being communicated. This may represent patient denial of previous positive HIV serology. This has great significance for HIV-associated morbidity and mortality as delayed diagnosis leads to delayed treatment.

In this study, the majority of participants were female. This may be as a result of the greater prevalence of HIV in females compared to males but different patterns in utilization of healthcare facilities or an unknown factor may play a role. Female predominance has not been consistently seen in other studies (15, 16, 19, 20, 24, 30). Locale specific gender predominance may be of importance as male gender is a risk factor for early HIV-associated mortality (31). The mean age of presentation was 36.6 years with similar mean ages seen in both genders. No statistically significant difference could be demonstrated by Student t-test ($p = 0.1710$). This analysis is limited by sample size. This condition is therefore common in young economically active individuals that

make up the majority of the population in the developing world. This was similar to other studies conducted in other HIV positive populations (15, 16, 19, 20, 24, 30). The peak age group for presentation for the entire study population as well as for females was in the 40 – 50 year age group. The peak for males was in the 36 – 40 year age group. This may be of importance as age over 40 has been identified as a risk factor for early HIV mortality independent of $CD4^+$ count (31).

The greatest proportion of participants was referred for ophthalmic assessment from CHC (46%). This makes these healthcare sites and important site for the education of healthcare providers regarding the appropriate initial management of this condition and for the diagnosis of HIV, initiation of appropriate early antiviral therapy and appropriate referral for ophthalmic assessment and HIV care services. The majority of participants (56%) presenting to these healthcare sites were unaware of their HIV seropositivity. The mean duration of start of rash to referral for ophthalmic assessment was greater than 3 days at all referral institutions with only 31% of participants presenting for assessment within the 1st 72 hours of rash being present. Early appropriate treatment may lower the rate of ocular complications and PHN but the optimum duration of therapy is unknown (10). Longer duration of treatment may be appropriate in the setting of HIV seropositivity as HIV-infection is associated with persistence of the virus (9). The fact that 72% of participants received no or inappropriate treatment at their referral center may be of importance with regard the rate of ocular complication and PHN. This number decreased to 54% if participants that received appropriate antiviral treatment on presentation for ophthalmic assessment were considered. The main site of referral, being

the CHC, only provided appropriate treatment to 16% of participants and inpatients received appropriate treatment in only 85% of cases. Of participants receiving appropriate therapy, the majority (73%) received oral therapy with the remaining participants receiving IV therapy. All participants receiving IV therapy were treated in the hospital inpatient setting. These prescribing patterns are in contradiction of published guidelines (9) but are probably related to the ability of healthcare facilities to provide the inpatient care due to the burden of HIV-associated disease.

Equal proportions (50%) of participants were known and unknown to be HIV seropositive at presentation.

The mean $CD4^+$ counts were similar for both genders and significantly below 350 cells/mm^3. No clinical significant difference could be demonstrated by Student t-test ($p = 0.4227$). The validity of this comparison is limited by sample size. $CD4^+$ counts of < 350 cells/mm^3 have been found to be a risk factor for early HIV associated mortality by investigators in Guinea-Bissau (32). The pattern of distribution of $CD4^+$ counts per gender followed a similar pattern. A significant proportions (40%) of participants had CD4+ counts < 200 cells/mm3 (the HAART initiation level when this study was conducted). An even greater proportion (67%) of participants had a $CD4^+$ count < 350 cells/mm^3 (the current level for initiation of HAART). Similar proportions were seen in male and female participants, but maybe of increased significance for male participants were male gender has been identified as a risk factor for early HIV-associated mortality (31).These cutoff levels have been used for selection of patients eligible for inclusion in

HAART treatment programs. When these proportions are compared for participants in whom HIV serostatus is known and unknown, these values take on even greater significance. In known seropositive participants, 43% had $CD4^+$ counts < 200 cells/mm^3 and 73% $CD4^+$ counts of < 350 cells/mm^3. This is important when seen in the context of only 33% of these participants are currently receiving HAART. Of the participants in whom serostatus is unknown, corresponding values of 35 and 65% were found. Therefore there are 73 and 65% of participants in the 2 groups respectively that have low $CD4^+$ count as a risk factor for early HIV-associated mortality. Of the participants receiving HAART, no participant was currently using a HAART regimen including a protease inhibitor. Martinez et al have shown that the use of protease inhibitors may represent an independent risk factor for the development of HZO in HIV seropositive patients making this an important negative finding in this study (7).

TB is an important cause of mortality in HIV seropositive individuals in Sub-Saharan Africa (31). Historically, 13% of participants in the study population had a history of previous treatment for TB with a further 6% currently receiving TB treatment.
There were a significant proportion of participants (9%) with a past history of zoster infection, with 60% of these cases having previously having HZO.

There were 11% of participants with evidence of previous or current luetic infection. This may be of significance as luetic uveitis, included in the differential diagnosis of granulomatous uveitis as is herpetic uveitis, has been shown to be of particular importance in HIV positive patients (7).

In 19% of participants, a missed diagnostic opportunity for HIV seropositivity was identified. Of these cases 4 reported previous pulmonary TB and 1 previous HZO. This is of concern because of the well documented associations between these 2 conditions and HIV (15, 31).

The majority of participants known to be HIV seropositive on inclusion in the study group were found to be HIV seropositive at CHC, ANC and during hospital inpatient stays (97%).

At presentation, the majority of participants reported the rash, periocular symptoms (pain, burning, itching and swelling) and ocular discomfort as reasons for presenting for assessment. Only 4% of participants reported headache but this is an important cause of headache that may present to the ophthalmologist. Importantly on 2% of participants reported decreased VA as the reason for seeking medical attention. This must be seen in the context of the majority of participants in the study group having normal or near normal VA at presentation but demonstrates that VA should not be used as a criterion for selecting patients requiring ophthalmic assessment. Of interest was that 7% of participants had multidermatomal involvement.

There were 6% of participants in this study with a BMI of < 18.5 kg/m^2. This has been identified as a poor prognostic feature for early mortality in HIV infected individuals (31, 32).

At presentation, the majority of participants (54%) has normal or near normal VA and 94% of participants could not be classified as globally visually impaired. This was of interest due to the known high rates of ocular complication during the course of HIV infection (5). This may be explained by the fact that blinding posterior segment complications such as CMV retinitis occur at more advanced stages of HIV infection. Other ocular conditions known to be HIV-associated encountered in the study population were presumed conjunctival squamous carcinoma, HIVAM and periocular molluscum contagiosum (6).

When blepharoconjunctivitis, an almost universal finding, is excluded from analysis, a wide spectrum of ocular complications was seen in the study population. At presentation, 70% had a least 1 ocular complication at presentation with 22% having multiple ocular complications at presentation. This supports the referral of all patients HIV seropositive patients with HZO for ophthalmic assessment as a priority. As a category, corneal complications (89%) were the most commonly encountered, followed by intraocular inflammation (46%). The rate of neurotrophic keratitis in this study was 86% as compared to 25% as described by Biswas et al (7). This finding is important as neurotrophic keratitis is a risk factor for visual loss (29). The higher rate of neurotrophic keratitis may be explained by differing levels of early access to early antiviral treatment. Intraocular inflammation has also been identified as a risk factor for visual loss (29). Hypertensive iridocyclitis was found in 16% of participants with iridocyclitis with raised IOP being persistent in a single participant. A single case of iridocyclitis was complicated by blood stained hypopyon. CD4+ count is known not to correlate with specific ocular

complications (20). Ocular perforation and intraocular inflammation having being found to be the most common causes of poor outcome in the African setting where access to antiviral medication is limited (24). Posterior segment complications were not observed in the study group. This may be due to the limited duration of the study and also small sample size. During the course of the study, participants had a mean of 1.9 ocular complications with 91% of participants having at least 1 ocular complication, 9% no ocular complications and 61% multiple ocular complications. Multiple ocular complications were the rule when rate of ocular complication was analysed with respect gender, age, $CD4^+$ count and BMI.

The value of Hutchinson's sign as a predictor of ocular involvement was evaluated. This was conducted using a definition using rash involving the tip of the nose as sole criteria (a common misconception in the experience of the investigator) and 1 using rash involving any part of the distribution of the nasociliary nerve. The limited definition was an insensitive marker for ocular involvement (35% sensitivity) whilst the full definition was a sensitive test for ocular involvement (94% sensitivity). The limited definition was specific for ocular involvement (100%) whilst the full definition was non-specific for ocular involvement (40% specificity). Therefore in view of the unreliable nature of this sign and the high rate of ocular complication, it is recommended by the investigator that all patients with HZO be sent for ophthalmological assessment. An opinion supported by van Dyk et al in a study evaluating the value of Hutchinson's sign in HIV positive patients (33). A positive Hutchinson's sign as by the full definition was found in 91% of participants, a risk factor for visual loss as described by Nithanandam et al (29).

On exit from the study, 78% of participants had normal or near normal VA and 11% were severely impaired or blind in the affected eye. The participants that had severe visual impairment or blindness on the ipsilateral side as the rash had severe corneal involvement (scar with neovascularization and perforation) and severe intraocular inflammation. The distribution of global visual impairment was identical to that on entry into the study. During the course of the study 89% of participants either had stable VA or improved significantly. This condition therefore has a fair outcome in the 1st month post-presentation but longer term follow-up would be required for more accurate prognostication (20, 24). The short term results suggest an intermediate situation when compared to 1st world population in whom antivirals are readily available and 3rd world populations in whom antivirals are not available (20, 24). On exit from the study 76% of participants had evidence of neurotrophic keratitis and 19% persistent intraocular inflammation placing them at ongoing risk for visual loss, emphasizing the need for continual follow-up of these patients to prevent late visual loss.

The prevalence of PHN in the study population was 74%. The severity of PHN was not included in the analysis because of difficulty in applying a subjective pain severity scale due to existing language barriers. This rate was greater than previously reported and may be related to subjective nature of assessment (3, 7, 10). No statistically significant difference could be demonstrated between the rates of PHN in those receiving and not receiving appropriate antiviral treatment by Chi-square test ($p = 0.224$). The higher rate of PHN in the group receiving appropriate antiviral treatment, a finding in direct contradiction to existing evidence, may be explained by difficulties in assessment for the presence of PHN due to subjective nature of symptoms.

7.0 CONCLUSION

HZO is a strong marker for HIV seropositivity in the South African public healthcare setting. It shows a female gender bias and most commonly affects young, potentially economically active individuals. It provides an opportunity for the early diagnosis of HIV and accessing of HIV healthcare services. It is a condition often presenting to both primary healthcare and hospital setting. Current initial assessment and treatment is inadequate and urgent healthcare worker education and provision of antiviral medication at the initial point of contact is a priority. There is an urgent need for treatment protocols that can be implemented at all levels of healthcare facility. It is often associated with $CD4^+$ counts that are associated with high rates of early HIV associated mortality and HAART therapy is indicated for a significant proportion of patients at presentation. The majority of patients do not present with decreased VA as a presenting complaint, multiple ocular complications are the rule, few patients have no ocular complications and ocular complications associated with visual loss (neurotrophic keratitis and intraocular inflammation) are commonly encountered. Hutchinson's sign is of doubtful value and all HIV seropositive patients with HZO should therefore be sent for ophthalmic assessment. The short term prognosis in our setting is favourable in most cases but long term follow-up is indicated. Rates of PHN are high and therefore pain management services form an important part of the management of this condition.

8.0 REFERENCES

1. Evans B. Management of blinding disease: loss of immunity and superinfection. Eye. 2005 Oct; 19(10): p. 1035-1036.
2. Treatment Action Campaign. Treatment action campaign online. [Online].; 2008 [cited 2012 January 7. Available from: http://www.tac.org.za/community/.
3. Vafai A, Berger M. Zoster in patients infected with HIV: A review. Am J Med Sci. 2001 Jun; 321(6): p. 372-80.
4. Dawodu O, Osahon A, Alikah A, Bakare CE. Herpes zoster ophthalmicus. S Afr M J. 2005 Jan; 95(1): p. 30-31.
5. Hodge W, Seiff S, Margolis TP. Ocular opportunistic infection incidence amongst patients who are HIV positive compared to patients that are HIV negative. Ophthalmology. 1998 May; 105(5): p. 895-900.
6. Sahoo S. HIV- and AIDS-related ocular manifestations in Tanzanian patients. Malay J Med Sci. 2010 Jan - Mar; 17(1): p. 12 - 16.
7. Biswas J, Sudharshan S. Anterior segment manifestations of human immunodeficiency virus/acquired immune deficiency syndrome. Indian J Ophthalmol. 2008 Sep - Oct; 56: p. 363 - 75.
8. Cochereau I, Mlika-Cabanne N, Godinaud P, Niyongabo T, Poste B, Ngayiragije A et al. AIDS related eye disease in Burundi, Africa. Br J Ophthalmol. 1999 Mar; 83(3): p. 339 - 42.
9. Gross G, Schöfer H, Wassilew H, Friese K, Timm A, Guthoff R et al. Herpes zoster

guideline of the German Deramtological Society (DDG). J Clin Virol. 2003 Apr; 26(3): p. 277-289.

10. Pavan-Langston D. Herpes zoster ophthalmicus. Neurology. 1995 Dec; 45(12 Suppl 8): p. S50-1.
11. Zaal M, Volker-Dieben H, D'Amaro J. Prognostic value of Hutchinson's sign in acute herpes zoster ophthalmicus. Graefe's Arch Clin Exp Ophthalmol. 2003 Mar; 241(3): p. 187-91.
12. Wiafe B. Herpes zoster ophthalmicus in HIV/AIDS. Community Eye Health. 2003; 16(47): p. 35-6.
13. Gnann JW, Whitley RJ. Herpes zoster. N Engl J Med. 2002 Aug; 347(5): p. 340-46.
14. Liesegang T. Herpes zoster virus infections. Curr Opin Ophthalmol. 2004 Dec; 15: p. 531-36.
15. Palexas GN, Welsh NH. Herpes zoster ophthalmicus: an early pointer to HIV-1 seropositivity in young African patients. Scand J Immunol. 1992; 36(Suppl 11): p. 67-8.
16. Adio A, Fiebai B. Herpes zoster ophthalmicus and HIV seropositivity in South-South Nigeria. Niger J Med. 2010 Apr - Jun; 19(2): p. 162 - 4.
17. Yau T, Butrus S. Presumed bilateral herpes zoster in an AIDS patient: A case report. Cornea. 1996 Nov; 15(6): p. 633-4.
18. Thean J, Hall A, Stawell R. Uveitis in herpes zoster ophthalmicus. Clin Experiment Ophthalmol. 2001 Dec; 29(6): p. 406-10.
19. Umeh R. Herpes zoster ophthalmicus and HIV infection in Nigeria. Int J STD AIDS.

1998 Aug; 9(8): p. 476-79.

20. Margolis TP, Milner MS, Shama A, Hodge W, Seiff . Herpes zoster ophthalmicus in patients with human immunodeficiency virus infection. Am J Ophthalmol. 1998 Mar; 125(3): p. 285-91.

21. Kaufman S. Anterior Segment Complications of Herpes Zoster Ophthalmicus. Ophthalmology. 2008 Feb; 115(2 supplement): p. S24-32.

22. Naseri A, Margolis TP. Varicella zoster virus immune recovery stromal keratitis in a patient with AIDS. Br J Ophthalmol. 2001 Nov; 85(11): p. 1390-1.

23. Neves RA, Rodriguez D, Power WJ, Muccioli C, Lane L, Belfort R et al. Herpes zoster peripheral ulcerative keratitis in patients with acquired immune deficiency syndrome. Cornea. 1996 Sep; 15(5): p. 446-50.

24. Lewallan S. Herpes zoster ophthalmicus in Malawi. Ophthalmology. 1994 Nov; 101(11): p. 1801-4.

25. Gariano RF, Berreen JP, Cooney EL. Progressive outer retinal necrosis and acute retinal necrosisin fellow eyes of a patient with acquired immune deficiency syndrome. Am J Ophthalmol. 2001 Sep; 132(3): p. 421-3.

26. Biswas J, Deka S, Padmaja S, Madhavan HN, Kumarasamy N, Solomon S. Central retinal vein occlusion due to herpes zoster as the inititial presenting sign in a patient with acquired immunodeficiency syndrome (AIDS). 2001 Jun; 9(2): p. 125-30.

27. Shayegani A, Odel JG, Kazim M, Hall LS, Bamford N, Schubert H. Varicella zoster virus retrobulbar optic neuritis in a patient with human immunodeficiency virus. Ophthalmology. 1996 Oct; 122(4): p. 586-88.

28. Pavan-Langston D. Herpes zoster: Antivirals and pain management. Ophthalmology. 2008 Feb; 115(2 supplement): p. S13-20.

29. Nithyanandam S, Stephen J, Joseph M, Dabir S. Factors affecting visual outcome in herpes zoster ophthalmicus: a prospective study. Clin Experiment Ophthalmol. 2010 Dec; 38(845-50).

30. Nithyanandam S, Joseph M, Stephen J. Ocular complications and loss of vision due to herpes zoster ophthalmicus in patients with HIV infection and a comparison with HIV negative patients. Int J STD AIDS. 2013 Mar; Epub prior to publication.

31. Gupta A, Nadkarni G, Yang WT, Chandrasekhar A, Gupte N, Bission GP et al. Early mortality in adults initiating antiretroviral therapy (ART) in low- and middle-income countries (LMIC): A systematic review and meta-analysis. Plos One. 2011 Dec; 6(12): p. 1 - 11.

32. Oliveira I, Andersen A, Furtado A, Medina C, da Silva D, Aaby P et al. Assessment of simple risk markers for early mortality among HIV-infected patients in Guinea-Bissau: a cohort study. BMJ Open. 2012 Nov; 2(6): p 1 - 10.

33. Van Dyk M, Meyer D. Hutchinson's sign as marker of ocular involvement in HIV-positive patients with herpes zoster ophthalmicus. SAMJ. 2010 Mar; 100(3): p. 172-174.