

https://dspace.org/

A five-year retrospective review of the frequency of malignancy in medial maxillectomy specimens for inverted papilloma at Chris Hani Baragwanath Academic Hospital

Adzatia, Etornam Kwame

2021

https://hdl.handle.net/10539/32334

Downloaded from a DSpace repository. https://dspace.org/

A FIVE-YEAR RETROSPECTIVE REVIEW OF THE FREQUENCY OF MALIGNANCY IN MEDIAL MAXILLECTOMY SPECIMENS FOR INVERTED PAPILLOMA AT CHRIS HANI BARAGWANATH ACADEMIC HOSPITAL.

DR. ETORNAM KWAME ADZATIA

Student number: 0501197R

A research report submitted to the Faculty of Health Sciences, University of the Witwatersrand, in partial fulfilment of the requirements for the degree of Master in Medicine (Otorhinolaryngology).

Supervisor: Dr. Yahya Atiya

School of Clinical Medicine, Faculty of Health Sciences, University of the Witwatersrand, South Africa

Johannesburg, 2021

DECLARATION

I, Etornam Kwame Adzatia, declare that this research report is my own work. It has been submitted for the degree of Master in Medicine in the Faculty of Health Sciences at the University of the Witwatersrand, Parktown, Johannesburg, South Africa. It has not been submitted before for any other degree or examination at this or any other University.



……

This day of 03/05/ 2021

RESEARCH OUTPUT

This work has not yet been presented or published.

ABSTRACT

Background: Sinonasal inverted papilloma (SNIP) is one of the most common benign tumours of the nose and paranasal sinuses. It has unpredictable rates of recurrence and malignant transformation. Studies assessing the prevalence of malignant transformation have been reported from India, China and Europe but not from Africa. The purpose of the study was to establish if the incidence of malignancy in inverted papilloma in a defined South African population is in keeping with that reported worldwide.

Method: This was a quantitative retrospective chart review of patients with malignant transformation of inverted papilloma attending the Otorhinolaryngology Department at Chris Hani Baragwanath Academic Hospital. The study was a retrospective data collection over 5 years from 1st January 2015 to 31st December 2019. Data sought were demographic data (age, 'race' and gender); the resection method used(pure endonasal endoscopic approach, external approach, or combined); risk factors (history of HIV, cigarette smoking, occupation); and factors related to malignant transformation (if present: time to occurrence, clinical stage, treatment method, survival).

Results: Adequate data were obtained from 26 records. The average age of the sample was 47.2 years (SD: 15.5), but the range was very broad. The minimum age was 23 years and the maximum age was 89 years. Thirty-eight percent (38%, n/N = 10/26) of the sample was female, and all expect one record had been obtained from a Black Africans (the one exception was classified as being of Indian decent). All resections were performed endoscopically, and viral cytopathy showed one individual with cytomegalovirus and three with human papillomavirus cytopathic effects. Thirty-eight percent (38%, n/N = 10/26) of patient records indicated that they had a history of smoking, and 15% (n/N = 4/26) were HIV-positive.

In terms of recurrences, there was a recurrence in 4 cases (15%, n/N = 4/26). The mean time to recurrence was 21 months (SD: 9.9), with a minimum time of 9 months and a maximum time of 36 months.

Conclusions: This study showed frequency of malignancy similar to those reported worldwide (11.5%) but slightly higher rates of tumour recurrence (15.4%) with a mean time to recurrence of 21 months. The higher tumour recurrence rate may be due to the incomplete surgery and delayed presentation or high disease stage at presentation. There was no distinct risk factor noted for SNIP recurrence or malignant transformation.

DEDICATION

I dedicate this work to my wife, Dr. Yvonne Donkor-Adzatia and my family for the constant support.

ACKNOWLEDGEMENTS

Many thanks to my supervisor Dr Yahya Atiya for his supervision and mentoring throughout my training. To Dr Sugenshnee Pather of the department of pathology for assisting with access to data. Finally to God Almighty for his constant grace and mercy over my life.

LIST OF ABBREVIATIONS

CHBAH Chris Hani Baragwanath Academic Hospital

ENT Ear, nose and throat

HPV Human papilloma virus

NHLS National Health Laboratory Services

NOS Not otherwise specified

SNIP Sinonasal inverted papilloma

SPSS Statistical Package for Social Sciences

TABLE OF CONTENTS

DECLARATION ii
RESEARCH OUTPUT iii
ABSTRACT iv
DEDICATION vi
ACKNOWLEDGEMENTS vii
LIST OF TABLES xi
LIST OF FIGURES xii
1. INTRODUCTION AND LITERATURE REVIEW 1
1.1. Introduction 1
1.2. Literature Review 1
1.2.1. Epidemiology 2
1.2.2. Histopathology 2
1.2.3. Aetiopathogenesis 3
1.2.4. Clinical Staging 4
1.2.5. Imaging 5
1.2.6. Management 6
1.2.7. Recurrence 7
1.2.8. Malignant association and transformation 8
1.3. Purpose 8
2. AIM AND OBJECTIVES 9
2.1. Aim 9
2.2. Objectives 9
3. MATERIALS AND METHOD 10
3.1. Study design 10
3.1.1. Study population 10
3.2. Sample size 11
3.2.1. Data sources, measurements and data collection 11
3.3. Data Analysis 11
4. RESULTS 13
4.1. Sample 13
4.2. Numerical data 13
4.3. Categorical data 14

4.4. Prevalence of dysplasia and malignant transformation 15
4.5. Relationship between variables 16
5. DISCUSSION 17
5.1. Risk factors for malignant transformation 17
5.2. Demographics 17
5.3. SNIP and risk factors 17
5.4. Dysplasia and malignant transformation and recurrence 18
5.5. Limitations 19
5.6. Significance of the study 19
6. CONCLUSIONS 20
7. REFERENCES 21
8. APPENDICES 27
8.1. APPENDIX A. ETHICS CERTIFICATE 27
8.2. APPENDIX B. CEO of CHBAH APPROVAL 28
8.3. APPENDIX C. Clinical Head of ENT at CHBAH approval 29
8.4. APPENDIX D. Head of the Department of Anatomical Pathology, NHLS / University of the Witwatersrand approval 30
8.5. APPENDIX E. TURNITIN REPORT 31

LIST OF TABLES

Table 1.1 The Krouse staging system for inverted papilloma (Krouse J, 2000) 5

Table 4.1 Numerical data.....13

Table 4.2 Categorical data 14

Table 4.3 Relationships between variables: numbers of patients (CMV = cytomegalovirus, HPV = human papillomavirus). 16

LIST OF FIGURES

Figure 4.1 Prevalence of dysplasia 15

1. INTRODUCTION AND LITERATURE REVIEW

1.1. Introduction

Sinonasal inverted papillomata (SNIP) has been described as one of the most common benign tumours of the nose and paranasal sinuses (Lisan et al, 2017). It arises from ectodermal Schneiderian mucosa that lines the sinonasal tract. Although this is a benign lesion, many authors have concluded that it has unpredictable rates of recurrence and malignant transformation (Saha et al, 2010).

1.2. Literature Review

The World Health Organization (WHO) divides sinonasal papillomata, based on their patterns of growth, into exophytic (squamous), inverted (endophytic), and oncocytic (cylindrical) subtypes (Sbrana et al, 2019; Flach et al, 2020). Histologically, the inverted papilloma invaginates into the underlying stroma and it is endophytic. (Vrabec, 1994). It is the most common type of Schneiderian papilloma (Flach et al, 2020). Sinonasal inverted papillomata, although benign, tend to be locally aggressive with bony destruction, have unpredictable rates of recurrence post excision, and in some instances, can result in malignancy (Saha et al, 2010; Sbrana et al, 2019).

Clinically, patients can present with unilateral nasal obstruction, epistaxis, rhinorrhoea and anosmia (Kerschner et al, 1996). They usually occur in the lateral wall of the nasal cavity (medial wall of maxillary sinus) but can also be found in the ethmoid and maxillary sinuses (Fulla et al, 2020).

1.2.1. Epidemiology

Sinonasal inverted papillomata make up approximately 0.5-7% of all tumours of the sinonasal tract and have an incidence of 0.2-0.7/100,000 people/year worldwide (Yu and Liu, 2014; Fulla et al, 2020). Even though relatively rare, most ENT surgeons are likely to encounter these multiple times during their career (Gamrot-Wrzol, 2017).

Males are more commonly affected than females with a ratio of 3.4:1, although some studies have shown higher ratios such as 10:1 (Saha et al, 2010; Govindaraj and Wang, 2014). It is seen between the fourth and seventh decades of life, but is more common in the fifth decade (Barnes, 2002; Banhiram and Casiano, 2005); a review of 44 patients with SNIP found that the mean age was 57 years (Sbrana et al, 2019)

1.2.2. Histopathology

Clinically, sinonasal inverted papillomata are firm, fleshy tumours with papillary fronds (Wolfowitz, 1971). They are usually large and polypoid with an uneven multinodular surface and appear greyish in colour (Govindaraj and Wang, 2014). The diagnosis of SNIP requires histological confirmation (Gamrot-Wrzol, 2017). A commentary on the WHO histological classification of tumours of the upper respiratory tract and ear (Shanmugaratnam and Sobin, 1993) divided sinonasal papillomata into the three histological subtypes as stated above. SNIP is the most common and is the focus of this study. Microscopically, they appear as hyperplastic epithelial invaginations into the underlying stroma and are made up of well differentiated columnar or ciliated respiratory epithelium (Shanmugaratnam and Sobin, 1993; Bishop et al, 2017). SNIP has been described as an endophytic tumour that is histologically more vascular than inflammatory. It is covered in respiratory, squamous or transitional

epithelium and rests on the normal respiratory epithelium with a clear cleavage plane. It lacks mucous secreting cells as well as eosinophils and the 'inverting' epithelial proliferating cells do not cross the basement membrane (Shanmugaratnam and Sobin, 1993). Inverted papilloma can have two patterns. They may either be papillary/exophytic (without invagination into the underlying stroma) or inverted with an invagination into the underlying stroma (Saha et al, 2010).

1.2.3. Aetiopathogenesis

There are many theories and controversies surrounding the possible causes of SNIP. Some of the common causes of SNIP as outlined in a paper by Wang and Noel (2016) include:

- Human Papilloma Virus (HPV)
- Cell cycle regulation (effect of p53 and p21 expression)
- Epstein-Barr virus
- Environmental factors (smoking, industrial and occupational exposures)
- Angiogenic factors (osteopontin & vascular endothelial growth factor)
- Influence of chronic inflammation.

Many authors have postulated that HPV is an important aetiological factor in the formation and malignant transformation of SNIP. However, there is conflicting evidence about the role of HPV infection in the pathogenesis of sinonasal inverted papillomata. Whilst some studies have found that HPV may play a role in early tumour development, recurrence and even malignant transformation, other studies have found no statistically significant relationship between HPV and SNIP. Such studies conclude that HPV may just be an incidental colonization as opposed to an important aetiological factor in tumour formation (Govindaraj and Wang, 2014; Wang and Noel, 2016). So, its role in the aetiology and prognosis of SNIP remains vague.

Smoking is regarded as the single major risk factor for neoplasms in the head and neck region. With regard to SNIP, multiple studies have found no correlation between smoking and the development of tumour. It does however seem to play a role in recurrence post treatment and malignant transformation (Moon et al, 2010; Hong et al, 2013; Wang and Noel, 2016). Patients with occupational and industrial exposure such as in construction, textile, welding and printing have been found to be at an increased risk of developing SNIP (Sham et al, 2010). It was previously believed that the Epstein-Barr virus (EBV) played a key role in the pathogenesis (Macdonald et al, 1995), but a subsequent review of the literature, found that EBV played no significant role in the development of SNIP (Anari et al, 2010).

Microscopic examination of SNIP usually shows chronic inflammatory changes. This has led to the theory that inflammation may play a role in the formation of SNIP. A review of specimens in Chinese patients showed increased neutrophils, macrophages, eosinophils and other inflammatory markers (Roh et al, 2004; Zhao et al, 2016). Angiogenic factors have also been known to contribute to the growth of SNIP. Osteopontin and vascular endothelial growth factor, which regulates angiogenesis, have been found in higher quantities in SNIP tissues. This may suggest that these factors may contribute to the clinical progression of the tumour (Liu et al, 2011).

1.2.4. Clinical Staging

The main goal of staging SNIP is to estimate prognosis (Lisan et al, 2017). Thorough nasal endoscopy is often impossible, due to tumour size and location in the maxillary sinus, and so imaging is used to assist in staging the tumour.

There have been several staging systems proposed for SNIP. Most of these are based on the location or extent of the tumour (Gras-Cabrerizo et al, 2010). Krouse (2000) suggested three factors in deciding the stage of the disease: location, extent, and presence of malignancy. The Krouse system remains the most widely used by ENT surgeons worldwide. Higher Krouse staging has been found to be associated with tumour recurrence after surgical excision (Lisan et al, 2017). Table 1 shows the Krouse staging system.

Table 1.1 The Krouse staging system for inverted papilloma (Krouse J, 2000)

STAGE	DESCRIPTION
T1	Tumour totally confined to the nasal cavity, without extension into the sinuses. The tumour can be localized to one wall or region of the nasal cavity, or can be bulky and extensive within the nasal cavity, but must not extend into the sinuses or into any extranasal compartment. There must be no concurrent malignancy
T2	Tumour involving the ostiomeatal complex, and ethmoid sinuses, and/or the medial portion of the maxillary sinus, with or without involvement of the nasal cavity. There must be no concurrent malignancy
T3	Tumour involving the lateral, inferior, superior, anterior, or posterior walls of the maxillary sinus, the sphenoid sinus, and/or the frontal sinus, with or without involvement of the medial portion of the maxillary sinus, the ethmoid sinuses, or the nasal cavity. There must be no concurrent malignancy
T4	All tumours with any extranasal/extrasinus extension to involve adjacent, contiguous structures such as the orbit, the intracranial compartment, or the pterygomaxillary space. All tumours associated with malignancy

1.2.5. Imaging

It is routine to order pre-operative imaging for patients with SNIP. This helps to delineate the location and extent of the tumour in order to accurately plan surgery. For example, tumours encroaching on vital structures like the skull base, if identified preoperatively, may benefit from the use of image guidance/navigation during surgery. CT staging has been the gold standard for staging SNIP (Gras-Cabrerizo JR et al, 2010). Imaging also assists in identifying the site of attachment which appears as a focal area of hyperostosis (Bhalla and Wright 2009; Saha et al, 2010). One of the main ways of preventing recurrence is resection of the tumour

with the periosteum and to drill the area of hyperostosis as seen on computerised tomography (CT) (Gamrot-Wrzol 2017; Wu et al, 2019).

A contrast-enhanced CT scan of the paranasal sinuses is usually adequate for imaging SNIP. MRI is ordered if orbital or intracranial extension is suspected on CT scan and rarely for malignant transformation. Imaging features of the tumour that may suggest malignancy include bony erosion on CT, loss of cerebriform pattern, tumour necrosis, intracranial extension and orbital invasion on MRI (Yan et al, 2019). In our relatively low-resourced setting, a CT scan is almost always adequate in assessing patients pre-operatively.

1.2.6. Management

Complete surgical excision is the main stay of treatment of SNIP (von Buchwald and Bradley, 2007). Surgery can be purely endoscopic, external approach or a combination of both (Bugter et al, 2017). It was previously thought that an open surgical approach was better for advanced tumour stage (Sham et al, 2009). Other studies have subsequently shown that endoscopic technique showed excision control rates comparable to an open technique (Laeson et al, 2003). A 17-year review by Coutinho et al (2020) also concluded that endoscopic surgery did not increase recurrence rates and can be regarded as an alternative to open surgery. This, together with advances in instrumentation and visualization for endoscopic sinus surgery, has led to a shift towards mainly endoscopic surgery for primary SNIP (Wu et al, 2018).

Even though surgery is still the mainstay of treatment, non-surgical options have been considered for the treatment of SNIP. Some authors have proposed radiation therapy for

patients with malignant transformation, recurrent disease or irresectable tumour (Rutenberg et al, 2013; Strojan et al, 2013).

1.2.7. Recurrence

Kim and Kwon in 2017 reported an average rate of recurrence of 13.72%. Multiple risk factors for recurrence have been reviewed by various researchers. One such risk is the surgical approach employed in treating SNIP. A meta-analysis showed that the endoscopic approach resulted in less recurrence compared with the open approach (Kim and Kwon, 2017). Incomplete or inadequate initial tumour removal and higher Krouse tumour staging has also been associated with recurrence (Lisan et al, 2017). A literature review identified factors that when elevated, increased the risk of tumour recurrence (Gamrot-Wrzol et al, 2017). These included the young age of patients (Jardine et al, 2000), female sex (Roh et al, 2016), tobacco smoking (Jardine et al, 2000) and certain histopathological findings such as increased hyperkeratosis (Katori et al, 2006).

Another reason for SNIP recurrence is involvement of certain areas such as the frontal recess, sphenoid sinus and lamina papyracea (Lawson et al, 2003). It has been established that removing mucosa and drilling the bone at the site of attachment of the tumour decreases recurrence (Wu et al, 2018). A review of the recurrence and malignant transformation of SNIP also concluded that incomplete tumour removal, location of tumour, stage and surgical approach used were direct risk factors for recurrence (Sun et al, 2017). SNIP located close to vital structures such as the optic nerve and internal carotid artery have a higher rate of recurrence (Suh et al, 2015).

1.2.8. Malignant association and transformation

To date, there are no known studies or data from Sub-Saharan Africa documenting the rate of malignancy in inverted papilloma. Several studies around the world have shown an average of 10% rate of malignant transformation, but the reported incidence varies widely (Kim et al, 2012). Some authors report as low as 0% (Mansell and Bates, 2000), while others quote as high as 53% (Yamaguchi et al, 1979). Malignancy may occur within the tumour itself, as a separate synchronous tumour or develop later as a metachronous lesion in the vicinity of a previously excised tumour (Mirza et al, 2007). The primary tumour may have areas of transformation into malignancy, depending on dysplastic changes. The area of the tumour may also later be associated with metachronous lesions if the tumour recurs. It is generally advocated that patients be followed up regularly long-term in order to detect recurrence and malignancy early.

1.3. Purpose

Chris Hani Baragwanath Academic Hospital (CHBAH) is the largest hospital in the southern hemisphere and the third largest in the world, serving more than 3.5 million people (Landman et al 2001). This, in terms of population size and referral/drainage areas, gives the hospital the advantage of having a diversity of pathologies in its patient population. The ENT Department by extension is one of the busiest in the country, servicing an average of 250 out-patients per week.

Studies assessing the prevalence of malignant transformation in inverted papilloma have been performed in India, China and Europe (Saha et al, 2010). The purpose of this study was to establish if the incidence of malignancy in inverted papilloma in a defined South African population is in keeping with that reported worldwide.

2. AIM AND OBJECTIVES

2.1. Aim

The aim of this study is to retrospectively assess the rate of malignant transformation in specimens of SNIP following medial maxillectomy.

2.2. Objectives

2.2.1 Describe the demographics of the patient population diagnosed with inverted papilloma with malignant transformation, and to compare these with patients without malignant transformation

2.2.2 Determine the rate of malignant transformation in inverted papilloma specimens at CHBAH.

2.2.3 Determine the risk factors, if any, for malignant transformation in inverted papilloma.

2.2.4 Determine whether dysplasia has an influence on SNIP recurrence.

3. MATERIALS AND METHOD

Approval to conduct the study was obtained from the Human Research Ethics Committee of the University of the Witwatersrand and the clearance certificate number is M2011159 (Appendix A). In addition, permission was given by the CEO of CHBAH (Appendix B), the Clinical Head of ENT at CHBAH (Appendix C) and the Head of Department of Anatomical Pathology, NHLS/University of the Witwatersrand (Appendix D).

3.1. Study design

This was a quantitative retrospective chart review of patients with malignant transformation of SNIP managed at the ENT Department at Chris Hani Baragwanath Academic Hospital. The study was a retrospective data collection from 1st January 2015 to 31st December 2019.

3.1.1. Study population

The study included all patients who had medial maxillectomy surgery for SNIP with subsequent histological analysis. The inclusion criteria were:

- Patients with SNIP who were treated surgically, and for whom histopathological results were available on the NHLS database.
- Any patient who had either open or endoscopic medial maxillectomy for SNIP
- All patients had to be over 18 years old

The exclusion criteria were:

- Patients who had medial maxillectomy surgery for diagnosis other than SNIP
- Patients for whom a laboratory report (diagnostic) was not available

3.2. Sample size

The estimated number of patients was 60, based on an average of one procedure per month.

3.2.1. Data sources, measurements and data collection

Patients were identified from two sources: the ENT operating theatre register and the ENT ward admission register. The theatre register was the primary reference, and the ward register was used to obtain additional data. The demographic data collected were age, race (as classified per 'population group') and sex. The resection method was recorded as pure endonasal endoscopic approach, external approach and combined approaches. Risk factors were recorded as history of HIV, cigarette smoking, outdoor and industrial occupations Factors related to malignant transformation were recorded as follows:

- Malignant transformation – yes or no. If yes, then:
    - Time (in months) for malignant transformation to occur
    - Clinical stage
    - Treatment method – surgery, radiotherapy, chemotherapy, palliation
    - Survival of patient by 31st December 2019 – alive, deceased, lost to follow up, last seen date.

3.3. Data Analysis

Data was captured onto a Microsoft Excel® spreadsheet and then imported into the Statistical Package for Social Sciences (SPSS) version 23.0. A confidence interval of 95% with a p-value of 0.05 was used. Descriptive statistics were the mean, median, range, standard deviation, variance and standard error. The data was to be tested for parametric distribution and it was intended to test for comparative statistics using two main groups: cases who had malignant transformation, and those without. Tests would include Pearson's chi-squared test,

Student’s t- test (paired or unpaired according to data distribution in each group) and correlation tests, where possible. If possible, survival analysis was to be done using the Cox Proportional Hazard for alive, deceased and lost to follow up patients.

4. RESULTS

4.1. Sample

Despite the anticipated sample size of 60, it was found that only 26 records could provide adequate data for analysis. One patient was excluded as she was 14 years at the time of surgery (minimum age for study was 18 years).

4.2. Numerical data

The data on age and time to SNIP recurrence are shown in Table 4.1

Table 4.1 Numerical data

Variable	Complete records	Mean	SD	Minimum	25th percentile	Median	75th percentile	maximum
Age(years)	26	47.2	15.5	23	34.2	45	56.8	89
Time to recurrence	5	21.2	9.9	9	18	19	24	36

The data set is small, consisting of 26 records. The average age of the sample was 47.2 years (SD: 15.5), but the range was very broad. The minimum age was 23 years, and the maximum age was 89 years.

4.3. Categorical data

Table 4.2 Categorical data

Variable	Complete records	Number of unique variables	Top counts
Sex	26	2	Male: 16, Female: 10
Race	26	2	African: 25, Indian: 1
Resection method	26	1	Endoscopic: 26
Viral cytopathy	26	3	None: 22, HPV: 3, CMV: 1
Smoking	26	2	No: 16, Yes: 10
HIV	26	2	Negative: 22, Positive: 4
Dysplasia	26	4	None: 20, Moderate: 3, High Grade: 2, Low Grade: 1
Malignant transformation group	26	4	None: 23, Invasive: 3
Malignant transformation: subgroup	3	2	Metachronous: 2, Synchronous: 1
Recurrence	26	2	No: 22, Yes: 4

Thirty-eight percent (38%, n/N = 10/26) of the sample was female, and all except one record (which was classified as Indian) were classified as African. All resections were performed endoscopically. Viral cytopathy revealed one patient with cytomegalovirus and three with human papillomavirus cytopathic effects.

Ten (38%) patients had a recorded history of smoking. Two records did not state HIV status and of the 25 that did, 4 (15%) were HIV-positive. No patient was recorded as having industrial exposure. In terms of recurrences, data from the 26 records, revealed recurrence in 4 cases (15.4%). The mean time to recurrence was 21 months, with a range of 9 months to 36 months.

4.4. Prevalence of dysplasia and malignant transformation

Dysplasia was recorded in 6 (23.1%) out of the 26 patient records reviewed. Dysplasia was classified as high, moderate, or low grade and the frequency is shown in Figure 4.1.

Figure 4.1 Prevalence of dysplasia

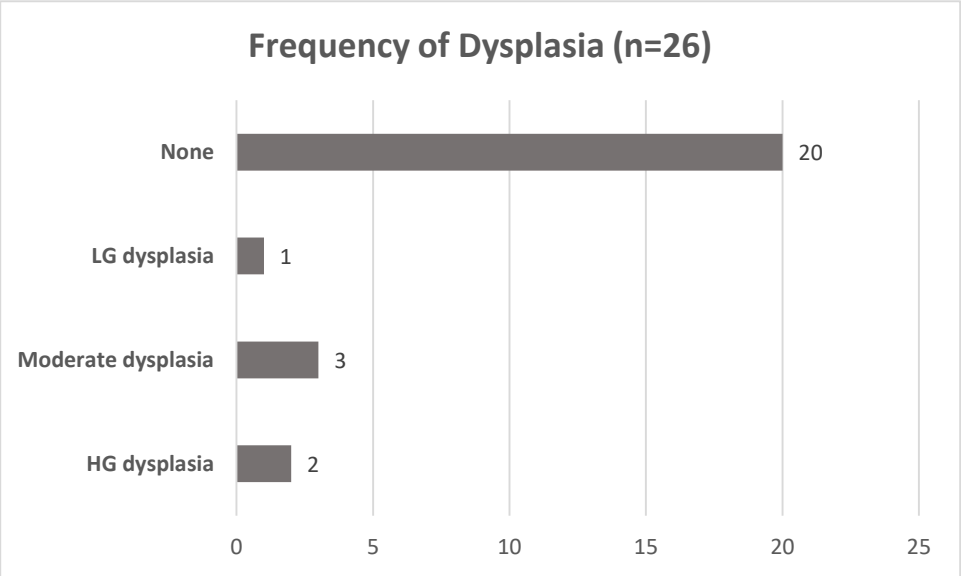

Malignant transformation was recorded for three patients, all being invasive squamous cell carcinoma with two being of the metachronous type, and one being synchronous. Data on the time for the transformation to occur was available for the 2 metachronous transformations and revealed that one had occurred 9 months and the other 19 months after surgery. All three occurred in different anatomical locations: the orbit of the eye, the ear, and the ethmoid and maxillary sinuses. All the malignant tumours were classified as grade T4 as per the Krouse staging system. All 3 tumours were treated with radiation therapy, but the synchronous, which occurred in the ethmoid sinuses, was also treated with surgery.

4.5. Relationship between variables

The small sample size and the small numbers in many of the variables precluded statistical analyses of any associations. Nevertheless, it was felt worthwhile to record the data (Table 4.3) as some relationships may help comparisons with other studies and point to future research on larger data sets. There do not appear to be relationships between any of the variables.

Table 4.3 Relationships between variables: numbers of patients (CMV = cytomegalovirus, HPV = human papillomavirus).

	Dysplasia (n=24)				Malignant Transformation
Variable	**High grade**	**Moderate**	**Low grade**	**None**	
HIV positive (n=4)	1	1	1	1	1
HIV negative (n=21)	1	0	2	17	2
Smoking (n=10)	1	0	2	7	1
Non-smoking (n=17)	1	1	1	13	2
Viral Cytopathy: CMV	0	0	1	0	0
Viral Cytopathy: HPV	0	0	1	2	0
Viral Cytopathy: none	2	1	1	18	3

5. DISCUSSION

5.1. Risk factors for malignant transformation

Multiple studies have shown varied rates of malignancy and recurrence of Sinonasal Inverted Papilloma. There has been no such study conducted in our patient population. This retrospective study was to review the demographics of patients with SNIP and to establish possible risk factors for malignancy.

5.2. Demographics

The mean age of patients included in this study was 47. Banhiram and Casiano (2005) showed that it is more common in the 5th decade. The ratio of male to female patients was 3:2 which has a slightly higher female incidence compared with Saha et al, (2010) who reported a male to female ratio of 3.4:1.

5.3. SNIP and risk factors

There have been no reported links or studies found between HIV and SNIP. There is a high burden of HIV in the South African population, and patients with HIV having a 1.7- 4.0-fold increased risk in developing Head and Neck cancer compared with the general population (Chaturvedi AK et al, 2009). The study aimed to establish if there was any association between HIV status and malignant transformation of SNIP and found that HIV seemed to have no associated effect on malignant transformation or recurrence.

There was also no association between smokers and recurrence or malignant transformation. This is contrary to that reported in the literature. Jardine et al, (2000) and Wang and Noel, (2016) suggested that smoking played a role in recurrence post treatment and malignant transformation.

Specimens that showed viral cytopathy (CMV and HPV) had no direct association with dysplasia or malignant transformation. This confirms what has been suggested, that HPV may just be an incidental colonization as opposed to an aetiological factor (Wang and Noel, 2016).

5.4. Dysplasia and malignant transformation and recurrence

The reported incidence of malignancy in SNIP varies widely (Kim et al, 2012). This study aimed to assess the frequency of malignant transformation of SNIP in our population. Dysplasia is regarded as a premalignant step in the spectrum of malignancy.

Of the 5 patients who had dysplasia, 3 had moderate, 2 high grade and 1 low grade. Only two progressed to malignancy in this study population. The synchronous tumour (malignancy at presentation) had already progressed, so it was not possible to ascertain whether there was dysplasia preceding malignancy or not. Only one of the patients with dysplasia had tumour recurrence. Of the 26 specimens reviewed, three had malignancy (11.5%). This is in keeping with the reported average of 10% around the world (Kim et al, 2012).

Four out of the 26 patients had tumour recurrence (15.4%). This is slightly higher than the reported average of 13.7% (Kim and Kwon, 2017). All tumours were excised via the endonasal approach, which has been shown to result in less disease recurrence. Other known causes of tumour recurrence, as stated earlier, include incomplete/inadequate tumour excision, young age, female sex and tobacco smoking.

5.5. Limitations

This was a retrospective study and was thus limited by the quality and completeness of information recorded, as there was a reliance on adequately completed records. This has resulted in a smaller than anticipated sample size. In addition, this was a single-centre study so the applicability of the data may be limited. The study was also relatively short term, and length of follow up could have been greater. Access to patient files for proper follow up was challenging as there is no computerised system of tracking patients. Perhaps electronic note keeping could improve further research.

5.6. Significance of the study

It is hoped that this study would significantly contribute to the already existing body of knowledge by giving an African perspective to this disease. The frequency of malignancy was similar to that reported worldwide. There was a slightly higher rate of tumour recurrence compared with those reported worldwide. This emphasizes the need for strict follow up and reviewing post-operative histology.

The implications of this study may result in the implementation of a follow-up protocol and encourage better endoscopic sinonasal surgery training (continuous professional development).

6. CONCLUSIONS

Unilateral nasal mass is one of the common clinical entities that is managed by ENTs. Although relatively rare, SNIP is one of the most important in differential diagnosis due to its tendency for recurrence and malignant transformation. This study showed frequency of malignancy similar to those reported worldwide (11.5%) but slightly higher rates of tumour recurrence (15.4%) with a mean time to recurrence of 21 months. The higher tumour recurrence rate may be due to incomplete surgery and/or delayed presentation/high disease stage at presentation. There was no distinct risk factor noted for tumour recurrence or malignant transformation. It is important for staff to continue to enhance surgical skills and post-operative evaluation to prevent and detect recurrence early.

7. REFERENCES

Anari S, Carrie S. (2010). Sinonasal inverted papilloma: narrative review. *The Journal of laryngology and otology*. 124(7), 705-15. doi: 10.1017/S0022215110000599

Banhiram W, Casiano R. (2005). Endoscopic sinus surgery for benign and malignant nasal and sinus neoplasm. *Current opinion in otolaryngology & head and neck surgery*. 13(1), 50-4. doi: 10.1097/00020840-200502000-00012

Barnes L. (2002). Schneiderian Papillomas and Nonsalivary Glandular Neoplasms of the Head and Neck. *Modern pathology: an official journal of the United States and Canadian Academy of Pathology*. 15, 279-97. doi: 10.1038/modpathol.3880524

Bhalla R, Wright E. (2009). Predicting the site of attachment of sinonasal inverted papilloma. *Rhinology*. 47(4), 345-8. doi: 10.4193/Rhin08.229.

Bishop J. (2017). OSPs and ESPs and ISPs, Oh My! An Update on Sinonasal (Schneiderian) Papillomas. *Head and Neck pathology*. 11(3), 269-77. doi: 10.1007/s12105-017-0799-9

Bugter O, Monserez D, Van Zijl F, De Jong R, Hardillo J. (2017). Surgical management of Inverted papilloma; a single-center analysis of 247 patients with long follow-up. *Journal of otolaryngology- head & neck surgery*. 46(1), 67. doi: 10.1186/s40463-017-0246-7

Chaturvedi AK, Madeleine MM, Biggar RJ Engels EA. (2009). Risk of human papillomavirus-associated cancers among persons with AIDS. *Journal of the National Cancer Institute*. Aug 19;101(16), 1120-1130. doi: 10.1093/jnci/djp205.

Coutinho G, Marques J, Leal M, Spratley J, Fernandes M, Santos M. (2020) Surgical outcomes of sinonasal inverted papilloma: a 17 year review. *Brazilian journal of otorhinolaryngology*. 86(3), 315-20. doi: 10.1016/j.bjorl.2018.12.011

Lisan Q, Moya-Plana A, Bonfils P. (2017). Association of Krouse Classification for Sinonasal Inverted Papilloma With Recurrence: A Systematic Review and Meta-analysis. *JAMA otolaryngology-- head & neck surgery*. 143(11),1104-10. doi: 0.1001/jamaoto.2017.1686

Liu W, Li Z, Luo Q, Lai Y, Zhang J, Chen F, et al. (2011). The elevated expression of osteopontin and vascular endothelial growth factor in sinonasal inverted papilloma and its relationship with clinical severity. *American journal of rhinology & allergy*. 25(5), 313-7. doi: 10.2500/ajra.2011.25.3662.

Flach S, Ferguson A, White S, White P, Manickavasagam J. (2020). Unique case of inverted papilloma of septum with nasopharyngeal carcinoma: Is it a metachronous tumour*? SAGE open med case reports*. 8(8), 1-5. doi: 10.1177/2050313X20922032

Fulla M, Szafarowski T, Frias-Gomez J, Quiros B, Clavero O, Goma M, et al. (2020). Human Papillomavirus and Factors Associated with Recurrence in Sinonasal Inverted Papillomas from Poland and Spain. *Head and neck pathology*. 14(3), 758-67. doi: 10.1007/s12105-019-1125-y

Gamrot-Wrzol M, Sowa P, Lisowska G, Scierski W, Misiolek M. (2017). Risk Factors of Recurrence and Malignant Transformation of Sinonasal Inverted Papilloma. *Biomed res international*. doi: 10.1155/2017/9195163

Govindaraj S, Wang H. (2014). Does human papilloma virus play a role in sinonasal inverted papilloma? *Current opinion in otolaryngology & head and neck surgery*. 22(1), 47-51. doi: 10.1097/moo.0000000000000017

Gras-Cabrerizo JR, Montserrat-Gili JR, Massegur-Solench H, León-Vintró X, De Juan J, Fabra-Llopis JM. (2010). Management of sinonasal inverted papillomas and comparison of classification staging systems. *American journal of rhinology & allergy*. 24(1), 66-9. doi: 10.2500/ajra.2010.24.3421

Hong SL, Kim BH, Lee JH, Cho KS, Roh HJ. (2013). Smoking and malignancy in sinonasal inverted papilloma. *Laryngoscope*. 123(5), 1087-91. doi: 10.1002/lary.23876

Jardine A, Davies G, Birchall M. (2000). Recurrence and malignant degeneration of 89 cases of inverted papilloma diagnosed in a non-tertiary referral population between 1975 and 1995: clinical predictors and p53 studies. *Clinical otolaryngology and allied sciences*. 25(5), 363-9. doi: 10.1046/j.1365-2273.2000.00357.x

Katori H, Nozawa A, Tsukuda M. (2006). Histopathological parameters of recurrence and malignant transformation in sinonasal inverted papilloma. *Acta oto-laryngolica*. 126(2), 214-8. doi: 10.1080/00016480500312554

Kerschner J, Futran N, Chaney V. (1996). Inverted papilloma associated with squamous cell carcinoma and adenocarcinoma: Case report and review of the literature. *American journal of otolaryngology*. 17(4), 257-9. doi: 10.1016/S0196-0709(96)90091-5

Kim K, Kim D, Koo Y, Kim CH, Choi EC, Lee JG, et al. (2012). Sinonasal carcinoma associated with inverted papilloma: a report of 16 cases. *Journal of cranio-maxillo-facial surgery: official publication of the European Association for Cranio-Maxillo-Facial Surgery*. 40(4), e125-9. doi: 10.1016/j.jcms.2011.07.007

Kim JS, Kwon SH. (2017). Recurrence of sinonasal inverted papilloma following surgical approach: A meta-analysis. *Laryngoscope*. 127(1), 52-8. doi: 10.1002/lary.26222

Krouse J. (2000). Development of a Staging System for Inverted Papilloma. *Laryngoscope*. 110(6), 965-8. doi: 10.1097/00005537-200006000-00015

Landman WA, Mouton J, Nevhutalu K. (2001). Chris Hani Baragwanath Hospital Ethics Audit. 2001. Ethics Institute of South Africa Research report no. 2.

Lawson W, Kaufman M, Biller H. (2003). Treatment Outcomes in the Management of Inverted Papilloma: An Analysis of 160 Cases. *Laryngoscope*.113(9), 1548-56. doi: 10.1097/00005537-200309000-00026

Macdonald M, Le K, Freeman J, Hui M, Cheung R, Dosch H. (1995). A majority of inverted sinonasal papillomas carries Epstein-Barr virus genomes. *Cancer*. 75(9), 2307-12. doi: 10.1002/1097-0142(19950501)75:9<2307::aid-cncr2820750920>3.0.co;2-z

Mansell N, Bates G. (2000). The Inverted Schneiderian Papilloma: A review and literature report of 43 new cases. *Rhinology*. 38, 97-101.

Mirza S, Bradley PJ, Acharya A, Stacey M, Jones N. (2007). Sinonasal inverted papillomas: recurrence, and synchronous and metachronous malignancy. *Journal of laryngology and otology*. 121(9), 857-64. doi: 10.1017/S002221510700624X

Moon IJ, Lee DY, Suh MW, Han DH, Kim ST, Min YG, et al. (2010). Cigarette smoking increases risk of recurrence for sinonasal inverted papilloma. *American journal of rhinology & allergy*. 24(5), 325-9. doi: 10.2500/ajra.2010.24.3510

Roh HJ, Procop G, Bantra P, Citardi M, Lanza D. (2004). Inflammation and the pathogenesis of inverted papilloma. *American journal of rhinology & allergy*. 18(2), 65-74. doi: 10.1177/19458924040180020

Roh H, Mun S, Cho K, Hong SL. (2016). Smoking, not human papilloma virus infection, is a risk factor for recurrence of sinonasal inverted papilloma. *American journal of rhinology & allergy*. 30(2), 79-82. doi: 10.2500/ajra.2016.30.4272

Rutenberg M, Kirwan J, Morris CG, Werning JW, Mendenhall WM. (2013). Radiation therapy for sinonasal inverted papilloma. *Practical radiation oncology*. 3(4), 275-81. doi: 10.1016/j.prro.2012.07.007

Saha S, Ghosh A, Sen S, Chandra S, Biswas D. (2010). Inverted Papilloma: A Clinico-Pathological Dilemma with Special Reference to Recurrence and Malignant Transformation. *Indian journal of otolaryngology and head and neck surgery: official publication of the Association of Otolaryngologists of India*. 62(4), 354-9. doi: 10.1007/s12070-010-0056-y

Sbrana M, Borges R, Pinna F, Neto D, Voegels R. (2019). Sinonasal inverted papilloma: rate of recurrence and malignant transformation in 44 operated patients. *Brazilian journal of otorhinolaryngology*. 87(1), 80-4. doi: 10.1016/j.bjorl.2019.07.003

Sham C, Woo J, van Hasselt C, Tong M. Treatment results of sinonasal inverted papilloma: an 18-year study. (2009). *American journal of rhinology & allergy*. 23(2), 203-11. doi: 10.2500/ajra.2009.23.3296.

Sham C, Lee D, van Hasselt C, Tong M. (2010). A case-control study of the risk factors associated with sinonasal inverted papilloma. *American journal of rhinology & allergy*. 24(1), 37-40. doi: 10.2500/ajra.2010.24.3408

Shanmugaratnam K, Sobin LH. (1993). The World Health Organization histological classification of tumours of the upper respiratory tract and ear. A commentary on the second edition. *Cancer*. 71(8), 2689-97. doi: 10.1002/1097-2(19930415)71:8<2689::aidcncr2820710843> 3.0.co;2-h

Strojan P, Jereb S, Borsos I, But-Hadzic J, Zidar N. (2013). Radiotherapy for inverted papilloma: a case report and review of the literature. *Radiology and oncology*. 47(1), 71-6. doi: 10.2478/v10019-012-0045-8

Suh J, Ramakrishnan V, Thompson C, Woodworth B, Adappa N, Nayak J, et al. (2015). Inverted papilloma of the sphenoid sinus: risk factors for disease recurrence. *Laryngoscope*. 125(3), 544-8. doi: 10.1002/lary.24929

Sun Q, An L, Zheng J, Zhu D. (2017). Advances in recurrence and malignant transformation of sinonasal inverted papillomas (Review). *Oncology letters*. 13(6), 4585-92. doi: 10.3892/ol.2017.6089

von Buchwald C, Bradley PJ. (2007). Risks of malignancy in inverted papilloma of the nose and paranasal sinuses. *Current opinion in otolaryngology & head and neck surgery*. 15(2), 95-8. doi: 10.1097/MOO.0b013e3280803d9b

Vrabec DP. The inverted Schneiderian papilloma: a 25-year study. (1994). *Laryngoscope*. 104(5 Pt 1), 582-605. doi: 10.1002/lary.5541040513.

Wang M, Noel J. Etiology of sinonasal inverted papilloma: A narrative review. (2016). *World journal of otorhinolaryngology- head and neck surgery*. 3(1), 54-8. doi: 10.1016/j.wjorl.2016.11.004

Wolfowitz B. Inverted papilloma of the nasal cavity and paranasal sinuses. (1971). *South African medical journal*. 45(18), 493-5.

Wu V, Siu J, Yip J, Lee J. Endoscopic management of maxillary sinus inverted papilloma attachment sites to minimize disease recurrence. (2018). *Journal of otolaryngology- head & neck surgery*. 47(1), 24. doi: 10.1186/s40463-018-0271-1

Yamaguchi KT, Shapshay SM, Incze JS, Vaughan CW, Strong MS. (1979). Inverted papilloma and squamous cell carcinoma. *The Journal of otolaryngology*. 8(2), 171-8.

Yan C, Tong C, Penta M, Patel V, Palmer J, Adappa N, et al. (2019). Imaging predictors for malignant transformation of inverted papilloma. *Laryngosco*pe. 129(4), 777-82. doi: 10.1002/lary.27582

Yu H, Liu G. Malignant transformation of sinonasal inverted papilloma: A retrospective analysis of 32 cases. (2014). *Oncology letters*. 8(6), 2637-41. doi: 10.3892/ol.2014.2539

Zhao L, Li C, Jin P, Ng C, Lin Z, Li Y, et al. (2016). Histopathological features of sinonasal inverted papillomas in chinese patients. *Laryngoscope*. 126(4), 141-7. doi: 10.1002/lary.25694

8. APPENDICES

8.1. APPENDIX A. ETHICS CERTIFICATE

UNIVERSITY OF THE WITWATERSRAND JOHANNESBURG

R49 Dr EK Adzatia

HUMAN RESEARCH ETHICS COMMITTEE (MEDICAL)
CLEARANCE CERTIFICATE NO. M2011159

NAME: (Principal Investigator)	Dr EK Adzatia
DEPARTMENT:	School of Clinical Medicine Department of Medicine Division of Internal Medicine - Otorhinolaryngology Medical School University
PROJECT TITLE:	*A five year retrospective review of the frequency of malignancy in medical maxillectomy specimens for inverted papilloma at Chris Hani Baragwanath Hospital*
DATE CONSIDERED:	Ad hoc
DECISION:	Approved unconditionally
CONDITIONS:	
SUPERVISOR:	Dr Y Atiya
APPROVED BY:	Dr CB Penny, Chairperson, HREC (Medical)
DATE OF APPROVAL:	2021/01/26

This Clearance Certificate is valid for 5 years from the date of approval. An extension may be applied for.

DECLARATION OF INVESTIGATORS

To be completed in duplicate and **ONE COPY** returned to the Research Office secretariat on the 3rd floor, Phillip Tobias Building, Parktown, University of the Witwatersrand, Johannesburg.

I/we fully understand the conditions under which I am/we are authorized to carry out the above-mentioned research and I/we undertake to ensure compliance with these conditions. Should any departure be contemplated from the research protocol as approved, I/we undertake to submit details to the Committee. **I agree to submit a yearly progress report**. When a funder requires annual re-certification, the application date will be one year after the date when the study was initially reviewed. In this case, the study was initially reviewed in **November** and therefore reports and re-certification will be due in the month of **November** each year. Unreported changes to the study may invalidate the clearance given by the HREC (Medical).

Signature of Principal Investigator

27/01/2021
Date

8.2. APPENDIX B. CEO of CHBAH APPROVAL

GAUTENG PROVINCE
HEALTH
REPUBLIC OF SOUTH AFRICA

MEDICAL ADVISORY COMMITTEE

CHRIS HANI BARAGWANATH ACADEMIC HOSPITAL

PERMISSION TO CONDUCT RESEARCH

Date:17th July2019

TITLE OF PROJECT:

A 5 year retrospective review of the frequency of malignancy in medial maxillectomy specimens for inverted papilloma at CHBAH

UNIVERSITY: Witwatersrand

Principal Investigator:Adzatia Etornam Kwame

Department:ENT

Supervisor :Yahya Atiya

Permission Head Department (where research conducted):Yes

The Medical Advisory Committee recommends that the said research be conducted at Chris Hani Baragwanath Academic Hospital. The CEO / management of Chris Hani Baragwanath Academic Hospital is accordingly informed and the study is subject to:-

- Permission having been granted by the Committee for Research on Human Subjects of the University of the Witwatersrand.
- The Hospital will not incur extra costs as a result of the research being conducted on its patients within the hospital
- The MAC will be informed of any serious adverse events as soon as they occur
- Permission is granted for the duration of the Ethics Committee Approval.

Recommended
(On behalf of the MAC)
17th July 2019

Approved/~~Not Approved~~
Hospital ManagementDate:
Date: 18/07/2019

8.3. APPENDIX C. Clinical Head of ENT at CHBAH approval

Dr MRI Ahmed
HOD
Dept of Otorhinolaryngology
Chris Hani Baragwanath Academic Hospital

To Whom it may concern,

Permission is hereby granted to Dr. Adzatia Etornam Kwame to conduct a research study entitled " A five-year Retrospective review of the frequency of malignancy in medial matxillectomy specimens for Inverted Papilloma at Chris Hani Baragwanath Academic Hospital" within the department of Otorhinolaryngology at Chris Hani Baragwanath Academic Hospital.

Permission is also granted to access patient records and other data that may be required to conduct this study.

Yours faithfully,



Dr MRI Ahmed

HOD- Dept of Otorhinolaryngology

Chris Hani Baragwanath Academic Hospital

8.4. APPENDIX D. Head of the Department of Anatomical Pathology, NHLS / University of the Witwatersrand approval

NATIONAL HEALTH LABORATORY SERVICE
UNIVERSITY OF THE WITWATERSRAND – JOHANNESBURG

UNIVERSITY OF THE WITWATERSRAND, JOHANNESBURG

SCHOOL OF PATHOLOGY
Division of Anatomical Pathology

NATIONAL HEALTH LABORATORY SERVICE

P.O. Box 1038, Johannesburg 2000
Tel : +27-11-489-8477
+27-11- 489-8479
Fax::+27-11-489-8512

Division of Anatomical Pathology
Faculty of Health Sciences
York Road
Parktown e-mail : Yvonne.perner@nhls.ac.za

Dr Y Perner MBBCh (Witwatersrand) FCPath (SA); MMed (Witwatersrand)

Human Research Ethics Committee (Medical)
University of the Witwatersrand
Johannesburg
20000

December 4, 2020

Re: Consent for access to NHLS database

This letter serves to confirm that the Department of Anatomical Pathology at the University of the Witwatersrand and NHLS is happy to assist Dr EK Adzatia with his study entitled "A seven-year retrospective assessment of the rate of malignant transformation of inverted papilloma specimens at Chris Hani Baragwanath Academic Hospital".

Publication of such work is encouraged. In order to obtain access to NHLS data, a collaborator from the Department of Anatomical Pathology is required. This collaborator must be included as a co-author on any publications emanating from the study. Dr Sugeshnee Pather from the Department of Anatomical Pathology has agreed to collaborate on this project and Dr Adzatia should contact her this regard.

Dr Adzatia will ensure that he registers on the NHLS AARMS system.

Assuring you of the Department of Anatomical Pathology's co-operation in this and future research projects.

With best wishes.

Yours sincerely,

Dr Yvonne Perner
Head: Department of Anatomical Pathology

8.5. APPENDIX E. TURNITIN REPORT

Filters used:

Exclude Quotes

Exclude Bibliography

Exclude sources of less than 2%.

Report summary:

