

https://dspace.org/

The effect of hyperstimulation on vascular endothelial growth factor (VEGF) and cyclooxygenase 2 (COX2) in the rat uterus in early pregnancy

Strkalj, Mirjana

2008-09-02T08:51:29Z
http://hdl.handle.net/10539/5586

Downloaded from a DSpace repository. https://dspace.org/

THE EFFECT OF HYPERSTIMULATION ON VASCULAR ENDOTHELIAL GROWTH FACTOR (VEGF) AND CYCLOOXYGENASE 2 (COX2) IN THE RAT UTERUS IN EARLY PREGNANCY

Mirjana Štrkalj

A dissertation submitted to the Faculty of Health Sciences, University of the Witwatersrand, in fulfillment of the requirements for the Degree of

Master of Science (Medicine)

DECLARATION

I, Mirjana Strkalj declare that this dissertation is my own work. It is being submitted for the Degree of Masters of Science in Medicine in the University of the Witwatersrand, Johannesburg. It has not been submitted before for any degree or examination in this or any other University.

……..

…… day of …… 2007.

Dedicated to:

My sons, Petar and Aleksandar

for giving me the strength and courage in everything I do

PUBLICATIONS AND PRESENTATIONS ARISING FROM THIS STUDY

Strkalj M. & Kramer B. 2006. Immunolocalization of cyclooxygenase 2 (COX2) in the hyperstimulated rat uterus. *Clinical Anatomy* 19:738. (abstract)

Strkalj M. & Kramer B. 2006. Immunolocalization of cyclooxygenase 2 (COX2) in the hyperstimulated rat uterus. Presented at the annual congress of the Anatomical Society of Southern Africa (ASSA) in April 2006 and Health Science Research Day in August 2006.

ABSTRACT

Vascular permeability and angiogenesis are crucial events in the rodent and human uterus in early pregnancy and are regulated by vascular endothelial growth factor (VEGF) and prostaglandins liberated from arachidonic acid by cyclooxygenase 2 (COX2). These events coincide with the typical morphological features of the receptive uterus and are regulated by synchronized release of ovarian hormones (oestrogen and progesterone). However, administration of follicle stimulating hormone (FSH) and human chorionic gonadotropin (hCG), commonly used in assisted reproduction, affect the synchrony of the hormonal milieu, particularly by increasing oestrogen levels. This causes detrimental changes to the uterine morphology and affects vascular permeability at the site of implantation. In the present study, the expression of COX2 and VEGF was compared between control and hyperstimulated rat uteri during the peri-implantation period using immunohistochemistry and Western blot analysis.

While in control pregnant rats COX2 and VEGF immunolocalization occurred in the luminal epithelial cells and stroma on consecutive days, strong immunolocalization of COX2 and VEGF occurred in the luminal epithelial cells but was inhibited in the stroma of the hyperstimulated rats. This appears to have resulted in the suppression of stromal decidualization and vascular permeability. Western blot analysis did not show any results. This may be due to low concentrations of the protein in the sample. Since vascular permeability and angiogenesis are critical to the process of implantation and are influenced by VEGF and COX2, disturbance of the pattern of these two proteins by hyperstimulation may contribute to the low implantation rate in IVF programes.

A NOTE ON THE BLOOD COLLECTION AND ANALYSIS OF BLOOD

The blood from the 36 animals used in this study was jointly collected by Mrs. A. Jovanovic, Embryonic Differentiation and Development Research Programme, School of Anatomical Sciences, and myself. Mrs. A. Jovanovic performed the Elisa test on half of the animals (n=18) and I performed the test on the other half of the animals (n=18). Analysis of the data obtained from the Elisa was carried out independently by Mrs. A. Jovanovic and myself.

AKNOWLEDGEMENTS

The completion of this thesis would not have been possible without the help of certain people to whom I am indebted.

Prof. Beverley Kramer, my supervisor, provided guidance, invaluable advice and constant support.

Prof. J. C. Allan and Mr J. Hemingway advised me on statistical procedures.

Mrs H. Ali assisted with the ICC.

Mrs S. Rogers gave me invaluable technical assistance and helped with photography.

Miss T. Dix Peek provided valuable suggestions on Western blotting.

Mrs A. Jovanovic was supportive through the good and the bad days.

Finally, I thank my family for their support and understanding during difficult times.

CONTENTS **PAGE**

DECLARATION i

DEDICATION ii

PUBLICATIONS AND PRESENTATIONS ARISING

FROM THIS STUDY iii

ABSTRACT ……. iv

A NOTE ON THE BLOOD COLLECTION AND

ANALYSIS OF BLOOD…… v

ACKNOWLEDGEMENTS vi

LIST OF CONTENTS …….. vii

LIST OF FIGURES xi

LIST OF TABLES xvii

1.0 INTRODUCTION 1

1.1 Controlled ovarian stimulation……. 1

1.2 Effect of hyperstimulation on the uterus ……. 3

1.3 Effect of exogenous hormones on embryo quality …….. 7

1.4 The expression of implantation related genes…… 8

1.5 Vascular permeability and angiogenesis…… 10

1.5.1 Vascular endothelial growth factor (VEGF) ……. 12

1.5.2 Cyclooxygenase2 (COX2)…….. 17

1.6 Aim of the study ……. 19

2.0 MATERIALS AND METHODS 20

2.1 Animals ……. 20

2.2 Progesterone and oestradiol ELISA ……... 23

2.3 Histology …… 24

2.4 Immunohistochemistry …… 24

2.4.1 VEGF immunostaining …… 25

2.4.2 COX2 immunostaining …… 26

2.4.3 Controls for immunohistochemistry ……. 27

2.5 Protein extraction …….. 27

2.6 Lowry protein assay …….. 28

2.7 Electrophoresis …….. 30

2.8 Western blot …….. 31

3.0. RESULTS 33

3.1 Oestradiol ELISA……. 33

3.1.1 Statistical analysis for Oestradiol concentration…… 35

3.2 Progesterone ELISA……. 37

3.2.1 Statistical analysis for Progesterone concentration …….. 39

3.3 Non-parametric Mann-Whitney test……. 41

3.4 Progesterone:Oestradiol ($P:E_2$) ratio……. 42

3.5 General observation…… 45

3.6 Histology …….. 46

3.7 Immunohistochemistry……. 50

3.7.1 Controls for COX2 immunohistochemistry…… 50

3.7.2 Immunolocalisation of COX2 in the control and hyperstimulated animals at 4.5, 5.5 and 6.5 days of pregnancy…… 51

3.8.1 Controls for VEGF imunohistochemistry…… 54

3.8.2 Immunolocalization of VEGF in the control and hyperstimulated animals at 4.5, 5.5 and 6.5 days of pregnancy……. 55

3.9 Summary of COX2 and VEGF immunolocalization in the control and hyperstimulated animals at 4.5; 5.5 and 6.5 days of pregnancy…… 58

3.10 Western blot analysis for VEGF and COX2…….. 61

4.0 DISCUSSION 98

4.1 Gross morphological changes in the uterus caused by exogenous hormones…… 98

4.2 Oestradiol and progesterone concentrations and P:E_2 ratio in the control and hyperstimulated animals during the peri-implantation period 100

4.3 Uterine receptivity and embryo implantation in the control and hyperstimulated animals 103

4.5 COX2 and VEGF expression in the control and

hyperstimulated rat uterus…… 111

4.5.1 COX2 Immunolocalization in the control and hyperstimulated rat uterus……. 112

4.5.2 VEGF Immunolocalization in the control and hyperstimulated rat uterus……. 118

5.0 CONCLUSION …… 124

REFFERENCES …….. 125

APPENDIX …….. 141

LIST OF FIGURES

Figure 1	Schematic illustration of five different VEGF isoforms (Krussel *et al.* 2003)…….....	13
Figure 2	Schematic illustrations of VEGF receptors and their interaction with different growth factors. (Krussel *et al.* 2003)…….	14
Figure 3	Standard curve for Bovine Serum Albumin (BSA) at known concentrations in μg/ml at an absorbance of 690 nm ……..	29
Figure 4	Graph showing plasma concentrations and standard deviations of oestradiol in the control and hyperstimulated animals…….	36
Figure 5	Graph showing plasma concentrations and standard deviations of progesterone in the control and hyperstimulated animals…..	40
Figure 6	Progesterone – Oestradiol ratio ($P:E_2$) in the control and hyperstimulated rats at 4.5, 5.5 and 6.5 days of pregnancy…….	44
Figure 7	Representative photomicrograph of dissected uterine horns of 5.5 control animal showing blue bands (implantation sites) Pontamine blue…….	63
Figure 8	Representative photomicrograph of dissected uterine horns of 5.5 hyperstimulated animal showing dilated uterine horns and large polycystic ovaries. Pontamine blue…….	63
Figure 9	Representative histological section of 4.5 day control ovarian tissue with numerous well developed corpora lutea.	

Haematoxylin and eosin x10……. 65

Figure 10 Representative histological section of 5.5 day hyperstimulated ovarian tissue showing numerous large follicles and numerous small corpora lutea. Haematoxylin and eosin x10……. 65

Figure 11 Representative histological section of 4.5 day control uterine tissue. Haematoxylin and eosin x10…… 67

Figure 12 Higher magnification of uterine tissue seen in Fig. 8 with the implanting embryo. Haematoxylin and eosin x40…… 67

Figure 13 Representative histological section of 4.5 control uterine tissue. Haematoxylin and eosin x40……... 67

Figure 14 Representative histological section of 4.5 day hyperstimulated uterine tissue. Haematoxylin and eosin x10…… 69

Figure 15 Representative histological section of 4.5 day hyperstimulated uterine tissue. Haematoxylin and eosin x40…….. 69

Figure 16 Representative histological section of 4.5 day hyperstimulated uterine tissue. Haematoxylin and eosin x40…….. 69

Figure 17 Representative histological section of 5.5 day control uterine Tissue. Haematoxylin and eosin x10……. 71

Figure 18 Representative histological section of 5.5 day pregnant uterine tissue Haematoxylin and eosin x40…….. 71

Figure 19 Representative histological section of 5.5 day hyperstimulated

uterine tissue. Haematoxylin and eosin x10…… 73

Figure 20 Representative histological section of 5.5 day hyperstimulated uterine tissue Haematoxylin and eosin x40……. 73

Figure 21 Representative histological section of 6.5 day control uterine tissue. Haematoxylin and eosin x10……. 75

Figure 22 Representative histological section of 6.5 day pregnant uterine tissue. Haematoxylin and eosin x40…….. 75

Figure 23 Representative histological section of 6.5 days hyperstimulated uterine tissue Haematoxylin and eosin x10……. 77

Figure 24 Representative histological section of 6.5 day hyperstimulated uterine tissue. Haematoxylin and eosin x40…….. 77

Figure 25 Representative histological section of lung carcinoma tissue incubated with COX2 antibody showing immunolocalization in the cytoplasm of the tumorous cells. Counterstained with haematoxylin x40……. 79

Figure 26 Representative histological section of 6.5 day hyperstimulated uterine tissue incubated with COX2 antibody. Counterstained with haematoxylin x40…… 79

Figure 27a Representative histological section adjacent to the section showing immunolocalization of 6.5 day hyperstimulated uterine tissue where the primary COX2 antibody was

	replaced with TRIS Counterstained with haematoxylin x40…..	79
Figure 27b	Representative histological section adjacent to the section showing immunolocalization of 6.5 day hyperstimulated uterine tissue where the secondary antibody was replaced with TRIS. Counterstained with haematoxylin x40……	79
Figure 28	Representative histological section of the uterus of 4.5 day control animal showing immunolocalisation of COX2. Counterstained with haematoxylin x40…….	81
Figure 29	Representative histological section of the uterus in 4.5 day hyperstimulated animal showing COX2 immunolocalization Counterstained with haematoxylin x40……..	81
Figure 30	Representative histological section of the uterus in a 5.5 day control animal showing immunolocalisation of COX2 Counterstained with haematoxylin x40……..	81
Figure 31	Representative histological section of the uterus of 5.5 day hyperstimulated animal Counterstained with haematoxylin x40..	81
Figure 32	Representative histological section of the uterus in 6.5 day control animal Counterstained with haematoxylin x40……	85
Figure 33	Representative histological section of the uterus in 6.5 day hyperstimulated animal showing COX2 immunolocalization. Counterstained with haematoxylin x40…….	85

Figure 34 Representative histological section of breast carcinoma tissue showing immunolocalization of VEGF in the cytoplasm of the tumour cells. Counterstained with haematoxylin x40…… 87

Figure 35 Representative histological section of 6.5 day pregnant uterine tissue showing VEGF immunolocalization in the cytoplasm of the luminal epithelial cells and stromal cells. Counterstained with haematoxylin x40……. 87

Figure 36a Representative histological section of 6.5 day pregnant uterine tissue adjacent to section in Fig. 32, where the primary VEGF antibody was replaced with TRIS. Counterstained with haematoxylin x40…….. 87

Figure 36b Representative histological section of 6.5 day pregnant uterine tissue adjacent to the section in Fig. 32, where the secondary antibody was replaced with TRIS. Counterstained with haematoxylin x40…… 87

Figure 37 Representative histological section of the uterus of 4.5 day control animal showing immunolocalisation of VEGF. Counterstained with haematoxylin x40…….. 89

Figure 38 Representative histological section of the uterus of 4.5 day hyperstimulated animal showing immunolocalization of VEGF. Counterstained with haematoxylin x40…… 89

Figure 39 Representative histological section of the uterus of 5.5 day control animal showing immunolocalisation of VEGF. Counterstained with haematoxylin x40…… 91

Figure 40 Representative histological section of the uterus of 5.5 day hyperstimulated animal showing immunolocalization of VEGF. Counterstained with haematoxylin x40……. 91

Figure 41 Representative histological section of the uterus of 6.5 day pregnant animal showing VEGF immunolocalization Counterstained with haematoxylin x10…… 93

Figure 42 Representative histological section of uterus of 6.5 day control animal showing VEGF localization. Counterstained with haematoxylin x40…….. 93

Figure 43 Representative histological section of the uterus of 6.5 day hyperstimulated animal showing VEGF immunolocalization Counterstained with haematoxylin x40…… 95

Figure 44 Representative gel after the protein separation stained with Commasie stain in the different groups of animals……. 96

Figure 45 Nitrocellulose membrane after Western blotting, representing expression of VEGF protein in the rat uterus…… 97

LIST OF TABLES

Table 3.1	Summary statistical oestradiol concentrations in the control animals…….	34
Table 3.2	Summary statistical oestradiol concentrations in the hyperstimulated animals……	34
Table 3.3	Summary statistical progesterone concentrations in the control animals…….	38
Table 3.4	Summary statistical progesterone concentrations in the hyperstimulated animals……..	38
Table 3.5	Summary of P:E_2 ratio of the control and hyperstimulated animals…….	42
Table 3.6	Summary of statistical analysis for P:E_2 ratio……..	43

APPENDIX

Appendix 1	The Schorr Staining…….	141
Appendix 2	Oestrous cycle diagram……	142
Appendix 3	Phosphate buffered saline pH 7.6……	143
Appendix 4	10% Neutral buffered formalin……	143
Appendix 5	Raw data for oestrogen and progesterone……	144
Appendix 6	Silane dipped slides…….	145
Appendix 7	Haematoxylin and eosin stain (Mayer's Staining Technique)…….	146

Appendix 8	Citrate buffer pH 6 ……..	147
Appendix 9	TRIS buffered saline pH 7, 6……..	147
Appendix 10	Homogenizing buffer stock ……	147
Appendix 11	Reagent A for Lowry protein assay ……	148
Appendix 12	Reagent B for Lowry protein assay ……	149
Appendix 13	Raw data for the protein extracts ……	150
Appendix 14	12% SDS- polyacrylamide separating gel ……..	151
Appendix 15	Electrophoresis Tank Buffer ……	151
Appendix 16	Sample transferring buffer pH 6.8 ……	151
Appendix 17	Towbin buffer ……...	152
Appendix 18	Commassie Blue Staining Solution ……..	152
Appendix 19	Distaining Solution 1 and 2 ……..	152

1.0 INTRODUCTION

Approximately 35 to 70 million couples worldwide face the problem of infertility (Schultz and Williams, 2002). Infertility is defined as an inability to conceive an intrauterine pregnancy after a year of sexual intercourse without contraception. A number of causes in both partners can lead to infertility. Some of these are ovulatory problems, fallopian tube blockage, endometriosis, decreased sperm count or motility, or abnormal sperm morphology. The majority of these causes can be successfully treated, but some remain unexplained (Tabibzadeh, 1998).

In 1978 the first "test tube baby" was born as a result of the *in vitro* fertilisation (IVF) and embryo transfer (ET) technique (Edwards *et al.,* 1980). It thus seemed that it was possible to resolve the infertility problem. While ongoing research helped to understand the complex process of fertilization, blastocyst stages, differentiation of the uterus to the receptive stage and attachment and implantation of the blastocyst, the use of the IVF and ET techniques did not increase implantation rates markedly, despite the improvement in selection and transfer of healthy embryos (Psychoyos & Martel, 1985; Sterzik *et al.,* 1988; Duc-Goiran *et al.,* 1999; Ma *et al.,* 2003).

1.1 Controlled ovarian stimulation

Discovery of the endocrine hypophyseal-gonadal axis early in the 20th century and purification of two separate gonadotropic hormones, FSH and LH, opened an era of ovarian stimulation (Macklon *et al.,* 2006). Over the last 25 years of controlled ovarian

stimulation (COS)/hyperstimulation used in IVF and ET techniques, various protocols were introduced in order to induce growth of multiple antral follicles (superovulation) and thus obtain many oocytes for IVF and ET (Macklon *et al.,* 2006). Increased numbers of oocytes are required in order to ensure transfer of sufficient numbers of blastocysts to the mother in order to ensure implantation of at least one blastocyst.

One of the commonly used superovulatory drugs is clomiphene citrate (CC). CC has few long term side effects and is simple to use (Edwards *et al.,* 1996; Macklon *et al.,* 2006). Despite successful superovulation in CC-treated patients, implantation rates are very low (Macklon *et al.,* 2006). It has been shown that CC affects normal uterine histology and ultrastructure, which in turn affects uterine receptivity (Hosie and Murphy, 1992; Hosie and Murphy, 1995).

Pregnancy rates in patients treated with CC alone are lower, compared with pregnancy rates in patients treated with gonadotropins (Macklon *et al.,* 2006). Gonadotropins are thus still widely and most commonly used in IVF and ET techniques (Edwards *et al.,* 1996; Macklon *et al.,* 2006). Successful implantation rates depend on the type of ovarian stimulation used (Sterzik et al., 1988) where doses of gonadotropins used are adjusted according to individual ovarian response (Macklon *et al.,* 2006). Even so, use of exogenous hormones in these techniques is implicated in the low implantation rates. In addition, the low percentage of successful pregnancies after IVF and ET, commonly result in multiple pregnancies. This creates another set of problems, often causing

maternal and neonatal complications, as well as increased cost in delivery and neonatal care (Edwards *et al*., 1996; Krussel *et al.,* 2003).

1.2 Effect of hyperstimulation on the uterus

As medico-legal and ethical problems restrict researchers from carrying out research on the human uterus, a rodent model is most often used for experimental studies. The previous studies in rodents showed that the use of exogenous hormones, superimposed on the normal hormonal milieu, induces a rise in oestrogen and progesterone levels and affects the progesterone:oestradiol ratio (Gidley-Baird *et. al.,* 1986; Kramer *et al.,* 1990) during the peri-implantation period. Since an increase in oestrogen levels alters gross morphological and histological appearance of the uterus (Gidley-Baird *et al.,* 1986; Kramer *et al.,* 1990; Stein *et al.,* 1993; Simon *et al.,* 1995.), as well as the expression of implantation related genes (Ma *et al.,* 2003), events in normal pregnancy need to be understood in order to explain changes that may occur during application of IVF techniques.

In mammals, implantation is a dynamic process where the blastocyst comes into close physical and physiological contact with the receptive uterus (Enders and Schlafke, 1967; Tranguch *et al.,* 2005). Successful attachment and implantation of the blastocyst is governed by synchrony between the receptive uterus and the blastocyst and is related to exquisite hormonal control. During the oestrous cycle in mammals, the uterus is in the refractory stage for most of the time (Psychoyos, 1973). Under the influence of the steroid hormones, oestrogen and progesterone, the uterus undergoes a series of changes that lead to its receptivity. The receptive stage, also known as the ”window” of

implantation, is a limited period of time during which the uterus supports blastocyst attachment and implantation (Psychoyos, 1973; Paria *et al.,* 1993; Ma *et al.,* 2003). It has also been shown that the duration of the "window" of uterine receptivity is dependent on oestrogen levels in mice (Ma *et al.,* 2003). Lower oestrogen levels maintain the "window" of implantation open for a longer period of time, while it closes rapidly at higher levels (Ma *et al.,* 2003). In mice, the uterus becomes receptive on day 4 of pregnancy and proceeds to a refractory state on day 5, which lasts for about 18h (Psychoyos, 1973), while in the rat, the uterus becomes receptive on day 5 and becomes non-receptive to blastocyst implantation by day 6 (Paria *et al.,* 1993). In humans the uterus is receptive between days 19-24 of the menstrual cycle. While oestrogen appears to influence the *duration* of uterine receptivity, the ratio between progesterone and oestrogen plays an important role in providing the normal morphology for implantation during this period.

At the onset of the receptive stage, the blastocysts are in close contact (apposition) with the luminal epithelium (Chen *et al.,* 2000). In rodents, the blastocyst is positioned at the antimesometrial side of the uterus with the embryonic pole of the blastocyst facing the mesometrial side (Enders and Schlafke, 1967). On day 5 of pregnancy in the rat, it is still possible to flush the blastocysts from the uterus. The pontamine blue reaction, which is predicated on vascular permeability, is usually not demonstrable at this stage (Enders and Schlafke, 1967).

In order for the blastocyst to implant, the endometrium must be in a receptive state to receive it. The receptive state is characterised by particular morphological features. However, the superphysiological oestrogen and progesterone levels recorded in hyperstimulated animals and humans, cause detrimental changes to the uterine morphology and affect uterine receptivity (Gidley-Baird *et. al.,* 1986; Testart 1987; Kramer *et al.,* 1990; Stein *et. al.,* 1993; Simon *et. al.,* 1995).

The attachment reaction occurs between the plasma membrane of the uterine epithelial cells and the trophoblast of the blastocyst (Murphy, 1992) under synchronized interaction of oestrogen and progesterone (Ljungkvist, 1972). In the normal pregnant rat uterus on day 5 of pregnancy, luminal epithelial cells are simple columnar and their apical borders are covered with numerous short microvilli (Enders and Schlafke, 1967). These cells contain large and numerous lipid droplets which are basally situated. The presence of lipid droplets in the luminal epithelial cells displaces the nucleus from the base of the cell to a central position (Enders and Schlafke, 1967). These features of the receptive epithelium are altered with raised oestrogen levels in hyperstimulated animals. In rats hyperstimulated with FSH and hCG, the luminal epithelial cells are tall columnar and covered with long microvilli (Kramer *et al.,* 1990). Lipid droplets are absent in these cells and the nucleus is basally situated. Treatment with oestradiol only causes hypertrophy and hyperplasia of the luminal epithelium, appearance of long apical microvilli and the reduction of lipid droplets within these cells in the rat uterus (Ljunkvist, 1972; Williams and Rogers, 1980).

Observations in the pseudopregnant rat showed replacement of microvilli with irregular projections of the cytoplasm eighteen hours after oestrogen treatment (Ljunkvist, 1972). These large apical cytoplasmic protrusions, physically overlying the rest of the uterine surface are also known as pinopodes (Psychoyos, 1973; Psychoyos and Martel, 1985; Klentzeris 1997; Carson *et al*., 2000) or uterodomes in the human uterus (Adams *et al.,* 2004), and are progesterone dependent, while, oestrogen inhibits their expression (Martel *et al.,* 1991). The function of pinopodes is not fully understood. However, it appears that pinopodes are involved in the reduction of the intraluminal fluid, allowing the blastocyst to come into close contact with the uterine epithelium (Psychoyos and Martel 1985). Bagot *et al.* (2001) stated that the pinopodes are probably a more sensitive marker of the window of implantation than any other histological feature of the luminal epithelial cells or detection of any molecular marker currently available. Pinopodes are observed on the surface epithelium of the human endometrium on days 19-21 of the menstrual cycle (Nikas *et al.,* 1995) and in mice at day 5 of pregnancy (Psychoyos, 1973). However, in controlled ovarian hyperstimulation cycles, uterodomes are present on days 19-20, suggesting premature uterine receptivity (Adams *et al.,* 2004).

Apposition of the blastocyst to the luminal epithelium of the uterus is followed by the attachment reaction. Carbohydrates, integrins and other cell-surface molecules contribute to the adhesion of the blastocyst at the implantation site (Murphy, 1995; Paria *et al.,* 2002). During the peri-implantation period in normal pregnant rats, uterine luminal epithelial cells demonstrate an increase in at least four different carbohydrate molecules (Murphy and Turner, 1991). One of these carbohydrates, the trisaccharides of

glucosamine are absent on day one of pregnancy, but increase significantly at the time of implantation (Murphy and Turner, 1991). Production of glucosamine trisaccharides in the glycocalyx of surface epithelial endometrial cells is inhibited in hyperstimulated pregnant rats affecting receptivity of the endometrium for blastocyst implantation (Kramer *et al.,* 1994; Peverini and Kramer, 1995). In addition, studies in hyperstimulated rodents showed that the number of implanted embryos was highly affected. Although embryos were present in the dilated lumina of the uterine horns at 5.5 and 6.5 days of hyperstimulated rats, it appeared that aberrant distribution of the adhesion molecules suppressed their attachment to the luminal epithelium and embryos were found lying freely in the lumen of the uterus (Kramer, 1997).

After the attachment reaction, the luminal epithelial cells of the uterus undergo apoptosis (programmed cell death), which facilitates the invasion of the maternal endometrium by the blastocyst (Parr *et al.,* 1987; Tsujii and Du Bois, 1995; Carson *et al.,* 2000; Tassell *et al.,* 2000; Zhang and Paria, 2006). At the same time, extensive proliferation and differentiation of the stromal cells form decidua (Enders and Schlafke, 1967; Kramer *et al.,* 1990; Kramer, 1997; Carson *et al.,* 2000). Under the influence of exogenous hormones, decidualisation is affected in rats and results in the stromal cells remaining flat and fibroblastic (Kramer *et al.,* 1990; Kramer, 1997).

1.3 Effect of exogenous hormones on embryo quality

In addition to endometrial receptivity, embryo quality is also important for successful implantation. It has been suggested that hyperstimulation causes a decreased

developmental ability of the embryos as a result of an increased proportion of chromosomal abnormalities in these embryos (Ertzeid and Storeng, 2001). Embryo donation studies in mice showed significantly lower implantation rates when the embryos from superovulated donors were transferred into control recipients, compared to that of control donors (Ertzeid and Storeng, 2001). It has also been reported that hyperstimulation of mice causes a delay in the development of embryos *in vitro* (Ertzeid and Storeng, 2001). Similarly in the human uterus, use of exogenous hormones causes a rise in oestradiol levels and affects embryo quality (Valbuena *et al.,* 2001). Existing data concerning research on human embryos, suggest that high oestrogen levels have a toxic effect on the cleavage stage of embryos, as well as affecting their adhesion *in vitro* (Valbuena *et al.,* 2001).

1.4 The expression of implantation-related genes

Many molecules and genes are important for implantation. However, the sequence of gene expression of these molecules during the period of implantation and their interaction and relationship is still not well understood (Paria *et al.,* 2002). To date, the best understood signalling sequence in implantation of mice embryos has been established with the target deletion of Hoxa-10, leukaemia inhibitory factor (LIF) and cyclooxygenase2 (COX2) (Paria *et al.,* 2002).

Due to epithelial-mesenchymal interactions between the uterus and the embryo during implantation, many classes of developmental genes are involved in the molecular cross-talk at the time of implantation (Paria *et al.,* 2002). Some of these genes are those

encoding for fibroblast growth factor, bone morphogenetic proteins, Indian hedgehog as well as the Homeobox of transcription factors. Homeobox (Hox) genes are vital during embryogenesis of the genitourinary tract, and particularly Hox10 gene expression is required for endometrial receptivity and embryo implantation (Taylor *et al.,* 1997; Bagot *et al.,* 2001). It has been previously reported that mice with a Hox10 gene disruption produce viable embryos, but these embryos fail to implant into the Hox 10-deficient mouse uterus (Satokata *et al.,* 1995). However, if the embryos of Hox10-deficient mice are transferred into the uterus of wild-type mice, implantation occurs (Satokata *et al.,* 1995). Studies of the mouse and human uterus confirmed that maternal Hox10 expression is required for uterine receptivity (Satokata *et al.,* 1995; Taylor *et al.,* 1997).

In the cytokine family, one of the essential cytokines for preparation of the uterus for implantation is leukaemia inhibitory factor (LIF). In mice, LIF is expressed in the uterine glands on day 4 of pregnancy in response to nidatory oestrogen, indicating its involvement in the preparation of the uterus for implantation (Song *et al.,* 2000). LIF is also expressed in the stromal cells at the site of blastocyst implantation during the attachment reaction on day 5 of pregnancy (Song *et al.,* 2000). Mutation of the LIF gene in mice results in failure of implantation (Sharkey, 1998; Song *et al.,* 2000; Dey *et al.,* 2004). Mice with the target disruption of the LIF gene show aberrant expression of some of the EGF family of growth factors at the time of implantation, suggesting the importance of synergistic expression of these factors (Song *et al.,* 2000). While LIF is particularly important for the attachment reaction, another member of the cytokine family, interleukin-11 (IL-11) is primarily involved in decidualization (Paria *et al.,* 2002).

Numerous growth factors are also important signalling molecules at the site of implantation. The epidermal growth factor (EGF) family of growth factors includes EGF itself, transforming growth factor-α (TGF- α), heparin binding-EGF (HB-EGF), amphiregulin (Ar), β-cellulin (BTC) epiregulin (Er), heregulins/neu-differentiating factors (NDFs)and cripto (Carson *et al.,* 2000). These factors are expressed in a spaciotemporal manner suggesting their involvement as local mediators at the time of implantation. TGF- α is expressed in the mouse uterus at the time of implantation. However, TGF- α mutant mice are fertile, suggesting that the deficiency might be compensated for by other growth factors (Carson *et al.,* 2000). Heparin binding EGF-like growth factor is the earliest known marker of implantation in mice (Paria *et al.,* 2002). The expression of HB-EGF is evident in the luminal epithelial cells surrounding the blastocyst, suggesting that the signals from the blastocyst initiate expression of HB-EGF. In addition, experiments *in vitro* showed that HB-EGF stimulates blastocyst proliferation, zona hatching, trophoblast outgrowth and phosphorylation of the receptor in the mouse blastocyst (Carson *et al.,* 2000). Soluble HB-EGF is used to improve the development of *in vitro*-fertilized human embryos (Martin *et al.,* 1998)

1.5 Vascular permeability and angiogenesis

Two major events which occur at the site of implantation are vascular permeability and angiogenesis. Vascular permeability and stromal oedema in the uterus of rodents are apparent during the attachment reaction and can be demonstrated by an intravenous injection of a macromolecular blue dye, pontamine blue, resulting in the formation of blue segmental bands along the length of the uterine horns (Psychoyos, 1973). Vascular

permeability at the site of implantation occurs as a result of the fenestrations of endometrial thin-walled vessels (Kramer *et al.,* 1993).

Vascular permeability occurs as a response to the angiogenic stimuli (Hyder and Stancel, 1999) in order to allow fibrinogen and other plasma proteins to infiltrate the surrounding tissue (Dvorak *et al.,* 1995). This results in the formation of extracellular fibrin gel which is a suitable substrate for endothelial and tumour cell growth (Dvorak *et al.,* 1995).

Cyclical changes in the ovaries and uterus during the menstrual cycle and the process of placentation during pregnancy require increased blood flow, which is maintained by the formation of new blood vessels. Angiogenesis is a complex process where new blood vessels arise from the pre-existing vasculature (Perrot-Applanat *et al.,* 2000; Robinson and Stringer, 2001). Angiogenesis is achieved by proliferation, migration and tissue infiltration of capillary endothelial cells and localised breakdown of the extracellular matrix (Hyder and Stancel, 1999). As a result of these events, new capillaries are formed (Dvorak *et al.,* 1995; Hyder and Stancel, 1999; Robinson and Stringer, 2001). During angiogenesis new capillaries originate from the smaller blood vessels, capillaries and venules (Hyder and Stancel, 1999). New blood vessels also develop by the process of vasculogenesis, from hemangioblasts (Coffin and Poole, 1988).

Angiogenesis is important in embryogenesis and tissue development. In adults, angiogenesis occurs primarily in the female reproductive tract, at the site of wound healing and bone remodelling (Robinson and Stringer, 2001). Apart from the normal physiological conditions in adults, angiogenesis is implicated in several pathological

conditions, such as diabetic retinopathy, rheumatoid arthritis and development of tumours (Folkman, 1990; Ferrara, 1996; Kim *et al.,* 1996).

Vascular permeability and angiogenesis in the female reproductive tract are regulated in different ways by oestrogen and progesterone *in vivo* (Matsumoto *et al*., 2002). Oestrogen induces uterine vascular permeability and inhibits angiogenesis, while progesterone stimulates angiogenesis and does not affect vascular permeability (Matsumoto *et al*., 2002). Numerous vasoactive agents such as histamine, platelet-activating factor, prostaglandins, fibroblast growth factor (FGF) and vascular endothelial growth factor (VEGF) are important for vascular permeability at the site of implantation (Hyder & Stancel, 1999; Paria *et al.,* 2002).

1.5.1 Vascular endothelial growth factor (VEGF)

The first discovery of a permeability factor secreted by hepatocarcinoma cell lines that induced dye leakage into the skin of the guinea pig was described by Senger *et al.* (1983). This permeability factor was later cloned and named vascular endothelial growth factor (VEGF) for its mitogenic effect on endothelium in culture (Leung *et al.,* 1989). VEGF is a glycoprotein, which exists in multiple isoforms that work primarily via two transmembrane tyrosine kinase receptors: VEGFR-1 encoded by *Flt-1*, and VEGFR-2 encoded by *KDR Flk-1* (Matsumoto *et al.,* 2002). Both receptors are exclusively expressed on endothelial cells. It appears that VEGF does not increase mitogenesis in any other cell type (Leung *et al.,* 1983; Roberts and Palade, 1995; Ferrara, 1996). The role of VEGF as a potent permeability factor has been studied by Roberts and Palade (1995). It has been shown that application of VEGF induces fenestrations of small venules and

capillaries in the cremaster muscle, which does not normally have a fenestrated endothelium in its vascular bed (Roberts and Palade, 1995).

VEGF-A is a member of a larger VEGF family that includes VEGF-B, VEGF-C, VEGF-D, VEGF-E and placental growth factor (PlGF) (Bates and Harper, 2003). VEGF-B is mainly distributed in heart and skeletal muscle, PlGF in the placenta, while VEGF-C and VEGF-D are related to lymphogenesis and maintenance of lymphatic vessels (Robinson and Stringer, 2001).

VEGF-A exists in several isoforms (Fig. 1), derived from the single gene through alternative gene mRNA spicing (Robinson and Stringer, 2001; Krussel *et al.,* 2003). VEGF protein in humans consists of 121, 145, 165, 189 and 206 amino acids ($VEGF_{121}$, $VEGF_{145}$, $VEGF_{165}$, $VEGF_{189}$, and $VEGF_{206}$).

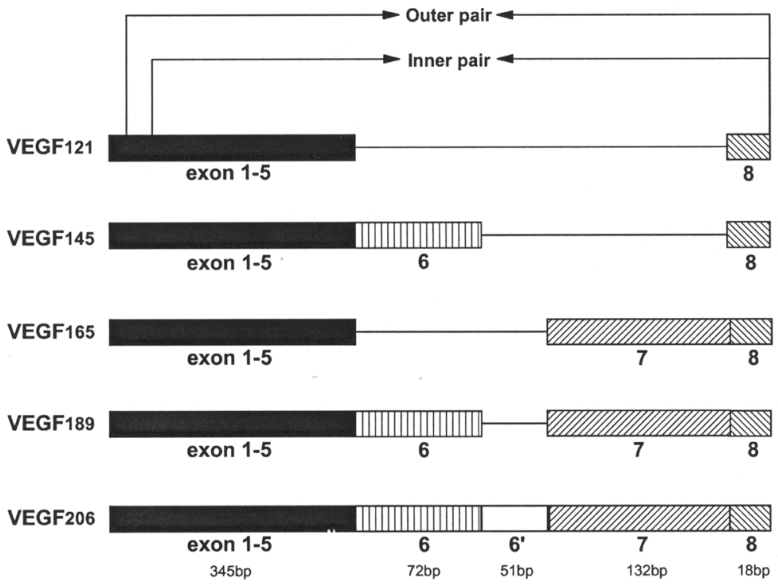

Fig. 1: Five different VEGF isoforms (Krussel *et al.,* 2003)

In rodents, different isoforms of VEGF protein contain one amino acid less than in humans. VEGF $_{121}$ and VEGF $_{165}$ are predominant isoforms in humans, while VEGF $_{120}$ and VEGF $_{164}$ are more predominant in mice (Ma *et al.,* 2001). All VEGF isoforms contain 8 exons of which 1-5 and exon 8 are constituents for all isoforms (Fig. 1) (Krussel *et al.,* 2003). Different isoforms are dependant on various combinations in additions of exons 6 and 7 (Bates and Harper, 2003). VEGF isoforms exist in secreted forms (VEGF $_{121, 145, 165}$) or they are bound to the cell surface (VEGF $_{189, 206}$) (Houck *et al.,* 1991; Bates and Harper, 2003). All secreted VEGF isoforms bind to transmembranous tyrosine kinase receptors Flt-1 and KDR (Fig. 2).

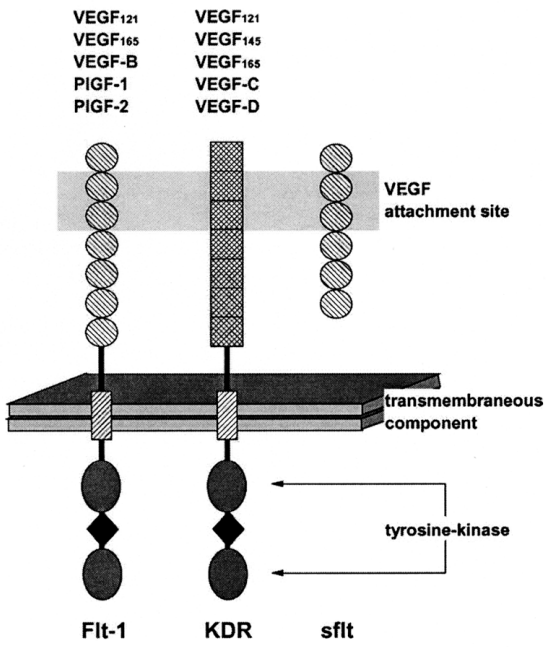

Fig. 2: Schematic illustration of VEGF receptors and their interaction with different growth factors (Krussel *et al.,* 2003)

Although VEGF has a greater affinity for binding to Flt-1 than KDR, it appears that its biological response is facilitated through the binding of VEGF to KDR rather than Flt-1 (Waltenberger *et al.,* 1994). However, both receptors and their interactions are required in order to induce VEGF biological responses (Ferrara, 1996; Ferrara and Davis-Smith, 1997). VEGF binding to these receptors causes phosphorylation and signal transduction that causes vascular permeability and angiogenesis (Krussel *et al.,* 2003; Bates and Harper, 2003). Waltenberger *et al.* (1994) reported that KDR mediates chemotaxis, mitogenesis and cytoskeletal reorganization of endothelial cells.

Experiments with knockout mice, have shown that targeted disruption of genes in the VEGF system, cause intrauterine death of embryos resulting in an inability of these animals to produce live offsprings (Fong *et al.,* 1995; Carmeliet *et al.,* 1996). Carmeliet *et al.* (1996) reported abnormal blood vessel formation in heterozygous and homozygous VEGF-deficient embryos resulted in death of the embryos at mid-gestation. Mice embryos with a VEGFR-1 (Flk-1) gene disruption die on embryonic day 8.5 as a result of aberrant blood vessels formation (Fong *et al.,* 1995). Although endothelial cells develop in these animals, their rearrangement into small vessels does not occur. KDR expression on the surface of hemangioblasts contributes to differentiation of these cells into haematopoietic and endothelial cells. Embryos with KDR gene disruption are not able to produce mature haematopoietic cells and endothelial cells (Krussel *et al.,* 2003).

Other receptors are also expressed on the endothelial cells and specifically bind to VEGF. VEGFR-3 is found predominantly on the lymphatic endothelial cells (Bates and Harper,

2003). Recently, neuropilin-1 (NRP1) has been identified as a neuronal receptor in developing nervous tissue. However, it has been shown that the VEGF $_{165}$ isoform, (one of the most predominant isoforms in the human uterus) binds to the NRP1 receptor (Day *et al.,* 2004). Studies on NRP1 knockout mouse showed cardiovascular abnormalities which caused death of the embryos on days 10.5-12.5 *in utero* (Kitsukawa *et al.,* 1997).

It has also been reported that another angiogenic factor, angiopoietin (angiopoietin-1 and angiopoietin-2) coordinates the expression of VEGF. Angiopoietin-1 upregulates and coordinates VEGF effects on vascular permeability and angiogenesis, while angiopoietin-2 acts as an antagonist by suppressing angiogenesis (Matsumoto *et al.,* 2002). However, before and during the attachment reaction in mice, vascular permeability and angiogenesis are predominantly regulated by VEGF expression (Matsumoto *et al.,* 2002). Studies in the human endometrium suggested that amongst several endometrial growth factors, only VEGF stimulates growth of the capillaries in the decidual endometrium (Zhang *et al.,* 1998; Demir *et al.,* 2004). Angiopoietins together with VEGF are important in these processes during decidualization following implantation (Matsumoto *et al.,* 2002).

Oestrogen and progesterone induce VEGF expression in the rodent uterus (Hyder and Stancel, 1999). Oestrogen and oestrogen agonists such tamoxifen, induce expression of VEGF in the rat uterus, and it appears that VEGF is oestrogen-receptor mediated (Hyder *et al.,* 1996). Similarly, other studies suggest that progesterone also induces VEGF expression in the rodent uterus (Cullinan-Bove and Koos, 1993).

1.5.2 Cyclooxygenase2 (COX2)

Cyclooxygenase1 (COX1) and COX2 are the rate-limiting enzymes that convert arachidonic acid into prostaglandins (PGs). Arachidonic acid is converted into prostaglandin H_2 (PGH_2), which is the precursor for a variety of prostaglandins (PGs) important in normal physiological and pathological conditions (Markenson, 1999). The principal bioactive PG metabolites are: prostaglandin E_2 ($PG E_2$), $PGF_{2\alpha}$, PGD_2, PGI_2 and TXA_2 (Breyer *et al.,* 2000). In rodents, prostaglandins are implicated in the events in early pregnancy (Kennedy, 1977; Kennedy and Lukash, 1982; Ni *et al.,* 2002; Ni *et al.,* 2003). Amongst biologically active PGs, PGE_2 and PGI_2 are the most predominant metabolites involved in the events in the rodent uterus in early pregnancy (Lim *et al.,* 1999). PGs mediate diverse events in various tissues by binding to a set of cell surface receptors (Lim and Day, 1997). The surface receptors for PGE_2, one of the predominant PGs in the uterus, are Ep_1, Ep_2, Ep_3 and EP_4 (Yang *et al.,* 1997). Genes of these receptors are expressed in a spatio-temporal manner, suggesting PGE_2's role in preparation of the uterus for implantation as well as decidualization (Lim and Day, 1997).

It has been previously suggested that an increase in PGs and expression of COX1 prior to implantation, mediates uterine oedema and luminal closure which are important for the attachment reaction in rodents (Kennedy, 1977; Chakraborty *et al.,* 1996). Chakraborty *et al.* (1996) stated that PGs produced at the site of implantation by COX2 are important for localized increased vascular permeability and the attachment reaction, and are involved in angiogenesis for the establishment of the placenta. In addition, it has been shown that PG levels are higher in the endometrium at implantation sites compared to the

inter-implantation sites in many species (Bany and Kennedy, 1997) supporting the importance of their involvement in implantation.

The two isoforms, COX1 and COX2 are encoded by two separate genes, Ptgs1 and Ptgs2 (Smith *et al.,* 2000). The expression of COX1 is more constant as it is important in regulating cell function, while COX2 expression is up-regulated in response to various stimuli (Das *et al.,* 1999). In mice, COX1 is expressed in the luminal epithelial cells and glandular cells on the morning of day 4 of pregnancy but is not detectable in these cells at the time of the attachment reaction (Dey *et al.,* 2004). COX2 is expressed in the luminal epithelial cells and subepithelial stromal cells at the site of implantation on day 5 of pregnancy in mice (Dey *et al.,* 2004).

Experiments with COX1-deficient mice show that the females are fertile with a specific parturition defect, while COX2-deficient females are infertile and show abnormalities in ovulation, fertilization, implantation and decidualization (Matsumoto *et al.,* 2001). Cheng and Stewart (2003) recently reported that wild-type blastocysts, following transfer into COX2 deficient mice, implant and develop successfully to term. These animals however, show a reduction in decidual growth when compared to the wild-type mice, but are restored to their normal growth rate after 24-36h. These results suggest that COX2 is required for the induction of other factors mediating angiogenesis (Cheng and Stewart, 2003). Specifically, VEGF is important for the process of vascular permeability and angiogenesis in the uterus, both in rodents and humans. Thus, it is possible that during

the initial stages of decidualization, COX2 is required for induction of VEGF expression (Cheng and Stewart, 2003).

Since exogenous hormones cause an increase in oestrogen levels and alter the progesterone:oestradiol ratio, which subsequently cause unsatisfactory changes in the uterine morphology and aberrant expression of implantation related genes, it would be of interest to see whether hyperstimulation affects COX2 and VEGF during the peri-implantation and thus the receptivity of the uterus for blastocyst implantation.

1.6 AIM OF THE STUDY

The aim of this study was:

1. To investigate the expression of VEGF and COX2 in the normal rat uterus during the peri-implantation period
2. To determine the effect of hyperstimulation on the expression of VEGF and COX2
3. To provide a better understanding of the use of hyperstimulation on these two important mediators of implantation during early pregnancy.

2.0 MATERIALS AND METHODS

2.1 Animals

Animal ethics clearance for this experiment was granted by the Animal Ethics Committee, University of the Witwatersrand (AESC NO: 2004/100/4). Adult, virgin female Sprague-Dawley rats (n=36) and two male rats of proven fertility were used for the experiment. Animals were obtained and housed in the Animal Unit of the University of the Witwatersrand. The animals were housed in an environment with a controlled temperature of 22°C and a 12h light and 12h darkness cycles. The animals were fed with rat cubes and water *ad libitum*.

Vaginal smears of the female rats were taken daily until a regular 4-day oestrous cycle had been established. The smears were fixed in alcohol and stained using Shorr's stain (Appendix 1). Stages of the oestrous cycle were assessed according to Kent and Smith (1945) (Appendix 2). The phases of the oestrous cycle are: oestrus, metoestrus, dioestrus and pro-oestrus. Animals showing at least three consecutive regular 4-day cycles were used for the experiment.

The animals were divided into two groups:

Group 1 – Experimental (hyperstimulated):

Female rats (n=18) received an intra-peritoneal injection of 20i.u. of follicle stimulating hormone (FSH) (Folligon, Intervet, Johannesburg) at mid-day of dioestrus followed by an

intraperitoneal injection of 20i.u. of human chorionic gonadotropin (hCG) (Chorulon, Intervet, Johannesburg) 24h later, at late dioestrus (Stein *et al.,* 1993)

Group 2 – Control (normal pregnant):

Female rats (n=18) received an intraperitoneal injection of sterile saline at the same stage of the oestrous cycle as the hyperstimulated animals received exogenous hormones. Control and experimental females were placed with a fertile male on the afternoon of pro-oestrous to mate.

On the morning following mating, female rats were examined to assess the presence of a mucous plug. Vaginal smears were examined for the presence of spermatozoa for confirmation of successful copulation. The day following mating was taken as day 0.5 of pregnancy following the work of Kramer *et al.* (1993). The timing of pregnancy in the present study differs to other studies where the morning after mating was taken as a day 1 of pregnancy (Enders and Schlafke, 1967; Psychoyos, 1973; Lim *et al.,* 1997). The reason for this is that the rats mate in the early evening and the females were killed for the experiment in the early morning of the following day of pregnancy. This corresponds to approximately 12 hours after mating or 0.5 days of pregnancy. Thus, in the other relevant published studies day 1 will correspond to day 0.5 in the present study. Vaginal smears were taken daily until the day of sacrifice to confirm the maintenance of pregnancy.

Animals were anaesthetized with 0.6 ml of Chanazen (Centaur Labs, Johannesburg, SA) and 0.24 ml of Ketamine (Centaur Labs, Johannesburg, SA) on days 4.5, 5.5 and 6.5 of

pregnancy (n=6 control and n=6 hyperstimulated per group, per day of sacrifice). Blood samples from heart punctures of these animals were collected and placed in sterile heparin tubes. The blood was immediately centrifuged and the plasma was stored at -70°C until assayed for oestradiol and progesterone levels by ELISA (enzyme-linked-immunosorbent assay).

An incision through the anterior abdominal wall was carried out in order to view the inferior vena cava, ovaries and uterine horns. A 1% pontamine blue solution (a high molecular weight dye) was injected into the inferior vena cava and was allowed to circulate in the anesthetized animal for 10-15 minutes (Psychoyos, 1973). Due to vascular permeability and leakage of the pontamine blue into the surrounding tissue, blue bands were noted at the site of the implanting blastocysts (Psychoyos, 1973). The uterine horns of the animals were then removed, dissected from the surrounding tissue and washed with phosphate buffered saline pH 7.6 (PBS) (Appendix 3) to remove blood. Regions of the uterine horns showing blue bands (implantation sites) were separated from the non-implantation sites by sharp dissection for total protein extraction and Western blot analysis. Uterine horns of animals not showing blue bands after pontamine blue injections were sectioned in pieces of approximately 5-10 mm in length from different regions of the uterine horns.

Dissected pieces of tissue were fixed in 10% neutral buffered formalin (Appendix 4). An automatic tissue processor (Shandon Citadel 1000) was used to dehydrate tissue through graded alcohols and chloroform followed by embedding the tissue in paraffin wax.

Tissue blocks were utilized for routine histology and immunohistochemical localisation of specific antigens. Following removal of the uterine horns the animals were killed by exsanguination.

2.2 Progesterone and oestradiol ELISA

Progesterone and oestradiol were quantitatively determined in the plasma of these animals by using an Estradiol (E2) Enzyme immunoassay test kit (Linear Chemicals, Spain) and a Progesterone enzyme immunoassay test kit (Linear Chemicals, Spain) for raw data see Appendix 5). ELISA (enzyme-linked-immunosorbent assay) is based on the competition principle in the microtitre plate. An unknown amount of antigen (progesterone or oestradiol) present in the sample and a fixed amount of enzyme-labelled antigen compete for the constant amount of rabbit anti-progesterone or anti-oestradiol. Each blood sample obtained from the control and experimental animals was assayed in duplicate. According to the manufacturer's recommendation 25 µl of standards, specimens and controls were dispensed into appropriate wells on the microtitre plate. Progesterone or oestradiol-HRP conjugate reagent (100 µl) and 50 µl of rabbit anti-progesterone or rabbit anti-oestadiol reagent were added to each well and mixed thoroughly. Incubation was carried out for 90 minutes at room temperature. After incubation, the wells were washed with distilled water to stop the competition reaction. After the substrate solution was added and incubated at room temperature for 20 minutes the reaction was stopped by adding 100 µl of stop solution to each well. The plate was gently mixed to allow a change from a blue colour to yellow. The concentration of antigen was inversely proportional to the optical density measured (read at 450 nm). The

standard curve was obtained by plotting the concentration of the standard versus the absorbance and was used to calculate the unknown sample concentration.

2.3 Histology

Sections 4µm thick, prepared from the paraffin wax blocks were placed on silane (3 Aminopropyl triethoxy-silane, obtained from Sigma-Aldrich Co, USA) dipped glass slides (Appendix 6). Every sixth section of each block was deparaffinised in xylene and rehydrated in a series of graded alcohols. Sections were than stained with haematoxylin and eosin (Appendix 7) in order to investigate the morphology of the uteri at different stages of pregnancy. The haematoxylin and eosin stain is a widely used histological stain. This staining method, demonstrates a large number of different tissue structures (Bancroft and Gamble, 2002). The haematoxylin component stains cell nuclei blue-black (basophilic), whilst the eosin stains cell cytoplasm and connective tissue fibres in shades of pink, orange and red (eosinophilic) (Bancroft and Gamble, 2002).

2.4 Immunohistochemistry

Formalin-fixed, paraffin embedded tissues were sectioned at 4µm. Fixation in formalin, as well as paraffin embedding of tissue is known to allow substantial changes in the antigen epitopes (the structural part of an antigen which reacts with an antibody). These changes in the antigen epitopes can lead to complete loss of immunoreactivity by the antigen or the "masking" of the antigen (Boenisch, 2001). Restoration of immunoreactivity or antigen unmasking (antigen retrieval) can be achieved by application of heat for varying lengths of time to the sections in an aqueous medium

(Boenisch, 2001). In the present study, antigen retrieval of the tissue was carried out by microwaving the sections in citrate buffer at pH6 (Appendix 8) twice, for 5 minutes. Sections were than incubated with 3% hydrogen peroxide for ten minutes at room temperature in order to block endogenous peroxidase activity. The immunostaining procedures were different for the two antibodies utilized following incubation with hydrogen peroxide, and are explained separately in the text below.

2.4.1 VEGF immunostaining

Sections were incubated with 1% rabbit serum in TRIS-buffered saline pH 7.6 (Appendix 9) for 10 minutes at room temperature for blocking non-specific binding. Primary mouse monoclonal VEGF antibody (sc-7269) was obtained from Santa Cruz Biotechnology. A series of dilutions were carried out to determine the optimal suitable concentration of the antibody. Sections were then incubated with the primary (VEGF) antibody at a dilution of 1:100 overnight at 4°C. After washing the sections twice for 5 minutes in Tris-buffered saline (TBS), a secondary rabbit anti-mouse antibody (Dako), was diluted in TBS (1:300) and then applied for 30 minutes at room temperature. Sections were washed twice for 5 minutes and a streptavidin horseradish peroxidase complex (Dako, Denmark) at a dilution of 1:300 was applied for 30 min at room temperature. The positive reaction was identified by the chromagen, diaminobenzidine (DAB) (Dako, Denmark). After incubation with DAB for 5 minutes, sections were washed in tap water for 5 minutes. Sections were then counterstained in haematoxylin for 20 seconds and dehydrated in graded alcohols and xylene, before coverslipping in entellan.

2.4.2 COX2 immunostaining

A primary goat polyclonal COX2 antibody (sc-1747; Santa Cruz Biotechnology USA) and Immunostaining kit (sc-2053 Immuno Cruz Staining System) was used for COX2 immunoassaying.

Sections (4µm in thickness) were incubated for 20 minutes at room temperature in 1-2 drops of serum block provided in the Immunostaining kit, followed by removal of the excess serum block. Primary goat polyclonal COX2 antibody at a dilution of 1:100 was applied to the sections for two hours at room temperature. After washing in TBS with 0.05% Tween 20 three times for 5 minutes, secondary biotinulated antibody (provided in the Immunosraining kit) was applied for 30 minutes at room temperature. Sections were washed three times for 5 minutes in TRIS-buffered saline with 0.05% Tween 20 and incubated with streptavidin HRP complex for 30 minutes at room temperature. Sections were washed 3 times in TBS with 0.05% Tween 20, and than incubated with DAB for 5 minutes. Sections were than washed in tap water for 5 minutes, counterstained in haematoxylin for 20 seconds and dehydrated in graded alcohols and xylane, before coverslipping in entellan. The sections were than analyzed for VEGF and COX2 immunolocalization by light microscopy using the Zeiss Axioscope microscope (Axioscope 2, MOT, Carl Zeiss, Germany). The images were captured by digital camera (Sony 3 CCD).

2.4.3 Controls for immunohistochemistry

Negative controls were prepared using tissue sections adjacent to the sections showing immunolocalization of antibodies. In the first instance the primary antibodies were replaced with TBS and in the second negative control, the secondary antibodies were replaced with TBS.

An absorption control (pre-absorbtion of the respective antibody with its antigen, and substituted for the primary antibody) was not carried out as the VEGF and COX2 antigens were not available commercially.

Formalin-fixed paraffin embedded breast carcinoma tissue was prepared by the same procedure as mentioned above and used as a positive control for VEGF immunostaining. Human lung carcinoma tissue was used as a positive control for COX2 immunolocalization. Human Ethics Committee approval for the use of these tissues was granted by the Human Ethics Research Committee of the University of the Witwatersrand (M050521).

2.5 Protein extraction

Dissected pieces of uterine tissue approximately 5-10 mm in length were further sliced with sterile scissors and placed in a clean homogenizer with 5 ml of homogenising buffer (Appendix 10) with DTT stock and protease inhibitor cocktail stock (Sigma-Aldrich Co, USA). Homogenizing was carried out slowly, letting in as little air as possible, to prevent foaming. The homogenized tissue was centrifuged at 12 000 rpm for 20 minutes at 4˚C,

followed by the removal of supernatant. Supernatant was aliquoted in 200µl aliquots and stored at -70˚C until used.

2.6 Protein Concentration (Lowry protein assay)

Total protein determination from the homogenized tissue was carried out by the Lowry protein assay. The assay is based on complex formation of the protein with copper. Adding folin phenol reagent results in binding to the protein and changes the colour from yellow to blue.

Bovine serum albumin (BSA) was used as the standard. A working solution was made up of 2000 µg BSA in 1000µl of PBS pH 7.4. Serial dilutions of two folds were carried out in triplicate up to a dilution of 1:31.25. Extracted protein samples of control and hyperstimulated animals were diluted in PBS (1:20) prior to testing. ELISA microtiter plates were used for the test. In respective wells of the microtiter plate, 50 µl of the diluted protein extract sample and 200 µl of reagent A (Appendix 11) were added and incubated on a shaker for 10 minutes at room temperature. Reagent B (50 µl) (Appendix 12) was added followed by incubation for 30 minutes on a shaker. Labsystems Multiskan Ascent (Amersham Pharmacia Biotech, Buckinghamshire, UK) a microtiter well reader was used to read absorbance at 690 nm. A standard curve was created by plotting the absorbance values of the BSA standards against their concentrations (Fig. 3). The protein concentration in the sample was than calculated automatically of the graph multiplied by the dilution factor (for raw data see Appendix 13).

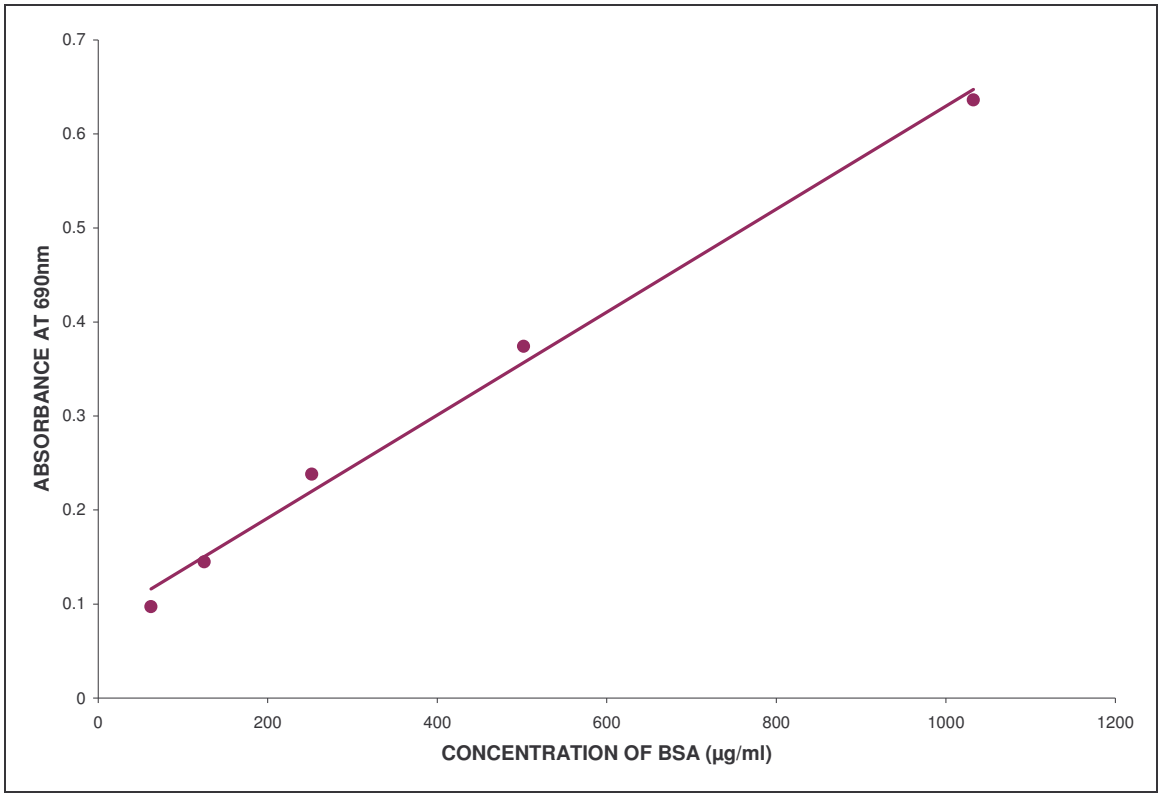

Fig. 3: **Standard curve for Bovine Serum Albumin (BSA) at known concentrations in µg/ml at an absorbance of 690 nm**

2.7 Electrophoresis

Protein separation was carried out on a 10% SDS-polyacrylamide gel (sodium dodecyl sulphate) (Appendix 14) in a Hoeffer Mighty Small Electrophoresis Unit (Amersham Pharmacia Biotech, Buckinghamshire, UK). The separating gel was allowed to set for approximately 30 minutes before the loading of samples.

The lower and upper buffer chambers of the electrophoresis unit were filled with electrophoresis tank buffer (Appendix 15). The wells of the separating gel were rinsed three times with the tank buffer to remove any unpolymerized gel solution. A Hamilton Syringe (Hamilton Company Incorporated, Whittier, California, USA) was used to load the molecular weight marker, positive control or protein samples to the wells of the separating gel. Two types of molecular weight markers were used. Some of the gels were loaded with wide range molecular weight marker (Sigma-Aldrich Co., USA; range 6.5-205kDa) and for a few gels, The PageRuler Prestained Ladder Plus (Fermentas, Life Sciences; range 10-250kDa) a highly purified coloured molecular weight marker, was available. The first well of the separating gel was loaded with 4µl of a molecular weight marker. The second well was loaded with a positive control consisting of 10µl of the whole cell lysate (sc-2210 for VEGF or sc-2211 for COX2, Santa Cruz Biotechnology, CA, USA). The other consecutive wells were loaded with concentrated sample and sample diluted 1:10 and 1:20 in order to produce band representing VEGF or COX2 in relation to the molecular weight marker. The example of sample dilution 1:10 is as follows: 10µl of neat protein extraction, 40µl of TBS pH 7.6 and 50µl of transfer buffer containing SDS, ß mercaptoethanol and bromophenol blue (Appendix 16). The positive

control samples and respective protein samples were boiled for 90 seconds, prior to loading in the wells of the gel.

The system was connected to an electric power pack (Consort E452; Separation Scientific, Honeydew, South Africa). The separation of the proteins was carried out at a constant current of 25mA for approximately one hour. The movement of the protein was closely monitored. After the separation of the protein, the gels were dipped in the Towbin buffer (Appendix 17) for 10 minutes at room temperature to stabilize. One gel was incubated with Commasie stain (Appendix 18) overnight. Destaining of the gels with destain 1 and 2 (Appendix 19) was carried out in order to visualize the bands of separated proteins and to determine the band of interest in correlation with the molecular weight marker.

2.8 Western blot

A second gel was used for Western blotting. Separated protein was transferred to a nitrocellulose membrane (Hybond – ECL, Amersham Pharmacia Biotechnology, UK). The nitrocellulose membrane was cut to the size of the gel and soaked in transfer Towbin buffer (Appendix 17). The gel was laid out in a "sandwich" consisting of a sponge and double filter paper, the gel with the separated proteins, a nitrocellulose membrane, another double filter paper and sponge. The gel was placed facing the side of the cathode (negative) tray as the transfer occurs from the negative to the positive side with electric current. The transfer of proteins was carried out in Hoeffer Western blotting transfer equipment (Hoeffer Scientific Instruments, San Francisco, USA) filled with cold Towbin

buffer. The electric current was set on 20V and left overnight at 4˚C. After successful transfer, the membrane was washed twice for 5 min each in TBS with Tween 20 (Merck, Germany).

The membrane was blocked in TBS with 5% non-fat milk for one hour at room temperature. Incubation with primary VEGF antibody (various dilution were probed: 1:500; 1:750; 1:1000) was carried out overnight at 4˚C. For COX2, the primary antibody incubation was carried out for 2 hours at room temperature (dilution 1:750 or 1:1000). Incubation with the primary antibody was followed by a washing step. The membranes were washed twice for 5 minutes with TBS with Tween 20 at room temperature. Incubation with secondary rabbit anti-mouse HRP (Dako) diluted 1:1000 in 5% non-fat milk with Tween 20 was applied for 45 minutes at room temperature. Secondary COX2 antibody rabbit anti-goat HRP (Santa Cruz Biotechnology) diluted 1:1000 in 5% non-fat milk with Tween 20 was applied for 45 minutes at room temperature. After washing the membranes in TBS with Tween 20 three times for 5 minutes each, and once for 5 minutes in TBS alone, the bands were detected by adding POD (BM Blue POD substrate, precipitating, Roche Diagnostics, Indianapolis, US) for 5 minutes at room temperature. The reaction was stopped with distilled water and the membrane allowed to dry.

3.0 RESULTS

3.1 Oestradiol ELISA

The summary statistical values for the ELISA oestradiol concentrations are shown in Table 3.1 for the control rats and Table 3.2 for the hyperstimulated animals at 4.5, 5.5 and 6.5 days of pregnancy. The oestradiol concentrations with standard deviations for both control and hyperstimulated animals are shown in Figure 4. Values of oestradiol concentrations are given in pg/ml.

In the control animals, the oestradiol concentrations increased from 4.5 days of pregnancy through 5.5 days and 6.5 days of pregnancy. In the hyperstimulated rats, oestradiol concentrations were higher at 5.5 days when compared to the 4.5 days hyperstimulated rats and then markedly decreased on day 6.5 of pregnancy compared to the concentrations of oestradiol at 5.5 days in the hyperstimulated rats. On day 5.5 in the hyperstimulated rats, an extremely high oestradiol concentration was recorded (66.60 pg/ml) in one of the animals. However, the outcome of the results did not change in the case when statistical analysis was carried out without the result of that particular animal.

Statistically significantly higher oestradiol levels were found only between the control and hyperstimulated animals at 6.5 days of pregnancy.

Table 3.1

Summary of the statistical values of oestradiol concentrations in the control animals

Factor	Hormone	Days of pregnancy	Number of animals	Mean pg/ml	SD	Min	Max
Control	Oestradiol	4.5	5	21.28	11.23	12.40	40.80
Control	Oestradiol	5.5	6	22.68	8.39	12.10	32.90
Control	Oestradiol	6.5	6	32.52	13.65	19.50	51.90

Table 3.2

Summary of the statistical values of oestradiol concentrations in the hyperstimulated animals

Factor	Hormone	Days of pregnancy	Number of animals	Mean pg/ml	SD	Min	Max
Hyper-stimulated	Oestradiol	4.5	6	28.46	8.14	19.50	41.10
Hyper-stimulated	Oestradiol	5.5	5	37.86	16.42	26.20	66.60
Hyper-stimulated	Oestradiol	6.5	6	17.87	6.46	12.90	29.90

All values are oestradiol concentrations in pg/ml.

3.1.1 Statistical analysis for oestradiol concentration

The unpaired Student's "t" test was used to statistically analyse the oestadiol mean concentrations between control animals at different stages of pregnancy as well as between control and hyperstimulated animals at different stages of pregnancy. The data were also log-transformed before calculating the p values. However, the p values obtained after log transformation were similar and the outcome of the results did not change.

No statistically significant differences for oestradiol were found between the control animals. However, significantly higher oestradiol levels were found between the 5.5 and 6.5 day hyperstimulated animals ($p=0.022$).

When oestradiol concentrations were compared between the 4.5 day control and 4.5 day hyperstimulated animals, this was not statistically significant ($p=0.250$).

At 5.5 days of pregnancy, a comparison between the mean oestradiol concentrations in the control and the hyperstimulated animals was not statistically significant ($P=0.118$).

However, at 6.5 days of pregnancy statistically significantly higher mean oestradiol concentrations were found in the control animals compared to the hyperstimulated animals ($P=0.039$).

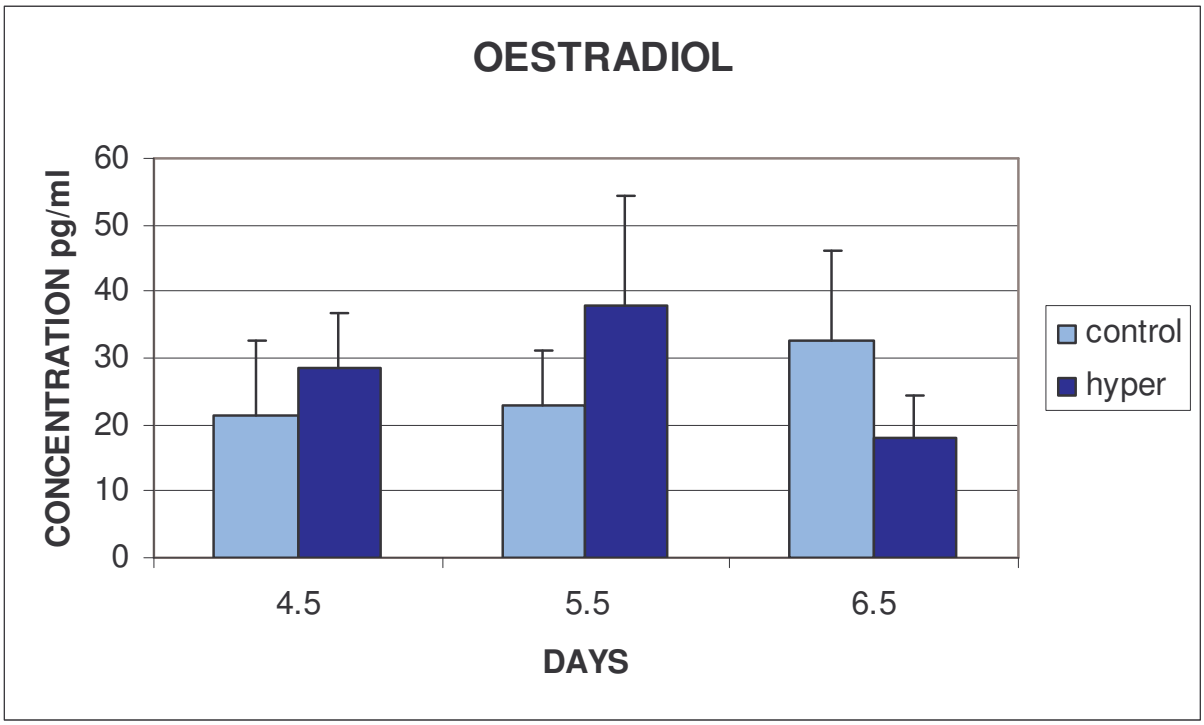

Fig. 4: **Graph showing plasma concentrations and standard deviations of oestradiol in the control and hyperstimulated animals. All concentrations are in pg/ml.**

3.2. Progesterone ELISA

The summary of the statistical values for progesterone concentrations obtained from control animals is shown in Table 3.3 and for hyperstimulated animals in Table 3.4, at 4.5, 5.5 and 6.5 days of pregnancy. The progesterone concentrations with standard deviations for both control and hyperstimulated animals are shown in Figure 5. Values of progesterone concentrations at 4.5, 5.5 and 6.5 days of pregnancy are given in ng/ml.

The mean progesterone concentrations increased in the 5.5 day control animals compared to the control animals at 4.5 days, while a slight decrease of progesterone was noticed at 6.5 days of pregnancy. In the hyperstimulated animals, the progesterone levels increased from 4.5 days through 5.5 days and 6.5 days of pregnancy.

Progesterone levels were higher in the hyperstimulated animals compared to the control animals at all stages of pregnancy examined. However, a statistically significantly higher progesterone concentration was found only between the control and the hyperstimulated animal groups on day 6.5 of pregnancy.

Table 3.3

Summary of the statistical values for the progesterone concentrations in the control animals

Factor	Hormone	Days of pregnancy	Number	Mean	SD	Min	Max
Control	Progesterone	4.5	6	22.51	6.04	11.90	28.90
Control	Progesterone	5.5	6	25.36	5.06	18.30	30.78
Control	Progesterone	6.5	6	23.46	5.00	16.10	31.30

Table 3.4

Summary of the statistical values for the progesterone concentrations in the hyperstimulated animals

Factor	Hormone	Days of pregnancy	Number	Mean	SD	Min	Max
Hyper-stimulated	Progesterone	4.5	6	25.45	4.50	19.10	31.33
Hyper-stimulated	Progesterone	5.5	5	32.06	7.70	24.30	44.30
Hyper-stimulated	Progesterone	6.5	7	33.07	4.97	26.20	39.20

All values are progesterone concentrations in ng/ml.

3.3.1 Statistical analysis for progesterone concentration

The unpaired Student's "t" test was used to compare progesterone concentrations between control animals at consecutive days of pregnancy, the same for the hyperstimulated animals at consecutive stages of pregnancy and between the pregnant and hyperstimulated animals at different stages of pregnancy. Data were also log-transformed before calculating the p values, as had been done with oestradiol data. However, the p values were similar and the outcome of the results did not change.

No statistically significant differences for the progesterone concentrations were recorded in either the control or hyperstimulated animals.

When progesterone concentrations were compared between 4.5 day control and 4.5 day hyperstimulated animals, these were not statistically significant ($p=0.362$).

No statistically significant differences were recorded between control and hyperstimulated animals at 5.5 days of pregnancy ($p=0.213$).

However, the progesterone concentrations were statistically significantly higher in the hyperstimulated animals compared to the control animals at 6.5 days of pregnancy ($p= 0.006$).

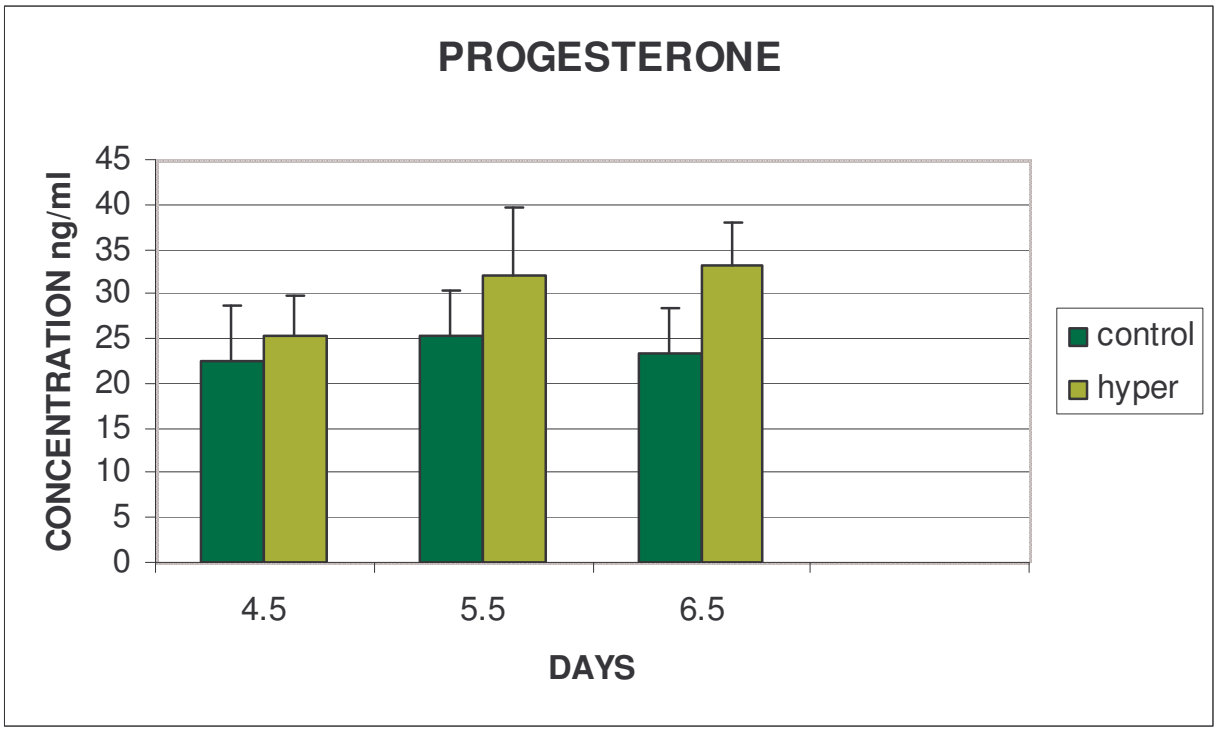

Fig. 5: **Graph showing plasma concentrations and standard deviations of progesterone in the control and hyperstimulated animals. All values are progesterone concentrations in ng/ml.**

3.3. Non-parametric Mann-Whitney test

In addition to statistical analysis using the Student's "t" test, a non-parametric Mann-Whitney test was used in order to determine possible statistically significant differences with regards to the progesterone and oestradiol concentrations between control and hyperstimulated animals at different stages of pregnancy. These statistical results were then compared with the outcome of the Student's "t" test. The outcome was the same in both statistical analyses. In other words, no significant statistical differences were found between control and hyperstimulated groups of animals for both progesterone and oestradiol concentrations at 4.5 and 5.5 days of pregnancy. However, significant statistical differences were evident between control and hyperstimulated animals at 6.5 days of pregnancy for both progesterone and oestradiol.

3.4. Progesterone:Oestradiol ($P:E_2$) ratio

The progesterone:oestradiol ratio ($P:E_2$) was calculated first for every individual animal in each group, followed by the calculation of the group $P:E_2$ ratio. The group $P:E_2$ ratio was calculated by dividing the mean progesterone concentration by the mean oestradiol concentration of the control animals at 4.5 or 5.5 or 6.5 days of pregnancy. The ratio was also calculated in the hyperstimulated animals at the same stages of pregnancy. The summary of the progesterone-oestradiol ratio is given in Table 3.5.

Table 3.5

Summary of the $P:E_2$ ratio of the control and hyperstimulated animals.

Day and Factor	Progesterone	Oestrogen	$P:E_2$
4.5 control	22.51	21.28	1.2352
5.5 control	25.36	22.68	1.2177
6.5 control	23.46	32.52	0.7977
4.5 hyperstimulated	25.45	28.46	0.9490
5.5 hyperstimulated	32.06	37.86	0.9454
6.5 hyperstimulated	33.07	17.87	2.0693

Statistical analysis for $P:E_2$ was carried out using the F-test of variance, Student's "t" test and the Welch test (non-parametric test of uniqual variance).

At 4.5 days and 5.5 days of pregnancy the $P:E_2$ ratio was higher in the control animals than in the hyperstimulated animals at the same day of pregnancy. However, it was not statistically significant.

At 6.5 days in the control animals, the $P:E_2$ was lower than in the hyperstimulated animals and this was statistically significant ($P < 0.01$).

Table 3.6

Summary of statistical analysis for $P:E_2$ ratio

	Control	**Hyperstimulated**			
Days	**mean (SD)**	**mean (SD)**	**F (P)**	**t (P)**	**Welch t (P)**
4.5	1.2352 (0.7117)	0.9490 (0.2765)	6.6245 (0.062)	0.91367 (0.385)	0.84747 (0.435)
5.5	1.2177 (0.4168)	0.9454 (0.3556)	1.7159 (0.568)	1.2542 (0.238)	1.2542 (0.240)
6.5	0.7977 (0.2776)	2.0693 (0.6083)	4.8029 (0.110)	-4.6582 (0.000) *	-4.6582 (0.002) *
* Significant difference $P < 0.01$					

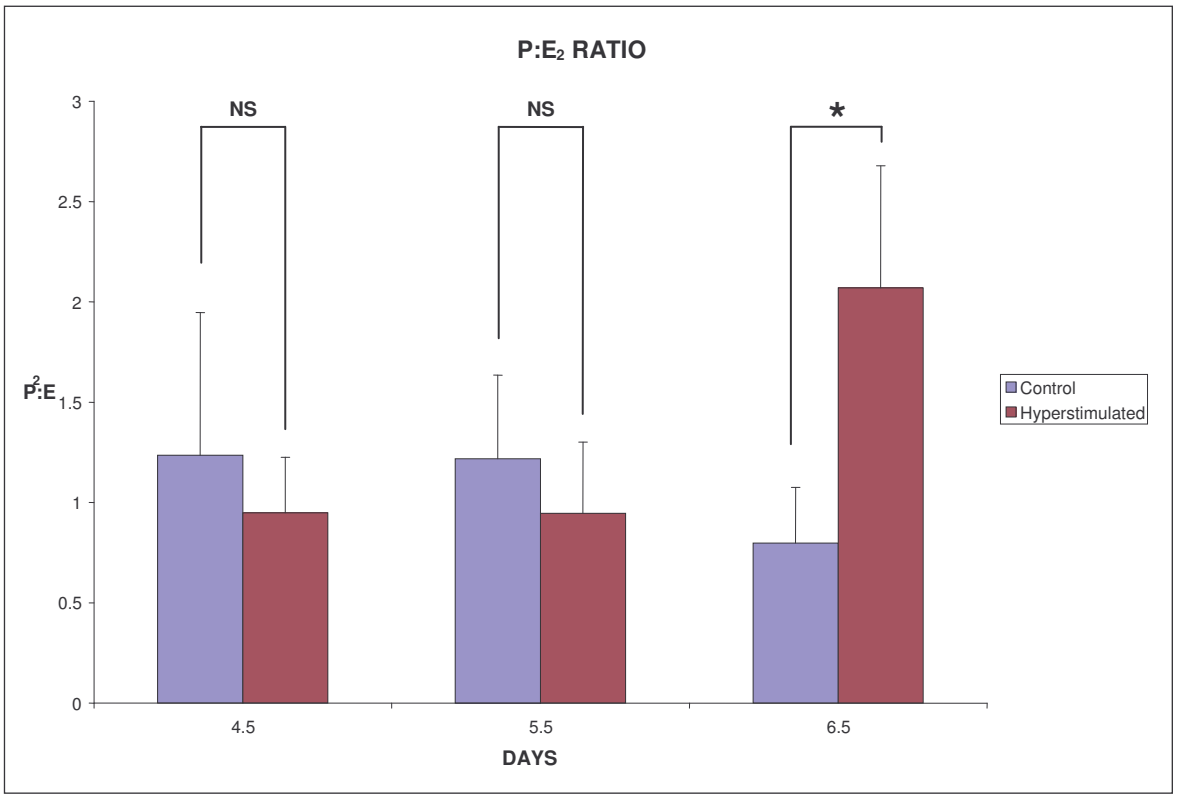

Fig. 6: Progesterone:Oestradiol ratio ($P:E_2$) in the control and hyperstimulated rats at 4.5, 5.5 and 6.5 days of pregnancy (NS = no significant difference between control and hyperstimulated groups; * = significant difference between groups: $P < 0.01$).

3.5. General Observation

The uterine horns and ovaries showed distinct gross morphological differences between the control and hyperstimulated animals. Ovaries appeared larger and contained numerous follicles in the hyperstimulated animals (Fig. 8) compared to the control rats (Fig. 7). Implantation sites, stained blue with the pontamine blue technique, were present in the uterine horns of one control animal (three implantation sites) at 4.5 days of pregnancy. All other animals in both the control and hyperstimulated groups at 4.5 days of pregnancy did not show blue bands. In all control animals on days 5.5 (Fig. 7) and 6.5 of pregnancy, numerous implantation sites staining blue were evident (average 8-15 implantation sites per animal). However, only in two animals in the hyperstimulated group at 5.5 days of pregnancy, one possible implantation site in each animal was evident. None of the hyperstimulated animals at 6.5 days showed blue bands.

The uterine horns of the hyperstimulated animals at all stages of pregnancy were markedly dilated (Fig. 8), when compared to control animals at the same stage.

3.6. Histology

The histology of the ovaries and the uterine tissue of control and hyperstimulated animals were examined in order to analyse tissue morphology.

The ovaries of the control animals at all stages examined (4.5, 5.5 and 6.5 days of pregnancy) contained numerous corpora lutea which were well developed (Fig. 9). The ovaries of the hyperstimulated animals at all stages examined, contained numerous large secondary follicles. Corpora lutea were also present in the ovaries of the hyperstimulated animals, however, smaller compared to those of normal pregnant animals (Fig. 10).

The surface of the uterine lumen in control animals at 4.5 days of pregnancy appeared smooth. The luminal walls were in apposition at the antimesometrial end of the uterine lumen (region of the implanting blastocyst) (Fig. 11). The luminal epithelial cells were simple cuboidal with oval nucleus, displaced from the base of the cell by the presence of vacuoles (Fig. 12). Numerous microvilli covered the apex of the cells (Fig. 13). Some of the cells in the subepithelial stroma adjacent to the luminal epithelial cells predominantly at the antimesometrial pole were round (indicating decidualization) and contained prominent round basophilic nuclei (Fig. 13). Potential spaces were apparent between the stromal cells indicated oedema of the tissue as a result of vascular leakage. However, the majority of the cells in the stroma were flat and fibroblastic and the tissue appeared compact.

Numerous glands were observed in the stroma. Glandular cells were simple cuboidal with prominent large nuclei which were basally placed in the cell. The presence of vacuoles was noted in the cytoplasm around the nucleus of the glandular cells (Fig. 13).

The uterine tissue of hyperstimulated animals at 4.5 days of pregnancy showed distinct differences in the luminal epithelium and tissue morphology compared to the 4.5 day control animals. The uterine lumen was markedly dilated and the mucosa was very folded (Fig. 14). The luminal epithelial cells were simple columnar with large, oval, basally placed nuclei (Fig. 15). Vacuoles were not present in these cells. The subepithelial stromal cells were flat and fibroblastic (Fig. 15). Numerous uterine glands were observed in the stroma. The glandular lumen was dilated. The glandular cells were simple cuboidal and contained large, basally placed nuclei (Fig. 16). Vacuoles were absent from the cytoplasm of the glandular cells at 4.5 days of pregnancy in the hyperstimulated animals.

The gross morphology of the uterine tissue at 5.5 and 6.5 days of pregnancy in control animals was similar to that of the tissue at 4.5 days of pregnancy in control animals. The uterine lumen was smooth and the uterine walls were in apposition (Fig. 17). However, histological changes of the uterine tissue were evident at 5.5 days of pregnancy. The luminal epithelial cells were simple cuboidal in shape (Fig. 18). The apical portions of these cells were covered with numerous microvilli. Oval nuclei were placed towards the base of the luminal epithelial cells on the antimesometrial side, as vacuoles were not present in these cells (Fig. 18). However, at the mesometrial side of the lumen, vacuoles

were present basally in the luminal epithelial cells, but were decreased in size. Decidual cells were arranged in a distinct thick layer in the subepithelial stroma (primary decidual zone). Numerous blood vessels were evident in the stroma. Spaces between the decidual cells were evident and indicated the collection of extracellular fluid in the tissue (Fig. 18). Uterine glands were numerous in the stroma and were arranged in clusters. The glandular cells remained simple cuboidal in shape. Vacuoles were not present in the glandular cells in 5.5 day control animals.

Uterine tissue of the hyperstimulated animals at 5.5 days showed similarities in morphology and histology to that of 4.5 day hyperstimulated animals. The uterine lumen of these animals was markedly dilated and contained numerous mucosal folds (Fig. 19). The luminal epithelial cells were simple columnar with numerous microvilli on their apical border. Large nuclei were basally placed in the luminal epithelial cells (Fig. 20). Subepithelial stromal cells remained flat and fibroblastic. Numerous glands arranged in clusters were present in the stroma (Fig. 20).

On day 6.5 of pregnancy in the control animals, more extensive decidualisation was evident compared to that at 5.5 days. Numerous stromal cells adjacent to the primary decidual zone were rounded and the stroma appeared oedematous. This histological change was indicative of formation of a secondary decidual zone (Fig. 21). The stromal blood vessels were numerous and were surrounded by decidual cells (Fig. 22). At the antimesometrial side, the luminal epithelial cells showed distinct differences to those at the mesometrial side of the lumen. At the mesometrial side of the uterine lumen, the

luminal epithelial cells were simple low cuboidal. At the antimesometrial side, luminal epithelial cells were simple squamous (Fig. 22) and at the margin with the implanting blastocyst, the epithelium had disappeared allowing for contact of the blastocyst and decidua.

Sections of uterine tissue of hyperstimulated animals on 6.5 days of pregnancy followed a similar pattern in morphology and histological appearance to that of 4.5 and 5.5 day hyperstimulated animals. The uterine lumen contained numerous folds of the luminal epithelial cells and subepithelial stromal tissue (Fig. 23). The luminal epithelial cells were simple columnar with large nuclei, basally placed in the cell. The subepithelial stromal cells were fibroblastic (Fig. 24). Numerous uterine glands were observed in the stoma. Glandular cells remain simple cuboidal and contained large basally placed nuclei (Fig. 24) without vacuoles in the cytoplasm.

3.3 Immunohistochemistry

3.3.1 Controls for COX2 immunohistochemistry

Human lung carcinoma was used as a positive control. Sections of the lung carcinoma tissue expressed COX2 immunoreactivity in the cytoplasm of the lung carcinoma cells (Fig. 25).

For the negative control, sections of the uterine tissue, in both control and hyperstimulated animals were used. Sections adjacent to the sections of the uterine tissue which showed COX2 immunolocalization were incubated with TRIS buffered saline in place of either the primary or secondary antibody. While the control tissue expressed immunolocalization of the respective protein (Fig. 26), the sections incubated with TRIS in the place of the primary antibody (Fig. 27a) or the secondary antibody (Fig. 27b) showed no evidence of COX2 protein expression.

3.3.2 Immunolocalisation of COX2 in control and hyperstimulated animals at 4.5, 5.5 and 6.5 days of pregnancy

Immunolocalization of COX2 was evident in the tissue of both control and hyperstimulated animals at different stages of pregnancy. However, differences in the distribution of COX2 immunolocalization were evident between the two groups of animals.

At 4.5 days of pregnancy in the control animals, COX2 immunolocalization was evident in the cytoplasm of the luminal epithelial cells, the subepithelial stromal cells and the glandular cells (Fig.28). While the expression of COX2 was clearly evident in the luminal epithelial cells, only scanty cytoplasmic COX2 immunolocalization was noted in the glandular cells and the rounded stromal cells immediately adjacent to the luminal epithelial cells, predominantly at the antimesometrial side at 4.5 days of pregnancy.

In the hyperstimulated animals at 4.5 days of pregnancy, intense immunolocalization of COX2 was evident in the cytoplasm of the luminal epithelial cells and less so, in the glandular cells. However, COX2 immunolocalization was absent in the stromal cells (Fig. 29). The luminal epithelial cells showed variable protein expression as some epithelial cells expressed highly intense COX2 immunolocalization compared with the other epithelial cells (Fig. 29). The majority of the luminal epithelial cells expressed more intense immunolocalization around the nucleus. Glandular cells expressed a lower

intensity of COX2 immunolocalization compared to the luminal epithelial cells, and this was evenly distributed in the cytoplasm (Fig. 29).

At 5.5 days of pregnancy in the control animals, COX2 immunolocalisation was weakly present in the luminal epithelial cells (Fig.30). It was less intense compared to that in the luminal epithelial cells of the animals at 4.5 days of pregnancy. COX2 immunolocalization was weakly present and evenly distributed in the glandular cells. Stromal decidual cells immediately adjacent to the luminal epithelial cells (primary decidual zone) expressed a stronger cytoplasmic COX2 localisation when compared to the 4.5 day control stromal tissue.

In the hyperstimulated animals at 5.5 days of pregnancy, an uneven and often intense localization of COX2 was evident in the luminal epithelial cells (Fig. 31). There was however an even, but very weak, distribution in the glandular cells (Fig. 31). Stromal cells at 5.5 days in hyperstimulated animals did not show COX2 immunolocalization.

At 6.5 days of pregnancy in the control animals, COX2 immunolocalization was not evident in the luminal epithelial cells which showed varying morphological appearances in the different regions of the lumen (Fig. 32). The glandular cells expressed scanty cytoplasmatic COX2 immunolocalization. However, the decidual stromal cells at 6.5 days of pregnancy in the control animals showed strong immunolocalization of COX2 which was particularly strongly localized around the nucleus of the decidual cells. Also, the cells in the primary decidual zone showed stronger localization compared to the

decidual cells in the secondary decidual zone. In the tissue sections containing an embryo, weak COX2 immunolocalization was evident in the embryonic cell mass (Fig. 32).

In the hyperstimulated animals at 6.5 days of pregnancy, strong expression of COX2 was evident in the simple high columnar luminal epithelial cells. Stromal cells did not express COX2 localization at this stage of pregnancy (Fig. 33).

3.4.1 Controls for VEGF immunohistochemistry

Sections of human breast carcinoma tissue were used as a positive control. VEGF immunoreactivity was observed in the cytoplasm of the tumour cells (Fig. 34).

For the negative control, sections of uterine tissue, in both the control and hyperstimulated animals, adjacent to the sections showing VEGF immunolocalization were incubated with TRIS buffered saline in place of either the primary or secondary VEGF antibody. While the experimental tissue expressed immunolocalization of the protein (Fig. 35), in the sections incubated with TRIS in place of the primary antibody (Fig. 36a) and the secondary antibody (Fig. 36b) no VEGF immunolocalization was present in any tissue compartment.

3.4.2 Immunolocalization of VEGF in control and hyperstimulated animals at 4.5, 5.5 and 6.5 days of pregnancy

Uterine tissue sections of control and hyperstimulated animals incubated with VEGF antibody showed differences in the distribution of VEGF immunolocalization in these two groups of animals at different stages of pregnancy.

At 4.5 days of pregnancy in the control animals, VEGF immunolocalization was evident in the cytoplasm of the luminal epithelial cells, the glandular epithelial cells and the subepithelial stromal cells (Fig. 37). Expression of VEGF was evident in the cytoplasm of the luminal epithelial cells, particularly in the basal part of the epithelial cells and surrounded the vacuoles which were present (Fig. 37). The cytoplasm of the glandular cells showed evenly distributed VEGF immunolocalization. In the subepithelial stroma, only the rounded cells indicating decidualization showed distinct cytoplasmic VEGF immunolocalization, while the fibroblasts did not show immunolocalization (Fig.37). VEGF immunolocalization was present in the stromal blood vessels as well.

A difference in distribution of VEGF immunolocalization was evident in the hyperstimulated uterine tissue compared to the control tissue at 4.5 days of pregnancy. While VEGF was evident in the cytoplasm of the luminal epithelial cells and glandular cells (Fig. 38) at 4.5 days in the hyperstimulated animals, the stromal cells did not show localization of the protein (Fig.38). VEGF was highly intense and evenly distributed in

the apical portions of the tall simple columnar luminal epithelial cells. In addition, the uterine glandular cells showed intense cytoplasmic VEGF immunolocalization (Fig. 38).

Distribution of VEGF immunolocalisation in control animals at 5.5 days of pregnancy followed a similar pattern of expression to the control animals at 4.5 days of pregnancy. However, the luminal epithelial cells, the glandular and decidual stromal cells of the 5.5 day control animals expressed a much higher intensity of VEGF localization compared to those of 4.5 day pregnancy (Fig. 39).

Hyperstimulated animals at 5.5 days of pregnancy expressed VEGF localization in the luminal epithelial cells and glandular cells. The intensity of VEGF imunolacalization was similar to that at 4.5 day hyperstimulated animals. The stromal cells at this stage, as at 4.5 days, did not show immunolocalization (Fig. 40).

At 6.5 days in the control animals, VEGF was differently localized when compared to the control animals at 5.5 days of pregnancy. These differences were particularly evident in the distribution of VEGF in the luminal epithelial cells and stromal cells. The luminal epithelial cells at the antimezometrial side, immediately adjacent to the embryo did not show VEGF localization, while localization was evident in the luminal epithelial cells at the mesometrial side of the lumen (Fig. 41). In addition, at the antimesometrial side some of the cells of the embryo, which appeared to be trophoblastic cells, showed intense immunolocalization of VEGF (Fig. 42). VEGF was also localized to the embryonic cells (Fig. 42). Decidual stromal cells showed immunolocalization in both, the primary and

secondary decidual zone. However, cells in the secondary decidual zone, expressed higher intensity of VEGF localization when compared to the primary decidual zone (Fig. 41).

VEGF immunolocalization in the hyperstimulated animals at 6.5 days of pregnancy was evident in the cytoplasm of the luminal epithelial cells and glandular cells, while the stromal cells, were negative for VEGF immunolocalization (Fig. 43). This was similar to the VEGF immunolocalization in the hyperstimulated animals at 4.5 and 5.5 days of pregnancy.

3.5 Summary of COX2 and VEGF immunolocalization in the control and hyperstimulated animals at 4.5; 5.5 and 6.5 days of pregnancy

Both COX2 and VEGF were immunolocalized to the uterine tissue at the different stages of pregnancy examined and in both control and hyperstimulated animals. However, differences, as well as similarities, in the distribution of COX2 and VEGF immunolocalization were evident between the two groups of animals at the various stages of pregnancy.

COX2 was expressed in the control groups of animals at 4.5, 5.5 and 6.5 days of pregnancy in the luminal epithelial cells, glandular cells and in the stromal cells that showed decidualization. While COX2 immunolocalization in the luminal and glandular epithelial cells was prominent in the control animals at 4.5 days, the intensity of immunolocalization decreased in these cells with the progression of pregnancy. A high intensity of cytoplasmic COX2 immunolocalization was evident in the decidual stromal cells of the control animals at 6.5 days of pregnancy particularly in the region immediately adjacent to the luminal epithelial cells (primary decidual zone).

In the hyperstimulated animals at 4.5 days, COX2 was present in the luminal epithelial cells and glandular epithelial cells and the intensity of immunolocalization increased slightly in these cells at 5.5 and 6.5 days of pregnancy. The major difference in COX2 immunolocalization between control and hyperstimulated animals was noted in the stromal cells. While the stroma of the control animals became decidualized and showed

COX2 localization in these cells at 4.5, 5.5 and 6.5 days of pregnancy, the stromal cells of hyperstimulated animals did not show decidua formation or localization of COX2 at any of the stages of pregnancy examined.

VEGF, like COX2 was immunolocalized to the luminal epithelial cells, glandular cells and decidual stromal cells of the uterine tissue in the control animals at 4.5, 5.5 and 6.5 days of pregnancy. Differences in the intensity of VEGF compared to COX2 expression were noticed in these cells in the control animals. The luminal epithelial and glandular cells showed intense VEGF immuniolocalization at all stages of pregnancy examined which was opposite to the COX2 immunolocalization. Expression of COX2 decreased in these cells with the progression of pregnancy. In addition, luminal epithelial cells did not show VEGF immunolocalization at the antimesometrial side around the implanting blastocyst at 6.5 days of pregnancy, while the simple cuboidal luminal epithelial cells at the mesometrial side expressed strong VEGF immunolocalization. Stromal cells exhibited differences in immunolocalization of VEGF compared to COX2 immunolocalization at 6.5 days of pregnancy. While COX2 was intensely localized in the decidual cells immediately adjacent to the luminal epithelial cells and decreased in the cells distant to this area, the opposite was true for VEGF immunolocalization. Intense VEGF immunolocalization was evident in the decidual stromal cells of the secondary decidual zone.

In the hyperstimulated animals, VEGF was present in the luminal epithelial cells and glandular cells, but was absent in the stromal cells which remained flat at all stages of

pregnancy examined. This was the same for COX2 immunolocalization. While cytoplasmatic COX2 immunolocalization was unevenly distributed in the cytoplasm of the luminal epithelial cells, VEGF was evenly expressed in these cells at all stages of pregnancy examined.

3.10 Western blot analysis for VEGF and COX2

Western blot analysis was carried out on samples of extracted protein from the uterine tissue of the control and hyperstimulated animals at all the stages of pregnancy examined.

Following electrophoresis of the samples, the gel incubated with destain 1 and destain 2 was observed to determine the band of interest (Fig. 44). However, it appeared that no band corresponding to the range of 21/42kDa (molecular weight of VEGF) or band in the range of 72-74kDa (molecular weight of COX2) was present.

The second gel obtained after electrophoresis was used for protein transfer on to the nitrocellulose membrane as per materials and methods. After incubation with the primary and secondary antibodies the membranes were incubated with POD in order to visualize the bands. However, no bands indicating VEGF or COX2 were visible on the membrane. Although different concentrations of the primary and secondary antibody were incubated with the membranes, and an increased volume of the samples was loaded for electrophoresis, no results could be produced. The reason for unsuccessful Western blot analysis may be that the concentration of VEGF and COX2 in the sample was too low, as very small pieces of the uterine tissue were used for the protein extraction. The coloured protein molecular weight marker used indicated that the transfer during the blotting was successful (Fig. 45).

Fig. 7: Representative photomicrograph of dissected uterine horns of a 5.5 day control animal. Note the presence of numerous blue bands (implantation sites; 13 in total). Ovaries appear normal. Pontamine blue reaction.

Fig. 8: Representative photomicrograph of dissected uterine horns of a 5.5 day hyperstimulated animal. Note the dilated uterine horns and no evidence of blue stained implantation sites. Ovaries appear large with numerous follicles. Pontamine blue reaction.

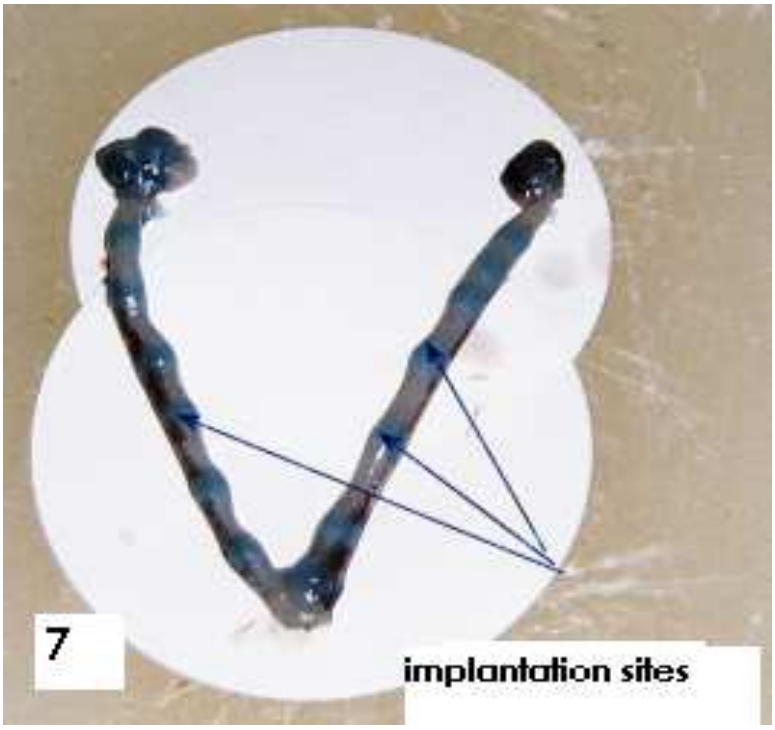
7
implantation sites

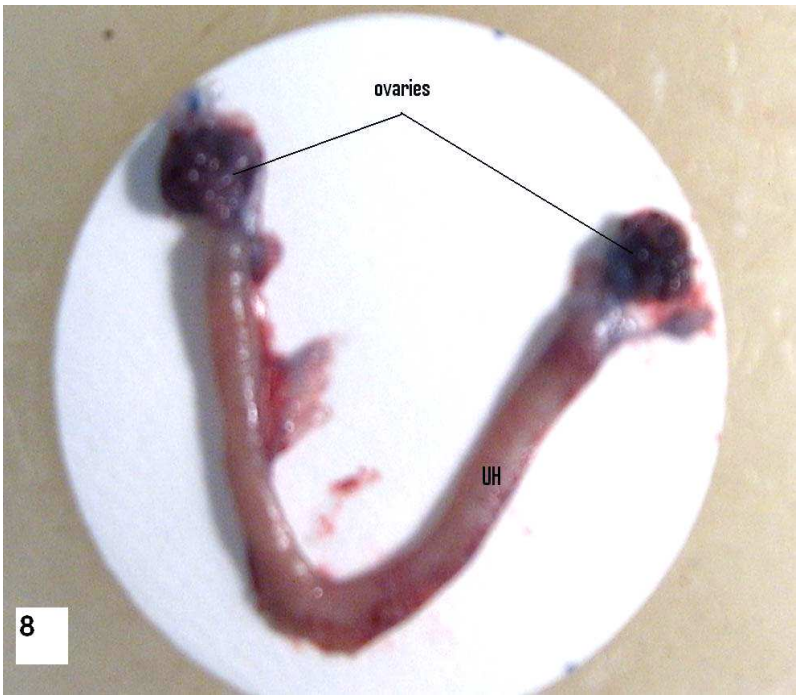
ovaries
UH
8

Fig. 9: Representative histological section of 4.5 day control ovarian tissue. Note numerous well developed corpora lutea (CL). Haematoxylin and eosin. x10.

Fig. 10: Representative histological section of 5.5 day hyperstimulated ovarian tissue. Note numerous large follicles (FL) and numerous small corpora lutea (CL). Haematoxylin and eosin. x10.

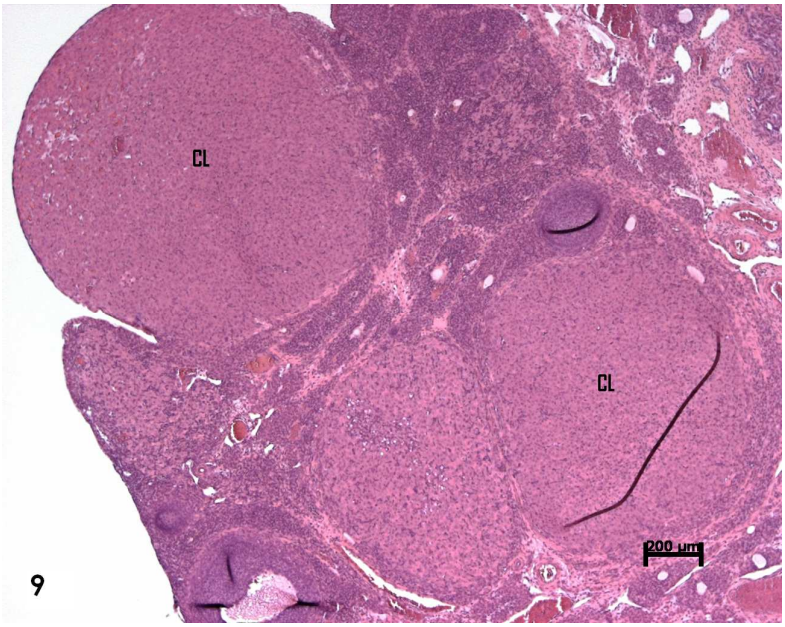
CL
CL
200 µm
9


CL
FL
CL
FL
200 µm
10

Fig. 11: Representative histological section of 4.5 day control uterine tissue. Note the apposed uterine walls at the antimesometrial site (AMM), and the smooth appearance of the uterine lumen. Decidualisation (DEC) is evident around the implanting embryo (EMB). Numerous uterine glands (GL) are present. Haematoxylin and eosin. x10.

Fig. 12: Higher magnification of 4.5 day control uterine tissue seen in Fig. 8. Note the simple cuboidal luminal epithelial cells with rounded centrally placed nuclei (N). The luminal epithelial cells contained vacuoles (V) basally placed in the cell. Immediately adjacent to the luminal epithelial cells around the implanting embryo (EMB), the stromal cells are rounded, indicating decidua formation (DEC). Haematoxylin and eosin. x40.

Fig. 13. Representative histological section of 4.5 control uterine tissue. Note the simple cuboidal luminal epithelial cells (LE) and glandular cells (GL) with vacuoles basally placed. The nucleus is centrally placed in the luminal epithelial cells. The apex of the luminal epithelial cells is covered with microvilli (MV). Subepithelial stromal cells (DEC) are rounded with scanty cytoplasm. Haematoxylin and eosin. x40.

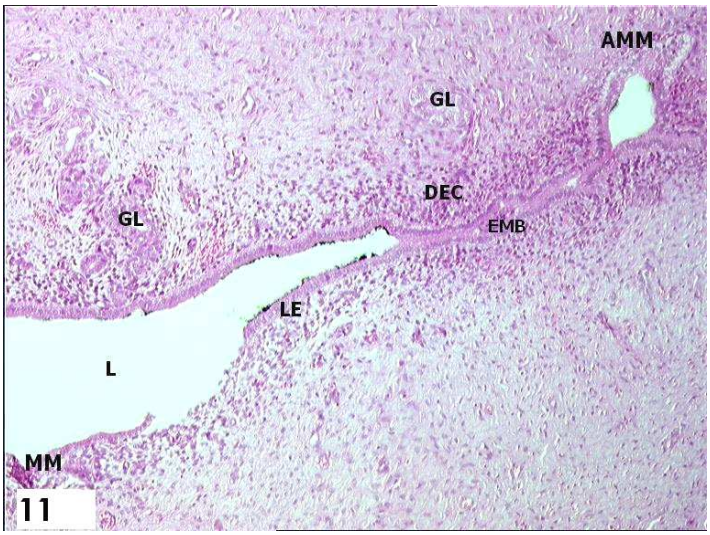
AMM
GL
DEC
GL
EMB
LE
L
MM
11

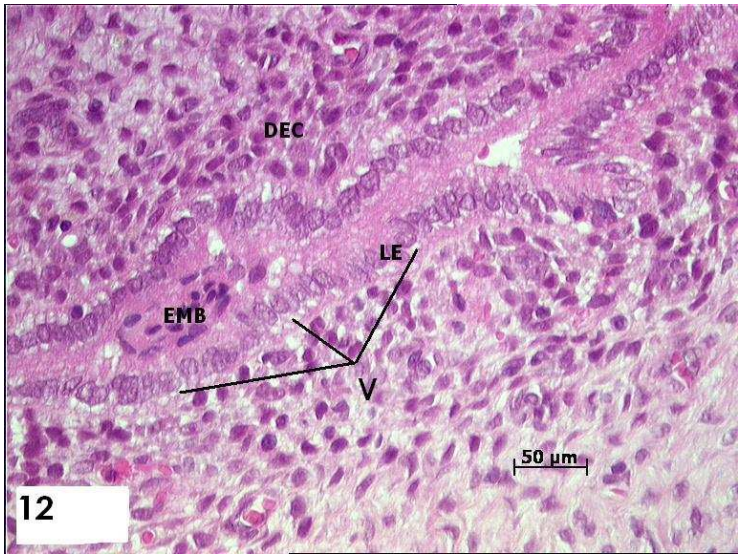
DEC
LE
EMB
V
50 µm
12

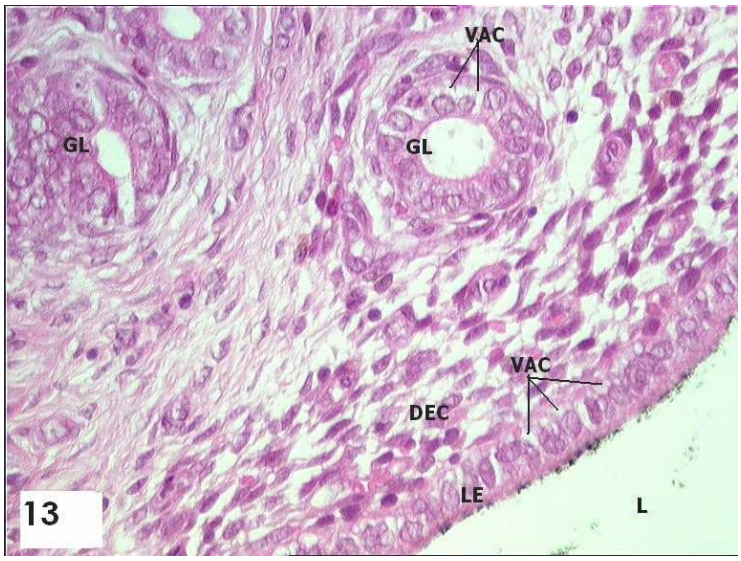
VAC
GL
GL
VAC
DEC
LE
L
13

Fig. 14: Representative histological section of 4.5 day hyperstimulated uterine tissue. Note the dilated uterine lumen (L) with numerous luminal mucosal folds. Numerous glands (GL) are present in the stroma (ST). Haematoxylin and eosin. x10.

Fig. 15: Representative histological section of 4.5 day hyperstimulated uterine tissue. Note the simple columnar luminal epithelial cells (LE) with basally placed nuclei. The subepithelial stromal cells (ST) are flat and fibroblastic (open lines). Haematoxylin and eosin. x40.

Fig. 16: Representative histological section of 4.5 day hyperstimulated uterine tissue showing stroma (ST) with flat, fibroblastic cells surrounding the uterine glands (GL). The lumen of the glands is dilated. Glandular cells are simple cuboidal with nuclei basally placed in each cell. Haematoxylin and eosin. x40.


GL
L
ST
GL
100 µm
14

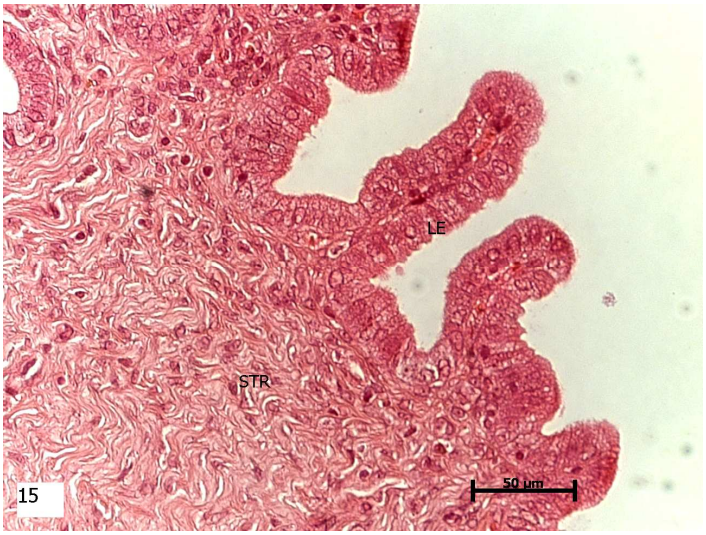
LE
STR
50 µm
15

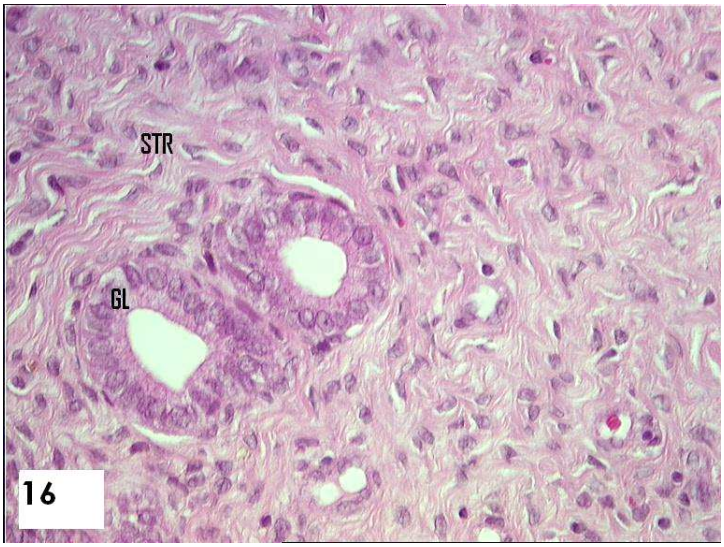
STR
GL
16

Fig. 17: Representative histological section of a 5.5 day control uterine tissue. Note the smooth appearance of the uterine lumen (L). Numerous glands (GL) are present in the endometrium. Note that uterine stroma at the mesometrial uterine side (MM) appears compact, while at the antimesometrial side (AMM) spaces between the cells are evident indicating stromal oedema and formation of primary decidual zone (PDZ). Haematoxylin and eosin. x10.

Fig. 18: Representative histological section of a 5.5 day pregnant uterine tissue showing simple cuboidal luminal epithelial cells (LE) with numerous microvilli (MV) on the apical border of the cells. Nuclei (N) are rounded and situated towards base of the cells. Note scanty cytoplasm in the decidual stromal cells (STR) and potential spaces between these cells as a result of tissue oedema. Haematoxylin and eosin. x40.


AMM
GL
DEC
LE
PDZ
L
100 µm
17

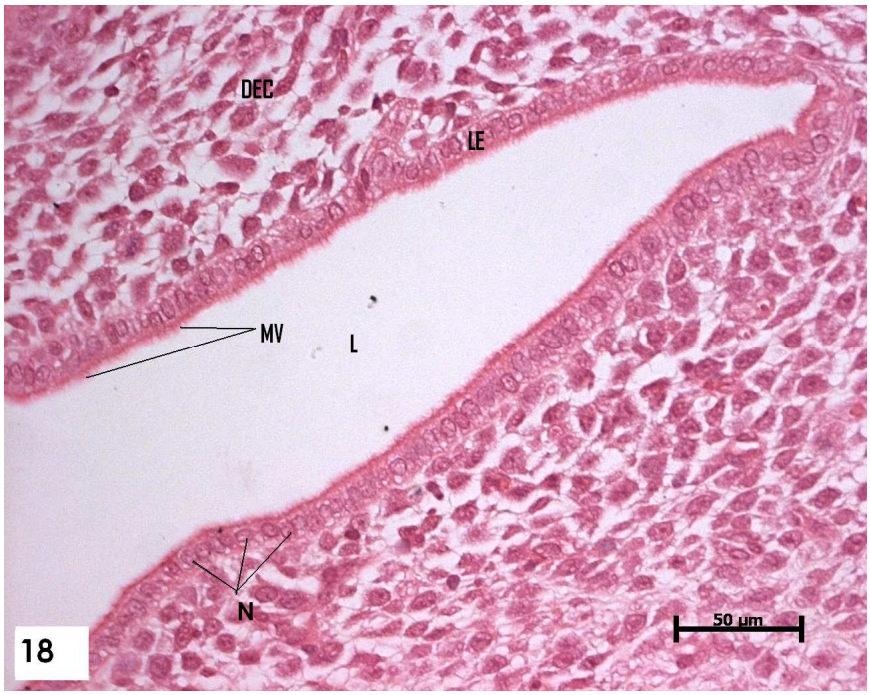
DEC
LE
MV
L
N
50 µm
18

Fig. 19: Representative histological section of a 5.5 day hyperstimulated uterine tissue. Note dilated lumen (L) and numerous luminal mucosal folds (LF). Haematoxylin and eosin. x10.

Fig. 20: Representative histological section of a 5.5 day hyperstimulated uterine tissue. Stromal cells (STR) are fibroblastic in shape. Uterine glandular cells (GL) are simple columnar with rounded basally placed nuclei. Haematoxylin and eosin. x40.

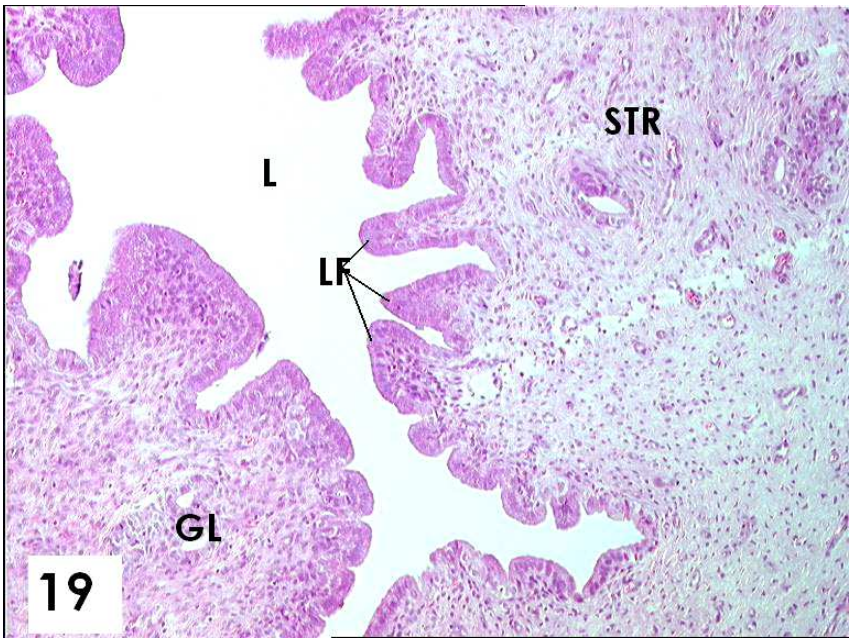
STR
L
LE
GL
19

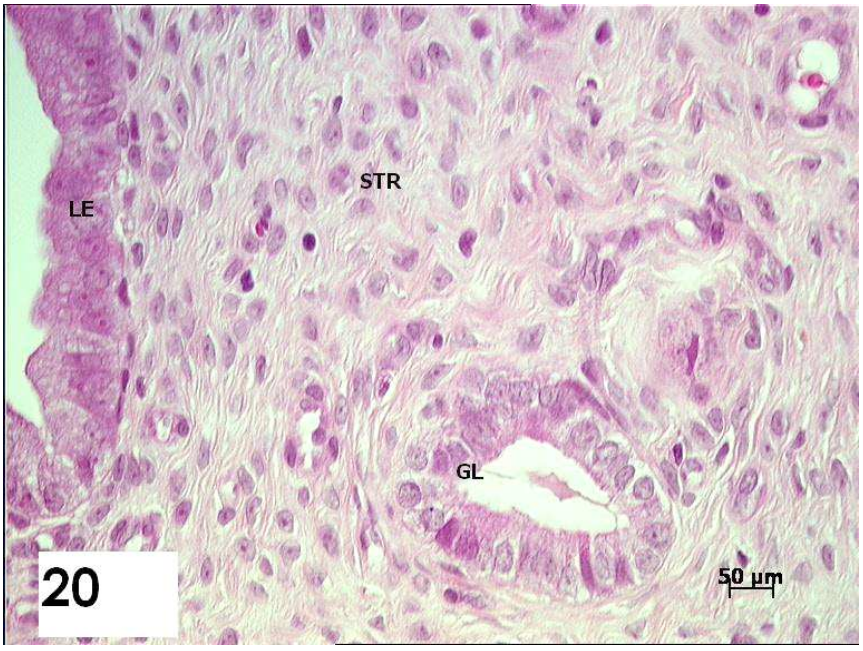
LE
STR
GL
20
50 µm

Fig. 21: Representative histological section of a 6.5 day control uterine tissue. The uterine luminal mucosa appears smooth. An embryo (EMB) is visible in the lumen (L). Note distinct decidua formation on the both sides of the lumen, mesometrial (MM) and antimesometrial (AMM) sides. Haematoxylin and eosin. x10.

Fig. 22: Representative histological section of a 6.5 day pregnant uterine tissue at the antimesometrial side. Luminal epithelial cells (LE) are low simple cuboidal with flat to round nuclei basally placed in the cell. Numerous decidual cells, rounded in shape, are visible in the subepithelial stroma (STR). Note numerous blood vessels (BV) surrounded by decidual cells. Haematoxylin and eosin. x40.

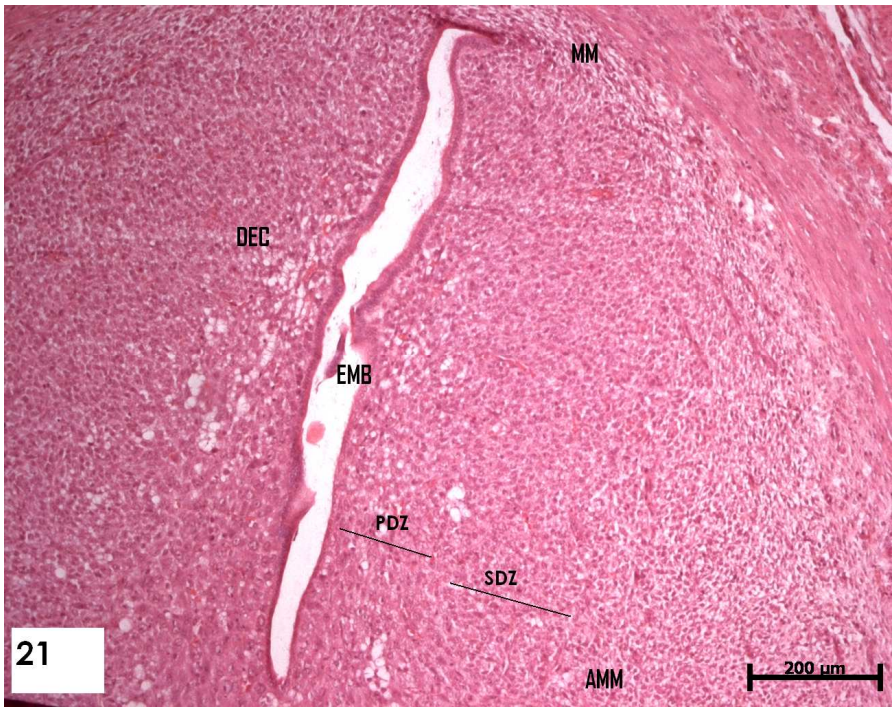

21



22

Fig. 23: Representative histological section of a 6.5 day hyperstimulated uterine tissue. Numerous mucosal folds (LF) are present in the dilated lumen (L). Note the numerous uterine glands (GL) in the stroma (STR). Haematoxylin and eosin. x10.

Fig. 24: Representative histological section of a 6.5 day hyperstimulated uterine tissue. Note simple tall columnar luminal epithelial cells (LE). Vacuoles are not present in the cytoplasm of these cells. The stromal cells (STR) are flat and fibroblastic. The glandular cells (GL) are simple columnar with basally placed nuclei. Haematoxylin and eosin. x40.

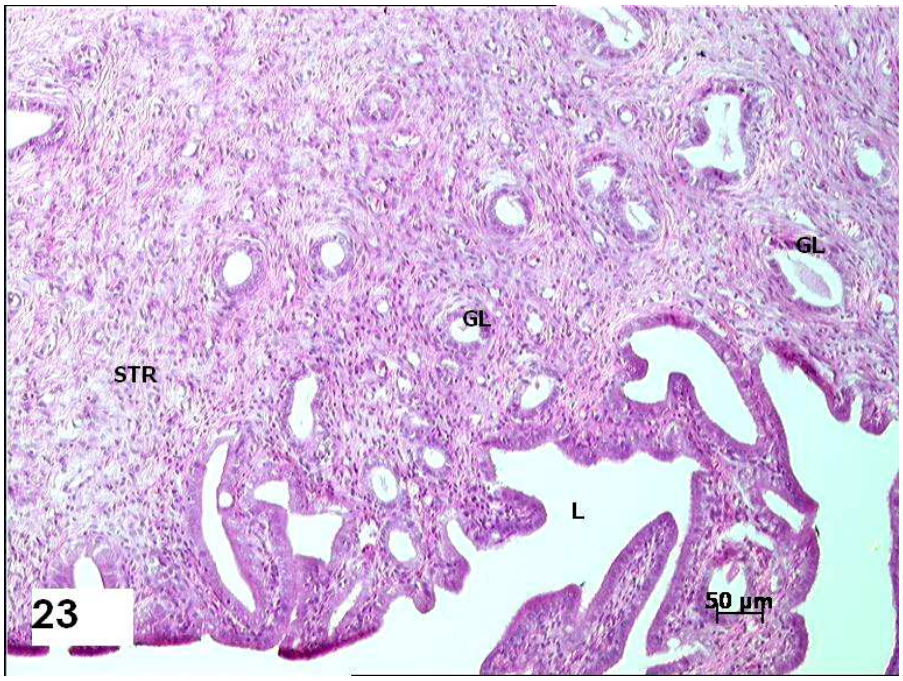
GL
GL
STR
L
50 µm
23

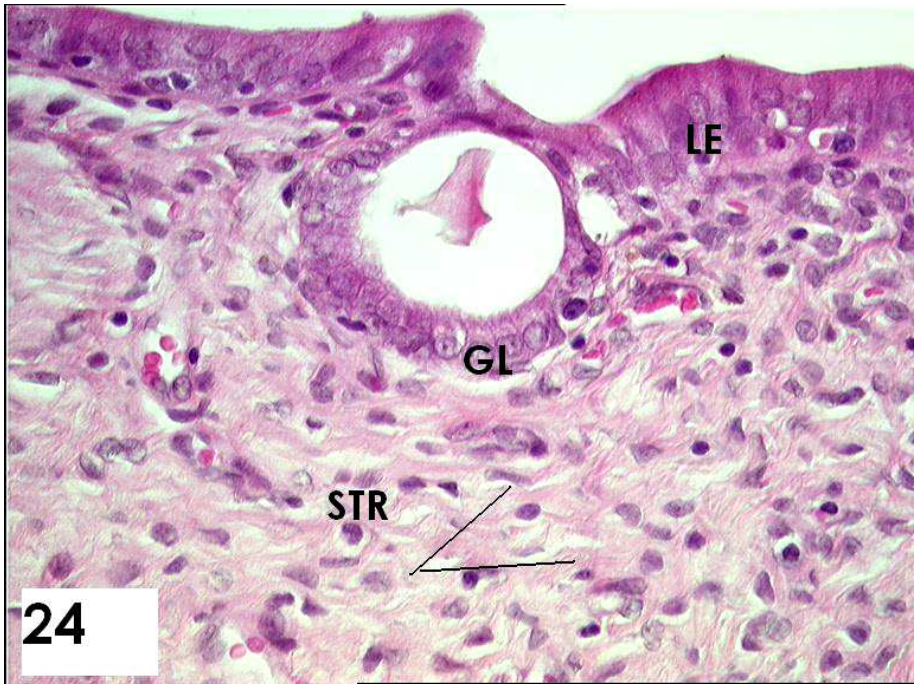
LE
GL
STR
24

Fig. 25: Representative histological section of lung carcinoma tissue incubated with COX2 antibody. Note COX2 immunolocalization in the cytoplasm of the tumorous cells. Counterstained with haematoxylin. x40.

Fig. 26: Representative histological section of 6.5 day hyperstimulated uterine tissue incubated with COX2 antibody, showing immunolocalization to the luminal epithelium (LE) Counterstained with haematoxylin. x40.

Fig. 27a: Representative histological section adjacent to the section showing immunolocalization of 6.5 day hyperstimulated uterine tissue where the primary COX2 antibody was replaced with TRIS. Note the absence of immunolocalization in any compartment of the tissue. Counterstained with Haematoxylin. x40.

Fig. 27b: Representative histological section adjacent to the section showing immunolocalization of 6.5 day hyperstimulated uterine tissue where the secondary antibody was replaced with TRIS. Note the absence of immunolocalization in any compartment of the tissue. Counterstained with Haematoxylin. x40.

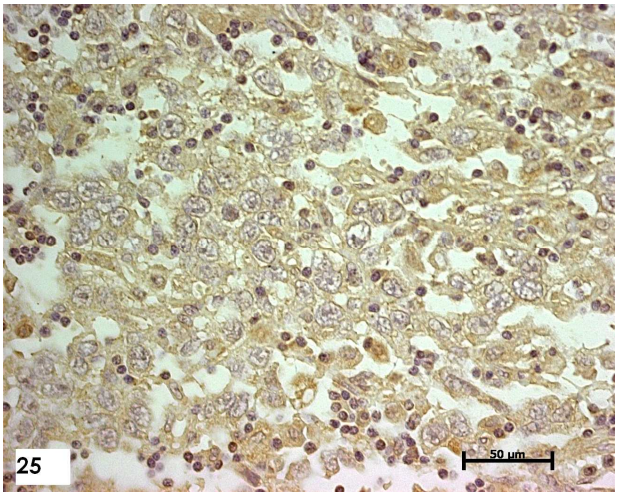
25
50 um


LE
ST
GL
26
50 um

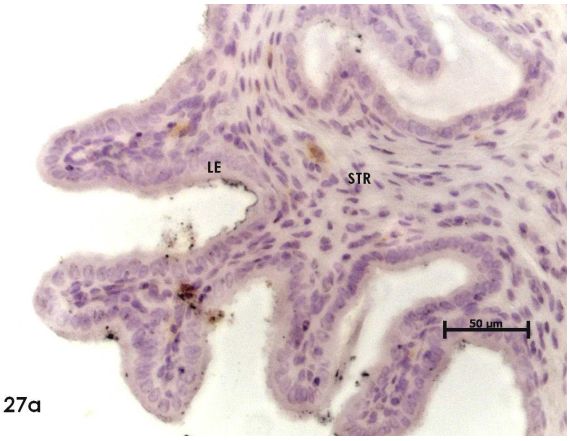
LE
STR
50 um
27a

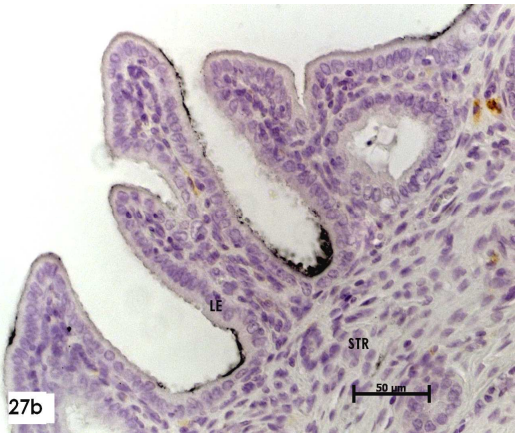
LE
STR
50 um
27b

Fig. 28: Representative histological section of a 4.5 day control uterine tissue. Note immunolocalisation of COX2 in the luminal epithelial cells (LE). Note scanty localization of COX2 in the cytoplasm of the subepithelial stromal cells (straight lines). Counterstained with haematoxylin. x40.

Fig. 29: Representative histological section of a 4.5 day hyperstimulated uterine tissue. Note the strong but variable immunolocalization of COX2 in the luminal epithelial cells (LE). In the glandular cells (GL) scanty immunolocalization is evenly distributed. No localization of the antibody was observed in the subepithelial stromal cells. Counterstained with haematoxylin. x40.

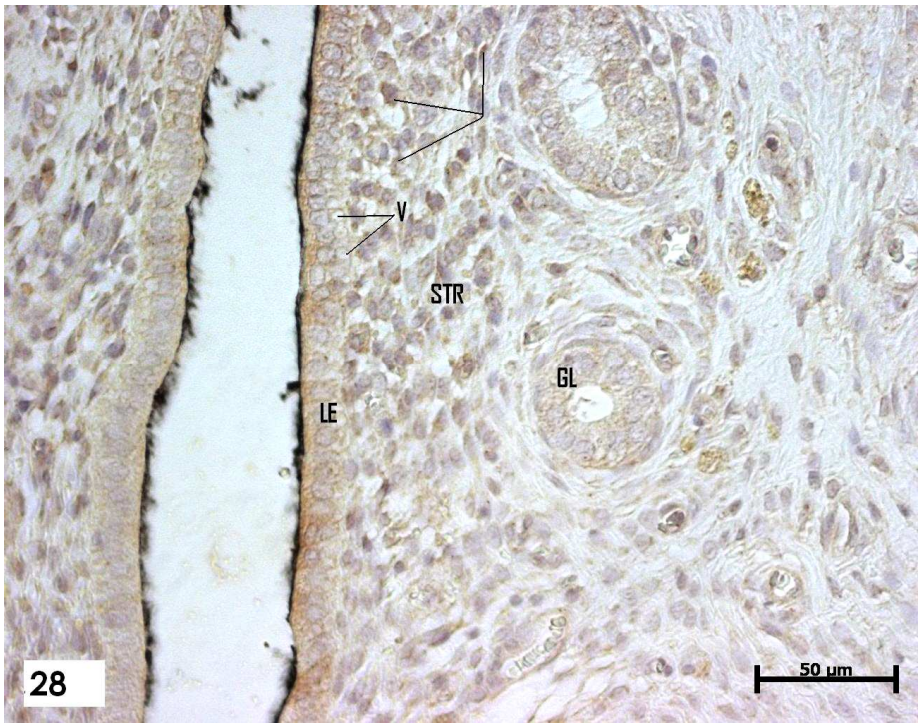
V
STR
GL
LE
28
50 µm

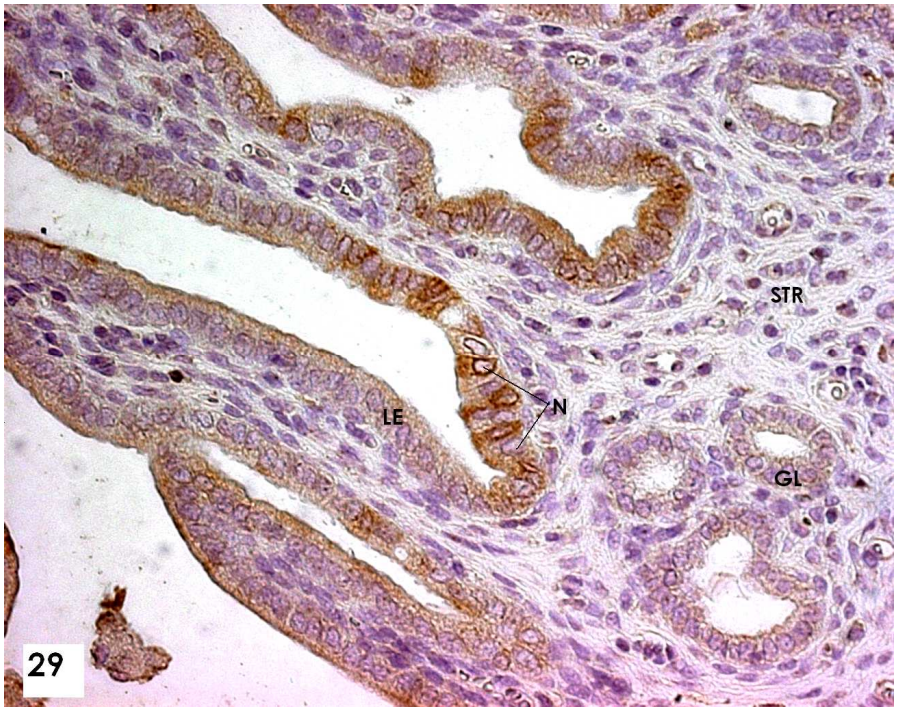
STR
N
LE
GL
29

Fig. 30: Representative histological section of a 5.5 day control uterine tissue. Immunolocalisation of COX2 in the luminal epithelial cells (LE) and glandular cells (GL) is present, but weak. Note irregular COX2 immunolocalization in the subepithelial stromal cells (STR).Cells immediately adjacent to the luminal epithelial cells show intense immunolocalization (straight lines), compared to the cells distant to the luminal epithelial cells. Counterstained with haematoxylin. x40.

Fig. 31: Representative histological section of a 5.5 day hyperstimulated uterine tissue. Note intense but irregular immunolocalization of COX2, predominantly distributed around the nucleus of the luminal epithelial cells (LE). Immunolocalization is evident in the glandular cells, while no localization of the antibody is observed in the subepithelial stromal cells (STR). Counterstained with haematoxylin. x40.

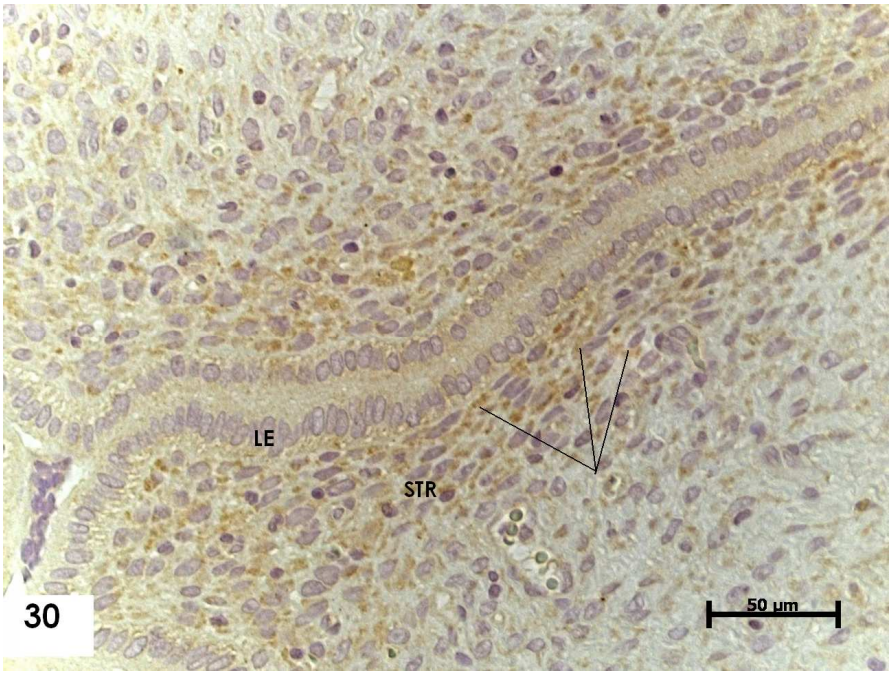
LE
STR
30
50 µm

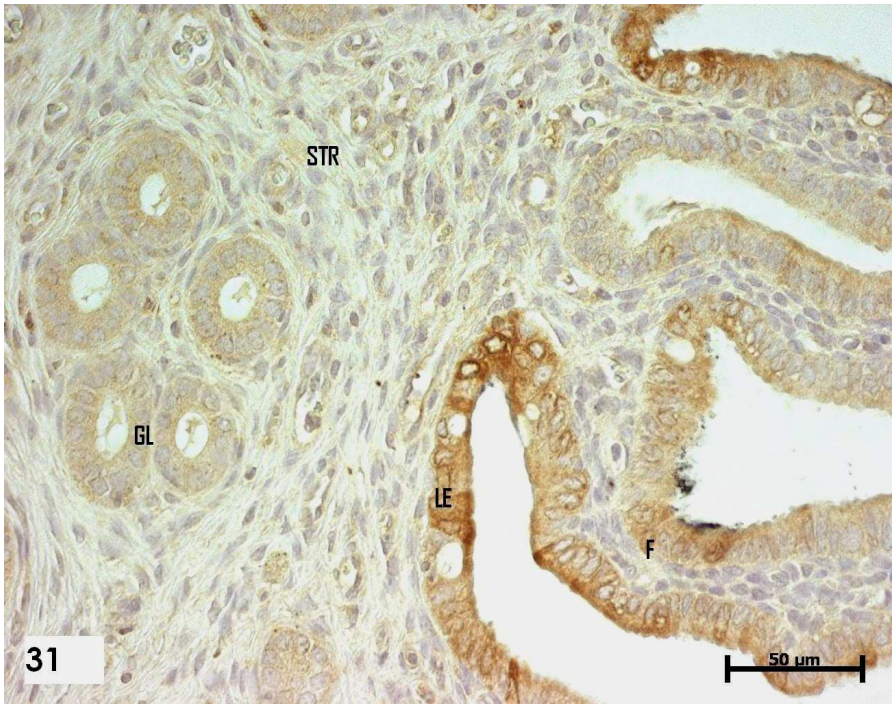
STR
GL
LE
F
31
50 µm

Fig. 32: Representative histological section of the uterus of a 6.5 day control animal. Note that localisation of COX2 was not evident in the cytoplasm of the luminal epithelial cells (LE) at the side of the implanting embryo. The subepithelial stromal cells (STR) in the primary decidual zone showed intense localization of COX2, while stromal cells in the secondary decidual zone distant to the lumen expressed low intensity of COX2 localization. Scanty COX2 immunolocalization was evident in the peripheral cells of embryo (EMB). Counterstained with haematoxylin. x40.

Fig. 33: Representative histological section of the uterus of a 6.5 day hyperstimulated animal. Note intense, but irregular, immunolocalization of COX2 in the luminal epithelial cells (LE). No localization of COX2 is observed in the subepithelial stromal cells (STR). Counterstained with haematoxylin. x40.

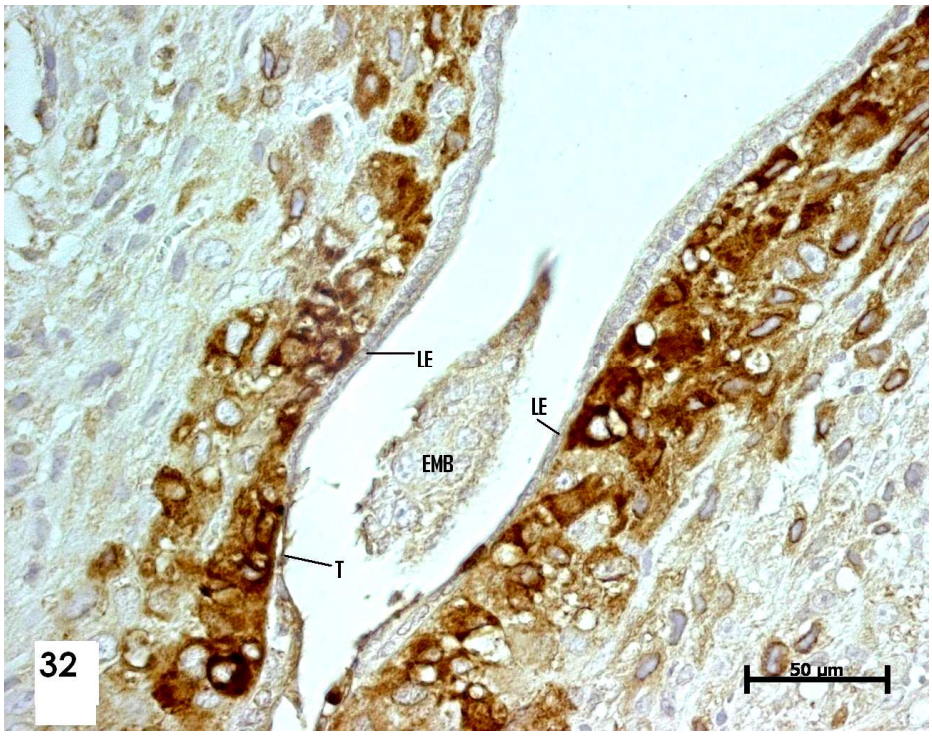
LE
LE
EMB
T
32
50 µm

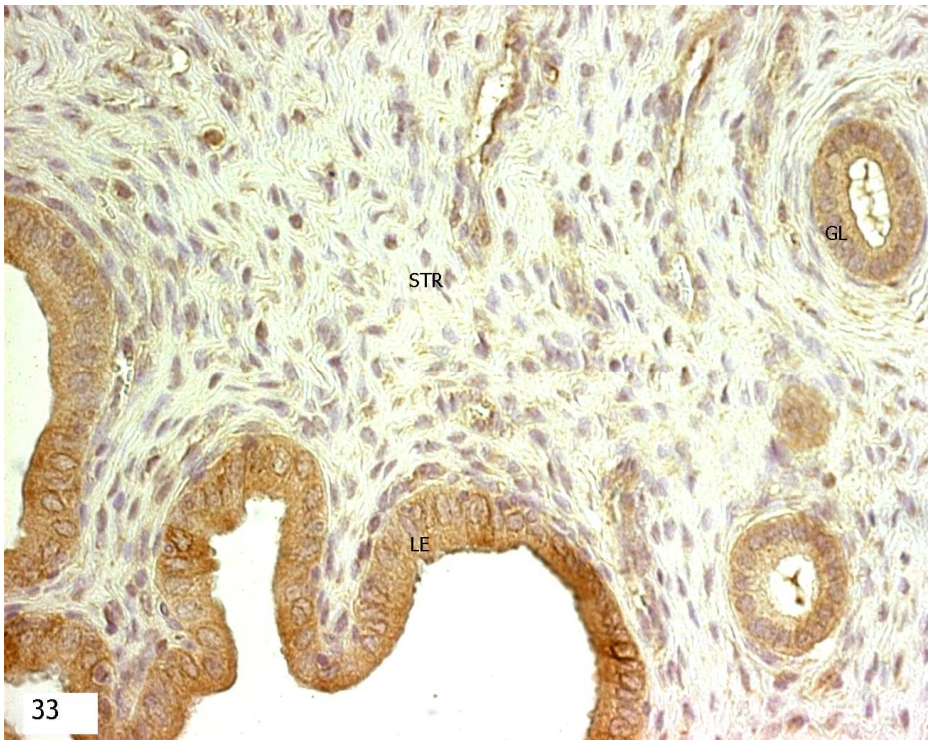
GL
STR
LE
33

Fig. 34: Representative histological section of breast carcinoma tissue. Note immunolocalization of VEGF in the cytoplasm of the tumour cells (TC). Counterstained with haematoxylin. x40.

Fig. 35: Representative histological section of 6.5 day pregnant uterine tissue showing VEGF immunolocalization in the cytoplasm of the stromal cells (STR), no immunolocalization was evident in the luminal epithelial cells (LE). Counterstained with haematoxylin. x40.

Fig. 36a: Representative histological section of the uterus of a 6.5 day control animal adjacent to section in Fig. 32, where the primary VEGF antibody was replaced with TRIS. Note that the luminal epithelial cells and stromal cells are not expressing cytoplasmatic VEGF immunolocalization. Counterstained with haematoxylin. x40.

Fig. 36b: Representative histological section of 6.5 day pregnant uterine tissue adjacent to the section in Fig. 32, where the secondary antibody was replaced with TRIS. Note that the no immunolocalization was evident in any tissue compartment. Counterstained with haematoxylin. x40.

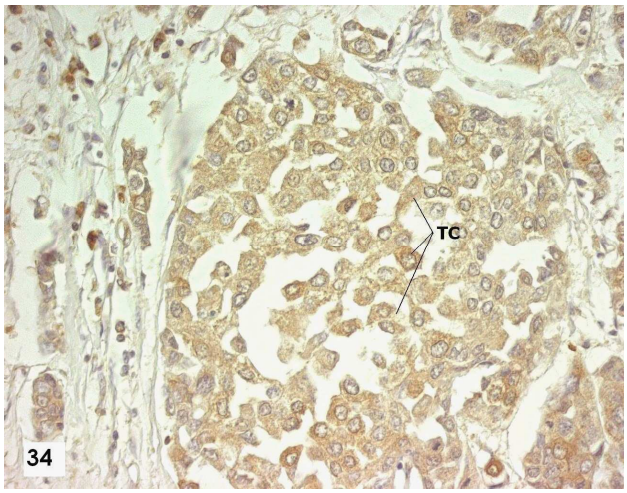
TC
34

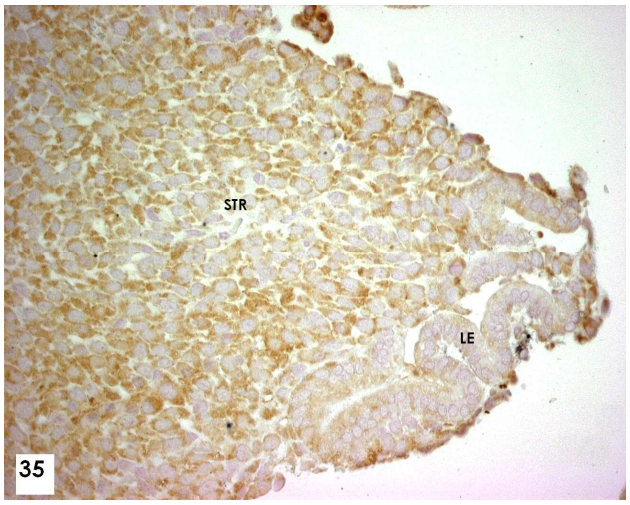
STR
LE
35


LE
STR
36a


STR
LE
50 µm
36b

Fig. 37: Representative histological section of the uterus of a 4.5 day control animal. Note the immunolocalisation of VEGF in the luminal epithelial (LE) cells and glandular cells (GL). Localization of the antibody is also evident in the subepithelial stromal cells (STR). Counterstained with haematoxylin. x40.

Fig. 38: Representative histological section of the uterus of a 4.5 day hyperstimulated animal. Note the immunolocalization of VEGF in the luminal epithelial cells (LE) and the glandular cells (GL), particularly in the apical portion of these cells (straight lines). No localization of the antibody is observed in the subepithelial stromal cells (STR). Counterstained with haematoxylin. x40.

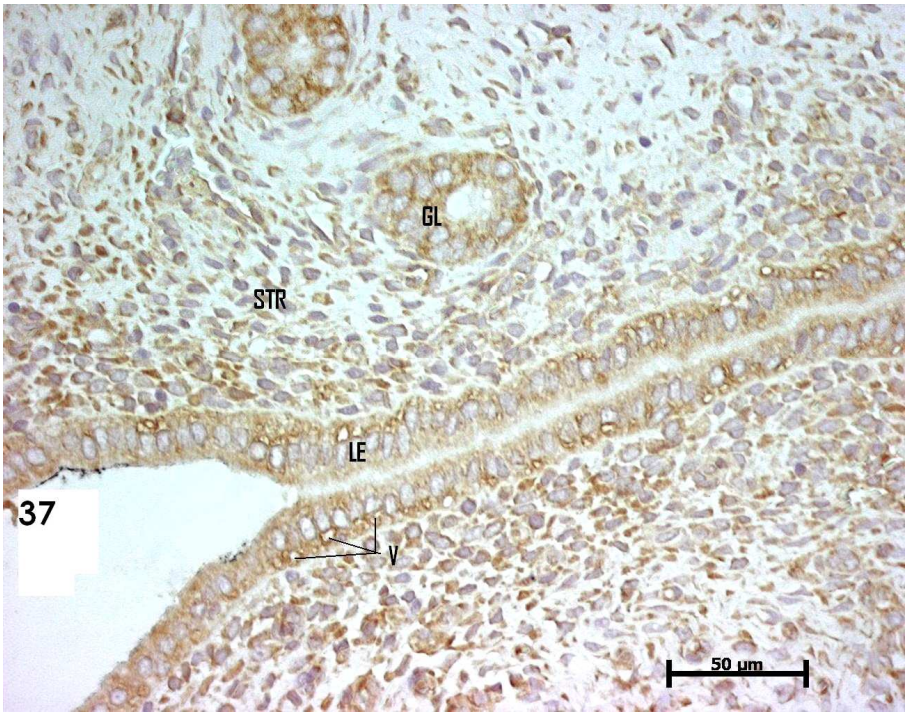
GL
STR
LE
37
V
50 µm

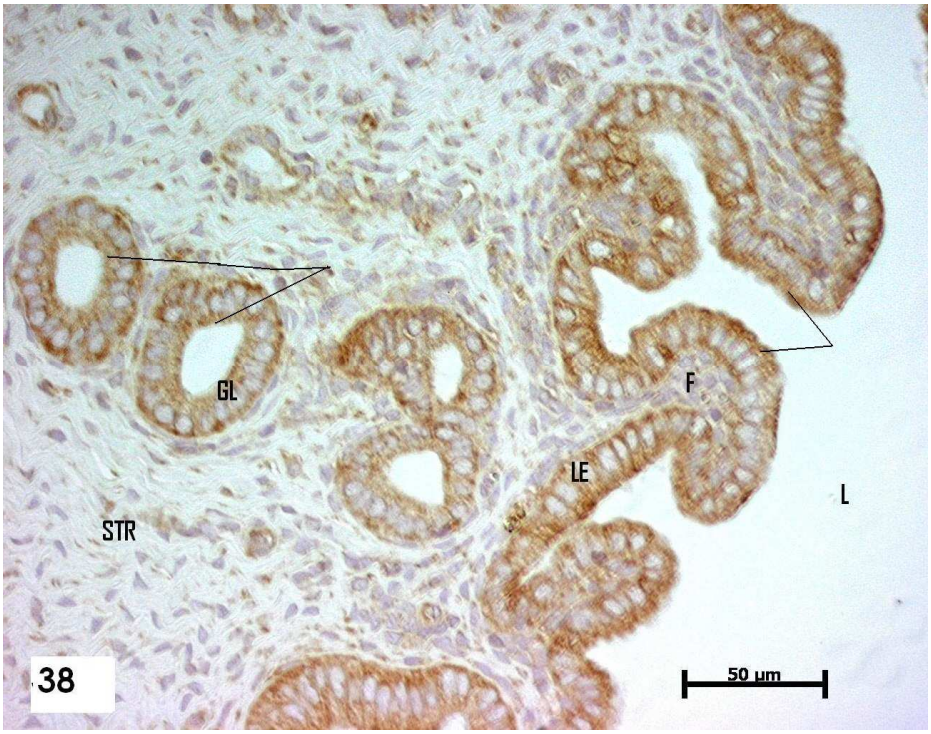
GL
F
LE
L
STR
38
50 µm

Fig. 39: Representative histological section of the uterus of a 5.5 day control animal. Immunolocalisation of VEGF is present in the luminal epithelial cells (LE) and the glandular cells (GL). Note the high intensity of cytoplasmic VEGF localization in the subepithelial stromal cells (STR). Counterstained with haematoxylin. x40.

Fig. 40: Representative histological section of the uterus of a 5.5 day hyperstimulated animal. Note immunolocalization of VEGF in the luminal epithelial cells (LE) and glandular cells (GL), predominantly in the apical portions (straight lines). No localization of VEGF is observed in the subepithelial stromal cells (STR). Counterstained with haematoxylin. x40.

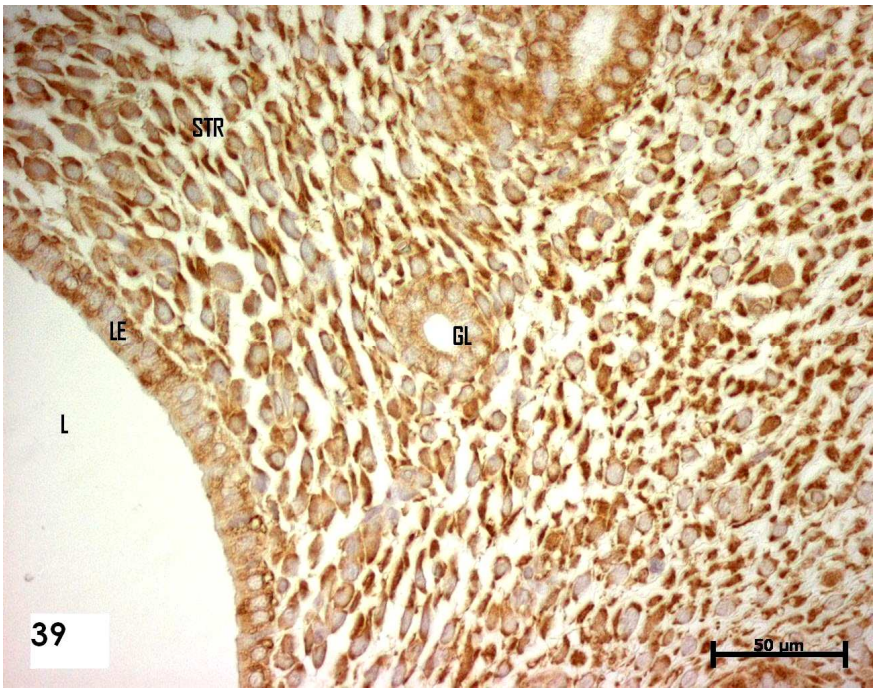
STR
LE
GL
L
39
50 µm

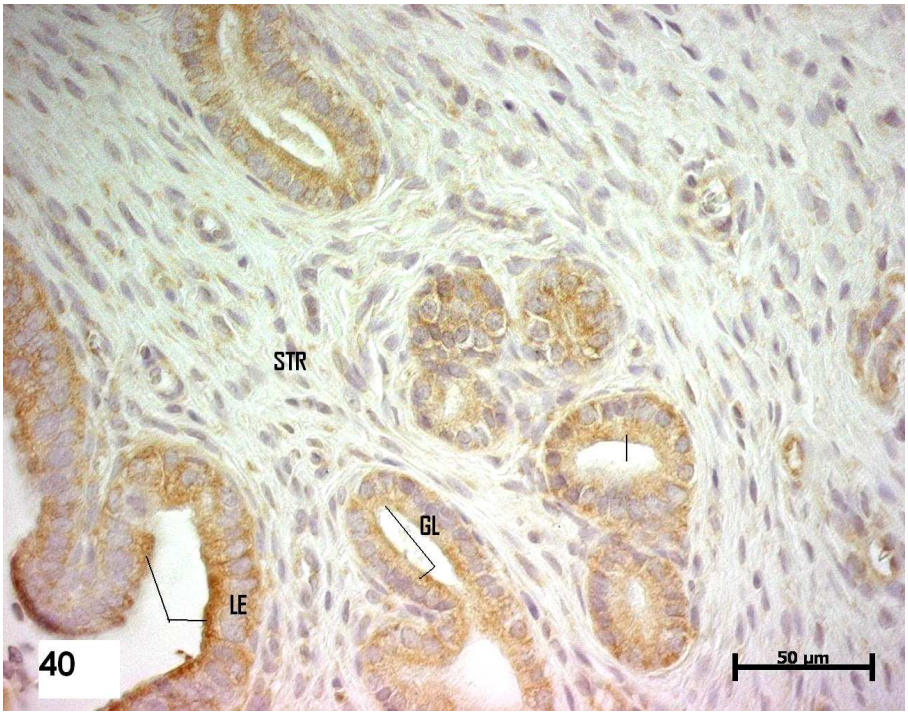
STR
GL
LE
40
50 µm

Fig. 41: Representative histological section of the uterus of a 6.5 day pregnant animal. An embryo (EMB) is visible in the lumen at the antimesometrial side (AMM). Stromal cells immediately adjacent to the luminal epithelial cells (primary decidual zone PDZ) show less VEGF immunolocalization compared to the stromal cells in the secondary decidual zone (SDZ). Counterstained with haematoxylin. x10.

Fig. 42: Representative histological section of the uterus of a 6.5 day control animal. Luminal epithelial cells (LE) do not show VEGF localization. Note scanty cytoplasmatic localization in the decidual cells (DEC) immediately adjacent to the implanting embryo (E). Embryonic cells show high intensity of VEGF immunolocalization. Counterstained with haematoxylin. x40.

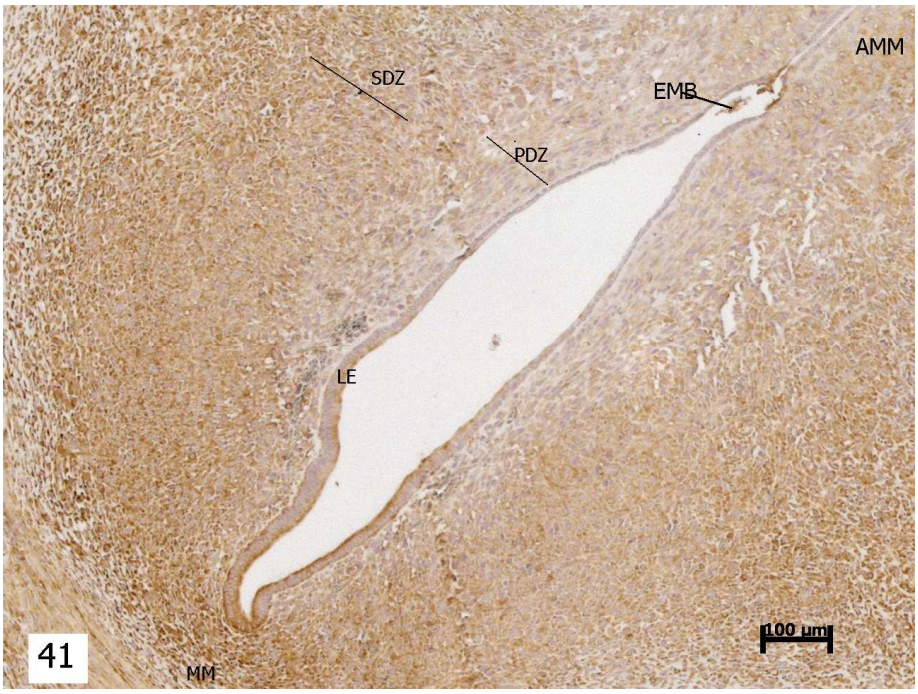
AMM
SDZ
EMB
PDZ
LE
100 µm
41
MM

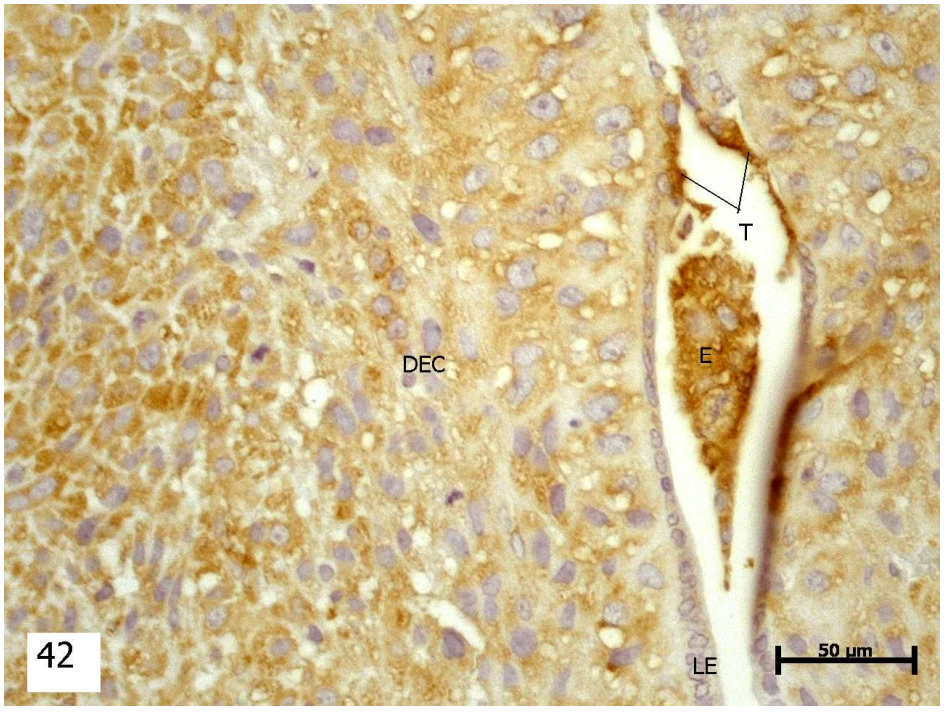
T
DEC
E
42
LE
50 µm

Fig. 43: Representative histological section of the uterus of a 6.5 day hyperstimulated animal. Note numerous folds, lined with the simple columnar epithelium, showing apical VEGF cytoplasmic immunolocalization (straight lines). The immunolocalization is also evident in the glandular cells. Stromal cells are flat and fibroblastic and do not show VEGF immunolocalization. Counterstained with haematoxylin. x40.

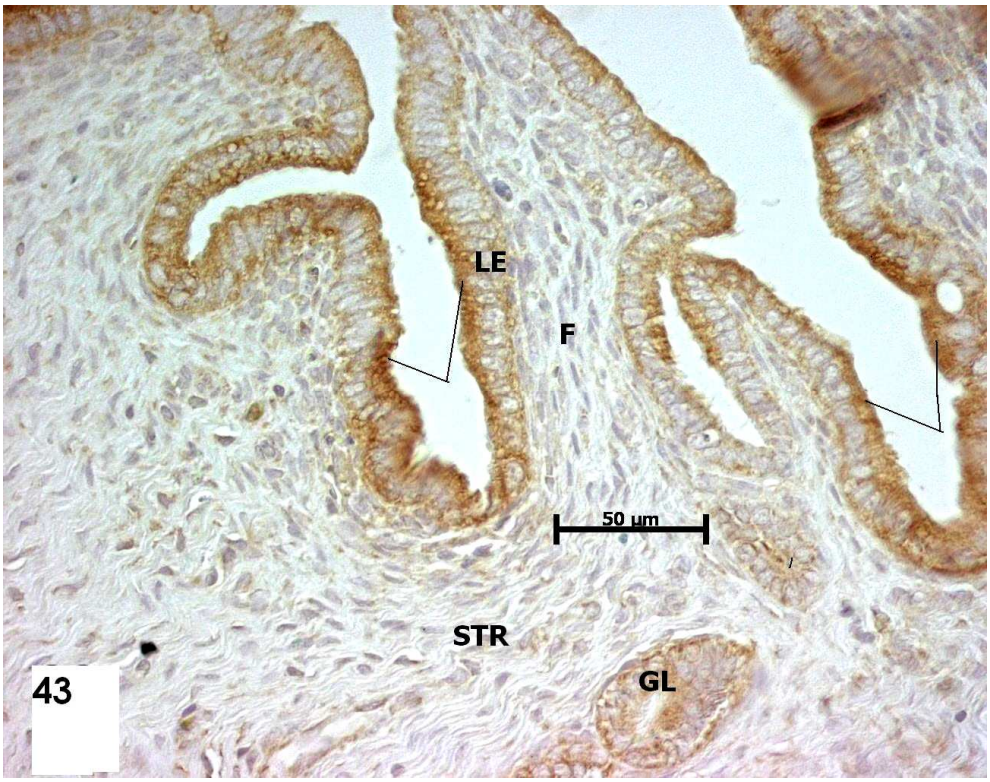
LE
F
50 µm
STR
GL
43



Fig. 44: **Representative gel after protein separation stained with Commasie stain in the different groups of animals.** Lane A was loaded with molecular weight marker (Sigma-Aldrich Co., USA), B= protein extract sample of 6.5 day control rat, C = 6.5 day hyperstimulated rat, D = 5.5 control rat, in E =5.5 day hyperstimulated rat, F = 4.5 day control rat and G = 4.5 day hyperstimulated rat.



Fig. 45: **Nitrocellulose membrane after Western blotting, representing expression of VEGF protein in the rat uterus.** The molecular weight marker confirmed successful transfer from the gel to the membrane.

4.0 DISCUSSION

The ovarian steroids oestrogen and progesterone are crucial in regulating uterine receptivity (Psychoyos, 1973; Carson, 2000; Day *et al.,* 2004). Numerous studies in normal pregnant rodents have shown that preparation of the endometrium during the pre-implantation stage is influenced by progesterone, while blastocyst implantation is initiated by oestrogen (Ljungkvist, 1972; Psychoyos, 1973). However, the low implantation rates in controlled ovarian stimulation [used in *in vitro* fertilization (IVF) and embryo transfer (ET) techniques] are the result of disruption of the synchrony of the hormonal milieu and cause detrimental changes to the uterine morphology. This affects uterine receptivity (Gidley-Baird *et al.,* 1986; Kramer *et al.,* 1990; Stein *et al.,* 1993; Simon *et al.,* 1995, 1998; Bourgain and Devroey, 2003) and expression of implantation related genes (Ma *et al.*, 2003).

4.1 Gross morphological changes in the uterus caused by exogenous hormones

In the present study, superovulation (hyperstimulation) of animals was achieved by administration of exogenous hormones (FSH and hCG), following the work of Kramer *et al.* (1990) and Stein *et al.* (1993). This resulted in the ovaries becoming cystic and enlarged. Exogenous hormones also affected the gross morphological appearance of the uterine horns which appeared markedly dilated in the hyperstimulated animals at 4.5, 5.5 and 6.5 days compared to the control animals. This was in accordance with previous studies by Stein and Kramer (1989) and Kramer *et al.* (1990).

Intravenous injection of a macromolecular blue dye, pontamine blue, results in the appearance of blue bands at the site of the implanting embryos (Psychoyos, 1973). Control animals showed numerous blue bands along the uterine horns at 5.5 and 6.5 days of pregnancy, while in the hyperstimulated animals, blue bands were not observed, indicating failure of vascular permeability and embryo implantation in these animals.

4.2. Oestradiol and progesterone concentrations and the P:E_2 ratio in the control and hyperstimulated animals during the peri-implantation period

In the present study, the oestradiol concentrations increased with the progression of pregnancy in the control animals while, in the hyperstimulated animals an initial rise of oestradiol concentrations from 4.5 days to 5.5 days was followed by a marked decrease at 6.5 days.

Although the oestradiol concentration was higher in the hyperstimulated compared to the control animals at 4.5 days of pregnancy, this was not statistically significant. This was not in agreement with the findings of Kramer *et al.* (1990), where a statistically higher oestradiol concentration was found in the hyperstimulated animals compared to control animals at 4.5 days of pregnancy. While the type of animals and protocols were identical in the study by Kramer *et al.* (1990) and the present study, the differences in these two observations may be due to the different kits used to assess oestradiol concentration. In the present study, an oestradiol ELISA kit was used, while in the study by Kramer *et al.* (1990) a RIA kit was used to measure oestradiol concentrations. In addition, although in both studies the blood samples were obtained from the animals in the morning, slight

difference in timing of obtaining the samples may cause different outcomes. This is due to the variations in timing of implantation that can differ between animals by half a day (Enders, 1975), as well as rapid fluctuations in the hormonal levels during the short peri-implantation period.

The oestradiol concentrations were higher in both the control and hyperstimulated animals at 5.5 days of pregnancy when compared to that at 4.5 days. In addition, the hyperstimulated animals had higher oestradiol concentrations at 5.5 days compared to the animals in the control group on the same day of pregnancy. However, once again, this was not statistically significant. A similar finding was previously reported by Kramer *et al.* (1990), where no statistically significant differences were found in the hyperstimulated compared to the control animals on day 5.5 of pregnancy, although higher oestradiol levels were evident in the hyperstimulated animals. The similarity in the results between the present and the previous study by Kramer *et al.* (1990) may be due to a better correlation in the timing of sample collections from these animals.

Statistically significantly lower oestradiol concentrations in the hyperstimulated animals compared to the control animals at 6.5 days were the result of a marked decrease in the oestradiol concentration in the hyperstimulated animals. In the study by Kramer *et al.* (1990) no statistically significant differences were noted in the hyperstimulated animals at 6.5 days. This does not correspond with the present study. However, again it is possible that some of the animals, due to a difference in timing of sample collection were

in a more advanced phase of pregnancy compared to the animals in the previous study, causing discrepancies in the results between the two studies.

In the control animals, the rise of progesterone concentrations from 4.5 days to 5.5 days of pregnancy, and a slight decrease at 6.5 days of pregnancy was noted. However, in the hyperstimulated animals, the progesterone concentrations increased with the progression of pregnancy. Statistically significantly higher progesterone concentrations were found in the hyperstimulated animals when compared with the control animals at 6.5 days of pregnancy. In a previous study by Kramer *et al.* (1990), progesterone concentrations were measured in the control and hyperstimulated animals from 1.5 to 6.5 days of pregnancy. However, no statistically significant differences in progesterone levels were found at any stage of pregnancy between the control and hyperstimulated animals. Differences in the outcome of the progesterone concentrations in the present study and the previous study by Kramer *et al.* (1990) may be due to the different kits used in these two studies.

It is well established that steroidal hormones, oestrogen and progesterone do not act independently in mediating events in the preparation of the uterus for the blastocyst implantation and establishment of pregnancy (Psychoyos, 1973; Gidley-Beard *et al.,* 1986; Tan *et al.,* 1999). Gidley-Beard *et al.* (1986) proposed that assessing the progesterone:oestradiol ratio ($P:E_2$) could be considered as a better predictor for the success of implantation than assessment of the levels of either hormone. Studies in women attending infertility clinics showed that a higher $P:E_2$ ratio and lower oestradiol

levels were a common appearance in women that became pregnant to those that failed to became pregnant after treatment with the exogenous hormones (Gidley-Beard *et al.,* 1986). Kramer *et al.* (1990) reported a similar finding in the study on the rats treated with exogenous hormones. The lower P:E_2 ratio and higher oestradiol concentrations during the peri-implantation stages of these animals coincided with the suppression of implantation. The control animals however, had higher P:E2 ratio and lower oestradiol concentrations which was accompanied by implantation of numerous blastocysts. The present study is in support of observations by Gidley-Beard *et al.* (1986) and Kramer *et al.* (1990). The control animals had higher P:E_2 ratio and lower oestradiol levels at the time of blastocyst apposition, attachment and initiation of implantation at days 4.5 and 5.5 of pregnancy when compared to the hyperstimulated animals at the same stages of pregnancy. Numerous implantation sites were evident in the control animals at 5.5 and 6.5 days of pregnancy, while no implantation sites were evident in the hyperstimulated animals. At 6.5 days of pregnancy, the hyperstimulated animals had a higher P:E2 ratio and lower oestradiol concentrations when compared to the control animals at 6.5 days of pregnancy. However, implantation sites were observed only in the control animals.

4.3. Uterine receptivity and embryo implantation in the control and hyperstimulated animals

The specific, transient, but unique period of uterine receptivity known as the "window" of implantation is a limited period of time which determines the uterine readiness to accept the blastocyst (Psychoyos, 1973; Day, 1996; Ma *et al.,* 2003). Ma *et al.* (2003) reported that oestrogen at different physiological concentrations can initiate implantation

while, the higher oestrogen concentrations affect the duration of the window of implantation, causing its rapid closure. The window of implantation is also characterized by the morphological features of the receptive uterus, necessary for successful implantation (Enders and Schlafke, 1967; Psychoyos, 1973; Enders, 1975; Kramer *et al.,* 1990).

In the present study at 4.5 days of pregnancy in the control rats, blastocysts were found at the antimesometrial side of the smooth uterine lumen. The luminal fluid was reduced indicated by the luminal walls appearing to be in apposition, closing down around the blastocyst. Reduction of the uterine luminal fluid is associated with uterine receptivity in the rat and dependant on the presence of a blastocyst and appropriate hormonal environment (Lindsay and Murphy, 2006.). Also in the human uterus, embryo attachment is accompanied by the extraction of uterine luminal fluid (Edwards, 1995). These morphological changes in the uterine tissue of the control animals allow trophoblastic cells of the implanting blastocyst to be in close contact with the luminal epithelial cells (Enders and Schlafke, 1967). In the hyperstimulated animals at 4.5 days, the uterine lumen was highly folded and dilated. Luminal dilation in these animals indicated the presence of excessive fluid. High oestradiol and progesterone levels in these animals appear to be the cause of aberrant redistribution of aquaporins (specialized transporters for the fluid in the transcellular fluid transport across cells) causing fluid retention in the uterine lumina of the hyperstimulated animals (Lindsay and Murphy, 2006).

Since the luminal epithelial cells are the site of the attachment of the blastocyst with the uterus, transition of the surface epithelium from the non-receptive to receptive state occurs as remodeling of these cells under the influence of the ovarian hormones (Psychoyos, 1973). The hormonal regulation is mediated through nuclear receptors, the oestrogen receptors α and ß (ER- α and ER- ß) and the progesterone receptor (PR) which exists in two isoforms (Tan *et al.,* 1999). Tan *et al.* (1999) reported proliferation of the luminal epithelial cells under the influence of pre-ovulatory oestrogen which coincides with the expression of the oestrogen receptor α (ER-α) in these cells on day 1 and 2 of pregnancy. A decrease in proliferation and occurrence of differentiation of the luminal epithelial cells, correlated with the expression of ER-α and PR (Tan *et al.,* 1999). Differentiation of these cells is essential for implantation and occurs on day 4 of pregnancy in mice under the influence of progesterone and a nidatory surge of oestrogen (Tan *et al.,* 1999).

In the present study, the simple cuboidal luminal epithelial cells of the control animals at 4.5 days of pregnancy showed morphological features of the receptive epithelium. The luminal epithelial cells contained large, basally placed lipid vacuoles, and their apical portions were covered with short microvilli. These findings were consistent with findings by Enders and Schlafke (1967). Also, Psychoyos and Martel (1985) reported flattening of the microvilli of the luminal epithelial cells around the receptive phase in the normal rat uterus. In contrast, in the hyperstimulated animals the luminal epithelial cells were high columnar and did not contain vacuoles, while microvilli were numerous and appeared longer compared to that of the control animals. With the progression of

pregnancy in the rat uterus, other specializations of the apical portions of the luminal epithelial cells emerge. Ljungkvist (1972) reported flattening of the microvilli and appearance of cytoplasmic projections or "pinopodes" in the rodent uterus. Similar structures are evident in the human uterus by day 18-19 of the menstrual cycle and are present for 24-48 hours (Psychoyos and Martel, 1985). The pinopodes or uterodomes in the human uterus are believed to be involved in the reduction of the luminal fluid (Psychoyos and Martel, 1985). The pinopodes are also considered as specific markers of uterine receptivity (Bagot *et al.,* 2001).

The morphological features of the luminal epithelium of the hyperstimulated animals coincided with the increased oestradiol levels in these animals when compared to the control animals at the same stage of pregnancy. A previous study by Ljunkvist (1972) showed that the microvilli of the luminal epithelial cells increased in length after oestrogen treatment of ovariectomized mice. Williams and Rogers (1980) demonstrated marked reduction in the cytoplasmic lipid droplets in the ovariectomized rat after treatment with oestrogen. Kramer *et al*. (1990) and Stein *et al.* (1993) reported significantly higher epithelium in the hyperstimulated animals at 4.5 days, when higher oestrogen and progesterone levels were recorded. The findings in the present study are consistent with these studies, were, in the hyperstimulated animals, higher oestradiol levels where associated with tall columnar luminal epithelial cells. Cytoplasmic lipid vacuoles were absent from these cells. Therefore the nuclei were not displaced and were basally placed.

The stroma of the 4.5 day control animals was compact, except at the antimesometrial side where a number of cells were rounded and widely separated, indicating tissue oedema. Enders and Schlafke (1967) previously reported similar results, indicating that the subepithelial stroma remains compact in the rat uterus on a day 5 (4.5).

In contrast, the subepithelial stroma of the hyperstimulated animals at day 4.5 remained compact, with flat, fibroblastic cells. Thus, the stroma did not show signs of decidualization. It has been suggested that failure of the stromal cells to decidualise following hyperstimulation is due to the increased levels of oestradiol caused by administration of the exogenous hormones, FSH and hCG (Stein and Kramer, 1987; Fossum *et al.,* 1989; Kramer *et al.,* 1990; Kramer, 1997). Numerous studies of the human endometrium suggest unfavorable, detrimental endometrial changes resulting in low implantation rates under the influence of the exogenous hormones used in assisted reproductive procedures (Testart, 1987; Sterzik *et al.,* 1988; Fossum *et al.,* 1989; Paulson *et al.,* 1990).

At the electron microscopic level in the control rats, well defined fenestrations in, and gaps between, endothelial cells in the uterine thin-walled blood vessels are present in the control animals at 4.5 and 6.5 days of pregnancy, allowing vascular leakage at the site of implantation (Kramer *et al.,* 1993; Kramer, 1997). These are not present in the blood vessels of hyperstimulated animals at the same stages of pregnancy (Kramer *et al.,* 1993; Kramer, 1997). The vascular permeability at the site of implantation can be demonstrated by the injection of the pontamine blue dye, resulting in the formation of the

blue bands along the uterine horns at the site of the implanting blastocyst (Psychoyos, 1973). However, blue bands were not observed in the hyperstimulated and control animals at 4.5 days, except in one control animal where three blue bands were found. The animals were killed on the morning of day 4.5 of pregnancy which is prior to the time given for normal implantation (Enders and Schlafke, 1967; Psychoyos, 1973), and the pontamine blue reaction is not usually found at that time (Enders and Schlafke, 1967). However, the presence of blue bands in an animal at 4.5 days is a possible occurrence, as variation may occur in the time of implantation in different animals (Enders, 1975).

Changes in the uterine morphology under the synchronized release of steroid hormones in the control animals were favorable for blastocyst implantation which resulted in numerous implantation sites in the 5.5 day control animals. This was confirmed by numerous blue stained bands along the uterine horns of the control animals. Routine histology of the uterine tissue of the 5.5 day control animals showed flattening of the luminal epithelial cells at the antimesometrial side of the lumen, together with disappearance of vacuoles in these cells. The nuclei of these cells were irregular in shape. These findings are consistent with the previous findings of Psychoyos (1973) and Parr *et al.* (1987). The microvilli of the luminal epithelial cells at the site of blastocyst implantation were flattened, compared to the microvilli of these cells at the mesometrial side (Enders, 1975; Parr *et al.,* 1987). On the contrary, the histological appearance of the luminal epithelial cells of the hyperstimulated animals at 5.5 day appeared unchanged when compared to that at 4.5 days.

The subepithelial stromal cells around the implanting blastocyst in the control animals at day 5.5 of pregnancy were rounded with large nuclei indicating formation of a distinct decidual zone. The proliferation of the subepithelial stromal cells was previously defined as the primary decidual zone by Day (1996). The stroma of these animals was also highly vascularized and oedematous. However, in the hyperstimulated animals decidualization did not occur and the cells appeared compact as has been previously reported (Stein and Kramer, 1987; Kramer *et al.,* 1990; Kramer, 1997). Observations of the uterine horns did not show blue stained bands after the pontamine blue injection. This indicated the failure of implantation. However, one blue band in each of two hyperstimulated animals at 5.5 days demonstrated possible sites of blastocyst implantation in these animals.

At this stage of pregnancy in the hyperstimulated animals, higher oestradiol and progesterone concentrations were measured compared to that at 4.5 days of hyperstimulation. It has been previously reported that high progesterone levels alone are not inhibitory to implantation. Progesterone can act against the inhibitory effect of high oestradiol levels (Gidley-Baird, 1986). A recent study on the uterus of pseudopregnant mice showed that progesterone supplementation can extend the uterine receptivity through day 6 (Song *et al.,* 2007). However, in the present study, the rise of oestradiol levels together with the rise of progesterone, coincided with the lower P:E_2 ratio when compared to the control animals at 5.5 days. This concurs with the study by Gidley-Baird (1986) who stated that the P:E_2 ratio is a better predictor of the success of the implantation. It has also been shown by Fossum *et al.* (1989), that after embryo transfer

in mice treated with an intraperitoneal injection of pregnant mare's serum gonadotropin and hCG, the implantation rate decreased. The implantation rate was statistically significantly lower in the hyperstimulated mice (8%) compared with 50% in the control mice.

In addition, it appears that the high oestradiol levels at 4.5 days hyperstimulated animals may have caused the premature closing of the "window" of implantation. This may have caused the premature transition of the uterus to a refractory state. Indeed, in the present study the persistent morphology of the uterus in the hyperstimulated animals at 4.5 and 5.5 days of pregnancy showed the features of an unsatisfactory uterine morphology for blastocyst implantation.

In the control animals at 6.5 days of pregnancy, the luminal epithelial cells showed signs of detachment and disappearance at the site of the implanting blastocyst, allowing the trophoblast to invade the stroma. An ultrastructural study of the luminal epithelial cells of mouse and rat embryo implantation sites shows features of apoptosis, rather than of necrosis, of these cells (Parr *et al.,* 1987). The embryos were commonly observed in the elongated implantation region at the antimesometrial side of 6.5 days control rats with the embryonic cell mass facing the mesometrial side of the lumen. Implantation of embryos was followed by extensive stromal decidualization and formation of a secondary decidual zone. Day (1996) defined the secondary decidual zone as a zone of stromal cells proliferation outside the primary decidual zone.

In the hyperstimulated animals at 6.5 days, the histology of the uterus did not show any changes compared to the hyperstimulated animals at the previous stages of pregnancy. However, the hormonal milieu at 6.5 days hyperstimulated animals appeared to be favorable for blastocyst implantation. The oestradiol concentrations dropped significantly while progesterone levels increased when compared to the control animals at the same stage of pregnancy. Even so, the P:E_2 ratio was higher when compared to the previous stages in the hyperstimulated animals and statistically significantly higher when compared to the control animals at 6.5 days. The pontamine blue reaction was not evident in these animals, and the histology of the uterus showed no signs of stromal oedema or decidua formation, indicating failure of fenestration of blood vessels and lack of tissue oedema.

In addition, it has been previously shown that although hyperstimulated animals have typical pregnancy vaginal smears, these animals do not have successful pregnancies and revert to the oestrous cycle after 10 days (Kramer *et al.,* 1990). It is also known that the closing of the window of implantation is followed by the refractory stage, when the uterus is unable to accept the blastocyst. The refractory phase is under the influence of the same hormones (oestrogen and progesterone) which are also responsible for the preparation and initiation of pregnancy (Psychoyos, 1973).

The other reason for implantation failure in the hyperstimulated animals might be the negative effect of raised steroid hormones on the development of the embryos. Previous findings by Stein and Kramer (1989), Kramer *et al*. (1990) and Kramer (1997) also

showed that although hyperstimulated animals did not have blue bands following pontamine blue injection, embryos were present in the lumina of the uterine horns. However, embryos seen in tissue sections of these animals were undeveloped and unattached to the luminal epithelium. Thus, it was possible to flush these unattached embryos out of the uterine horns at 5.5 and 6.5 days of pregnancy (Kramer, 1997). In a study by Ertzeid and Storeng (2001), a significantly lower implantation rate was noted when blastocysts from the hyperstimulated donors were transferred into the control recipient, compared to the transfer of the blastocyst from the control donors.

4.4. COX2 and VEGF expression in the control and hyperstimulated rat uterus

Studies in rodents using either pseudopregnant or knockout animal models have revealed the importance of VEGF and prostaglandins, produced by the COX pathway, in early pregnancy and their effect on vascular permeability and angiogenesis (Kennedy, 1977; Kennedy and Lukash, 1982; Lim *et al.*, 1997; Matsumoto *et al.,* 2002; Chakraborty *et al.,* 1995; Bates and Harper, 2003). However, inhibition of decidualization and vascular permeability under the influence of exogenous hormones, previously reported by Kramer *et al.* (1993) and Kramer (1997) were suggested to be the result of increased levels of oestradiol and progesterone during the peri-implantation in rats. In the present study, it appears that expression and distribution of VEGF and COX2 during the peri-implantation period were also affected in the hyperstimulated animals after the administration of exogenous hormones.

4.4.1. COX2 Immunolocalization in the control and hyperstimulated rat uterus

In the present study, marked differences were evident in COX2 expression in the rat uterus between the control animals at consecutive stages of pregnancy, indicating involvement of COX2 in the regulation of numerous events during the peri-implantation period. However, COX2 immunolocalization did not change substantially in the hyperstimulated animals at consecutive stages of pregnancy and appeared to be severely affected by the administration of the exogenous hormones (FSH and hCG) when compared to the control animals. Western blot analysis did not show any results. After electrophoresis of the protein the band corresponding to the molecular weight marker at 80kD which is the molecular weight of COX2 could not be determined. A reason for this could be that the COX2 protein concentration in the sample was too low to be detected.

Studies in the rodent uterus have shown that prostaglandins produced from arachidonic acid through the COX pathway are implicated in the process of vascular permeability, angiogenesis, as well as adhesion and blastocyst invasion of the stroma during the peri-implantation period (Chakraborty *et al.,* 1996; Lim *et al.,* 1997; Matsumoto *et. al.,* 2002). Two COX isoforms are differently expressed during the peri-implantation period in rodents. At the site of implantation, COX1 expression is more constant and occurs in the rodent uterus prior to implantation. COX2, on the contrary, is up-regulated during inflammation and cellular transformation by various stimuli (Hla and Neilson, 1992, Smith *et al.,* 1994). The expression of COX2 is suggested to be one of the crucial factors during the peri-implantation period in the rodent uterus (Lim *et al.*, 1997; Matsumoto *et al.,* 2002).

In the present study, it appears that the presence of numerous implantation sites during the peri-implantation period of the control rats was the result of the synchronized steroid hormonal release. The routine histology of the normal pregnant uterus showed features of the receptive uterus, while immunohistochemistry showed distribution of COX2, both in the luminal epithelial cells and stroma. In contrast, hyperstimulated rats had higher progesterone and oestradiol concentrations compared to the control animals during peri-implantation period, morphological features of a non-receptive surface epithelium and intense COX2 immunolocalization in the luminal epithelial cells, but not in the stroma.

It is well established that during early pregnancy the attachment reaction is followed by apoptosis of the luminal epithelial cells (Parr *et al.,* 1987; Tsujii and Du Bois, 1995; Carson *et al.,* 2000; Tassell et al., 2000; Zhang and Paria, 2006). At the same time, extensive proliferation and differentiation of the stromal cells occurs to form the decidua (Enders and Schlafke, 1967; Kramer *et al.,* 1990; Kramer, 1997; Carson *et al.,* 2000). In the present study, only light microscopy was used to study the morphology of the uterus. Thus, apoptotic luminal epithelial cells could not be identified. However, the flattening and detachment of luminal epithelial cells noticed in the control animals at 6.5 days of pregnancy, was not evident in the hyperstimulated rats. A previous study by Tsujii and Du Bois (1995) on intestinal epithelial cells, suggests that COX2 over-expression suppresses apoptosis and causes changes in cellular adhesion. The intense COX2 expression in the luminal epithelial cells of the hyperstimulated animals may be considered as over-expression. Over-expression of COX2 may thus have contributed to the unsuccessful implantation of embryos in the hyperstimulated animals. The presence

of unattached embryos in the uterine lumen of hyperstimulated animals, as has been observed in the present study and previous studies by Stein and Kramer (1989), Kramer *et al*. (1990) and Kramer (1997), may be influenced by the over-expression of COX2. Different uterine cells are organized in tissue compartments which are involved in signaling from one compartment to another and are regulated by the steroid hormones, oestrogen and progesterone. It has been previously reported that signaling from the luminal epithelial cells is required to induce the decidual reaction in the stroma (Lejeune, 1981). Lim *et al.* (1997) reported that expression of COX2 mRNA in the luminal epithelial cells of the mouse uterus is important in initiating decidualization. Thus, in the present study, COX2 expression in the luminal epithelial cells of the control animals was indeed followed by initiation of stromal decidualization, seen as rounding of the subepithelial stromal cells. Decidualization however, was not observed in the stroma of the hyperstimulated animals, although intense COX2 immunolocalization in the luminal epithelial cells was evident during the peri-implantation. It appears that over-expression of COX2 may also be inhibitory to stromal decidualization.

Early studies on the rodent uterus suggested an important role for prostaglandins in the initiation of decidualization at the site of implantation (Kennedy, 1977; Kennedy and Lukash, 1982). It has been previously reported that treatment with indomethacin (an inhibitor of prostaglandin biosynthesis) at the time of implantation, can cause a delay in implantation (Kennedy, 1977). In the same study, it was noted that the concentrations of prostaglandins were significantly higher in the implantation sites of control, compared to implantation sites of the indomethacin-treated animals at day 5 of pregnancy (Kennedy,

1977). Later, Kennedy and Lukash (1982) showed that after the initial decidualization, prostaglandin levels decreased, indicating that decidual growth did not require high prostaglandin levels. Studies on COX2 knock-out mice showed that artificial decidualization does not occur after intraluminal oil infusion on day 4 of pseudopregnancy, even if the physiological steroidal regime is provided (Lim *et. al.*, 1997). This suggests that COX2 may be one of the crucial mediators for blastocyst implantation.

Decidualization failure in the hyperstimulated animals coincided with the rise of oestradiol and progesterone at 5.5 days of pregnancy, the lower P:E_2 ratio compared with the control animals and the absence of COX2 immunolocalization in the stromal cells. Previously, Hewitt *et al.* (2002) showed that initial COX2 induction is hormone independent, while its later induction is dependant on both progesterone and oestrogen priming. Chakraborty *at al.* (1996) stated that COX1 gene expression is influenced by ovarian hormones, while the COX2 gene expression is hormone independent and regulated by the implanting blastocyst. However, in the present study it appears that higher concentrations of oestradiol and progesterone inhibited stromal COX2 expression thus the stroma did not show signs of decidualization in the hyperstimulated animals. Ma *et al.* (2003) indeed showed aberrant expression of the COX2 gene at higher oestrogen levels in pseudo-pregnant mice. Injection of a high dose of oestrogen on day 7 immediately after blastocyst transfer did not change the normal expression of the COX2 gene within a 24 h period. However, the COX2 gene could not be detected after 24 hours

of injection of the high oestrogen dose, and aberrant expression of other implantation-related genes were also noted (Ma *et al.,* 2003).

The regulation of COX2 expression is also regulated by the presence of the blastocyst in the uterine lumen (Chakraborty *at al.*, 1996). However, although embryos were observed in hyperstimulated animals in the present and previous studies, the embryos were not attached to the surface epithelium and the stroma did not show decidualization and COX2 immunolocalization. Thus, it can be concluded that not only the presence of the blastocysts in the uterine lumen, but attachment to the surface epithelium is required for the regulation of COX2 expression and initiation of decidualization of the stroma.

Intense COX2 immunolocalization was also observed in the luminal epithelial cells of the hyperstimulated animals at 6.5 days. However, the higher P:E_2 ratio of these animals and statistically significantly lower oestradiol concentration when compared to the control animals at the same stage of pregnancy, did not allow for the induction of decidualization and COX2 immunolocalization in the stromal cells. Thus, it appears that not only expression, but rather optimal expression of COX2 in the luminal epithelial cells is required to induce decidualization of the stroma. It is also possible that the refractory state of the uterus induced at the earlier stages of pregnancy at 4.5 and 5.5 days at higher oestradiol and progesterone concentrations, was not converted to the receptive state with the improved hormonal environment in the hyperstimulated animals at day 6.5.

Kennedy and Lukash (1982) reported an increase in vascular permeability in the rat uterus in response to prostaglandin infusion. In the present study, blue stained bands as a

result of vascular permeability were present along the uterine horns of the control animals at 5.5 and 6.5 days of pregnancy. In addition, routine histology of the uterine sections of the control animals at the same days of pregnancy showed spaces between decidual cells indicating stromal oedema. COX2 was immunolocalized in the cytoplasm of these decidual cells, at the antimesometrial side, indicating an influence of COX2 on vascular permeability and tissue oedema at the site of implantation. Chakraborty e*t al.* (1996) reported COX2 gene expression in the luminal epithelium and subepithelial stroma at the antimesometrial side of the mouse uterus on day 4 and day 5 of pregnancy. Chakraborty e*t al.* (1996) suggested that the mesometrial COX2 gene expression on day 6 of pregnancy facilitated the establishement of the placenta. Intense cytoplasmic COX2 immunolocalization in the subepithelial stromal cells adjacent to the implanting embryo at day 6.5 in the present study differs from the study by Chakraborty e*t al.* (1996). In the present study the rat uterus was used while Chakraborty e*t al.* (1996) used mouse uterus for their experiment, which could be the reason for the discrepancies in the observations between the two studies.

Evidence that prostaglandins are important inducers of vascular permeability has been confirmed in studies on mutant mice. Matsumoto *et al.* (2002) reported poor vascular permeability at the site of blastocyst apposition in COX2 deficient mice, proposing that fenestration of the uterine vessels had not occurred. In the present study in control rats numerous blood vessels were observed in the stroma, surrounded by the decidual cells, particularly at 5.5 and 6.5 days of pregnancy. In contrast, the non-decidualized and compact stroma of the hyperstimulated animals did not show a rich blood supply.

Numerous studies on mutant mice have shown a crucial role for COX2 during the peri-implantation period. COX2 deficient mice show multiple reproductive failures, causing infertility of these animals (Lim *et al.*, 1997). However, recent study by Cheng and Stewart (2003) argued these statements by showing a delay but not inhibition of implantation after the blastocyst transfer in COX2-deficient mice. These results are in support of the theory that COX2 mediates the initial decidual response, but negates the importance of COX2 in further decidual growth and embryo development. Cheng and Stewart (2003) suggested the importance of COX2 as an inducer of the expression of other mediators of decidualization and vascular permeability, such as VEGF.

4.4.2. VEGF Immunolocalization in the control and hyperstimulated rat uterus

In the present study, closure of the uterine lumen around the blastocysts and supepithelial stromal oedema in the control animals at 4.5 days, coincided with VEGF expression in the luminal and glandular epithelial cells and rounded subepithelial stromal cells at the antimesometrial side of the lumen. In contrast, the subepithelial stroma of the hyperstimulated animals was compact and the uterine lumen highly folded and dilated. VEGF was immunolocalized to the luminal epithelial and glandular cells, but not localized to the stroma. Western blot did not show any results.

Studies on the normal mouse uterus have shown VEGF localization in the luminal epithelial cells and stroma on day 4 of pregnancy (Chakraborty *et al.,* 1995). VEGF was thus suggested to be the signal for generalized vascular permeability in the stroma prior to implantation (Chakraborty *et al.,* 1995).

VEGF is a crucial mediator for vascular permeability during the peri-implantation in rodents and humans (Cullinan-Bove and Koos, 1993; Chakraborty *et al.,* 1995; Hyder *et al.,* 1996) and a promoter of angiogenesis (Ferrara, 1996; Matsumoto *et al.,* 2002; Krussel *et al.,* 2003). In addition, it is also well established that vascular permeability and angiogenesis are hormonally regulated in the reproductive system of rodents and humans (Shweiki *et al.,* 1993; Hyder and Stancel, 1999; Perrot-Applanat *et al.,* 2000; Ma *et al.,* 2001). Ma *et al.* (2001) have shown that oestrogen induces vascular permeability which coincides with the expression of VEGF, while oestrogen is also responsible for inhibiting angiogenesis. In addition it has been shown that VEGF receptors Flk-1/KDR are up-regulated by VEGF in the absence of a direct oestrogen effect (Harve *et al.,* 2006). Progesterone has little effect on vascular permeability but stimulates uterine angiogenesis (Ma *et al.,* 2001; Walter *et al.,* 2005).

Hyder *et al.* (1996) stated that the stroma with the highest blood vessel density in the uterus responds with massive oedema after hormone treatment. Also, isolated stromal cells express increased VEGF mRNA after treatment with a physiological concentration of oestrogen or both oestrogen and progesterone (Perrot-Applanat *et al.,* 2000). Hyder (2002) stated that the VEGF is up-regulated at the low oestrogen concentrations in the rat uterus. In the human uterus oestradiol up-regulates all VEGF isoforms (Bausero *et al.,* 1998). Srivastava *et al.* (1998) stated that progesterone does not alter expression of VEGF, while Ancelin *et al.* (2002) have shown up-regulation of the $VEGF_{189}$ isoform in the human uterus under the influence of progesterone.

In the present study, the nidatory oestradiol surge in the control animals at 4.5 days indeed induced stromal vascular permeability which coincided with epithelial and stromal VEGF immunolocalization. However, it appears that increased oestradiol levels inhibited VEGF expression and vascular permeability in the stroma of the hyperstimulated animals. It is more likely that the high oestradiol levels in these animals altered morphology of the uterus which was unsatisfactory for the blastocyst implantation, while suppression of VEGF in the stroma of these animals may be a result of aberrant COX2 expression at the site of implantation. This finding is in agreement with Cheng and Stewart (2003) who suggested that COX2 may be essential for VEGF expression. Thus, the aberrant COX2 expression on 4.5 days in the hyperstimulated animals, may have failed to induce VEGF stromal expression and resulted in the suppression of the fenestration of the thin blood vessels as reported by Kramer (1997).

The other possibility for the failure of the stromal VEGF expression and decidualization might be that the predominant VEGF isoforms in the rodent uterus ($VEGF_{120}$ and $VEGF_{164}$) exist as secreted forms (Houck *et al.,* 1991). Since VEGF immunolocalization was most predominantly found in the apical portions of the luminal and glandular epithelial cells of the hyperstimulated animals at all consecutive stages of pregnancy, it is possible that VEGF produced in these cells was secreted into the lumen and did not act on the stroma to induce vascular permeability.

It has also been shown that human blastocyst expresses mRNA encoding for the free VEGF proteins which induces vascular permeability at the implantation site (Krussel et

al., 2001). It was suggested that only the free VEGF isoforms are able to induce angiogenesis at the implantation site and be involved in the process of embryo implantation (Krussel *et al.,* 2001). VEGF was also detected in the giant trophoblast cells and early yolk sac (Jakeman *et al.,* 1993).

In the present study, implanting embryos of control animals at 6.5 days showed VEGF immunolocalization. This coincided with VEGF immunolocalization in the decidual cells of the subepithelial stroma. The VEGF was also strongly expressed in the cells adjacent to the stroma and implanting blastocyst which appeared to be the trophoblastic cells. This was consistent with the study by Jakeman *et al.* (1993). However, in the hyperstimulated animals at 6.5 days, blastocysts present in the lumen were not attached to the luminal epithelium. Decidualization of the stromal cells was not evident and these cells did not show VEGF immunolocalization. It appears that the initiation of the stromal VEGF expression may require the presence of the implanting embryos.
The observations in the present study are also in support to the previous observations that non-decidual stromal cells do not express VEGF (Srivastava *et al.,* 1998).

It has been previously reported that the subepithelial stroma is the most potent region for the micro-vessel growth in the rodent uterus (Shweiki *et al.,* 1993). The primary decidual zone immediately surrounding the implanting blastocyst expressed scanty VEGF immunolocalization, while intense VEGF localization was evident on the mesometrial side and in the secondary decidual zone in the control animals on day 6.5. The present study is in support to the observation by Shweiki *et al.,* (1993), as numerous blood

vessels were observed in the primary decidual zone in the control animals at 6.5 days of pregnancy. It appeared that the intense VEGF immunolocalization in the primary decidual zone at the previous stages of pregnancy, particularly at 5.5 days at the antimesometrial side facilitated angiogenesis and development of new blood vessels. Cessation of VEGF expression in the primary, but more intense expression in the secondary decidual zone and at the mesometrial side observed in the present study, may have been induced by extensive decidualization at these sites. Vascular permeability and angiogenesis failed to occur in the hyperstimulated animals at 6.5 days which was confirmed by the compact appearance of the stroma and fewer blood vessels, when compared to the control animals at the same stage of pregnancy.

The biological response of VEGF is achieved by it binding to transmembranous tyrosine kinase receptors (Ferrara, 1996). Also, VEGF binds to the heparin-sulfate proteoglycans on the cell surfaces or extracellular matrix, necessary to induce release of other angiogenic factors, such as basic fibroblast growth factor (bFGF) (Krussel *et al.,* 2001). It is thought that VEGF and bFGF have synergistic effects in induction of endothelial cell proliferation and angiogenesis (Srivastava *et al.,* 1998). In the human uterus, $VEGF_{121}$ splice variant is unable to bind to the extracellular matrix, due to absence of the exons 6 or 7 which contain heparin-binding domains (Krussel *et al.,* 2001). Thus, failure of the stromal oedema and vascular permeability in the hyperstimulated rats may be explained by an inability of $VEGF_{120,}$ one of the most predominant splice variants in the rodent uterus, to bind to the extracellular matrix and induce secretion of bFGF.

Decidualization requires an increased oxygen supply for the survival of the newly formed cells (Diakoku *et al.,* 2003). A strong correlation exists between hypoxia and VEGF expression in physiological angiogenesis (Bates and Harper, 2003; Daikoku *et al.,* 2003; Ryzhov *et al.,* 2007). It is also known, that a reduction in oxygen concentration below 2% induces VEGF mRNA in many cell types (Zhang *et al.,* 1998). Thus, it is possible that hypoxia occurred causing strong VEGF immunolocalization at the mesometrial side and in the secondary decidual zone in the uterus of the control animals at 6.5 days which may have induced vascular permeability and angiogenesis. Chakraborty *et al.* (1995) suggested that VEGF expression at the mesometrial side in uteri of mice on day 5 of pregnancy contributes to angiogenesis for the establishment of the placenta.

In addition to the detrimental change in the uterine morphology as a result of raised oestradiol concentrations, the ovarian hyperstimulation syndrome (OHSS) is a severe complication following treatment with gonadotrophins. VEGF is implicated in the pathogenesis of OHSS due to its effect on vascular permeability (Garcia-Velasco *et al.,* 2004) and through the mediation of hCH on the up-regulation of VEGF (Wang *et al.,* 2002). The ovary is the main source of VEGF (Garcia-Velasco *et al.,* 2004). The fact that VEGF is produced by stimulation of both FSH and hCG, which are used in IVF and ET techniques, emphasizes the importance of balanced, or even decreased doses of these hormones in order to prevent the risk of OHSS. This may allow for successful superovulation and a favorable uterine environment for blastocyst implantation.

5.0 CONCLUSION

Superovulation was achieved by the administration of the exogenous hormones, FSH and hCG. Administration of the exogenous hormones altered the physiological levels of oestrogen and progesterone at the time of preparation of the uterus for blastocyst implantation. The increased oestrogen levels in the hyperstimulated animals at the time of implantation had deleterious effects on the morphology of the uterus which resulted in failure of blastocyst implantation. In addition, the exogenous hormones had a negative effect on the expression and distribution of VEGF and COX2 in the uterine tissue during the peri-implantation period. Thus it appears that numerous factors are important and need to be synchronized for implantation to occur.

In order to further understand the complexities of assisted reproduction, it is necessary to investigate other molecules and factors that are involved in this process. In addition, although experiments on the ovariectomized rodents provide invaluable information regarding the effects of assisted reproductive techniques on the the peri-implantation period, validation of these results should be carried out superimposed on the normal hormonal milieu of intact animals. The findings of these studies may thus provide safe and successful implantation in assisted reproductive procedures in the future.

REFERENCES

1. Adams, S.A., Terry, V., Hosie, M.J., Gayer, N., Murphy, C. 2004. Endometrial response to IVF hormonal manipulation: Comparative analysis of menopausal, down regulated and natural cycles. *Reproductive Biology and Endocrinology,* 2, 21-37.
2. Ancelin, M., Buteau-Lozano, H., Meduri, g., Osborne-Pellegrin, M., Sordello, S., Plouet, J., Perrot-Aplanat, M. 2002. A dynamic shift of VEGF isoforms with a transient and selective progesterone-induced expression of VEGF 189 regulates anfiogenesis and vascular permeability in human uterus. *Proceedings of the National Academy of Sciences USA*, 99, 6023-6028.
3. Bagot, C. N., Kliman, H. J., Taylor H. S. 2001. Maternal Hoxa10 is required for pinopod formation in the development of mouse uterine receptivity to embryo implantation. *Developmental Dynamics*, 222, 538-544.
4. Bancroft, J.D., Gamble M. (eds.) 2002. Theory and Practice of Histological Techniques. 5th edition. London: Churchill Livingstone.
5. Bany, B.M., Kennedy, T. G. 1997. Regulation of cyclooxygenase gene expression in rat endometrial stromal cells: the role of epidermal growth factor. *Developmental Genetics,* 21, 109-115.
6. Bates, D.O., Harper, S.J. 2003. Regulation of vascular permeability by vascular endothelial growth factor. *Vascular Pharmacology,* 39, 225-237.
7. Bausero, P., Freitas, S., Meduri, G., Perrot-Applanat, M. 1998. Paracrine action of VEGF in the human endometrium: regulation by ovarian steroids. *Angiogenesis,* 2, 167-182.

8. Boenisch, T. (ed.) 2001. *Imunochemical Staining Methods*. 3rd edition. Carpinteria: DAKO Corporation.

9. Bourgain, C., Devroey, P. 2003. The endometrium in stimulated cycle for IVF. *Human Reproduction Update,* 9, 515-522.

10. Breyer, R.M., Kennedy, C.R.J., Zhang Y., Breyer M.D. 2000. Structure-function analyses of eicosanoid receptors: physiological and therapeutic implications. *Annals of New York Academy of Science,* 905, 221-231.

11. Carmeliet, P., Ferreira, V., Breier, G., Pollefeyt, S., Kieckens, L., Gertsenstein, M., Fahrig, M., Vendenhoeck, A., Harpal K., Eberhardt, C., Declercq, C., Pawling, J., Moons, L., Collen, D., Risau, W., Nagy, A. 1996. Abnormal blood vessel development and lethality in embryos lacking a single VEGF allele. *Nature,* 380, 453-439.

12. Carson, D.D., Bagchi, I., Dey, S.K., Enders, A.C., Fazleabas, A.T., Lessey, B.A., Yoshinaga, K. 2000. Embryo implantation. *Developmental Biology,* 223, 217-237.

13. Chakraborty, I., Das, S.K., Dey, S.K. 1995. Differential expression of vascular endothelial growth factor and its receptor mRNAs in the mouse uterus around the time of implantation. *Journal of Endocrinology*, 147, 339-352.

14. Chakraborty, I., Das, S.K., Wang, J., Dey, S.K. 1996. Developmental expression of the cyclo-oxygenase-1 and cyclo-oxygenase-2 gene in the peri-implantation mouse uterus and their differential regulation by the blastocyst and ovarian steroids. *Journal of Molecular Endocrinology,* 16, 107-22.

15. Chen, J.R, Cheng, G., Shatzer T., Sewell, L., Hernandez, L., Stewart, C.L. 2000. Leukemia inhibitory factor can substitute for nidatory oestrogen and is essential to

inducing a receptive uterus for implantation but is not essential for subsequent embryogenesis. *Endocrinology,* 141, 4365-4372.

16. Cheng, J., Stewart, C.L. 2003. Loss of cyclooxygenase-2 retards decidual growth but does not inhibit embryo implantation or development to term. *Biology of Reproduction, 68,* 401-404.
17. Coffin, D., Poole, T.J. 1988. Embryonic vascular development: immunohistochemical identification of the origin and subsequent morphogenesis of the major vessel primordial in quail embryos. *Development,* 102, 735-748.
18. Cullinan-Bove, K., Koos, R. 1993. Vascular endothelial growth factor/vascular permeability factor expression in the rat uterus: rapid stimulation by estrogen correlates with estrogen-induced increases in uterine capillary permeability and growth. *Endocrinology*, 133, 829-837.
19. Daikoku, T., Matsumoto, H., Gupta, R.A., Das, S.K., Gassmann, M., DuBois, R.N., Dey, S.K. 2003. Expression of hypoxia-inducible factors in the peri-implantation mouse uterus is required in a cell-specific and ovarian steroid hormone-dependent manner. *The Journal of Biological Chemistry*, 278, 7683-7691.
20. Das, S.K., Wang, J., Dey, S.K., Mead, R.A. 1999. Spatiotemporal expression of cyclooxygenase1 and cyclooxygenase 2 during delayed implantation and the periimplantation period in the western spotted skunk. *Biology of Reproduction*, 60, 893-899.
21. Demir, R., Kayisli, U.A., Seval, Y., Celik-Ozenci, C., Korgun, E.T., Demir-Weusten, A.Y., Huppertz, B. 2004. Sequential expression of VEGF and its

receptors in human placental villi during very early pregnancy: differences between placental vasculogenesis and angiogenesis. *Placenta,* 25, 560-572.

22. Day, S.K. 1996. Implantation. In Adasshi EY, Rock, JA, Rosenwaks Z (eds) reproductive Endocrinology, surgery, and technology. Lippincott-Raven, New York, 421-434.

23. Dey, S.K., Lim, H., Das, S.K., Reese, J., Paria, B.C., Daikoku, T., Wang, H., 2004. Molecular cues to implantation. *Endocrine Reviews,* 25, 314-373.

24. Duc-Goiran, P., Mignot, T.M., Bourggeois, C., Ferre, F. 1999. Embryo-maternal interactions at the implantation site: a delicate equilibrium. *European Journal of Obstetric and Gynecology and Reproductive Biology,* 83, 85-100.

25. Dvorak, H. F., Brown, L.F., Detmar, M., Dvorak, A.M. 1995. Vascular permeability factor/vascular endothelial factor, microvascular hyperpermeability, and angiogenesis. *American Journal of Pathology,* 146, 1029-1039.

26. Edwards, R.G., Steptoe, P. C., Purdy, J.M. 1980. Establishing full-term human pregnancies using cleaving embryos grown in vitro. *British Journal of Obstetrics and Gynaecology,* 87, 737-756.

27. Edwards, R.G. 1995. Physiological and molecular aspects of human implantation. *Human Reproduction,* 10, 1-13.

28. Edwards, R. G., Lobo, R., Bouchard, P., 1996. Time to revolutionize ovarian stimulation. *Human Reproduction*, 11, 917-919.

29. Enders, A.C. 1975. The implantation chamber, blastocyst and blastocyst imprint of the rat: a scanning electron microscopy study. *Anatomical Record,* 182, 137-150.

30. Enders, A.C., Schlafke, S., 1967. A morphological analysis of the early implantation stages in the rat. *American Journal of Anatomy,* 120, 185-226.

31. Ertzeid, G., Storeng R. 2001. The impact of ovarian stimulation on implantation and fetal development in mice. *Human Reproduction,* 16, 221-225.

32. Ferrara, N. 1996. Vascular endothelial growth factor. *European Journal of Cancer,* 32A, 2413-2422.

33. Ferrara, N., Davis-Smith T. 1997. The biology of vascular endothelial growth factor. *Endocrine Reviews,* 18, 4-25.

34. Folkman, J. 1990. What is the evidence that tumors are angiogenesis dependent? *Journal of Nat. Cancer Inst.* 82, 4-6.

35. Fong, G. H., Rossant J., Gertsenstein, M., Breitman, M.L. 1995. Role of the Flt-1 receptor tyrosine kinasein regulating the assembly of vascular endothelium. *Nature,* 376, 66-70.

36. Fossum, G.T., Davidson, A., Paulson, R.J. 1989. Ovarian hyperstimulation inhibits embryo implantation in the mouse. *Journal of in vitro Fertilization and Embryo Transfer,* 6, 7-10.

37. Garcia-Valasco, J.A., Zuniga, A., Pacheco, A., Gomez, R, Simon, C., Remohi, J., Pellicer, A. 2004. Coasting acts through downregulation of VEGF gene expression and protein secration. *Human Reproduction,* 19, 1530-1538.

38. Gidley-Baird, A.A., O'Neill, C., Sinocisich, M.J., Porter, N.R., Pike, I.L., Saunders, D.M. 1986. Failure of implantation in human in vitro fertilization and embryo transfer patients: the effect of altered progesterone/estrogen ratios in humans and mice. *Fertility and Sterility*, 45, 69-74.

39. Herve, M.A.J., Meduri, G., Petit, F.G., Domet, T.S., Lazennec, G., Mourah, S., Perrot-Applanat, M. 2006. Regulation of the vascular endothelial growth factor (VEGF) receptor Flk-1/KDR by estradiol through VEGF in uterus. *Journal of Endocrinology,* 188, 91-99.

40. Hewitt, C. S., Goulding, E. H., Eddy, E.M., Korach, K.S. 2002. Studies using the estrogen receptor α knockout uterus demonstrate that implantation but not decidualization-associated signaling is estrogen dependent. *Biology of Reproduction,* 67, 1268-1277.

41. Hla, T., Neilson, K. 1992. Human cyclooxygenase-2 cDNA. *Proceedings of the National Academy of Sciences USA*, 89, 7384-7388.

42. Hosie, M.J., Murphy, C.R. 1992. Clomiphene citrate alters surface ultrastructure of luminal epithelial cells. *Acta Anatomica* 145, 2, 175-178.

43. Hosie, M.J., Murphy, C.R. 1995. A scanning and light microscope study comparing the effects of clomiphene citrate, estradiol 17-beta and progesterone on the structure of uterine luminal epithelial cells. *European Journal of Morphology*, 33, 39-50.

44. Houck, K.A., Ferrara, N., Winer, J., Cachianes, G., Li, B., Leung, D.W. 1991. The vascular endothelial growth factor family: identification of a fourth molecular species and caracterization of alternative splicing of RNA. *Molecular Endocrinology,* 5, 1806-1814.

45. Hyder, S. M., Stancel, G.M. 1999. Regulation of angiogenic growth factors in the female reproductive tract by estrogens and progestins. *Molecular Endocrinology,* 13, 806-811.

46. Hyder, S.M. 2002. The role of steroid hormones on the regulation of vascular endothelial growth factor. *American Journal of Pathology,* 161, 345-346.

47. Hyder, S.M., Stancel, G.M., Chiappetta, C., Murthy L., Boettger-Tong, H.L., Makela, S. 1996. Uterine expression of vascular endothelial growth factor is increased by estradiol and tamoxifen. *Cancer Research,* 56, 3954-3960.

48. Jakeman, L.B., Armanini, M., Phillips, H.S., Ferrara, N. 1993. Developmental expression of binding sites and messenger ribonucleic acid for vascular endothelial growth factor suggests a role for this protein in vasculogenesis and angiogenesis. *Endocrinology,* 133, 848-859.

49. Kennedy, T.G. 1977. Evidence for a role for prostaglandins in the initiation of blastocyst implantation in rat. *Biology of Reproduction,* 16, 289-291.

50. Kennedy, T.G., Lukash, L.A. 1982. Induction of decidualization in rats by the intrauterine infusion of prostaglandins. *Biology of Reproduction*, 27, 253-260

51. Kent, G.C., Smith, R.A. 1945. A study of the oestrus cycle of the golden hamster, *cricetus auratus* waterhouse. *Anatomical Record,* 92, 263-271.

52. Kim, K.J., Li, B., Winer, J 1996. Inhibition of vascular endothelial growth factor-induced angiogenesis suppresses tumor growth in vivo. *Nature,* 362, 841-844.

53. Kitsukawa, T., Shimizu, M., Sanbo, M., Hirata, T., Taniguchi, M., Bekku, Y., Yagi, T., Fujisawa, H. 1997. Neuropilin-semaphorin III/D-mediated chemopulsive signals play a crucial role in peripheral nerve projection in mice. *Neuron,* 19, 995-1005.

54. Klentzeris, L.D. 1997. The role of endometrium in implantation. *Human Reproduction,* 2, 170-175.

55. Kramer, B. 1997. Changes in vascular permeability and deciduoma formation during the peri-implantation period of the rat in response to exogenous gonadotropins. *Anatomical Record,* 247, 20-24.

56. Kramer, B., de Wet, G. 1994. Exogenous gonadotropin administration affects the glicocalyx of rat endometrial epithelial cells during the period of implantation. *Journal of Assisted Reproduction and Genetics,* 11, 504-509.

57. Kramer, B., Magan, A., de Wet, G. 1993. Hyperstimulation affects vascular permeability at implantation sites in the rat endometrium. *Journal of Assisted Reproduction and Genetics,* 10, 163-168.

58. Kramer, B., Stein, B.A., van der Walt, L.A. 1990. Exogenous gonadotropins-serum oestrogen and progesterone and the effect on endometrial morphology in the rat. *Journal of Anatomy*, 173, 177-186.

59. Krussel, J.S., Behr, B., Milki, A.A., Hirchenhain, J., Wen, Y., Bielfeld, P., Lake, Polan, M. 2001. Vascular endothelial growth factor (VEGF) mRNA splice variants are differentially expressed in human blastocysts. *Molecular Human Reproduction*, 7, 57-63.

60. Krussel, J.S., Bielfeld, P., Polan, M.L., Simon, C. 2003. Regulation of embryonic implantation. *European Journal of Obstetrics & Gynecology and Reproductive Biology,* 110, S2-S9.

61. Lejeune, B., Van Hoeck, J., Leroy, F. 1981. Transmitter role of the luminal uterine epithelium in the induction of decidualization in rats. *Journal of Reproduction and Fertility,* 61, 235-240.

62. Leung, D.W., Cachienes G., Kuang W.-J., Goeddel D.V., Ferrara N. 1989. Vascular endothelial growth factor is a secreted angiogenic mitogen. *Science,* 246, 1306-1309.

63. Lim, H., Dey, S.K. 1997. Prostaglandin E2 receptor subtype EP2 gene expression in the mouse uterus coincides with differentiation of the luminal epithelium for implantation. *Endocrinology,* 138, 4599-4607.

64. Lim, H., Gupta, R.A., Ma, W-G, Paria, B.C., Moller, D.E., Morrow, J.D., Du Bois, R.N., Trazaskos, J.M., Dey, S.K. 1999. Cyclo-oxygenase-2-derived prostacyclin mediates embryo implantation in the mouse via PPARδ. *Genes and Development,* 13, 1561-1574.

65. Lim, H., Paria, B.C., Das, S.K., Dinchuk, J.E., Langenbach, R., Trzaskos, J.M. and Dey, S.K. 1997. Multiple female reproductive failures in cyclooxygenase 2 deficient mice. *Cell,* 91, 197-208.

66. Lindsay, L.A., Murphy, C.R., 2006. Redistribution of aquaporins 1 and 5 in the rat uterus is dependent on progesterone: a study with light and electron microscopy. *Reproduction*, 131, 369-378.

67. Ljungkvist, I. 1972. Attachment reaction of rat uterine luminal epithelium. IV The cellular changes in the attachment reaction and its hormonal regulation. *Fertility and Sterility,* 23, 847-865.

68. Ma, W., Tan, J., Matsumoto, H., Robert, B., Abrahamson, D.R., Das, S.K., Dey, S.K. 2001. Adult tissue angiogenesis: evidence for negative regulation by estrogen in the uterus. *Molecular Endocrinology,* 15, 1983-1992.

69. Ma, W., Song, H., Das, S.K., Das, S.K., Paria, B.C., Dey, S.K. 2003. Estrogen is a critical determinant that specifies the duration of the window of uterine receptivity for implantation. *Proceedings of the National Academy of Sciences USA,* 100, 2963-2968.

70. Macklon, N.S., Stouffer, R.L., Giudice, L.C., Fauser, B.C.J.M. 2006. The science behind 25 years of ovarian stimulation for in vitro fertilization. *Endocrine Reviews,* 27, 170-207.

71. Markenson, J., 1999. Clinical implications of Cyclooxygenase enzymes: COX1/COX2 role of the new NSAIDs. *Cancer Control*, 6, 22-25.

72. Martin, K.L., Barlow, D.H., Sargent, I.L. 1998. Heparin-binding epidermal growth factor significantly improves human blastocyst development and hatching in serum-free medium. *Human Reproduction,* 13, 1645-1652.

73. Martel, D., Monier, M.N., Roche, D., Psychoyos, A. 1991. Hormonal control of pinopode formation at the uterine luminal surface. *Human Reproduction,* 6, 597-603.

74. Matsumoto, H., Ma, W., Daikoku, T., Zhao, Z., Paria, B.C., Das, S.K., Trzaskos, J.M., Dey, S.K. 2002. Cyclooxygenase-2 differentially directs uterine angiogenesis during implantation in mice. *The Journal of Biological Chemistry,* 277, 29260-29267.

75. Matsumoto, H., Ma, W., Smalley, W., Trzaskos, J.M., Breyer, R. M., Dey, S.K. 2001. Diversification of cyclooxygenase2 derived prostaglandins in ovulation and implantation. *Biology of Reproduction*, 64, 1557-1565.

76. Murphy, C.R., Turner, V.F. 1991. Glycocalyx carbohydrates of uterine epithelial cells increase during early pregnancy in rat. *Journal of Anatomy,* 177, 109-115.

77. Murphy, C.R. 1995. The cytoskeleton of uterine epithelial cells: a new player in uterine receptivity and plasma membrane transformation. *Human Reproduction Update,* 1, 567-880.

78. Murphy, C.R. 1992. Structure of the plasma membrane of uterine epithelial cells in blastocyst attachment: a review. *Reprod. Fertil. Dev*, 4, 633-643.

79. Ni, H., Sun, T., Ding, N., Ma, X., Yang, Z. 2002. Differential expression of microsomal prostaglandin E synthase at implantation sites in decidual cells of mouse uterus. *Biology of Reproduction*, 67, 351-358.

80. Ni, H., Sun, T., Ma, X., Yang, Z., 2003. Expression and regulation of cytosolic prostaglandin E synthase in the mouse uterus during the peri-implantation period. *Biology of Reproduction,* 68, 744-750.

81. Paria, B.C., Huet-Hudson, Y.M., Dey S.K. 1993. Blastocyst's state of activity determines the "window" of implantation in the receptive mouse uterus. *Proceedings of the National Academy of Sciences USA,* 90, 10159-10162.

82. Paria, B.C., Reese, J., Das, S.K., Dey, S.K. 2002. Deciphering the cross talk of implantation: advances and challenges. *Science,* 296, 2185-2188.

83. Parr, E.L., Tung, H.N., Parr, M.B. 1987. Apoptosis as the mode of uterine epithelial cell death during embryo implantation in mice and rats. *Biology of Reproduction,* 36, 211-225.

84. Paulson, R.J., Sauer, M.V., Lobo, R.A. 1990. Embryo implantation after human in vitro fertilization: importance of endometrial receptivity. *Fertility and Sterility,* 53, 870-873.

85. Perrot-Applanat, M., Ancelin, M., Buteau-Lozano, H., Meduri, G., Bausero, P. 2000. Ovarian steroids in endometrial angiogenesis. *Steroids*, 65, 599-603.

86. Peverini, S., Kramer, B. 1995. Superovulation affects glucosamine trisaccharides in the glycocalyx of the rat endometrium at the time of implantation. *Journal of Anatomy*, 187, 487-490.

87. Psychoyos, A. 1973. Endocrine control of egg implantation. In: Greep R.O., Astwood E.G., Geiger S.R. (eds.) *Handbook of Physiology*. Washington DC: American Physiology Society; 187-215.

88. Psychoyos, A., Martel, D. 1985. Problems related to the implantation of the human egg after in vitro fertilization. *Acta Europaea Fertilitatis*, 16,107-109.

89. Robinson, C.J., Stringer, S.E. 2001. The splice variant of vascular endothelial growth factor (VEGF) and their receptors. *Journal of Cell Science,* 114, 853-865.

90. Roberts, W.G., Palade, G.E. 1995. Increased microvascular permeability and endothelial fenestration induced by vascular endothelial growth factor. *Journal of Cell Science,* 108, 2369-2379.

91. Ryzhov, S., McCaleb, J.L., Goldstein, A.E., Biaggioni, I., Feoktistov, I. 2007. Role of adenosine receptors in the regulation of angiogenic factors and neovascularisation in hypoxia. *Journal of Pharmacology and Experimental Therapeutics,* 320, 565-572.

92. Satokata, I., Benson, G., Mass, R. 1995. Sexually dimorphic sterility phenotypes in Hox-10 deficient mice. *Nature* 374, 460-463.

93. Schultz, R. M., Williams C. J. 2002. The science of ART, *Science,* 269, 2188-2190.

94. Senger, D. R., Galli, S.J., Dvorak, A. M., Perruzzi, C.A., Harvey, S. Dvorak, H.F. 1983. Tumor cells secrete a vascular permeability factor that promotes accumulation of ascites fluid. *Science*, 219, 983-985.

95. Sharkey, A. 1998. Cytokines and implantation. *Reviews of Reproduction*, 3, 52-61.

96. Shweiki, D., Itin, A., Neufeld, G., Gitay-Goren, H., Keshet, E. 1993. Patterns of expression of vascular endothelial growth factor (VEGF) and VEGF receptors in mice suggest a role in hormonally regulated angiogenesis. *Journal of Clinical Investigations,* 91, 2235-2243.

97. Simon, C., Cano, F., Valbuena, D., Peinado, J.A., Remohi, J., Pellicer, A. 1995. Implantation: clinical evidence for a detrimental effect on uterine receptivity of high oestradiol concentrations in high and normal responder patients. *Human Reproduction*, 10, 2432-2437.

98. Simon, C., Valasco, G.V., Valbuena, D., Peinado, J.A., Moreno, C., Remohi, J., Pellicer, A. 1998. Increasing uterine receptivity by decreasing estradiol levels during the periimplantation period in high responders with the use of follicle-stimulating hormone step-down regimen. *Fertility and Sterility,* 70, 234-239.

99. Smith, W.L., Meade, E.A., DeWitt, D.L. 1994. Interactions of PGH synthase isozymes-1 and-2 with NSAIDs. *Annals of the New York Academy of Science,* 744, 50-57.

100. Smith, W. L., DeWitt, D.L., Garavito, R.M. 2000. Cyclooxygenases: structural, cellular, and molecular biology. *Annual Review of Biochemistry,* 69, 149-182.

101. Song, H., Lim, H., D, S.K., Paria, B.C., Dey, S.K. 2000. Dysregulation of EGF family of growth factors and COX-2 in the uterus during the preattachment and attachment reactions of the blastocyst with the luminal epithelium correlates with implantation failure in LIF-deficient mice. *Molecular Endocrinology*, 14, 1147-1161.

102. Song, H., Han, K., lim, H. 2007. Progesterone supplementation extends uterine receptivity for blastocyst implantation in mice. *Reproduction,* 133, 487-493.

103. Stein, B. A., Kramer, B., 1989. The effect of exogenous gonadotropic hormones on the endometrium of the rat. *Journal of Anatomy,* 164, 123-130.

104. Stein, B.A., Kramer, B., de Wet, G., van der Walt, L.A. 1993. Dose-dependent effects of exogenous gonadotrophins on the endometrium of the rat. *South African Medical Journal,* 83, 122-125.

105. Sterzik, K., Sasse, V., Dallenbach, C., Dallenbach-Hellweg, G., Schneider, V. 1988. In vitro fertilization: the degree of endometrial insufficiency varies with the type of ovarian stimulation. *Fertility and Sterility,* 50, 457-462.

106. Srivastava, R.K., Gu, Y., Ayloo, M., Gibori, G. 1998. Developmental expression and regulation of basic fibroblast growth factor and vascular endothelial growth factor in rat decidua in a decidual cell line. *Journal of Molecular Endocrinology*, 21, 355-362.

107. Tabibzadeh, S. 1998. Molecular control of the implantation window. *Human Reproduction Update,* 4, 465-471.

108. Tan, J., Paria, B.C., Dey, S.K., Das, S.K. 1999. Differential uterine expression of estrogen and progesterone receptors correlates with uterine preparation for implantation and decidualization in the mouse. *Endocrinology,* 140, 5310-5321.

109. Tassell, W., Slater, M., Barden, J.A., Murphy, C.R. 2000. Endometrial cell death during early pregnancy in the rat. *The Histochemical Journal,* 32, 373-379.

110. Taylor, H.S., Venden Heuvel, G.B., Igarashi, P. 1997. A conserved Hox axis in the mouse and human female reproductive system: late establishment and persistent adult expression of the Hoxa cluster genes. *Biology of Reproduction*, 57, 1338-1345.

111. Testart, J. 1987. Evidence of uterine inadequacy to egg implantation in stimulated in vitro fertilization cycles. *Fertility and Sterility,* 47, 855-857.

112. Tranguch, S., Daikoku, T., Guo, Y., Wang, H., Dey, S.K. 2005. Molecular complexity in establishing uterine receptivity and implantation. *Cellular and Molecular Life Sciences,* 62, 1964-1973.

113. Tsujii, M., Du Bois, R.N., 1995. Alteration of cellular adhesion and apoptosis in epithelial cells overexpressing endoperoxide synthase 2. *Cell,* 83, 493-501.

114. Valbuena, D., Martin, J., de Pablo, J.L., Remohi, J., Pellicer, A., Simon, C. 2001. Increasing levels of estradiol are deleterious to embryonic implantation because they directly affect the embryo. *Fertility and Sterility,* 76, 962-968.

115. Waltenberger, J., Claesson-Welsh, L., Siegbahn, A., Shibuya, M., Heldin, C. 1994. Different signal transduction properties of KDR and Flt-1, two receptors for vascular endothelial growth factor. *The Journal of Biological Chemistry,* 269, 26988-26995.

116. Walter, L.M., Rogers, P.A.W., Girling, J.E. 2005. The role of progesterone in endometrial angiogenesis in pregnant and ovariectomised mice. *Reproduction,* 129, 765-777.

117. Wang, T., Horno, S., Chang, C., Wu, H., Tsai, Y., Wang, H., Song, Y. 2002. Human chorionic gonadotropin-induced ovarian hyperstimulation syndrome is associated with up regulation of vascular endothelial growth factor. *Journal of Clinical Endocrinology and Metabolism,* 87, 3300-3308.

118. Williams, T., Rogers, A. W. 1980. Morphometric studies of the response of the luminal epithelium in the rat uterus to exogenous hormones. *Journal of Anatomy*, 140, 867-881.

119. Yang, Z. M., Das, S. K., Wang, J., Sugimoto, Y., Ichikawa, A., Dey, S.K. 1997. Potential sites of prostaglandin actions in the periimplantation mouse uterus: differential expression and regulation of prostaglandin receptor genes. *Biology of Reproduction*, 56, 368-379.

120. Zhang, L., Scott, P.A.E., Turley, H., Leek, R., Lewis, C.E., Gatter, K.C., Harris, A.L., Mackenzie, I.Z., Rees, M.C., Bicknell, R. 1998. Validation of anti-vascular endothelial growth factor (anti-VEGF) atibodies for immunohistochemical localization of VEGF in tissue sections: expression of VEGF in the human endometrium. *Journal of Pathology*, 185, 402-408.

121. Zhang, Q., Paria, B.C. 2006. Importance of cell death, renewal, and their hormonal regulation in hamsters that show progesterone-dependent implantation. *Endocrinology,* 175, 2215-2227.

Appendix 1

The Schorr Staining

Preparation (1 litter of stain)

ethyl alcohol (50%)	
Biebrich scarlet (water soluble)	5.0 g
orange G	2.5 g
fast green FCF	0.75 g
phosphotungstic acid	5.0 g
phosphmolybdic acid	5.0 g
glacial acetic acid	10 ml

METHOD:

1. Stain for 1-2 minutes in Schorr's stain.
2. Rinse in 70% alcohol
3. Rinse in 90% alcohol.
4. Rinse in 100% alcohol twice.
5. Clear in xylene twice.
6. Count in synthetic resin mountain.

Appendix 2

Oestrous cycle diagram.

Oestrus

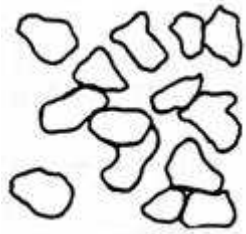

Abundance of cornified polygonal cells

Metoestrus

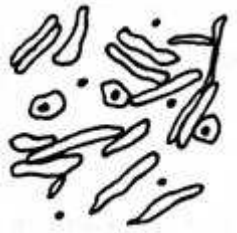

Abundance of elongated cornified cells. Some nucleated cuboidal cells. Occasional leucocytes

Early-dioestrus



Numerous nucleated cuboidal cells. Some cornified polygonal cells. Abundance of leucocytes

Mid-dioestrus



Numerous nucleated cuboidal cells. Occasional elongated polygonal cornified cells. Some leucocytes

Late-dioestrus



Elongated to polygonal cornified cells fairly numerous. Some nucleated cuboidal cells. Occasional leucocytes

Proestrus



Polygonal cornified cells numerous. Some nucleated cuboidal cells. Some nucleated cuboidal cells. Very few leucocytes

Appendix 3

Phosphate buffered saline pH 7.6

NaCl	16.0 g
$Na_2HPO_4.2H_2O$	3.5 g
KCL	0.4 g
KH_2PO_4	0.4 g
2 litter distilled H_2O	

Appendix 4

10% Neutral buffered formalin

formalin	100 ml
sodium dihydrogen phosphate	3.5 g
di-sodium hydrogen phosphate	6.5 g
distilled H_20	900 ml

Appendix 5 Raw data for the oestradiol and progesterone concentrations

Day of pregnancy	Progesterone ng/ml	Sample	Oestradiol pg/ml
	Pregnant rats		Pregnant
4.5	20.521	I1	19.424
4.5	11.925	H3	12.449
4.5	21.755	A3	15.589
4.5	28.892	C1	18.163
4.5	26.203	C4	40.808
4.5	25.831	E2	
5.5	18.257	F4	12.122
5.5	27.349	H4	23.802
5.5	25.495	F3	17.978
5.5	30.784	G2	17.549
5.5	20.4	B2	32.887
5.5	29.847	D3	31.879
6.5	16.077	B1	20.386
6.5	24.668	D2	19.516
6.5	24.129	C2	45.854
6.5	31.349	A4	51.91
6.5	23.992	G4	24.738
6.5	20.724	H1	32.693
	Hyperstimulated		Hyperstimulated
4.5	19.115	I2	26.737
4.5	23.319	I3	20.272
4.5	25.841	F2	30.627
4.5	23.467	H2	19.459
4.5	31.33	I4	41.092
4.5	29.65	E3	32.583
5.5	44.291	G1	35.637
5.5	34.309	A2	26.164
5.5	28.9	B4	31.413
5.5	24.345	E1	29.492
5.5	28.453	E4	66.595
5.5			
6.5	35.444	A1	29.87
6.5	32.128	G3	15.197
6.5	36.88	F1	12.952
6.5	26.774	D4	13.844
6.5	39.1755	B3	14.904
6.5	26.153	W3	20.51
6.5	34.975	W4	

Appendix 6

Silane dipped slides

2% Silane in acetone

3 Aminopropyl triethoxy silane	6 ml
acetone	294 ml

Method:

1. Soak slides in 10% Contrad or Super 10 overnight
2. Rinse in running water minimum 2 hours
3. Dry in oven at 60°C
4. Dip in acetone
5. Dip in 2% silane in acetone for 30 minutes
6. Wash in two changes of acetone 1-2 dips
7. Wash briefly in distilled water
8. Dry at 42°C in the incubator overnight.

Appendix 7

Haematoxylin and eosin stain (Mayer's Staining Technique)

Haematoxylin:	haematoxylin 4 g
	distilled water 1000 ml
	potassium alum 50 g
	citric acid 1.5 g
	chloral hydrate 75 g
Eosin:	1% Eosin 500 ml
	1% phloxine 250 ml
	distilled water 750 ml

Method:

1. Dewax in two changes of xylene (2 x 5 min)
2. Pass through graded alcohols followed by rinsing the slides into running water.
3. Stain in haematoxylin for 5 minutes. Wash in tap water to "blue". Check staining under the microscope.
4. If necessary differentiate by dipping slides 2-3 times in 1% acid alcohol.
5. Wash in running water for 5 min, until nuclei are bright blue.
6. Counter-stain in eosin for 30 sec to 1 minute.
7. Wash briefly in running water.
8. Slides are passed up through alcohol series and than into Xylene, mounted with Entellan and cover-slipped and left to dry.

Appendix 8

Citrate buffer pH 6

Solution A: 0.1M citric acid

10.5 g citric acid and 500 ml distilled water

Solution B: 0.1M sodium citrate

29.4 g sodium citrate and 1000 ml distilled water

Method:

Solution A	9 ml
Solution B	41 ml
Distilled H_2O	500 ml

Appendix 9

TRIS buffered saline pH 7, 6

TRIS base	6.06 g
NaCl	8.77 g
Distilled H_20	**1000 ml**

Appendix 10

Homogenizing buffer stock

50mM TRIS HCl pH 7.5

10% glycerol

5mM Mg acetate

0.2mM EDTA

1% Triton-X-100

Add 500 µl of 0.5 M DTT and 50 µl of protease inhibitor stock to 10 ml of homogenizing buffer just before the protein extraction.

Appendix 11

Reagent A for Lowry protein assay

Reagents

1) 2% sodium carbonate (Na2CO3) made up in 0.1M NaOH
2) 1% copper sulphate (CuSO4.5H2O)
3) 2% sodium potassium tartrate (NaKC4H4O6.4H20)

Reagent A

20 ml of (1)

200 µl of (2)

200 µl of (3)

Appendix 12

Reagent B for Lowry protein assay

Folin reagent diluted 1:4 in distilled water

Method for Lowry protein assay:

Use ELISA plate and disperse the following in order:

1. 50 µl of sample
2. 200 µl of reagent A (leave for 10 min on shaker)
3. 50 µl of reagent B (leave for 30 min on shaker)
4. Read absorbance at 690nm

Appendix 13 Raw data for the protein in the sample

Day of pregnancy	Volume of protein in the sample (µg/µl)	Sample
	Pregnant rats	
4.5	3.396	I1
4.5	5.666	H3
4.5	3.504	A3
4.5	2.613	C1
4.5	2.330	C4
4.5	2.850	E2
5.5	5.031	F4
5.5	7.435	H4
5.5	3.214	F3
5.5	3.543	G2
5.5	2.313	B2
5.5	3.140	D3
6.5	2.829	B1
6.5	3.278	D2
6.5	3.101	C2
6.5	3.653	A4
6.5	3.354	G4
6.5	3.411	H1
	Hyperstimulated rats	
4.5	4.690	I2
4.5	3.933	I3
4.5	5.934	F2
4.5	3.562	H2
4.5	2.622	I4
4.5	3.238	E3
5.5	4.068	G1
5.5	3.014	A2
5.5	2.639	B4
5.5	2.828	E1
5.5	2.584	E4
5.5		
6.5	2.187	A1
6.5	4.242	G3
6.5	5.978	F1
6.5	3.518	D4
6.5	2.777	B3
6.5	6.099	W3

Appendix 14

10% SDS- polyacrylamide separating gel

dH2O	5.9ml
30% acrilamide monomer stock solution	5ml
1.5M TRIS-HCl pH8.8	3.75ml
10% sodium dodecyl sulphate (SDS)	150µl
10% ammonium persulphate	150µl
N,N,N',N'-tetramethylethylenediamine (TEMED)	6µl

Appendix 15

Electrophoresis Tank Buffer

0.025M TRIS pH 8.3

0.192M glycine

0.15 SDS

Appendix 16

Sample transferring buffer pH 6.8

0.125M Tris-HCl pH 6.8

4% SDS

20% glycerol

10% ß mercaptoethanol

10µg/ml bromophenol blue

Appendix 17

Towbin buffer

TRIS	15.15g
glycine	72.05g
SDS	5g
dH20	4000ml
methanol	1000ml

Appendix 18

Commassie Blue Staining Solution

0.25 g Commasie blue

100 ml ethanol

100 ml distilled water

Stir for an hour until dye is completely dissolved.

Add 25 ml acetic acid

Add distilled water to make 250 ml of stain.

Appendix 19

Distaining Solution 1	**Distaining Solution 2**
50% methanol	5% methanol
10% acetic acid	7% acetic acid