

https://dspace.org/

Paediatric doctors error rate in detection of paediatric elbow injuries in Rahima Moosa mother and child hospital

Magano, Gopolang

2019
https://hdl.handle.net/10539/27906

Downloaded from a DSpace repository. https://dspace.org/

Paediatric Doctors Error Rate in Detection of Paediatric Elbow Injuries in Rahima Moosa Mother and Child Hospital

Dr Gopolang Magano

Student number: 0502898M

Course registered for: MMed (RadD)

A research report submitted to the Faculty of Health Sciences, University of the Witwatersrand, Johannesburg, in partial fulfilment of the requirements for the degree of Master of Medicine in Diagnostic Radiology.

Johannesburg, 2019

Declaration

I, Dr G. Magano, declare that this research report is my own work. It is being submitted for the degree of MMed (RadD) at the University of the Witwatersrand, Johannesburg. It has not been submitted before for any degree or examination at this or any other University.



DR G. MAGANO

On this 3rd day of June 2019.

Declaration

I, Dr G. Magano, declare that this research report is my own work. It is being submitted for the degree of MMed (RadD) at the University of the Witwatersrand, Johannesburg. It has not been submitted before for any degree or examination at this or any other University.

DR G. MAGANO

On this 3rd day of June 2019.

Thank you to my Husband, Sipho Mndebele for always reminding me that nothing is impossible because it is my duty to make it possible.

To my parents, Pono and Paul Magano, thank you for the unconditional love and support.

Galebokwe lebitso la Morena.

Publications and presentations

This study abstract was presented orally at the South African Society of Paediatric Imaging (SASPI) Congress in Spier Estate (Stellenbosch) on 05 November 2016.

The abstract was published on the online publication of the *South African Journal of Radiology*; Volume 21, No 1 in May 2017.

Abstract

Introduction: Elbow fractures are common paediatric injuries that are often misdiagnosed. Quality imaging and accurate interpretation is essential to avoid complications that can result in growth disturbance.

Aim: The aim of this study was to determine error rates of elbow injuries by medical doctors in paediatric department in Rahima Moosa Mother and Child Hospital.

Methods: 28 doctors participated in the study. 20 preselected radiographs (10 normal and 10 abnormal) were projected in a power point slide show. The doctors completed a tick sheet to assess whether the x-ray was normal or not. This was followed by a 20 minute tutorial on the approach to paediatric elbow x-rays. Following that, the same images were projected in a different sequence and with a more detailed tick sheet for the readers to evaluate.

Results: The detection rate of elbow fractures by paediatric doctors was poor. Although there was an improvement in the detection of fractures before (52.1%) and after (56.4%) the tutorial, the difference was not statistically significant (paired t-test; p=0.16).

Conclusion: The paediatric elbow is a common site where pathology is missed on x-rays. The study showed that the detection rate of elbow fractures by the paediatric doctors is poor, even after a tutorial on the radiological features. We recommend on-going in-service training of clinicians to improve detection of fractures.

Acknowledgements

- To my supervisors Dr Pillay and Dr Lucas, thank you for your patience and working with me in advancing this research.
- To Professor Coovadia, thank you for allowing your paediatric department to participate in this study.
- To Professor Magano, I am grateful for your support, guidance and continuous motivation.
- To Ms C. Tamukedde, thank you for assisting me in proof reading and spell checks.
- To my son Galebokwe Mndebele, daughter Sphokazi Mndebele and my siblings Boipelo Ntsaluba, Ntsabelo Ntsaluba, Oregopotse Magano and Boiphemelo Magano, thank you for allowing me to shine my light. Your faith and belief in me is truly inspiring.

Table of Contents

Declaration ii
Publications and presentations iv
Abstract v
Acknowledgements vi
Table of Contents vii
List of Figures ix
List of Tables x
List of Abbreviations and Terminology xi
1. Introduction 1
1.2. Anatomy of the paediatric elbow 1
1.2.1. Differences between the adult and paediatric elbow 2
1.3. Elbow imaging 3
1.3.1. Elbow joint radiographs 3
1.3.2. Elbow ultrasound 5
1.3.3. Elbow MRI 6
1.3.4. CT of the elbow 6
1.4. Elbow injuries 7
1.4.1 Non Accidental injuries 10
1.4.2. Elbow injury complications 11
1.4.3. Common errors made by ED doctors 11
1.5. Aim 12
1.6. Study objectives 12
2. Materials and Methods 13
2.1. Research paradigm 13
2.2. Inclusion criteria 15
2.3. Exclusion criteria 16
2.4. Data collection 16
2.5 Statistical analysis 16
2.5.1 Sample size 16
2.5.2 Analysis: general 16
2.6. Ethics 17

3. Results 18
3.1. Pre-tutorial results 18
3.2. Post-tutorial results 20
3.3. Comparison of pre and post tutorial scores 22
4. Discussion 28
4.1 The context 28
4.2. Current applications 30
4.3. Limitations of the current study 30
4.4. Future applications 31
5. Conclusion 32
6. References 33
Appendix A: Ethics Clearance Certificate 35
Appendix B: Tick sheet A 36
Appendix C: Tick sheet B 38
Appendix D: Turn it in report 40
Appendix E: Note on referencing style 41

List of Figures

Figure 1.1 Lateral radiograph with normal anterior humeral line 3
Figure 1.2 AP and lateral radiograph with a normal radiocapitellar line 4
Figure 1.3. AP radiograph of the elbow with the normal Bauman angle..... 5
Figure 2.1 AP and lateral radiograph of a normal elbow. 14
Figure2.2 AP and lateral radiograph of elbow with a supracondylar fracture..... 15
Figure 2.3 AP and lateral radiograph with soft tissue swelling and joint effusion..... 15
Figure 3.1.Pre tutorial correctly scored results 19
Figure 3.2 Pre tutorial error rate results 20
Figure 3.3 Post tutorial correct results 21
Figure 3.4 Post tutorial error rate results..... 22
Figure 3.5 pre and post tutorial Gartland fracture types percentage error results..... 23
Figure 3.6 Comparison of post- and pre-tutorial scores 24
Figure 3.7 Lateral and AP radiograph of slide 7 (pre tutorial)..... 25
Figure 3.8 Lateral and AP radiograph of slide 8 (pre tutorial) and slide 13 (post tutorial). 25
Figure 3.9 Lateral and AP radiograph of slide 12 (pre-tutorial) and slide 6 (post tutorial). 26
Figure 3.10 Lateral and AP radiograph of slide 18 (pre-tutorial) and slide 9 (post tutorial) 26
Figure 3.11 Lateral and AP radiographs of slide 20 (pre tutorial) and slide 12 (post tutorial) 27
Figure3.12 Lateral and AP radiographs of slide 8 (post tutorial) 27

List of Tables

Table 1.1. Ossification centres and age at ossification 2
Table 1.2. Gartland classification of supracodylar fractures of the elbow 8
Table 1.3. Milch classification for lateral condyle fractures..... 9
Table 1.4 Salter Harris fracture classification..... 10
Table 3.1. Classification of pre and post tutorial..... 18
Table 3.2 Pre-tutorial error results..... 19
Table 3.3 Post tutorial error rate..... 21

List of Abbreviations and Terminology

Abbreviation	Meaning
AP	Antero-Posterior
AVN	Avascular Necrosis
CT	Computer Tomography
ED	Emergency Department
MRI	Magnetic Resonance Imaging
MSK	Musculoskeletal
NAI	Non Accidental Injury
RMMCH	Rahima Moosa Mother and Child Hospital

1. Introduction

“Elbow fractures are commonly encountered in the emergency department (ED) and their complexity often goes unrecognised in their initial evaluation” (1). In the setting of paediatric trauma casualty, elbow fractures are the most commonly encountered injuries (2). Interpretation of imaging determines the management, which is pertinent in avoiding future complications. This situation therefore calls for quality imaging and accurate interpretation by medical doctors treating the patients.

The ED doctors are the first to interact with patients in the hospital setting. They therefore have the important role of directing particular investigations, interpreting them and managing the findings accordingly.

In the ED setting, a study by Skaggs and Pershad found that the paediatric elbow injury is commonly misdiagnosed with an increase in high lawsuit claims for orthopaedic injuries in their department (2). Avoidance of malpractice should not be the primary concern; as misdiagnosis can lead to complications. This emphasises the importance of continuous teaching, having protocols in the hospital and other health service centres.

1.2. Anatomy of the paediatric elbow

In order to be able to diagnose pathology, it is important to understand the anatomy. The elbow joint is a hinge joint with flexion–extension and supination–pronation range of motion (3). The elbow joint consists of three bones; the radius, ulna and humerus. These bones articulate together forming the radiocapitellar and ulnotrochlear joints that make it possible for the elbow to be able to have its range of movement mentioned (3). The anterior cubital fossa is a triangular shaped space in the anterior aspect of the elbow joint that allows passage of structures (arteries, veins, nerves, attachment of tendons and ligaments) from the arm to the forearm (3).

The elbow is stabilized by the medial collateral ligament, lateral collateral ligament and the annular ligament enclosed by a thin joint capsule. It has extra synovial anterior and posterior fat pads which are surrounded by a joint capsule (3-5). The anterior and posterior fat pad

become pertinent in the diagnosis of undisplaced, occult elbow fractures as the presence of a prominent or displaced fat pad may represent a joint effusion (3).

1.2.1. Differences between the adult and paediatric elbow

The anatomy of the elbow in the child differs to the adult with vulnerabilities that predispose the paediatric elbow to difficulty or failure to identify fractures or dislocations. As a child grows, the body is in a constant changing phase. Adults have less elastic ligaments and tendons, so they are more prone to ligamentous or tendon injuries (3). For growth to occur, the bones in the bodies have multiple growth plates with ossification centres. The ossification centre is an area where the beginning of ossification (i.e. cartilage cells enlarge and arrange themselves in a row) occurs. If the knowledge of these ossification centres is not understood, they may be misdiagnosed as fractures (6). This incorrect diagnosis may have serious complications. There are six different ossification centres around the paediatric elbow. The mnemonic CRITOE (capitallium, radial head, internal (or medial) epicondyle, trochlea, olecranon, lateral (or external) epicondyle) is used to describe their sequential order of age appearance as in Table 1.1 (7) .

Table 1.1. Ossification centres and age at ossification

Ossification Centre	Age at ossification (Years)
Capitellum	1
Radius	3
Medial epicondyle	5
Trochlea	7
Olecranon	9
Lateral Epicondyle	11

1.3. Elbow imaging

1.3.1. Elbow joint radiographs

Anterior posterior (AP) and lateral radiographs are the standard views obtained on elbow x-ray imaging; however an oblique radiograph can also be requested to demonstrate pathology. There are two important elbow radiographic lines, namely the anterior humeral line and radiocapitellar line which are used to assess the elbow joint.

On a true lateral, a line is drawn along the anterior margin of the humerus and should intersect the middle third of the capitellum (8). This is demonstrated on figure 1.1 where the lateral radiograph demonstrates the anterior humeral line as a black line drawn along the anterior surface of the humerus and is seen passing through the middle third of the capitellum. If less than a third of the capitallium is anterior to this line there is high suspicion of a supracondylar fracture or capitellar physeal fracture dislocation (8).



Figure 1.1 Lateral radiograph with normal anterior humeral line

On both the AP and lateral radiographs the radiocapitellar line is drawn from the mid diaphysis of the radius to the capitellum, failure to intersect the capitellum suggests a radial head dislocation (3, 9). A normal radiocapitellar line is demonstrated in figure 1.2 with a black line drawn through the centre of the radius to the centre of the capitellum.

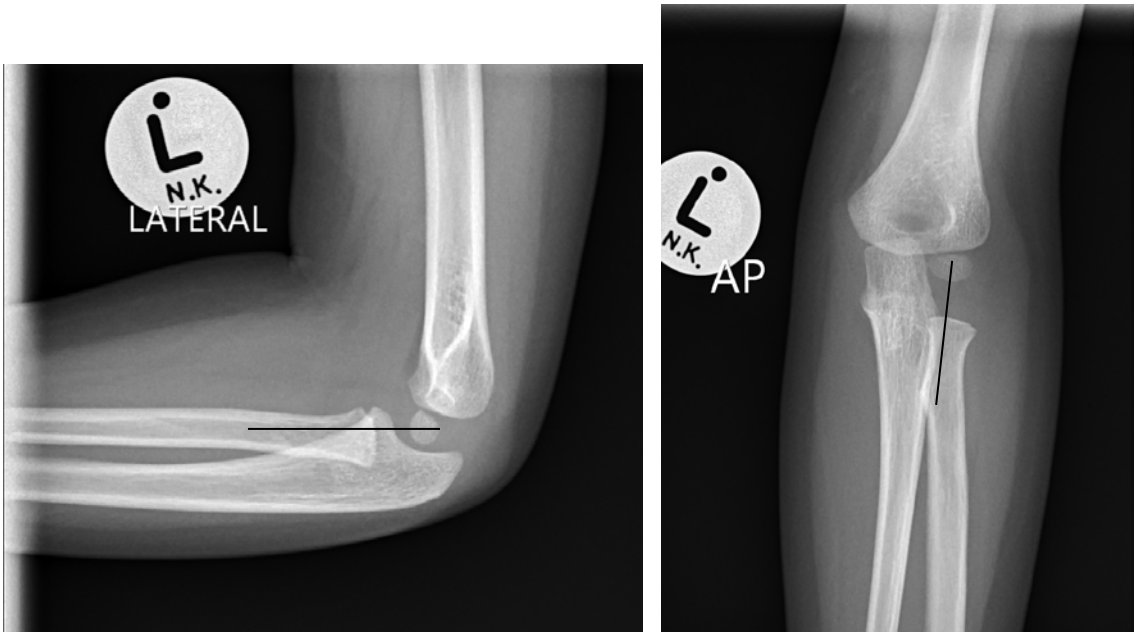

Figure 1.2 AP and lateral radiograph with a normal radiocapitellar line

Further evaluation using the Baumann's angle can be made in the elbow joint. This angle is particularly used to assess displacement of supra condylar fractures, varus and rotational abnormalities. It is formed by the "intersection of a line drawn perpendicular to the humeral shaft and a line along the physis of the lateral condyle" (7), and is evaluated on an AP radiograph.

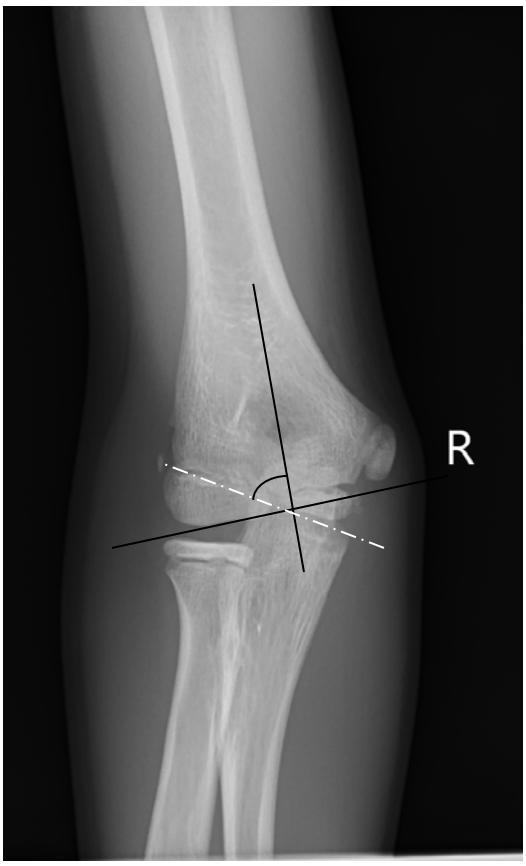

Figure 1.3. AP radiograph of the elbow with the normal Bauman angle

According to a study by Williamson and Coates, the mean Baumann angle was found to be 72 degrees (SD 4 degrees), and 95% of normal elbows ranged from 64 – 81 degrees (8). However, a recent South African study by Kilborn and Moodley gives a range of 85 - 89 degrees, with comparison of both elbow angles not exceeding 5 degrees which would indicate a varus deformity (7).

1.3.2. Elbow ultrasound

Ultrasound is not routinely used in the setting of paediatric elbow fractures or other MSK trauma injuries (9). It has been proven to be good at detection of bone fractures and is therefore comparable to the x-ray (9-11). Ultrasound depiction of the posterior fat pad sign was found to be superior to the x-ray radiographs according to Maeseneer and Jacobson (9, 12). It also has advantages of being accessible, affordable and safe as it has no ionizing radiation exposure compared to x-rays (9,10,13). It has benefits of dynamic real time imaging by providing the opportunity for therapeutic guided injections in certain cases (13), and it allows the parents' presence during investigation(13).

Not only does ultrasound evaluate osseous pathology but it also has an advantage of examination of the soft tissue structures (ligaments, tendons and blood vessels) with the benefit of dynamic evaluation (13). Its largest disadvantage is the skill of performing and interpreting the ultrasound. Another disadvantage is that it may be limited by an above elbow cast therefore allowing examination of the surface of the bone and not the medullary matrix(14).

X-ray therefore takes precedence in our setting because of the expectation to be able to interpret an elbow radiograph from junior level and the abundant availability in many health care facilities.

1.3.3. Elbow MRI

Elbow radiographs that demonstrate only an effusion with no fracture line visualised can be further imaged by magnetic resonance imaging (MRI) (15). MRI can demonstrate occult fractures, articular surface injuries and cartilage injury (14, 15). It is also the most sensitive imaging tool in the identification of effusion (12). Complications such as vascular injuries, septic arthritis and avascular necrosis (AVN) are also well visualized under MRI imaging (15).

Motion artefact needs to be avoided when imaging patients and because MRI takes lengthy duration in acquiring images, this can result in poor imaging from movement particularly in children. This can be avoided by sedating or putting the patient under general anaesthesia (14). This therefore means additional staffing (anaesthetics) for sedation and monitoring as this is required to avoid added complications.

MRI is also not easily available in most hospitals and is expensive compared to x-rays (14, 15).

1.3.4. CT of the elbow

Computer tomography (CT) scan is not routinely used for examination of the paediatric elbow fractures particularly because of exposure to ionising radiation. In a study done to

evaluate the usefulness of CT in paediatric traumatized injury, it was found that management remained unchanged from using clinical and radiographic investigation (16). The same study found that in the adult elbow trauma CT was more useful in obtaining further information particular for surgical intervention(16) .

1.4. Elbow injuries

The elbow is a common site of injury in children. According to Skaggs, paediatric elbow fractures are more common than any other musculoskeletal injuries (2). Sheehan and Dyer approximate that traumatic elbow injuries account for up to 15% visits in the emergency department for both the adult and paediatric population (1).

Trauma to the elbow can cause injury to bones, ligaments, tendons, fat spaces and neuro-vasculature. The injuries of interest for this study are the bony fractures and dislocation. These elbow fractures consist of supracondylar fractures, lateral condyle fractures, medial epicondyle avulsion, olecranon fractures, proximal radial bone fractures and radial head dislocations (4, 7).

Elbow fractures sometimes present only with secondary soft tissue changes on the radiograph. This indicates swelling of the surrounding soft tissue or fluid within the joint. As previously noted, the elbow consists of anterior and posterior fat pad, covered by a capsule. The anterior fat pad extends from the coronoid fossa and is seen anterior to the distal humerus as a thin lucent line (3, 5, 17, 18).

When there is trauma causing effusion or haematoma, the anterior fat pad is lifted anterior superiorly forming a triangular bulge that is called a sail sign (3, 5, 18, 19). The posterior fat pad is deeply situated in the olecranon fossa and is not visualised on a normal radiograph (5, 17). When there is joint effusion it gets lifted posterior away from the humerus becoming evident on a lateral radiograph as the positive fat pad sign (19). These two signs are indirect findings in diagnosing an occult fracture in the elbow, particularly an undisplaced supra condylar fracture (20).

Approximately 60% of all paediatric elbow fractures are supracondylar fractures (3, 21, 22) affecting children between ages 3-10 (21) who have fallen on an out stretched hand (15). Behdad noted that there was a peak increase in supracondylar fractures between age 2-7, this being secondary to the tensile strengthening of the capsule and ligament compared to the bones thereby increasing the chance of elbow injury when there is sufficient force applied (22). Supra condylar fractures are also found to have gender predilection with 75% occurring more in males than in females (22, 23). This is attributed to the different ways of playing by the gender groups (20, 21). Boys tend to be outdoors and rougher, with cycling and playground injuries making the male gender more vulnerable to fracture compared to the female gender.

Furthermore, it was found that the left arm is more predisposed than the right in supracondylar fractures (21, 22) . This was more likely secondary to dominance of the right arm compared to the left.

Supracondylar fractures are known to carry a high risk for neurovascular compromise (3). They are classified according to the Gartland fracture classification (24), which gives guidance in treatment options. Gartland fracture classification is summarised in table 1.2 below:

Table 1.2. Gartland classification of supracondylar fractures of the elbow

Gartland classification	Presentation
Type I	Without displacement
Type II	Distal displacement
Type III	Complete displacement
Type IV	Open fracture or neuro-vascular signs on clinical examination

The second most common elbow injury is the lateral condyle fracture with a prevalence of 10-15% in the age group of 6-10 years. It occurs from a varus force applied to extended elbow while the forearm is supinated (7, 25). The fracture is intra-articular, covered in

synovial fluid that makes it susceptible to non union(25). They are classified according to the Milch calcification which is summarised in table 1.3 below:

Table 1.3. Milch classification for lateral condyle fractures

Classification	Presentation
Milch I	• Fracture through the capitellum. • Lateral trochlear ridge remains normal, preventing dislocation of the radius and ulna. • Stable elbow.
Milch II	• Trans trochlear-lateral metaphyseal fracture. • Medial capsuloligamentous disruption of the radius and lateral dislocation of the ulna. • Unstable elbow.

The remaining fractures in order of highest prevalence are:

- Medial epicondyle fracture (10 %) affecting ages 7-15 years;
- Olecranon fracture (4-7%) affecting ages 10-18 years;
- Proximal radius has a (4-5%);
- Medial condyle (<1%) affecting ages 8-14 years; and the rare lateral epicondyle affecting ages 9-15 years (7).

Some of the fractures are classified under the Salter Harris type of fracture (26, 27). This is a fracture affecting the physis and sometimes epiphysis of a bone. The classification is demonstrated in table 1.4 with illustrations (27) below :

Table 1.4 Salter Harris fracture classification

Type	Figure	Description
Type I		Transverse fracture through the physis
Type II		Fracture line through the physis and the metaphysis
Type III		Fracture through the physis and the epiphysis
Type IV		Fracture through physis, metaphysis, and epiphysis
Type V		Crush injury of the epiphyseal plate

There are other fractures in the radius and ulna bones which are associated with dislocations named the Monteggia and Galeazzi injuries (28, 29). The Monteggia fracture dislocation was first described in 1814 by Giovanni Monteggia. This injury demonstrates fracture of the ulna shaft with associated dislocation of the radiocapitellar joint (4, 20, 28). The Galeazzi fracture-dislocation demonstrates radial shaft fracture with distal radioulnar dislocation and it was first described by Galeazzi in 1943 (4, 20, 29).

1.4.1 Non Accidental injuries

Non Accidental injuries (NAI) should be considered in paediatric elbow fractures. Musculoskeletal injuries are important when assessing for the diagnosis of child abuse because of their different mechanism and presentation on radiographs (30). Presentation in non accidental injuries can be radiographically demonstrated as metaphyseal corner fracture

and bucket handle fractures (30). Supracondylar fractures and other fractures labelled above can also be present in NAI. In situations where clinicians are suspecting NAI, further examination and skeletal survey should be done according to the hospital protocol.

1.4.2. Elbow injury complications

If elbow injuries are missed or inappropriately managed there are three main complications which may follow causing both morbidity and in very rare cases mortality depending on the severity (19).

The common complication is that of mal-union which results in bony deformity and angulation at site of injury. The second more severe complication that warrants immediate attention is that of acute neurovascular injury which is frequently associated with elbow fractures and can also be difficult to assess in an apprehensive child (2) . These injuries may cause ischemic contractures from brachial artery injury resulting in volar compartment syndrome (31, 32). Immediate orthopaedic consultation is indicated for any child with an elbow injury in whom neurologic or vascular compromise is suspected (2). Damage to the ulna nerve (most common), median nerve or radial nerve are also complications to be examined by the clinician (31, 32).

1.4.3. Common errors made by ED doctors

Paediatric elbow fractures are a common injury and require medical doctors to be adequate in their diagnosis and management.

A study done by Espinosa and Nolan, showed that ‘’the disagreement between ED doctors and radiologist ranged between 8-11% with change of management required for 1-3% of those patients (33). The study by Smith and Beasley measured the necessity of second readings by radiologists and they found the general doctors should have basic knowledge to interpret fractures on radiographs that should not result in changes of patient management following interpretation by radiologists (34). In the same study, no particular change had to be made to alter management in the elbow injuries.

In this research study, focus was put on the interpretation of traumatic elbow injury by medical doctors rotating through the paediatric department at Rahima Moosa Mother and Child Hospital (RMMCH).

1.5. Aim

The aim of this study was to determine the rate of errors in elbow injuries by medical doctors in the paediatric department in Rahima Moosa Mother and Child Hospital (RMMCH).

1.6. Study objectives

The objectives of the study were:

i. To determine the rate of error of elbow x-ray reports in the paediatric population by the medical doctors within the paediatric department.
ii. To determine the common type of elbow injury missed by medical doctors in the paediatric department.
iii. To determine the impact of a tutorial on the reporting error by medical doctors in the paediatric department.

2. Materials and Methods

2.1. Research paradigm

This was an intervention-based (diagnostic accuracy) outcome study using a PowerPoint tutorial to teach an approach to interpreting paediatric elbow x-rays. We used data collected during a morning meeting in the Paediatric Department of RMMCH.

The tutorial and the assessments used 20 pre-selected paediatric elbow x-rays: 10 films that were normal and 10 films that were abnormal. These images were selected from the RMMCH PACS database by a paediatric radiologist, representing the Gold Standard. The abnormal images showed a range of pathology from subtle changes to obvious fractures.

The project was conducted on 02 February 2016 at RMMCH during the paediatric department's Tuesday morning meeting. The total number of doctors present for both the tutorial and assessment and thus eligible for inclusion in the study was twenty eight. The group was made up of eighteen interns, one medical officer, five registrars and four consultants. The meeting began with an explanation of the project and thereafter the participants were given time to read through the information participation sheet and to sign the consent form.

The first session consisted of a PowerPoint slideshow containing 20 images, each displayed for one minute. The participants were given a tick sheet (appendix B) to answer from the following options: A = normal, B = possibly abnormal and C = abnormal (Figure 2.1 to 2.3 are examples of the imaging used in the study). Abnormality was further subdivided into: fracture, dislocation and effusion.

The second session consisted of a power point tutorial on the approach to paediatric elbow injury. This power point included slides starting with anatomy, followed by a detailed description of all the commonest elbow fractures and dislocations. The paediatric radiologist reviewed the power point to ensure its appropriateness for this course.

The third session had the same images used as in the first session however in a different sequence and with a second tick sheet (appendix C) for the participants. The participants were provided with the following choices: A= normal, B= possibly abnormal and C = abnormal. Abnormality was further subdivided into; supra condylar, proximal radial, ulna and other related. All tick sheets were kept anonymous.

There were four doctors and medical students that decided not to participate in the study however they were allowed to sit through the tutorial to further their knowledge.

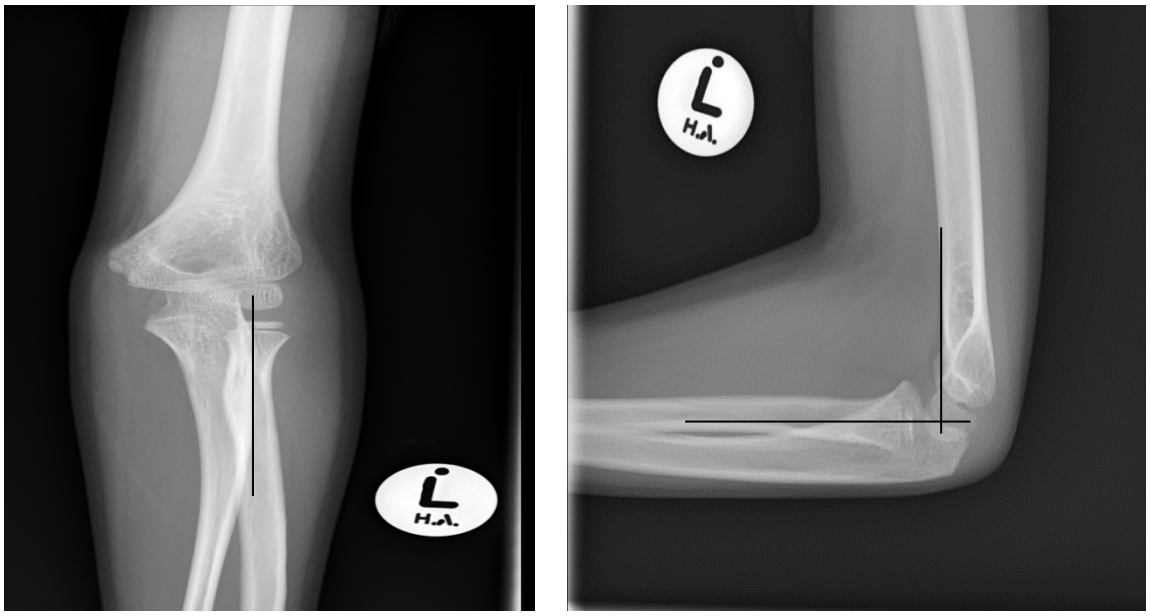

Figure 2.1 AP and lateral radiograph of a normal elbow

There radiograph demonstrates normal radio capitellar line (black line) and anterior humeral line (white line).

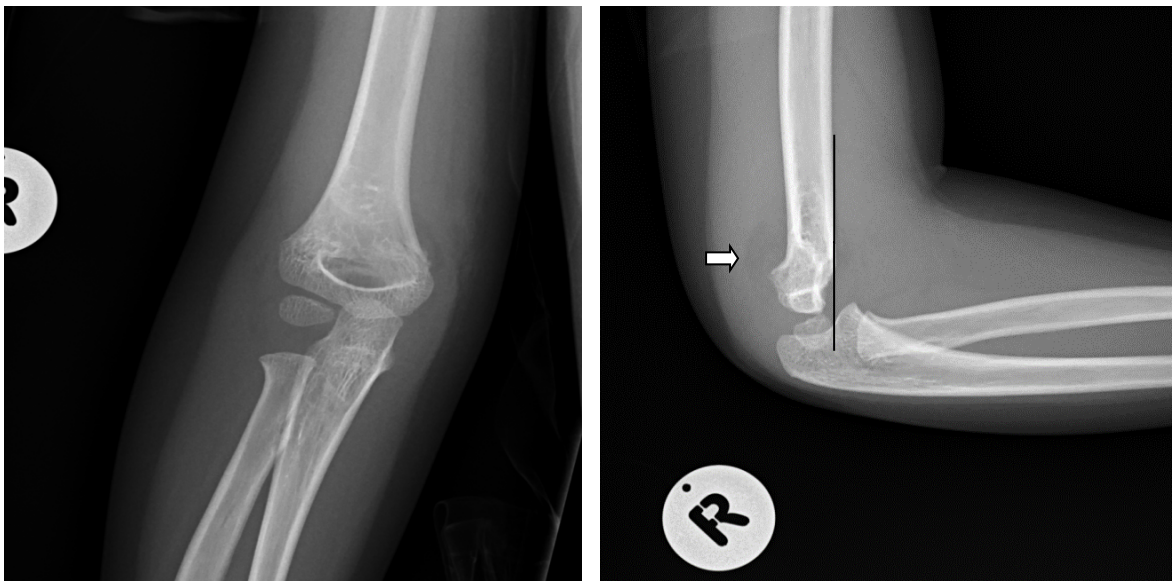

Figure2.2 AP and lateral radiograph of elbow with a supracondylar fracture

There radiographs demonstrate s a positive posterior fat pad sign (white arrow) and displacement of the Anterior humeral line (black line).

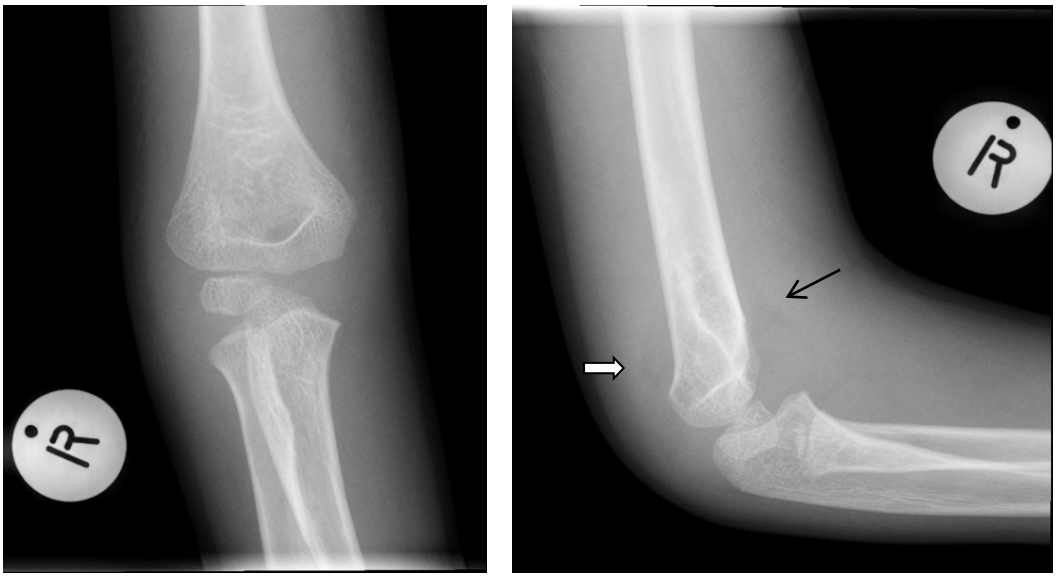

Figure 2.3 AP and lateral radiograph with soft tissue swelling and joint effusion.

The radiograph shows a positive posterior fat pad sign (white arrow) and a triangular shaped anterior fat pad demonstrating indicating a sail sign (black arrow).

2.2. Inclusion criteria

The inclusion criterion was all medical doctors working in the paediatric department that attended the paediatric department morning meeting on the project day.

2.3. Exclusion criteria

All doctors who were late for the paediatric departmental meeting and those who did not consent to participate were excluded from the study.

2.4. Data collection

Data was collected as Pre-tutorial tick sheet A (Appendix B) and post tutorial tick sheet B (Appendix C). This data was entered into an Excel-spread sheet for analysis.

2.5 Statistical analysis

2.5.1 Sample size

Sample size requirements were based on the key research question, namely the comparison of pre-and post-tutorial scores. The sample size estimation was based on a paired t-test, the 5% confidence level and 80% power. The detection of small, medium and large effect sizes (dz=0.2, 0.5 and 0.8 respectively) would require sample sizes of 199, 34 and 15 respectively. The actual sample size of 27 in this study was thus adequate only for the detection of a medium to large effect size (dz=0.56). Sample size calculations were carried out in G*Power (35).

2.5.2 Analysis: general

Descriptive analysis of the data was carried out as follows: Categorical variables are expressed as frequencies and percentages and illustrated by means of bar charts. Continuous variables are summarised by the mean, standard deviation, median and interquartile range, and their distribution illustrated by means of histograms. The comparison of the pre- and post-tests scores was carried out using the paired t-test. Data analysis was carried out using SAS. The 5% significance level was used throughout, thus p-values <0.05 indicate significant results

2.6. Ethics

The study was approved by the Human Research Ethics Committee of the University of the Witwatersrand; approval number M150759. This certificate is attached as Appendix A.

3. Results

Descriptive analysis of the true classification and injury type of the x-rays

The sample size was small and this resulted in the answers being grouped into normal and abnormal. The pre-tutorial abnormal answers included effusion/fracture. The post tutorial abnormal answers included effusion/supracondylar fracture. This is demonstrated in Table 3.1. The findings of possibly abnormal scored slides were grouped with the abnormal results for statistical purposes. A small percentage on the pre (3%) and post tutorial (5%) results was not represented because of incorrect ticking on the answer sheet. This was seen with questions that had multiple conflicting answers as well as questions that were omitted.

Table 3.1. Classification of pre and post tutorial

PRE		POST	
Classification	**n**	**Classification**	**n**
Normal	10	Normal	10
Abnormal	10	Abnormal	10

3.1. Pre-tutorial results

On the pre-tutorial results the mean percentage scored correctly was 52.1% (SD=9.9%, range 35 – 75%). The distribution of the data is shown in figure 3.1.

The slides 3,4,5,9 and 16 were the radiographs that scored the most correct from the participants. These slides displayed Gartland II and Gartland III supracondylar type elbow fractures. These findings were anticipated because of the obvious displacement and or cortical break demonstrated on these fractures.

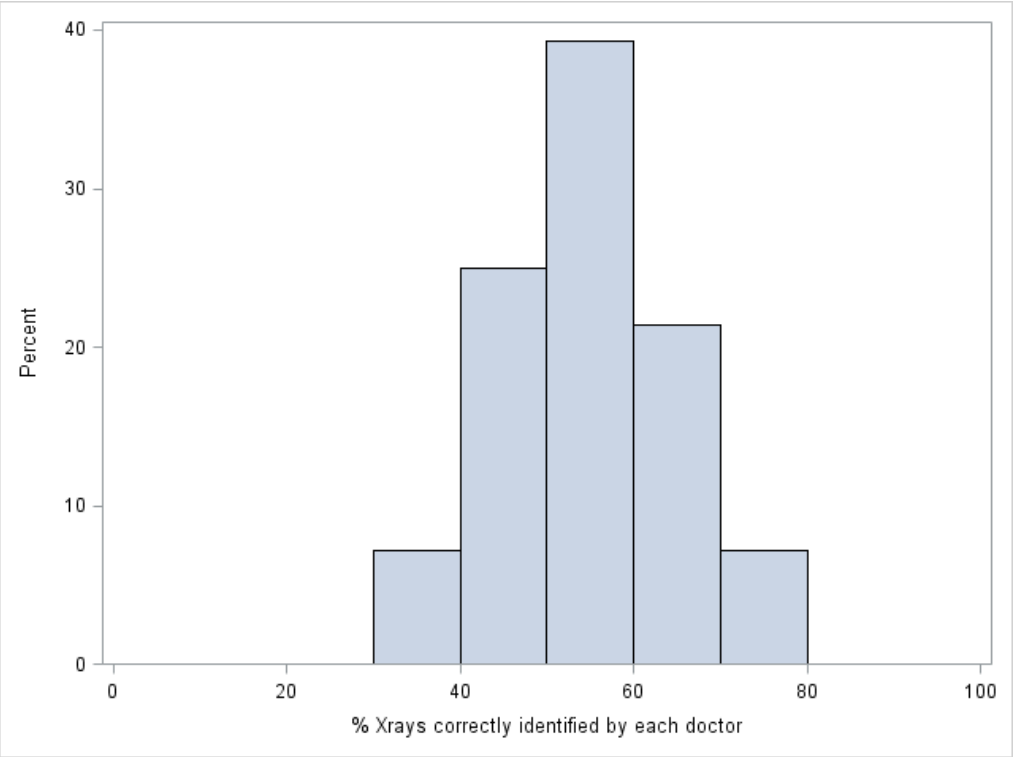

Figure 3.1.Pre tutorial correctly scored results

The pre- tutorial mean percentage error rate result was found to be high at 45%. This percentage is calculated across the 20 radiographs viewed by the 28 doctors resulting in 560 radiographs scored and thus 252 (45.0%) radiographs being scored incorrectly. The breakdown of these 252 radiographs by fracture type, and by slide, is given in figure 3.2. More errors were made by incorrectly diagnosing 148 (58.7%) normal radiographs than the 104 (41.3%) radiographs with fractures, as tabulated in table 3.2.

Table 3.2 Pre-tutorial error results

True result	Number of errors	
	n	%
Abnormal	104	41.3%
Normal	148	58.7%

Figure 3.2 demonstrates the breakdown of errors made. The radiographs that had errors most commonly were radiographs 7, 8, 12, 18 and 20 (The images are demonstrated in figure 3.7-3.11). The abnormal radiographs 20, 12 and 7 are seen to have a higher error rate. These radiographs were diagnosed with Gartland type I supra condylar fracture, that

radiologically represents an undisplaced fracture with secondary soft tissue injury signs. This finding was expected in the pre-tutorial because of the difficulty found when interpreting undisplaced elbow radiographs.

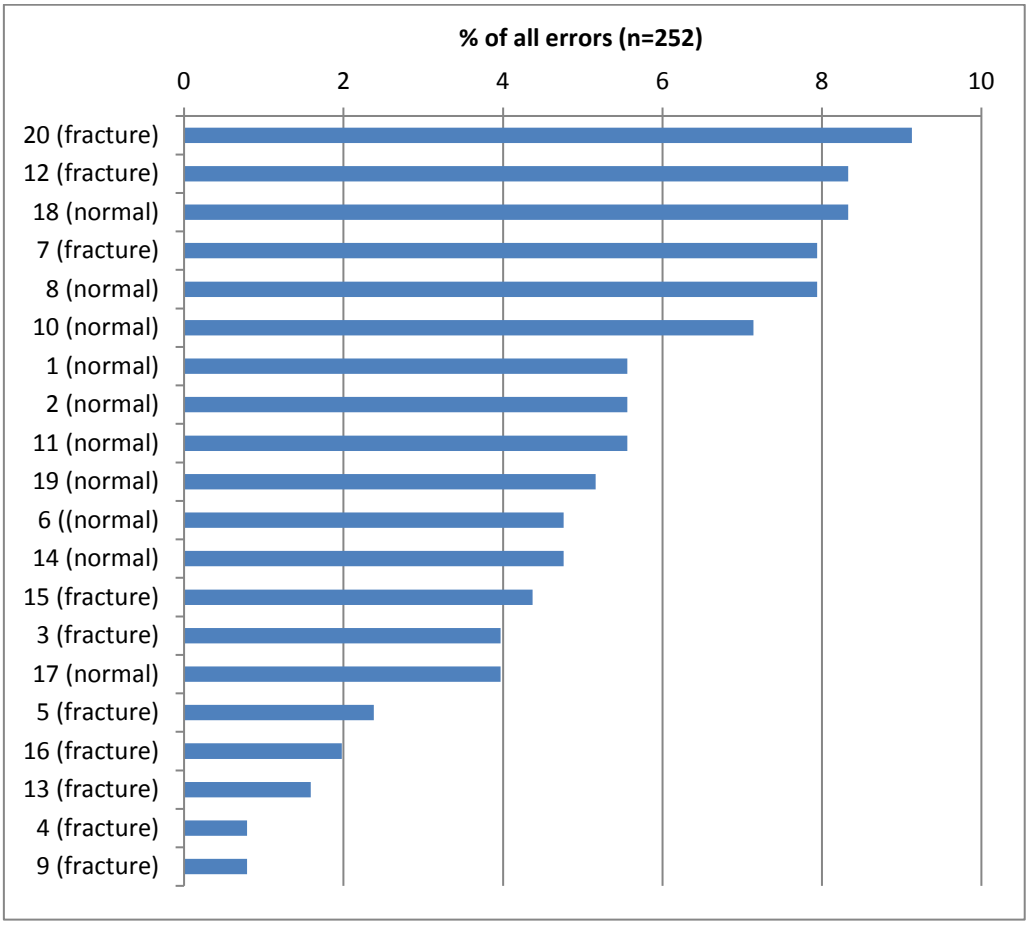

Figure 3.2 Pre tutorial error rate results

3.2. Post-tutorial results

The overall post tutorial mean percentage correctly scored radiographs is 56.4% (range 35-70%, SD=9.5%); and this is demonstrated on figure 3.3. These findings show a 4.3% increase from the pre tutorial results and therefore is not statistically significant.

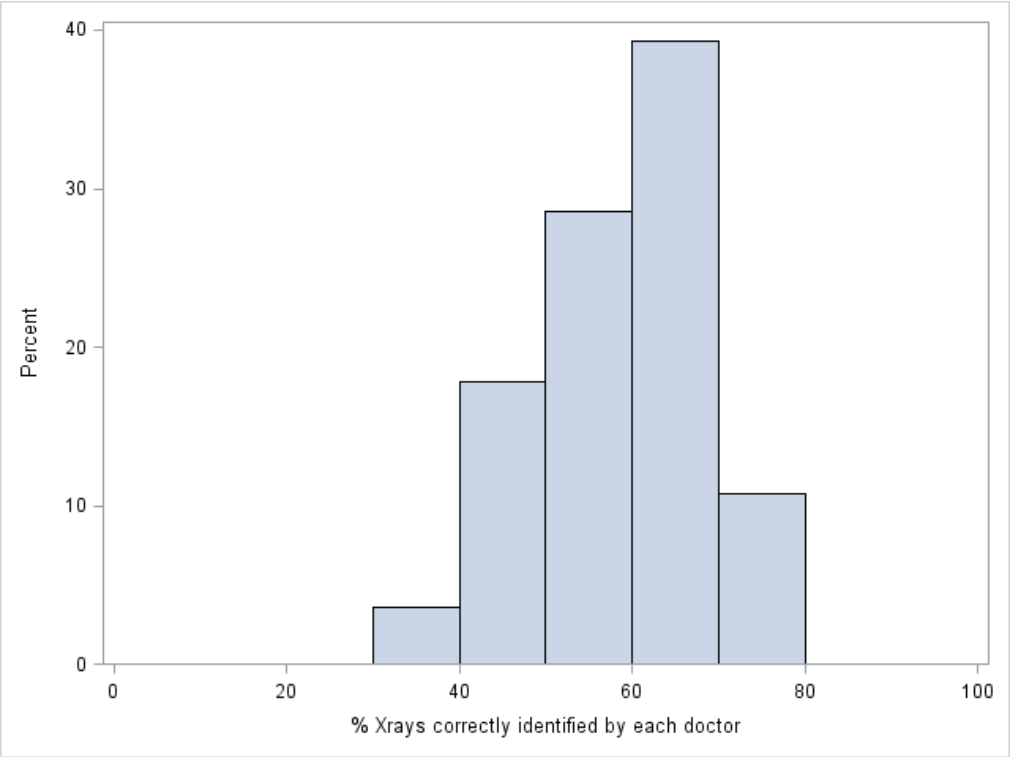

Figure 3.3 Post tutorial correct results

The post- tutorial mean percentage error rate result is found to be 39.3%. This percentage is calculated across the 20 radiographs viewed by the 28 doctors resulting in 560 radiographs scored with 220 (39.3%) radiographs being scored incorrectly. The breakdown of these radiographs by fracture type, and by slide, is given in figure 3.4. The table 3.3 illustrates that more errors were made by incorrectly diagnosing 105 (68.2%) normal radiographs (68.2%) than diagnosing 70 (31.8%) fractures as in table 3.3.

Table 3.3 Post tutorial error rate

True result	Number of errors	
	n	%
Abnormal	70	31.8%
Normal	150	68.2%

Figure 3.4 shows the breakdown of errors by radiographs. Errors were made most commonly on radiographs 8, 9, 12, and 13, these being predominantly normal radiographs (The images are demonstrated in figure 3.8-3.12). The radiographs which demonstrated obvious

supracondylar fractures of Gartland II and III seen in slide 10, 14, 16 and 18 were most correctly scored.

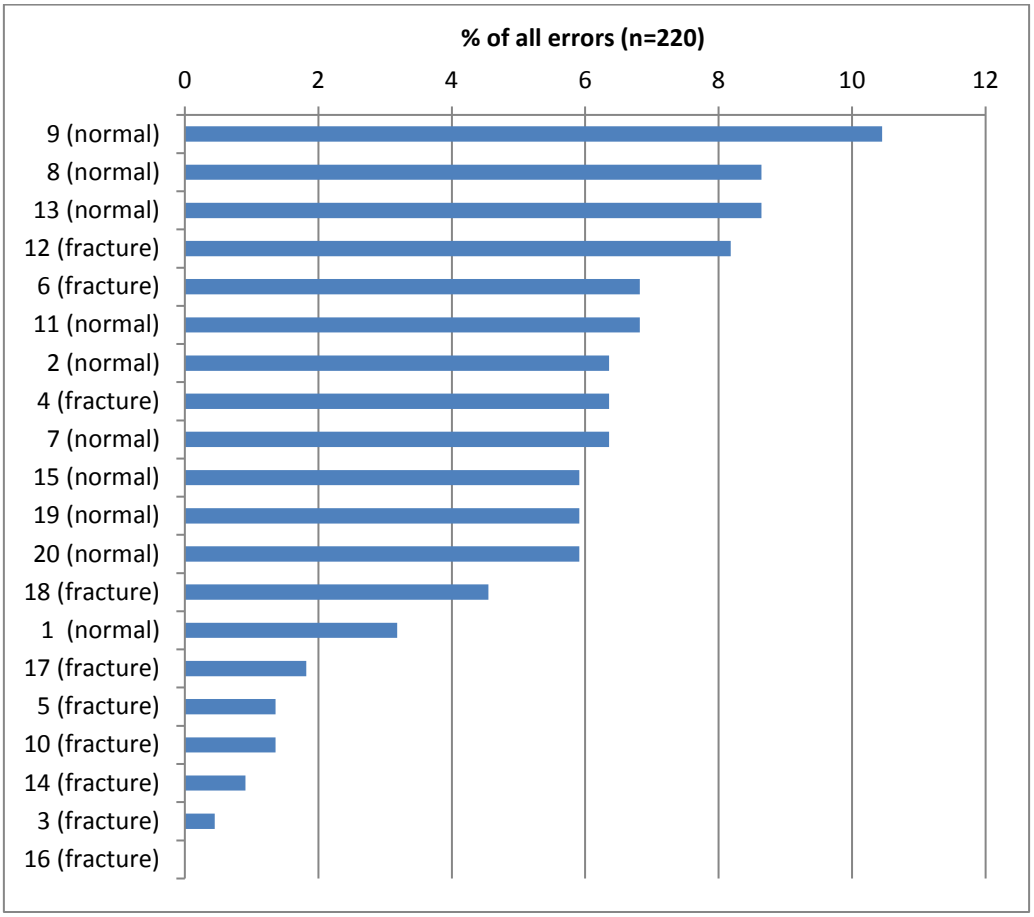

Figure 3.4 Post tutorial error rate results

3.3. Comparison of pre and post tutorial scores

The bar graph in Figure 3.5 demonstrates breakdown of the fracture type comparing pre and post tutorial. The supracondylar Gartland I type fracture has high error rate in the pre compared to the post tutorial which demonstrates improvement in diagnosing the fracture type, although no statistically significant improvement was demonstrated. The findings of supracondylar fracture Gartland type II and III demonstrates improvement with a decrease error rate found on the post-tutorial compared to the pre-tutorial. These findings confirm an improvement in the clinical diagnostic evaluation than statistical evaluation.

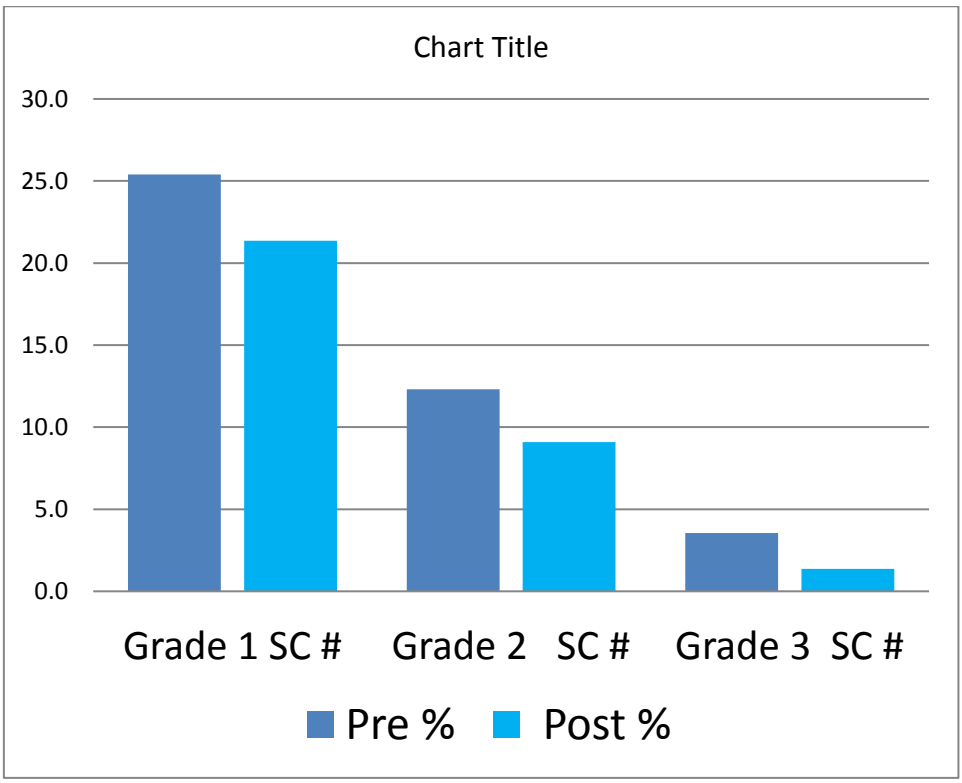

Figure 3.5 pre and post tutorial Gartland fracture types percentage error results

***SC # = Supra condylar fracture**

A profile plot is shown as Figure 3.6 illustrating that there was no significant change in the percentage of radiographs scored correctly from PRE to POST (paired t-test; p=0.16). The mean change was 4.3% (95% CI: -0.5% to 9.0%).

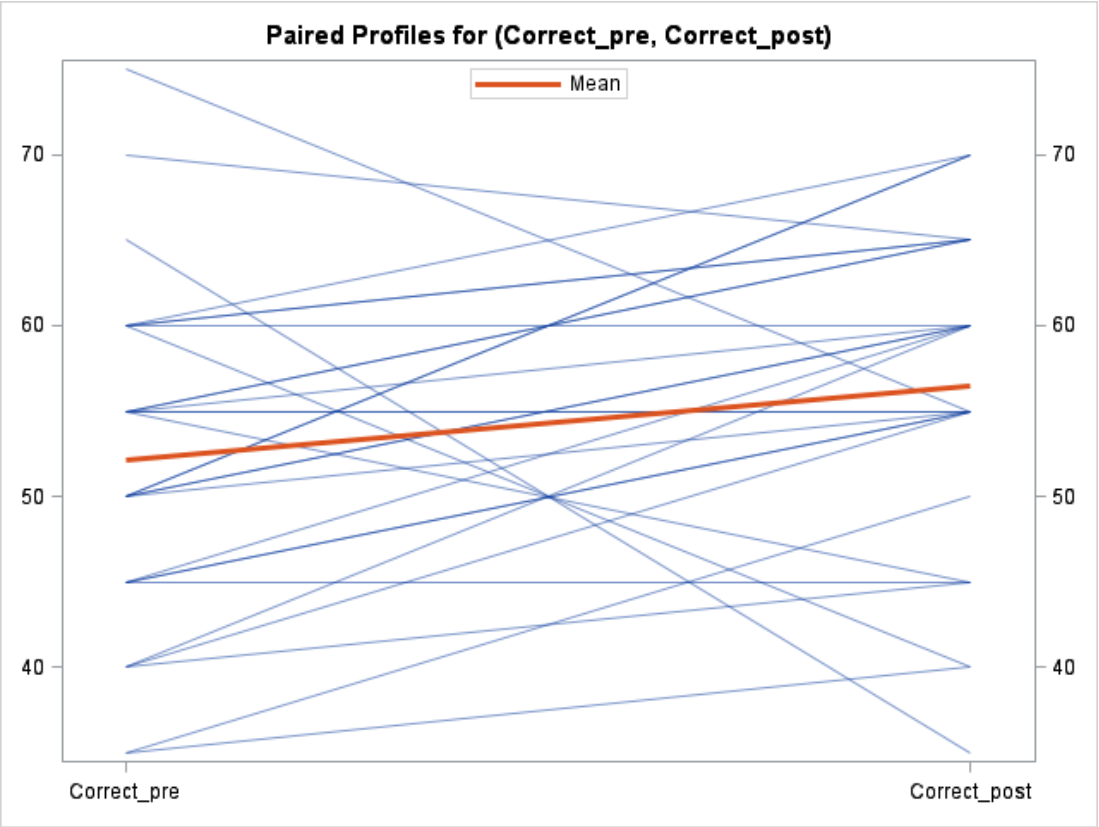

Figure 3.6 Comparison of post- and pre-tutorial scores

Result summary

The results demonstrate little improvement with only a small percentage error rate difference between the pre- and post tutorial. The study findings demonstrate that although no statically significant improvement was demonstrated, the knowledge of supracondylar fracture Gartland type II and III was correctly diagnosed with decrease error rate found on the post-tutorial compared to the pre-tutorial. Furthermore, it demonstrated that although supra condylar fractures Gartland I is still incorrectly diagnosed, it was of a less percentage error rate on the post tutorial compared to the pre-tutorial. There was however notable increase error in over calling normal radiographs on the post tutorial.

Images of the radiographs with the highest error rates from both pre tutorial and post tutorial section:

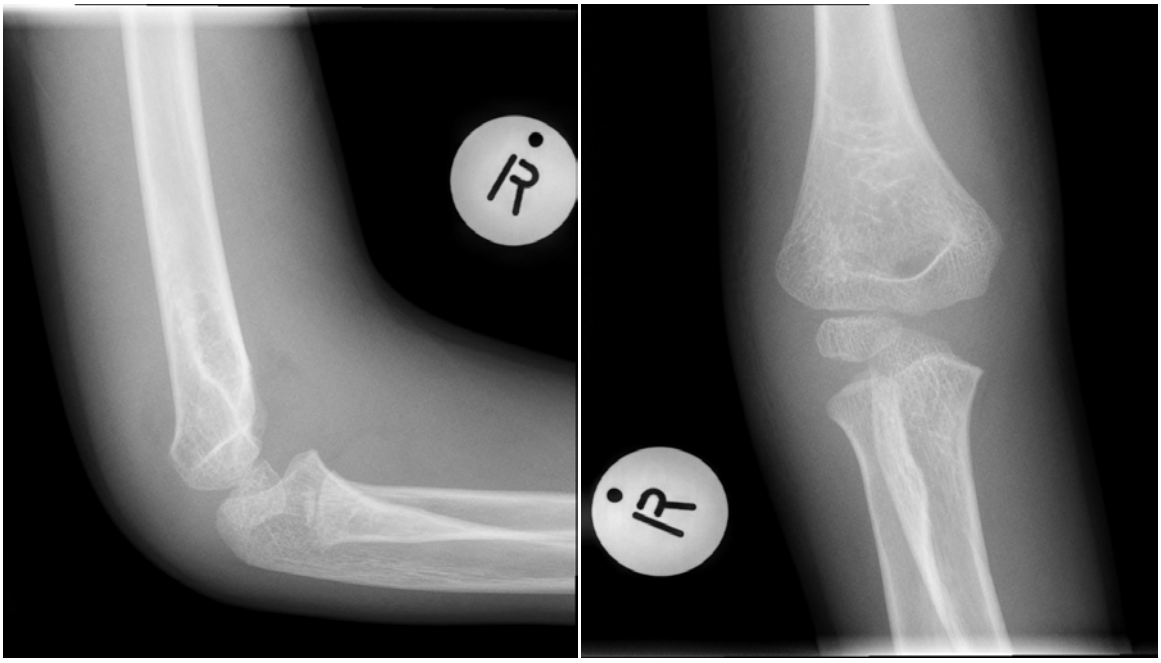

Figure 3.7 Lateral and AP radiograph of slide 7 (pre tutorial)

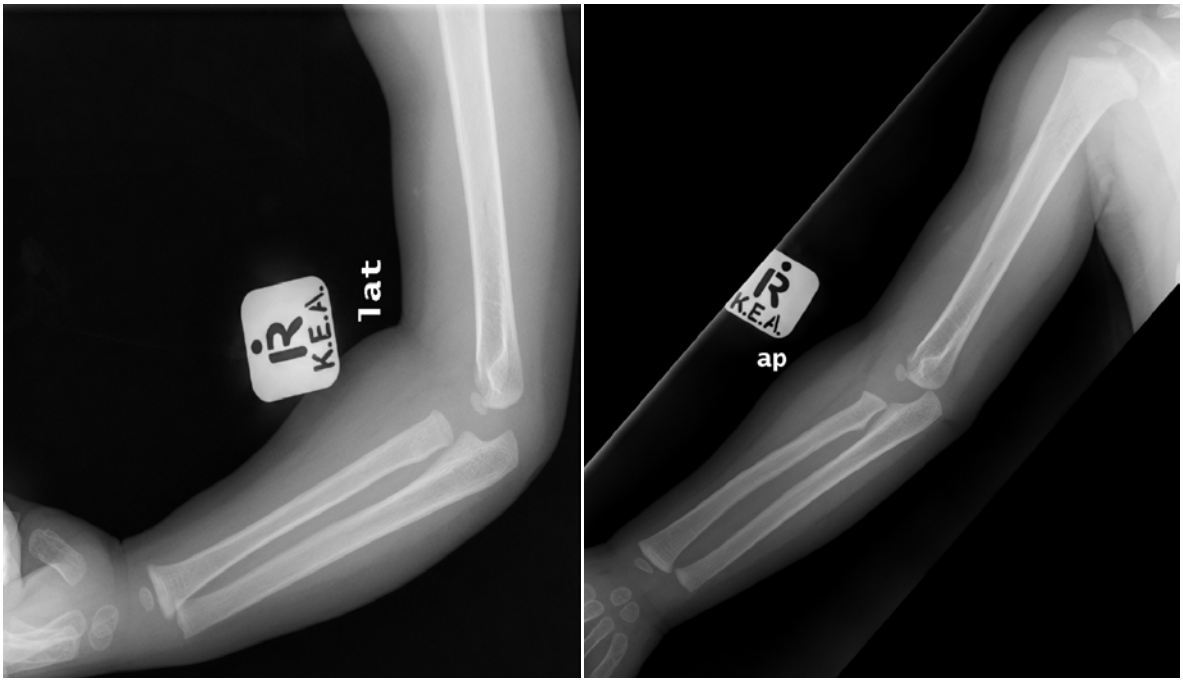

Figure 3.8 Lateral and AP radiograph of slide 8 (pre tutorial) and slide 13 (post tutorial)

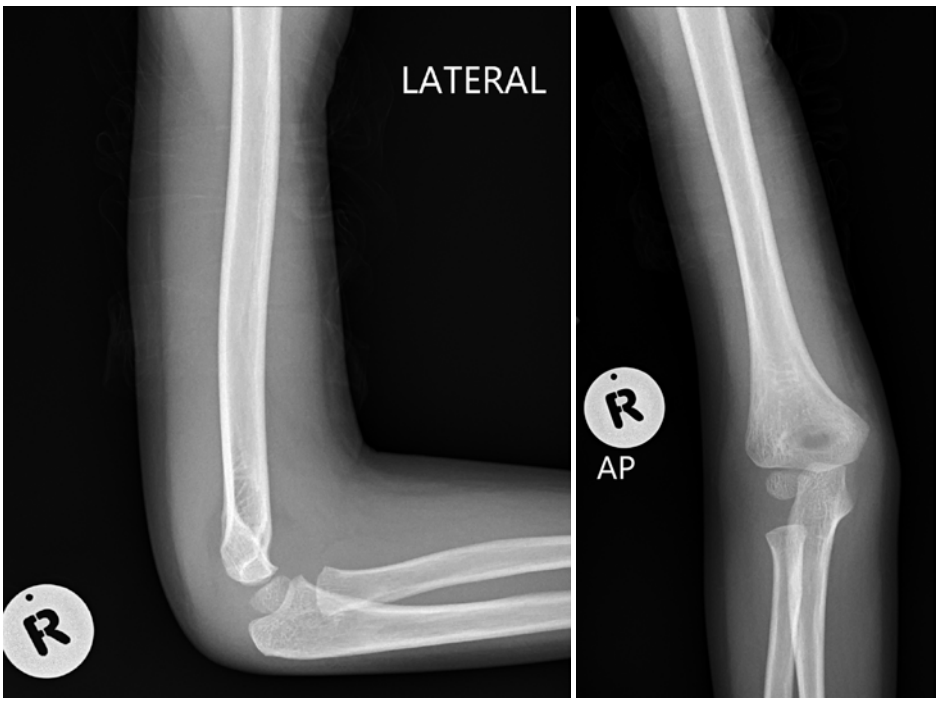

Figure 3.9 Lateral and AP radiograph of slide 12 (pre-tutorial) and slide 6 (post tutorial)

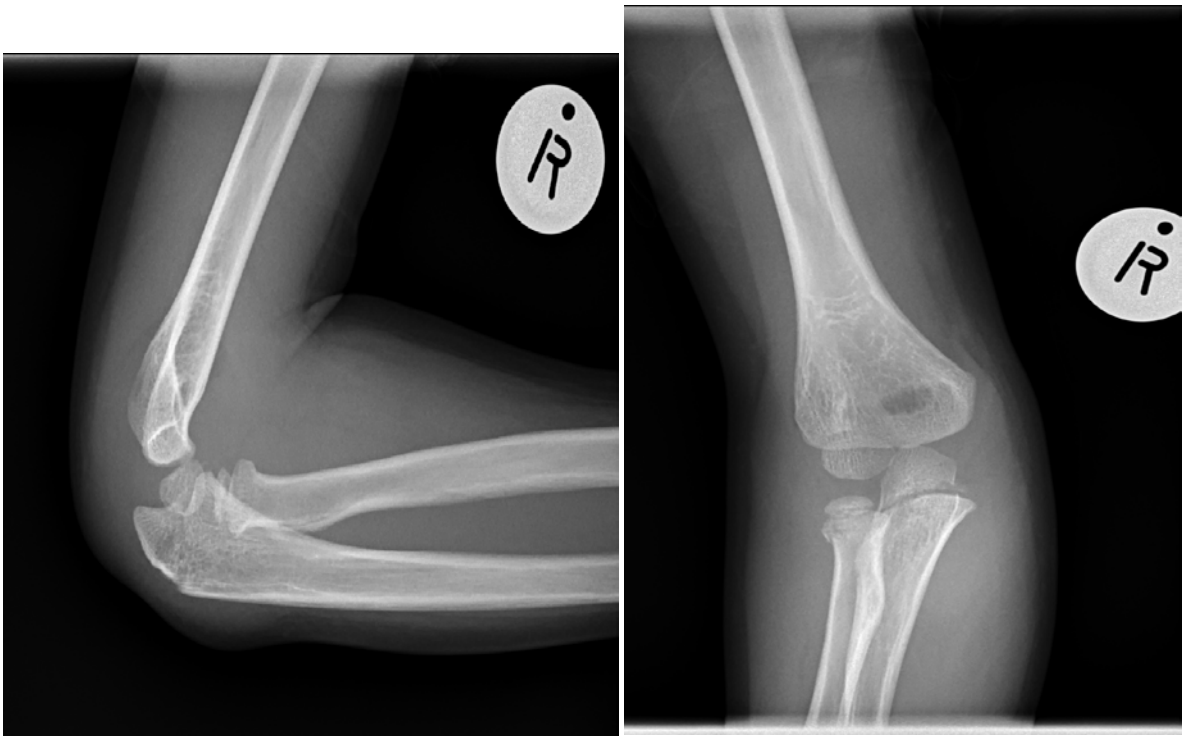

Figure 3.10 Lateral and AP radiograph of slide 18 (pre-tutorial) and slide 9 (post tutorial)

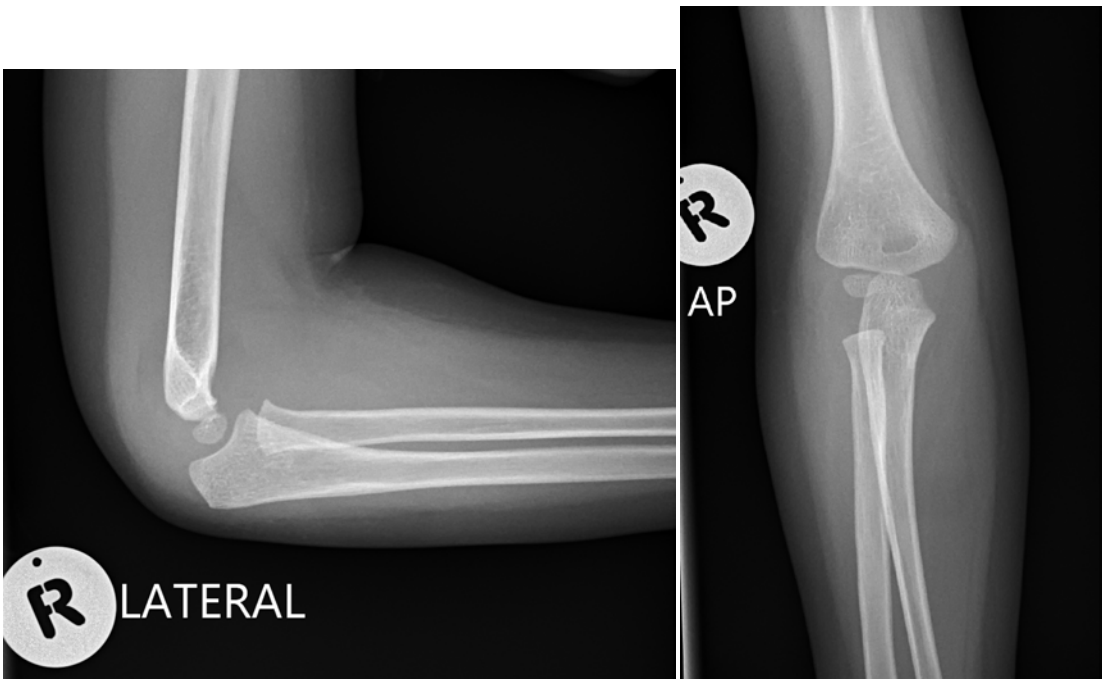

Figure 3.11 Lateral and AP radiographs of slide 20 (pre tutorial) and slide 12 (post tutorial)



Figure3.12 Lateral and AP radiographs of slide 8 (post tutorial)

4. Discussion

4.1 The context

Elbow x-rays are the first line of investigation in the assessment of injury to the elbow making their interpretation vital in directing management of the patient. The elbow has been recognised to be an anatomical region where fractures are commonly missed (2, 36). This makes the knowledge and understanding of growing paediatric elbow anatomy and ossification centres important (6).

Minnes and Klassen did a study comparing emergency practitioners and radiologists regarding the agreement in interpretation of paediatric extremity radiographs in injured children and adolescents. This study demonstrated that compared to all the other extremities, the elbow joint was the most common anatomic site that the emergency practitioners found it difficult to identify pathology (36).

Gartland was the first author to document error rates in diagnostic radiology(24). He reported a high error rate of 30% on abnormal radiographs by paediatric radiologists. A total error rate of 2.7% was found with a 1.6% miss rate and a 1.1% over call rate(24). The ankle showed the highest error rate at 2.9 %, with the elbow the second highest error rate of 2.7% (37).

Literature has more examples where the error rate was evaluated and found to be less than that found in Gartland's study, and they all did not exceed 5% error rate. The following are examples of articles on error rate amongst radiologists:

- Borgstede et al used a RADPEER program to investigate interpretive disagreement rates by radiologists and the study found an error rate of 2.9% in difficult cases and 0.8% in non-difficult cases (37, 38).
- Soffa et al reviewed 6,703 cases and found an error rate of 3.5% in a study (37, 39) . This study aimed to calculate disagreement rates by radiologists and therefore developed a modality benchmark to use in quality assessment imaging interpretation (39).

- Siegle et al reviewed a group of community hospitals over a period of 7 years with greater than 11 000 images reviewed by 35 radiologists. They were assessing the disagreement in imaging interpretation by radiologists and found the error rate to be 3% (40).

Two studies compared emergency doctors (ED) and radiologists in interpreting radiographs. Minnes et al found an 85% agreement between the findings of the ED and the radiologists (36) and Petinaux et al concluded that there was a good agreement in interpreting extremity radiographs, with an error rate of 2.7% on orthopaedic x-rays(41) . Minnes further stated that the disagreements were mostly in those presenting with effusion and minor fractures (36).

In our study, we found a higher error rate, both pre tutorial 48% of and post tutorial of 39.3%. This high error rate could have been influenced by our small sample size compared to the studies quoted above.

A second factor that could have impacted on our error rate was that we assessed the doctors in the paediatric department, not the orthopaedic or emergency department. Although the paediatric specialists and registrars do not commonly come across elbow fractures, they are expected to be able to interpret and diagnose elbow injuries. In a study by Ryan at el, the paediatric registrars were evaluated on their ability to diagnose and manage fractures. They also found that the skill to recognise and manage paediatric fractures was suboptimal. They showed a proportion of correct answers of 60%, i.e. error rate of 40%, which is similar to our finding. They stressed the importance of their paediatric registrars' competency in acquiring basic skill in orthopaedic clinical assessment and interpretation of radiographs (42).

Literature has shown that supra condylar fractures are the most common elbow fracture (7, 36) . In our study, we found that supracondylar fracture Gartland type I is the most common to be incorrectly diagnosed. The Gartland type I supracondylar fracture presents as an undisplaced fracture, with soft tissue changes being the main diagnostic clue: positive posterior fat pad indicating an effusion. Effusion is an important radiological sign of subtle pathology. Savage and Kelly also found this sign to be difficult to interpret and emphasised

that the elbow requires critical evaluation on the true lateral x-ray for cortical break, alignment and secondary soft tissue swelling signs (20).

4.2. Current applications

In our study we found that although there was small change in the post-tutorial section, there was improvement in diagnosing the supra condylar fractures. In our hospital setting (RMMCH) the knowledge of supracondylar fracture influences quality patient management. The earlier the diagnosis is made the sooner the patient is managed or referred to the orthopaedic department. This also improves service delivery in our hospital making our doctors efficient and effective with time management as well as patient care. These factors tie in with our South African Batho Pele principals. These are principals that are aligned to the South African Constitution and ensure that patients know the service they are entitled to (43).

Our study further found that there was increase error in over calling normal radiographs on the post tutorial section. In our setting all the radiographs are reviewed and reported by the radiology registrar, thereafter approved by the paediatric radiologist between 8h00 and 16h00 during the week. This assists with any concern the clinicians have with difficult radiographs and also contributes in correcting missed fractures or over called fracture diagnosis. In the instance where there is over calling of a fracture, the patient is managed with a u-slab /cast that will be removed within four weeks. This study established that the clinicians showed radiological and clinical growth with regard to the pre and post tutorial findings.

4.3. Limitations of the current study

- As compared to other studies the limitation of this study is the sample size. The small number of participates resulted in a poor statistical significant study.

- Low representation of senior doctors compared to the junior doctors in the study. Although the interest was in the junior doctors, it would have been interesting to be able to compare the junior doctors with the senior doctors.

- Lack of Involvement of other clinical disciplines, particularly emergency department. The emergency department at RMMCH was invited but did not participate.

4.4. Future applications

Continuous in-house lectures to the clinicians of various emergency paediatric pathologies particularly elbow injuries are recommended. This can be done via an intervention based monthly tutorials prepared by the juniors with a supervisor from the senior group, and may be in the form of posters, presentations or oral power point presentation.

Furthermore, assessments of the clinicians should also be conducted on a regular basis as well as auditing of radiological cases retrospectively to assess impact of the above-mentioned interventional lectures and tutorials.

5. Conclusion

Elbow fractures are common in the paediatric patient and can be associated with neurovascular complications and skeletal deformity resulting in patient morbidity. This requires good knowledge of the paediatric elbow anatomy and a proper evaluation and interpretation of elbow radiographs so that appropriate initial management of fractures occurs, thereby minimizing morbidity.

The study error rate of interpreting elbow fractures by the paediatric doctors is high. There was diagnostic improvement of the doctors in diagnosing supracondylar fractures particularly type I. This also resulted in misdiagnosing normal radiographs by overcalling them as fractures. These findings demonstrate that our doctors are now more alert when it comes to reviewing elbow injuries and this therefore improves their clinical management and service delivery. We recommend on-going in-service training of clinicians to maximise detection of fractures.

6. References

(1) Sheehan SE, Dyer GS, Sodickson AD*, et al.* 2013. Traumatic Elbow Injuries: What the Orthopedic Surgeon Wants to Know. *RadioGraphics*, 33(3):869-88.

(2) Skaggs D, Pershad J. 1997. Pediatric elbow trauma. *Pediatr Emerg Care*, 13(6):425-34.

(3) Ramponi DR, Kaufmann JA. 2012. Elbow injuries and fractures. *Adv Emerg Nurs J*, 34(2):99-109; quiz 10-1.

(4) Grayson DE. 2005. The Elbow: Radiographic Imaging Pearls and Pitfalls. *Seminars in Roentgenology*, 40(3):223-47.

(5) Bernard F. Morrey, Sanchez-Sotelo J. The Elbow and Its Disorders Fourth ed: Saunders 2008.

(6) Fick DS, Lyons TA. 1997. Interpreting elbow radiographs in children. *Am Fam Physician*, 55(4):1278-82.

(7) Kilborn T, Moodley H, Mears S. 2015. Elbow your way into reporting paediatric elbow fractures – A simple approach. *South African Journal of Radiology*, 19(2).

(8) Williamson DM, Coates CJ, Miller RK*, et al.* 1992. Normal characteristics of the Baumann (humerocapitellar) angle: an aid in assessment of supracondylar fractures. *J Pediatr Orthop*, 12(5):636-9.

(9) Eckert K, Ackermann O, Schweiger B*, et al.* 2013. Ultrasound evaluation of elbow fractures in children. *J Med Ultrason (2001)*, 40(4):443-51.

(10) Rathfelder FJ, Paar O. 1995. [Possibilities for using sonography as a diagnostic procedure in fractures during the growth period]. *Unfallchirurg*, 98(12):645-9.

(11) Moritz JD, Hoffmann B, Meuser SH*, et al.* 2010. Is ultrasound equal to X-ray in pediatric fracture diagnosis? *Rofo*, 182(8):706-14.

(12) De Maeseneer M, Jacobson JA, Jaovisidha S*, et al.* 1998. Elbow effusions: distribution of joint fluid with flexion and extension and imaging implications. *Invest Radiol*, 33(2):117-25.

(13) Lee KS, Rosas HG, Craig JG. 2010. Musculoskeletal ultrasound: elbow imaging and procedures. *Semin Musculoskelet Radiol*, 14(4):449-60.

(14) Gordon AC, Friedman L, White PG. 1997. Pictorial review: magnetic resonance imaging of the paediatric elbow. *Clin Radiol*, 52(8):582-8.

(15) Pudas T, Hurme T, Mattila K*, et al.* 2005. Magnetic resonance imaging in pediatric elbow fractures. *Acta Radiol*, 46(6):636-44.

(16) Blickman JG, Dunlop RW, Sanzone CF*, et al.* 1990. Is CT useful in the traumatized pediatric elbow? *Pediatr Radiol*, 20(3):184-5.

(17) John SD, Wherry K, Swischuk LE*, et al.* 1996. Improving detection of pediatric elbow fractures by understanding their mechanics. *RadioGraphics*, 16(6):1443-60; quiz 63-4.

(18) Brant WE HC. Fundamentals of diagnostic radiology: Lippincott Williams & Wilkins; 2007.

(19) Datir A, Thurston M, Thurston M*, et al.* 2017. Supracondylar humeral fractures. Available: https://radiopaedia.org/articles/supracondylar-humeral-fracture-2 [Accessed on 11/12/2017].

(20) Savage T, Kelly B. 2013. Interpretration of radiographs. *Ulster Med J*, 82(1):26-30.

(21) Madjar-Simic I, Talic-Tanovic A, Hadziahmetovic Z*, et al.* 2012. Radiographic assessment in the treatment of supracondylar humerus fractures in children. *Acta Inform Med*, 20(3):154-9.

(22) Behdad A, Behdad S, Hosseinpour M. 2013. Pediatric Elbow Fractures in a Major Trauma Center in Iran. *Arch Trauma Res*, 1(4):172-75.

(23) Marquis CP, Cheung G, Dwyer JSM*, et al.* 2008. Supracondylar Fractures Of The Humerus. *Cur Orthopaed*, 22(1):62-9.

(24) Garland LH. 1949. On the Scientific Evaluation of Diagnostic Procedures. *Radiology*, 52(3):309-28.
(25) Smithuis R. 2008. Elbow Fractures in Children.Available: http://www.radiologyassistant.nl/en/p58c4dd5b9219a/elbow-fractures-in-children.html [Accessed on 18/03/2018].
(26) Salter R, Harris R. 1963. Injuries Involving the Epiphyseal Plate. *J Bone Joint Surg Am*, 45(3): 587-622.
(27) Murphy A, Gaillard F. 2017. Salter-Harris classification. Available: https://radiopaedia.org/articles/salter-harris-classification [Accessed on 2018/03/30].
(28) Monteggia G. 1814. Istituzioni Chirurgiche. *Milan: Maspero*, 5.
(29) Sebastin SJ, Chung KC. 2010. A historical report on Riccardo Galeazzi and the management of Galeazzi fractures. *J Hand Surg Am*, 35(11):1870-7.
(30) Dwek JR. 2011. The radiographic approach to child abuse. *Clin Orthop Relat Res*, 469(3):776-89.
(31) Greenspan A. Orthopedic imaging, a practical approach. Fourth ed. USA: Lippincott Williams & Wilkins; 2004.
(32) Borut Marincek , Dondelinger RF. 2008. Emergency Radiology: Imaging and Intervention. *Radiology*, 247(1):37-37.
(33) Espinosa JA, Nolan TW. 2000. Reducing errors made by emergency physicians in interpreting radiographs: longitudinal study. *BMJ*, 320(7237):737-40.
(34) Smith PD, Temte J, Beasley JW*, et al.* 2004. Radiographs in the office: is a second reading always needed? *J Am Board Fam Pract*, 17(4):256-63.
(35) Faul F, Erdfelder E, Lang A-G*, et al.* 2007. G*Power 3: A flexible statistical power analysis program for the social, behavioral, and biomedical sciences. *Behavior research methods*, 39(2):175-91.
(36) Minnes BG, Sutcliffe T, Klassen TP. 1995. Agreement in the interpretation of extremity radiographs of injured children and adolescents. *Acad Emerg Med*, 2(9):826-30.
(37) Bisset GSI, Crowe J. 2014. Diagnostic errors in interpretation of pediatric musculoskeletal radiographs at common injury sites. *Pediatr Radiol*, 44(5):552-7.
(38) Borgstede JP, Lewis RS, Bhargavan M*, et al.* 2004. RADPEER quality assurance program: a multifacility study of interpretive disagreement rates. *J Am Coll Radiol*, 1(1):59-65.
(39) Soffa DJ, Lewis RS, Sunshine JH*, et al.* 2004. Disagreement in interpretation: a method for the development of benchmarks for quality assurance in imaging. *J Am Coll Radiol*, 1(3):212-7.
(40) Siegle RL, Baram EM, Reuter SR*, et al.* 1998. Rates of disagreement in imaging interpretation in a group of community hospitals. *Acad Radiol*, 5(3):148-54.
(41) Petinaux B, Bhat R, Boniface K*, et al.* 2011. Accuracy of radiographic readings in the emergency department. *Am J Emerg Med*, 29(1):18-25.
(42) Ryan LM, DePiero AD, Sadow KB. 2004. Recognition and management of pediatric fractures by pediatric residents. *Paediatrics*, 114(6):1530-3.
(43) Administration DoPSa. 1997. Transforming Public Service Delivery (Batho Pele White Paper) Available: http://www.dpsa.gov.za/dpsa2g/documents/acts&regulations/frameworks/white-papers/transform.pdf [Accessed on 31/03/2018].

Appendix A: Ethics Clearance Certificate

R14/49 Dr Gopolang Magano

HUMAN RESEARCH ETHICS COMMITTEE (MEDICAL)

CLEARANCE CERTIFICATE NO. M150759

NAME: (Principal Investigator)	Dr Gopolang Magano
DEPARTMENT:	Radiation Sciences University of Witwatersrand with data from Rahima Moosa Mother and Child Hospital
PROJECT TITLE:	Paediatric Doctors Error rate in Detectetion of Paediatric Elbow Injuries at Rahima Moosa Mother and Child Hospital
DATE CONSIDERED:	31 July 2015
DECISION:	Approved unconditionally
CONDITIONS:	
SUPERVISOR:	Dr T. Pillay
APPROVED BY:	Professor A Woodiwiss, Co-Chairperson, HREC (Medical)
DATE OF APPROVAL:	17/08/2015

This clearance certificate is valid for 5 years from date of approval. Extension may be applied for.

DECLARATION OF INVESTIGATORS

To be completed in duplicate and **ONE COPY** returned to the Secretary in Room 10004, 10th floor, Senate House, University.

I/we fully understand the conditions under which I am/we are authorized to carry out the above-mentioned research and I/we undertake to ensure compliance with these conditions. Should any departure be contemplated, from the research protocol as approved, I/we undertake to resubmit the application to the Committee. **I agree to submit a yearly progress report**.

Principal Investigator Signature

Date 21/08/2015

PLEASE QUOTE THE PROTOCOL NUMBER IN ALL ENQUIRIES

Appendix B: Tick sheet A

Paediatric elbow pathology: Answer sheet of section A.

Please tick one of the boxes below following the image displaced. Rank:

Image 1	Normal ☐ Possibly abnormal ☐	Abnormal : ☐ Effusion ☐ Fracture ☐ Dislocation ☐
Image 2	Normal ☐ Possibly abnormal ☐	Abnormal : ☐ Effusion ☐ Fracture ☐ Dislocation ☐
Image 3	Normal ☐ Possibly abnormal ☐	Abnormal : ☐ Effusion ☐ Fracture ☐ Dislocation ☐
Image 4	Normal ☐ Possibly abnormal ☐	Abnormal : ☐ Effusion ☐ Fracture ☐ Dislocation ☐
Image 5	Normal ☐ Possibly abnormal ☐	Abnormal : ☐ Effusion ☐ Fracture ☐ Dislocation ☐
Image 6	Normal ☐ Possibly abnormal ☐	Abnormal : ☐ Effusion ☐ Fracture ☐ Dislocation ☐
Image 7	Normal ☐ Possibly abnormal ☐	Abnormal : ☐ Effusion ☐ Fracture ☐ Dislocation ☐
Image 8	Normal ☐ Possibly abnormal ☐	Abnormal : ☐ Effusion ☐ Fracture ☐ Dislocation ☐
Image 9	Normal ☐ Possibly abnormal ☐	Abnormal : ☐ Effusion ☐ Fracture ☐ Dislocation ☐
Image 10	Normal ☐ Possibly abnormal ☐	Abnormal : ☐ Effusion ☐ Fracture ☐ Dislocation ☐

Image 11	Normal ☐ Possibly abnormal ☐	Abnormal : ☐ Effusion ☐ Fracture ☐ Dislocation ☐
Image 12	Normal ☐ Possibly abnormal ☐	Abnormal : ☐ Effusion ☐ Fracture ☐ Dislocation ☐
Image 13	Normal ☐ Possibly abnormal ☐	Abnormal : ☐ Effusion ☐ Fracture ☐ Dislocation ☐
Image 14	Normal ☐ Possibly abnormal ☐	Abnormal : ☐ Effusion ☐ Fracture ☐ Dislocation ☐
Image 15	Normal ☐ Possibly abnormal ☐	Abnormal : ☐ Effusion ☐ Fracture ☐ Dislocation ☐
Image 16	Normal ☐ Possibly abnormal ☐	Abnormal : ☐ Effusion ☐ Fracture ☐ Dislocation ☐
Image 17	Normal ☐ Possibly abnormal ☐	Abnormal : ☐ Effusion ☐ Fracture ☐ Dislocation ☐
Image 18	Normal ☐ Possibly abnormal ☐	Abnormal : ☐ Effusion ☐ Fracture ☐ Dislocation ☐
Image 19	Normal ☐ Possibly abnormal ☐	Abnormal : ☐ Effusion ☐ Fracture ☐ Dislocation ☐
Image 20	Normal ☐ Possibly abnormal ☐	Abnormal : ☐ Effusion ☐ Fracture ☐ Dislocation ☐

Appendix C: Tick sheet B

Paediatric elbow pathology: Answer sheet of section B.

Please tick one of the boxes below following the image displaced. Rank:

Image 1	Normal	☐	Abnormal :	☐	
			Effusion	☐	Supra condylar fracture ☐
	Possibly abnormal	☐	Dislocation	☐	Proximal ulna fracture ☐
					Proximal radial fracture ☐
					Other fractures ☐
Image 2	Normal	☐	Abnormal :	☐	
			Effusion	☐	Supra condylar fracture ☐
	Possibly abnormal	☐	Dislocation	☐	Proximal ulna fracture ☐
					Proximal radial fracture ☐
					Other fractures ☐
Image 3	Normal	☐	Abnormal :	☐	
			Effusion	☐	Supra condylar fracture ☐
	Possibly abnormal	☐	Dislocation	☐	Proximal ulna fracture ☐
					Proximal radial fracture ☐
					Other fractures ☐
Image 4	Normal	☐	Abnormal :	☐	
			Effusion	☐	Supra condylar fracture ☐
	Possibly abnormal	☐	Dislocation	☐	Proximal ulna fracture ☐
					Proximal radial fracture ☐
					Other fractures ☐
Image 5	Normal	☐	Abnormal :	☐	
			Effusion	☐	Supra condylar fracture ☐
	Possibly abnormal	☐	Dislocation	☐	Proximal ulna fracture ☐
					Proximal radial fracture ☐
					Other fractures ☐
Image 6	Normal	☐	Abnormal :	☐	
			Effusion	☐	Supra condylar fracture ☐
	Possibly abnormal	☐	Dislocation	☐	Proximal ulna fracture ☐
					Proximal radial fracture ☐
					Other fractures ☐
Image 7	Normal	☐	Abnormal :	☐	
			Effusion	☐	Supra condylar fracture ☐
	Possibly abnormal	☐	Dislocation	☐	Proximal ulna fracture ☐
					Proximal radial fracture ☐
					Other fractures ☐
Image 8	Normal	☐	Abnormal :	☐	
			Effusion	☐	Supra condylar fracture ☐
	Possibly abnormal	☐	Dislocation	☐	Proximal ulna fracture ☐
					Proximal radial fracture ☐
					Other fractures ☐
Image 9	Normal	☐	Abnormal :	☐	
			Effusion	☐	Supra condylar fracture ☐
	Possibly abnormal	☐	Dislocation	☐	Proximal ulna fracture ☐
					Proximal radial fracture ☐
					Other fractures ☐
Image 10	Normal	☐	Abnormal :	☐	
			Effusion	☐	Supra condylar fracture ☐
	Possibly abnormal	☐	Dislocation	☐	Proximal ulna fracture ☐
					Proximal radial fracture ☐
					Other fractures ☐

Image 11	Normal	☐	Abnormal :	☐	
			Effusion	☐	Supra condylar fracture ☐
	Possibly abnormal	☐	Dislocation	☐	Proximal ulna fracture ☐
					Proximal radial fracture ☐
					Other fractures ☐
Image 12	Normal	☐	Abnormal :	☐	
			Effusion	☐	Supra condylar fracture ☐
	Possibly abnormal	☐	Dislocation	☐	Proximal ulna fracture ☐
					Proximal radial fracture ☐
					Other fractures ☐
Image 13	Normal	☐	Abnormal :	☐	
			Effusion	☐	Supra condylar fracture ☐
	Possibly abnormal	☐	Dislocation	☐	Proximal ulna fracture ☐
					Proximal radial fracture ☐
					Other fractures ☐
Image 14	Normal	☐	Abnormal :	☐	
			Effusion	☐	Supra condylar fracture ☐
	Possibly abnormal	☐	Dislocation	☐	Proximal ulna fracture ☐
					Proximal radial fracture ☐
					Other fractures ☐
Image 15	Normal	☐	Abnormal :	☐	
			Effusion	☐	Supra condylar fracture ☐
	Possibly abnormal	☐	Dislocation	☐	Proximal ulna fracture ☐
					Proximal radial fracture ☐
					Other fractures ☐
Image 16	Normal	☐	Abnormal :	☐	
			Effusion	☐	Supra condylar fracture ☐
	Possibly abnormal	☐	Dislocation	☐	Proximal ulna fracture ☐
					Proximal radial fracture ☐
					Other fractures ☐
Image 17	Normal	☐	Abnormal :	☐	
			Effusion	☐	Supra condylar fracture ☐
	Possibly abnormal	☐	Dislocation	☐	Proximal ulna fracture ☐
					Proximal radial fracture ☐
					Other fractures ☐
Image 18	Normal	☐	Abnormal :	☐	
			Effusion	☐	Supra condylar fracture ☐
	Possibly abnormal	☐	Dislocation	☐	Proximal ulna fracture ☐
					Proximal radial fracture ☐
					Other fractures ☐
Image 19	Normal	☐	Abnormal :	☐	
			Effusion	☐	Supra condylar fracture ☐
	Possibly abnormal	☐	Dislocation	☐	Proximal ulna fracture ☐
					Proximal radial fracture ☐
					Other fractures ☐
Image 20	Normal	☐	Abnormal :	☐	
			Effusion	☐	Supra condylar fracture ☐
	Possibly abnormal	☐	Dislocation	☐	Proximal ulna fracture ☐
					Proximal radial fracture ☐
					Other fractures ☐

Appendix D: Turn it in report

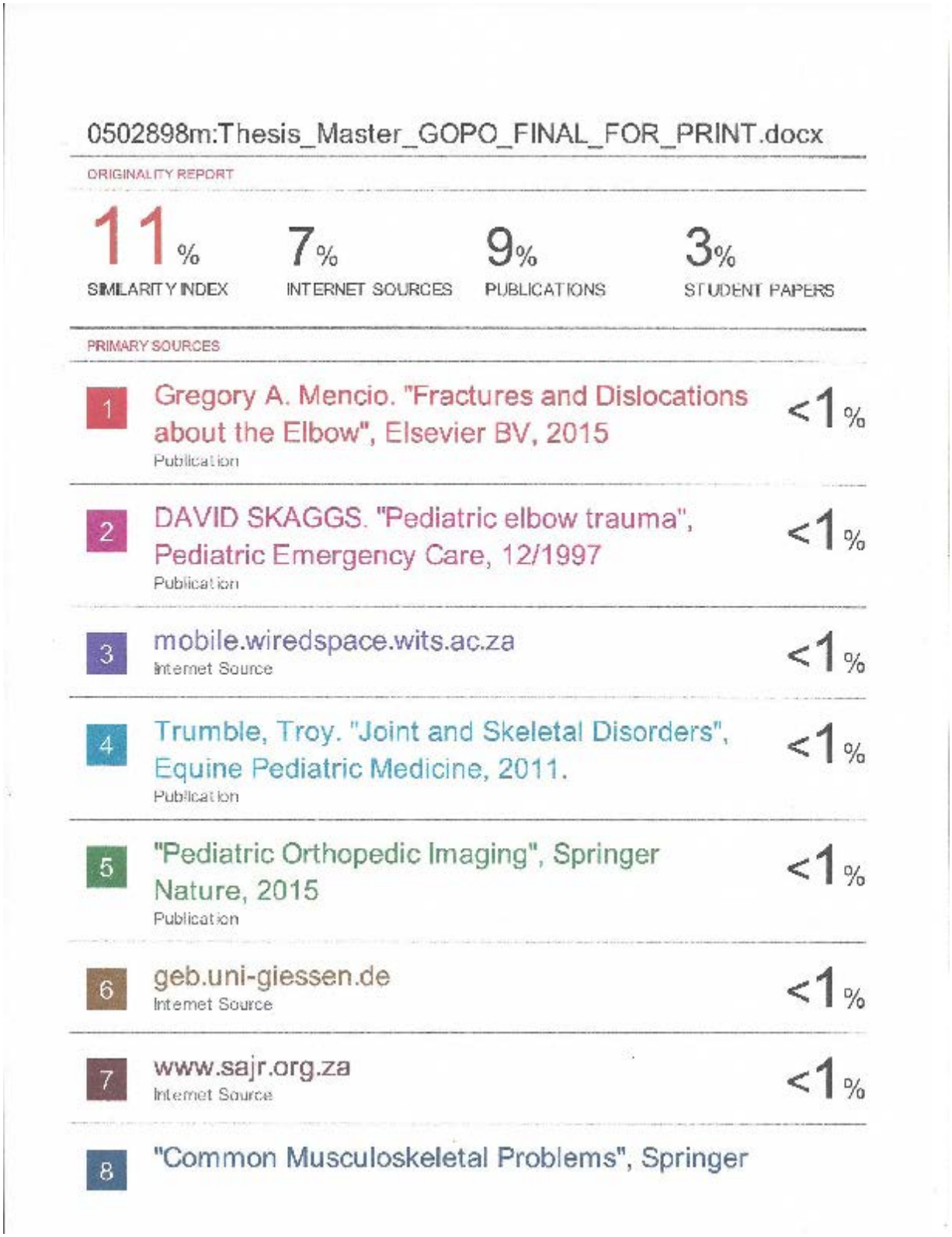

0502898m:Thesis_Master_GOPO_FINAL_FOR_PRINT.docx

ORIGINALITY REPORT

11%	7%	9%	3%
SIMILARITY INDEX	INTERNET SOURCES	PUBLICATIONS	STUDENT PAPERS

PRIMARY SOURCES

1	Gregory A. Mencio. "Fractures and Dislocations about the Elbow", Elsevier BV, 2015 Publication	<1%
2	DAVID SKAGGS. "Pediatric elbow trauma", Pediatric Emergency Care, 12/1997 Publication	<1%
3	mobile.wiredspace.wits.ac.za Internet Source	<1%
4	Trumble, Troy. "Joint and Skeletal Disorders", Equine Pediatric Medicine, 2011. Publication	<1%
5	"Pediatric Orthopedic Imaging", Springer Nature, 2015 Publication	<1%
6	geb.uni-giessen.de Internet Source	<1%
7	www.sajr.org.za Internet Source	<1%
8	"Common Musculoskeletal Problems", Springer	

Appendix E: Note on referencing style

Please note that the referencing in this thesis is a modification of the Vancouver Referencing style, done according to the Faculty of Health Sciences Style Guide as set out by the Wits Health Sciences Library.

The information on this WHSL Vancouver Citation Style Guide for Theses, Dissertations and Research Reports is available from http://libguides.wits.ac.za/whsl-vancouver updated on 30 January 2017.