

https://dspace.org/

Evaluating the Foveal Avascular Zone using Optical Coherence Tomography Angiography in patients with Diabetes: A Cross sectional study

Hussain, Taimeia

2024

University of the Witwatersrand, Johannesburg

https://hdl.handle.net/10539/46710

Hussain, Taimeia . (2024). Evaluating the Foveal Avascular Zone using Optical Coherence Tomography Angiography in patients with Diabetes: A Cross sectional study [Master`s dissertation, University of the Witwatersrand, Johannesburg]. WIReDSpace. https://hdl.handle.net/10539/46710

Downloaded from a DSpace repository. https://dspace.org/

Evaluating the Foveal Avascular Zone using Optical Coherence Tomography Angiography in patients with Diabetes: A Cross sectional study

Dr Taimeia Hussain
Department of Ophthalmology
University of the Witwatersrand
Student Number 0700875V

19 October 2024

Contents Page

Candidate Declaration	3
Acknowledgements	3
Introduction	4
Methods	6
Results	8
Discussion	9
Limitations	12
Conclusion	13
References	13
Appendix A: Ethics Clearance Certificate	16
Appendix B: Research Protocol	17

Candidate Declaration



PLAGIARISM DECLARATION TO BE SIGNED BY ALL HIGHER DEGREE STUDENTS

SENATE PLAGIARISM POLICY: APPENDIX ONE

I Taimeia Hussain (Student number: 0700875V) am a student registered for the degree of Master of Medicine in Ophthalmology in the academic year 2024.

I hereby declare the following:

- I am aware that plagiarism (the use of someone else's work without their permission and/or without acknowledging the original source) is wrong.
- I confirm that the work submitted for assessment for the above degree is my own unaided work except where I have explicitly indicated otherwise.
- I have followed the required conventions in referencing the thoughts and ideas of others.
- I understand that the University of the Witwatersrand may take disciplinary action against me if there is a belief that this is not my own unaided work or that I have failed to acknowledge the source of the ideas or words in my writing.
- I have included as an appendix a report from 'Turnitin' (or other approved plagiarism detection) software indicating the level of plagiarism in my research document.

Signature:  Date: 19/10/2024

Acknowledgements

Dr Ismail Dindar for the initial grading of fundus photos for study patients.
Dr Petra Gaylard for assistance with the data analysis.

Introduction

Diabetic Retinopathy (DR) is a microvascular complication of Diabetes Mellitus (DM) that affects the retina. It is the leading cause of blindness among the working-age population in developed countries.[1-6] The International Diabetes Federation predicts that DM will affect 700 million people worldwide by 2045.[7] In South Africa, DM has a similar prevalence as the global average (around 8%), and studies have found that DR affects between 26-39% of diabetics in the country.[8-9] The high prevalence of DR in South Africa presents a significant burden on the healthcare system and the workforce.[8]

Diabetes mellitus (DM) affects the microcirculation of the retina, which consists of two distinct layers: the superficial and deep plexuses. The superficial plexus is located in the innermost nerve fibre layer of the retina, while the deep plexus is found in the inner nuclear layer. In addition, the choriocapillaris provides a third blood supply to the retina.[3] The foveal region, which lacks blood vessels, is known as the foveal avascular zone (FAZ). DM causes visual impairment through three primary mechanisms: macular oedema, macular ischaemia (DMI), and complications of retinal neovascularization.[2-4] DMI can cause significant visual impairment including central visual loss and difficulty reading due to reduced blood flow to the macula but it may not be readily apparent during clinical examination.[10,11] It is characterized by the enlargement of the FAZ, with irregularities of its margin.[2-6]

DR is typically classified according to the modified Airlie House Classification of the Early Treatment of Diabetic Retinopathy Study (ETDRS) (Table 1).[12] Ophthalmoscopy or colour fundus photography is usually employed to perform the staging.[13] The gold standard for visualizing the retinal microcirculation is fluorescein angiography (FA) which involves dye injection intravenously.[6] This technique has good resolution and can highlight structural abnormalities such as filling defects of the capillaries and areas of leakage.[4] However, FA has several limitations, such as invasiveness, being time consuming, potential complications ranging from nausea to fatal anaphylaxis, and the inability to differentiate the retinal circulation into superficial and deep plexuses. In addition, FA may not accurately assess the FAZ in cases of macular oedema where dye leakage can obscure the borders of the FAZ.[2,6]

Table 1: The ETDRS Classification of Diabetic Retinopathy[12]

Grade	Features
No DR[1]	
Non-Proliferative DR	
Very Mild NPDR[2]	Microaneurysms only
Mild NPDR	Microaneurysms, retinal haemorhages, hard exudates, cotton wool spots. No intra-retinal microvascular anomalies or significant beading
Moderate NPDR	Severe retinal haemorrhages. Significant venous beading. Cotton wool spots
Severe NPDR	One of the following: Severe hemorrhages in all quadrants. Significant venous beading in 2 quadrants. Intra-retinal microvascular anomalies
Very Severe NPDR	Two or more criteria for severe NPDR
Proliferative DR	
Mild-Moderate PDR[3]	New vessel formation at disc (NVD) or new vessel formation elsewhere (NVE)
High risk PDR	Any NVD greater than a third of the disc area. NVD with vitreous haemorrhage. NVE greater than half the disc area.
Advanced Diabetic Eye Disease	Tractional retinal detachment. Significant persistent vitreous haemorrhages. Neovascular glaucoma.

1 Diabetic Retinopathy, 2 Non-proliferative diabetic retinopathy, 3 Proliferative retinopathy

Optical Coherence Tomography Angiography (OCTA) is a novel technology that eliminates the need for invasive dye injection, providing an advantage over FA.[2] It is a non-invasive three-dimensional imaging technique based on Optical Coherence Tomography that enables high-resolution imaging of the retinal vasculature by detecting the movement of the red blood cells in the capillary network.[14] OCTA can detect areas of capillary dropout and non-perfusion with higher resolution than FA, and it also allows for the separation of the image into the superficial, deep, and choroidal vasculature.[1,3-5]

Prior studies investigating DR have found that microvascular changes are more readily detected by OCTA at all stages of retinopathy, sometimes before they are clinically visible, as well as in patients that are pre-diabetic.[15,16] Several have defined quantitative metrics using OCTA such as the foveal avascular zone and perifoveal vessel density and shown that these are associated with the severity of the DR. Multiple studies have found that the FAZ is enlarged in patients with DM compared with normal controls with some studies going further and detecting early FAZ

enlargement in the deep capillary layers but not yet in the superficial layers. [4,5,17,18] This suggests that these metrics may be used as biomarkers in patients without clinical detectable DR. Furthermore, since enlargement of the FAZ is a feature of sight-threatening diabetic macular ischaemia, it is important to detect early.

The aim of this study is to evaluate the FAZ using OCTA in diabetic patients with various stages of DR compared to healthy controls. We also examined whether OCTA metrics are related to HbA1C as well as urea and creatinine levels in diabetics.

Methods

The study is a cross-sectional study of diabetic patients compared to normal controls who presented to the Ophthalmology Clinic at Lenasia South Community Healthcare Clinic (LSCHC) during the study period of February 2020 to February 2023. Ethical clearance was obtained from the Human Research Ethics Committee, University of the Witwatersrand (M180814).

Inclusion criteria were (i) Age > 18 years, (ii) Patients with Type I or Type II Diabetes, (iii) clear view of the fundus. The inclusion criteria for the control group were (i) Age > 18 years (ii) Fundus clearly visible, iii) Random blood glucose < 8 mmol/l

The exclusion criteria for both groups are (i) Presence of media opacities that will prevent adequate fundus visualisation/photography, (ii) History of glaucoma, (iii) history of intravitreal injections or laser to the eye, (iv) retinal diseases other than DR, (v) history of vitreo-retinal surgery, (vi) poor quality or un-gradable OCT/OCTA images, or colour fundus images , vii) Patients unable to provide informed consent e.g. due to mental disability.

Estimation of the sample size was based on the comparison of mean FAZ area between the four study groups. The calculation was based on data from Nesper et al using the means of 0.269mm^2 , 0.309 mm^2 , 0.356 mm^2 and 0.493 mm^2 for the controls, diabetic patients with no DR, patients with non-proliferative DR and severe DR.[1] Using the largest SD of the four groups of 0.24, an effect size of 0.35 was calculated. Assuming balanced groups, the detection of such an effect size with 80% power at the 5% significance level requires a sample size of 96 (with 24 per group).

Sample size calculations were carried out in G*Power.[19] Control patients were selected once the study group had been finalised and were of the same age range as the study group with a same ratio of male and female participants.

Consecutive diabetic patients who fulfilled the inclusion criteria were invited to participate in the study on the day of their visit. A comprehensive ophthalmological examination was performed, and relevant patient data was collected using a data collection sheet that included age, co-morbidities, duration of diabetes, smoking history, and previous ocular surgery. The right eye of each participant was enrolled, and if it was not feasible, the left eye was used. Uncorrected distance visual acuity (VA) and pinhole VA were measured in decimal notation. The examination included slit lamp biomicroscopy, dilated fundoscopy, and color fundus photography using a handheld fundus camera. Blood samples were collected to determine glycated hemoglobin (HBA1C) and renal function (urea and creatinine), which are predictors of clinical outcomes and the course of diabetes. The patient's blood pressure was also checked. Non-diabetic control patients underwent a finger prick blood glucose test and a blood pressure measurement using a standard adult blood pressure cuff. All participants underwent OCT and OCTA imaging using the Revo NX device (Optopol, Norway). OCTA images were captured over a 3 x 3 mm area centered around the macula, which is known to have the best resolution in numerous studies. Built-in software was used to separate the images into superficial and deep layers.

The fundus photographs were analysed by a retinal specialist to grade the severity of DR according to the modified Airlie House classification. The OCTA images were analyzed using the built-in software to define the avascular zone. The software provided quantitative measurements of the foveal avascular zone (FAZ) area and perimeter.

Statistical analysis was conducted using STATISTICA v14.0 (TIBCO Software Inc). A significance level of 5% was applied. Continuous variables were summarized using descriptive statistics such as means, medians, and standard deviations, while categorical variables were summarized using frequency distributions and percentages. The one-way Analysis of Variance (ANOVA) was employed to compare continuous variables between study groups, while the chi-squared test was used for categorical variables.

Results

During the study period, 79 eyes of diabetic patients who met the eligibility criteria were enrolled, along with 16 control patients. Twenty-nine patients were excluded from the study due to various reasons, such as diabetic macular edema (16), poor imaging quality (9), previous treatment for proliferative diabetic retinopathy (2), and vitreomacular traction (2).

The median age of the study group was 61 years (range 33-89), with 55 females (69.6%) and 24 males (30.4%). This group was categorized into those without DR (n=50, 63.3%), mild DR (n=20, 25.3%), and moderate to severe DR (n=9, 11.4%). The control group (n=16) had a median age of 58 years (range 34-73), with 10 females (62.5%) and 6 males (37.5%).

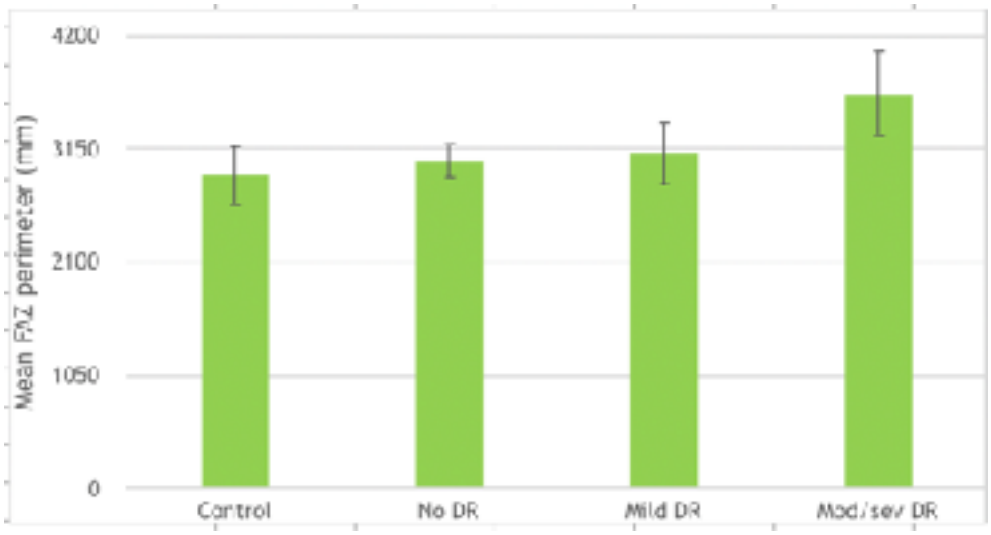

Figure 1: Decimal Visual Acuity of participants in each group

Visual acuity was significantly lower in patients with DM compared to controls, with a worsening trend observed with increasing severity of DR (Figure 1).

The OCTA images were separated into SCP and DCP however due to poor resolution of the DCP with the Revo Nx resulting in inability to delineate an avascular zone, the SCP measurements exclusively were used for measurement of the FAZ area and perimeter. The overall test for differences in mean foveal avascular zone (FAZ) area in the SCP between the groups was statistically significant (p=0.021), but pairwise differences between each of the groups were not significant in the post hoc tests. This could be attributed to the unbalanced groups. Measurements of FAZ perimeter showed overall significant differences between all groups (p=0.015) and

specifically between the control group and the moderate/severe DR group (p=0.032).

There was no significant relationship found between HbA1c levels and FAZ area or perimeter (p=0.21 and p=0.099), and no significant correlation was observed between urea and creatinine levels and FAZ area (p=0.37 and p=0.39) or perimeter (p=0.92 and p=0.16).

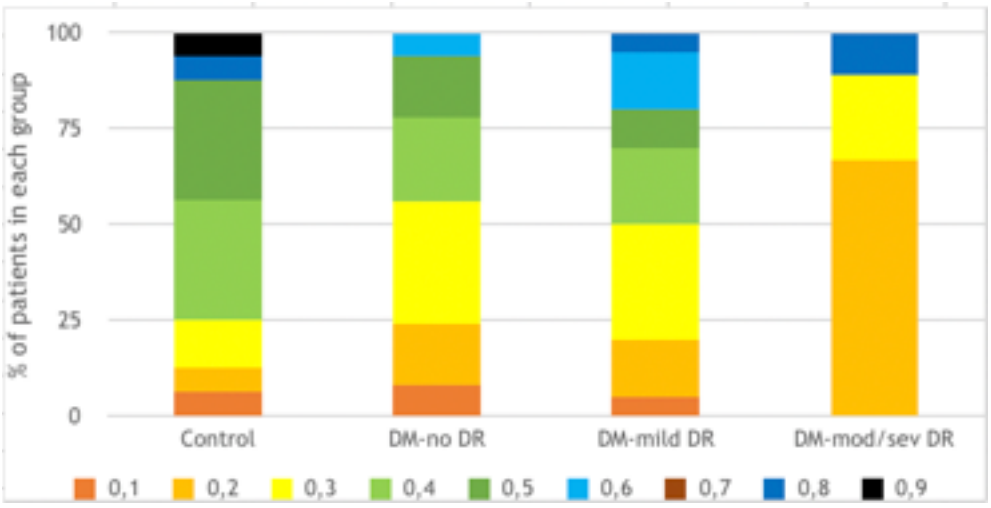

Figure 2: Mean FAZ perimeter comparison between groups (*error bars denote 95% confidence interval for mean***)**

Discussion

Diabetic macular ischaemia represents a significant global health concern, emphasizing the need for annual screening and prompt intervention to prevent associated morbidity. The management of diabetic retinopathy focuses on glycemic control and subsequent targeted treatments for macular oedema and proliferative disease. Given the significant morbidity associated with this condition, it is crucial to identify early markers of disease progression to facilitate timely interventions and prevent morbidity.[11]

This study investigated the relationship between the enlargement of the foveal avascular zone (FAZ) and different stages of diabetic retinopathy. Study results indicate that this enlargement is present in diabetic patients even without clinically evident diabetic retinopathy and increases as the disease progresses. The FAZ differences between the groups however, were not found to be statistically significant

Table 2: Demographic information and measured data for all participants

Characteristic	Category	Control		No DR[1]		Mild DR		Moderate/ severe DR		p-value (between-group test)
		n	%	n	%	n	%	n	%	
n		**16**		**50**		**20**		**9**		
Age (years)	mean (SD)	57.9 (11.6)		60.6 (10.0)		61.4 (13.7)		59.1 (9.6)		0.78
Sex	Male	6	38	18	37	3	15	2	22	0.28
	Female	10	63	31	63	17	85	7	78	
Comorbidities	HPT[2]	9	56	41	82	15	75	9	100	0.058
	Other	3	19	13	26	5	25	2	22	0.95
Other comorbidities	*Cholesterol*			*4*				*1*		
	Renal			*1*		*1*				
	RVD [3]			*2*						
	Asthma			*1*		*1*				
	CVA[4]			*1*						
	Arthritis			*1*						
	Not specified	*3*		*2*		*3*		*1*		
Smoker	Yes	1	6	4	8	1	5	1	11	0.94
HbA1c	mean (SD)			8.4 (2.2)		8.1 (1.5)		10.1 (1.3)		0.089
Urea	Normal			42	84	16	94	9	100	0.46
	Abnormal			8	16	1	6			
Creatinine	Normal			32	65	12	71	6	67	0.98
	Abnormal			17	35	5	29	3	33	
FAZ[5] (mm^2)	mean (SD)	386 (122)		398 (148)		435 (165)		554 (61)		0.021
FAZ Perimeter (mm)	mean (SD)	2903 (531)		3035 (571)		3110 (628)		3658 (521)		0.015

1 Diabetic retinopathy, 2 Hypertension, 3 Retroviral disease (HIV), 4 Cerebrovascular accident (stroke), 5 Foveal Avascular Zone

during the post hoc analysis. This can be attributed to the unbalanced patient numbers between the groups. Although a large number of patients were screened for inclusion into the study, patients with moderate or severe diabetic retinopathy were often excluded from the study. These patients have a higher risk of significant

cataracts, diabetic macular oedema, glaucoma and proliferative retinopathy (all exclusion criteria), leading to the unbalanced groups. Even though not statistically significant, these findings suggest that the enlargement of the FAZ may serve as an early marker for diabetic macular ischaemia, even in the absence of clinically evident diabetic retinopathy.

This study's finding of a significantly larger FAZ area in patients with moderate to severe DR is consistent with previous studies that reported an enlargement of the FAZ area in diabetic patients. The present study used the same means to estimate the sample size as the study by Nesper et al and the results were consistent with that study as well as several other studies.[1,3,4,15-18,20,21] The most significant enlargements were seen in those groups with moderate and severe retinopathy compared to the control group as well as the no DR and mild DR groups. This study did not find a significant difference between the FAZ area of patients with no DR and the control patients as has been reported by some studies.[15] Similar to what was described by Mastropasqua *et al*, this may be related to the range of variation of the FAZ area in the no-DR group as in normal control patients. [20]

This study focused solely on measuring the FAZ in the SCP and did not include the DCP . Although some research suggests that early enlargement of the FAZ occurs in the DCP before the SCP,[18] other studies indicate that separate measurement of the DCP may not be essential.[5,16,22] Due to limitations in the OCTA machine used in the current study, the FAZ in the DCP layers could not be measured reliably. Nonetheless, our results still revealed differences in the SCP measurement, which could be more practical for real-world applications.

The study observed a significant increase in the perimeter of the foveal avascular zone (FAZ) between the groups, with the most prominent differences observed between the control group and the moderate to severe diabetic retinopathy groups. The statistical significance of these differences was confirmed by post hoc tests, despite the unbalanced group sizes. This finding is also consistent with previous studies, for instance, a study by Dimitrova et al. reported that patients with diabetes had significantly larger FAZ perimeter than normal controls.[22] The perimeter of the FAZ is correlated with its area but may also indicate increasing irregularity or circularity of this zone which has been suggested as another biomarker and an addition-

al metric for evaluating its enlargement.[21,23] These findings reinforce the notion that the enlargement of the FAZ can serve as a valuable clinical marker for the progression of diabetic retinopathy.

Prior investigations have not established a direct correlation between the size of the foveal avascular zone (FAZ) or its perimeter and glycemic control, as measured by HbA1c levels.[24] HbA1c is reflective of more recent glucose control and not indicative of previous levels, while FAZ enlargement is indicative of chronic, long-term changes. Although our study observed a trend towards higher HbA1c levels among individuals in the moderate/severe DR group, this difference was not statistically significant (p=0.089) and did not correspond to larger FAZ measurements, even after controlling for age and sex. These findings suggest that glycemic control, as measured by HbA1c, may not be directly associated with the size of the FAZ in diabetic retinopathy and it is not possible to draw conclusions about the the retinal microcirculation using a current HbA1c level.[24]

Previous studies have revealed a significant correlation between the severity of diabetic retinopathy and impaired kidney function.[16,25] However, there is currently no evidence demonstrating a direct association between kidney dysfunction, as determined by serum urea and creatinine levels, and the size of the foveal avascular zone (FAZ). In this study, we found no significant relationship between serum urea or creatinine levels and the enlargement of the FAZ.

Limitations

This study had several limitations. The sample size was relatively small and study groups unbalanced due to many patients being excluded especially as those with more severe retinopathy were more likely to have exclusion factors. Recruitment for the study was also impacted by the Covid-19 pandemic and closure of clinics for a large portion of the collection period. This resulted in smaller numbers across all groups. Another limitation was the inability of the Revo Nx to provide high resolution images of both the DCP and SCP.

Conclusion

The present study is a cross-sectional study that aimed to investigate the differences in the foveal avascular zone (FAZ) area and perimeter as measured by OCTA in diabetic patients compared to normal controls. The results showed that the mean FAZ area was larger in patients with diabetes compared to controls and increased with increasing severity of retinopathy with the overall test for differences in mean FAZ area between the groups being statistically significant. Measurements of FAZ perimeter also showed overall significant differences between control groups and those with DM. These measurements have the potential to be used as biomarkers of diabetic macular ischaemia, especially in those with no clinically discernible diabetic retinopathy. Blood tests such as HbA1C and renal function, whilst an important part of the monitoring of diabetic patients, are not directly correlated with DMI and an enlarging FAZ.

We recommend further larger scale studies to fully ascertain the differences in the FAZ with worsening retinopathy. Studies are further needed to look more closely at the relationship between the enlarging FAZ and on other aspects of VA such as contrast sensitivity and whether such relationships may provide tools for screening.

References

1. Nesper PL, Roberts PK, Onishi AC, Chai H, Liu L, Jampol LM, Fawzi AA. Quantifying microvascular abnormalities with increasing severity of diabetic retinopathy using optical coherence tomography angiography. *Invest Ophthalmol Vis Sci*. 2017;58(6). doi: 10.1167/IOVS.17-21787. PMID: 28623939.

2. Bandello F, Corbelli E, Carnevali A, Pierro L, Querques G. Optical coherence tomography angiography of diabetic retinopathy. *Developments in Ophthalmology*. 2016;56:107â€“112. doi: 10.1159/000442801.

3. Mastropasqua R, Toto L, Mastropasqua A, Aloia R, de Nicola C, Mattei PA, di Marzio G, di Nicola M, di Antonio L. Foveal avascular zone area and parafoveal vessel density measurements in different stages of diabetic retinopathy by optical coherence tomography angiography. *Int J Ophthalmol*. 2017;10(10):1545-1551. doi: 10.18240/ijo.2017.10.11. PMID: 29090015; PMCID: PMC5653698.

4. Gozlan J, Ingrand P, Lichtwitz O, Cazet-Supervielle A, Benoudis L, Boissonnot M, Hadjadj S, Leveziel N. Retinal microvascular alterations related to diabetes assessed by optical coherence tomography angiography. *Medicine (Baltimore)*. 2017;96(15) . doi: 10.1097 MD.0000000000006427. PMID: 28403105; PMCID: PMC5409675.

5. Kim K, Kim ES, Yu SY. Optical coherence tomography angiography analysis of foveal microvascular changes and inner retinal layer thinning in patients with diabetes. *Br J Ophthalmol*. 2018;102(9):1226-1231. doi: 10.1136/bjophthalmol-2017-311149. Epub 2018 Feb 2. PMID: 29395021.

6. Garcia JMBDB, Lima TT, Louzada RN, Rassi AT, Isaac DLC, Avila M. Diabetic macular ischemia diagnosis: Comparison between optical coherence tomography angiography and fluorescein angiography. *J Ophthalmol*. 2016;2016:3989310. doi: 10.1155/2016/3989310. Epub 2016 Mar 23. PMID: 27073749; PMCID: PMC4812504.

7. International Diabetes Federation. *IDF Diabetes Atlas, 9th edition*. Brussels, Belgium: International Diabetes Federation; 2019. Available at: https://www.diabetesatlas.org.

8. Webb EM, Rheeder P, Roux P. Screening in primary care for diabetic retinopathy, maculopathy and visual loss in South Africa. *Ophthalmologica*. 2016;235(3):141-149. doi: 10.1159/000443972. Epub 2016 Jun 3. PMID: 27260692.

9. De Jager W, Mayet I. Determining the prevalence of diabetic retinopathy in a high-risk diabetic clinic in Soweto, South Africa, using digital colour fundus photographs for screening. *S Afr J Ophthalmol*. 2022;18(1):10-14. Available at: https://medicalacademic.co.za/issues/2023/SAOphthalmologyJournal/Vol18No1/.

10. Klein R, Klein BE, Moss SE, Davis MD. Dealing with blindness caused by diabetic retinopathy. *BMJ: British Medical Journal*. 1998;316(7134):693-695. doi: 10.1136/bmj.316.7134.693.

11. Sim DA, Keane PA, Zarranz-Ventura J, et al. The effects of macular ischemia on visual acuity in diabetic retinopathy. *Invest Ophthalmol Vis Sci*. 2013;54(3):2353-2360.

12. Salmon J. *Kanski's Clinical Ophthalmology*. 9th ed. Amsterdam: Elsevier; 2019.

13. Scanlon PH, Aldington SJ, Stratton IM. Epidemiological issues in diabetic retinopathy. *Middle East Afr J Ophthalmol*. 2013;20(4):293-300. doi: 10.4103/0974-9233.120007.

14. Or C, Sabrosa AS, Sorour O, Arya M, Waheed N. Use of OCTA, FA, and ultra-widefield imaging in quantifying retinal ischemia: A review. *Asia Pac J Ophthalmol*. 2018;7(1).

15. Cao D, Yang D, Huang Z, Zeng Y, Wang J, Hu Y, et al. Optical coherence tomography angiography discerns preclinical diabetic retinopathy in eyes of patients with type 2 diabetes without clinical diabetic retinopathy. *Acta Diabetol*. 2018;55(5):469â€“477.

16. El Sawy S, Bekhit M, Abdelhamid A, Esmat S, Ashraf H, Naguib M. Assessment of early macular microangiopathy in subjects with prediabetes using optical coherence tomography angiography and fundus photography. *Acta Diabetol*. 2024;61(1):69â€“77.

17. Bhanushali D, Anegondi N, Gadde SGK, Srinivasan P, Chidambara L, Yadav NK, Roy AS. Linking retinal microvasculature features with severity of diabetic retinopathy using optical coherence tomography angiography. *Invest Ophthalmol Vis Sci*. 2016;57(9):519â€“525. doi: 10.1167/iovs.15-18901.

18. Takase N, Nozaki M, Kato A, Ozeki H, Yoshida M, Ogura Y. Enlargement of foveal avascular zone in diabetic eyes evaluated by en face optical coherence tomography angiography. *Retina*. 2015;35(11):2377â€“2383.

19. Faul F, Erdfelder E, Lang AG, Buchner A. G*Power 3: A flexible statistical power analysis program for the social, behavioral, and biomedical sciences. *Behav Res Methods*. 2007;39:175-191.

20. Chua J, Sim R, Tan B, Wong D, Yao X, Liu X, et al. Optical coherence tomography angiography in diabetes and diabetic retinopathy. *J Clin Med*. 2020;9(6):1723. Available from: https://www.ncbi.nlm.nih.gov/pmc/articles/PMC7357089/. PMID: 32503234.

21. Samara WA, Shahlaee A, Adam MK, Khan MA, Chiang A, Maguire JI, Hsu J, Ho AC. Quantification of diabetic macular ischemia using optical coherence tomography angiography and its relationship with visual acuity. *Ophthalmology*. 2017;124(2):235-244. doi: 10.1016/j.ophtha.2016.10.008. Epub 2016 Nov 23. PMID: 27890537.

22. Dimitrova G, Chihara E, Takahashi H, Amano H, Okazaki K. Quantitative retinal optical coherence tomography angiography in patients with diabetes without diabetic retinopathy. *Invest Ophthalmol Vis Sci*. 2017;58(1):190-196. doi: 10.1167/iovs.16-20531.

23. Krawitz BD, Mo S, Geyman LS, Agemy SA, Scripsema NK, Garcia PM, Chui TYP, Rosen RB. Acircularity index and axis ratio of the foveal avascular zone in diabetic eyes and healthy controls measured by optical coherence tomography angiography. *Vision Res*. 2017;139:177-186. doi: 10.1016/j.visres.2016.09.019.

24. Storch MW, Zinser G, Lauermann P, Khattab MH, Nguyen-HÃ¶hl A, Raddatz D, Gollisch K, Callizo J, Hoerauf H, Feltgen N. Influence of the size of the foveal avascular zone on functional and morphological parameters in patients with early-stage diabetic retinopathy. *Clin Ophthalmol*. 2022;16:1207â€“1213. doi: 10.2147/OPTH.S358467.

25. Wong TY, Coresh J, Klein R, Muntner P, Couper DJ, Sharrett AR, et al. Retinal microvascular abnormalities and renal dysfunction: the Atherosclerosis Risk in Communities Study. *J Am Soc Nephrol*. 2004;15(9):2469-76. doi: 10.1097/01.ASN.0000136133.28194.E4.

Appendix A: Ethics Clearance Certificate

UNIVERSITY OF THE WITWATERSRAND, JOHANNESBURG

R14/49 Dr Taimeia Hussain

HUMAN RESEARCH ETHICS COMMITTEE (MEDICAL)

CLEARANCE CERTIFICATE NO. M180814

NAME: (Principal Investigator)	Dr Taimeia Hussain
DEPARTMENT:	Opthalmology Lenasia South Community Healthcare Clinic
PROJECT TITLE:	Evaluationg the Foveal Avascular Zone and Parafoveal Vessel Density using optical Coherence Tomography Angiography in patients with Diabetes: A Case Control Study
DATE CONSIDERED:	31/08/2018
DECISION:	Approved Unconditionally
CONDITIONS:	
SUPERVISOR:	Dr Naseer Ally
APPROVED BY:	Doctor CB Penny, Chairperson, HREC (Medical)
DATE OF APPROVAL:	07/12/2018

This clearance certificate is valid for 5 years from date of approval. Extension may be applied for.

DECLARATION OF INVESTIGATORS

To be completed in duplicate and **ONE COPY** returned to the Research Office Secretary on the Third Floor, Faculty of Health Sciences, Phillip Tobias Building, 29 Princess of Wales Terrace, Parktown, 2193, University of the Witwatersrand. I/we fully understand the conditions under which I am/we are authorized to carry out the above-mentioned research and I/we undertake to ensure compliance with these conditions. Should any departure be contemplated, from the research protocol as approved, I/we undertake to resubmit the application to the Committee. **I agree to submit a yearly progress report**. The date for annual re-certification will be one year after the date of convened meeting where the study was initially reviewed. In this case, the study was initially reviewed in **September** and will therefore be due in the month of **September** each year. Unreported changes to the application may invalidate the clearance given by the HREC (Medical).

Principal Investigator Signature

Date

PLEASE QUOTE THE PROTOCOL NUMBER IN ALL ENQUIRIES

Appendix B: Research Protocol

Research Protocol Summary

Researcher Name	Dr Taimeia Hussain
Supervisors' Names	Dr Saadiah Goolam Dr Naseer Ally
Co-Investigators' Names	Dr Naseer Ally Dr Ismail Dindar
Research Department	Lenasia South Community Hospital. Ophthalmology Outreach Program attached to St John's Eye Hospital, affiliated with Department of Ophthalmology at the University of the Witwatersrand
Title of Proposed Research	Evaluating the Foveal Avascular Zone and Parafoveal Vessel Density using Optical Coherence Tomography Angiography in patients with Diabetes: A Case-control study

Glossary of Terms

Avascular	Containing no blood vessels
Choriocapillaris	The blood supply of the choroid, a layer of the eye beneath the retina. This circulation provides nourishment to the macula which is an avascular zone
Fluorescein Angiogram	An imaging technique wherein a fluorescent dye is injected intravenously and the retinal vasculature is photographed as the dye passes through it. It highlights vascular abnormalities, areas of ischaemia, oedema and leakage
Fovea	The depression in the centre of the macula. This area provides the clearest color vision
Macula	The macula is located at the center of the back of the eye and has the highest concentration of cone cells that are responsible for color vision.
Macular Oedema	Swelling at the macula which is associated with a decrease in vision
Microangiopathy	A pathological process affecting the smallest vessels in the body (capillaries)
Neovascularisation	New vessel formation
Optical Coherence Tomography	OCT technology uses near-infrared light waves and scatter to collect information about the structures in the eye to a sub-micrometer resolution.
Vitreous haemorrhage	Bleeding into the vitreous, a gel-like structure directly adjacent to the retina making up 80% of the ocular volume.
Non-perfusion	Lack of blood flow

Introduction

Diabetic Retinopathy (DR), one of the consequences of the microangiopathy caused by Diabetes Mellitus (DM), is known to be the leading cause of blindness in the income producing population in the developed world.[1-9] According to the World Health Organisation, the incidence of DM may reach 360 million people worldwide by 2030.[10] In

South Africa, DM affects +- 8% of the population (similar to the world-wide prevalence). A 2016 study found that the prevalence of DR in diabetics in South Africa was 24.9%. [11] This represents a large burden on our healthcare system as well as the work force. DR is a preventable condition when measures such as good glucose control and management of coexisting conditions is instituted.[11]

Literature Review

Diabetes affects the microcirculatory system of the retina. The retinal circulation is divided into superficial and deep capillary plexuses. The superficial plexus lies in the innermost nerve fibre layer of the retina and the deep plexus is found in the inner nuclear area of the retina. A third blood supply is derived from the choriocapillaris. [4] The fovea is devoid of blood vessels and this area is defined as the foveal avascular zone (FAZ) [Figure 1].[12] The parafoveal area is the area immediately surrounding the fovea. [Figure 2]

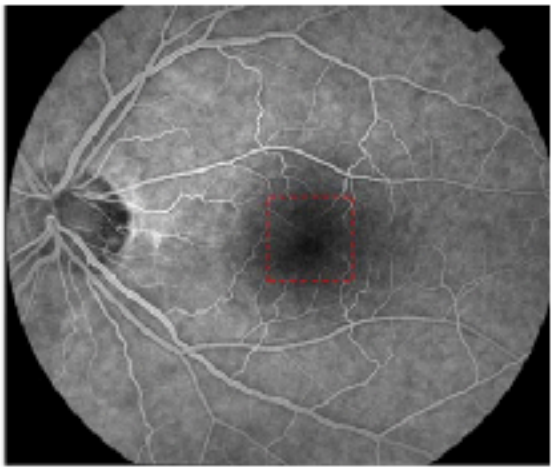

Figure 1: The Foveal Avascular Zone (red dashed line) seen on a Fluorescein Angiogram of a normal retina. [12]

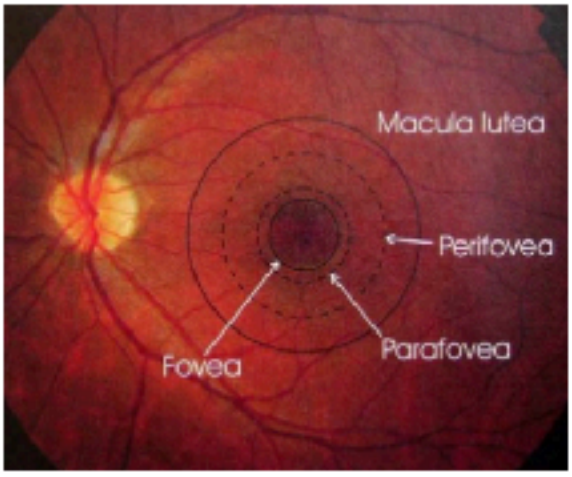

Figure 2: Fundus photograph showing the macula, fovea and parafoveal zones in an eye with no diabetic retinopathy. [13]

There are 3 different mechanisms by which DM is known to cause visual impairment. These are (i) Macular oedema, (ii) Complications of retinal neovascularisation (Retinal detachments, vitreous haemorrhage and neovascular glaucoma), and (iii) Diabetic macular ischaemia (DMI). Enlargement of the foveal avascular zone with irregularities of its margin as well as perifoveal capillary dropout are the two main characteristics of DMI. [5]

DR is staged according to the Early Treatment Diabetic Retinopathy Study (ETDRS- The modified Airlie House Classification) An abbreviated version is set out below in Table 1.

Table 1: The ETDRS Classification of Diabetic Retinopathy[14]

Grade	Features
No DR	
Non-Proliferative DR	
Very Mild NPDR	Microaneurysms only
Mild NPDR	Microaneurysms, retinal haemorhages, hard exudates, cotton wool spots. No intra-retinal microvascular anomalies or significant beading
Moderate NPDR	Severe retinal haemorrhages (About 20). Significant venous beading. Cotton wool spots
Severe NPDR	One of the following: Severe hemorrhages in all quadrants. Significant venous beading in 2 quadrants. Intra-retinal microvascular anomalies
Very Severe NPDR	Two or more criteria for severe NPDR
Proliferative DR	
Mild-Moderate PDR	New vessel formation at disc (NVD) or new vessel formation elsewhere (NVE)
High risk PDR	Any NVD greater than 1/3 of the disc area. NVD with vitreous haemorrhage. NVE greater than 1/2 disc area.
Advanced Diabetic Eye Disease	Tractional retinal detachment. Significant persistent vitreous haemorrhages. Neovascular glaucoma.

Currently, ophthalmoscopy and colour fundus photography are the standard for the staging of DR.[15] Fluorescein angiography (FA), involving the injection of fluorescein dye, has been the gold standard for imaging the retinal vascular network and detecting the extent of retinal ischaemia in many conditions. [4,15,17] It has good resolution and provides information about structural abnormalities, filling defects of capillaries as well as problems such as leakage from the vessels.[4] This technique has several downfalls. It is an invasive, time consuming technique with potential complications ranging from nausea to potentially fatal anaphylaxis. [2,3,8] Additionally, FA is not able to provide information about the superficial, deep and choroidal plexuses separately since it provides a two dimensional image. [2-4,5-9,16-19] FA also may not assess the FAZ accurately. For example, in patients with macular oedema, the borders of the FAZ are obscured by the leakage of the fluorescein dye [3]

Optical Coherence Tomography Angiography (OCTA) is a three-dimensional technique based on Optical Coherence Tomography that allows for high-resolution imaging of the vasculature of the retina by following the movement of the red blood cells in the capillary network. [16] OCTA is an emerging technology that can image the retina and its vasculature without the need for invasive dye injection, providing an advantage over the more invasive FA.[2] OCTA obtains multiple A and B scans concurrently over time and collates them to allow for visualization of retinal flow and retinal structure simultaneously. [2] It is capable of

delineating areas of capillary dropout and non-perfusion with higher resolution than FA. It also allows for the separation of the image into the superficial, deep and choroidal vasculature. [1,4-6]

Prior studies using OCTA in the investigation of DR have found that microvascular changes are more readily detected at all stages of retinopathy, with some changes such as micro aneurysms being detected before they are clinically visible.[15] Multiple studies have found that the foveal avascular zone is enlarged in patients with DM compared with normal age-matched controls.[1,5,7,10] A study by Takase *et al* further found that when separating the OCTA images into deep and superficial layers, FAZ enlargement could be detected in the deep layers but not the superficial layers. In this case, had the images not been separated, these enlargements would have been missed. [20,21] Several other studies have also highlighted the importance of examining the deep layer in DR. [1,3,7,22]

Some studies have found that the parafoveal vessel density decreases in the early stages of disease and may be present before enlargement of the FAZ occurs. This decrease may even be present in patients with no clinical DR, which would be very useful in the early screening and management of these patients.[4,10,15] The reduction in the parafoveal vessel density was shown to affect all layers, but the deep capillary layer was affected earlier in the disease process.[5,15] Enlargement of the FAZ and a decrease in parafoveal vessel density are important to detect early as they are the features of sight-threatening diabetic macular ischaemia.

Problem Statement

Diabetic retinopathy is a preventable cause of blindness worldwide. Fluorescein angiography is the gold standard for imaging and grading of DR (along with fundoscopy and color fundus photography) but it is invasive and time consuming and may not detect early changes. OCTA provides quick, non-invasive images of retinal vasculature that may aid in the detection of microvascular changes, perhaps even before they are clinically detectable and may be an invaluable screening tool. There are no studies in the South African setting that investigate the FAZ and parafoveal vessel density using OCTA in patients with different stages of DR compared to normal subjects.

Research Question

Setting

Lenasia South Community Healthcare Clinic, Ophthalmology Department. This department is an outreach of St John's Eye Hospital at Chris Hani Baragwanath Hospital.

Study Participants

The study will include a sample of diabetic patients with diabetes presenting to the eye clinic at LSCHC during the study period who fulfil the inclusion and exclusion criteria. A group of non-diabetic controls with normal eyes (i.e. no retinal pathology) will be selected from the eye clinic as well.

Study Sample

The study sample size of 160 patients (40 per group) was calculated using a one-way analysis of variance (ANOVA) using **the means of 0.269mm² 0.309 mm² 0.356 mm² 0.493 mm² for the controls, diabetic patients with no DR, patients with NPDR and PDR** respectively. The with-in group variance was set at 0.1 with 80% power to detect a difference at an alpha level of 0.05. The following graph illustrates the sample size required for different within group variances.

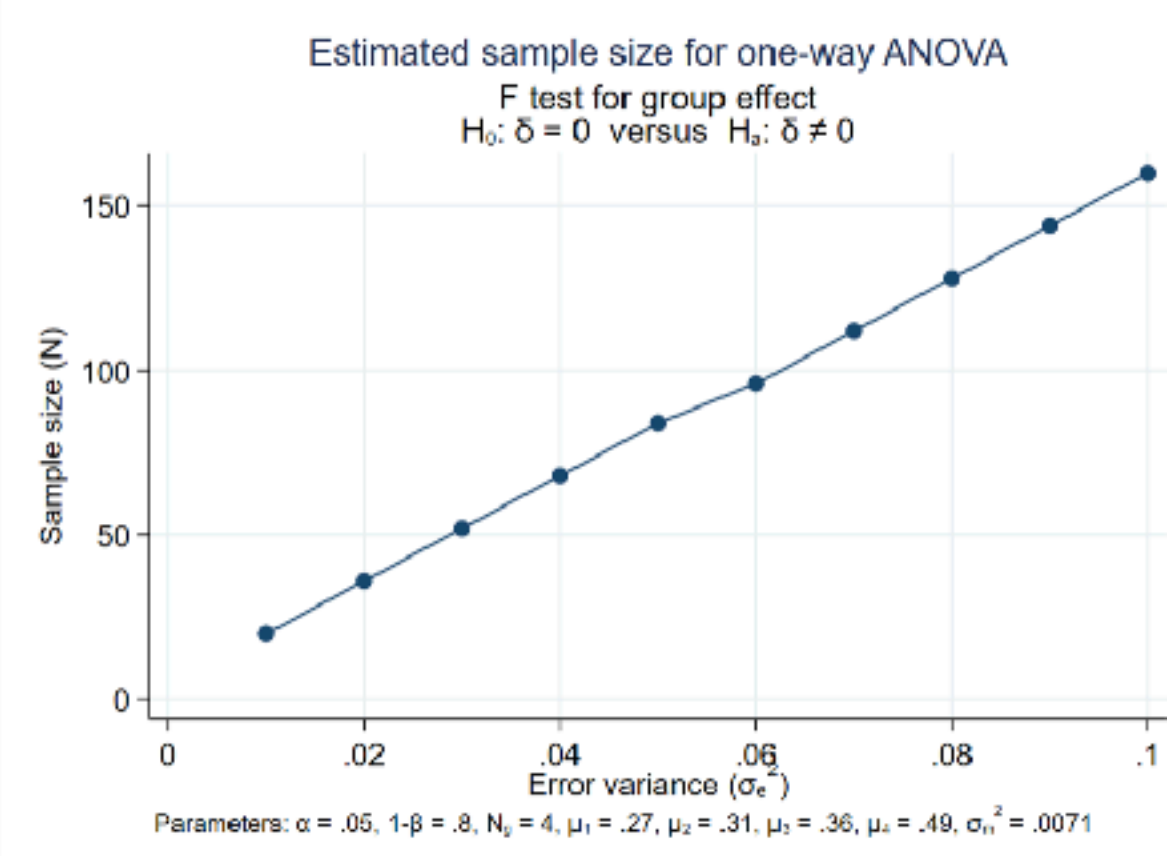

Age and sex matched controls will be selected as well.

Is there a significant difference in the size of the FAZ and parafoveal vessel density between diabetic patients and healthy non-diabetic controls?

Aim

The aim of this study is to evaluate the foveal avascular zone and parafoveal vessel density (PFVD) using OCTA in diabetic patients compared to healthy controls at Lenasia South Clinic

Objectives

Primary

1. To assess if there is a significant difference between the FAZ and PFVD in diabetic patients with no DR, non-proliferative DR and proliferative DR compared to normal non-diabetic controls. We postulate that there will be an increase in size of the FAZ and decrease PFVD as the severity of DR increases.

Secondary

1. To assess if there is an increase in the size of the FAZ as the severity of DR increases.
2. To evaluate if there is a decrease in the parafoveal vessel density as the severity of DR increases.

Exploratory

1. To assess if there is a relationship between glycated haemoglobin (HbA1C) and FAZ & PFVD in diabetic retinopathy.
2. To assess if there is a relationship between the urea & electrolytes and FAZ & PFVD in diabetic retinopathy.

Study Design and Methods

Study Design

The study is a cross-sectional study of diabetic patients compared to normal controls who present to the Ophthalmology Clinic at Lenasia South Community Healthcare Clinic (LSCHC) during the study period.

Inclusion and Exclusion Criteria

The inclusion criteria are (i) Age > 18 years, (ii) Patients with Type I or Type II Diabetes, (iii) Fundus and macula are clearly visible. One eye will be enrolled. The inclusion criteria for the control group is (i) Age > 18 years (ii) Fundus clearly visible, iii) Random blood glucose < 8

The exclusion criteria for both groups are (i) Presence of media opacities that will prevent adequate fundus visualisation/photography, (ii) History of glaucoma, (iii) history of intravitreal injections or laser to the eye, (iv) other retinal diseases, (v) history of vitreo-retinal surgery, (vi) poor quality OCT images, vii) Patients unable to provide informed consent e.g. due to mental disability.

Methods

- Consecutive diabetic patients who meet the above inclusion and exclusion criteria will be identified and invited to participate in the study on the day of the visit.
- A full history will be taken including the patients age, history of other co-morbidities, duration of diabetes, smoking history and previous ocular surgery.
- The uncorrected distance visual acuity as well as pinhole visual acuity will be measured in decimal notation.
- Only one eye per patient will be used for the study. They eye will be selected using a computer generated randomized number sequence. If the randomly selected eye cannot be used for some reason, the fellow eligible eye will be used. The severity of DR will be graded according to the modified Airlie House classification.
- The patient's blood pressure will be measured
- This will be followed by a clinical eye examination including slit lamp biomicroscopy and fundus photography.
- A blood sample will be taken for glycated hemoglobin (HBA1C) and renal function (U & E) (both predictors of clinical outcome and course of disease in diabetes). This is standard of care for diabetic patients.
- Non-diabetic control patients will have a finger prick blood glucose test as well as a blood pressure measurement using a standard adult blood pressure cuff. This is standard of care in patients presenting to primary healthcare clinics.
- Patients' eyes will be dilated for the examination. All details will be recorded onto a patient data sheet (See Appendix A).

- An OCT will be performed to be used as a reference when analyzing the OCTA to identify any artefacts. The OCT device used is the Revo NX (Optopol, Norway).
- OCTA will be performed. The images will be of a 3 x 3 mm area centred around the macula (this was found to have the best resolution in numerous studies). The images are separated by the software into superficial and deep layers and all images are provided. The images will be downloaded for later analysis.
- A similar procedure will be followed for identified control patients, however they will not have any blood samples taken.

Data Analysis

- Data will be stored using the Wits REDCAP software. Statistical analysis will be performed using STATA 15.1 (STATACorp, Texas USA). A p value of <0.05 will be regarded as significant. Descriptive statistics such as the means, medians and standard deviation will be used for continuous variables and frequency distribution and percentages will be used for categorical variables.
- The unpaired t-test or Wilcoxon rank sum test will be used to test whether there is a significant difference between the FAZ and PFVD between diabetics and non-diabetic controls respectively. The one-way Analysis of Variance (ANOVA) test will be used to assess the effect of increasing severity of DR on the FAZ and PFVD. Univariate and multivariate linear regression will be used to assess if there is an effect of HbA1C, U&E, age and sex on the FAZ and PFVD.
- Fundus photos will be analyzed by two observers to stage the patient's DR.
- OCTA images will also be analyzed using custom made MATLAB (MathWorks, Inc., Natick, MA, USA) code. The images will be exported into MATLAB. Image processing techniques will be used to define the FAZ. The Otsus clustering technique will first be used to segment the image to allow the FAZ to be outlined. The area within the border is then calculated by the software.
- To assess parafoveal density, the images of the superficial layer, the deep layer and the full thickness image will be exported into MATLAB code. The parafoveal zone is defined as an annulus centered on the fovea with inner and outer ring diameters of 1 and 3 mm. Vessel density will be calculated using a grayscale OCTA image. The percentage of pixels occupied by blood vessels in the defined region will be calculated using Otsus clustering pixel thresholding and expressed as a percentage of the whole image.

Ethical Issues

- Risks : Patients will experience blurriness of vision and an inability to read after their eyes are dilated. This is the standard of care for all diabetics that present to the clinic for

fundoscopy. The effect is transient and the pupils return to their normal diameter within 4-6 hours. There will be some pain when taking the routine blood samples from the diabetic patients. To minimize this risk, the phlebotomy will be done by a trained doctor (the principal investigator/phlebotomist) and not auxiliary staff. Approximately 5 mls of blood will be taken. There is a risk of minimal bleeding after the venipuncture as well as a small risk of infection at the wound site after the blood is taken. Fundus photography and OCTA can cause the patient minor discomfort as they are asked to look directly into a lens which uses red light to take the picture. This is transient with no permanent long-term sequelae.

- Confidentiality: All patients will be identified solely by a unique study ID code and no identifying data such as names, telephones numbers etc, will be kept with the scans and clinical data. All links between the codes and names of patients will be kept and stored separately. OCT and OCTA images will be identified by Study ID as well. Patients will only be known to the principal investigator. Only de-identified data will be presented to co-investigators.
- Cost to patients: Patients will not incur any costs by participating in the study.
- Ethics: The protocol will be submitted to the University of the Witwatersrand Human Research Ethics Committee for clearance before the study is commenced. Permission will also be obtained from the CEO at LSCHC before commencement of the study.

Resource Requirements

Visual acuity charts using the decimal system are available at the clinic. The fundus camera belongs to the principal investigator and is available to use. The OCTA machine is available at LSCHC.

All stationery will be provided by the principal investigator.

No further funding will be necessary

Study Timeline

Protocol committee	Data collection commences	Data collection complete	Writeup begins	Writeup complete	Submission to journal
July 2019					
	September 2019				
		February 2020			

		March 2020	June2020 July 2020

Supervision

The study will be supervised by Dr Saadiah Goolam at Charlotte Maxeke Johannesburg General Hospital and Dr Naseer Ally at St John Eye Hospital.

Dissemination

The aims are to

- Present an internal report to the Department of Ophthalmology, University of the Witwatersrand.
- Publish the data in a scientific journal
- Present findings at the congress for the Ophthalmic Society for South Africa
- To use as a basis for further studies on the use of OCTA for screening DR

References

1. Nesper PL, Roberts PK, Onishi AC, Chai H, Liu L, Jampol LM, et al. Quantifying Microvascular Abnormalities With Increasing Severity of Diabetic Retinopathy Using Optical Coherence Tomography Angiography. Investigative Ophthalmology & Visual Science. 2017;58(6)
2. Bandello F, Corbelli E, Carnevali A, Pierro L, Querques G. Optical Coherence Tomography Angiography of Diabetic Retinopathy. Developments in Ophthalmology OCT Angiography in Retinal and Macular Diseases. 2016;56:107–12.
3. Gill A, Cole ED, Novais EA, Louzada RN, Carlo TD, Duker JS, et al. Visualization of changes in the foveal avascular zone in both observed and treated diabetic macular edema using optical coherence tomography angiography. International Journal of Retina and Vitreous. 2017;3(1).
4. Mastropasqua R, Lisa T, Mastropasqua A, Aloia R, De Nicola C, Matei PA, et al. Foveal avascular zone area and parafoveal vessel density measurements in different stages of diabetic retinopathy by optical coherence tomography angiography. International Journal of Ophthalmology. 2017;18;10(10).
5. Gozlan J, Ingrand P, Lichtwitz O, Cazet-Supervielle A, Benoudis L, Boissonnot M, et al. Retinal microvascular alterations related to diabetes assessed by optical coherence tomography angiography. Medicine. 2017;96(15).

6. Goudot MM, Sikoray A, Semoun O, Miere A, Jung C, Courbebaisse B, et al. Parafoveal OCT Angiography Features in Diabetic Patients without Clinical Diabetic Retinopathy: A Qualitative and Quantitative Analysis. Journal of Ophthalmology. 2017;2017:1–14.
7. Kim K, Kim ES, Yu S-Y. Optical coherence tomography angiography analysis of foveal microvascular changes and inner retinal layer thinning in patients with diabetes. British Journal of Ophthalmology. 2017;19:1–6.
8. Garcia JM, Lima TT, Louzada RN, Rassi AT, Isaac DLC, Avila M. Diabetic Macular Ischemia Diagnosis: Comparison between Optical Coherence Tomography Angiography and Fluorescein Angiography. Journal of Ophthalmology. 2016;2016:1–6.
9. Krawitz BD, Mo S, Geyman LS, Agemy SA, Scripsema NK, Garcia PM, et al. Acircularity index and axis ratio of the foveal avascular zone in diabetic eyes and healthy controls measured by optical coherence tomography angiography. Vision Research. 2017;139:177–86.
10. Bhanushali D, Anegondi N, Gadde SG, Srinivasan P, Chidambara L, Yadav NK, et al. Linking Retinal Microvasculature Features With Severity of Diabetic Retinopathy Using Optical Coherence Tomography Angiography. Investigative Opthalmology & Visual Science. 2016;57(9).
11. Webb EM, Rheeder P, Roux P. Screening in Primary Care for Diabetic Retinopathy, Maculopathy and Visual Loss in South Africa. Ophthalmologica. 2016;235(3):141–9
12. Kim DY, Fingler J, Zawadzki RJ, Park SS, Morse LS, Schwartz DM, et al. Noninvasive Imaging of the Foveal Avascular Zone with High-Speed, Phase-Variance Optical Coherence Tomography. Investigative Opthalmology & Visual Science. 2012;53(1):85.
13. Jha RKN. Retina Anatomy and Diabetic Retinopathy. LinkedIn SlideShare 2016. https://www.slideshare.net/ophthalmgmcri/retina-1-anatomy-and-diabetic-retinopathy-d-rknjha260516 (accessed July 19, 2018).
14. Bowling, B. (2016). Clinical Ophthalmology: A Systemic Approach. 8th ed. Sydney: Elsevier, p.522.
15. Cao D, Yang D, Huang Z, Zeng Y, Wang J, Hu Y, et al. Optical coherence tomography angiography discerns preclinical diabetic retinopathy in eyes of patients with type 2 diabetes without clinical diabetic retinopathy. Acta Diabetologica. 2018;55(5):469–77.
16. Or C, Sabrosa AS, Sorour O, Arya M, Waheed N. Use of OCTA, FA, and Ultra-Widefield Imaging in Quantifying Retinal Ischemia: A Review. Asia-Pacific Journal of Ophthalmology. 2018;7(1).
17. Shen C, Yan S, Du M, Zhao H, Shao L, Hu Y. Assessment of capillary dropout in the superficial retinal capillary plexus by optical coherence tomography angiography in the early stage of diabetic retinopathy. BMC Ophthalmology. 2018;18(1).

18. Soares M, Neves C, Marques IP, Pires I, Schwartz C, Costa MÂ, et al. Comparison of diabetic retinopathy classification using fluorescein angiography and optical coherence tomography angiography. British Journal of Ophthalmology. 2016;101(1):62–8.
19. Samara WA, Shahlaee A, Adam MK, Khan MA, Chiang A, Maguire JI, et al. Quantification of Diabetic Macular Ischemia Using Optical Coherence Tomography Angiography and Its Relationship with Visual Acuity. Ophthalmology. 2017;124(2):235–44.
20. Moore J, Bagley S, Ireland G, Mcleod D, Boulton ME. Three dimensional analysis of microaneurysms in the human diabetic retina. Journal of Anatomy. 1999;194(1):89–100.23
21. Takase N, Nozaki M, Kato A, Ozeki H, Yoshida M, Ogura Y. Enlargement of Foveal Avascular Zone In Diabetic Eyes Evaluated By En Face Optical Coherence Tomography Angiography. Retina. 2015;35(11):2377–83.
22. Simonett JM, Scarinci F, Picconi F, Giorno P, Geronimo DD, Renzo AD, et al. Early microvascular retinal changes in optical coherence tomography angiography in patients with type 1 diabetes mellitus. Acta Ophthalmologica. 2017;95(8).