

https://dspace.org/

# Progressive nodular histiocytosis: an exceedingly rare variant of the Non-Langerhans cell histiocytoses group of conditions

**Pillay, Lushen**

**2013-09**
http://hdl.handle.net/10539/17740

Downloaded from a DSpace repository. https://dspace.org/

# PROGRESSIVE NODULAR HISTIOCYTOSIS

## AN EXCEEDINGLY RARE VARIANT OF THE NON – LANGERHANS CELL HISTIOCYTOSES GROUP OF CONDITIONS

**DR LUSHEN PILLAY**

A research report submitted to the Faculty of Health Sciences, University of the Witwatersrand, in partial fulfillment of the requirements for the degree of Masters of Medicine in Dermatology by coursework and research report

Johannesburg 2013

DECLARATION

I, Lushen Pillay, declare that this research report is my own work. It is being submitted for the degree of Masters of Medicine in Dermatology at the University of the Witwatersrand, Johannesburg. It has not been submitted before for any other degree at this or any other university.



Dr Lushen Pillay

Date : 22/09/2013

This thesis is dedicated to my family

My wife, Kalaivani, daughters Kemeeka and Kishalia

My parents Sathia and Saroj and my siblings Vanessa and Uneal

For providing me with the support and motivation always.

## ACKNOWLEDGEMENTS

- I would like to thank my supervisor, Professor Deepak Modi for his support, invaluable advice, and continuous motivation in completing this Masters degree
- Professor EJ Schulz for assisting in the management of this condition and her support throughout my studies
- Professor Jenny Kromberg for assisting in the checking and correct completion of this report

## Table of Contents

**Declaration** .....2

**Dedication**.....3

**Acknowledgements** .....4

**Table of contents** .....5-6

**List of Figures** .....7

**List of Tables** .....8

**1. Introduction & Background** 9

1.1 Histiocytoses of dermal dendrocytes 11

1.2 The Juvenile Xanthogranuloma (JXG) Family 13

1.3 Diagnosis Of The Non-LCH 17

1.3.1 Histopathology 17

1.3.2 Clinical Diagnosis 19

1.4 Summary of cases previously describes in the literature 23

1.5 Objectives and Aims 26

1.6 Summary 27

1.7 Conclusion 29

**2. Subjects and Methods** 30

**3. Case report** 34

3.1 History / Background 34

3.2. Blood tests 38

3.3. Radiological investigations 38

3.4. Histology 40

**4. Conclusion** **43**
**5. References** **45**
**6. Appendix** **48**
**– ethics clearance certificate**

## List of Figures


1) Fig 1: Spectrum of disease in the Non – Langershans cell histiocytoses group of conditions .....15

2) Fig 2: Maturation of histiocytes showing progressive spindling of cells.....17

3) Fig 3: Face of patient ..... 35

4) Fig 4: Trunk of patient.....35

5) Fig 5: Limbs of patient .....36

6) Fig 6: Close up of limb lesions .....37

7) Fig 7: Full body PET Scan ..... 39

8) Fig 8: High Resolution CT Chest.....39

9) Fig 9: H & E stain ..... 41

10) Fig 10 : CD-68 stain.....41

11) Fig 10: S-100 stain ..... 42

12) Fig 11: HAM – 56 Histology stain ..... 42

## List of Tables

1) Table 1 : Classification og the non Langerhans cell histiocytoses.....21

2) Table 2 : Differential diagnoses of Progressive nodular histiocytosis....23

3) Table 3 : Diagnostic criteria for Progressive nodular histiocytosis.....28

## 1. Introduction & Background

Progressive nodular histiocytosis (PNH) is an uncommon disorder. It belongs to the non – Langerhans cell histiocytic group. The main pathogenic constitutive element is the dermal dendrocyte. These processes are considered by some to represent a spectrum of a single disease[1-3, 5].

A patient with progressive nodular histiocytosis is described with peculiarities that have not been reported in the English literature thus far[5, 6, 14-18].

Histiocytic disorders are currently identified by their component cells. The non-Langerhans Cell Histiocytoses (non-LCH) are a group of disorders defined by the accumulation of histiocytes that do not meet the phenotypic criteria for the diagnosis of LCH. They consist of a long list of diverse disorders which have been difficult to categorize[5, 6]. A conceptual way to simplify these disorders is based on immunophenotyping and clinical presentation[6,7-12].

The histiocytoses are reactive or malignant conditions in which various tissues, including the skin, are infiltrated by cells of the monocyte macrophage lineage[5].

They are a heterogeneous group of disorders that are unique by their rarity and by the large number of terms that have been used to describe them[6].

In 1985 The Writing Group of the Histiocyte Society[1] reclassified the histiocytoses into three classes:

Class 1: Langerhans cell histiocytosis.

Class 2: Non-Langerhans cell histiocytoses

Class 3: Malignant histiocytoses.

This pragmatic classification has been universally adopted. It still leaves, however, an enormous group of Class 2 histiocytoses that are very diverse.

These conditions have only been anecdotally reported in the literature, but few with completeness with respect to histology and immune- histochemistry[6,8-10].

Histiocytes are a diverse group of cells, having the CD34 bone marrow precursor as their progenitor cell[2] entering a number of ontological pathways to finally become morphologically recognizable cells in the skin and other tissues[1, 2]. One type of histiocyte was first identified in 1986 by Hedington[3,] who termed the cell `a dermal dendrocyte'. Unfortunately, little is known about the kinetics and turnover of the dermal dendrocyte and, although we assume that the bone marrow CD34 cell is the precursor, this has not been scientifically demonstrated[1]. Dermal dendrocytes are MHC Class II antigen positive, suggesting a role in antigen presentation, but functional studies on their immune function have not been conducted to date[3,5,6].

An important surface marker for the dermal dendrocyte is the blood clotting transglutaminase Factor XIIIa. The presence of this factor on the dermal dendrocytes has led to speculation that this cell could have a function in controlling blood loss following damage to the superficial plexus of blood vessels in the skin.

In human skin, dermal dendrocytes are found in the upper papillary dermis perivascularly and around adnexal structures.

## 1.1 Histiocytoses of dermal dendrocytes

Studies have shown that a number of these entities share the same immunophenotype. These include benign cephalic histiocytosis, juvenile xanthogranuloma, generalized eruptive histiocytosis, xanthoma disseminatum and progressive nodular histiocytosis[4].

In all of these conditions, Factor XIII cells are found. In one large study, biopsies from benign cephalic histiocytosis, generalized eruptive histiocytosis and juvenile xanthogranuloma were examined. In all specimens examined, three distinct patterns of proliferation of histiocytes were observed; papillary dermal, lichenoid and diffuse[4,5,12-15].

In benign cephalic histiocytosis, generalized eruptive histiocytosis and early non-xanthomatous juvenile xanthogranuloma, the three conditions could not be specifically differentiated from each other on histopathological grounds[2,3,5]. With time, the juvenile xanthogranulomas become more xanthomatized and can then be more specifically differentiated from the other two entities.

Histiocytic disorders are currently identified by their component cells. In the right clinical context, lesional cells that are CD1aþ/Langerinþ/S100þ can be identified as Langerhans cell histiocytosis (LCH) cells without looking for ultrastructural Birbeck granules[1, 2]. The non-Langerhans cell histiocytoses (non-LCH) are a diverse group of disorders defined by the accumulation of histiocytes that do not meet the phenotypic criteria for the diagnosis of Langerhans cells (LCs). Although some may

have a haemophagocytic component, the definition excludes primary and secondary forms of haemophagocytic lymphohistiocytosis (HLH) [3].

In general, the type of histiocyte that makes up the majority of a given lesion can be matched to a counterpart in the normal developmental cycle of the histiocyte. Much of this knowledge arises from studies done in vitro. In fact, from recent studies, the view is emerging that the cells of the mononuclear phagocytic system, including LCs, may evolve from a number of different precursors including monocytes, lymphocytes and possibly even mesenchymal cells[1-3, 15]

At present, however, it still appears that most histiocytes arise from the CD34þ stem cell which, driven by cytokines in the cellular microenvironment, develops along two major pathways, to CD14 negative or positive cells. The CD14 cell in the presence of TNFa and GMCSF develops into the LC while the CD14þ cell develops either into the interstitial/ dermal dendrocyte or the monocyte/macrophage depending on the cytokine-environment[1]

There is continuing modulation between cells in the various developmental pathways, driven by changes in the microenvironment [2].

From a clinical point of view, it remains useful to divide histiocytic disorders into those arising from dendritic cells such as LCs and dermal dendrocyte and those arising from the macrophage line. The dermal dendrocyte has as one of its hallmarks positive immunostaining for factor XIIIa and seems to be the precursor cell of many of the non-LCH [3]. The dermal dendrocyte can be found in cutaneous and extracutaneous sites, which would explain the occurrence of the extracutaneous

forms of the diseases. It has been suggested that these cells should more correctly be termed interstitial dendritic cells [4,6-8].

**The non-LCH** are benign proliferative disorders which clinically can be divided into three major groups—

1) those that predominantly affect the skin,
2) those that affect the skin but have a systemic component as a major part of the disease, and
3) those such as Erdheim– Chester disease (ECD) and sinus histiocytosis with massive lymphadenopathy (SHML) (Rosai–Dorfman disease) that primarily involve extracutaneous sites, although skin may be part of the disease spectrum[14,15].

### 1.2 The Juvenile Xanthogranuloma (JXG) Family

The non-LCH histiocytoses consist of a long list of diverse disorders, which have been difficult to categorize and even more difficult to remember. Based on studies done by Zelger et al[5] and later Chu[6] it is shown that the lesional cell of most of the non-LCH have the identical immunophenotype, being Factor XIIIa positive, particularly at the early stages, as well as CD68, CD163, fascin and CD14 positive, S100 and CD1a negative. This suggests that these diseases form a spectrum of the same disorder and that they derive from the same precursor cell . Zelger et al[5], Chu[6], and others have since referred to these disorders as the JXG family. Only a few of the non-LCH appear to derive from a different cell line, the most important examples of these non-JXG family disorders are SHML (Rosai Dorfman disease) and multicentric reticulohistiocytosis (MRH).

This concept of the JXG family is similar to what is found in LCH, in which wide spectrums of clinical forms of disease share the identical immunophenotype.

In their attempt to formulate a unifying concept for the non-LCH, Zelger et al[5] described five major morphologic types of histiocytes namely scalloped, vacuolated, xanthomatised, spindle-cell, and oncocytic[5]. They found that JXG is usually polymorphous with all five types of histiocytes recognizable morphologically and that the other cutaneous histiocytoses are usually largely monomorphous and could be defined by a specific histiocyte, as well as by the clinical features of the disease. Chu[6] took the concept forward by suggesting that the various cell types form a continuum along a pathway of maturation, from the early scalloped cell through vacuolated to xanthomatized to the mature spindle shaped cells. Chu[6] also suggested that the more mature the histiocyte, the more resistant the disease to adjuvant therapy. Thus he felt that benign cephalic histiocytosis (BCH), generalized eruptive histiocytosis (GEH) and JXG represent the most immature end of the spectrum, occurring earlier in life and presenting with disease that usually resolves spontaneously.

At the more mature end of the spectrum is xanthoma disseminatum (XD) in which the disease resolves but usually only after many years, and at the later stage is dominated by spindle-shaped histiocytes[19,20]( See Fig 1).

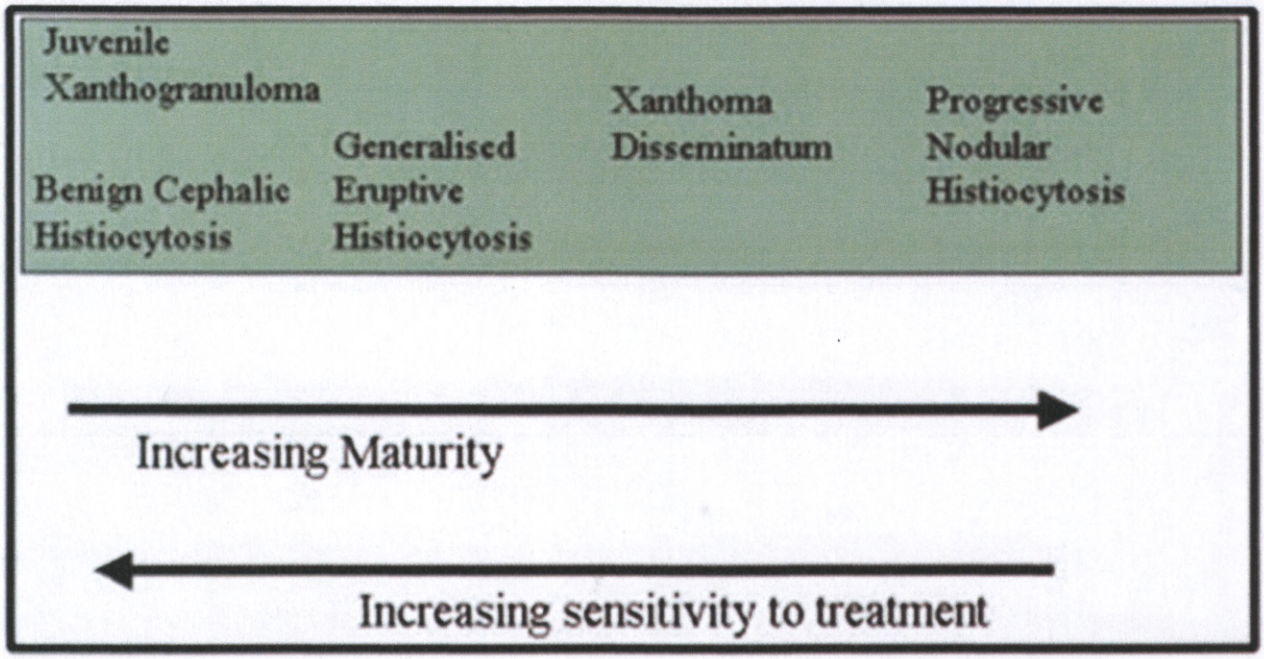


**Fig 1. At the extreme end of the spectrum is progressive nodular histiocytosis (PNH), a disease of mature spindle-shaped cells, which is very resistant to treatment[9] .**

The disease is progressive and although spontaneous involution may occur after many years, patients may be left with severe disfigurement[8, 10, 15-18]. Although these concepts remain unproven, considerable evidence exists to support them. Numerous cases have been described that show one type of lesion beside another[11, 12] as have patients with lesions that follow a time cycle with progression from immature histiocytes to the more mature cells[13-15, 18, 19]. Lesions of BCH have been shown pathologically to mature to lesions typical of JXG, and some authors now refer to BCH as early JXG[8]. Similarly GEH has been shown to be a precursor of JXG, XD, and of PNH. Finally strong expression of MS-1 protein, a high molecular weight protein specific for sinusoidal endothelial cells and dendritic perivacular histiocytes, was found in all non- LCH cells tested, but not LCH. The strong cytoplasmic MS-1 expression in small lesional histiocytes, with expression confined

to a rim surrounding the xanthomatized center of large xanthomatoid and multinucleated cells, also suggests a common maturation pathway for these cells and for these disorders[5]. A similar picture has been seen in LCH with recurrences, sometimes years later at the site of an earlier proven LCH lesion, but with a phenotype that suggests that the constitutive cells are more mature than the previous LCH cells, with loss of CD1a/ Langerin, upregulation of surface HLA-DR, and increased fascin expression[3].

If we accept the concept that disorders that are clinically present quite differently may be due to the same basic cell type at different stages of maturation, then the long list of non-LCH disorders may be made more understandable and certainly easier to remember and to teach, by considering them in the context of early, middle and late maturation stage[5, 7].

Whether histiocyte morphology can be used for pathologic diagnosis however as suggested by Zelger[3] is controversial, and some pathologists believe that the morphology is too variable to be used in this fashion, as might be expected if the diseases are occurring from cells at varying stages along a continuum (See Fig 2).

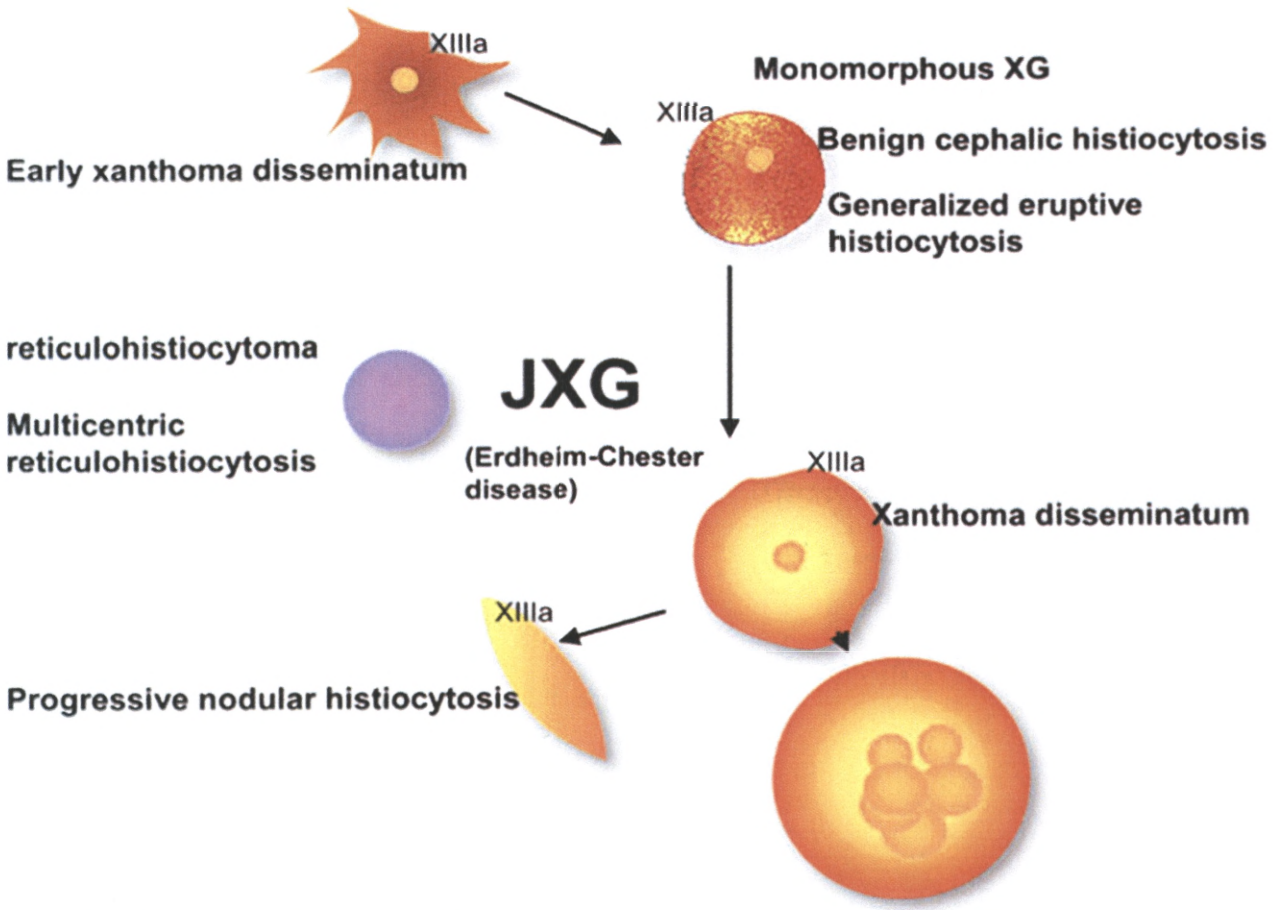


**Fig 2. This illustration depicts the maturation and progressive spindling of histiocytic cells in these disorders. It further highlights the progression of the disease, in particular our case on PNH (Progressive nodular Histiocytosis)[9]**

### 1.3 Diagnosis Of The Non-LCH

#### 1.3.1 Histopathology

Histopathology is used to diagnose the presence of a non-LCH, but differentiation between the different subtypes is based mostly on immunohistochemistry and the clinical setting.

The basic histopathology of the non-LCH shows well circumscribed nodules with a dense infiltrates of histiocytes. Those that involve skin usually mainly infiltrate the dermis. Multinucleate giant cells in variable numbers are present, and there is a variable degree of predominantly perivascular and perilesional inflammatory cells. Touton[4] giant cells (seen in 85% of cases of JXG, in a recent series), but not limited to JXG, are characterized by a wreath of nuclei around a homogenous eosinophilic cytoplasmic center, while the periphery shows prominent xanthomatization[15]. Electron microscopy has revealed a variety of non-specific organelles including dense bodies, worm-like bodies and popcorn bodies amongst others[16]. In MRH and solitary reticulohistiocytoma multinucleate giant cells and histiocytes containing an eosiniphilic "ground glass" material are characteristically found[8-10, 23].

Thus lesional cells, taken in context, that are positive for factor XIIIa, CD68, CD163, fascin, CD68, and CD14 and that are negative for CD1a, S100, Langerin and/or Birbeck granules are diagnostic of the JXG family. MRH, on the other hand is defined by histiocytes and multinucleated giant cells that are factor XIIIa negative, CD68 positive and appear to derive from the macrophage line, as do the constitutive S100þ cells of SHML (Rosai–Dorfman disease)[26].

The final group of conditions that lack markers for LCH, JXG, or macrophage lineage, but are clearly dendritic in nature have been referred to as dendritic cell histiocytosis when CD1a negative, and as indeterminate cell histiocytosis when they are CD1a positive but lack Birbeck granules on EM. Cases usually occur de novo but lesions occurring at the same site as previous LCH but which appear to have lost the CD1a positivity, have been seen[17].

The therapy for all solitary lesions is primarily surgical excision and subdivision appears to serve no useful function.

### 1.3.2 Clinical Diagnosis

Once the diagnosis of "JXG family" is made on immunohistochemistry, the various diseases can be defined by the clinical setting, that is, whether they are solitary, multiple, or disseminated, the areas of the body involved and the age of the patient[8,10 12,15,16,18].

Thus, JXG is divided into cutaneous and extracutaneous forms. Multiple cutaneous lesions confined to the head and neck area in a young child is BCH, multiple skin lesions occurring in adolescence or young adults with prominent involvement of flexures as well as viscera and mucosa, and comprising mainly xanthomatized cells is XD, multiple lesions appearing in crops, generally sparing the flexures and occurring in normolipemic patients is GEH, while multiple lesions arising in skin of an older patient and progressing to form large nodules, with no evidence of spontaneous regression and comprising mainly spindle-shaped histiocytes[5,6], is PNH.

The reason for the variations in presentation of what appears to be the same disorder, may be due to differing immune responses to what may essentially be the same initiating factor/s. Cytokines can activate macrophages and modulate their phenotype, and the clinicopathologic variations seen are likely to be due to differing "cytokine microenvironments"[5]. A variation in host response could explain the predilection of specific diseases according to the age and gender of the patient. Thus, the majority of BCH and JXG occur in young children, XD characteristically

affects males in their late teens or early twenties, PNH affects elderly patients of either gender[5], and MRH usually begins in the fourth decade and predominantly affects women[23]. All of these disorders have been rarely described in children however.

All of the disorders considered here are uncommon and pose significant diagnostic challenges. From a clinical point of view, however, they share some important characteristics[6-8].

In general, non-LCH in very young children are usually widespread but tend to be benign and self-limited[6].

With increasing age[5], JXG is more likely to be present as a solitary lesion but most still involute spontaneously.

In adults, non-LCH including adult XG, most commonly occur as solitary lesions which tend however, not to undergo spontaneous involution. The majority are cured by excision. Generalized lesions in adults are less common, but when they occur they rarely regress spontaneously, and chemotherapy and radiation therapy often have little impact on the course of the disease[5,6] (See Table 1). Finally, all of these disorders may be associated with underlying infectious, autoimmune or malignant diseases, the likelihood of which increases with increasing age and is most commonly seen in MRH[23].

**Table 1. Classification of the non langerhans cell histiocytoses group of conditions. Highlighted is PNH (progressive nodular histiocytosis), in which our patient fitted the typical features as discussed.[6,8]**

| | Histiocytoses | | | | |
|---|---|---|---|---|---|
| Diagnosis | Age range | No. of lesions | Appearance | Sites of predelection | Natural history |
| JXG | 0 18 (median 2 years) | Single:multiple 9:1 | Reddish progressing to yellow brown | Head and neck can be any site | Gradual involution |
| | <6 months, >M | Multiple disseminated | Same | Same | Involution |
| Giant JXG | Young >F | Single | >2 cm | Upper extremity/ upper back | Involution |
| Systemic JXG (4% of JXG) | Median age 0.3 years | Single to multiple | Almost 50% have no skin lesions | Subcutis, liver, spleen, lung, CNS, ocular (iris) | May involute<br>N.B. CNS, ocular JXG fatalities 4% 10% |
| Adult XG | 18 80 (median 35 years) | Single | Same as JXG | Upper body (not legs) | No involution |
| BCH | Young child | Few to multiple | Reddish tan papules | Head and neck | Involution or progression to XG |
| GEH | Young adult | Multiple disseminated | Reddish tan papules appears in crops | Face, trunk, arms spares flexures | Involution or progression to XG, XD, PNH |
| PNH | 40 60 years M & F | Multiple disseminated | 1. Xanthomatous skin<br>2. Deeper subcut nodules | Any | Progression to disfigurement |
| XD | Late teen young adult usually <25 years, >M | Disseminated | Yellow/reddish brown grow forming plaques and nodules | Any skin, eyelids flexures, mucosae viscera inc. CNS transient DI | Slow involution over years or progression rare fatalities |
| MRH | 40+ >F 85% white | Multiple | Pink reddish brown or yellow | Dorsum hands, 'coral bead' peri ungual vermicular around nostrils face, pinna, arms, legs<br>Symmetric erosive polyarthritis usually precedes rash | Progression may involute after years<br>Disabling arthritis in some patients |
| ECD | 7 84 (mean 53 years) | Mainly systemic | Xanthelasma xanthoma | Symmetrical long bone sclerosis proptosis, lung, kidney retroperitoneal fibrosis, CNS including DI | High fatality rate lung fibrosis resp/ cardiac failure |
| SHML | Mean 20.6 years wide range | Mainly systemic | Firm indurated papules | Cervical adenopathy 80% "B"symptoms 43% extranodal skin, soft tissue, upper resp bone, eye, CNS (dural based) other | Exacerbations and remissions often self limited (years) 5% 11% fatalities |

**JXG – Juvenile Xanthogranuloma; BCH – Benign cephalic histiocytosis; GEH – generalized eruptive histiocytosis; PNH – progressive nodular Histiocytosis; XD – Xanthoma Disseminatum; MRH – Multicentric reticulohistiocytosis; ECD – Erdheim Chester disease; SHML - Sinus histiocytosis with massive lymphadenopathy**

Histological examination of benign cephalic histiocytosis, juvenile xanthogranuloma, generalized eruptive histiocytosis, xanthoma disseminatum and progressive nodular

histiocytosis shows a spectrum of cell types from plump dendritic histiocytes to mature spindle shaped cell. In benign cephalic histiocytosis and juvenile xanthogranuloma, the cells appear to be the most immature and the disease has the shortest lifespan, resolving after a few months. At the other end of the spectrum, progressive nodular histiocytosis is a disease of mature spindle-shaped cells, and the disease is progressive with no tendency to spontaneous remission and is very resistant to treatment[5, 6]. At the more mature end of the spectrum is xanthoma disseminatum where the disease resolves, but usually only after many years and at the later stages, is dominated histologically by spindle shaped cells.

With maturation of the dermal dendrocytes in these conditions, the cells appear to become less responsive to treatment with radiotherapy or chemotherapy. Widespread juvenile xanthogranuloma is sensitive to radiotherapy and chemotherapy, while progressive nodular histiocytosis is resistant to all forms of therapy. It is possible that early in the disease progressive nodular histiocytosis and xanthoma disseminatum may be sensitive to treatment but as the cells become more mature, they become resistant to treatment.

The patient fitted the typical pattern of PNH (See Table 2) .There is therefore a powerful argument for early aggressive treatment in these conditions, particularly in Xanthoma Disseminatum where ocular, central nervous system and meningeal involvement can cause significant morbidity, and in progressive nodular histiocytosis where the disease causes severe disfigurement[6].

**Table 2. The differential diagnoses of Progressive nodular histiocytosis[5,6].**

| | PNH | GEH | XD | JXG* | BCH |
|---|---|---|---|---|---|
| Age | Adults > children | Adults > children | Young adults | First 2 years | Young children |
| Sex | No sex predilection | Males > females | Males > females | Males > females | No sex predilection |
| Skin lesions, *n* | Multiple | Multiple | Multiple | Single or multiple | Few to multiple |
| Type of lesions | Yellowish-brown papules; deep dermal nodules | Crops of reddish-tan papules | Yellowish-brown papules that tend to coalesce | Reddish-yellow papules and nodules | Reddish-brown papules and nodules |
| Distribution | Generalized with prominent facial involvement | Generalized and symmetrical | Generalized with prominent flexural involvement | Generalized with predilection for the face and upper trunk | Head and neck |
| Mucous membranes | Yes | No | Yes | Rarely | Yes |
| Systemic involvement | Usually not | Usually not | Diabetes insipidus Respiratory tract involvement | Rarely | Yes |
| Course | Progressive but with benign behavior | Benign with spontaneous resolution | Progressive with rare fatalities | Spontaneous regression | Spontaneous resolution or progression to JXG |

## 1.4 Summary of cases previously describes in the literature:

1) The first case of PNH was described in 1978 by authors who described themselves as `lumpers' rather than `splitters' but could not categorize their patient into an existing class of histiocytosis [28]. They reported a 9-year-old girl who eventually developed hundreds of lesions that were similar clinically and histologically to JXG, but were non-regressing and not flexural.
2) An 85-year-old woman from England presented with an intensely pruritic eruption of 5 years duration that affected mainly the shoulders and proximal limbs. It was particularly pronounced at times of psychological stress, and had failed to respond to intermittent mild topical steroids. Examination revealed multiple firm flesh-coloured nodules, 1–2 cm in diameter and elevation, clinically in keeping

with nodular prurigo. Smaller monomorphic dermal nodules were also evident, particularly on the thighs and upper arms. The face, scalp and flexures were not involved, and there was no lymphadenopathy.[29]

3) A 24 yr old female from Germany who suffered from progressive nodular histiocytosis, had two distinct lesions namely superficial xanthomatoid papules up to 5 mm and deep nodules and tumours from 1–3 cm. Histologically the nodules represented spindle cell xanthogranulomas. The patient had no response to treatment and lesions continued a disfiguring course.[30]
4) A 13-year-old girl from the UK presented with multiple cutaneous histiocytic lesions, precocious puberty, growth hormone deficiency and a hypothalamic tumour. It was concluded that she had progressive nodular histiocytosis. In this patient with cutaneous histiocytosis and a hypothalamic tumour, the coincidental onset of cutaneous and endocrine disorders suggests a common cause. Furthermore, the hypothalamus is a site of predilection for histiocytic lesions and magnetic resonance imaging enhancement excluded the more common diagnosis of hamartoma, again supporting the hypothesis that the brain lesion is histiocytic. Involvement of the central nervous system has been reported only three times previously. In view of the onset in later childhood and progressive course, PNH is a more likely diagnosis than JXG.[31]
5) A 7-year-old Japanese boy presented with a 6-year history of yellow maculopapular facial lesions. There was a history of onset at the age of one year, when yellow macules and papules had appeared on the cheeks one day after falling into a dirty gutter. There was associated thickening of the cheek skin with

gradual enlargement of macular lesions bilaterally. After medical consultation and a skin biopsy, he was diagnosed with benign cephalic histiocytosis and was kept under regular observation. However, the yellow macules progressed to involve his entire cheek on both sides. At the age of 7 years, there were no signs of spontaneous resolution. On examination, there were facial plaques with bilateral involvement of the lower eyelids, cheeks and chin. Moreover, numerous red-brown nodules with a diameter of 0.5–2 cm were associated with these plaques and were asymptomatic. When the clinical appearance of the condition was compared with the appearance at 4 years of age, it was found that the yellow plaques had not resolved and the redbrown nodules had enlarged and were increased in number.

This case was considered to be a type of non- Langerhans cell histiocytosis (class 2) because of the histological features of the foam cells, Touton giant cells and spindle cells and the immunohistochemical results that CD68 and MAC387 were present but CD1a and S-100 proteins were absent [1,32].

6) A 52-year-old woman from the middle east, who 12 years prior to presentation, had begun to develop papules and nodules that appeared gradually and displayed a progressive course without any signs of spontaneous resolution. The lesions were disfiguring but not painful or pruritic. She had involvement of the eyelids but no ectropion. She had decreased vision and optic atrophy, which may not have been related to the skin lesions. The lesions were excised with good results.[33]

7) A 34 yr old female from Florida, USA, with a 7-year-history of progressive increase in growth and number of skin lesions beginning on the back, and later involving the head and neck, was referred for evaluation of obstructive breathing and dysphagia. She had multiple pedunculated soft tissue lesions on her forehead, eyes, nose, lips, cheeks and back. This case is unique in its clinical presentation because of the extent of pharyngeal and laryngeal involvement.[34]

## 1.5 Objectives and Aims

The aims of this study and thesis is to highlight the rarity of the condition Progressive Nodular Histiocytosis. Its is so rare that it has been termed an 'orphan' disease, thereby little or no funding goes towards research and newer treatment modalities in this condition.

The diagnosis of the condition relies heavily on experienced pathologists who actively look for the features of the disease. It is the hope, that with academic awareness, more of these patients will be diagnosed earlier, and thereby greatly improving treatment outcomes.

If dermatologists and physicians are made aware of the condition, further investigations such as biopsies, etc will be done and pathologists will be asked to look for the disease features and ask for special stains. With this, there may be many patients who are either misdiagnosed or without diagnosis. This will improve treatment outcomes.

## 1.6 Summary

Progressive nodular histiocytosis was first described as progressive nodular histiocytoma by Taunton et al[4]. It is a proliferative disorder, mainly of dermal dendrocytes, currently classified within the histiocytoses of varied biological behaviour and, within these, included in a subgroup of dendritic cell disorders related to juvenile xanthogranuloma. This subgroup, which also includes xanthoma disseminatum, benign cephalic histiocytosis, progressive nodular histiocytosis, spindle cell xanthogranuloma, and generalized eruptive histiocytosis, forms a group that is difficult to define because of their clinical overlapping, so that in fact there is a tendency towards their unification according to clinical and histopathological criteria[2, 3, 5, 7].

In 1995 Zelger et al[8] reported their histopathological observations regarding this type of histiocytosis, describing the pathological features of progressive nodular histiocytosis as xanthogranulomas with a predominance of storiform spindle-shaped histiocytes, positive to macrophage/dendritic cell line markers (CD68, HAM 56 and factor XIIIa), as well as SM-actin and HHF35, with no Birbeck granules visible on electron microscopic examination. Very few universally accepted reports of progressive nodular histiocytosis exist, and these have received diverse nomenclature.

The disease is characterized by the progressive appearance of cutaneous and mucosal histiocytomas without spontaneous resolution in a normolipaemic state.

Flexural folds and joints are not predominantly involved. Two clinically distinct lesions have been reported: superficial, firm, round or pedunculate, yellowish-brown tumours and deep purplish nodules with overlying telangiectasia. They often grow to a large size (0.4–5 cm). Histologically, the lesions consist of a fibrohistiocytic infiltrate with multinucleated and foamy cells. Characteristically specific stains for lipids (oil red O stain) and iron (Gomori's stain) are positive.

Therefore, the appearance after childhood, progressive nature without spontaneous resolution, no predilection for the flexural folds , and the absence of systemic involvement, are characteristic of progressive nodular histiocytoma[5-8, 18] (See table 3).

Progressive nodular histiocytosis is characterized by an intense involvement of the face where the lesions tend to group resulting in the typical morphology of leonine facies. Hereditary progressive mucinous histiocytosis[9] is an inherited disease. Typically the lesions are smaller and histological studies demonstrate the presence of mucin.

**Table 3. Diagnostic criteria for progressive nodular histiocytosis**

| |
|---|
| 1 Presence of two distinct types of skin lesion, with multiple occurrence and generalized distribution[a] |
| 2 Progressive course[a] |
| 3 Histopathology consistent with xanthogranuloma |
| 4 Immunohistochemistry consistent with non-Langerhans cell histiocytoses (CD68-positive, CD1a-negative, S-100 protein-negative) |
| 5 Absence of Birbeck granules on electron microscopy |

'a' – Diagnostic criteria that must be present to make the diagnosis of PNH

## 1.7 Conclusion

The non-LC histiocytic disorders may be clinically divided into those mainly affecting the skin (the cutaneous histiocytoses), those with skin plus a major systemic component, and those that are mainly systemic. Despite their clinical diversity, the majority appear to originate from a common precursor and form part of a spectrum of a single disorder.

It is pragmatic to subdivide these disorders (according to immunohistochemical criteria) into JXG family members and non-JXG. It is possible that early on, progressive nodular histiocytosis may be sensitive to treatment. There is therefore a powerful argument for early aggressive treatment as the disease causes severe disfigurement, before dermal dendrocytes have differentiated into xanthomatized or spindle-shaped variants[5-7].

Our patient presented with an extremely rare variant of Histiocytosis, and to date, is the first reported case in Africa. It is also the first case reported in a black male.

## 2. SUBJECTS AND METHODS

This was an extremely rare case and there was therefore only one subject of the case report. This patient was seen from 2008 up to 2012 and was fully investigated at the Charlotte Maxeke Hospital. All investigations and tests are fully paid for.

Special investigations included the following :

- Chest X-Rays, High resoloution CT Chest, PET scan
- Immunohistochemistry performed on histopathological specimens
- Numerous Blood investigations

Consent for photographs and research was obtained from the patient and ethics clearance was given (see Appendix 1).

**Methods of processing of histology specimens as follows:**

Specimens of skin removed for pathological examination ideally should contain a representative sample of epidermis, dermis and subcutaneous tissue. The sample should be transported in fixative (usually 10% neutral buffered formalin)

**In the laboratory**

**Fixation**

The purpose of fixation is to preserve the skin specimen indefinitely in a life-like state. For normal histological sections, the specimen of skin is immediately placed in formol saline (formalin). It remains in this preservative for a minimum of 24 hours prior to processing by a histotechnologist.

Formalin fixes the tissue by forming cross-links between lysine residues in the proteins, which does not alter their structure. It is buffered with phosphate to prevent acidity provoked by tissue hypoxia, maintaining a pH of 7. It penetrates effectively into the tissue but rather slowly, depending on its thickness; tissues can be fixed faster if they are warmed.

If no fixative is available at the time of biopsy, the specimen should be kept moist with saline and transported to the laboratory as soon as possible, contacting the lab in advance to confirm that there will be someone available to receive it.

**Tissue processing**

The technologist assigns the specimen a unique accession number, examines it and describes the gross appearance of the specimen. If malignancy is suspected, the edges of the specimen may be marked with ink to identify excision margins. All or parts of the specimen are placed into one or more small plastic cassettes which hold and identify the tissue while it is being processed, and which acts as the backing for the final paraffin block. Initially, the cassettes are placed into a fixative.

Paraffin blocks are then prepared to allow the tissue to be cut into thin microscopic sections (3-5 microns). Using an automated processor, the water is removed from the tissue by alcohol dehydration. The alcohol is cleared using xylene and then the tissue is ready to be embedded in paraffin wax. The technician removes the tissue from its cassette, aligns it carefully in a mould and

pours hot paraffin wax over it. As the wax cools, it solidifies to form the block ready for sectioning.

### Sectioning

The embedded tissue is cut into sections using a microtome, which moves the block across a very sharp knife every 3 to 5 microns. The sections are then floated on a warm water bath, picked up on a glass microscope slide and dried in a warm oven.

---

**Preparation of the specimen**

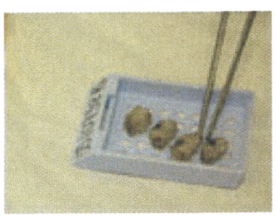

Skin fragments in cassette



Completed paraffin block



Sectioning the biopsy



Microtome



Water bath to collect section



Staining machine

---

### Staining

By another automated process, the paraffin is removed from the sections by sequentially immersing in xylene, then alcohol and then water. The slide is then stained routinely using haematoxylin & eosin (H & E). This is an automated

process in larger laboratories, but some centres stain manually. In some situations, other special stains may be used.

Haematoxylin stains include a variety of metal cations that result in varying hues (blue). It is a basic dye that stains the nucleic acids of the cell nucleus and is usually partially removed by an acid-alcohol solution.

Eosin stains are acidic and dye cytoplasmic components of the cell red.

**Mounting**

The stained slide is processed again through water, alcohol and xylene. A resin is applied to glue a cover slip or plastic film in place over the section. The slide is now ready for the pathologist to examine and report the microscopic description, the diagnosis and comments.

# 3. CASE REPORT

## 3.1. History

A 50-year-old black male from Johannesburg, South Africa, presented with skin lesions that began 25 yrs ago. There was no family history of note. He was a resident of SA, and had no history of travel into Central Africa.

There was progressive evolution of cutaneous lesions, which had increased in size and number, with associated mechanical deformities.

Physical examination showed multiple disseminated cutaneous lesions, consisting of papules and nodules in a generalized distribution, with sparing of the axillae or inguinal areas. Some of them were small, corresponding to lesions of just a few months' evolution, and others large, of longer duration (See Fig 7 and Fig 8). They involved the head (face, scalp and auricular regions), neck, trunk and extremities.



Fig. 3 Face



Fig. 4 Trunk

Their colour was heterogeneous, reddish with greyish tones, and generally smooth and shiny on the limbs (See Fig 9 and Fig 10).They were delineated by healthy skin and were mostly mounted on the skin, although a few were pediculated. Similar nodular lesions were present on the foot.



Fig. 5 Limbs



Fig. 6 Close up – leg

There were no signs of necrosis or spontaneous regression of the lesions, which on palpation were of hard consistency and not painful. The conjunctival, nasal, and oropharyngeal mucosae were free of lesions. There were no other physical findings of note.

### 3.2. Blood tests

They included the following:

Urea, creatinine, glucose, liver enzymes, total, direct, and indirect bilirubin, alkaline phosphatase, electrolytes, creatinine phosphokinase, total proteins, serum osmolarity and erythrocyte sedimentation rate, but the results were all normal (N). The uric acid concentration was normal. Blood lipid studies showed triglycerides: 0.97 mmol (N) , total cholesterol: 2.54 mmol (N) , high-density cholesterol lipoprotein (HDLc): 0.89 mmol (low), low-density cholesterol lipoprotein (LDLc): 1.99 mmol(N), Protein electrophoresis was normal, as were the levels of immunoglobulins, rheumatoid factor, ASOT, as well as C3 and C4 complement.

Organ-specific autoantibodies and antinuclear antibodies were negative. Serological tests for syphilis, and hepatitis were negative. Urine analysis showed no protein.

### 3.3. Radiological investigations

Chest X-rays were normal. The bones showed typical degenerative changes for his age, with no evidence of osteolytic lesions.

Abdominal ultrasound was done and showed no abnormalities

PET scan showed reactive uptake in the axillary and inguinal lymph nodes (see Fig 3)

High Resolution CT Chest showed no evidence of pulmonary or cardiac involvement. (See Fig 4).

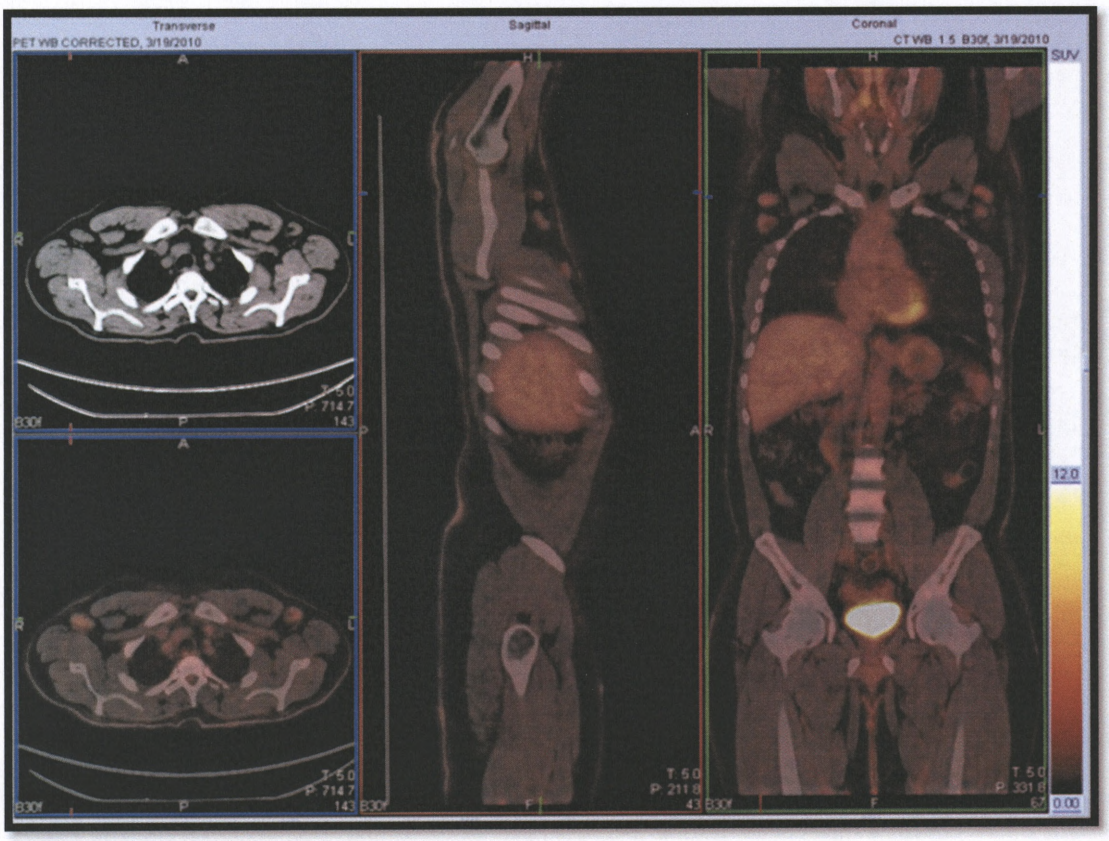


Fig 7. PET scan

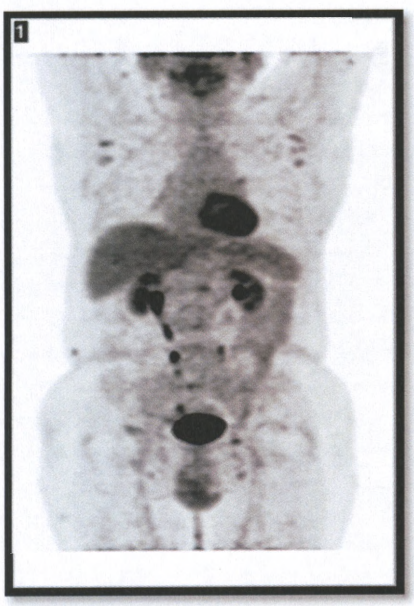

Fig 8. High Res CT Chest

### 3.4. Histology

Several biopsies were taken. H & E study of the recent lesion showed no epidermal alterations, with the dermis presenting a mixed proliferation of xanthomatized and scalloped histiocytes with numerous scattered lymphocytes. The older nodule also showed a normal epidermis with a dense cellular dermal proliferation with predominant spindle-shaped histiocytes, arranged in a storiform pattern. The connective tissue was slightly increased. (See Fig 9)

Immunohistochemical study showed strong staining for markers of CD68. S-100 stain was negative (See Fig 10 and 11).

No Birbeck granules were seen on electron microscopic examination.Other special stains which are specifically positive are HAM-56 and Factor XIIIa (See Fig 12).This patient was given a trial of radiotherapy without improvement. The distinction from other non-LCH, in particular multiple juvenile xanthogranulomas, which may be more likely to show spontaneous remission, is somewhat unclear; patients with PNH usually follow a serious and disfiguring clinical course.

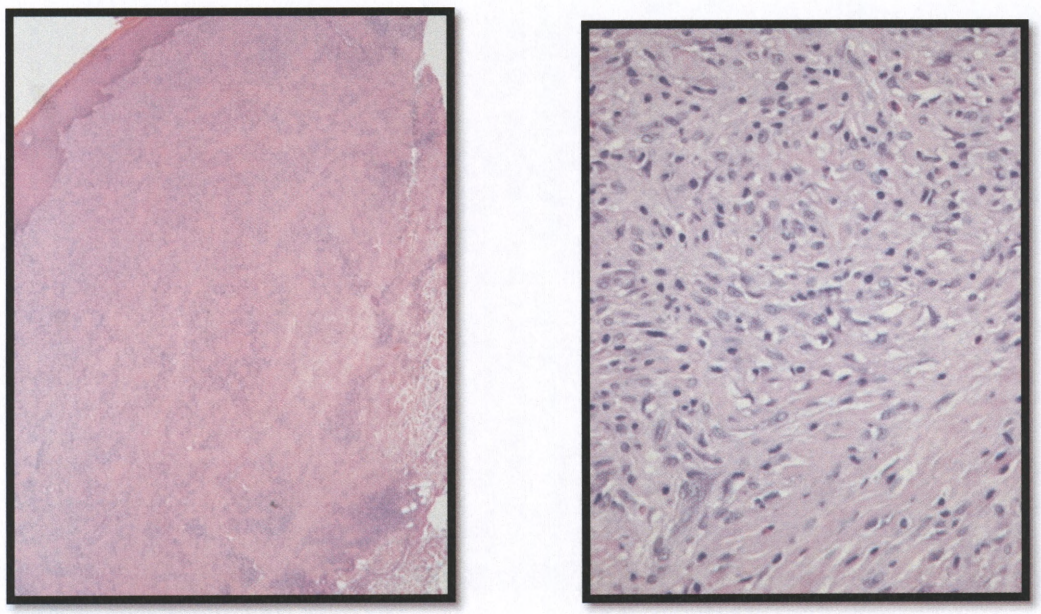

Fig. 9. H&E.

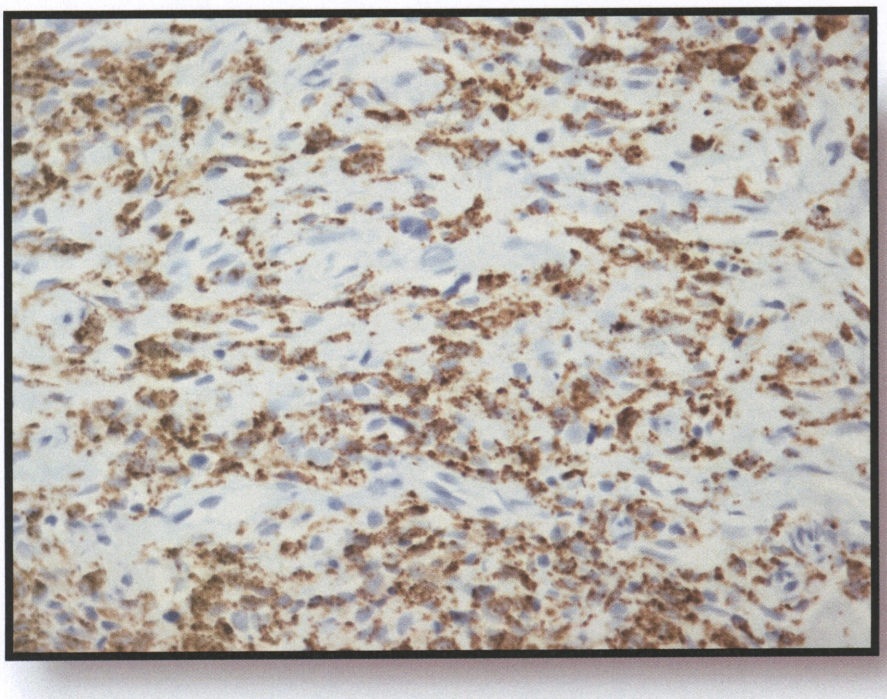

Fig. 10 CD-68

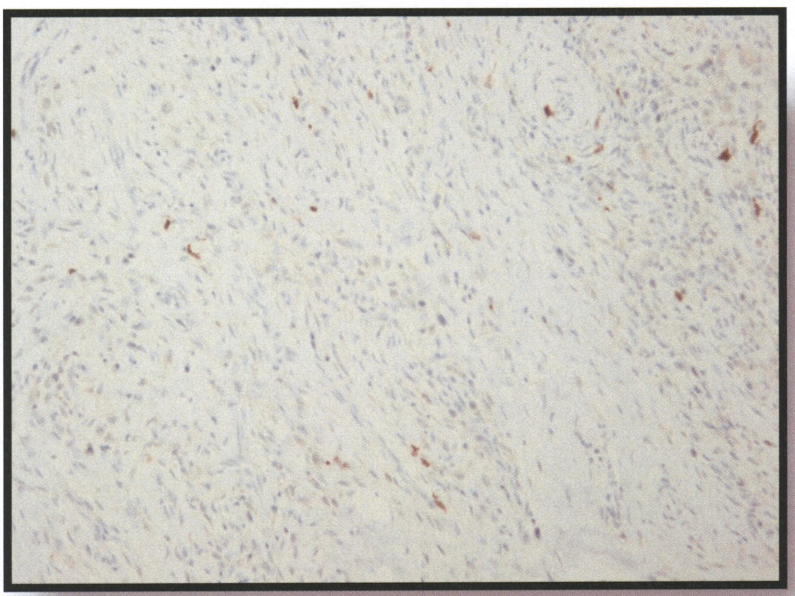

Fig. 11. S-100

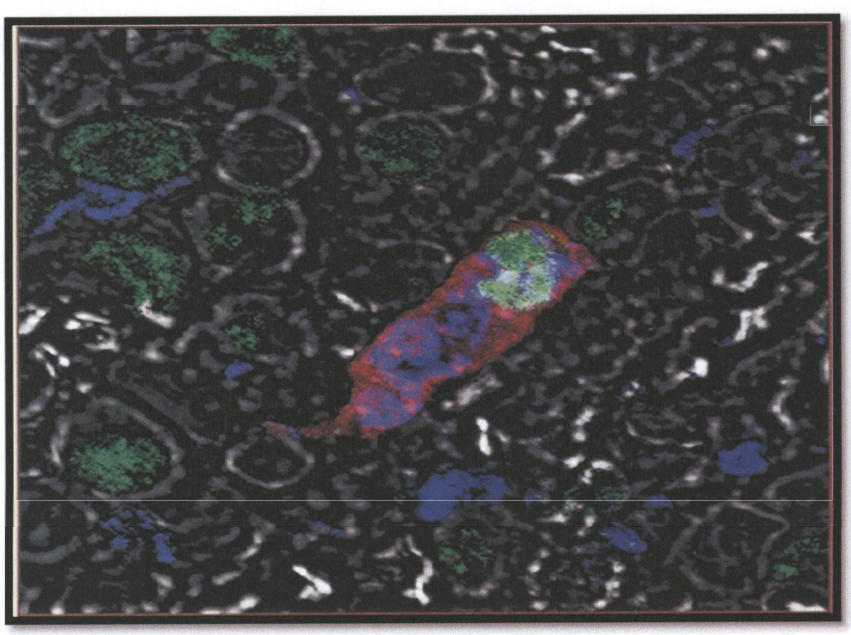

Fig. 12. HAM-56

## 4. CONCLUSION

Although PNH is characterized by a progressive course and does not tend towards spontaneous resolution, patients usually remain in good general health without visceral involvement. The spontaneous regression of some lesions has been an exceptional finding in one patient, and systemic disorders in association with PNH have been reported in three patients.

The associated findings include chronic myeloid leukemia, hepatosplenomegaly, hypothyroidism, hyperuricemia, and hypocholesterolemia in one patient, precocious puberty, growth hormone deficiency, and a hypothalamic tumor in a second patient, and thrombocytopenia with absent radii (TAR) syndrome in a third. However, no definite relationships between these disorders and PNH have yet been established.

The diagnosis of the condition relies heavily on experienced pathologists who actively look for the features of the disease. It is the hope, that with academic awareness, more of these patients will be diagnosed earlier, and thereby greatly improving treatment outcomes.

If dermatologists and physicians are made aware of the condition, further investigations such as biopsies, etc will be done and pathologists will be asked to look for the disease features and ask for special stains. With this, there may be many patients who are either misdiagnosed or without diagnosis. This will improve treatment outcomes.

This is an extremely rare variant of the Histiocytosis group of conditions, and our patient is the first reported case in Africa. Our patient did not exhibit any systemic symptoms, but regular follow up is mandatory. It is with hope, that additional study of the

immunologic and other host factors responsible for these proliferations may someday allow more targeted therapy of these currently resistant forms.

## References


1. Caux C, Lebecque S, Liu J-Y, et al. Developmental Pathways of human myeloid dendritic cells. In: Lotze MT, Thomson AW, Editors. Dendritic cells: biology and clinical application. San Diego: Academic Press; 1999. pp 63–92.

2. Romani N, Holzmann S, Tripp CH, et al. Langerhans cells— Dendritic cells of the epidermis. APMIS 2003;111:725–740.

3. Zelger BWH, Burgdorf WH. The cutaneous "histiocytoses". Adv Dermatol 2001;17:77–114.

4. Banchereau J, Fay J, PascualV, et al. Dendritic cells: Controllers of the immune system and a new promise for immunotherapy. Novartis Found Symp 2003;252:226–235.

5. Zelger BW, Sidoroff A, Orchard G, et al. Non-Langerhans cell histiocytoses. A new unifying concept. Am J Dermatopathol 1996; 18:490–504.

6. Chu AC. The confusing state of the histiocytoses. Br J Dermatol 2000;143:475–476.

7. Favara BE, Feller AC, Pauli M, et al. Contemporary classification of histiocytic disorders. Reclassification Working Group of the Histiocyte Society. Med Pediatr Oncol 1997;29:157–166.

8. Zelger BWH, Cerio R. Xanthogranuloma is the archetype of non- Langerhans cell histiocytosis. Br J Dermatol 2001;45:369–370.

9. Munn S, Murray S, Chu AC. Adult Langerhans cell histiocytosis— A review of 46 cases. Med Pediatr Oncol 2001;38:222.

10. Luz FB, Gaspar AP, Kalil-Gaspar N, et al. Multicentric reticulohistiocytosis. J Eur Acad Dermatol Venereol 2001;15:524–531.

11. Chang MW. Update on juvenile xanthogranuloma: Unusual cutaneous and systemic variants. Semin Cutan Med Surg 1999; 18:195–205.

12. Mullans EA, Helm TN, Taylor JS, et al. Generalized non- Langerhans cell histiocytosis: Four cases illustrate a spectrum of disease. Int J Dermatol 1995;34:106–112.

13. Gianotti R, Alessi E, Caputo R. Benign cephalic histiocytosis: A distinct entity or a part of a wide spectrum of histiocytic proliferative disorders of children. Ahistopathological study.AmJ Dermatopathol 1993;15:315–319.

14. Gonzalez-Ruiz A, Bernal Ruiz AI, Aragoneses Fraile H, et al. Progressive nodular histiocytosis accompanied by systemic disorders. Br J Dermatol 2000;143:628–631.

15. Dehner LP. Juvenile xanthogranulomas in the first two decades of life: A clinicopathologic study of 174 cases with cutaneous andextracutaneous manifestations. Am J Surg Pathol 2003;27: 579–593.

16. Wee SH, Kim HS, Chang SN, et al. Generalized eruptive histiocytoma: A pediatric case. Pediatr Dermatol 2000;17:453–455.

17. Jaffe R, Favara BE. Non-Langerhans dendritic cell histiocytosis (abstract). Pediatr Dev Pathol 2002;5:99.

18. Chang SE, Koh GJ, Choi JH, et al. Widespread skin-limited adult Langerhans cell histiocytosis: Long term follow up with good response to interferon alpha. Clin Exptl Dermatol 2002;27:135–137.

19. Freyer DR, Kennedy R, Bostrom BC, et al. Juvenile xanthogranuloma: Forms of systemic disease and their clinical implications. J Pediatr 1996;129:227–237.

20. Tahan SR, Pastel-Levy C, Bhan AK, et al. Juvenile Xanthogranuloma. Clinical and Pathologic characterization. Arch Pathol Lab Med 1989;113:1057–1061.

21. Szekeres E. Xanthoma disseminatum:Arare condition with non-X, non-lipid cutaneous histiocytopathy. Dermatol Surg Oncol 1988; 14:1021–1024.

22. Ferrando J, Campo-Voegeli A, Soler-Carrillo J, et al. Systemic xanthohistiocytoma: A variant of xanthoma disseminatum.Br J Dermatol 1998;138:155–160.

23. Outland JD, Keiran SJ, Schikler KN, et al. Multicentric reticulohistiocytosis in a 14-year-old girl. Pediatr Dermatol 2002; 19:527–531.

24. Gorman JD, Danning C, Schumacher HR, et al. Multicentric reticulohistiocytosis: Case report with immunohistochemical analysis and literature review. Arthritis Rheum 2000;43:930–938.

25. Juskevicius R, Finlay JL. Rosai–Dorfman disease of the parotid gland, cytologic and histopathologic .Arch Pathol Lab Med 2001;125:1348–1350.

26. Foucar E, Rosai J, Dorfman R. Sinus histiocytosis with massive lymphadenopathy (Rosai–Dorfman disease): Semin Diagn Pathol 1990;7:19–73.

27. Seybold, HeidiSimon, Miklós Burgdorf, Walter Progressive nodular histiocytosis – rare variant of cutaneous non-Langerhans cell histiocytosis. Journal Der Deutschen

Dermatologischen Gesellschaft = Journal Of The German Society Of Dermatology: JDDG [J Dtsch Dermatol Ges] 2006 Mar; Vol. 4 (3), pp. 236-8..

28. Beswick SJ ; Kirk JM ; Bradshaw K ; Sanders DS ; Moss C. The British Journal Of Dermatology [Br J Dermatol] 2002 Jan; Vol. 146 (1), pp. 138-40 S. A. Holme and C. M. Mills Department of Dermatology, Royal Gwent Hospital, Newport. NP202UB, 2002.

29. Adult primary cutaneous Langerhans' cell histiocytosis mimicking nodular prurigo. Holme SA ; Mills CM. Clinical And Experimental Dermatology [Clin Exp Dermatol] 2002 May; Vol. 27 (3), pp. 250-1.

30. Kunimoto K ; Uede K ; Furukawa F Progressive nodular histiocytosis. The Journal Of Dermatology [J Dermatol] 2010 Dec; Vol. 37 (12), pp. 1071-3.

31. Progressive nodular histiocytosis: Nofal A ; Assaf M ; Tawfik A ; Elsayed N ; Nofal E Elnakib N ; Elmosalamy K. International Journal Of Dermatology [Int J Dermatol] 2011 Dec; Vol. 50 (12), pp. 1546-51.

32. Glavin FL ; Chhatwall H ; Karimi K. Progressive nodular histiocytosis: a case report with literature review, and discussion of differential diagnosis and classification. Journal Of Cutaneous Pathology [J Cutan Pathol] 2009 Dec; Vol. 36 (12), pp. 1286-92.

33. Progressive nodular histiocytosis – rare variant of cutaneous non-Langerhans cell histiocytosis .Journal der Deutschen Dermatologischen Gesellschaft; March 2006, p236-238.

34. Ikeda M ; Yamamoto Y ; Kitagawa N ; Kodama H ; Moriki T ; Hiroi M. Solitary nodular Langerhans cell histiocytosis. The British Journal Of Dermatology [Br J Dermatol] 1993 Feb; Vol. 128 (2), pp. 220-2.

# Appendix 1 : Ethics clearance certificate

**UNIVERSITY OF THE WITWATERSRAND, JOHANNESBURG**
Division of the Deputy Registrar (Research)

**HUMAN RESEARCH ETHICS COMMITTEE (MEDICAL)**
R14/49 Dr Lushen Pillay

| | |
|---|---|
| **CLEARANCE CERTIFICATE** | **M120499** |
| **PROJECT** | Progressive Nodular Histiocytosis-An Exceedingly Rare Variant of the Non-Langerhans Cell Histiocytoses |
| **INVESTIGATORS** | Dr Lushen Pillay. |
| **DEPARTMENT** | Division of Dermatology |
| **DATE CONSIDERED** | 04/05/2012 |
| **+DECISION OF THE COMMITTEE*** | Approved unconditionally |

**Unless otherwise specified this ethical clearance is valid for 5 years and may be renewed upon application.**

**DATE** 04/05/2012 **CHAIRPERSON** .....
(Professor PE Cleaton-Jones)

*Guidelines for written 'informed consent' attached where applicable
cc: Supervisor : Prof D Modi

---

**DECLARATION OF INVESTIGATOR(S)**
To be completed in duplicate and **ONE COPY** returned to the Secretary at Room 10004, 10th Floor, Senate House, University.
I/We fully understand the conditions under which I am/we are authorized to carry out the abovementioned research and I/we guarantee to ensure compliance with these conditions. Should any departure to be contemplated from the research procedure as approved I/we undertake to resubmit the protocol to the Committee. **I agree to a completion of a yearly progress report.**

*PLEASE QUOTE THE PROTOCOL NUMBER IN ALL ENQUIRIES...*