

https://dspace.org/

Real world treatment and clinical outcomes of diabetic macular edema at Charlotte Maxeke Johannesburg academic hospital (CMJAH), a six month study

Mothekhe, Priscilla

2022

https://hdl.handle.net/10539/34424

Downloaded from a DSpace repository. https://dspace.org/



Real World Treatment and Clinical outcomes of Diabetic Macular Edema at Charlotte Maxeke Johannesburg Academic Hospital (CMJAH), a six month study

Name: Priscilla Mothekhe
Student ID:2014939

A research proposal presented to the Division of Ophthalmology, University of Witwatersrand, as the requirement towards the fulfilment for the Degree of Master in medicine (MMED).

Supervisor:
Dr A Makgotloe
Department of Neurosciences, Division of Ophthalmology
University of Witwatersrand

UNIVERSITY OF THE WITWATERSRAND, JOHANNESBURG
FACULTY OF HEALTH SCIENCES

SCHOOL OF CLINICAL MEDICINE

DEPARTMENT OF NEUROSCIENCES

Neurology; Neurosurgery; Ophthalmology; Otorhinolaryngology (ENT)

7 York Road, Johannesburg 2193, South Africa *Telephone: 27-11-717 2774*

Plagiarism declaration for written work

I ...Priscilla Nnuku Mothekhe..... as a postgraduate student registered for a MMed at the University of the Witwatersrand declare the following:

- I am aware that plagiarism is the use of someone else's work without their permission and or without acknowledging the original source.
- I am aware plagiarism is wrong.
- I confirm that this written work is my own work except where I have stated otherwise.
- I have followed the required conventions in referencing the thoughts and ideas of others.
- I understand that the University of the Witwatersrand may take disciplinary action against me if there is a belief that this is not my own unaided work or if I have failed to acknowledge the ideas or writing of others.

Signature: ……

Date: ……06/04/2022…

Acknowledgements

In the course of this project, I would like to express my profound gratitude to the following people:

My supervisor Dr Aubrey Makgotloe for his invaluable guidance, comments, and suggestions.

My parents, Alinah and Joshua Mothekhe, for their unconditional love and support.

Last but not least, I am grateful to my loving and supportive husband, Dr Segomotso Moholo. You kept me going when times got tough and you made numerous sacrifices to enable me to earn my Master's degree.

Abstract

Aim : To evaluate the six months treatment patterns and clinical outcomes of DME management in a real world setting at a South African central hospital

Methods: A retrospective analysis of DME patients treated with bevacizumab from 1 September 2018 to 31 October 2019. Patients were required to have been followed up for six months.

Results: A total of 127 records of patients were evaluated. Thirty-two eyes of 22 patients met the inclusion criteria. At six months the median visual acuity (VA) change in the loading dose group was 0.1 logMAR (p = 0.2) and 0.1 logMAR (p = 0.152) in the non-loading dose group, both not statistically significant. Central foveal thickness (CFT) was significantly reduced in the loading dose group but not in the non-loading dose group, 18% (p = 0.038) vs 6% (p = 0.678) respectively. The mean number of injections were 4,7 (SD = 1,87) in the unilateral eye injection group and 5.2 (SD = 1.94) in the bilateral eye injection group.

Conclusion: In a real-life clinical setting, intravitreal bevacizumab improved visual acuity and anatomical outcomes in patients with diabetic macula oedema. Compared to major clinical trials, lower visual acuity gains and less frequent intravitreal injections were observed.

Keywords: Diabetic macular oedema; Intravitreal bevacizumab; Follow up.

Table of Contents

BACKGROUND **6**
INTRODUCTION **6**
RESEARCH QUESTION **14**
AIMS AND OBJECTIVES **14**
METHOD AND DESIGN **15**
DATA ANALYSIS **16**
RESULTS **16**
BASELINE CHARACTERISTICS 16
VISUAL ACUITY OUTCOMES 18
STRUCTURAL OUTCOMES 19
DISCUSSION AND CONCLUSION **20**
REFERENCES **23**

Background

Intravitreal injections are the first-line treatment for diabetic macular edema (DME). Treatment intervals were determined using pro re nata, fixed, or treat-and-extend regimens in several clinical trials[1]. However, real-world studies reveal a high rate of infrequent treatment, resulting in unsatisfactory outcomes. This study retrospectively analysed six months of real-world experience with intravitreal bevacizumab[1,2].

Introduction

Diabetic retinopathy is the most frequent and severe ocular complication of diabetes mellitus and a leading cause of blindness in the working age population in developed countries[1,2].

Diabetic retinopathy is the term used to describe the microvascular abnormalities that are seen in the fundus of patients with diabetes mellitus on colour fundus photography or clinical examination. The earliest presentation is the dot-like microaneurysms (MA) which are small localized outpouchings of the capillary wall. MA occur frequently in relation to areas of capillary non-perfusion. Retinal haemorrhages are another important manifestation of DR, they usually found throughout the fundus. They may be flame-shaped if located in the nerve fiber layer, or dot and blot-like if located in the middle layers of the retina[2]. Venous dilation and beading are typical DR-related changes, and the latter in particular represents focal increases in venous calibre resembling a string of beads. Hard exudates are another manifestation of DR, arising as a consequence of chronic localized leakage from the retinal vessels[2]. Hard exudates are mainly composed of lipid and appear as yellowish white lesions usually with distinct margins and occur close to clusters of

microaneurysms. Soft exudates, also known as cotton wool spots, arise when there is a blockage in the flow of axoplasm in the retinal nerve fiber layer which occurs due to focal ischemia. They represent infarcted inner retina and appear as greyish-white round or oval areas with ill-defined feathery edges[2].

Diabetic macular edema (DME) is accumulation of extracellular fluid and proteins in the central part of the macula. This results from the breakdown of the blood-retina barrier due to an increase in vascular permeability[1,2,3]. Vascular endothelial growth factor (VEGF) plays an important role in the mediation of growth and permeability of the retina blood vessels. For this reason, it is the main site of target for pharmacologic intervention[1,2,3]. Decreased central vision is the most common clinical symptom of DME. Other symptoms may include metamorphopsia (distortion of visual image), floaters, decrease in colour and contrast sensitivity and the development of scotomas[2]. DME can occur in isolation without other signs of microangiopathy in the fundus, therefore it needs to be classified as a separate entity[2]. Impairment of vision may be reversible in the short term, but persistent macular oedema can result in irreversible damage causing permanent visual loss[2]. Other causes of macular oedema include central and branch retinal vein occlusion and neovascular age-related macular degeneration (nAMD)[4,5].

Previously the gold standard of diagnosing macular oedema clinically was performing a fundus examination[2]. Based on this gold standard, the most severe form of DME was described as clinically significant macular oedema (CSME), which is retinal oedema within 500 μm of the centre of the fovea or hard exudates within 500 μm of the centre of the fovea or if associated with adjacent retinal thickening

(which may be outside the 500 μm limit); and one disc area of retinal oedema (1500 μm) or larger, any part of which is within one disc diameter of the centre of the fovea[1,2]. Before the advent of optical coherence tomography (OCT), fluorescein angiography (FA) was an essential diagnostic modality for the assessment of macular oedema and localizations of retinal alteration to allow targeted laser therapy[2]. The diagnosis of macular oedema can now be based solely on OCT. Nonetheless FA is still the only diagnostic tool that can reliably differentiate leaking from non-leaking microaneurysms and identify capillary non-perfusion[2]. Once the treatable lesions are identified by FA, MA and other focal leakages areas are treated with 50–100mm argon laser for a duration of 0.1 second or less, until whitening around the MA or leakage area occurs[3]. Grid laser is used to treat sites with diffuse leakage within 2disc diameters of the macular centre. This is accomplished by setting the laser machine to 50–200 mm spot sizes[3]

The emergence of anti-VEGF therapy resulted in a reduced need for focal/grid laser therapy. This has led to OCT being used as an objective and reproducible instrument to detect the presence of macular oedema and monitor response to treatment. A simple OCT-based classification of DME is often used as centre-involving or non-centre-involving DME[1,2,3,6]

The three intravitreal anti-VEGF agents commonly used for DME treatment are aflibercept, ranibizumab and bevacizumab. A number of landmark clinical trials provided strong evidence supporting their safety and efficacy. Randomized clinical trials which investigated the efficacy of intravitreal anti VEGF agents in the management of DME demonstrated significant improvements in visual acuity with

the anti VEGF agents alone or in combination with laser photocoagulation. In these clinical trials, patients received frequent monitoring and intravitreal injections in the first 12 months [2,7,8]

Bevacizumab (Avastin) is a humanized monoclonal antibody that inhibits all VEGF isoforms. It was specifically designed to treat colon cancer by reducing tumour growth. It is currently used off-label in ophthalmology for ocular diseases including macular oedema[2,4]. For intravitreal administration, it is given at a dosage of 1.25 mg in 0.05 ml insulin syringe[2,4]. The intravitreal half-life of bevacizumab is 3 to 6 days and it can be retained systemically for up to 4 weeks. Protocol H by DRCR.net was the first phase 2 randomized clinical trial to evaluate the safety and efficacy of bevacizumab. This study compared focal laser, intravitreal bevacizumab and combination therapy. Improved visual outcomes were achieved in patients receiving bevacizumab. The bevacizumab or laser therapy (BOLT) study was another pivotal randomized clinical trial evaluating the efficacy of bevacizumab in patients with center-involving DME. This study supported the longer-term use of bevacizumab for treatment of DME [2,4,5,9]

Aflibercept (Eylea) is a recombinant decoy-receptor type inhibitor of VEGF and placental growth factor. The VIVID DME and VISTA DME were the randomized clinical trials that demonstrated the importance of aflibercept in the treatment of DME. The approved dose for aflibercept is 2 mg/0.05 mL given intravitreally every 4 weeks for the first 12 weeks, followed by 2 mg /0.05 mL once every 8 weeks.[2,10]

Ranibizumab (Lucentis) is a recombinant humanized Fab fragment of a monoclonal antibody designed for intraocular use, which binds and inactivates all isoforms of VEGF-A.

Ranibizumab has been shown to be beneficial and relatively safe for the treatment of DME in several randomized clinical trials and has become a standard for treatment of DME[11]. One major randomized clinical trial demonstrated that ranibizumab mono-therapy provides significantly superior benefit over laser in patients with visual impairment due to DME [2]. In cases of insufficient response, ranibizumab may be switched to aflibercept with better clinical outcome response due to its higher affinity to VEGF-A.[10]

The DRCR.net Protocol T, was the first head-to-head landmark study comparing efficacy and safety of all three anti-VEGF therapies in patients with centre-involved DME associated with decreased visual acuity. This trial demonstrated that when the initial visual acuity loss is mild, there are no clinically significant differences, among aflibercept, bevacizumab and ranibizumab for the management of DME. [10,12] When visual acuity loss is moderate or severe, aflibercept is more likely to improve visual acuity. Protocol T also indicated that in all treatment groups the median number of required injections in year 1 were 9 to 10 and the number decreased to almost half in year 2.[10,12,13]

RCTs are considered gold standard for providing safety and efficacy of pharmaceutical agents. However due to the strict settings in clinical trials, data from RCTs may not provide representative information about the real-world situation. [2,10] These landmark clinical trials have featured frequent, typically 4 to 6 weekly follow

up visits with the number of injections ranging from 9 to 12 in the first year of treatment [8]. Patients in clinical practice are demographically and clinically more diverse than the clearly defined and carefully selected patient populations of randomized clinical trials. Furthermore, anti-VEGF utilization and patient follow-up patterns in the treatment of DME in clinical practice are far less intensive.[4,13,14]

Real-world evidence is defined as evidence derived from collection and analysis of real-world data elements[15]. Although real-world evidence has a lower ranking level of certainty in the hierarchy of evidence, it can complement findings from randomised controlled trials and have higher external validity since it represents day to day clinical practice. Real-world studies may reveal small but significant management effects in routine clinical practice by longer patient tracking, assessing a broader set of outcomes like safety, and quality of life follow up trends and long-term effectiveness[15].

This notion was demonstrated by Koc et al in a retrospective study comparing anatomical and visual effects of intravitreal ranibizumab, bevacizumab and triamcinolone for the treatment of diabetic macular edema in clinical practice. In all treatment groups there were similar visual improvements and reduction in central foveal thickness which were statistically significant[13]. However, compared to the results found in Protocol T, the mean number of injections was significantly lower and so were the visual outcomes in the ranibizumab and bevacizumab group[13].

A similar study was done in United States evaluating real-world visual outcomes of anti VEGF treatment in macular oedema. A sample of patients was collected from a

large database of medical records[16]. It consisted of patients from different geographic and demographic areas with DME who received monthly anti-VEGF injections for three months. In this study patients were also divided into three treatment groups according to the anti VEGF agents they were receiving (either aflibercept, bevacizumab or ranibizumab). The number of injections and VA outcomes were assessed and the results were significantly lower than in those noted in the randomized clinical trials[16]

Frequent intravitreal injections needed to achieve and maintain satisfactory clinical outcomes can be burdensome to patients and the healthcare system.[17] These factors have led to the development of new strategies and alternative methods for the treatment of DME.[17,18] Pro re nata (prn) or as needed, treat-and-extend and other regimens are adopted. Four weekly intravitreal injections only administered PRN were proven to have almost similar results as fixed four weekly dosing in patients pre-treated with ranibizumab loading dose. [19]

Brolucizumab is one of the new longer acting drugs developed. It is a humanized single-chain antibody fragment that binds to VEGF A with enhanced tissue penetration and rapid clearance from systemic circulation. It is the first anti VEGF to offer less frequent intravitreal injections. It has recently been approved for treatment of macula oedema secondary to nAMD in the US.[17,18,20] In the Hawk and Harrier study, a loading dose of brolucizumab consisting of monthly injections for three months was administered, followed by 12 weekly injections with the option of switching to 8 weekly dosing in case of recurrent disease activity.[20,21] The primary endpoint of non-inferiority compared to aflibercept given every eight weeks was

achieved. More than 50% of patients were maintained exclusively on a 12-week maintenance dose through week 48.[21] Currently there is a prospective randomized phase III clinical trial called the KITE and KESTREL study, evaluating the non-inferiority of brolucizumab to aflibercept and comparing functional, morphological and durability effects of the two drugs over a period of 2 years in treating diabetic macular edema.[22]

The other recent advance in DME management is sub-threshold micropulse laser. It works by selective photocoagulation of the outer layer of the retina, the retinal pigment epithelium[23]. This type of laser reduces thermal damage to the other layers of retina and the adjacent choroid. Thermal damage to the retinal pigment epithelium results in modification of gene expression leading activation of curative cellular cascades by the viable retinal epithelium cells surrounding the areas of thermal injury.[23] Contrary to standard threshold laser (eg focal/grid laser), sub-threshold micropulse laser produces minimal laser related side effects such as subretinal fibrosis, decreased colour and contrast sensitivity and paracentral scotomas.[23,24] Recent data suggests that subthreshold micropulse laser has similar and, in some instances, superior efficacy to standard laser with minimal retinal damage.[25]

Currently at Charlotte Maxeke Johannesburg academic hospital, diabetic macular edema patients with a visual acuity of 6/12 (0.3 logMAR) and less are treated with a loading dose consisting of monthly bevacizumab intravitreal injections for three months, followed by a monthly maintenance dose which is given until complete resolution occurs or until further response can no longer be obtained.[26] A study was conducted at this hospital evaluating visual and macular thickness outcomes

following treatment of diabetic macular edema with bevacizumab consisting of monthly injection for three consecutive months. Compared to the group that did not complete loading dose, positive results were observed in the loading group .[26]
South Africa is a developing country and patient demographics are vastly different to those stipulated in the major clinical trials. A tailor made and individualized management approach is required to these patients. In order to improve future clinical outcomes, it is crucial to understand the current state of management in clinical practice. It is against this background that I decided to study real-world outcomes of bevacizumab intravitreal injections in the treatment of DME in our setting. This study examined the trends of bevacizumab injections as well as visual and structural outcomes in this group.

Research question

What are the injection trends and changes in central foveal thickness and visual acuity in diabetic macular edema patients treated with bevacizumab for six months?

Aims and objectives

The aim of this study is to describe the short term real world treatment and clinical outcomes of DME at central Johannesburg hospital, The Charlotte Maxeke Johannesburg Academic Hospital (CMJAH). The primary objective is to describe the DME treatment patterns at 6 months following the index Bevacizumab intravitreal injection, as measured by the cumulative number and frequency of ophthalmology visits and intravitreal Avastin injections. The secondary objectives are to describe the DME clinical outcomes at 6 months following the index Bevacizumab intravitreal injection, as measured by the Snellen visual acuity chart and Central foveal

thickness measurements taken using the Zeiss Cirrus 5000 OCT (Carl Zeiss Meditec, Inc).

This is a retrospective case series, reviewing hospital records of patients treated for DME with intravitreal bevacizumab injections, who received their index injection between 01 September 2018 to 31 October 2019. For purposes of this study, an index injection was defined as the first injection in the study eye. In an eye which was treated with intravitreal injection before, an index injection was defined as the injection given 6 months following the last Bevacizumab injection.

Method and design

All patients who had a diagnosis of DME, and were treated with intravitreal Bevacizumab during the period 01 September 2018 to 31 October 2019 were identified from the CMJAH intravitreal injections database. This period was chosen because details of patients who were treated with intravitreal injections during this period were kept in the retinal clinic database, using the Redcap electronic platform hosted by the university of the Witwatersrand.

The inclusion criteria were: centre-involving DME in the study eye, study eye treated with intravitreal Bevacizumab injections for DME, receiving an index injection during the study period and available spectral domain OCT scans which were done prior to the index intravitreal bevacizumab injection and following treatment. Patients who had concomitant retinal disease in the study eye which could account for the loss of vision were excluded from the study.

Medical records of patients who met the study inclusion criteria were retrieved and analysed. The study received ethics clearance from the Ethics committee of the university of the Witwatersrand (HREC committee)

Data Analysis

All data were extracted from patients' hospital records and entered into a Widows Excel 2021 program for analysis. Data distribution was analysed by the Shapiro–Wilk test.

Descriptive statistics were used to analyse the data. Continuous variables such as age were reported as means with standard deviations. Categorical data such as gender was reported in percentages or ratios. For statistical analysis of visual acuity the Snellen visual acuity was converted to logMAR notations. To compare medians between the groups, a Mann-Whitney U test was used for both logMAR visual acuity and central foveal thickness. A p-value of less than 0.05 was considered significant.

Results

Baseline characteristics

A total of 127 records of patients treated for diabetic macula oedema from 1 September 2018 to 31 October 2019 were retrieved. Thirty-two eyes of 22 patients were included and 105 patients were excluded, reasons for their exclusion are summarized in figure 1.

Figure1. Number of eyes excluded.

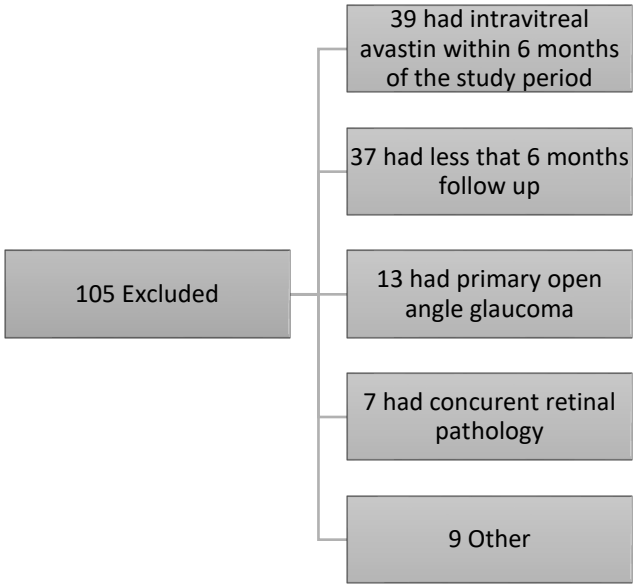

Each eye in the study was treated independently. Twelve patients had unilateral treatment and 10 had bilateral eye treatment (defined as patients that had an intravitreal injection in the fellow eye during the study period). The study sample was further categorized into those that completed the loading dose and those that did not complete the loading dose. Fourteen patients received the loading dose while 18 patients did not. Where there is no recorded sixth month visit after six months of follow-up, the first recorded visit after six months was included in the analysis. Patient demographics are summarized in Table 1.

Table 1. Baseline demographics

Variables	
Gender, n (%)	
Female	11 (50)
Male	11 (50)
Age	
Mean (SD)	63.5 (6.57)
Race, n (%)	
Black	11 (31.2)
White	6 (15.6)

Indian	2 (6.2)
Mixed race	2 (6.2)
Unspecified	4 (9.3)

N = number; SD = standard deviation

Visual acuity outcomes

A total of 136 injections were given in 32 eyes, 95 in the right eye and 69 in the left eye. Each study eye received an average of 4,3 injections during the study period. There were 18 (66%) eyes that received a loading dose, and 14 (33%) who did not receive a loading dose. The median l visual acuity (logMAR). VA in the baseline group that received a loading dose was 0.6 logMAR (IQR = 0.5-0.9) and 0.8 (IQR = 0.6-2.2) for the group that did not receive the loading dose, as indicated in Table 2.

Table 2 also shows that at baseline, the loading dose group had a median VA of 0.6 logMAR (IQR = 0.5 - 0.9) and the final median VA of 0.5 logMAR (IQR 0.3 - 0.8). The difference was 0.1 logMAR and this difference was not statistically significant, $p = 0.2$ (Mann-Whitney U test). The median baseline VA in the non-loading dose group was 0.8 logMAR (IQR = 0.6 - 2.2) and the final VA in the non- loading dose group was 0.7 logMAR (IQR = 0.2 - 1). The difference between the two groups was 0.1 logMAR. This difference was not statistically significant, $p = 0.152$ (Mann-Whitney U test).

Structural outcomes

Changes in central foveal thickness (CFT) from baseline to the sixth visit were also compared. Table 2 shows that the CFT the median in baseline loading dose group was 443 (IQR = 312µm – 514µm) and 362 (IQR = 314µm -394µm). The reduction of the CFT from baseline to the sixth visit was from 18%, and this difference was statistically significant, $p = 0.038$ (Mann-Whitney U test). The baseline median CFT in the group that did not receive the loading dose was 355 (IQR 300µm – 406µm) and at six months the CFT decreased to 332µm (IQR 291µm – 351µm). The reduction was 6% and this was not statistically significant, $p = 0.678$ (Mann-Whitney U test).

Table 2. Visual acuity and CFT outcomes in the loading dose group and the non-loading dose.

	Loading dose N = 18 (66%)			**Non loading dose N = 14 (33%)**		
	Median	**IQR**	**p-value**	**Median**	**IQR**	**p-value**
Visual acuity (logMAR)						
Baseline VA	0.6 logMAR	0.5 logMAR - 0.9 logMAR		0.8 logMAR	0.6 logMAR - 2.2 logMAR	
VA at 6 months	0.5 logMAR	0.3 logMAR - 0.8 logMAR		0.7 logMAR	0.2 logMAR - 1 logMAR	

VA change from baseline to 6 months	0.1 logMAR	0.2	0.1 logMAR		0.152
Central foveal thickness (µm)					
Baseline CFT	443µm	312µm - 514µm	355µm	300µm - 406µm	
CFT at 6 months	362µm	314µm - 394µm	332µm	291µm - 351µm	
CFT change from baseline to 6 months (%)	81µm (18%)	0.038	23µm (6%)		0.678

N = number; VA = visual acuity; IQR =interquartile range; logMAR = logarithm of the minimum angle of resolution; CFT = central foveal thickness; M = months; µm = microns

Table 3. Clinic visit patterns for unilateral and bilateral eye injections

	Unilateral eye injections		Bilateral eye injections	
	Clinic visits	**No of injections**	**Clinic Visits**	**No of injections**
Total no	73	57	91	80
Mean	6,1	4,7	9.1	5.2
SD	1,73	1,87	3.03	1.94

SD = standard deviation

Table 3 summarizes the clinic visits patterns. The total number of clinic visits in patients who received bilateral intravitreal injections was 91 with a mean of 9,1 (SD =

3,03), 40 visits for the right eye and 52 for the left. The total number of injections in this group was 80. In the unilateral eye injection group, there was a total of 73 clinic visits with a mean of 6.1 (SD = 1.73). There were 57 injections administered with a mean of 4.7 (SD = 1.87).

Discussion and conclusion

This study was a retrospective analysis of real-world vision outcomes of bevacizumab treated DME eyes at Charlotte Maxeke Johannesburg academic hospital. It offers some valuable insights into the current situation of diabetic macular edema management in a South African public hospital.

Major clinical trials have demonstrated that good visual acuity at baseline is associated with less incidents of persistent macular oedema[9]. The disruption of the external limiting membrane and the photoreceptor inner segment and outer segment junction are associated with unfavourable visual outcomes[9]. In Protocol T study conducted by the DCRC network, the baseline median visual acuity was 69 ETDRS letter (IQR = 73 - 79), an equivalent of approximately 0.3 logMAR[27]. Visual acuity improvement was defined as an increase of more than five (ETDRS) letters (equivalent of one line) from baseline[16]. At 6 months there was a total of 8 ETDRS letter improvement to 77 (IQR 82 - 68) ETDRS, approximately 0.2 logMAR.

Thomas et al. conducted a large US-based real-world study assessing the translatability of Protocol T to clinical practice. Baseline visual acuity of the bevacizumab group was 56.6 EDTRS (Early treatment diabetic retinopathy study). In their study the six-month cohort of patients that received bevacizumab had a mean visual acuity improvement of 6.4 ETDRS letters ($p < 0.001$). The visual acuity

outcomes and the number of injections were significantly less than recorded in RCTs[28].

In our real-world analysis the median VA at baseline was 0.6 (IQR 0.5 – 0.9) in the loading dose group and 0.8 logMAR (IQR 0.6 – 2.2) in the non-loading dose group. The VA improvement from baseline to the sixth month visit was the same in both groups, 0.1 logMAR (p =0.2) in the loading dose group and 0.1 logMAR (p=0.587) in the non-loading dose group.

The DRCR Protocol T also defined improvement as a decrease of more than 10% in CFT [16]. In our study CFT reduction in the loading dose group was 18% (p = 0.038) which was comparable to the 12-26% range described in literature[29]. The non-loading dose group showed a reduction of 6%. In literature failure to complete the loading dose has been associated with poorer outcomes[2,8,12].

With regard to clinic visits and number of injections our study showed that the mean number of clinic visits was 6,1 in the unilateral injection group and 9,1 in the bilateral injection group. Thirty-three percent of patients did not receive the loading doses routinely given during clinical trials[14,16]. Furthermore, the average number of injections was 4,9 in each eye during the study period which is less compared to fixed doses administered in major clinical trials. In a large real world study by Thomas et al the number of injections was also slightly less. The average number of intravitreal injections was 5.1 at six months.

Even though the number of clinic visits in our study was six in the unilateral group most scheduled intravitreal injections were cancelled due to uncontrolled hypertension and diabetes mellitus which emphasises the need for continuous counselling regarding hypertension and diabetic control[28].

This study had several limitations as it is retrospective with a small sample size and the selective six monthly follow-up requirement criteria may not represent real-world patients. There was a lack of background information such as the type and duration of diabetes, the presence of macular ischaemia, and other comorbidities that could have influenced vision outcomes. However, this study adds to the current literature and also encourages future studies with larger samples including patients with different demographic backgrounds in order to craft a better management plan for DME.

References

1. Virgili G, Parravano M, Evans J, et al. Anti-vascular endothelial growth factor for diabetic macular edema: a network meta-analysis. Cochrane Database Syst Rev. 2018;10(10)
2. Schmidt-Erfurth U, Garcia-Arumi J, Bandello F, et al. Guidelines for the management of diabetic macular edema by the European Society of Retina Specialists (EURETINA). Ophthalmologica. 2017;237(4):185-222

3. Relhan N, Flynn HW Jr. The Early Treatment Diabetic Retinopathy Study historical review and relevance to today's management of diabetic macular edema. Curr Opin Ophthalmol. 2017;28(3):205-212
4. Ehlken C, Helms M, Boehringer D, et al. Association of treatment adherence with real-life VA outcomes in AMD, DME, and BRVO patients. Clin ophthalmol. 2017;12:13-20.
5. Azmeh A. Ocular and systemic vascular adverse events following intravitreal Bevacizumab injection. J Ophthalmol & Vis Sci 2016;1(1):1004
6. Ruia S, Saxena S, Cheung CMG, et al. Spectral domain optical coherence tomography features and classification systems for diabetic macular edema: a review. Asia Pac J Ophthalmol 2016;5(5):360-367.
7. Fong DS, Luong TQ, Contreras R, et al. Treatment patterns and 2-year vision outcomes with bevacizumab in diabetic macular edema: an analysis from a large US integrated health care system. Retina. 2018;38(9):1830-1838
8. Wells JA, Glassman AR, Jampol LM, et al. Association of baseline visual acuity and retinal thickness with 1-year efficacy of aflibercept, bevacizumab, and ranibizumab for diabetic macular edema. JAMA Ophthalmol 2016;134(2):127-134.
9. Sivaprasad S, Crosby-Nwaobi R, Heng LZ, et al. Injection frequency and response to bevacizumab monotherapy for diabetic macular edema (BOLT Report 5). Br J Ophthalmol 2013;97(9):1177-1180
10. Cai S, Bressler NM. Aflibercept, bevacizumab or ranibizumab for diabetic macular edema: recent clinically relevant findings from DRCR. net Protocol T. Curr Opin Ophthalmol. 2017;28(6):636-643

11. Massin P, Bandello F, Garweg JG, et al. Safety and Efficacy of Ranibizumab in Diabetic Macular Edema (RESOLVE Study): a 12-month, randomized, controlled, double-masked, multicenter phase II study. Diabetes Care. 2010;33(11):2399-2405.

12. Holekamp NM, Campbell J, Almony A, et al. Vision outcomes following anti–vascular endothelial growth factor treatment of diabetic macular edema in clinical practice. Am J Ophthalmol 2018;191(8):83-91.

13. Koç İ, Kadayıfçılar S, Eldem B. Real-world results of intravitreal ranibizumab, bevacizumab, or triamcinolone for diabetic macular edema. Ophthalmologica 2018;239(2-3):85-93.

14. Busch C, Fraser-Bell S, Zur D et al. Real-world outcomes of observation and treatment in diabetic macular edema with very good visual acuity: the OBTAIN study. Acta Diabetol 2019;56(7):777-84.

15. Mehta H, Tufail A, Daien V et al. Real-world outcomes in patients with neovascular age-related macular degeneration treated with intravitreal vascular endothelial growth factor inhibitors. Prog Retin Eye Res 2018;65(7):127–146.

16. Ciulla TA, Bracha P, Pollak J et al. Real-world outcomes of anti-vascular endothelial growth factor therapy for macular edema in the United States. Ophthalmol Retina 2018;2(12):1179-1187.

17. Hussain R, Ciulla T. Addressing the Anti-VEGF Treatment Burden. Review Ophthalmology.2018.Available from https://www.reviewofothalmology.com/article/addressing-theantivegf-treatment-burden

18. Sacconi R, Giuffrè C, Corbelli E et al. Emerging therapies in the management of macular edema: a review. F1000Res 2019;8:F1000 Faculty Rev-1413.

19. Boyer DS, Nguyen QD, Brown DM, et al. Outcomes with as-needed ranibizumab after initial monthly therapy: long-term outcomes of the phase III RIDE and RISE trials. Ophthalmology 2015;122(12):2504-2513.
20. Sharma A, Parachuri N, Kumar N, et al. Brolucizumab-key learnings from HAWK and HARRIER.Ophthalmology2019;126(12):95-96.
21. Dugel PU, Koh A, Ogura Y, et al. HAWK and HARRIER: phase 3, multicenter, randomized, double-masked trials of brolucizumab for neovascular age-related macular degeneration. Ophthalmology 2020;127(1):72–84.
22. Garweg JG. A randomized, double-masked, multicenter, phase III study assessing the efficacy and safety of brolucizumab versus aflibercept in patients with visual impairment due to diabetic macular edema (KITE). Klin Monbl Augenheilkd. 2020;237(4) :450-453
23. Latalska M, Prokopiuk A, Wróbel-Dudzińska D et al. Subthreshold micropulse yellow 577 nm laser therapy of diabetic macular edema in rural and urban patients of south-eastern Poland. Ann of Agric Environ Med 2017; 24(1):96–99.
24. Scholz P, Altay L, Fauser S. A review of subthreshold micropulse laser for treatment of macular disorders. Adv Ther 2017;34(7):1528–1555.
25. Lois N, Gardner E, Waugh N et al. Diabetic macular edema and diode subthreshold micropulse laser (DIAMONDS): study protocol for a randomised controlled trial. Trials 2019;20(1):122
26. Hasrod I. (2018) The outcome of bevacizumab treatment for diabetic macular edema at the Charlotte Maxeke Johannesburg Academic Hospital. Available from https://hdl.handle.net/10539/26937.

27. Bressler N, Beaulieu T, Glassman R et al. Persistent macula oedema thickening following intravitreous aflibercept, bevacizumab or ranibizumab for central involving diabetic macula oedema with vision impairment: A secondary analysis of a randomised clinical trial. Jama opthalmol. 2018;136(5):257-269
28. Ciulla T, Pollack J, Williams D. Visual acuity outcomes and anti-VEGF therapy intensity in diabetic macular edema: a real-world analysis of 28 658 patient eyes. *Br* J Ophthalmol. 2021;105(2):216 - 221.
29. Salimi A, Vila N, Modabber M et al. One-year outcomes of Aflibercept for refractory diabetic macular edema in Bevacizumab nonresponders. Indian J Ophthalmol. 2021; 69(2):360 -3 67.