

https://dspace.org/

The in vitro and in vivo effects of Bulbine frutescens and Bulbine natalensis on cutaneous wound healing

Pather, Nalini

2010-01-27T13:28:12Z
http://hdl.handle.net/10539/7481

Downloaded from a DSpace repository. https://dspace.org/

The *in vitro* and *in vivo* effects of *Bulbine frutescens* and *Bulbine natalensis* on cutaneous wound healing

WitsETD

Nalini Pather

This thesis is submitted to the
Faculty of Health Sciences of the University of the Witwatersrand, Johannesburg
in fulfilment for the requirement of the degree
Doctor of Philosophy

2009

created with nitroPDF professional
download the free trial online at nitropdf.com/professional

This thesis is dedicated to my family

for their unconditional love, motivation and support.

WitsETD

"For YOU created my inmost being; you knit me together in my mother's womb. I praise you because I am fearfully and wonderfully made; your works are wonderful I know that full well."

Psalm 139: 13-14

created with nitroPDF professional
download the free trial online at nitropdf.com/professional

ACKNOWLEDGEMENTS

I would like to express my sincere gratitude to:

- **Professor Beverley Kramer**, my advisor for giving all of herself in soundly guiding and mentoring me over the past few years and for the support in completing this thesis.
- **Professor Alvaro Viljoen,** my co-advisor for his patience and advice during this project.
- **National Research Foundation Thuthuka Programme** for providing the financial support for this project.
- **Monica Gomes,** for your friendship and for wading through the maze of biochemical and immunohistochemical assays with me in the last hurdle of experiments.
- the Dean, **Professor Helen Laburn,** for supporting a timeous Faculty 'time- off' grant
- **Glynis Veale,** for your friendship and assistance with the grant management.
- the histology technicians of the School of Anatomical Sciences – **Sherrie Rogers, Hasiena Ali, Therese Dix-Peek** and **Alison Mortimer**, for your willingness to assist me always.
- **Jill Dickenson** for helping me gain confidence in the cell culture techniques.
- colleagues in the School of Therapeutic Sciences, **Dr Robyn Van Zyl** and **Dr Sandy Van Vuuren**, for your invaluable assistance with the MTT and antimicrobial assays – I am indebted to you both for your eagerness in assisting me.
- **Dr Norbert E Fusenig** of the German Cancer Research Center (DKFZ) for donating the HaCaT cell line.
- **Drs Kennedy Erlwanger** and **Leith Meyer**, for your veterinary assistance in the animal biopsies; and the **technicians at the Animal Unit of the Faculty of Health Sciences**, for your eagerness to assist, even over weekends, with the pigs.
- **Professor Viness Pillay**, School of Therapeutic Sciences, for the hire of the tensiometer.
- **Fellow colleagues of the School of Anatomical Sciences and especially the EDDRP postgraduate students**, for your support and friendship during this project.
- **Rev. Les Hammond** for inspiring me through your lifetime of continued learning and developing; and for always being a great source of encouragement in my life.
- **Dave and Radha,** my parents for believing that I could do anything I put my mind to.
- **Glen,** my husband and friend, for the myriad of ways you support me in my determination to make a contribution to our world.
- **Rayuel** and **Jehiel,** for being the sunshine of my life and accepting the many times when you had to be 'without mum'.

WiseTD

created with nitroPDF professional
download the free trial online at nitropdf.com/professional

ABSTRACT

In recent years, there has been a growing interest in natural and traditional medicines for the treatment of wounds. Attempts to find agents that promote wound-healing and that are affordable, effective and non-toxic have a long history. In South Africa, hundreds of different indigenous plants are used to treat wounds and burns. The merits of relatively few of these have been scientifically evaluated. *Bulbine natalensis* and *Bulbine frutescens* of the Asphodelaceae family are indigenous to southern Africa and are widely used as a skin remedy. This study aimed to investigate the *in vitro* and *in vivo* effect of *Bulbine natalensis* and *Bulbine frutescens* on cutaneous wound healing.

In vitro cell culture study: *In vitro* studies were carried out on dermal fibroblasts and human keratinocytes cultured under standard conditions using Iscove's Modified Eagles Medium (MEM) and Dulbecco's MEM respectively. Confluent cultures of both cell lines were treated with varying concentrations of the leaf extracts of *B. frutescens* and *B. natalensis*. These cultures were subjected to the MTT, WST-1 and BrdU assays to determine the cytotoxicity and proliferation effect of the extracts. In addition, migration of cells across a score was analysed over a 48 hour period. ***In vivo animal study:*** Excisional and incisional wounds were created on the back of 12 domestic pigs. Mirror imaged wounds were created as control wounds. The excisional wounds were biopsied at days 2, 4, 7, 10 and 16 and the incisional wounds were biopsied at day 16. The rate of closure of the wounds was also recorded. Each excisional wound was analyzed for its biochemical composition by estimating the total amount of protein, DNA, collagen and hexosamine that was present in the wound tissue. The wound healing process was documented histologically (using haematoxylin and eosin and a Mallory's trichrome stain) and immunohistochemically (using anti- α smooth muscle actin, vascular endothelial growth factor

WitsETD

created with nitroPDF professional
download the free trial online at nitropdf.com/professional

and transforming growth factor β receptors I and II). The incisional wounds were used to test tensile strength of the healed wounds using a tensiometer.

In the *in vitro* studies, neither extract caused cytotoxicity to either the fibroblast or keratinocyte cells. Cell proliferation was greater than 100% at 0.1-5 and 100-300 µg/ml for *Bulbine natalensis* and at 0.1µg/ml for *Bulbine frutescens*. There was no significant difference in the effects of the two leaf extracts on cell proliferation. The biochemical analysis of the wound tissue showed a significant increase in the collagen, protein and total DNA content of both *B frutescens* and *natalensis* treated wounds when compared to the untreated wounds. There was no significant difference in the hexosamine content of both *B. frutescens*- and *B. natalensis*-treated and untreated wounds. Analysis of the wound tissue displayed an increase rate of closure of the wound tissue treated with *B. frutescens* and *B. natalensis* when compared to the untreated wounds. Full re-epithelialisation of both treated wounds occurred earlier than in the untreated wounds.

These findings have important implications for the use of these extracts to treat wound healing.

WitsETD

created with nitroPDF professional
download the free trial online at nitropdf.com/professional

LIST OF TABLES

Table No. ***Page No.***

1.1 Bulbine species used in traditional medicine 3

1.2: Cytokines in wound healing (adapted from Singer and Clark, 1999) 13

3.1: Summary of collagen concentration (mg/100ml) per day of treatment 76

3.2: Summary of collagen concentration (mg/100ml) per day of treatment 77

3.3: Hexosamine concentration (mg/100ml) per day of treatment 80

3.4: Hexosamine concentration (mg/100ml) per day of treatment 81

3.5: Summary of protein concentration (mg/100ml) per day of treatment 83

3.6: Summary of protein concentration (mg/100ml) per day of treatment 84

3.7: Summary of collagen:DNA content 87

3.8: Summary of wound healing features from histological sections 89

3.9: Mean maximal distance between wound edges (mm) and percent closed from day 0 89

3.10: Summary of the results of the present study 167

WitsETD

created with nitroPDF professional
download the free trial online at nitropdf.com/professional

LIST OF FIGURES

Figure No. ***Page No.***

1.1: ***A.*** *B. natalensis with broad, fleshy leaves;* ***B.*** *B. natalensis inflorescens;* ***C.*** *B. frutescens with long fleshy leaves and* ***D.*** *B. frutescens inflorescens* *3*

1.2: *A- Histological structure of thin skin from scalp (x5); B- epidermis (x100)* *6*

1.3: *The process of re-epithelialisation (modified from Parks, 1999)* *10*

1.4: *Stages of wound healing (Kloth and McCulloch, 2002)* *11*

1.5: *Inflammatory phase - A cutaneous wound three days after injury* *14*

1.6: *A cutaneous wound five days after injury* *16*

1.7: *Transforming growth factor β receptors (TGF-βR)* *24*

1.8: *Histological features of pig skin and human skin* *27*

2.1: *Flow diagram of tissue culture experiments* *36*

2.2: *Flow diagram of animal experiments* *43*

2.3: *Representative photographs of a: wounds created on dorsal surface of a pig; b-d: tissue being harvested* *44*

2.4: *Photograph of a day 16 incisional wound skin sample mounted on the TA. XT. plus Texture Analyser® system* *47*

2.5: *Representative graph of the standard curve obtained for estimation of collagen concentration from the hydroxyproline standard (1mg/100ml)* *49*

3.1: *MTT Assay – effect of B. frutescens and B. natalensis on keratinocytes* *65*

3.2: *MTT Assay – effect of B. frutescens and B. natalensis on dermal fibroblasts* *65*

3.3: *WST-1 Assay – effect of B. frutescens and B. natalensis on dermal fibroblasts* *67*

3.4: *WST-1 Assay – effect of B. frutescens and B. natalensis on HaCaT* *67*

3.5: *BrdU Assay – effect of B. frutescens and B. natalensis on keratinocytes* *69*

3.6: *BrdU Assay – effect of B. frutescens and B. natalensis on fibroblasts* *69*

3.7: *Representative photomicrograph of a HaCaT score assay* *71*

3.8: *Representative photomicrograph of a fibroblast score assay* *71*

3.9: *Percent of contraction for B. natalensis, B. frutescens-treated and untreated wounds.* *73*

3.10: *Tensile strength of incisional wounds at day 16* *74*

WitsETD

created with nitroPDF professional
download the free trial online at nitropdf.com/professional

3.11: Collagen content of B. natalensis-treated and untreated wounds. 76

3.12: Collagen content of B. frutescens-treated and untreated wounds. 77

3.13: Hexosamine content of B. natalensis-treated and untreated wounds. 80

3.14: Hexosamine content of B. natalensis-treated and untreated wounds 81

3.15: Protein content of B. natalensis-treated and untreated wounds 83

3.16: Protein content of B. natalensis-treated and untreated wounds 84

3.17: DNA content of B. natalensis-treated and untreated wounds 86

3.18: DNA content of B. frutescens-treated and untreated wounds 86

3.19: Wound healing in untreated tissue on day 2 post-wound creation 93

3.20: Representative histological section of day 2 untreated wound showing granulation tissue 94

3.21: Representative histological section of an untreated wound on day 2 post-wounding 95

3.22: Wound healing of B. natalensis- treated tissue on day 2 post-wound creation 96

3.23: Granulation tissue of a B. natalensis- treated wound on day 2 post-wounding 97

3.24: Representative histological section on day 2 post- wounding B. natalensis- treated wound showing the migrating tongue 98

3.25: Wound healing of B. frutescens-treated tissue on day 2 post-wound creation 99

3.26: Granulation tissue of a B. frutescens- treated wound on day 2 post-wounding 100

3.27: Representative histological section of untreated wound on day 2 post-wounding 101

3.28: Representative histological section of B. natalensis-treated wound on day 2 post-wounding 102

3.29: Representative histological section of day 2 B. frutescens-treated wound 103

3.30: Wound healing of untreated tissue on day 4 post-wound creation 105

3.31: Wound healing of B. natalensis-treated tissue on day 4 post-wound creation 106

3.32: Wound healing of B. frutescens-treated tissue on day 4 post-wound creation 107

3.33: Wound healing of B. frutescens-treated tissue on day 4 post-wound creation 108

3.34: Representative histological section of granulation tissue of untreated tissue on day 4 post-wound creation 110

WiseTD

created with nitroPDF professional
download the free trial online at nitropdf.com/professional

3.35: *Representative histological section of granulation tissue of B. natalensis-treated tissue on day 4 post-wound creation* 111

3.36: *Representative histological section of granulation tissue of B. frutescens-treated tissue on day 4 post-wound creation* 112

3.37: *Representative histological sections of day 4 to day 16 post-wound creation* 113

3.38: *Wound healing of B. natalensis-treated tissue on day 4 post-wound creation* 114

3.39: *Wound healing of untreated tissue on day 7 post-wound creation* 116

3.40: *Wound healing of B. natalensis-treated tissue on day 7 post-wounding* 117

3.41: *Wound healing of B. frutescens-treated tissue on day 7 post-wound creation* 118

3.42: *Representative histological section of granulation tissue on day 7 post-wounding* 120

3.43: *Wound healing of untreated tissue on day 10 post-wound creation* 122

3.44: *Wound healing of B. natalensis-treated tissue on day 10 post-wound creation* 123

3.45: *Wound healing of B. frutescens-treated tissue on day 10 post-wound creation* 124

3.46: *Wound healing of B. frutescens-treated tissue on day 10 post-wound creation* 125

3.47: *Representative histological sections of A-normal unwounded dermis; B- Granulation tissue of untreated wound on day 10 post-wound creation; C- Granulation tissue of B. natalensis- treated wound on day 10 post-wound creation tissue; D- Granulation tissue of B. frutescens-treated wound on day 10 post-wound creation* 127

3.48: *Wound healing in untreated tissue on day 16 post-wound creation* 129

3.49: *Wound healing of a B. natalensis-treated tissue day 16 post-wound creation* 130

3.50: *Wound healing of B. frutescens-treated tissue on day 16 post-wound creation* 131

3.51: *Granulation tissue on day 16 post-wound creation* 133

3.52: *Representative histological sections of αSMA control tissue* 135

3.53: *Representative sections of αSMA localisation in wounds on day 2* 137

3.54: *Representative sections of αSMA localisation in untreated wounds and B. natalensis- and B. frutescens-treated wounds from day 2 to day 16 post-wound creation* 138

3.55: *Representative sections of αSMA localisation in day 4 wounds* 140

3.56: *Representative sections of αSMA localisation in day 7 wounds with insets demonstrating the area adjacent to the granulation tissue* 141

3.57: *Representative sections of αSMA localisation in day 10 wounds with insets demonstrating the area adjacent to the granulation tissue* 143

WiseETD

created with nitroPDF professional
download the free trial online at nitropdf.com/professional

3.58: Representative sections of αSMA localisation in day 16 wounds with insets demonstrating the area adjacent to the granulation tissue 144

3.59: Representative sections of VEGF controls 146

3.60: Representative sections of VEGF localisation in day 2 wounds 148

3.61: Representative sections of VEGF localisation in day 4 wounds 150

3.62: Representative sections of VEGF localisation on day 7 wounds 152

3.63: Representative sections of VEGF localisation in the neo-epidermis on day 16 post-wound creation 153

3.64: Representative sections of TGFβR$_I$ localisation in mouse ovarian tissue 155

3.65: Representative sections of TGFβR$_I$ localisation in day 2 wound tissue 156

3.66: Representative sections of TGFβR$_I$ localisation in day 4 wound tissue 158

3.67: Representative sections of TGFβR$_{II}$ localisation on day 4 wound tissue 159

3.68: Representative sections of TGFβR$_I$ localisation in day 7 wound tissue 160

3.69: Representative sections of TGFβR$_{II}$ localisation in day 7 wound tissue 161

3.70: Representative sections of TGFβR$_I$ localisation in day 10 wound tissue 162

3.71: Representative sections of TGFβR$_{II}$ localisation in day 10 wound tissue 163

3.72: Representative sections of TGFβR$_I$ localisation in day 16 wound tissue 164

3.73: Representative sections of TGFβR$_{II}$ localisation on day 16 wound tissue 165

WiSETD

created with nitroPDF professional
download the free trial online at nitropdf.com/professional

LIST OF ABBREVIATIONS

ATCC®	*American Type Culture Collection®*
B.	*Bulbine*
BrdU	*Bromodeoxyuridine*
BSA	*Bovine serum albumin*
DAB	*Diaminobenzidine*
DMEM	*Dulbecco's modified Eagles Medium*
DMSO	*Dimethyl sulfoxide*
ECM	*Extracellular matrix*
H&E	*Haemotoxylin and eosin*
IMEM	*Iscove's modified Eagles Medium*
INT	*Iodonitrotetrazolium violet*
MTT	*3-(4,5-dimethylthiazol-2-yl)-2,5-diphenyltetrazolium bromide*
PBS	*Phosphate buffered saline*
TBS	*Tris Buffered Saline*
TGFβ	*Transforming growth factorβ*
TGFβRI	*Transforming growth factorβ receptor I*
TGFβRII	*Transforming growth factorβ receptor II*
VEGF	*Vascular endothelial growth factor*
VEGFR	*Vascular endothelial growth factor receptor*

WitsETD

created with nitroPDF professional
download the free trial online at nitropdf.com/professional

TABLE OF CONTENTS

Page No.

DEDICATION ..... *ii*

ACKNOWLEDGEMENTS ..... *iii*

ABSTRACT ..... *iv*

LIST OF TABLES ..... *vi*

LIST OF FIGURES ..... *vii*

LIST OF ABBREVIATIONS ..... *xi*

CHAPTERS

I. INTRODUCTION 1

1.1 *Bulbine* 2

1.2 Cutaneous (skin) wound healing 5

1.3 Vascular endothelial growth factor (VEGF) in wound healing 20

1.4 Myofibroblasts in wound healing 21

1.5 Transforming growth factor β (TGF β) in wound healing 23

1.6 Animal models in wound healing 25

1.7 Wound creation 29

Aims 31

II. MATERIALS AND METHODS 33

2.1 Preparation of *Bulbine* gels 33

WitsETD

created with nitroPDF professional
download the free trial online at nitropdf.com/professional

2.2 Part 1 : An *in vitro* study of the effects of *B. natalensis* and *B. frutescens* on human epidermal keratinocytes and dermal fibroblasts 35

2.3 Part 2: An *in vivo* animal study of the effects of *B. natalensis*- and *B. frutescens*-treated wounds compared to untreated wounds in pig skin 41

2.3.1 Experimental animals 41

2.3.2 Analysis of wound biopsies 45

2.3.2.1 Rate of contraction and period of re-epithelialisation 45

2.3.2.2 Measurement of tensile strength 46

2.3.2.4 Biochemical analyses of excisional wounds 48

2.3.2.4 Histological analyses of excisional wounds 54

2.3.2.5 Immunohistochemical analyses of excisional wounds 56

2.4 Part 3: An *in vivo* human study of the effects of *B. natalensis*- and *B. frutescens*-treated wounds compared to untreated wounds 61

2.5 Statistical analyses 62

III. RESULTS 63

3.1 An *in vitro* study of the effects of *B. natalensis* and *B. frutescens* on human epidermal keratinocytes and dermal fibroblasts 63

3.2 An *in vivo* animal study of the effects of *B. natalensis*- and *B. frutescens*-treated wounds compared to untreated wounds in pig skin 72

3.2.2.1 Rate of contracture and period of re-epithelialisation 72

3.2.2.2 Measurement of tensile strength 74

WitsETD

created with nitroPDF professional
download the free trial online at nitropdf.com/professional

3.2.2.3 Biochemical analyses of the excisional wounds treated with *B. natalensis* and *B. frutescens* compared to the untreated wounds 75

3.2.2.4 Histological analyses of the excisional wounds treated with *B. natalensis* and *B. frutescens* compared to the untreated wounds 88

3.2.2.5 Immunohistological analyses of the excisional wounds treated with *B. natalensis* and *B. frutescens* compared to the untreated wounds. .134

3.3 An *in vivo* human study of the effects of *B. natalensis*- and *B. frutescens*-treated wounds compared to untreated wounds in skin 166

3.4 An overall summary of the results of the present study 167

IV. DISCUSSION 173

V. CONCLUSION 202

VI. REFERENCES 203

VII. APPENDICES 223

WitsETD

created with nitroPDF professional
download the free trial online at nitropdf.com/professional

1. INTRODUCTION

The use of traditional medicines is firmly entrenched in the cultural practices of developing countries (Makunga *et al.,* 2008). Globally however, and especially in developed countries, there has been a 'cultural renaissance' towards natural methods of healing (Makunga *et al.,* 2008). In the United States alone, 62% of the population use complementary and alternative medicines contributing annually to a US$20 billion industry (Makunga *et al.,* 2008). The World Health Organisation (WHO) estimated that about 80% of the world's population still rely on plant based medicines for their primary health care needs (WHO, 2002). Medicines derived from such plants as *Cinchona succirubra* and *Cinchona ledgeriana* (for quinine; an anti-malarial), *Papaver somniferum* (for codeine and morphine; both analgesics) and *Digitalis purpurea* or *Digitalis lanata* (for digoxin; a cardiac glycoside) are widely used (Rates, 2000). More recently, newer drugs such as taxol (from the yew tree, *Taxus brevifolia*) have been developed for use in cancer therapy (Murphy *et al*., 1993; Harvey, 2001; Teicher, 2008).

There has been a growing interest in natural and traditional medicines for wound healing, driven largely by the extremely high financial burden of the treatment of wounds (Tonnesen *et al.,* 2000). Tonnesen *et al.* (2000) estimated that in the United States alone, there are at least a total of 2.5 million acute wounds per annum, arising from burns. The ideal therapy for wound healing should be affordable, effective and non-toxic. Prevention of infection and the associated discomfort of wound healing

WitsETD

created with nitroPDF professional
download the free trial online at nitropdf.com/professional

are also of major importance in the search for agents that expedite healing (Shukla *et al.,* 1999).

Approximately one-third of all traditional medicines are used for the treatment of wounds or skin disorders, compared to only 1-3% of modern drugs (Mantle *et al.,* 2001). The use of such medicinal plant extracts has arguably been based largely on historical or anecdotal evidence, since there is relatively little scientific data supporting these claims. Similarly in South Africa, while hundreds of different plants are used by traditional healers to treat wounds and burns, the merits of relatively few of these have been scientifically evaluated. One plant, indigenous to southern Africa and widely used as a skin remedy by people of both African and European decent is *Bulbine* of the Asphodelaceae family (Van Wyk and Gericke, 2000).

WitsETD

1.1 *Bulbine*

According to Hutchings *et al.* (1996) and Van Wyk *et al.* (2002), the *Bulbine* species used in South Africa for its (skin) wound healing properties are *Bulbine asphodeloides (B. asphodeloides)*, *Bulbine frutescens (B. frutescens)* and *Bulbine natalensis (B. natalensis)* (Table 1.1).

created with nitroPDF professional
download the free trial online at nitropdf.com/professional

Table 1.1 Bulbine species used in traditional medicine		
Genus	**Synonyms**	**Common/Vernacular Names**
B. asphodeloides		'copaiva', 'geelkatstert', 'kopieva', 'wildekopieva', 'ibhucu', 'intelezi', 'mmele'
B. frutescens	*B. caulescens* *B. rostrata*	burn jelly plant, cat's tail, 'balsemkopiva', 'rankkopieva', yellow & orange garlic, 'ingelwane', 'ibhucu', 'ithethe elimpofu'
B. natalensis	*B. latifolia* *B. brunsvigiaefolia*	'rooiwortel', 'ibhucu' , 'ibucu'

This study focuses on the effect of two of these *Bulbine* species on wound healing: *B. natalensis* and *B. frutescens* (Fig. 1.1) as *B. asphodeloides* is less commonly used for wound healing in South Africa.



Figure 1.1: ***A.*** *B. natalensis with broad, fleshy leaves;* ***B.*** *B. natalensis inflorescens;* ***C.*** *B. frutescens with long fleshy leaves and* ***D.*** *B. frutescens inflorescens*

created with nitroPDF professional
download the free trial online at nitropdf.com/professional

B. natalensis is a perennial with broad pointed fleshy leaves (Fig. 1.1). It has long, thin flowering stems with clusters of star-shaped yellow flowers. This plant is indigenous to southern Africa particularly South Africa, Malawi, Zimababwe and Mozambique. In South Africa, it favours the provinces of Kwa-Zulu Natal and Eastern Cape. *B. frutescens* is a geophytic shrublet with numerous long, bright green leaves. It grows in dense short masses with yellow or orange flowers (Fig. 1.1). It is found throughout South Africa, preferring dry areas like the Northern, Western and Eastern Cape (Joffe, 1993; Dyson, 1998). The leaves of both the plants are filled with a clear gel similar in appearance and consistency to the gel from the leaves of *Aloe vera*.

The gel of both these *Bulbine* species is commonly used by traditional healers and the local population for the treatment of wounds, burns, rashes, itches, ringworm, cracked lips and herpes, and is applied directly to the skin or used in the form of a warm poultice (Hutchings *et al.,* 1996).

WITSETD

Although the stem and root of *Bulbine* are known to contain anthraquinones such as chrysophanol (which has anti-bacterial properties) and knipholone (Van Staden and Drewes, 1994; Van Wyk *et al.,* 1995), these are thought to be of minor importance in wound healing. Rabe and Van Staden (1997) tested the antimicrobial activity of water and methanol extracts of the leaf sap of *B. frutescens* on cultures of *Staphylococcus aureus, Staphylococcus epidermis, Bascillus subtilis, Escherichia coli* and *Klebsiella pneumoniae.* They concluded that there was no antimicrobial activity attributed to the extracts of *B. frutescens*. Abegaz *et al.* (2002) however found that several phenylanthraquinones isolated from *B. frutescens* displayed antiparasitic

created with nitroPDF professional
download the free trial online at nitropdf.com/professional

activity when tested against *Plasmodium falciparum*, *Trypanosoma cruzi* and *Trypanosoma brucei rhodesiense.*

It is not known which component of the *Bulbine* plant is effective in wound healing. Van Wyk *et al.* (2002) speculated that since *Bulbine* belongs to the same family as *Aloe vera,* its healing effect is more likely to be due to glycoproteins (such as aloctin A and aloctin B) which have been found in the leaf gel of *Aloe vera,* a plant internationally recognised for its healing properties. These glycoproteins have not yet been identified in *Bulbine,* nor have their effects been scientifically evaluated.

WitsETD

1.2 Cutaneous (skin) wound-healing

Skin is composed of three layers: an epidermis, dermis and variable hypodermis. The epidermis is the surface layer in contact with the environment (Fig. 1.2). It consists of stratified squamous keratinised epithelium. The predominant cell type in the epidermis is the keratinocyte. Other cells found in the epidermis include melanocytes, Langerhans cells and Merkel's cells. The epidermis consists of several layers that reflect the stages in the process of keratinocyte maturation or keratinisation. In thick skin, these layers are, from the basement membrane to the exterior, the stratum basale, the stratum spinosum, the stratum granulosum, the stratum lucidum and the stratum corneum (Fig. 1.2). In thin skin, the stratum lucidum is absent (Junquiera and Carneiro, 2005; Ross and Pawlina, 2005).

created with nitroPDF professional
download the free trial online at nitropdf.com/professional

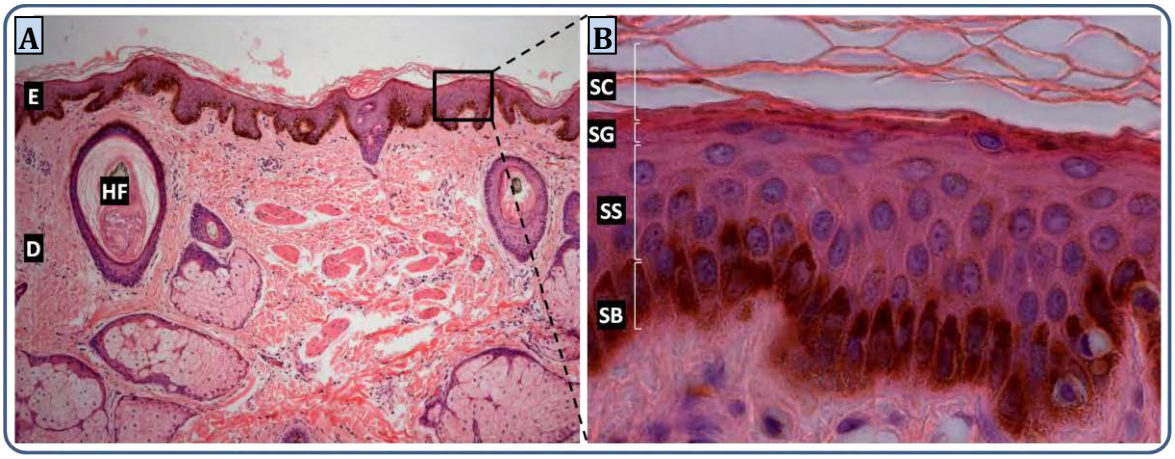

Figure 1.2: Histological structure of thin skin from scalp.
A. epidermis and dermis(x5); B. epidermis (x100)
***E**- epidermis; **HF**- hair follicle; **D**- dermis; **SC**- stratum corneum; **SG**- stratum granulosum; **SS**- stratum spinosum; **SB**-stratum basale.*
(Histology Collection of the School of Anatomical Sciences, University of the Witwatersrand)

WiSETD

The ***stratum basale*** is the deepest layer of the epidermis (Fig. 1.2). The keratinocytes in this layer are small, cuboidal in shape and are attached to the basement membrane. A variable amount of melanin is present in the cytoplasm of these cells which are transferred from the neighbouring melanocytes interspersed in this layer. These keratinocytes in the basal layer are regarded as stem cells of the skin and can undergo mitosis (Marks and Miller, 2006). The formation of new keratinocytes in this layer gradually pushes previously formed cells into the next layer, the s***tratum spinosum***. The keratinocytes in this layer are polygonal in shape and, following fixation, remain in contact with each other by a system of intercellular bridges formed from small cytoplasmic projections on the cell surface. The cytoplasm of the cells in this layer contain many tonofilaments (intermediate filaments) which are particularly concentrated in the cytoplasmic projections leading into the desmosomes and are more numerous in the layers closer to the stratum

created with nitroPDF professional
download the free trial online at nitropdf.com/professional

granulosum, the next layer of the epidermis (Junquiera and Carneiro, 2005; Ross and Pawlina, 2005). As keratinocytes approach the surface of the epidermis, they accumulate intermediate filaments and secrete a waxy material into the intercellular space; these changes are visible in the ***stratum granulosum***. In thick skin, the stratum granulosum consists of a few layers of flattened cells while in thin skin, a single layer may be visible. The cytoplasm of the keratinocytes in the stratum granulosum contains numerous, keratohyalin granules. The keratohyalin granules form "free" accumulations in the cytoplasm of the cells. Together, the intermediate filaments and the contents of the keratohyalin granules form the fibrous protein, keratin. In addition, the cells of the stratum granulosum contain membrane-bound granules which contain a mixture of lipids. The keratinocytes of this layer release the contents of these granules into the intracellular spaces. The lipids fill the entire interstitial space, which is important for the epidermis to function as a barrier to the external environment (Junquiera and Carneiro, 2005; Ross and Pawlina, 2005). The next layer of the epidermis is the ***stratum lucidum***, which consists of several layers of flattened dead cells. The nuclei of the keratinocytes begin to degenerate in the more superficial layers of the stratum granulosum. In the stratum lucidum, faint nuclear outlines are visible in only a few of the cells. In human thin skin, the stratum lucidum is absent. As maturing keratinocytes seal off the intercellular spaces through which they receive nutrients, they eventually die and form the ***stratum corneum***, a tough and relatively impermeable layer of hardened, dead cells. In the *stratum corneum*, cells are completely filled with keratin filaments. Individual cells are difficult to observe because nuclei can no longer be identified, the cells are very flat and the space between the cells has been filled with lipids, which cement the cells

WitsETD

created with nitroPDF professional
download the free trial online at nitropdf.com/professional

together into a continuous membrane. Closest to the surface of the epidermis, the stratum corneum has a somewhat looser appearance. Eventually, as cells reach the surface, they are sloughed off (Junquiera and Carneiro, 2005; Ross and Pawlina, 2005). In human skin, the entire epidermis above the basal layer is replenished within about two to four weeks. Replacement is accelerated by injury.

The epidermis forms an uneven boundary with the dermis characterized by fingerlike connective tissue protrusions of the dermis, called dermal papillae, into the epidermis. This is complimented by similar epidermal protrusions called epidermal ridges or rete ridges (Fig. 1.2A). The dermis is generally described as having two distinct layers: the papillary layer and the reticular layer (Junquiera and Carneiro, 2005; Ross and Pawlina, 2005). The ***papillary layer*** consists of loose connective tissue immediately below the epidermis. This layer is relatively thin and includes the area of the dermal papillae. The collagen fibers (predominantly type I and III) in this layer are not as thick as in the reticular layer. There is an irregular network of elastic fibers present. The ***reticular layer*** lies immediately below the papillary layer and is the thicker and less cellular layer of the two. It contains thick irregular bundles of collagen (mostly type I) and coarser elastic fibres. The dermis contains many specialized cells and structures. These include the hair follicles (normally associated with the arrector pili muscle), associated sebaceous and apocrine glands, eccrine (sweat) glands, blood vessels, nerves and specialized nerve cells. The major cell types found in the dermis include **fibroblasts** (which normally replenish the extracellular matrix (ECM)), **endothelial cells** (found lining vessels and capillaries),

WitsETD

created with nitroPDF professional
download the free trial online at nitropdf.com/professional

macrophages (normally present, but increase in number during inflammation) and **platelets** (which release growth factors and adherence proteins during inflammation) (Junquiera and Carneiro, 2005; Ross and Pawlina, 2005).

Skin, while structurally adapted to serve as a protective barrier is also vulnerable to injury. Wound healing is a well ordered response to injury characterised by diverse cellular activities that include inflammation, cell migration, angiogenesis (formation of new blood vessels) and matrix deposition (Brown *et al.,* 1992). The repair of a wound is a complex process, generally independent of the form or site of injury (Rosenberg and de la Torre, 2003). Skin healing is predominantly a process of re-epithelialisation and contraction through a process of connective tissue repair (Leitch *et al.,* 1993). Re-epithelialisation is the process of restoring an intact epidermis after cutaneous injury (Li *et al.,* 2007) and is keratinocyte-dependant (Fig. 1.3). The process of contraction, which is defined as the closure of an open wound by the inward movement of the surrounding integument (Leitch *et al.,* 1993), is fibroblast-dependant (Cho-Lee and Moon, 2003). The end product is a predominantly collagen, fibrous scar.

WitsETD

created with nitroPDF professional
download the free trial online at nitropdf.com/professional

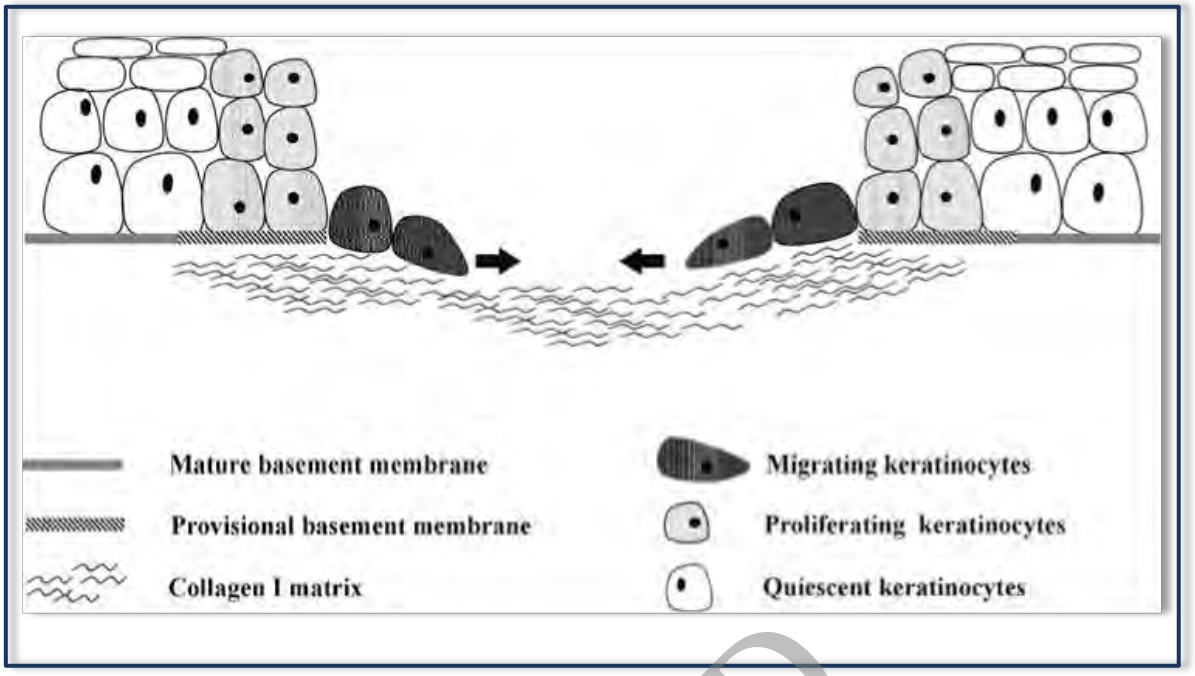

Figure 1.3: The process of re-epithelialisation *(modified from Parks, 1999)*

WitsETD

Re-epithelialisation involves several processes viz. keratinocyte migration from areas adjacent to the wound, keratinocyte proliferation, differentiation of the neo-epithelium into a stratified epidermis and the formation of an intact basement membrane (Li *et al.,* 2007).

Collagen and other components of the ground substance are synthesized in the highly vascular granulation tissue that is formed within the wound space. Since collagen provides strength and integrity to the dermis and other supporting tissues, its synthesis, secretion and subsequent organization plays an integral role in wound healing (Chithra *et al.,* 1998a; 1998b).

created with nitroPDF professional
download the free trial online at nitropdf.com/professional

The three overlapping stages of wound-healing are (Fig. 1.4):

a. inflammation (haemostasis and inflammation)

b. proliferation and

c. tissue remodelling or maturation.

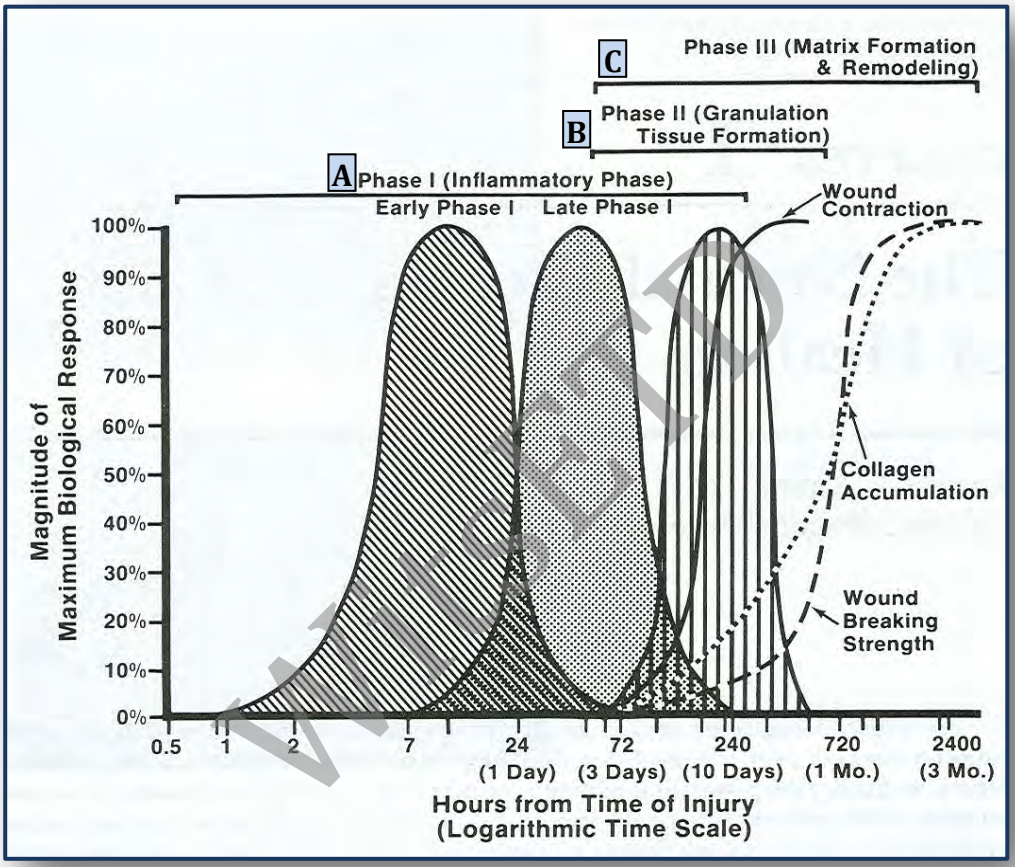

Figure 1.4: Stages of wound healing *(Kloth and McCulloch, 2002)*
A*- inflammatory phase;* ***B****- proliferative phase and* ***C****- maturation phase*

In each of these stages, specific components play a part through several mediators (Kloth and McCulloch, 2002). The following is a *brief* summary of the phases of wound healing**:**

created with nitroPDF professional
download the free trial online at nitropdf.com/professional

a. The inflammatory phase

The **inflammatory phase (also called the exudative phase)** is characterized by haemostasis and inflammation. It is initiated immediately after injury by the release of several growth factors, cytokines and low-molecular-weight compounds from the serum of the injured blood vessels and granulating platelets (Werner and Grose, 2003). Collagen activates the clotting cascade, initiating the inflammatory phase. The damaged cell membranes release thromboxane A2 and prostaglandin 2-α, potent vasoconstrictors. This initial response helps to limit haemorrhage (Werner and Grose, 2003).

WitsETD

Multiple chemokines (Table 1.2), including epidermal growth factor (EGF), fibronectin, fibrinogen, histamine, platelet-derived growth factor (PDGF), serotonin, and von Willebrand factor are released in the first few hours following wounding (Singer and Clark, 1999). These factors help stabilize the wound through clot formation which is composed of cross-linked fibrin and extracellular matrix (ECM) proteins such as fibronectin, vitronectin and thrombospondin (Clark, 1993; Werner and Grose, 2003). The blood clot provides a matrix for invading cells and acts as a reservoir for growth factors required in the proceeding stages of wound healing (Werner and Grose, 2003).

created with nitroPDF professional
download the free trial online at nitropdf.com/professional

Table 1.2: Cytokines in wound healing (adapted from Singer and Clark, 1999)

Cytokines	Major Source	Target Cells and Major Effects
Epidermal growth factor (EGF) family		***Epidermal and mesenchymal regeneration***
EGF	platelets	Pleiotropic cell motility and proliferation
Transforming growth factor (TGF)α	macrophages, epidermal cells	Pleiotropic cell motility and proliferation
Heparin binding EGF	macrophages	Pleiotropic cell motility and proliferation
Fibroblast Growth Factor (FGF) family		***Wound vascularisation***
Basic FGF	macrophages, endothelial cells	Angiogenesis and fibroblast proliferation
Acidic FGF	macrophages, endothelial cells	Angiogenesis and fibroblast proliferation
Keratinocyte GF	fibroblasts	Epidermal cell motility and fibroblast proliferation
Transforming Growth Factor (TGF) β family		***Fibrosis and increased tensile strength***
TGFβ1 and TGFβ2	platelets, macrophages	Epidermal cell motility, chemotaxis of macrophages and fibroblasts, ECM synthesis and remodelling
TGFβ3	macrophages	Anti-scarring effects
Other		
Platelet derived GF (PDGF)	platelets, macrophages, epidermal cells	Fibroblast proliferation and chemoattraction, macrophage chemoattraction and activation
Vascular endothelial GF (VEGF)	epidermal cells, macrophages	Angiogenesis, increase vascular permeability
Tumor necrosis factorα (TNFα)	neutrophils	Pleiotropic expression of growth factors
Interleukin-1 (IL-1)	neutrophils	Pleiotropic expression of growth factors
Insulin like GF 1	fibroblasts, epidermal cells	Re-epithelialisation and granulation tissue formation
Colony-stimulating GF 1	multiple cells	Macrophage activation and granulation tissue formation

WitsETD

The chemokines recruit inflammatory leucocytes to the wound site. The infiltrating neutrophils kill bacteria and decontaminate the wound of foreign debris (Singer and

created with nitroPDF professional
download the free trial online at nitropdf.com/professional

Clark, 1999) (Fig. 1.5). In response to specific chemo-attractants, monocytes also infiltrate the wound and become activated macrophages which initiate the formation of granulation tissue. These invading cells also produce a variety of proteinases and reactive oxygen species as a defence against microorganisms and are involved in phagocytosis of debris (Werner and Grose, 2003). These cells are also essential for wound healing and secrete numerous enzymes and cytokines (Table 1.2), e.g. collagenases, which debride the wound, degrading collagen around the damaged cells; interleukins and tumor necrosis factor (TNF) which stimulate fibroblasts and

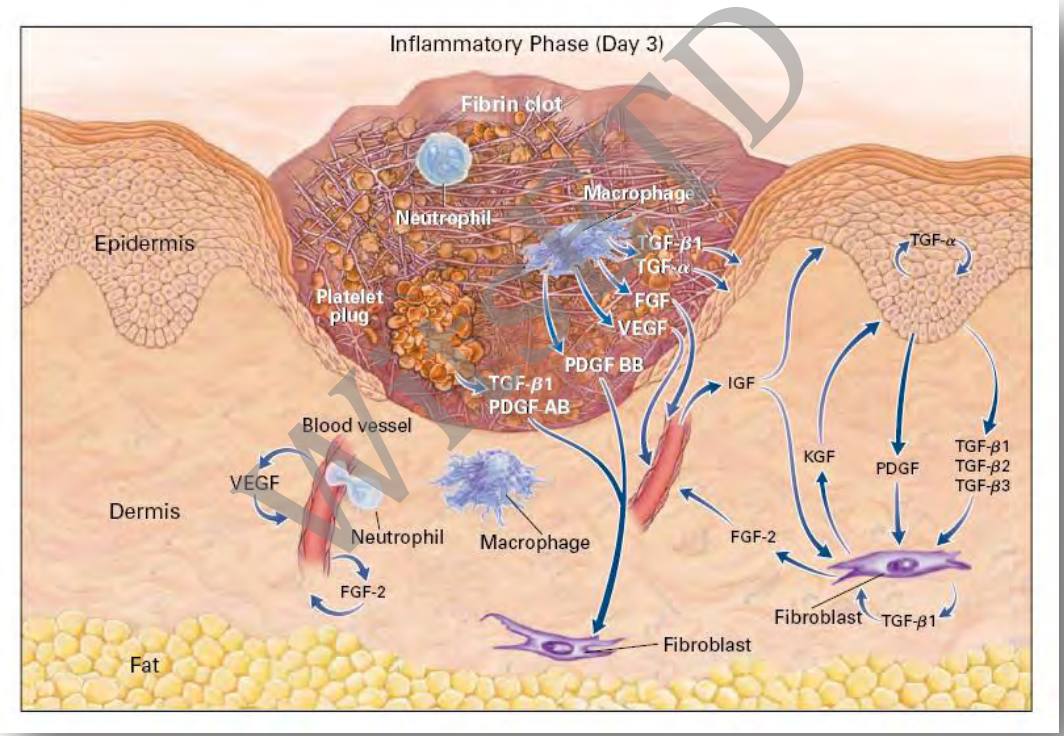

Figure 1.5: Inflammatory phase - A cutaneous wound three days after injury- *the wound is filled with a fibrin clot and inflammatory cells have invaded the wound area. TGF-β1, TGF-β2 and TGF-β3 - transforming growth factor β1, β2 and β3, respectively; TGF-α- transfroming growth factor α; FGF- fibroblast growth factor; VEGF- vascular endothelial growth factor; PDGF- platelet derived growth factor; IGF- insulin like growth factor and KGF- keratinocyte growth factor [Singer and Clark (1999).]*

created with nitroPDF professional
download the free trial online at nitropdf.com/professional

promote angiogenesis; and transforming growth factor (TGF) which stimulates keratinocytes (Rosenberg and de la Torre, 2003). This step marks the transition to the process of tissue reconstruction, ie, the proliferative phase.

b. The proliferative phase

The second stage of wound-healing is the **proliferative phase** (Fig. 1.6). Epithelialisation, angiogenesis, granulation tissue formation, and collagen deposition are the principal steps in this anabolic portion of wound-healing (Singer and Clark, 1999). If the basement membrane remains intact, the epithelial cells migrate towards the surface in the normal pattern. This is equivalent to a first-degree skin burn and the normal layers of epidermis are restored in 2-3 days. If the basement membrane has been destroyed which is similar to a second- or third-degree burn, then the wound is re-epithelialised from the normal epidermal cells at the periphery of the wound and from the skin appendages, if intact (e.g., hair follicles, sweat glands) (Rosenberg and de la Torre, 2003).

WiSETD

Granulation tissue begins to form approximately 4 days after injury (Tonnesen *et al.,* 2000). Numerous new capillaries are found in the granular substance. Macrophages and blood vessels move into the wound space (Moulin *et al.,* 2000). Macrophages provide a continuing source of cytokines which are needed to stimulate fibroplasia and angiogenesis. Fibroblasts in the neighbourhood of the wound begin to proliferate and migrate into the wound matrix where they produce large amounts of

created with nitroPDF professional
download the free trial online at nitropdf.com/professional

ground substance and then collagen (Fig. 1.6). Glycosaminoglycans and proteoglycans are synthesized by fibroblasts in the wound area. These substances form a highly hydrated gel-like ground substance, a provisional matrix in which the collagen fibers are embedded. As the collagen accumulates, hexosamine levels decrease (Dunphy and Udupa, 1955). In addition, fibroblasts in the wound area acquire a contractile phenotype and transform into myofibroblasts (Werner and Grose, 2003). Myofibroblasts play a major role in wound contraction.

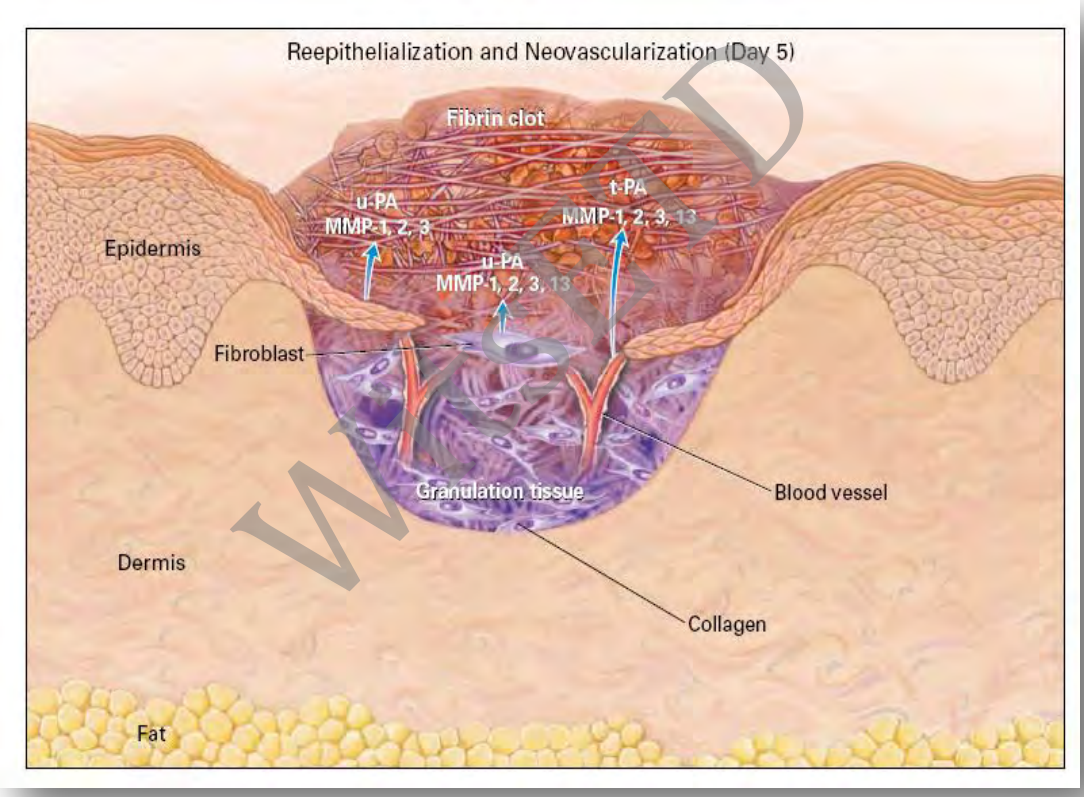

Figure 1.6: A cutaneous wound five days after injury*- blood vessels are sprouting into the fibrin clot as epidermal cells resurface the wound. Proteinases thought to be necessary for migration are shown. U-PA- urokinase-type plasminogen activator; MMP-1,2,3 and 13- matrix metalloproteinases 1, 2, 3, and 13; t-PA- tissue plasminogen activator (Singer and Clark, 1999)*

created with nitroPDF professional
download the free trial online at nitropdf.com/professional

The ultimate part of the proliferative phase is granulation tissue formation. This commences approximately four days after injury. Initially, granulation tissue is composed of fibroblasts and macrophages, and then blood vessels move into the wound space (Fig. 1.6). As the granulation tissue matures, the ECM components appear. The fibroblasts are responsible for the synthesis, deposition and remodelling of the ECM (Singer and Clark, 1999).

Angiogenesis plays an important role in wound healing and newly formed blood vessels constitute 60% of repair tissue (Shukla *et al.,* 1999). The formation of new blood vessels is necessary to sustain the newly formed granulation tissue. Angiogenesis is a complex process that relies on the ECM in the wound bed as well as the migration and mitogenic stimulation of the endothelial cells (Madri *et al.,* 1996). The resulting connective tissue in the wound area is known as granulation tissue because of the granular appearance of the numerous capillaries within it.

WitsETD

The factors which stimulate angiogensis in wound healing are gradually being elucidated. Initially, it was thought that FGF-1 (acidic FGF) and FGF-2 (basic FGF) were responsible for angiogenesis (Folkman and Klagsbrun, 1987). More recently, other factors have been shown to have angiogenic properties e.g. VEGF, TGFβ, angiogenin, angiopoietin and human mast cell tryptase. It is thus now well accepted that several growth factors assist wound healing.

created with nitroPDF professional
download the free trial online at nitropdf.com/professional

The ground substance is deposited into the wound bed, followed by collagen deposition as the wound undergoes the final phase of repair. Many different cytokines are involved in the proliferative phase of wound repair (Rosenberg and de la Torre, 2003). The exact mechanisms of how these cytokines effect proliferation is not yet fully understood. Some of the cytokines include PDGF, insulin-like growth factor (IGF), and EGF. All are necessary for collagen formation. Once an abundant collagen matrix has been deposited in the wound, the fibroblasts stop producing collagen and the fibroblast-rich granulation tissue is replaced by a relatively acellular scar (Singer and Clark, 1999). The scar tissue is mechanically insufficient and lacks appendages, including hair follicles, sebaceous glands and sweat glands (Werner and Grose, 2003).

WitsETD

c. The maturation phase

The final phase of wound healing is the **maturation (re-modelling) phase**. The wound undergoes contraction, ultimately resulting in a smaller amount of apparent scar tissue. The entire process is a dynamic continuum with an overlap of each of the preceding phases and continued remodelling which takes more than a year to complete. One of the crucial processes in wound healing is the progressive increase in biomechanical strength of the healing tissue. Stabilization of the new matrix and increase in mechanical strength results from the formation and maturation of intermolecular collagen cross-links. These links are initially bivalent and then convert into the multivalent mature cross-links as scar tissue matures (Paul *et al.,* 1997). The strength of a wound therefore relates to the size, number and

created with nitroPDF professional
download the free trial online at nitropdf.com/professional

architectural arrangement of the collagen fibrils (Berthod *et al.,* 2001). Tensile strength is a quantitative parameter that can be correlated with the degree of cell proliferation of fibroblasts and the alignment and density of the collagen fibre networks in the dermis (Cho-Lee and Moon, 2003). The wound reaches maximal strength at one year, with a tensile strength that is 30% of normal skin (Singer and Clark, 1999). Collagen deposition continues for a prolonged period, but the net increase in collagen deposition plateaus after 21 days (Rosenberg and de la Torre, 2003).

The synthesized collagen molecules are laid down at the wound site and become cross linked to form fibers. Wound strength is acquired from both the remodelling of the collagen and the formation of stable intra- and inter-molecular cross links. If the tensile strength of the wound which was treated with an exogenous agent is greater than the untreated wound, then it may be inferred that the agent not only increases collagen synthesis, but also aids in the cross linking of the protein (Chithra *et al.,* 1998b).

The process of wound healing appears to be controlled by multiple growth factors and chemokines. The roles of many of the endogenous growth factors have only been partly elucidated based on expression studies or cell culture studies. The *in vivo* function of many of these growth factors still remains to be confirmed (Werner and Grose, 2003).

WitsETD

created with nitroPDF professional
download the free trial online at nitropdf.com/professional

1.3 Vascular endothelial growth factor (VEGF) in wound healing

VEGF (initially named vascular permeability factor, VPF) currently includes VEGF-A, VEGF-B, VEGF-C, VEGF-D, VEGF-E and placenta growth factor (PLGF) (Werner and Grose, 2003, Kapoor *et al.,* 2006). VEGFs are structurally closely related to the platelet derived growth factors (PDGF) (Kapoor *et al.,* 2006). VEGFs exert their function by binding to three different trans-membrane tyrosine kinase receptors viz. VEGFR-1, VEGFR-2 and VEGFR-3 (Fig. 1.8). VEGF-A and its associated receptors VEGFR-1 and VEGFR-2 has been recognized as the major regulator of vasculogenesis and angiogenesis during development (Gale and Yancopoulos, 1999) and its role in the regulation of angiogenesis in wound healing has recently been noted (Werner and Grose, 2003). Studies have shown that VEGF-A is strongly expressed after cutaneous injury by keratinocytes and macrophages (Brown *et al.,* 1992, Frank *et al.,* 1996). The associated receptors have been detected in the blood vessels found in granulation tissue (Lauer *et al.,* 2000).

WitsETD

VEGF-A is an endothelial cell specific mitogen that exists as four variants based on molecular weight, in humans i.e. 121, 165, 189 and 206 amino acids. $VEGF_{121}$ and $VEGF_{165}$ are exported from the cell while $VEGF_{189}$ and $VEGF_{206}$ are cell-associated (Elçin *et al.,* 2001). It has been previously reported that $VEGF_{121}$ and $VEGF_{165}$ are both readily available forms that are predominantly expressed in most human cells and tissues (Corral *et al.,* 1999). $VEGF_{165}$ appears to biologically active in physiological and pathological angiogenesis, being the most potent angiogenic protein known (Kapoor *et al.,* 2006).

created with nitroPDF professional
download the free trial online at nitropdf.com/professional

VEGF has a number of functions. It has potent angiogenic activity. It increases microvascular permeability, exerts mitogenic effects on endothelial cells stimulating their proliferation and migration. It also induces the expression of interstitial collagenase and promotes macrophage migration (Elçin *et al.,* 2001). Reactive oxygen species which are thought to aid in killing bacteria also up-regulate VEGF expression (Bates and Pritchard-Jones, 2003). VEGF is produced in large quantities by the epidermis (Tonnesen *et al.,* 2000) especially in the basal layer (Kapoor *et al.,* 2006) during wound healing and is induced by hypoxia. VEGF released by epidermal keratinocytes (Frank *et al*., 1995) is critical for angiogenesis during the proliferative phase of granulation tissue formation from day 4 to day 7 (Nissen *et al*., 1998; Tonnesen *et al.,* 2000), peaking on day 7 following injury (Kapoor *et al.,* 2006). VEGF expression can be regulated by certain enzyme systems like nitric oxide syntase (NOS) and cyclooxygenase (COX) (Kapoor *et al.,* 2006).

WitsETD

1.4 Myofibroblasts in wound healing

Myofibroblasts were first described by Gabiani in 1979 (Bates and Pritchard-Jones, 2003) and are largely responsible for the contraction of the wound edges (Bates and Pritchard-Jones, 2003). In the early stages of wound healing, fibroblasts invade the wound space where they proliferate and differentiate into myofibroblasts. Myofibroblasts are a unique group of 'smooth-muscle-like fibroblasts' containing α-smooth muscle actin (αSMA) and a lesser amount of vimentin in their cytoplasm. These myofibroblasts are functionally different from fibroblasts in that they are

created with nitroPDF professional
download the free trial online at nitropdf.com/professional

essential to neodermal formation and wound contraction (Moulin *et al.,* 2001). Wound contraction occurs biphasically. In the first phase immediately following wounding, contraction is myofibroblast independant. In the second phase, myofibroblasts increase the rate of contraction by using an actin-myosin complex. Intracellular actin microfilaments terminate in adhesion complexes at the cell surface which connect them with the surrounding ECM and result in matrix reorganisation and wound contraction (Mirastschijski *et al.,* 2004).

Another important event in wound healing is the migration and growth of keratinocytes in the neo-epidermis followed by the formation of a complete basement membrane that ensures the structural and mechanical stability of the dermo-epithelial junction. Keratinocyte interactions with fibroblasts differ from that of keratinocytes with myofibroblasts. Moulin *et al.* (2000) suggest that myofibroblasts are involved in neo-epidermis formation and contraction whereas fibroblasts stimulate keratinocyte growth and neo-dermis formation. Myofibroblasts have been shown to express VEGF mRNA (Bates and Pritchard-Jones, 2003).

WitsETD

created with nitroPDF professional
download the free trial online at nitropdf.com/professional

1.5 Transforming growth factor β (TGF β) in wound healing

The TGF-β superfamily comprises TGF-β (1-5, with only 1-3 in humans), inhibins, activins and bone morphogenic proteins (Kapoor *et al.,* 2006). TGF-β stimulates or inhibits the growth of many cell types, depending upon the presence of other growth factors and is a potent chemo-attractant for macrophages (Lynch *et al.,* 1998).

The effects of TGF-β are mediated by heteromeric receptor complexes consisting of receptor type I ($TGF\beta R_I$) and receptor type II ($TGF\beta R_{II}$) which activate intracellular signalling cascades (Werner and Grose, 2003). Three isoforms of TGF-β exist in mammalian tissue viz., TGF-β1, TGF-β2 and TGF-β3. They are usually secreted in a complex with latent TGF-β-binding protein which is removed extracellularly to release the active TGF-β (Werner and Grose, 2003) (Fig. 1.7). Active TGF-βs then mediate their function by binding to the receptor complex. In addition, they bind with high affinity to a non-signalling type III receptor ($TGF\beta R_{III}$) (Fig. 1.7). The three TGF- βs have distinct but overlapping functions. They are mitogenic for fibroblasts, but inhibit proliferation of most other cells, including keratinocytes. They are also stimulators of the expression of ECM proteins and integrins (Massagué, 1990).

WitsETD

created with nitroPDF professional
download the free trial online at nitropdf.com/professional

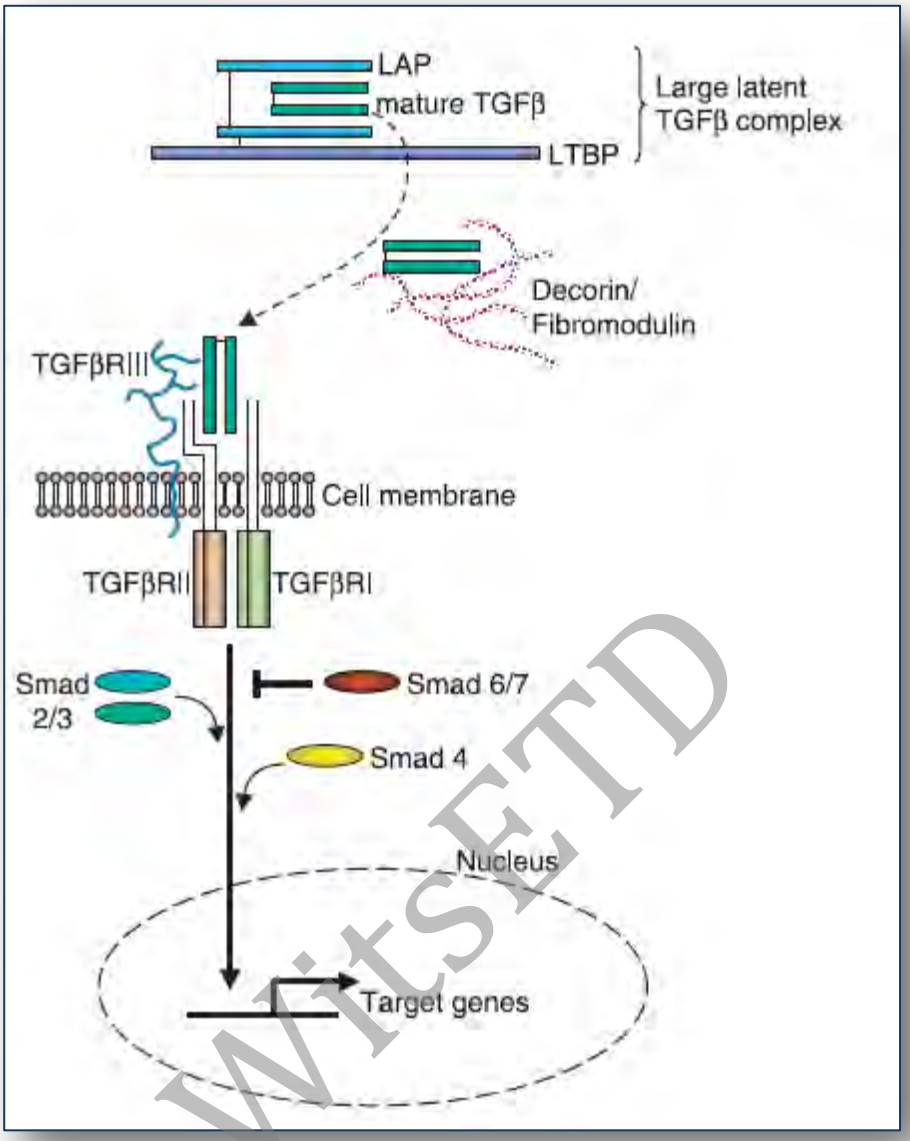

WiSETD

Figure 1.7: Transforming growth factor β receptors (TGF-βR)*: TGF-β is secreted as an inactivated precursor which binds to latency associated protein (LAP). When activated, TGF-β is either sequestered by extracellular binding proteins or it binds to receptor type III which then presents it to receptor type II or I. (Werner and Grose, 2003)*

There is a continuous supply of TGF-βs during wound healing (Massagué, 1990). Following injury, TGF-β1 is released by platelets. This acts as a chemoattractant for neutrophils, macrophages and fibroblasts. The presence of these cells further increases TGF-βs secretions. All three isoforms of TGF-β have been detected in

created with nitroPDF professional
download the free trial online at nitropdf.com/professional

wound healing with the distribution of each isoform being characteristic. Rapid induction of TGF-β1 and TGF-β2 occurs early in wound healing while TGF-β3 expression is seen in later stages of wound healing. TGF-β1 and TGF-β2 are stimulators of ECM production. The $TGF\beta R_I$ and $TGF\beta R_{II}$ are widely distributed and found on essentially all cell types (Gold *et al.,* 1997 and Schmid *et al.,* 1998). TGF-β stimulates fibroblast division at low concentrations, but stimulates differentiation at high concentrations (Slavin, 1996). The differentiated phenotype is associated with increased ECM production. It is thought that TGF-βs stimulate re-epithelialisation and granulation tissue formation. TGF-β1 plays a central role in cutaneous scar formation and is a potential target for anti-scarring agents. TGF-β3 is an antagonist of TGF-β1 (Kapoor *et al.,* 2006).

WitsETD

1.6 Animal models in wound healing experiments

The medical literature describes a number of *in vitro* and *in vivo* wound healing models (Sullivan *et al.,* 2001). *In vivo* testing of potential intervention therapies is important as *in vitro* assays are limited in their ability to replicate all of the factors which interact in complex biological processes such as wound healing (Vardaxis *et al.,* 1997). While human studies may be the most ideal, they are often complicated and impractical, especially in identifying sufficient numbers of patients with identical and similar wounds (Sullivan *et al.,* 2001). In addition, objective measurements of human wound healing are difficult in that these experiments require numerous biopsies for

created with nitroPDF professional
download the free trial online at nitropdf.com/professional

histological assessment during the healing period. It is for this reason that animal studies provide a suitable alternative to assess the efficacy of potential therapies (Sullivan *et al.,* 2001).

It is important to choose an animal model carefully for wound healing studies. Wound healing research has been carried out on numerous animal models *viz*. rat, mouse, rabbit, guinea pig and more recently, the pig. Smaller animal models are often preferred due to the cost and ease of handling (Sullivan *et al.,* 2001). This however is not ideal as these smaller animals differ considerably both anatomically and physiologically, from human subjects. Smaller animals typically have dense body hair and a thin epidermis and dermis. Healing is also primarily through contraction rather than re-epithelialisation (Sullivan *et al.,* 2001).

WitsETD

The pig has proven to be a superior model to assess wound healing interventions (Vardaxis *et al.,* 1997) as its skin is both anatomically and physiologically similar to human skin (Sullivan *et al.,* 2001) (Fig. 1.8). Pig skin consists of two layers: the epidermis and dermis, with a relatively thick hypodermis consisting of fat. The epidermis is a stratified sqaumous keratinised epithelium. Both stratum granulosum and stratum basale are filled with basophilic granules (Mowafy and Cassens, 1975). The porcine epidermis is thrown into a great number of folds resulting in the formation with well developed rete-ridges (Winter, 1972; Vardaxis *et al.,* 1997; Sullivan *et al.,* 2001). Studies on pig and human skin have shown a similar epidermal thickness and dermal-epidermal ratio (Vardaxis *et al.,* 1997; Sullivan *et al.,* 2001). In addition, both skin types have comparable hair and blood vessel size, orientation and

created with nitroPDF professional
download the free trial online at nitropdf.com/professional

distribution. Biochemically, porcine collagen is like human collagen and is therefore used in a number of wound healing products (Heinrich *et al.,* 1971).

Both pig and human have apocrine sweat glands in their skin (Montagna and Yun, 1964). In addition, the *panniculus carnosus* which is found in smaller loose skinned animal models is absent in pigs and humans (Sullivan *et al.,* 2001).

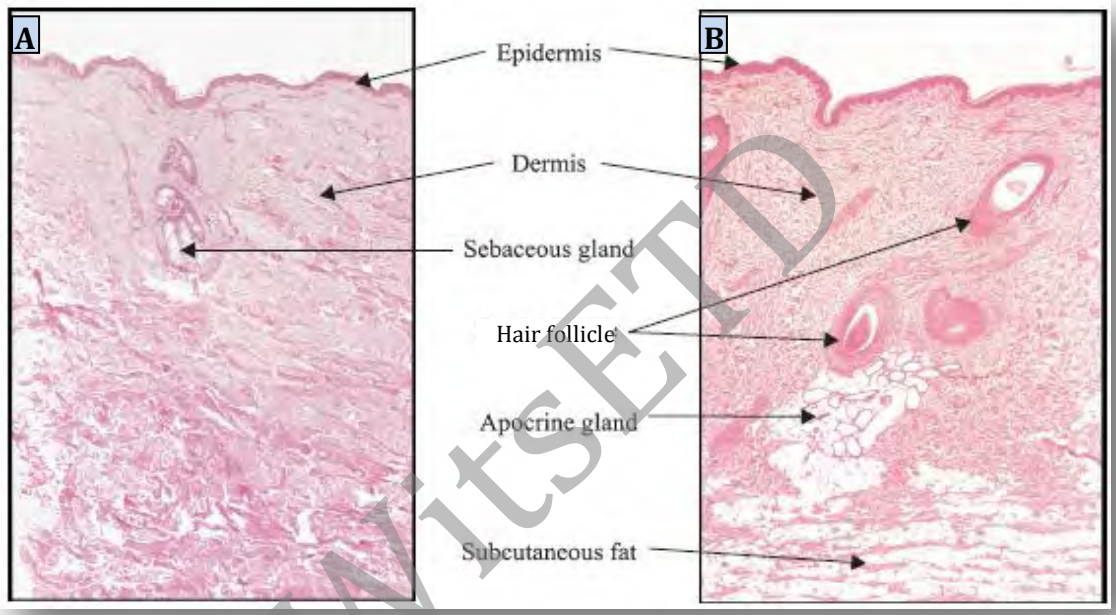

Figure 1.8: Histological features of pig skin and human skin.
***A**-pig skin; **B**-human skin x10, H&E (Sullivan, 2001)*

WitsETD

Functionally, pig and human skin both have a similar epidermal total turnover time - porcine skin is ~30 days and human skin is ~27-28 days (Vardaxis *et al.,* 1997). The type of keratinous proteins and the lipid composition of the stratum corneum are comparable in both skin types. Immunohistochemical studies have also shown similar expression patterns and responses to growth factors such as EGF, IL-1α, bFGF and PDGF (Wollina, 1991).

created with nitroPDF professional
download the free trial online at nitropdf.com/professional

While there are many similarities between porcine and human skin, differences do exist. In porcine skin, the stratum lucidum is absent in the epidermal layer. This skin is thus similar to thin skin of humans rather than the thick skin. The pig contains no eccrine glands. Unlike human skin, porcine skin has lower elastic fibre content (Montagna and Yun, 1964) but this is higher than in other mammals. Mast cells are abundant in the papillary layer of porcine skin. Hence, the pig has a rapid and marked mast cell sensitivity to stress. The sub-epidermal plexus is less developed in the pig (Sullivan *et al.,* 2001). Yet in spite of these differences, Sullivan *et al.* (2001) concluded in a review of the pig as a wound healing model, that healing in porcine skin was comparable to human skin and that pig skin is an excellent tool for the evaluation of potential therapeutic agents for wound healing. The use of pigs in wound healing studies however is infrequent due to the cost of using pigs over that of other smaller animals (Sullivan *et al.*, 2001). In addition, pigs are difficult to handle and grow quickly.

In this study, the pig was chosen as the *in vivo* animal model, as porcine skin has many similarities to human skin in anatomical structure and in the process of wound healing.

WitsETD

created with nitroPDF professional
download the free trial online at nitropdf.com/professional

1.7 Wound creation models

In vivo animal studies usually utilise two methods of creating the wound area that is to be studied viz. incisional and excisional wounding. The choice of these wound types depend on the parameters of wound healing to be analysed.

Incisional wounds

Incisional wounds are formed by cutting the skin with a surgical blade. This results in rapid disruption of the tissue integrity with minimal collateral damage. There is rapid release of blood cells into the wound space, haemostasis and the formation of a fibrin clot. Pig skin, like human skin is firmly attached to the underlying structures and gapes little in this type of incision (Sullivan *et al.,* 2001). These wounds may be closed with sutures, staples or clips. This results in rapid and efficient bridging of the wound edges by granulation tissue and the new epithelium. This type of wound is excellent for biomechanical analysis of wound strength. It is less adequate for histological assessment of healing because of the limited volume:area ratio of wound healing activity (Davidson, 2001).

Excisional wounds

Excisional wounds involve the removal of an area of the tissue. The area which begins to heal provides an adequate sample for determining biochemical and histological analysis (Davidson, 2001). In full thickness wounds, there is complete removal of the epidermis and dermis to the depth of the fascial plane or

WitsETD

created with nitroPDF professional
download the free trial online at nitropdf.com/professional

subcutaneous fat (Davidson, 2001). The wound that is formed then heals by cell migration from the wound margin and the formation of a fibrin clot (eschar) that is invaded by granulation tissue. Various devices are used to generate this type of lesion in a standardized fashion, including biopsy punch, scalpel, and dermatome (Davidson, 2001). This model offers the advantages of significant wound volume, involvement of all dermal components, and epithelialisation only from the wound margins. The ability to analyze chemistry, histology, and cell populations in the wound site (Davidson, 2001) is afforded by the larger volume:area of tissue. The rate of healing is monitored as a percentage of the total excisional volume (or cross-sectional area) filled with granulation tissue (neo-epidermis), extent of re-epithelialisation, histological organization of connective tissue, angiogenesis, and biochemical content of collagen or proteoglycans (Davidson, 2001).

WitsETD

Study Rationale

As seen from this brief review, wound-healing is a complex process in which many different cell types, processes and factors are involved. The main goal of wound management is rapid wound closure and a functional aesthetic scar. Plant extracts may influence one or more of the pathways involved in wound-healing. If an indigenous plant, traditionally used for healing, can be scientifically proven to enhance the healing process, this would be of major beneficial value to the people of South Africa in particular.

In order to investigate the effect of a plant extract, the process of wound-healing needs to be uncoupled in the first instance, and certain processes e.g.

created with nitroPDF professional
download the free trial online at nitropdf.com/professional

epithelialization, fibroblast proliferation and collagen deposition, would initially need to be examined. This will be followed by studies of wound healing in an *in vivo* situation in both an animal and human model.

AIM OF STUDY

The aim of this study was to compare the *in vitro* and *in vivo* effect of *B. frutescens* and *B. natalensis* on cutaneous wound healing. The investigation involved three parts; the aims of each are detailed below:

WitsETD

Part 1 - An *in vitro* study of the effects of *B. natalensis* and *B. frutescens* on human epidermal keratinocytes and dermal fibroblasts:

A. To investigate and compare the effect of the leaf gel of *B. frutescens* and *B. natalensis* on human dermal fibroblast and human keratinocyte cell cultures. The following aspects were examined on each of the cell lines:

a. the cytotoxic effect of the extracts
b. the proliferative effect of the extracts
c. the migratory effect of the extracts
d. the antimicrobial effect of the extracts

created with nitroPDF professional
download the free trial online at nitropdf.com/professional

Part 2 - An *in vivo* animal study of the effects of *B. natalensis*- and *B. frutescens*-treated wounds compared to untreated wounds in pig skin:

To investigate the effect of the *B. frutescens* and *B. natalensis* leaf extracts on incisional and excisional full thickness skin wounds using an animal model. The following aspects were studied:

a. Rate of contracture and period of epithelialisation
b. Mechanical strength of the re-epithelialised wound
c. Biochemical analysis:
    i. estimation of collagen content
    ii. estimation of hexosamine content
    iii. estimation of total protein content
    iv. estimation of total DNA content
d. Histological structure of wound closure
e. Immunohistochemistry – to investigate the expression of α-smooth muscle actin (αSMA), VEGF and TGF-βR_I and TGF-βR_{II}

WiseTD

Part 3 - An *in vivo* study human study of the effects of *B. natalensis*- and *B. frutescens*-treated wounds compared to untreated wounds in skin:

To investigate the effect of the *B. frutescens* and *B. natalensis* leaf extracts on superficial lesions on human skin.

created with nitroPDF professional
download the free trial online at nitropdf.com/professional

2. MATERIALS & METHODS

2.1 Preparation of the *Bulbine* gels

Plant material (i.e. *B. frutescens* and *B. natalensis*) for this study was sourced from the Walter Sisulu Botanical Gardens in Roodepoort, Johannesburg. The taxonomic identity of the plants was confirmed by the principal horticulturalist. The plant voucher numbers were: *B. frutescens*, GSIS323 and *B. natalensis,* GSIS324.

In an initial pilot study, the gel from the leaves of *B. frutescens* and *B. natalensis* was prepared individually according to the method used by Chithra *et al.* (1998a; 1998b) for the preparation of the leaf gel extract from the *Aloe vera* plant. Briefly, the full size mature leaves from each plant were cut. The rind was removed and the colourless parenchyma was ground in a blender and centrifuged at 10 000 rpm for 30 minute at 4^0C to remove the fibres. The supernatant was lyophilized and frozen until needed. The lyophilized gel was reconstituted with phosphate buffered saline (PBS) and then filtered using a sterile filter with a pore size of 0.2µm. This lyophilised leaf gel was initially used in the cell culture studies but did not have any effect on the cell cultures. The use of the reconstituted gel without filter sterilisation was difficult because of the presence of a large number of fibrous strands which made viewing the cells difficult.

Therefore, for all experiments reported in this thesis, an alternative method for the preparation of leaf extract was used. The mature leaves of *B. frutescens* and *B. natalensis* plants were harvested and washed in running water. The leaves were

WiSETD

created with nitroPDF professional
download the free trial online at nitropdf.com/professional

wiped with 70% alcohol. The exposed ends of each leaf were cut using a sterile surgical blade. A sterile pizza machine was then used to squeeze the gel out of the leaves. The gel was collected in a sterile petri dish. Fresh gel was squeezed for each experiment. The pH of the fresh leaf gel of *B. frutescens* and *B. natalensis*, tested using litmus paper, was 4 and 5, respectively. This method of using the fresh gel was chosen because it is the fresh gel from the leaves that is used by the indigenous peoples of South Africa for treating skin ailments and wounds.

WitsETD

created with nitroPDF professional
download the free trial online at nitropdf.com/professional

2.2 An *in vitro* study of the effects of *B. natalensis* and *B. frutescens* on human epidermal keratinocytes and dermal fibroblasts

Human ethics clearance for this study was obtained from the University of the Witwatersrand Human Ethics Committee (M050108).

The following two cell lines were used for all the experiments:

1. The CCD-1140Sk normal adult dermal fibroblast cell line was purchased from the American Type Culture Collection® (ATCC®) (catalogue no. CRL-2714) and cultured in Iscove's modified Eagles Medium (IMEM) supplemented with 10% fetal calf serum.
2. The HaCaT cell line, an immortalized, but non-tumourgenic keratinocyte cell line which retains its differentiation potential (Boukamp *et al.,* 1988) was generously provided by the German Cancer Research Center (DKFZ) and cultured in Dulbecco's modified Eagles Medium (DMEM) supplemented with 10% fetal calf serum and 0.1% penicillin/streptomycin .

Monolayer cultures of both cell lines were maintained under standard culture techniques at 37°C in 5% CO_2 in air. IMEM, DMEM, fetal calf serum and all other reagents were obtained from Whitehead Scientific (Pty) Ltd, South Africa.

WitsETD

created with nitroPDF professional
download the free trial online at nitropdf.com/professional

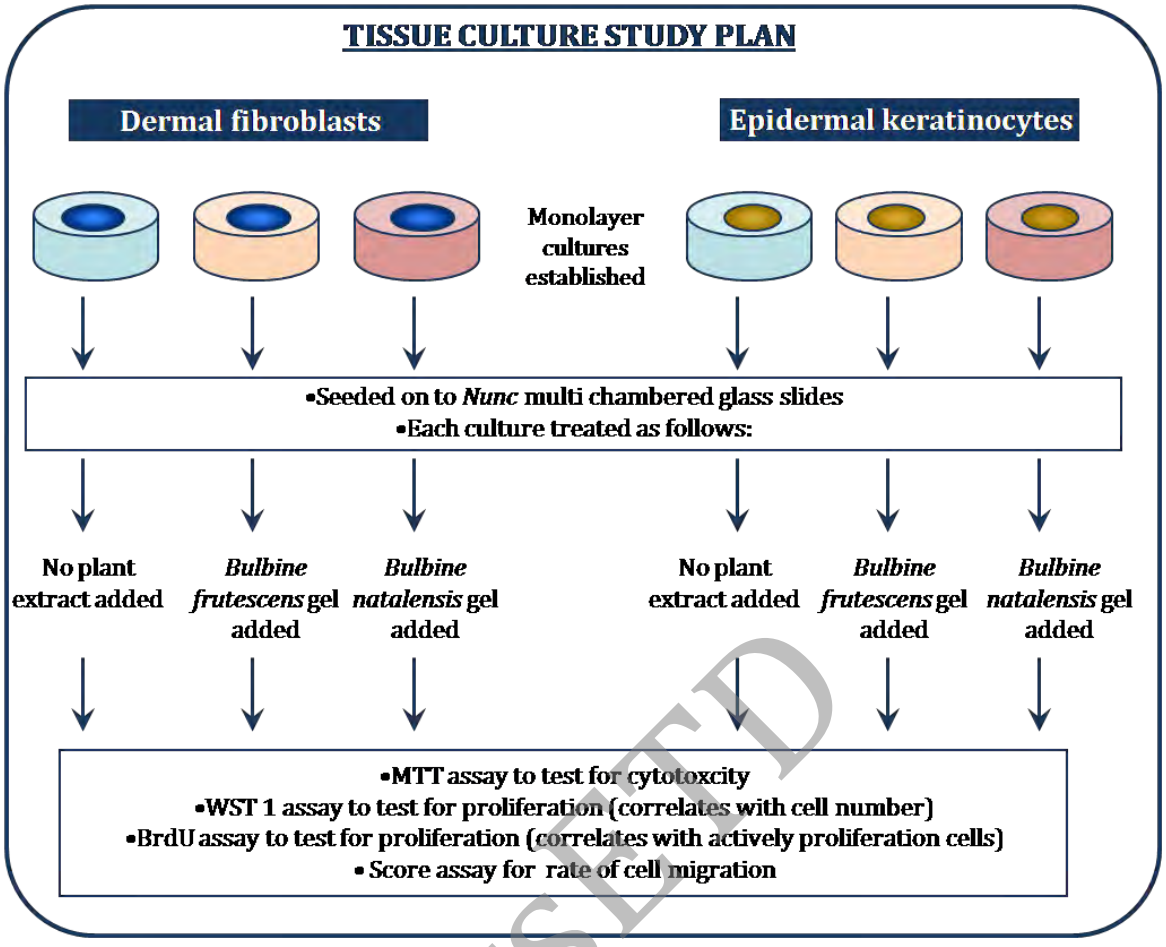

Figure 2.1: Flow diagram of tissue culture experiments

WITSETD

The following assays were carried out on monolayer cultures of both the cell lines using *B. frutescens* and *B. natalensis* (Fig. 2.1):

The **MTT** [3-(4,5-dimethylthiazol-2-yl)-2,5-diphenyltetrazolium bromide] cell viability assay (Mosmann, 1983) which is a standard colorimetric assay, was used to determine the cytotoxicity of the potential medicinal plants. In this assay, the yellow MTT enters the cell mitochondria and is reduced to an insoluble purple formazan salt that can be quantified using spectrophotometry (Mosmann, 1983). This assay was

created with nitroPDF professional
download the free trial online at nitropdf.com/professional

done at the laboratory facilities of the School of Therapeutic Sciences (Faculty of Health Sciences, University of the Witwatersrand). Briefly, for all of the MTT assays, keratinocyte and fibroblast cells were seeded into Nunc® 96 well microplates at a concentration of 1.6 x10^5 cells per ml of medium. The cell cultures were then treated with varying concentrations of the fresh leaf gel extracts prepared in medium (DMEM for keratinocytes and IMEM for fibroblasts) at the time of seeding. Wells with cells which were not treated with the extracts were used as the untreated control cultures, while wells which contained medium only (no cells) were used as a blank for spectrophotometry. The cells were incubated at 37^{0}C in 5% CO_2 for 48 hours. Four hours before the end of incubation, 20µl of the MTT solution (50mg/ml MTT made up in PBS (pH 7.4) (Appendix A1) was added to each well in the microplate. After four hours of incubation, the medium was removed from each well and replaced with 150µl of dimethyl sulfoxide (DMSO) to dissolve the blue/purple crystals formed in the cells. The microplate was then read in a spectrophotometer at a test wavelength of 540nm and a reference wavelength of 690nm. The viability of the cells was determined as a percentage of the untreated controls.

WitsETD

The **WST-1 assay** which measures the metabolic activity of viable cells was used to measure *in vitro* cell proliferation. This assay is based on the cleavage of the tetrazolium salt WST-1 to a formazan dye by mitochondrial succinate-tetrazolium reductase in viable cells. As the cells proliferate, the quantity of the formazan dye increases (Brodie *et al.* 1999). WST-1 has been reported to have increased sensitivity when compared to other cytotoxicity assays (Tan and Berridge, 2000). Briefly, for all

created with nitroPDF professional
download the free trial online at nitropdf.com/professional

of the WST-1 assays, cells were seeded into Nunc® 96 well microplates at a concentration of 1.6 x10^5 cells per ml of medium and incubated at 37°C in 5% CO_2 in air for 24 hours. Cells were treated with varying concentrations of the fresh leaf gel made up in the respective cell culture media. Wells with untreated cultures were used as controls, while wells which contained medium only and no cells were used as a blank for spectrophotometry. The cells were then incubated for 24 hours after which 10µl of WST-1 was added to each well. Cells were then incubated for a further 4 hours. During this 4 hour period, the absorbance at 600nm was measured using a spectrophotometer at 0.5, 1, 2 and 4 hours. The absorbance values obtained from the WST-1 assay are a direct correlation of cell number (Brodie *et al.* 1999).

WitsETD

The **Bromodeoxyuridine (BrdU) Cell Proliferation Assay** in which BrdU (a synthetic analogue of thymidine) is incorporated into the newly synthesized DNA of replicating cells, was used to measure DNA synthesis of the cells. For all of the BrdU assays, cells were seeded into Nunc® 96 well microplates at a concentration of 1.6 x10^5 cells per ml of medium and incubated at 37^0C in 5% CO_2 in air. After two days, the cells were confluent and the medium was replaced with medium containing various concentrations (0.1-900µl/ml) of the fresh gel extracted from the leaves of *B. frutescens* and *B. natalensis* made up in the respective cell culture medium. Following incubation for 24 hours, the cells were then washed in a PBS solution (Appendix A1). The BrdU kit (Calbiochem®; catalogue number QIA58) was used according to the manufacturer's instructions. Briefly, the cells were treated with the BrdU antibody and incubated for 2 hours, then washed to remove any unbound antibody before

created with nitroPDF professional
download the free trial online at nitropdf.com/professional

being treated with horseradish peroxidise-conjugated goat anti-mouse IgG HRP. Tetra-methyl benzidine was then added. This results in a blue solution which changes to yellow with the addition of a stopping reagent. The plate was then read on a spectrophotometer at a wavelength of 540nm. The intensity of the colour in each well is directly proportional to the amount of proliferation occurring.

The **Score Assay** was used to measure the time in which a score made in the monolayer cultures 'closed' and to visualize the migration of the cells (Liang *et al.,* 2007). For this assay, cells were seeded into Nunc® four well microplates at a concentration of 1.6 x10^5 cells per ml of medium (DMEM and IMEM for the keratinocyte and fibroblast cultures, respectively) and incubated at 37^{0}C in 5% CO_2 in air for 24 hours. The cultures were then incubated for 24 hours with a 50% concentration of fresh gel extracted from the leaves of *B. frutescens* and *B. natalensis* made up in the respective media. Thereafter, the medium was aspirated and replaced with fresh medium without any extract. Untreated cultures were used as controls. All cultures were then scored with a P200 pipette tip (Liang *et al.,* 2007). The scores were photographed on a Carl Zeiss inverted phase control microscope at regular intervals over a period of 48 hours. The time to 'closure' (i.e. full population of the score by the migrated cells) was recorded.

All experiments were repeated six times.

WiSETD

created with nitroPDF professional
download the free trial online at nitropdf.com/professional

Antimicrobial activity

The leaf extracts were also analysed for their efficiency in preventing wound infection, decreasing the bacterial adherence or decreasing the bacterial proliferation of already colonized wounds. The minimal inhibitory concentration of the plant extracts against *Staphylococcus aureas*, *Staphylococcus epidermidis* and *Pseudomonas aeruginosa* was determined using the method of Eloff (1998) and the laboratory facilities of the School of Therapeutic Sciences (Faculty of Health Sciences, University of the Witwatersrand). These are the most common pathogens causing human wound infection. The leaf gel from *B. natalensis* and *B. frutescens* with a starting concentration of 64mg/ml was made up in sterile water . This was then serially diluted in a 96 well microtiter plate. Cultures (100µl of a 1% solution) of *Staphylococcus aureus* (ATCC® No. 6538), *Staphylococcus epidermidis* (ATCC® No. 2223) and *Pseudomonas aeruginosa* (ATCC® No. 27858) made up in sterile Müller-Hinton broth (Merck, Germany) were added to three rows each of the microtiter plate and incubated for 24 hours. Thereafter, 40µl of 0.2mg/ml p-iodonitrotetrazolium violet (INT) (Sigma Aldrich) was added to each well. Six hours later the microtiter plate was visually assessed. Spectrophotometer analysis was not performed as the microbial growth was distinctly evident in all wells.

WitsETD

created with nitroPDF professional
download the free trial online at nitropdf.com/professional

2.3 An *in vivo* animal study of the effects of *B. natalensis*- and *B. frutescens*-treated wounds compared to untreated wounds in pig skin

2.3.1 Experimental animals

Animal ethics clearance for this part of the study was granted by the Animal Ethics Committee of the University of the Witwatersrand, Johannesburg (AESC #2006 2804).

WitsETD

Post-weaning female pigs (*Sus scrofa domestica*) were chosen for this study due to the similarities between porcine and human skin. This component of the study utilised a total of 12 pigs which weighed between 20-30kgs immediately post-weaning. The animals were allowed to acclimate themselves to the animal facilities at the Central Animal Unit of the University of Witwatersrand Medical School for five days prior to surgery.

Wound creation

When using pigs as an animal model, it is important to standardise the biopsy sites as contraction varies depending on the site of the wound (Sullivan *et al.,* 2001). The wounds in this study were created using the methods described by Chithra *et al.* (1998a; 1998b). Since skin thickness, wound contraction and healing can depend on the site of injury, each animal served as its own control by using mirror-image wounds. Mirror-image wounds have the advantage of providing a control site at an

created with nitroPDF professional
download the free trial online at nitropdf.com/professional

anatomically similar position to the 'experimental' site with regard to location and orientation (Gonçalves *et al.,* 2007).

The animals were premedicated with intramuscular ketamine (15mg/kg) and phenobarbitone (0.4mg/kg). General anaesthesia was induced by the administration of 1-2% halothane by a mask. The skin on the dorsal aspect of all the animals was then shaved. The animals were divided into two groups viz. a *B. frutescens* and a *B. natalensis* group.

Each of the animals had two sets of mirror-imaged wounds created on either side of the dorsal midline as follows (Fig. 2.2):

a. 2 x 2cm full-thickness (i.e. down to the subcutaneous fascial sheath) **incisional** wound. These wounds were closed using interrupted sutures with silk thread to secure the edges of the incisional wounds. These wounds were used for testing the tensile strength of the repaired skin.

b. 5 x 0.4mm full-thickness (completely transdermal) **excisional** wounds made with a biopsy puncture. These wounds were used for biochemical and histological analysis.

WitsETD

created with nitroPDF professional
download the free trial online at nitropdf.com/professional

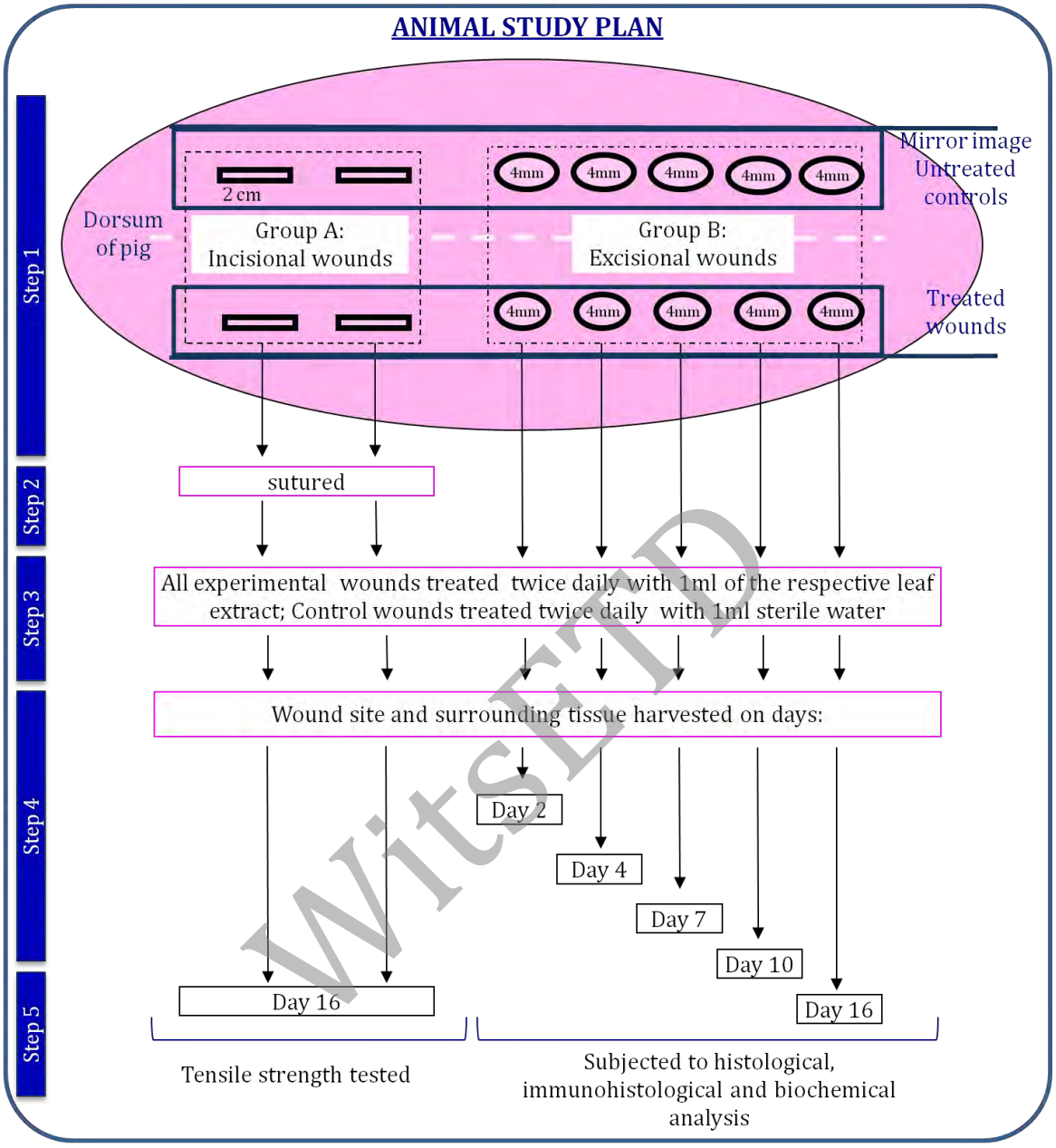

WitsETD

Figure 2.2: Flow diagram of animal experiments

The day on which the wounds were created is referred to as day 0. The wounds were treated with 1ml of the corresponding leaf extract applied topically to the wound twice a day (treated, n=6 for each harvest day). At this time 1ml of sterile water was applied to the respective untreated wounds (untreated, n=6 for each harvest day). All

created with nitroPDF professional
download the free trial online at nitropdf.com/professional

wounds were covered with Opsite® and secured with Elastoplast® and a veterinary sock. This was to prevent the wounds becoming soiled and being infected as the pigs were prone to rolling on the sty floor. The leaf gels were applied and dressings were changed daily. Each of the pigs was housed individually and received food and water *ad libitum*.



Figure 2.3: Representative photographs of
***a**: wounds created on dorsal surface of a pig; **b-d**: tissue being harvested*

The excisional wound together with a uniform perimeter of surrounding tissue was harvested on the 2nd, 4th, 7th, 10th and 16th day after wounding (Fig. 2.3) following

WitsETD

created with nitroPDF professional
download the free trial online at nitropdf.com/professional

anaesthetising (as above for wound creation) of the pig. The outer margin of the excisional wounds was traced on transparent film immediately before harvesting. The excised tissue was then bisected; one half was stored at -70^{0}C for biochemical analysis and the other half was fixed in 10% buffered formalin (Appendix C1) for histological analysis. At the time of harvesting, a calibration tag was placed adjacent to the wound and all wounds were photographed with a Sony Photoshot® camera.

2.3.2 Analysis of the wound biopsies

2.3.2.1 Rate of contracture and period of re- epithelialisation

WitsETD

The time taken for full re-epithelialisation of the wound biopsies was noted. The time for the excisional wounds to 'close' was calculated from the digital photographs and the wound tracings. The wound tracings on the transparent film were scanned together with a mm-ruler for calibration of the image using Hewlett Packard PSC 1500 All-in-One Scanner®. Digitized images were captured and converted into TIFF format. The image was imported into the ImageJ® program (a free image processing and analysis software programme developed by NIH) and the area of the wound (mm^2) was calculated by tracing the wound edge manually. This was repeated three times for each wound tracing and the repeatability of the measurements tested for accuracy and repeatability using the Lin's Concordance Correlation Co-efficient Test (Lin, 1989). If the Lin's Concordance Correlation (P_c) value was less than 0.9, all the measurements were re-taken and re-analysed using Lin Concordance Correlation Co-

created with nitroPDF professional
download the free trial online at nitropdf.com/professional

efficient Test until a value between 0.9 and 1 was obtained. The mean of the three measurements was then used for statistical analysis.

The change in wound size over a period of 16 days was then calculated as the percentage of the original wound area that was created:

Area of wound created with the 4mm biopsy punch = *Wound area at Day 0*
$= \pi r^2$
$= 3.1415 \times 2^2$
$= \mathbf{12.57mm^2}$

Therefore,

$$\%\ change\ in\ wound\ re\text{-}epithelialised = \frac{Wound\ area\ at\ day\ 0 - Wound\ area\ at\ Day\ X}{Wound\ area\ at\ day\ 0} \times 100$$

$$= \frac{12.57mm^2 - wound\ area\ at\ day\ X}{12.57mm^2} \times 100$$

WitsETD

2.3.2.2 Measurement of tensile strength

The tensile strength of the treated and untreated incisional wounds harvested on day 16 was examined using a method adapted from Shukla *et al.* (1999) and Cho-Lee and Moon (2003). The *TA. XT. Plus* Texture Analyser® system housed in the School of Therapeutic Sciences at the University of the Witwatersrand, was used to measure the maximum force and time taken for the skin samples harvested on day 16 to snap or break. This system provides a mechanical test frame fitted with pneumatic clamps.

created with nitroPDF professional
download the free trial online at nitropdf.com/professional

The harvested 16 day incisional wounds were trimmed into strips that were 20mm long and 2mm wide with the area of the original wound lying lengthwise in the middle of the sample. The TA. XT. plus Texture Analyser® system was calibrated with a 5kg load and a 10mm distance between the upper and lower clamp surfaces at the start of testing. The skin strips were then mounted securely into the upper and lower clamps (Fig. 2.4). The skin sample was then stretched for 0.19 seconds (this time period was determined from calibrating the system at a 10mm distance between the clamps). The stretch distance and maximum force tolerated by each skin sample was recorded.

WISETD



Figure 2.4: Photograph of a day 16 incisional wound skin sample mounted on the TA. XT. plus Texture Analyser® system

created with nitroPDF professional
download the free trial online at nitropdf.com/professional

2.3.2.3. Biochemical analyses of the excisional wounds

The excised tissue was biochemically analysed to estimate the total amount of collagen (hydroxyproline), hexosamine, protein and DNA present in the treated and untreated wound tissue as detailed below and each of these tests were repeated six times, except for the estimation of collagen which was repeated five times.

a. Estimation of collagen (hydroxyproline)

Hydroxyproline is a basic constituent of collagen (Shukla *et al.,* 1999). The collagen content of the granulation tissue was determined by estimating hydroxyproline content, as described by Woessner (1961) and modified by Switzer (1991) and Reddy and Enwemeka (1996).

WitsETD

The wet tissue samples were weighed and 0.02g of each sample was homogenised in 50µl of 0.9% saline (Appendix B1) which was then vortexed with 50µl of 10M NaOH. The resulting solution was autoclaved at 120^{0}C for 20 minutes. The hydrolysis solution (100µl) was then transferred into eppendorf tubes and mixed with chloramine-T reagent (Appendix B2). This was then incubated for 25 minutes at room temperature. Thereafter, 500µl freshly prepared p-dimethylamino-benzaldehyde (Ehrlich's reagent) solution (Appendix B3) was added and incubated for 20 minutes at 60°C. Following incubation, 150µl of each solution was transferred to a 96-well microplate and read at an absorbance of 550nm using a spectrophotometer.

created with nitroPDF professional
download the free trial online at nitropdf.com/professional

Hydroxyproline content was determined by comparing the amount obtained from the skin samples with a standard curve. The standard curve was obtained by using serial dilutions of 1mg hyroxyproline in 1ml of assay buffer solution. An example of the standard curve obtained from the absorbance values of the hydroxyproline is shown in figure 2.5. This was repeated six times for each wound tissue sample. The change in the collagen content of the treated and untreated groups was expressed as a ratio.

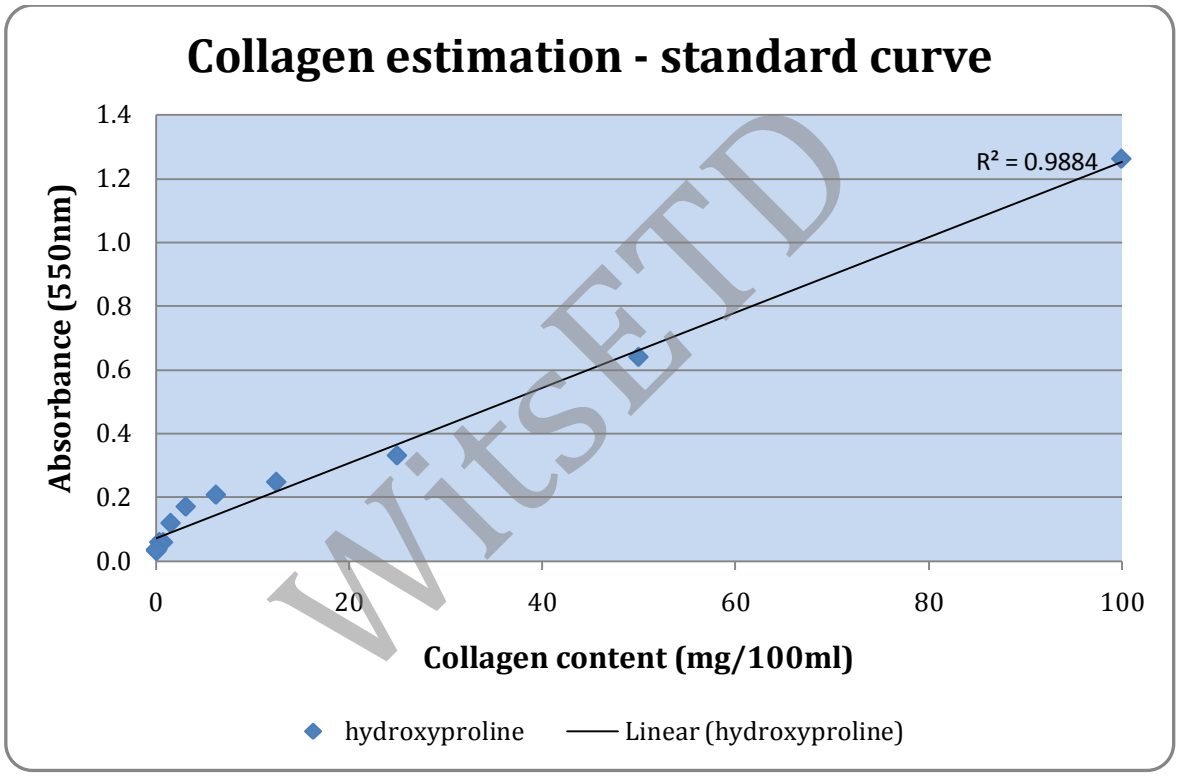

WitsETD

Figure 2.5: Representative graph of the standard curve obtained for estimation of collagen concentration from the hydroxyproline standard (1mg/100ml)

created with nitroPDF professional
download the free trial online at nitropdf.com/professional

b. Estimation of hexosamine

Hexosamine levels will decrease as collagen accumulates (Dunphy and Udupa, 1955) and is therefore used to deduce the increase in collagen concentrations in the tissue.

The hexosamine content of the granulation tissue was estimated by a modified Elson-Morgan reaction developed by Rondle and Morgan (1955) and modified by Levvy and McAllan (1959).

The *B. natalensis*- and *B. frutescens*-treated and untreated wound tissue for each of the biopsy days was dissected and 0.02g was weighed, homogenised in 50µl saline and then vortexed with 50µl NaOH. This solution was then autoclaved at 120^{0}C for 20 minutes. Thereafter, 100µl of the solution was transferred into eppendorf tubes and 20µl of potassium tetraborate (Appendix C1) was added. This solution was then vortexed and heated in boiling water for 3 minutes before cooling in tap water. Following cooling, 600µl of p-dimethylamino-benzaldehyde solution (Ehrlich's reagent) (Appendix C2) was added to each solution, thoroughly mixed and then placed in a 37^{0}C water bath for 20 minutes. The solution was then cooled in running tap water and the absorbance was measured at 530nm using a spectrophotometer. The amount of hexosamine of each sample was extrapolated using a standard curve for hexosamine. The standard curve was obtained by using serial dilutions of 0.1% N-acetylglucosamine (Appendix C3) made in assay buffer solution.

WitsETD

created with nitroPDF professional
download the free trial online at nitropdf.com/professional

The technique was repeated six times for each wound tissue sample. The change in the hexosamine content of the treated and untreated (control) groups was expressed as a ratio.

c. Estimation of protein (Lowry protein assay)

B. natalensis- and *B. frutescens*-treated and untreated wound tissue for each of the biopsy days was dissected and weighed to 0.2g. The tissue was then homogenised with 5ml of homogenising buffer (Appendix D1) with DTT and protease inhibitor cocktail stock (Sigma-Aldrich Co., USA). This was done slowly to prevent foaming by limiting the amount of air entering. The homogenised solution was centrifuged at 12 000 rpm for 20 minutes at 4^0C. The supernatant was gently aliquoted into 200µl aliquots that were stored at -70^0C until used.

WitsETD

The total protein content of each sample was then determined by using the Lowry protein assay. The assay is based on the addition of the folin phenol reagent which forms a complex with protein and copper thus resulting in a colour change (from yellow to blue) (Hartree, 1972).

Bovine serum albumin (BSA) was used as the standard for the protein assays. A working stock solution was made of 2000µg BSA in 1000µl of PBS (pH 7.4). A serial dilution of the stock solution was then carried out in the respective wells of an ELISA 96 well-microtiter plate. The protein samples of the treated and untreated tissue were diluted in PBS (1:20) prior to testing. In the respective wells of the plate, 50µl

created with nitroPDF professional
download the free trial online at nitropdf.com/professional

of the diluted protein sample and 200µl of reagent A (sodium carbonate with copper sulphate and sodium potassium tartrate) (Appendix D2) was added. This was incubated for 10 minutes at room temperature on a shaker. Thereafter, 50µl of Folin reagent (Appendix D2) was added and incubated for 30 minutes on a shaker. The absorbance of the solutions in the microtiter plate was read at an absorbance of 690nm using as Labsystems Multiskan Ascent® (Amersham Pharmacia Biotech, Burkinghamshire, UK). A standard curve was created by plotting the absorbance values of the BSA standards against their concentrations. The protein concentration of the samples was then extrapolated from the graph and multiplied by the dilution factor.

This was repeated six times for each wound tissue sample. The change in the protein content of the treated and untreated (control) groups was expressed as a ratio.

WitsETD

d. Estimation of total DNA content

The protein and DNA content of granulation tissue indicates the levels of protein synthesis and cellular proliferation. Higher protein and DNA content will indicate cellular proliferation and suggest an increase in the synthesis of collagen. According to Chithra *et al.* (1998b), the collagen/DNA ratio in granulation tissue may be taken as the index of the synthesis of collagen per cell in the wound area.

DNA content was extracted from the *B. natalensis*- and *B. frutescens*-treated and untreated wound tissue for each of the biopsy days using the phenol-chloroform

created with nitroPDF professional
download the free trial online at nitropdf.com/professional

method. Tissue (0.02g) from the treated and untreated (control) wounds was placed in sterile eppendorf tubes together with 200µl lysis buffer (Appendix E1) and 20µl of Proteinase K (Appendix E2). This was then incubated overnight on a heat block at 55^{0}C. The solutions were then heated on the heat block at 85^{0}C for 10 minutes. Thereafter, 400µl of a phenol-chloroform mixture (Appendix E3) was added and vortexed. This solution was centrifuged for 3 minutes and 12 000rpm. The upper phase in each eppendorf was then carefully removed with a sterile pipette and transferred to a new sterile labeled eppendorf. In this step, it was important not to remove the protein layer at the interface. The phenol-chloroform mixture (400µl) was then added and the mixture centrifuged for 3 minutes at 12000rpm. Again, the aqueous upper phase was carefully pipetted into a sterile labeled eppendorf containing 40µl of 3M sodium acetate and 280µl isopropanol. The eppendorf tubes were then centrifuged at 14 000rpm for 30 minutes. A small pellet was visible at the bottom of each eppendorf tube. The supernatant was then carefully pipetted off and discarded. Thereafter, 500µl of 70% ethanol was added and the tube was centrifuged for 2 minutes. The ethanol was removed from the tube and the pellet allowed to dry for 2 minutes at 65^{0}C. The pellet was then resuspended in 100µl MilliQ™ water and incubated on a heat block at 65^{0}C for 10 minutes.

The total amount of DNA in each of the samples was then measured in triplicate using a Thermo Scientific NanoDrop™ 1000 Spectrophotometer.

WitsETD

created with nitroPDF professional
download the free trial online at nitropdf.com/professional

2.3.2.4. Histological analyses of the excisional wounds

Serial sections (4µm thick) of paraffin-embedded treated and untreated porcine tissue mounted on silane coated slides (Appendix F1) were prepared for histology and immunohistochemistry.

a. Haemotoxylin and eosin stain

In order to compare the histology of the treated and untreated wound tissue, every sixth section was deparaffinised in xylene and rehydrated in a series of graded alcohols. These sections were then stained with haemotoxylin and eosin (Appendix F2). Haemotoxylin and eosin are widely used as stains for general morphology. The haemotoxylin stain is a basophilic stain which stains cell nuclei blue-black while the eosin stain is an eosinophilic stain which stains the cytoplasm and connective tissue fibres in shades of pink, orange and red (Bancroft and Gamble, 2002). The layers of the epidermis and dermis were studied to describe the regeneration of the epidermis.

b. Mallory's trichrome stain

In order to compare the deposition of collagen in the treated and untreated wound tissue, sections were deparaffinised in xylene and rehydrated in a series of graded alcohols. These sections were then processed with three stains: 1% acid fuschin, 5% phosphotungstic acid water and the Mallory's mixture. This trichromatic stain colours collagen and reticular fibres deep blue, nuclei and smooth muscle red, elastic fibres pink, red blood cells and myelin orange.

WiseTD

created with nitroPDF professional
download the free trial online at nitropdf.com/professional

For collagen deposition studies in the wound area, the faintest traces of staining reaction, hyalinization, and irregular arrangement of collagen bundles were considered as +, while the most intense reaction and compactly arranged collagen bundles were considered as +++. Two areas in each section (of the six treated and six untreated sections per treatment day) were assessed for neo-vascularization and fibroblast proliferation.

WitsETD

created with nitroPDF professional
download the free trial online at nitropdf.com/professional

2.3.2.5. Immunohistochemical analyses of the excisional wounds

a. Immunolocalisation of smooth muscle actin

Formalin fixed, paraffin embedded tissue was sectioned at 4µm and mounted on to silane coated slides (Appendix G1) for immunohistochemistry. The sections were then dewaxed in xylene and passed through a series of graded alcohols before washing in running tap water for 5 minutes. The sections were then incubated with 3% hydrogen peroxide in H_2O for 30 minutes to block endogenous peroxidase activity. After triple washing of the sections in PBS (pH7.6) (Appendix G2) for 5 minutes each, the sections were incubated in a humid chamber with 20% normal rabbit serum in PBS to block non-specific binding. Monoclonal anti-smooth muscle actin (SMA) antibody was obtained from Santa Cruz Biotechnology. A series of dilutions was carried out to determine the optimal concentration of the antibody using mouse heart as the control tissue. Animal ethics approval for the use of the mouse heart tissue was granted by the Animal Ethics Committee of the University of the Witwatersrand, Johannesburg (AEC# 2007232A). The sections were then incubated in a humid chamber at room temperature with the primary antibody (anti-smooth muscle actin) at a dilution of 1:200 made up in 3% BSA-PBS for 60 minutes.

After washing the section three times in PBS, the sections were incubated in a secondary antibody (mouse immunoglobulins from Dako, Denmark) at a concentration of 1:50 for 30 minutes in a humid chamber. The sections were washed three times in PBS and then incubated with a strepavidin horseradish peroxidase

WitsETD

created with nitroPDF professional
download the free trial online at nitropdf.com/professional

complex (Dako, Denmark) at a dilution of 1:500 in BSA-PBS (Appendix G3) for 30 minutes. The sections were then washed three times in PBS and stained with the chromagen, diaminobenzidine (DAB) (Dako, Denmark) (Appendix G4) for 5 minutes, followed by washing in running tap water for 5 minutes. Sections were counterstained with Mayer's haematoxylin for 20 seconds and washed for a further 5 minutes. The sections were then passed through a series of graded alcohols and xylene before coverslipping with entellan.

b. Immunolocalisation of VEGF

WitsETD

Formalin fixed, paraffin embedded tissue was sectioned at 4µm and mounted on to silane coated slides for immunohistochemistry. The sections were then dewaxed in xylene and passed through a series of graded alcohol before washing in running tap water for 5 minutes. Antigen retrieval was carried out by microwaving the sections in citrate buffer (pH 6) (Appendix G5) twice for 5 minutes and then cooling at room temperature for 20 minutes. The sections were then incubated with 3% hydrogen peroxide in H_2O for 30 minutes to block endogenous peroxidase activity. After triple washing of the sections in PBS (pH7.6) for 5 minutes each, they were incubated in a humid chamber at room temperature with 10% normal rabbit serum in PBS to block non-specific binding. Primary mouse monoclonal VEGF antibody (sc-7269) was obtained from Santa Cruz Biotechnology. A series of dilutions was carried out to determine the optimal concentration of the antibody using human breast cancer as the control tissue. Human ethics approval (M050521) for the use of the breast carcinoma tissue was granted by the Human Ethics Research Committee of the

created with nitroPDF professional
download the free trial online at nitropdf.com/professional

University of the Witwatersrand, Johannesburg. The sections were then incubated in the primary antibody at a dilution of 1:50 made up in PBS overnight at 4^0C. After washing the sections three times in PBS, they were incubated in a secondary antibody (rabbit anti-mouse antibody, Dako, Denmark) at a dilution of 1:300 made up in PBS for 30 minutes in a humid chamber at room temperature. The sections were washed three times in PBS and then incubated with a strepavidin horseradish peroxidase complex (Dako, Denmark) at a dilution of 1:300 in BSA-PBS for 30 minutes. These were then washed three times in PBS and stained with the chromagen, DAB (Dako, Denmark) for 5 minutes, followed by washing in running tap water for 5 minutes. Sections were counterstained with Mayer's haematoxylin for 20 seconds and washed for a further 5 minutes. The sections were then dehydrated through a graded series of alcohols and cleared in xylene before coverslipping with entellan.

WitsETD

c. Anti- TGFβR$_I$ and Anti- TGFβR$_{II}$

Formalin fixed, paraffin embedded tissue was sectioned at 4µm and mounted on to silane coated slides for immunohistochemistry. The sections were then dewaxed in xylene and passed through a series of graded alcohol before washing in running tap water for 5 minutes. Antigen retrieval was carried out by microwaving the sections in citrate buffer (pH 6) (Appendix G5) twice for 5 minutes and then cooling at room temperature for 20 minutes. The sections were then incubated with 0.3% hydrogen peroxide in H_2O for 20 minutes to block endogenous peroxidase activity. After triple washing of the sections in Tris Buffered Saline (TBS) (pH7.6) (Appendix G6) for 5 minutes each, they were incubated in a humid chamber at room temperature with 10% normal goat serum in TBS to block non-specific binding. TGBβR$_I$ and TGBβR$_{II}$

created with nitroPDF professional
download the free trial online at nitropdf.com/professional

antibodies (sc-398 and sc-220) were obtained from Santa Cruz Biotechnology. A series of dilutions was carried out to determine the optimal concentration of the antibody using 4µm paraffin embedded sections of mouse ovary as the control tissue. Animal ethics approval (2004/100/4) for the use of the mouse ovary tissue was granted by the Animal Ethics Research Committee of the University of the Witwatersrand, Johannesburg. The sections were then incubated in either the TGBβR$_I$ or the TGBβR$_{II}$ primary antibody at a dilution of 1:25 made up in TBS overnight at 4^{0}C. After washing the sections three times in TBS, they were incubated in a secondary antibody (goat anti-rabbit antibody, Dako, Denmark) at a dilution of 1:300 made up in TBS for 30 minutes in a humid chamber at room temperature. The sections were washed three times in TBS and then incubated with a strepavidin horseradish peroxidase complex (Dako, Denmark) at a dilution of 1:300 in BSA-PBS for 30 minutes. These were then washed three times in TBS and stained with the chromagen, DAB (Dako, Denmark) for 5 minutes, followed by washing in running tap water for 5 minutes. Sections were counterstained with Mayer's haematoxylin for 20 seconds and washed for a further 5 minutes. The sections were then dehydrated through a graded series of alcohols and cleared in xylene before coverslipping with entellan.

WitsETD

d. Controls for immunohistochemistry

Negative controls for all the immunohistochemistry were prepared using adjacent wound tissue sections which were treated identically as above except that the primary and secondary antibodies were respectively replaced with the buffer (PBS for αSMA and VEGF, and TBS for TGFβR$_I$ and TGFβR$_{II}$).

created with nitroPDF professional
download the free trial online at nitropdf.com/professional

Formalin fixed paraffin embedded mouse heart (Animal ethics clearance # 2007 232A), human breast carcinoma tissue (Human ethics clearance # M05052) and mouse ovary (Animal ethics clearance # 2004/100/4)were prepared as described above and were used as the positive control for α-smooth muscle actin, VEGF and TGFβR_I and TGFβR_{II} immunolocalisation, respectively.

WitsETD

created with nitroPDF professional
download the free trial online at nitropdf.com/professional

2.4 An *in vivo* human study of the effects of *B. natalensis*- and *B. frutescens*-treated wounds compared to untreated wounds

Ethical clearance for this part of the study was obtained from the Human Ethics committee of the University of the Witwatersrand (Human ethics clearance # M050108). Female adult patients presenting with bilateral superficial skin lesions at the Stoma Clinic at Helen Joseph Hospital and at the Dermatology Clinic at the Charlotte Maxeke Johannesburg Academic Hospital (at the time of the study, known as the Johannesburg General Hospital) were invited to participate in this study. Patients with chronic skin lesions, cancerous lesions and with associated medical conditions known to affect wound healing such as diabetes mellitus and vascular diseases, were excluded from this study. Each potential participant was given an overview of the study using the Subject Information Sheet (Appendix H1). Six patients from the Dermatology Clinic at the Johannesburg General Hospital initially agreed to participate in this part of the study by signing as informed consent form (Appendix H2). Of these, two were from the "Coloured" and four from indigenous African population groups. Most patients at both clinics from indigenous African population groups refused to participate in this study preferring to use conventionally accepted 'Western' medication for their lesions.

A digital photograph of both skin lesions of each patient was taken at the time of the first meeting. The leaf gel extract was then given to the patient in a colour-coded-

WitsETD

created with nitroPDF professional
download the free trial online at nitropdf.com/professional

bottle with directions on how to apply the gel. No information of the plant source appeared on the bottle. The patient was instructed to treat one lesion with the extract and to leave the second lesion untreated for seven days. At the end of the seven days, the patient was instructed to return to the clinic to obtain a second bottle of the leaf gel extract and for a follow-up digital photograph of the skin lesion. The digital photographs were then used to compare the re-epithelialisation of the treated and untreated lesions.

STATISTICAL ANALYSIS

In this study, the Student's t-test and a one way analysis of variance (ANOVA) tests ($p \geq 0.05$) were used for the comparison between two means and to thus establish statistically significant differences between the treated and untreated groups and between the *B. natalensis* and *B. frutescens* treated groups. SPSS® for Windows Version 16.0 and Microsoft Excel® were used to perform all statistical tests.

All cell culture and biochemical tests were repeated six times. The results are expressed as a mean ± standard deviation (SD) of the mean of the absorbance values.

WitsETD

created with nitroPDF professional
download the free trial online at nitropdf.com/professional

3. RESULTS

3.1 An *in vitro* study of the effects of *B. natalensis* and *B. frutescens* on human epidermal keratinocytes and dermal fibroblasts

The result of each of the assays used in the cell culture studies is detailed below. For ease of reading and reporting, cultures that were treated with either *B. frutescens* or *B. natalensis* are referred to as treated cultures. The control cultures that were not treated with the plant leaf gel extracts are referred to as untreated cultures. The average pH of the leaf gels of *B. frutescens* and *B. natalensis* used in all experiments was 4 and 5, respectively.

WitsETD

a. MTT assay

In general, the results of the MTT assay revealed that the leaf gel extract of *B. frutescens* and *B. natalensis* was not cytotoxic to either the keratinocyte or the fibroblast cultures (Figs. 3.1 and 3.2).

For the HaCaT keratinocyte cell cultures, there was no significant difference between *B. natalensis*-treated and the untreated cultures (p=0.96). In contrast, at higher concentrations, the *B. frutescens*-treated keratinocytes showed significantly more non-viable cells when compared to the corresponding untreated cultures (p=0.01). This was particularly noted at concentrations greater than 100µl/ml (Fig. 3.1). In the keratinocyte cultures, an effect greater than 100% of the untreated cultures was seen

created with nitroPDF professional
download the free trial online at nitropdf.com/professional

at a concentration of 0.1µl/ml for *B. frutescens* and, 0.1, 5 and 100-300µl/ml for *B. natalensis* (Fig. 3.1).

In the dermal fibroblast cultures, the effect of the treatment with *B. natalensis* and *B. frutescens* was not significantly different from that of the untreated cultures (p=0.94 and p=0.24, respectively). An effect greater than 100% of the untreated fibroblast cultures was seen at concentrations of 0.1µl/ml of *B. frutescens* and 200 and 300µl/ml of *B. natalensis* (Fig. 3.2) in the treated cultures.

When comparing the cytotoxic effect of the leaf gel extracts between the cell lines (i.e. *B. frutescens* on keratinocyte and fibroblast cultures and similarly, *B. natalensis* on keratinocyte and fibroblast cultures), there was no significant difference in the effect of *B. frutescens* (p=0.11) and *B. natalensis* (p=0.29) on each of the cell lines tested.

WitsETD

However, when comparing the effect of the two gel extracts on a particular cell line (i.e. *B. frutescens* and *B. natalensis* on keratinocytes, and *B. frutescens* and *B. natalensis* on fibroblasts), the difference in the effect of the two extracts was statistically significant in the keratinocyte cell cultures (p=0.02) but not in the fibroblast cell cultures (p=0.94). The effect of *B. frutescens* on the keratinocyte cell line was dose dependant, increasing as the concentration increased while the effect of *B. natalensis* was more constant with a peak 0.1 and 100-200µl/ml.

created with nitroPDF professional
download the free trial online at nitropdf.com/professional

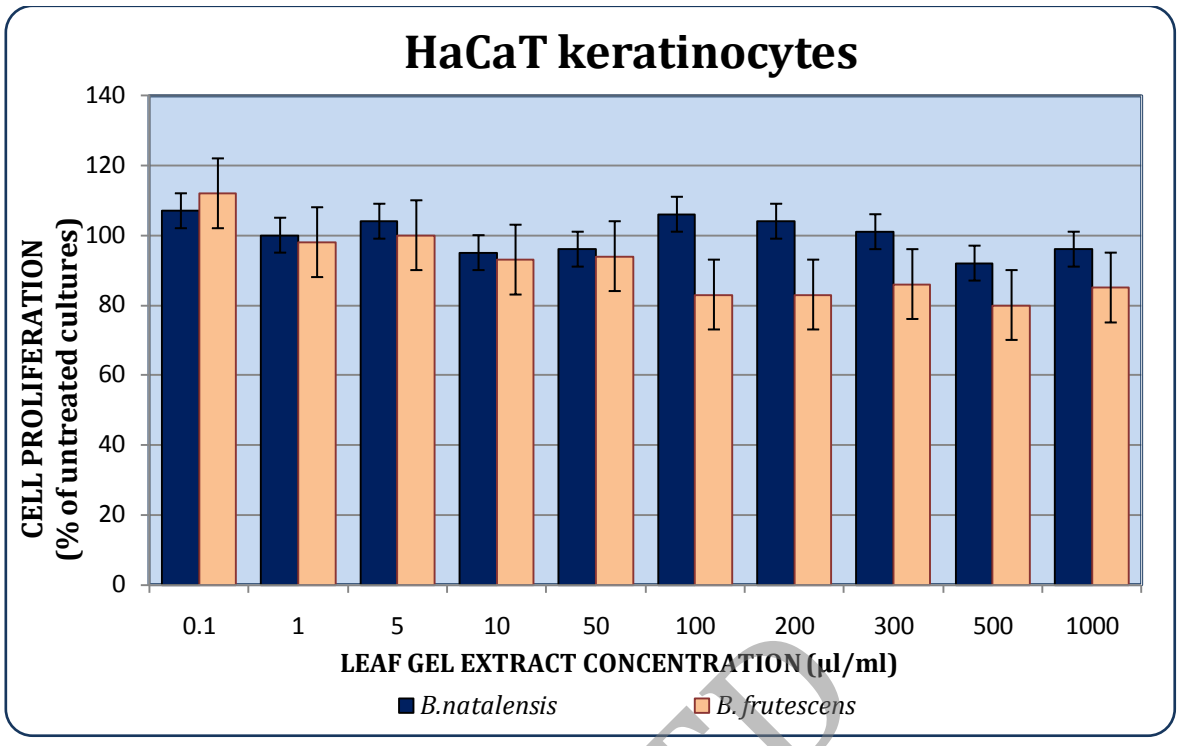

Figure 3.1: MTT assay – the effect of B. frutescens and B. natalensis on HaCaT keratinocytes (n=6 for each plant leaf gel)

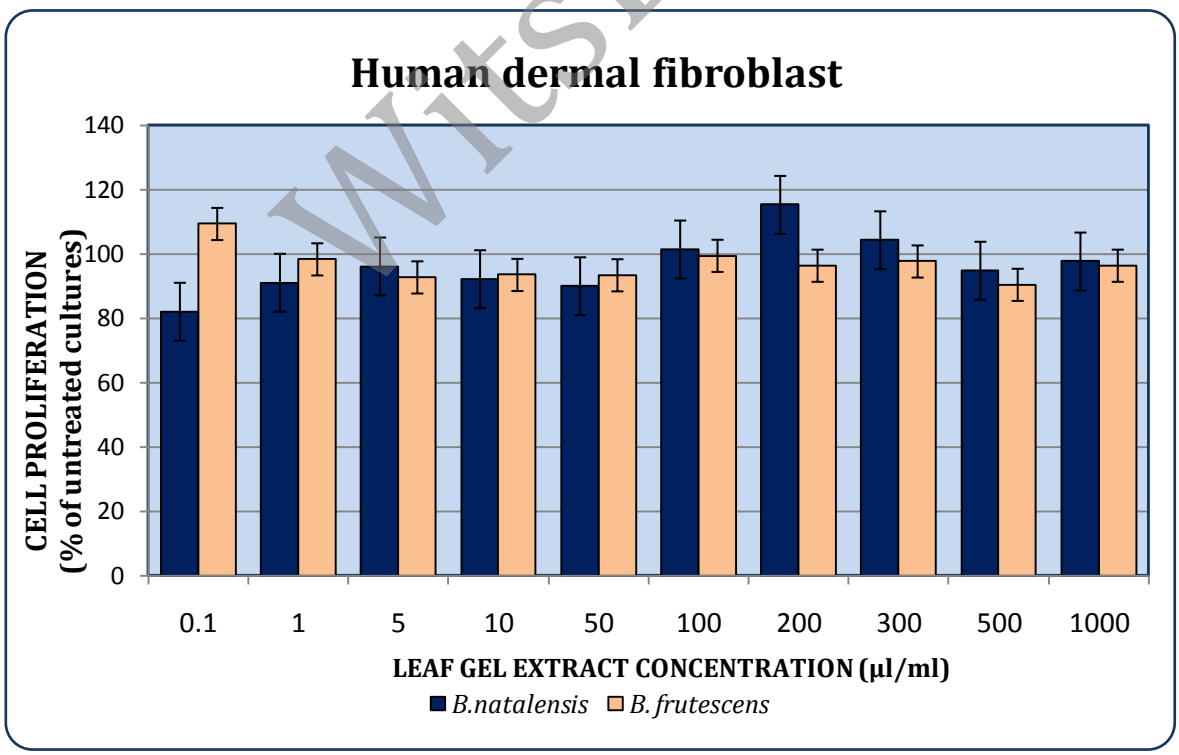

Figure 3.2: MTT assay – the effect of B. frutescens and B. natalensis on human dermal fibroblasts (n=6 for each plant leaf gel)

WitsETD

created with nitroPDF professional
download the free trial online at nitropdf.com/professional

b. WST-1 Assay

The cell numbers for both the keratinocyte and fibroblast cell lines was significantly greater at all concentrations of *B. frutescens* and *B. natalensis* than for the untreated cultures (Figs. 3.3 and 3.4).

In the dermal fibroblast cultures, the greatest effect of treatment with *B. frutescens* on cell number was seen at a concentration of 50µl/ml (Fig. 3.3). This was followed by a gradual decrease as the concentration of the extract increased. In contrast, *B. natalensis* had the greatest effect on cell number at concentrations between 300 and 400µl/ml (Fig. 3.3). Thereafter, there was a slow decrease in cell number. On average, the cell number for the *B. frutescens* and *B. natalensis*-treated fibroblast cultures was 4.6 and 5.2 times that of the untreated (control) cultures. There was no significant difference between the effect of the two leaf gels on the dermal fibroblast cultures ($p=0.51$).

WitsETD

In contrast, in the keratinocyte cultures, the proliferative effect of *B. frutescens* mirrored that of *B. natalensis* in that there was a gradual increase in cell number, reaching a maximum at the 400µl/ml concentration (Fig. 3.4). This was followed by a gradual decrease in cell number. On average, the cell number for the *B. frutescens* and *B. natalensis*-treated keratinocyte cultures was 5.1 and 4.9 times greater than that of the untreated cultures. There was no significant difference between the effect of the two leaf gels on the keratinocyte cultures ($p=0.83$).

There was also no significant difference in the effect of *B. frutescens* and *B. natalensis*

created with nitroPDF professional
download the free trial online at nitropdf.com/professional

between the two cell lines (p=0.55 and p=0.76, respectively).

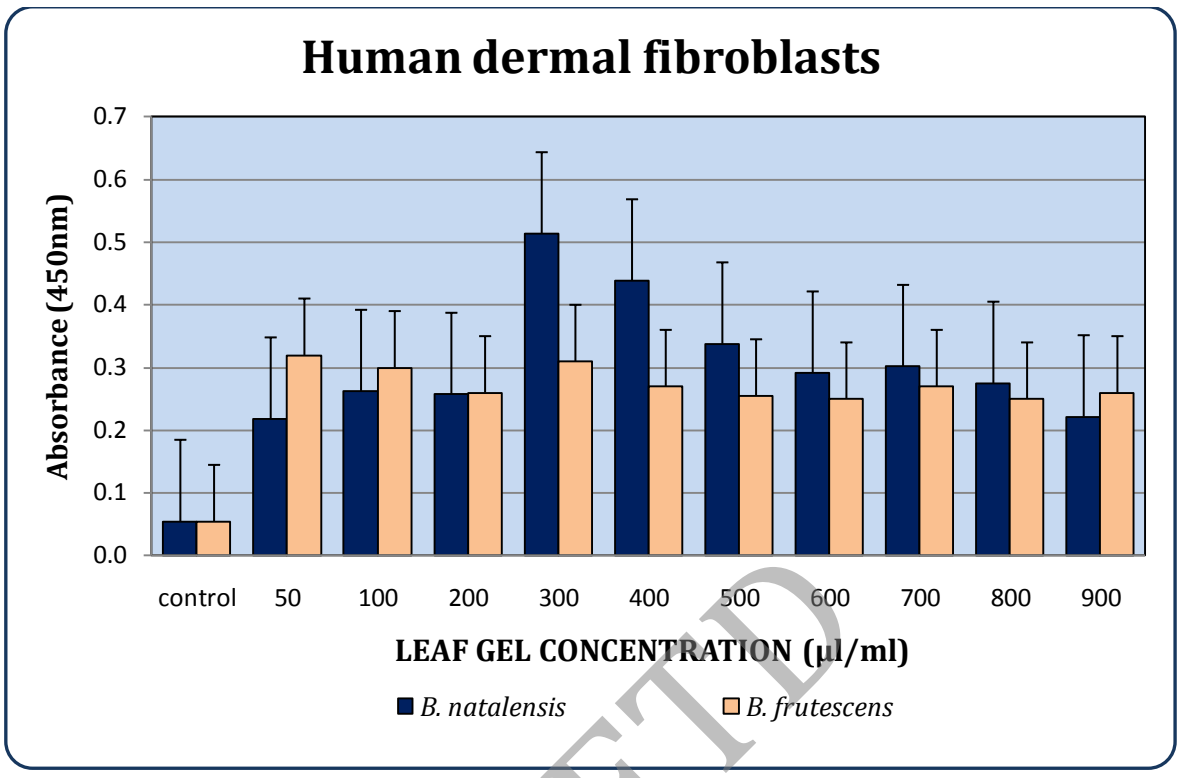

Figure 3.3: WST-1 assay –the effect of B. frutescens and B. natalensis on human dermal fibroblasts

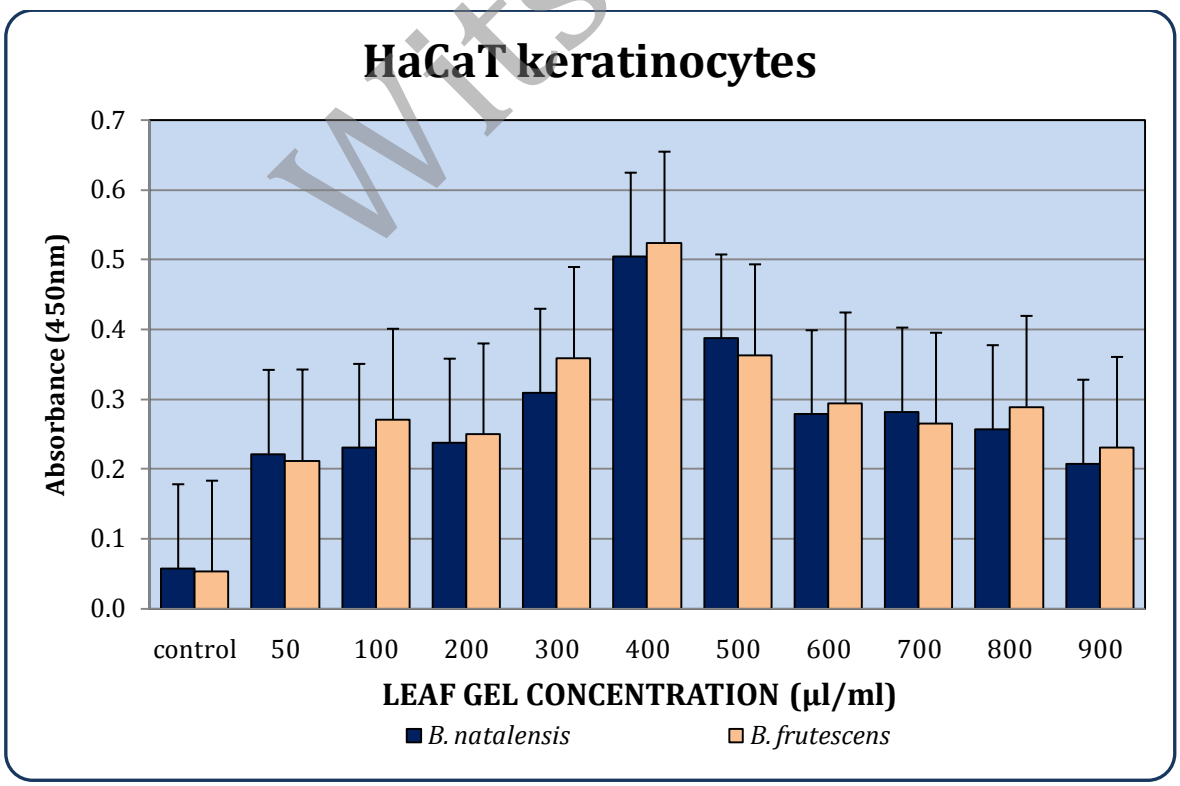

Figure 3.4: WST-1 assay – the effect of B. frutescens and B. natalensis on HaCaT

WitsETD

created with nitroPDF professional
download the free trial online at nitropdf.com/professional

c. BrdU Assay

The BrdU assay also demonstrated a statistically significant increase in cell proliferation at all concentrations for both the *B. frutescens* and *B. natalensis* extracts respectively, compared to the untreated cultures of both cell types (Figs. 3.5 and 3.6).

In the keratinocyte cell cultures, *B. natalensis* had the greatest effect on cell proliferation at a concentration of 400µl/ml (Fig. 3.5). In contrast, the effect of *B. frutescens* was greatest at 700µl/ml. At all of the other concentrations tested, the effect of *B. frutescens* was fairly constant. There was no significant difference between the effects of the two leaf gel extracts on the keratinocyte cell cultures ($p=0.41$).

The effect of the leaf gels on proliferation as shown by the BrdU assay was less pronounced in the fibroblast cell cultures. Both *B. natalensis* and *B. frutescens* exerted a maximum effect at 400µl/ml (Fig. 3.6). Again, there was no significant difference on proliferation of the fibroblast cell line between the two leaf gels on the fibroblast cell cultures ($p=0.77$).

There was also no significant difference between the effect of *B. natalensis* and *B. frutescens* on the keratinocyte and fibroblast cultures ($p=0.57$ and $p=0.67$, respectively).

WitsETD

created with nitroPDF professional
download the free trial online at nitropdf.com/professional

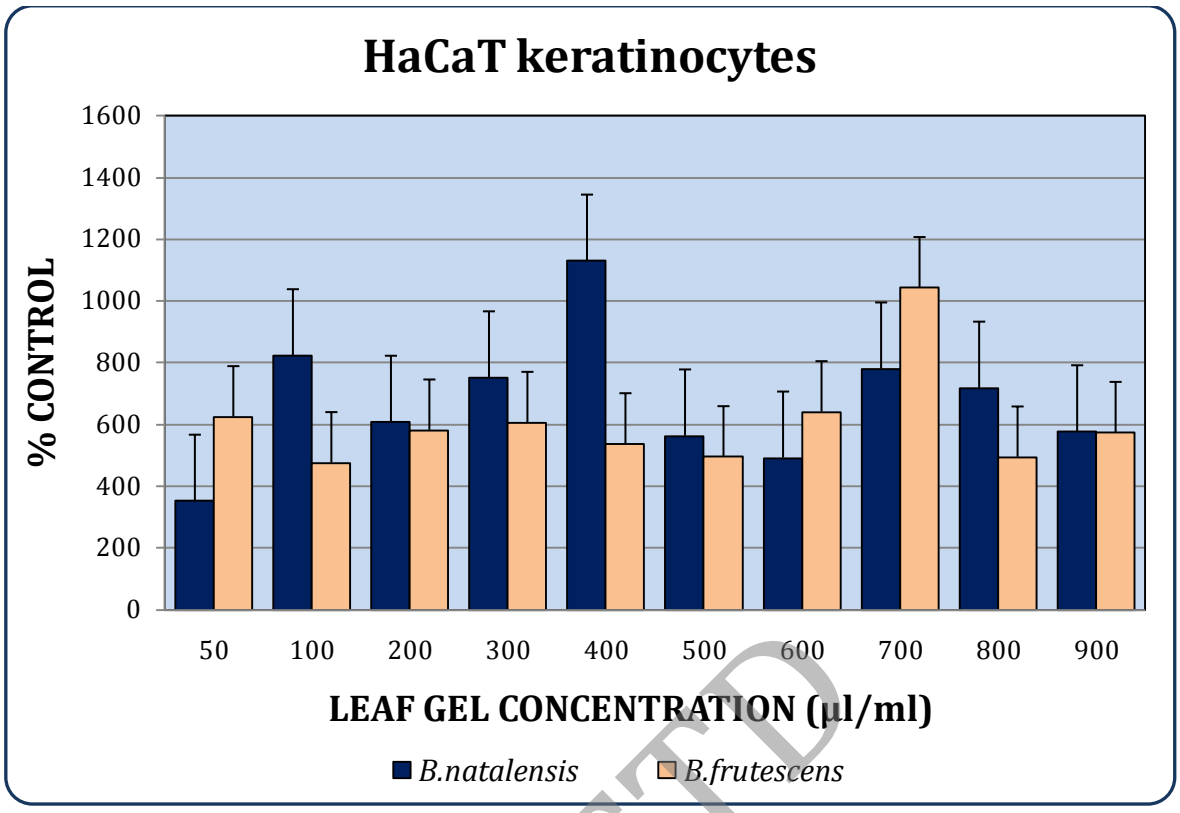

Figure 3.5: BrdU assay – the effect of B. frutescens and B. natalensis on HaCaT keratinocytes

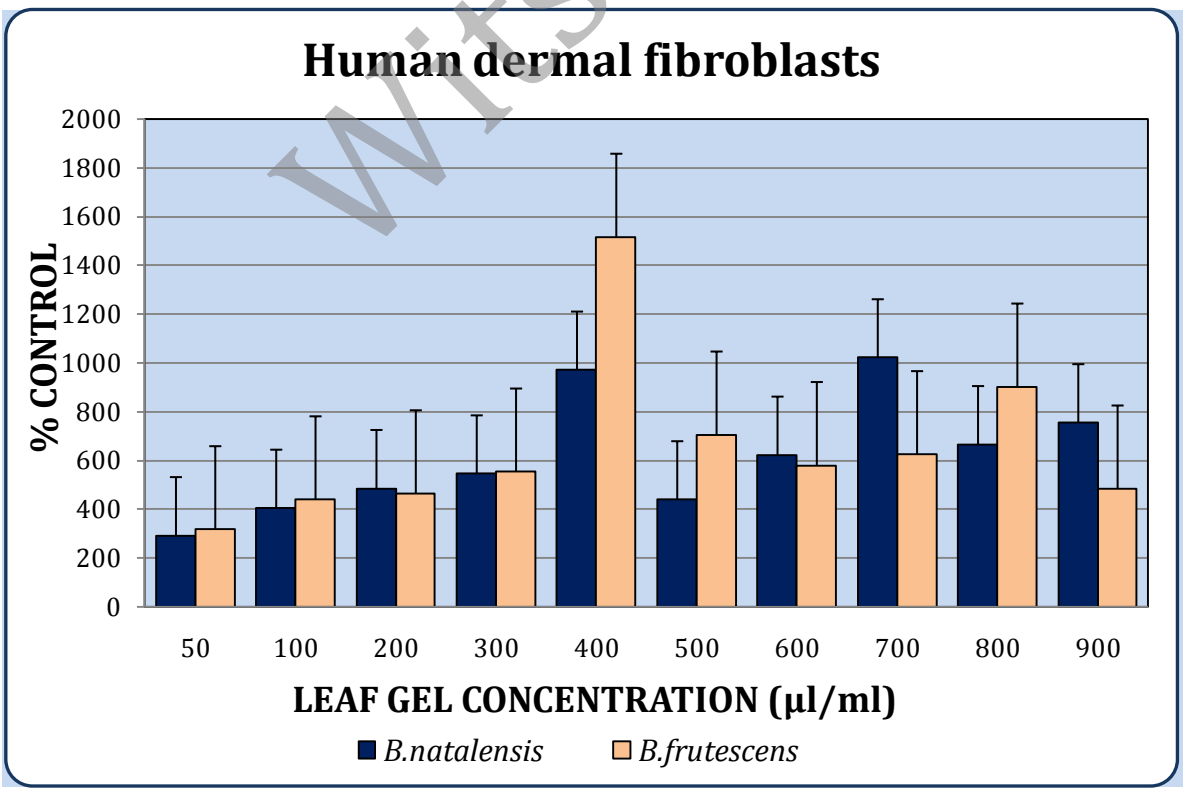

Figure 3.6: BrdU assay – the effect of B. frutescens and B. natalensis on human dermal fibroblasts

WitsETD

created with nitroPDF professional
download the free trial online at nitropdf.com/professional

d. Score assay

The score assay measures the time to 'closure of the wound'. HaCaT cultures were confluent at the time of scoring. In general, the cells were of uniform size and polygonal in shape with close cell-to-cell contacts (Fig. 3.7a). Immediately after scoring, the 'wound' area was clear of cells and had a uniform edge (Fig. 3.7b). The fibroblast cell cultures were also confluent at the time of 'wounding' (Fig. 3.8a). These cells were spindle shaped with a number of extended processes. The score edge that was created in these cultures was uniform with no cells in the scored area (Fig. 3.8b).

The keratinocyte cultures treated with *B. frutescens* (n=6) and *B natalensis* (n=6) closed within 32 hours, while the untreated scores (n=6) did not close at all in this time frame. In the keratinocyte cell cultures, the cells were not scattered in the score area (Fig. 3.7c and e). The scores appeared to close by the displacement of the score edges closer to each other due to cell proliferation on either side of the score.

In general, the scores created in the fibroblast cultures took longer (mean: 4 hours) than the keratinocyte cultures to 'close'. The fibroblast cultures treated with *B. frutescens* (n=6) 'closed' within 40 hours, while those cultures treated with *B natalensis* (n=6) 'closed' within 36 hours. The scores of the untreated cultures (n=6) were 'closed' by 48 hours. In the fibroblast cell cultures, the cells were found scattered in the score with the migrating cells lying in random directions (Fig. 3.8c and e). The migrating cells displayed long processes.

WitsETD

created with nitroPDF professional
download the free trial online at nitropdf.com/professional



Figure 3.7: Representative photomicrograph of a HaCaT keratinocyte score assay – ***a****, standard culture prior to scoring and treatment (x40);* ***b****, untreated score at 4 hours (x10);* ***c****, untreated score at 32 hours (x10);* ***d****, B. natalensis- treated score at 4 hours(x10);* ***e****, B. natalensis-treated score at 32 hours (x10). Arrows indicating cells entering the score area.*



Figure 3.8: Representative photomicrograph of a human dermal fibroblast score assay – ***a****, standard culture prior to scoring and treatment(x40);* ***b****, untreated score at 4 hours (x10);* ***c****, untreated score at 36 hours (x10);* ***d****, B. natalensis- treated score at 4 hours(x10);* ***e****, B. natalensis-treated score at 36 hours (x10). Arrows indicating cells entering the score area.*

created with nitroPDF professional
download the free trial online at nitropdf.com/professional

3.2 An *in vivo* animal study of the effects of *B. natalensis*- and *B. frutescens*-treated wounds compared to untreated wounds in pig skin

3.2.1 Rate of contracture and period of re-epithelialisation

Daily inspection of the wounds was conducted and no local adverse effects were noted on the surrounding skin of the pig or on hair growth, from the treatment with both leaf gel extracts or with the sterile saline. By day 16 hairs had sprouted from all wound sites. Scabs (eschar) formed on all wounds by day 2. Both treated and untreated wounds of all the pigs were fully re-epithelialised by day 7 (i.e. *B. natalensis*, n=6 and *B. frutescens*, n=3 pigs; untreated wounds, n=12). However, in 3 pigs treated with *B. frutescens,* complete re-epithelialisation occurred by day 4.

WitsETD

The area of the wounds treated with the leaf extracts was indistinguishable from the surrounding normal skin by day 10. This only occurred on day 16 in the case of the untreated wounds.

The percent of wound contraction for untreated wounds and *B. natalensis*- and *B. frutescens*-treated wounds are shown in figure 3.9. There was a significant increase in wound contraction in the *B. natalensis*-treated wounds when compared to the untreated wounds on days 2, 4 and 10 ($p=0.004$, $p=0.007$ and $p=0.03$, respectively). In the *B. frutescens*-treated wounds, a significant increase in wound contraction when

created with nitroPDF professional
download the free trial online at nitropdf.com/professional

compared to that of the untreated wounds was evident only on day 4 (p=0.004) (Fig. 3.9). There was no significant difference in the rate of contraction of the wound on any of the treatment days between the *B. natalensis*- and *B. frutescens*-treated wounds.

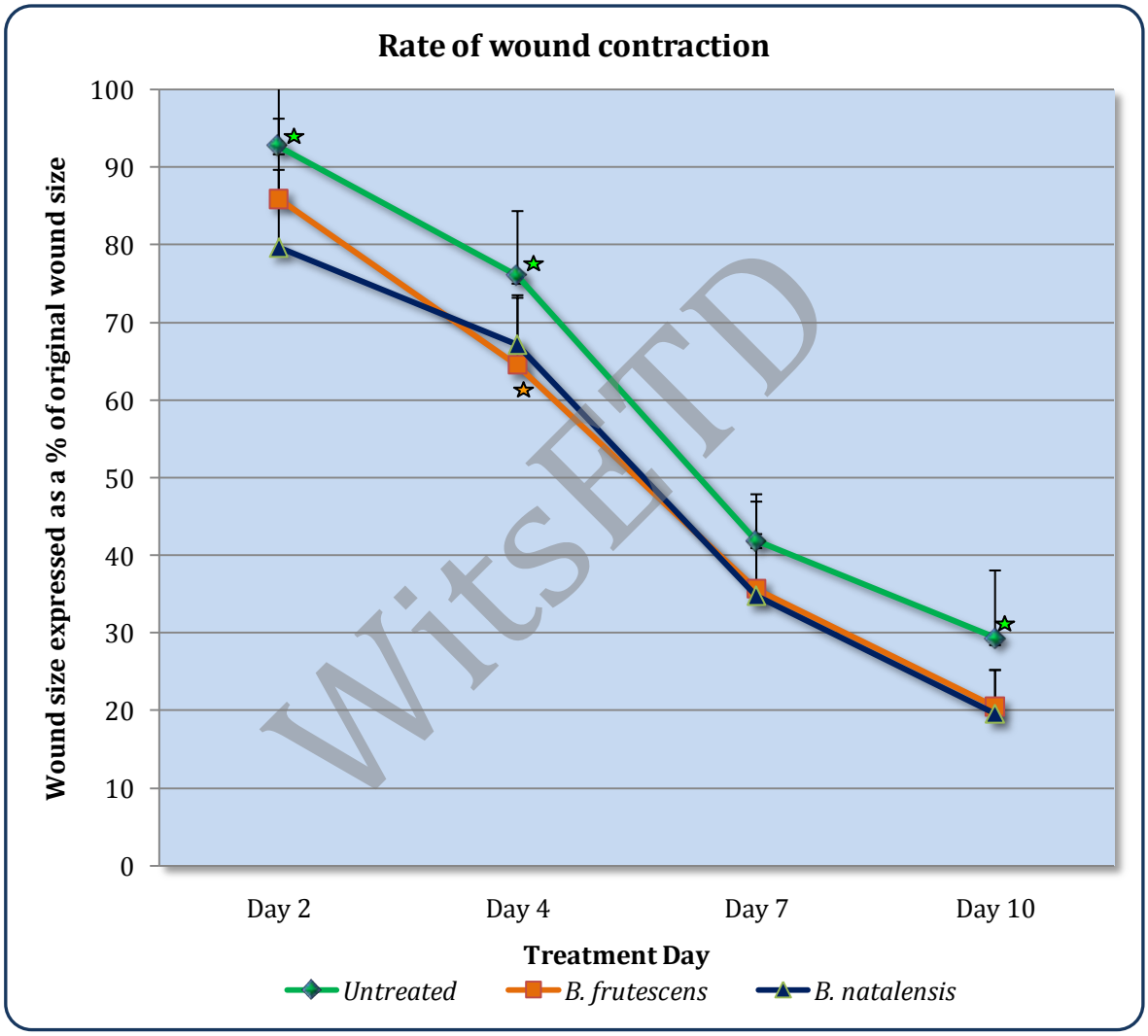

WitsETD

Figure 3.9: Percent of contraction for B. natalensis-treated, B. frutescens-treated and untreated wounds over the experimental period.
Note the ★ indicates significant differences between the treated and untreated wounds.

created with nitroPDF professional
download the free trial online at nitropdf.com/professional

3.2.2.2 Measurement of tensile strength

The tensile strength of the incisional wounds harvested on day 16 is shown in figure 3.10. The tensile strength of the wounds treated with *B. frutescens* and *B. natalensis* were significantly stronger than that of the untreated wounds (p=0.002 and p=0.019, respectively), with the *B. natalensis-treated* wounds being stronger than the *B. frutescens*-treated wounds (p=0.02). The stretch distance (mm) for the wounds over a period of 19 seconds was: untreated wounds, 10.82; *B. frutescens*-treated, 12.98 and *B. natalensis*-treated, 11.64, respectively. The stretch distance is an indication of the elasticity of the tissue. This implies that while the *B. natalensis*-treated wounds were stronger, the *B. frutescens*-treated wounds were more elastic than the *B. natalensis*-treated wounds because *B. frutescens*-treated wounds were able to stretch for a greater distance.

WitsETD

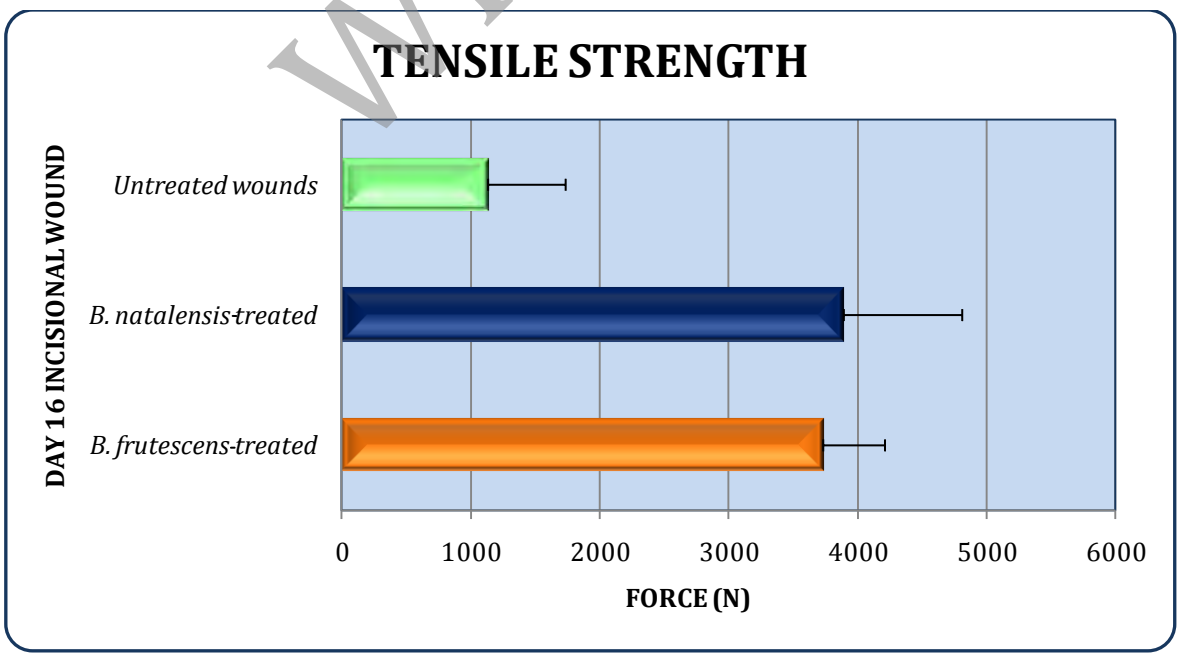

Figure 3.10: Tensile strength of incisional wounds at day 16

created with nitroPDF professional
download the free trial online at nitropdf.com/professional

3.2.2.3. Biochemical analyses of the excisional wounds treated with *B. natalensis* and *B. frutescens* compared to the untreated wounds

a. Estimation of collagen (hydroxyproline)

The collagen content in the granulation tissue of the treated and untreated wounds for *B. natalensis* and *B. frutescens* is shown in figures 3.11 and 3.12, respectively.

The mirror imaged untreated wounds for both treatment groups showed no significant difference (p=0.398) to each other. The collagen content of the untreated tissue gradually increased from day 2 and reached a peak at day 7. At day 10 there was a decrease in collagen content with an increase again at day 16.

In the group treated with *B. natalensis* leaf gel, treatment caused a significant difference in the collagen content of the wound tissue between the untreated and treated wounds (p=0.007). The collagen content in the treated group increased, to peak at day 10, where it was 2.76 times more than in the untreated wounds (Table 3.1). Although this was followed by a decrease on day 16, the collagen content was still greater (1.75 times) than that of the untreated wounds on the same day. Over the duration of the 16 days of treatment, the average collagen content of the treated wounds was 1.70 Times greater than that of the untreated wounds (Table 3.1).

WitsETD

created with nitroPDF professional
download the free trial online at nitropdf.com/professional

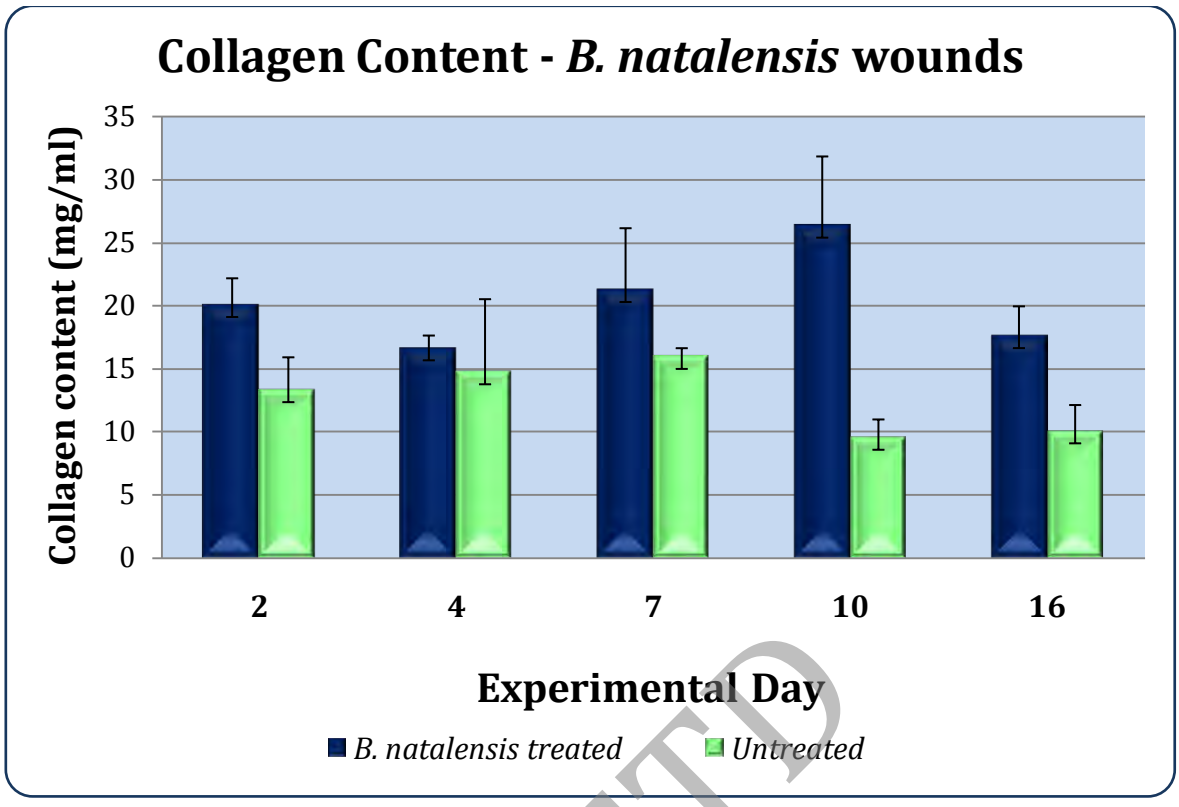

Figure 3.11: Collagen content of B. natalensis-treated and untreated wounds.
Data is given as mean ± S.D. for six wounds in each group per day of treatment

WitsETD

Table 3.1: Summary of collagen concentration (mg/100ml) per day of treatment

COLLAGEN CONCENTRATION (mg/100ml) AVERAGE PER DAY			
DAY	***B. natalensis*-treated wounds**	**Untreated wounds**	**Ratio Treated:Untreated**
2	20.09±2.07	13.33±2.56	1.51
4	16.65±0.97	14.75±5.75	1.13
7	21.28±4.86	15.97±0.65	1.33
10	26.39±5.44	9.55±1.41	**2.76**
16	17.62±2.32	10.06±2.04	1.75
	Mean for the 16 day period		***1.70***

created with nitroPDF professional
download the free trial online at nitropdf.com/professional

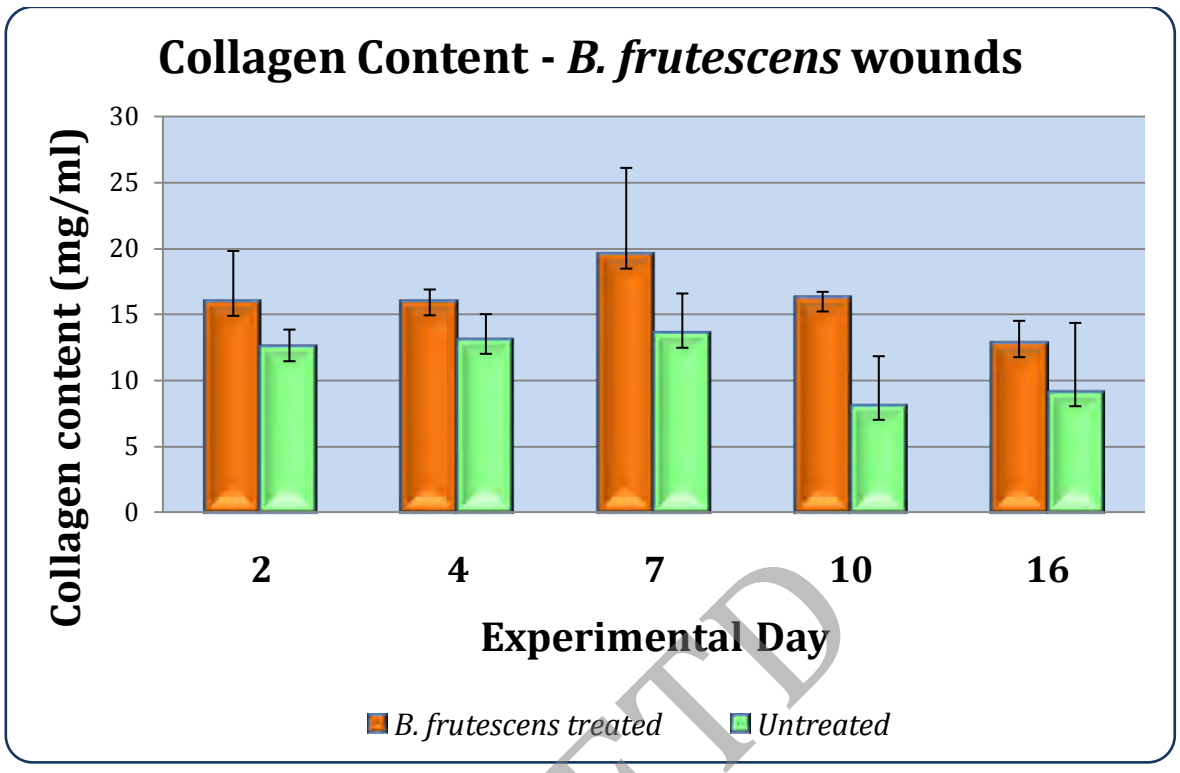

Figure 3.12: Collagen content of B. frutescens-treated and untreated wounds.
Data is given as mean ± S.D. for six wounds in each group per day of treatment

WitsETD

Table 3.2: Summary of collagen concentration (mg/100ml) per day of treatment

COLLAGEN CONCENTRATION (mg/100ml) AVERAGE PER DAY			
DAY	***B. frutescens*-treated wounds**	**Untreated wounds**	**Ratio Treated:Untreated**
2	15.89±3.91	12.45±1.40	1.28
4	15.93±0.96	13.01±2.01	1.22
7	19.47±6.63	13.47±3.12	1.45
10	16.22±0.49	8.01±3.82	**2.02**
16	12.76±1.75	9.04±5.31	1.41
Mean for the 16 day period			***1.48***

created with nitroPDF professional
download the free trial online at nitropdf.com/professional

Similarly, treatment with *B. frutescens* resulted in a significant difference between the collagen content in the treated and untreated wounds (p=0.013). In this treatment group however, the collagen content of the treated wounds peaked at day 7 (Fig. 3.12) being 1.45 times that of the untreated wounds (Table 3.2). Although the collagen content was lower on day 10 than on day 7 in the treated group, the difference in the concentration between the treated and untreated wounds was at the greatest (treated wounds were 2.02 times the collagen content compared to the untreated wounds). Over the duration of the 16 day treatment period, the collagen content of the *B. frutescens*-treated wounds was 1.48 times that of the untreated wounds (Table 3.2).

There was no significant difference between the *B. natalensis* and *B. frutescens*-treated groups (p=0.063), although collagen content of the treated wounds peaked on different days (Day 10 and 7, respectively). In both groups, the highest ratio of the collagen concentration of the treated:untreated wounds occurred on day 10.

WitsETD

created with nitroPDF professional
download the free trial online at nitropdf.com/professional

b. Estimation of hexosamine

There was no significant difference in the hexosamine content of the untreated wounds between both treatment groups (p=0.55). In the untreated wounds of both groups, the maximum content of hexosamine was present on day 4 followed by a gradual decrease to day 16.

There was also no significant difference between the *B. natalensis* and *B. frutescens*-treated groups (p=0.64). Treatment with both leaf gels followed the same pattern in hexosamine content (Figs. 3.13 and 3.14) as the untreated wounds with a maximum hexosamine content on day 4 followed by a steady decrease to day 16. In both the treated and untreated wounds, there was an overall decrease in hexosamine content between day 2 and day 16.

WitsETD

Over the duration of the 16 day treatment period, the hexosamine content (mean) of the *B. natalensis* and *B. frutescens*-treated groups was 1.08 and 1.07 times greater than that of the untreated groups, respectively (Tables 3.3 and 3.4). Statistically, this was not significantly different from the untreated wounds. In both treatment groups the highest ratio of treated:untreated wounds occurred on day 7 with a gradual decrease to day 16. The lowest ratio was prevalent in wounds on day 16.

created with nitroPDF professional
download the free trial online at nitropdf.com/professional

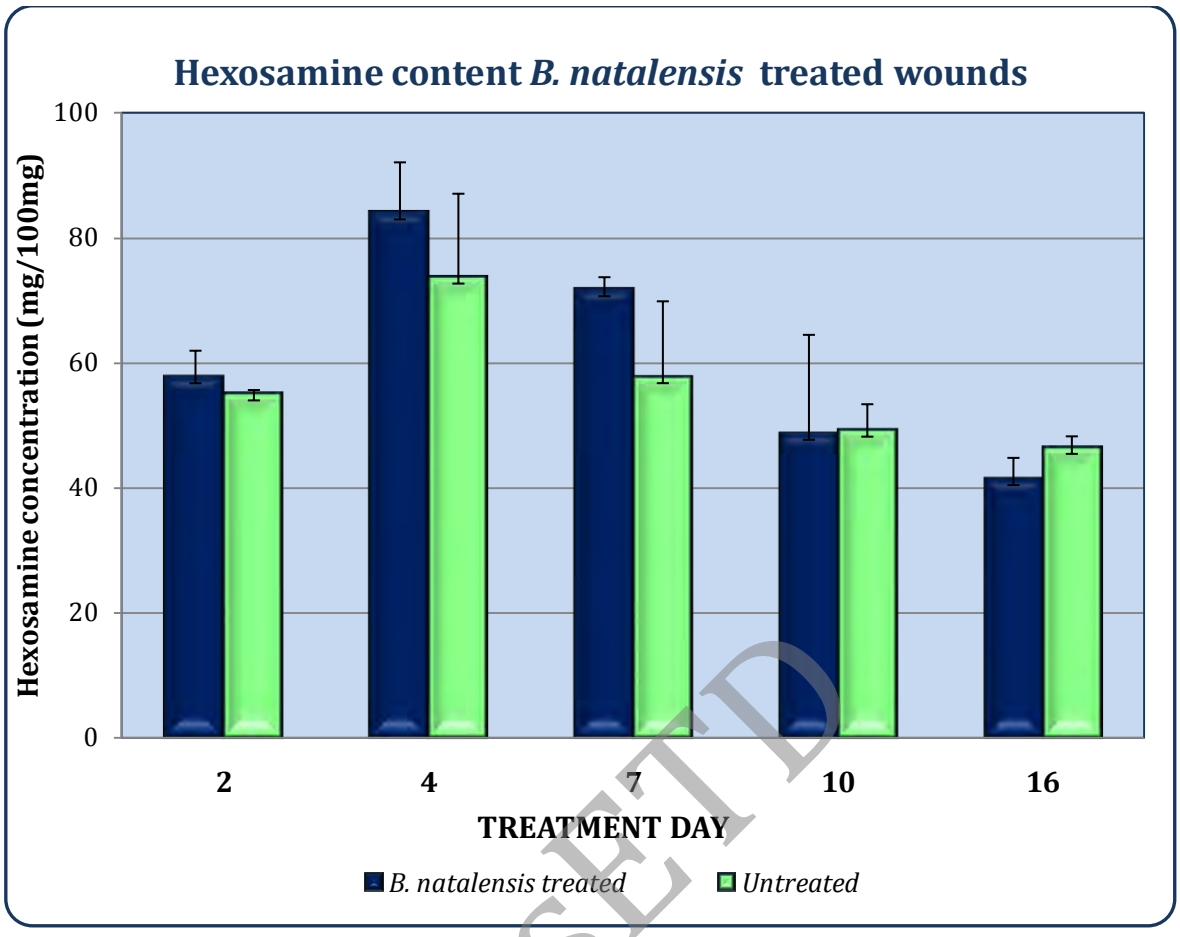

Figure 3.13: Hexosamine content of B. natalensis-treated and untreated wounds.
Data is given as mean ± S.D. for six wounds in each group day of treatment

WITSETD

Table 3.3: Hexosamine concentration (mg/100ml) per day of treatment

HEXOSAMINE CONCENTRATION (mg/100ml) AVERAGE PER DAY			
DAY	***B. natalensis*-treated wounds**	**Untreated wounds**	**Ratio Treated:Untreated**
2	54.96±0.66	57.70±4.21	1.05
4	73.66±13.38	83.93±8.14	1.14
7	57.72±12.10	71.63±2.05	**1.24**
10	49.16±4.19	48.65±15.80	0.99
16	46.41±1.80	41.41±3.36	0.89
Mean	**56.38±6.43**	**60.66±6.71**	**1.08**

created with nitroPDF professional
download the free trial online at nitropdf.com/professional

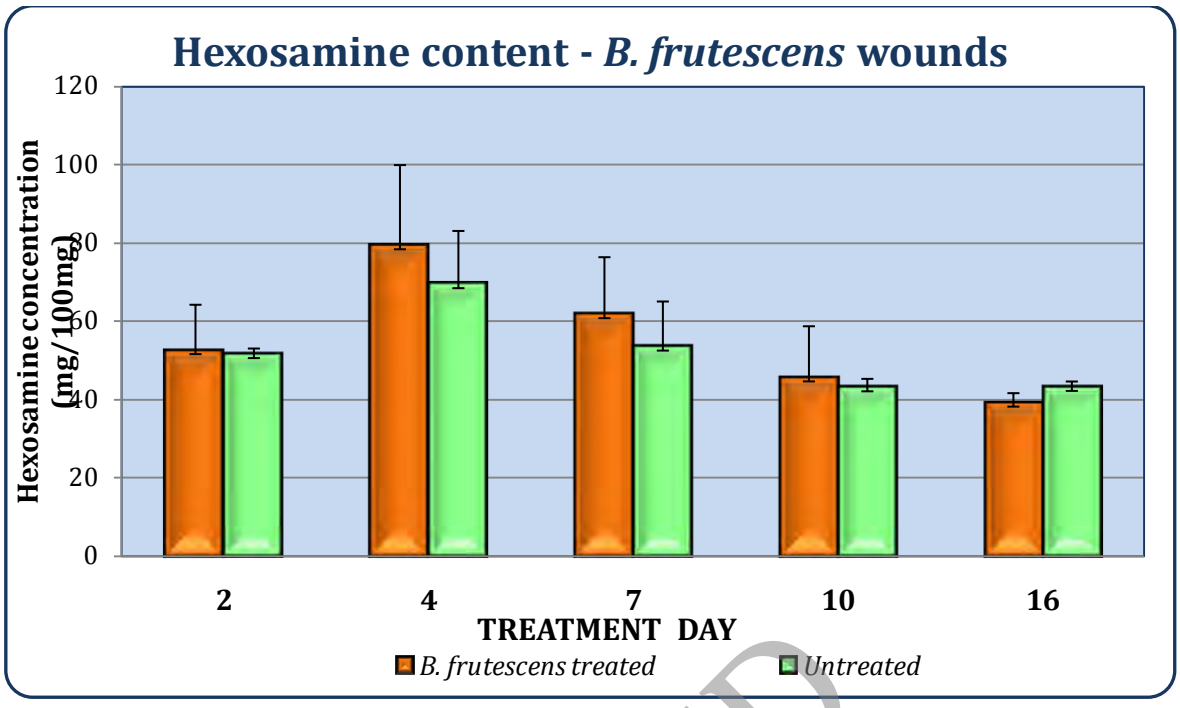

Figure 3.14: Hexosamine content of B. natalensis-treated and untreated wounds.
Data is given as mean ± S.D. for six wounds in each group per day of treatment

WITSETD

Table 3.4: Hexosamine concentration (mg/100ml) per day of treatment

HEXOSAMINE CONCENTRATION (mg/100ml) AVERAGE PER DAY			
DAY	***B. frutescens*-treated wounds**	**Untreated wounds**	**Ratio Treated:Untreated**
2	51.51±1.44	52.53±11.61	1.02
4	69.38±13.62	79.32±20.51	1.14
7	53.43±11.54	61.72±14.58	**1.16**
10	43.02±2.18	45.56±13.09	1.06
16	43.13±1.41	39.11±2.44	0.91
Mean	**52.10±6.04**	**55.65±12.45**	**1.07**

created with nitroPDF professional
download the free trial online at nitropdf.com/professional

c. *Estimation of protein*

Over the 16 day treatment period, the untreated wounds in both treatment groups displayed no significant difference from each other (p=0.79) (Figs. 3.15 and 3.16). In both groups of untreated wounds, there was a rapid increase in the protein content from day 4 to day 7 preceded a sharp decrease to day 16.

Both groups of treated wounds followed a similar pattern in protein content to the untreated wounds in that the highest protein content was prevalent on day 7 and then gradually decreased to day 16 (Figs. 3.15 and 3.16).

Treatment with *B. natalensis* appeared to significantly increase the protein content of the wounds over that of the untreated wounds (p=0.03). Over the duration of the 16 day treatment period, there was an increase in the protein content in all of the treated wounds (Table 3.5). This increase followed the same pattern as the untreated wounds until day 7. On day 10, a major decrease in the amount of protein was noted in the untreated wounds compared to the treated wounds (Fig. 3.15).

B. frutescens treatment, similarly to *B. natalensis* treatment, increased the protein content of the wounds significantly over that of the untreated wounds (p=0.04) over the 16 day treatment period. This increase followed the same pattern as the untreated wounds until day 7. On day 10, the decrease in the amount of protein in the untreated wounds was slightly greater than in the treated wounds.

WitsETD

created with nitroPDF professional
download the free trial online at nitropdf.com/professional

There was no significant difference in the protein content between the two treated groups (p=0.30). The mean ratio of the treated to untreated wounds in the *B. natalensis* and *B. frutescens* groups was 2.38 and 2.02, respectively (Table 3.5 and 3.6).

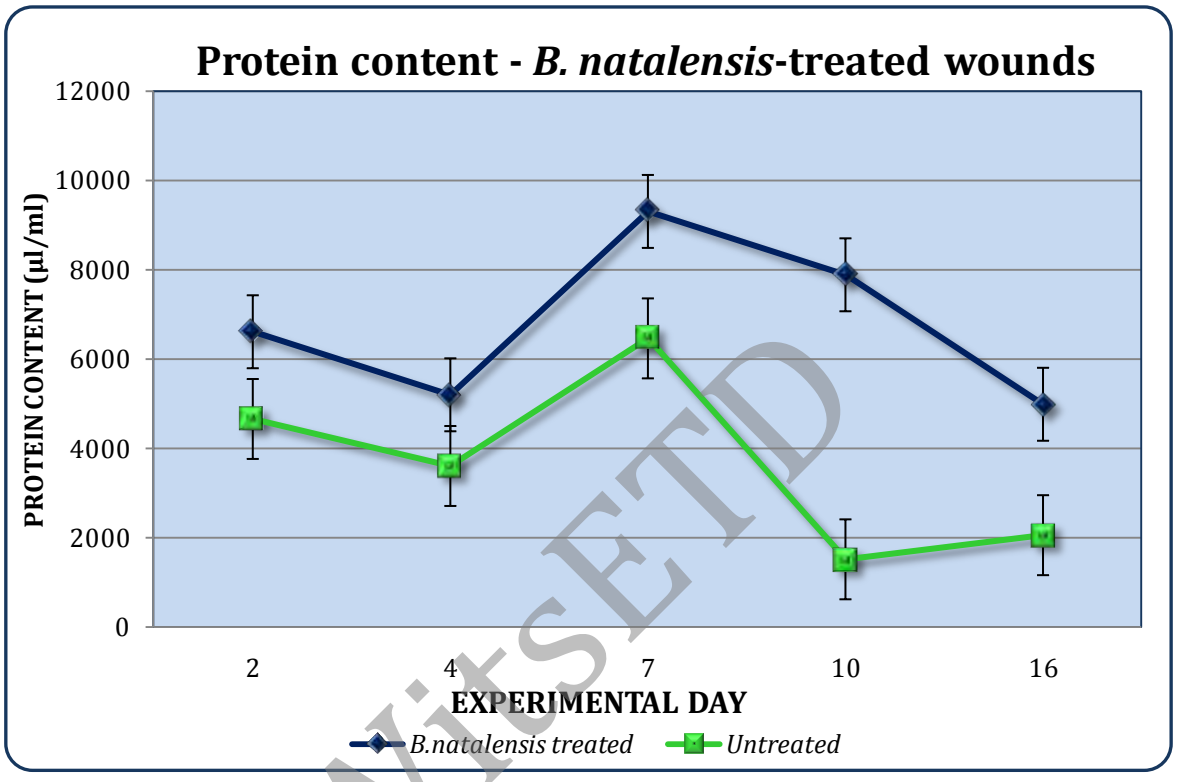

WitsETD

Figure 3.15: Protein content of B. natalensis-treated and untreated wounds.

Table 3.5: Summary of protein concentration (mg/100ml) per day of treatment

PROTEIN CONCENTRATION (mg/100ml)AVERAGE PER DAY			
DAY	**Untreated**	***B. natalensis*-treated**	**Ratio Treated:Untreated**
2	4670.20±154.76	6623.60±1312.79	1.42
4	3617.58±13.34	5211.72±50.70	1.44
7	6475.13±1406.18	9318.41±5.34	1.44
10	1527.00±389.87	7899.22±72.04	5.17
16	2067.85±138.75	4999.22±1134.02	2.42
Mean	**3671.55±960.58**	**6810.42±514.98**	**2.38**

created with nitroPDF professional
download the free trial online at nitropdf.com/professional

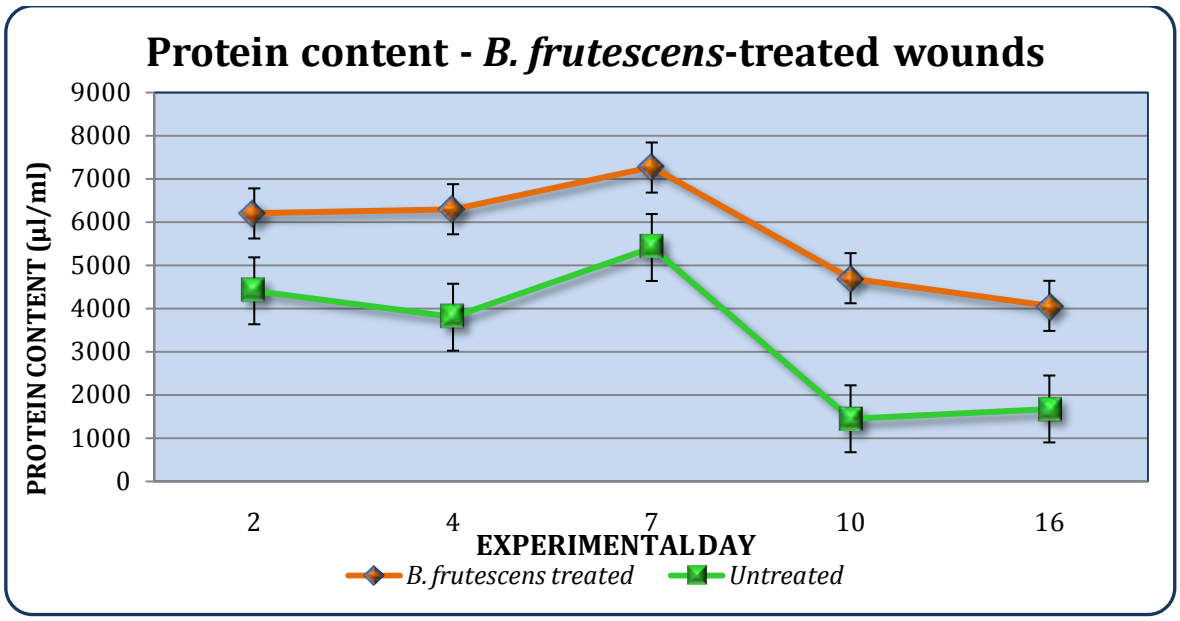

Figure 3.16: Protein content of B. natalensis-treated and untreated wounds.

WitsETD

Table 3.6: Summary of protein concentration (mg/100ml) per day of treatment

PROTEIN CONCENTRATION (mg/100ml) AVERAGE PER DAY			
DAY	**Untreated**	***B. frutescens*-treated**	**Ratio Treated:Untreated**
2	4408.71±3495.44	6199.31±1739.72	1.41
4	3797.14±261.49	6296.47±298.85	1.66
7	5410.64±82.72	7261.55±266.83	1.34
10	1446.57±53.37	4700.35±5.34	3.25
16	1673.92±152.09	4060.69±357.60	2.43
Mean	3347.39±809.02	5703.67±533.66	2.02

created with nitroPDF professional
download the free trial online at nitropdf.com/professional

d. Estimation of total DNA content

The total DNA content of the untreated wounds of both groups displayed a similar pattern (Figs. 3.17 and 3.18). There was an increase in DNA content to day 7, followed by a sharp decrease to day 10. There was no significant differences between the untreated groups (p=0.87).

Treatment with both leaf gels significantly increased the DNA content of the wounds compared to the untreated wound *(B. natalensis*, p=0.04 and *B. frutescens*, p=0.04). However, the effect of *B. natalensis* and *B. frutescens* was not significantly different from each other (p=0.80). Over the 16 day treatment period, there was a noticeable increase in DNA content in both sets of treated groups compared to the untreated wounds *(B. natalensis*, 1.78 and *B. frutescens*, 1.77 times that of the control). However, in the group treated with *B. natalensis* there was a more gradual increase in the DNA content from day 4 to day 7 than in the *B. frutescens* group.

WitsETD

created with nitroPDF professional
download the free trial online at nitropdf.com/professional

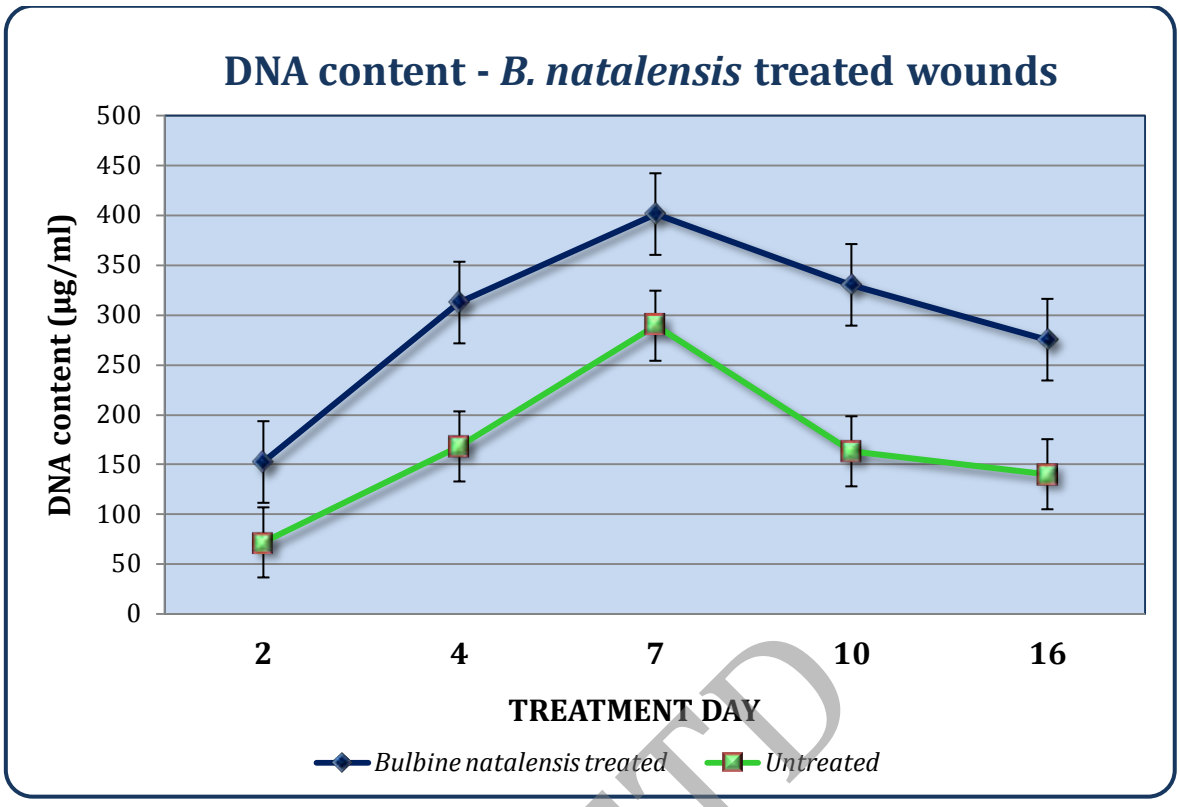

Figure 3.17: DNA content of B. natalensis-treated and untreated wounds.

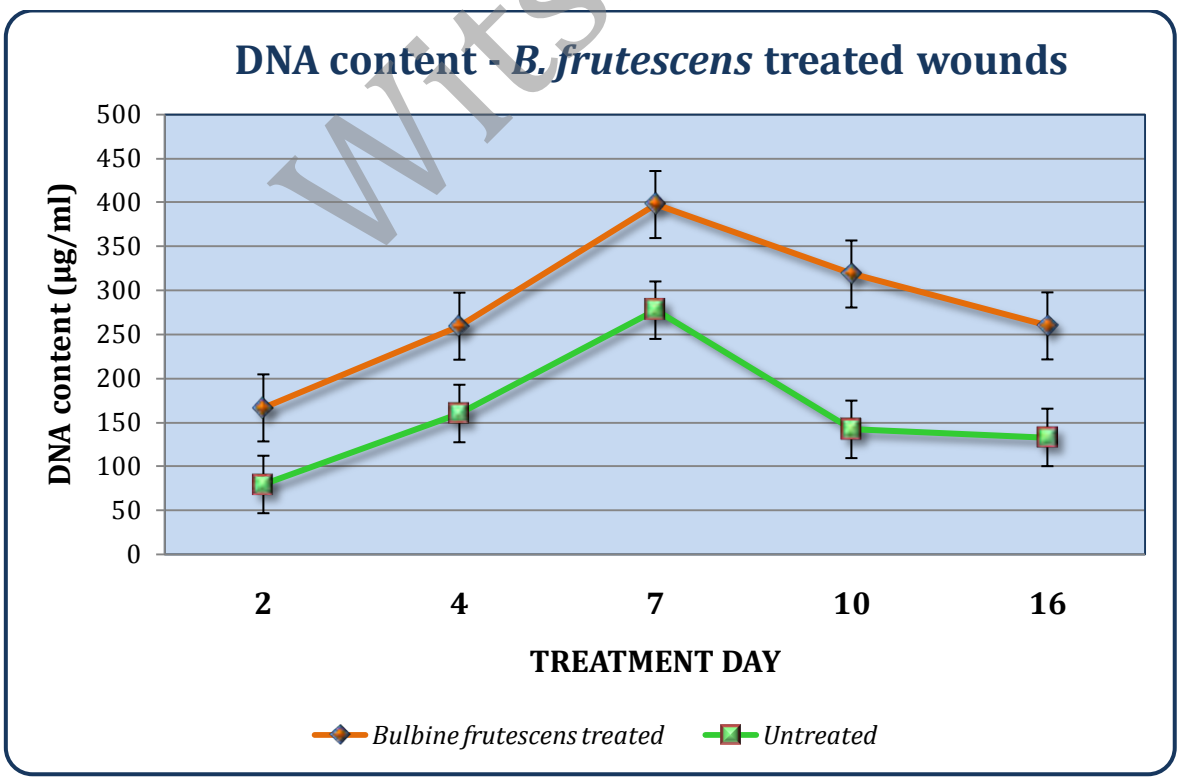

Figure 3.18: DNA content of B. frutescens-treated and untreated wounds.

WitsETD

created with nitroPDF professional
download the free trial online at nitropdf.com/professional

e. Collagen: DNA ratio

The ratio of collagen content to DNA content is said to be an indication of the synthesis of collagen (Chithra, 2003). The ratio of collagen:DNA content for both treatment groups and the untreated control wounds is given in Table 3.7. There was no significant difference between treatment with either *B. natalensis* or *B. frutescens* compared to the untreated wounds (p=0.57 and p=0.37, respectively). There was no statistically significant difference between both untreated groups.

WitsETD

Table 3.7: Summary of collagen:DNA content

RATIO OF COLLAGEN:DNA CONTENT				
DAY	*B. frutescens group*		*B. natalensis group*	
	Treated	Untreated	Treated	Untreated
2	0.096	0.163	0.133	0.186
4	0.059	0.077	0.052	0.093
7	0.050	0.050	0.053	0.056
10	0.051	0.054	0.080	0.052
16	0.049	0.069	0.061	0.078

created with nitroPDF professional
download the free trial online at nitropdf.com/professional

3.2.2.4. *Histological analyses of the B. natalensis- and B. frutescens-treated wounds compared to untreated wounds in pig skin*

The histology of the biopsied excisional untreated and the *B. natalensis*- and *B. frutescens*- treated wounds were examined in order to describe the wound at different points in time during the healing process using haematoxylin and eosin and the Mallory trichrome stains. The results of the analysis of the three groups per day is summarised in Table 3.8. The results for each are also described below.

Montages of representative wounds for the three groups are presented with each description of wound healing for each day over the 16 day period. Note: the differences in the distribution of light across these figures are due to the compilation of these montages.

WitsETD

created with nitroPDF professional
download the free trial online at nitropdf.com/professional

Table 3.8 : Summary of wound healing features from histological sections

Day and Treatment		N	Granulation tissue	Migrating keratinocytes	Blood vessels	Wound contraction	Collagen
DAY 2	*Untreated*	12	+	+	+	+	-
	B. natalensis-treated	6	+++	++	++	++	-
	B. frutescens-treated	6	++	+	++	+	-
Day 4	*Untreated*	12	++	+	+	+	-
	B. natalensis-treated	6	+++	++	++	++	+
	B. frutescens-treated	6	+++	+++	+++ (++)*	+++	++
Day 7	*Untreated*	12	+++	+++	++	++	+
	B. natalensis-treated	6	+++	+++	+++	+++	++
	B. frutescens-treated	6	+++	+++	+++	+++	++
Day 10	*Untreated*	12	+++	-	++	+++	++
	B. natalensis-treated	6	++	-	+++	+++	+++
	B. frutescens-treated	6	+	-	+++	+++	+++
Day 16	*Untreated*	12	++	-	++	+++	++
	B. natalensis-treated	6	+	-	+	+++	+++
	B. frutescens-treated	6	+	-	+	+++	+++

Key: **In the B. frutescens-treated wounds at day 4, two groups of wounds were discernable viz. fully re-epithelialised and partly re-epithelialised treated wounds.*

WitsETD

Table 3.9: Mean maximal distance between wound edges (mm) and percent closed from day 0

Day	Untreated		B. natalensis		B. frutescens	
	Mean distance	% Closed	Mean distance	% Closed	Mean distance	% Closed
2	3.71 ±0.38	**7.00**	3.18 ±0.40	**20.50**	3.44 ±0.41	**14.00**
4	3.14 ±0.33	**21.50**	2.69 ±0.24	**32.75**	2.58 ±0.36	**35.50**
7	1.68 ±0.24	**58.00**	1.39 ±0.32	**62.25**	1.43 ±0.45	**64.25**
10	1.18 ±0.35	**70.50**	0.79 ±0.22	**80.25**	0.82 ±0.19	**79.50**
16	Wound Contraction Complete					

created with nitroPDF professional
download the free trial online at nitropdf.com/professional

The mean maximal distances between the wound edges is shown in Table 3.9. This indicates the time taken for the wound space to contract or 'close' and is independent of re-epithelialisation. Wound contraction was more rapid in both treated groups than in the untreated wounds. In the untreated wounds, wound contraction was initially slow from day 2 to day 4; followed by a sudden increase in contraction between day 4 and day 7. The wound contraction in the untreated wounds differed from both treated groups. Treatment with *B. natalensis* and *B. frutescens* resulted in a similar pattern of wound contraction. Treatment with both *B. natalensis* and *B. frutescens* resulted in a gradual rate of contraction from day 2 to day 16. The overall contraction of both groups of treated wounds was greater than the untreated wounds.

WitsETD

a. Wound healing on day 2 post-wound creation

The mean maximal distance between the wound edges for the untreated (n=12), the *B. natalensis*-treated (n=6) and the *B. frutescens*-treated wounds (n=6) on day 2 following wound creation is shown in Table 3.9. There was no statistically significant difference between the three groups.

The granulation tissue of the untreated wound on day 2 was sparse and displayed scattered fibroblasts and large numbers of red blood cells (Fig. 3.19 and 3.20). Numerous blood vessels were noted. No collagen fibres were present in the granulation tissue. There was a distinctly visible neo-epidermis over the edges of the

created with nitroPDF professional
download the free trial online at nitropdf.com/professional

wound area (Figs. 3.19). The migrating edge ('tongue') of epidermis was several cell layers thick. The basement membrane and stratum basale were distinct throughout the neo-epidermis but became indistinct in the region of the migrating 'tongue' (Fig. 3.21).

On day 2, both treated groups also displayed normal granulation tissue formation. In the *B. natalensis*-treated group, the granulation tissue was dense with a greater number of fibroblasts present in the granulation tissue than in the corresponding untreated tissue (Fig. 3.20 and 3.23). Red blood cells were scattered in the granulation tissue. Numerous blood vessels were also present. Neo-epidermis formation was present in all of the *B. natalensis* treated wounds on day 2 (Figs. 3.22 and 3.24). The extent of migration of the keratinocytes to re-epithelialise the wound area was greater than that in the untreated tissue (Figs. 3.19 and 3.24). The stratum basale was distinguishable throughout the neo-epidermis but not in the migrating 'tongue'.

WitsETD

In the *B. frutescens*-treated group on day 2, the granulation tissue was more dense than that of the untreated tissue, but not as dense as the *B. natalensis*-treated group on the same day (Figs. 3.23 and 3.25). The extent of migration of the keratinocytes in this group was comparable with the untreated group but not as advanced as the *B. natalensis* treated group (Fig. 3.25). There appeared to be more blood vessels present in the granulation tissue of the *B. frutescens*-treated group (Fig. 3.26) when compared to the untreated tissue, but this was not quantified. Neo-epidermis formation was present in all day 2 wounds of the *B. frutescens* treated groups.

created with nitroPDF professional
download the free trial online at nitropdf.com/professional

In all three groups, there was no evidence of collagen formation in the granulation tissue (Figs. 3.27, 3.28 and 3.29). There was a fibrin clot present in all wound spaces (as seen in this representative section of a *B. frutescens*-treated wound, Fig. 3.29). This comprised of a dense network of fibrin and red blood cells.

WitsETD

created with nitroPDF professional
download the free trial online at nitropdf.com/professional

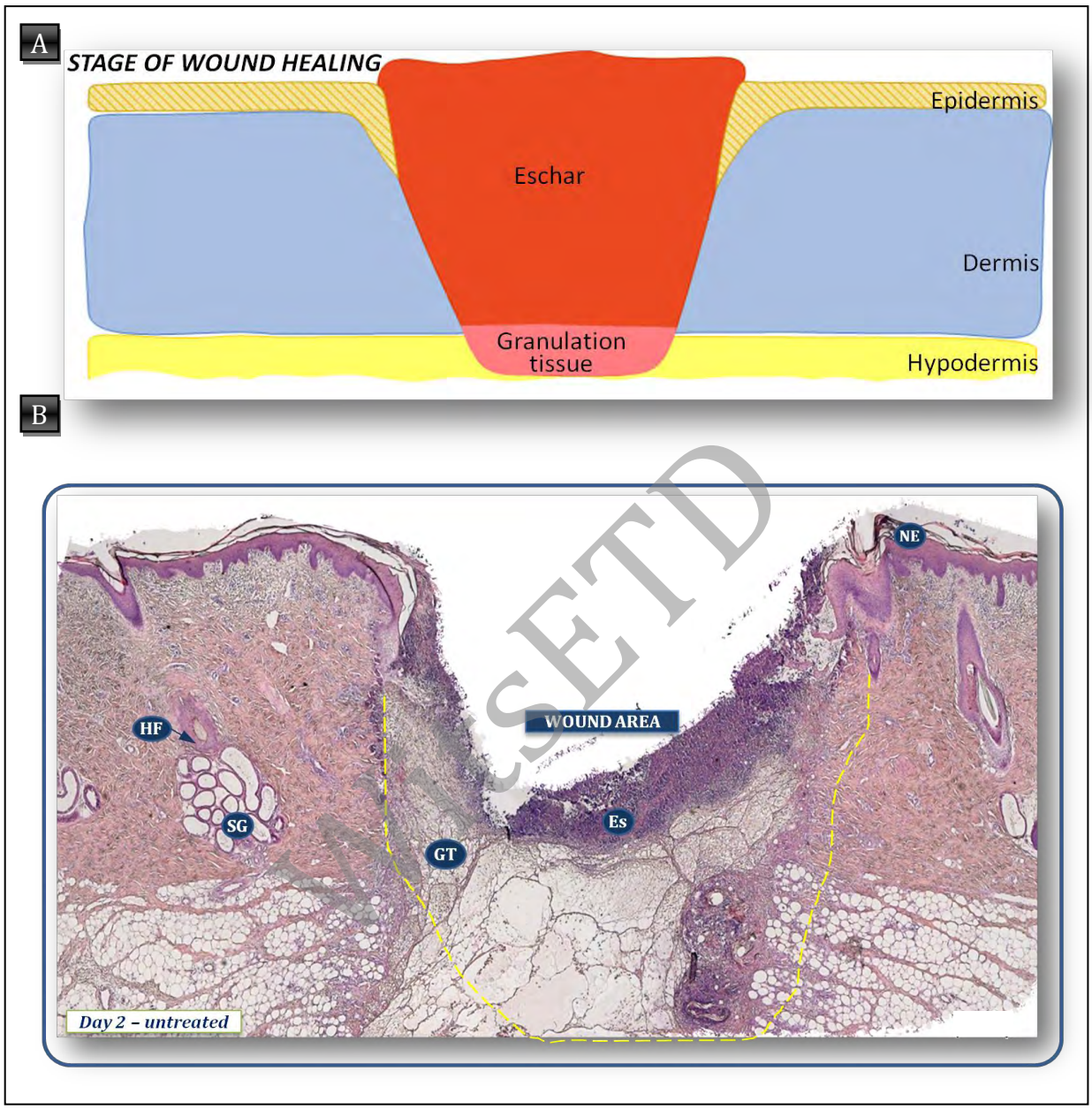

Figure 3.19: Wound healing in untreated tissue on day 2 post-wound creation.
A. *Illustration of the stage of wound healing*
B. *Representative histological section of untreated tissue on day 2 post-wound creation. Note the formation of the neo-epidermis (NE) and the sparse granulation tissue(GT). In the area adjacent to the wound, hair follicles (HF)- hair follicle, sebaceous glands (SG) are present. Only part of the eschar (Es) which normally fills the wound can be seen, due to removal of the tissue during sectioning. (H and E, x5)*

created with nitroPDF professional
download the free trial online at nitropdf.com/professional

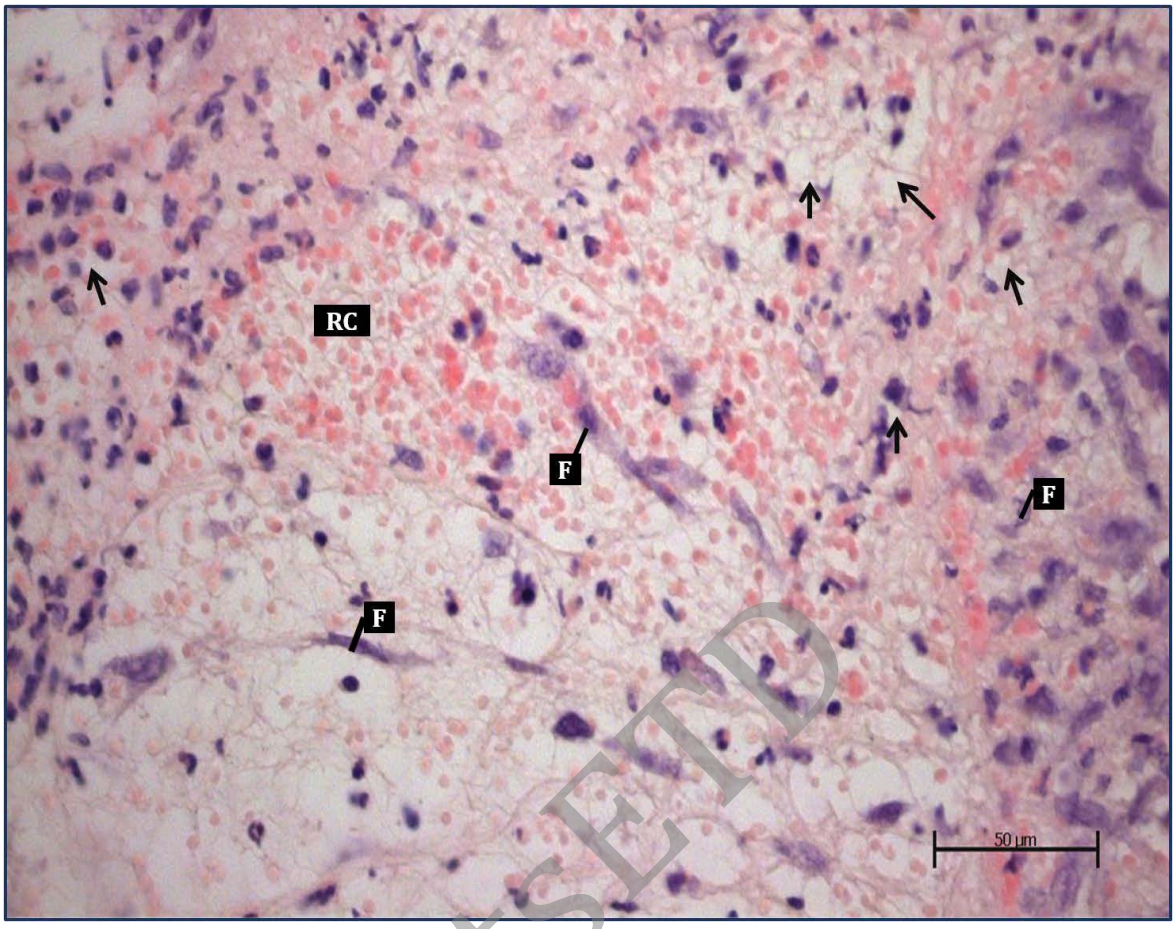

Figure 3.20 Representative histological section of day 2 untreated wound showing granulation tissue.
Note the fibroblasts (F) and red blood cells (RC) scattered in the sparse granulation tissue (H and E, x40)

WitsETD

created with nitroPDF professional
download the free trial online at nitropdf.com/professional

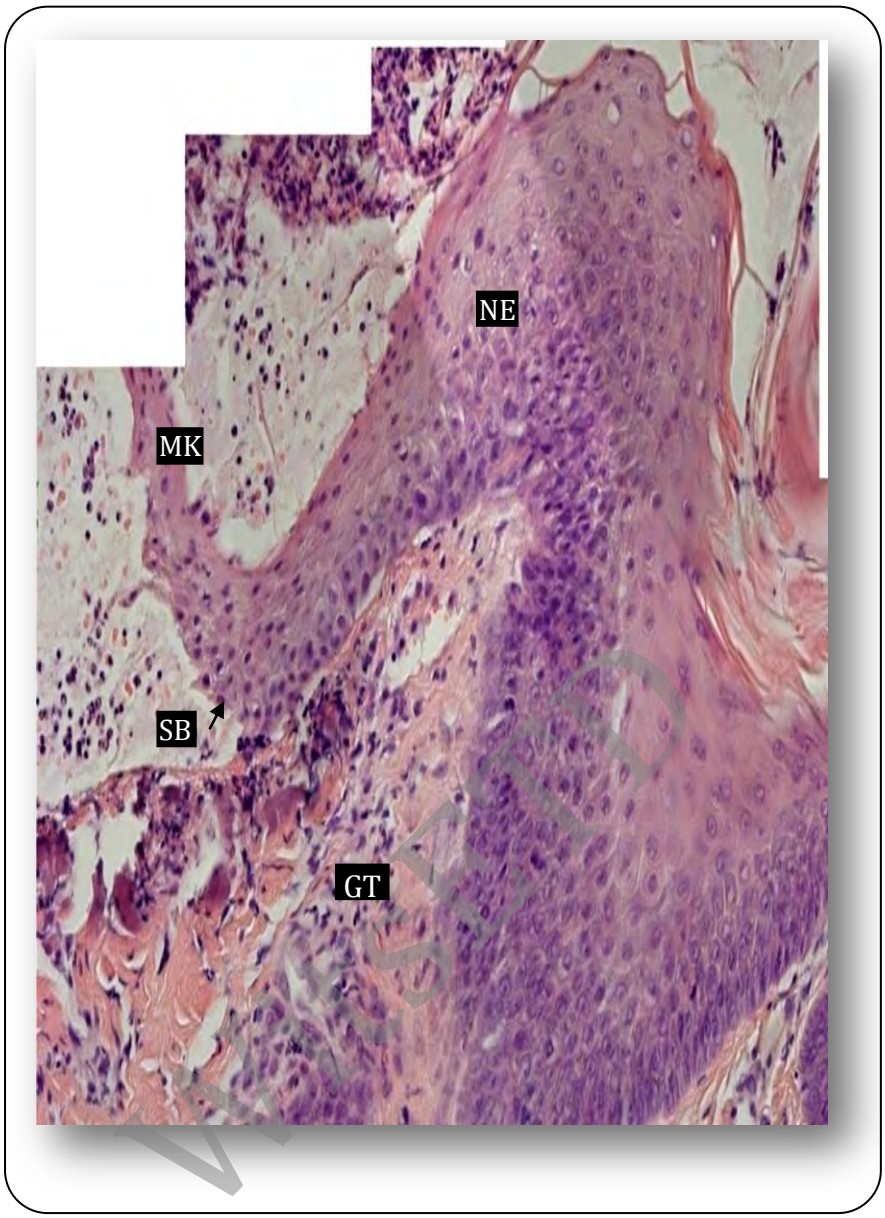

Figure 3.21: Representative histological section of an untreated wound on day 2 post-wounding. *Note the keratinocytes forming the migrating tongue (MK). The neo-epidermis is several layers thick (NE). MK is relatively thin with and indistinguishable stratum basale (SB). The underlying granulation tissue (GT) is well formed. (H and E; x40)*

created with nitroPDF professional
download the free trial online at nitropdf.com/professional

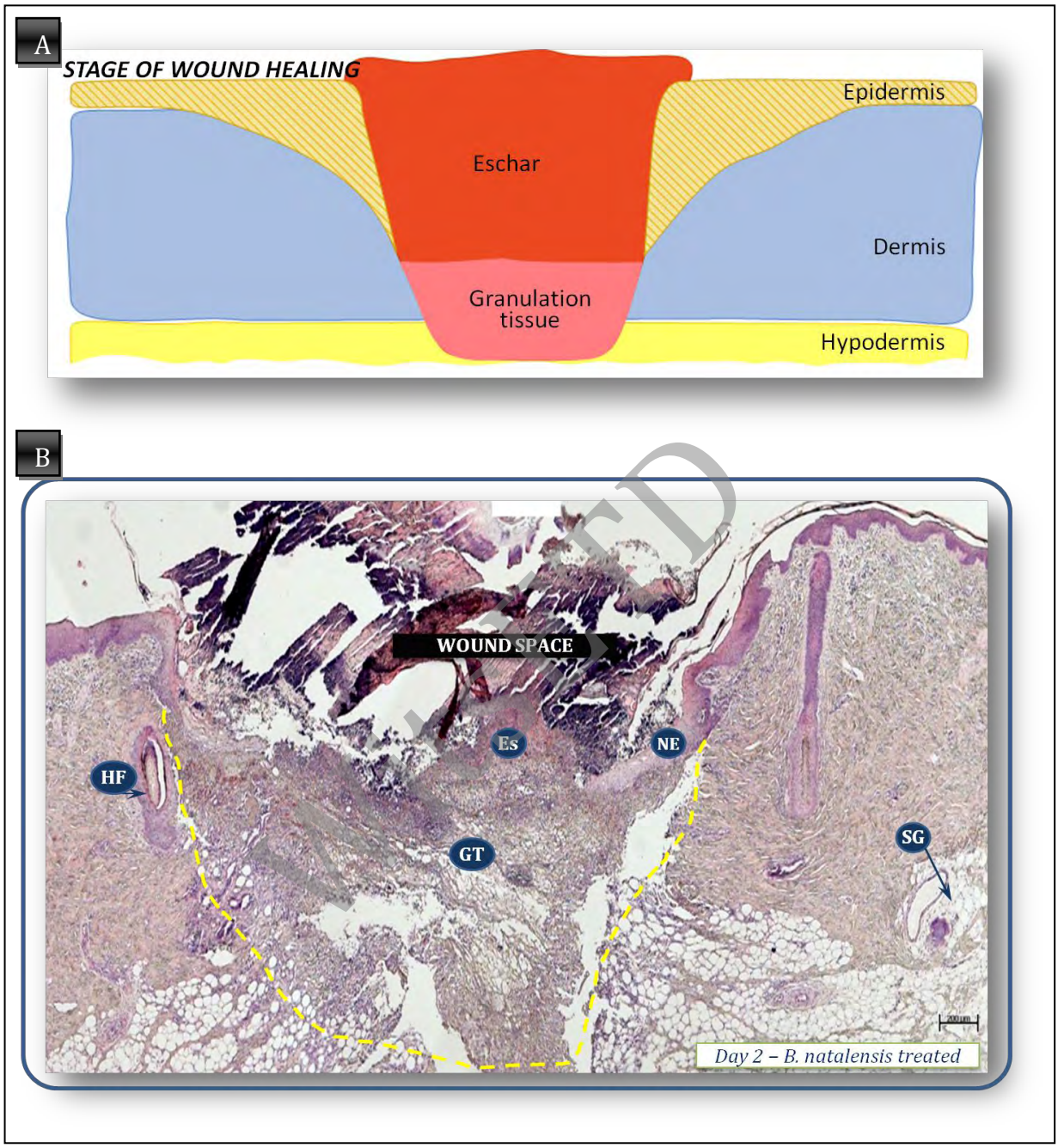

Figure 3.22: Wound healing of B. natalensis- treated tissue on day 2 post-wound creation.
A. *Illustration of the stage of wound healing*
B*. Representative histological section of day 2 B. natalensis-treated wound tissue*
Note the extensive migration of the neo-epidermis and the granulation tissue formation
HF- hair follicle; SG- sebaceous gland; GT- granulation tissue; NE- neo-epidermis; Es- eschar. (H and E, x5)

created with nitroPDF professional
download the free trial online at nitropdf.com/professional

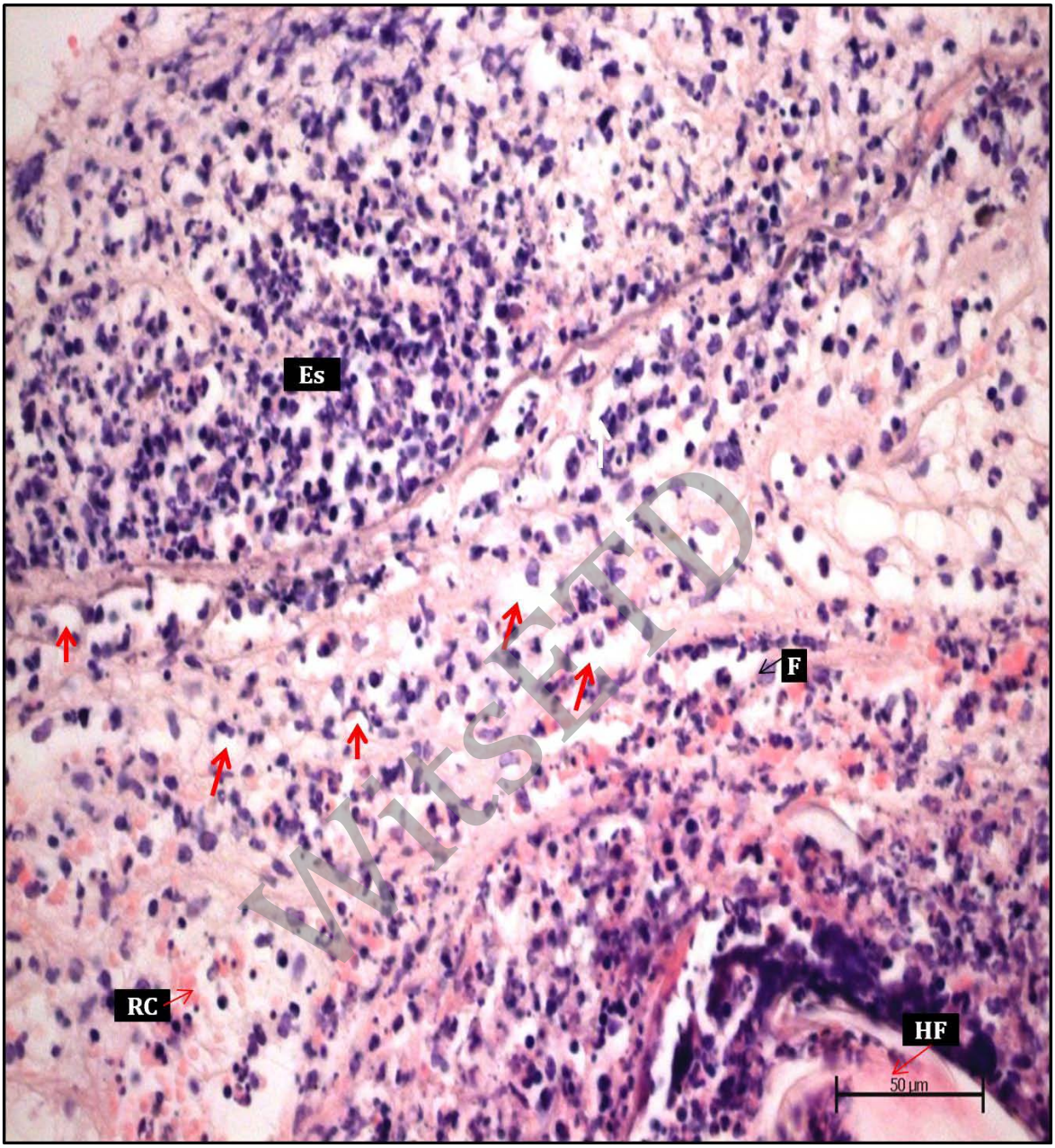

WitsETD

Figure 3.23: Granulation tissue of a B. natalensis- treated wound on day 2 post-wounding. *Note the presence of numerous fibroblasts (F) and red blood cells (RC). A number of small vessels indicated by red arrows are visible. (H and E, x40)*

created with nitroPDF professional
download the free trial online at nitropdf.com/professional

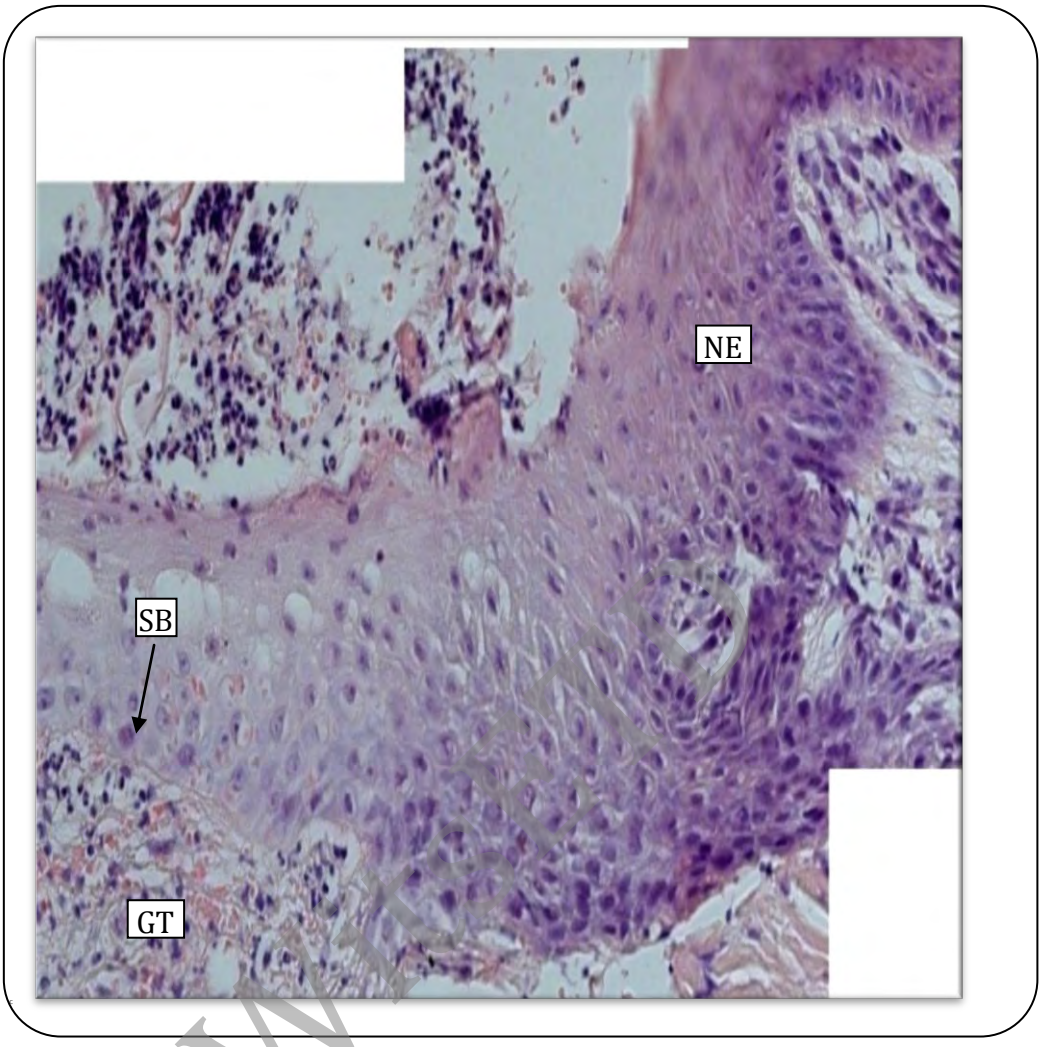

Figure 3.24: Representative histological section of a B. natalensis-treated wound showing the migrating tongue on day 2 post- wounding.
Note the formation of the neo-epidermis (NE) with a distinct stratum basale (SB). (H and E, X40)

created with nitroPDF professional
download the free trial online at nitropdf.com/professional

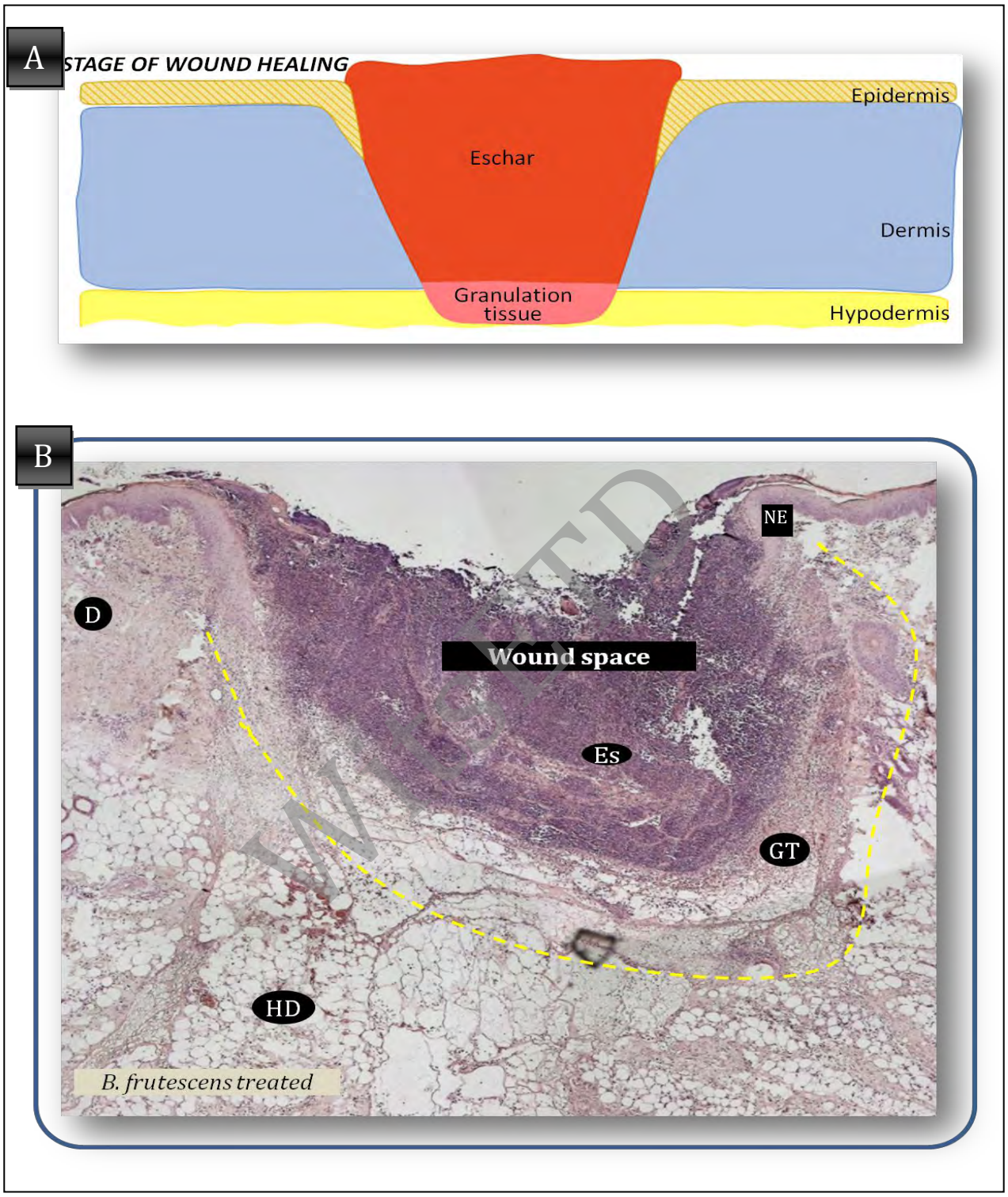

Figure 3.25: Wound healing of B. frutescens-treated tissue on day 2 post-wound creation.
A. *Illustration of the stage of wound healing*
B. *Representative histological section of B. frutescens-treated wound.*
Note the formation of the neo-epidermis (NE) and the granulation tissue (GT). The dermis (D), hypodermis (HD) and granulation tissue (GT) are visible. The eschar (Es) fills the wound space. (H and E, x5)

created with nitroPDF professional
download the free trial online at nitropdf.com/professional

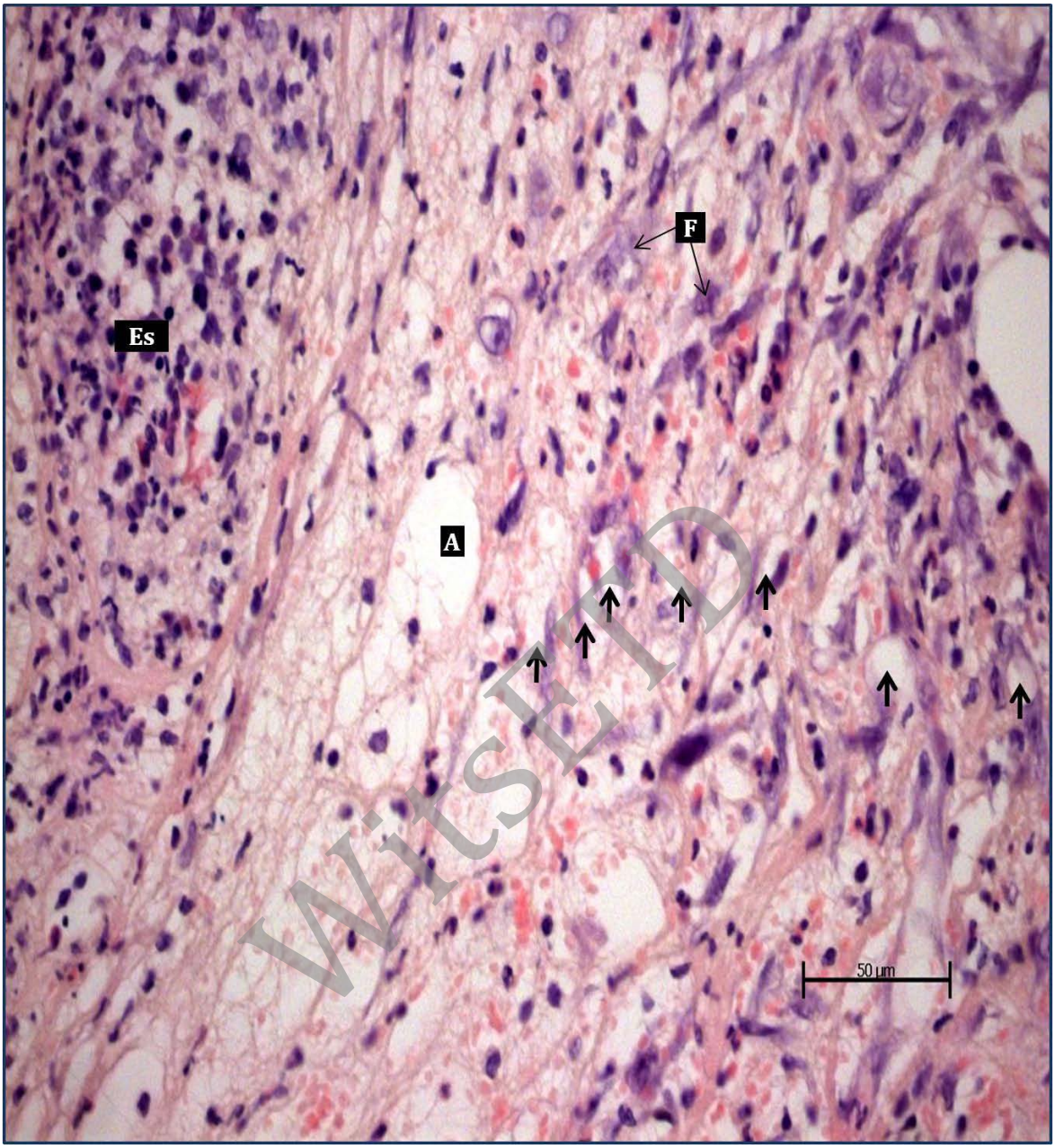

WiSER

Figure 3.26: Granulation tissue of a B. frutescens- treated wound on day 2 post-wound creation.
Note the presence of numerous fibroblasts (F) and blood vessels (black arrows). (H and E, x40)

created with nitroPDF professional
download the free trial online at nitropdf.com/professional

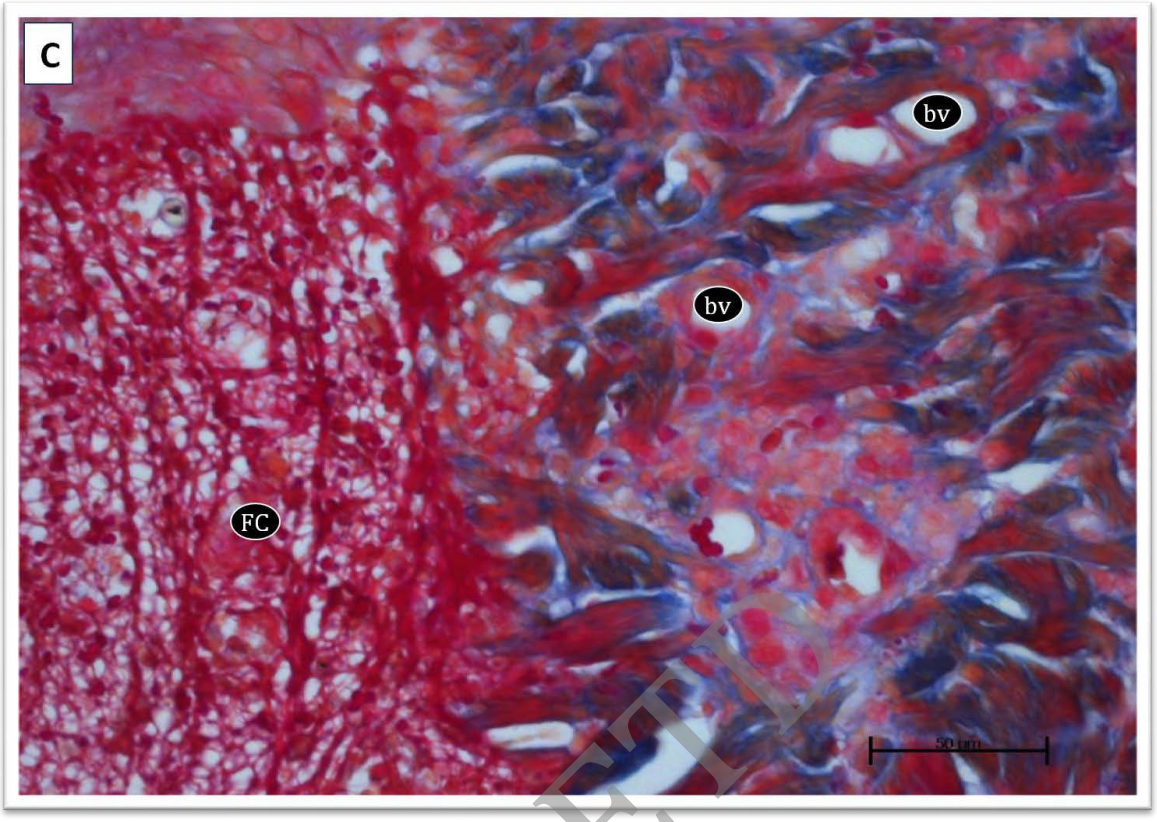

Figure 3.27: Representative histological section of untreated wound on day 2 post-wounding. *Note the fibrin clot (FC) is well formed with numerous red blood cells and fibrin in the wound space. There is no collagen deposition visible in the wound space. The adjacent unwounded tissue (UW) has dense collagen bundles with intersperse blood vessels (bv).*
(Mallory trichrome stain, x40)

WitsETD

created with nitroPDF professional
download the free trial online at nitropdf.com/professional

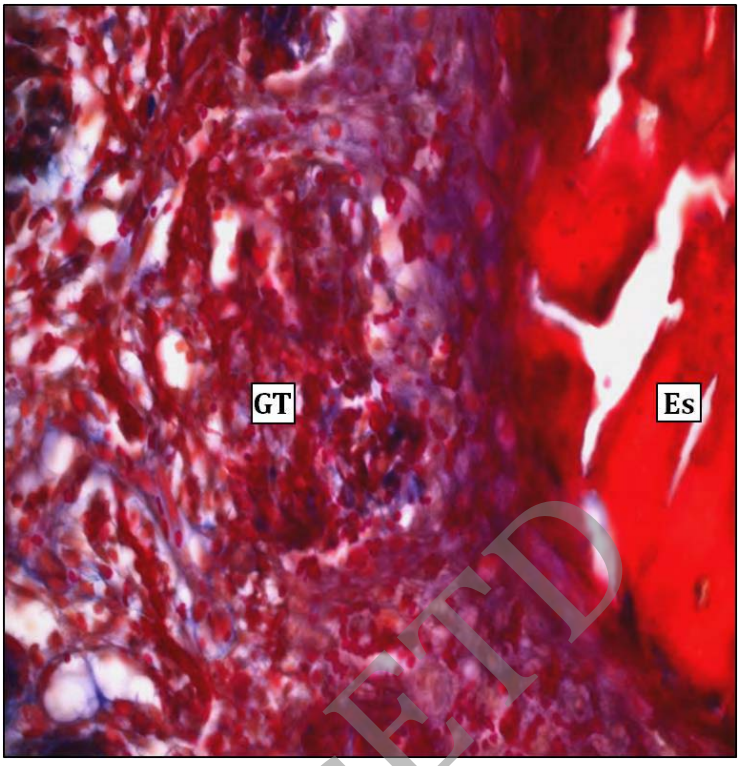

Figure 3.28: Representative histological section of a B. natalensis-treated wound on day 2 post-wounding.
Note that the granulation tissue (GT) has abundant fibroblasts and no collagen and the eschar (Es) in the wound space is distinct (Mallory trichrome stain x40)

WITSETD

created with nitroPDF professional
download the free trial online at nitropdf.com/professional

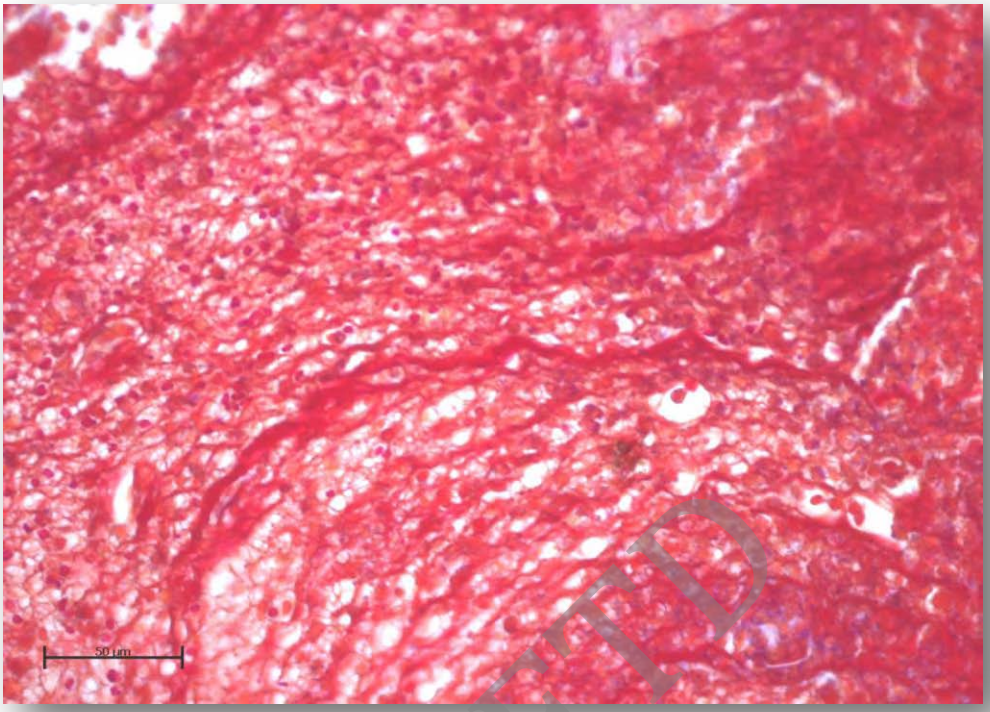

Figure 3.29: Representative histological section of day 2 B. frutescens-treated wound.
Note the fibrin clot is dense with a large number of red blood cells and fibrin. There is no collagen deposition visible in the wound space (Mallory trichrome stain, X40)

WITSETD

created with nitroPDF professional
download the free trial online at nitropdf.com/professional

Wound healing on day 4 post-wound creation

The mean maximal distance between the wound edges for the untreated (n=12), the *B. natalensis*-treated (n=6) and the *B. frutescens*-treated (n=6) wounds is shown in Table 3.9. Wound contraction was significantly different in both treated groups when compared to the untreated group (*B. natalensis*-treated, p=0.007 and *B. frutescens*-treated p=0.004) with the greatest contraction prevalent in the *B. frutescens*-treated group. There was no statistically significant difference between the two treatment groups.

The area of the wound space was clearly visible in the untreated wounds and the *B. natalensis*-treated group (Figs. 3.30 and 3.31). Neo-epidermis formation was present in all the wounds i.e. untreated and the *B. natalensis*- and *B. frutescens*- treated groups (Figs. 3.30, 3.31 and 3.32). The extent of the migration of keratinocytes was visibly different in both treatment groups when compared to the untreated group. The extent of keratinocyte migration was greatest in the *B. frutescens*-treated group (Fig. 3.30), followed by the *B. natalensis*-treated group. In the *B. frutescens* group, there was evidence of full re-epithelialisation (Fig. 3.32) in 50% of the treated wounds. The remaining 50% of the *B. frutescens*-treated wounds (Fig. 3.33) showed similar re-epithelialisation to the *B. natalensis*-treated wounds. Hair follicles were present in the wound area of all three groups but were more numerous in the *B. frutescens*-treated group. Keratinocytes from the hair follicles also appeared to contribute to the re-epithelialisation.

WiseTD

created with nitroPDF professional
download the free trial online at nitropdf.com/professional

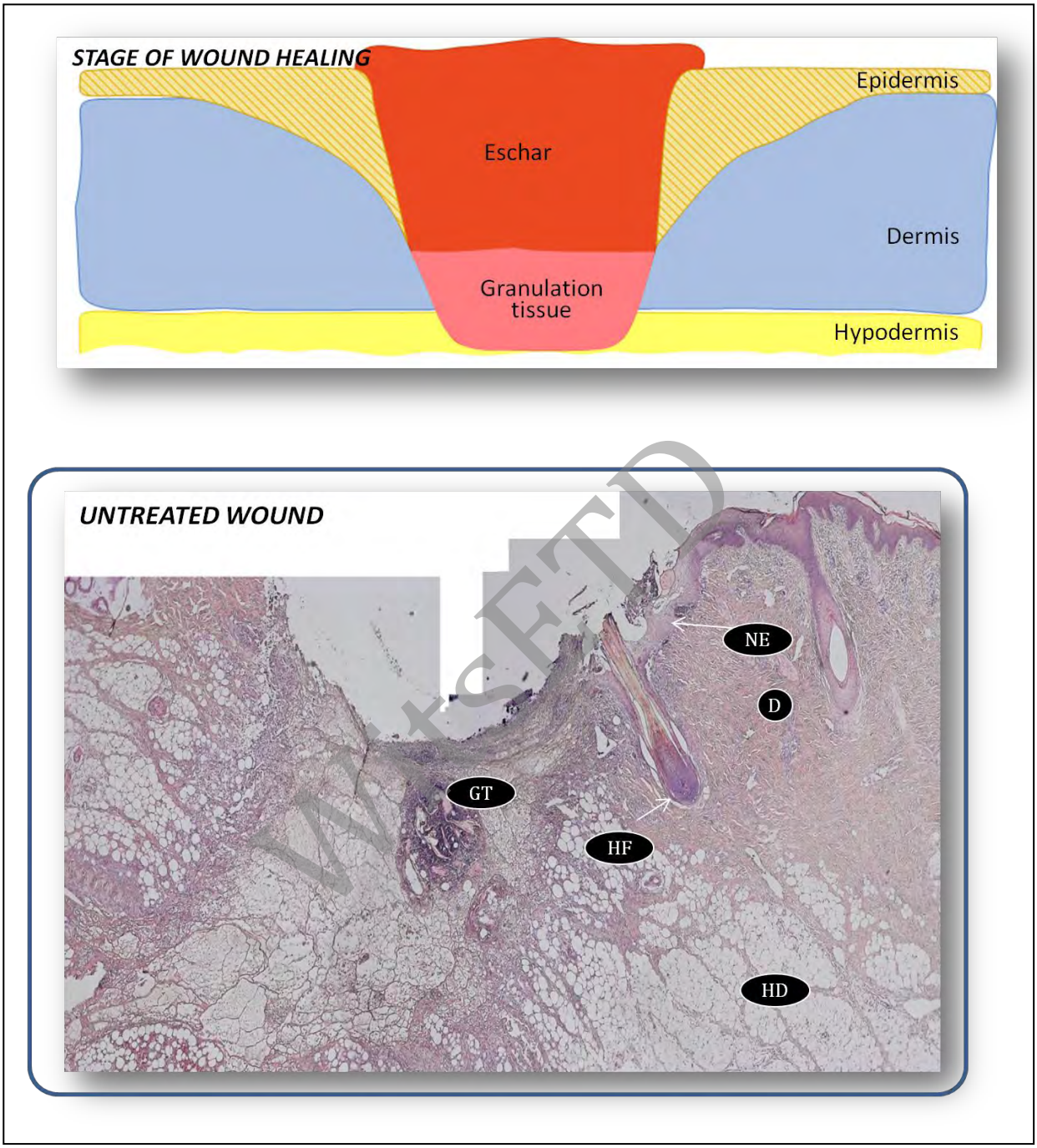

WitsETD

Figure 3.30: Wound healing of untreated tissue on day 4 post-wound creation
A. *Illustration of the stage of wound healing*
B*. Representative histological section of day 4 untreated untreated wound. Note the formation of the neo-epidermis (NE) and the limited area of granulation tissue (GT) formation. Prominent well developed hair follicles (HF) and sebaceous glands (SG) are present in the wound area. This may be due these structures being partly intact following the biopsy and therefore regenerating more quickly.(H and E, x10)*

created with nitroPDF professional
download the free trial online at nitropdf.com/professional

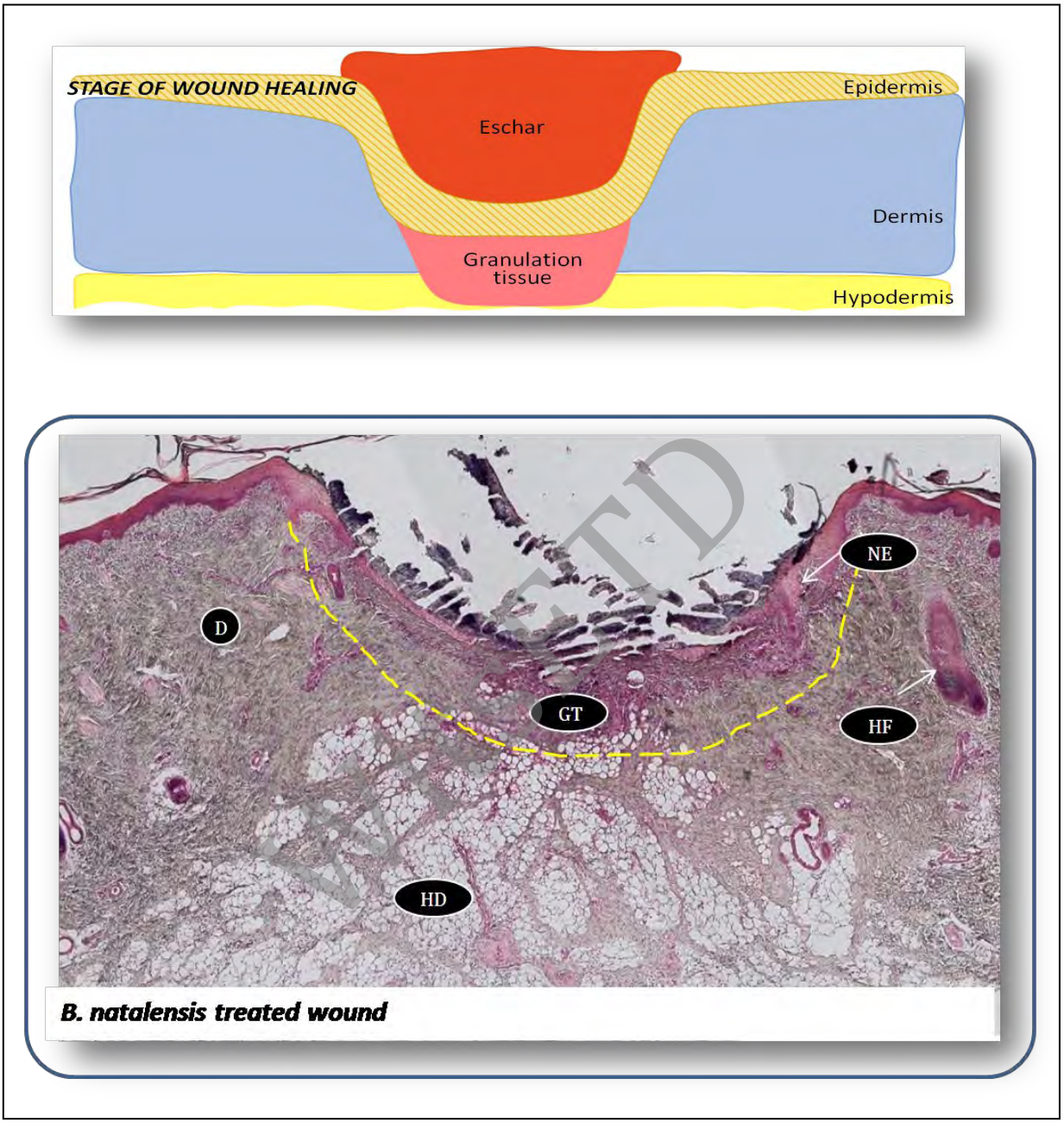

Figure 3.31: Wound healing of B. natalensis-treated tissue on day 4 post-wound creation
A. *Illustration of the stage of wound healing*
B*. Representative histological section of day 4 B. natalensis-treated wound.*
Note the re-epithelisation that is almost complete and the limited area of granulation tissue (GT) present below in the dermis (D) below the neo-epidermis (NE). The wound area is still clearly distinguishable. (H and E, x10)

created with nitroPDF professional
download the free trial online at nitropdf.com/professional

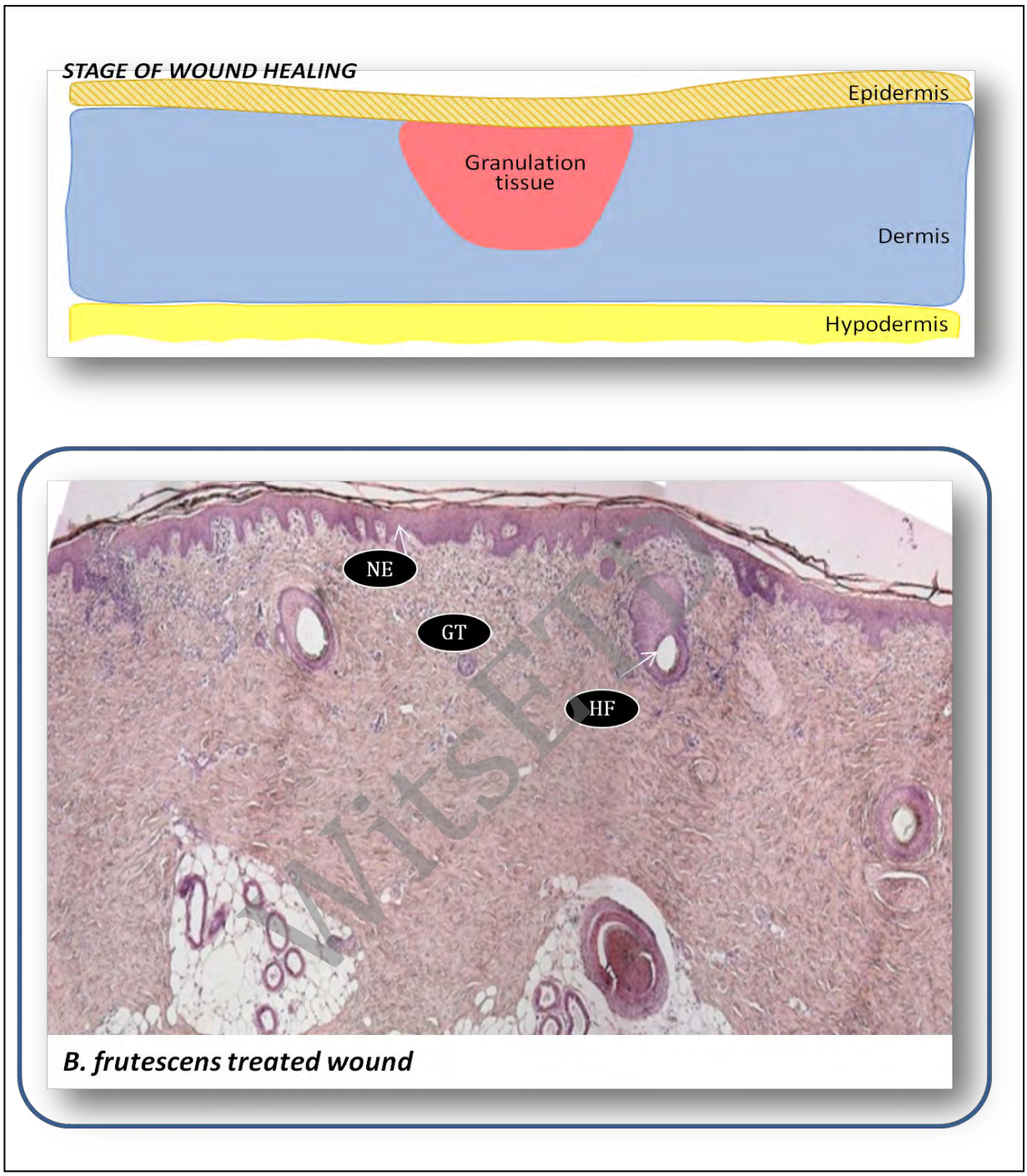

Figure 3.32: Wound healing of B. frutescens-treated tissue on day 4 post-wound creation
A. *Illustration of the stage of wound healing*
B*. Representative histological section of day 4 B. frutescens-treated wound.*
HF- hair follicle; GT- granulation tissue; NE- neoepidermis.
Note the full re-epithelialisation of the wound area and the collagen interspersed in the granulation tissue (GT). The area of the wound is not distinguishable from the surface. The neo-epidermis (NE)has well developed rete ridges. Hair follicles (HF)are visible in the dermis. (H and E, x10)

created with nitroPDF professional
download the free trial online at nitropdf.com/professional

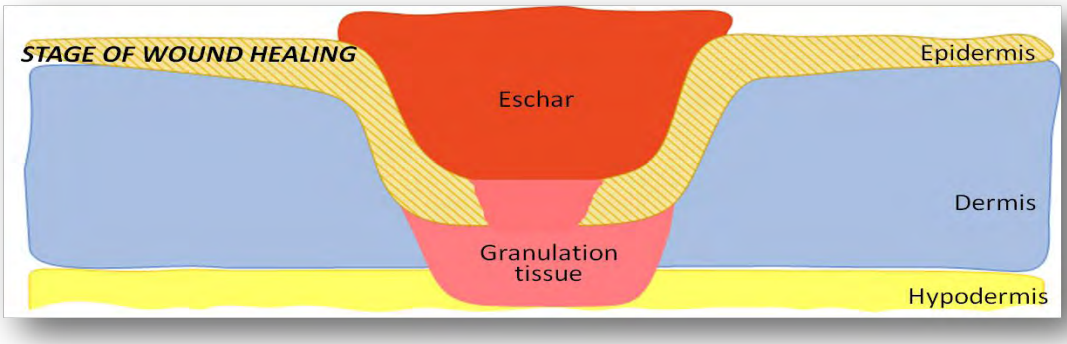

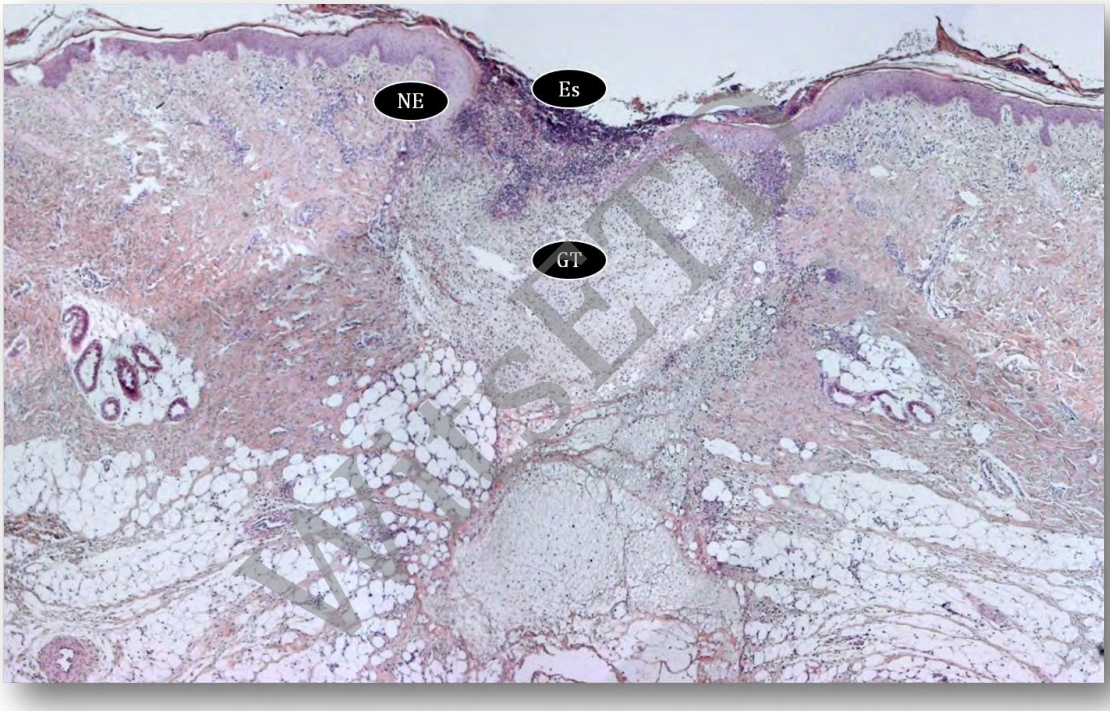

Figure 3.33: Wound healing of B. frutescens-treated tissue on day 4 post-wound creation
A. *Illustration of the stage of wound healing*
B*. Representative histological section of day 4 B. frutescens-treated wound.*
Note the extent of the migration of the neo-epidermis (NE) and the dense granulation tissue (GT) in the dermis below the wound area. The eschar (Es) is visible in the wound space. (H and E, x10)

created with nitroPDF professional
download the free trial online at nitropdf.com/professional

The granulation tissue of the untreated wound on day 4 showed the presence of infiltrating cells, but was less dense than both treatment groups (Fig. 3.34). A large number of fibroblasts were present in the granulation tissue at this stage. The number of blood vessels present in the granulation tissue appeared to be greater than that of the untreated wounds on day 2. The granulation tissue of the *B. natalensis*- and *B. frutescens*-treated groups appeared more dense with fibroblasts and numerous blood vessels when compared to that of the untreated wounds on day 4 (Fig. 3.35 and 3.36). In the *B. frutescens*- treated group, the wounds with full re-epithelialisation and the wounds that had not completely re-epithelialised showed no difference in the granulation tissue.

There was evidence of collagen formation (evident as blue staining in the Mallory trichrome stained sections) in the granulation tissue of all wounds (Fig. 3.37). The collagen deposition although not quantified histologically, appeared to be greater in the *B. frutescens*-treated group than in the *B. natalensis*-treated group. There was little collagen deposition in the untreated groups.

WitsETD

created with nitroPDF professional
download the free trial online at nitropdf.com/professional

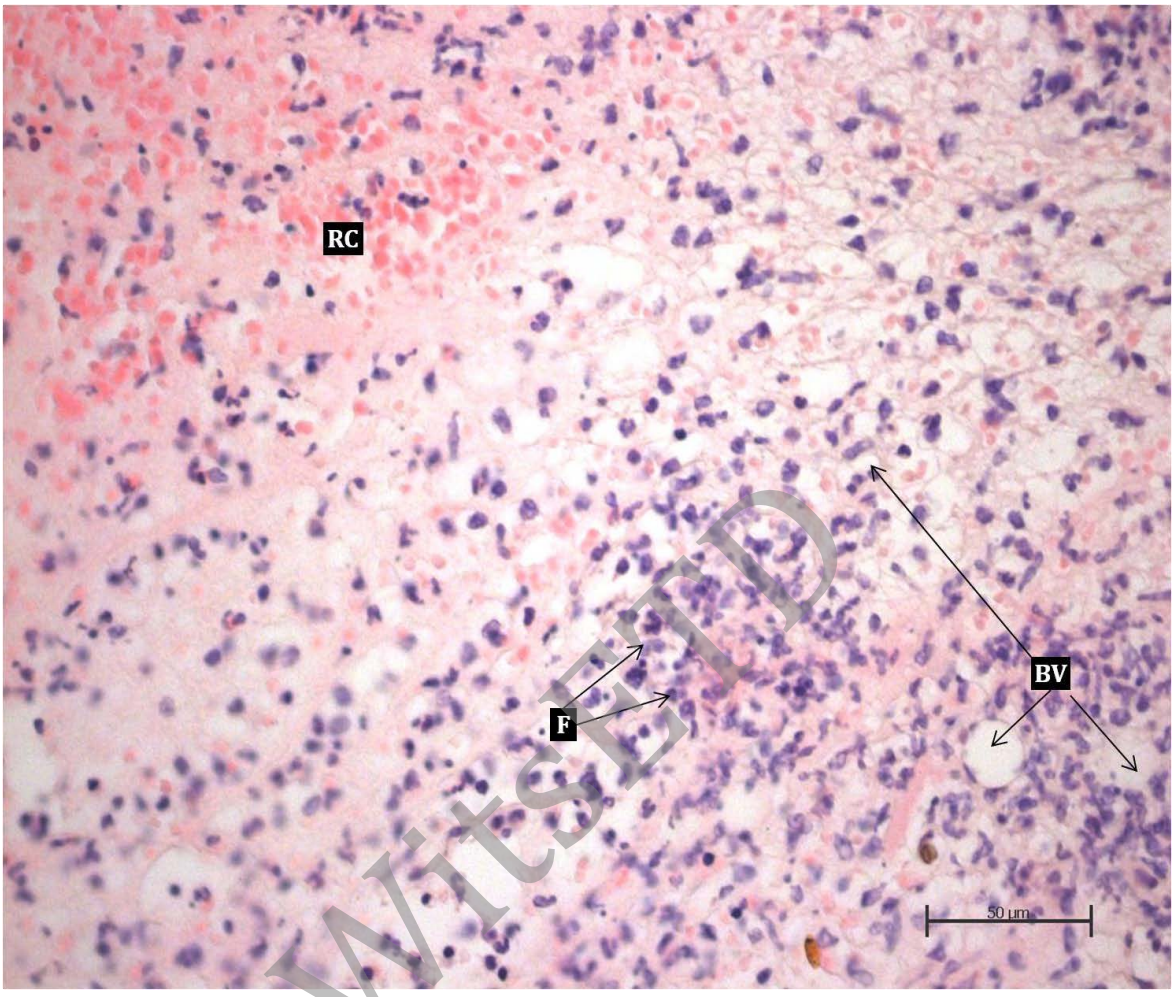

WitsETD

Figure 3.34: Representative histological section of granulation tissue of untreated tissue on day 4 post-wound creation.
Note the granulation tissue has a number of scattered fibroblasts (F) and red blood cells (RC). Numerous blood vessels (BV) are also present
(H and E, x40)

created with nitroPDF professional
download the free trial online at nitropdf.com/professional

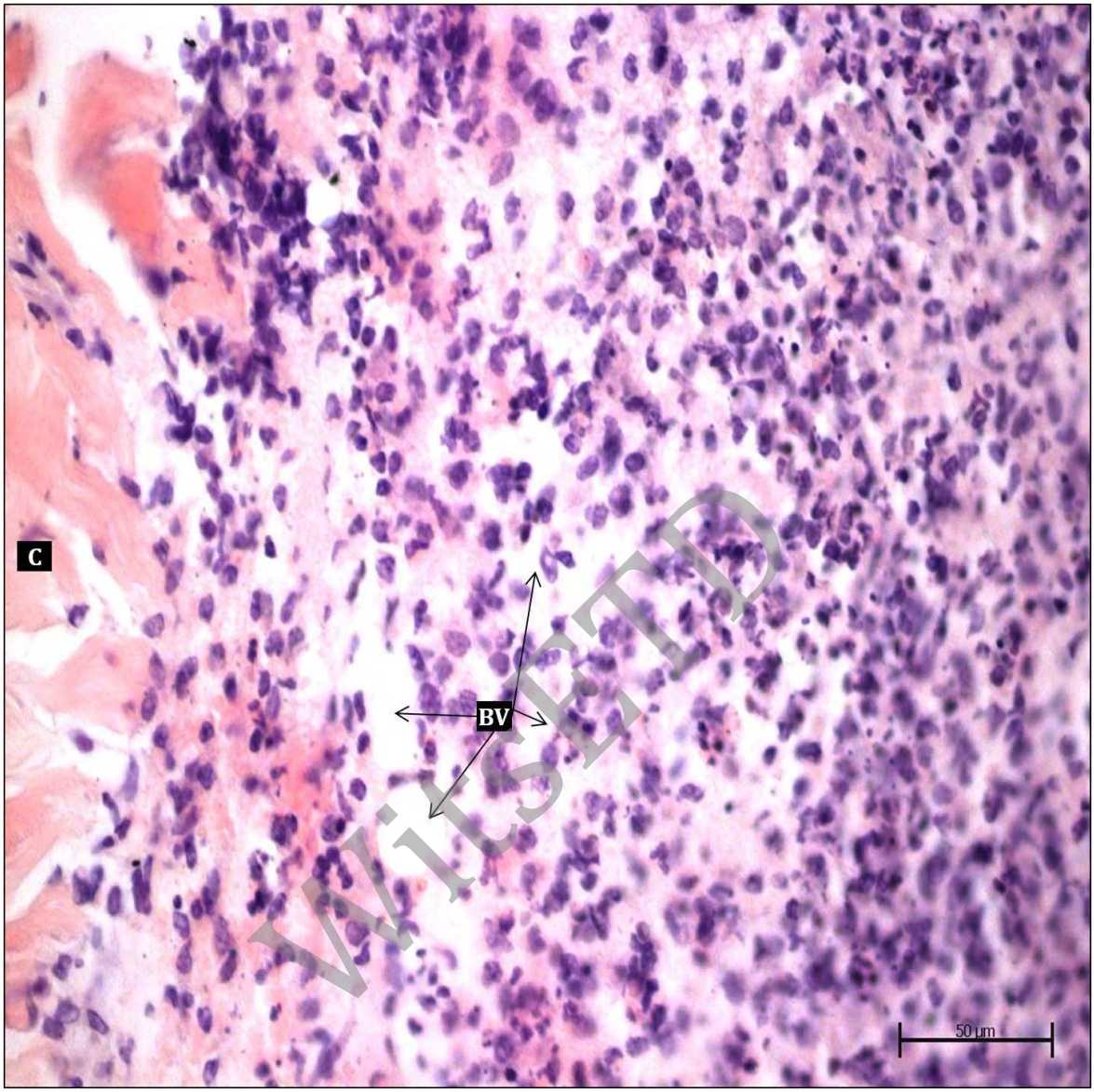

WiSETD

Figure 3.35: Representative histological section of granulation tissue of B. natalensis-treated tissue on day 4 post-wound creation

BV- blood vessels; C- collagen is adjacent tissue

Note the granulation tissue is dense with a large number fibroblasts (F) and numerous blood vessels (BV) (H and E, x40)

created with nitroPDF professional
download the free trial online at nitropdf.com/professional

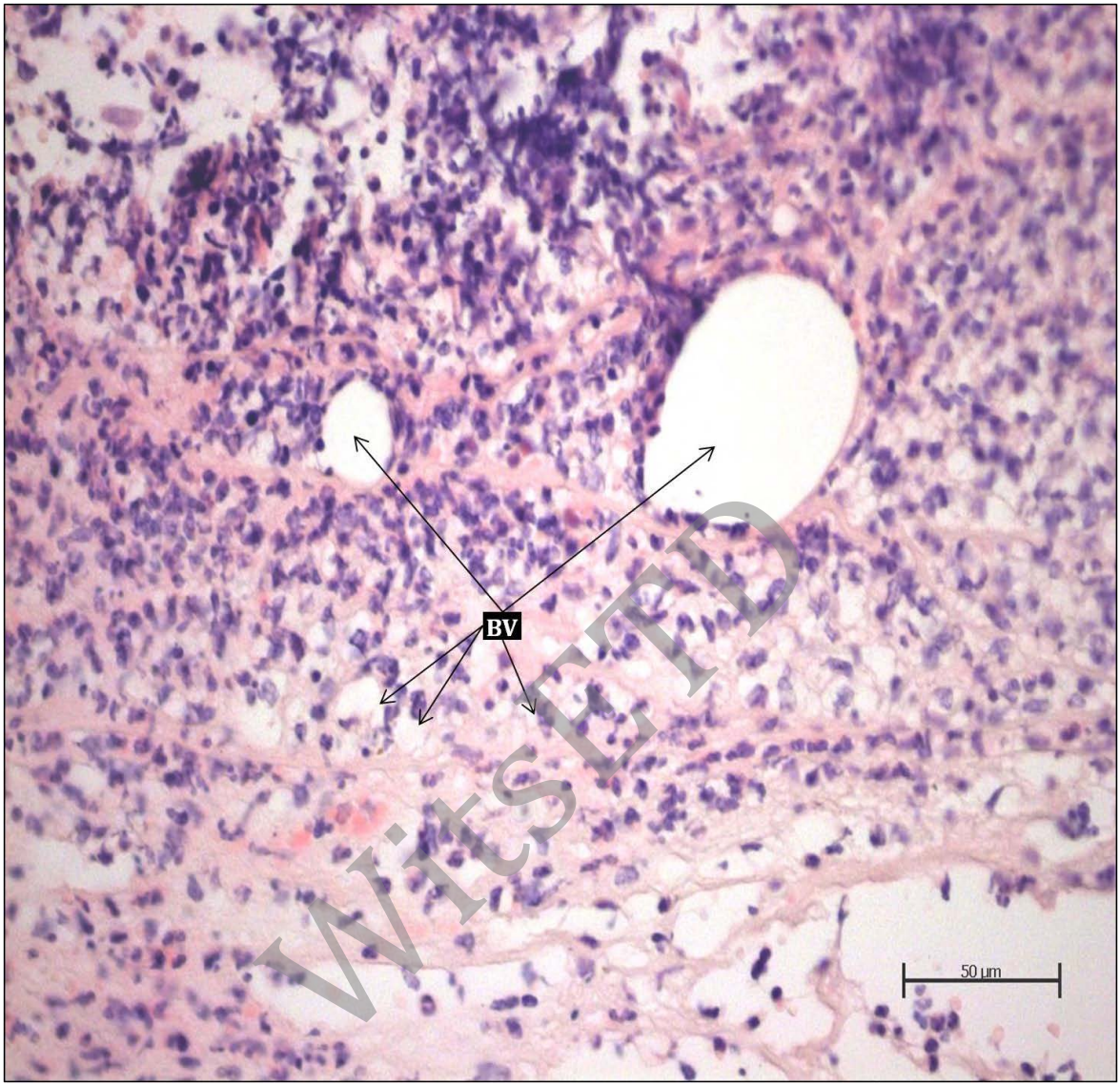

WitsETD

Figure 3.36: Representative histological section of granulation tissue of B. frutescens-treated tissue on day 4 post-wound creation

Note the granulation tissue is dense with a large number o f fibroblast s and blood vessels (BV).(H and E, x40)

created with nitroPDF professional
download the free trial online at nitropdf.com/professional

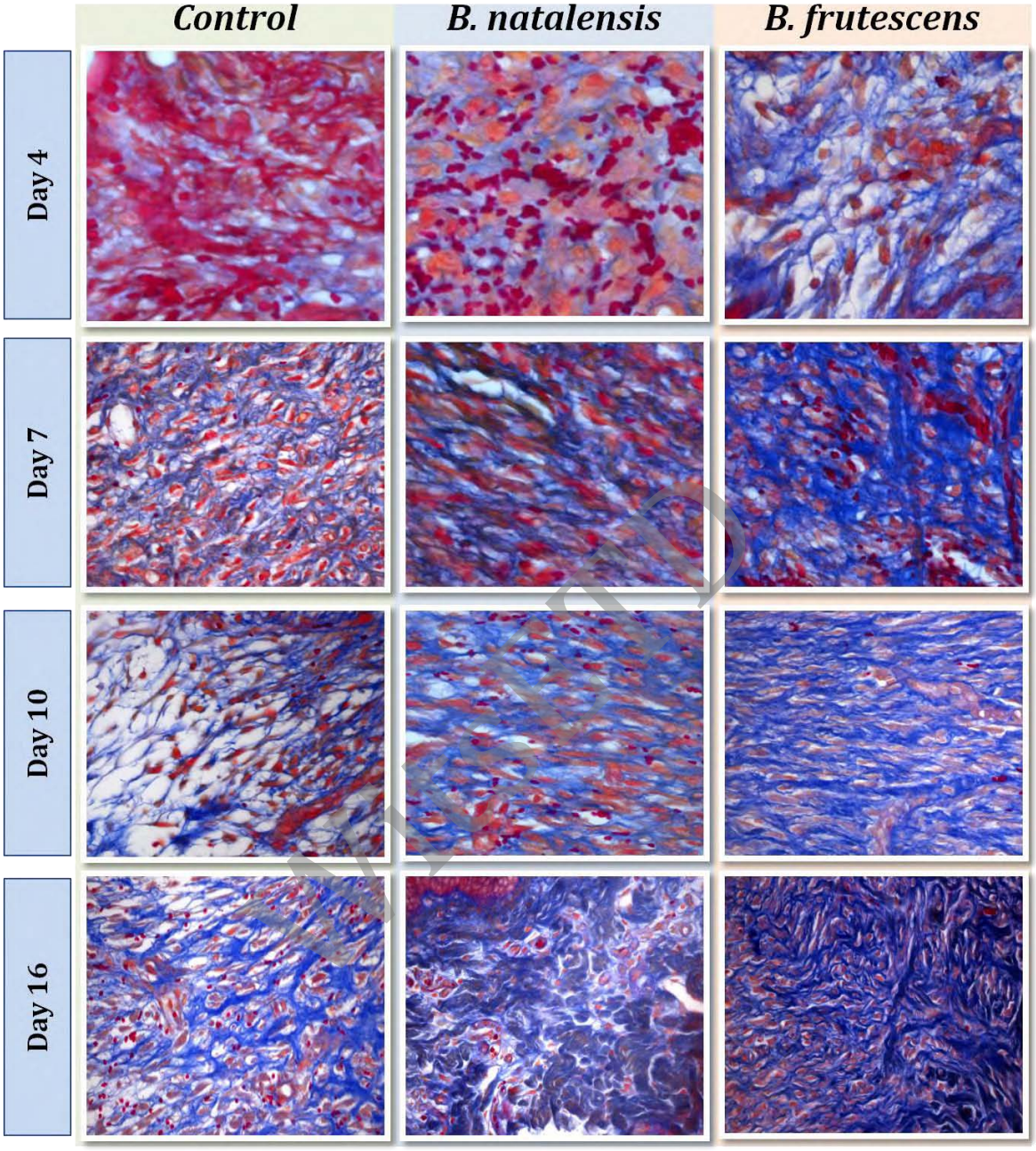

Figure 3.37: Representative histological sections of day 4 to day 16 post-wound creation
Note: the collagen fibres are stained blue. There appears to be a gradual increase in the deposition of collagen in all groups from day 4 to day 16. There also appears to be an increase in collagen in both treatment groups compared to the untreated wounds.(Mallory trichrome, x40)

created with nitroPDF professional
download the free trial online at nitropdf.com/professional

In one of the *B. natalensis*-treated wounds on day 4, there was complete re-epithelialisation of the wound area (Fig. 3.38). In this specimen, the granulation tissue was very dense with many fibroblasts and numerous blood vessels. There was also growth of the epithelial layer into the granulation tissue. No hair follicles were present in this wound.

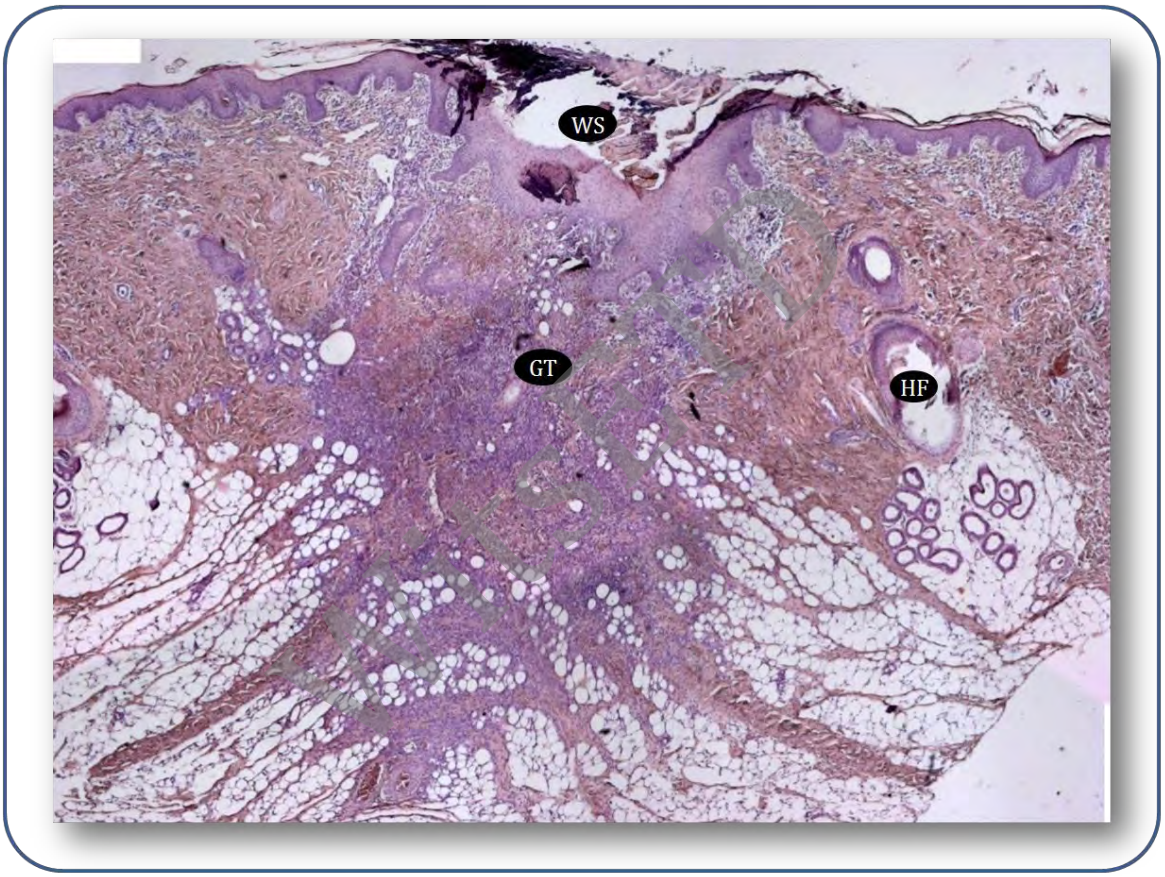

Figure 3.38: Wound healing of B. natalensis-treated tissue on day 4 post-wound creation
Note the extensive growth of the epithelium into the granulation tissue (GT). The thick neo-epidermis has completely re-epithelialised the wound area (WS). There are a number of blood vessels present in the granulation tissue. The wound area has no hair follicles present although both hair follicles and glands can be seen at the periphery of the wound . (H and E, x5)

created with nitroPDF professional
download the free trial online at nitropdf.com/professional

Wound healing on day 7 post-wound creation

The mean maximal distance between the wound edges for the untreated, the *B. natalensis*-treated and the *B. frutescens*-treated wounds is shown in Table 3.9. The wound contraction of the untreated group was not statistically different from that of the treated groups on day 7 post wounding. There was also no statistically significant difference between the two treatment groups.

Migration of keratinocytes to cover the wound area was complete in all three groups (Figs. 3.39, 3.40 and 4.41). However, the wound 'space' was clearly visible in the untreated group (Fig. 3.39) as a depression on the skin surface. This depression was not visible in either of the treatment groups (Figs. 3.40 and 3.41). In the *B. frutescens*-treated group, the area of the wound on the surface of the skin was indistinguishable from the surrounding area. The neo-epidermis was thicker in the *B. natalensis*-treated wounds than the untreated and the *B. frutescens*-treated wounds. The basement membrane was clearly visible throughout the neo-epidermis of all three groups. In the untreated wounds, rete ridges were not present while in both the treated groups these ridges were beginning to be evident.

WiseTD

created with nitroPDF professional
download the free trial online at nitropdf.com/professional

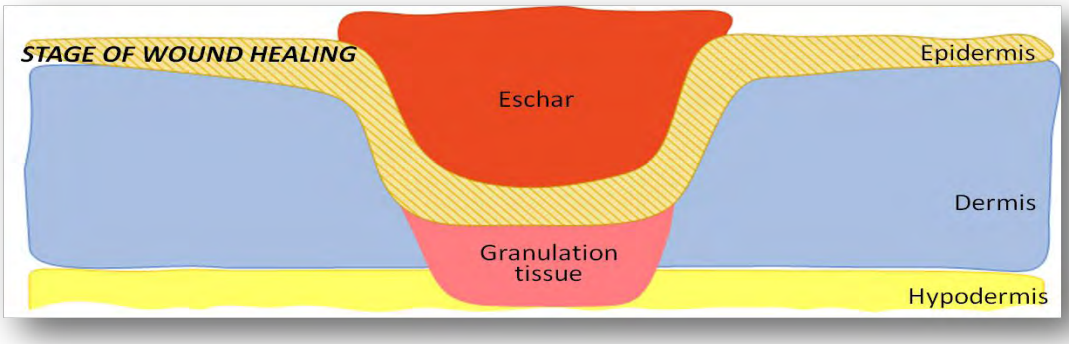

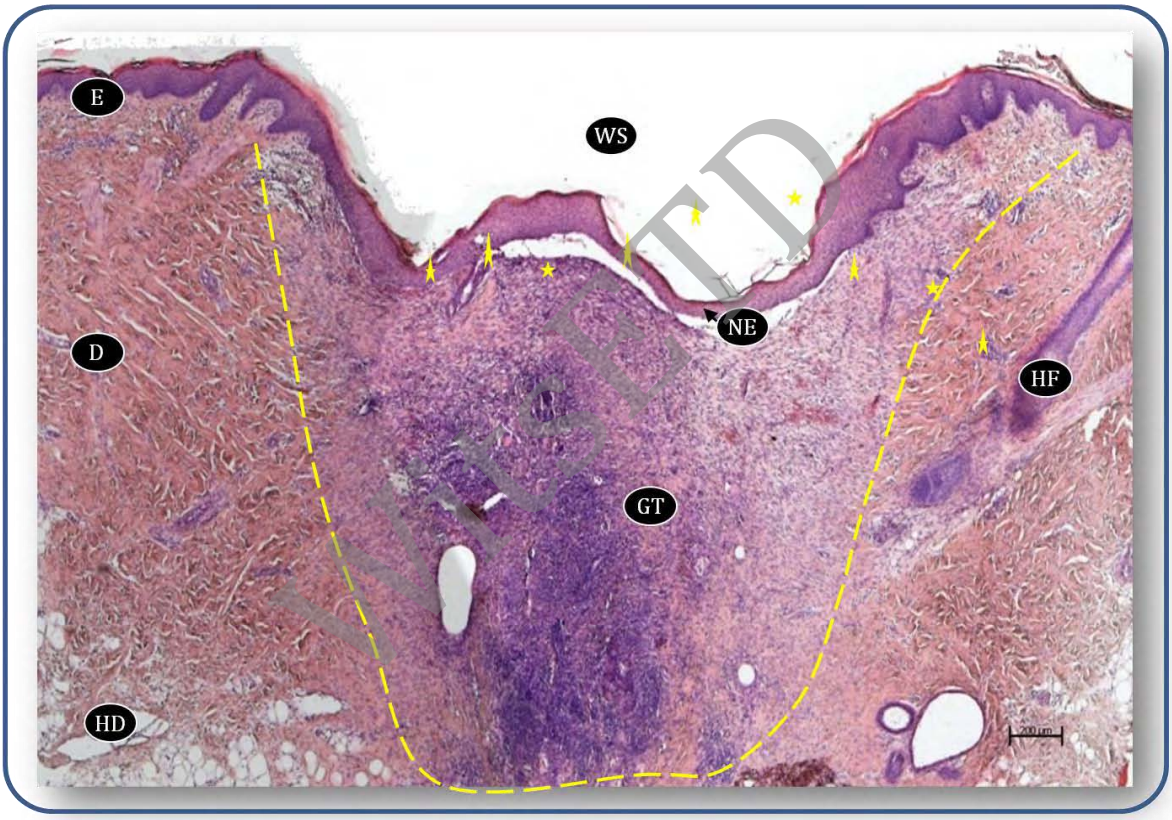

Figure 3.39: Wound healing of untreated tissue on day 7 post-wound creation
A. *Illustration of the stage of wound healing*
B*. Representative histological section of day 7 untreated wound.*
WS- wound space; E- epidermis; D- dermis; HD- hypodermis; HF- hair follicle; GT- granulation tissue; NE- neo-epidermis. Note the complete re-epithelialisation of the wound (ne) and the dense granulation tissue (GT). The wound space (WS) is still distinguishable from the surrounding tissue. The adjacent dermis (D) has hair follicles (HF) and an underlying hypodermis is visible (H and E, x5)

created with nitroPDF professional
download the free trial online at nitropdf.com/professional

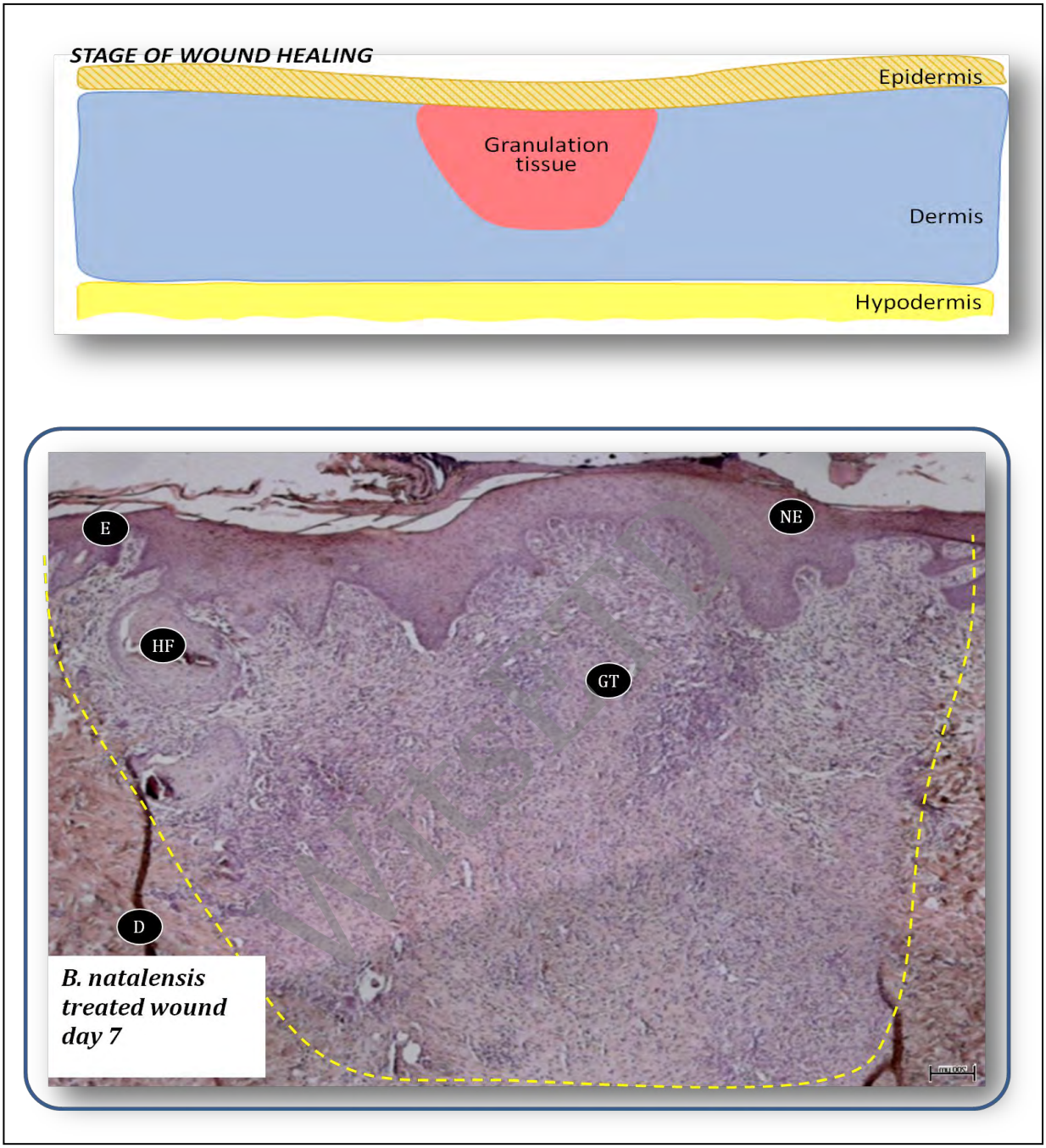

Figure 3.40: Wound healing of B. natalensis-treated tissue on day 7 post creation.
A. *Illustration of the stage of wound healing*
B. *Representative histological section of day 7 B. natalensis-treated wound. Note complete re-epithelisation of the wound area and the neo-epidermis (NE) and the dense granulation tissue (GT) in the dermis (D)below the wound area. The neo-epidermis is several layers thick. (H and E, x10)*

created with nitroPDF professional
download the free trial online at nitropdf.com/professional

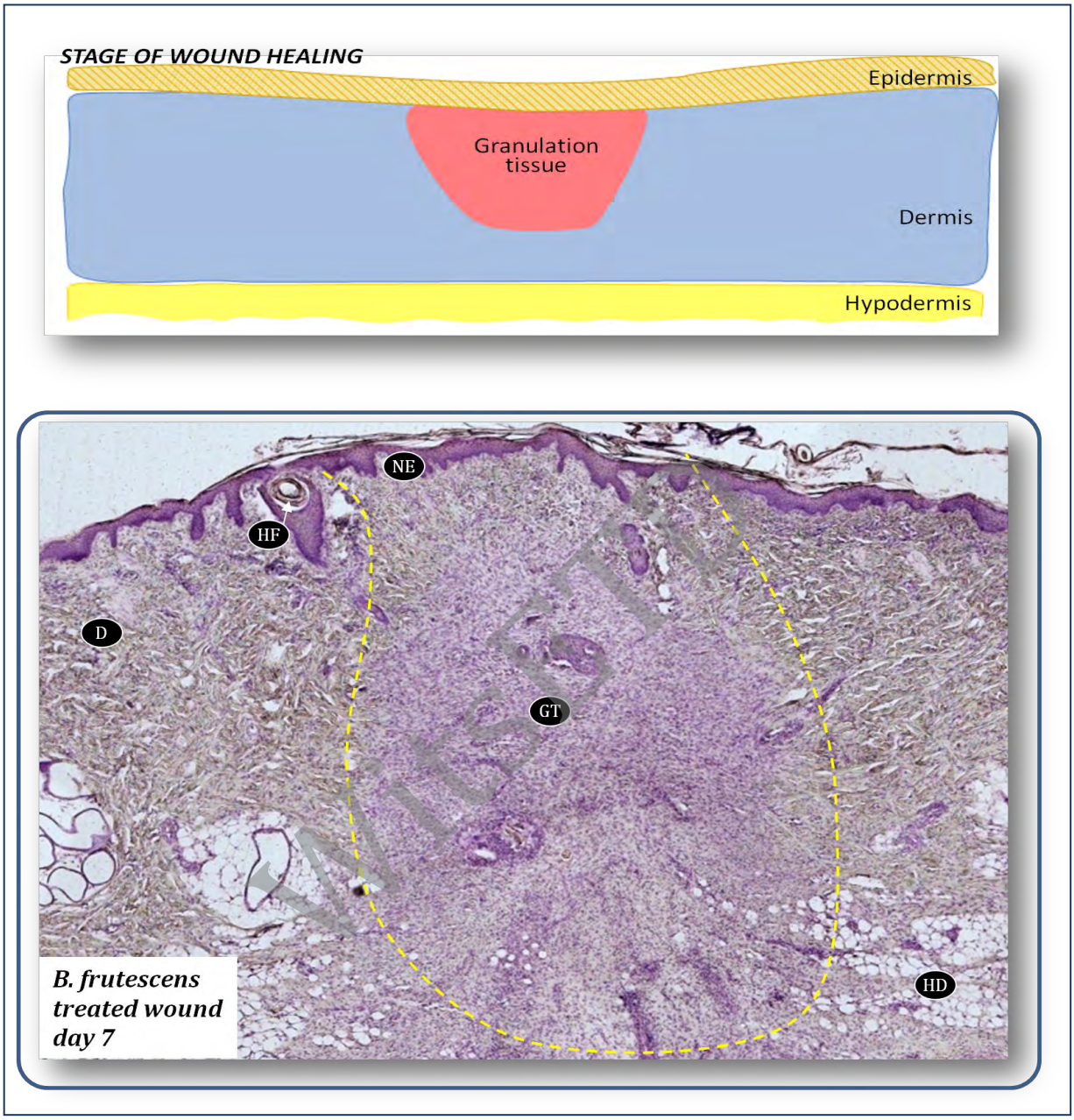

Figure 3.41: Wound healing of B. frutescens-treated tissue on day 7 post-wound creation.
A. *Illustration of the stage of wound healing*
B. *Representative histological section of day 7 B. frutescens-treated wound.*
Note the complete re-epithelisation of the wound area and the neo-epidermis (NE). The granulation tissue (GT) spans a wide area in the dermis (D). Superficially, the wound area is indistinguishable from the surrounding tissue on the surface. Fat cells are visible in the hypodermis (HD) (H and E, x10)

created with nitroPDF professional
download the free trial online at nitropdf.com/professional

By day 7 post-wounding, the granulation tissue of all the groups of wounds was well formed with a dense population of fibroblasts (Fig. 3.42). The granulation tissue of the *B. natalensis* treated group was more extensive (i.e. spanned a wider area) than that of the untreated group (Fig. 3.40). There was evidence of collagen formation in the granulation tissue of all wounds (Figs. 3.42 and 3.37). The collagen appeared to be more dense in both treatment groups than the untreated group and appeared much more dense in the *B. frutescens* group in the *B. natalensis* group (Fig. 3.37). In all groups, the collagen fibres appeared to be arranged in parallel.

WitsETD

created with nitroPDF professional
download the free trial online at nitropdf.com/professional

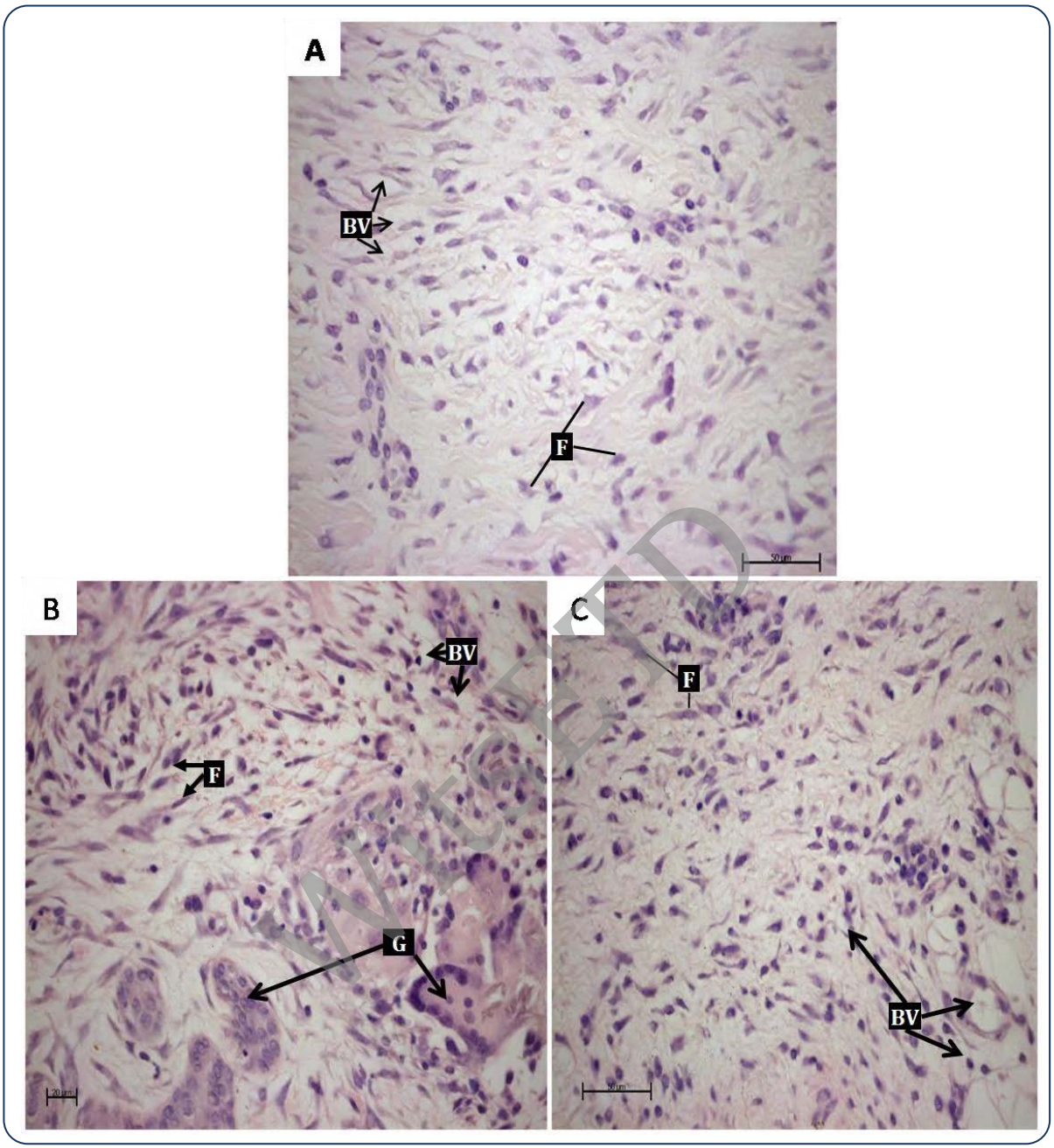

Figure 3.42: Representative histological section of granulation tissue on day 7 post-wounding. ***A.*** *Untreated wound tissue;* ***B****. B. natalensis- treated tissue and* ***C-*** *B. frutescens-treated wound. Note the scattered fibroblasts (F) of the granulation tissue which is denser in both treatment groups than in the untreated wound. The B. frutescens tissue has a large number of blood vessels (BV) present. There is some glandular tissue (G) formation evident in the B. natalensis treated tissue. (H and E, x40)*

created with nitroPDF professional
download the free trial online at nitropdf.com/professional

Wound healing on day 10 post-wound creation

The mean maximal distance between the wound edges for the untreated, the *B. natalensis*-treated and the *B. frutescens*-treated wounds is shown in Table 3.9. The wound contraction of the untreated group was significantly less than that of *B. natalensis* treated group (p=0.03).

Migration of keratinocytes to cover the wound area was complete and the wound space was not visible superficially in all three groups. In the untreated wounds, this neo-epidermis was well developed and growth of the epidermis into the granulation tissue was apparent (Fig. 3.43). This was especially evident in areas in which hair follicles were present. The stratum basale was clearly visible throughout the neo-epidermis of all three treatment groups (Fig. 3.43, 3.44 and 3.45). Rete ridges in the epidermis were not well developed in the untreated wounds. In the *B. natalensis* treated group, the rete ridges appeared to be more developed but not as distinct as the surrounding unwounded tissue (Fig. 3.44). In 66% of the *B. frutescens*-treated wounds on day 10, the rete ridges were not well developed (Fig. 3.45) but in the remaining 33% of the wounds, the rete ridges were very well developed and appeared exaggerated (Fig. 3.46). The more developed rete ridges were accompanied by a greater distribution of hair follicles in the wound area. The thickness of the epidermis was similar in both treatment groups and was thicker than that of the untreated wounds. Several hair follicles were present in the granulation tissue of the wounds of all treatment groups. The vascularity of the tissue was also similar for all groups.

WitsETD

created with nitroPDF professional
download the free trial online at nitropdf.com/professional

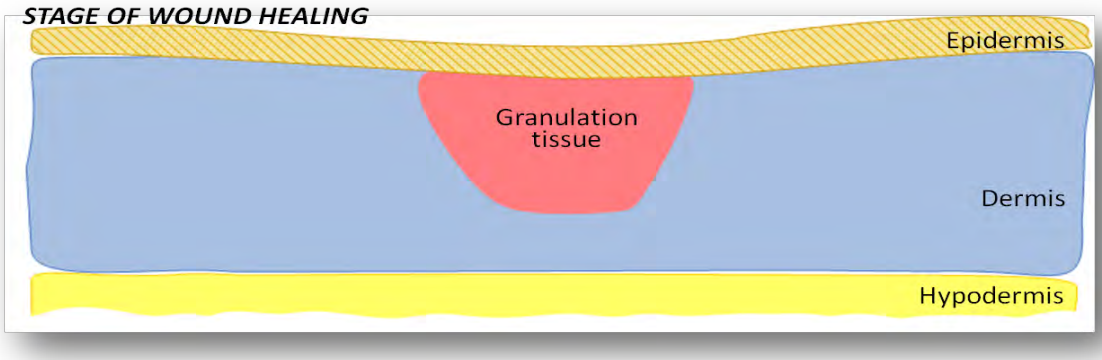

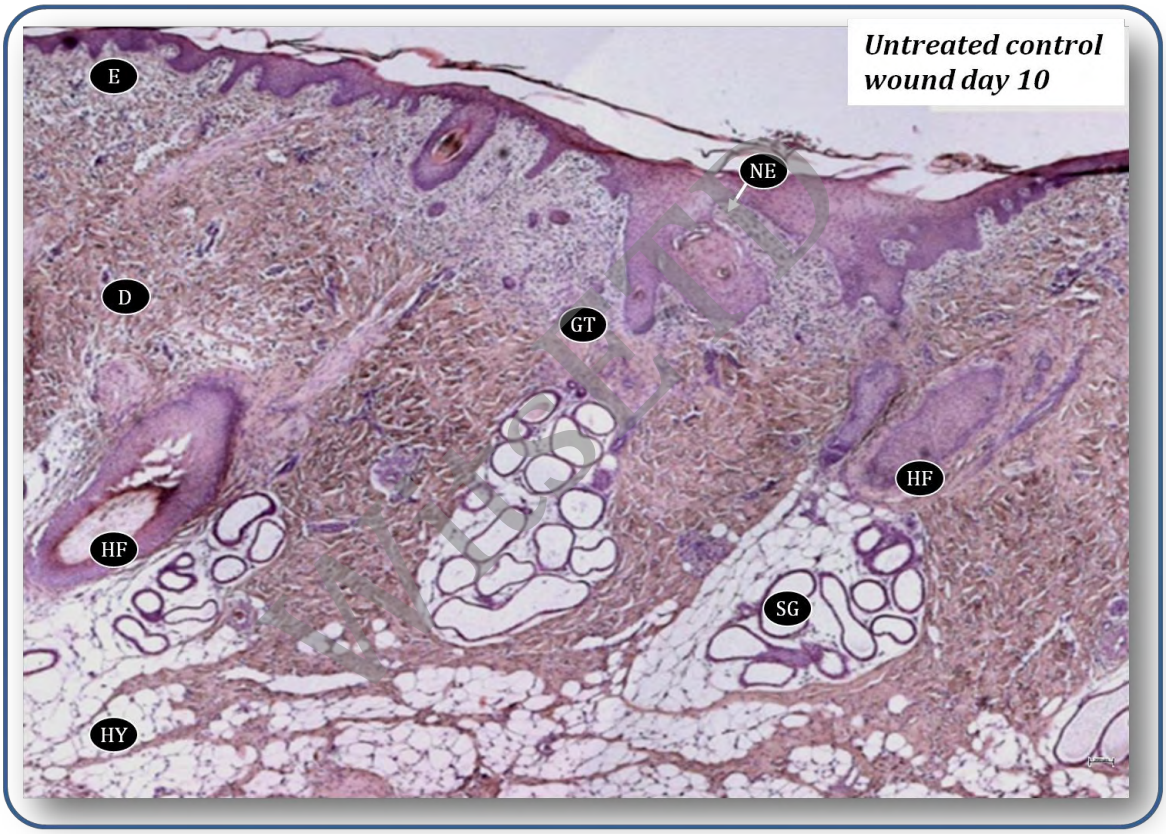

Figure 3.43: Wound healing of untreated tissue on day 10 post-wound creation
A. *Illustration of the stage of wound healing*
B *Representative histological section of day 10 untreated wound.*
Note the complete re-epithelisation of the wound area and the thick neo-epidermis (NE) that has infiltrated into the granulation tissue (GT). There are several hair follicles (HF) visible in the wound space and adjacent dermis (D). (H and E, x10)

created with nitroPDF professional
download the free trial online at nitropdf.com/professional

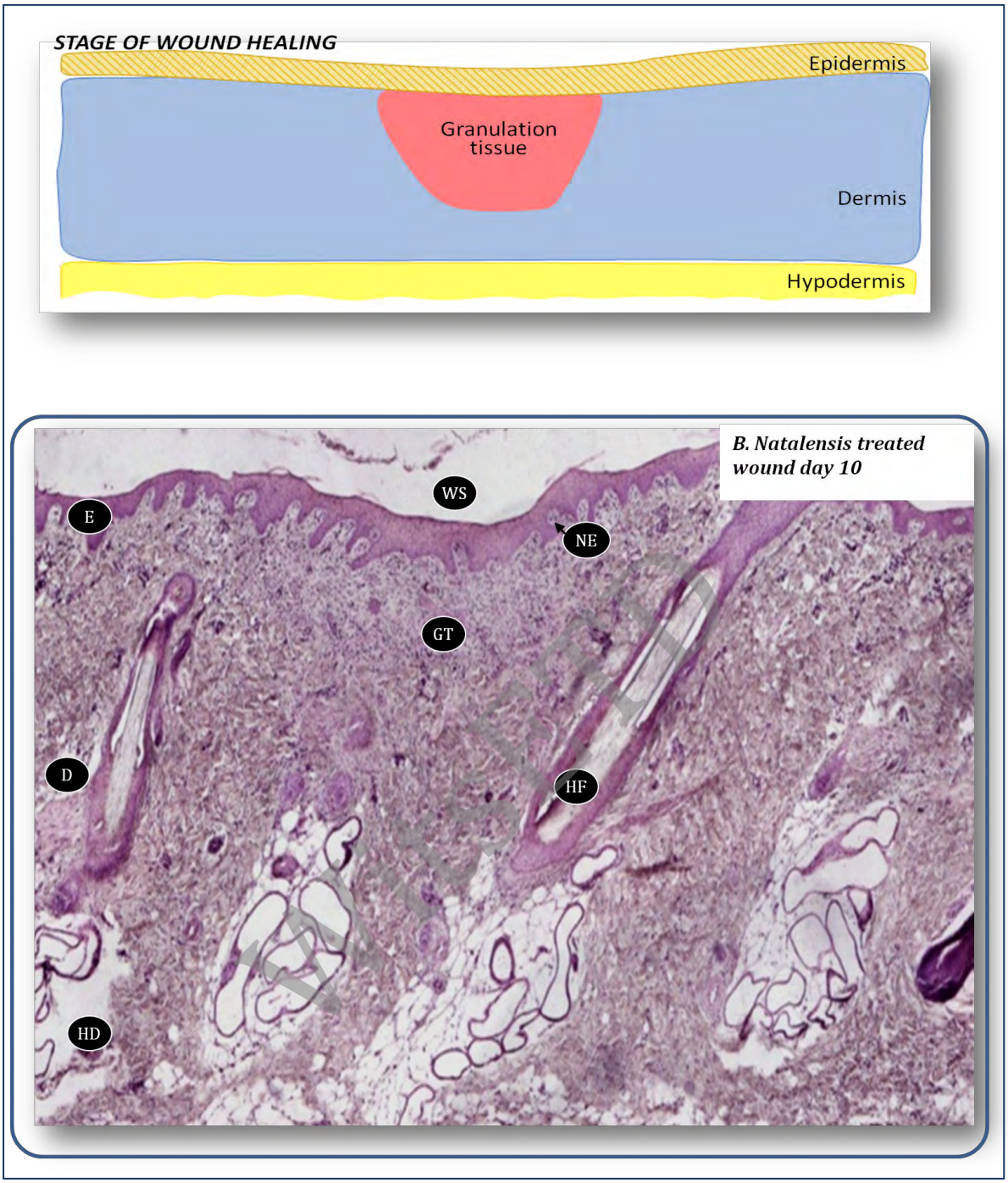

Figure 3.44: Wound healing of B. natalensis-treated tissue on day 10 post-wound creation
A. *Illustration of the stage of wound healing*
B *Representative histological section of day 10 B. natalensis-treated wound.*
Note the complete re-epithelisation of the wound area and the thick neo-epidermis (NE) with rete ridges below the wound space (WS). There are several hair follicles (HF) visible in the granulation tissue (GT) and adjacent dermis (D). (H and E, x10)

created with nitroPDF professional
download the free trial online at nitropdf.com/professional

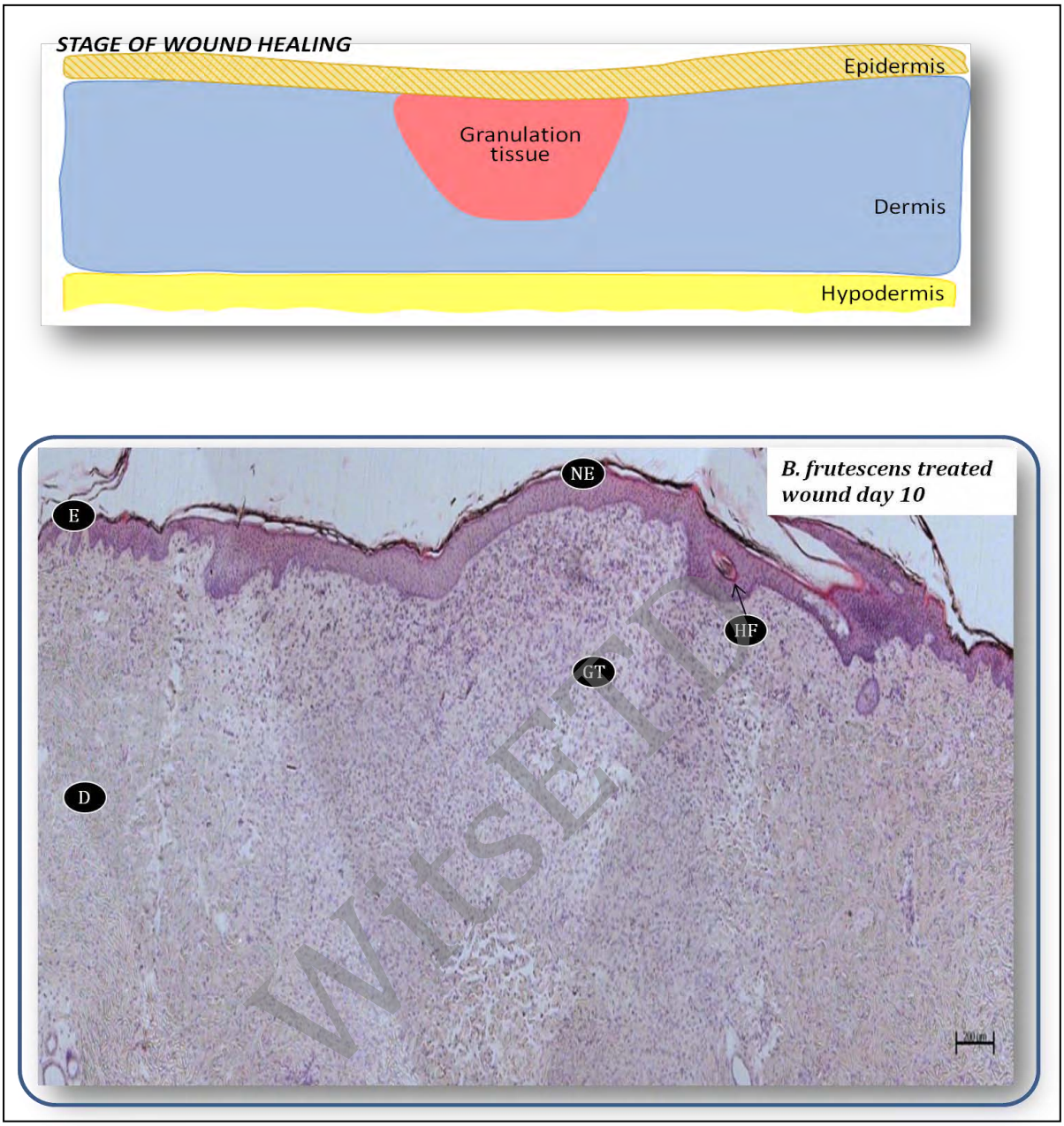

Figure 3.45: Wound healing of B. frutescens-treated tissue on day 10 post-wound creation
A. *Illustration of the stage of wound healing*
B *Representative histological section of day 10 B. frutescens-treated wound.*
Note the complete re-epithelisation of the wound area and the neo-epidermis (NE) that has no rete ridges. The granulation tissue (GT) is sparse and the dermis has few hair follicles (HF). (H and E, x10)

created with nitroPDF professional
download the free trial online at nitropdf.com/professional

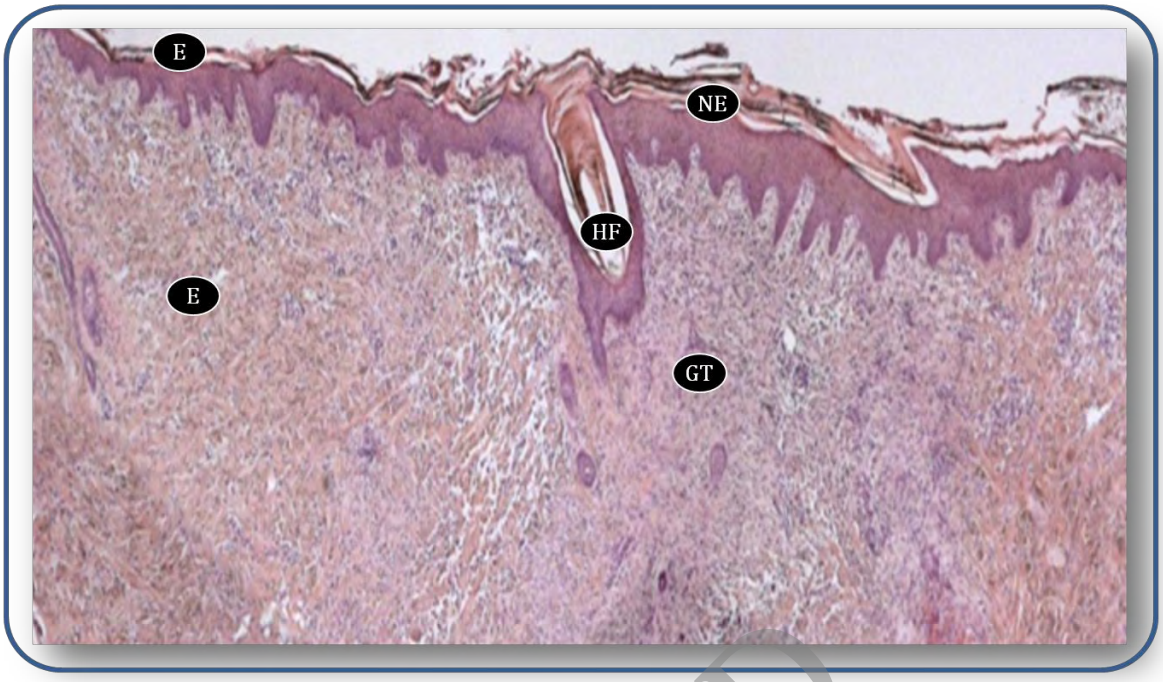

Figure 3.46: Wound healing of B. frutescens-treated tissue on day 10 post-wound creation
Note the complete re-epithelisation of the wound area and the thick neo-epidermis (NE) with exaggerated rete ridges. There is a prominent hair follicle (HF) visible in the wound area. (H and E, x10)

WitsETD

created with nitroPDF professional
download the free trial online at nitropdf.com/professional

On day 10 post-wounding, the granulation tissue of all groups of wounds was well formed (Fig. 3.47 B-D). There appeared to be more fibroblasts present in the untreated tissue than in both treatment groups. All three groups had blood vessels present in the granulation tissue. The treated groups, however, displayed a greater density of vessels and a number of larger vessels. Collagen fibres were present in all wounds. The collagen was more loosely arranged in the untreated wounds (Fig. 3.37) than in the treated groups. In the treated groups, the collagen appeared to be irregular while in the untreated group the fibres where parallel and regular.

WitsETD

created with nitroPDF professional
download the free trial online at nitropdf.com/professional

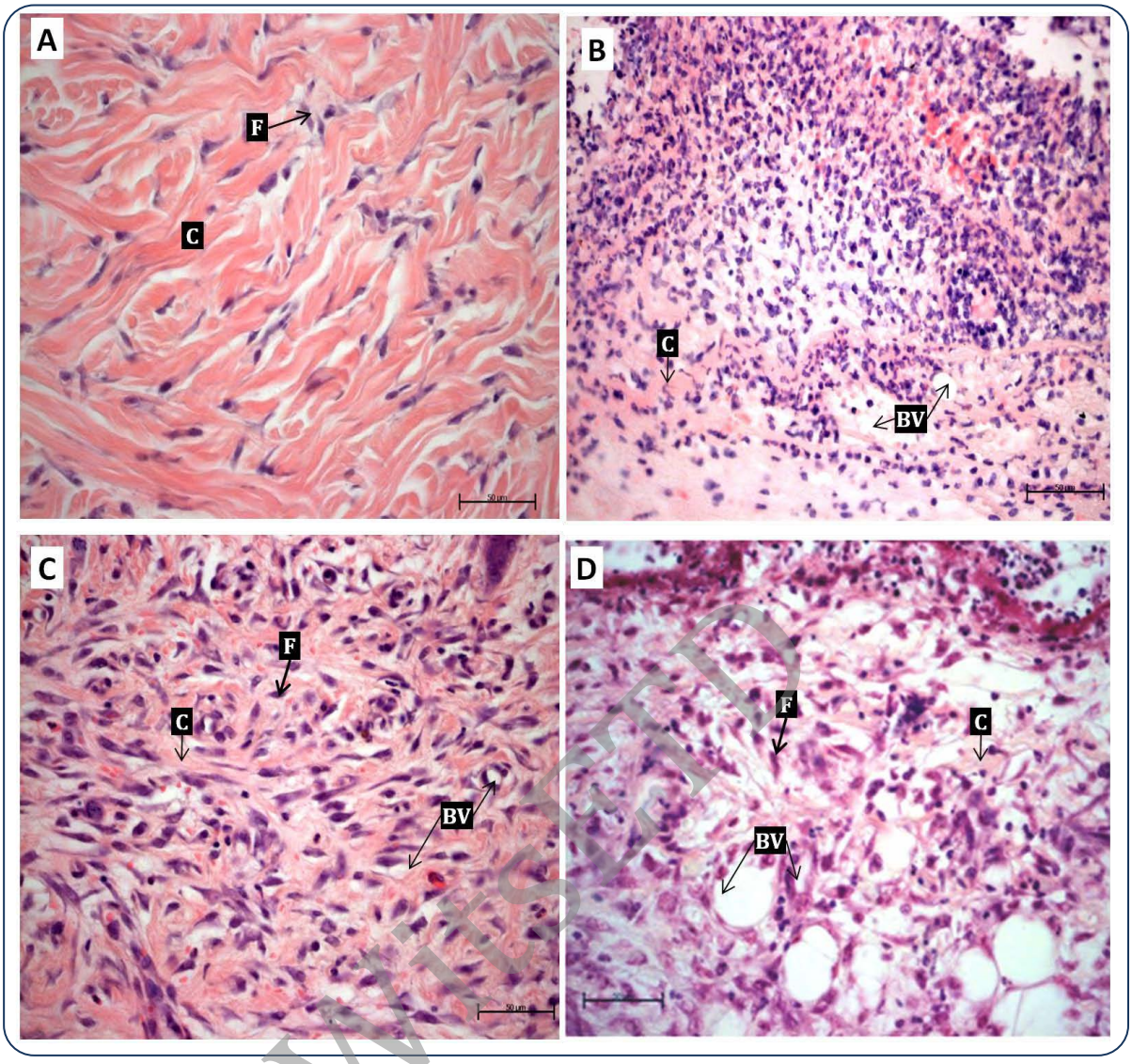

Figure 3.47: Representative histological sections of :
A*-normal unwounded dermis;*
B*- Granulation tissue of untreated wound on day 10 post-wound creation;*
C*- Granulation tissue of B. natalensis- treated wound on day 10 post-wound creation tissue;* ***D****-Granulation tissue of B. frutescens-treated wound on day 10 post-wound creation*
Note the scattered fibroblasts (F) in the granulation tissue with several blood vessels (BV) (H and E, x40)

created with nitroPDF professional
download the free trial online at nitropdf.com/professional

Wound healing on day 16 post-wound creation

By day 16, the wounds in all three groups had completed contraction and re-epithelialisation (Figs. 3.48, 3.49 and 3.50). When viewed from the exterior, the wounds of both treatment groups were indistinguishable from the surrounding tissue. The wound area of the untreated group was faintly visible.

Migration of keratinocytes to cover the wound area was complete in all three groups by day 16 (Figs. 3.48, 3.49 and 3.50). The neo-epidermis of the untreated group showed some growth of the epidermis into the granulation tissue (Fig. 3.48). The basement membrane was clearly visible throughout the neo-epidermis of all three groups. Once again, the epidermal rete ridges were not well formed in the untreated wounds (Fig. 3.48). In the *B. natalensis* treated group, the rete ridges appeared to be more developed and were very similar to the adjacent unwounded tissue. The thickness of the epidermis was similar in both treatment groups and thicker than that of the untreated wounds.

WitsETD

created with nitroPDF professional
download the free trial online at nitropdf.com/professional

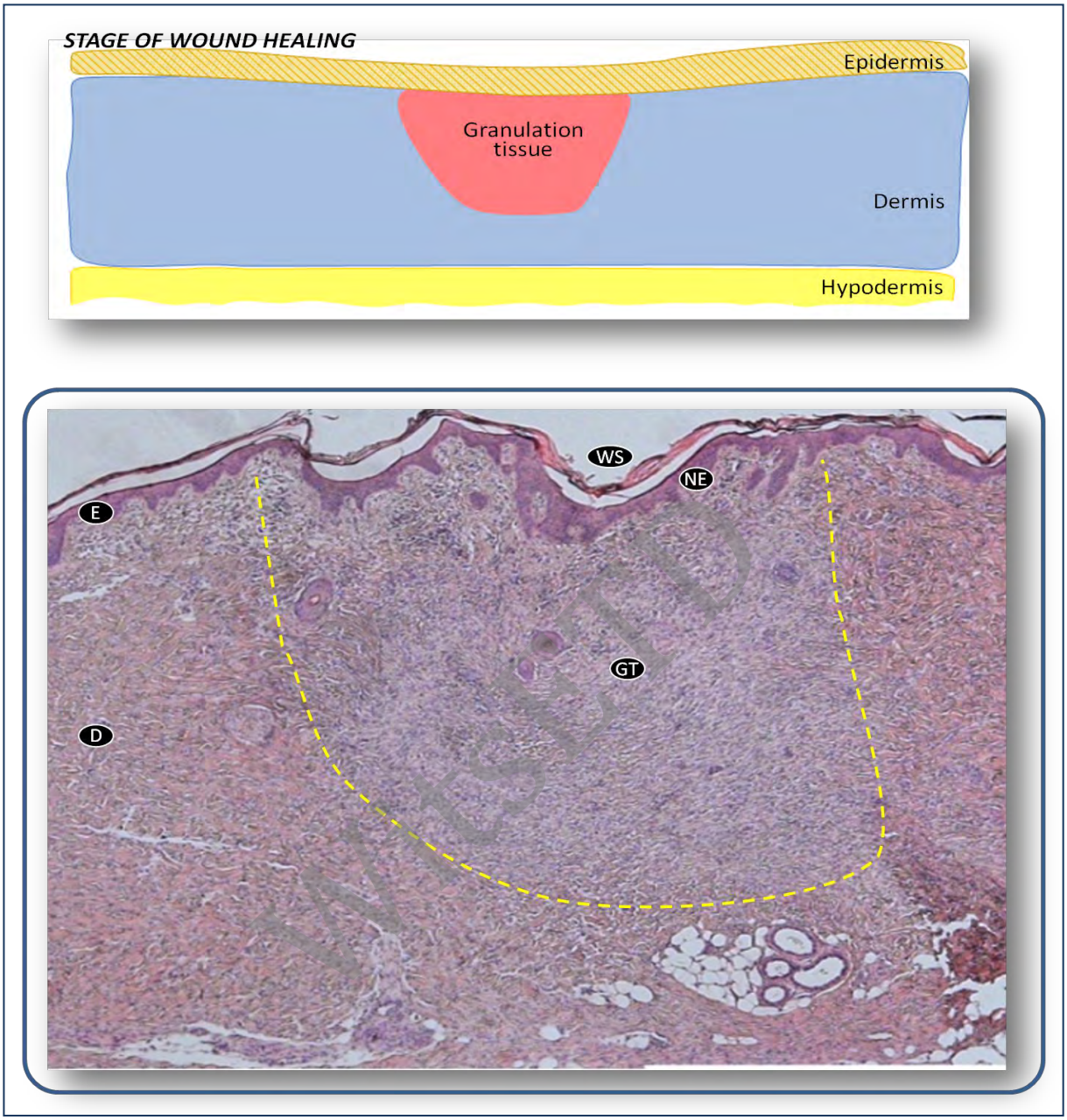

Figure 3.48: Wound healing in untreated tissue on day 16 post-wound creation
A. *Illustration of the stage of wound healing*
B. *Representative histological section of day 16 untreated wound.*
Note the complete re-epithelisation of the wound area and the neo-epidermis (NE) that shows some formation of rete ridges. There are several hair follicles visible in the granulation tissue (GT) of the wound area and in the adjacent dermis (D). The wound space (WS) is distinguishable from the adjacent epidermis (E) on the surface of the skin. (H and E, x10)

created with nitroPDF professional
download the free trial online at nitropdf.com/professional

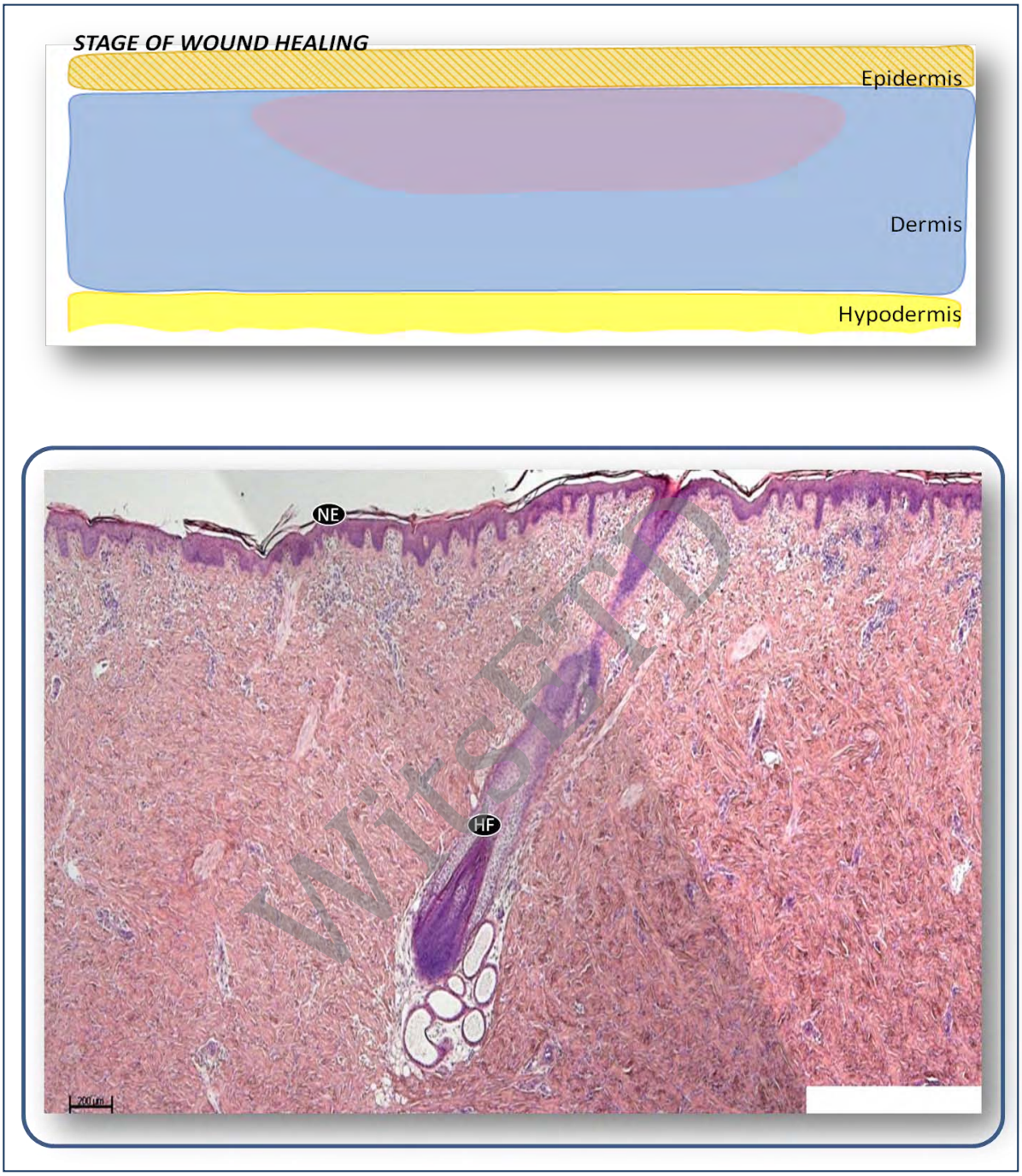

WitsETD

Figure 3.49: Wound healing of a B. natalensis-treated tissue day 16 post-wound creation
A. *Illustration of the stage of wound healing*
B *Representative histological section of day 16 B. natalensis-treated wound. Note the complete re-epithelisation of the wound area and the neo-epidermis (NE) that is indistinguishable from the surrounding tissue. There are several well formed rete ridges. There is a prominent hair follicle and glands visible in the wound area. (H and E, x10)*

created with nitroPDF professional
download the free trial online at nitropdf.com/professional



WitsETD

Figure 3.50: Wound healing of B. frutescens-treated tissue on day 16 post-wound creation
A. *Illustration of the stage of wound healing*
B *Representative histological section on day 16 B. frutescens-treated wound.*
Note the complete re-epithelisation of the wound area and the neo-epidermis (NE) lacking rete ridges. There are few hair follicles (HF) visible adjacent to the the granulation tissue (GT) of the wound area. (H and E, x10)

created with nitroPDF professional
download the free trial online at nitropdf.com/professional

By day 16, the granulation tissue of all groups of wounds appeared to be less dense than in the preceding days (Fig. 3.51 A-C). There appeared to be a greater number of fibroblasts present in the untreated wounds than in either of the treated groups. Several hair follicles were present in the granulation tissue area of the wounds of both the treatment groups. The vascularity of the untreated wounds appeared to be greater than in both treatment groups. There was evidence of collagen fibres in the granulation tissue of all wounds – there appeared to be more collagen present in both treatment groups than the untreated group (Fig. 3.37). The collagen fibres of the untreated wound appeared more loosely woven than that of the *B. natalensis*-treated wounds with more fibroblasts interspersed in the tissue. The collagen fibres in the *B. frutescens* group appeared to be fairly dense with some overlapping.

In both treatment groups there was a greater density of hair follicles and what appeared to be the formation of some glandular tissue (Figs. 3.48, 3.49 and 3.50).

WitsETD

created with nitroPDF professional
download the free trial online at nitropdf.com/professional

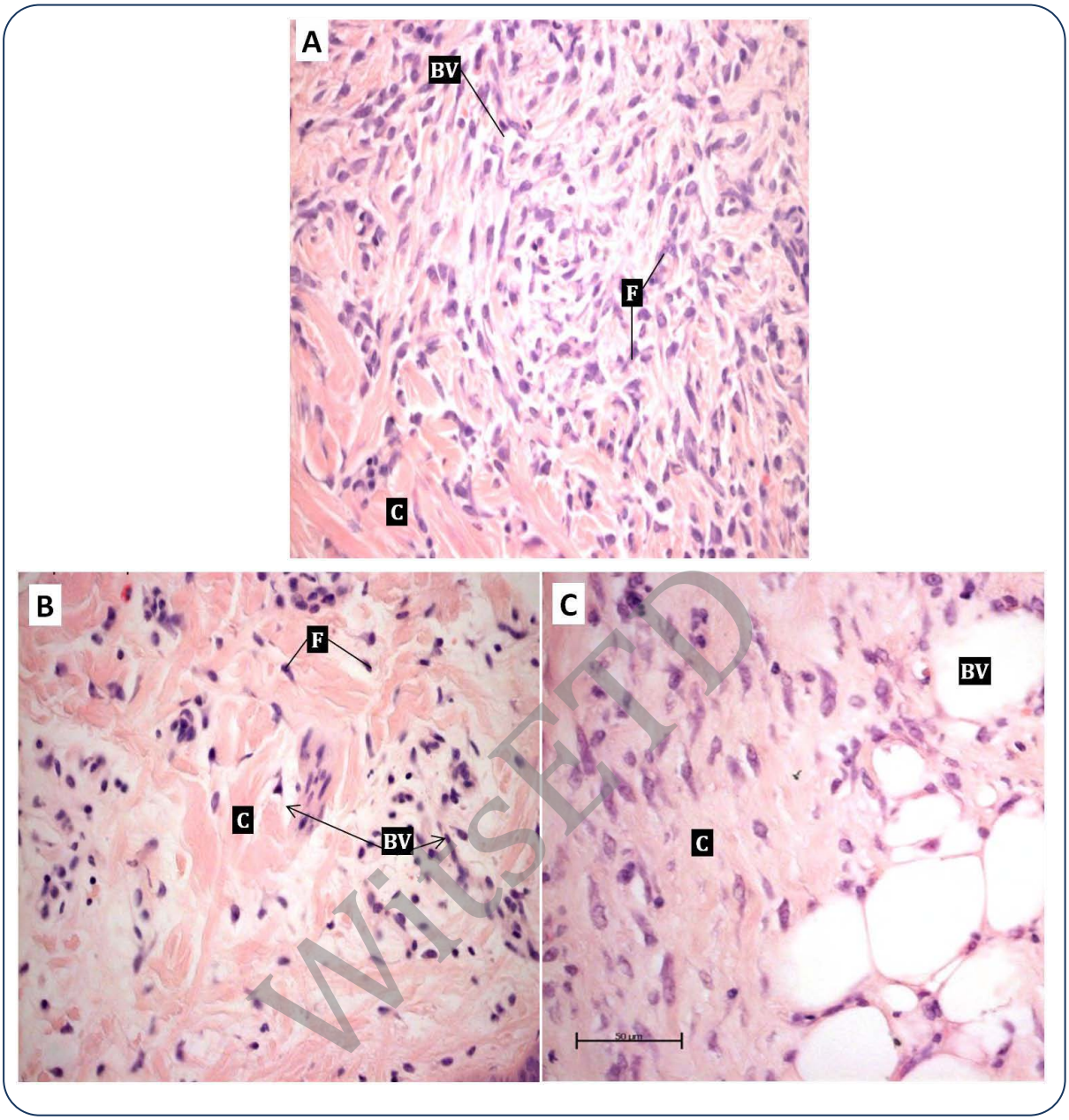

WitsETD

Figure 3.51: Granulation tissue on day 16 post-wound creation

A. *Representative histological section of an untreated wound;* ***B*** *Representative histological section of B. natalensis-treated wound;* ***C.*** *Representative histological section of a B. frutescens treated wound. Note the scattered fibroblasts and blood vessels (BV). Collagen (C) deposition is evident. (H and E, x40)*

created with nitroPDF professional
download the free trial online at nitropdf.com/professional

3.3.2.4. Immunohistochemical analyses of the excisional wounds

a. α smooth muscle actin (α SMA) localisation

Controls

Mouse heart was used as a positive control for αSMA since myocytes are known to express αSMA (Vanderkerckhove *et al.*, 1986; Schildmeyer *et al*., 2000). Cytoplasmic localisation of the actin (Fig.3.52A) was evident within the cardiac tissue.

In the wound tissue of pig skin, localisation of αSMA in the epidermis and dermis was evident (Fig. 3.52 D and G). The specificity of the immunolocalisation of αSMA in pig skin was confirmed with negative controls using adjacent wound sections. No immunolocalisation of αSMA was present in the sections in which the primary (Fig. 3.52 E and H) and secondary (Fig. 3.52F and I) antibodies were replaced with PBS.

WitsETD

created with nitroPDF professional
download the free trial online at nitropdf.com/professional

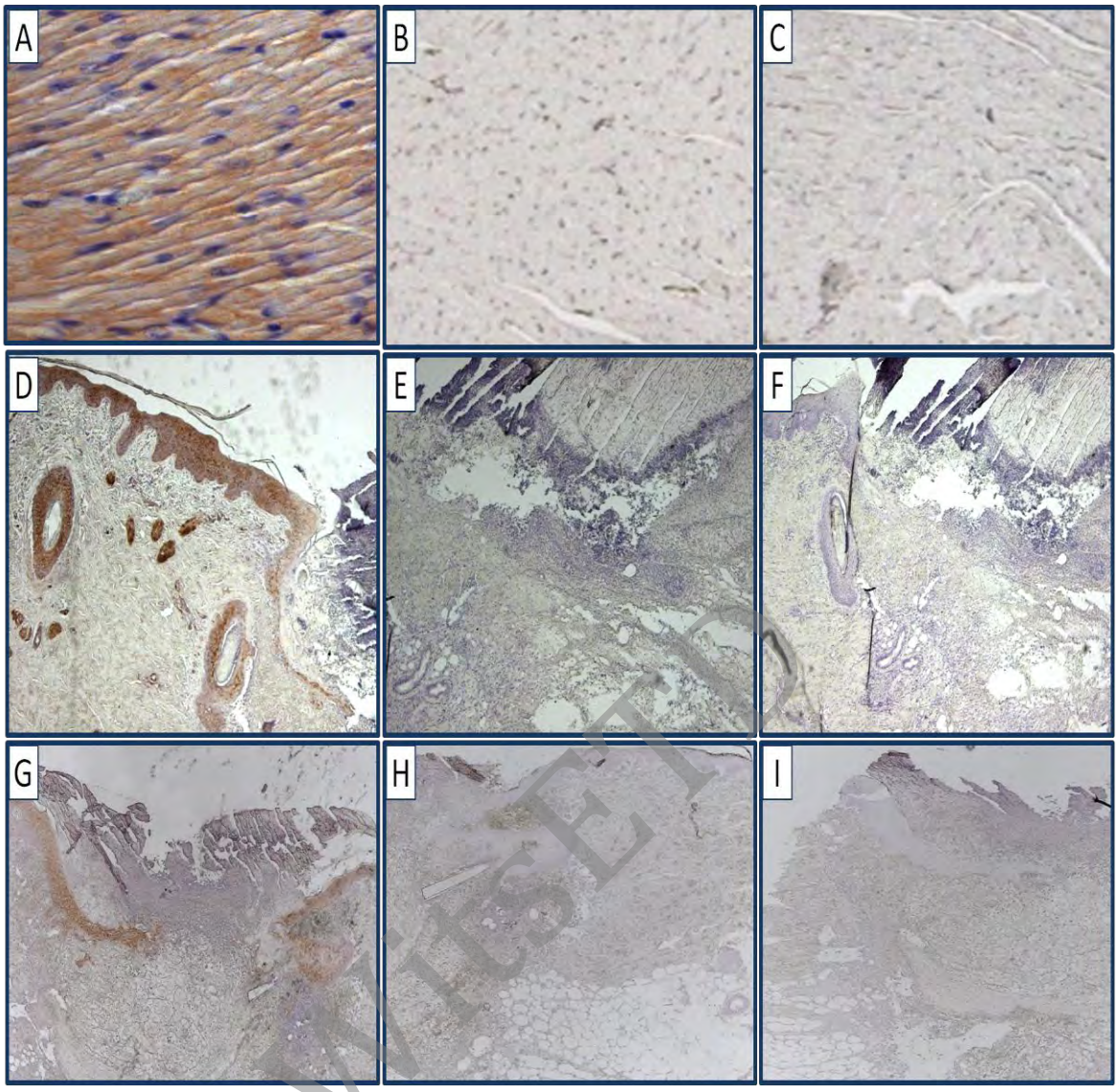

Figure 3.52: Representative histological sections of αSMA control tissue

A- *mouse heart tissue positive control,* ***B-*** *mouse heart tissue negative control omitting the primary antibody;* ***C-*** *mouse heart tissue negative control omitting the secondary antibody;* ***D-*** *positive localisation of a day 2 pig skin wound,* ***E-*** *negative control of a day 2 pig skin wound omitting the primary antibody,* ***F-*** *negative control of a day 2 pig skin wound omitting the secondary antibody;* ***G-*** *positive localisation of a day 4 pig skin wound,* ***H-*** *negative control of a day 4 pig skin wound omitting the primary antibody,* ***I-*** *negative control of a day 4 pig skin wound omitting the secondary antibody. (Stained with DAB and counterstained with haematoxylin; x5)*

WISER

created with nitroPDF professional
download the free trial online at nitropdf.com/professional

Immunolocalisation of αSMA in wounds treated with B. natalensis and B. frutescens compared to untreated wounds.

Immunolocalisation of αSMA was present in several regions of the untreated and the *B. natalensis*- and *B. frutescens*-treated wounds on **day 2**. In the epidermis, keratinocytes in all of the layers expressed localisation of αSMA. In both the untreated and the *B. frutescens*-treated wounds on day 2, this expression of αSMA by the keratinocytes was similar to that of the adjacent unwounded epidermis and to each other (Fig.3.53 A and C). In the *B. natalensis*-treated group, the expression of αSMA by the keratinocytes was less intense than that of the adjacent unwounded epidermis and the untreated and *B. frutescens*-treated wounds (Fig.3.53B).

WitsETD

αSMA was also localised in the epithelium of the sebaceous glands and the root sheaths of the hair follicles. There was no visible difference in this localisation in both the treated groups and in the untreated wounds. The hair follicle root sheaths in all three groups showed strong expression of αSMA. In the underlying granulation tissue, αSMA was localised in the walls of the blood vessels in all wounds (Fig. 3.53; indicated by red arrows) and in the dermis adjacent to the granulation tissue, there were several areas of localisation that indicated the presence of myofibroblasts (Figs. 3.53 and 3.54). Although not quantified, there appeared to be a greater number of myofibroblasts in both the untreated and the *B. frutescens*-treated wounds than in the *B. natalensis*-treated group.

created with nitroPDF professional
download the free trial online at nitropdf.com/professional

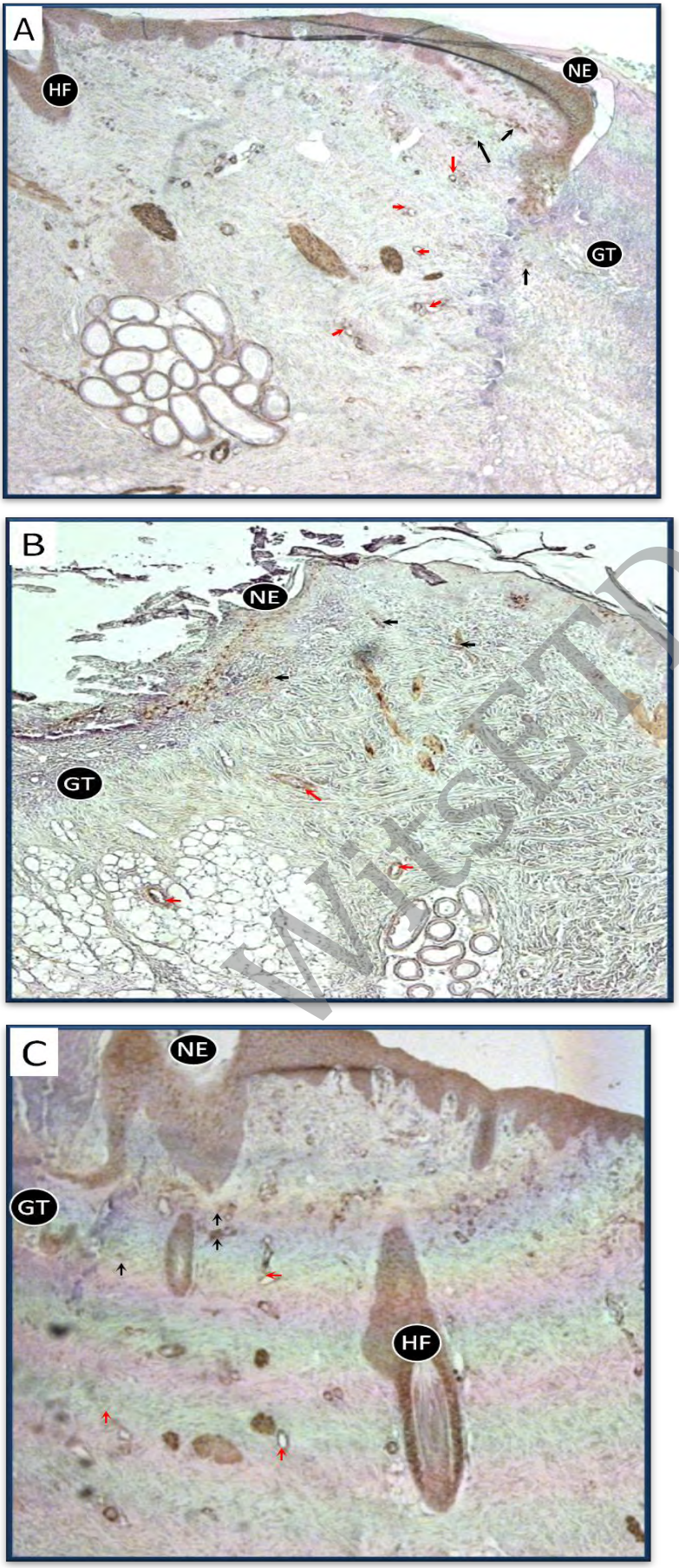

Figure 3.53: Representative sections of αSMA localisation in wounds on day 2.
A*- untreated wound;*
B*- B. natalensis-treated wound;*
C*- B. frutescens-treated wound. Note the expression of αSMA in the epidermis, hair follicles and sweat glands. Localisation of αSMA was also noted in capillaries (red arrows) and in condensations of myofibroblasts (black arrows). (anti- αSMA, x10)*

WITSETD

created with nitroPDF professional
download the free trial online at nitropdf.com/professional

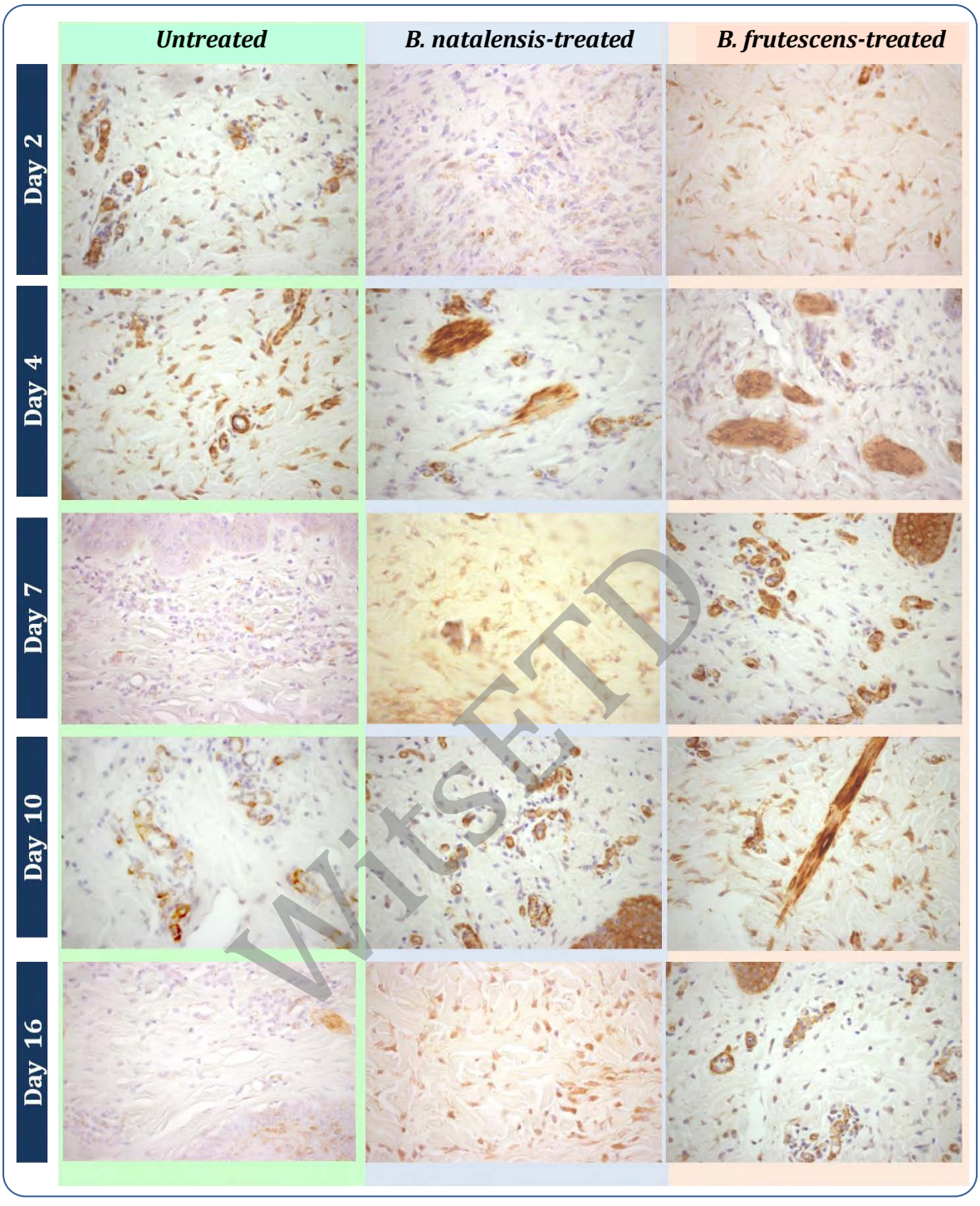

WitsETD

Figure 3.54: Representative sections of αSMA localisation in untreated wounds and B. natalensis- and B. frutescens-treated wounds from day 2 to day 16 post-wound creation.
Note the localisation of αSMA in the walls of the blood vessels and scattered in the dermis. There is a progressive increase in the myofibroblasts population in both treated groups compared to the untreated wounds. (anti- αSMA; x40)

created with nitroPDF professional
download the free trial online at nitropdf.com/professional

There was also strong expression of αSMA in all wounds on **day 4.** Both the control and *B. natalensis*- and *B. frutescens*- treated wounds showed immunolocalisation of αSMA in all layers of the neo-epidermis, the root sheaths of the hair follicles and the walls of the blood vessels (Figs. 3.54 and 3.55). There was also expression of αSMA in the fibroblasts (indicating myofibroblasts) scattered in the dermis adjacent to the granulation tissue.

The expression of αSMA in the keratinocytes of the epidermis was strongest in the untreated wounds and weakest in the *B. natalensis*- treated wounds (Figs. 3.54 and 3.55 A and B). The granulation tissue of the untreated wounds and *B. natalensis*-treated wounds had few myofibroblasts. The *B. frutescens*-treated wounds however showed several areas of αSMA localisation in the myofibroblasts located in the wound area accompanied by complete re-epithelialisation (Fig. 3.55 C) of the wounds.

In the *B. natalensis*-treated wound showing growth of the epidermis into the dermal regions, there was localisation of αSMA in the keratinocytes (Fig. 3.55D). This was also accompanied by several aggregations of myofibroblasts in the dermis below the wound and complete re-epithelialisation of the wound.

WitsETD

created with nitroPDF professional
download the free trial online at nitropdf.com/professional

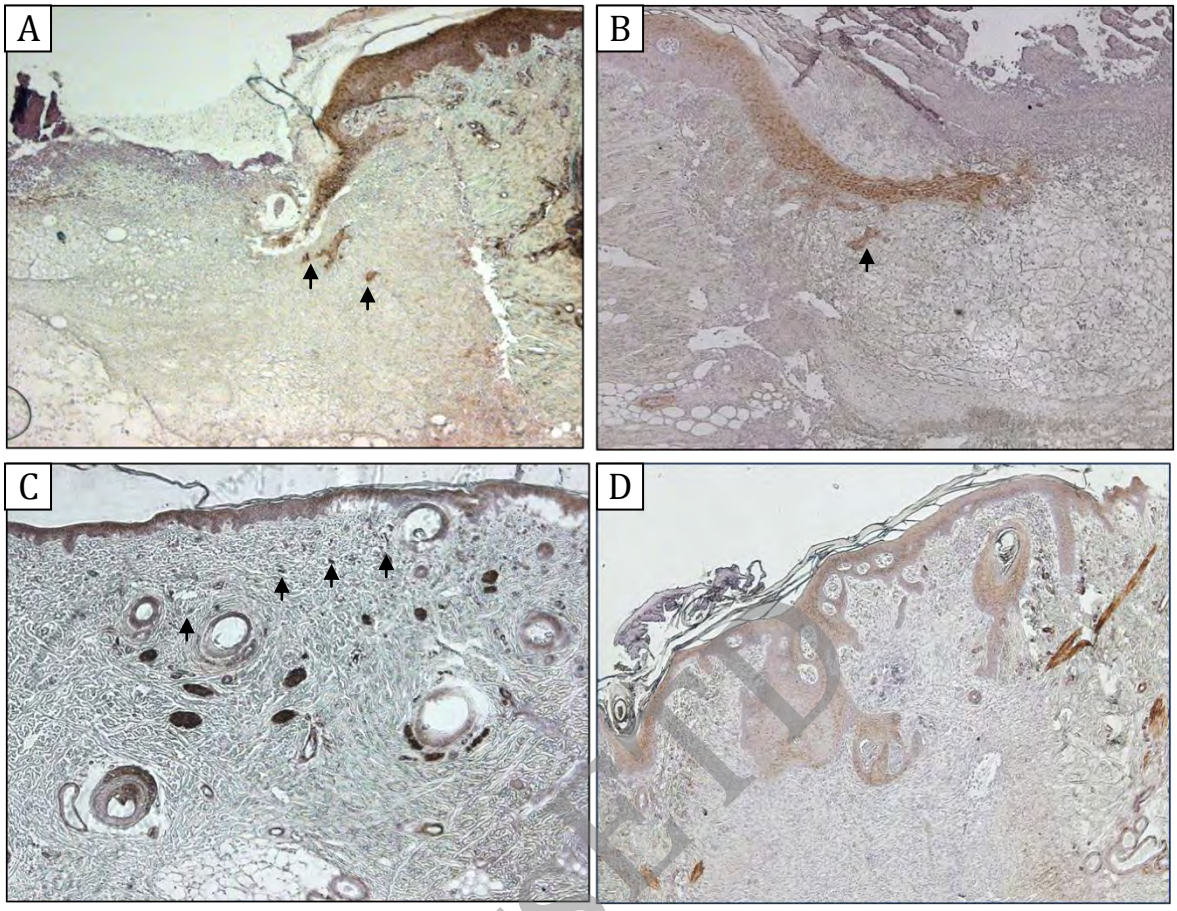

Figure 3.55: Representative sections of αSMA localisation in day 4 wounds*. **A**- untreated wound; **B**- B. natalensis treated wound; **C**- B. frutescens treated wounds; **D**- B. natalensis treated wound with growth of the epidermis into the dermis. This down growth of the epidermis may indicate the presence of a hair follicle or a gland. Note the expression of αSMA in the keratinocytes of the epidermis, hair follicles and sweat glands. Localisation of αSMA was also noted in condensations of myofibroblasts (black arrows). There is also localisation of αSMA muscle bundles that appeared to be erector pilli muscles. (X10)*

WitsETD

created with nitroPDF professional
download the free trial online at nitropdf.com/professional

In the wounds on **day 7**, the expression of αSMA was weaker in the epidermal layers and in the dermis than in the preceding days. Both the untreated and treated wounds showed immunolocalisation of αSMA in the epidermis (most strongly in the stratum spinosum), root sheaths of the hair follicles and walls of the capillaries (Fig. 3.56 A, B and C). The localisation of αSMA was much weaker in the epidermis than on days 2 and 4.

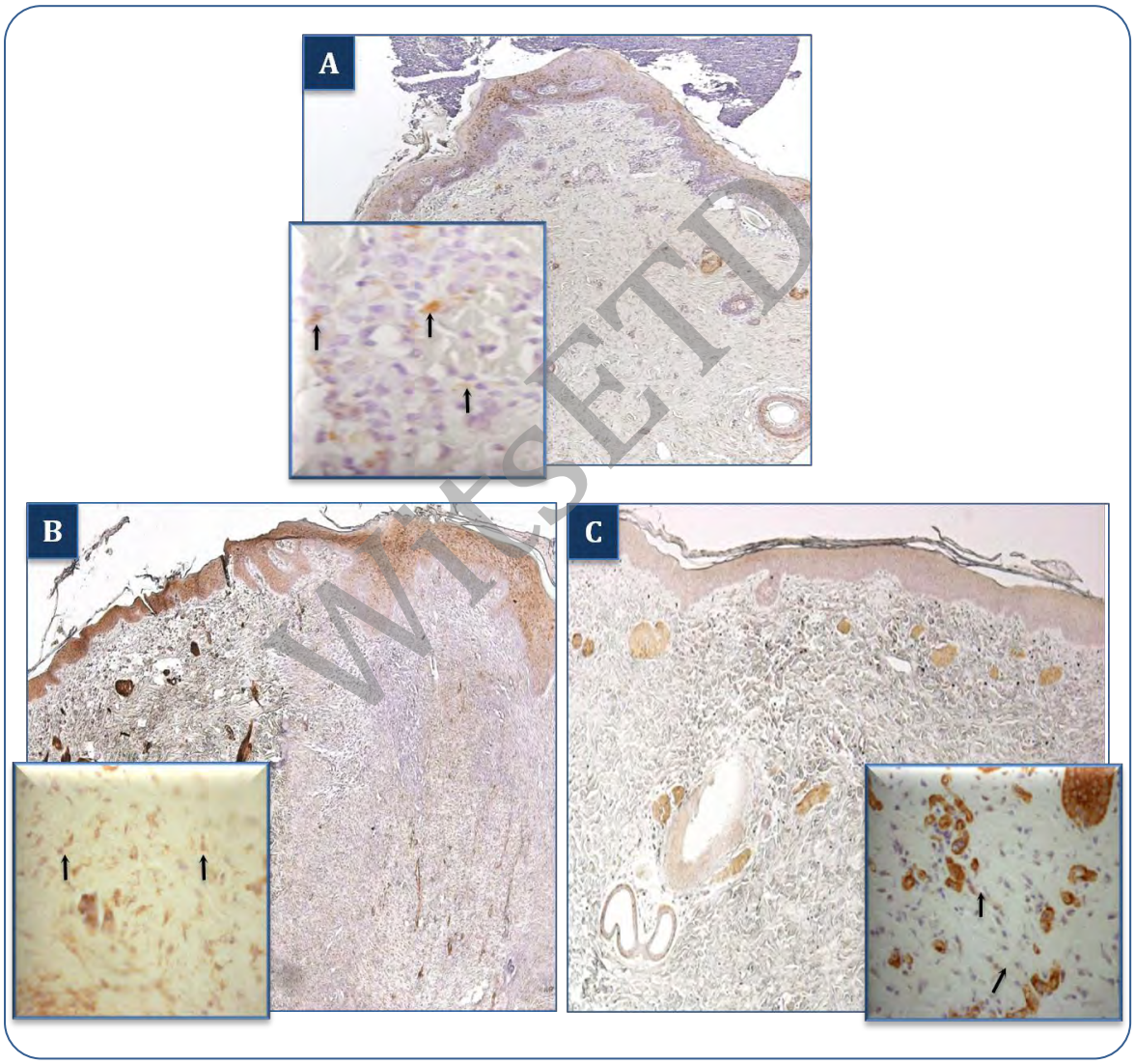

Figure 3.56: Representative sections of αSMA localisation in day 7 wounds with insets demonstrating the area adjacent to the granulation tissue. A*- Untreated wound;* ***B****- B. natalensis-treated wound;* ***C****- B. frutescens-treated wounds. Note the weaker expression of αSMA in the layers of the epidermis, hair follicles and sweat glands. Intense localisation is present in the arrector pilli muscle. Black arrows in the insets indicate the location of myofibroblasts. (x10; insets, x40)*

WESTERN CAPE

created with nitroPDF professional
download the free trial online at nitropdf.com/professional

Myofibroblasts were present in the areas adjacent to the granulation tissue of the wounds in all three groups (Figs. 3.54 and 3.56 insets). In the untreated tissue, there appeared to be fewer myofibroblasts (although this was not quantified) than in both treated groups. These myofibroblasts were more scattered in the underlying dermis. The wounds treated with *B. natalensis* gel displayed a greater number of myofibroblasts with stronger expression of αSMA. These myofibroblasts were aggregated in the area adjacent to the wound granulation tissue (Fig. 3.56). Few myofibroblasts invaded the area of the granulation tissue. In the wounds treated with *B. frutescens*, myofibroblasts were evident as aggregations underlying the neo-epidermis.

WitsETD

created with nitroPDF professional
download the free trial online at nitropdf.com/professional

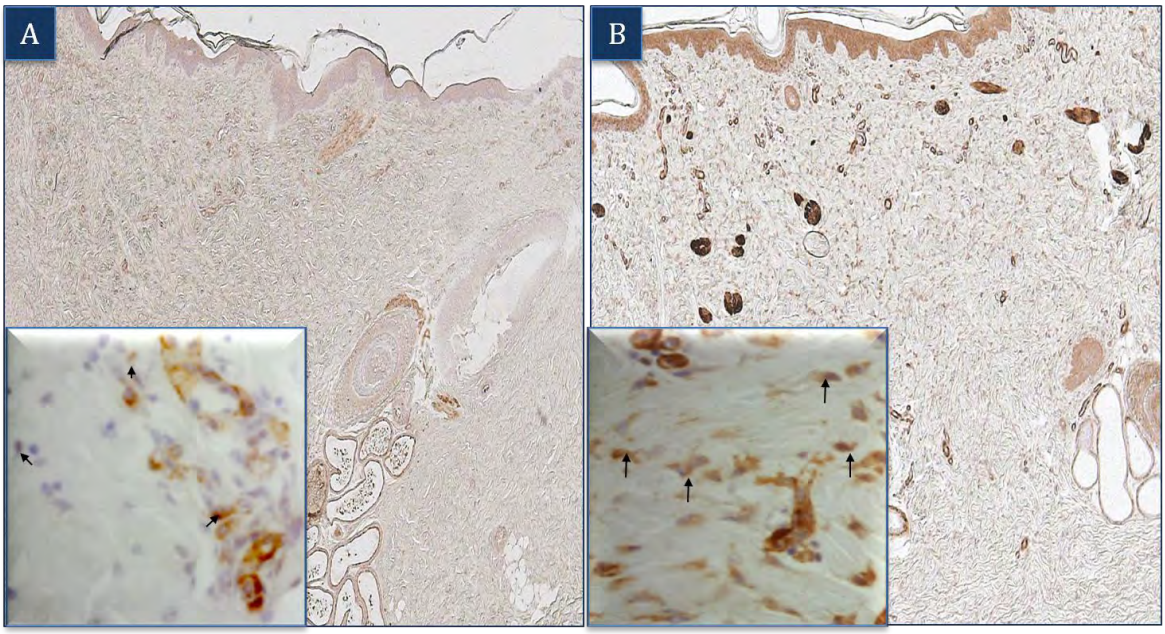

Figure 3.57: Representative sections of αSMA localisation in day 10 wounds with insets demonstrating the area adjacent to the granulation tissue. ***A-*** *Untreated wound;* ***B-*** *B. natalensis treated wound;* ***C-*** *B. frutescens-treated wound with well developed rete ridges. Note the weaker expression of αSMA in the epidermis, hair follicles and sweat glands of the untreated wound compared to both treatment groups. Myofibroblasts were more numerous in the B.natalensis-treated wounds. Black arrows in the insets indicate the location of myofibroblasts. (X10; insets, x40)*

Witsetd

Re-epithelisation was complete in all wounds by **day 10.** The expression of αSMA in the layers of the epidermis, root sheaths of the hair follicles and myofibroblasts in the area adjacent to the granulation tissue was weaker in the untreated wound tissue than in the *B. natalensis*- and *B. frutescens*-treated wounds (Fig. 3.57). Myofibroblasts localisation appeared to be greatest in the *B. natalensis*-treated wounds.

created with nitroPDF professional
download the free trial online at nitropdf.com/professional

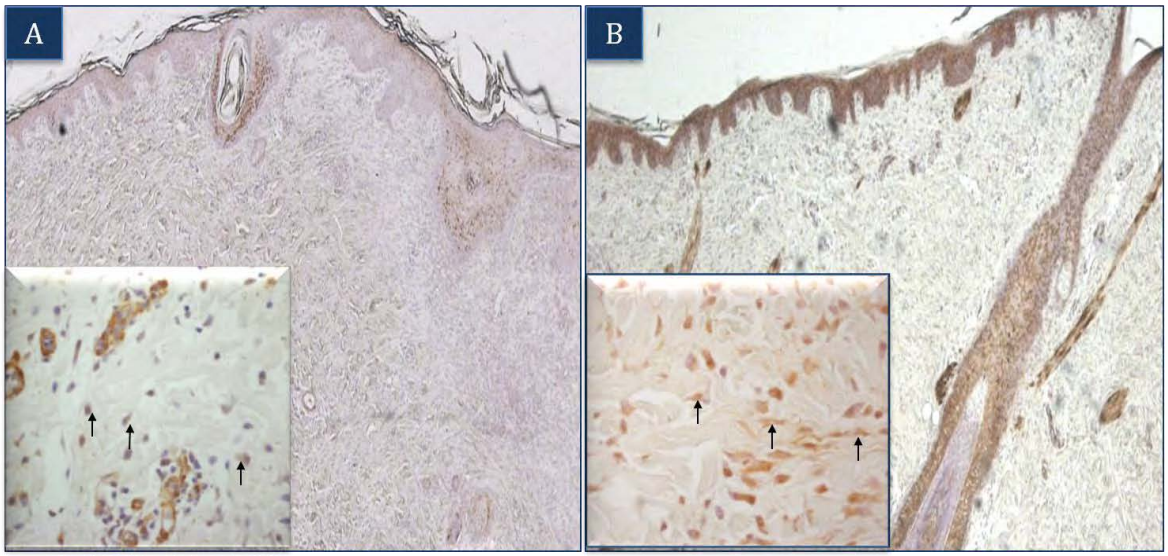

Figure 3.58: Representative sections of αSMA localisation in day 16 wounds with insets demonstrating the area adjacent to the granulation tissue.
***A**- Untreated wound; **B**- B. natalensis treated wound; **C**- B. frutescens-treated wound with well developed rete ridges.. Note the weaker expression of αSMA in the untreated wound compared to both treatment groups. Black arrows in the insets indicate the location of myofibroblasts. (X10; insets, x40))*

WISETD

By **day 16**, the untreated wounds showed weak expression of αSMA in the epidermis, sebaceous glands and hair follicles. Stronger localisation was prevalent in both the *B. natalensis*- and *B. frutescens*- treated groups. There was no observable difference in the strength of the expression of both the treated groups (Fig. 3.54). Aggregations of myofibroblasts in the area adjacent to the wound area were present in all groups. These aggregations were more numerous in the *B. frutescens*-treated group. There were also more numerous blood vessels present in the dermis underlying the wound tissue of the *B. frutescens* group.

created with nitroPDF professional
download the free trial online at nitropdf.com/professional

b. VEGF localisation

Controls

Human breast carcinoma was used as a positive control for VEGF since tumour genesis is known to be accompanied by angiogenesis. Human breast carcinoma tissue is also recommended as a positive control tissue by Santa Cruz Biotechnology, Inc, the supplier of the antibody used in these experiments. The breast carcinoma tissue displayed cytoplasmic localisation of VEGF as expected (Fig. 5.39).

The specificity of the immunolocalisation of the VEGF antibody was confirmed with negative controls using adjacent sections of wound tissue. No immunolocalisation of VEGF was present in the sections in which the primary and secondary antibodies were replaced with PBS (Fig3.59).

WitsETD

created with nitroPDF professional
download the free trial online at nitropdf.com/professional

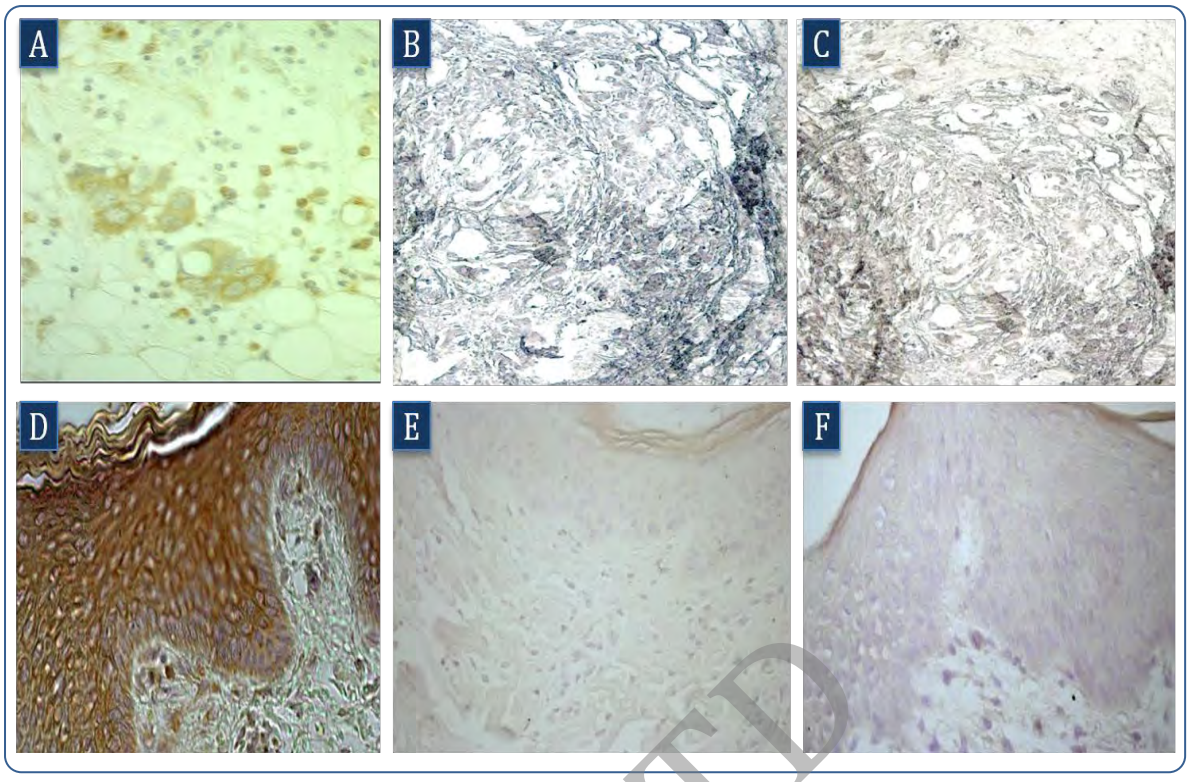

***Figure 3.59*: Representative sections of VEGF controls:**
A- *VEGF localisation in human breast carcinoma section,* ***B***- *Human breast carcinoma – negative control omitting the primary antibody;* ***C***- *Human breast carcinoma omitting the secondary antibody.*
D- *VEGF localisation in pig wound tissue,* ***E***- *Pig wound tissue – negative control omitting the primary antibody;* ***F***- *Pig wound tissue – negative control omitting the secondary antibody. (x40)*

WitsETD

created with nitroPDF professional
download the free trial online at nitropdf.com/professional

Immunolocalisation of VEGF in B. natalensis- and B. frutescens-treated wounds compared with untreated wounds

On **day 2** post-wounding, there was evidence of VEGF localisation in the untreated wounds and in the wounds of both treated groups. In the epidermis, there was cytoplasmic localisation of VEGF in all the layers. The localisation was relatively less intense in the stratum basale than in the stratum spinosum. When comparing the three groups, VEGF localisation was weaker in the untreated and the *B. natalensis*-treated wounds (Fig. 3.60) than in the *B. frutescens*-treated wounds.

In the granulation tissue, there was scattered localisation of VEGF in all the groups. There were no observable differences in the localisation of the VEGF in the cells of the granulation tissue.

WitsETD

created with nitroPDF professional
download the free trial online at nitropdf.com/professional

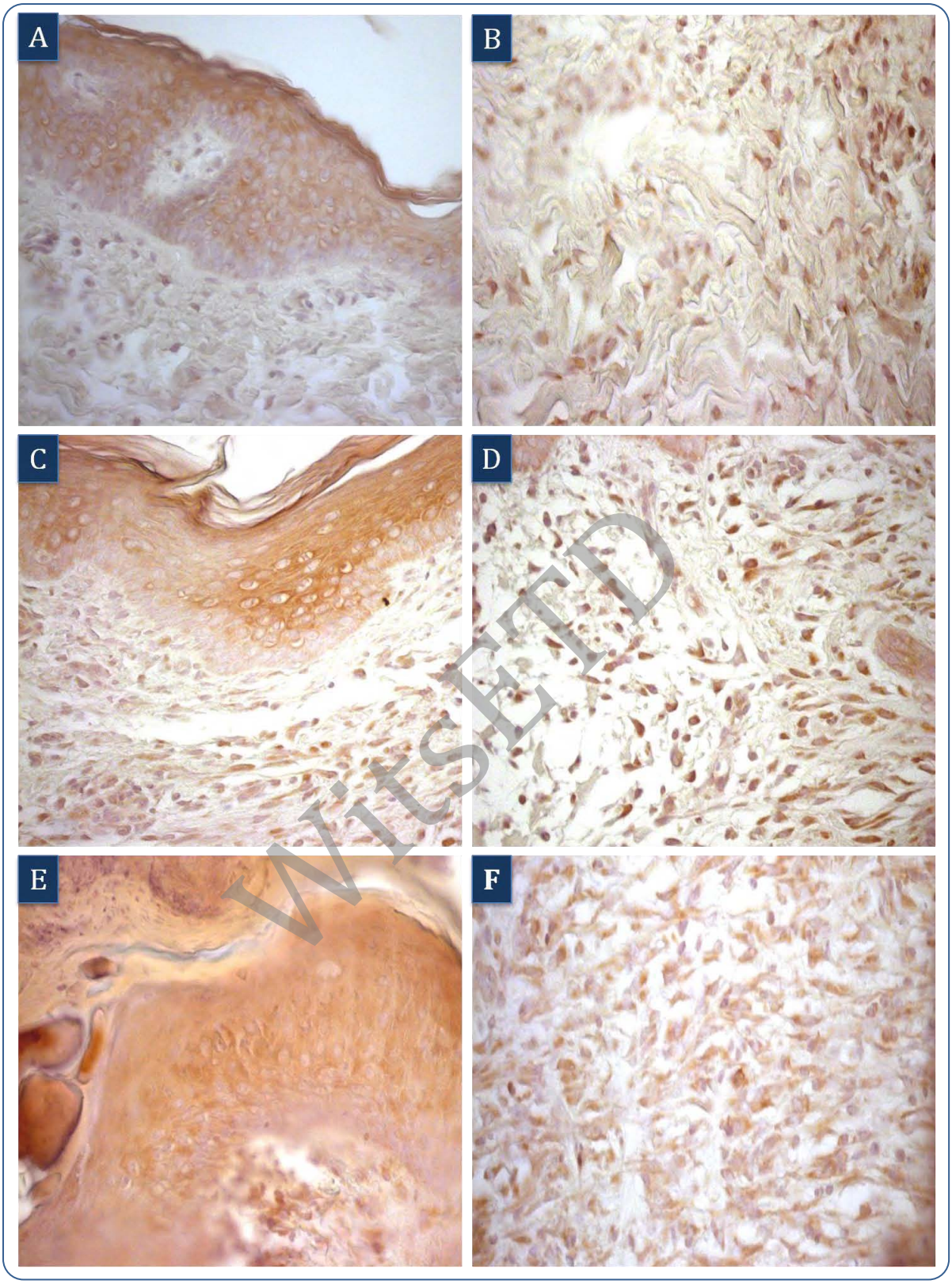

WitsETD

Figure 3.60: Representative sections of VEGF localisation in day 2 wounds*. **A**& **B**- Untreated wounds neo-epidermis and wound granulation tissue; **C** & **D**- B. natalensis- treated wound neo-epidermis and granulation tissue; E&F- B. frutescens-treated wound neo-epidermis and granulation tissue. Note the localisation of VEGF in all layers of the epidermis. This localisation is relatively less intense in the stratum basale. In the granulation tissue, there is scattered localisation of VEGF. (x40)*

created with nitroPDF professional
download the free trial online at nitropdf.com/professional

On **day 4**, the expression of VEGF was less intense in the untreated wounds and in the *B. natalensis*-treated wounds than in the *B. frutescens*-treated wounds (Fig. 3.61). This localisation was also less intense than that of the day 2 post-wounding tissue. The VEGF expression was present in the cytoplasm of the epidermal cells, and was weakly expressed in cells of the stratum basale. VEGF localisation was weaker in the neo-epidermis than in the surrounding unwounded tissue.

WitsETD

created with nitroPDF professional
download the free trial online at nitropdf.com/professional

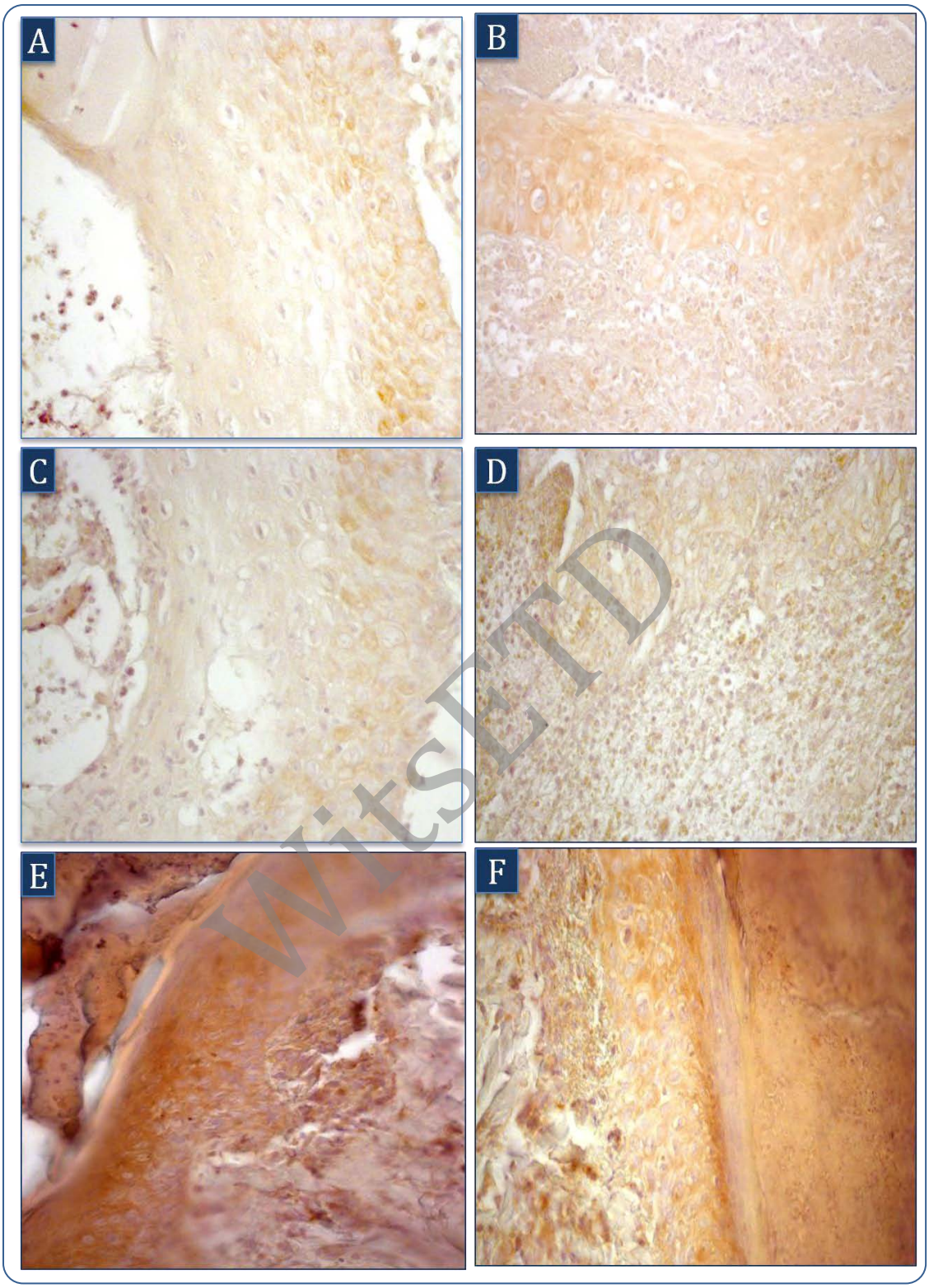

WitsETD

Figure 3.61: Representative sections of VEGF localisation in day 4 wounds. ***A*** *&* ***B****- Untreated wounds neo-epidermis and wound granulation tissue;* ***C*** *&* ***D****- B. natalensis-treated wound neo-epidermis and granulation tissue;* ***E*** *&* ***F****- B. frutescens-treated wound neo-epidermis and granulation tissue. Note the less intense localisation of VEGF in the epidermis of the untreated wound and the B. natalensis-treated wound. (x40)*

created with nitroPDF professional
download the free trial online at nitropdf.com/professional

On **day 7**, there was evidence of VEGF localisation in all three groups (Fig. 3.62). The strongest VEGF expression was in the epidermis of the *B. frutescens*-treated wounds. This expression was visible in all layers of the epidermis (including the stratum basale). There was stronger expression of VEGF in the epidermal layers of the untreated wounds than that of the *B. natalensis*-treated wounds. This expression in the untreated wounds however, was less intense in the stratum basale. In the *B. natalensis*-treated wounds, the expression of VEGF was weak in all the layers of the epidermis. In the granulation tissue on day 7, the cytoplasmic expression of VEGF was more intense in the *B. frutescens*-treated wounds.

WitsETD

created with nitroPDF professional
download the free trial online at nitropdf.com/professional

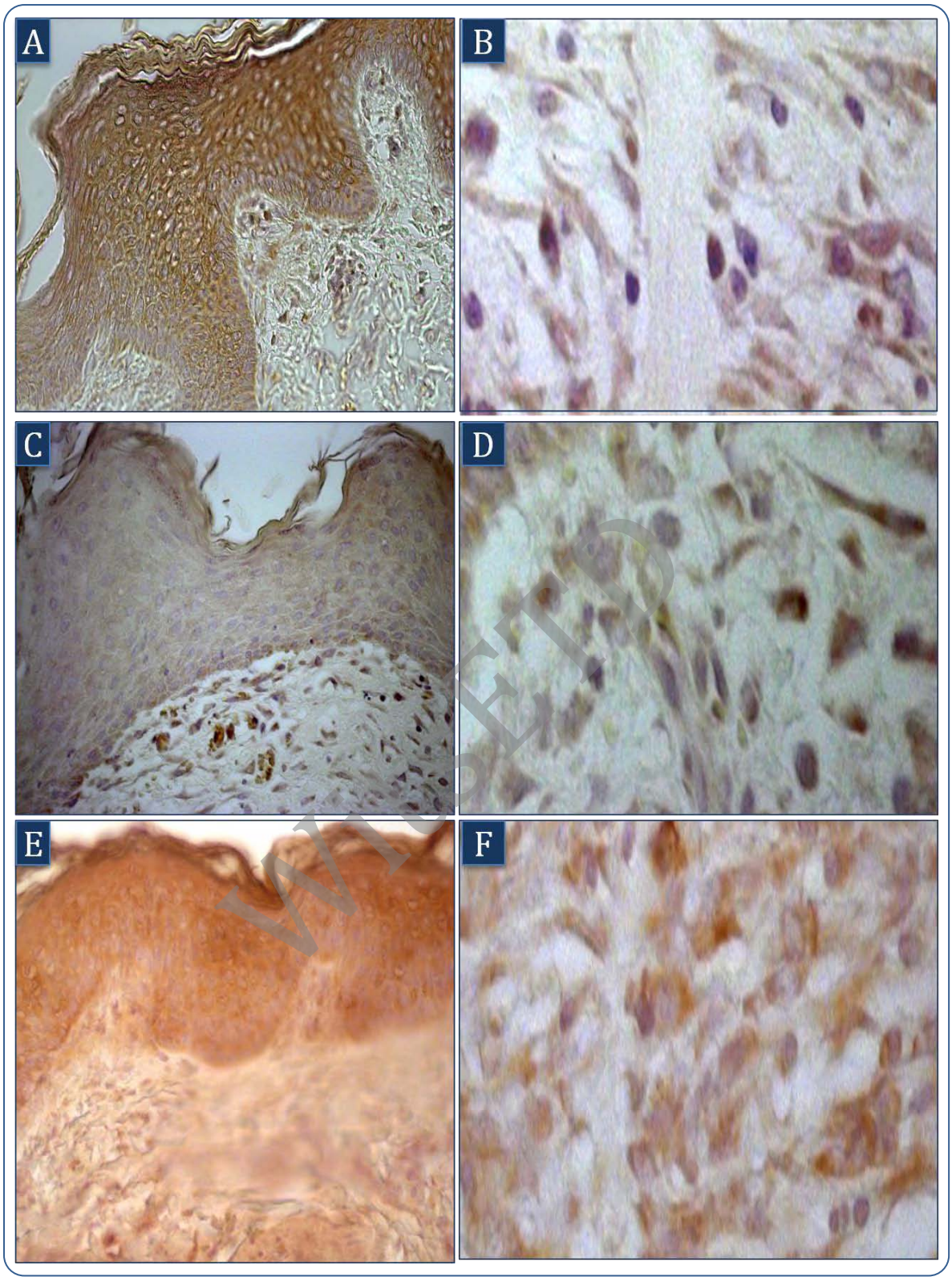

Figure 3.62: Representative sections of VEGF localisation on day 7 wounds*. **A**& **B**- Untreated wounds neo-epidermis and wound granulation tissue; **C** & **D**- B. natalensis-treated wound neo-epidermis and granulation tissue; **E** & **F**- B. frutescens-treated wound neo-epidermis and granulation tissue. Note the strong expression of VEGF in the epidermis of the B. frutescens-treated wound and in the untreated wound. (x40)*

created with nitroPDF professional
download the free trial online at nitropdf.com/professional

VEGF was localised in all wounds on **day 16** (Fig. 3.63). In the epidermis, the strongest expression of VEGF was in the *B. frutescens*-treated wounds in all the layers (including the stratum basale) while in the untreated wounds, expression of VEGF in the epidermal layers was weak. The expression was progressively less intense towards the stratum basale. In the *B. natalensis*-treated wounds, the expression of VEGF was less intense in all the layers of the epidermis and almost absent in the stratum basale when compared to that of the *B. frutescens*-treated wounds. There was cytoplasmic expression of VEGF in cells scattered in the granulation tissue. This was strongest in the *B. frutescens*-treated wounds and the weakest in the untreated wounds.

WitsETD

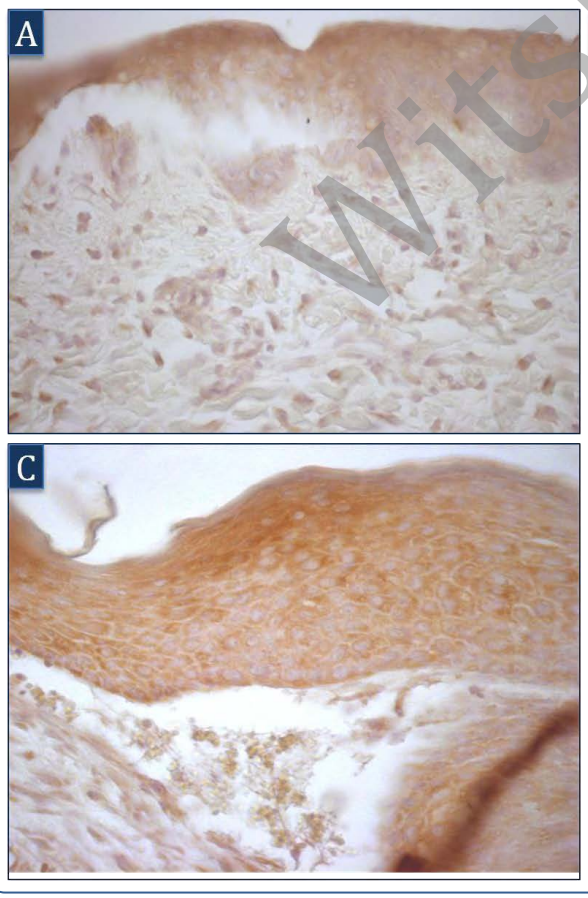

***Figure 3.63: Representative sections of VEGF localisation in the neo-epidermis on day 16 post-wound creation. A** - Untreated wounds neo-epidermis; **B**- B. natalensis-treated wound neo-epidermis; **C**- B. frutescens-treated wound neo-epidermis (x40)*

created with nitroPDF professional
download the free trial online at nitropdf.com/professional

c. TGFβR$_I$ and TGFβR$_{II}$ localisation

Controls

Mouse ovary was used as a positive control for TGFβR$_I$ and TGFβR$_{II}$ since it is known to express TGF-β (Ghiglieri *et al.*, 1995). Localisation of TGFβR$_I$ and TGFβR$_{II}$ (Fig.3.64) was seen in the granulosa and theca cells of the mouse ovarian tissue. The specificity of the immunolocalisation of TGFβR$_I$ and TGFβR$_{II}$ was confirmed with negative controls using adjacent sections of wound tissue. No immunolocalisation of TGFβR$_I$ and TGFβR$_{II}$ was present in the sections in which the primary (Fig. 3.64) and secondary (Fig. 3.53B) antibodies were replaced with PBS.

WitsETD

created with nitroPDF professional
download the free trial online at nitropdf.com/professional

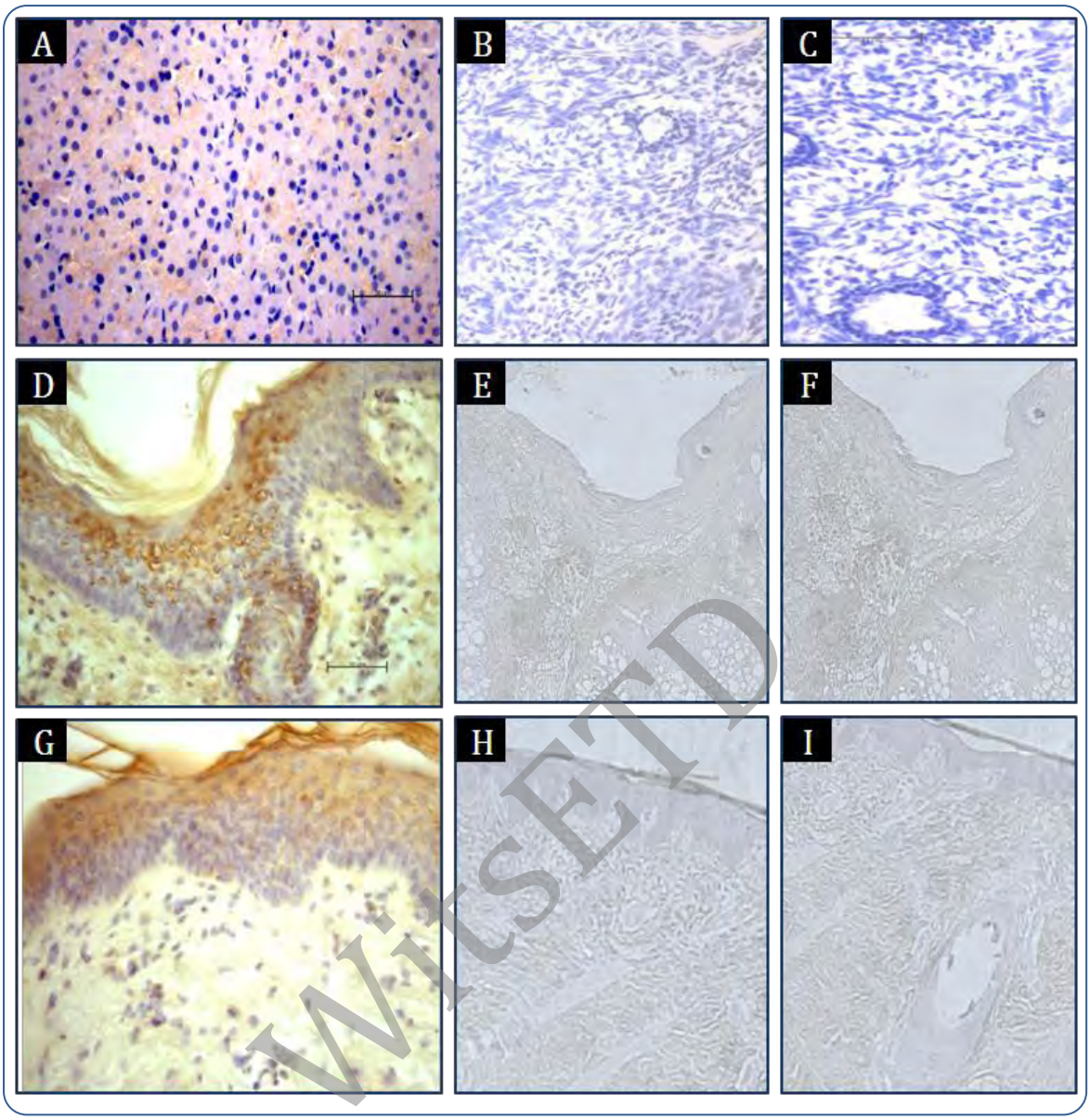

WitsETD

Figure 3.64: Representative sections of TGFβR$_I$ localisation in mouse ovarian tissue*. **A** – Mouse ovary -positive control, **B** and **C** - Negative control omitting the primary and secondary antibodies, respectively; **D**- Pig wound tissue depicting localisation of TGFβR$_I$; **E** and **F**- . Negative control omitting the primary and secondary antibodies, respectively; **G**- Pig wound tissue showing localisation of TGFβR$_{II}$; E and F- . Negative controls omitting the primary and secondary antibodies, respectively. (x40)*

created with nitroPDF professional
download the free trial online at nitropdf.com/professional

On **day 2,** TGFβR$_I$ was localised in all the wound tissue examined. In the epidermis, there was localisation of TGFβR$_I$ in all layers except for the stratum basale and lower layers of the stratum spinosum. When comparing the three 'treatment' groups, TGFβR$_I$ localisation was most intense in the untreated and the *B. frutescens*-treated wounds (Fig. 3.65 C).

There was also scattered localisation of TGFβR$_I$ in the granulation tissue of the untreated and both the treatment groups, with no observable differences between the groups.

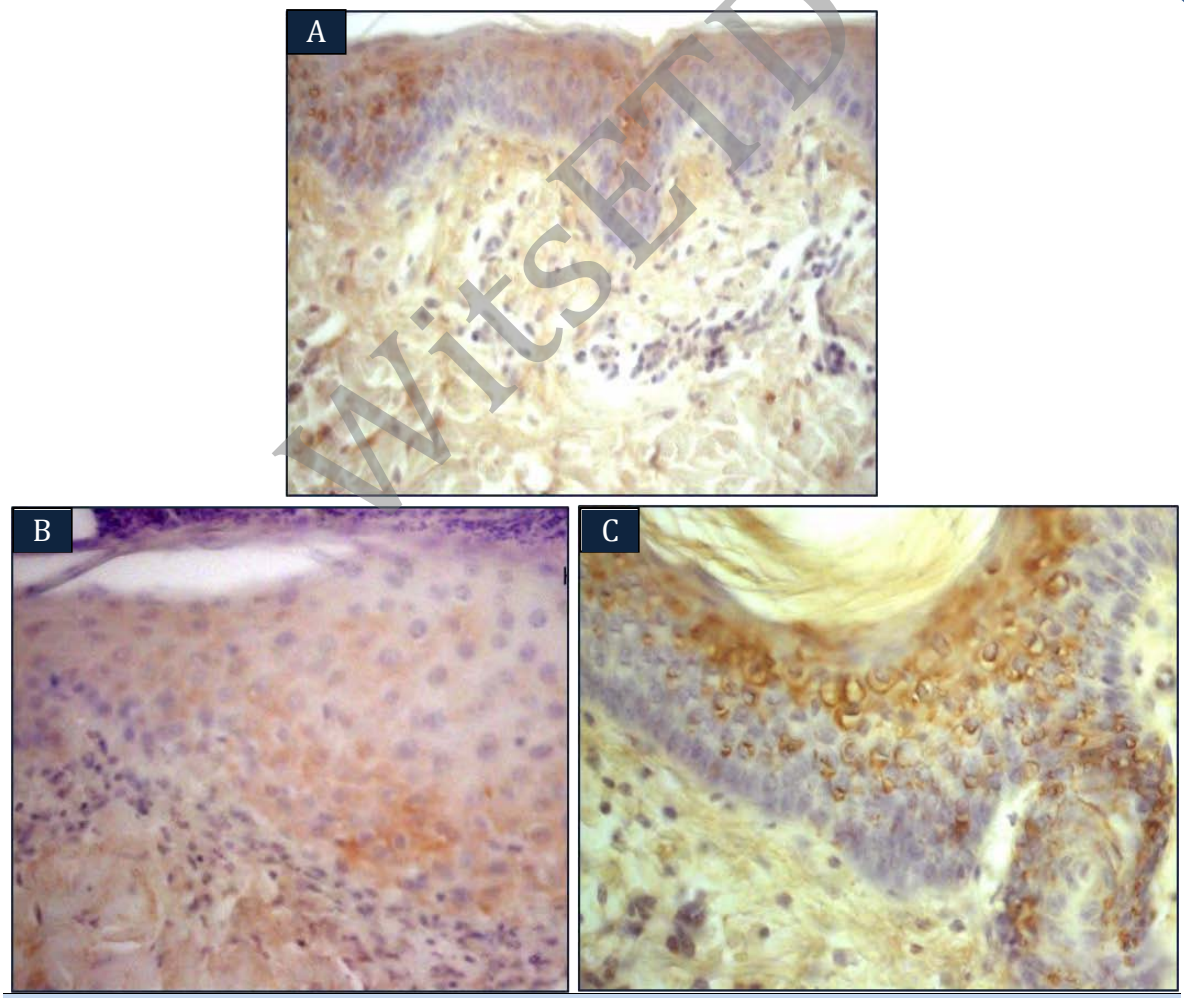

***Figure 3.65: Representative sections of TGFβR$_I$ localisation in day 2 wound tissue. A** – Negative control omitting the primary antibody; **B**- negative control ; **C**- B. frutescens treated wound migrating keratinocytes and granulation tissue. Note the more intense expression of TGFβR$_I$ in the more superficial layers of the epidermis. (x40)*

WitsETD

created with nitroPDF professional
download the free trial online at nitropdf.com/professional

On **day 4** post-wounding, $TGF\beta R_I$ was again strongly localised in the epidermis of the wounds treated with *B. frutescens* and the untreated wounds (Fig. 3.66) and was weakest in the *B. natalensis*-treated wounds. The localisation was evident in all layers of the epidermis except for the stratum basale. In the granulation tissue, $TGF\beta R_I$ was localised in scattered cells and in the epithelial cells of the hair follicles.

$TGF\beta R_{II}$, however, was equally expressed in the epidermis of all three groups (Fig. 3.67) on day 4 post wounding. As for the expression of $TGF\beta R_I$, the localisation of $TGF\beta R_{II}$ in the epidermis was evident in all layers of the epidermis except for the stratum basale and in the granulation tissue, in scattered cells and in the epithelial cells of the hair follicles.

WitsETD

created with nitroPDF professional
download the free trial online at nitropdf.com/professional

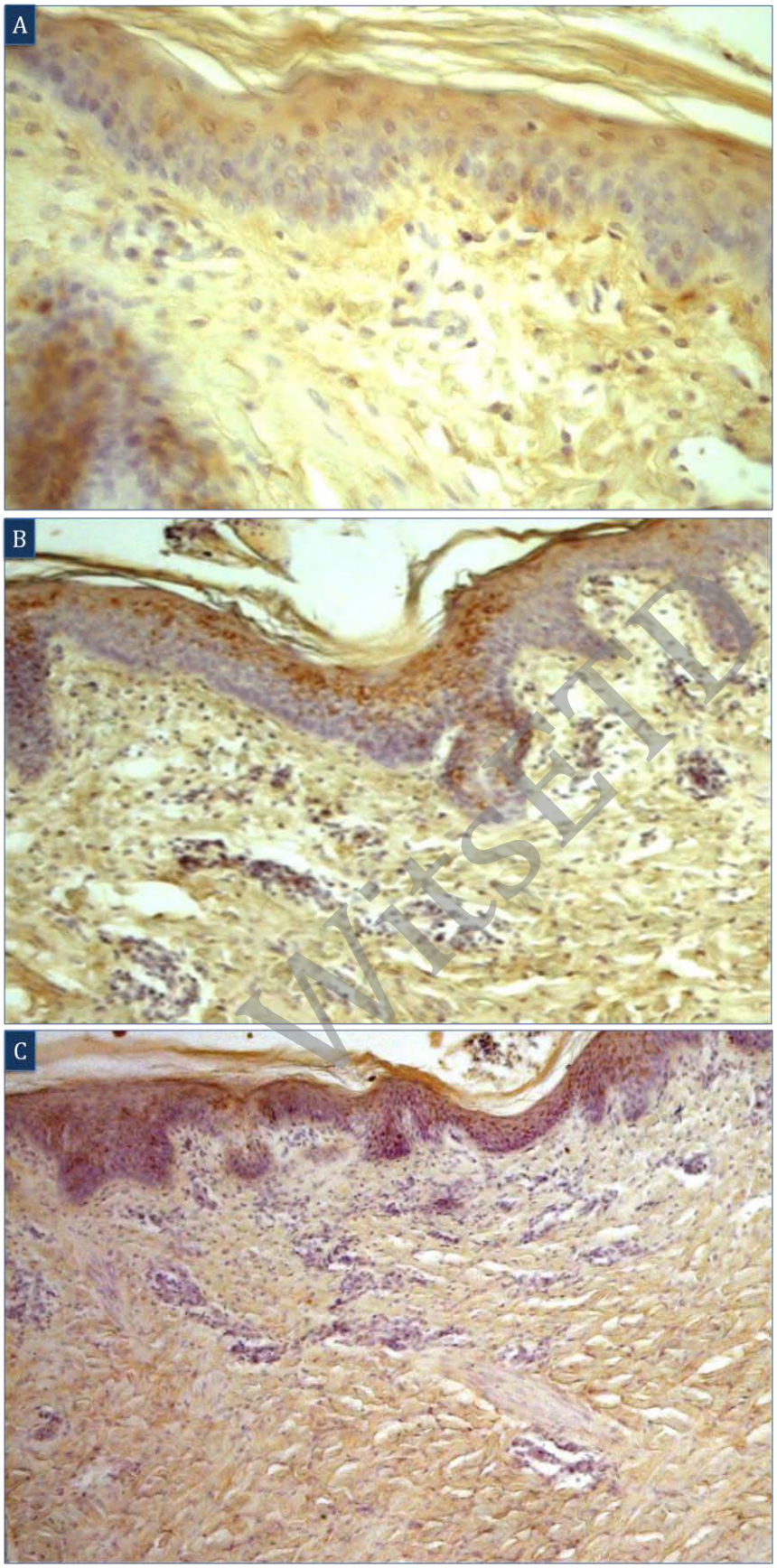

WitsETD

Figure 3.66:
Representative sections of TGFβR$_I$ localisation in day 4 wound tissue.
A *– untreated tissue;*
B*- B. natalensis- treated wound;*
C*- B. frutescens- treated wound.*
Note the expression of TGFβR$_I$ is more intense in the more superior layers of the epidermis. (x40)

created with nitroPDF professional
download the free trial online at nitropdf.com/professional

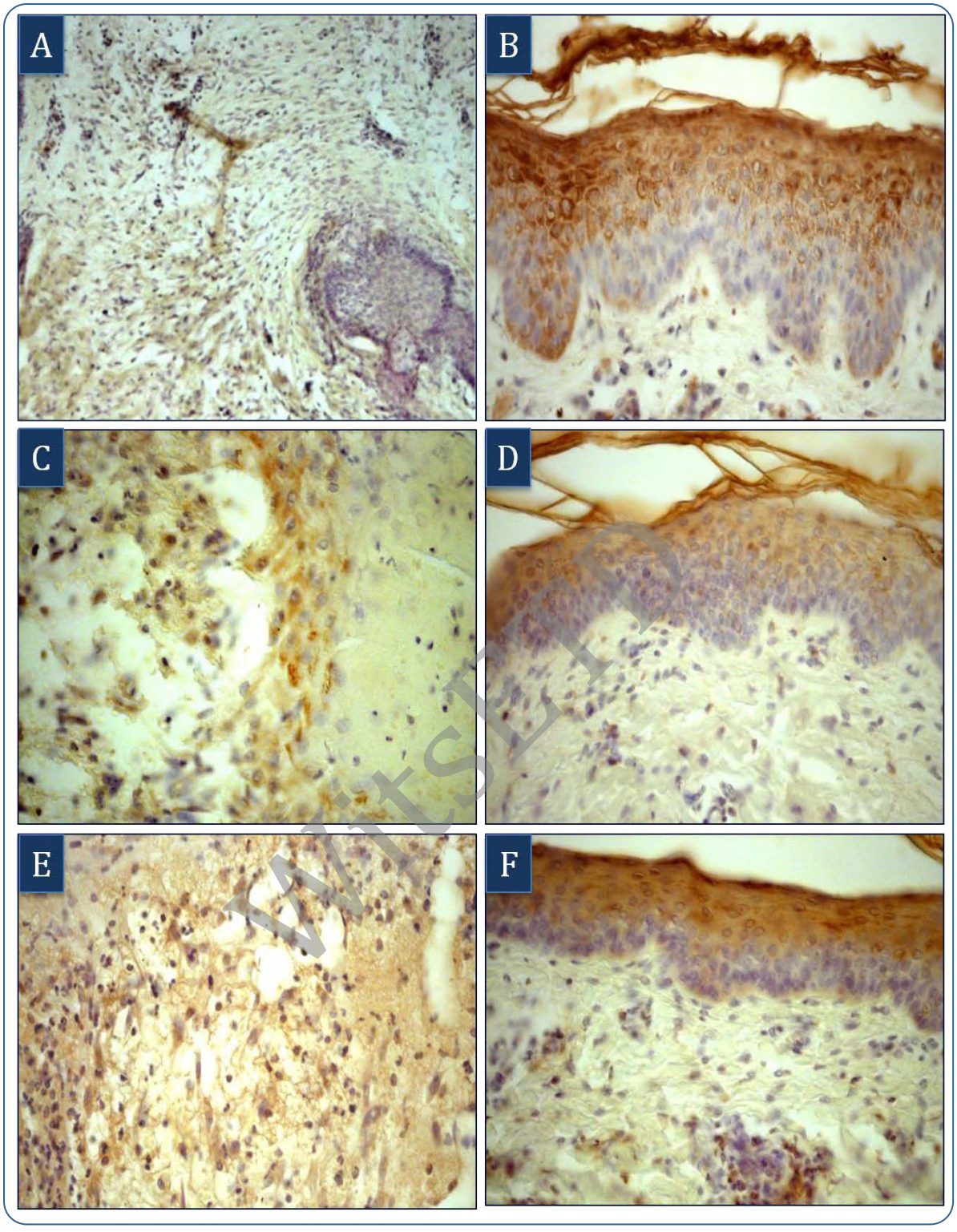

Figure 3.67: Representative sections of TGFβR$_{II}$ localisation on day 4 wound tissue. A & B– *untreated tissue;* ***C & D-*** *B. natalensis-treated wound ;* ***E & F-*** *B. frutescens-treated wound. Note the expression of TGFβR$_{II}$ is less intense in the stratum basale of the epidermis. (x40)*

created with nitroPDF professional
download the free trial online at nitropdf.com/professional

On **day 7** post-wounding, TGFβR$_I$ was strongly expressed in the epidermis of the untreated tissue. The localisation was evident in all the epidermal layers except for the stratum basale. The expression was weaker in both treatment groups with little difference between them (Fig. 3.68). In both treatment groups, the localisation was limited to the upper layers of the stratum spinosum. TGFβR$_I$ was also localised in cells scattered in the granulation tissue and in the hair follicles of the untreated wounds and both treatment groups. This localisation appeared to be stronger in the untreated and the *B. frutescens*-treated wounds.

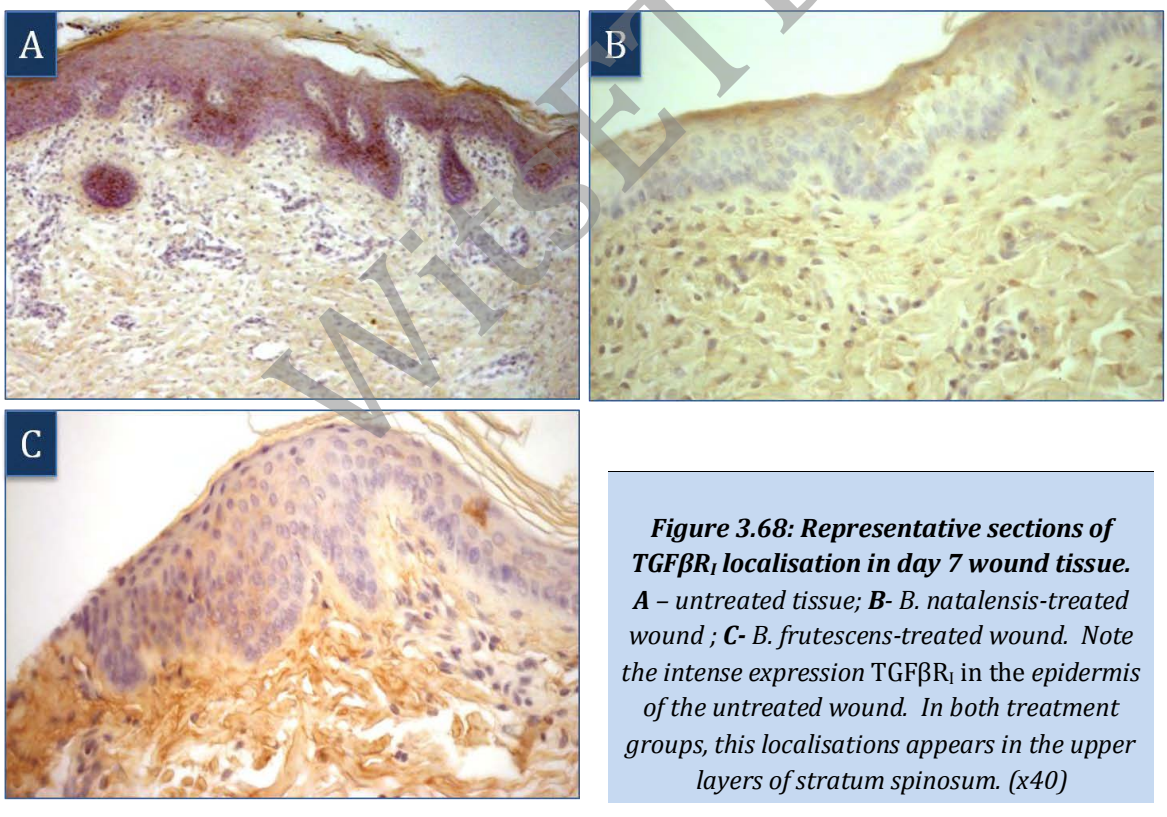

Figure 3.68: Representative sections of TGFβR$_I$ localisation in day 7 wound tissue. ***A*** *– untreated tissue;* ***B-*** *B. natalensis-treated wound ;* ***C-*** *B. frutescens-treated wound. Note the intense expression* TGFβR$_I$ *in the epidermis of the untreated wound. In both treatment groups, this localisations appears in the upper layers of stratum spinosum. (x40)*

WiSETD

created with nitroPDF professional
download the free trial online at nitropdf.com/professional

On **day 7** post wounding, TGFβR$_{II}$ expression appeared stronger in the untreated tissue, being present in all the layers of the epidermis except for the stratum basale. The expression of TGFβR$_{II}$ in the epidermis of both treatment groups appeared to be similar to each other, but weaker than that of the untreated wound tissue (Fig. 3.69). In all three groups, TGFβR$_{II}$ was also localised in scattered cells of the granulation tissue and in the epithelial cells of the roots sheath of the hair follicles. This localisation appeared to be stronger in the untreated wound tissue than in the treated groups.

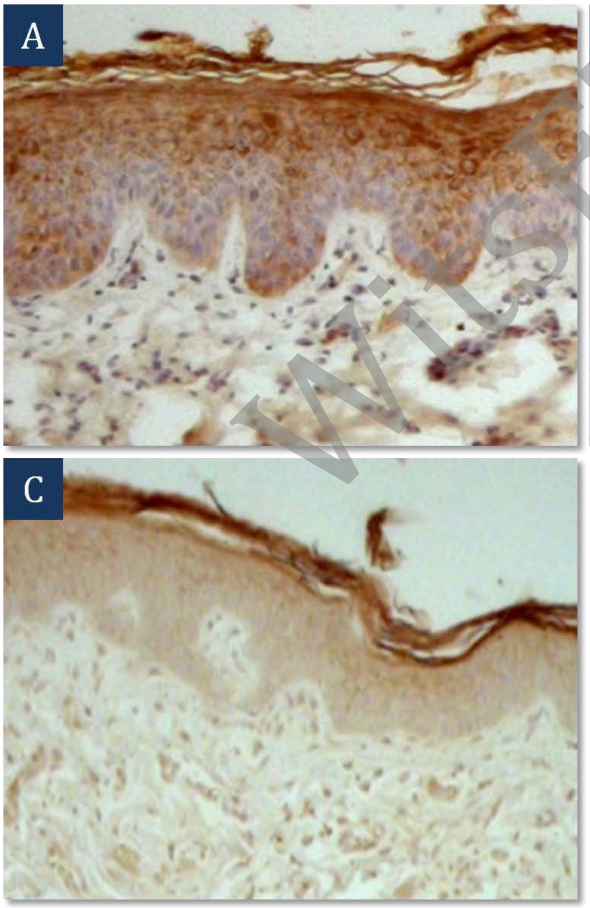

Figure 3.69: Representative sections of TGFβR$_{II}$ localisation in day 7 wound tissue. ***A*** *– untreated tissue;* ***B****- B. natalensis treated wound ;* ***C****- B. frutescens treated wound. Note the strong expression of TGFβR$_{II}$ in the untreated wound. (x40)*

WisERD

created with nitroPDF professional
download the free trial online at nitropdf.com/professional

In the tissue on **day 10** post-wounding, TGFβR$_I$ and TGFβR$_{II}$ was strongly expressed in the epidermis and granulation tissue of both treatment groups compared to that of the untreated tissue (Figs. 3.70 and 3.71). In all three groups, the localisation was evident in all layers of the epidermis except for the stratum basale. TGFβR$_I$ and TGFβR$_{II}$ were also localised in cells scattered in the granulation tissue and in the hair follicles with the localisation of TGFβR$_I$ and TGFβR$_{II}$ being stronger in both treatment groups when compared to the untreated wound tissue.

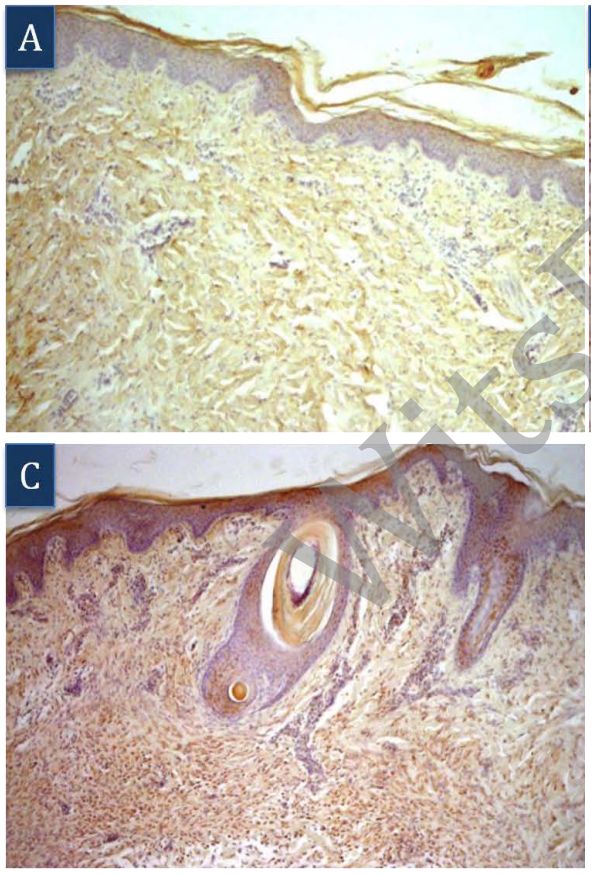

Figure 3.70: Representative sections of TGFβR$_I$ localisation in day 10 wound tissue. ***A*** *– untreated tissue;* ***B****- B. natalensis-treated wound ;* ***C****- B. frutescens- treated wound. Note more intense expression in both treatment groups than the untreated wound. (x40)*

UnitsED

created with nitroPDF professional
download the free trial online at nitropdf.com/professional

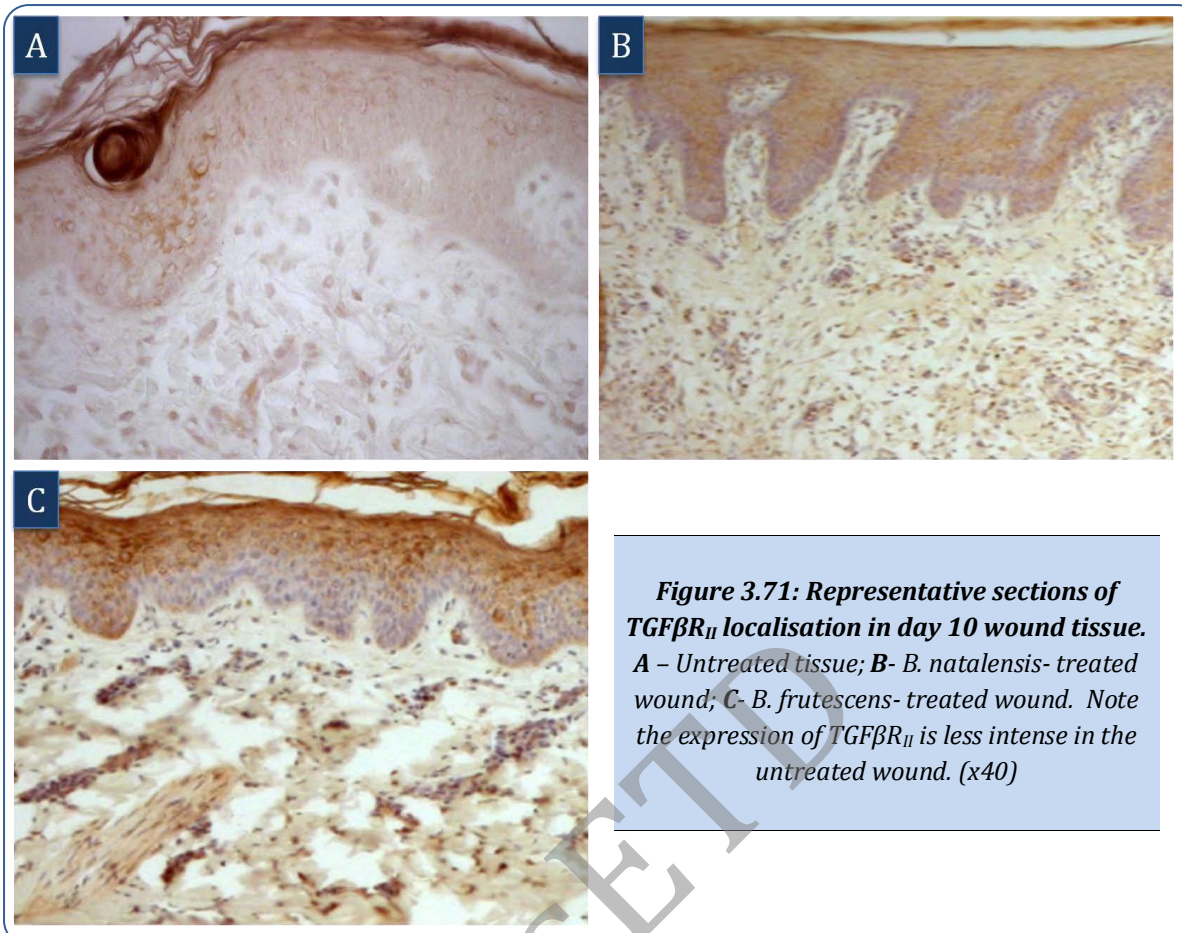

Figure 3.71: Representative sections of TGFβR$_{II}$ localisation in day 10 wound tissue. ***A*** *– Untreated tissue;* ***B****- B. natalensis- treated wound;* ***C****- B. frutescens- treated wound. Note the expression of TGFβR$_{II}$ is less intense in the untreated wound. (x40)*

WitsETD

created with nitroPDF professional
download the free trial online at nitropdf.com/professional

In the tissue on **day 16** post wounding, $TGF\beta R_I$ was equally expressed in all three experimental groups (Fig. 3.72). In all of the three groups, the localisation of $TGF\beta R_I$ was evident in all the layers of the epidermis except for the stratum basale. This expression appeared to be less intense than on the previous days. $TGF\beta R_{II}$ was most strongly expressed in the *B. natalensis*- treated group and weakest in the *B. frutescens*-treated wounds (Fig. 3.73).

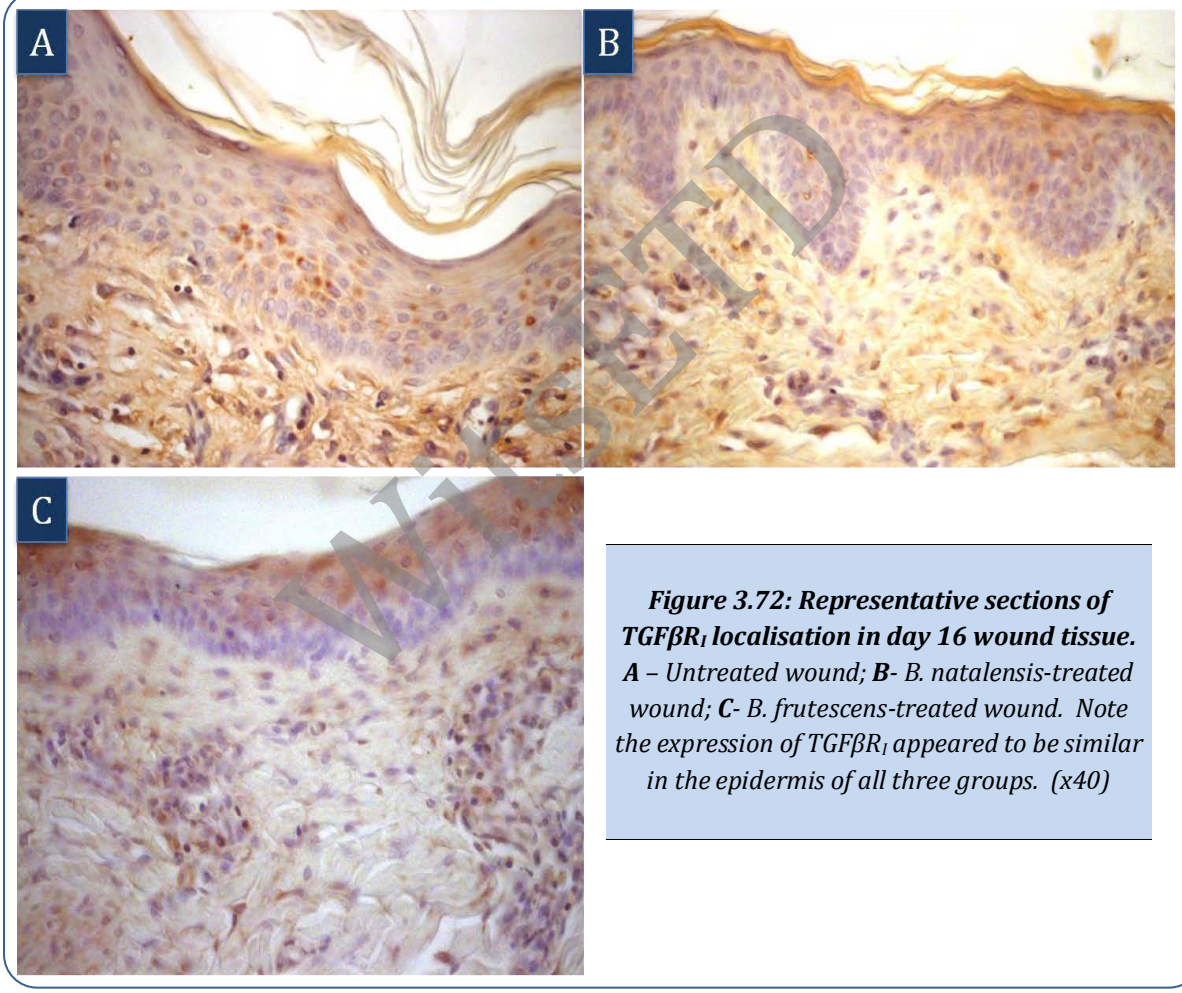

Figure 3.72: Representative sections of $TGF\beta R_I$ localisation in day 16 wound tissue. ***A*** *– Untreated wound;* ***B****- B. natalensis-treated wound;* ***C****- B. frutescens-treated wound. Note the expression of $TGF\beta R_I$ appeared to be similar in the epidermis of all three groups. (x40)*

WISETD

created with nitroPDF professional
download the free trial online at nitropdf.com/professional

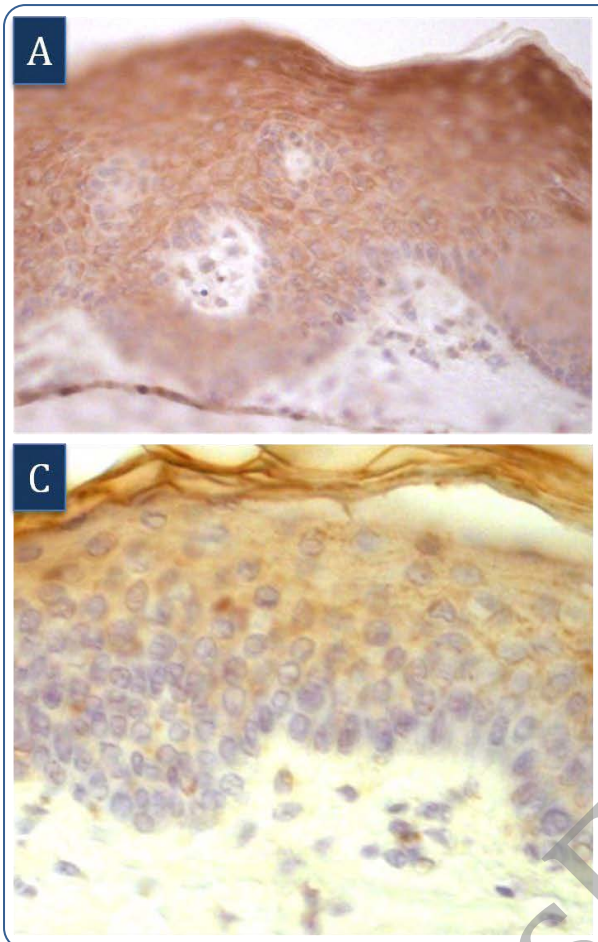

Figure 3.73: Representative sections of $TGF\beta R_{II}$ localisation on day 16 wound tissue. ***A*** *– Untreated tissue;* ***B****- B. natalensis-treated wound; C- B. frutescens-treated wound. Note the stronger expression $TGF\beta R_{II}$ in the B. natalensis-treated group than the B. frutescens-treated group. (x40)*

WitsETD

created with nitroPDF professional
download the free trial online at nitropdf.com/professional

3.3. An *in vivo* human study of the effects of *B. natalensis*- and *B. frutescens*-treated wounds compared to untreated wounds in skin

Six patients from the Dermatology Clinic at the Johannesburg General Hospital agreed to participate in this part of the study. Initial digital photographs of the bilateral skin lesion of patients were taken (Fig. 3.74) before any treatment was administered. The patients were given colour-coded bottles of the leaf gel extracts and instructions on how to apply the gel. Following seven days of treatment the patients were instructed to return to the clinic for follow-up assessment. None of the patients returned to the clinic for the follow-up assessment. Several telephone calls to the patients remained unanswered. One patient indicated that she had not used the leaf gel extract supplied to her. The results of this part of the study were therefore inconclusive due to patient non-compliance.

WitsETD

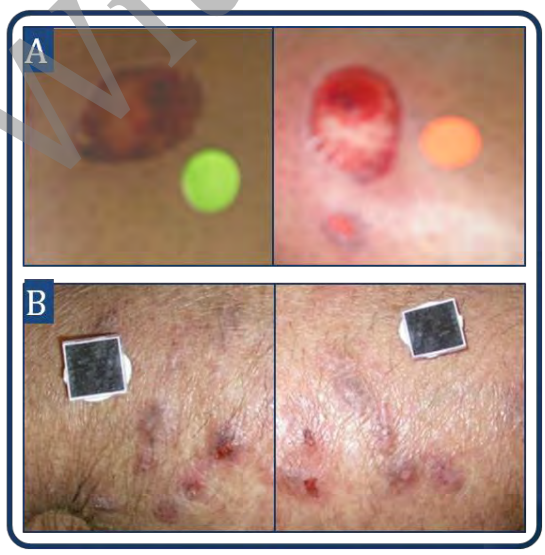

Figure 3.74: Representative photographs of the patient lesions before treatment. *A –patient presented with burn wounds on both arms; B- patient presented with several lesions on both forearms*

created with nitroPDF professional
download the free trial online at nitropdf.com/professional

3.4. An overall summary of the results of the present study

Table 3.10 presents a brief summary of results of each part of the present study.

Table 3.10 : Summary of the results of the present study

	Bulbine natalensis	***Bulbine frutescens***
Part 1: An in vitro study of the effects of B. natalensis and B. frutescens on human epidermal keratinocytes and dermal fibroblasts		
1. MTT ASSAY	***Keratinocyte Cell Line:*** No significant difference compared to untreated cultures at all concentrations tested (p=0.96)	***Keratinocyte Cell Line:*** More non-viable cells than untreated cultures at concentrations greater than 100µl/ml
	Fibroblast Cell Line: No significant difference between treated and untreated cultures (p=0.94)	***Fibroblast Cell Line:*** No significant difference between treated and untreated cultures (p=0.24)
2. WST-1 Assay	***Keratinocyte Cell Line:*** Gradual increase in cell number, reaching a maximum at the 400µl/ml concentration. Cell number 5.1 times that	***Keratinocyte Cell Line:*** Gradual increase in cell number, reaching a maximum at the 400µl/ml concentration. Cell number 4.9 times that

WiSETD

created with nitroPDF professional
download the free trial online at nitropdf.com/professional

	of untreated cultures.	of untreated cultures.
	Fibroblast Cell Line: Greatest effect on cell number at concentrations between 300-400µl/ml. Cell number 4.6 times that of untreated cultures.	***Fibroblast Cell Line:*** Greatest effect on cell number at a concentration of 50µl/ml. Cell number 5.2 times that of untreated cultures.
3. BrdU assay	***Keratinocyte Cell Line:*** Greatest effect on cell proliferation at 400µl/ml.	***Keratinocyte Cell Line:*** Greatest effect on cell proliferation at 700µl/ml.
	Fibroblast Cell Line: Significantly increased cell proliferation at 400-700 µl/ml.	***Fibroblast Cell Line:*** Significantly increased cell proliferation at 400-800 µl/ml.
4. Score assay	***Keratinocyte Cell Line:*** Score 'closed' at 32 hours.	***Keratinocyte Cell Line:*** Score 'closed' at 32 hours
	Fibroblast Cell Line: Score 'closed' at 36 hours.	***Fibroblast Cell Line:*** Score 'closed' at 40 hours
Part 2: An in vivo animal study of the effects of B. natalensis- and B. frutescens-treated wounds compared to untreated wounds in pig skin		
5. Rate of contraction	Significant increase in wound contraction when compared to the untreated wounds on days 2, 4 and	Significant increase in wound contraction when compared to that of the untreated wounds evident

WitsETD

created with nitroPDF professional
download the free trial online at nitropdf.com/professional

	10 (p=0.004, p=0.007 and p=0.03, respectively).	only on day 4 (p=0.004).
6. Tensile Strength	Significantly stronger than that of the untreated wounds (p=0.019).	Significantly stronger than that of the untreated wounds (p=0.002).
Biochemical analyses of the excisional wounds treated with B. natalensis and B. frutescens compared to the untreated wounds		
7. Estimation of Collagen	Significant increase in collagen in the treated compared to the untreated wounds (p=0.014). Over the duration of the 16 days of treatment, the average collagen content of the treated wounds was 1.70 times greater than that of the untreated wounds.	Significant increase in collagen in the treated compared to the untreated wounds (p=0.018). Over the duration of the 16 day treatment period, the collagen content of the treated wounds was 1.48 times that of the untreated wounds.
8. Estimation of Hexosamine	Over the duration of the 16 days of treatment, hexosamine content was 1.08 times greater than that of the untreated group.	Over the duration of the 16 days of treatment, hexosamine content was 1.07 times greater than that of the untreated group.
9. Estimation of protein	Significant increase over that of the untreated wounds	Significant increase over that of the untreated

WitsETD

created with nitroPDF professional
download the free trial online at nitropdf.com/professional

	(p=0.03).	wounds (p=0.04)
10. Estimation of total DNA	Significant increase in the DNA content of the treated wounds compared to the untreated wound p=0.04. Over the 16 day treatment period, DNA content 1.78 times that of the untreated wounds.	Significant increase in the DNA content of the treated wounds compared to the untreated wound p=0.04. Over the 16 day treatment period, DNA content 1.77 times that of the untreated wounds.
11. Collagen:DNA ratio	No significant difference between treated and untreated wounds (p=0.57)	No significant difference between treated and untreated wounds (p=0.37)
Histological analyses of the B. natalensis- and B. frutescens-treated wounds compared to untreated wounds in pig skin		
12. Granulation tissue	Dense granulation tissue from as early as day 2 post wounding continuing until day 7. Density of cells in wound space decreases at day 10.	Less dense granulation tissue at day 2 post wounding but equivalent to *B. natalensis* at days 4 and 7. Density of cells decreased drastically at day 10.
13. Migrating keratinocytes	The distinct migrating 'tongue' at the edge of the wound present at day	Some migrating keratinocytes visible at day 2, distinct migrating 'tongue' at

WitsETD

created with nitroPDF professional
download the free trial online at nitropdf.com/professional

	2 becomes more distinct and migrates further at day 7. Distinct migrating tongue in untreated cultures only evident from day 7.	the edge of the wound clearly visible at day 4. Distinct tongue in untreated cultures evident at day 7.
14. Blood Vessels	Greater vascularity than untreated wounds.	Greater vascularity than untreated wounds.
15. Wound contraction	Wound contraction begins early and continues until wound closes as early as day 10.	Wound contraction begins early and continues until wound closes as early as day 7.
16. Collagen deposition	Collagen deposition evident at day 4 compared to at day 7 in the untreated wounds.	Dense collagen fibres present at day 4.
Immunohistochemical analyses of the excisional wounds		
17. αSMA	Expressed in the layers of the epidermis and in the myofibroblasts and linings of vessels in the dermis.	Expressed in the layers of the epidermis and in the myofibroblasts and linings of vessels in the dermis.
18. VEGF	Expression in the suprabasal layers of the	Strongly expressed in wound tissue especially in

WitsETD

created with nitroPDF professional
download the free trial online at nitropdf.com/professional

	epidermis not as strong as in *B. frutescens*-treated wounds but stronger than in the untreated tissue.	suprabasal layers of the epidermis.
19. TGFβR$_{I}$	Expression weaker than *B. frutescens*-treated and untreated wounds.	Strongly expressed especially in the suprabasal layers of the epidermis and in cells scattered in the granulation tissue
20. TGFβR$_{II}$	Equally expressed: in early wound healing, weaker expression than in the untreated tissue but stronger that than untreated tissue in late wound healing	Equally expressed: in early wound healing, weaker expression than in the untreated tissue but stronger that than untreated tissue in late wound healing

WitsETD

created with nitroPDF professional
download the free trial online at nitropdf.com/professional

4. DISCUSSION

Wound healing commences immediately following injury and proceeds in a complicated but well organised sequence involving the interaction of many cell types and cytokines (Lin *et al.,* 2003). The main objective of wound management is to heal the injury in the shortest possible time with minimal pain and discomfort to the patient. At the site of the wound, a flexible fine scar with maximal tensile strength is desired (MacKay and Miller, 2003).

In the quest to accelerate healing, scientists have utilized medicinal plants to promote the various stages of wound healing (e.g. coagulation, inflammation, fibroblast proliferation, collagen formation and deposition, re-epithelialisation and wound contraction). Some of these plants include *Aloe vera* (Chithra *et al*., 1998a; Chithra *et al*., 1998b; Choi *et al*., 2001; Subramanian *et al.*, 2006), *Centella asiatica* (Shukla *et al.,* 1999) and *Calotropis procera* (Rasik *et al*., 1999). All three of these plants have been shown to promote fibroblast proliferation and collagen formation. *Cudrania cochinchinensis,* a Vietnamese folk remedy, was shown to stimulate fibroblast proliferation at low concentrations (Hien *et al*., 1997). These authors further suggested that the extract was able to afford fibroblast and endothelial cells some protection from oxidative damage by altering the cell membrane. Rabe and van Staden (1997) demonstrated the antibacterial activity of a number of South African indigenous plants used to treat wounds including *Bidens pilosa*, *Psidium guajava* and *Warburgia salutaris,* while Thang *et al.* (2001) demonstrated a possible anti-oxidant effect of *Chromolaena odorata* (a plant used commonly in Vietnamese traditional

WiseTD

created with nitroPDF professional
download the free trial online at nitropdf.com/professional

medicine), on wound healing. Phan *et al*. (1998) further demonstrated increased fibroblast and endothelial cell proliferation *in vitro* in cultures treated with Eupolin (an extract of Chromolaena *odorata*).

The present study examined the *in vitro* and *in vivo* effects of the leaf gel extracted from *B. natalensis* and *B. frutescens* on wound healing. While both these leaf gels are used in traditional medicine for wound healing, their effects have not previously been scientifically validated. In traditional medicine, the fresh leaf gel is squeezed directly on to the skin wound to promote healing. In the present study, this method of extraction was used to mimic the use of the gel in traditional medicine. In addition, the initial use of the lyophilised gel of the plant leaves in *in vitro* experiments, did not elicit results. This may be due to some molecules being destroyed in the lyophilising process. Khalil *et al.* (2007) also preferred to mimic the customary mode of administration of extracts in their experiments evaluating the wound healing effects of the fresh leaf extracts of Jordanian traditional medicinal plants using male albino Swiss mice.

WitsETD

In traditional use, both the *Bullbine* leaf gels are used at 100% concentration. The use of the crude extracts of both *Bulbine* leaf gels in the *in vivo* experiments confirmed their beneficial effect on wound healing when compared to untreated wounds. It is possible that the effectiveness of the 100% concentrated leaf gels *in vivo* can be attributed to cell interactions between the different cell types of the dermis and epidermis and also between growth factors and cytokines released in the processes

created with nitroPDF professional
download the free trial online at nitropdf.com/professional

of wound healing. It is also possible that absorption of the active ingredient of the leaf gels is optimal when the leaf gels are applied in the crude form.

The *Bulbine* leaf gel extracts tested negative for antimicrobial activity using both the well and disc diffusion methods of antimicrobial testing. This confirms the negative antimicrobial results for both water and methanol extracts of *B. frutescens* obtained by Rabe and van Staden (1997) who tested *B. frutescens* against *Staphylococcus aureus*, *Staphylococcus epidemis*, *Escherichia coli*, *Bacillus subtilis* and *Klebsiella pneumoniae* bacterial cultures. *B. natalensis* was not previously tested for antimicrobial activity. The results of the present study imply that the beneficial effect of both *Bulbine* leaf gels on wound healing is not related to a potential antimicrobial activity. Interestingly, Rabe and van Staden (1997) demonstrated that of 21 South African indigenous plant species used for the treatment of skin lesions, only 10, 8 and 12 of these species were active against *Staphylococcus aureus*, *Staphylococcus epidemis* and *Bacillus subtilis*, respectively. They further concluded that as this activity was evident in the methanol and not the water extracts of these plants, it was unlikely that this antimicrobial activity was present in the traditional use of these plants where the plants are used as crude extracts or prepared in water.

The present study is the first *in vitro* comparative study of the effects of *B. frutescens* and *B. natalensis* on both fibroblast and the keratinocyte cell lines. Both cell types are integral to the process of wound healing (Öztürk *et al.,* 2007). In evaluating possible therapeutic agents, fibroblast cell cultures have been widely accepted as an *in vitro* system for testing wound healing activity. However, fibroblasts and keratinocytes

WitsETD

created with nitroPDF professional
download the free trial online at nitropdf.com/professional

have varied responses to exogenous agents. The inclusion of a keratinocyte cell line in the present study was to elucidate differences, if any, in the effects of the extracts on these two predominant cells present in skin.

Medicinal plants and their extracts are often falsely perceived to be safe. Therefore when assessing the therapeutic effects of medicinal plants, it is important to evaluate their cytotoxicity. In the present study, the cytotoxicity of the leaf gels was evaluated using a MTT assay. In the keratinocyte cultures, at low concentrations both *B. natalensis and B. frutescens* did not differ from the untreated cultures with regard to cytotoxicity. However, at higher concentrations, treatment with *B. frutescens* significantly depressed keratinocyte proliferation when compared to the untreated cultures resulting in a dose-dependent response especially at concentrations greater than 100µl/ml. This inhibition of cellular proliferation was always less than 20% below that of the untreated cultures. In the fibroblast cell line, treatment with either of the two gels, at any of the concentration tested, did not significantly alter the proliferation of the cultures from that of the untreated cultures. Generally, an exogenous agent is considered cytotoxic at the concentration capable of inhibiting cellular growth by 50% (IC_{50}) (Mosmann, 1983). As neither of the leaf gel extracts achieved an IC_{50} in either the keratinocyte or fibroblast cell lines, it can be concluded that the leaf gels of both plant species were not cytotoxic to either cell lines.

In interpreting the results of the MTT assay, it is important to note that the assay cannot be used as an accurate indicator of cell proliferation or DNA synthesis which

WitsETD

created with nitroPDF professional
download the free trial online at nitropdf.com/professional

both require more sensitive assays. Rather, Hong *et al.* (2001) suggests that the combination of a WST-1 assay and a BrdU assay is useful in evaluating the specific effect of a factor or drug on either DNA synthesis and metabolic activity or both. The WST-1 assay indicates the number of metabolically active cells while the BrdU assay measures DNA synthesis and therefore indicates cell proliferation. The WST-1 assay has an increased sensitivity compared to the MTT assay due to its low background absorbance and lower molecular mass (Tan and Berridge, 2000). Generally during wound healing, cell proliferation, cell number and DNA synthesis increase.

The results of this study show that the extracts of both *B. frutescens* and *B. natalensis* significantly increased the number of metabolically active cells (as indicated by the results of the WST-1 assay), cell proliferation and DNA synthesis (as indicated by the BrdU assay results) of both keratinocytes and dermal fibroblasts *in vitro*. *B. natalensis* had the greatest effect on the number of metabolically active cells in keratinocyte and fibroblast cultures at a concentration of 300µl/ml and 400µl/ml, respectively while its effect on DNA synthesis was greatest at 400µl/ml for both cell cultures. *B. frutescens* had its greatest effect on the metabolically active cell number at concentrations between 50-100µl/ml and 300µl/ml in the fibroblast cultures and at 300-500µl/ml in the keratinocyte cultures, while its effect on DNA synthesis and cell proliferation was greatest at 400µl/ml for fibroblast cultures and 700µl/ml for the keratinocyte cultures. The maximal proliferative effect of *B. frutescens* was significantly greater than that of *B. natalensis* on the keratinocyte cultures. The analysis of the cell culture experiments demonstrated that both the *Bulbine* leaf gel extracts are able to increase fibroblast and keratinocyte cell proliferation *in vitro*.

WitsETD

created with nitroPDF professional
download the free trial online at nitropdf.com/professional

This *in vitro* increase in cell proliferation was subsequently confirmed by the *in vivo* experiments that demonstrated increased granulation tissue and thus, ECM formation, and earlier re-epithelialisation in both treatment groups compared to that of the untreated wounds.

In general, the maximal effect of *B. natalensis* on both types of cell cultures was achieved at the same concentration. However, the maximal effect of *B. frutescens* was at a higher concentration in the keratinocyte cell cultures than the fibroblast cell cultures. This may suggest a greater sensitivity of the keratinocyte cell cultures to *B. frutescens*. Thang *et al.* (2001) also showed a varied response between fibroblasts and keratinocyte cell cultures treated with *Chromolaena odorata* (the leaves of this shrub are used for skin ailments in Vietnam) and suggested that human epidermal keratinocytes display 'a more complicated' response to plant extracts than do human fibroblast cultures. In the Thang *et al.* (2001) study, fibroblasts were more dependent on the dose of the gel, while keratinocytes were more sensitive to oxidative damage. In their study, Thang *et al.* (2001) also demonstrated an increase in fibroblast and keratinocyte cell proliferation, and keratinocyte migration in cultures treated with *Chromolaena odorata.*

Abdullah *et al.* (2003) demonstrated an increased proliferative effect on human diabetic fibroblasts treated with 1.25% and 2.5% of *Aloe vera* extract compared to no effect on non-diabetic fibroblasts. The latter study did not provide a rationale for the concentration of the *Aloe vera* extract used in the experiments, which was much lower than the effective concentration of both *B. natalensis* and *B. frutescens* extracts

WitsETD

created with nitroPDF professional
download the free trial online at nitropdf.com/professional

on fibroblast cultures (40%) and keratinocyte cultures (40% and 70% respectively). Due to these and other unpublished results, Abdullah *et al.* (2003) concluded that the role of *Aloe vera* in promoting wound healing is to decrease the glucose concentration at the site of the injury. As *B. natalensis* and *B. frutescens* belong to the same family as *Aloe vera*, it is interesting to note their positive effect on non-diabetic fibroblasts. This suggests that the mechanism of action of *B. natalensis* and *B. frutescens* may differ from that *Aloe vera*. As the treatment of wounds in diabetic patients is particularly problematic, future studies should compare the activity of *B. natalensis* and *B. frutescens* on diabetic fibroblasts to evaluate their potential effect, if any, on diabetic wounds.

Treatment with *B. natalensis* and *B. frutescens* increased migration across a 'score' in both keratinocyte and fibroblast cultures. In addition, the scores in *B. natalensis*-treated cultures closed sooner than *B. frutescens*-treated cultures. Choi *et al.* (2001) demonstrated a similar earlier closure of scores in human keratinocyte cell cultures treated with an *Aloe vera* glycoprotein fraction. The latter study found a larger population of migrating cells in cultures treated with the *Aloe vera* fraction after 40 hours than in the untreated cultures, which did not fully populate the scored area. The results of the 'score' assay of the present study correlates well with the results of the histological study which showed increased wound contraction in both treatment groups compared to that of the untreated wounds. This suggests increased cell migration leading to faster re-epithelialisation and granulation tissue formation.

WitsETD

created with nitroPDF professional
download the free trial online at nitropdf.com/professional

In this study, wound contraction was measured as the percentage change in the area of the excisional wound. Treatment of the wounds with both leaf gels appeared to initiate wound contraction on days 2 and 4 which is earlier than in the untreated wounds. From the histological analysis, wounds treated with either of the leaf gels were found to re-epithelialise significantly faster than the untreated wounds. Once again, these results are comparable to the effect of *Aloe vera* on diabetic wounds in the male Wistar rat (Chithra *et al.,* 1998a), where wounds treated with topical *Aloe vera* contracted 10% faster than the untreated wounds. Similarly, Rasik *et al.* (1999) demonstrated increased wound contraction in guinea pig skin treated with 1% *Calotropis procera* (a well known plant of the family Asclepiadaceae, used in Ayurvedic medicine).

WitsETD

Wound contraction is fibroblast-dependant and involves the deposition and maturation of collagen. The role of collagen in wound healing commences immediately the wound is formed and continues for months after it appears to have healed. Collagen is the predominant extracellular protein in the granulation tissue of wounds (Chithra *et al.,* 1998b). Immediately following injury, there is an increase in the synthesis of collagen in the wound area. Collagen plays a role in haemostasis and in providing strength and integrity to the wound matrix. It is also essential for re-epithelialisation and cell-cell and cell-matrix interactions (Raghow, 1994; Chithra *et al.,* 1998a).

created with nitroPDF professional
download the free trial online at nitropdf.com/professional

Hydroxyproline is the major constituent of collagen and is also found almost exclusively in collagen. The estimation of hydroxyproline is an accepted method of biochemically evaluating the total collagen content of a sample (Lin *et al.,* 2003) and is also used as a marker of collagen synthesis (Rasik *et al.*, 1999). A biochemical analysis of the excisional wound tissue of both *B. natalensis*- and *B. frutescens*-treated wounds demonstrated a significant increase in the total collagen content compared to that of the untreated wounds. In all three groups, the total collagen content reached a maximum on day 7. The histological analysis of the untreated wound sections demonstrated collagen deposition on day 7 with an increase on day 10 and then to day 16 with some reorganisation on day 16. In both treated groups, collagen deposition was evident earlier than day 7 (on day 4). The collagen appeared more densely packed on day 7 in the *B. frutescens*-treated wounds when compared to the other two groups on the same day. Re-organisation of the collagen (indicating collagen maturation) was evident as early as day 10 in the sections of both treatment groups. Chithra *et al.* (1998a) reported a similar pattern in their biochemical estimation of collagen content (with maximal collagen content on day 8) in the wounds of both the diabetic rats treated with *Aloe vera* and their corresponding untreated control wounds. An increase in the collagen content of the ECM is a characteristic change observed in the proliferative phase of wound healing (Lin *et al.,* 2003). This suggests that in the wound tissue of the pig, the proliferative stage reaches a peak on day 7.

According to Chithra *et al.* (1998a; 1998b) and Lin *et al.* (2003) an increase in collagen may be attributed to an increase in collagen synthesis or an increase in the

WitsETD

created with nitroPDF professional
download the free trial online at nitropdf.com/professional

proliferation of fibroblasts which synthesise collagen, or both. When considering the increase in the hydoxyproline (collagen) content of the *B. natalensis*- and *B. frutescens*-treated wounds, together with the increased numbers of fibroblasts seen in the *in vitro* studies, both leaf gels appear to increase collagen content by increasing proliferation of fibroblasts. Chithra *et al.* (1998a) showed that wounds in rats given either topical or oral *Aloe vera* displayed increased collagen content with a greater increase present in the group receiving orally administered *Aloe vera*. This increased collagen content was attributed to both fibroplasia and an increase in the synthesis of collagen per cell (indicated by the collagen/DNA ratio). The study by Chithra *et al.* (1998a; 1998b) demonstrated that the active ingredients of *Aloe vera* were not destroyed in the stomach following oral administration. This corroborates the earlier study of Davis (1987) that demonstrated a greater reduction in wound diameter in mice receiving 100 mg/kg/day oral *Aloe vera* compared to those receiving topical 25% *Aloe vera*. As the present study also demonstrated a similar increase in fibroblast proliferation and in collagen synthesis in wounds treated topically with the leaf gel extracts of *B. natalensis* and *B. frutescens*, it would be interesting to compare the effect of the *Bulbine* leaf extracts on wound healing using different methods of administration.

Glycoaminoglycans (GAG) and proteoglycans are synthesised by fibroblasts in the wound area. These substances form a hydrated gel-like ground substance (the provisional matrix) on which collagen is deposited. As the collagen content increases, hexosamine levels decrease (Dunphy and Udupa, 1955; Chithra *et al.,* 1998b). Estimation of hexosamine therefore, estimates the amount of ground substance in a

WitsETD

created with nitroPDF professional
download the free trial online at nitropdf.com/professional

wound (Chithra *et al.,* 1998b). From the biochemical estimation of hexosamine in the present study, it was found that treatment with *B. natalensis* and *B. frutescens* resulted in a maximal concentration of hexosamine on day 4 followed by a steady decrease to day 16. This was associated with a concomitant increase in total collagen content in both treated groups at day 7. This indicates replacement of granulation tissue in the wound area by collagen. This is corroborated by the increased collagen deposition seen in the histological sections of the treated wounds. As collagen deposition increases, it begins to occupy a greater area at the wound site.

In the present study, collagen deposition was evident in the granulation tissue of both groups of treated wounds from day 4. The collagen deposition appeared to be greater in the *B. frutescens*-treated group than the *B. natalensis*-treated group only on day 4 (as seen with Mallory trichrome staining). Thereafter, the amount of collagen in both treatment groups was similar. In the untreated wounds, collagen deposition was only evident from day 7. Reorganising of the collagen into bundles, indicating some maturation, was evident as early as day 10 post-wounding. At this stage, the arrangement of collagen in the untreated wounds appeared to lie in parallel rows. The collagen in the *B. frutescens*-treated group appeared more dense than that of the *B. natalensis*-treated group. In the *B. natalensis*-treated group however, more densely packed bundles of collagen was present, indicating a more advanced stage of collagen maturation. In both treatment groups, the early increase in the collagen content of the treated groups (from the biochemical estimation of hydroxyproline) could be associated with an increase in the density of fibroblasts in the granulation tissue. Therefore, the increased collagen may be the result of fibroplasia.

WitsETD

created with nitroPDF professional
download the free trial online at nitropdf.com/professional

Collagen imparts tensile strength and elasticity to healed skin. The tensile strength of the incisional wounds on day 16 post wounding, was significantly greater in both treated groups of wounds than in the untreated wounds. According to Singer and Clark (1999), wounds gain 20% of their final strength in the first three weeks post-wounding. Thereafter the rate at which the wounds gain tensile strength is reduced. Scar tissue will only ever reach 70% of the strength of normal unwounded tissue over a period of two years (Singer and Clark, 1999). The tensile strength of a wound can be related to its collagen formation and maturation. As the wound heals, collagen molecules are synthesised and laid down at the wound site. These molecules become cross linked to form fibres. The strength of the repaired wound tissue is a result of the remodelling of collagen and the formation of stable intra- and inter-molecular cross linking.

WitsETD

The significant increase in tensile strength of the treated incisional wounds in the present study was corroborated by the biochemical results of the excisional wound tissue which confirmed the presence of a significantly greater total collagen content in both treated groups compared to that of the untreated wounds. This was further confirmed by the greater density and organisation of the collagen in the histological sections of the treated wounds compared to the untreated wounds. Since the incisional wounds treated with *B. natalensis* and *B. frutescens* displayed greater tensile strength than the untreated wounds, it may imply that the leaf gel extracts are able to increase collagen synthesis and possibly even aid in formation of cross linkages as the collagen matures. Shukla *et al*. (1999) demonstrated a 53% increase in tensile strength of wounds treated with 0.2% asiaticoside (isolated from *Centella*

created with nitroPDF professional
download the free trial online at nitropdf.com/professional

asiatica, a plant widely used in eastern traditional medicine for its wound healing properties) compared to untreated wounds in a guinea pig wound healing experiment. Chithra *et al.* (1998b) confirmed the earlier results of Davis *et al.* (1987) who showed that treatment of wounds with *Aloe vera* increased collagen concentration and tensile strength when compared with the untreated wounds. Chithra *et al.* (1998b) attributed this to an increase in the aldehyde groups of collagen fibres responsible for forming cross-linkages and therefore resulting in greater tensile strength of the *Aloe vera* treated wounds. Subramanian *et al.* (2006) studied rabbit skin excisional wounds (harvested on days 7 and 14 post-wounding) treated with *Aloe vera* and concluded that *Aloe vera* increased wound contraction and collagen synthesis and significantly increased protein and DNA synthesis. This was attributed to mannose-6-phosphate known to be present in *Aloe vera* leaf gel (Subramanian *et al*., 2006). Mannose containing products have been shown to increase macrophage activity and therefore stimulate fibrobast activity (Tizard *et al.*, 1989; Davis *et al.,* 1994).

Migration of keratinocytes across the wound gap is an early step in wound healing. Re-epithelialisation is critical to optimal wound repair because it aids in contraction of the wound and restores the protective barrier (Tsirogianni *et al.,* 2006). In the present study, re-epithelialisation of the wound area occurred earlier in both treatment groups compared to the untreated wounds. Between the treatment groups, the rate of re-epithelialisation (indicated histologically by keratinocyte migration to form the neo-epidemis) was greater in the *B. frutescens*-treated wounds than the *B. natalensis*-treated wounds. This may suggest that in addition to

WitsETD

created with nitroPDF professional
download the free trial online at nitropdf.com/professional

stimulating fibroblast proliferation, both leaf gels also stimulate keratinocyte proliferation and migration. This confirms the results of the *in vitro* part of this study which demonstrated increased proliferation of the keratinocyte cells in culture when treated with either *B. natalensis* or *B. frutescens* leaf gel extracts (as demonstrated by the BrdU and WST-1 assays). This is further corroborated by the increased migration seen in the 'scores' created in the *B. natalensis*- and *B. frutescens*-treated keratinocyte and fibroblast cultures compared to that of the untreated cultures. Keratinocytes are increasingly being accepted as the key regulators of inflammation and remodelling in skin wound healing (Hakvoort *et al*., 2000). Keratinocyte motility is facilitated by the expression of surface intergrin receptors that interact with components of the ECM (Tsirogianni *et al.,* 2006). The formation of the neo-epidermis dissects the wound, separating the granulation tissue from the eschar. Macrophages and keratinocytes produce TGF-β1 (a major modulator of wound healing) which stimulates migration, heparin binding epidermal growth factor and TGF-α that in turn mediates the migration, differentiation and proliferation of keratinocytes (Frank *et al.*, 1996; Tsirogianni *et al.,* 2006). The intense immunolocalisation of $TGF\beta R_I$ and $TGF\beta R_{II}$ in the epidermis of the treated wounds indicates increased TGF-β receptor binding activity. An increase in TGF-β corroborates the increased keratinocyte migration and proliferation seen in the histological sections of wounds from both treatment groups.

According to Braiman-Wiksman *et al.* (2007), the histological features of wound healing on days 1-3 post-wounding include blood clot formation, activation of the epidermal edges and early inflammation. Granulation tissue begins to fill the wound

WitsETD

created with nitroPDF professional
download the free trial online at nitropdf.com/professional

space 2-3 days following injury and consists of endothelial cells, fibroblasts, inflammatory macrophages, lymphocytes and new ECM (Tsirogianni *et al.,* 2006). In the histological examination of the wound tissue in the present study, the granulation tissue in the wounds of both treatment groups was more dense than the untreated wounds on days 2 and 4. The granulation tissue of the *B. natalensis*-treated groups was more dense than that of the *B. frutescens*-treated group on day 2. By day 7, the granulation tissue of all three groups was similar. Following day 7, the granulation tissue of both treatment groups became sparser, as collagen deposition increased. Collagen deposition of the untreated wounds remained unchanged from day 10 to day 16. According to Tsirogianni *et al.* (2006), fibroblasts reach their peak numbers at 7 to 14 days following wounding when they start to produce bFGF, TGFB, PDGF, KGF and IGF-1. The early density of the granulation tissue in wounds of both treatment groups suggests that treatment with *B. frutescens* and *B. natalensis* increases proliferation of fibroblasts earlier than in the untreated wounds. This confirms the biochemical estimation of the total protein and DNA content of the excisional wound tissue which also suggested greater cell proliferation in the treated wounds than the untreated wounds. The protein and DNA content of the granulation tissue is said to indicate the levels of protein synthesis and cell proliferation (Rasik *et al.*, 1999). Bourguinon and Bourguinon (1987) state that the increase in protein content is due to an increase in collagen synthesis. In the present study, the total protein and DNA content of both treatment groups were similar; reaching a maximum on day 7 followed by a decline to day 16 and was significantly greater than in the untreated wounds. There was a significant increase in both the protein and DNA content of both the *B. natalensis*- and *B. frutescens*-treated wounds. In the

WitsETD

created with nitroPDF professional
download the free trial online at nitropdf.com/professional

untreated wounds there was a sharp decline in protein content on day 10 – this was not evident in both the treatment groups. Chithra *et al.* (1998a; 1998b) suggests that when the protein and DNA content of treated wounds are greater than in the untreated wounds, it implies that the treatment stimulates cell proliferation. Thus, the *B. natalensis* and *B. frutescens* leaf gels appear to stimulate cell proliferation. Shukla *et al.* (1999) demonstrated a significant increase in DNA content but no increase in protein content in guinea pig skin wounds treated with a 0.2% asiaticoside isolated from *Centella asiatica*. They attributed this discrepancy to the specificity of the assays used for the estimation of the different amino acids.

Collagen: DNA ratios are said to indicate the collagen produced per cell. In the present study, the collagen:DNA ratios showed no significant difference between the untreated wounds and the two treatment groups. There may be several reasons for the similarity of the collagen:DNA ratios in these three groups e.g. a rapid cell proliferation initiated by the inflammatory response or an initial exponential increase in cell numbers, followed by a stationary phase. *In vivo* studies on wound healing are generally carried out over a period of 7 days post-wounding. It is possible that the profile of the collagen:DNA ratio may change as the experimental time of the study is extended due to collagen deposition and maturation. The extended experimental time in the present study using the pig model was essential to sample the different phases in wound healing. It is possible that increasing the experimental time even further may demonstrate collagen remodelling more clearly. In wound experiments on the red *Duroc* pig, Zhu *et al.* (2005) demonstrated that skin is restored to its normal structure in 6-8 weeks. New collagen formation continues for up to 6 weeks

WitsETD

created with nitroPDF professional
download the free trial online at nitropdf.com/professional

post- wounding. Thereafter the fibroblasts stop producing collagen and undergo apoptosis. Remodelling of the collagen fibres by degradation and re-synthesis allows the wound to gain strength. Remodelling continues for up to 2 years and the resulting scar is less cellular than normal skin and never achieves the same tensile strength as uninjured skin. A longer experimental period would provide insight into the long term effects of the plant leaf gel on tensile strength and collagen maturation. Experimental time however inevitably needs to be guided by the aim of the study and the cost of the experiment.

Studies have shown that, in early wounds, fibroblasts express morphological and functional characteristics of smooth muscle during wound healing which are essential to wound contraction (Desmoulière, 1995; Moulin, 1998). It is during the second week of wound healing that these fibroblasts differentiate into myofibroblasts (Tsirogianni *et al.,* 2006). Myofibroblasts contain cytoplasmic inclusions which are microfilaments or stress fibres thought to be involved in wound contraction. αSMA is the most common cell marker used to identify myofibroblasts populations based on their content of smooth muscle actin (Desmoulière, 1995; Moulin, 1998), which is located in the microfilaments. The localisation of αSMA was thus used in the present study to identify myofibroblasts in the wound tissue. Following wound contraction and collagen formation, both fibroblasts and myofibroblasts at the wound site undergo apoptosis.

In the present study, in addition to the localisation of αSMA in the myofibroblasts, αSMA was also localised in the keratinocytes of the epidermis, root sheaths of the

WitsETD

created with nitroPDF professional
download the free trial online at nitropdf.com/professional

hair follicles and the epithelium of the sebaceous glands. The mechanism of keratinocyte migration is not fully understood. Keratinocyte migration begins early in wound healing. Cells at the wound edge and from the remaining skin appendages undergo keratinocyte activation and adapt their phenotype to facilitate migration across the wound (Li *et al.*, 2007). These adaptations include the disassembly of desmosomes, the development of lamellipodia, retraction of intracellular tonofilaments and the formation of peripheral cytoplasmic actin filaments which allow movement (Goliger and Paul, 1995; Kwon *et al.*, 2007; Li *et al.*, 2007). When migration ceases due to contact inhibition, the keratinocytes reattach themselves by reconstituting the basement membrane and then begin the process of terminal differentiation to form a stratified epithelium (Li *et al.*, 2007). While the localisation of smooth muscle actin in the keratinocytes was at first surprising, Li *et al.* (2007) most recently demonstrated keratinocytes producing actin filaments at the edge of their cytoplasm to prepare for migration.

WitsETD

In the underlying granulation tissue, αSMA was also localised in the walls of the blood vessels and in scattered myofibroblasts at the edges of the granulation area. *B. frutescens*-treated wounds demonstrated an earlier expression of αSMA in myofibroblasts than the *B. natalensis* treated group at day 2 post-wounding. The localisation of αSMA in myofibroblasts at the edge of the wound site was similar in both treatment groups from day 7 post-wounding, being more intense than that of the untreated wounds. At day 10 post-wounding, fewer myofibroblasts appeared to be present in the wounds of both treated groups than on previous days and when compared to the untreated wounds. This decrease in myofibroblasts was correlated

created with nitroPDF professional
download the free trial online at nitropdf.com/professional

with wound contraction nearing completion. Kwon *et al*. (2007) demonstrated a greater number of myofibroblasts in rat skin wounds treated with fibronectin compared to untreated wounds on days 5 and 7 post-wounding. Fibronectin expressed primarily by fibroblasts at the wound site interacts with components of the ECM and is involved in fibroblast and keratinocyte migration. From their study, Kwon *et al.* (2007) concluded that exogenous fibronectin increased macrophage, myofibroblasts and fibroblast migration. The increased fibroblasts at the wound site increased the deposition of ECM and collagen at the wound site. Similarly in the present study, the increased expression of αSMA in the granulation tissue of the wounds of both treatment groups at day 7 post-wounding appears to indicate increased myofibroblast differentiation at the wound site. A greater number of myofibroblasts at the wound site would result in increased ECM and collagen production which correlates well with the increased hydroxyproline and total protein content estimated biochemically and with the histological sections of the wound site of both treatment groups at day 7 post-wounding compared to the untreated wounds.

WitsETD

In wound healing, during granulation tissue formation, myofibroblasts develop and then disappear when contraction is complete (Desmoulière, 1995). In the present study, the less intense expression of αSMA on days 10 and 16 post-wounding was concurrent with complete re-epithelialisation and wound contraction. Thus, it appears that the leaf gels of both plants increase wound contraction by increasing myofibroblast differentiation. This supports the earlier wound contraction seen in both treatment groups compared with the untreated wounds. The mechanisms of

created with nitroPDF professional
download the free trial online at nitropdf.com/professional

regulating myofibroblast formation and function are unclear. Myofibroblasts appear to undergo apoptosis in the wound area (Desmoulière, 1995) after contraction. In the present study, as contraction approached completion, there was a concomitant decrease in the presence of myofibroblasts at the wound site. It has been shown that in the fetus, wound healing occurs without scar formation and that scar formation coincides with the development of αSMA by myofibroblasts (Desmoulière, 1995). Moulin (1998) demonstrated that myofibroblasts synthesize significantly higher amounts of collagen than fibroblasts *in vitro.* In the present study, the increased levels of total protein and hydroxyproline content of the treated wound tissue compared to the untreated wound tissue coincided with the increased number of myofibroblasts immunolocalised in the treated wound tissue. The increased collagen content of the treated wounds may thus be related to the increase in the myofibroblast populations of the granulation tissue. Furthermore, TGF-β1 is the most recognized stimulator of myofibroblast differentiation. The increased expression of αSMA in the treated wounds maybe the result of increased TGF-β activity (as seen in the localization of $TGF\beta R_I$ and $TGF\beta R_{II}$ in the present study).

$TGF\beta R_I$ and $TGF\beta R_{II}$ have similar ligand binding affinities. Both receptors have a high affinity for TGF-β1 and a low affinity for TGF-β2. $TGF\beta R_{III}$ has a high affinity for both TGF-β1 and TGF-β2 (Cheifetz *et al.,* 1988). TGF-β1 is released during the inflammatory stage. In addition to embryogenesis and cell differentiation, the TGF-βs are also involved in apoptosis (Munir *et al.,* 2004). TGF-β1 promotes epithelial migration, fibroblast and keratinocyte proliferation and re-epithelialisation of skin wounds (Desmouliere, 1993; O'Kane and Ferguson, 1997; Lin *et al.,* 2003; Kwon *et al.*, 2007). One of the reasons postulated for the scarless wound healing seen in fetal skin

WitsETD

created with nitroPDF professional
download the free trial online at nitropdf.com/professional

is the low levels of TGF-β1, which is considered to be a scar promoting cytokine (Singer and Clark, 1999). Scarring is reduced in adults who are given antibodies to neutralise TGF-β1 and TGF-β2, or TGF-β3 which down regulate TGF-β1 and TGF-β2 (Sullivan *et al.,* 1995).

In the present study, $TGF\beta R_I$ and $TGF\beta R_{II}$ were localised in the wound tissue of all three groups from day 2 to day 16. This localisation was in all the layers of the epidermis except the stratum basale. This expression was initially (on days 2-4) stronger in the *B. frutescens*-treated and in the untreated wounds than in the *B. natalensis*-treated wounds. On day 16, the expression was stronger in the *B. natalensis*-treated wounds than in the *B. frutescens*-treated and the untreated wounds. According to Lin *et al.* (2003), a decrease in TGF- β1 is responsible for reduced collagen accumulation. TGF- β is thought to exercise an inhibitory effect on keratinocyte proliferation (Yang *et al.,* 1996; Werner and Smola, 2001). When found in high concentrations at the wound site, TGF-β, especially TGF-β1, stimulates fibroblast proliferation and plays a role in hypertrophic scarring. Several researchers suggest that TGF-β has a paradoxical effect on re-epithelialisation and granulation tissue formation. It is said to be a negative regulator of re-epithelialisation but also induces the expression of integrins needed for keratinocyte migration (Gailet *et al*., 1994; Zambruno *et al*., 1994; Werner and Grose, 2002). Werner and Grose (2002) showed that exogenous TGF-β increases both the rate of wound healing and the strength of the healed wound. Broadley *et al.* (1990) demonstrated that elevated levels of TGF-β1 lead to the stimulation of monocytes and further increases in cellular proliferation. Kwon *et al.* (2007) stated that the increased cellular proliferation at the

WisETD

created with nitroPDF professional
download the free trial online at nitropdf.com/professional

wound site would lead to a further increase of TGF-β1. In the present study, the localization of $TGF\beta R_I$ and $TGF\beta R_{II}$ was stongest in early wound healing and was progressively weaker after day 7. This could be related to the initial increase in cell proliferation followed by collagen production at the wound site which was confirmed from the histological analysis of the wound sections.

VEGF is critical for angiogenesis during the formation of granulation tissue from day 4 to day 7 post-wounding (Nissen *et al.,* 1998). In addition, VEGF mediates vascular hyper-permeability and promotes the secretion of active growth factors and cytokines necessary for wound repair (Corral *et al.,* 1999). VEGF is expressed in macrophages and in keratinocytes migrating to cover a wound defect (Brown *et al.,* 1992), with the keratinocytes in the basal and suprabasal layers expressing VEGF equally (Brown *et al.,* 1992) even when wound re-epithelialisation is complete. Senger and Van de Water (2000) stated that epidermal keratinocytes are the principal source of VEGF during wound healing. They further commented that during wound healing, the 'avascular epidermis regulates plasma protein extravasation and angiogenesis in the underlying dermis through a paracrine mechanism involving keratinocyte expression of VEGF'. The present study also confirms previous reports that VEGF expression in wound healing is greater in the epidermis than in the underlying dermis (Brown *et al.,* 1992; Kishimoto *et al.,* 2000; Senger and Van de Water, 2000). In the present study, VEGF expression was evident in the epidermis and scattered in the granulation tissue of the wound tissue of all three groups from day 2 to day 16. This expression, however, was stronger in the *B. frutescens*-treated wounds than in the *B. natalensis*-treated group. This is in keeping with the results of

WitsETD

created with nitroPDF professional
download the free trial online at nitropdf.com/professional

the histological study which showed greater vascularity of the *B. frutescens*-treated wounds than the untreated wounds, and to a lesser extent, the *B. natalensis*-treated wounds. In general, the expression of VEGF was stronger in the more superficial layers of the epidermis than in the stratum basale. A similar non-staining stratum basale in normal human skin was previously reported by several researchers (Viac *et al.,* 1997; Harada *et al.,* 2001). Viac *et al*. (1997) investigated the relationship between VEGF expression and keratinocyte proliferation and differentiation. They suggested that the expression of VEGF by suprabasal keratinocytes correlates VEGF production with keratinocyte differentiation. Their explanation for this was that the extracellular calcium concentration increases with keratinocyte differentiation and calcium modulates VEGF production and secretion by keratinocytes.

WitsETD

An increase in vascularity of the granulation tissue was noted in the histological analysis of the present study, in both groups of treated wounds compared to the untreated wounds. Although not quantified, more vessels were noted in the *B. frutescens*-treated wounds than in the *B. natalensis*-treated wounds on day 4. On day 10 post-wounding, the vascularity of all three groups appeared to be similar, while on day 16 both treatment groups displayed a more dense collagen network with interspersed capillaries in the wound area. Localisation with αSMA confirmed larger vessel formation in the wound area of both treated groups. The formation of new blood capillaries is essential to provide nutrients and oxygen to the granulation tissue (Tsirogianni *et al.,* 2006). During this process, endothelial cells proliferate and migrate through the ECM to form capillary buds. The main stimuli for endothelial proliferation are the increase in aFGF (now known as FGF-1) by macrophages and

created with nitroPDF professional
download the free trial online at nitropdf.com/professional

damaged endothelial cells and the production of VEGF by keratinocytes and macrophages.

Humans have always been faced with the dilemma of how to treat wounds (MacKay and Miller, 2003). Many diverse and interesting approaches have been applied throughout medical history. Although scientific proof was lacking, some wound care therapies applied by 'adventurous' physicians are still considered valuable today e.g. honey and sugar paste were used for scarless healing and *Symphytum officinalis* (comfrey) was initially applied externally to the skin to heal fractures (MacKay and Miller, 2003). As recent as 2000, Aljady *et al*. (2000) demonstrated a significant increase in DNA and collagen content in male rats treated with honey. They also showed an increase in wound contraction on days 4, 8 and 12 post-wounding and concluded that treatment with honey increased cell proliferation in early granulation tissues.

WitsETD

Similarly, *Centella asiatica* and *Aloe vera* have been used for decades as folk remedies for burns, wounds and scars (Subramanian *et al.,* 2006). *Centella asiatica* has been documented to aid wound healing primarily by stimulating collagen type 1, production thus significantly increasing the breaking strength of treated wounds (MacKay and Miller, 2003). Topical administration of *Aloe vera* to wounds of both diabetic and non-diabetic rats has demonstrated improved healing (Davis *et al.,* 1988). It is postulated that the benefit in wound healing is due to an increased collagen content of the granulation tissue as well as the degree of cross linkage of the collagen fibres. This increase in collagen content may be due to an increase in

created with nitroPDF professional
download the free trial online at nitropdf.com/professional

collagen synthesis or in fibroblast proliferation or both (MacKay and Miller, 2003). In spite of their wide use, the biochemical basis for action or influence in wound healing of *Centella asiatica* and *Aloe vera* is just beginning to be understood (MacKay and Miller, 2003). The mechanism by which *B. natalensis* and *B. frutescens* promote wound healing appears to be similar to that of *Aloe vera* and *Centella asiatica* in that they increases fibroblast and keratinocyte proliferation and collagen deposition. It would be interesting to investigate if this effect differs with variable modes of administration (eg. topical *vs* oral administration). Moreover, as with *Aloe vera* and *Centella asiatica*, extensive well-defined, blinded clinical trials to assess the safety, efficacy and potential active ingredients of these two plants in wound healing needs to be carried out before these can be administered in mainstream medicine. It is, however, difficult to assess the administration of these indigenous plants clinically, as it is difficult to get patients to comply in a study of this kind. The human study which was initially planned as part of the present study had to be discontinued due to difficulties in obtaining suitable patients and also due to poor patient compliance. It was surprising that many of the people of African descent (the population group that uses these plants as a traditional medicine) refused to participate in the present study and preferred to use established 'western' medication. Six patients consented to participate in the present study but none of them returned to the clinics for evaluation after using the leaf extracts.

The present study demonstrated that the fresh leaf gels of *B. frutescens* and *B. natalensis* have a beneficial effect on several phases of wound healing such as keratinocyte and fibroblast proliferation, collagen synthesis, angiogenesis and wound

WitsETD

created with nitroPDF professional
download the free trial online at nitropdf.com/professional

contraction resulting in faster healing than in the untreated wounds. The mechanism by which these leaf gels bring about these effects is however unclear. Future studies screening the water soluble fractions of the leaf gels using chromatography, ultraviolet and infrared spectrophotometery may elucidate the chemical components of the leaf gels active in wound healing. *Aloe vera* has also been shown to heal wounds faster when used as a crude gel. Chithra *et al.* (1998a; 1998b) claims that this is due to the polysaccharides found in the gel. It may be important to evaluate the component of the leaf gel that is effective in wound healing so that treatment and therapeutic agents are developed more effectively. Van Wyk *et al.* (2000) speculate that since *Bulbine* belongs to the same family as *Aloe vera,* that its healing effect is more likely to be due to glycoproteins (such as Aloctin A and Aloctin B) which have been found in the leaf gel of *Aloe vera,* a plant internationally recognised for its healing properties. These glycoproteins have not yet been identified in *Bulbine.* Additionally, since the first reported treated data on *Aloe vera* in the 1930s, there is still much doubt as to its active ingredient(s) and their biological effects (Reynolds and Dweck, 1999). This is further complicated by the contradictory results reported from research on *Aloe vera* (Reynolds and Dweck, 1999). Davis *et al.* (1987) demonstrated anti-inflammatory properties following topical application of the *Aloe* gel on skin punch biopsies. Later, in 1989, the same researchers demonstrated improved healing following systemic administration of the *Aloe vera*. In contrast, Schmidt and Greenspoon (1991) reported delayed healing in dermal wounds treated with *Aloe vera* gel. Reynolds and Dweck (1999) in a review of research on *Aloe vera* indicated that amidst all this controversy, a clearer picture of its biological activity is slowly beginning to emerge. They ascribe the delay in

WitsETD

created with nitroPDF professional
download the free trial online at nitropdf.com/professional

isolating the active ingredients and the conflicting published results to the conundrum of wound healing in that it involves a number of interacting factors.

Although the stem and root of *Bulbine* are known to contain anthraquinones such as chrysophanol (which has anti-bacterial properties) and knipholone (Dagne and Yenesew, 1994), these are thought to be of minor importance in wound healing. Widgerow and Chait (2000) describe the use of a microporous tape treated with both *B. frutescens* and *Centella asiatica*. They claim that the *B. frutescens* increases hydration by 'leaving a layer of fatty vesicles of glycoprotein on the skin surface which also has anti-bacterial properties'. This claim was previously purported by Briggs (1995). While this may be so *in vivo*, it does not account for the significant increase in cell numbers seen *in vitro* in the present study. Both the *in vitro* and *in vivo* results of this study indicate that both leaf gels stimulate fibroblast and keratinocyte proliferation and collagen deposition. Widgerow and Chait (2000) reported improved wound healing in 90% of patients using the microporous tape containing the combination of *B. frutescens* and *Centella asiatica*. They claim that the major component responsible for healing is the *Centella asiatica* and that *B. frutescens* is responsible for the hydration of the wound. A similar reason for the efficacy of *Aloe vera* in wound healing is proposed by Meadows (1980), Fox (1990), Marshall (1990) and Briggs (1995). Sudworth (1997) however showed that *Aloe vera* was as effective in treating oral wounds that were always moist. This study proposes that the leaf gel of both *B. natalensis* and *B. frutescens* plants contain active ingredients (yet to be isolated) that impacts keratinocyte and fibroblast proliferation and collagen deposition which could be the major contributor to increased ECM deposition and

WitsETD

created with nitroPDF professional
download the free trial online at nitropdf.com/professional

wound healing. In addition, both leaf gels increase wound contraction by increasing the differentiation of myofibroblasts.

Ethnopharmacology investigates the 'pharmacological basis of culturally important plants' (Gertsch, 2009). Reports of plants that are beneficial to wound healing abound in the literature. These reports however are inconsistent and often draw conclusions from *in vitro* studies alone that use inconsistent bioassays. In evaluating wound healing using exogenous agents (such as plant extracts) in *both in vitro* and *in vivo* models, there is a need to standardise the experiments in order to make comparisons between the different therapeutic agents more meaningful. Maenthaisong *et al.* (2007) in a systematic review of 1069 scientific articles of the efficacy of *Aloe vera* for the healing of burns found a lack of consistency in the amount of the active ingredient used, the age of the plants, the harvesting times and the extraction methods. They also concluded that the outcome of interest (complete epithelialisation) was very subjective and suggested that studies evaluating histological changes in wound healing needed multiple assessors and standard controls to be accepted. The need to standardise the protocol used to evaluate the potential pharmacological application of natural products has previously been acknowledged by the Editorial Board of the Journal of Ethnopharmacology (Verpoorte, 2006) and has most recently been highlighted by Gertsch (2009) who also stated that 'few claims from *in vitro* observations stand the test *in vivo*'. In the present study, the *in vitro* 'wound healing' effect of the *Bulbine* leaf gels were subjected to *in vivo* confirmation using the pig animal model as porcine skin has the closest histological structure to human skin.

WiSETD

created with nitroPDF professional
download the free trial online at nitropdf.com/professional

Naturally derived compounds are purported to be the most relevant compounds for future drug discovery, yet the biological activity of much of the world's biodiversity remains scientifically untested (Harvey, 2000; Harvey, 2008). This is particularly true for much of the flora of South Africa. Despite the anecdotal evidence of the use of *B. frutescens* as a traditional wound healing agent and more recently its appearance in a variety of 'healing' lotions and creams, the previous literature does not present scientific data supporting the wound healing capabilities of either *B. frutescens* or *B. natalensis*. In rural communities in South Africa, skin lesions arising from bruises, cuts and scratches amongst others are sometimes untreated at the initial stages especially in children (Grierson and Afolayan, 1999). In most cases such wounds become infected and septic. Primary health care in these situations is often sought from traditional healers and herbalists. The validation of herbal remedies is therefore essential and in addition to preserving the indigenous heritage, has an enormous beneficial value to these communities. This study is the first to scientifically evaluate the effects of *B. frutescens* and *B. natalensis* in wound healing using both *in vitro* and *in vivo* experiments.

WitsETD

created with nitroPDF professional
download the free trial online at nitropdf.com/professional

5. CONCLUSION

Wound healing is a complex process involving the interaction of many cytokines and growth factors. The present study has demonstrated the ability of *B. natalensis* and *B. frutescens* to facilitate the process of wound healing. This is achieved by decreasing the time taken for complete re-epithelialisation and wound contraction. The present study further demonstrated, by histological analysis of the *Bulbine*- treated and the untreated wound sections, to increase fibroblast and keratinocyte proliferation and migration, increase ECM and collagen deposition and to promote collagen remodelling. Biochemical analysis of the wound tissue confirmed increased total collagen, protein and DNA in the treated wound tissue when compared to the corresponding untreated wound tissue. The increase of these biochemical molecules have resulted in increased tensile strength of the treated wounds when compared to the untreated wounds. Both *B. natalensis* and *B. frutescens* appear to act in a similar manner. The active ingredients of these plants that effect wound healing are not known as yet. This present study further highlighted the need for a 'gold' standard to assess wound healing activity of endogenous agents.

The present study is the first comprehensive study of the *in vitro* and *in vivo* effects of *B. natalensis* and *B. frutescens* on wound healing. The results of this study validate the traditional use of these plants to treat skin ailments and may have an impact primary on health care especially in rural communities.

WitsETD

created with nitroPDF professional
download the free trial online at nitropdf.com/professional

6. REFERENCES

1. Abdullah K.M., Abdullah A., Johnson M.L., Bilski J.J., Petry K., Redmer D.A., Relnolds L. and Grazul-Bilska A.T. (2003) Effect of *Aloe vera* on gap junction intercellular communication and proliferation of human diabetic and nondiabetic skin fibroblasts. *Journal of Alternative and Complementary Medicine*. **9**: 711-718.

2. Abegaz B.M., Bezabih M., Msuta T., Brun R., Menche D., Mühlbacher J. and Bringmann G. (2002) Gaboroquinones A and B and 4'-O-demethylknipholone-4'-O-ß-D-glucopyranoside, phenylanthraquinones from the roots of *Bulbine frutescens. Journal of Natural Products* **65(8)**: 1117-1121.

3. Aljady A.M., Kamaruddin M.Y., Jamal A.M. and Yassim M.Y. (2000) Biochemical study of the efficacy of Malaysian honey on inflicted wounds: An animal model. *Medical Journal of Islamic Academic Science* **13**: 125-132.

4. Bancroft, J. D. and Gamble, M. (2002) *Theory and practice of histological techniques.* 5th Edn, Churchill Livingstone Publishers, Edinburgh.

5. Bates D.O. and Pritchard-Jones R.O. (2003) The role of VEGF in wound healing. *International Journal of Lower Extremity Wounds*. 2(2): 107-120

6. Berthod F., Germain L., Li H., Xu W., Damour O. and Auger F.A. (2001) Collagen fibril network and elastic system remodelling in a reconstructed skin transplanted on nude mice. *Matrix Biology* **20**: 463–473

WitsETD

created with nitroPDF professional
download the free trial online at nitropdf.com/professional

7. Boukamp P., Petrussevska R.T., Breitkreutz D., Hornung J., Markham A. and Fusenig N.E. (1988) Normal keratinization in a spontaneously immortalized aneuploid human keratinocyte cell line. *The Journal of Cell Biology* **106**:761-771

8. Bourguignon G.J. and Bourguignon L.Y. (1987) Electric stimulation of protein and DNA synthesis in human fibroblasts. *FASEB Journal* **1**:398–402

9. Braiman-Wiksman L., Solomonik I., Spira R. and Tennenbaum T. (2007) Novel insights into wound healing sequence of events. *Toxicologic Pathology* **35:** 767-779.

10. Briggs C. (1995) Herbal medicine: Aloe. *Canadian Pharmacists Journal/Revue des Pharmaciens du Canada.* **128**:48-50.

11. Broadley K.N., Aquino A.M., Woodward S.C., Buckley-Sturrock A., Sato Y., Rifkin D.B. and Davidson J.M. (1989) Monospecific antibodies implicate basic fibroblast growth factor in normal wound repair. *Laboratory Investigations* **61**: 571–575.

12. Brodie, A.E., Manning, V.A., Ferguson, K.R., Jewel, D.E. and Yuan Hu, C. (1999) Conjugated linoleic acid inhibits differentiation of pre- and post-confluent 3T3-L1 preadipocytes but inhibits cell proliferation only in preconfluent cells. *Journal of Nutrition* **129**: 602-606.

13. Brown, G.L., Curtsinger, L.J. and White, M. (1988) Acceleration of tensile strength of incisions treated with EGF and TGF-β. *Annals of Surgery* **208:** 788-794.

WitsETD

created with nitroPDF professional
download the free trial online at nitropdf.com/professional

14. Brown, L.F., Yeo, K., Berse, T., Senger, D.R., Dvorak, H.F. and Van De Water, L. (1992) Expression of vascular permeability factor (vascular endothelial growth factor) by epidermal keratinocytes during wound healing. *Journal of Experimental Medicine* **176:** 1375-1379.

15. Cheifetz, S., Andreas, J.L. and Massague, J. (1988) The transforming growth factor-beta receptor type III is a membrane proteoglycan. *Journal of Biological Chemistry* **263 (32)**: 16984-16991.

16. Chithra P., Sajithlal G.B. and Chandrakasan G. (1998a) Influence of *Aloe vera* on the healing of dermal wounds in diabetic rats. *Journal of Ethnopharmacology* **59(3)**:195-201.

17. Chithra P., Sajithlal, G.B. and Chandrakasan, G. (1998b) Influence of *Aloe vera* on the glycosaminoglycans in the matrix of healing dermal wounds in rats. *Journal of Ethnopharmacology* **59(3)**: 179–186

18. Cho Lee A.R. and Moon H. (2003). Effect of topically applied silver sulfadiazine on fibroblast cell proliferation and biomechanical properties of the wound. *Archives of Pharmaceutical Research* **26**: 855–860

19. Choi S., Son B.W., Son Y.S., Park Y-I., LeeS-K. and Chung M-H. (2001) The wound healing effect of a glycoprotein fraction isolated from *Aloe vera*. *British Journal of Dermatology.* **145(4)**: 535-545

20. Clark R.A.F. (1993) Biology of dermal wound repair. *Dermatology Clinics* **11**:647–666

WitsETD

created with nitroPDF professional
download the free trial online at nitropdf.com/professional

21. Corral C.J., Siddiqui A., Wu L., Farrell C.L., Lyons D. and Mustoe T.A. (1999) Vascular endothelial growth factor is more important than basic fibroblast growth factor during ischemic wound healing. *Archives of Surgery* **134**: 200–205

22. Dagne E. and Yenesew A. (1994) Anthraquinones and chemotaxonomy of the Asphodelaceae. *Pure* and *Applied Chemistry* **66**: 2395-2398

23. Davidson, J.M. (2001). Experimental animal wound models. *Wounds* **13(1)**: 9-23.

24. Davis R.H., Di Donato J.J., Hartman G.M. and Haas R.C. (1994) Anti-inflammatory & wound healing activity of a growth substance in Aloe vera. *Journal of the American Podiatric Medical Association* **84 (2)**: 77-81.

25. Davis R.H., Kabbani, J.M. and Maro, N.P., (1987) *Aloe vera* and wound healing. *Journal of the American Podiatric Medical Association* **77**:165–169

26. Desmouliere, A. (1995). Factors influencing myofibroblast differentiation during wound healing and fibrosis. *Cell Biology International* **19(5):** 471-476.

27. Dunphy J.E. and Udupa, K.N. (1955) Chemical and histochemical sequences in the normal healing of wounds. *New England Journal of Medicine* **253:** 847–851.

WitsETD

created with nitroPDF professional
download the free trial online at nitropdf.com/professional

28. Dyson, A. (1998) *Discovering indigenous healing plants of the herb and fragrance gardens at Kirstenbosch National Botanical Garden.* NBI, Cape Town

29. Elçin, Y.M., Dixit, V. and Gitnick, G. (2001) Extensive *in vivo* angiogenesis following controlled release of human vascular endothelial cell growth factor: implications for tissue engineering and wound healing. *Artificial organs* **25 (7)**: 558-565

30. Eloff J.N. (1998) A sensitive and quick microplate method to determine the minimal inhibitory concentration of plant extracts for bacteria *Plant Medica* **64**: 711–713.

31. Folkman J. and Klagsbrun M. (1987) Angiogenic factors. *Science* **235** (4787): 442-447

32. Fox, T. R. (1990) *Aloe vera*: Revered, mysterious healer. *Health Foods Business*, 45-46.

33. Frank S., Hübner G., Breuer G., Longaker M.T., Greenhalgh D.G and Werner S. (1995) Regulation of VEGF expression in cultured keratinocytes: implications for normal and impaired wound healing. *Journal of Biological Chemistry.* **270**: 12601-12613

34. Frank S., Madlener M. and Werner S. (1996) Transforming growth factors-beta1, -beta2 and -beta3 and their receptors are differentially regulated during normal and impaired wound healing. *Journal of Biological Chemistry.* **271**: 10188-10193

WitsETD

created with nitroPDF professional
download the free trial online at nitropdf.com/professional

35. Gailit J., Welch M.P. and Clark R.A.F. (1994). TGF-beta 1 stimulates expression of keratinocyte integrins during re-epithelialization of cutaneous wounds. *Journal of Investigative Dermatology* **103**: 221–227

36. Gale, N.W. and Yancopoulos, G.D. (1999) Growth factors acting via endothelial cell-specific receptor tyrosine kinases: VEGFs, angiopoietins, and ephrins in vascular development. *Genes and Development* **13,** 1055-1066

37. Gertsch J. (2009) How scientific is the science in ethnopharmacology? Historical perspectives and epistemological problems *Journal of Ethnopharmacology* **122 (**2):177-183

38. Ghiglieri C., Khatchadourian C., Tabone E., Hendrick J.C., Benahmed M. and Ménézo Y. (1995) Ovary: Immunolocalization of transforming growth factor-β_1 and transforming growth factor-β_2 in the mouse ovary during gonadotrophin-induced follicular maturation. *Human Reproduction* **10 (8)**: 2115-2119

39. Gold L.I., Sung J.J., Siebert J.W. and Longaker M.T. (1997) Type I (RI) and type II (RII) receptors for transforming growth factor-β isoforms are expressed subsequent to transforming growth factor-β ligands during excisional wound repair. *American Journal of Pathology* **150**: 209–222

40. Goliger J.A. and Paul D.L. (1994) Expression of gap junction proteins Cx26, Cx31.1, Cx37, and Cx43 in developing and mature rat epidermis. *Developmental Dynamics* **200 (1)**:1-13

WitsETD

created with nitroPDF professional
download the free trial online at nitropdf.com/professional

41. Gonçalves W.L.S., Souza F.M., Conti C.L., Cirqueira J.P., Rocha W.A., Pires J.G.P., Barros L.A.P. and Moysés M.R. (2007) Influence of He-Ne laser therapy on the dynamics of wound healing in mice treated with anti-inflammatory drugs *Brazilian Journal of Medical and Biological Research.* **40**: 877-884

42. Grierson D.S. and Afolayan A.J. (1999) Antibacterial activity of some indigenous plants used for the treatment of wounds in the Eastern Cape, South Africa. *Journal of Ethnopharmacology* **66:**103–106

43. Hakvoort T.E., Altun V., van Zuijlen V.P.P., de Boer W.I., van Schadewij W.A.A.M. and van der Kwast T.H. (2000) Transforming growth factor-beta1, -beta2, -beta3, basic fibroblast growth factor and vascular endothelial growth factor expression in keratinocytes of burn scars. *European Cytokine Network*. **11**(2): 233-239

44. Harada Y., Ogata Y., Shirouzu K. (2001) Expression of vascular endothelial growth factor and its receptor KDR (kinase domain-containing receptor)/Flk-1 (fetal liver kinase-1) as prognostic factors in human colorectal cancer. *International Journal of Clinical Oncology* **6**: 221–228

45. Hartree E.F. (1972) Determination of protein: A modification of the Lowry method that gives a linear photometric response. *Analytical Biochemistry* **48** (2):422-427

46. Harvey, A.L. (2001) *Natural Product Pharmaceuticals: A Diverse Approach to Drug Discovery*, Scrip Reports, PJB Publications, Surrey, UK

WitsETD

created with nitroPDF professional
download the free trial online at nitropdf.com/professional

47. Harvey A.L. (2008) Natural products in drug discovery. *Drug Discovery* **13 (20)**: 894-901

48. Heinrich W., Lange P.M., Stirz T., Iancu C. and Heidermann E. (1971) Isolation and characterization of the large cyanogen bromide peptides from α1 and α2 chains in pig skin collagen. *FEBS Letters* **16 (1)**: 63–67

49. Hein T.V., Hughes M.A. and Cherry G.W.C. (1997) In vitro studies on the antioxidant and growth stimulatory activities of a polyphenolic extract from *Cudrania conchinchinensis* used in the treatment of wounds in Vietnam. Wound Repair and Regeneration **5**: 159-167

50. Hong H., Chen F., Chen Z., Zhu Y. and Wang Y. (2001) Simultaneous measurement of VSMCs metabolic activity and proliferation with WST-1 and cell proliferation ELISA (BrdU). *Biochemica* **3**:24-25

51. Hutchings, A., Scott A.H., Lewis G. and Cunningham A. (1996) *Zulu medicinal plants: an inventory.* University of Natal Press, Pietermaritzburg, South Africa

52. Joffe, P. (1993) *The gardener's guide to South African plants*. Tafelberg Publishers, Cape Town, South Africa

53. Junqueira L. and Carneiro J. (2005) *Basic Histology: text and atlas*. 11th Edn., McGraw-Hill Medical.

WiSETD

created with nitroPDF professional
download the free trial online at nitropdf.com/professional

54. Kapoor, M., Nomiyama, T., Bruemmer, D., Kojima, F. and Crofford, L.J. (2006) Growth factors and cytokines: Emphasis on their role in wound healing and atherosclerosis. *Current Anaesthesia and Critical Care* **17:** 13-20

55. Khalil E.A., Afifi F.U. and Al-Hussaini M. (2007) Evaluation of the wound healing effect of some Jordanian traditional medicinal plants formulated in Pluronic F127 using mice (*Mus musculus*). *Journal of Ethnopharmacology* **109 (1):**104-112

56. Kishimoto J., Ehama R., Ge Y., Kobayashi T., Nishiyama T., Detmar M. and Burgeson R.E. (2000) *In vivo* detection of human vascular endothelial growth factor promoter activity in transgenic mouse skin. *American Journal of Pathology* **157**:103-110

57. Kloth, L.C. and McCulloch, J.M. (2002). *Wound Healing, Alternatives in Management,* 3rd Edn., F. A. Davis Company, Philadelphia

58. Kwon Y.B., Kim C.D., Youm J-K., Gwak H.S., Park B.D., Lee S.H., Jeon S., Kim J., Seo H.S., Park J-K. and Lee J.H. (2007) Novel synthetic ceramide derivatives increase intracellular calcium levels and promote epidermal keratinocyte differentiation. *Journal of Lipid Research* **48**:1936-1943

59. Lauer G., Sollberg S., Cole M., Flamme I., Stürzebecher J., Mann K., Krieg T., Eming S.A. (2000) Expression and proteolysis of VEGF is increased in chronic wounds. *Journal of Investigative Dermatology* **115**: 12–18

WitSETD

created with nitroPDF professional
download the free trial online at nitropdf.com/professional

60. Leitch, I.O.W., Kucukcelebi A. and Robson, M.C. (1993) Inhibition of wound contraction by topical antimicrobials. *Australian and New Zealand Journal of Surgery* **63***:* 289-293.

61. Levvy G.A. and McAllan A. (1959) The N-acetylation and estimation of hexosamine. *Journal of Biochemistry* **73**: 127-132

62. Li, J., Chen, J. and Kirsner, R. (2007) Pathophysiology of acute wound healing. *Clinics in Dermatology* **25:** 9-18.

63. Liang, C., Park, A.Y. and Guan, J. (2007) *In vitro* scratch assay: a convenient and inexpensive method for analysis of cell migration *in vitro*. *Nature Protocols* **2(2):** 329-333.

64. Lin L.I-K. (1989) A concordance correlation coefficient to evaluate reproducibility. *Biometrics* **45 (1):** 255–268.

65. Lin Z-Q., Kondo T.,Ishida Y.,Takayasu T. and Mukaida N. (2003) Essential involvement of IL-6 in the skin wound-healing process as evidenced by delayed wound healing. *Journal of Leukocyte Biology* **73**:713-721

66. Lynch M. A., Nakashima R., Song H., DeGroff V. L., Wang D., Enomoto T. and Weghorst C. M. (1998) Mutational analysis of the transforming growth factor β receptor type II gene in human ovarian carcinoma. *Cancer Research.* **58**: 4227–4232

67. MacKay, D. and Miller, A.L. (2003) Nutritional Support for Wound Healing. *Wound Healing* **8(4):** 359-377

WitsETD

created with nitroPDF professional
download the free trial online at nitropdf.com/professional

68. Madri J.A., Sankar S. and Romanic A.M. (1996) '*Angiogenesis*' in Clark R. A. F. (ed), *The Molecular and Cellular Biology of Wound Repair*, 2nd Edn., Plenum

69. Maenthaisong R., Chaiyakunapruk N., Niruntraporn S. and Kongkaew C. (2007) The efficacy of *Aloe vera* used for burn wound healing: A systematic review. *Burns* **33 (6)**:713-718

70. Makunga, N.P., Philander, L.E. and Smith, M. (2008) Current perspectives on an emerging formal natural products sector in South Africa. *Journal of Ethnopharmacology* **119:** 365-375

71. Mantle D., Gok M.A., Lennard T.W. (2001). Adverse and beneficial effects of plant extracts on skin and skin disorders. *Adverse Drug Reaction Toxicology Review* **20(2)**:89-103

72. Marks J.G. and Miller J. (2006) Lookingbill and Marks principles of dermatology, 4th Edn., Elsevier.

73. Marshall, J.M. (1990) *Aloe vera* gel: what is the evidence? *Pharmaceutical Journal* **24**, 360-362.

74. Massagué J. (1990) The transforming growth factor-β family. *Annual Review of Cell Biology* **6:** 597–641

75. Meadows, T.P. (1980) Aloe as a humectant in new skin preparations. *Cosmetic Toiletries* **95**, 51–56.

WitsETD

created with nitroPDF professional
download the free trial online at nitropdf.com/professional

76. Mirastschijski, Haaksma C.J., Tomasek J.J. and Agren M.S. (2004) Matrix metalloproteinase inhibitor GM 6001 attenuates keratinocyte migration, contraction and myofibroblast formation in skin wounds. *Experimental Cell Research* **299**: 465–475

77. Montagna, W. and Yun, J.S. (1964) The skin of the domestic pig. *Journal of Investigative Dermatology* **43:** 11.

78. Mossman, T. (1983) Rapid colorimetric assay for cellular growth and survival: application to proliferation and cytotoxicity assays. *Journal of Immunological Methods* **65:**55-63.

79. Moulin, V., Auger, F.A., Garrel, D. and Germain, l. (2000) Role of wound healing myofibroblasts on re-epithelialization of human skin. *Burns* **26:** 3-12

80. Moulin, V., Tam, B.Y., Castilloux, G., Auger, F.A., O'Connor, M.C., Court, M.D., Phillip, A. and Germain, L. (2001) Foetal and adult human skin fibroblasts display intrinsic differences in contractile capacity. *Journal of Cell Physiology* **188(2):** 211-222

81. Mowafy, M., Cassens, R.G. (1975) Microscopic structure of pig skin. *Journal of Animal Science* **41 (5):** 1281-1290

82. Munir, S., Xu, G., Wu, Y., Yang, B., Lala, P.K. and Peng, C., (2004) Nodal and ALK7 inhibit proliferation and induce apoptosis in human trophoblast cells. *Journal of Biological Chemistry* **279 (30):** 31277-31286

WitsETD

created with nitroPDF professional
download the free trial online at nitropdf.com/professional

83. Murphy W.K, Fossella F.V., Winn R.J., Shin D., Hynes H.E., Gross H.M., Davilla E., Leimert J., Dhingra H., Raber M.N., Krakoff I.H. and Hong W,K. (1993). Phase II study of *Taxol* in patients with untreated advanced non-small-cell lung cancer. *Journal of the National Cancer Institute.* **85**(5):384-388

84. Nissen N.N., Polverini P.J., Koch A.E., Volin M.V., Gamelli R.L. and Dipietro L.A. (1998) Vascular endothelial growth factor mediates angiogenic activity during the proliferative phase of wound healing. *American Journal of Pathology* **152**: 1445–1452

85. O'Kane S. and Ferguson M.W. (1997) Transforming growth factor beta and wound healing. *International Journal of Biochemistry and Cell Biology.* **29(1)**:63–78

86. Öztürk N., Korkmaz S. and Öztürk Y. (2007) Wound-healing activity of St. John's Wort (Hypericum perforatum L.) on chicken embryonic fibroblasts. *Journal of Ethnopharmacology* **111(1)**: 33-39

87. Parks W.C. (1999). Matrix metalloproteinases in repair. *Wound Repair and Regeneration* **7**:423–432

88. Paul R.G., Tarlton J.F., Purslow P.P., Sims T.J., Watkins P., Marshall F., Ferguson M.J. and Bailey A.J. (1997) Biomechanical and biochemical study of a standardized wound healing model. *The International Journal of Biochemistry & Cell Biology* **29 (1)**:211-220

89. Phan T-T., Allen J., Hughes M.A., Cherry G.W.C. and Wojnarowska F. (2000) Upregulation of adhesion complex proteins and fibronectin by human

WiSETD

created with nitroPDF professional
download the free trial online at nitropdf.com/professional

keratinocytes treated with an aqueous extract from the leaves of *Chromolaena odorata* (Eopolin). *European Journal of Dermatology* **10 (7):** 522-527.

90. Phan T-T., Wang L., See P., Grayer R.J., Chan S-Y. and Lee S.T. (2001) Phenolic compounds of *Chromolaena odorata* protect cultured skin cells from oxidative damage: implication for cutaneous wound healing. *Biological and Pharmaceutical Bulletin* **24**: 1373-1379.

91. Rabe, T. and van Staden, J. (1997) Antibacterial activity of South African plants used for medicinal purposes. *Journal of Ethnopharmacology* **56:** 81-87.

92. Raghow, R. (1994) The role of extracellular matrix on post-inflammatory wound healing and fibrosis. *FASEB Journal* **8**: 823-831.

93. Rasik A. M., Raghubir R., Gupta A., Shukla A., Dubey M.P., Srivastava S., Jain H.K. and Kulshreshtha D.K. (1999). Healing potential of *Calotropis procera* on dermal wounds in Guinea pigs. *Journal of Ethnopharmacology* **68**:261-266

94. Rates S.M.K. (2001). Plants as source of drugs. *Toxicon* **39:** 603–613

95. Reddy, G.K., Enwemeka, C.S. (1996). A simplified method for the analysis of hydroxyproline in biological tissues. *Clinical Biochemistry* **29(3):** 225-229

96. Reynolds, T. and Dweck, A.C. (1999) *Aloe vera* leaf gel: a review update. *Journal of Ethnopharmacology* **68:** 3-37

WitsETD

created with nitroPDF professional
download the free trial online at nitropdf.com/professional

97. Rheinwald J.G. and Green H. (1975) Serial cultivation of strain of human epidermal keratinocytes: the formation of keratinizing colonies from single cells. *Cell* **6:** 331-344.

98. Rondle C. J. M. and Morgan W. T. J. (1955) Determination of glucosamine and galactosamine. *Journal of Biochemistry* **61**: 586-589

99. Rosenberg L. and de la Torre J. (2003) Wound healing growth factors. Emedicine.com. Retrieved 11 March 2005 from http://www.emedicine.com/plastic/topic457.htm

100. Ross M.H. and Pawlina W. (2005) *Histology: A text and atlas with correlated cell and molecular biology.* 5th Edn., Lippincott Williams and Wilkins

101. Schildmeyer, L. A., Braun, R., Taffet, G., Debiasi, M., Burns, A. E., Bradley, A. and Schwartz, R. J. (2000) Impaired vascular contractility and blood pressure homeostasis in the smooth muscle alpha-actin null mouse. *FASEB Journal* **14**, 2213-2220

102. Schmid P., Itin P., Cherry G., Bi C. and Cox D.A. (1998) Enhanced expression of transforming growth factor-ß type I and type II receptors in wound granulation tissue and hypertrophic scar. *American Journal of Pathology* **152**:485-493

103. Schmidt J.M. and Greenspoon J.S. (1991) *Aloe vera* dermal wound gel is associated with a delay in wound healing. *Obstetrics and Gynecology.* **78(1):**115-117

WiseTD

created with nitroPDF professional
download the free trial online at nitropdf.com/professional

104. Senger D.R. and Van De Water L. (2000) VEGF Expression by epithelial and stromal cell compartments. *American Journal of Pathology* **157**:1-3

105. Shukla A., Rasik A.M., Jain G.K., Shankar R., Kulshrestha D.K. and Dhawan B.N. (1999) *In vitro* and *in vivo* wound healing activity of asiaticoside isolated from *Centella asiatica*. *Journal of Ethnopharmacology* **65** :1–11

106. Singer, A.J. and Clark, R.A. (1999). Cutaneous wound healing. *New England Journal of Medicine* **341(10):** 738-46

107. Slavin, J. (1996) The role of cytokines in wound healing. *Journal of Pathology* **178:** 5-10

108. Subramanian S., Kumar D.S. and Arulselvan P. (2006) Wound healing potential of *Aloe vera* leaf gel studied in experimental rats. *Asian Journal of Biochemistry.* **1(2):**178-185

109. Sudworth R., (1997). The use of *Aloe vera* in dentistry. *Positive Health*, 49.

110. Sullivan, K.M., Lorenz H.P., Meuli, M., Lin, R.Y. and Adzick, N.S. (1995) A model of scarless human fetal wound repair is deficient in transforming growth factor beta . *Journal of Paediatric Surgery* **30**: 198-203

111. Sullivan, T. P., Eaglestein, W. H., Davis, S. C., and Mertz, P. (2001) The pig as a model for human wound healing. *Wound Repair and Regeneration* **9**, 66–76

112. Switzer, B.R. (1991) Determination of hydroxyproline in tissue. *Journal of Nutritional Biochemistry* **2**: 229–321

WitsETD

created with nitroPDF professional
download the free trial online at nitropdf.com/professional

113. Tan A.S. and Berridge M.V. (2000) Superoxide produced by activated neutrophils efficiently reduces the tetrazolium salt, WST-1 to produce a soluble formazan: a simple colorimetric assay for measuring respiratory burst activation and for screening anti-inflammatory agents. *Journal of Immunological Methods* **238**:59-68

114. Teicher B.A. (2008) Newer cytotoxic agents: attacking cancer broadly. *Clinical Cancer Research* **14**: 1610-1617

115. Thang P.T., Patrick S., Teik L.S. and Yung C.S. (2001) Anti-oxidant effects of the extracts from the leaves of *Chromolaena odorata* on human dermal fibroblasts and epidermal keratinocytes against hydrogen peroxide and hypoxanthine-xanthine oxidase induced damage. *Burns* **27(4):**319-327

116. Tizard I.R., Carpenter R.H., McAnalley B.H. and Kemp M.C., (1989) The biological activates of mannans and related complex carbohydrates. *Molecular Biotherapy* **1**:290-296

117. Tonnesen, M.G., Feng, X. and Clark, R.A.F. (2000). Angiogenesis in wound healing. *Journal of Investigative Dermatology symposium proceedings* **5 (1)**: 40-46.

118. Tsirogianni A.K., Moutsopoulos N.M. and Moutsopoulos H.M. (2006) Wound healing: immunological aspects. *Injury* **37**(1):S5–S12

119. Van Staden L.F. and Drewes S.E. (1994) Knipholone from *Bulbine latifolia* and *Bulbine frutescens*. *Phytochemistry* **35**(3): 685-686

WitsETD

created with nitroPDF professional
download the free trial online at nitropdf.com/professional

120. Van Wyk B-E., Yenesew A. and Dagne, E. (1995) Chemotaxonomic significance of anthraquinones in the roots of *Asphodeloideae* (*Asphodelaceae*). *Biochemical Systematics and Ecology* **23(3)**: 277-281

121. Van Wyk B.-E. and Gericke N. (2000) *People's plants: a guide to useful plants of Southern Africa*. Briza Publications, Pretoria, South Africa

122. Van Wyke B-E., Van Oudsthoorn B. and Gericke N. (2002) *Medicinal plants of South Africa.* 2nd edition, Pretoria, Briza Publications, South Africa

123. Vardaxis, N.J., Brans, T.A., Boon, M.E., Kreis, R.W. and Marres, L.M. (1997) Confocal laser scanning microscopy of porcine skin: implications for human wound healing studies. *Journal of Anatomy* **190**: 601-611

124. Verpoorte R. (2006) Setting standards! *Journal of Ethnopharmacology.* **106**: 289

125. Viac J., Palacio S., Schmitt D. and Claudy A. (1997) Expression of vascular endothelial growth factor in normal epidermis, epithelial tumors and cultured keratinocytes. *Archives of Dermatology Research* **289**: 158–163

126. Werner S. and Grose R. (2003) Regulation of wound healing by growth factors and cytokines. *Physiology Review* **83**:835–870

127. Werner S. and Smola H. (2001) Paracrine regulation of keratinocyte proliferation and differentiation. *Trends in Cell Biology.* **11(4)**: 143-146

128. Widgerow A.D. and Chait L.A. (2000). New innovations in scar management. *Aesthetic Plastic Surgery*. **24(3)**:227-34

WitsETD

created with nitroPDF professional
download the free trial online at nitropdf.com/professional

129. Winter, G.D. (1972) 'Epidermal regeneration in domestic pig.' *In* Maibach H. and Rovee D.T. (eds.). *Epidermal Wound Healing*, 3rd Edn., Medical Publishers Inc., Chicago. 71-112

130. Woessner, J.F. (1961) The determination of hydroxyproline in tissue and protein samples. *Archives of Biochemistry and Biophysiology* **93:** 440-447

131. Wollina U., Berger U. and Mahrle G. (1991) Immunohistochemistry of porcine skin. *Acta Histochemica* **90**: 87–91

132. World Health Organisation Report (2002) *Traditional medicine strategy 2002–2005*. World Health Organisation.

133. Yang Y., Gil M., Byun S.M., Choi I., Pyun K.H. and Ha H. (1996) Transforming growth factor-β1 inhibits human keratinocyte proliferation by upregulation of a receptor-type tyrosine phosphatase R-PTP-κ gene expression. *Biochemical and Biophysical Research Communications*. **228(3)**: 807-812

134. Zambruno G., Marchisio P.C., Marconi A., Vaschieri C., Melchiori A., Giannetti A. and De Luca M. (1995) Transforming growth factor-beta 1 modulates beta 1 and beta 5 integrin receptors and induces the *de novo* expression of the alpha v beta 6 heterodimer in normal human keratinocytes: implications for wound healing. *Journal of Cell Biology* **129**: 853–865

135. Zhu K.Q., Engrav L.H., Armendariz R., Muangman P., Klein M.B., Carroughe, G.J., Deubner H. and Gibran N.S. (2005) Changes in VEGF and nitric oxide after deep dermal injury in the female red duroc pig – further similarities

WitsETD

created with nitroPDF professional
download the free trial online at nitropdf.com/professional

between female duroc scar and human hypertrophic scar. *Burns* **31(1)**: 5-10

WitsETD

created with nitroPDF professional
download the free trial online at nitropdf.com/professional

APPENDICES

REAGENTS AND BUFFERS FOR TISSUE CULTURE (2.2)

A1. Phosphate buffered saline (PBS)	**pH 7.6**
$Na_2HPO_4.2H_2O$	3.5 g
NaCl	16 g
KCl	0.4g
KH_2PO_4	0.4g
Make up in 2L distilled water and pH to 7.6	

WitsETD

created with nitroPDF professional
download the free trial online at nitropdf.com/professional

2. REAGENTS AND BUFFERS FOR COLLAGEN ESTIMATION (2.3.2.3 a)

B1. Saline 0.9% solution	
1. Sodium chloride	0.9g
2. dH_20	100ml

Dissolve in dH_20

B2. Chloramine – T reagent – 0.056M	
1. Chloramine-T	0.32g
2. dH_20	5.2ml
3. n-propanol	6.5ml
4. Stock buffer (Appendix B2.1 above)	13.3ml

Solution is unstable

Make fresh each time it is needed

B 2.1. Acetate – citrate buffer pH 6.5 (stock buffer)	
1. Citric acid monohydrate	50g
2. Glacial acetic acid	12ml
3. Sodium acetate truhydrate	120g
4. Sodium hydroxide	34g

Dissolve in 1L dH_2O

pH solution to 6.5 and store at 4^0C in a dark bottle

Solution is stable for 2 months

WitsETD

created with nitroPDF professional
download the free trial online at nitropdf.com/professional

B3. p-dimethylamino-benzaldehyde (Ehrlich's reagent) – 1M	
1. Dimethylaminobenzaldehyde	3.73g
2. n-propanol	15ml
3. Perchloric acid	6.5ml
Bring to a volume of 25ml with dH_2O	
Make fresh each time it is needed	

Collagen assay buffer
1 part stock buffer to 10 parts dH_2O

WitsETD

created with nitroPDF professional
download the free trial online at nitropdf.com/professional

REAGENTS AND BUFFERS FOR HEXOSAMINE ESTIMATION (2.3.2.3 b)

C1. Potassium tetraborate 0.8M pH 9.1	
1. Borate (Boric Acid H_3BO_3)	61.1g
2. dH_2O	250ml

C2. Chloramine – T reagent – 0.056M	
1. Chloramine-T	0.32g
2. dH_20	5.2ml
3. n-propanol	6.5ml
4. Stock buffer (Appendix B2.1 above)	13.3ml
Solution is unstable	
Make fresh each time it is needed	

C2. p-dimethylamino-benzaldehyde (Ehrlich's reagent) – 1M	
1. Dimethylaminobenzaldehyde	3.73g
2. n-propanol	15ml
3. Perchloric acid	6.5ml
Bring to a volume of 25ml with dH_2O	
Make fresh each time it is needed	

C3. 0.1% N-acetylglucosamine	
1. N-acetylglucosamine	0.1g
2. dH_20	100ml

WitsETD

created with nitroPDF professional
download the free trial online at nitropdf.com/professional

REAGENTS AND BUFFERS FOR PROTEIN ESTIMATION (2.3.2.3c)

D1. Homogenising buffer

50mM Tris HCl (pH 7.5)

5mM acetate

0.2mM EDTA

10% glycerol

1% Triton X-100

Add 500µl of 0.5M DTT and 50µl of protease inhibitor to 10ml homogenizing extraction.

D2. Lowry protein assay

1.	Reagent A	2% sodium carbonate (Na_2CO_3) made up in 0.1M NaOH	20ml
		1% copper sulphate ($CuSO_4.5H_2O$)	200µl
		2% sodium potassium tartrate ($NaKC_4H_4O_{6.4}H_2O$)	200µl
2.	Folin Reagent	Folin reagent (diluted 1:4 in distilled H_2O	

Add 50µl of sample to an ELISA plate

Add 200µl of reagent A – incubate at room temperature on a shaker for 10 minutes

Then add 50µl of Reagent B – incubate at room temperature on a shaker for 30 minutes.

Read Absorbance at 690nm

WitsETD

created with nitroPDF professional
download the free trial online at nitropdf.com/professional

REAGENTS AND BUFFERS FOR DNA ESTIMATION (2.3.2.3d)

E1. Lysis buffer – pH 8	
1. 50mM TRIS	0.606g
2. 5mM EDTA	0.186g
3. 0.5% Tween 20 (Merck)	

Autoclave before use

E2. Proteinase K	**pH 8**
1. Proteinase K (Roche Boehringer Mannheim)	100mg

Dissolve in 2ml MilliQ H_20, aliquot into 50µl aliquots and store in the freezer.

To use:

Add 200µl MilliQ H_20.

Sodium acetate	**pH 5.2**
1. 3M sodium acetate (BD)	100mg

E3. Phenol chloroform

1 part *Tris* buffer saturated phenol (Sigma-Aldrich) to 1 part chloroform (Merck). Invert gently to mix and leave undisturbed to allow the phases to separate (± 2 days)

WitsETD

created with nitroPDF professional
download the free trial online at nitropdf.com/professional

REAGENTS AND BUFFERS FOR HISTOLOGY (2.3.2.4)

F1. Silane coated slides (Mutter, 1988)

1. Soak slides in 10% Contrad or Super 10 overnight
2. Rinse in hot running water – minimum – 2 hours
3. Dry in oven at 60°C
4. Dip in Acetone (optional)
5. Dip in 2% Silane in Acetone for 30 minutes (6ml Silane + 294ml Acetone)
6. Wash in two changes of acetone 1-2 dips
7. Wash briefly in distilled water
8. Dry in 42°C incubator overnight

10% Neutral buffered formalin

1.	Formalin	100ml
2.	Sodium dihydrogen phosphate	3.4g
3.	di-sodium hydrogen phosphate	6.5g
4.	Distilled water	900ml

WitsETD

created with nitroPDF professional
download the free trial online at nitropdf.com/professional

F2. Haematoxylin and Eosin stain

1.	Haematoxylin	Haematoxylin	4g
		Distilled H2O	1000ml
		Potassium alum	50g
		Citric acid	1.5g
		Chloral hydrate	75g
2.	Eosin	1% Eosin	500ml
		1% phloxine	250ml
		Distilled H_2O	750ml

- Dewax in two changes of Xylene
- Pass through graded alcohols
- Rinse in running water
- Stain in haematoxylin for 5 minutes
- Wash in tap water to 'blue' – check staining under a microscope
- If necessary, differentiate by dipping slides for 2-3 minutes in 1% acid alcohol
- Wash in running water for 5 minutes until nuclei are bright blue
- Counter stain in eosin for 30 seconds to 1 minute
- Wash briefly in running water
- Slides are passed through alcohol series and then into Xylene
- Mount with Entellan and coverslip

WitsETD

created with nitroPDF professional
download the free trial online at nitropdf.com/professional

REAGENTS AND BUFFERS FOR IMMUNOHISTOCHEMISTRY (2.3.2.5)

G1. Silane coated slides (Mutter, 1988)

1. Soak slides in 10% Contrad or Super 10 overnight
2. Rinse in hot running water – minimum – 2 hours
3. Dry in oven at 60°C
4. Dip in Acetone (optional)
5. Dip in 2% Silane in Acetone for 30 minutes (6ml Silane + 294ml Acetone)
6. Wash in two changes of acetone 1-2 dips
7. Wash briefly in distilled water
8. Dry in 42°C incubator overnight

G2. Phosphate buffered saline (PBS) 7.6 pH

$Na_2HPO_4.2H_2O$	3.5 g
NaCl	16 g
KCl	0.4g
KH_2PO_4	0.4g
Distilled water	2l
	pH to 7.6

WiSETD

created with nitroPDF professional
download the free trial online at nitropdf.com/professional

G3. BSA – PBS 7.6 Ph	
BSA	0.3 g
PBS	10 ml

G4. D.A.B.

Weight 1mg (0.001g) D.A.B. into new Bijou bottle

At start of second day of run put measuring cylinder containing 29ml distilled water into fridge at 4C

Just before use add 2ml Tris HCl pH 7.6 to D.A.B. in bijou bottle

Then add 1ml 30% Perhydrol to the now cold distilled water to make a 1% solution and mix well.

Add 20ul of the 1% perhydrol to the D.A.B. solution, mix on whirlimix

Filter before use

Pipette onto section timing each individually for 5 minutes

WitsETD

created with nitroPDF professional
download the free trial online at nitropdf.com/professional

G5. Citrate Buffer pH 6	
Solution A	0.1 M Citric acid 10.5 g Citric acid in 500ml distilled water
Solution B	0.1 M Sodium Citrate 29.4g Sodium Citrate in 1000ml distilled water
Mix 9ml of solution A and 41 ml of solution B Make up to 500 ml at distilled water	
Microwave slides in this solution for 2 x 5 minutes at high power Allow slides to cool for 20 minutes at room temperature	

G6. Tris buffered saline 7.6 pH	
Tris base	12.12 g
NaCl	17.54 g
Distilled water	2L pH to 7.6

WiSETD

created with nitroPDF professional
download the free trial online at nitropdf.com/professional

G7. Tris HCl (PBS) pH7.6	
Tris HCl	7.88 g
Tris base	6.06 g
Tween 20	0.5ml
NaCl	8.77g
Distilled water	1L
	pH to 7.6

WitsETD

created with nitroPDF professional
download the free trial online at nitropdf.com/professional

H1: HUMAN STUDY - SUBJECT INFORMATION SHEET

THE UNIVERSITY OF THE WITWATERSRAND, JOHANNESBURG
PROJECT INFORMATION SHEET:
THE EFFECT OF *BULBINE* ON WOUND HEALING

My colleagues (Professors Beverley Kramer and Alvaro Viljoen) and I (Nalini Pather) are researchers at the University of the Witwatersrand, Johannesburg. We would like to invite you to participate in our study (described below) by using an indigenous plant gel on a skin wound formed by a routine surgical procedure that you have decided to undergo. We will photograph the wound in a weeks' time and then use these photographs to investigate the effect of the indigenous plant (*Bulbine*) on the healing of wounds. This project is briefly described below:

Naturally derived medicines represent more than half of the drugs in clinical use. These are for diversely different conditions like malaria, heart disease and cancer and are derived from a wide variety of plants. Recently, interest in natural medicines for wound healing has grown. *Bulbine*, an indigenous South African plant of the same family as *Aloe vera*, has long been used by the people of South Africa for the treatment of wounds, burns, rashes, itches, ringworm and cracked lips. This project aims to evaluate the effect of *Bulbine* on the healing of skin wounds.

Please note, your participation is entirely voluntary. Should you **not** wish to participate in this study, there will be not adverse consequences and your normal treatment cannot be withheld. This participation is entirely confidential and your name and details will not be recorded at any stage. Furthermore, if after agreeing to participating in this study, you change your mind within the next two weeks, please inform us your wound photos will be withdrawn from this study and discarded. Note also, there will be no financial reward to you for participating in this project.

WITSERD

While this project will be of no direct benefit to you, we hope that through this project, the effect of this plant on the healing of skin wounds will be scientifically tested and if validated, will be of enormous benefit to the people of South Africa.

Thank you.

Project investigators:

Nalini Pather Professor Beverley Kramer Dr Alvaro Viljoen
Contact telephone numbers: 011 – 7172208/7172305

created with nitroPDF professional
download the free trial online at nitropdf.com/professional

H2: HUMAN STUDY – CONSENT FORM

UNIVERSITY OF THE WITWATERSRAND, JOHANNESBURG
PARTICIPATION IN SKIN BIOPSY STUDY FOR THE PURPOSE OF MEDICAL SCIENCE

I, (*Full name in block letters*) _____

Identity Number _____

Residing at _____

Consent to use an indigenous plant gel on the wound left behind from a routine skin biopsy that I am to undergo.

I understand that this wound will be photographed in a week and the photographs will be used for the purpose of investigating the wound healing properties of a plant extract as described in the project information sheet which I have read.

I understand that I will receive no remuneration *in lieu* of this donation. I understand too, that this is entirely voluntary.

Signed _____

At _____ on the _____ - _____ -20 _____
(Name of Hospital/Institution)

Witnesses:

Name _____ Name _____

Signature _____ Signature _____

Date _____ Date _____

WitsETD

created with nitroPDF professional
download the free trial online at nitropdf.com/professional

RESULTS APPENDICES

COLLAGEN ESTIMATION

COLLAGEN CONCENTRATION (mg/100ml) AVERAGE PER DAY				
B. natalensis Animal Group				
DAY	*Treated wounds*	*Untreated wounds*	*Treated wounds S.D.*	*Untreated wounds S.D.*
2	20.3096	13.3390	2.07	2.56
4	16.2664	15.5782	0.97	5.75
7	21.3198	16.1520	4.86	0.65
10	26.5396	8.4738	5.44	1.41
16	16.8911	10.9096	2.32	2.04
B. frutescens Animal Group				
DAY	*Treated wounds*	*Untreated wounds*	*Treated wounds S.D.*	*Untreated wounds S.D.*
2	15.9727	12.9099	3.91	1.40
4	15.2926	12.3013	0.96	2.01
7	19.8647	13.9170	6.63	3.12
10	16.3311	7.6565	0.49	3.82
16	12.8121	9.0961	1.75	5.31

WiSETD

created with nitroPDF professional
download the free trial online at nitropdf.com/professional

COLLAGEN RATIO : **TREATED/CONTROL WOUNDS** **Average per day**		
DAY	***B. natalensis***	***B. frutescens***
2	1.52	1.24
4	1.04	1.24
7	1.32	1.43
10	**3.13**	**2.13**
16	1.54	1.41
MEAN	1.71	1.49

WitsETD

created with nitroPDF professional
download the free trial online at nitropdf.com/professional