

https://dspace.org/

Pathologic findings in reduction mammaplasty specimens: a South African perspective

Sofianos, Chrysis

2018
https://hdl.handle.net/10539/25341

Downloaded from a DSpace repository. https://dspace.org/

PATHOLOGIC FINDINGS IN REDUCTION MAMMAPLASTY SPECIMENS: A SOUTH AFRICAN PERSPECTIVE

CHRYSIS SOFIANOS

0400283W



MMed in Surgery (Plastic and Reconstructive Surgery)

2015

Table of Contents

DECLARATION 4

ACKNOWLEDGMENTS 5

PUBLICATION 6

ABSTRACT 7

1 INTRODUCTION 9

1.1 Background 9

1.2 Occult carcinoma in breast reduction 9

1.3 The South African perspective 10

1.4 Intraoperative principles 11

1.5 Pathological examination of specimens 11

1.6 Treatment of breast cancer discovered during breast reduction 12

2 METHODS 13

2.1 Study Aim 13

2.2 Study Objectives 13

2.3 Study area 14

2.4 Study design 14

2.5 Inclusion criteria 14

2.6 Preoperative screening 15

2.7 Pathological assessment 15

2.8 Data Collection 15

2.9 Statistical analysis 16

2.10 Ethics approval 16

3 RESULTS 17

4 DISCUSSION 23

REFERENCES 30

APPENDIX A – REPRINTED ARTICLE 34

APPENDIX B – ETHICS APPROVAL 38

APPENDIX C – SUPERVISOR DECLARATION 39

APPENDIX D – DATA COLLECTION FORM 40

Declaration

I declare that this research is my own work. It is being submitted to the University of the Witwatersrand, in fulfilment of the requirements for the degree of MMed in the branch of Plastic and Reconstructive Surgery. This research report is being submitted by published paper.

It has not been previously submitted for any other degree or examination at this or any other university. This report does not utilise any previous or current work produced by another individual.



_____ **30 October 2015**

Chrysis Sofianos Date

Acknowledgments

Thank you to my supervisors for your support and guidance in every aspect of this research. Your input and knowledge has resulted in research that is not only of an acceptable standard, but also of a standard that has allowed it to be published in one of South Africa's premier peer-reviewed medical journals.

To my family, my gratitude could never be quantified. You have moulded every stage of my life into a quest to not only better my life but also the lives of those around me. Your love, ambition and tenacity are qualities that will remain with me forever.

Publication

This research report was accepted for publication in the South African Medical Journal (SAMJ) on 13 February 2015.

Sofianos C, Zinn RJ, Geoffreys DA, Kruger D. Pathological findings in reduction mammoplasty specimens: A South African perspective. S Afr Med J 2015;105(4):308-311. DOI:10.7196/SAMJ.9108

Presentations

- Association of Plastic and Reconstructive Surgeons of South Africa Congress, October 2014, winner of runner-up best clinical paper
- Bert Myburgh Research Forum, University of the Witwatersrand, November 2014

Abstract

Background

Preoperative, intraoperative and follow-up guidelines for managing occult carcinoma in reduction mammoplasty specimens are scant.

Methods

We retrospectively analysed the records and pathology reports of 200 patients who had undergone reduction mammoplasty at two major public hospitals in Johannesburg, South Africa, during 2009 - 2014. Demographic data, their history of breast cancer and preoperative screening, and the surgical techniques used and pathological reports were included. In all cases, preoperative screening for breast cancer had been negative.

Results

All the patients were female, mean age 37.1 years, range 20 - 84 (standard deviation 11.9). All reductions were performed using standard techniques. Benign pathology was observed in 98 patients (49%) and malignant pathology in four (2%). The most common benign pathology observed was fibrocystic disease, and the most common malignant pathology ductal carcinoma in situ. Patient age correlated significantly with benign or malignant disease.

Conclusions

Reduction mammoplasty produces tissue that should always be sent for pathological assessment. Patients should be stratified by risk, as doing so helps in selecting both the surgical setting and the approach to pathological analysis of the specimen. While the

incidence of occult carcinoma in reduction mammoplasty specimens is low, all patients undergoing the procedure should be informed that tissue will be sent for pathological examination, allowing them to prepare to receive possible news of breast cancer and be adequately equipped for subsequent decision-making.

1 Introduction

1.1 Background

Breast reduction (reduction mammoplasty) is a procedure that aims to reduce breast size when it has become excessive. It is frequently performed by plastic and breast surgeons to relieve macromastia symptoms.[1] It is also performed to obtain breast symmetry after contralateral breast cancer operations. [2] In the USA, a 97% increase in the number of reduction mammoplasty procedures has been observed.[2] The procedure increases both physical and psychological wellbeing and improves quality of life for many patients.[3]

1.2 Occult carcinoma in breast reduction

Crikelair and Malton[4] published the first reported case of occult carcinoma discovered during reduction mammoplasty in 1959. They described the presence of ductal carcinoma seen on microscopic examination of surgical specimens. Interestingly, they then published an addendum to their initial report when the patient developed another primary tumour in the other breast. Since then, as detailed below, many studies have attempted to investigate the incidence of occult carcinoma in reduction mammoplasty specimens.

Snyderman and Lizardo[5] performed a landmark study investigating the presence of occult carcinoma in reduction mammoplasty specimens. They examined 5 008 cases and demonstrated an incidence of 0.38%. In 1997, Jansen et al.[6] found an incidence of 0.16% in their series of 2 576 patients; however, the study design made use of a postal questionnaire sent out to consultant plastic surgeons, so it was susceptible to sampling bias. A population-based series study in Ontario, Canada, found a significantly lower incidence (0.06%) of

breast cancer at the time of reduction mammoplasty.[7] While older studies such as this are possibly outdated, given the improved awareness of breast malignancy and enhanced clinical and radiological techniques used in its detection, in the above series, patients diagnosed with breast cancer at the time of reduction mammoplasty were less likely to have advanced cancer than the general population and had a better 5-year survival rate. Preoperative screening featured both a clinical breast examination and mammography.[7]

1.3 The South African perspective

In South Africa (SA), the country from which our data are drawn, the latest available statistics from the South African National Cancer Registry are from 2006 and show that the incidence of breast cancer in SA is 0.029%.[8]

Macromastia is in itself a factor predisposing to breast cancer.[9] The increased prevalence of carcinoma of the breast in these women suggests that they may ultimately develop breast cancer following breast reduction. [10] Surgeons should be mindful of this fact, and undertake preoperative screening. [11] The recommended triple breast evaluation steps outlined in Table 1 must be followed.

The Royal College of Pathologists, in 2002, in a document aimed to better distribute pathology resources, claimed that specimens obtained from reduction mammoplasty procedures offered little clinical utility and did not significantly alter patient care. [12] As a direct response to this publication, Cook and Fuller, demonstrated that microscopic histopathologic examination of breast reduction specimens that appear macroscopically normal, had important pathological findings in 2.4% of patients. [13] At present, no South African study exists that describes the rational use of pathology services based on the source

of specimen. Cook and Fuller's research, although performed in the United Kingdom, clearly demonstrates that microscopic findings could be found even when macroscopy was negative; such a conclusion prompts us to believe that histological examination of these specimens could still offer some benefit.

Table 1. Triple breast evaluation

History	Carefully gather a patient history, with the aim of identifying any personal or family history of breast cancer, or any predisposing factors[9]
Clinical examination	Undertake a physical examination (including breast and nodal basin examination)[2]
Imaging	Undertake imaging, by either a mammogram or breast ultrasound[2,11]

1.4 Intraoperative principles

At the time of breast reduction, the surgeon has direct exposure to breast tissue and should undertake a careful palpation of the breast for any mass lesions. [17] If a malignant lesion is encountered at the onset of the procedure, the surgeon should not proceed with the reduction. [17] If it is encountered later in the reduction mammoplasty, the procedure should aim for adequate oncologic margins. [17]

1.5 Pathological examination of specimens

Until universal guidelines on risk stratification and pathological examination of reduction mammoplasty specimens are developed, all specimens obtained should be submitted for

pathological examination. [16] Histology should be of the same standard for all breast reduction specimens and should not differ with regards to age or other breast cancer risk factors. [17]

1.6 Treatment of breast cancer discovered during breast reduction

Diagnosis of breast cancer prior to reduction mammoplasty is vital as management and treatment options may change significantly.[14] A woman would be unlikely to opt to proceed with reduction mammoplasty without having both a biopsy and a multidisciplinary team decision on the management of malignancy. The diagnosis of breast cancer during reduction mammoplasty reduces the number of appropriate surgical options available and also complicates further treatment of the cancer.[2]

2 Methods

The worldwide incidence of occult carcinoma in reduction mammoplasty specimens is low. No study examining these pathological findings has been performed in SA. As discussed, studies have been conducted in developed countries, but this information may not be accurately extrapolated to developing countries such as SA.

2.1 Study Aim

The aim of this local study is to describe the spectrum of pathological findings in reduction mammaplasty specimens, both benign and malignant, in the South African setting.

2.2 Study Objectives

- To measure the incidence of abnormal pathologic findings, both benign and malignant, in reduction mammaplasty specimens in two high volume, multi-disciplinary surgical centres in Johannesburg, South Africa
- To stratify the incidence of pathologic findings in reduction mammaplasty specimens in different age groups
- To identify specific pathologic lesions in reduction mammaplasty specimens and stratify these according to age

2.3 Study area

Chris Hani Baragwanath Academic Hospital (CHBAH) is a public hospital situated in Soweto, Johannesburg, South Africa. It serves a mostly black African, lower-income population of 2.5 million. Mammoplasty procedures are performed at CHBAH free of charge to the patient. Helen Joseph Hospital (HJH) is a public hospital situated in Westdene, Johannesburg, and serves a population of approximately 198 000 of mixed socioeconomic status. Mammoplasty procedures are not provided free of charge at HJH, but the cost is lower than that at a private hospital.

2.4 Study design

A retrospective record review was performed of all patients who had undergone reduction mammoplasty procedures at CHBAH or HJH between January 2009 and January 2014, inclusive. Along with demographic data, patient histories of breast cancer, findings on preoperative screening, surgical techniques and pathological reports were recorded.

2.5 Inclusion criteria

To be included in the study sample, each patient had to meet the following three inclusion criteria: no preoperative history or examination suggestive of any breast disease; reduction mammoplasty performed on one or both breasts, using standard surgical techniques; and surgical specimens submitted for pathological review.

2.6 Preoperative screening

A detailed history was obtained, and aimed to identify previous or current breast disease and personal or family risk factors for breast disease. Screening further included clinical examination of the breasts as well as imaging – specifically, breast ultrasound for patients <35 years of age, and mammography for those aged ≥35 years or older. Preoperative imaging not only enabled significant breast disorders to be identified before surgery, but provided a control for detection of abnormalities after surgery had been performed.[15] Our institutional protocol dictates that preoperative screening of all reduction mammaplasty patients should be performed routinely however it is unknown whether this is the case with other Plastic Surgeons in South Africa. This uncertainty is not unique to South Africa, as the rate of preoperative screening before this procedure is also unknown in developed countries, such as the United Kingdom. [16]

2.7 Pathological assessment

Pathological findings were categorised into two broad groups: benign lesions and malignant lesions. Fibrocystic disease was included under benign pathology. Malignant pathology included carcinoma in situ. Only cases with at least two random blocks per breast were included. All specimens had been submitted to the SA National Health Laboratory Service.

2.8 Data Collection

Patients undergoing reduction mammaplasty procedures during this time period will be identified from theatre booking lists. The medical notes and histopathology reports for

surgical specimens from these procedures will be obtained. Information recorded will be patient demographics (age and race), diagnosis, laterality of procedure (unilateral or bilateral), specimen weight, and pathological findings. It will also be determined whether the patients received any pre-operative investigation, in the form of clinical breast examination, mammography or breast ultrasound. This information will be recorded on a data collection sheet (see Appendix D).

2.9 Statistical analysis

The Statistical Package for the Social Sciences (SPSS) 20.0 (SPSS Inc., USA) software program for Macintosh was used in data analysis. Descriptive results were expressed as means and standard deviations (SDs). Statistical evaluations were performed using the non-parametric Mann-Whitney U-test. The level of significance was set at $p<0.05$.

2.10 Ethics approval

Ethical approval was obtained from the Human Research Ethics Committee of the University of the Witwatersrand (clearance No. M140239). All study participants were given a study number to ensure anonymity of data.

3 Results

Figure 1. Patient Inclusion in Study



A total of 209 patients were identified for inclusion in the study. Nine were excluded because their operative specimens had not been submitted for pathological analysis. The 200 patients included were all female, with a mean (SD) age of 37.1 (11.9) years. The youngest patient was 20 years of age, and the oldest 84.

All patients had undergone a preoperative work-up including history-taking, clinical examination and imaging.

All reductions were performed using standard techniques, with 195 procedures being bilateral and five unilateral. The mean (SD) weight of specimens submitted for pathological review was 1 002.8 (652.1) g.

Benign pathology was observed in 98/200 patients (49%) and malignant pathology in four (2%). Specific pathological findings are listed in Table 2. Positive histological findings in individual patients, coupled with their ages, are tabulated in Table 3. Benign pathology was observed at a mean age of 46.5 years and malignant pathology at a mean of 50.2 years.

Table 2. Specific benign and malignant lesions

Pathological diagnosis	***n***
Benign lesions (*N*=98)	
Atypical ductal hyperplasia	1
Phyllodes	1
Ductal ectasia	2
Lipoid necrosis	2
Ductal hyperplasia	8
Fibroadenoma	14
Sclerosing adenosis	20
Fibrocystic change	50
Malignant lesions (*N*=4)	
Ductal carcinoma *in situ*	3
Invasive lobular carcinoma	1

Table 3. Individual Patient Age and Histological Findings

Age	Pathological diagnosis	No. of patients in Category
35	FIBROCYSTIC CHANGE	7
36	FIBROCYSTIC CHANGE	5
37	FIBROCYSTIC CHANGE	3
38	FIBROCYSTIC CHANGE	5
39	FIBROCYSTIC CHANGE	5
40	FIBROCYSTIC CHANGE	2
41	FIBROCYSTIC CHANGE	5
42	FIBROCYSTIC CHANGE	5
43	FIBROCYSTIC CHANGE	5
44	FIBROCYSTIC CHANGE	5
45	FIBROCYSTIC CHANGE	2
45	LIPOID NECROSIS	2
46	SCLEROSING ADENOSIS	5
47	SCLEROSING ADENOSIS	6
48	SCLEROSING ADENOSIS	4
49	SCLEROSING ADENOSIS	5
50	ATYPICAL DUCTAL HYPERPLASIA	1
50	DCIS	3
51	DUCTAL ECTASIA	2
51	DUCTAL HYPERPLASIA	1
51	LOBULAR NEOPLASIA, FIBROCYSTIC CHANGE	1
51	PHYLLODES	1

52	DUCTAL HYPERPLASIA	2
54	DUCTAL HYPERPLASIA	2
55	DUCTAL HYPERPLASIA	2
56	DUCTAL HYPERPLASIA	1
56	FIBROADENOMA	1
57	FIBROADENOMA	4
59	FIBROADENOMA	1
60	FIBROADENOMA	2
62	FIBROADENOMA	3
65	FIBROADENOMA	2
69	FIBROADENOMA	1
84	FIBROCYSTIC CHANGE	1

Figure 2. Benign Lesions by Type

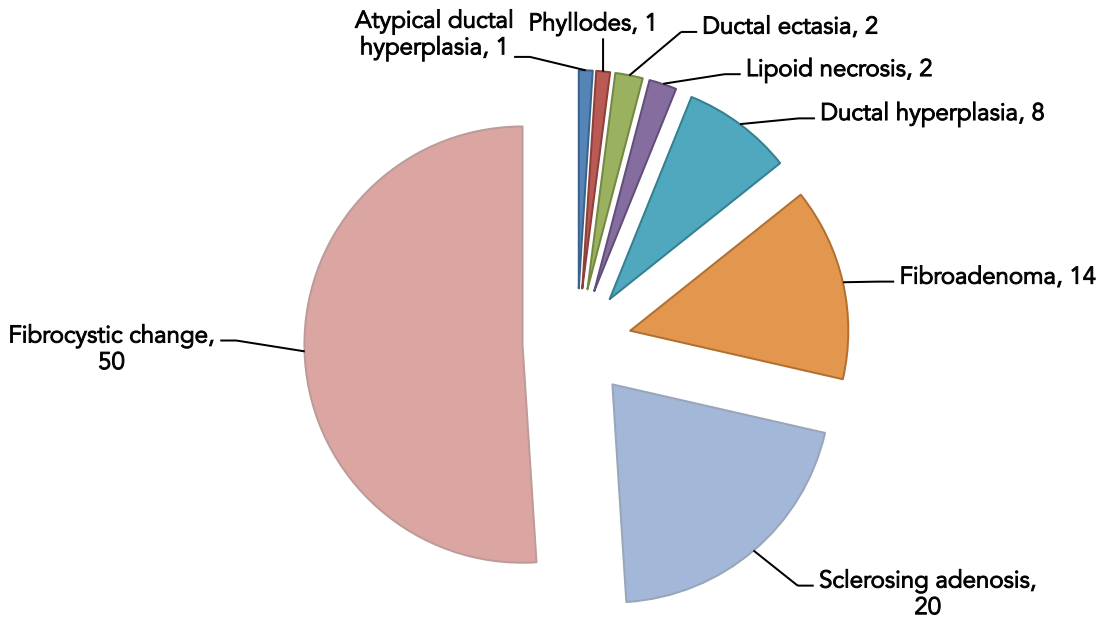

The Shapiro-Wilk test of normality revealed that the age and average specimen weight variables were not normally distributed. A Mann-Whitney U-test showed that age was a variable significantly associated with the presence both of benign disease ($p<0.0001$) and malignant disease ($p=0.012$). No significant difference was found when the presence of benign or malignant disease was correlated with specimen weight. Furthermore, there was no significant difference when specific malignant lesions were compared, probably owing to the small sample number.

Figure 3. Statistical Analysis of Age vs the Presence of Malignant Disease

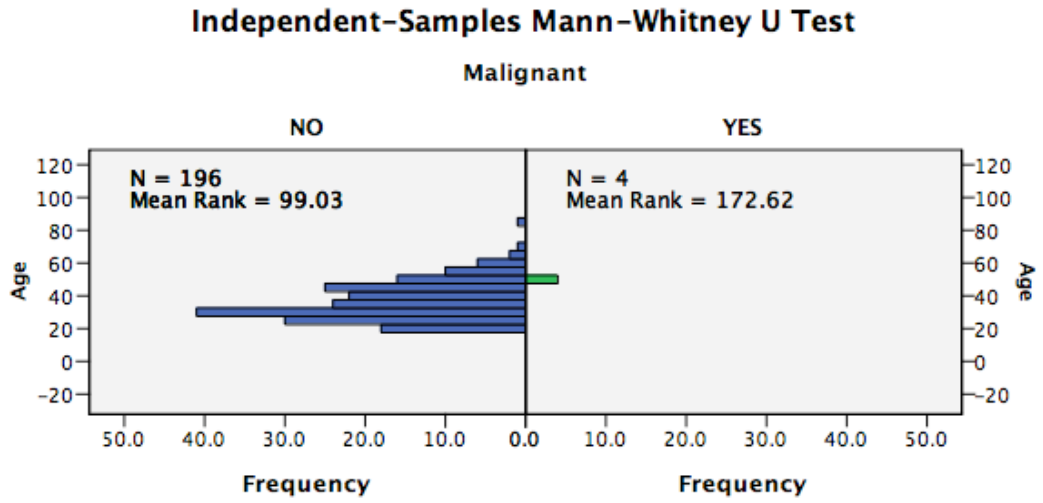

Figure 4. Statistical Analysis of Age vs the Presence of Benign Disease

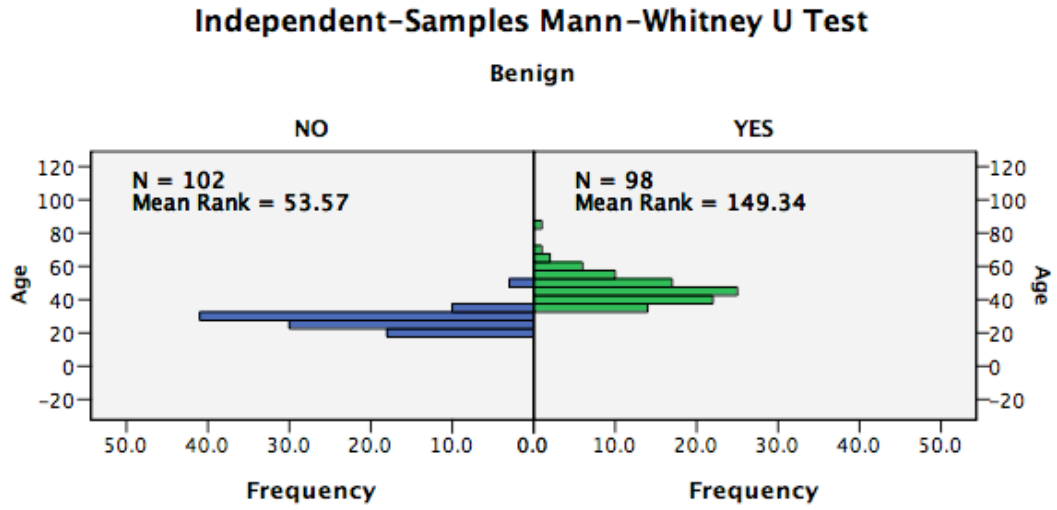

4 Discussion

Reduction mammoplasty produces a variable amount of tissue that should always be sent for pathological examination.[17] The procedure is of both cosmetic and oncological significance.[18] Its oncological significance is based primarily on the observation that breast cancer risk is reduced proportionate to the amount of breast tissue removed during the procedure.[19] Additionally, breast cancer encountered before, during, or after reduction mammoplasty requires a multidisciplinary approach to treatment, like any other breast cancer.

Malignant pathology was observed in 2% (n=4) of the 200 patients in this study. The incidence of occult breast carcinoma in other series ranges from 0.06% to 4.6%, with the most recent study in 2013 reporting a 0.56% rate of malignant pathology (including both invasive carcinoma and carcinoma in situ).[20] Differences in incidence arise because some studies include patients with previous or current breast disease, while in others, carcinoma in situ was not included. In addition, the pick-up of abnormal pathology increases in proportion to the degree of the pathological analysis.[21] In 1984, Nielsen et al.[22] showed through intense pathological scrutiny of breast specimens obtained from autopsy (200 or more blocks per specimen) that 14 - 16% of these specimens had occult carcinoma or carcinoma in situ. A future direction for our study would be a prospective investigation including a higher number of blocks per specimen to increase the rate of pick-up of pathological lesions.

Freedman et al.[23] found that the incidence of both premalignant and malignant lesions increased with increasing patient age; this trend was also seen in the current study, the significance extending to benign lesions as well as premalignant and malignant lesions. The malignant conditions encountered were largely (75%) of the ductal carcinoma in situ variety.

The most common benign lesion encountered was fibrocystic change, followed by sclerosing adenosis. We found fibroadenoma, classically a condition encountered in younger individuals, to be more common among older patients. Fibroadenomas in older patients tend to exhibit atrophy coupled with calcifications, however these are still considered benign conditions.[24] The weight of the specimen was not found to influence the presence of benign or malignant disease.

In this study, benign breast disease was observed in 98/200 patients (49%). In patients not undergoing reduction mammoplasty, benign breast disease is, in the majority of cases, a pathology that is identified when breast imaging abnormalities are found and/or a lump is found on clinical examination. Not all benign breast disease is equal, with different histological categories conferring different risks for breast cancer. Proliferative lesions without atypia confer a 1.5 to 2-fold increase in risk for breast cancer, while the risk may be as high as 4 to 5-fold in proliferative lesions with atypia. [25] The detection of benign breast disease in specimens submitted from reduction mammoplasty procedures does not ultimately alter the ongoing care of these patients and it could be argued that histologically examining these specimens is a waste of scarce resources in a country such as South Africa. The challenge arises in patients with a negative preoperative screening and the finding of breast disease intraoperatively; being selective in which specimens should be submitted for histology based on a presumed benign diagnosis, would require the surgeon to make this diagnosis intraoperatively based solely on his or her clinical expertise. In my opinion, even a single missed diagnosis of malignant breast disease due to the surgeon incorrectly classifying this disease as benign, intraoperatively, is inexcusable and the suggestion remains that no assumptions be made on whether a pathology detected intraoperatively is benign or malignant.

Patients who undergo reduction mammoplasty at CHBAH or HJH are followed up at 6 and 12 months. They are given advice regarding further screening, and are also followed up as part of SA's standard breast cancer screening programmes. Long-term follow-up of these patients would be of value to ascertain the incidence of breast cancer in the remaining breast tissue. Furthermore, in countries with a high prevalence of HIV/AIDS, variables such as HIV positivity and CD4 count would be useful data to capture and examine in future research. These data were not available for our retrospective review, but could be included in future prospective studies.

Every patient in the current study had had preoperative screening, despite the scant availability of universal guidelines for preoperative assessment and pathological assessment.

All methods of breast reduction allow for good exposure of breast parenchyma, and for direct visualisation and palpation of other segments; theoretically, any palpable tumour therefore can and should be detected at that time.[1] Titley et al.[26] suggested in 1996 that surgical specimens be separated clearly into left and right, and a marker stitch be placed in the main specimen, possibly separating tissues into quadrants. Since the majority of reduction mammoplasty specimens do not have occult carcinoma, it would be difficult to convince all surgeons to ink the margins of surgical specimens; however, it is reasonable to insist that specimens from women at an increased risk of developing breast cancer be inked for orientation.[2]

More recently it has been suggested that patients undergoing reduction mammoplasty be stratified according to risk; doing so would dictate the setting in which surgery should take place and the approach to pathological analysis of the specimen.[18] Table 4 outlines the approach to risk stratification and in what settings surgery should take place.

Table 4. Risk stratification for reduction mammoplasty patients[16]

Risk group	Features	Setting in which surgery should take place	Approach to specimen
High risk	Personal history of breast cancer BRCA1 or BRCA2 mutations Previous radiation to the chest Personal history of cancer syndromes	Pathology and surgical oncology services should be available	Margins should be inked and specimens orientated and divided into individual containers per segment resected
Intermediate risk	Family history of breast cancer Proliferative benign breast lesions	Pathology and surgical oncology services should be available	Inking of margins may be omitted
Low risk	Age <30 years No family history of breast cancer	Surgery may be performed at an outpatient centre	Specimen may be sent in two containers: left and right breast

No universal guidelines exist in South Africa for the handling of these specific specimens, although some institutional protocols dictate that all specimens be submitted, while other institutions suggest that only high risk specimens be submitted. In a resource-poor setting, utilitarianism should be the ideal, and in the case of pathological examination of reduction mammoplasty specimens, stratifying patients by risk could direct the Plastic Surgeon in selecting which specimens are submitted for review, and furthermore direct the Pathologist on the most cost-effective examination of these specimens. Until risk stratification and specimen selection for histopathology is standardised, all specimens should be submitted for pathological examination. Although it is simpler that all specimens be handled or marked intraoperatively in the same manner, the suggestion that different approaches to the specimen

based on risk stratification means that in low risk individuals, time is not wasted marking these specimens. Higher risk demands more time be allocated to ensuring proper marking and orientation of these specimens.

Pathological examination of reduction mammoplasty specimens is different in each institution. Dotto et al suggest that in routine reduction mammoplasty specimens, a macroscopic inspection followed by microscopic examination of 4 sections of tissue per specimen is sufficient. [9] Our study demonstrated a mean weight of 1002,8g per specimen, thus it is conceivable that only 4 sections of tissue (2 slides) would indeed not be sufficient, however the detection rate was still relatively high (49% benign, 2% malignant). Again no South African guidelines exist on the minimum number of sections that should examined in these specimens.

Patients diagnosed with breast cancer at the time of reduction mammoplasty are likely to be treated with a completion mastectomy.[7] It is unknown at present whether this is the actual management employed by South African plastic surgeons, and whether South African patients are being informed of the eventuality of a mastectomy if cancer is detected intraoperatively. The basis of the decision to proceed to completion mastectomy is the rearrangement of tissues during the procedure, as well as the possibility of tumour seeding in the normal breast. Discovery of a breast carcinoma during or after a reduction mammoplasty poses a number of technical challenges: a large field of dissection, including a breach of pectoral fascia in certain areas; a larger skin incision; and possible contamination of the other breast during bilateral procedures.[14] The suggested technique, if breast cancer is discovered in pathological examination of surgical specimens from reduction mammoplasty, is a completion mastectomy that includes pre-existing incisions from the reduction mammoplasty procedure.[27] Reduction mammoplasty should not be considered a contraindication to

sentinel lymph node biopsy, as many lymphatic channels remain intact and most breast reduction techniques involve incisions on the inferior aspect of the breast.[28]

Many philosophical debates on ethics and informed consent have arisen in recent years. In the UK, screening for breast cancer is not recommended for any woman under the age of 50.[29] Furthermore, the US Preventive Services Task Force's breast screening recommendations recently indicated that mammography is of no benefit for patients under the age of 50.[30] Given these recommendations, many young women worldwide who are undergoing reduction mammoplasty are in effect undergoing a 'screening procedure' without their informed consent.[31] Although the incidence of occult carcinoma among reduction mammoplasty specimens is low, all patients undergoing the procedure should be fully informed that the tissue will be sent for pathological examination, as doing so allows them to prepare for the possibility of receiving news of breast cancer, and to be adequately equipped for the decision-making that will follow.[31] Indeed, 'The primary intent of mammoplasty is cosmetic, but it is a medical procedure, taking place in a medical setting, and those performing it have a fiduciary obligation towards their patients' health and wellbeing.'[31]

Conclusion

It has been demonstrated that, even in developing countries, it is of vital importance that surgeons aim to adequately investigate reduction mammoplasty candidates preoperatively and ensure that all tissue is submitted for pathological analysis. During the informed consent process for the procedure, patients should be fully informed of the potential consequences of the pathological analysis of surgical specimens obtained. Multidisciplinary approaches to breast cancer treatment should always be included for patients undergoing reduction mammoplasty who are diagnosed with breast cancer. Age was found to correlate significantly with the presence of benign or malignant disease in reduction mammoplasty specimens. Further areas of study exist, and the results thereof could increase our understanding of the various pathological lesions found in reduction mammoplasty specimens.

A need for developing clear guidelines for preoperative investigation, intraoperative marking and pathological examination of reduction mammoplasty specimens is evident, and should be directed by the requirement of cost-effectiveness in a resource-limited setting such as South Africa. These guidelines could further steer South African Plastic Surgeons towards a unified approach to these patients as much uncertainty exists on how these patients are currently handled. We hope that this study serves as a starting point for developing guidelines that will not only be of utility in South Africa but for Plastic Surgeons performing reduction mammoplasty in any setting.

References

1. Viana GA, Pitanguy I, Torres E. Histopathological findings in surgical specimens obtained from reduction mammaplasties. Breast 2005;14(3):242-248. [http://dx.doi.org/10.1016/j.breast.2004.12.006]
2. Keleher AJ, Langstein HN, Ames FC, et al. Breast cancer in reduction mammaplasty specimens: Case reports and guidelines. Breast J 2003;9(2):120-125. [http://dx.doi.org/10.1046/j.1524-4741.2003.09216.x]
3. Goyal A, Coulson SG, Wu JM, et al. Occult breast carcinoma in breast reduction specimens in European women. Breast Cancer Res Treat 2011;128(3):749-753. [http://dx.doi.org/10.1007/s10549-011-1589-9]
4. Crikelair GF, Malton SD. Mammaplasty and occult breast malignancy: Case report. Plast Reconstr Surg Transplant Bull 1959;23(6):601-606. [http://dx.doi.org/10.1097/00006534-195906000-00006]
5. Snyderman RK, Lizardo JG. Statistical study of malignancies found before, during, or after routine breast plastic operations. Plast Reconstr Surg Transplant Bull 1960;25(3):253-256. [http://dx.doi.org/10.1097/00006534-196003000-00006]
6. Jansen DA, Murphy M, Kind GM, et al. Breast cancer in reduction mammoplasty: Case reports and a survey of plastic surgeons. Plast Reconstr Surg 1998;101(2):361-364. [http://dx.doi.org/10.1097/00006534-199802000-00014]
7. Tang CL, Brown MH, Levine R, et al. Breast cancer found at the time of breast reduction. Plast Reconstr Surg 1999;103(6):1682-1686. [http://dx.doi.org/10.1097/00006534-199905000-00016]
8. National Health Laboratory Service. National Cancer Registry of South Africa. http://www.nioh.ac.za/assets/files/NCR_2006_TABLES_FINAL.pdf (accessed 29 April 2014).

9. Dotto J, Kluk M, Geramizadeh B, et al. Frequency of clinically occult intraepithelial and invasive neoplasia in reduction mammoplasty specimens: A study of 516 cases. Int J Surg Pathol 2008;16(1):25-30. [http://dx.doi.org/10.1177/1066896907307176]
10. Rees TD, Coburn R. Breast reduction: Is it an aid to cancer detection? Br J Plast Surg 1972;25(2):144-146. [http://dx.doi.org/10.1016/S0007-1226(72)80036-5]
11. Van der Torre PM, Butzelaar RM. Breast cancer and reduction mammoplasty: The role of routine pre-operative mammography. Eur J Surg Oncol 1997;23(4):341-342. [http://dx.doi.org/10.1016/S0748-7983(97)90885-4]
12. Royal College of Pathologists. Histopathology of limited or no clinical value. RCPath publication 2002. London: Royal College of Pathologists.
13. Cook IS, Fuller CE. Does histopathological examination of breast reduction specimens affect patient management and clinical follow up? J Clin Pathol 2004; 57(3): 286–289. [PMID: 14990601] [http://dx.doi.org/10.1136%2Fjcp.2003.012427]
14. Gottlieb JR, McKinney P, Walkinshaw MD, et al. Occult breast carcinoma in patients undergoing reduction mammaplasty. Aesthetic Plast Surg 1989;13(4):279-283. [http://dx.doi.org/10.1007/BF01570361]
15. Shiffman MA. Mammograms in cosmetic breast surgery. In: Shiffman MA, ed. Mastopexy and Breast Reduction: Principles and Practice. 1st ed. Heidelberg: Springer, 2009:37-40.
16. Hennedige AA1, Kong TY, Gandhi A. Oncological screening for Bilateral Breast Reduction: a survey of practice variations in UK Breast and Plastics surgeons 2009. J Plast Reconstr Aesthet Surg 2011;64(7):878-83.
17. Ishag MT, Bashinsky DY, Beliaeva IV, et al. Pathologic findings in reduction mammaplasty specimens. Am J Clin Pathol 2003;120(3):377-380. [http://dx.doi.org/10.1309/4KD652HN739XTLM3]

18. Jansen DA, Ghere MC, Lee M, et al. Breast cancer and reduction mammaplasty. In: Shiffman MA, ed. Mastopexy and Breast Reduction: Principles and Practice. 1st ed. Heidelberg: Springer, 2009:657-670.
19. Brinton LA, Persson I, Boice JD jr, et al. Breast cancer risk in relation to amount of tissue removed during breast reduction operations in Sweden. Cancer 2001;91(3):478-483. [http://dx.doi.org/10.1002/1097-0142(20010201)91:3%3C478::AID-CNCR1025%3E3.3.CO;2-X]
20. Aytac B, Sahsine T, Erturk FY, et al. Evaluation of incidence and histolopathological findings of breast lesions in reduction mammoplasty specimens: Uludag University experience. J Pak Med Assoc 2013;63(7):878-881. [PMID: 23901713]
21. Kerrigan CL, Slezak SS. Evidence-based medicine: Reduction mammaplasty. Plast Reconstr Surg 2013;132(6):1670-1683. [http://dx.doi.org/10.1097/PRS.0b013e3182a807ec]
22. Nielsen M, Jensen J, Andersen J. Precancerous and cancerous breast lesions during lifetime and at autopsy: A study of 83 women. Cancer 1984;54(4):612-615. [http://dx.doi.org/10.1002/1097-0142(1984)54:4%3C612::AID-CNCR2820540403%3E3.0.CO;2-B]
23. Freedman BC, Smith SM, Estabrook A, et al. Incidence of occult carcinoma and high-risk lesions in mammaplasty specimens. Int J Breast Cancer 2012;2012:145630. [http://dx.doi.org/10.1155/2012/145630]
24. Wiratkapun C, Piyapan P, et al. Fibroadenoma versus phyllodes tumor: distinguishing factors in patients diagnosed with fibroepithelial lesions after a core needle biopsy. Diagn Interv Radiol;2014 Jan-Feb;20(1):27-33. [PMID: 24356293] [http://dx.doi.org/10.5152/2013/13133]

25. Schnitt SJ. Benign breast disease and breast cancer risk: morphology and beyond. Am J Surg Pathol 2003;27(6):836. [PMID: 12766590] [http://dx.doi.org/10.1097/00000478-200306000-00017]

26. Titley OG, Armstrong AP, Christie JL, et al. Pathological findings in breast reduction surgery. Br J Plast Surg 1996;49(7):447-451. [http://dx.doi.org/10.1016/S0007-1226(96)90028-4]

27. Rudolph R, Niedbala AR. Surgical management of the patient with invasive carcinoma discovered at reduction mammoplasty. Am Surg 2003;69(11):1003-1005. [PMID: 14627265]

28. Golshan M, Lesnikoski BA, Lester S. Sentinel lymph node biopsy for occult breast cancer detected during breast reduction surgery. Am Surg 2006;72(5):397-400. [PMID: 16719192]

29. McPherson K. Screening for breast cancer – balancing the debate. BMJ 2010;340:c3106. [http://dx.doi.org/10.1136/bmj.c3106]

30. Screening for breast cancer: US Preventive Services Task Force recommendation statement. Ann Intern Med 2009;151(10):716-736. [http://dx.doi.org/10.7326/0003-4819-151-10-200911170-00008]

31. Keshtgar M, Hamidian Jahromi A, Davidson T, et al. Tissue screening after breast reduction. BMJ 2009;338:b630. [http://dx.doi.org/10.1136/bmj.b630]

Appendix A – Reprinted Article

Pathological findings in reduction mammoplasty specimens: A South African perspective

C Sofianos, MB BCh, MRCS (Eng); **R J Zinn**, MB ChB, FC Plast Surg (SA), MMed; **D A Geoffreys**, MB ChB, FC Plast Surg (SA); **D Kruger**, BSc, PGCHE, PhD

Department of Surgery, Faculty of Health Sciences, University of the Witwatersrand, Johannesburg, South Africa

Corresponding author: *C Sofianos (sofianosc@gmail.com)*

Background. Preoperative, intraoperative and follow-up guidelines for managing occult carcinoma in reduction mammoplasty specimens are scant.
Methods. We retrospectively analysed the records and pathology reports of 200 patients who had undergone reduction mammoplasty at two major public hospitals in Johannesburg, South Africa, during 2009 - 2014. Demographic data, their history of breast cancer and preoperative screening, the surgical techniques used and pathological reports were included. In all cases preoperative screening for breast cancer had been negative.
Results. All the patients were female, mean age 37.1 years, range 20 - 84 (standard deviation 11.9). All reductions were performed using standard techniques. Benign pathology was observed in 98 patients (49%) and malignant pathology in four (2%). The most common benign pathology observed was fibrocystic disease, and the most common malignant pathology ductal carcinoma *in situ*. Patient age correlated significantly with benign or malignant disease.
Conclusions. Reduction mammoplasty produces tissue that should always be sent for pathological assessment. Patients should be stratified by risk, as doing so helps in selecting both the surgical setting and the approach to pathological analysis of the specimen. While the incidence of occult carcinoma in reduction mammoplasty specimens is low, all patients undergoing the procedure should be informed that tissue will be sent for pathological examination, allowing them to prepare to receive possible news of breast cancer and be adequately equipped for subsequent decision-making.

S Afr Med J 2015;105(4):308-311. DOI:10.7196/SAMJ.9108

Breast reduction (reduction mammoplasty) is frequently performed by plastic and breast surgeons to relieve macromastia symptoms.[1] In the USA, a 97% increase in the number of reduction mammoplasty procedures has been observed.[2] The procedure increases both physical and psychological wellbeing and improves quality of life for many patients.[3]

Crikelair and Malton[4] published the first reported case of occult carcinoma discovered during reduction mammoplasty in 1959. They described the presence of ductal carcinoma seen on microscopic examination of surgical specimens. Interestingly, they then published an addendum to their initial report when the patient developed another primary tumour in the other breast. Since then, as detailed below, many studies have attempted to investigate the incidence of occult carcinoma in reduction mammoplasty specimens.

Snyderman and Lizardo[5] performed a landmark study investigating the presence of occult carcinoma in reduction mammoplasty specimens. They examined 5 008 cases and demonstrated an incidence of 0.38%. In 1997, Jansen *et al.*[6] found an incidence of 0.16% in their series of 2 576 patients; however, the study design made use of a postal questionnaire sent out to consultant plastic surgeons, so it was susceptible to sampling bias. A population-based series study in Ontario, Canada, found a significantly lower incidence (0.06%) of breast cancer at the time of reduction mammoplasty.[7] While older studies such as this are possibly outdated, given the improved awareness of breast malignancy and enhanced clinical and radiological techniques used in its detection, in the above series, patients diagnosed with breast cancer at the time of reduction mammoplasty were less likely to have advanced cancer than the general population and had a better 5-year survival rate. Preoperative screening featured both a clinical breast examination and mammography.[7]

In South Africa (SA), from which our data are drawn, the latest available statistics from the SA National Cancer Registry are from 2006 and show that the incidence of breast cancer in SA is 0.029%.[8]

Macromastia is in itself a factor predisposing to breast cancer.[9] The increased prevalence of carcinoma of the breast in these women suggests that they may ultimately develop breast cancer following breast reduction.[10] Surgeons should be mindful of this fact, and undertake preoperative screening.[11] If a lesion is detected, the recommended triple breast evaluation steps outlined in Table 1 must be followed.

Diagnosis of breast cancer prior to reduction mammoplasty is vital, as management and treatment options may change significantly.[12] A woman would be unlikely to opt to proceed with reduction mammoplasty without having both a biopsy and a multidisciplinary team decision on the management of malignancy. The diagnosis of breast cancer during reduction mammoplasty reduces the number of appropriate surgical options available and also complicates further treatment of the cancer.[2]

Methods

The worldwide incidence of occult carcinoma in reduction mammoplasty specimens is low. No study examining these pathological findings has been performed in SA. As discussed, studies have been conducted in developed countries, but this information may not be accurately extrapolated to developing countries such as SA.

Study area

Chris Hani Baragwanath Academic Hospital (CHBAH) is a public hospital situated in Soweto, Johannesburg, South Africa. It serves a mostly black African, lower-income population of 2.5 million. Mammoplasty procedures are performed at CHBAH free of charge to the patient. Helen Joseph Hospital (HJH) is a public hospital situated in Westdene,

Table 1. Triple breast evaluation

History	Carefully gather a patient history, with the aim of identifying any personal or family history of breast cancer, or any predisposing factors[9]
Clinical examination	Undertake a physical examination (including breast and nodal basin examination)[2]
Imaging	Undertake imaging, by either a mammogram or breast ultrasound[2,11]

Johannesburg, and serves a population of approximately 198 000 of mixed socioeconomic status. Mammoplasty procedures are not provided free of charge at HJH, but the cost is lower than that at a private hospital.

Study design

A retrospective record review was performed of all patients who had undergone reduction mammoplasty procedures at CHBAH or HJH between January 2009 and January 2014, inclusive. Along with demographic data, patient histories of breast cancer, findings on preoperative screening, surgical techniques and pathological reports were recorded.

Inclusion criteria

To be included in the study sample, each patient had to meet the following three inclusion criteria: no preoperative history or examination suggestive of any breast disease; reduction mammoplasty performed on one or both breasts, using standard surgical techniques; and surgical specimens submitted for pathological review.

Preoperative screening

A detailed history was obtained, and aimed to identify previous or current breast disease and personal or family risk factors for breast disease. Screening further included clinical examination of the breasts as well as imaging – specifically, breast ultrasound for patients <35 years of age, and mammography for those aged ≥35 years. Preoperative imaging not only enabled significant breast disorders to be identified before surgery, but provided a control for detection of abnormalities after surgery had been performed.[13]

Pathological assessment

Pathological findings were categorised into two broad groups: benign lesions and malignant lesions. Fibrocystic disease was included under benign pathology. Malignant pathology included carcinoma *in situ*. Only cases with at least two random blocks per breast were included. All specimens had been submitted to the SA National Health Laboratory Service.

Statistical analysis

The Statistical Package for the Social Sciences (SPSS) 20.0 (SPSS Inc., USA) software program for Macintosh was used in data analysis. Descriptive results were expressed as means and standard deviations (SDs). Statistical evaluations were performed using the non-parametric Mann-Whitney *U*-test. The level of significance was set at $p<0.05$.

Ethical approval

Ethical approval was obtained from the Human Research Ethics Committee of the University of the Witwatersrand (clearance No. M140239).

Results

A total of 209 patients were identified for inclusion in the study. Nine were excluded because their operative specimens had not been submitted for pathological analysis. The 200 patients included were all female, with a mean (SD) age of 37.1 (11.9) years. The youngest patient was 20 years of age, and the oldest 84. All patients had undergone a preoperative work-up including history-taking, clinical examination and imaging. All reductions were performed using standard techniques, with 195 procedures being bilateral and five unilateral. The mean (SD) weight of specimens submitted for pathological review was 1 002.8 (652.1) g.

Table 2. Specific benign and malignant lesions

Pathological diagnosis	*n*
Benign lesions (*N*=98)	
Atypical ductal hyperplasia	1
Phyllodes	1
Ductal ectasia	2
Lipoid necrosis	2
Ductal hyperplasia	8
Fibroadenoma	14
Sclerosing adenosis	20
Fibrocystic change	50
Malignant lesions (*N*=4)	
Ductal carcinoma *in situ*	3
Invasive lobular carcinoma	1

Benign pathology was observed in 98/200 patients (49%) and malignant pathology in four (2%). Specific pathological findings are listed in Table 2. Benign pathology was observed at a mean age of 46.5 years and malignant pathology at a mean of 50.2 years.

The Shapiro-Wilk test of normality revealed that the age and average specimen weight variables were not normally distributed. A Mann-Whitney *U*-test showed that age was a variable significantly associated with the presence of both benign disease ($p<0.0001$) and malignant disease ($p=0.012$). No significant difference was found when the presence of benign or malignant disease was correlated with specimen weight. Furthermore, there was no significant difference when specific malignant lesions were compared, probably owing to the small sample number.

Discussion

Reduction mammoplasty produces a variable amount of tissue that should always be sent for pathological examination.[14] The procedure is of both cosmetic and oncological significance.[15] Its oncological significance is based primarily on the observation that breast cancer risk is reduced proportionate to the amount of breast tissue removed during the procedure.[16] Additionally, breast cancer encountered before, during, or after reduction mammoplasty requires a multidisciplinary approach to treatment, like any other breast cancer.

Malignant pathology was observed in 2% ($n=4$) of the 200 patients in this study. The incidence of occult breast carcinoma in other series ranges from 0.06% to 4.6%, with the most recent study in 2013 reporting a 0.56% rate of malignant pathology (including both invasive carcinoma and carcinoma *in situ*).[17] Differences in incidence

Table 3. Risk stratification for reduction mammoplasty patients[14]

Risk group	Features	Setting in which surgery should take place	Approach to specimen
High risk	Personal history of breast cancer BRCA1 or BRCA2 mutations Previous radiation to the chest Personal history of cancer syndromes	Pathology and surgical oncology services should be available	Margins should be inked and specimens orientated and divided into individual containers per segment resected
Intermediate risk	Family history of breast cancer Proliferative benign breast lesions	Pathology and surgical oncology services should be available	Inking of margins may be omitted
Low risk	Age <30 years No family history of breast cancer	Surgery may be performed at an outpatient centre	Specimen may be sent in two containers: left and right breast

arise because some studies include patients with previous or current breast disease, while in others, carcinoma *in situ* was not included. In addition, the pick-up of abnormal pathology increases in proportion to the degree of the pathological analysis.[18] In 1984, Nielsen *et al.*[19] showed through intensive pathological scrutiny of breast specimens obtained from autopsy (200 or more blocks per specimen) that 14 - 16% of these specimens had occult carcinoma or carcinoma *in situ*. A future direction for our study would be a prospective investigation including a higher number of blocks per specimen to increase the rate of pick-up of pathological lesions.

Freedman *et al.*[20] found that the incidence of both premalignant and malignant lesions increased with increasing patient age; this trend was also seen in the current study, the significance extending to benign lesions as well as premalignant and malignant lesions. The malignant conditions encountered were largely (75%) of the ductal carcinoma *in situ* variety. The most common benign lesion encountered was fibrocystic change, followed by sclerosing adenosis. We found fibroadenoma, classically a condition encountered in younger individuals, to be more common among older patients. The weight of the specimen was not found to influence the presence of benign or malignant disease.

Patients who undergo reduction mammoplasty at CHBAH or HJH are followed up at 6 and 12 months. They are given advice regarding further screening, and are also followed up as part of SA's standard breast cancer screening programmes. Long-term follow-up of these patients would be of value to ascertain the incidence of breast cancer in the remaining breast tissue. Furthermore, in countries with a high prevalence of HIV/AIDS, variables such as HIV positivity and CD4 count would be useful data to capture and examine in future research. These data were not available for our retrospective review, but could be included in future prospective studies.

Every patient in the current study had had preoperative screening, despite the scant availability of universal guidelines for preoperative assessment and pathological assessment.

All methods of breast reduction allow for good exposure of breast parenchyma, and for direct visualisation and palpation of other segments; theoretically, any palpable tumour therefore can and should be detected at that time.[1] Titley *et al.*[21] suggested in 1996 that surgical specimens be separated clearly into left and right, and that a marker stitch be placed in the main specimen, possibly separating tissues into quadrants. Since the majority of reduction mammoplasty specimens do not have occult carcinoma, it would be difficult to convince all surgeons to ink the margins of surgical specimens; however, it is reasonable to insist that specimens from women at an increased risk of developing breast cancer be inked for orientation.[2]

More recently it has been suggested that patients undergoing reduction mammoplasty be stratified according to risk; doing so would dictate the setting in which surgery should take place and the approach to pathological analysis of the specimen.[15] Table 3 outlines the approach to risk stratification and in what settings surgery should be done.

Patients diagnosed with breast cancer at the time of reduction mammoplasty are likely to be treated with a completion mastectomy.[7] The basis of this decision is the rearrangement of tissue during the procedure, as well as the possibility of tumour seeding in the normal breast. Discovery of a breast carcinoma during or after a reduction mammoplasty poses a number of technical challenges: a large field of dissection, including a breach of pectoral fascia in certain areas; a larger skin incision; and possible contamination of the other breast during bilateral procedures.[12] The suggested technique, if breast cancer is discovered in pathological examination of surgical specimens from reduction mammoplasty, is a completion mastectomy that includes pre-existing incisions from the reduction mammoplasty procedure.[22] Reduction mammoplasty should not be considered a contraindication to sentinel lymph node biopsy, as many lymphatic channels remain intact and most breast reduction techniques involve incisions on the inferior aspect of the breast.[23]

Many philosophical debates on ethics and informed consent have arisen in recent years. In the UK, screening for breast cancer is not recommended for any woman under the age of 50.[24] Furthermore, the US Preventive Services Task Force's breast screening recommendations recently indicated that mammography is of no benefit for patients under the age of 50.[25] Given these recommendations, many young women worldwide who are undergoing reduction mammoplasty are in effect undergoing a 'screening procedure' without their informed consent.[26] Although the incidence of occult carcinoma among reduction mammoplasty specimens is low, all patients undergoing the procedure should be fully informed that the tissue will be sent for pathological examination, as doing so allows them to prepare for the possibility of receiving news of breast cancer, and to be adequately equipped for the decision-making that will follow.[26] Indeed, 'The primary intent of mammoplasty is cosmetic, but it is a medical procedure, taking place in a medical setting, and those performing it have a fiduciary obligation towards their patients' health and wellbeing.'[26]

Conclusion

It has been demonstrated that, even in developing countries, it is of vital importance that surgeons aim to adequately investigate reduction mammoplasty candidates preoperatively and ensure that all tissue is submitted for pathological analysis. During the informed consent process for the procedure, patients should be fully informed of the potential consequences of the pathological analysis of surgical specimens obtained. Multidisciplinary approaches to

breast cancer treatment should always be included for patients undergoing reduction mammoplasty who are diagnosed with breast cancer. Age was found to correlate significantly with the presence of benign or malignant disease in reduction mammoplasty specimens. Further areas of study exist, and the results thereof could increase our understanding of the various pathological lesions found in reduction mammoplasty specimens.

References

1. Viana GA, Pitanguy I, Torres E. Histopathological findings in surgical specimens obtained from reduction mammaplasties. Breast 2005;14(3):242-248. [http://dx.doi.org/10.1016/j.breast.2004.12.006]
2. Keleher AJ, Langstein HN, Ames FC, et al. Breast cancer in reduction mammaplasty specimens: Case reports and guidelines. Breast J 2003;9(2):120-125. [http://dx.doi.org/10.1046/j.1524-4741.2003.09216.x]
3. Goyal A, Coulson SG, Wu JM, et al. Occult breast carcinoma in breast reduction specimens in European women. Breast Cancer Res Treat 2011;128(3):749-753. [http://dx.doi.org/10.1007/s10549-011-1589-9]
4. Crikelair GF, Malton SD. Mammaplasty and occult breast malignancy: Case report. Plast Reconstr Surg Transplant Bull 1959;23(6):601-606. [http://dx.doi.org/10.1097/00006534-195906000-00006]
5. Snyderman RK, Lizardo JG. Statistical study of malignancies found before, during, or after routine breast plastic operations. Plast Reconstr Surg Transplant Bull 1960;25(3):253-256. [http://dx.doi.org/10.1097/00006534-196003000-00006]
6. Jansen DA, Murphy M, Kind GM, et al. Breast cancer in reduction mammoplasty: Case reports and a survey of plastic surgeons. Plast Reconstr Surg 1998;101(2):361-364. [http://dx.doi.org/10.1097/00006534-199802000-00014]
7. Tang CL, Brown MH, Levine R, et al. Breast cancer found at the time of breast reduction. Plast Reconstr Surg 1999;103(6):1682-1686. [http://dx.doi.org/10.1097/00006534-199905000-00016]
8. National Health Laboratory Service. National Cancer Registry of South Africa. http://www.nioh.ac.za/assets/files/NCR_2006_TABLES_FINAL.pdf (accessed 29 April 2014).
9. Dotto J, Kluk M, Geramizadeh B, et al. Frequency of clinically occult intraepithelial and invasive neoplasia in reduction mammoplasty specimens: A study of 516 cases. Int J Surg Pathol 2008;16(1):25-30. [http://dx.doi.org/10.1177/1066896907307176]
10. Rees TD, Coburn R. Breast reduction: Is it an aid to cancer detection? Br J Plast Surg 1972;25(2):144-146. [http://dx.doi.org/10.1016/S0007-1226(72)80036-5]
11. Van der Torre PM, Butzelaar RM. Breast cancer and reduction mammoplasty: The role of routine pre-operative mammography. Eur J Surg Oncol 1997;23(4):341-342. [http://dx.doi.org/10.1016/S0748-7983(97)90885-4]
12. Gottlieb JR, McKinney P, Walkinshaw MD, et al. Occult breast carcinoma in patients undergoing reduction mammaplasty. Aesthetic Plast Surg 1989;13(4):279-283. [http://dx.doi.org/10.1007/BF01570361]
13. Shiffman MA. Mammograms in cosmetic breast surgery. In: Shiffman MA, ed. Mastopexy and Breast Reduction: Principles and Practice. 1st ed. Heidelberg: Springer, 2009:37-40.
14. Ishag MT, Bashinsky DY, Beliaeva IV, et al. Pathologic findings in reduction mammaplasty specimens. Am J Clin Pathol 2003;120(3):377-380. [http://dx.doi.org/10.1309/4KD652HN739XTLM3]
15. Jansen DA, Ghere MC, Lee M, et al. Breast cancer and reduction mammaplasty. In: Shiffman MA, ed. Mastopexy and Breast Reduction: Principles and Practice. 1st ed. Heidelberg: Springer, 2009:657-670.
16. Brinton LA, Persson I, Boice JD jr, et al. Breast cancer risk in relation to amount of tissue removed during breast reduction operations in Sweden. Cancer 2001;91(3):478-483. [http://dx.doi.org/10.1002/1097-0142(20010201)91:3%3C478::AID-CNCR1025%3E3.3.CO;2-X]
17. Aytac B, Sahsine T, Erturk FY, et al. Evaluation of incidence and histolopathological findings of breast lesions in reduction mammoplasty specimens: Uludag University experience. J Pak Med Assoc 2013;63(7):878-881.
18. Kerrigan CL, Slezak SS. Evidence-based medicine: Reduction mammaplasty. Plast Reconstr Surg 2013;132(6):1670-1683. [http://dx.doi.org/10.1097/PRS.0b013e3182a807ec]
19. Nielsen M, Jensen J, Andersen J. Precancerous and cancerous breast lesions during lifetime and at autopsy: A study of 83 women. Cancer 1984;54(4):612-615. [http://dx.doi.org/10.1002/1097-0142(1984)54:4%3C612::AID-CNCR2820540403%3E3.0.CO;2-B]
20. Freedman BC, Smith SM, Estabrook A, et al. Incidence of occult carcinoma and high-risk lesions in mammaplasty specimens. Int J Breast Cancer 2012;2012:145630. [http://dx.doi.org/10.1155/2012/145630]
21. Titley OG, Armstrong AP, Christie JL, et al. Pathological findings in breast reduction surgery. Br J Plast Surg 1996;49(7):447-451. [http://dx.doi.org/10.1016/S0007-1226(96)90028-4]
22. Rudolph R, Niedbala AR. Surgical management of the patient with invasive carcinoma discovered at reduction mammoplasty. Am Surg 2003;69(11):1003-1005.
23. Golshan M, Lesnikoski BA, Lester S. Sentinel lymph node biopsy for occult breast cancer detected during breast reduction surgery. Am Surg 2006;72(5):397-400.
24. McPherson K. Screening for breast cancer – balancing the debate. BMJ 2010;340:c3106. [http://dx.doi.org/10.1136/bmj.c3106]
25. Screening for breast cancer: US Preventive Services Task Force recommendation statement. Ann Intern Med 2009;151(10):716-736. [http://dx.doi.org/10.7326/0003-4819-151-10-200911170-00008]
26. Keshtgar M, Hamidian Jahromi A, Davidson T, et al. Tissue screening after breast reduction. BMJ 2009;338:b630. [http://dx.doi.org/10.1136/bmj.b630]

Accepted 13 February 2015.

Appendix B – Ethics Approval

R14/49 Dr Chrysis Sofianos

HUMAN RESEARCH ETHICS COMMITTEE (MEDICAL)

CLEARANCE CERTIFICATE NO. M140239

NAME: (Principal Investigator)	Dr Chrysis Sofianos
DEPARTMENT:	Surgery Helen Joseph Hospital Chris Hani Baragwanath Academic Hospital
PROJECT TITLE:	Pathologic Findings in Reduction Mammaplasty Specimens: A South African Perspective (Changed Title 30/05/2014)
DATE CONSIDERED:	28/02/2014
DECISION:	Approved unconditionally
CONDITIONS:	
SUPERVISOR:	Dr R Zinn, Dr D Geoffreys and Dr D Kruger
APPROVED BY:	Professor P Cleaton-Jones, Co-Chairperson, HREC (Medical)
DATE OF APPROVAL:	14/03/2014

This clearance certificate is valid for 5 years from date of approval. Extension may be applied for.

DECLARATION OF INVESTIGATORS

To be completed in duplicate and **ONE COPY** returned to the Secretary in Room 10004, 10th floor, Senate House, University.
I/we fully understand the conditions under which I am/we are authorized to carry out the above-mentioned research and I/we undertake to ensure compliance with these conditions. Should any departure be contemplated, from the research protocol as approved, I/we undertake to resubmit the application to the Committee. **I agree to submit a yearly progress report**.

Principal Investigator Signature Date

PLEASE QUOTE THE PROTOCOL NUMBER IN ALL ENQUIRIES

Appendix C – Supervisor Declaration

02 March 2015

Attention: Faculty of Health Sciences, University of the Witwatersrand

Re: Pathological Findings in Reduction Mammaplasty Specimens

This letter serves to certify that Chrysis Sofianos is the primary author of the above-entitled research. It has been approved for publication to the South African Medical Journal.

It is sufficient for consideration as a published paper towards the research component of his MMed degree at the University of the Witwatersrand.

His contribution to the research was as follows

- Protocol write-up, submission thereof and presentation to the Faculty of Health Sciences
- Ethics application
- Collection of data, entry into relevant processing programs and ultimate data analysis
- Research write-up
- Formatting for submission to the journal
- Communication with the journal editor and refining of review points

As supervisors of the research project, we reviewed the research at regular intervals, made changes to improve the write-up and verified the data analysis.

We agree that the research was the work of Chrysis Sofianos, assisted and refined by us.



RJ Zinn
richard.zinn@gmail.com



DA Geoffreys
dale.geo@gmail.com



D Kruger
Deirdre.Kruger@wits.ac.za

Appendix D – Data Collection Form

Study Number: _____

Age _____ Study Group (1,2,3) _____

Female or Male _____ Hospital CHBAH or HJH

Preoperative history of breast ca YES / NO

Preoperative screening Clinical Breast Exam / Mammography / Breast Ultrasound

Surgery

Reduction mammaplasty YES / NO Standard technique used YES / NO

Laterality Right breast / Left breast / both

Pathology

Pathology lab number _____

Weight of specimen Left _____ Right _____

Macroscopy Not reported / Normal / Benign Disease / Malignant Disease

Microscopy Not reported / Normal / Benign Disease / Malignant Disease

Specific Microscopic Finding

- Fibrocystic disease LEFT BREAST / RIGHT BREAST / BOTH
- Sclerosing adenosis LEFT BREAST / RIGHT BREAST / BOTH
- Ductal hyperplasia without atypia LEFT BREAST / RIGHT BREAST / BOTH
- Microcalcification LEFT BREAST / RIGHT BREAST / BOTH
- Fibroadenoma LEFT BREAST / RIGHT BREAST / BOTH
- Ductal ectasia LEFT BREAST / RIGHT BREAST / BOTH
- Lipoid necrosis LEFT BREAST / RIGHT BREAST / BOTH
- Atypical ductal hyperplasia LEFT BREAST / RIGHT BREAST / BOTH
- Ductal carcinoma in situ LEFT BREAST / RIGHT BREAST / BOTH
- Ductal papillomatosis LEFT BREAST / RIGHT BREAST / BOTH
- Intraductal papilloma LEFT BREAST / RIGHT BREAST / BOTH
- Invasive ductal carcinoma LEFT BREAST / RIGHT BREAST / BOTH
- Invasive lobular carcinoma LEFT BREAST / RIGHT BREAST / BOTH

Entered into Excel YES / NO