

https://dspace.org/

A retrospective audit of computed tomography angiography in penetrating wound of lower limb at Chris Hani Baragwanath Academic Hospital

Abid, Rabia

2024
https://hdl.handle.net/10539/37905

Downloaded from a DSpace repository. https://dspace.org/

A Retrospective audit of Computed Tomography Angiography in penetrating wound of lower limb at Chris Hani Baragwanath Academic Hospital

Dr Rabia Abid

A research report submitted to the Faculty of Health Sciences, University of the Witwatersrand, Johannesburg, in partial fulfilment of the requirements for the degree of Master of Medicine in Diagnostic Radiology

Johannesburg, March 2023

Declaration

I, Rabia Abid, declare that this research report is my own, unaided work. It is being submitted for the Degree of Master of Medicine in the branch of Diagnostic Radiology at the University of the Witwatersrand, Johannesburg. It has not been submitted before for any degree or examination at this or any other University.

Rabia Abid (electronically signed)
On this 24th day of March 2023.

Dedication

To those who mean the most to me: my mother Soogran Begum, my father Abid Hussain and my kids Abdullah, Zainab and Zahra.

Special thanks to my husband for helping me attain my life’s achievements and supporting me during tough times of my life.

May I forever make you all proud.

Presentations and Publications

This work has never been published and it has never been presented at a congress or conference.

Abstract

INTRODUCTION:

There is high rate of violence-related injuries in South Africa. These injuries include gunshot wounds, stab wounds and blunt force trauma. Many patients with penetrating wounds present in the emergency department with vascular injuries. Penetrating wounds of lower limbs with or without arterial injuries are managed according to trauma protocols. Patients presenting hard signs vascular injury are transferred to theatre for immediate exploration and repair. Patients with soft signs are clinically examined and, if indicated, imaging is planned. Clinical examination is crucial in diagnosing arterial injuries in penetrating limb injuries and Ankle-Brachial index (ABI) is an important parameter to rule out arterial injuries. Doppler ultrasound is a good, non-invasive imaging modality but is operator dependent. Computed Tomography Angiography (CTA) has excellent outcomes in diagnosing arterial injuries in penetrating wounds of lower limb, with a sensitivity and a specificity close to 100%. CTA is a non-invasive, rapid, and reliable modality, but subjects the patient to radiation exposure. This study aimed to determine the prevalence and type of vascular injuries in penetrating injuries of lower limb in on South African academic hospital.

METHOD:

A retrospective audit of CTAs done for penetrating wounds of lower limbs to rule out vascular injuries at Chris Hani Baragwanath Academic Hospital (CHBAH) was executed. Data of CTAs performed from January 2017 to December 2018 were retrieved from the imaging PACS of the CHBAH radiology department. Ethics approval was obtained from HREC of the University of Witwatersrand, and data was captured from the relevant records.

RESULTS:

Descriptive statistics were used to describe the characteristics of the population, in the form graphs and figures. Data of 91 CTAs were collected. The average age of subjects was 32.2 years, and 83 of the cohort were males. The most common mechanism of injury was a gunshot wound. Only one case out of 91 of the collected CTAs was positive for arterial injury.

CONCLUSIONS: Low rate of positive CTA studies over span of a 2-year period emphasizes the need for thorough examination for the suitability of a CTA. This approach avoids unnecessary radiation exposure to the patients and is cost effective. In low-risk patients, doppler ultrasound should be considered for imaging of potential arterial injuries and has no radiation exposure. The use of lower threshold value of ABI is an option for patients presenting with soft signs of arterial injuries. Revising the management protocol for penetrating injuries of lower limb used by trauma surgeons at CHBAH for requesting CTAs will be cost effective by avoiding unnecessary imaging.

Acknowledgements

Firstly, I am thankful to my mentor and Academic head of department Prof Nasreen Mahomed. She has been a fantastic mentor to me and has had a big impact on my career and the way I practice. She has a wealth of knowledge and is a valuable asset to the department.

I would also like to thank my supervisors Dr Grace Rubin, Prof AA Aden and Prof SK Magobotha for all their assistance, guidance and friendship. The completion of this study would not have been possible without their input. I have learned a lot through this process.

Table of Contents

Declaration ii
Dedication iii
Presentations and Publications iv
Abstract v
Acknowledgements vii
Table of Contents viii
List of Tables x
List of Abbreviations and Terminology xi
1.Introduction 12
1.1 Aim of Study 21
1.2 Study Objectives 21
2.Methods 22
2.1 Research Questions 22
2.2 Research Design 22
2.3 Selection of Participants 22
2.4. Inclusion and Exclusion criteria 23
2.5. Data Collection 23
2.6. Data management and analysis 23
2.7. Statistical analysis 24
2.8. Ethics 24
3.Results 25
4.Discussion 31
5.Limitations and recommendations 33
6.Conclusion 34
7.References 35
Appendix A: Ethics Clearance Certificate 39
Appendix B: Data Link Sheet 37
Appendix C: Data Collection Sheet 38

List of Figures

Figure 1.1	Treatment protocol for patients with arterial injuries	14
Figure 1.2	Treatment protocol in patients presenting with penetrating lower limb injuries	15
Figure 1.3	Normal spectral waveform of common femoral artery with triphasic pattern	17
Figure 1.4	Doppler ultrasound study	18
Figure 1.5	Patient with stab wound showing active extravasation of contrast from radial artery	20
Figure 1.6	Ulnar artery pseudoaneurysm in penetrating trauma from sharp object.	20
Figure 1.7	AP and Lateral radiographs of right knee with lateral and posterior knee dislocation and maximum intensity projection	20
Figure 1.8	Vasospasm and venous thrombus	20
Figure 1.9	Transverse hypodense linear focus extending into lumen near the junction of axillary with brachial artery showing small intimal injury	21
Figure 3.1	Ratio of male to female referred for CTA following penetrating extremity wound	26
Figure 3.2	Mechanism of injury referred to Radiology for penetrating extremity trauma.	27
Figure 3.3	Number of associated fractures in patients with penetrating extremity wound	28
Figure 3.4	*Associated fracture*s *in patient*s *with penetrating wounds of lower extremity*	28
Figure 3.5	Clinical information provided on CTA request form	29
Figure 3.6	Anatomical location of gunshot wounds	30

List of Tables

Table 1.1	Hard and Soft signs of vascular injuries in penetrating wound of lower limb	12
Table 2.1	Sample Size for Frequency in a Population	23
Table 2.1	Inclusion and Exclusion Criteria	23
Table 3.1	Demographic Summary	26

List of Abbreviations and Terminology

ABI	Ankle-brachial index
CHBAH	Chris Hani Baragwanath Academic Hospital
CTA	Computed Tomography Angiography
DSA	Digital Subtraction Angiography
HREC	Human Research Ethics committee
PACS	Picture Archiving and Communication System
PET	Penetrating extremity trauma

1. Introduction

Injuries and violence are among the major causes of death and permanent disability in South Africa.[1] Gender-based and interpersonal violence are the predominant cause of injury, followed by falls, self-inflicted injuries, and road traffic injuries[1]. Young men are predominantly involved in violence both as perpetrators, and as victims; and most femicide are perpetrated by male partners. Several social factors are the driving forces of the interpersonal violence problem in South Africa.[1]

Easy access to weapons, like knives and firearms, is one major cause of penetrating injuries in South Africa.[1-3] Two thirds of victims sustaining gunshot wounds need surgical treatment; more than a third of patients require surgical treatment in knife injuries; and the rate of operation is 19% for stab injuries of lower and upper limb.[1,2] Peripheral vascular injuries are the main indication for surgery in penetrating wounds of the upper and or lower limb.[1]

Penetrating injuries of limbs can be devastating. They range from minor wounds to complex limb injuries that may lead to an amputation, depending on amount of force being transferred to soft tissue envelope of lower limb. Three quarters of arterial injuries occur as a consequence of penetrating trauma, while only a quarter manifest because of blunt trauma.[4] The amount of penetrating force into tissue determines whether the result will be a minor wound or complex injury to the limb.

Clinical examination is critical to document soft and hard signs of arterial injuries. Hard signs of arterial injuries include active haemorrhage, rapidly expanding haematoma, absent pulses, palpable thrill, audible bruit, and hypovolemic shock with ongoing bleeding. Soft signs of vascular injuries are non-expanding haematoma, diminished pulses, neurologic injury, or juxtaposition of wound to an artery (Table 1.1).

Table 1.1: Hard and Soft signs of vascular injuries in penetrating wound of lower limb

Hard signs	Soft signs
Arterial bleeding	Injury to adjacent nerve
Hypovolemic Shock	Non-expanding haematoma
Expanding haematoma	Decrease pulse
Absent pulse	History of active bleeding
Ischemic limb	Penetrating wound in juxtaposition to major vessel
An audible bruit or thrill	

Whether a patient presents with hard or soft signs of an arterial injury depends on the type of arterial injury. There are different types of vascular injuries, including arterial spasm, intimal tear, total wall defect, pseudoaneurysm, and arteriovenous fistula. Femoral, popliteal, and brachial arteries are the most common arteries injured in penetrating wounds.[4,5]

Peripheral vascular injuries can cause devastating complications including, but not limited to, the loss of a whole or portion of a limb distal to the peripheral vascular injury, multiple organ failure due to pre-hospital blood loss, and death due to massive blood loss. The loss of a limb in peripheral vascular injuries can be caused by delays in diagnosis, reperfusion injuries, severe bone and soft tissue injuries, and complications of repair. Treatment of peripheral vascular injuries in penetrating wounds of the lower limb starts at the scene of the accident, by applying direct pressure and resuscitation, according to Advanced trauma life support (ATLS) principles. Any displaced fracture or dislocation with signs of peripheral vascular injury should be reduced and splinted. Peripheral vascular examination should be repeated and compared with the contralateral limb[5] (Figure 1.1).

Figure 1.1 Treatment protocol for patients with arterial injuries

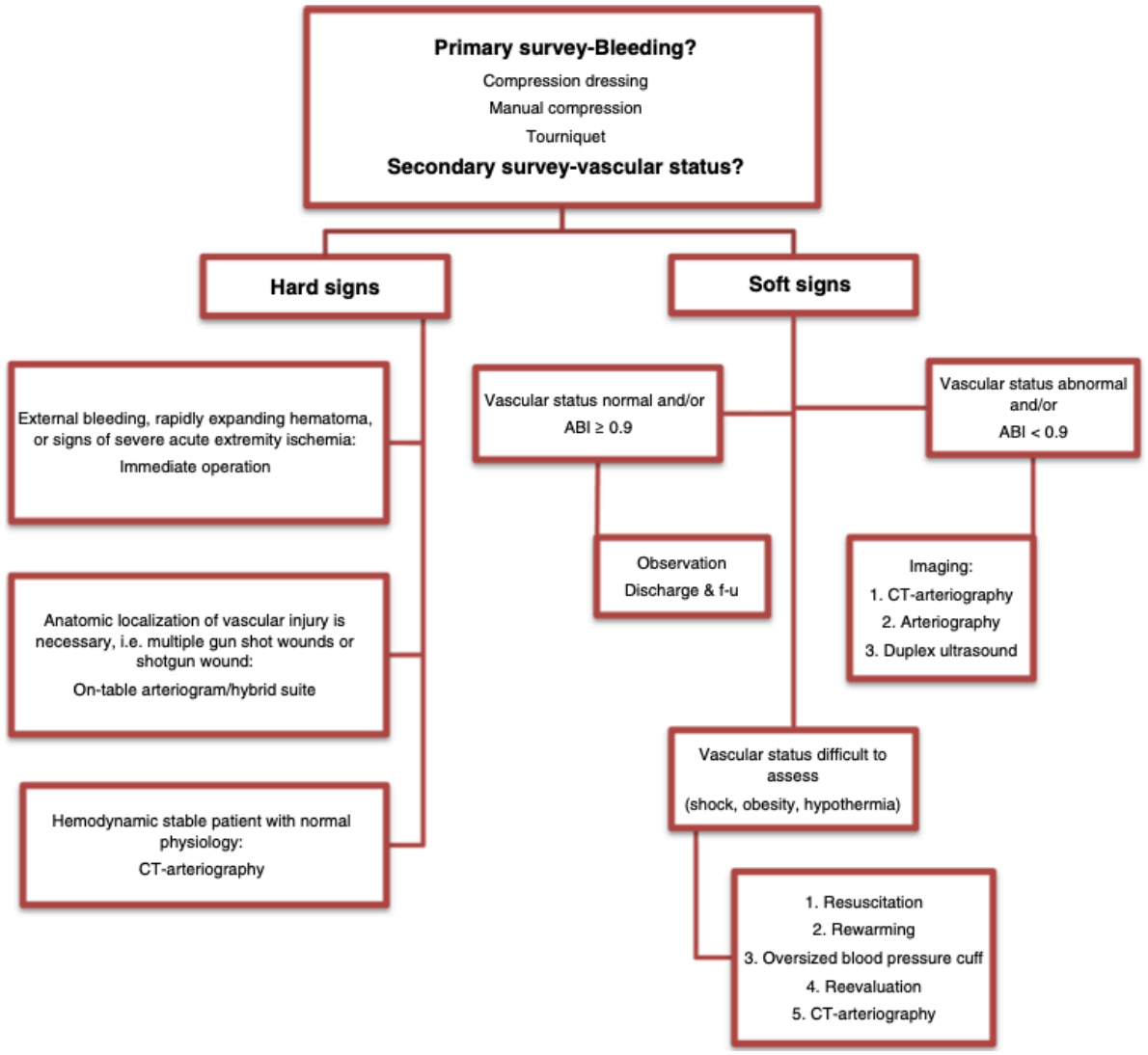

Showing algorithm of treatment protocol for patients with arterial injuries having hard or soft signs, modified from Western Trauma Association.[4]

With an absence of hard signs indicating an arterial injury, most patients are observed for 24 to 48 hours, then discharged. On the other hand, patients presenting with hard signs of arterial injuries may need an urgent surgical procedure in case of life-threatening active bleeding, a rapidly expanding haematoma, or the occlusion of a major artery. These presentations do not necessitate any imaging, but the patient should be transported to theatre urgently to perform an angiogram on the table and appropriately attend to the injury.[4,5] The Western Trauma Association published treatment guidelines depending on type of arterial injury, bony involvement, and physiological status of patient (Figure 1.2).

Figure 1.2 Treatment protocol in patients presenting with penetrating lower limb injuries

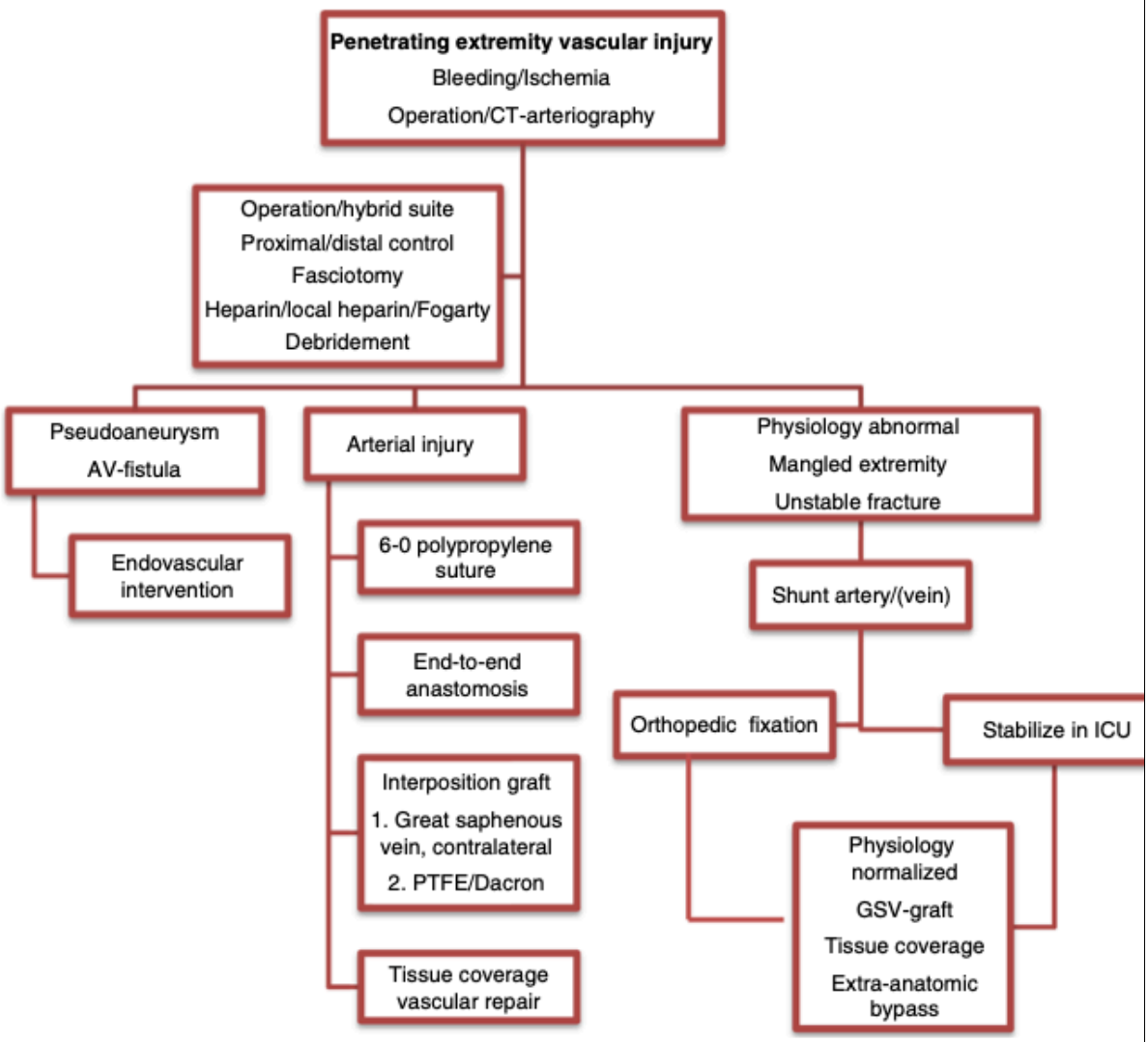

Modified from Western Trauma Association.[4]

Physical examination is critical in diagnosing arterial injuries in penetrating wounds of the lower limb with a specificity and a sensitivity of 93.85% and 95.3% respectively – this is higher for lower limbs compared to upper limbs. A retrospective study by Le Roux et al. established the importance of physical examination in penetrating wounds of limbs.[7] 345 patients with penetrating wounds underwent clinical examination, and vascular injuries were missed in 5 patients only, 3 of them not requiring surgical repair[7]. The specificity of physical examination of arterial injuries in gunshot wounds was higher than that of stab wounds.

Frykberg et al. found that physical examination of penetrating extremity trauma patients is cost effective, safe, and reliable in ruling out an arterial injury.[8] Physical examination alone had a positive predictive value close to 100%, as 21 out of 23 patients with penetrating extremity trauma who underwent surgical intervention were

initially detected by physical examination. All patients with negative physical examination were observed for 24 hours before discharge and only 2 out of 286 vascular injuries were missed, with a 0.7% false negative value.

One common recommendation in patients with soft signs is to carry out physical examination every 4 to 6 hours over a period of 24 hours after admission. A preeminent clinical test to rule out peripheral arterial injuries in penetrating lower limb trauma patients without hard signs is the ankle-brachial index (ABI). Several studies have shown the importance of ABI in ruling out arterial injuries without hard signs, as well as informing decisions to perform further imaging to confirm diagnosis of arterial injuries in patients with soft signs of peripheral vascular injuries. In the absence of hard signs on clinical examination, an ABI value of <0.9 carries a sensitivity of 87% and a specificity of 97%. These figures climb up to 95% and 97% respectively after excluding patients with clinically insignificant arterial injuries. Sadjadi and colleagues published data of 182 patients with penetrating wounds of the lower limbs, all of whom had an ABI of >0.9 and only one out of 182 had delayed presentation of compartment syndrome two days after discharge.[6] They concluded that ABI has 100% specificity in predicting safe discharge in penetrating extremity trauma without hard signs of vascular injuries. Physical examination without hard signs of vascular injury and ABI value of >0.9 are sufficient to discharge a patient from hospital.[6,8]

There is a substantial link between arterial injury in penetrating lower limb trauma and ABI value to diagnose arterial injury, avoiding costly investigations and radiation exposure. There is a debate in literature on <0.9 value of ABI as threshold in penetrating lower limb trauma - whether to lower ABI threshold value of <0.9 to <0.7, or <0.6, to predict arterial injuries in patients with soft signs of vascular injuries. No prospective studies have been performed to test reliability of this, though some literature has shown that lowering to an ABI threshold value of <0.7 was more accurate. No vascular injuries were missed when a lower threshold value of ABI (<0.6) was used and this also has also been established to be the most precise threshold, with highest combined sensitivity and specificity .[6,8-10]

There is a major predicament of false negative results in penetrating lower limb trauma if they lead to missed vascular injuries requiring repair, risking loss of a limb for patients. It will be vital to uncover outcomes of patients with ABI value of >0.7 and that were managed non-operatively. In the literature, there is no available data for those patients who sustained vascular injury needing repair but had normal ABI value.[6,9,10]

Different radiological diagnostic modalities are available to diagnose vascular injuries in penetrating wounds of the lower limbs. These include Catheter angiography, doppler ultrasound, and CTA. Each modality has its own disadvantages and advantages. For example, when compared to an angiogram, the doppler ultrasound has a high sensitivity and an acceptable specificity, with the added advantage of being inexpensive and non-invasive (Figure 1.3).

Figure 1.3: Normal spectral waveform of common femoral artery with triphasic pattern

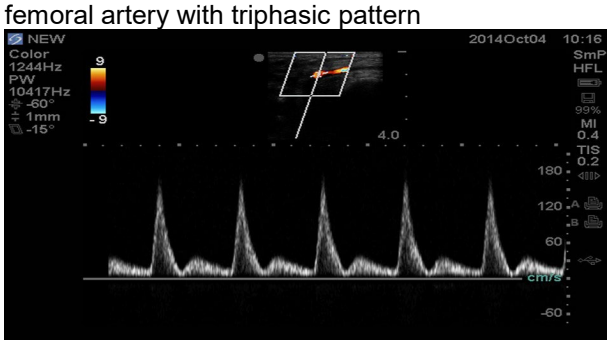

Normal peak systolic velocity and end diastolic velocity, normal spectral width, and no reversal of blood flow.[12]

Angiography in literature has proven sensitivity and specificity of 100% and 98% respectively. Pezeshki Rad et al compared angiography with doppler ultrasound and concluded that sensitivity and specificity of doppler ultrasound is 94.8% and 91.6%, respectively. However, they identified few scenarios with obscured normal findings, like an artery pushed away from its normal position by a fracture haematoma, arterial spasm, arterial injury not detected because of the dressing over the area being too thick to perform doppler ultrasound and opening up of collateral arteries leading to normal patterns on doppler ultrasound.[11,12]

Technically, doppler ultrasound is operator dependent. The low penetration with high resolution by high frequency linear transducer is all that is needed to diagnose an arterial injury. Normal arteries are round, compared to veins, which are oval, and they are noncompressible and have echogenic walls. Arteries show triphasic pattern (Figure 1.3) in pulse doppler spectrum comprised of systolic closure of the aortic valve and elasticity of the arterial wall, respectively. Acute loss of triphasic pattern due to disappearance of the third phase is caused by injury or obstruction and indicates arterial injury (Figure 1.4). Obesity, haematoma, thick dressings, emphysema, and large open wounds are technical limitations to the penetration of sound waves, and therefore can be a misleading factor in diagnosis of arterial injuries in penetrating lower limb injuries.[12]

Figure1.4: Doppler ultrasound study

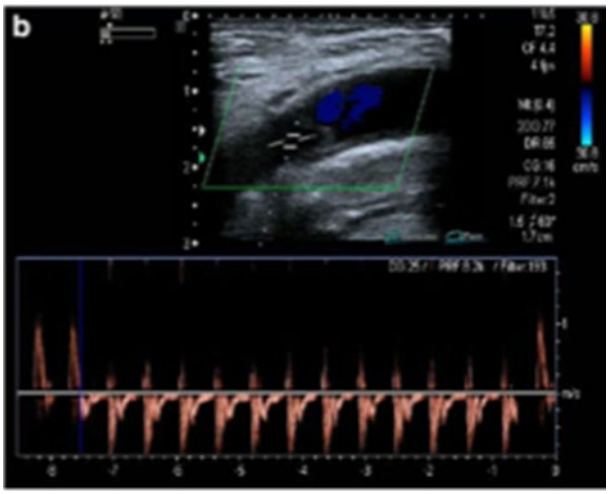

Echogenic flap into lumen of femoral artery in keeping with an intimal flap of a femoral artery with change in direction of flow and turbulence near the moving intimal flap.
No aneurysm, pseudoaneurysm or thrombosis of vessel.[12]

Computed tomography angiography has gained popularity as a diagnostic tool for arterial injuries in penetrating lower limb injuries. Several studies have shown excellent sensitivity and specificity for CTA to diagnose arterial injuries. Inaba et al. documented findings of CTA against doppler ultrasound, catheter-based angiography and intraoperative findings. In 62 cases out of 63 CTAs done, positive CTA findings were confirmed intraoperatively by operating surgeons, showing excellent sensitivity of CTA to diagnose arterial injuries.[13] CTA is a non-invasive, cost-effective imaging modality and has less complications when compared to catheter angiography. Furthermore, it limits the need of conventional angiography to diagnose arterial injuries.

Conventional angiography carries a high cost and the inevitable delay caused by wating for an interventional radiologist coming from home, for example, especially after hours. There is a high complication rate, compared to CTA. This includes haematoma formation, arterial thrombosis, pseudoaneurysm, cholesterol embolization, contrast-induced allergic reaction, and renal insufficiency, among others. Compared to conventional angiography, CTA is rapid and has low complication rate, permitting the screening of multiple areas at the same time. There are other shortfalls with CTA, however - high radiation exposure, inconclusive diagnosis of arterial injuries due to artifacts produced by bony or bullet fragments, and flawed timing of contrast injection causing inadequate arterial imaging.[13-17]

There are different contrast injection techniques used in CTA to detect peripheral vascular injuries in penetrating lower limb injuries, namely the bolus

tracking technique, test bolus technique, and fixed time delay. The volume of contrast used depends on the area being examined and the size of patient. Non-ionic iodine is used as a contrast medium by volume between 100ml-150ml of 350mgI/ml. Image acquisition timing is usually calculated using the different contrast techniques - bolus tracking is the most frequently used. Deciding on acquisition timing is influenced by many factors. These include time to peak, test bolus, coverage of image, cardiac output, saline bolus, image duration, injection site, and location of target vessel.[18-20]

Computed tomographic imaging has three phases to diagnose arterial injuries: non-contrast, arterial, venous, and delayed phase. The non-contrast phase has significant efficacy in assessing intramural haematoma of aorta. Arterial phases provide great utility in assessing arterial lumen, thus diagnosing varieties of arterial injuries, while venous phase gives information regarding small vessels and slower, low-volume haemorrhage. Evaluating both axial as well as reformatted CTA provides the best information in diagnosing various types of arterial injuries. Signs of arterial injuries in CTA images include active extravasation of contrast material (Figure 1.5), arteriovenous fistula formation as well as pseudoaneurysm (Figure 1.6), lack of opacification of an arterial segment (Figure 1.7), abrupt narrowing of an artery or vasospasm (Figure 1.8), and intimal injury (Figure 1.9).[18,19,20]

Figure1.5: Patient with stab wound showing active extravasation of contrast from radial artery.



Maximum intensity projection images in coronal section showing contrast accumulating between the arterial 'a' and delayed 'b' phase images.[19]

Figure1.6: Ulnar artery pseudoaneurysm in penetrating trauma from sharp object.

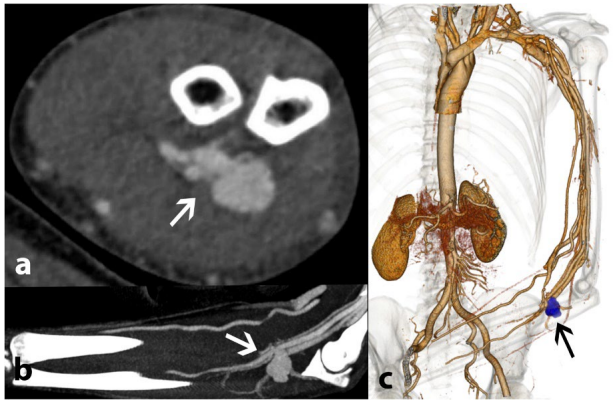

Axial, sagittal and 3D reconstruction images from a CTA image showing a focal contrast-filled pouch with early opacification of adjacent vein in keeping with both pseudoaneurysm and arteriovenous fistula.[19]

Figure1.7: AP and Lateral radiographs of right knee with lateral and posterior knee dislocation and maximum intensity projection

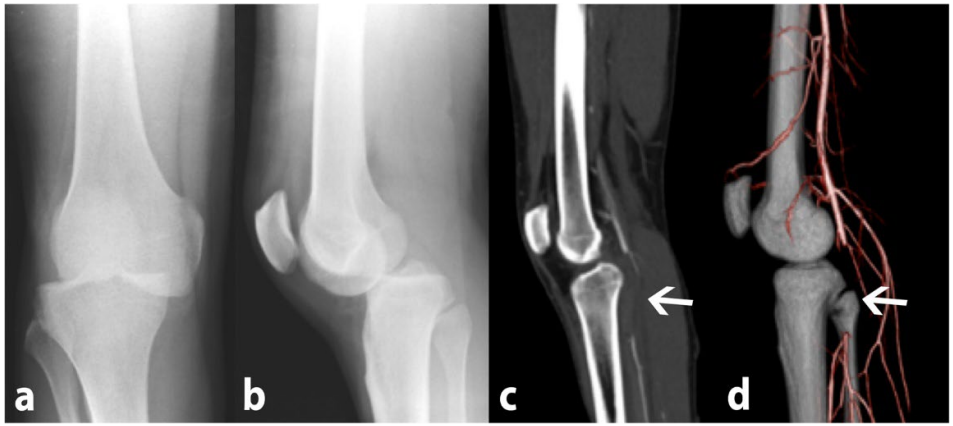

CTA images and 3D images showing complete cut off of popliteal artery secondary to occlusion and reconstitution of tibial arteries.[19]

Figure1.8: Vasospasm and venous thrombus.

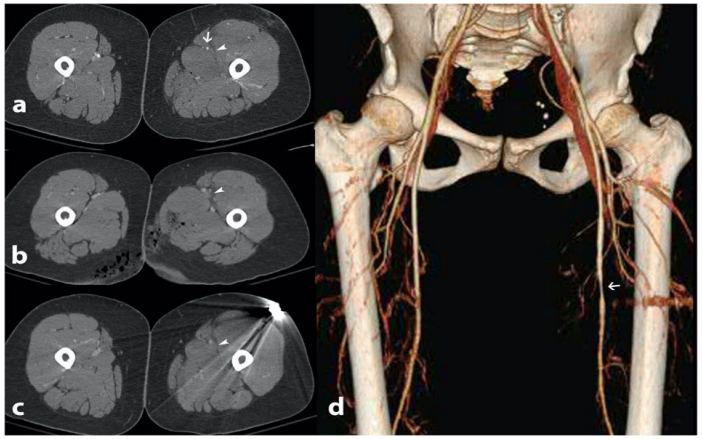

There is moderate to severe narrowing of the mid left superficial femoral artery.[19]

Figure1.9: Transverse hypodense linear focus extending into lumen near the junction of axillary with brachial artery showing small intimal injury.



There is normal opacification of artery proximal and distal to intimal injury and no arterial thrombus formation.[19]

1.1 Aim of Study

To determine the prevalence and pattern of arterial injuries in CTA done for penetrating wounds of the lower limbs at Chris Hani Baragwanath Academic Hospital (CHBAH).

1.2 Study Objectives

To determine the prevalence of arterial injuries in penetrating injuries of the lower limbs referred to the Radiology Department for CTA at CHBAH.

To determine patterns of arterial injuries in penetrating injuries of the lower limbs being evaluated by CTA at the Radiology Department of CHBAH.

2. Methods

2.1 Research Questions

What is the prevalence of arterial injuries in penetrating injuries of the lower limbs referred to Radiology Department for CTA at CHBAH?
What are the patterns of vascular injuries in penetrating injuries of the lower limbs being evaluated by CTA at Radiology Department at CHBAH?

2.2 Research Design

A retrospective study was employed to analyse frequencies and patterns of CTA performed at the Radiology Department of CHBAH for patients presenting with penetrating wounds of the lower limbs at the Emergency Department. All records of CTAs done for patients with penetrating injuries of the lower limbs were retrieved from the imaging Picture Archiving and Communication System (PACS) of the Radiology Department.

2.3 Selection of Participants

Once the research proposal was accepted, ethics approval was obtained from the Human Research Ethics committee (HREC) of the University of Witwatersrand. Records were retrieved from the imaging PACS about patients who presented with penetrating trauma to the lower limbs at CHBAH Emergency Department, referred to Radiology department for the lower limb CTA. All patients presenting with penetrating lower limb trauma at CHBAH Emergency Department referred to Radiology Department for lower limb CTA from 01/01/2017 to 31/12/2018 were included in this study. No patients below the age of 18 year were referred by trauma unit in this period. Patients who underwent CTA for blunt extremity trauma were excluded.

Frykberg et al. suggest an appropriate confidence interval of 95%, and thus, using a similar method to determine sample size (Table 2.1), the sample for this study needed to ideally be 158 patients.

Table 2.1: Sample Size for Frequency in a Population	
Population size (for finite population correction factor or fpc) (*N*):	1000000
Hypothesized % frequency of outcome factor in the population (*p*):	11.6%+/-5
Confidence limits as % of 100(absolute +/- %) (*d*):	5%
Design effect (for cluster surveys-*DEFF*):	1

Sample Size(*n*) for Various Confidence Levels	
Confidence level (%)	Sample size
80%	68
90%	111
95%	158
97%	194
99%	273
99.9%	444
99.99%	621

Equation

Sample size n = [DEFF*Np(1-p)]/ [($d^2/Z^2_{1-\alpha/2}$*(N-1)+p*(1-p)]

2.4. Inclusion and Exclusion criteria

Table 2.2: Inclusion and Exclusion Criteria

Inclusion Criteria	Exclusion Criteria
1. All patients presenting with penetrating wounds of the lower limbs who had CTA performed in the Radiology Department at CHBAH.	1. Patients without consultant approved reports. 2. Poor quality non-diagnostic scan. 3. CTA done for blunt lower limb trauma. 4. CTA done for chronic peripheral vascular disease.

2.5. Data Collection

The data was collected on a data link sheet (Appendix A) from the imaging PACS and then captured on a data collection sheet for analysis (Appendix B). Each patient was assigned a unique code assure anonymity. Data regarding date, gender, age, mechanism of penetrating injury, and associated injuries were collected. The corresponding CTA images of the patients were retrieved from the imaging PACS and analysed in terms of the vascular injuries. Other relevant details were captured, like if the patient was hemodynamically stable or not, and other clinical findings to motivate for study written on the CTA request form.

2.6. Data management and analysis

Data was entered into an Excel spreadsheet from the data collection sheets. Data cleaning processes included checking for duplicates, missing values, recoding and categorizing variables. This served as a quality assurance process.

This digital data was imported into STATA Version 15 (Stata Corp) for statistical analysis. Descriptive statistics were calculated.

2.7. Statistical analysis

To compare the different categories, proportions and percentages were used to summarize the categorical variables. The summary of continuous variables used the mean and the standard deviation, or median with interquartile range. Graphs were generated, and Orange version 3 was used for text analysis.

2.8. Ethics

The study was approved by the Human Research Ethics Committee of the University of the Witwatersrand, approval number M190401 (Appendix C).

3. Results

All patients were initially resuscitated according to ATLS guidelines and protocol set by the Department of Trauma at CHBAH. According to the local trauma protocol, a full history is taken, and a thorough problem-oriented clinical examination is undertaken for those patients who are haemodynamically stable at presentation, and for those who become stable after successful resuscitation. Based on the history and the clinical examination, further investigations are done if needed, for example, x-rays of limbs, spine, chest, pelvis etc. For gunshot injuries of the lower limbs, X-rays of the affected limb are routinely done.

Findings from history and clinical examination dictate whether CTA of lower limb is performed for penetrating limb trauma. Difference of systolic pressure of normal limb and injured limb are used at CHBAH by trauma surgeons instead of ABI. Haemodynamically unstable patients and patients with hard signs of arterial injuries are transferred straight to the operating theatre, where exploration with repair is undertaken. Patients who are haemodynamically stable, and with negative history and clinical examination but suspicion of a vascular injury, are referred to the Radiology Department for CTA.

After 24 hours of observation, if there are no complications or other injuries, patients are discharged. All patients receive instructions to watch for alarming symptoms and signs of vascular injuries (e.g., expanding haematoma, loss of pulse, pallor, cold limb or sensory loss and eventually loss of function of the affected limb) and general signs of infection (erythema, swelling, warmth). If any one of these occur, they are encouraged to return to the health care facility immediately. The details of this protocol were obtained from a Consultant Trauma surgeon at CHBAH as no written protocol was available.

A total of 91 CTAs were included in this study. Of these, 83 (91%) were male and 8 (9%) were female. Six of the 8 females sustained gunshot injuries, while one had a fall and sustained a penetrating wound. The last woman’s injury was caused by an object falling on her thigh. Out of 83 males, 40 sustained gunshot injuries, 30 had stab wounds, and the rest were penetrating injuries secondary to PVA, history of object falling on the thigh, and a fall from a height.

Figure 3.1: Ratio of male to female referred for CTA following penetrating extremity wound

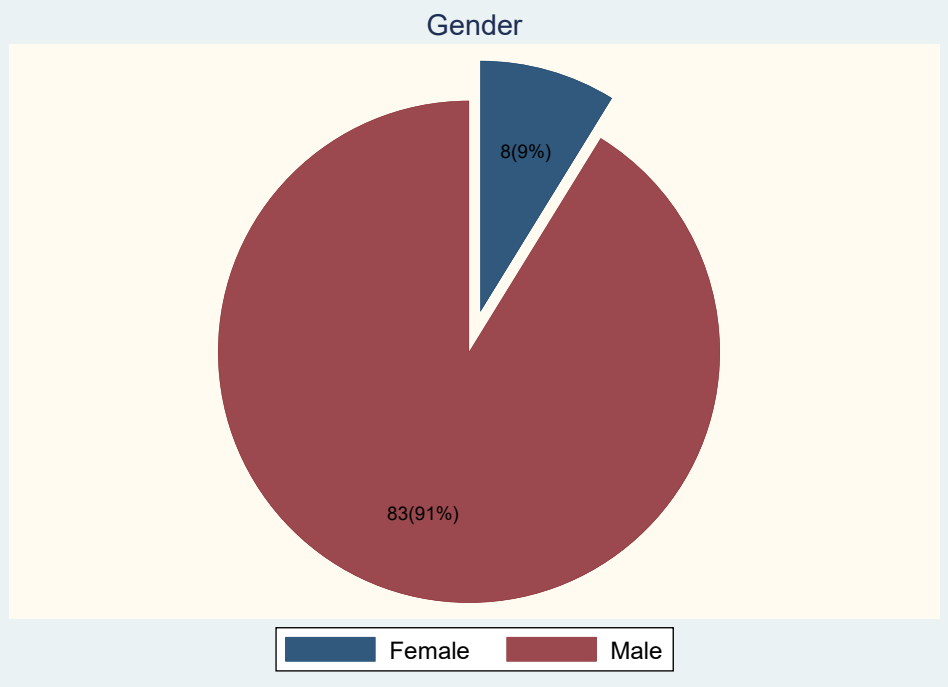

The mean age of the study population was 32.2 with standard deviation of 7.8. The 30-39-years-old age group made up just over half of the sample. The CTA report showed a single (1%) vascular injury. The main mechanism of injury in these patients was a gunshot at 71 (78%), followed by stabbing 12 (13%). Pedestrian vehicle accidents tied with falls as second least common mechanism of injury. Other mechanisms were a fall, either from a height or of an object landing on the thigh. Most patients sustained the injury on the left or right, with 41 (45%) patients in each group.

Table 3.1: Demographic Summary

Variable	**Mean**	**SD**
Age	32.2	7.8
Age category	**N**	**%**
19-29	33	36
30-39	47	52
40-49	9	10
50-59	0	0
60+	2	2
Total	91	100
Sex	**N**	**%**
Female	8	9
Male	83	91
Vascular Injury	**N**	**%**
No	90	99
Yes	1	1
Mechanism of injury	**N**	**%**

Gunshot + stab	1	1
Fall	2	2
Pedestrian Vehicle Accident	2	2
Motor Vehicle Accident	3	4
Stab	12	13
Gunshot	71	78
Side of injury	**N**	**%**
Left	41	45
Left and right	9	10
Right	41	45

The sole vascular injury was a gunshot to the right thigh. The predominant group with gunshots and no vascular injury was the 30-39 age group, with 17 (24%) males wounded on the left, and 13 (19%) on the right. Most stabbed patients were in the 19-29-year-old group, 3 males wounded on the right (25%). There were 3 patients stabbed on the left side, in the 30-39-year-old group (25%) (Figure 3.2).

Figure 3.2: Mechanism of injury referred to Radiology for penetrating extremity trauma.

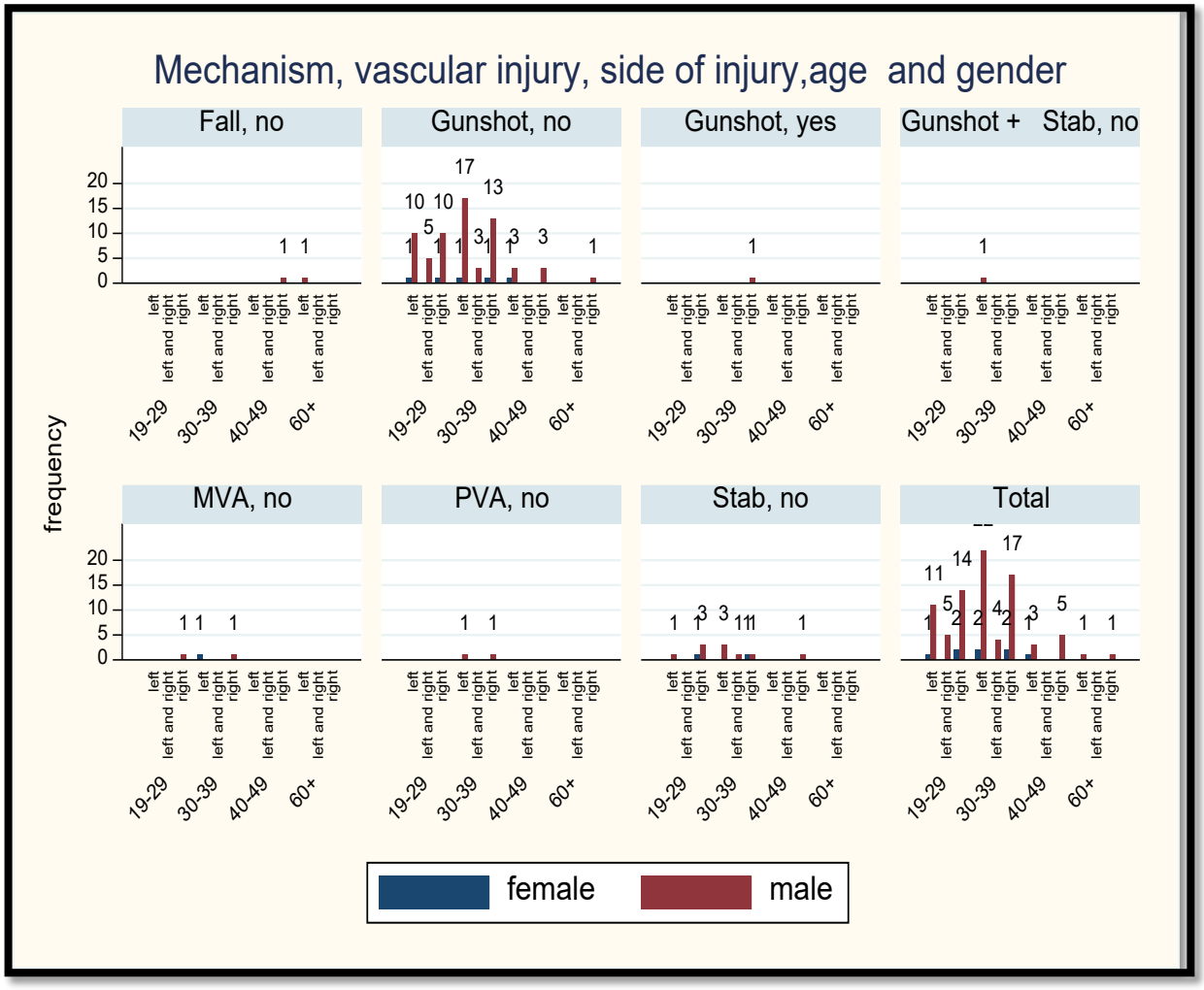

Stratifying the data by age, side of injury, vascular injury experienced, and gender (Figure 3.3), showed that the right side was most affected in all age

categories, except in the 30-39 years category 16 (34%) in comparison to left 22 (47%).

Figure 3.3: Number of associated fractures in patients with penetrating extremity wound

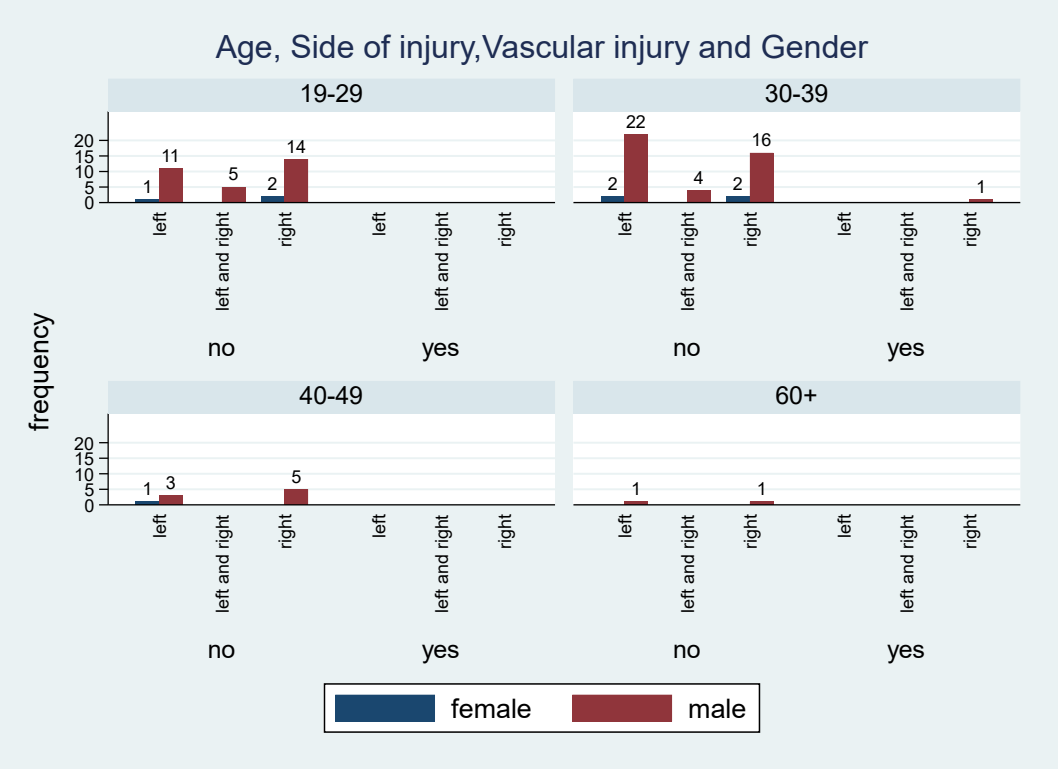

For associated fractures, the frequency of no fracture sustained was 53 distal femur fracture 8 followed by midshaft femur fracture with 3. There were 2 tibia and 1 fibula fractures (Figure 3.4).

Figure 3.4: Associated fractures in patients with penetrating wounds of lower extremity



The clinical information on the request form included information or frequency of the following: no clinical information 34, decrease in distal pulses 8, decrease in peripheral pulses 4, soft tissue swelling 4, different pulses distally 3. Other clinical information with frequencies of 2 or less included hemodynamically unstable, bleeding from wound and other as shown in Figure 3.5.

Figure 3.5 Clinical information provided on CTA request form

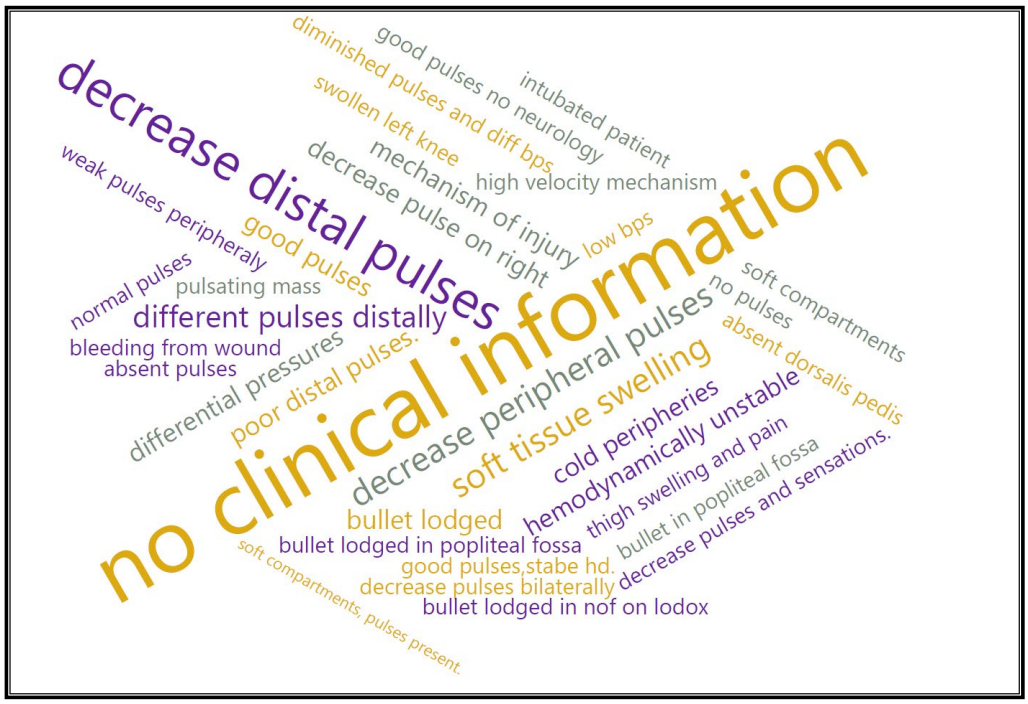

Mechanism of injury had was frequently mentioned as a gunshot (61 patients), with location described for 51 patients as thigh, 36 as fracture, 29 as pulses, 26 as femur, 21 as distal, 16 as decrease, 14 as stabbed, and 12 as leg. Ten patients were recorded as sustaining multiple gunshot wounds, 7 to the tibia, 7 to the knee, 7 to the thighs, 7 to the chest, and 6 to the fibula. No clinical information available for 33 entries.

The location of injury included 48 to the thigh, 9 to the leg, 5 to the knee, 4 to the thigh, chest, upper limbs, and 3 described as ‘penetrating injury.’ Other different injuries included tibia, buttock, abdomen, back, femur, arm, hip, and pelvis. No more than 2 of these injuries were recorded in relevant patients (Figure 3.6).

Figure 3.6: Anatomical location of gunshot wounds



4. Discussion

Injuries resulting from violence are common in South African society and are one of the leading causes of morbidity and mortality. This constitutes an immense financial burden on the South African health care sector. Young males are affected more often than females by violence and international statistics also shows similar pattern. In this study, only 8 patients out of a sample of 91 cases with penetrating wounds of the lower limbs, were females. Six of them were gunshot injuries. Similar results were found by other researchers regarding gender and violent injuries. Frykberg and colleagues prospectively assessed 366 penetrating extremity wounds in 310 patients, male being dominant in the group with 88% while female comprising of only 12% of total number of patients.[8] Jordaan et al., in a retrospective review of 285 patients, found that 83% of them were male.[14] Adibi et al also had 74 (91.2%) males and 7 (8.8%) females from a total of 80 patients in their study on gunshot wounds of lower extremity showing predominantly young males involved in violent injuries.[16] Wallin et al. similarly found that only 12% were females from 132 documented patients presenting with penetrating lower limb trauma.[17]

Younger adults are most commonly victims of injuries arising from violence. The average age of patients in this study was 30.9 years, similar to other studies published on penetrating limb wounds. Jordaan and colleagues' local study showed similar results, where the average age of 285 patients was 30 years - mostly young people are affected by violence.[14] Wallin and colleagues documented an average age of 25 years in 132 patients presenting with penetrating extremity trauma.[17] In the cohort of 80 patients from Adibi et al.'s study, gunshot wounds were predominantly sustained by males (91.2%) with a mean age of 26 years.[16] The most common mechanism of injury causing penetrating wound in their study was gunshot followed by stab wounds. Jordaan and colleagues reported similar findings, with 63 gunshot wounds and no patients with stab wounds.[14]

Wallin et al. documented gunshot wounds were the most common mechanism of injury, making up 93% of all patients, while the mechanism of injury reported in 5% of patients was a stab wound.[17] In South Africa, crime and illegal possession of guns are two major contributing factors towards gunshot injuries causing penetrating injuries of lower limbs. In their study of 80 patients, Adibi et al. found that 85% had penetrating wounds of lower extremity, and all of these were gunshot injuries.[16]

In this study, 38% patients had associated fractures, and most of fractures were sustained by patients with gunshot wounds. Jordaan et al. in their series

reported that 75% of the total patients with associated fractures, with gunshots accounted for half of the mechanisms of injury, a very similar outcome compared to our study regarding incidence of associated fractures .[14]

In this study, only one vascular injury was found out of cohort of 91 (1.09%) patients who underwent lower limb CTA. This finding is divergent to other studies on CTA in penetrating extremity wounds. This is much less than Inaba et al. reported: 22 positive CTAs out of a total of 63(34%) CTAs performed in patients with penetrating lower limb injuries, with 19 cases requiring surgical intervention.[13] Similar findings have been show by Adibi et al. with 43 cases of arterial injuries confirmed with CTA out of 80 (53.7%) patients with gunshot wounds.[16] Jordaan et al. reported 34% patients had positive CTA and 13% of these patients required further intervention.[14] There were also reports of poor information of clinical parameters and incorrect indications of CTA in some patients.[14]

In this study, there was only one positive CTA out of 91 CTA done, possibly reflective of poor clinical assessment in accident and emergency department, a lack of an established protocol for management of vascular injuries in penetrating wounds of lower extremity among trauma surgeons at CHBAH, and subsequent incorrect indication of CTA in patients with penetrating injuries of lower limb. A thorough clinical examination should include signs of vascular injuries, neurologic examination, entry wound examination along with bullet trajectory, depth of wound, exit wound and ABI value. Doppler ultrasound has shown good sensitivity and specificity to diagnose vascular injuries and is commonly used in emergency settings.[11] In this study, data clearly show that no doppler ultrasound was done before performing CTAs, which would have reduced number of negative CTAs. Another possible reason for low percentage of positive CTAs is that patients with hard signs of arterial injuries are transferred to the operating room immediately, and exploration with or without catheter-based angiogram is performed, while patients with soft signs or no signs of vascular injuries with penetrating wounds of lower extremity, with poor clinical history, physical examination, and without ABI values, being referred to the Radiology department for CTA - proven from data available on CTA request forms.

Prevalence of low-velocity gunshot wounds in civilian violence and high number of associated fractures are further possible reasons for low percentage of vascular injuries, as Abghari et al. have shown in their cohort of 133 patients with 148 gunshot wounds and 51 fractures - only 6.3% of total patients underwent lower limb CTA and 6.1% of total patients had vascular injuries.[21]

5. Limitations and recommendations

There are limitations of this study and being a retrospective study is one of them. There was no record of hard or soft signs, nor ABI values and other clinical parameters on CTA request form filled by Trauma surgeons. This information would have been reflected on the PACS Imaging system for subjects of the study, but this could not be guaranteed in old data. The only indication to perform CTAs on the request form was presentation of penetrating lower limb injuries, irrespective of signs of peripheral vascular injuries and ABI value. It is thus difficult to understand if this was caused by misclassification, bias from doctors, or other causes.

A prospective study would be able to specifically require data regarding outcome of patient treatment, so that accurate sensitivity and specificity of CTA can be determined. Wallin et al in their retrospective study collected data of 132 patients and only 53 underwent CTA. Out of 59 CTAs performed only 19 were positive and 34 were negative, and out of the 34 negative CTAs, two patients required further surgical intervention. Further, of those 19 positive CTAs, 11 needed surgical intervention and 8 had only minor injuries, all which were managed non-operatively. Out of 8 indeterminate CTAs, 2 required surgical intervention and 6 were managed non-operatively. Combining clinical parameters and findings of CTAs, the sensitivity and specificity of CTA rises but it does not reach 100%.[17]

Regarding this study's results of only one positive CTA out of 91, it is important to revise trauma surgeons' treatment protocol currently in use regarding the management of patients with penetrating injuries of lower limb. A good history and thorough clinical examination, ABI measurement and doppler ultrasound must be performed before making decision of performing CTA. If indicated, only then, CTA should be performed. A prospective study of CTA in penetrating extremity wounds will be valuable in further understanding of challenges in management as well as writing up management protocol at this institution.

6. Conclusion

Violence related injuries are a major source of morbidity and mortality in the South African population. Gunshot wounds are a major cause of penetrating limb injuries, with the risk of vascular injuries. There is male predominance in this study, reflecting what was found in reviewed literature. This study showed a very low rate of positive CTA at only one percent - an important finding. Findings from clinical examination are critical, alongside Ankle-Brachial index measurement and doppler ultrasound, to make decisions to perform CTA for diagnosing vascular injuries in penetrating lower limb trauma. Trauma surgeons can be involved in developing treatment protocols for penetrating injuries of limbs, potentially invaluable to guiding appropriate indication for CTA to avoid unnecessary investigation. Different patterns of vascular injuries are described in literature, and this study noted a pseudoaneurysm of popliteal artery. There are established treatment protocols in literature to manage these injuries with the achievement of good outcome. Radiological imaging plays a key role in diagnosing arterial injuries in penetrating extremity wounds if correct indication is practiced.

7. References

1. Seedat M, Van Niekerk A, Jewkes R, Suffla S, Ratele K. Violence and injuries in South Africa: prioritising an agenda for prevention. [published correction appears in Lancet. 2009 Sep 19;374(9694):978]. *Lancet*. 2009;374(9694):1011-1022. doi:10.1016/S0140-6736(09)60948-X
2. Kong VY, Blodgett JM, Weale R, et al. Discrepancy in clinical outcomes of patients with gunshot wounds in car hijacking: a South African experience. *S Afr J Surg*. 2019;57(4):25-28.
3. Uchino H, Kong VY, Pantelides A, Anderson J, O'Neill H, Bruce JL et al. The scourge of knife crime: trends in knife-related assault managed at a major centre in South Africa. *S. Afr. j. surg*. 2020;58(3):150-153. http://dx.doi.org/10.17159/2078-5151/2020/v58n3a3251
4. Wahlgren, C.M., Riddez, L. Penetrating Vascular Trauma of the Upper and Lower Limbs. *Curr Trauma Rep*. 2016;2(1):11–20. https://doi.org/10.1007/s40719-016-0035-1
5. Feliciano DV, Moore FA, Moore EE, et al. Evaluation and management of peripheral vascular injury. Part 1. Western Trauma Association/critical decisions in trauma. *J Trauma*. 2011;70(6):1551-1556. doi:10.1097/TA.0b013e31821b5bdd
6. Fox N, Rajani RR, Bokhari F, et al. Evaluation and management of penetrating lower extremity arterial trauma: an Eastern Association for the Surgery of Trauma practice management guideline. *J Trauma Acute Care Surg*. 2012;73(5 Suppl 4):S315-S320. doi:10.1097/TA.0b013e31827018e4
7. Le Roux J, Burger M, Du Preez G, Ferreira N. The reliability of physical examination in diagnosing arterial injury in penetrating trauma to extremities: A first look at different anatomical regions and injury mechanisms. *S Afr Med J*. 2021;111(9):891-895. Published 2021 Sep 2.
8. Frykberg ER, Dennis JW, Bishop K, Laneve L, Alexander RH. The reliability of physical examination in the evaluation of penetrating extremity trauma for vascular injury: results at one year. *J Trauma*. 1991;31(4):502-511. doi:10.1097/00005373-199104000-00009
9. Hemingway J, Adjei E, Desikan S, et al. Re-evaluating the safety and effectiveness of the 0.9 ankle-brachial index threshold in penetrating lower extremity trauma. *J Vasc Surg*. 2020;72(4):1305-1311.e1. doi:10.1016/j.jvs.2020.01.051
10. Hemingway J, Adjei E, Desikan S, et al. Lowering the Ankle-Brachial Index Threshold in Blunt Lower Extremity Trauma May Prevent Unnecessary Imaging. *Ann Vasc Surg*. 2020;62:106-113. doi:10.1016/j.avsg.2019.05.052
11. Pezeshki Rad M, Mohammadifard M, Ravari H, Farrokh D, Ansaripour E, Saremi E. Comparing color Doppler ultrasonography and angiography to assess traumatic arterial injuries of the extremities. *Iran J Radiol*. 2015;12(1):e14258. Published 2015 Jan 1. doi:10.5812/iranjradiol.14258
12. Montorfano MA, Pla F, Vera L, Cardillo O, Nigra SG, Montorfano LM. Point-of-care ultrasound and Doppler ultrasound evaluation of vascular injuries in penetrating and blunt trauma. *Crit Ultrasound J*. 2017;9(1):5. doi:10.1186/s13089-017-0060-5
13. Inaba K, Potzman J, Munera F, et al. Multi-slice CT angiography for arterial evaluation in the injured lower extremity. *J Trauma*. 2006;60(3):502-507. doi:10.1097/01.ta.0000204150.78156.a9
14. Jordaan P, Roche S, Maqungo S. Computerised Tomographic Angiography (CTA) in extremity trauma - A level one hospital experience. *S Afr J Surg*. 2016;54(4):11-16.

15. Patterson BO, Holt PJ, Cleanthis M, et al. Imaging vascular trauma. *Br J Surg*. 2012;99(4):494-505. doi:10.1002/bjs.7763
16. Adibi A, Krishnam MS, Dissanayake S, et al. Computed tomography angiography of lower extremities in the emergency room for evaluation of patients with gunshot wounds. *Eur Radiol*. 2014;24(7):1586-1593. doi:10.1007/s00330-014-3174-1
17. Wallin D, Yaghoubian A, Rosing D, Walot I, Chauvapun J, de Virgilio C. Computed tomographic angiography as the primary diagnostic modality in penetrating lower extremity vascular injuries: a level I trauma experience. *Ann Vasc Surg* [Internet]. 2011;25(5):620–3. http://dx.doi.org/10.1016/j.avsg.2011.02.022
18. Adler C, Hangge PT, Albadawi H, et al. Multi-Detector Computed Tomography Imaging Techniques in Arterial Injuries. *J Clin Med*. 2018;7(5):88. Published 2018 Apr 24. doi:10.3390/jcm7050088
19. Walkoff L, Nagpal P, Khandelwal A. Imaging primer for CT angiography in peripheral vascular trauma. *Emerg Radiol*. 2021;28(1):143-152. doi:10.1007/s10140-020-01826-w
20. Miller-Thomas MM, West OC, Cohen AM. Diagnosing traumatic arterial injury in the extremities with CT angiography: pearls and pitfalls. *Radiographics*. 2005;25 Suppl 1:S133-S142. doi:10.1148/rg.25si055511
21. Abghari M, Monroy A, Schubl S, Davidovitch R, Egol K. Outcomes Following Low-Energy Civilian Gunshot Wound Trauma to the Lower Extremities: Results of a Standard Protocol at an Urban Trauma Center. *Iowa Orthop J*. 2015;35:65-69.

Appendix A: Data Link Sheet

A Retrospective audit of Computed Tomography Angiography in penetrating wound of lower limb at Chris Hani Baragwanath Academic Hospital.

DATA LINK SHEET (MMed Project)

Study Code:

Hospital Number:

Forename: Surname:

Age:

Indication of study:

Diagnosis:

Date of Computed tomography angiography (CTA) done:

Side of Lower limb undergone CTA: Right ☐ Left ☐

Findings of CTA:

Any Complication of procedure (CTA):

Appendix B: Data Collection Sheet

A Retrospective audit of Computed Tomography Angiography in penetrating wound of lower limb at Chris Hani Baragwanath Academic Hospital.

DATA COLLECTION SHEET (MMed Project)

Study Code:

Diagnosis:

Date of Computed tomography angiography (CTA) done:

Side of Lower limb undergone CTA: Right ☐ Left ☐

Findings of CTA:

Any Complication of procedure (CTA):

Appendix C: Ethics Clearance Certificate

UNIVERSITY OF THE
WITWATERSRAND
JOHANNESBURG

R14/49 Dr Rabia Abid

HUMAN RESEARCH ETHICS COMMITTEE (MEDICAL)

CLEARANCE CERTIFICATE NO. M190401

NAME: (Principal Investigator)	Dr Rabia Abid
DEPARTMENT:	Radiology Chris Hani Baragwanath Academic Hospital
PROJECT TITLE:	A Retrospective audit of Lower limb computed tomography angiography in penetrating would of lower limb at Chris Hani Baragwanath Academic Hospital
DATE CONSIDERED:	26/04/2019
DECISION:	Approved unconditionally
CONDITIONS:	
SUPERVISOR:	Dr MN Iqbal
APPROVED BY:	Dr CB Penny, Chairperson, HREC (Medical)
DATE OF APPROVAL:	29/04/2019

This clearance certificate is valid for 5 years from date of approval. Extension may be applied for.

DECLARATION OF INVESTIGATORS

To be completed in duplicate and **ONE COPY** returned to the Research Office Secretary on the Third Floor, Faculty of Health Sciences, Phillip Tobias Building, 29 Princess of Wales Terrace, Parktown, 2193, University of the Witwatersrand. I/we fully understand the conditions under which I am/we are authorized to carry out the above-mentioned research and I/we undertake to ensure compliance with these conditions. Should any departure be contemplated, from the research protocol as approved, I/we undertake to resubmit the application to the Committee. **I agree to submit a yearly progress report**. The date for annual re-certification will be one year after the date of convened meeting where the study was initially reviewed. In this case, the study was initially reviewed in April and will therefore be due in the month of April each year. Unreported changes to the application may invalidate the clearance given by the HREC (Medical).

Principal Investigator Signature Date

PLEASE QUOTE THE PROTOCOL NUMBER IN ALL ENQUIRIES