

https://dspace.org/

A cadaveric of the course and characteristics of the greater palatine artery

Koutras, Sandra

2019
https://hdl.handle.net/10539/28153

Downloaded from a DSpace repository. https://dspace.org/

A CADAVERIC STUDY OF THE COURSE AND CHARACTERISTICS OF THE GREATER PALATINE ARTERY

Sandra Koutras



A research report submitted to the Faculty of Health Sciences, University of the Witwatersrand, Johannesburg, in partial fulfilment of the requirements for the degree of Master in Dentistry

Johannesburg, 2019

DECLARATION

I, Sandra Koutras declare that this research report is my own work. It is being submitted for the degree of Master in Dentistry at the University of the Witwatersrand, Johannesburg. It has not been submitted before for any other degree or examination at this or any other University.

_____

Sandra Koutras 0404632F

28th day of February 2019

ABSTRACT

Background: The purpose of this study was to detail the topography of the greater palatine artery (GPA), looking specifically at its depth from the overlying masticatory mucosa as well as its diameter so as to be able to ascertain the safest area for graft harvesting from partially and fully edentate individuals.

Methods and materials: Thirty-six maxillae from human cadavers, whose age and sex are known, were analysed at the School of Anatomical Sciences, University of the Witwatersrand, Johannesburg, South Africa. Following dissection of 72 GPA, the width and length of the palate as well as the diameter of the greater palatine artery and its relationship to the overlying palatal mucosa was recorded at 3mm intervals.

Results: A total of 64 GPA were evaluated. Despite a relatively even distribution of male and female individuals, there was no statistically significant difference between the sexes. The left and right diameters of the GPA as well as the right and left distances from the GPF to the palatal raphe were not found to be significantly different. The depth of the GPA decreased as it coursed anteriorly from the greater palatine foramen ranging from 6.67 mm to 4.35 mm. The depth at both the 3mm and 6mm intervals decreased by approximately 1.2mm with an increase of 10mm in palatal width.

Conclusion: No directional asymmetry or sex and age bias could be found. Wider palates tend to have shallower GPAs posteriorly at the 3mm and 6mm landmark. A new landmark is recommended for use in partially dentate and edentulous individuals to measure the GPA depth at the point where the palatal raphe bisects a line adjoining the two GPFs.

DEDICATION

To Bjørn and Magnus (and Lennox)

ACKNOWLEDGEMENTS

I would like to thank Dr. Hemingway for his guidance and mentorship throughout this long journey both hands on in the collection of data and write up and giving way beyond what is required of a supervisor. Also to the School of Anatomical Sciences and all the individuals who donated their bodies to medical education and research, who gave up their last possession for the benefit of future generations.

TABLE OF CONTENTS

DECLARATION i

ABSTRACT ii

DEDICATION iii

ACKNOWLEDGEMENTS iv

TABLE OF CONTENTS v

LIST OF FIGURES viii

LIST OF TABLES ix

CHAPTER 1: INTRODUCTION AND LITERATURE REVIEW 1

1.1 Introduction 1

1.2 Literature review 2

1.3 Aims and objectives 5

CHAPTER 2: MATERIALS AND METHODS 6

2.1 Study Design 6

2.2 Study population and sample size 6

2.3 Sample size 6

2.4 Instrumentation 6

2.5 Methods and procedures 8

2.5.1 Dissection Protocol 8

2.5.2 Data collection 9

2.6 Calibration 11

2.7 Data analysis 12

CHAPTER 3: RESULTS 13

3.1 Calibration 13

3.2 Sample size, age and population group 13

3.3 Descriptive statistics 13

3.4 Test for directional asymmetry 14

3.5 Differences between male and female individuals 15
3.6 Greater palatine artery depth discrepancy postero-anteriorly 16
3.7 Correlations amongst variables 18

CHAPTER 4: DISCUSSION 21
4.1 Sample sizes 21
4.2 GPA diameter 21
4.3 GPA depth 22
4.4 Directional asymmetry and sexual dimorphism 23
4.5 Palatal dimensions in relation to the depth of the GPA 24
4.6 Proposed harvesting site 25
4.7 Limitations 27

CHAPTER 5: CONCLUSION 28

APPENDIX 29

REFERENCES 30

ABBREVIATIONS

CEJ- Cemento-enamel junction

CT- Computed tomography

GPA – Greater palatine artery

GPF- Greater palatine foramen

GPN- Greater palatine nerve

LGPF- Line adjoining the greater palatine foramina

PM- Palatal mucosa

R- Coefficient of reliability

SCTG- Subepithelial connective tissue graft

TEM – Technical error of measurement

TMJ – Temporomandibular joint

UNC-15 – University of North Carolina- 15

LIST OF FIGURES

Figure 2.1. Hillson-Fitzgerald Dental Caliper……7

Figure 2.2. UNC-15 probe……..7

Figure 2.3. Greater palatine artery (right) after dissection…….10

Figure 2.4. Measurements taken from the hard palate……11

Figure 3.1. The depth of the GPA) in relation to the distance from the line adjoining the greater palatine foramina (mm) ……...17

Figure 3.2. The average depth of the GPA (mm) in relation to the distance (mm) along the palatal raphe at 3mm intervals ……..18

Figure 3.3. Scatterplot illustrating the relationship between the palate width and the depth of the GPA at the 3mm interval……19

Figure 3.4. Scatterplot illustrating the relationship between the palate width and the depth of the GPA at the 6mm interval……20

LIST OF TABLES

Table 3.1. Intra-observer error using the technical error of measurement……..13

Table 3.2. Descriptive statistics for all the measures, separated by sex and side……...14

Table 3.3. Descriptive statistics for all the measures averaged for side; independent of sex..15

Table 3.4. Pairwise comparisons between observed depths of the GPA at 3mm intervals….16

Table 3.5. Association between palatal measures and depth of the GPA at 3mm intervals…19

CHAPTER 1: INTRODUCTION AND LITERATURE REVIEW

1.1 Introduction

Friedman et al was the first to define mucogingival surgery as "surgical procedures designed to preserve gingiva, remove aberrant frenulum or muscle attachments, and increase the depth of the vestibule" [1]. These procedures addressed challenges related with the amount of gingiva available and the presence of recession defects.

Subsequently, Miller in 1993 broadened the concept into *periodontal plastic surgery* allowing for the inclusion of the correction of ridge form and soft tissue aesthetics [2]. These procedures are widely used in periodontal practice to fulfil aesthetic and functional demands. Soft tissue grafts form the basis of many such procedures which include: root coverage, ridge augmentation, vestibuloplasty and papilla reconstruction procedures [3].

The palatal mucosa is the chief intra-oral donor site for harvesting free soft tissue grafts [3]. This is in part due to its histological similarities with the gingiva. These histological similarities include a stratified squamous epithelium (which is keratinized) supported by a dense collagenous lamina propria. The lamina propria is firmly attached to the underlying periosteum by a relatively dense fibrous submucosa [4].

Autogenous free soft tissue grafts may either be epithelialized or non-epithelialized. Initially, epithelialized palatal grafts were used to enlarge the width of attached gingiva and cover denuded root surfaces as a result of recession defects [5]. In the 1980's, the subepithelial connective tissue graft (SCTG) was first introduced to correct edentulous ridge concavities following tooth extraction [6]. In 1982, Langer founded the use of SCTGs for root recession coverage[7]. In 1985, 90% coverage of Miller Class I and II recessions together with improved aesthetics were reported [8], remaining the most effective and predictable outcome for root coverage procedures.

The relevance of soft tissue grafts has been highlighted in the literature with respect to long term dental implant maintenance. The presence of an adequate band of keratinized tissue is essential in reducing the risk for mucosal recession [9] and alveolar bone loss [10] at dental implant sites. In addition, free soft tissue grafts have been predictably employed to enhance and augment missing tissue volume prior to dental implant placement [11], creating a

favourable future peri-implant environment and subsequently improving the aesthetic outcomes; particularly in the anterior maxillary region [12].

Although predictable results are achieved through the use of free soft tissue grafts, limitations include post-operative pain [13] and limited supply of donor tissue [14]. Soft tissue substitutes, examples of which include acellular dermal matrix [15] and collagen matrix [16], can be used. However, these allografts, in comparison to autogenous soft tissue grafts, have shown to be less effective and predictable, due to their considerable shrinkage [17]. Thus, soft tissue grafts from the palate are currently considered the "gold standard" for periodontal plastic surgery [18].

The success of the procedures within the realm of periodontal plastic surgery however, depend on the size and thickness of the graft [3]. A thin graft loses considerable volume and can result in necrosis or atrophy whilst a thick graft can result in lack of revascularization and subsequent healing problems [3]. The amount of soft tissue graft that can be harvested is dictated by the topography of the palate, thickness of the palatal masticatory mucosa and the depth at which the greater palatine neurovascular bundle lies [19].

This study aimed to document the diameter of the greater palatine artery (GPA) and establish the depth at which the artery lies in relation to the overlying palatal mucosa in order to assist clinicians in identifying the ideal graft harvesting site whilst simultaneously avoiding complications, the most serious of which is haemorrhage. Accidental sectioning of the GPA or any of its branches may result in an excessive bleed which may be life threatening [20].

1.2 Literature review

The hard palate, which is covered by masticatory mucosa, is formed by the two palatal processes of the maxilla and two horizontal plates of the palatine bone [21]. The GPA is the main arterial supply to the hard palate, which originates from the descending palatine artery, the third branch of the maxillary artery.

The maxillary artery is one of two terminal (end) branches of the external carotid artery in the neck. It arises within the parenchyma of the parotid gland, passing forward between the ramus of the mandible and sphenomandibular ligament to enter and traverse the infratemporal

fossa. It then enters the pterygopalatine fossa through the pterygomaxillary fissure where it splits into its three terminal branches. The descending palatine artery branches from the maxillary artery in the pterygopalatine fossa, giving rise to the lesser and greater palatine arteries [21].

The GPA enters the pterygopalatine canal and surfaces through the greater palatine foramen (GPF) onto the hard palate [22]. As it exits the GFP, the GPA, together with the greater palatine nerve, course anteriorly intimately with the alveolar ridge [24] with the terminal branch of the artery entering the incisive canal where it anastomoses with the nasopalatine branch of the sphenopalatine artery [25].

Although the principal trunk of the artery and nerve run in different courses,[26] it is important to note that the main trunk of the greater palatine nerve (GPN) is found to be more superficially located within the masticatory mucosa as compared to the GPA [26,27], and thus likely to be severed together with the GPA during a traumatic incident.

The hard palate anatomy within individuals varies widely which will subsequently affect the width, length and thickness of donor tissue that can be harvested [24]. Thus, an accurate understanding of the position of the GPA in relation to the palatal mucosa is required, to assist clinicians in developing a pre-operative plan to ascertain the volume of donor tissue that can be obtained without damaging the GPA, which can result in severe haemorrhaging [20].

Numerous methods are currently employed to calculate the thickness of the palatal mucosa, namely: periodontal probes [28], endodontic reamers [29], injection needles [30], ultrasonic devices [29] and CT imaging [3]. Their common limitation is that they measure the entire thickness of the palatal mucosa down to the bone, also known as “bone sounding”, which does not take into account the depth at which the GPA is located.

Several authors have assessed the thickness of the palatal mucosa with varying results. In a study by Schacher et al [31], the palatal mucosa was thinnest at the position of the first molar and thickest in the area of the second molar; [31] however this region adjacent to the second molar is seldom used because of low accessibility [3]. Studies by Studer et al and Muller et al have also shown that the bulky palatal root of the first molar presents an anatomical challenge in soft tissue graft harvesting [28,32].

Based on these studies, the recommendation for the most useful soft tissue harvesting site in the hard palate is located from the mesial surface of the first molar tooth extending to the distal region of the canine [19,33]. This is because the palatal tissue thickness is minimal at the first molar, and the GPA branches and courses more coronally beyond the canine region [24].

Numerous studies have investigated the anatomy of the hard palate in dry skulls of various populations around the world including South Africa [34,35,36]. Parameters analysed included palatal dimensions (length, breadth and height) together with the location, shape and dimensions of the GPF. Three dimensional imaging such as computed tomography and cone-beam computerized tomography images have also been used to assess the palatal mucosa thickness [33,37].

Only four studies have been performed on cadavers, originating from Korea, Thailand and America, to investigate the anatomy of the hard palate [19,26,38,39]. They detailed the conformation of the GPA, its course, branches and depth from the palatal masticatory mucosa so as to assess graft dimensions and harvesting site. The total length and diameter of the artery was measured at the height of the GPF, maxillary premolar and incisive fossa by Klosek and Rungruang [38], whilst in the study by Kim et al [39],only the main branch of the GPA was measured. The branching patterns of the GPA were subdivided into four categories according to the course of the three main branches, namely: lateral, medial and canine branches [26].

Klosek and Rungruand on the other hand, only recorded the number of branches which deviated either towards the alveolar process or the palatal vault and compared these findings between the sexes [38]. In females, the GPA branching was most commonly found at the level of the first premolar (38%) and at the first and second molars (43%), whilst in males, branching towards the alveolar side at the level of the first and second premolars together was present in 56% of individuals and 32% at the level of the second and third molars. Although the thickness of the mucosa at different intervals is mentioned, there has been no description of how this measurement was taken [26].

Although the above-named studies have examined the anatomical variations of the GPA, none were carried out on edentulous, or partially edentulous individuals, where pre-prosthetic

surgery might be needed to increase the dimensions of existing soft tissue prior to implant or other prosthesis placement.

It is this paucity in the literature that has prompted a more in-depth examination of the topography of the GPA and overlying thickness of the palatal mucosa in partially and completely edentate cadavers of a South African population to be conducted. Furthermore, the depth of the masticatory mucosa and its relation to the GPA, one of the most important parameters in determining the site of graft harvesting has not been well documented.

1.3 Aims and objectives

Aim: To determine the course and dimension of the GPA, and its relationship to the overlying palatal mucosa.

Thus, the specific **objectives** are:

1. To measure the diameter of the GPA as it emerges from the GPF.
2. To measure the distance from the GPF to the palatal raphe.
3. To establish the thickness of the palatal mucosa overlying the GPA.
4. To determine the length and width of the palate.
5. To test for the presence of directional asymmetry and sexual dimorphism.

CHAPTER 2: MATERIALS AND METHODS

2.1 Study Design

A cross sectional study of human cadavers.

2.2 Study population and sample size

Thirty-six maxillae from human cadavers, whose age and sex are known, were analysed at the School of Anatomical Sciences, University of the Witwatersrand, Johannesburg, South Africa. Following dissection, the width and length of the palate as well as the diameter of the GPA and its relation to the overlying palatal mucosa were recorded. The sample is limited to white South Africans due to availability and thus, extrapolation of the results obtained here to other populations should be cautioned against.

For inclusion in the study, both dentate/edentulous male and female cadavers, of 18 years and older forming part of a South African population housed at the School of Anatomical Sciences, University of the Witwatersrand, Johannesburg were analysed. Trauma or pathology to the craniofacial complex in the region of the GPA or anything that would bring about excessive asymmetry of the maxilla and palate were excluded from the study.

2.3 Sample size

Due to the nature of cadaveric analyses, sample size was determined based on the maximum number of available specimens. In 2017 there were 20 cadavers available to this particular study and in 2018 there were 16. Although more cadavers are utilized by the School, their primary purpose is for the education of health professionals. As a result, cadavers which conflicted with the dissection requirement of other specific disciplines were excluded from this study.

2.4 Instrumentation

A Special ABS Coolant Proof Hillson-Fitzgerald Dental Caliper (Mitutoyo IP67; No 99MAD022M, Series No.500; Figure 2.1), was used to measure the length and width of the palate, the diameter of the GPA and the distance between the GPF and palatal raphe.



Figure 2.1. Hillson-Fitzgerald Dental Caliper

The University of North Carolina-15 (UNC-15) probe was used to assess the depth of the GPA from the overlying palatal mucosa at three-millimetre intervals (Figure 2.2). The measurements taken with the periodontal probe were rounded off to the nearest millimeter. This is a standard worldwide accepted periodontal instrument used clinically to measure various periodontal parameters, including the thickness of the palatal mucosa of the palate [40].

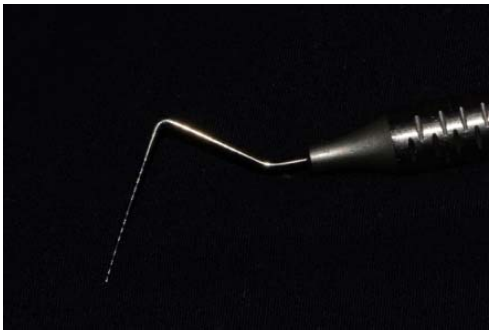

Figure 2.2. UNC-15 probe

2.5 Methods and procedures

2.5.1 Dissection Protocol

Firstly, the external carotid artery was dissected bilaterally and injected using a plastic syringe filled with latex (Dala Casting Rubber) with a red acrylic agent (Dala acrylic paint) to enable clear observation of the GPA. The latex was allowed to set for a week before further analysis was undertaken.

Due to the nature of preserved cadaveric remains, it was necessary to release the mandible to allow for the dissection and data collection from the palate. Using a scalpel, incisions were made along the inferior margin of the mandible, extending from the most anterior tip of the mental protuberance to each mandibular angle to allow access to the external and internal surfaces of the mandible. This incision permitted the reflection of the overlying soft tissues using blunt dissection techniques, with the exceptions of the firm insertions of the masseter and medial pterygoid muscles.

Care was taken retain the arrangement and relative positions of those structures passing under the body of the mandible as best as possible, cutting cleanly and reflecting carefully. For example, the facial artery and veins were cut cleanly across their transition at the antegonial notch of the mandible. The soft tissue over the external and internal surfaces of the body and ascending ramus of the mandible was reflected as superiorly as possible, leaving only the attachment of the lateral pterygoid and temporalis muscles. This allowed for structures such as the submandibular gland to be reflected without damage.

The stylomandibular and sphenomandibular ligaments were cut as close to their mandibular attachments as possible and the attachments of the geniohyoid and genioglossus to the genial tubercles were severed. The muscles of facial expression that find origin on the mandible were bluntly reflected. This method aims to keep as many structures intact and retain the anatomy for the region for future dissections.

The next step involved the reflection of the facial muscles together with the parotid gland to expose the temporomandibular joint (TMJ). A scalpel incision was made from the angle of the mouth in a superolateral direction towards the zygomatic process, just anterior to the tragus of the external ear, while avoiding damage to the zygomaticus major and minor muscles. An intrasulcular incision enabled a full mucoperiosteal flap to be reflected inferiorly

and laterally from the mandible to meet up with the reflected space along the external surfaces. A similar incision was performed alongside the lingual surface of the alveolar process or ridge to meet with the reflected space along the internal surface of the mandible.

Once the muscles of facial expression and parotid gland were reflected, the TMJ was disarticulated by incising laterally through the capsule and supportive ligaments. The temporalis attachment was then released by an incision at the coronoid process. The same was performed for the lateral pterygoid at its attachment on the condyloid process of the mandible. The mandible was then removed to allow for a clear view of the palate thus enabling ease of access for dissection of the palatal mucosa and necessary measurements

2.5.2 Data collection

Thirty-six embalmed cadavers and a total of 72 GPA were dissected and examined by the principal researcher. All 72 GPA were examined but only 64 could be properly visualized and used for data collection.

Following palpation of the greater palatine foramen, a full thickness mucoperiosteal flap (consisting of the epithelium and underlying connective tissue) overlying the neurovascular bundle was raised (Figure 2.3). This was done using a 15c blade and mucoperiosteal elevator. When teeth were present, intrasulcular incisions were made to facilitate flap reflection, whereas in edentulous individuals a mid-crestal incision was made. The length and width of the palate was measured using the Hillson-Fitzgerald Dental calliper. The latter was measured at the greatest distance between the greater palatine foramina with the former extending from the incisive papilla to the tip of the posterior nasal spine which was identified by probing. Following flap elevation, the GPF and GPA could be visualized, allowing meticulous dissection of the GPA as far anteriorly as visible.

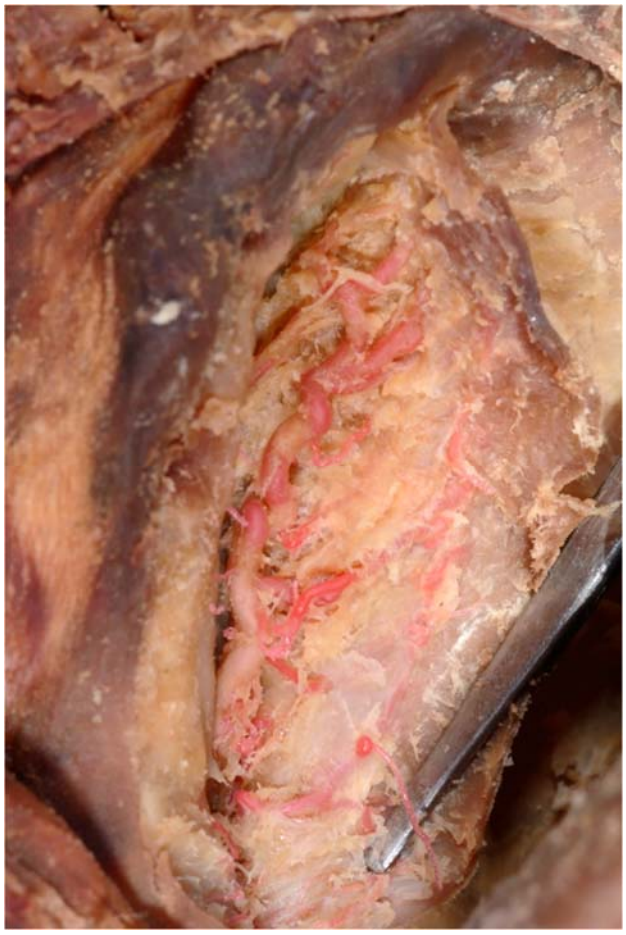

Figure 2.3. Greater palatine artery (right) after dissection.

The following parameters were measured on both sides of each maxilla:

- The diameter of the principal branch of the GPA upon emergence from the GPF.
- The distance between the GPF and the palatal raphe.
- The distance between the bilateral GPFs.
- The location and depth of the GPA in relation to the overlying palatal mucosa at regular intervals.

The location and depth of the GPA in relation to the overlying palatal mucosa was assessed by drawing an imaginary line spanning across the palate at the level of the greater palatine foramina (Figure 2.4). A UNC-15 periodontal probe was utilised to measure the depth at which the GPA lay, at 3 mm intervals starting from the imaginary line between the greater palatine foramina and coursing anteriorly along the palatal raphe (Figure 2.4).

The digital callipers were used to provide accuracy whilst the periodontal probe allowed for clinical extrapolation. The callipers were calibrated before obtaining each measurement.

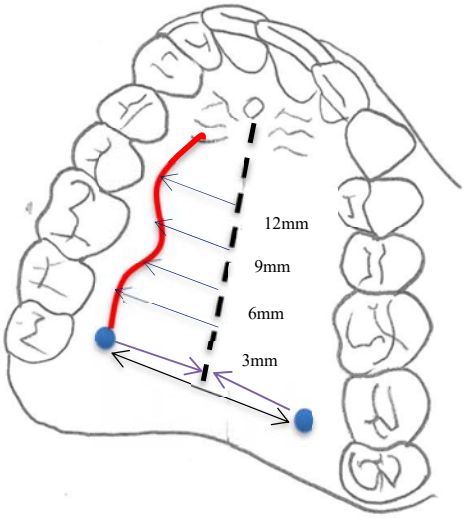

Figure 2.4. Measurements taken from the hard palate

2.6 Calibration

There was a single principal researcher. Intra-observer calibration was performed to ensure uniformity during data collection.

For intra-observer calibration a series of 10 cadavers were scrutinized independently. The same ten cadavers were revisited, one week later by the principal researcher. Findings were compared to the initial measurements to confirm intra-observer consistency using the technical error of measurement (TEM), a common measure of imprecision calculated as the square root of measurement error variance [41]. Because TEM is related to the size of the measurement, it is also reported as the relative TEM (%TEM), which involves its division by the mean of the measures and multiplication by 100. Some authors prefer the use of the coefficient of reliability (R), and thus this was calculated by dividing the square of the TEM by the variance of the specific measure and subtracting the result from one.

2.7 Data analysis

The difference between left and right measurements was assessed using the Wilcoxon signed-rank, a nonparametric hypothesis test used to compare two related samples [42]. If no significant directional asymmetry exists, the average between the left and right measures can be used in the remaining analyses. The Mann-Whitney U test, also a nonparametric test was used to test whether there were any differences in measurements between male and female individuals [43].

The differences of the depths of the GPA postero-anteriorly was assessed using the Kruskal-Wallis test and, if significant, further analysed using the sequential Bonferroni-corrected pairwise Mann-Whitney U tests[42,43]. The Holm–Bonferroni method is used to counteract the problem of multiple comparisons thereby controlling the error rate[45]. The Spearman's Rank Order Correlation coefficient assesses the presence and strength of the relationship between two variables and was used to assess whether correlations existed between the palatal measures and the depth measures[46].

CHAPTER 3: RESULTS

3.1 Calibration

The intra- observer calibration results showed substantial agreement on all parameters (Table 3.1). While the measure of mucosal depths recorded the highest level of relative TEM, the associated coefficient of reliability suggests that as least 96% of the population variance regarding this measure was free of measurement error, above the acceptable threshold of 95% [41]. The remaining measures were well within this limit for repeatability.

Table 3.1. Intra-observer error using the technical error of measurement. TEM, technical error of measurement; %TEM, relative technical error of measurement; R, coefficient of reliability.

	Palate width	Palate length	GPA diameter	GPF to midpalate	Mucosal depths
TEM	0.357	0.483	0.084	0.123	0.296
%TEM	1.199	1.254	3.282	0.775	4.930
R	0.996	0.981	0.977	0.998	0.961

3.2 Sample size, age and population group

Of the total 36 cadavers that were examined, 21 were female (58.33%) and 15 were male (41.67%). Because of the nature of bequests and cultural beliefs, all of the cadavers were white and of an older age [47]. The mean age for females and males was 80.6 years and 70.9 years, respectively, with a total sample mean age of 79.8 years; However, there was no significant difference between the ages of the female and male samples (Mann-Whitney U = 102.5; p = 0.532).

3.3 Descriptive statistics

The results of the descriptive statistics for each of the variables are presented in table 3.2, separated by sex, and side (where applicable). Age was not available for five individuals.

Table 3.2. Descriptive statistics for all the measures, separated by sex and side. All values, with the exception of sample size, are measured in millimeters. n: sample size; sd: standard deviation.

		Female			Male		
		n	mean	sd	n	mean	sd
Age		17	80.59	11.02	14	78.86	8.85
Palate Width		21	31.84	4.73	15	34.12	3.23
Palate Length		21	39.11	4.06	15	42.13	5.22
GPA diameter	left	20	2.57	0.51	13	2.71	0.72
	right	21	2.48	0.75	13	2.36	0.69
GPF to palatal raphe	left	21	16.14	2.71	15	17.03	5.14
	right	21	15.72	1.99	14	18.42	2.09
3mm depth	left	18	6.33	1.24	13	6.23	1.36
	right	19	6.63	1.57	13	7.23	1.30
6mm depth	left	18	6.17	1.15	13	5.54	1.13
	right	19	5.79	1.44	13	7.38	2.57
9mm depth	left	18	5.56	1.46	13	5.62	0.96
	right	19	5.58	1.12	13	6.92	2.63
12mm depth	left	18	5.00	1.28	13	5.08	1.19
	right	19	5.42	1.02	13	5.85	3.13
15mm depth	left	18	4.50	1.29	12	4.58	1.16
	right	19	4.89	0.88	13	4.62	0.65
18mm depth	left	3	5.00	1.73	5	3.60	0.89
	right	3	4.00	1.00	5	4.60	1.52

3.4 Test for directional asymmetry

The Wilcoxon sign-rank non-parametric test was used to evaluate whether directional asymmetry existed between the left and right measurements of all parameters recorded [42]. P-values were obtained through the Monte Carlo permutation approach [48]. Of the 36 pairs of greater palatine arteries that were evaluated, four could not be visualized and accurately dissected.

Although subtle differences existed regarding the GPA diameter, the distance from the GPF to the palatal raphe, and the depth of the artery in relation to the overlying mucosa at 3 mm intervals, no significance was found between the bilateral pairs. More specifically, the left

and right diameters of the GPA as well as the right and left distances from the GPF to the palatal raphe were found not to be significantly different ($p = 0.509$ and $p = 0.799$, respectively). There was also no significant directional asymmetry observed for each of the recorded mucosal depths (3 mm, $p = 0.069$; 6 mm, $p = 0.309$; 9 mm, $p = 0.319$; 12 mm, $p = 0.270$; 15 mm, $p = 0.468$).

3.5 Differences between male and female individuals

The Mann-Whitney U non-parametric test was used to assess sexual dimorphism among the measures [43]. Again, the associated p-values were obtained through Monte Carlo permutation [48]. Despite a relatively even distribution of male and female individuals, there was no statistically significant difference between the sexes. Specifically, the GPA diameter, palate width and length were not statistically significant ($p = 0.789$, $p = 0.117$ and $p = 0.061$, respectively). There was also no significant difference observed between sexes for each of the recorded mucosal depths (3 mm, $p = 0.512$; 6 mm, $p = 0.203$; 9 mm, $p = 0.176$; 12 mm, $p = 0.699$; 15 mm, $p = 0.84$). As no directional asymmetry or sex and age bias could be found, the descriptive statistics of the dimensions, averaged by left and right and independent of sex, are provided in table 3.3.

Table 3.3. Descriptive statistics for all the measures averaged for side and independent of sex. All values, with the exception of sample size, are measured in millimeters. n: sample size; sd: standard deviation.

	n	mean	Sd
Age	31	79.81	9.97
Palate Width	36	32.79	4.27
Palate Length	36	40.37	4.75
GPA diameter	36	2.49	0.57
GPF to palatal raphe	36	16.44	3.50
3mm depth	35	6.67	1.16
6mm depth	35	6.23	1.20
9mm depth	35	5.84	1.19
12mm depth	35	5.34	1.33
15mm depth	34	4.69	0.82
18mm depth	10	4.35	1.27

3.6 Greater palatine artery depth discrepancy postero-anteriorly

The Kruskal-Wallis non-parametric test was used to compare depth measures at the various intervals [44]. Because the Kruskal-Wallis test (corrected for ties) suggested that significant differences existed ($H = 61.93$; $p = 4.85\times10^{-12}$), multiple post-hoc Mann-Whitney U tests were used to explore where the differences lay (Table 3.4). The resulting p-values were corrected using the sequential Bonferroni method to avoid inflating type I error rates [45].

Table 3.4. Pairwise comparisons between observed depths of the GPA at 3 mm intervals. Values beneath the diagonal are the Mann-Whitney U values and above the diagonal are the sequential Bonferroni-corrected p-values. Significant values are marked with an asterisk.

	3mm	6mm	9mm		12mm		15mm		18mm	
3mm		0.2572	0.0254	*	4.9×10^{-5}	*	2.8×10^{-8}	*	0.0014	*
6mm	467.0		0.2124		0.0063	*	2.6×10^{-6}	*	0.0059	*
9mm	366.5	507.0			0.0965		0.0004	*	0.0213	*
12mm	221.0	326.5	422.5				0.1039		0.0979	
15mm	98.5	164.5	253.5		405.5				0.1987	
18mm	35.0	49.5	65.5		87.5		112.0			

The results of table 3.4 show that the depth of the GPA at 3 mm is significantly deeper than at 9 mm, 12 mm, 15 mm and 18 mm respectively, but not than that observed at 6 mm. Likewise, the depth at 6 mm is deeper than that at 12 mm, 15 mm and 18 mm, but not than that at 9 mm. At 9 mm, the average depth was greater than that at 15 mm and 18 mm, but not different from that at 12 mm. The average depths at 12 mm, 15 mm and 18 mm did not differ significantly. These results propose that there is a significant reduction in the depth of the GPA as it courses anteriorly from the GPF.

The average decrease in depth of the GPA, anteriorly, appears to be linearly related to the distance from the line adjoining the greater palatine foramina (LGPF). The relationship was highly correlated ($r = -0.997$; $p = 0.0028$), with a slope suggesting a 0.16 mm decrease in mucosal thickness for every millimetre anteriorly from LGPF (Figure 3.1), or a 1 mm loss of

mucosal tissue for every 6.25 mm from LGPF. Although the mean depth of the artery in relation to the distance along the palatal raphe was similar in males and females, the peak demonstrated in figure 3.1 indicates that males can have deeper located GPAs as compared to females.

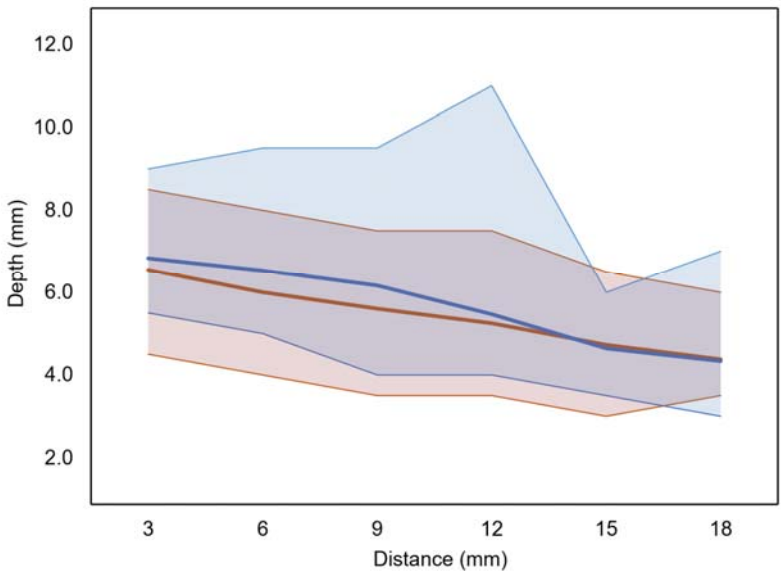

Figure 3.1. The depth of the GPA in males (blue) and females (red) in relation to the distance from the line adjoining the greater palatine foramina (mm) with 3 mm being the most posterior point and 18mm being the most anterior point. The bold lines represent the means, and the shaded regions indicate the ranges, for each sex at every interval.

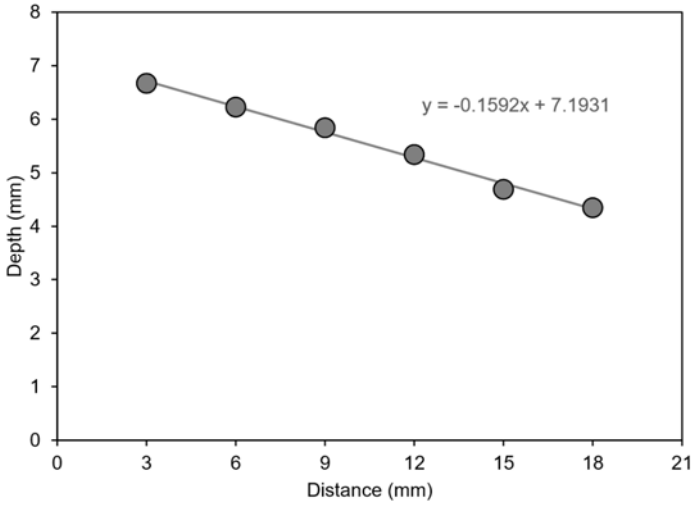

Figure 3.2. The average depth of the GPA (mm) in relation to the distance (mm) along the palatal raphe at 3 mm intervals coursing anteriorly from the line adjoining the greater palatine foramina.

3.7 Correlations amongst variables

Spearman's Rank Order Correlation coefficients assessed whether associations existed between the palatal measures and the depth of the GPA at various intervals [46]. Most of the correlations failed to be significant, with the exception of the palatal width and the depth of the GPA at the 3 mm and 6 mm intervals (Table 3.5).

Exploring these associations further, the resulting scatterplots and regressions suggest that there is a clear decrease in the depth of the GPA associated with wider palates at the 3 mm and 6 mm intervals (Figure 3.3 and Figure 3.4, respectively). The depth at both the 3 mm and 6 mm intervals decrease by approximately 1.2 mm with an increase of 10 mm of the palatal width (slopes of -0.122 and -0.125, respectively).

Table 3.5: Results of the Spearman's Rank Order Correlation tests for association between palatal measures and depth of the GPA at 3 mm intervals

	Palate Width			Palate Length		GPF to palatal raphe	
	r_s	p		r_s	P	r_s	P
3 mm	-0.4893	0.0033	*	-0.1294	0.4657	-0.1856	0.2934
6 mm	-0.4618	0.0060	*	-0.1353	0.4456	0.0147	0.9344
9 mm	-0.1958	0.2672		-0.1978	0.2621	0.0555	0.7552
12 mm	-0.0563	0.7518		-0.0585	0.7425	-0.0569	0.7492
15 mm	-0.0611	0.7315		-0.2403	0.1710	0.0773	0.6641

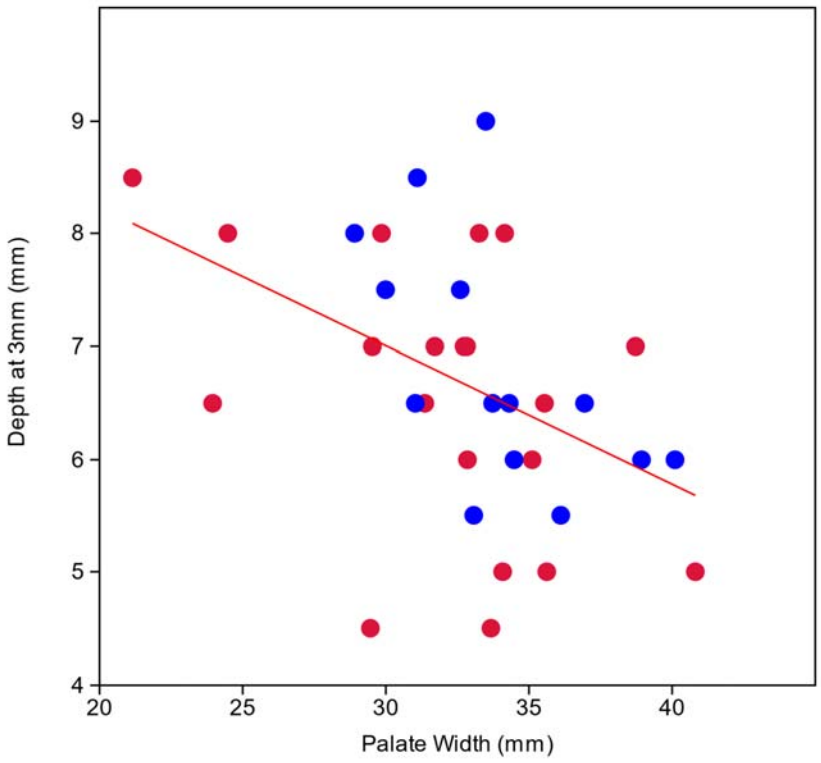

Figure 3.3. Scatterplot illustrating the relationship between the palate width and the depth of the GPA at the 3 mm interval. The red dots represent the female individuals, whilst the blue dots represent the male individuals. The regression considers all individuals, independent of sex.

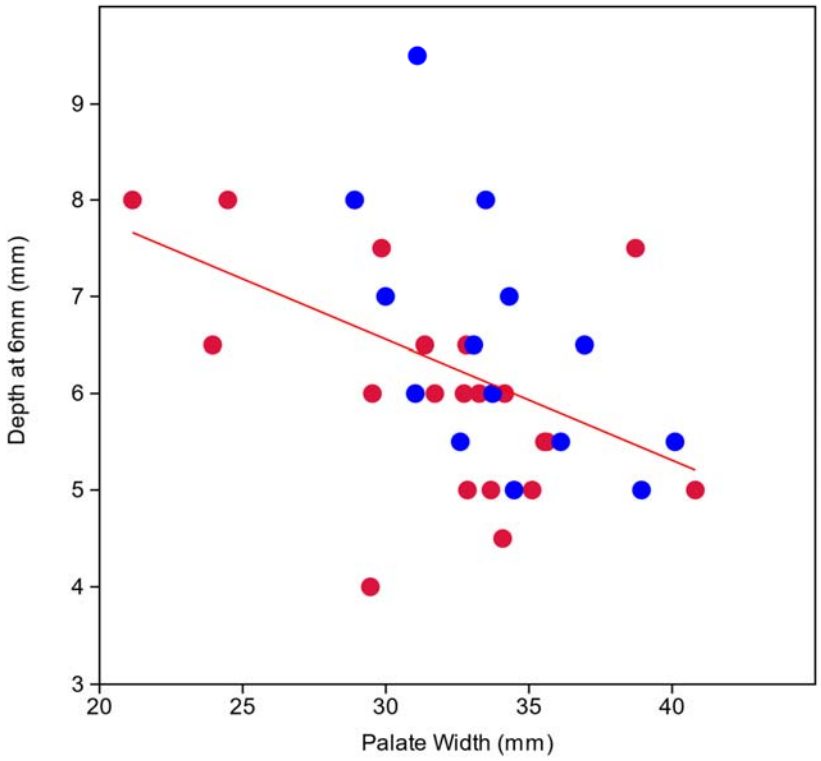

Figure 3.4. Scatterplot illustrating the relationship between the palate width and the depth of the GPA at the 6 mm interval. The red dots represent the female individuals, whilst the blue dots represent the male individuals. The regression considers all individuals, independent of sex.

CHAPTER 4: DISCUSSION

The neurovascular bundle, which consists of the GPA and greater palatine nerve (GPN), provides the main blood supply and innervation to the hard palate. The GPA emerges onto the palate through the GPF which is usually situated adjacent to the third molar [33]. It distributes collateral branches as it courses anteriorly, which supply the gingiva and palatal mucosa [38].

Performing safe and precise periodontal surgical procedures in this area, the majority of which are graft harvesting techniques, require an estimation of the position of the GPA by means of easily detectible and palpable anatomic landmarks. These include the cemento-enamel junction (CEJ) of teeth, the palatal raphe and the posterior border of the hard palate, identified by the posterior nasal spine [23,35,38].

This study aimed to 1) document the diameter of the GPA and the depth at which it lies in relation to the overlying mucosa; 2) assess whether significant directional asymmetry or sex and age bias exists regarding these measures; and 3) discover whether the dimensions of the palate can be used to guide clinicians in harvesting grafts, without damaging the underlying artery.

4.1 Sample sizes

This study is significant as the sample size of 36 individuals approached that of the largest study by Klosek and Rungruang [38], but far exceeded the samples by Kim et al [39], Fu et al [19], Yu et al [26] and Benninger et al [27] who only analysed the palates of 41, 22, 11, 24 and 17 individuals, respectively. This does not undermine the value of the latter studies, as the methods employed often restricted the number of individuals that could be assessed. Sample sizes in studies of this nature are severely restricted by the availability of cadaveric material.

4.2 GPA diameter

It was found that the diameter of the GPA, as it emerges from the GPF, was independent of the side and sex with an overall mean of 2.49 mm. This falls in line with the measure of 2.65

mm observed in a sample of Thai cadavers [38], but well above that of a sample of Korean cadavers [39], in which a measure of 1.3 mm and 1.0 mm were observes in males and females, respectively. The latter study, however, assessed the diameter of the GPA from photographs, and is thus not directly comparable with this study.

4.3 GPA depth

The masticatory mucosa overlying the hard palate is composed of several layers. The most superficial is the keratinized stratified squamous epithelium which overlies the underlying lamina propria (subepithelial connective tissue) which harbours the neurovascular bundle [21].

Several authors have documented the thickness of the palatal mucosa (PM) with varying results. Song et al [3] described the PM thickness, which was at its thickest dimension at the maxillary second premolar (3.8 mm) and thinnest at the first molar (3.1 mm). Kim et al found that the PM thickness at the canine (2.8 mm) increased towards the premolar, reduced at the first molar region and increased once more to its thickest dimension of 3.5 mm at the second molar. The decreased depth of the PM at the first molar can be attributed to the protuberance of the palatal root [49]. These findings led to the recommendation that the canine to premolar region is the most suitable donor site for obtaining a consistent graft dimension[39].

In this study, the depth of the GPA at 3 mm intervals reduced significantly as it coursed anteriorly from the GPF, which is in accordance with other studies [24,39]. With every 6.25 mm of length coursing anteriorly from the line adjoining the two greater palatine foramina, there was a 1 mm decrease in mucosal depth. Another interesting finding was that the depth of the GPA artery at 3 mm and 6 mm intervals decreased by about 1.2 mm with every 10 mm in increase of the palate width. Thus, in wider palates, one would anticipate that the GPA is lying more superficially as it emerges from the GPF, predisposing such individuals to a greater chance of GPA severance.

In a study by Cho et al [50], the depth of the mucosa overlying the GPA was measured from histological sections ranging from the distal canine to the distal first molar in 16 individuals. They found the average depth of the GPA to range from 3.09 mm to 5.50 mm from the surface epithelium, with the least and greatest depths being observed adjacent to the distal surface of the first premolar and first molar, respectively. Another study by Kim et al [39]

analysed the distance between the GPA and overlying mucosa from hemisectioned hard palates spanning from the canine to the second molar. They recorded the depths to decrease postero-anteriorly from a depth of 5.7 mm at the second molar, to 2.3mm at the canine. These observations are all in line with the findings of the current study, where the depth of the GPA decreased as it coursed anteriorly from the GPF, ranging from 6.67 mm to 4.35 mm, noting that the GPF lies further posteriorly, in the region of the second and third molars. Unfortunately, as most of the cadavers were partially or completely edentulous, these depths could not be classified according to tooth position, and thus no direct comparisons can be made with the results of Cho et al [50].

4.4 Directional asymmetry and sexual dimorphism

No differences were observed between the left and right measures, as well as between males and females. Although there is no reason to suspect directional asymmetry in the blood supply to the palate, this has to my knowledge never been studied, and could therefore not be overlooked. The lack of directional asymmetry suggests that grafts can be harvested from either side with equal success rates expected.

The absence of sexual dimorphism of the palatal masticatory mucosal depth supports the findings of Klosek and Rungruang, and Stipetić et al who described similar depths of the overlying mucosa in males and females [38,49]. Kim et al however, noted that the palatal mucosa increased in thickness from the second premolar to the second molar region in female individuals and from the maxillary canine to the first premolar in males; however this was not statistically significant [39]. Although the PM overlying the GPA in relation to the distance (mm) along the palatal raphe were similar in males and females in the current study, the maximal ranges showed that males can have deeper GPAs as compared to females.

Although the palatal vault was not documented in the current study, there are mixed results with a study reporting sexual dimorphism in its height [24] , and another finding no significance [39].The current study found no sexual dimorphism in the measures of the palate.

4.5 Palatal dimensions in relation to the depth of the GPA

Palatal width was found to be associated with the thickness of the PM overlying the GPA at the 3 mm and 6 mm intervals. The thickness of PM decreased with increasing palatal width, at a rate of -1.2 mm with every 10 mm increase in the width of the palate. No other study has reported such a relationship but have found relationships between the vault and its effect on the position and depth of the GPA.

The height of the palatal vault influences the extent of the graft that can be harvested [24]. Reiser et al. measured the distance from the neurovascular bundle to the CEJ in cadavers based on the vault of the palate which was classified as shallow, average or high [24]. The vault of the palate was measured as the shortest distance between the midline of the hard and soft palate and the CEJ of the first molars. A mean distance of 7, 12, and 17 mm of the GPA from the CEJs of the premolars and molars was reported in shallow, average, and high palatal vaults, respectively.

These findings suggest that the position of the neurovascular bundle in high vaulted palates is located at a greater distance from the CEJ than that of shallow palates, allowing for increased tissue availability in the former. Based on the aforementioned anatomical landmarks, the maximum graft dimensions of 8 mm in height and 31.7 mm in length were demonstrated on stone casts of periodontally healthy subjects [3,50]. However, a difference between the approximate location of the GPA on models and its accurate location on cadavers tended to be underestimated by about 4mm [19], rendering the former technique fairly inaccurate.

On an average palatal height of 14 mm [24],the palatal neurovascular bundle reduced in depth from 13.1 mm at the first molar to 12.2 mm at the first premolar [19,38]. Similar figures were reported by Yu et al., with a 13 mm distance from the CEJ to the GPA at the second molar decreasing sharply to 11 mm at the first premolar [26]. The canine branch also arose at a right angle near the premolar region. Consequently, when the graft is harvested from the suggested area (distal line angle of the canine to the midpalatal aspect of the first molar), the location of the GPA should be estimated particularly cautiously at the first premolar region [24,27].

These measurements are relatively easy to apply in dentate scenarios, but instances where individuals are fully edentulous could be trickier. Substantial resorption of the maxilla occurs

in a centrifugal direction (upward and inward); following tooth loss, further reducing the distance of the GPA from the edentulous alveolar ridge. In addition, tooth position can vary in relation to the arch, in relation to adjacent teeth in cases of malposition/tilting as well as drifting following extraction of neighbouring teeth. Taking these factors into consideration, it was decided, in this study, to use the palatal width and length as opposed to the palatal vault to make associations with the GPA position and depth. The palatal raphe which overlies the median palatine suture was used as the landmark from which the GPA was measured, as opposed to tooth CEJs. This is a static landmark which is not affected by the presence or absence of teeth [52].

4.6 Proposed harvesting site

The general consensus is that the region distal of the canine extending to the midpalatal aspect of the first molar is the best zone to harvest a graft [24,27,51]. This is due to the existence of a uniformly thick mucosa, which can provide a maximal tissue graft length of 31.7 mm [3,51]. Furthermore, the palatal ruggae located anteriorly can be avoided together with the neurovascular bundle posteriorly [25]. Taking this into consideration, it should be highlighted that due to disparities in the hard palate anatomy, the dimensions of available donor tissue will differ between individuals [24].

Kim et al [39] (who used an image-analysis system, a more accurate method of measuring the location of the GPA) recommended that particular attention be paid in the first molar region, particularly in individuals with a shallow palate. This is because the diameter of the GPA was found to be larger here and in close proximity to the CEJ and the gingival margin which is different to its relation with the second premolar and second molar. In addition, the palatal mucosa is at its shallowest here due to the bulkiness of the palatal root.

The authors further state that the second molar area is a harder region to access a graft from when compared to the premolar region. It also contains a greater abundance of minor salivary glands and adipose tissue which are not favourable [39]. Due to the abovementioned parameters, they recommended the premolar region (especially the second premolar), as the optimal donor site for grafts with a maximum size and thickness of 9.3mm and 4.0mm respectively, being able to be harvested [39].

This is in contrary to Klosek and Rungruang [38] who reported that there is a high frequency of GPA branching at the level of the first and second premolars in men, and at the first premolar in women and that the path of the GPA was nearer to the alveolar crest at the level of the first premolar [38]. They concluded that a graft of at least 5 mm in height can be harvested between the second premolar and second molar. These results are skewed in that bony hard palates were used for measurements eliminating the possibility of taking the thickness of the palatal mucosa into account.

Tavelli et al proposed a "safety zone" existing between the distal aspects of the canine extending to the second molar. The dimensions recommended included the 2mm of presumed distance from the gingival margin to the CEJ, which would represent an ideal scenario in a periodontally healthy patient with no clinical attachment loss [53].

The partial and complete loss of teeth confounds their use as landmarks for identifying the optimum graft harvesting site. Given this shortcoming, the perpendicular distance from the line bisecting the greater palatine foramina was used as a landmark from which the depth of the GPA could be measured at regular intervals of 3 mm.

The mean depth of the artery at each interval ranged from 6.67 mm to 4.35 mm at 3 mm and 18 mm respectively. Graft thickness has been considered one of the main factors for graft success, with a thickness of at least 2 mm being recommended [3]. Because a safety margin of 2mm from the GPA is required during surgical procedures, it can be extrapolated that a graft of optimum thickness of 2 mm can be obtained along the entire length of the palate, but not without caution particularly anterior to the 16 mm landmark.

Although the safety margin is greater posteriorly, one is limited by access and quality of the graft due to an increase in adipose tissue in this region. Additionally, the diameter of the GPA at this point is at its maximal, with increased complication associated with its potential severing. The findings of this study do not allow conclusions to be made regarding the size of the graft that can be obtained, given that it is predominantly determined by the medio-lateral dimension of the palate whose measurement is facilitated by the presence of teeth (distance from the tooth CEJ to the palatal raphe).

Another proposed landmark to facilitate avoidance of neurovascular impingement involves the palpation of the bony crest. Two palatal grooves, the medial and the lateral, within which

the GPA and GPN reside are separated by a bony crest [26,27]. This bony crest, which seems to exist irrespective of the absence or presence of teeth, has a protective role and the clinician would benefit from identifying it so as to avoid the neurovascular bundle when performing surgery. Although Reiser et al and Benninger et al reported the ability of the clinician to palpate this anatomical landmark, 10 mm in length antero-posteriorly due to its spine type prominence [26], attempts to do so in this study were deemed unsuccessful as mirrored by Dridi et al [54].

4.7 Limitations

Difficulties were encountered whilst trying to dissect the GPA branches due to their thin and friable nature and thus data regarding this parameter could not be elaborated upon. This is unfortunate seeing as one is more likely to sever the numerous collateral branches that the GPA ramified into as opposed to the principal branch.

Yu et al examined 36 hemi-maxillae with the help of a surgical microscope to visualise the GPA and its branching patterns [26]. The most common branching pattern reported (41.7% of cases) consisted of a lateral branch running in the lateral groove of the bony crest, coursing anteriorly from the GPF, and then giving off a medial and a canine branch subsequent to the bony crest.

Unexpected bleeding could occur when performing the primary incision which is in the region of this branch. Furthermore, branches are more predominant on the alveolar process side primarily in the premolar region as opposed to the palatine raphe [38].

Another limitation of this study was the examination of only one population group (White) due to availability, thus extrapolation to different groups is not possible.

CHAPTER 5: CONCLUSION

The palate is the most frequently used site for intra-oral autogenous grafting due to its similar characteristics with the gingiva. Knowledge of the palatal anatomy and its vascularization is essential to prevent complications intra-operatively, the most common of which is severing of the GPA or one of its branches, resulting in haemorrhage.

Safe zones for harvesting grafts in relation to teeth so as to prevent complications have been widely reported in the literature. In cases of partial or complete edentulism, however, traditional markers are inadequate for identifying the optimal site for graft harvesting. This study aimed to identify the depth of the GPA in relation to the overlying mucosa without using tooth landmarks. A new landmark is recommended at the point where the palatal raphe bisects a line adjoining the two GPFs.

In this study, the depth of the GPA was found to decrease gradually from 6.67 mm to 4.35 mm as it coursed anteriorly. Given that a graft thickness of 2 mm is ideal, and a safety zone between the most apical extent of the graft and the GPA should be at least 2 mm, the ideal harvesting site should not exceed 15 mm from this proposed landmark. However, this does not mean that harvesting a graft in line with the 3 mm interval grants the clinician immunity from severing the GPA and caution should be executed at all times.

The anatomic data attained from this study could help clinicians to better plan the graft harvesting region, thereby preventing adverse outcomes. In addition, it is hoped that this study initiates further research in obtaining grafts safely from fully or partially edentate individuals who are the individuals most likely to require grafting procedures.

APPENDIX

Human Research Ethics Committee (Medical)

Golden Jubilee: October 1966 – October 2016

Research Office Secretariat: Senate House Room SH10005, 10th floor. Tel +27 (0)11-717-1252
Medical School Secretariat: P V Tobias Health Sciences Building, 2nd floor
Tel +27 (0)11-717-2700 / 1234 / 1252 / 2656
Private Bag 3, Wits 2050, www.wits.ac.za. Fax +27 (0)11-717-1265
South African National Health Research Ethics Council registration: REC-250208-04
United States Office of Human Research Protections registration: FWA00000715 IRB00001223

Ref: W-CJ-160919-1 19/09/2016

TO WHOM IT MAY CONCERN:

Waiver: This certifies that the following research does not require clearance from the Human Research Ethics Committee (Medical).

Investigator: **Dr S Koutras (Student No 0404632F)**

Project title: **A cadaveric study of the course and characteristics of the greater palatine artery.**

Reason: This study falls within the School of Anatomical Sciences' waiver (W-CJ-140604-1) in terms of the National Health Act concerning donation of cadavers for research purposes. Permission to do a study on a cadaver rests with the Head of the School of Anatomical Sciences; such permission has been obtained. The current waiver is provided to Dr Koutras to satisfy Faculty requirements for a higher degree.

UNIVERSITY OF THE WITWATERSRAND
PROF PE CLEATON-JONES
HREC (MEDICAL)
2016 -09- 19
JOHANNESBURG

Professor Peter Cleaton-Jones

Chair: Human Research Ethics Committee (Medical)

Copy – HREC (Medical) Secretariat: Zanele Ndlovu, Rhulani Mkansi.

REFERENCES

1. Friedman N. Mucogingival surgery. Tex Dent J. 1957;75:358–62.

2. Miller Jr PD. Regenerative and reconstructive periodontal plastic surgery. Mucogingival surgery. Dent Clin North Am. 1988; 32(2):287-306.

3. Song J-E, Um Y-J, Kim C-S, Choi S-H, Cho K-S, Kim C-K, et al. Thickness of Posterior Palatal Masticatory Mucosa: The Use of Computerized Tomography. J Periodontol. 2008; 79(3):406-12.

4. Young B, Woodford P, Gerladine O. Functional histology. Wheater's Functional Histology: A Text and Colour Atlas. 2013. Elsevier Health Sciences;

5. Sullivan HC, Atkins JH. Free Autogenous Gingival Grafts. I Principles of Successful Grafting. J Chem Inf Model. 1968;6:121-9.

6. Langer B, Calagna L. The subepithelial connective tissue graft. J Prosthet Dent. 1980; 44(4):363-7.

7. Langer B. The subepithelial connective tissue graft. A new approach to the enhancement of anterior cosmetics. Int J Periodontics Restor Dent. 1982;(2):22–33.

8. Langer B, Langer L. Subepithelial connective tissue graft technique for root coverage. J Periodontol. 1985; 56(12):715-20.

9. Kim BS, Kim YK, Yun PY, Yi YJ, Lee HJ, Kim SG, et al. Evaluation of peri-implant tissue response according to the presence of keratinized mucosa. Oral Surgery, Oral Med Oral Pathol Oral Radiol Endodontology. 2009; 107(3):e24-8.

10. Bouri A, Bissada N, Al-Zahrani MS, Faddoul F, Nouneh I. Width of keratinized gingiva and the health status of the supporting tissues around dental implants. Int J Oral Maxillofac Implants. 2008;23(2)

11. Covani U, Marconcini S, Galassini G, Cornelini R, Santini S, Barone A. Connective Tissue Graft Used as a Biologic Barrier to Cover an Immediate Implant. J Periodontol. 2007; 78(8):1644-9.

12. Roccuzzo M, Gaudioso L, Bunino M, Dalmasso P. Surgical treatment of buccal soft tissue recessions around single implants: 1-year results from a prospective pilot study. Clin Oral Implants Res. 2014; 25(6):641-6.

13. Griffin TJ, Cheung WS, Zavras AI, Damoulis PD. Postoperative Complications Following Gingival Augmentation Procedures. J Periodontol. 2006; 77(12):2070-9.

14. Kolliyavar B, Setty S, Thakur S. Determination of thickness of palatal mucosa. J Indian Soc Periodontol. 2012; 16(1):80.

15. Park JB. Increasing the width of keratinized mucosa around endosseous implant using acellular dermal matrix allograft. Implant Dent. 2006;15(3):275-81.

16. Sanz M, Lorenzo R, Aranda JJ, Martin C, Orsini M. Clinical evaluation of a new collagen matrix (Mucograft® prototype) to enhance the width of keratinized tissue in patients with fixed prosthetic restorations: A randomized prospective clinical trial. J Clin Periodontol. 2009;36 (10):868-76.

17. Wei P-C, Laurell L, Lingen MW, Geivelis M. Acellular Dermal Matrix Allografts to Achieve Increased Attached Gingiva. Part 2. A Histological Comparative Study. J Periodontol. 2002;73 (3):257-65.

18. Chambrone L, Chambrone D, Pustiglioni FE, Chambrone LA, Lima LA. Can subepithelial connective tissue grafts be considered the gold standard procedure in the treatment of Miller Class I and II recession-type defects? Journal of Dentistry. 2008.1;36(9):659-71.

19. Fu J-H, Hasso DG, Yeh C-Y, Leong DJM, Chan H-L, Wang H-L. The Accuracy of Identifying the Greater Palatine Neurovascular Bundle: A Cadaver Study. J Periodontol. 2011; 82(7):1000-6.

20. Brasher WJ, Rees TD, Boyce WA. Complications of Free Grafts of Masticatory Mucosa. J Periodontol. 2013; 46(3):133-8.

21. Standring S, Tunstall R. Gray's Anatomy: The Anatomical Basis Of Clinical Practice. Ann R Coll Surg Engl. 2006; 26(10):2703.

22. Li KK, Meara JG, Alexander A. Location of the descending palatine artery in relation to the Le fort I osteotomy. J Oral Maxillofac Surg. 1996; 54(7):822-5.

23. Methathrathip D, Apinhasmit W, Chompoopong S, Lertsirithong A, Ariyawatkul T, Sangvichien S. Anatomy of greater palatine foramen and canal and pterygopalatine fossa in Thais: Considerations for maxillary nerve block. Surg Radiol Anat. 2005; Dec; 27(6):511-6.

24. Reiser GM, Bruno JF, Mahan PE, Larkin LH. The subepithelial connective tissue graft palatal donor site: anatomic considerations for surgeons. Int J Periodontics Restorative Dent. 1996; 16(2).

25. Greenstein G, Cavallaro J, Tarnow D. Practical Application of Anatomy for the Dental Implant Surgeon. J Periodontol. 2008; 79(10):1833-46.

26. Yu SK, Lee MH, Park BS, Jeon YH, Chung YY, Kim HJ. Topographical relationship of the greater palatine artery and the palatal spine. Significance for periodontal surgery. J Clin Periodontol. 2014; 41(9):908-13.

27. Benninger B, Andrews K, Carter W. Clinical measurements of hard palate and implications for subepithelial connective tissue grafts with suggestions for palatal nomenclature. J Oral Maxillofac Surg. 2012; 70(1):149-53.

28. Studer SP, Allen EP, Rees TC, Kouba A. The Thickness of Masticatory Mucosa in the Human Hard Palate and Tuberosity as Potential Donor Sites for Ridge Augmentation Procedures. J Periodontol. 1997; 68(2):145-51.

29. Eger T. Ultrasonic determination of gingival thickness Subject variation and influence of tooth type and clinical features. J Clin Periodontol. 1996; 23(9):839-45.

30. Olssoin M, Lindhe J, Marinello CP. On the relationship between crown form and clinical features of the gingiva in adolescents. J Clin Periodontol. 1993; 20(8):570-7.

31. Schacher B, Bürklin T, Horodko M, Raetzke P, Ratka-Krüger P, Eickholz P. Direct thickness measurements of the hard palate mucosa. Quintessence Int. 2010; 41(8).

32. Müller HP, Schaller N, Eger T, Heinecke A. Thickness of masticatory mucosa. J Clin

Periodontol. 2000; 27(6):431-6

33. Tomaszewska IM, Tomaszewski KA, Kmiotek EK, Pena IZ, Urbanik A, Nowakowski M, et al. Anatomical landmarks for the localization of the greater palatine foramen - A study of 1200 head CTs, 150 dry skulls, systematic review of literature and meta-analysis. J Anat. 2014; 225(4):419-35.

34. Langenegger JJ, Lownie JF, Cleaton-Jones PE. The relationship of the greater palatine foramen to the molar teeth and pterygoid hamulus in human skulls. J Dent. 1983; 11(3):249-56.

35. Hassanali J, Mwaniki D. Palatal analysis and osteology of the hard palate of the Kenyan African skulls. Anat Rec. 1984; 209(2):273-80.

36. Sarilita E, Soames R. Morphology of the Hard Palate: a Study of Dry Skulls and Review of the Literature. Rev Arg Anat Clin. 2015; 7(1):34-43.

37. Se HH, Jae HS, Young HJ, Byung GK, Jin Hee C, Jun MK. An anatomic study using three-dimensional reconstruction for pterygopalatine fossa infiltration via the greater palatine canal. Clin Anat. 2011; 24(5):576-82.

38. Klosek SK, Rungruang T. Anatomical study of the greater palatine artery and related structures of the palatal vault: Considerations for palate as the subepithelial connective tissue graft donor site. Surg Radiol Anat. 2009; 31(4):245-50.

39. Kim DH, Won SY, Bae JH, Jung UW, Park DS, Kim HJ, et al. Topography of the greater palatine artery and the palatal vault for various types of periodontal plastic surgery. Clin Anat. 2014; 27(4):578-84.

40. Ramachandra SS, Mehta DS, Sandesh N, Baliga V, Amarnath J. Periodontal probing systems: a review of available equipment. Compend Contin Educ Dent. 2011; 3(3).

41. Ulijaszek SJ, Kerr DA. Anthropometric measurement error and the assessment of nutritional status. Br J Nutr. 1999; 82(3):165-77.

42. Wilcoxon F, Paiardini A, Piscitelli M, Pascarella S, Bechor-Shental D, Martz E, et al. Individual Comparisons by Ranking Methods. Biometrics Bull. 1945; 1(6):80-3.

43. Mann HB, Whitney DR. On a test of whether one of two random variables is stochastically larger than the other. Statistics (Ber). 1947: 50-60.

44. Kruskal WH, Wallis WA. Use of Ranks in One-Criterion Variance Analysis. J Am Stat Assoc. 1952; 47(260):583-621.

45. Holm S. A Simple Sequentially Rejective Multiple Test Procedure Author(s): Scand J Stat. 1979: 65-70.

46. Spearman C. The proof and measurement of association between two things. By C. Spearman, 1904. Am J Psychol. 1987; 100(3/4):441-71.

47. Kramer B, Hutchinson EF. Transformation of a cadaver population: Analysis of a South African cadaver program, 1921-2013. Anat Sci Educ. 2015; 8(5):445-51.

48. Lin LI-K. A Concordance Correlation Coefficient to Evaluate Reproducibility. Biometrics. 1989; 255-68.

49. J. S, Z. H, A. Č. Thickness of masticatory mucosa in the human hard palate and tuberosity dependent on gender and body mass index. Coll Antropol. 2005; 15;29(1):243-7.

50. Cho K-H, Yu S-K, Lee M-H, Lee D-S, Kim H-J. Histological assessment of the palatal mucosa and greater palatine artery with reference to subepithelial connective tissue grafting. Anat Cell Biol. 2013; 46(3):171-6.

51. Monnet-Corti V, Santini A, Glise J-M, Fouque-Deruelle C, Dillier F-L, Liébart M-F, et al. Connective Tissue Graft for Gingival Recession Treatment: Assessment of the Maximum Graft Dimensions at the Palatal Vault as a Donor Site. J Periodontol. 2006; 77(5):899-902.

52. Johnson K. A study of the dimensional changes occurring in the maxilla after tooth extraction. Part III. Open face immediate denture treatment. Aust Dent J. 1964; 9(2):127-34.

53. Tavelli L, Barootchi S, Ravidà A, Oh TJ, Wang HL. What Is the Safety Zone for Palatal Soft Tissue Graft Harvesting Based on the Locations of the Greater Palatine

Artery and Foramen? A Systematic Review. Journal of Oral and Maxillofacial Surgery. 2019.

54. Dridi S-M, Chousterman M, Danan M, Gaudy JF. Haemorrhagic risk when harvesting palatal connective tissue grafts: a reality? Perio—Periodontal Practices Today. 2008; 5(4):231-40.