

https://dspace.org/

Fissures of the frontal operculum in as a South African sample

Kamanzi-wa, Sylvia

2006-11-16T07:36:51Z
http://hdl.handle.net/10539/1759

Downloaded from a DSpace repository. https://dspace.org/

FISSURES OF THE FRONTAL OPERCULUM IN A SOUTH AFRICAN SAMPLE

Sylvia Kamanzi-wa

A dissertation submitted to the Faculty of Health Sciences,

University of Witwatersrand, Johannesburg,

in fulfilment of the requirements for the

degree of Master of Science in Anatomy.

Johannesburg, 2006

DECLARATION

I, SYLVIA KAMANZI-WA, declare this dissertation to be my own work. It is being submitted in fulfilment of the requirements for the degree of Master of Science in Anatomy, at the University of Witwatersrand. It has not been submitted before for any degree or examination at this or any other University.

_____

DATED at JOHANNESBURG on this the _____ day of _____ 2006.

To

My Family,

Especially my children, Brian and Conchita

ABSTRACT

This study primarily seeks to confirm two systems of classifying the sulci of the frontal operculum[1] (F3): the radiologically derived system of Ebeling et al (1989) involving *four Types of Sulcal Connections*, and the anatomical classification of the anterior rami of the lateral fissure, involving *three patterns*. Sulcal- and intersulcal- lengths are also considered.

The sample consisted of 220 cadaveric hemispheres; 65 of which were whole brains (control category); and 90 consisting of equal numbers of separate right- and left-hemispheres (case category). Specimens were orientated by examining relevant features of: the lateral fissure; the postcentral sulcus; and the central fissure. Features of the remaining boundary sulci (precentral sulcus / sulci, and inferior frontal sulcus) of F3 were also considered. The focus was on examining the: frequency of occurrence, shape, and connections of the sulci of the F3. The sulci of F3 were designated as: *major sulci* [anterior ascending (AAR)- and anterior horizontal (AHR)- rami, and stem of the anterior rami when present); and *accessory sulci* (sulci of the –pars opercularis and –pars triangularis). Sulcal lengths were measured using thread, with needles as anchors. Intersulcal lengths were recorded as straight-line distances between parallel pins inserted into the sulci of the frontoparietal operculum. Specimens fixed outside the cranial cavity were excluded from measurement. The reliability of the data was monitored, by repeating the observations.

The two systems of classification were broadly confirmed. The criteria for the Types of Sulcal Connections were modified in view of the findings on double precentral sulci and the connections of the opercular sulcus (which occurred as either one or as two sulci). A sulcus of the pars triangularis (which occurred as either one, two, or as three sulci) was found to be a useful landmark. The Chi-square test was applied to the data in the two systems of classification. There were no significant interhemispheric differences with respect to the incidences of: Types 1-4 of Sulcal Connections, or Patterns of the Anterior Rami (*ℐ, Y,* and *VU*). Sulcal lengths were similar to that reported by Ono et al (1990). The Student t-test was applied to sample sizes 18 and above. No significant interhemispheric differences, in the lengths of the sulci that were considered, were found. A significant

[1] The definition of the frontal operculum as the inferior frontal gyrus only, is used for the purposes of this study. The frontal operculum may also be abbreviated as F3.

difference was found in two instances when comparing the case- and control- categories. Intersulcal distances are reported on in the frontal- and frontoparietal- operculum.

ACKNOWLEDGEMENTS

1. My husband **Kamanzi-wa-Binyavanga** (Department of Statistics, Walter Sisulu University) - thank you for

    - The support, especially during my absences from home, as well as the
    - Guidance and assistance with the statistics.

2. My mother Soobokuim Poovan, brother Denny and his wife Sally – thank you for the support.

3. My supervisors – thank you to

    - **Dr E Gilisson**, for the assistance with the presentation of the design of the experiment, to the departmental and faculty review boards.
    - **Professor JC Allan**, for kindly agreeing to take me on board after the departure of Dr Gilisson (soon after the faculty review), and forgiving me my eccentricities. ***It has been a privilege to be your student***.

4. Technical staff - thank you for assistance with the collection and storage of specimens:

    - **Dr Mathura and Mr Siva** (Department of Human Biology, Durban Institute of Technology);
    - **Mr Guzana** (Department of Anatomy, Walter Sisulu University); and

- **Too numerous to mention individually (Department of Anatomical Sciences, University of Witwatersrand**)

5. Other members of staff at the Department of Anatomical Sciences, University of Witwatersrand - thank you to

    - **S Rodgers** for assistance with the magnifier and the processing of the photographic negatives
    - **M Dayal, V Clausens, D Lizamore,** for assistance with the microscribe digitiser
    - **F Ladner**, **G Veale,** and **O Oyedele** for general advice and/or assistance
    - **P Manger** for the paper by Tomaiuolo et al (1999).

6. ***The South African Institute of Race Relations, Bursary Department – thank you for the two years of financial assistance.***

    (REFERENCE NUMBER: USTELP / WITS / 0699/ 2002)

7. **V Tchokonte- Nana** (Department of Anatomy, Walter Sisulu University) – thank you for the translation of Galaburda (1980).

Section	TABLE OF CONTENTS	Page
	DECLARATION	(ii)
	DEDICATION	(iii)
	ABSTRACT	(iv)
	ACKNOWLEDGEMENTS	(vi)
	TABLE OF CONTENTS	(viii)
	LIST OF FIGURES	(xvi)
	LIST OF TABLES	(xxii)
1	**INTRODUCTION**	**1**
1.1	Opening Remarks	**1**
1.2	Summary of the Aims and Objectives of the Present Study	**6**
1.2.1	The Short Term Aims and Objectives	**6**
1.2.1.1	The Broad Questions posed here are:	**6**
1.2.1.2	Descriptive Objectives	**7**
1.2.1.3	Quantitative Objectives	**8**
1.2.2	The Long Term Aims of this Study	**9**
1.3	Gyri and Sulci are Defined Relative to Each Other	**9**
1.4	The General Organisation of Gyri and Sulci on the Superolateral aspect of the Frontal Lobe	**12**
1.5	The Concept of Operculation	**13**
1.6	The Anatomy of the Frontal Operculum	**17**
1.7	The Justification for this Study	**20**
1.8	Literature Survey	**22**

Section	TABLE OF CONTENTS	Page
1.8.1	The Reference study for the Types of Connections (Ebeling et al, 1989)	**22**
1.8.2	References for the Patterns of the Anterior Rami of the Lateral Fissure	**32**
1.8.2.1	The Studies of Cunningham (1890 and 1892), Eberstaller (1890), and Connolly (1950)	**32**
1.8.2.2	The Study of Ide (1999)	**34**
1.8.2.3	The Study of Ono et al (1990)	**37**
1.8.3	References for the Sulci of the Pars Opercularis	**41**
1.8.4	References for the Sulci of the Pars Triangularis	**45**
1.8.5	References on Measurements in the Frontal Operculum (F3)	**46**
1.8.6	The Questions posed by the Present Study Relative to the Literature Survey	**47**
1.9	Further on the Defining Features of Gyri and Sulci	**51**
1.10	A Synopsis of the Developmental Anatomy associated with Gyri and Sulci	**53**
2.0	**MATERIALS and METHODS**	**58**
2.1	The Broad Questions posed by the Present Study (Relative to the Descriptive Objectives)	**58**
2.1.1	Questions relating to the Fissures and Sulci that were used for Orientation Purposes	**58**
2.1.2	Questions relating to the Sulci that form the Boundaries of the Frontal Operculum (F3)	**59**

Section	TABLE OF CONTENTS	Page
2.1.3	Questions relating to the Sulci that are found within F3 (for Ungrouped data)	**59**
2.1.4	Questions relating to the Sulci that are found within F3 (for Grouped data)	**60**
2.2	The Broad Questions posed by the Present Study relative to the Quantitative Objectives	**61**
2.2.1	Questions associated with the Measurements of Ungrouped data	**61**
2.2.2	Questions associated with the Measurements of Grouped data	**62**
2.2.3	The Question posed by the Present Study associated with Alternative Methods for Acquiring Quantitative Data	**63**
2.3	The Sample used in the Present sStudy	**63**
2.3.1	The Type of Specimens used by the Present sStudy	**63**
2.3.2	The Effect of the Sample Type on the Broad Questions posed by the Present Study	**64**
2.3.3	The Source of the specimens and the Exclusion Criteria	**65**
2.4	Ethics Clearance	**67**
2.5	The Pre-Recording Phase	**68**
2.6	The Boundaries of F3 as was used in the Present Study	**68**
2.7	Preceding Comments on the Physical Recording of the Descriptive data	**77**
2.8	The Method used for Recording the Descriptive data in	**78**

Section	TABLE OF CONTENTS	Page
	the Present Study	**78**
2.8.1	Identification, Orientation, and Pattern Recognition of the Fissures and Sulci that are relevant to the Present Study	**78**
2.8.2	Features of the relevant Fissures and Sulci that were considered pertinent to the Present Study	**87**
2.9	The Direct Method used for Recording Sulcal Lengths (Quantitative data) in the Present Study	**97**
2.10	The Method used for the Recording of Intersulcal Lengths (Quantitative data) in the Present sStudy	**103**
2.11	Less Direct Methods Examined, for Obtaining Quantitative data	**108**
2.11.1	Data Recovery through use of Photographic Negatives	**108**
2.11.2	Data Recovery from Photographs through use of Printed Images	**108**
2.11.3	Data Recovery from Pen Tracings of the Surface Fissures and Sulci	**109**
2.11.4	Data Recovery through use of the Microscribe Digitiser	**110**
2.12	Methods used for Analysing Data	**111**
2.12.1	Methods for Analysing Descriptive data	**111**
2.12.2	Methods for Analysing Quantitative data	**112**
3	**RESULTS**	**114**
3.1	Report on the Methods used to Acquire Data in the Present Study	**114**

Section	TABLE OF CONTENTS	Page
3.1.1	Report on Descriptive Methods used in the Present Study	**114**
3.1.2	Report on Quantitative Methods used in the Present Study	**121**
3.1.2.1	Observations on the Measurement of Sulcal Lengths in the Trial Run	**121**
3.1.2.2	Consequences arising from the Initial Observations on the measurement of Sulcal Lengths	**122**
3.1.2.3	Observations on the Measurement of Intersulcal Lengths	**128**
3.2	Report on the Descriptive Part of the Present Study	**128**
3.2.1	Report on the Orientating Fissures and Sulci	**128**
3.2.1.1	The Central Fissure	**129**
3.2.1.2	The Postcentral Sulcus	**133**
3.2.2	Report on the Boundary Sulci of the Frontal Operculum (F3)	**136**
3.2.2.1	The Precentral Sulcus	**137**
3.2.2.2	The Inferior Frontal Sulcus	**145**
3.2.3	Report on the Sulci of F3 with respect to Ungrouped Data	**148**
3.2.3.1	Report on the Major Sulci of F3	**149**
3.2.3.2	Report on the Accessory Sulci of F3	**159**
3.2.4	Report on the Sulci of F3 with respect to data Grouped according to the Types of Connections	**172**
3.2.4.1	The Modification of the Criteria for the Types of Connections	**173**
3.2.4.2	The Interhemispheric Comparison of the Types of Connections (Modified)	**182**

Section	TABLE OF CONTENTS	Page
3.2.5	Report on the Sulci of F3 with respect to data Grouped according to the Patterns of the Anterior Rami	**184**
3.2.6	Incidences of the Patterns of the Anterior Rami with respect to the Types of Connections	**187**
3.3	Report on the Quantitative Part of the Present Study	**189**
3.3.1	Overview of the manner in which the Quantitative Data was handled	**189**
3.3.2	Report on the Mean Lengths of Individual Sulci in F3, for Ungrouped and Grouped Data	**193**
3.3.2.1	Mean Lengths, Standard Deviations, and Coefficients of Variation, for Individual Major Sulci in F3	**194**
3.3.2.2	Mean Lengths, Standard Deviations, and Coefficients of Variation, for Individual Accessory Sulci in F3	**198**
3.3.3	Interhemispheric studies on the Mean Lengths of Individual Sulci	**207**
3.3.4	Control and Case Studies	**219**
3.3.5	Report on Mean Intersulcal Lengths in the Frontoparietal Operculum	**222**
4	**DISCUSSION**	**225**
4.1	Discussion on the Methods used to Acquire Data in the Present Study	**226**
4.1.1	Discussion on the Methods used to acquire Descriptive Data, the Associated Limitations and the Recommendations	**226**

Section	TABLE OF CONTENTS	Page
	arising There-from	**226**
4.1.2	Discussion on the Methods used to acquire Quantitative Data, their Limitations, and the Recommendations arising There-from	**228**
4.1.2.1	Direct Methods of Measuring Sulcal- and Intersulcal-Lengths	**228**
4.1.2.2	Indirect Methods of Measuring Sulcal- and Intersulcal-Lengths	**229**
4.1.3	Summary of the Recommendations arising from the Discussion on Methods	**231**
4.2	Discussion of the Descriptive Aspect of the Present Study	**231**
4.2.1	Discussion on the Orientating Fissures and Sulci relative to the Remaining Questions posed in Chapter 2	**232**
4.2.2	Discussion on the Boundary Sulci relative to the Remaining Questions posed in Chapter 2	**236**
4.2.3	Discussion on the Sulci of the Frontal Operculum relative to the Remaining Questions posed in Chapter 2	**240**
4.2.3.1	Discussion on the Major Sulci of the Frontal Operculum	**241**
4.2.3.2	Discussion on the Accessory Sulci of the Frontal Operculum	**241**
4.2.4	Discussion on the Types of Connections and Patterns of The Anterior Rami in the Frontal Operculum	**247**
4.2.5	Summary of the Recommendations arising from the Discussion on the Descriptive Study	**257**

Section	TABLE OF CONTENTS	Page
4.3	Discussion on the Quantitative Aspect of the Present Study	**258**
5	**CONCLUSION**	**264**
	APPENDIX A: Report on the Data obtained at the Durban Institute of Technology	**265**
	APPENDIX B: A Copy of the Waiver of the Need for an Ethics Clearance	**267**
	APPENDIX C: The Descriptive Record in Diagrammatic Form	**268**
	APPENDIX D: Record of which specimens were used in the Quantitative Study	**312**
	APPENDIX E: Record of Individual Sulcal Lengths for Ungrouped Data	**314**
	APPENDIX F: Record of Individual Sulcal Lengths for Data Grouped According to the Types of Sulcal Connections in the Frontal Operculum	**338**
	APPENDIX G: Record of Individual Sulcal Lengths for Data Grouped According to the Patterns of the Anterior Rami	**349**
	APPENDIX H: Record of Intersulcal Lengths	**361**
	APPENDIX I: The Procedure for the Shapiro-Wilk Test	**394**
	APPENDIX J	**396**
	REFERENCES	**400**

Figure	LIST OF FIGURES	Page
1.1	Concepts of: gyri, sulci, and lobulation	**3**
1.2	The primary and secondary areas of study	**3**
1.3	Sulci of the Frontal and Parietal lobes relevant to the Current Study	**4**
1.4	Idealised gyri and sulci (in section)	**4**
1.5	Opercula of the lateral fissure	**14**
1.6	Gyri of the Frontal Lobe	**14**
1.7	The Major sulci of the Frontal Operculum	**15**
1.8	The three components of the Frontal Operculum	**15**
1.9	The Types of Connections of Ebeling (Ebeling et al, 1989)	**24**
1.10	Major patterns of the Anterior Rami of the lateral fissure (Cunningham, 1890; Eberstaller, 1890)	**35**
1.11	The Major Patterns of the Anterior Rami of the lateral fissure [Ide (1999, and Ono (1990)]	**38**
1.12	Accessory sulci of the Frontal Operculum	**43**
2.1	Boundaries of the Inferior Frontal Gyrus in the Presence of a Single Precentral Sulcus	**69**
2.2	Boundaries of the Inferior Frontal Gyrus in the presence of Two Precentral sulci	**70**
2.3	An Aid to Pattern Recognition in the Parietal Operculum	**82**
2.4	An Aid to Pattern Recognition in the Frontal Operculum	**82**
2.5	Features of the Central Fissure	**88**

Figure	LIST OF FIGURES	Page
2.6	Features of the Postcentral Sulcus	**88**
2.7	Shape and Direction of the Anterior Rami of the Lateral Fissure	**92**
2.8	Shape and Direction of the Accessory Sulci	**92**
2.9 (a)	Locating the Origin of a Sulcus	**99**
2.9 (b)	Marking the Thread	**99**
2.9 (c)	Thread Manipulation	**99**
2.9 (d)	Needle Insertion	**100**
2.9 (e)	Pin Insertion	**100**
2.9 (f)	Marking the Termination of a Sulcus	**100**
2.9 (g)	Filing of the Thread	**101**
2.10 (a)	Placement of the Pins for the Measurement of Intersulcal Distances in the Frontoparietal Operculum	**101**
2.20 (b)	Measurement of Intersulcal Distances in the Frontoparietal Operculum	**105**
2.10 (c)	Measurement in the Pars Triangularis	**105**
3.1	Identification of Sulci in the Frontoparietal Operculum [1]	**116**
3.2	Identification of Sulci in the Frontoparietal Operculum [2]	**117**
3.3	Identification of Sulci in the Frontoparietal Operculum [3]	**118**
3.4	A Further note on Sulci in the Frontal Operculum	**119**
3.5	A True- versus a Pseudo- connection with the Lateral Fissure	**120**
3.6	The Effect of Distance from the Camera on the	**124**

Figure	LIST OF FIGURES	Page
	Perception of Sulcal Length	**124**
3.7	Magnification changes Relative to Changes in Height from the Camera	**124**
3.8	Pen Tracings of the External Cerebral Surface	**125**
3.9	Terminations of the Inferior End of Orientating and Boundary Sulci	**125**
3.10	The Three Segment Form of the Central Fissure	**130**
3.11	Segmentation of the Postcentral and Precentral Sulci	**130**
3.12	Double Precentral Sulci and the Inferior Frontal Sulcus	**139**
3.13	The Four Segment form of the Precental Sulcus and the Two Segment form of the Inferior Frontal Sulcus	**141**
3.14	Selected shapes of the sulci in the Frontal Operculum	**151**
3.15	The Predominance of the Anterior Ascending Ramus over the Anterior Horizontal Ramus	**152**
3.16	A Connection of the Anterior Ascending Ramus with the Inferior Frontal Sulcus	**152**
3.17	The Location of the Anterior Horizontal Ramus at the Orbital Margin	**157**
3.18	The Location of the Anterior Horizontal Ramus on the Orbital Surface	**157**
3.19	Infrequent Connections of the Anterior Rami	**158**
3.20	Accessory Sulci	**158**
3.21	A Case of Double Opercular Sulci and a Single Triangular	**160**

Figure	**LIST OF FIGURES**	Page
	Sulcus	**160**
3.22	Type 1 (of Sulcal Connections) with both *VU- and Y-patterns of the anterior rami.*	**175**
3.23	Type 2 (of Sulcal Connections) with the *VU pattern* of the Anterior Rami	**176**
3.24	Type 3 (of Sulcal Connections) with Single and Double Precentral Sulci	**178**
3.25	Type 4 (of Sulcal Connections)	**179**
3.26	The *$\mathscr{I}$ pattern* of the Anterior Rami	**179**
3.27	A Summary of the Types of Sulcal Connections in the Presence of a Single Precentral Sulcus	**180**
3.28	A Summary of the Types of Sulcal Connections in the Presence of Double Precentral Sulci	**181**
3.29	Mean Lengths of the Stem clustered according to Ungrouped and Grouped Data	**195**
3.30	Mean Lengths of the Anterior Ascending Ramus clustered according to Ungrouped and Grouped Data	**196**
3.31	Mean Lengths of the Anterior Horizontal Ramus clustered according to Ungrouped and Grouped Data	**197**
3.32	Mean Lengths of the Sole Opercular Sulcus clustered according to Ungrouped and Grouped Data	**198**
3.33	Mean Lengths of the First Opercular Sulcus clustered according to Ungrouped and Grouped Data	**199**

Figure	LIST OF FIGURES	Page
3.34	Mean Lengths of the Second Opercular Sulcus clustered according to Ungrouped and Grouped Data	**200**
3.35	Mean Lengths of the Sole Triangular Sulcus clustered according to Ungrouped and Grouped Data	**201**
3.36	Mean Lengths of the Anterior of Two Triangular Sulci clustered according to Ungrouped and Grouped Data	**202**
3.37	Mean Lengths of the Posterior of Two Triangular Sulci clustered according to Ungrouped and Grouped Data	**203**
3.38	Mean Lengths of the Anterior of Three Triangular Sulci clustered according to Ungrouped and Grouped Data	**204**
3.39	Mean Lengths of the Middle of Three Triangular Sulci clustered according to Ungrouped and Grouped Data	**205**
3.40	Mean Lengths of the Posterior of Three Triangular Sulci clustered according to Ungrouped and Grouped Data	**206**
3.41	Mean Lengths of the Stem clustered according to Cerebral Hemisphere	**208**
3.42	Mean Lengths of the Anterior Ascending Ramus clustered according to Cerebral Hemisphere	**208**
3.43	Mean Lengths of the Anterior Horizontal Ramus clustered according to Cerebral Hemisphere	**209**
4.44	Mean Lengths of the Sole Opercular Sulcus clustered according to Cerebral Hemisphere	**209**
3.45	Mean Lengths of the First Opercular Sulcus clustered	**210**

Figure	LIST OF FIGURES	Page
	according to Cerebral Hemisphere	**210**
3.46	Mean Lengths of the Second Opercular Sulcus clustered according to Cerebral Hemisphere	**210**
3.47	Mean Lengths of the Sole Triangular Sulcus clustered according to Cerebral Hemisphere	**211**
3.48	Mean Lengths of the Anterior of Two Triangular Sulci clustered according to Cerebral Hemisphere	**211**
3.49	Mean Lengths of the Posterior of Two Triangular Sulci clustered according to Cerebral Hemisphere	**212**
3.50	Mean Lengths of the Anterior of Three Triangular Sulci clustered according to Cerebral Hemisphere	**212**
3.51	Mean Lengths of the Middle of Three Triangular Sulci clustered according to Cerebral Hemisphere	**213**
3.52	Mean Lengths of the Posterior of Three Triangular Sulci clustered according to Cerebral Hemisphere	**213**

Table	**LIST OF TABLES**	Page
1.1	The Incidence of the Types of Connections in Ebeling et al (1989)	**26**
1.2	The Incidences of Connections between the Central Fissure and the Lateral Fissure	**26**
1.3	The Incidences of Connections between the Inferior Precentral Sulcus and the Lateral Fissure	**27**
1.4	The Incidences of Connections between the Inferior Precentral Sulcus and the Inferior Frontal Sulcus	**27**
1.5	The Incidence of Patterns of the Anterior Rami as reported by Ide et al (1999) and Ono et al (1990)	**39**
1.6	Connections of the Diagonal (Opercular) sulcus (Ono, et al, 1990)	**44**
1.7	Lengths of Sulci in the frontal operculum	**46**
2.1	Sample source and number	**65**
2.2	Patterns of the Inferior Frontal Sulcus (Ono, 1990)	**71**
3.1	The Pattern of the Central Fissure (CF) as a whole	**131**
3.2	The Shape of the Inferior Termination of the CF	**132**
3.3	The Connections of the Inferior end of the CF at and below the level of the Inferior Frontal Sulcus	**132**
3.4	The Frequency of Occurrence of the Anterior- and Posterior- Subcentral Sulci	**133**
3.5	The Pattern of the Postcentral sulcus as a whole	**135**
3.6	The Shape of the Inferior Termination of the Postcentral	**135**

Table	LIST OF TABLES	Page
	Sulcus	**135**
3.7	The Connections of the Inferior Termination of the Postcentral Sulcus at and below the level of the Inferior Frontal Sulcus	**136**
3.8	The Incidence of the Double and Single Precentral Sulci	**138**
3.9	The Pattern of the Single Precentral sulcus (as a whole)	**140**
3.10	The Pattern of the Anterior Precentral sulcus (as a whole)	**140**
3.11	The Pattern of the Posterior Precentral sulcus (as a whole)	**142**
3.12	The Shape of the Inferior Termination of the Single Precentral Sulcus	**142**
3.13	The Shape of the Inferior Termination of the Anterior Precentral Sulcus	**143**
3.14	The Shape of the Inferior Termination of the Posterior Precentral Sulcus	**143**
3.15	Connections of the Single Precentral Sulcus at and below the level of the Inferior Frontal Sulcus	**144**
3.16	Connections of the Anterior Precentral Sulcus at and below the level of the Inferior Frontal Sulcus	**144**
3.17	Connections of the Posterior Precentral Sulcus at and below the level of the Inferior Frontal Sulcus	**145**
3.18	Patterns of the Inferior Frontal Sulcus as a whole	**146**
3.19	Connections of the Posterior end of the Inferior Frontal Sulcus with either the Inferior Precentral Sulcus or the	**147**

Table	LIST OF TABLES	Page
	Inferior Precentral Sulcus Anterior	**147**
3.20	Total number of branches of the Inferior Frontal Sulcus into F3	**147**
3.21	The Incidence of the Accessory Sulci as Branches of the Inferior Frontal Sulcus (including notches)	**148**
3.22	The Frequency of Occurrence of the Anterior Ascending Ramus	**150**
3.23	The Shape of the Anterior Ascending Ramus as a whole	**153**
3.24	The Connections of the Anterior Ascending Ramus	**154**
3.25	The Frequency of Occurrence and Location of the Anterior Horizontal Ramus	**154**
3.26	The Shape of the Anterior Horizontal Ramus as a whole	**155**
3.27	The Connections of the Anterior Horizontal Ramus	**156**
3.28	The Frequency of Occurrence of the Opercular Sulcus and the Number of such Sulci when it was present as more than One Sulcus	**159**
3.29	The Shape of the Opercular Sulcus when it was present alone	**161**
3.30	The Shape of the Opercular Sulcus when it was Present as Two Sulci	**163**
3.31	The Connections of the Opercular Sulcus when it was present alone	**164**
3.32	The Connections of the Opercular Sulcus when it was	**165**

Table	LIST OF TABLES	Page
	was present as Two Sulci	**165**
3.33	The Frequency of Occurrence of the Triangular Sulcus and the Number of such Sulci when it was present as more than One Sulcus	**166**
3.34	The Shape of the Triangular Sulcus when it was present alone	**167**
3.35	The Shape of the Triangular Sulci when they were present as Two Sulci	**168**
3.36	The Shape of the Triangular Sulci when they were present as Three Sulci	**169**
3.37	The Connections of the Triangular Sulcus when it was present alone	**171**
3.38	The Connections of the Triangular Sulcus when they were present as Two Sulci	**171**
3.39	The Connections of the Triangular Sulcus when they were present as Three Sulci	**172**
3.40	The Incidence of the Types of Connections relative to the Right and Left cerebral hemispheres in the Control group	**182**
3.41	The Incidence of the Types of Connections relative to the Right and Left cerebral hemispheres in the Case group	**183**
3.42	The Incidence of the Patterns of the Anterior Rami relative to the Right and Left cerebral hemispheres in the Control group	**185**

Table	LIST OF TABLES	Page
3.43	The Incidence of the Patterns of the Anterior Rami relative to the Right and Left cerebral hemispheres in the Case group	**186**
3.44	The Incidence of the Patterns of the Anterior Rami with Respect to the Types of Connections in the Control group	**187**
3.45	The Incidence of the Patterns of the Anterior Rami with Respect to the Types of Connections in the Case group	**188**
3.46	Mean lengths, standard deviations, and coefficients of variation, for the Stem for ungrouped and grouped data in F3	**195**
3.47	Mean lengths, standard deviations, and coefficients of variation, for the Anterior Ascending Ramus for ungrouped and grouped data in F3	**196**
3.48	Mean lengths, standard deviations, and coefficients of variation, for the Anterior Horizontal Ramus for ungrouped and grouped data in F3	**197**
3.49	Mean lengths, standard deviations, and coefficients of variation, for the Sole Opercular (accessory) sulcus, for ungrouped and grouped data in F3	**198**
3.50	Mean lengths, standard deviations, and coefficients of variation, for the First Opercular (accessory) sulcus, for ungrouped and grouped data in F3	**199**
3.51	Mean lengths, standard deviations, and coefficients of variation, for the Second Opercular (accessory)	**200**

Table	LIST OF TABLES	Page
	sulcus, for ungrouped and grouped data in F3	**200**
3.52	Mean lengths, standard deviations, and coefficients of variation, for the Sole Triangular (accessory) sulcus, for ungrouped and grouped data in F3	**201**
3.53	Mean lengths, standard deviations, and coefficients of variation, for the Anterior Triangular (accessory) sulcus, when the triangular sulcus was present as two sulci, for ungrouped and grouped data in F3	**202**
3.54	Mean lengths, standard deviations, and coefficients of variation, for the Posterior Triangular (accessory) sulcus, when the triangular sulcus occurred as two sulci, for ungrouped and grouped data in F3	**203**
3.55	Mean lengths, standard deviations, and coefficients of variation, for the Anterior Triangular (accessory) sulcus, when the triangular sulcus was present as three sulci, for ungrouped and grouped data in F3	**204**
3.56	Mean lengths, standard deviations, and coefficients of variation, for the Middle Triangular (accessory) sulcus, for ungrouped and grouped data in F3	**205**
3.57	Mean lengths, standard deviations, and coefficients of variation, for the Posterior Triangular (accessory) sulcus, when the triangular sulcus occurred as three sulci, for ungrouped and grouped data in F3	**206**

Table	LIST OF TABLES	Page
3.58	Two-sided t-tests for the mean difference in two pairs of samples selected from Table 3.46 on page 193 [Stem of the Anterior Rami].	**215**
3.59	Two-sided t-tests for the mean difference in five pairs of samples selected from Table 3.47 on page 194 [Anterior Ascending Ramus].	**217**
3.60	Two-sided t-tests for the mean difference in five pairs of samples selected from Table 3.48 on page 194 [Anterior Horizontal Ramus].	**217**
3.61	Two-sided t-tests for the mean difference in one pair of samples selected from Table 3.52 on page 199 [Sole Triangular Sulcus].	**218**
3.62	Two-sided t-tests for the mean difference in two pairs of samples selected from Table 3.47 on page 194 [Anterior Ascending Ramus].	**218**
3.63	Two-sided t-tests for the mean difference in two pairs of samples selected from Table 3.48 on page 195 [Anterior Horizontal Ramus].	**219**
3.64	Two-sided t-tests for the mean difference in two pairs of samples selected from Table 3.47 on page 195 [Control and Case - Anterior Ascending Ramus].	**220**
3.65	Two-sided t-tests for the mean difference in two pairs of samples selected from Table 3.48 on page 196 [Control and Case - Anterior Horizontal Ramus].	**220**

	LIST OF TABLES	**Page**
3.66	Summary of p-values in Tables 3.59 - 3.64.	**221**
3.67	Intersulcal lengths anterior to the anterior ascending ramus for the control group	**223**
3.68	Intersulcal lengths posterior to the anterior ascending ramus for the control group	**223**
3.69	Intersulcal lengths anterior to the anterior ascending ramus for the case group	**224**
3.70	Intersulcal lengths posterior to the anterior ascending ramus for the case group	**224**
4.1	Incidence of the Sole Opercular Sulcus when diagonal in shape	**244**
4.2	Connections of the Sole Opercular Sulcus when diagonal in shape	**245**
4.3	Connections of the First and Second Opercular Sulcus when diagonal in shape	**245**
4.4	Incidence of the Types of Sulcal Connections (Present Study relative to Ebeling et al 1989)	**250**
4.5	Incidence of the Patterns of the Anterior Rami (Present Study relative to others in the literature survey, hemispheres not considered separately)	**253**
4.6	Incidence of the Patterns of the Anterior Rami (Present Study relative to others in the literature survey, hemispheres considered separately)	**254**

	LIST OF TABLES	**Page**
4.7	Sulcal Lengths for Ungrouped Data (Present Study relative to Ono et al, 1990)	**259**

LIST OF ABBREVIATIONS AND TERMS

1. For fissures:
    (a) CF = Central Fissure
    (b) LF = Lateral Fissure
2. For gyri:
    (a) POP = pars opercularis (between the inferior part of the precentral sulcus and the anterior ascending ramus of the lateral fissure)
    (b) POR = pars orbitalis (between the anterior horizontal ramus of the lateral fissure and the orbital sulci
    (c) PTR = pars triangularis [between the anterior ascending ramus and the anterior horizontal ramus (of the lateral fissure)]
    (d) F3 = inferior frontal gyrus. In this study, the frontal operculum was defined as the inferior frontal gyrus.
3. For sulci:
    (a) anterior rami = anterior rami of the lateral fissure (AAR and AHR)
    (b) AAR = anterior ascending ramus of the lateral fissure = anterior ascending ramus
    (c) AHR = anterior horizontal ramus of the lateral fissure = anterior horizontal ramus
    (d) Fo = fronto-orbital sulcus
    (e) Fm = fronto-marginal sulcus
    (f) IFS = inferior frontal sulcus
    (g) InFS = intermediate frontal sulcus
    (h) Sb = side branch of the stem of the lateral fissure

(i) st = stem = stem of the AAR and AHR

(j) SFS = superior frontal sulcus

(k) Tr = triangular sulcus when it is the sole sulcus in the PTR

(l) Tra = anterior triangular sulcus

(m) Trp = posterior triangular sulcus

(n) Trm = intermediate triangular sulcus (between Tra and Trp)

(o) Op = sulcus of pars opercularis (diagonal sulcus)

(p) Op_1 = anterior-most or superior-most of two opercular sulci

(q) Op_2 = posterior-most or inferior-most of two opercular sulci

4. For sulcal lengths:

(a) x_1 = length of the stem of the anterior rami

(b) x_2 = length of the AAR

(c) x_3 = length of the AHR

(d) Ope = length of sole opercular sulcus

(e) Ope_1 = length of the anterior-most or superior-most of the opercular sulci, when they occur as two sulci

(f) Ope_2 = length of the posterior-most or inferior-most of the opercular sulci, when they occur as two sulci

(g) Tri = length of sole triangular sulcus

(h) $Tria_2$ = length of anterior triangular sulcus, when the triangular sulcus was present as two sulci

(i) $Trip_2$ = length of posterior triangular sulcus, when the triangular sulcus was present as two sulci

(j) $Tria_3$ = length of anterior triangular sulcus, when the triangular sulcus was present as three sulci

(k) Trim = length of middle triangular sulcus, when the triangular sulcus was present as three sulci

(l) $Trip_3$ = length of posterior triangular sulcus, when the triangular sulcus was present as three sulci

(m) $Tria_{2/3}$ = Used in the Appendices to indicate that the column of data concerned, records lengths of the anterior triangular sulcus when the triangular sulcus occurs as either two or three sulci

(n) $Trip_{2/3}$ = Used in the Appendices to indicate that the column of data concerned, records lengths of the posterior triangular sulcus when the triangular sulcus occurs as either two or three sulci

(o) Statistical symbols:

i. Σ = the sum of

ii. $\bar{x}$ = sample mean

iii. s = sample standard deviation

iv. cv = coefficient of variation

(p) $x_4 = \Sigma (Ope_1 + Ope_2)$. In the case of a sole opercular sulcus, x_4 = Ope

(q) $x_5 = \Sigma (Tria_2 + Trip_2)$ or $\Sigma (Tria_3 + Trim + Trip_3)$. In the case of a sole triangular sulcus, x_5 = Tri

5. Other:

a. B = Black African (race)

b. d = damaged (rendered unsuitable for measurement)

c. Fig(s) = Figure(s)

d. n = number

e. sn = specimen number

f. n_o = notch (spur), a tiny sulcus

g. pg (s) = page(s)

h. RH = Right Hemisphere

i. LH = Left Hemisphere

j. Disregard = Used in the Appendices to indicate that the Triangular sulcus was measured but that its recording was set aside because the measured length extended beyond the superior boundary of the frontal operculum

k. MRI = Magnetic Resonance Imaging

l. Control category = hemispheres belonging to known whole brains

m. Case category = separate hemispheres

n. Ungrouped data = quantitative data prior to its grouping into either: Types of Sulcal Connections, or Patterns of the Anterior Rami

o. Grouped Data = quantitative data that was distributed into one of the: four Types of Sulcal Connections, or three Patterns of the Anterior Rami.

1. INTRODUCTION

1.1 OPENING REMARKS

The discovery, in the nineteenth century, that a higher order of mental function such as speech, could be disturbed by the destruction of certain gyri[1] in a particular hemisphere (Foundas, Eure, Luevano, and Weinberger, 1998), led to the following conclusions (amongst others):

- That gyri were the repositories of higher order neural function, and

- That there appeared to be an inter-hemispheric asymmetry with respect to the distribution of certain functions. *These findings provided the impetus for an ongoing field of research that seeks to explore the structural substrates of cortical functioning, as well as the significance of their lateralization to either the dominant left cerebral hemisphere or the non-dominant right cerebral hemisphere.* ***The description and measurement of fissures and sulci[2] (as in the present study) also forms a part of this body of research.***

Studies such as that of Ebeling, Steinmetz, Huang, and Kahn (1989) bring immediate application, to the research on fissures and sulci by pointing to the value of using them as landmarks, in order to localise important functional areas. Such localization contributes to

[1] Convolutions, see section 1.3 pg 9 as well as Figs 1.1, pg 3 and 1.4, pg 4
[2] Furrows, see section 1.3, pages 9 and 10 for a definition, as well as Figs 1.1, pg 3 and 1.4, pg 4

radiological diagnosis pre-operatively and aids in the preservation of key functional areas during neurosurgery. Critical reference material in this regard is the knowledge of the variations of significant sulci with respect to their location, connections, and to a lesser extent their appearance.

Ebeling et al (1989) suggest a useful classification (see section 1.8.1 from paragraph 2 on page 23 to page 26, and Fig 1.9 on page 24) for the variations of the connections, of significant sulci, in the ***anterior speech area*****.** This functional area is located in the ***frontal operculum***[3] and is also known as the inferior frontal gyrus or the third frontal gyrus of the human cerebral hemispheres. Their classification of these variations into the four *Types of Sulcal Connections* was based on the connections of the ***externally visible*** portions of the fissures and sulci associated with the anterior speech area[4].

The ***thrust of the current study is confirmatory*** and is based on the work of:

(a) Ebeling et al (1989), as regards the types of connections of fissures and sulci of the frontal operculum (**F3**), and

(b) Others, as regards the patterns of the anterior rami of the lateral fissure (anterior ascending and anterior horizontal).

[3] also abbreviated as F3, see section 1.6 on pg 17 (paragraph 1), as well as Fig 1.5 on pg 14
[4] also known as Broca's area in the left cerebral hemisphere

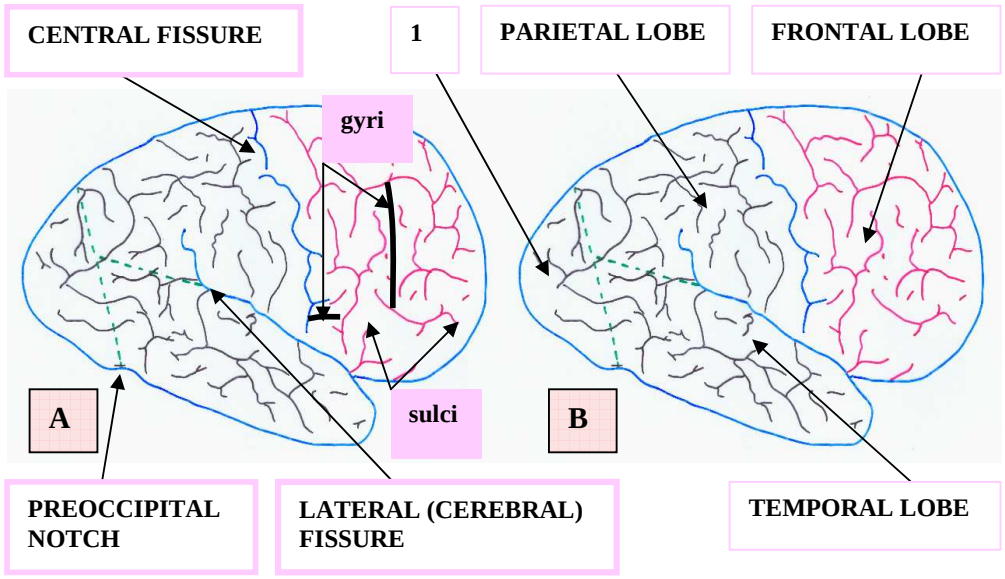

Figure 1.1 Concepts of gyri, sulci and lobulation (pen tracings of the superolateral surface, of the human right cerebral hemisphere). In diagram A, note that a gyrus may be found between a sulcus and a fissure, or between a sulcus and a sulcus. In diagram B, note that the central fissure, the lateral fissure, and the broken green lines, are used as lobar dividers. The occipital lobe (1) is posterior. In both diagrams the pink lines highlight the sulci of the frontal lobe, and the black lines the sulci of the other lobes.

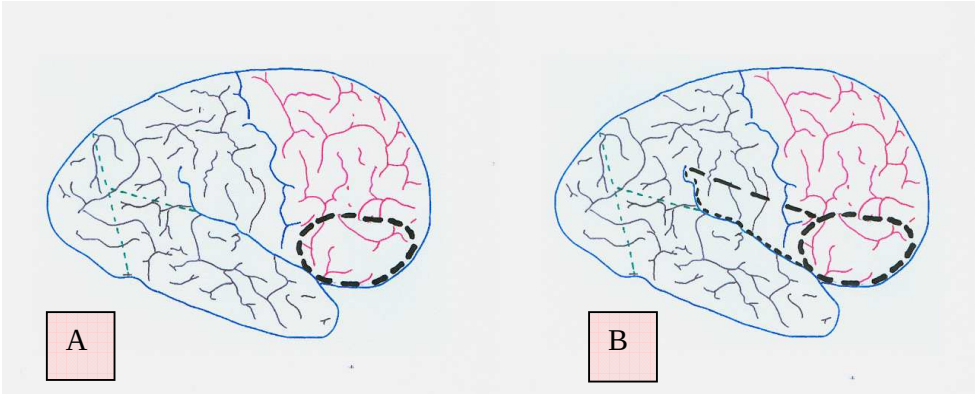

Figure 1.2 The primary and secondary areas of study. The selected area in diagram A outlines the frontal part of the superior operculum, which is the area under study (frontal operculum). The extended selected area in diagram B outlines those areas examined for orientation purposes.

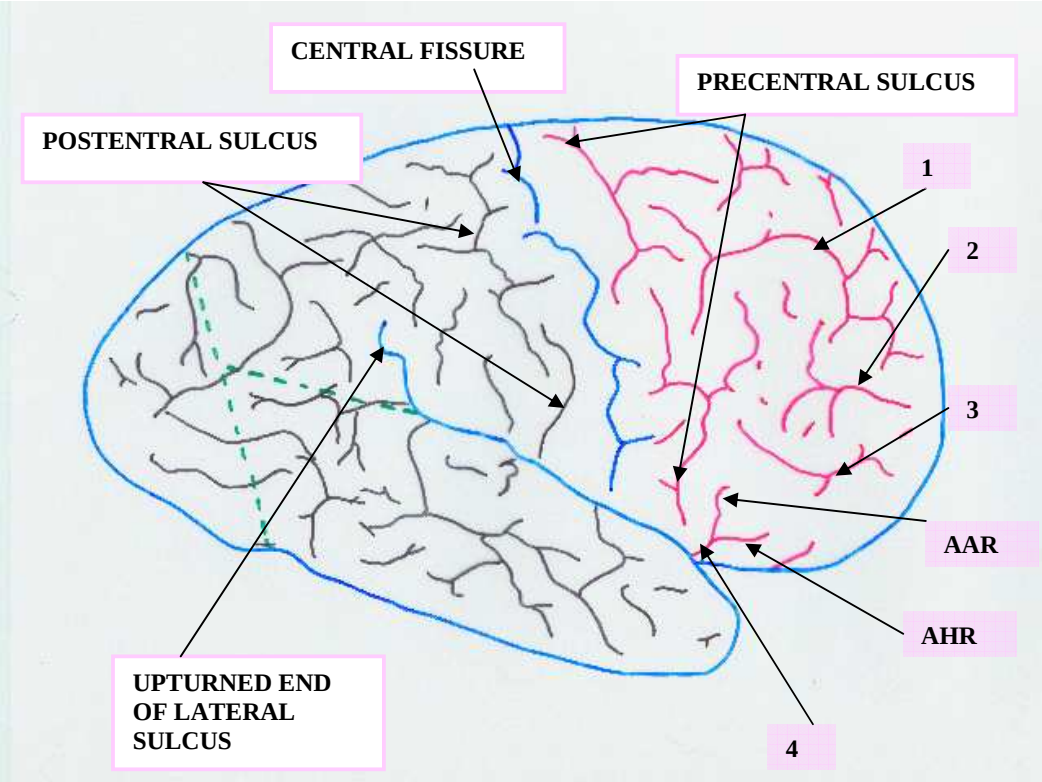

Figure 1.3 The sulci of the frontal and parietal lobes relevant to the current study. [1. Superior frontal sulcus 2. Intermediate frontal sulcus 3. Inferior frontal sulcus 4. Stem of the: anterior ascending ramus- and the anterior horizontal ramus- of the lateral fissure. Note that when the stem is absent, the two rami of the lateral fissure (anterior ascending = AAR and anterior horizontal= AHR) arise separately from the lateral fissure].

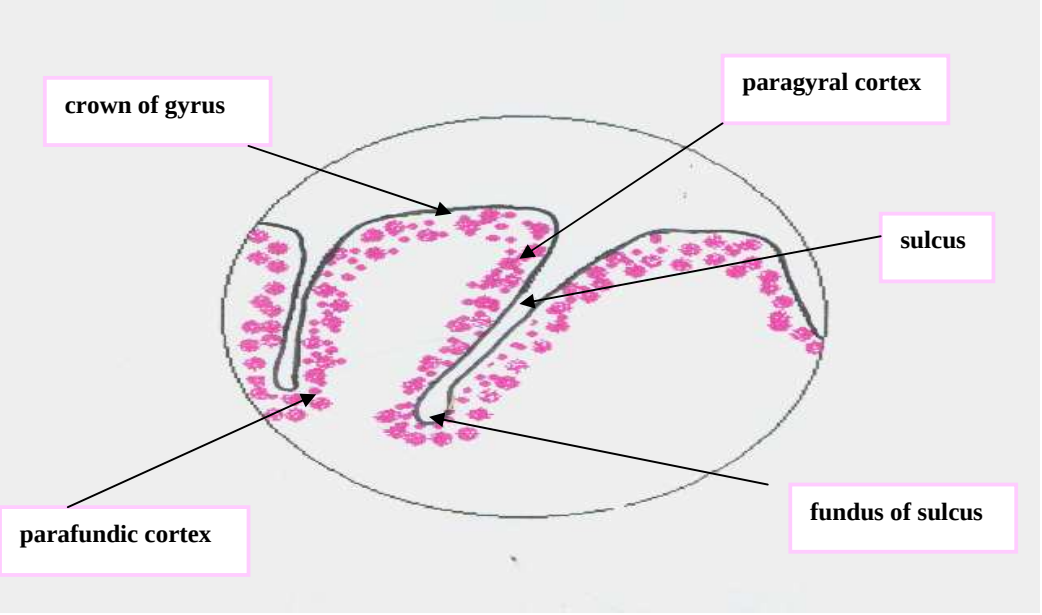

Figure 1.4 Idealied gyri and sulci (in section).

The following is a list of:

(a) Fissures and sulci that are located in the frontal operculum. Note that they are closely associated with the neural elements of speech.

i. Major sulci (see Fig 1.7 on pg 15):

- *The anterior ascending- and anterior horizontal- rami of the lateral (cerebral) fissure; and the stem of the anterior ascending ramus- and anterior horizontal ramus- of the lateral fissure (when it is present).*

ii. Accessory sulci (see Fig 1.12 on pg 43):

- *The sulci of the -pars opercularis- and -pars triangularis*

iii. Fissures and Sulci that contribute to the boundaries of the anterior speech area (see Fig 1.3 on pg 4):

- *The inferior part of the precentral sulcus (inferior precentral sulcus, the inferior frontal sulcus, and the lateral fissure*

iv. Fissures that are used for orientation purposes (see Fig 1.1A on pg 3):

- *The central- and lateral- fissures*

(b) Types of connections that are associated with the fissures and sulci of the frontal operculum, as described by Ebeling et al (1989), see Fig 1.9 on pg 24:

- *Type 1, Type 2, Type 3, and Type 4*

(c) Patterns associated with the anterior rami of the lateral fissure (see Figs 1.10 on pg 35; and 1.11 on pg 38). Note that the patterns of the anterior rami, which are as follows, are designated by letters of the alphabet:

- *𝒥 pattern, Y pattern, and V-U pattern*

1.2 SUMMARY OF THE AIMS AND OBJECTIVES OF THE PRESENT STUDY (*see Appendix J on page 396*)

1.2.1 SHORT TERM AIMS AND OBJECTIVES

1.2.1.1 THE BROAD QUESTIONS POSED HERE ARE:

In a South African sample,

- Is it possible to reproduce the systems of classification, of the fissures and sulci in the frontal operculum, as reported in the literature review?

- Is there a difference between the right- and the left- cerebral hemispheres, with respect to the above systems of classification, when considering both:

    - Descriptive data, and
    - Quantitative data

1.2.1.2 DESCRIPTIVE OBJECTIVES

(a) To describe the patterns and connections of the fissures and sulci of the frontal operculum, with a view to confirming or modifying the system of classification introduced by:

- Ebeling et al (1989), as regards the *Types of Sulcal Connections* (in F3), and
- Others, as regards the *Patterns of the Anterior Rami of the Lateral Fissure*.

(b) To compare the incidence of the:

- *Types of Sulcal Connections* found in the right frontal operculum to that found in the left frontal operculum, and
- *Patterns of the Anterior Rami of the Lateral Fissure* found in the right frontal operculum to that found in the left frontal operculum.

(c) To report on the incidence of the *Patterns of the Anterior rami* with respect to the *Types of Sulcal Connection*, in the frontal opercula, of the right- and left- cerebral

hemispheres.

1.2.1.3 QUANTITATIVE OBJECTIVES

(a) To report on the individual lengths, of the major- and accessory- sulci in the frontal operculum (see section 1.1 on pg 5).

(b) To illustrate the relationship, if any, between:

i. *Sulcal lengths* and the *Types of Sulcal Connections* (in the frontal operculum),

ii. *Sulcal lengths* and the *Patterns of the Anterior Rami of the Lateral Fissure*, (in the frontal operculum).

(c) To report on intersulcal lengths in the:

- Inferior frontal gyrus
- Inferior part of the precentral gyrus
- Inferior part of the postcentral gyrus

(d) To explore and validate alternative methods for data acquisition, such as:

- Measurements from photographs,

- Measurements from pen tracings of the surface of the brain, and
- Mechanical means of measuring (directly from the specimen).

1.2.2 THE LONG TERM AIMS OF THIS STUDY ARE:

To contribute to the establishment of a database on the:

- *Types of Connections of Sulci and Fissures*,
- *Patterns of the Anterior Rami of the Lateral Fissure*, as well as
- *Sulcal- and Intersulcal- Lengths*, in the frontal opercula of the two cerebral hemispheres.

1.3 GYRI AND SULCI ARE DEFINED RELATIVE TO EACH OTHER

The cerebral cortex of the mammalian brain is characterised by a species-specific pattern of folding that ranges from almost smooth to a high degree of complexity (Ide, Dolezal, Fernandez, Labbe, Mandujano, Montes, Segura, Verschae, Yarmuch, and Aboitiz, 1999**;** and Welker, 1990). The irregular sinusoidal nature of the folding of the cortex produces irregular alternating convolutions and furrows. The convolutions are termed **gyri** and the furrows **sulci** or **fissures** (see Fig 1.1 on pg 3). Adjacent gyri abut closely on each other,

meeting in the depths of the sulci. The terms fissure and sulcus although often used synonymously, are not quite identical as indicated by Welker (1990). Fissures tend to arise developmentally earlier than sulci and are generally deeper and longer than sulci (Lemre, Loeser, Leech, Ellsworth, and Alvord, 1975; Welker, 1990). The exceptions are the callosal-, olfactory-, circular-, and cingulate- sulci, which arise between the time of the origin of the lateral fissure and that of the central fissure (Chi, Dooling, and Gilles, 1977).

The two portions of a gyrus that are visible externally are its **crown** and its **paragyral** cortex (see Fig 1.4 on pg 4). The crown is a smooth elevation that may be either flat or of variable convexity. The irregular nature of gyri is reflected in the variable intersulcal lengths or expansions, among crowns (see Fig 1.3 on pg 4). The crown is followed by the curved paragyral cortex. The sulcal walls begin where two adjacent paragyral cortices meet. It continues internally as the apposing surfaces of adjacent gyri. These walls become slightly concave as they approach the deepest extremity of the sulcus, which is referred to as the **fundus**. The walls of the sulci and the parafundic cortices are the concealed portions of the gyri. **The focus in the current study is on the externally visible areas**.

Three levels of sulci have been described (Welker, 1990). The **distinct sulci** or **fissures** have characteristic cytoarchitectural differences (see section 1.9 on pages 51 to 53) between their crowns and fundi, and unless otherwise here stated, they shall be referred to as sulci or fissures only. They may branch into limbs (rami), give rise to spurs (notches), or exhibit no particular additional feature. The **incipient sulcus** is a slightly depressed cortical zone. A **dimple** differs from the incipient sulcus only by being slightly deeper. The dimples

and the incipient sulci, unlike the vascular furrows, are classified as sulci because they also demonstrate significant crown-fundic cytoarchitectural differences.

A gyrus consists of an outer cortex and an inner central core (see Fig 1.4 on pg 4). The cortex consists of neuronal cell bodies and neuroglia, as well as their dendrites and axons. Nerve cell bodies, when observed under the light microscope, appear to be surrounded by a mesh of the beginnings and endings of nerve fibres only. But, when viewed under the electron microscope, this mesh (referred to by some, as the neurophil) is seen to consist of: a 'conglomerate of the cell bodies of astrocytes; and the processes of neurons, only a few of which are myelinated' (Ham and Cormack, 1979). The neuroglia, amongst which are the astrocytes, hold the cell bodies and processes of neurons in their 'proper spatial arrangement.' The central core or stalk of a gyrus consists of white matter, which contains fibres that are both afferent- and efferent- to the cortex.

The cortex may consist of up to six horizontally disposed layers, which are referred to as laminae. The six-layered variety is the predominant neocortex (isocortex). The layers are termed Laminae I to VI (from superficial to deep). The 'functional unit' of the cortex, however is considered to be vertically disposed cortical columns that extend radially through all laminae. The cortical columns are measured in the order of micrometres. Neocortex in which the six layers are clearly apparent, are termed homotypical. Heterotypical cortex occurs where there is a merging of some of the six layers. Examples of heterotypical cortex are the granular and the agranular types. The anterior speech area consists of heterotypical granular cortex.

1.4 THE GENERAL ORGANISATION OF GYRI AND SULCI IN THE SUPERO-LATERAL ASPECT OF THE FRONTAL LOBE

'Gyri are often arranged in groups or formations. Large topographical regions of cortical outgrowth containing several gyral groups are referred to as lobes' (Welker, 1990). In the human brain, the lobes have been designated as frontal, parietal, occipital, temporal, and limbic (see Fig 1.1B on pg 3).

The general shape and orientation of the gyral groups in each of the lobes differ from each other in a fairly predictable fashion. Therefore, the supero-lateral surface of the frontal lobe characteristically contains (see Fig 1.3 on pg 4 and Fig 1.6 on pg 14):

- One supero-inferiorly directed gyrus (precentral gyrus), that is more or less parallel to the central sulcus, and

- Three antero-posteriorly directed gyri (superior-, middle-, and inferior- frontal) that are more or less perpendicular to the precentral gyrus.

The *precentral gyrus* is limited posteriorly by the central fissure and anteriorly by the precentral sulcus. The *superior frontal gyrus* lies between the longitudinal fissure and the superior frontal sulcus. The *middle frontal gyrus* lies between the superior frontal sulcus and the inferior frontal sulcus. It may contain an *intermediate frontal sulcus*. *The inferior-*

or third- frontal gyrus lies between the inferior frontal sulcus superiorly and the lateral fissure inferiorly. The superior-, middle, and inferior-, frontal gyri are limited posteriorly by the precentral sulcus.

1.5 THE CONCEPT OF OPERCULATION

During the foetal development of mammalian brains, some gyri develop at a slower rate than others. The more rapidly developing gyri tend to overlap the tardy ones. Portions of the adjacent gyri that take part in an actual overlap are referred to as the **opercula** of the buried area.

In the human brain, the rapidly developing frontal, parietal, and temporal lobes overlap, and consequently bury the **insula**. This transforms the lateral fossa, which is a depression that is located:

- Lateral to the insula,
- Inferior to the developing fronto-parietal lobes, and
- Superior to the developing temporal lobe, into the lateral fissure. Those aspects of the three lobes that abut on each other and cover the insula are referred to as the opercula of the lateral fissure (see Fig 1.5 on pg 14). The two broad opercula thus formed are referred to as the superior- and the inferior- opercula. The superior

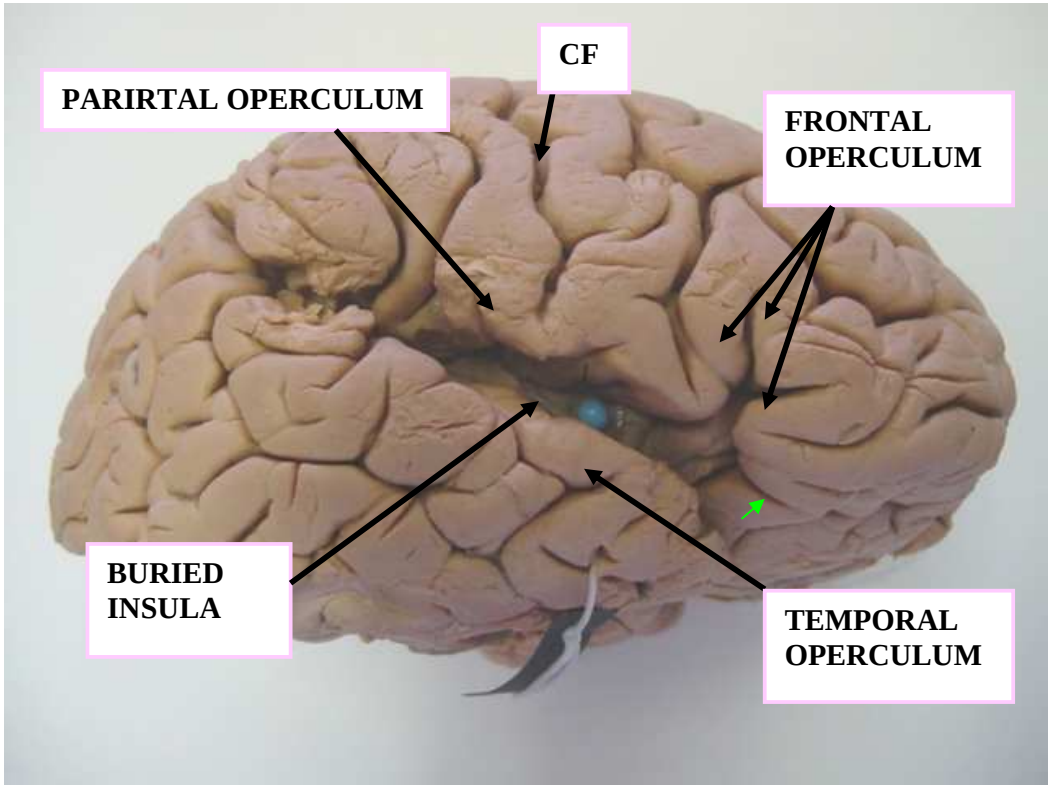

Figure 1.5 The opercula of the lateral fissure. Note that the blue dot is a pinhead that is resting on the insula. The green arrowhead points to a side branch of the stem of the lateral fissure that passes into the orbital gyrus . CF refers to the central fissure.

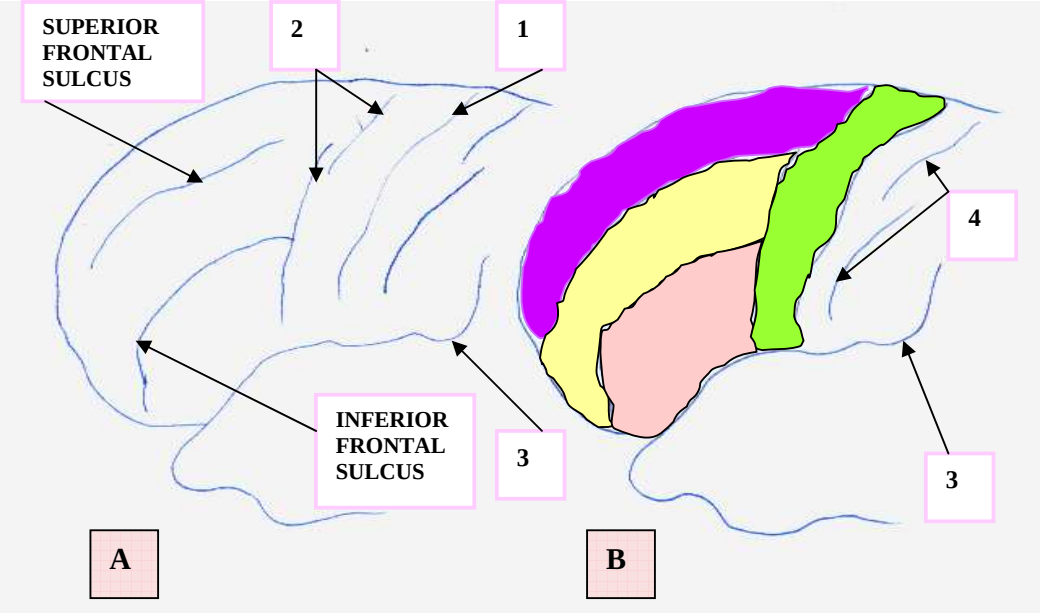

Figure 1.6 Gyri of the frontal lobe. In Diagram B, the gyri are: precentral (green), inferior frontal (pink), middle frontal (yellow), superior frontal (purple). Diagram A is the key [the precentral gyrus occurs primarily between the central fissure (1), and the precentral sulcus (2); the superior- and inferior frontal- sulci help separate the three horizontally disposed gyri from each other; the lateral fissure (3) limits the inferior frontal gyrus inferiorly]. Note that the postcentral sulcus (4) is in the parietal lobe.

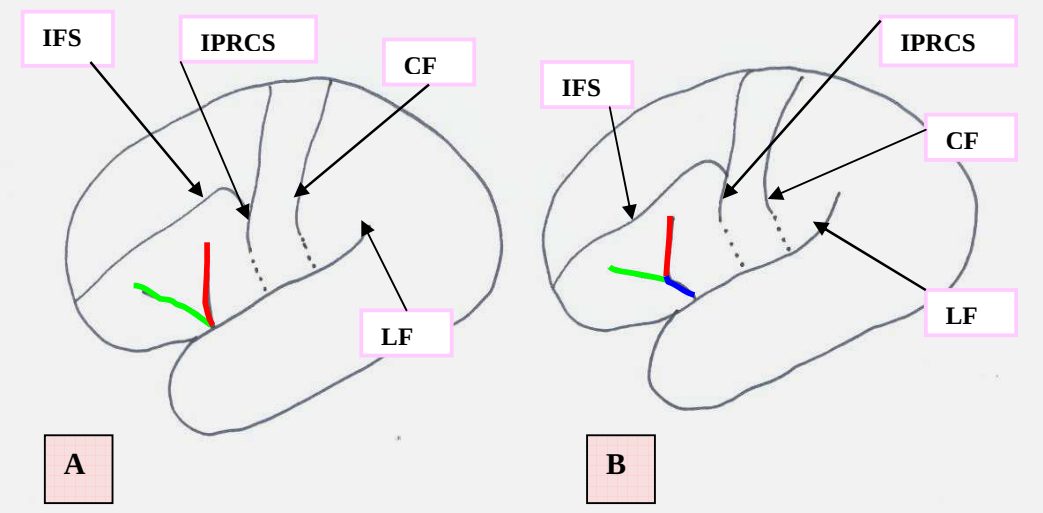

Figure 1.7 The major sulci of the frontal operculum. Diagram A shows the separate pattern- of the major sulci (anterior rami: anterior ascending ramus (AAR, red) and the anterior horizontal ramus (AHR, green) arising separately from the lateral fissure). Diagram B shows the Y pattern- of the major sulci (anterior rami of the lateral fissure, the AAR and the AHR arising from a common stem (blue). [Fissures: central (CF), lateral (LF); Sulci: inferior frontal (IFS), inferior precentral (IPRCS)]

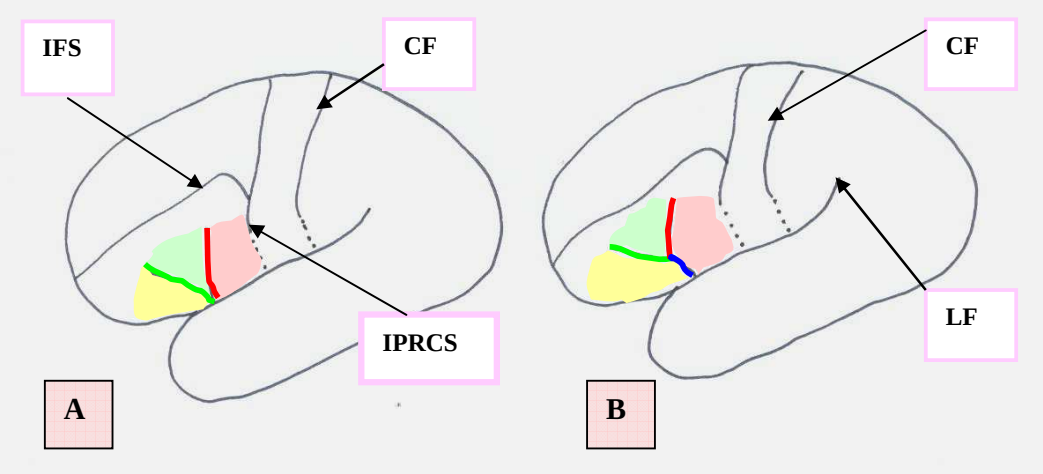

Figure 1.8 The three components of the frontal operculum. [Note that the labels for the fissures and sulci in Fig 1.7 above, are applicable in Fig 1.8.] Diagram A shows the separate pattern- and diagram B the Y pattern- of the anterior rami of the lateral fissure. The *pars opercularis* (between the inferior precentral sulcus (IPRCS) and the anterior ascending ramus in diagram A; and between the IPRCS and the AAR plus the common stem, in diagram B is highlighted in pink. The *pars triangularis* (between the AAR and the anterior horizontal ramus (AHR) in both diagrams, is highlighted in green. The *pars orbitalis* (antero-inferior to the AHR in diagram A and antero-inferior to the AAR plus the common stem in diagram B, is highlighted in yellow.

operculum has two components: the anteriorly located **frontal operculum**, and the posteriorly located **parietal operculum**. The inferior operculum is the **temporal operculum**.

Longstanding interest in the opercula of the lateral fissure relate to the **'functional asymmetry'** associated with them, and the **'morphological correlates,'** or structural substrates, of such asymmetries (Rubens, 1977). The following functional asymmetries are well established:

- Portions of the left- rather than the right- frontal operculum have been shown to be associated with the motor aspects of speech, although not consistently so (Foundas et al, 1998).

- The left- rather than the right- planum temporale of the temporal operculum has been linked to the comprehension of speech.

Gerchwind and Levitsky demonstrated conclusively in 1968, the left over right asymmetry for the planum temporale (Rubens, 1977). **Although such proof has been sought for the anterior (motor) speech area, the fndings have been unequivocal (Sherwood, Broadfield, Holloway, Gannon, and Hof, 2003).**

1.6 THE ANATOMY OF THE FRONTAL OPERCULUM

Ono, Kubik, and Abernathey (1990) define the frontal operculum as the inferior frontal gyrus and also include the adjacent part of the inferior precentral sulcus. But, the definition of the frontal operculum as the inferior frontal gyrus only, is used for the purposes of this study (*Rubens, 1977*, in Harnad, Doty, Goldstein, Jaynes, and Krauthamer, 1977) since it provides a focus for the stated aims (see section 1.2, on pages 6 to 9). The frontal operculum may also be abbreviated as F3.

The well-established boundaries of the inferior frontal gyrus are:

- Posteriorly, the inferior precentral sulcus,
- Superiorly, the inferior frontal sulcus, and
- Inferiorly, the lateral fissure. The anterior boundary of the third frontal gyrus is

generally left unstated. Albanese, Merlo, Albanese, and Gomez (1989), in a quantitative study, use the orbital sulcus as the anterior (ventro-rostral) boundary.

Two sulci that are anterior branches (rami) of the lateral fissure penetrate superiorly into the frontal operculum. These rami may occur as separate sulci or they may be joined to each other in a 'Y' formation (see Fig 1.7 on pg 15). When separate, the anterior-most of the two rami is the **anterior horizontal ramus (AHR)**, which as the name suggests, **tends**

to be more horizontally disposed. This is closely followed by the **anterior ascending ramus (AAR)**, which **tends** to be more vertically disposed. When the two rami are joined to each other, they arise from a common **stem of the AAR and AHR** (which shall hereafter, in this text, be referred to as the stem)**.** This stem is, in turn, a branch of the lateral fissure. These sulci are collectively referred to as the *major sulci*, in the present study. The two anterior rami of the lateral fissure retain their positions relative to each other even when arising from a common stem.

When the anterior rami arise separately from the lateral fissure, they subdivide the third frontal gyrus (see Fig 1.6 on pg 14) into three broad regions, from posterior to anterior, as follows:

- **The pars opercularis (POP)**, which lies between: the inferior precentral sulcus, posteriorly; and the anterior ascending ramus, anteriorly (see Figs 1.7A and 1.8A on pg 15).

- **The pars triangularis (PTR)**, which lies between: the anterior ascending ramus, posteriorly; and the anterior horizontal ramus, anteriorly (see Figs 1.7A and 1.8A on pg 15).

- **The pars orbitalis (POR)**, which lies between: the anterior horizontal ramus, posteriorly; and an ill defined area at, or lateral to, the lateral-most placed branches of the orbital sulcus (see Figs 1.7A and 1.8A on pg 15).

When the anterior rami of the lateral fissure arise from a common stem, they also subdivide the third frontal gyrus into three components as follows:

- **The pars opercularis (POP)**, which lies between: the inferior precentral sulcus, posteriorly; and the anterior ascending ramus, including the stem of the AAR and AHR, anteriorly (see Figs 1.7B and 1.8B on pg 15).

- **The pars triangularis (PTR)**, which lies between the anterior ascending ramus, posteriorly; and the anterior horizontal ramus, anteriorly (see Figs 1.7B and 1.8B on pg 15). This implies that the inferior extent of the pars triangularis, in this situation, occurs where the two anterior rami meet with the stem of the AAR and AHR.

- **The pars orbitalis (POR)**, which lies between the anterior horizontal ramus, including the stem of the AAR and AHR, posteriorly; and an ill defined area at, or lateral to, the lateral-most placed branches of the orbital sulcus (see Figs 1.7B and 1.8B on pg 15).

Other sulci of the frontal operculum include those **within** its three parts (see Fig 1.12 on pg 43) and in this text, are named according to the part of the inferior frontal sulcus in which they are found. Hence, there is (are) the sulcus (sulci) of the:

- pars opercularis (opercular sulcus/ sulci)

- pars triangularis (triangular sulcus/ sulci). However, the nomenclature of these sulci

differs somewhat in the literature reviewed (see section 1.8.3 on pages 41 to 45, on the review of the opercular sulcus and section 1.8.4 on pages 45 to 46, on the review of the triangular sulcus). The triangular sulcus has been reported to subdivide the pars triangularis into the pars triangularis anterior and the pars triangularis posterior (Wada, Clarke, and Hamm, 1975; and Falzi, Perrone, and Vignolo, 1982). The pattern of two sub-convolutions separated by a minor sulcus has also been reported for the pars opercularis (Tomaiuolo, MacDonald, Caramanos, Posner, Chiavaras, Evans, and Petrides, 1999). The minor sulcus in the case of the pars opercularis is the sulcus of the pars opercularis (reported as the diagonal sulcus in the literature). The sulci of the pars - triangularis and - opercularis are collectively referred to as the *accessory sulci*, in the present study.

The pars opercularis and pars triangularis occupy Brodmann's cytoarchitectonic areas 44 and 45 respectively (Broca's area in the left hemisphere).

1.7 THE JUSTIFICATION FOR THIS STUDY

Ono et al (1990) state that although primary fissures, for example the central fissure, are constant enough to warrant their use in general orientation, secondary- and tertiary- sulci are subject to 'great individual variability.' Furthermore, it is proposed via the same study that the extent of variability in fissures and sulci may well be underestimated. While some of this variability may appear to be more subtle than others, this still has particular

significance in the cerebral cortex, where small shifts have implications for large numbers of neurons and hence function.

Knowledge of the extent of inter-hemispheric and inter-subject variability as regards: types of connections of sulci and fissures, patterns of gyri and sulci, as well as sulcal- and intersulcal- lengths, in the general population, could constitute important reference material. Such information has:

- Application in radiology and neurosurgery where fissures and sulci are used as landmarks in order to facilitate decision making, especially with respect to sensitive functional areas

- Relevance for those studying and diagnosing cortical pathologies associated with, for example, epilepsy, schitzophrenia and dyslexia.

There is the potential that study of the developmental basis of cortical folding together with studies of: variation in cortical pattern; electrophysiology; and lateralization, can compliment each other in elucidating structure-function relationships. Information can be accumulated on cortical patterns and lateralization, as we await the development of more sophisticated exploratory techniques as regards developmental neurobiology and electrophysiology. **Ono et al (1990) indicate that the greatest variability, in humans, occurs in the frontal lobe and in the parieto-occipital regions. It is the intention of this study to focus on the frontal operculum.**

1.8 LITERATURE SURVEY

1.8.1 THE REFERENCE STUDY FOR THE TYPES OF SULCAL CONNECTIONS IN F3 (EBELING ET AL, 1989)

Pattern recognition and reference ranges are important tools in the identification of functional areas of the cerebral cortex, relative to gyri and sulci. This is especially so in the frontal operculum where the speech area is immediately adjacent to the premotor- and the motor- areas. This relationship led to studies such as that of Ebeling et al, in 1989 (see section 1.1, from paragraph 2 on pg 1 to pg 2).

The central fissure is invariably used as a reliable landmark for orientation purposes, in studies such as that of Ebeling et al (1989), because of its consistent features. It is usually identified as a single (uninterrupted) sulcus that seldom has a connection with the lateral fissure (see Fig 1.3 on pg 4). The relative stability, of the incidence of its connection with the lateral fissure, as reported in the literature is a testament to this (reference range 5% - 19%, see Table 1.2 on pg 26). The primary motor cortex is located anterior to the central fissure.

The inferior part of the precentral sulcus separates the primary motor area (posterior to it), from the premotor area (anterior to it). The motor speech area (Broca's area in the left hemisphere) is anterior to the premotor area. The features of the precentral sulcus are, however, not as reliable as that of the central sulcus. This led Ebeling et al (1989) to search for reliable landmarks for its identification. The next two likely items as landmarks,

anterior to the inferior precentral sulcus were: the inferior frontal sulcus, and the anterior ascending ramus (of the lateral fissure). The areas immediately related to these two sulci were also included (see Fig 1.9 on pg 24).

The work of Ebeling et al (1989) was a combined radiological- and anatomical- study that examined twenty healthy volunteers by MRI scanning (magnetic resonance imaging) and sixty-two intact postmortem hemispheres. The aim of their exercise was to: 'identify characteristic relationships of the inferior precentral sulcus to nearby sulci and gyri,' with a view to determining whether or not unique sulcal landmarks for the identification of the motor and the adjacent speech cortex could be recognised. The extended region of interest was the frontoparietal operculum, excluding the pars orbitalis and the postcentral area. The main focus was on the pars opercularis and the pars triangularis. The categorization of the hemispheres examined, involved their grouping into four types of sulcal connections (see Fig 1.9 on pg 24). The criterion used for the typing was the incidence of particular combinations of sulcal connections (see Table 1.1 on pg 26). The types of sulcal connections are as follows:

TYPE 1 **(see Fig 1.9B on pg 24)**:

- The anterior ascending ramus preceeds the inferior precentral sulcus;
- The inferior frontal sulcus has a connection with the inferior precentral sulcus;
- The inconstant segments include the: anterior horizontal ramus, connection of the inferior precentral sulcus with the lateral fissure, and connection of the central fissure with the lateral fissure.

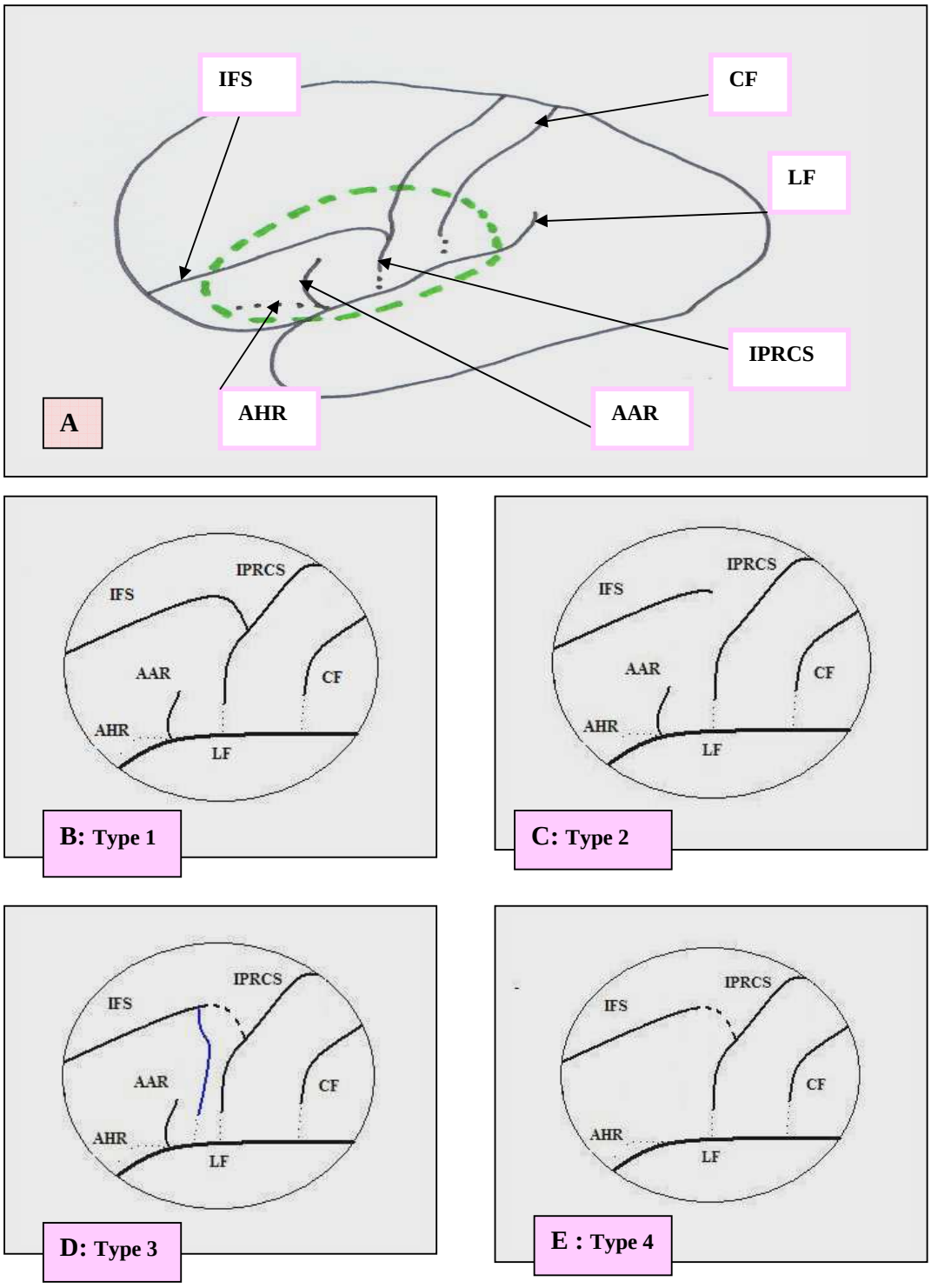

Figure 1.9 The Types of Connections, as in Ebeling et al (1989). The selected area (broken green ellipse in Diagram A, has been expanded in Diagrams B-E, demonstrating the features each of the four Types of Ebeling. [Fissures – Central (CF), Lateral (LF); Sulci – Inferior precentral (IPRCS), Inferior frontal (IFS), Anterior ascending- (AAR), Anterior horizontal (AHR)- rami. Broken lines indicate inconstant connections of fissures or sulci or an inconstant sulcus (AHR). Note that the additional *blue* branch in Type 3 (diagram D) is probably the diagonal (opercular) sulcus.

TYPE 2 **(see Fig 1.9C on pg 24)**:

- The anterior ascending ramus preceeds the inferior precentral sulcus;
- There is no connection between the inferior frontal sulcus and the inferior precentral sulcus;
- The inconstant sulcal segments occur as in Type 1.

TYPE 3 **(see Fig 1.9D on pg 24)**:

- An additional branch from the inferior frontal sulcus, probably the diagonal sulcus (referred to as the opercular sulcus in the present study) descends between the anterior ascending ramus and the inferior precentral sulcus;
- The connection of the inferior frontal sulcus with the inferior precentral sulcus is inconstant;
- The other inconstant sulcal segments occur as in Type 1.

TYPE 4 **(see Fig 1.9E on pg 24)**:

- The anterior ascending ramus is absent.
- The other inconstant sulcal segments occur as in Type 1.

The anterior ascending ramus was seen as the key sulcus for the subdivision of the third frontal gyrus. Eberstaller (1890) and Cunningham (1892) were quoted in the definition of the anterior ascending ramus. They reported it as being distinguished by its continuity with the circular sulcus of the insula (which forms the rim of the insula). The anterior horizontal ramus was then identified anterior to the anterior ascending ramus and the diagonal (opercular) sulcus posterior to it.

Table 1.1: The Incidence of Types of Sulcal Connections in F3 (Ebeling et al, 1989). Note that both Anatomical and Magnetic Resonance Imaging (MRI) Studies were conducted.

	Type 1	Type 2	Type 3	Type 4
Anatomical Study	**76%**	**11%**	**10%**	**3%**
MRI [5]Study	**90%**	**5%**	**5%**	**0%**

Table 1.2: The Incidence of the Presence of a Connection between the Central Fissure and the Lateral Fissure.

HEMISPHERES STUDIED BY:	INCIDENCE (%)
1. Cunningham (1892)	**5**
2. Lang and Betz (1981)	**19**
3. Ono et al (1990) –average of right and left readings	**16**
4. Ebeling et al (1989) – anatomical study	**15**
5. Ebeling et al (1989) – MRI study	**13**
Reference range [including figures of Ebeling et al (1989)] = 5% - 19% (a difference of 14% between the maximum and minimum)	

[5] Magnetic resonance imaging

Table 1.3: The Incidence of the Presence of a Connection between the Inferior Precentral Sulcus and the Lateral Fissure.

HEMISPHERES STUDIED BY:	INCIDENCE (%)
1. Cunningham (1892)	**15**
2. Lang and Betz (1981)	**42**
3. Ono et al (1990) –average of right and left readings	**24**
4. Ebeling et al (1989) – anatomical study	**60**
5. Ebeling et al (1989) – MRI study	**80**
Reference range [excluding figures of Ebeling et al (1989)] = 15% - 42% (a difference of 27% between the maximum and minimum, and 45 when including Ebeling et al's (1989) anatomical study, and 65 when including the MRI study.	

Table 1.4: The Incidence of the Presence of a Connection between the Inferior Precentral Sulcus and the Inferior Frontal Sulcus.

HEMISPHERES STUDIED BY:	INCIDENCE (%)
1. Eberstaller (1890)	**76**
2. Cunningham (1892)	**67.4**
3. Ono et al (1990) –average of right and left readings	**90**
4. Ebeling et al (1989) – anatomical study	**81**
5. Ebeling et al (1989) – MRI study	**90**
Reference range [including figures of Ebeling et al (1989)] = 67.4% - 90% (a difference of 22.6%)	

The study of Ebeling et al (1989), did not find '***significant asymmetries between the sulcus patterns in the right and left hemispheres***.' Note that there is no indication in the article whether, or not, a statistical comparison was conducted.

COMMENTS ON THE STUDY OF EBELING ET AL (1989):

(a) In my judgement, the decision of Ebeling et al (1989) to investigate combinations of sulci was an important contribution to pattern recognition in the frontal operculum, because of the:

- Inconstant connection of the inferior precentral sulcus with the lateral fissure (see Table 1.3 on pg 27)
- Inconstant connection of the inferior precentral sulcus with the inferior frontal sulcus (see Table 1.4 on pg 27)
- Presence of two anterior rami of the lateral fissure, whose relationship to each other needs to be resolved, especially in situations where it might be difficult to establish the continuity of the anterior ascending ramus with the circular sulcus.
- Presence of other sulci within the pars -opercularis and -triangularis, which may complicate the process of pattern recognition.

(b) The basis of the system of classification derived by Ebeling et al (1989) was the incidences of connection(s) and occurrences of certain key sulci. In the absence of another study on types of connections, there is a need to compare the findings of

Ebeling et al (1999) on these sulci with the reports of other researchers (on an individual basis):

i. *Regarding the main orientating sulcus (central fissure) and its connection with the lateral fissure.* From Table 1.2 on pg 26 it can be seen that their results are within the range of other researchers reviewed.

ii. *Regarding the inferior precentral sulcus and its connection with the lateral fissure.* From Table 1.3 on pg 27, it can be seen that their results are much higher than the range of other researchers reviewed. They explain the higher incidence of their MRI study as opposed to their own anatomical study as a consequence of the imaging technique overestimating connections (due to the presence of gyral bridges). It may also be possible that the presence of the meninges and the blood vessels in the MRI scanned group may mask, to a certain extent, the lack of a connection between the inferior precentral sulcus and the lateral fissure. Still, the high incidence of a connection between the inferior precentral sulcus and the lateral fissure, in their own anatomical study is unusual.

When the difference between the maximum and minimum incidences of, the three connections [excluding the recordings of Ebeling et al (1989) for the connection between the inferior precentral sulcus and the lateral sulcus] are compared, fairly consistant results are obtained:

- A difference of 14% for a connection between the central fissure and lateral fissure

- A difference of 27% for a connection between the inferior precentral sulcus and the lateral fissure

- A difference of 22.6% for a connection between the inferior precentral sulcus and the inferior frontal sulcus.

The implications for the study of Ebeling et el (1989) are that, perhaps: different criteria were used to establish whether or not a connection existed between the inferior precentral sulcus and the lateral fissure; or that this was an artifact of the sampling technique; or that there may be a relationship between incidence of certain connections and the predominant language spoken. **The implication, for the present study, is that a closer examination of the terminal portion of the inferior precentral sulcus is in order.**

iii. *Regarding the inferior precentral sulcus and its connection with the inferior frontal sulcus.* From Table 1.4 on pg 27, it can be seen that their results are within the range of other researchers reviewed, rendering the incidences of Type 1 and Type 2, in my view, more plausible. The primary defining feature of Type 1 and Type 2 is accepted (the connection- or lack of a connection- between the inferior precentral sulcus and the inferior frontal sulcus respectively).

iv. *Regarding the additional branch in the pars opercularis.* This sulcus is used as a distinguishing feature of Type 3. Ebeling et al (1989) state that it descends from the inferior frontal sulcus and is probably the diagonal sulcus, although it was not necessarily found to be diagonal in its course. The sulcus of the pars opercularis has been reported elsewhere, but with other connections (see section 1.8.3, on pages 41 to 45) as well. **The implication for the present study is that the sulcus of the pars opercularis (diagonal sulcus) needs to be reviewed and reported on.**

v. *Regarding the absence of the anterior ascending ramus in Type 4.* This ramus has been reported to be absent in the context of an *𝒥 pattern*[6] of the anterior rami (see the section 1.8.2 on pages 32 to 34). The incidence of its absence, has been deduced from the study of Ide et al (1999) to be 17.5% in the right hemisphere and 2.5% in the left hemisphere. An incidence of 3% for Type 4 is, therefore, held to be reasonable. Ebeling et al (1989) depict the anterior horizontal ramus by means of a dashed line in Type 4 (see Fig 1.9 on pg 24), indicating its inconstancy. Since the anterior ascending- and anterior horizontal- rami have not, in the review thus far, been reported to be absent concurrently, this represents a new pattern for the anterior rami. **The implication for the current study is that the patterns of the anterior rami, and particularly the *𝒥 pattern,* needs to be closely examined.**

[6] Patterns of the anterior of the lateral fissure are designated by letters of the alphabet

(c) When depicting the four *Types of Sulcal Connections*, Ebeling et al (1989) use only the *VU pattern* of the anterior rami, of the lateral fissure, and no mention is made of the *Y pattern.* From the review in section 1.8.2 (on pages 32 to 40), it seems unlikely that the *Y pattern* would not have been encountered in a study of this size. **The implication for the current study is that the incidences of the patterns of the anterior rami, would need to be reported on relative to each of the four types of sulcal connections.**

1.8.2 REFERENCES FOR THE PATTERNS OF THE ANTERIOR RAMI OF THE LATERAL FISSURE

1.8.2.1 THE STUDIES OF CUNNINGHAM (1890 and 1892), EBERSTALLER (1890) AND CONNOLLY (1950)

Rubens (1977) quotes Eberstaller (1890) on the anterior rami of the lateral fissure and the frontal operculum. The anterior rami were grouped as follows (see Fig 1.10 on pg 35):

- A single sulcus (***I pattern***)

- Two sulci, whose relationship to each other, yield the following patterns:

    - ***Y pattern (***conjoined anterior rami arising from a common stem)**,**
    - ***V pattern*** (separate anterior rami, but having the same point of origin from the lateral fissure, and

- ***U pattern*** (completely independent anterior rami)**.** The incidence of the four patterns is not quoted.

Eberstaller ascribes the variation in pattern to a 'differential downgrowth of the pars triangularis into a single ramus'. The ***I pattern*** was therefore thought to be the simplest, and the ***Y -*** and ***V- patterns*** successive intermediates to the final ***U pattern***.

Bergmann, Afifi, and Miyauchi (2000) in the Virtual Hospital, Illustrated Encyclopedia of Human Anatomic Variation, quoted Cunningham (1890) on the configurations of the anterior rami of the lateral fissure. The patterns of the rami as reported by Cunningham's study in 1890 were as follows (see Fig 1.10 on pg 35):

- 'I' shaped (***I pattern***), where the two rami were reduced to one (30%). The single ramus could take the position of either ramus, or be intermediate in position
- 'Y' shaped (***Y pattern***), where a common stem gave rise to both the anterior ascending ramus and the anterior horizontal ramus (32% of hemispheres)
- 'V' or 'U' shaped (***VU pattern***), where the anterior ascending ramus and the anterior horizontal ramus joined the lateral fissure separately (37% of hemispheres)
- in the remaining 1%, there were more than two rami.

Rubens (1977) quoted Cunningham (1892) on the incidence of the ***I pattern.*** In a study of forty- six right hemispheres and thirty- four left hemispheres, a single ramus was found in 41% of right hemispheres and 15% of left hemispheres. Rubens (1977) uses the study of

Connolly (1950), of sixty brains, in order to support the finding of a right over left asymmetry for the ***𝒥 pattern*** of Cunningham in 1892. Connolly (1950) reports the:

- ***𝒥 pattern*** in 25% of right hemispheres and 3% of left hemispheres, and also
- 'less significant' inter-hemispheric differences for the ***Y pattern*** and the ***VU pattern*** (note that no indication is given whether or not this was statistically significant.

<u>COMMENT</u>: Although these early studies throw up the basic patterns of the anterior rami, they either don't, or inadequately report on: inter-hemispheric comparisons; the presence of sulci other than the major sulci; or the connections of the fissures and sulci of- the frontal operculum.

1.8.2.2 <u>THE STUDY OF IDE et al (1999)</u>

The patterns of the anterior rami of the lateral fissure have also been described more recently. Ide et al (1999), in a study of 40 brains reported the following patterns (see Table 1.5 on pg 39 for the incidence of these patterns, as well as Fig 1.11B, C, and D on pg 38):

(a) *a single anterior ramus was present.* This could be either the anterior ascending ramus or the anterior horizontal ramus. <u>In the **right hemisphere**</u> the:

- Anterior ascending ramus predominated in 27.5% of cases, and
- Anterior horizontal ramus predominated in 17.5% of cases.

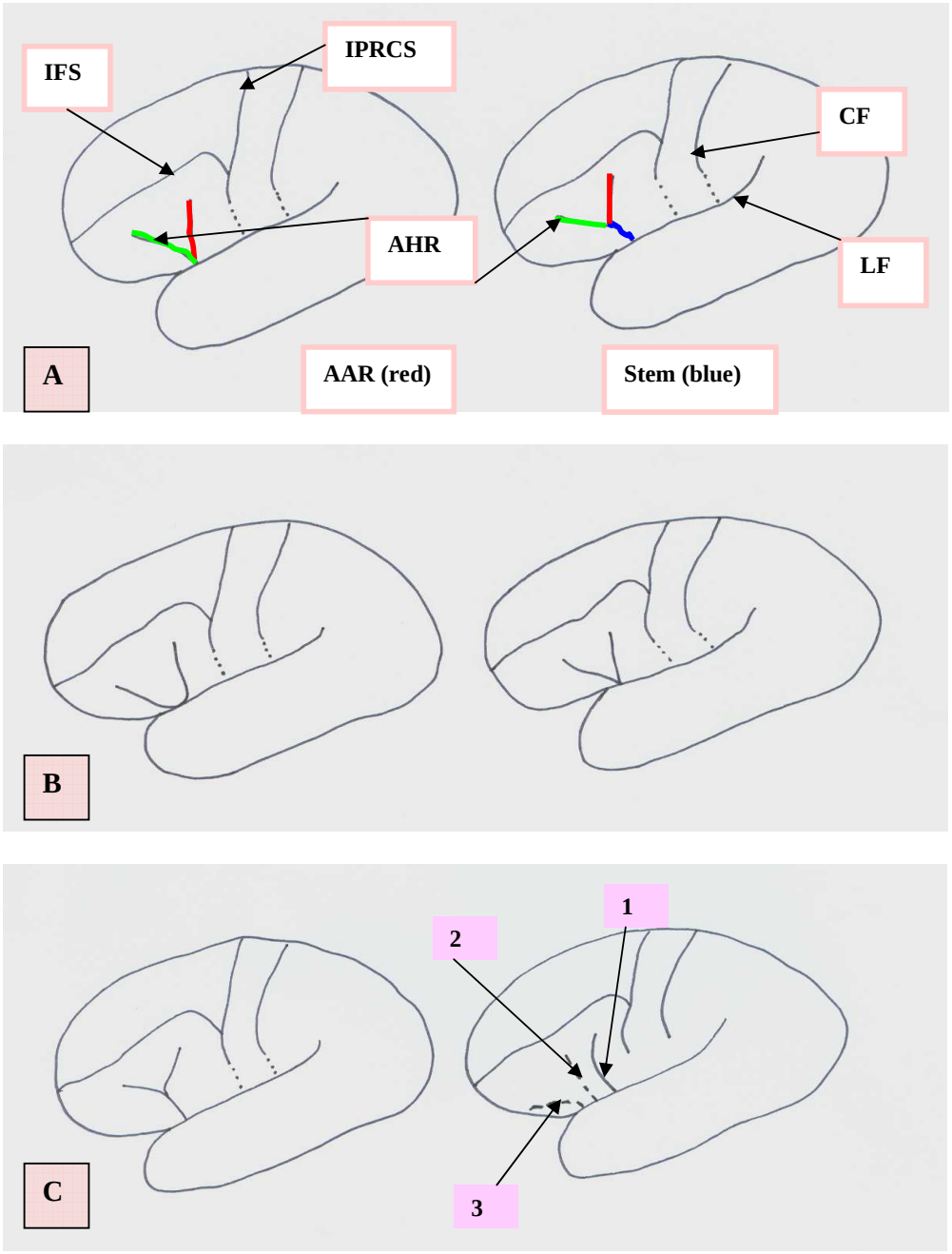

Figure 1.10 Major patterns of the anterior rami of the lateral fissure as reported by Cunningham (1890) Diagram A is the key diagram. Diagram B shows the 'U' pattern on the left and the 'V' pattern on the right. Diagram C shows the 'Y' pattern on the left and the '$\mathcal{S}$' pattern on the right. Note that the position occupied by the sole AAR (1) is indicated by a solid line and that the broken lines indicate: a possible intermediate position for the sole ramus (2), and a possible position for the sole AHR (3). [Fissures – Central (CF), Lateral (LF); Sulci – Inferior precentral (IPRCS), Inferior frontal (IFS), Anterior ascending ramus (AAR), and Anterior horizontal ramus (AHR)]. Also note that the pattern of rami other than two is not demonstrated since the position of the additional ramus is not indicated in the reference of Bergmann et al (2000). These diagrams are also adequate as a summary of the work of Eberstaller (1890).

In the **left hemisphere** the:

- Anterior ascending ramus predominated in12.5% of cases, and the
- Anterior horizontal ramus predominated in 2.5% of cases.

(b) *both the anterior ascending ramus and the anterior horizontal ramus were present and arose from a common stem, yielding a 'Y' shaped pattern.*

(c) *both the anterior rami were present and, were equally well developed.* In the study cited above, Ide et al (1999) also found increased folding in the left hemisphere as opposed to the right. This is inferred from the fissurization patterns, where both the anterior ascending ramus and the anterior horizontal ramus were better developed in the left hemisphere. The study concludes that this may possibly indicate increased cortical surface on the left, and this was related to the lateralisation of the anterior speech area in the left hemisphere.

CONCLUSIONS: The pattern of a single anterior ramus was more likely to be found in the right hemisphere, and when this occurred, the single ramus was more likely to be the anterior ascending ramus. This is similar to the *𝒥 pattern* of Eberstaller (1890) and Cunningham (1890). The pattern of a stem with the two anterior rami arising from it was more likely to be found in the left hemisphere. This is similar to the *Y pattern* of Eberstaller (1890) and Cunningham (1890). The most common pattern was that of an equal representation of both anterior rami, and this was more likely to be found in the left

hemisphere. This is similar to the *VU patterns* of Eberstaller (1890) and Cunningham (1890).

<u>COMMENT</u>: The study of Ide et al (1999) confirms the findings of the earlier studies on patterns of the anterior rami, and the lateralisation of the *𝒥 pattern* to the right hemisphere. The pattern of more than two anterior rami was, however, not found. This is not surprising since it was reported, by Cunningham (1892) to be a rare finding. Although the study of Ide (1999) reports on inter-hemispheric comparisons, it does not consider other sulci- and sulcal connections- within the frontal operculum.

1.8.2.3 <u>THE STUDY OF ONO et al (1990)</u>

Ono et al (1990), in a study of twenty- five brains reported on both the patterns- and the lengths- of the following sulci: the anterior ascending ramus; the anterior horizontal ramus; the stem (of the AHR and AAR); and the diagonal (opercular) sulcus. The following patterns were observed for the anterior rami of the lateral fissure (see Table 1.5 on pg 39 for the incidence of the patterns, and Fig 1.11E, F, and G, on pg 38):

(a) *Only a single ramus, the anterior ascending ramus, was present*

(b) *A common trunk for the anterior rami was present, yielding a 'Y' shaped pattern*

(c) *Both the anterior ascending ramus and the anterior horizontal ramus were present, but were separate from each other*.

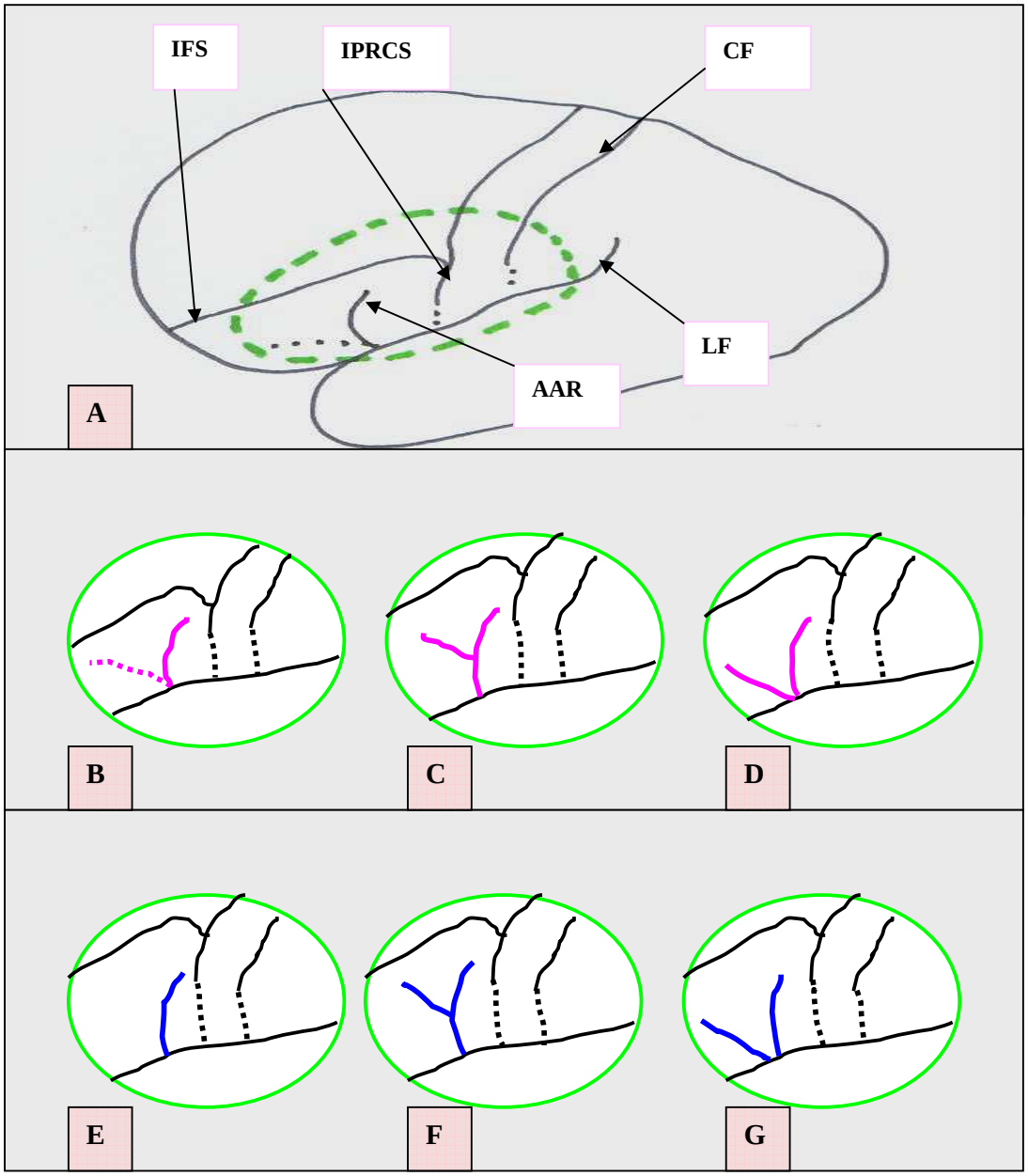

Figure 1.11 Patterns of the anterior rami of the lateral fissure as reported by Ide et al, in 1999, (diagrams B, C, and D) and Ono et al, in 1990 (diagrams E, F, and G). [The key diagram is diagram A. Fissures: central (CF), lateral (LF); sulcus: inferior frontal (IFS), inferior precentral sulcus (IPRCS), anterior ascending ramus (AAR). The selected area in diagram A has been expanded to demonstrate the patterns of the anterior rami]. In diagrams B-D [patterns of Ide et al (1999)], Diagram B shows the *I pattern* with the sole ramus occupying the position of either the anterior ascending ramus (AAR – solid pink line) or the anterior horizontal ramus (AHR – pink dashed line). Diagram C shows the *Y pattern* pattern (rami arising from a common stem), and Diagram D shows the *V-U pattern* (completely separate rami). In diagrams E-G [patterns of Ono et al (1990)], diagram E shows the *I pattern,* with the sole ramus occupying the position of the anterior ascending ramus (AAR) only. Diagram F shows the *Y pattern* (rami arising from a common stem), and diagram C shows the *V-U pattern* (completely separate rami).

Table 1.5: The Incidence of Patterns of the Anterior Rami as reported by Ide et al in 1999 and Ono et al in 1990 (expressed as percentages).

PATTERN	INCIDENCE	
	RIGHT HEMISPHERE	LEFT HEMISPHERE
(a) *𝒥 pattern*		
Ide et al (1999)	**45**	**15**
Ono et al (1990)	**8**	**16**
(b) *Y pattern*		
Ide et al (1999)	**25**	**40**
Ono et al (1990)	**28**	**24**
(c) *V-U pattern*		
Ide et al (1999)	**30**	**45**
Ono et al (1990)	**64**	**60**

CONCLUSIONS: The pattern of a single anterior ramus was more likely to be found in the left hemisphere, and when this occurred, the single ramus was always the anterior ascending ramus. A Type 4 of Ebeling would have been excluded from this sample (as in the MRI study of Ebeling et al in 1989, which was of similar size). This pattern, however, is similar to the *𝒥 pattern* of Eberstaller (1890), Cunningham (1890), and Ide et al (1999).

The pattern of a stem with the two anterior rami arising from it was slightly more likely to be found in the right hemisphere. This is similar to the *Y pattern* of Eberstaller (1890), Cunningham (1890) and Ide et al (1999). The most common pattern was again that of two separate anterior rami, and this was slightly more likely to be found in the right hemisphere. This is similar to the *VU patterns* of Eberstaller (1890), Cunningham (1890) and Ide et al (1999).

<u>COMMENTS</u>: Again all patterns, except that of more than two anterior rami, have been reported. However, in contrast to the study of Ide (1999):

- **the *ℐ pattern* was more likely to be found in the left- rather than the right-hemisphere**

- **the *Y*- and *VU- patterns* were slightly more likely to be found in the right- rather than the left- hemisphere. When examining Table 1.5 on pg 39, it becomes apparent that a clear difference in incidences exists between the two studies for the *ℐ pattern*- and the *VU- pattern* (in the right hemisphere). Since the patterns themselves are highly conserved across researchers, the differences may perhaps be explained in terms of sample size [the smaller sample of Ono (1990) may have masked some of the trends demonstrated by the sample of Ide (1999)]. The implication for the current study is that it ought to have a sample size greater than forty brains.**

Although Ono (1990) reports in detail on the:

- **Sulcus of the pars opercularis (diagonal sulcus), the sulcus of the pars triangularis is not mentioned, and the**

- **Connections of fissures and sulci, are not used to derive any system of classification on the basis of their connections.**

1.8.3 REFERENCES FOR THE SULCI OF THE PARS OPERCULARIS

Tomaiuolo et al (1999), quote studies (other than their own) on the diagonal sulcus [see Fig 1.12 (D, E, and F) on pg 43]:

(a) Eberstaller (1890) as well as Bailey and Bonin (1951):

- The diagonal sulcus was defined as a small sulcus that was present within the pars opercularis. The incidence of its occurrence was not stated.

- The connections of the diagonal sulcus were as follows:

    - None, it was free in the pars opercularis,
    - With the inferior frontal sulcus superiorly,
    - With the inferior precentral sulcus posteriorly, and
    - With the lateral fissure, inferiorly.

(b) Turner (1948) in contrast to Bailey and Bonin (1951) found the 'diagonal sulcus to be a regular feature of the human brain', but the frequency with which it was present was not quoted.

(c) Galaburda (1980) examined the photographs of the 102 brains studied by Geschwind and Levitsky (1968) and found the diagonal sulcus to be present in 12.75% of right hemispheres and 26.5% of left hemispheres.

Galaburda (1980) describes four patterns for the diagonal sulcus. These were:

- Present in both hemispheres, in most cases,
- Present only in the left hemisphere, 27 cases,
- Present only in the right hemisphere, 13 cases, and
- Absent from both hemispheres

The diagonal sulcus was always shown as being connected to the anterior ascending ramus. He, however, does not comment on its connections with respect to other sulci. A concern was expressed that it was not always possible to tell from the manner of its joining to the anterior ascending ramus, whether the diagonal sulcus was a branch into the pars triangularis or into the pars opercularis.

Ono et al (1990) reported that the diagonal sulcus was present in 64% of right hemispheres and 28% of left hemispheres. Five connections were listed (see Table 1.6 on pg 44).

Albanese et al (1989) also mention the diagonal sulcus. But, they place it within the pars triangularis, and use it to subdivide this portion of the frontal operculum into the ‘triangularis caudalis’ and ‘triangularis rostralis’. Other researchers such as Falzi et al (1982); Galaburda (1980); and Wada et al (1975) also use a sulcus in exactly this position but refer to it differently (see section 1.8.4 on pages 45 to 46, on the triangular sulcus).

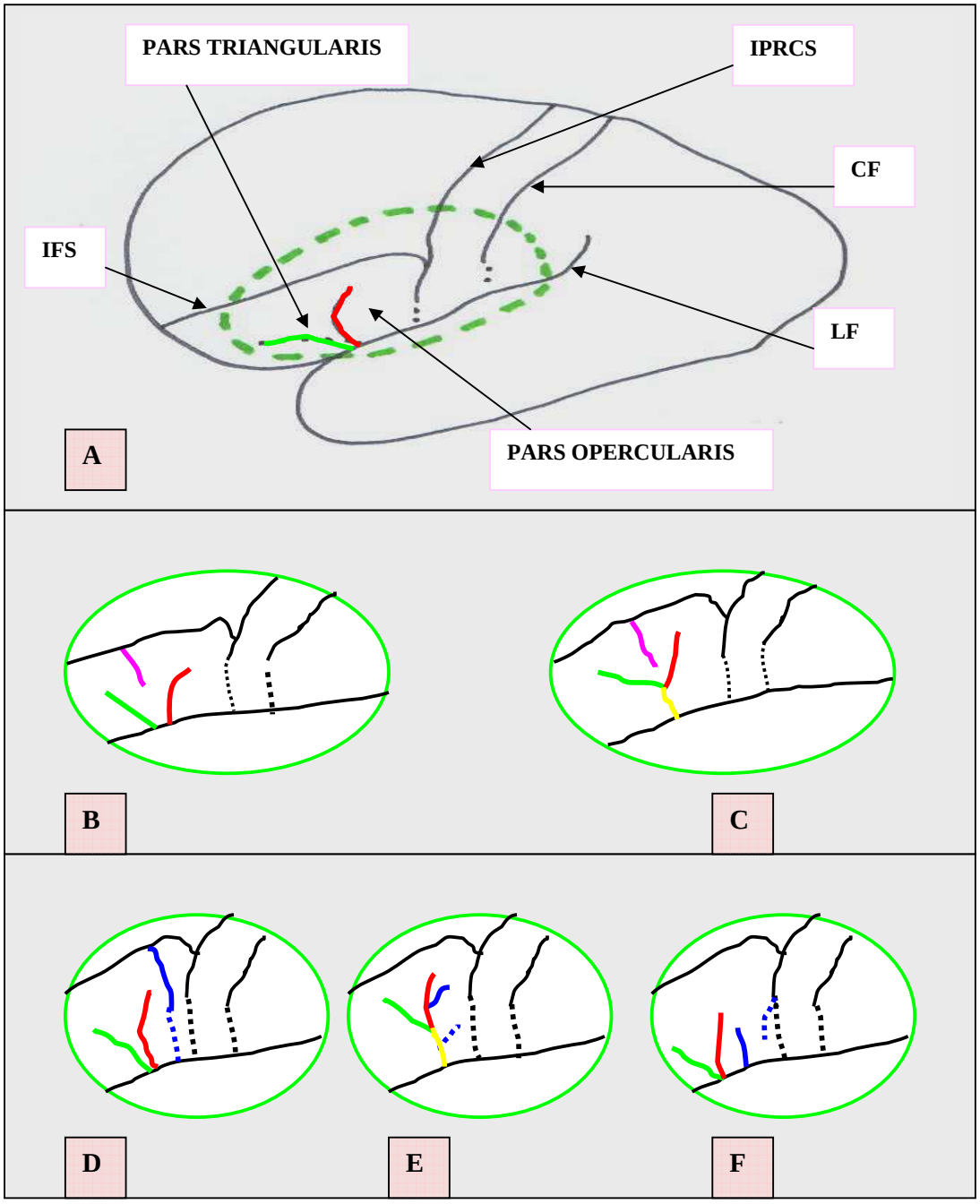

Figure 1.12 Accessory sulci of the frontal operculum (highlighted in purple and blue). Diagram A is the key diagram [Fissures: central (CF), lateral (LF); Sulci: inferior frontal (IFS), inferior precentral (IPRCS), anterior ascending ramus (AAR) is the red line, the anterior horizontal ramus (AHR) is the green line, stem (yellow); regions: pars opercularis – between the IPRCS and the AAR, pars triangularis – between the AAR and the AHR. Diagrams B and C show the triangular sulcus (in purple) originating from the IFS, in the *V-U pattern*- and *Y pattern*- of the anterior rami, respectively. Diagrams D, E, and F show the opercular (diagonal) sulus. The solid blue lines indicate one possible connection and the dashed line indicates an alternative possible connection. Note that any of these connections, except that to the stem, can occur relative to any pattern of the anterior rami. Diagram D shows connections of the opercular sucus to the IFS only; or between the IFS and LF. Diagram E shows connections between the opercular sulcus and the AAR or the stem. Diagram F shows connections of the opercular sulcus to the LF or to the IPRCS.

Table 1.6: Connections of the Diagonal Sulcus (Opercular sulcus) as reported by Ono et al (1990)[7]

		PERCENTAGE(%) INCIDENCE	
	CONNECTIONS OF THE DIAGONAL SULCUS WITH THE:	**RIGHT HEMISPHERE**	**LEFT HEMISPHERE**
1	**Posterior ramus of the lateral fissure**	**64**	**36**
2	**Anterior ascending ramus**	**0**	**24**
3	**Stem (of AAR and AHR)**	**0**	**4**
4	**Inferior Frontal Sulcus**	**4**	**24**
5	**Inferior Precentral Sulcus**	**0**	**4**

Tomaiuolo et al (1999) in an *in vivo* MRI study of the pars opercularis, reported the incidence of the diagonal sulcus as 32% in the right hemisphere and 34% in the left hemisphere. It was stated that the sulcus was as is described in the maps of Brodmann 1908, 1909) and Economo & Koskinas (1925). Tomaiuolo et al (1999) also mention the presence in the pars opercularis, of a 'small dimple in almost all hemispheres.'

Amunts, Schleicher, Burgel, Mohlberg, Uylings, and Zilles (1999) in a cytoarchitectonic study, report the diagonal sulcus as being an inconstant sulcus, occurring within the pars opercularis. They further state that it could either be located within Brodmann's area 44 or mark the **histological border** between Brodmann's areas 44 and 45.

[7] Note that it is possible for a sulcus to have more than one connection.

CONCLUSION: The incidence and connections of the sulcus of the pars opercularis (diagonal sulcus) is variable.

COMMENTS: I agree with Tomaiuolo et al (1999) that a likely explanation for the variability in the reporting on the sulcus of the pars opercularis could be the use of different criteria for its identification. The implication for the present study is that:

- **The primary criterion distinguishing the *Type 3 of Ebeling (the presence of an additional branch in the pars opercularis originating from the inferior frontal sulcus)* would need to be broadened to include other connections.**

- **There is also a need to examine when the 'so called' diagonal sulcus, is actually diagonal in nature.**

1.8.4 REFERENCES FOR THE SULCI OF THE PARS TRIANGULARIS

Galaburda (1980) refers to this sulcus as the '*incisure du cap*' and describes it as a branch of the inferior frontal sulcus that descends into the pars triangularis [see Fig 1.12 (B and C), on pg 43]. Wada et al (1975) considered this triangular sulcus sufficiently constant to use as an anterior landmark for planimetric measurement of the frontal operculum. Rubens (1977) questions the reliability of using this sulcus as such a landmark and quotes Wada et al (1975) on the description of the triangular sulcus as: a deep branch that descends into the

pars triangularis towards the lateral fissure, from the midpoint of the inferior sulcus. From their description, Albanese et al (1989) also use the triangular sulcus as a marker in a quantitative study, although they name it as the diagonal sulcus.

COMMENTS: There appears to be no record of the incidence or the length of the sulcus of the pars triangularis although it seems to have been recognised as a very useful landmark. The implication for the present study is that it is worthy of exploration.

1.8.5 REFERENCES ON MEASUREMENTS IN THE FRONTAL OPERCULUM

Ono et al (1990) report on: sulcal lengths within the frontal operculum, except for that of the triangular sulcus (see Table 1.7 on pg 46); and intersulcal lengths, at the level of the lateral fissure, but not at the level considered in the present study.

Table 1.7: Lengths of Sulci in the Frontal Operculum (Ono et al, 1990). All measurements are in centimetres.

SULCUS	MEAN LENGTH IN RIGHT HEMISPHERE (RANGE)	MEAN LENGTH IN LEFT HEMISPHERE (RANGE)
1. AHR	1.5 (0.2-3.5)	1.4 (0.9-2.7)
2. AAR	1.6 (0.2-2.7)	1.8 (0.3-2.9)
3. Stem (of AHR and AAR)	0.8 (0.4-3.0)	0.9 (0.5-1.5)
4. Diagonal (Opercular)	1.9 (4.0-3.0)	1.7 (0.2-3.2)

1.8.6 THE QUESTIONS POSED BY THE CURRENT STUDY RELATIVE TO THE LITERATURE SURVEY

(a) An analysis of the study of Ebeling et al (1989) has revealed the following shortfalls:

- The additional branch (probably the diagonal sulcus) described in Type 3, which is a key defining feature of this type of sulcal connections, is reported in the literature to have several possible connections, and not only one (to the inferior frontal sulcus) as indicated.
- A potentially useful landmark (triangular sulcus) was not mentioned. Its position relative to the anterior horizontal ramus, when present, could be helpful in assessing the frontal operculum especially in a Type 4 situation (absence of the anterior ascending ramus).
- Only two patterns of the anterior rami (*V-U pattern* and *𝒥 pattern*) are depicted. The literature review reveals that the *Y pattern* is also a significant pattern.
- Ono el al in 1990, report the presence of a double precentral sulcus. Ebeling et al (1989) do not report this. Studies on the Types of Connections in the frontal operculum, subsequent to the finding of Ono el al (1990) on the existence of a double precentral sulcus, would need to incorporate this information into the description of the Types of Sulcal Connections, if necessary.

(b) The implication for the current study is that the descriptive objectives would need to address the following questions:

(i) What are the sulci of the frontal operculum and with what frequency do they occur, in both cerebral hemispheres?

(ii) What are the connections of the fissures and sulci of the frontal operculum, in both cerebral hemispheres?

(iii) Is there a need to modify the key criterion distinguishing Type 3?

(iv) Is the occurrence and location of the triangular sulcus consistent enough to be used as a landmark?

(v) Can the information in (a), (b), and (c) be used to replicate the study of Ebeling et al (1989), in its original form or in a modified form?

(vi) What are the incidences of the patterns of the anterior rami relative to the Types of Ebeling?

(vii) Is there an interhemispheric difference with respect to the incidences of the Types of Connections as well as Patterns of the Anterior Rami?

(c) Since reports on measurements in the frontal operculum appear to be scanty, and reference ranges of sulcal and intersulcal lengths are useful tools, the following questions are posed:

(i) What are the mean lengths of the major and accessory sulci in the frontal operculum, of both cerebral hemispheres (see section 1.1 on pg 5 and Fig 1.7 on pg 15 and Fig 1.12 on pg 43)?

(ii) What are the mean lengths of the major and accessory sulci, with respect to the:

- Types of Connections, and
- Patterns of Anterior Rami, in the frontal operculum, in both cerebral hemispheres?

(iii) What are the mean intersulcal lengths between the:

- Major sulci of the frontal operculum, in both hemispheres,
- Major- and accessory- sulci of the frontal operculum, in both hemispheres,
- Anterior ascending ramus and the inferior precental sulcus,
- Inferior precentral sulcus and the central fissure,
- Central fissure and the inferior postcentral sulcus, at the horizontal level corresponding to the superior termination of the anterior ascending ramus?

(d) The following question is posed from the point of view of lateralization studies:

Is it possible to illustrate the relationship, if any, between:

- *Sulcal length* and the *Types of Sulcal Connections in F3*,

- *Sulcal length* and the *Patterns of the Anterior Rami of the Lateral Fissure*,

by considering the following sulci (individually) in both hemispheres:

- ***Major sulci*** *(*the *stem of the AAR and AHR* (stem), the *anterior ascending ramus of the lateral fissure* (AAR), and the *anterior horizontal ramus* (AHR) *of the lateral fissure)?*
- ***Accessory sulci*** *(the triangular- and opercular- sulcus/ sulci)?*

(e) In view of the difficulty in obtaining specimens for anatomical studies on the brain, and the time consuming nature of the process of measurement, the following question is posed: can alternative (less direct) methods of acquiring data, such as:

- Measurements from photographs,
- Measurements from pen tracings of the surface of the brain,
- And mechanical means of measuring, be used to measure

sulcal lengths accurately?

1.9 FURTHER DEFINING FEATURES OF GYRI AND SULCI

The cytoarchitecture of the cerebral cortex differs on a local and a regional basis. The regional differences have enabled the cortex to be mapped into distinct histological fields. One such map of the human cerebral cortex is that prepared by Brodmann (Greger and Windhorst, 1996). Findings in basic science and clinical medicine have made it possible for various functions to be integrated into these histological maps. Some functional areas of the cortex may lie within such histological fields. In cases where different functional areas arise from adjacent fields that differ histologically, sulci may serve as separators.

Local differences in cytoarchitecture are manifest in individual gyral and sulcal complexes. The histological structure of gyral crowns is significantly different from that of the fundic cortex, whilst that of sulcal and fissural walls is intermediate between that of crown- and fundic- cortex (Welker, 1990). The differences between crown and fundic- cortex are reflected as follows:

(a) Crown cortex is thicker than fundic cortex.

(b) The crown cortex is less dense in cell bodies than the fundic cortex. The mesh, of neuronal processes and astrocytes (the neurophil, see section 1.3, paragraph 1 on pg 11) that occurs between the nerve cell bodies, is more dense in crown cortex than in fundic cortex. This is responsible for the spacing of the cell bodies.

(c) Although lamination is more distinct in crown cortex than in fundic cortex, certain laminae tend to be better represented in crown cortex than in fundic cortex (see section 1.3, paragraph 2 on pg 11). Laminae I and II are thinner in crown cortex than in fundic cortex but, laminae V and VI are thicker in crown cortex than in fundic cortex.

(d) The myelinated afferent fibres to the crown cortex tend to be more vertical in orientation than those to the fundic cortex. These afferents tend to branch more profusely in crown- rather than in fundic- cortex.

(e) The junctional area between the grey and white matter tends to be more diffuse in the crown whereas that of the fundus is sharpened by the presence of a distinct bundle of 'U' shaped fibres.

In spite of the obvious differences listed above, cytoarchitectural studies have not revealed a clear and consistent relationship between functional areas and fissurization. Electrophysioloical studies of sensory cortices and their receptive fields in different mammalian species have however, pointed to a functional correlate for the above structural differences (Welker, 1990). More sensitive areas of the skin have been discovered to project to gyral crowns and less sensitive areas to fundi. **This raises the possibility that fissurization, rather than simply being a passive phenomenon, might well reflect the underlying fibre connections and functional parcelling of gyri.**

A particular function need not necessarily reside within the territory of a single gyrus and

its associated sulcal cortex. Complex functions that are typically associated with the cerebral cortex are generally composed of sub-functions or modalities of function, which may be widely distributed in gyri (and the associated sulcal cortices) in different parts of the brain. They remain connected so as ensure holistic functioning. Fitzgerald, (1992) summarises this structural-, functional-, and connectional- relationship as follows: ‘gyral and sulcal cortices appear to serve as ‘nodal points’ in distributed networks of function, as a consequence of their widespread connections with other areas of the brain.

1.10 A SYNOPSIS OF THE DEVELOPMENTAL ANATOMY ASSOCIATED WITH GYRI AND SULCI

Mammalian brains that have relatively fewer gyri and sulci are referred to as lissencephalic and those that have relatively many gyri are called gyrencephalic. Variability in number and size of gyri and sulci can also be observed within species. In the human, aberrations of development, giving rise to, for example, lissencephaly and microgyria, point to the possibility that the morphology of gyri and sulci are linked to developmental processes. In humans, cerebral convolutions and fissures make their appearance in the fifth foetal month. The first fissures to appear (demarcating convolutions), are termed, primary. Examples include the central- and lateral- fissures as well as the precentral- and inferior frontal- sulci. These are followed by the secondary- and tertiary- sulci, which ‘peculiar to the human brain, are developments of the final foetal months’ (Arey, 1965). Tertiary sulci

although most numerous, ‘become fully demarcated only months after birth’ (Richman, Stewart, and Hutchinson, et al., 1975).

Richman et al (1975) state that while primary and secondary convolutions are relatively constant in their location, configuration, and relationship to cortical cytoarchitectonic fields, tertiary convolutions **appear unpredictable** in their form and anatomical relations.

Various models of cortical folding have been proposed. Early studies focussed on the constraints of non-deformable neighbouring structures on the expanding cerebral hemispheres or on intra-cortical factors such as differential growth. The more modern studies focus on the formation of connections (connectivity).

The period of gyrus and fissure formation coincides with the period of maximal increase in volume of the cerebral cortex. Since the period of cell migration is essentially complete by the fifth foetal month, the increased growth could be attributed to the processes of gyral modelling and modification. Some factors implicated in gyrogenesis are (Welker, 1990): neuronal differentiation and dendrogenesis; neuronal orientation; arrival, penetration, fasciculation, and arborisation of afferent neurons; synaptogenesis; glial proliferation; modelling of the laminae; plasticity; rearrangement of cell adhesion molecules and related membrane structures; as well as different timetables. There also appears to be a relationship between gyral- and skull- formation, although the nature of the link is unclear.

Research findings have implicated the formation and timing of fibre connection as key factors in cortical folding. These findings are strengthened by observations from developmental pathology. In the presence of the corpus callosum, the cingulate sulcus and its branches separate the medial frontal gyrus, paracentral lobule, and precuneus superiorly from the cingulate gyrus inferiorly. In congenital absence of the corpus callosum, this pattern is replaced by sulci radiating from the callosal sulcus towards the longitudinal fissure (Ono, Kubik, and Abernathey, 1990; Lemre, Loeser, Leech, Ellsworth, and Alvord, 1975).

The influence of the formations of connections on cortical folding has been illustrated by means of the enucleated monkey model (Rakic, 1988; Dehay, Giroud, Berland, Killackey, and Kennedy, 1996). Early removal of both eyes led to morphological changes at the level of the thalamus and the cortex. There was a massive loss of neurons in the inferior pulvinar and the lateral geniculate nucleus and hence a reduction in the thalamo-cortical projection. Although the size of the occipito-temporal cortex remained the same, there was a reduction in the size of the striate cortex that was accompanied by an increase in cortical folding on the lateral opercular surface. This amounted to a shift in the border between Brodmann's areas 17 and 18. It may be inferred that the formation of connections as well as the timing of its onset is an important determinant of fissurization in the brain. **Sulcal variation could thus be a reflection of the underlying fibre connections and the timing of its onset.**

Van Essen (1997) in his 'Tension- based theory of morphogenisis and compact wiring in the central nervous system' states that greater folding in large as opposed to small brains

occurs because the cortical surface area increases disproportionately with respect to brain size. The spatial pattern of folding was linked to the onset of connections between cortical areas ('cortico-cortical connectivity'). It is proposed that tension in the white matter is the primary driving force for cortical folding. This theory uses as support, the findings on the elastic properties of neurities (axon like extensions produced by neurons and neuronal cell lines *in vitro*). It is also suggested via an analysis of the relationship between folding and fibre connections in the macaque model that: the production of neural circuitry that is compact, requires the total lengths of axons and dendrites to be kept at a minimum; and that tension is a means of achieving this end.

Although the link between connectivity and cortical folding is clear, a strict causal relationship does not necessarily follow. A case for a genetic basis for fissurization has been opened up by recent findings that:

- 'Two transverse boundaries of gene expression have been identified in the cerebellar primodium which coincide roughly with the positions of the two earliest sulci or fissures' (*Mason and Sotelo, 1997; Herrup and Kuemerle, 1999*, in Rogers, Ciossek, Menzel, and Pasquale, 1999).
- Tyrosine kinase receptors with ephrins as the ligands attaching them to cells ('Eph receptors) and ephrins may be the first molecules to demarcate individual cerebellar lobules during development' (Rogers et al, 1999).
- Mutations of the doublecortin gene account for approximately twenty percent of the cases of lissencephly in humans (Tanaka, Seerneo, Tseng, Kulkarni, Tsai, and Gleeson, 2004)

If indeed, the development of fissurization, is under direct genetic control, important outstanding questions would relate to: the extent of this control with respect to primary, secondary, and tertiary fissures or sulci, and its relationship to variation and cortical functioning.

2. MATERIALS AND METHODS

2.1 BROAD QUESTIONS POSED BY THE PRESENT STUDY (RELATIVE TO THE DESCRIPTIVE OBJECTIVES)

2.1.1 QUESTIONS RELATING TO THE FISSURES AND SULCI THAT WERE USED FOR ORIENTATION PURPOSES

(a) What are the incidences of the pertinent features of the fissures and sulci, used for orientation purposes, in both cerebral hemispheres for ungrouped data, in the present study? These fissures and sulci are: the central fissure, the upturned end of the posterior ramus of the lateral fissure, and the inferior part of the postcentral sulcus [see Fig 2.3 on pg 82; as well as sections 2.8.2 (a) and 2.8.2 (b) on pages 87 and 89 respectively]. Note that:

- ***Ungrouped data*** **refers to data on sulci prior to its classification according to: the Types of Connections of Ebeling, and the Patterns of the Anterior Rami of the Lateral Fissure.**
- ***Grouped data*** **refers to data on sulci that was classified according to: the Types of Connections of Ebeling; and the Patterns of the Anterior Rami of the Lateral Fissure**
- Questions are not posed for the lateral fissure itself but for its branches or rami (anterior).

(b) Are the incidences of the pertinent features of the orientating fissures and sulci [as listed in sections 2.8.2 (a) and 2.8.2 (b) on pages 87 and 89 respectively], consistent with the findings of previous studies reviewed thus far?

2.1.2 QUESTIONS RELATING TO SULCI THAT FORM THE BOUNDARIES OF THE FRONTAL OPERCULUM

(a) What are the incidences of the pertinent features of the sulci forming the superior- and posterior- boundaries of the frontal operculum, in both cerebral hemispheres for ungrouped data? These sulci are: the inferior frontal sulcus and the inferior part of the precentral sulcus, [see Figs 2.1 and 2.2 on pages 69 and 70 respectively; as well as sections 2.8.2 (c) and 2.8.2 (d) on pages 90 and 91 respectively].

(b) Are the incidences of the pertinent features [see them listed in sections 2.8.2 (c) and 2.8.2 (d) on pages 90 and 91 respectively] of the two boundary sulci mentioned in section 2.1.2 (a), consistent with the findings of previous researchers?

2.1.3 QUESTIONS RELATING TO THE SULCI THAT ARE FOUND WITHIN THE FRONTAL OPERCULUM (FOR UNGROUPED DATA)

(a) What are the incidences of the pertinent features of the major- and accessory- sulci

[see Fig 1.7 on pg 15 and Fig 1.12 on pg 43; as well as section 2.8.2 (e-h) on pages 93 to 96] in the frontal opercula of both cerebral hemispheres, for ungrouped data? The major sulci are the anterior rami and the stem of the anterior rami when present. The accessory sulci are the opercular sulci and the triangular sulci.

(b) Are the incidences of the features of the major- and accessory- sulci of the frontal operculum that were listed in section 2.8.2 (e-h) on pages 93 to 96, consistent with the findings of previous researchers, for ungrouped data?

2.1.4 QUESTIONS RELATING TO THE SULCI THAT ARE FOUND WITHIN THE FRONTAL OPERCULUM (FOR GROUPED DATA)

(a) Can the information gathered on the fissures and sulci of the frontal operculum be used to replicate the studies of:

- Ebeling et al (1989), as regards the Types of Connections (see section 1.8.1 on pg 22 to 26; and Fig 1.9 on pg 24), and
- Others, as regards the Patterns of the Anterior Rami, of the Lateral Fissure (see section 1.8.2 on pages 32 to 40; and Figs 1.10 on pg 35 and 1.11 on pg 38), in their original forms, or in modified forms?

(b) Is there a significant inter-hemispheric difference with respect to the incidences of:

- Each of the four Types of Connections of Ebeling, and
- Each of the three Patterns of the Anterior Rami of the Lateral Fissure?

(c) What are the incidences of the Patterns of the Anterior Rami (of the Lateral Fissure) relative to the Types of Connections of Ebeling?

2.2 BROAD QUESTIONS POSED BY THE PRESENT STUDY RELATIVE TO THE QUANTITATIVE OBJECTIVES

2.2.1 QUESTIONS ASSOCIATED WITH THE MEASUREMENTS OF UNGROUPED DATA

(a) What are the mean lengths of the individual major- and accessory- sulci of the frontal opercula, in the right- and left cerebral hemispheres (see Fig 1.7 on pg 15 and Fig 1.12 on pg 43) for ungrouped data?

(b) Is there an inter-hemispheric difference (significant if possible) with respect to the means of the lengths of the individual major- and accessory- sulci of the frontal opercula, for ungrouped data?

(c) What are the mean intersulcal lengths, taken at the level the termination of the anterior rami, within the fronto-parietal operculum, for ungrouped data?

2.2.2 QUESTIONS ASSOCIATED WITH THE MEASUREMENTS OF GROUPED DATA

(a) What are the mean lengths of individual major- and accessory- sulci of the frontal operculum, in each cerebral hemisphere, for data grouped according to the:

- Types of Connections of Ebeling,
- Patterns of the Anterior Rami of the Lateral Fissure?

(b) Is there an inter-hemispheric difference (significant if possible) with respect to the means of the lengths of the individual major- and accessory- sulci of the frontal opercula, for data that are grouped according to the:

- Types of Connections of Ebeling
- Patterns of the Anterior Rami of the Lateral Fissure

2.2.3 THE QUESTION POSED BY THE PRESENT STUDY THAT IS ASSOCIATED WITH ALTERNATIVE METHODS FOR ACQUIRING QUANTITATIVE DATA

Can other less direct methods [*when compared to that used by the present study and described in section 2.9 on pages 97 to 103*)], such as:

- The use of photographic negatives,
- The use of printed photographs,
- The use of pen tracings of the external portions of sulci, and
- The use of mechanical means of acquiring data directly from the brain, be

used to measure sulcal lengths accurately?

2.3 THE SAMPLE USED IN THE PRESENT STUDY

2.3.1 THE TYPE OF SPECIMENS IN PRESENT STUDY

Only human brains were considered for the present study. The target sample number was set at two hundred cerebral hemispheres. This was exceeded (by twenty). The right- and the left- hemispheres were equally represented in this sample.

The majority of the specimens in the sample (59%) originated from whole brain specimens, in which the right- and the left- cerebral hemispheres originated from the same individual. The remainder of the specimens (41%) consisted of a collection of separate right- and left-hemispheres, in which the two hemispheres (in all probability) originated from different individuals.

In order to avoid any possible bias in the reporting of data relative to the right- or the left-cerebral hemisphere, the two categories of specimens in the sample were treated as follows:

- The category of whole brains, was designated as the **control group**, since a direct comparison could be made between the right- and left- cerebral hemispheres of each individual.

- The category of separate hemispheres was designated as the **case group**, since a collection of right hemispheres, was being compared to a collection of left hemispheres.

2.3.2 THE EFFECT OF THE SAMPLE TYPE ON THE BROAD QUESTIONS POSED BY THE PRESENT STUDY.

The questions listed in section 2.1 on pages 58 to 61 and section 2.2 pages 61 to 62, are still posed. They are however, posed relative to the case- and control- categories as described in section 2.3.1 above.

2.3.3 THE SOURCE OF THE SPECIMENS AND THE EXCLUSION CRITERIA

The brains were obtained from the departmental collections of two sources: the School of Anatomical Sciences, University of Witwatersrand (**a**); and the Department of Anatomy, Walter Sisulu University (**b**), see table 2.1 below.

Table 2.1: Sample source and number. Note that: University of Witwatersrand and Walter Sisulu University are designated by (**a**) and (**b**) respectively.

SOURCE	WHOLE BRAINS	SEPARATE LEFT HEMISPHERES	SEPARATE RIGHT HEMISPHERES	TOTAL NUMBER OF HEMISPHERES
a	**55**	**45**	**31**	**186**
b	**10**	**-**	**14**	**34**
(a+b)	**65**	**45**	**45**	**220**

Unfortunately information relating to language, age, and gender was not available for these specimens, from either institution. The collection of the Department of Human Biology, Durban Institute of Technology was explored in the hope of obtaining such information. A sufficiently representative sample number (from this group of specimens) for the specific criteria sought was not forthcoming either (*see Appendix A on pages 265 to 266*). Time constraints made further information gathering in this direction unfeasible. Consequently, this set of specimens, and the aims associated with them were not pursued.

The two hundred and twenty hemispheres processed fell into two new categories:

- Those that were preserved by fixative *in situ*, and
- Those that were removed at postmortem and preserved separately in fixative.

It was noted that the postmortem set of brains examined at the University of Witwatersrand, appeared to be visibly larger than those preserved *in situ*, (the observations were made by inspection and not through measurement). The postmortem brains, on initial immersion in preservative, absorb fluid, and expand visibly (personal communication with F Ladner, June 2002, senior technician in the Department of Anatomical Sciences, Witwatersrand University). The postmortem set of specimens examined at the University of Transkei and at the Durban Institute of Technology also appeared visibly larger than their *in situ* counterparts. This appears to point to a mechanical effect rather than to the type of fixative used, or to the technique used in fixing the brains.

The brains fixed *in situ*, are constrained by the skull, and therefore cannot expand to any significant extent. The postmortem brains, on the other hand are not constrained by the skull and appear to accumulate extra fluid in the intercellular space, thus enlarging the size of gyri. The texture of the postmortem brains is also softer than that of their *in situ* counterparts. The expansion criterion was not relevant to the descriptive study as the sulcal patterns and connections appeared undistorted. **The postmortem set was, however, excluded from the quantitative study.** This implied that a part of the University of Witwatersrand sample and the entire contribution from the Walter Sisulu University could

not be measured. The need for the calculation of a shrinkage-constant was, therefore, also eliminated. See *Appendix D* (pg 312 - 313) for the record of which specimens were used in the quantitative study.

Since all the specimens appeared normal, all were accepted into the sample. In some cases, the specimens were damaged, which rendered them unsuitable for measurement. The appearance of the damage suggested that it might have been the result of cuts sustained during the extraction of these brains from the cranial cavity, or due to over-handling of the specimens (see Fig 1.5 on pg 14).

2.4 ETHICS CLEARANCE

The committee for Research on Human Subjects (Medical), University of Witwatersrand, has waived ethics clearance as, the activities within this study are covered by the Human Tissue Act, No. 65, of 1983. See Appendix B on pg 267, for a copy of the letter of the waiver.

2.5 THE PRE-RECORDING PHASE

Each specimen was tagged with a strip of plastic 'dymo' tape (see Figure 1.5 on pg 14). The initials of the author as well as the specimen number, were attached to either the basilar artery or to the hemisphere itself (when the basilar artery was absent). The meninges and the blood vessels were then carefully removed from the entire hemispheric surfaces in order to expose the gyri and sulci clearly. The central fissure was located in each hemisphere and an office pin was inserted into the precentral gyrus, as an aid to subsequent speedy orientation. The specimens were then stored in numerical order in labelled tanks so as to ensure easy access to them.

2.6 THE BOUNDARIES OF THE FRONTAL OPERCULUM AS USED IN THE PRESENT STUDY

(a) THE SUPERIOR BOUNDARY OF THE FRONTAL OPERCULUM

The inferior frontal sulcus contributes to the superior boundary of the frontal operculum. This sulcus has been reported to be frequently discontinuous or interrupted (see Table 2.2 on pg 71). The presence of a connection of the posterior end of the inferior frontal sulcus to the inferior part of the precentral sulcus has also been found to be inconstant in occurrence (see Table 1.4 on pg 27).

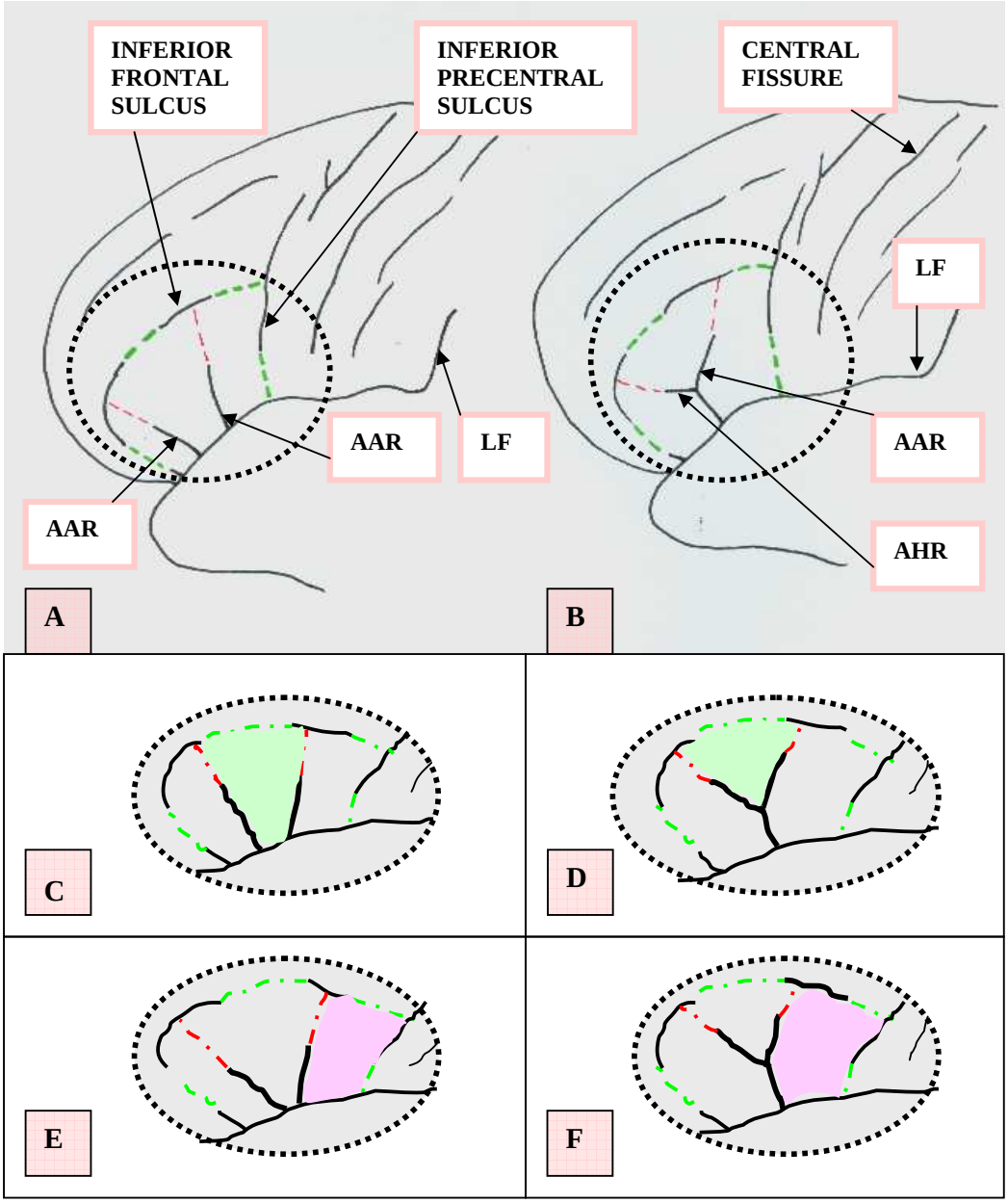

Figure 2.1 Boundaries of the inferior frontal gyrus in the presence of a single precentral sulcus. Note that: the green dashed lines complete the external boundaries frontal operculum , and the red dashed lines complete the intra-opercular boundaries of the frontal operculum. In Diagram A (separate anterior rami), the inferior boundary, is formed by the stem of the lateral fissure (LF), the LF between the anterior ascending rams (AAR) and the anterior horizontal ramus (AHR), and by the initial part of the posterior ramus of the LF. In Diagram B (anterior rami arising from a common stem of the AAR and AHR), the inferior boundary is formed by the stem of the LF and the initial part of the posterior ramus of the LF. The areas selected by the dashed black lines are expanded in diagrams C to F. Diagrams Cand D depict the pars triangularis for the VU- and Y-patterns respectively, in the presence of a single precentral sulcus. Diagrams Eand F depict the pars opercularis for the VU- and Y-patterns respectively, in the presence of a single precentral sulcus.

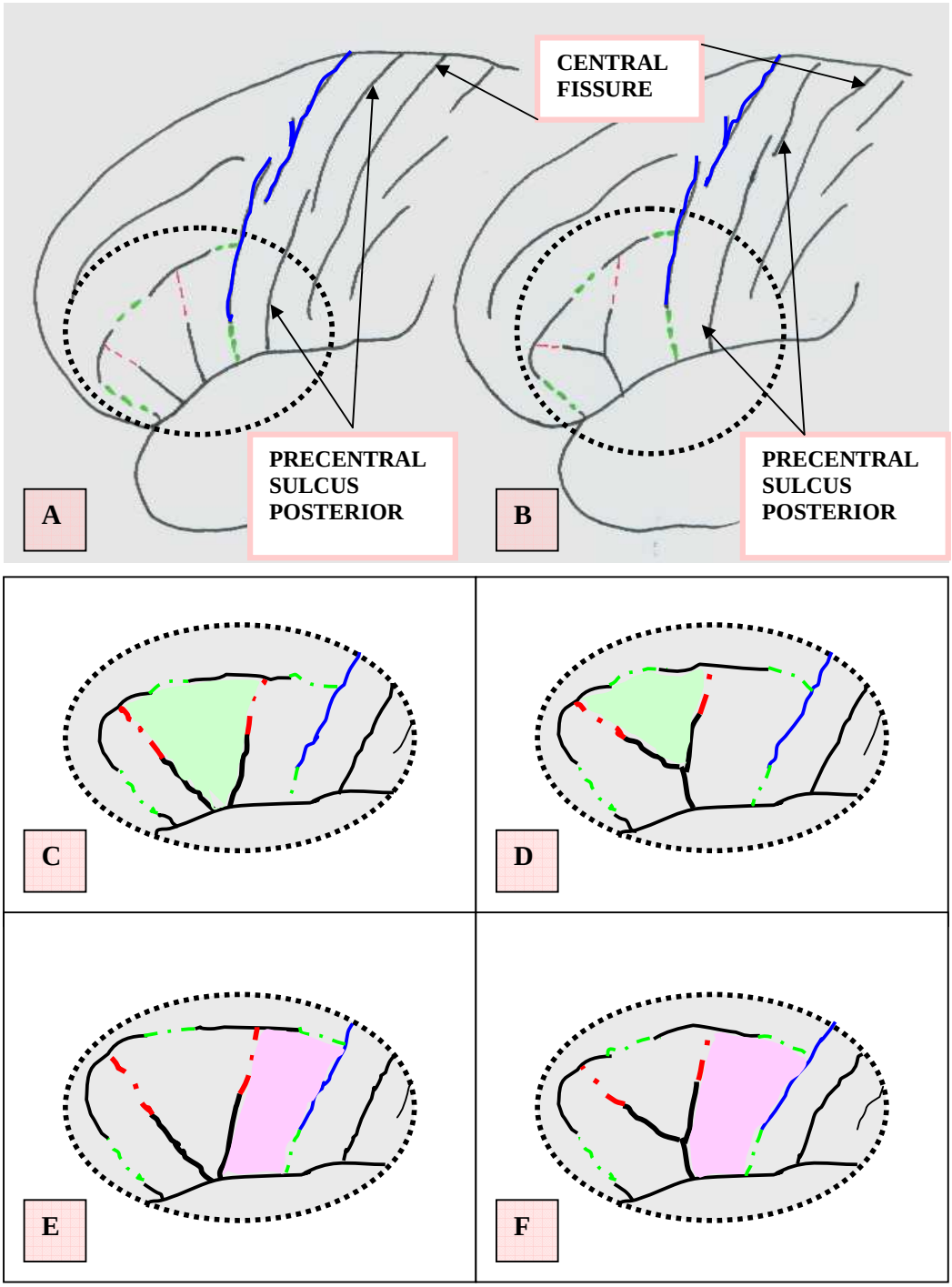

Figure 2.2 Boundaries of the frontal operculum in the presence of two precentral sulci. Note that: the green dashed lines complete the external boundaries of the frontal operculum , and the red dashed lines complete the intra-opercular boundaries of the frontal operculum. Also, the posterior boundary of the frontal operculum, is formed by the inferior part of the anterior precentral sulcus (inferior precentral sulcus anterior), which is the blue sulcus; all other labels as in Fig 2.1, pg 69. The black sulcus immediately posterior to it is the inferior part of the posterior precentral sulcus (precentral sulcus posterior). The areas selected by the dashed black lines are expanded in diagrams C to F. Diagrams Cand D depict the pars triangularis for the VU- and Y-patterns respectively, in the presence of a double precentral sulcus. Diagrams Eand F depict the pars opercularis for the VU- and Y-patterns respectively, in the presence of a double precentral sulcus.

Amunts, Schleicher, Burgel, Mohlberg, Uylings, and Zilles (1999), in a cyto-architectural study, found that the position of the histological superior border of the pars opercularis and pars triangularis was variable with respect to the ventral and dorsal bank of the inferior frontal sulcus, but that this superior border never reached the free surface of the middle frontal gyrus. **In view of these findings, imaginary lines joining the segment(s) of the inferior frontal sulcus to each other and to the inferior precentral sulcus, along the natural lie of the inferior frontal sulcus, was taken as the superior border of the frontal operculum, when the inferior frontal sulcus was of the interrupted type and/ or unconnected to the inferior precentral sulcus** (see Fig 2.1 and 2.2 on pages 69 and 70)**.**

Table 2.2: The Patterns of the Inferior Frontal Sulcus (Ono, 1990)

PATTERN	**RIGHT HEMISPHERE** (rate of occurance in %)	**LEFT HEMISPHERE** (rate of occurance in %)
1. Continuous	56	40
2. Two segments	32	32
3. Three segments	8	28
4. Four segments	4	0

(b) THE POSTERIOR BOUNDARY OF THE FRONTAL OPERCULUM

The precentral sulcus as a whole may be present either as a single sulcus or as a duplicated sulcus (see Fig 2.1 and Fig 2.2 on pages 69 and 70 respectively). The single precentral sulcus is often discontinuous (see Fig 1.3 on pg 4), with the two-segment

form predominating. Ono et al (1990) report the two-segment form in 48% of right hemispheres and in 64% of left hemispheres. They also found the incidence of the double precentral sulcus to be 4% in each hemisphere. Each of the double precentral sulci may be present as either continuous sulci or as interrupted sulci (the incidence of this feature is not reported.

The findings of Amunts et al in 1999 (using an observer independent method of differentiating cytoarchitectonic areas), was used to help in resolving the status of the additional precentral sulcus. They report that the pars opercularis contained dysgranular cortex (laminae III and V tend to invade lamina IV to a variable exent) in contrast to the premotor cortex, which was agranular. From the foregoing findings, it was assumed, in the present study, that this additional sulcus physically marks off the premotor area from the pars opercularis anteriorly (see Fig 2.2 on pg 70). The additional gyrus between the precentral sulcus anterior and the precentral sulcus posterior was taken to be the premotor area. The posterior border of the pars opercularis (see Fig 2.1 on pg 69 and Fig 2.2, on pg 70) was therefore, taken to be formed by either:

- The inferior part of the single continuous (uninterrupted) precentral sulcus or by the inferior part (segment) of the interrupted single precentral sulcus.
- The inferior part, of the anterior-most, of the two precentral sulci, in the presence of a double precentral sulcus (whether or not it is interrupted).

The presence of a connection between the single precentral sulcus and the lateral fissure was found to be an inconstant (see Table 1.3 on pg 27) occurrence. Incidences for this relationship, in the case of double precentral sulci, were not quoted in the literature surveyed. **When a connection between the inferior precentral sulcus (or the inferior precentral sulcus anterior), and the lateral fissure was lacking, the posterior border of the frontal operculum was completed by means of an imaginary line joining the termination of the precentral sulcus (or the inferior precentral sulcus anterior) to the lateral fissure, along the lie of the inferior part of the precentral sulcus (or the inferior precentral sulcus anterior). See Fig 2.1 and Fig 2.2 on pages 69 and 70 respectively.**

The decision to close the posterior border of the pars opercularis in the fashion mentioned above, rather than by use of the anterior subcentral sulcus as in the study of Foundas et al (1998) was again based on the information gleaned from the cytoachitectural study of Amunts et al (1999) mentioned above. Since the anterior subcentral sulcus, when it is present, lies between the precentral sulcus and the central sulcus, it is related to either premotor or motor cortex. Use of it as a border would therefore erroneously enlarge the size of the pars opercularis.

(c) THE VENTROROSTRAL BOUNDARY OF THE FRONTAL OPERCULUM

The ventrorostral boundary tends to be either unreported or inadequately reported. Greys Anatomy (37th edition, 1989) simply states that the pars orbitalis continues round

the superciliary margin onto the orbital surface. Ono et al (1990) stated that, in their sample studied:

- A side branch of the stem of the lateral fissure, which passed into the orbital gyrus, marked the end of the pars orbitalis, when it was present (see the fissure marked by the green arrowhead in Fig 1.5 on pg 14),
- This side branch was found to be present in 56% of cases in the right hemisphere and 52% of cases in the left hemisphere,
- This side branch was found to be medial to the end of the pars orbitalis, in 0% of cases in the right hemisphere and 8% of cases in the left hemisphere. But, the border of the pars orbitalis when the side branch marker was either absent, or very medial in position, was not stated. **In the present study, part of the ventro-rostral border of the pars orbitalis was taken, provisionally, to be the above side branch of the lateral fissure when it was present, or the lateral-most branch of the orbital sulcus, when the side branch was absent.**

Since neither the side branch of the lateral fissure nor the lateral-most branch of the orbital sulcus have connections with the inferior frontal sulcus, a line joining these sulci to the inferior frontal sulcus (see Fig 2.1 and Fig 2.2 on pages 69 and 70 respectively) was used to complete the ventrorostral boundary of the frontal operculum, and hence that of the pars orbitalis.

(d) THE INFERIOR BOUNDARY OF THE FRONTAL OPERCULUM

The lateral fissure separates the frontal- and the parietal- lobes from the temporal lobe (see Fig 1.1 on pg 3). Its initial portion, the stem of the lateral fissure lies mainly on the inferior surface of the brain. The medial end of the stem is marked by ‘a line drawn between the lateral olfactory striae and the ambient gyrus’ (limen insulae), Ono et al (1990). The lateral end of the stem of the lateral fissure may end at the origin of the:

- Anterior horizontal ramus, when it occurs as a separate branch of the lateral fissure, or
- Stem of the anterior horizontal ramus and the anterior ascending ramus, when the anterior rami are joined, or
- Anterior ascending ramus when the anterior horizontal ramus is absent.

The lateral portion of the stem of the lateral fissure forms the inferior boundary of the pars orbitalis. When the anterior rami are present separately, the portion of the lateral fissure between the anterior ascending ramus and the anterior horizontal ramus marks the inferior boundary of the pars triangularis. When the anterior rami are joined to a stem, the conjoined anterior rami mark the inferior boundary of the pars triangularis [see Fig 2.1 (C and D) and Fig 2.2 (C and D) on pages 69 and 70 respectively].

The posterior ramus of the lateral fissure lies between the origin of the:

- Anterior asending ramus and the terminal ascending segment (upturned end) of the lateral fissure, when the anterior ascending ramus occurs separately.
- Stem of the anterior rami and the upturned end of the lateral fissure, when the anterior rami are joined.

The initial part of the posterior ramus of the lateral fissure was used to complete the inferior border of the pars opercularis [see Fig 2.1 (E and F) and Fig 2.2 (E and F) on pages 69 and 70 respectively), in the presence of both a single precentral sulcus and a double precentral sulcus.

(e) <u>FURTHER ON INTRA-OPERCULAR BOUNDARIES</u>

The anterior ascending ramus and the anterior horizontal ramus very rarely have connections with the inferior frontal sulcus. **Therefore, imaginary lines that connect the superior terminations of these rami to the inferior frontal sulcus, along the lie of each of the two sulci, were used to complete the boundaries between: the pars orbitalis and the pars triangularis, and that between the pars triangularis and the pars opercularis (see Fig 2.1 and Fig 2.2 on pages 69 and 70 respectively).**

2.7 PRECEEDING COMMENTS ON THE RECORDING OF DESCRIPTIVE DATA

The identification of gyri and sulci, without the aid of physiological- or cytoarchitectonic-confirmatory data (*as in the present study*), is to a large extent, dependent on pattern recognition. Constant sulci in key positions serve as landmarks for orientation and other sulci are identified and often named relative to them. It was therefore seen to be necessary to include two categories of fissures and sulci in this study. The first category served as fissures and sulci that were used for orientation purposes and included the: lateral fissure; central fissure; anterior subcentral sulcus and posterior subcentral sulcus (where present); and the postcentral sulcus. These fissures and sulci were checked for key features that would aid in their identification and contribute to the aims of this study. The second category of sulci constituted the focus of this study and included:

- The two sulci that contribute to the boundaries of the frontal operculum. These were the inferior precentral -sulcus or –sulci, and the inferior frontal sulcus.
- The major- and accessory- sulci of the frontal operculum (see section 1.1 on page 5; and Fig 1.7 on pg 15 and Fig 1.12 on pg 43).

The general criteria that were examined for each of the sulci were:

- Its presence or absence.

- Its existence as a continuous- or an interrupted- sulcus and the number of segments where applicable.
- Its shape where feasible (straight, curved, or a combination of both shapes).
- The number of branches, if present.
- The connections of the sulcus with other sulci.

The presence of a feature was recorded by means of a plus sign (+) and its total absence by a minus sign (-).

2.8 THE METHOD USED FOR RECORDING THE DESCRIPTIVE DATA IN THE PRESENT STUDY

2.8.1 IDENTIFICATION, ORIENTATION, AND PATTERN RECOGNITION OF THE FISSURES AND SULCI THAT ARE RELEVANT TO THE PRESENT STUDY

(a) The lateral fissure was the first fissure to be considered in the orientation process. It is identified as a deep constant fissure that separates the frontal- and the parietal-lobes from the temporal lobe (see Fig 1.3 on pg 4). It is primarily antero-posteriorly positioned. Its identification was confirmed by tracing its course from the origin of its stem to its last ascending branch [see section 2.6 (d) on pg 75 to 76] on the

inferior boundary of the frontal operculum], which, in this text, is referred to as the upturned end of the lateral fissure.

(b) The central fissure was the second fissure to be considered in the orientation process. It is identified as a deep constant fissure that separates the frontal lobe from the parietal lobe (Fig 2.5 on pg 88). It is antero-inferiorly directed on the superolateral surface of the cerebral hemispheres. Its identification was confirmed by: first locating the approximate midpoint between the frontal and the occipital poles of the cerebrum, and then selecting the first deep antero-inferiorly directed sulcus that was approximately one centimetre (cm) anterior to the aforementioned midpoint. An office pin was inserted into the lower end of the central fissure an aid to subsequent speedy orientation.

Since the only superiorly directed sulci that arise from or immediately above the lateral sulcus, posterior to the central sulcus, are successively the (Ono, 1990): small inconstant posterior subcentral sulcus, the long constant post-central sulcus, and the short upturned end of the posterior ramus of the lateral sulcus, the identification of the central sulcus was confirmed by checking against these sulci.

The small inconstant anterior subcentral sulcus may be located between the central sulcus and the inferior precentral sulcus. The anterior- and posterior- subcentral sulci were only considered as being separate from the central sulcus if they were not aligned with its general disposition (see Fig 2.3 on pg 82).

(c) The postcentral sulcus (see Fig 2.6 on pg 88) was the third sulcus considered in the orientation process. This sulcus is more or less parallel to the central fissure. It is identified as the first:

- Deep, constant sulcus (either continuous or interrupted), that is located posterior to the central fissure, and anterior to the superiorly directed part of the termination (of the posterior ramus) of the lateral sulcus,
- That extends between the lateral- and the longitudinal- fissures (note that the longitudinal fissure separates the two cerebral hemispheres in the sagittal plane).

(d) The inferior frontal sulcus was the first boundary sulcus to be considered. It is the first horizontally disposed sulcus that is both superior to, and roughly parallel to the lateral sulcus for most of its course [see section 2.6 (a) on pages 68 and 71, on the superior boundary of the frontal operculum; and Fig 1.3 on pg 4]. It was verified by checking against the superior frontal sulcus, and the intermediate frontal sulcus where necessary (see section 1.4 on pg 12).

In the current study, the posterior extremity of the inferior frontal sulcus, whether free or connected to the precentral sulcus, was taken to be the origin of the inferior frontal sulcus. The branches of the inferior frontal sulcus were recorded as such only when they deviated away from the general lie of the inferior frontal sulcus.

(e) The inferior precentral sulcus was the next boundary sulcus to be considered. The following two scenarios were expected:

- The existence of a single precentral sulcus between the anterior rami and the central sulcus, with or without an opercular (diagonal) sulcus intervening between the anterior ascending ramus and the inferior precentral sulcus (see Fig 2.1 on pg 69).
- The existence of a double precentral sulcus between the anterior rami and the central sulcus, with or without an opercular (diagonal) sulcus intervening between the anterior ascending ramus and the inferior precentral sulcus anterior (see Fig 2.2 on pg 70).

The following steps were followed in order to distinguish between the two situations described above:

STEP 1: A precentral sulcus was identified as:

- The first deep sulcus anterior to and parallel to the central fissure [see section 2.6 (b) on pages 71 to73; and Fig 2.1 and Fig 2.2 on pages 69 and 70 respectively, on the posterior boundary of the frontal operculum),
- That extends between the lateral fissure and the longitudinal fissure.

STEP 2: The frontal operculum was scanned in order to identify the anterior rami [see section 2.8.1 (f) on pages 83 to 86].

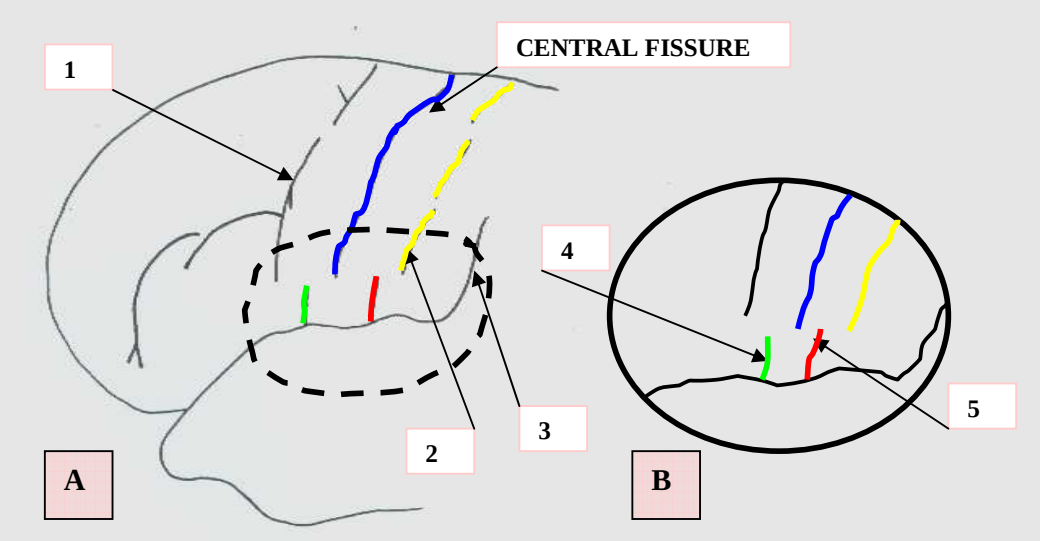

Figure 2.3 An aid to pattern recognition in the parietal operculum. In diagram A note that the central fissure (blue) lies between the precentral sulcus (1) anteriorly, and the post central sulcus (2) posteriorly. The identification of the central fissure is confirmed by (a) locating the upturned end of the lateral fissure (3), and (b) then locating the (2) anterior to it, and (c) locating the next deep sulcus parallel and anterior to (2), which is the central sulcus. In diagram B (the selected area in diagram A) note that the anterior subcentral (4)- and posterior subcentral (5)- sulci are not aligned with the natural lie of the central fissure.

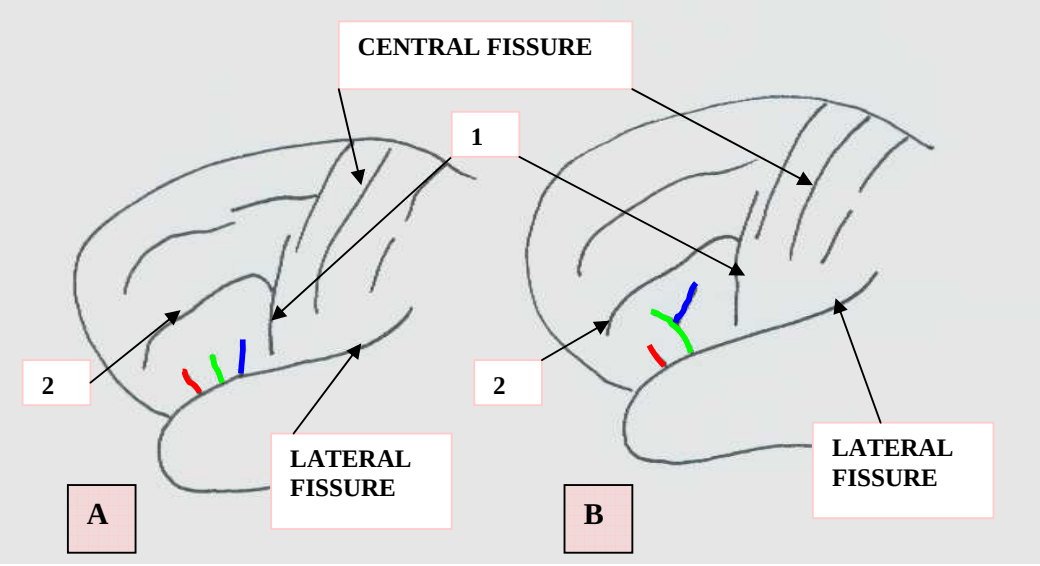

Figure 2.4 An aid to pattern resolution in the frontal operculum. Note that the inferior part of the precentral sulcus (1) is anterior to the central fissure. In diagram A, the three rami inferior to the inferior frontal sulcus (2) and anterior to (1), from anterior to posterior, are: the anterior horizontal ramus (AHR, red), the anterior ascending ramus (AAR, green), the opercular sulcus (diagonal, blue). In diagram B, note that although a 'Y' pattern can be observed, this does not represent a 'Y' pattern of the anterior rami of the lateral fissure because the AHR (red) exists. The sulcus that approaches and joins the AAR from posteriorly, is thus the opercular sulcus (blue).

STEP 3: If no other long sulcus (either continuous or interrupted) was identified between the anterior rami and the proposed precentral sulcus, then it was concluded that the situation of a sole precentral sulcus pertained (see Fig. 2.1 on pg 69). If another long sulcus, either continuous or interrupted (that extended between the lateral fissure and longitudinal fissure) was identified between the anterior rami and the proposed precentral sulcus, then it was concluded that the situation of a double precentral sulcus pertained (see Fig. 2.2 on pg 70).

Note that the key confirming feature for the identification of the additional precentral sulcus was the counting of the relevant sulci from posterior to anterior: firstly the upturned end of lateral fissure; followed by the postcentral sulcus; and then the central fissure; and lastly the sole precentral sulcus or the double precentral sulci.

(f) Resolution of the relationship of the major- and accessory- sulci of the frontal operculum to each other.

i. The anterior ascending ramus is a major sulcus of the frontal operculum. It is identified, by being:

- Anterior to the single precentral sulcus or, anterior to the inferior precentral sulcus anterior (in the presence of a double precentral sulcus) [see Fig 1.7 on pg 15, Fig 2.1(A, B) on pg 69 and Fig 2.2 (A, B) on pg 70 as well as section 1.6, pages 17 to 19], as:
    - The sole anterior ramus of the lateral fissure, or

- The posterior of two separate anterior rami of the lateral fissure, or
- The posterior of two anterior rami arising from a common stem (forming a 'Y' shaped pattern[8]), which in turn is a branch of the lateral fissure.

- A deep branch of the lateral fissure that has continuity with the circular sulcus of the insula.

The inconstant sulcus (sulci) of the pars opercularis may intervene between the anterior ascending ramus and the inferior precentral sulcus. The joining of this opercular sulcus to the posterior aspect of the anterior ascending ramus may also give rise to a 'Y' shaped pattern (see Fig 2.4 on pg 82). In the event of this occurring, the position of the opercular sulcus, as well as the presence and position of the anterior horizontal ramus, was used to help to confirm the identification of the anterior ascending ramus.

In the event of three rami arising from the lateral fissure anterior to the inferior precentral sulcus, in the present study (see Fig 2.4 on pg 82); the following criteria were descided upon:

- The posterior most branch was taken to be an opercular sulcus arising from the posterior ramus of the lateral fissure,

[8] If the 'walls of the stem' were widely separated, and its height low, an attempt was made to gently appose the two walls. If this manipulation failed to appose the 'walls of the stem,' it was concluded that the separation was due to an extension of the LF and that a true stem did not exist.

- The intermediate branch was taken to be the anterior ascending ramus, and
- The anterior-most branch was taken to be the anterior horizontal ramus

In the event of the sulcus anterior to the inferior precentral sulcus making a pseudo (shallow) connection rather than a true (deep) connection with the lateral fissure (Ono et al, 1990), the sulcus was taken, in the present study, to be an opercular sulcus rather than the anterior ascending ramus.

The anterior ascending ramus was taken, in the present study, to be absent when a sole anterior ramus arose further anteriorly, from the lateral fissure, close to the expected position of the anterior horizontal ramus [see Fig 1.10C (diagram on the right) on pg 35].

ii. The anterior horizontal ramus is a major sulcus of the frontal operculum (see Fig 1.7 on pg 15 and section 1.6 on pages 17 to 19). It is identified, by being:

- Anterior to the anterior ascending ramus as:
    - The sole anterior ramus of the lateral fissure, or
    - The anterior of two separate anterior rami of the lateral fissure, or
    - The anterior of two anterior rami that arise from a common stem (which forms a 'Y' shaped pattern). The stem in turn, arises from the lateral fissure.

- As a deep branch of the lateral fissure, that has continuity with the circular sulcus of the insula.

The anterior horizontal ramus, in the present study, was taken to be absent when a sole anterior ramus arose further posteriorly, from the lateral fissure, close to the expected position of the anterior ascending ramus [see Fig 1.10C (diagram on the right) on pg 35].

iii. The opercular sulcus is an accessory sulcus and may be identified within the pars opercularis [see Fig 1.12 (D, E, F) on pg 43], either as a free sulcus or attached to an adjacent sulcus (see section 1.8.3 on pg 41 to 45). In the event of an additional sulcus occurring, in the present study, at the same vertical level as the anterior ascending ramus, it was recorded as an inferior branch of the inferior frontal sulcus and not as an opercular sulcus.

iv. The triangular sulcus is an accessory sulcus and may be identified within the pars triangularis, attached to the inferior frontal sulcus [see section 1.8.4 on pg 45 and Fig 1.12 (B and C) on pg 43]. In the event of an additional sulcus occurring, in the present study, at the same vertical level as either the anterior ascending or the anterior horizontal ramus, it was recorded as an inferior branch of the inferior frontal sulcus, and not as a triangular sulcus.

2.8.2 FEATURES OF THE RELEVANT FISSURES AND SULCI THAT WERE CONSIDERED PERTINENT TO THE PRESENT STUDY

(a) FEATURES EXAMINED FOR THE CENTRAL FISSURE

i. The pattern of the central fissure as a whole (see Fig 2.5A on pg 88):

- Its presence as a continuous- or as an interrupted- sulcus
- The number of segments in the event of an interrupted sulcus

ii. The shape of the inferior end of the central fissure (see Fig 2.5 B-D on pg 88):

- Straight
- 'Y' (inverted)
- 'T' (inverted)
- Any other

iii. The connections of the inferior end of the central fissure (at and below the level of the inferior frontal sulcus), with, see Fig 2.5A-D on pg 88:

- The Lateral Fissure
- Any other sulcus

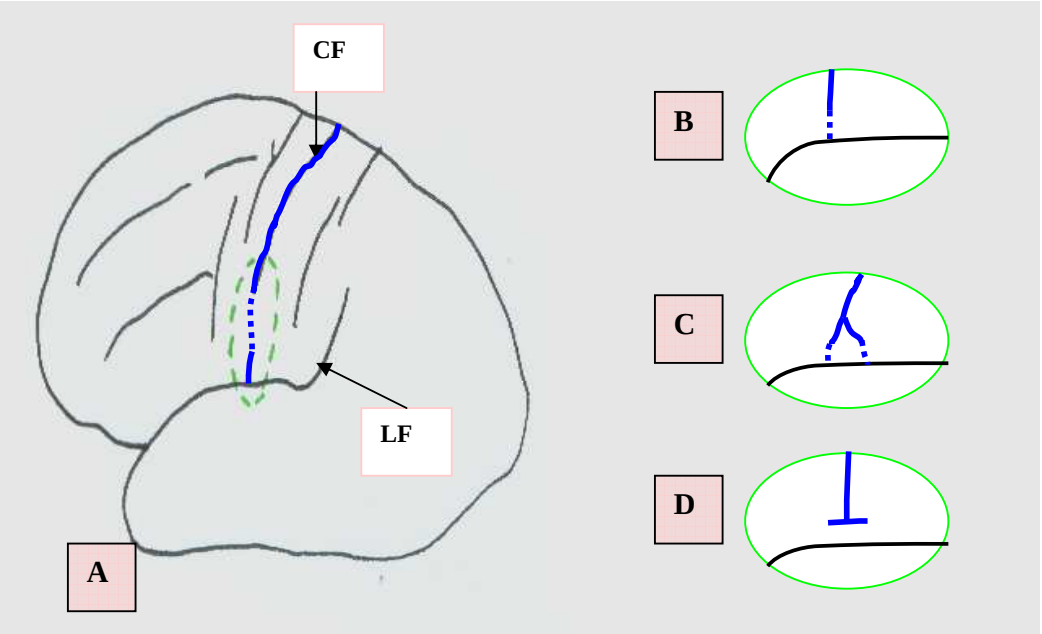

Figure 2.5 Features of the central fissure (CF). In diagram A the dashed blue line indicates that the CF may or may not be interrupted into segments. The area selected in green in Diagram A has been expanded in diagrams B-D, which depict possible shapes of the termination of the CF, whether or not there is a connection with the lateral fissure (LF), [straight end (B), 'Y' shaped end – inverted (C), and 'T' shaped end- inverted (D).

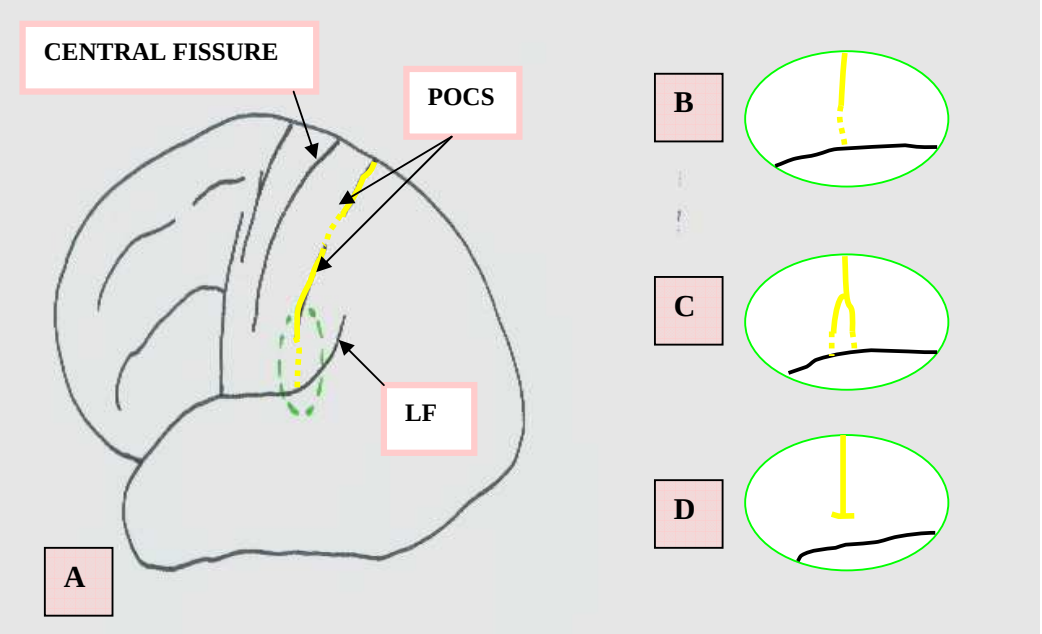

Figure 2.6 Features of the postcentral sulcus (POCS). In diagram A the interruptions in the yellow line indicate that the POCS may be interrupted; and may not have a connection with the lateral fissure (LF). The area selected in green in Diagram A has been expanded in diagrams B-D, which depict possible shapes of the termination of the CF, whether or not there is a connection with the LF [straight end (B); 'Y' shaped end (C), and 'T' shaped end (D), both inverted].

iv. The presence of an anterior subcentral sulcus (asc), posterior subcentral sulcus (psc), or both (a/psc). See Fig 2.3 (A, B) on pg 82.

(b) <u>FEATURES EXAMINED FOR THE POSTCENTRAL SULCUS</u>

i. The pattern of the postcentral sulcus as a whole [see Fig 2.6(A) on pg 88]:

- Its presence as a continuous- or as an interrupted- sulcus
- The number of segments in the event of an interrupted sulcus

ii. The shape of the inferior end of the postcentral sulcus [see Fig 2.6 (B-D) on pg 88]:

- Straight
- 'Y' (inverted)
- 'T' (inverted)
- Any other

iii. The connections of the inferior end of the postcentral sulcus (at and below the level of the inferior frontal sulcus), with, see Fig 2.6 (A-D) on pg 88:

- The Lateral Fissure
- Any other sulcus

(c) <u>FEATURES EXAMINED FOR THE PRECENTRAL SULCUS</u>

i. The pattern of the precentral sulcus as a whole (see Figs 2.1 and 2.2 on pg 69 and 70 respectively):

- Its presence as a single sulcus or as a double sulcus
- Its / their presence as a continuous sulcus or as an interrupted sulcus
- The number of segments in the event of an interrupted sulcus or sulci

ii. The shape of the inferior end of the precentral sulcus [as for the central fissure, Fig 2.5 (B, C and D) on pg 88]:

- Straight
- 'Y' (inverted)
- Any other

iii. The connections of the inferior end of the precentral sulcus, at and below the level of the inferior frontal sulcus, with (see Fig 2.1 and Fig 2.2 on pages 69 and 70 respectively):

- The Lateral Fissure
- Any other sulcus or fissure

(d) <u>FEATURES EXAMINED FOR THE INFERIOR FRONTAL SULCUS</u>

i. The pattern of the inferior frontal sulcus as a whole [see Figs 2.1 and Fig 2.2 on pages 69 and 70 respectively as well as Fig 2.3 (A) on pg 82]:

- Its presence as a continuous- or as an interrupted- sulcus
- The number of segments in the event of an interrupted sulcus

ii. Connections of the inferior frontal sulcus with (see Fig 2.1 and Fig 2.2 on pages 69 and 70 respectively):

- The inferior precentral sulcus (or inferior precentral sulcus anterior)
- Any other sulcus

iii. Branches of the inferior frontal sulcus into the frontal operculum (see Fig 1.12 on pg 43):

- The total number of inferior branches
- The occurrence of an opercular sulcus as a branch
- The occurrence of a triangular sulcus as a branch

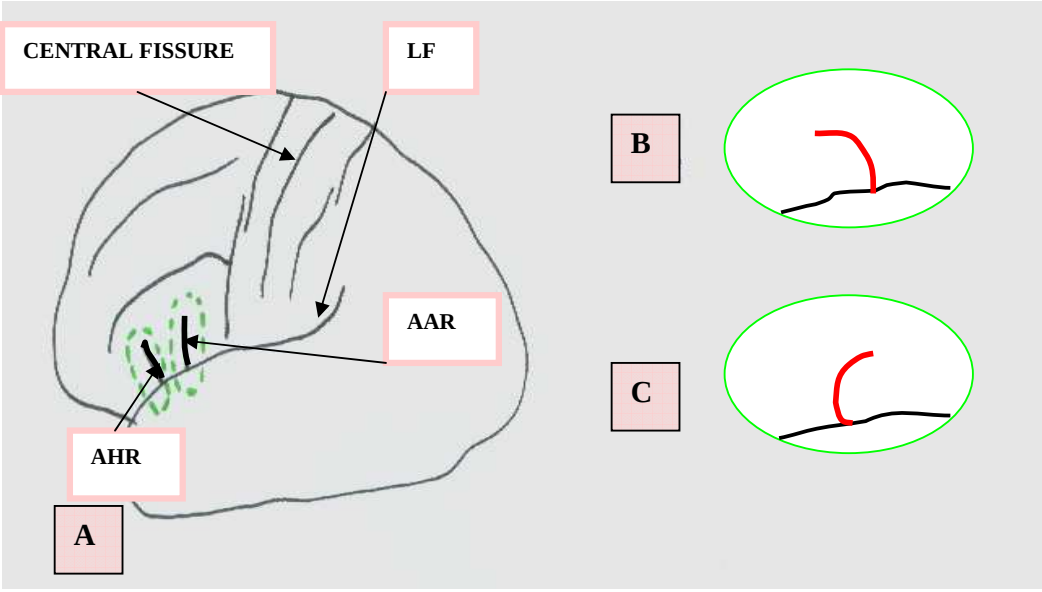

Figure 2.7 Shape and direction of the anterior rami of the lateral fissure (LF). Note that the straight shapes of both the anterior ascending (AAR)-, and anterior horizontal (AHR)- rami of the LF, are depicted in diagram A. The AAR and the AHR are selected in the same colour in diagram A, because the shapes in the expanded view in diagrams B and C are applicable to both sulci. Diagram B demonstrates concave anteriorly, and diagram C demonstrates concave posteriorly.

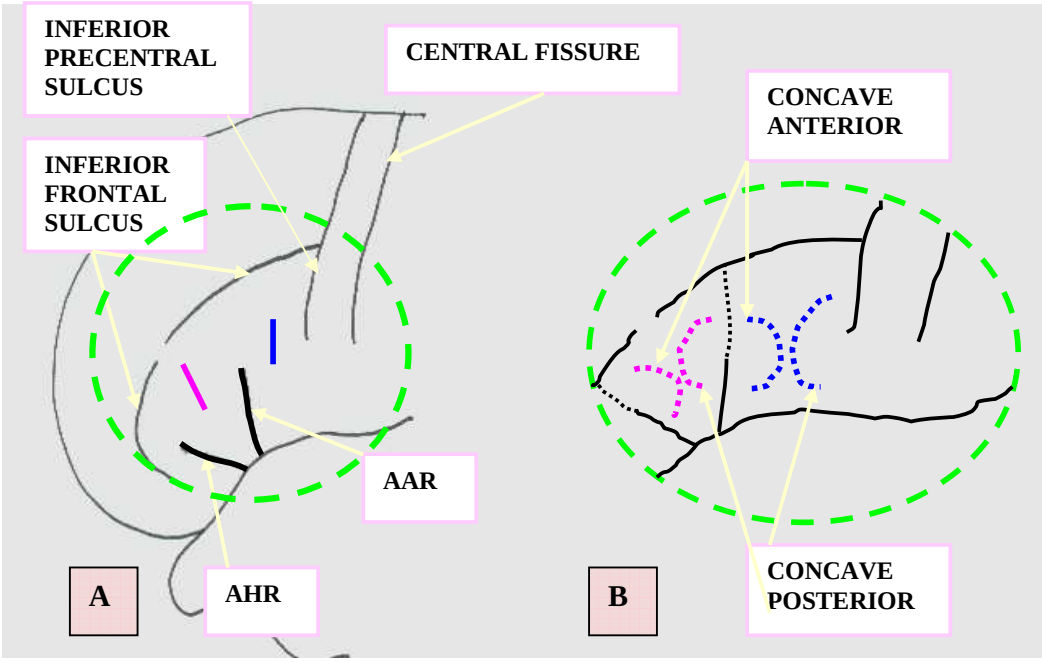

Figure 2.8 Shape and direction of the accessory sulci. In diagram A: the straight shape of the triangular sulcus (purple); and that of the opercular sulcus (blue) is demonstrated. Note that both sulci are shown unconnected to other sulci (free in the frontal operculum). The anterior rami are the: anterior ascending (AAR) and the anterior horizontal (AHR). The selected area in diagram A is expanded in diagram B to demonstrate the concave anterior, and the concave posterior, shape and direction of the triangular and opercular sulci (also free in this case).

(e) FEATURES EXAMINED FOR THE ANTERIOR ASCENDING RAMUS

i. The pattern of the anterior ascending ramus [see Fig 1.7 on pg 15 and 1.9 E on pg 24]:

- Its presence or absence

ii. The shape and direction of the anterior ascending ramus (see Fig 2.7 on pg 92):

- Straight
- Curved:
    - Concave anteriorly
    - Concave posteriorly
- Any other

iii. Connections of the anterior ascending ramus with the [see Fig 1.7 (B) on pg 15, Fig 1.12 on pg 43, and Fig 2.8 (B) on pg 92]:

- Stem (of the anterior ascending- and anterior horizontal rami)
- Lateral fissure
- Inferior frontal sulcus
- Opercular sulcus
- Any other sulcus

(f) FEATURES EXAMINED FOR THE ANTERIOR HORIZONTAL RAMUS

i. The pattern and location of the anterior horizontal ramus (see Fig 1.7 on pg 15):

- Its presence or absence
- When present, its location:
    - On the lateral surface of the frontal operculum
    - At the orbital margin of the frontal lobe
    - On the orbital surface of the frontal lobe

ii. The shape and direction of the anterior horizontal ramus (see Fig 2.7 on pg 92):

- Straight
- Curved:
    - Concave anteriorly
    - Concave posteriorly
- Any other

iii. Connections of the anterior horizontal ramus with the (see Fig 1.7 on pg 15):

- Stem (of the anterior ascending- and anterior horizontal rami)
- Lateral fissure

- Inferior frontal sulcus
- Any other sulcus

(g) <u>FEATURES EXAMINED FOR THE OPERCULAR SULCUS OR SULCI</u>

i. The pattern of the opercular sulcus (see Fig 1.12 on pg 43):

- Its presence (single or otherwise), or absence

ii. The shape and direction of the opercular sulcus (see Fig 2.8 on pg 92):

- Straight
- Curved:
  - Concave anteriorly
  - Concave posteriorly
- Any other

iii. Connections of the opercular sulcus with the [see Fig 1.12 (D, E, and F) on pg 43 and Fig 2.8 on pg 92]:

- Lateral fissure
- Anterior ascending ramus
- Inferior frontal sulcus
- No other sulcus (Free in the pars opercularis)

- Any other sulcus

(h) <u>FEATURES EXAMINED FOR THE TRIANGULAR SULCUS OR SULCI</u>

i. The pattern of the triangular sulcus (see Fig 1.12 on pg 43 and Fig 2.8 on pg 92):

- Its presence (single or otherwise) or absence

ii. The shape and direction of the triangular sulcus (see Fig 2.8 on pg 92):

- Straight
- Curved:
    - Concave anteriorly
    - Concave posteriorly
- Any other

iii. Connections of the triangular sulcus with the [see Fig 1.12 (B, C) on pg 43 and Fig 2.8 on pg 92]:

- Inferior frontal sulcus
- No other sulcus (Free in the pars triangularis)
- Any other sulcus

2.9 THE DIRECT METHOD USED FOR THE RECORDING OF SULCAL LENGTHS IN THE PRESENT STUDY (QUANTITATIVE DATA)

Note that the procedure for the measurement of sulcal lengths was the result of an exploration of various techniques of measuring sulcal lengths (see section 3.1.2 on pages 121 to 127, on the route to the measurement of choice). The procedure is as as follows:

(a) THE STABILISATION OF THE SPECIMEN

The specimen was always stabilised such that the sulcus to be measured, was as perpendicular to the eye as possible.

(b) THE CONVENTION USED FOR DETERMINING THE ORIGINS OF SULCI:

- The origin of sulci arising from the lateral sulcus, was guided by the abutting temporal operculum (when present). The point at which the sulcal walls began to diverge into the lateral fissure marked the actual origin of such sulci.
- The origins of sulci arising from other sulci were marked, by the inferor-most point at which the walls of the sulcus (being measured) began to diverge from the parent sulcus.

- The origins of free sulci (sulci that were unattached to other sulci) was marked by the inferior- most point at which the sulcal walls began to diverge from each other.

(c) <u>THE CONVENTION USED IN DETERMINING THE TERMINATIONS OF SULCI</u>:

- The last point where two parallel adjacent sulcal walls were observed was taken to be the termination of the sulcus.
- If a vascular furrow prolonged a sulcus, it was not measured.

(d) <u>THE PROCEDURE FOR MEASURING SULCAL LENGTHS</u>:

- **<u>STEP 1</u>:** The surface of the brain was dried with paper towel. This prevented the threads (used for measuring) from getting wet. The origin of the sulcus concerned was determined according to the criteria set out in section 2.9 (b) on page 97 [see Fig 2.9 (a) on pg 99].

- **<u>STEP 2</u>:** A length of thread (with a needle already threaded onto it) was marked as indicated in Fig 2.9 (b) on page 99.

- **<u>STEP 3</u>:** The thread was drawn through a needle such that the marked point was located inside the eye of the needle [see Fig 2.9 (c) on pg 99].

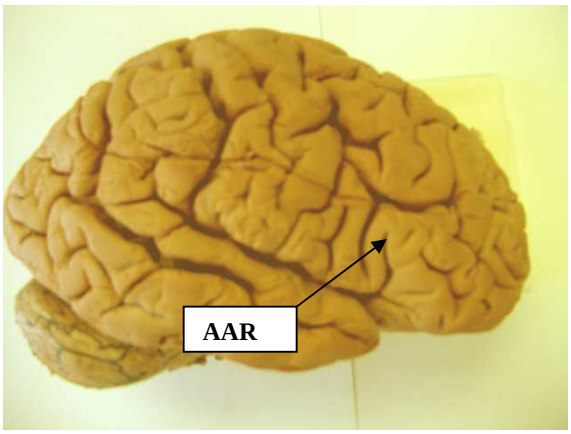

Figure 2.9 (a) Locating the origin of a sulcus [see section 2.9 (b)].

The anterior ascending ramus, (AAR) was the chosen sulcus for the demonsration of the method. The origin of this sulcus was located by:

- **(i) following it inferiorly until the lateral fissure, and**
- **(ii) noting the point at which the sulcal walls began to diverge from each other**



Figure 2.9 (b) Marking of the thread.

Note that a small black dot was marked onto the thread (black arrow).



Figure 2.9 (c) Thread manipulation

Note that the needle was drawn through the thread until the small black dot, seen in Fig 2.9 (b), was no longer visible. This is because it is now located in the eye of the needle.

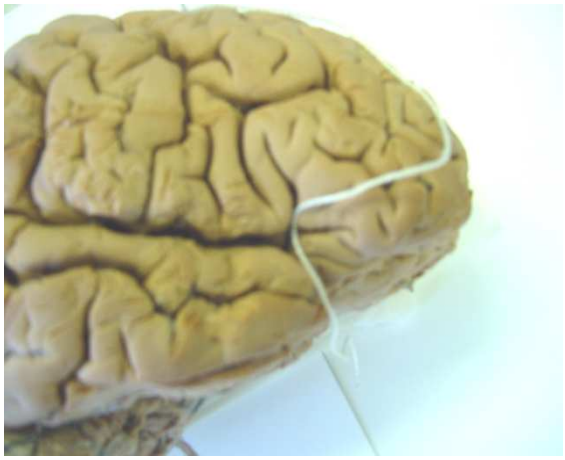

Figure 2.9 (d) Needle insertion

The needle was inserted into the origin of the AAR until the eye of the needle was level to the sulcus. This meant that the black dot mentioned in Figure 2.9 (b) on pg 99, was as close to the actual origin as possible. Note that the long part of the thread was facing superiorly



Figure 2.9 (e) Pin insertion

The thread was moulded along the course of the sulcus. An office pin was inserted into the termination of the sulcus [see section 2.9 (c) on pg 98].

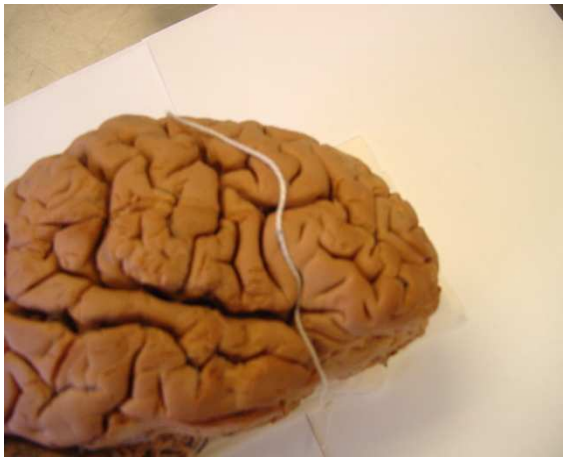

Figure 2.9 (f) Marking the termination of the sulcus.

A second black dot was added to the thread where it passed over the office pin mentioned in Figure 2.9 (e). Note that the terminatons of sulci tend to be more superior than the origins. The needle was removed from the brain. The thread was then snipped away from both black dots.



Figure 2.9 (g) Filing of the thread

Note that the measured length was carefully arranged onto a straight line. The name of the sulcus, the hemisphere, and the specimen number was added to the sheet. The length could now be read straight off a ruler.



Figure 2.10 (a) Placement of pins for the measuring of intersulcal distances in the frontoparietal operculum. The first pin was inserted into the termination of the anterior ascending ramus (black arrow). A ruler was ased to get a line as parallel as possible to the horizontal portion of the frontoparietal operculum (blue arrows). Pins were then inserted into the relevant sulci [see section 2.10 (a) ii, STEP 3, on page 104] at the same horizontal level. Note that the pins are parallel to each other.

- **STEP 4:** The needle was inserted into the origin of the sulcus, with the short end of the thread facing away from the sulcus to be measured, until the eye of the needle was resting on the origin of the sulcus to be measured [see Fig 2.9 (d) on pg 100].

- **STEP 5:** The thread was moulded over the course of the sulcus [see Fig 2.9 (e) on pg 100].

- **STEP 6:** An office pin was inserted into the termination of the sulcus [see Fig 2.9 (f) on pg 100]. Note the termination of the sulcus was determined according to the criteria set out in section 2.9 (c) on page 98.

- **STEP 7:** The thread was marked as it passed over the centre of the head of the office pin [see Fig 2.9 (f), on pg 100].

- **STEP 8:** The thread was then snipped beyond the second mark, and arranged onto a line, on a page of lined blue notepaper, without undue tension. It was taped into this position on its line using magic tape. The points marked on the thread were immediately remarked on the magic tape (immediately below the original mark), so that any shrinkage of the thread would be noticed [see Fig 2.9 (g), on pg 101]. An appropriate label was inserted below the thread.

- **STEP 9:** A second recording was taken a minimum of two days later and pasted next to the first recording. If necessary, a third recording was taken, and the two closest recordings were retained.

- **STEP 10:** As the threads were already pasted onto a straight line, the sulcal lengths were read directly off a ruler, to the closest half a millimetre. Since it was thought that the true lengths of the sulci was somewhere between the two readings, the average of the two recordings was taken as the final length for each sulcus.

2.10 THE METHOD USED FOR THE RECORDING OF INTERSULCAL LENGTHS IN THE PRESENT STUDY (QUANTITATIVE DATA)

(a) THE MEASUREMENT OF INTERSULCAL LENGTHS POSTERIOR TO THE ANTERIOR ASCENDING RAMUS

i. STABILISATION OF THE SPECIMEN

The specimen was stabilised such that the frontoparietal operculum was more or less perpendicular to the eye.

ii. THE STEPS TAKEN WHEN MEASURING THE INTERSULCAL DISTANCES [see Fig 2.10 (a, b) on pages 101 and 105 respectively]

- **STEP 1:** An office pin was inserted into the termination of the

anterior ascending ramus. It was ensured that the pin was upright.

- **STEP 2:** A ruler was used to get a line as parallel as possible to the straight portion of the posterior ramus of the lateral sulcus.

- **STEP 3:** At the horizontal level where the ruler crossed the sulci, pins were successively inserted into the:

    - Opercular sulcus (sulci) when present at this level,
    - Central fissure, and
    - Postcentral sulcus, see Fig 2.10 (a) on page 101.

  It was ensured that all the pins were parallel to each other.

- **STEP 4:** A ruler was positioned such that the zero point coincided with the pin in the postcentral sulcus. The ruler also touched the pin in the termination of the anterior ascending ramus [see Fig 2.10 (b) on page 105].

- **STEP 5:** With the head held directly above the ruler, the straight line distance between:

    - The pin in the central fissure and the pin in the inferior postcentral sulcus,
    - The pin in the inferior precentral sulcus and the pin in the central fissure,



Figure 2.10 (b) Measurement in the frontoparietal operculum (2). A ruler was held perpendicular to the pins. The zero point of the millimetre marker was positioned just above the pin in the postcentral sulcus. The ruler was then aligned with the other pins as shown in the picture. The intersulcal lengths were then read straight off the ruler.

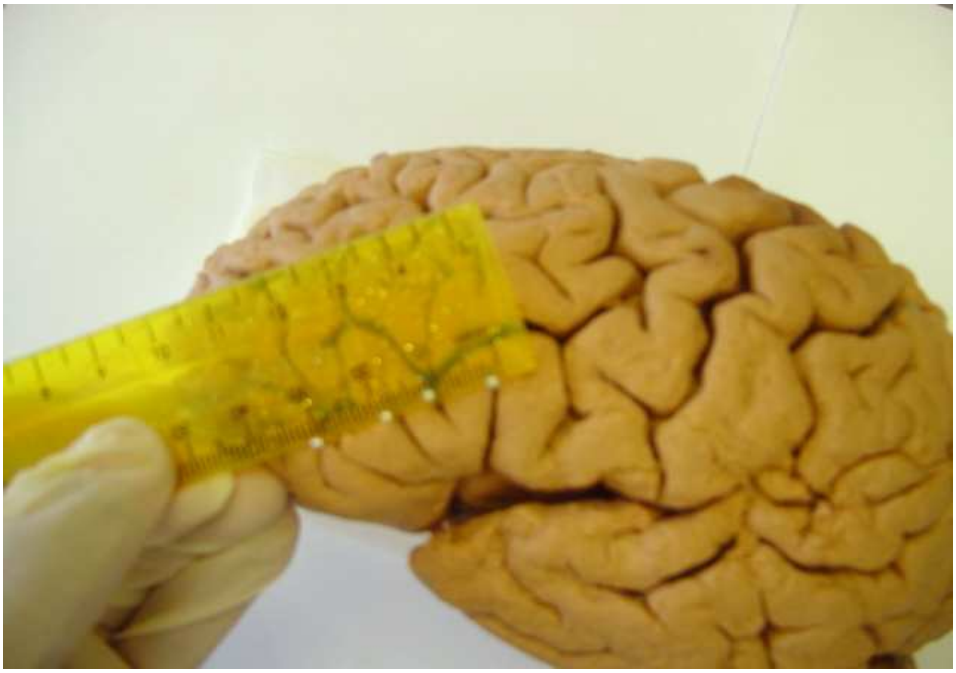

Figure 2.10 (c) Measurement in the pars triangularis. All pins in the frontoparietal operculum except that in the termination of the anterior ascending ramus were removed. A pin was inserted into the termination of the anterior horizontal ramus. A ruler was placed between the two pins and additional pins placed in the triangular sulcus (sulci) at the same horizontal level, as shown in the picture. The intersulcal lengths were then read straight off the ruler.

- The pin in the termination of the anterior ascending ramus and and the pin in the inferior precentral sulcus, and
- The pin in the termination of the anterior ascending and the pin(s) in the opercular sulcus (sulci), if present at this level, was read off the ruler, to the closest half a millimetre,

see Fig 2.10 (b) on pg 105.

- **STEP 3**: A second recording was taken a minimum of two days later.

(b) THE MEASUREMENT OF INTERSULCAL LENGTHS ANTERIOR TO THE ANTERIOR ASCENDING RAMUS

i. STABILISATION OF THE SPECIMEN

The specimen was stabilised such that the frontal operculum was as perpendicular to the eye as possible.

ii. THE STEPS TAKEN WHEN MEASURING THE INTERSULCAL DISTANCES [see Fig 2.10 (c) on page 105]

- **STEP 1:** An office pin was inserted into the termination of the anterior ascending ramus. It was ensured that the pin was upright.

- **STEP 2:** A second pin was inserted into the termination of the anterior horizontal ramus. It was ensured that the pin was both

upright and parallel to the pin in the termination of the anterior ascending ramus.

- **STEP 3:** A ruler was brought up to meet the two pins, in the plane of the specimen and perpendicular to the pins. At this horizontal level, pins were inserted into the triangular – sulcus or –sulci [see Fig 2.10 (c) on pg 105].

- **STEP 4:** A ruler was positioned such that the zero point coincided with the pin in the termination of the anterior ascending ramus. The ruler also touched the pin in the termination of the anterior horizontal ramus.

- **STEP 5:** With the head held directly above the ruler, the straight line distance between:

    - The pins in the terminations of the anterior ascending and anterior horizontal rami,
    - The pin in the termination of the anterior ascending ramus and and the pin(s) in the triangular sulcus (sulci), was read off the ruler, to the closest half a millimetre.

- **STEP 6:** A second recording was taken a minimum of two days later.

2.11 LESS DIRECT METHODS EXAMINED, FOR OBTAINING QUANTITATIVE DATA

2.11.1 DATA RECOVERY FROM PHOTOGRAPHS THROUGH USE OF PHOTOGRAPHIC NEGATIVES

Three separate cerebral hemispheres were selected and photographed together with a centimetre marker that was placed at the same level as the surface on which the specimen rested (table level). The negatives were then taped onto the stage of a magnifier. The knobs (for altering magnification) were adjusted until the centimetre marker read as close as possible to one centimetre.

The intension was: to make a tracing of the relevant sulci, from the negatives, once the 1:1 magnification was achieved; and to then measure the relevant sulcal- and intersulcal-lengths (from the tracing), by the use of an image analyser (THE VIDEOPLAN, IMAGE ANALYSIS SYSTEMS (KONTRON BILDANALYSE), 1988.

2.11.2 DATA RECOVERY FROM PHOTOGRAPHS THROUGH USE OF PRINTED IMAGES

A digital camera was fixed at a constant height from the surface on which each of the specimens selected in 2.11.1 were to be placed. The supero-lateral surfaces of all three

specimens where photographed from the same spot together with a centimetre marker placed at table level.

At the time of photography, it was noticed that that due to the: curvatures (antero-posterior and left-right); as well as the gradual tapering of the frontal lobe towards the frontal pole, different points on the specimen, even in the frontal operculum, were at slightly different heights from the camera. In order to explore the effect of this feature on the measurement of lengths, four threads of equal length were placed on one specimen, and then photographed.

2.11.3 DATA RECOVERY FROM PEN TRACINGS OF THE SURFACE FISSURES AND SULCI

A square sheet of ordinary plastic cling-wrap[9] was placed over the supero-lateral surface of the frontal lobe. The lower edge was tucked neatly into the lateral fissure. The plastic was carefully adjusted and moulded over the gyri. When a satisfactory fit was obtained, a permanent marker (Artline 750) was used to trace out the sulci.

The plastic was then removed, taped onto a blank sheet of paper, and labelled. This meant that the tracings were already represented on a flat sheet, and at a magnification of 1:1. It was thought feasible to use the image analyser mentioned in section 2.11.1 to measure the

[9] Purchased at the local supermarket

traced sulcal- and intersulcal- lengths. In a trial run, the tracing was fixed to a digitising tablet, and the data was acquired by, clicking and dragging a crosshair cursor from the origin to the end of a sulcus.

2.11.4 DATA RECOVERY THROUGH USE OF THE MICROSCRIBE DIGITISER

This device (MICROSCRIBE 3D, IN RHINO, IMERSION COORPORATION) has a mechanical arm, to which a digitising pen is attached. A point on a surface can be recorded by exerting sufficient pressure on the pen tip to produce a click. The three -dimensional coordinates of such a point is then stored in the Rhino software program. The strength of the program is that it has the ability to collate the digitised points and render these into a digital model. After this process, the option to measure could be used to yield readings for lengths as well as surface area. The soft surface of the brain was expected to present a problem for the recording of points. No attempt was made to resolve this problem since the above method was abandoned [see section 3.1.2.2 (a) iv, on pg 126].

2.12 METHODS USED FOR ANALYSING DATA

2.12.1 METHODS USED FOR ANALYSING DESCRIPTIVE DATA

(a) The analysis of the descriptive data revolved around:

- The calculation of percentage incidences for the occurrence of the relevant features of the sulci examined (for ungrouped data); and

- Inter-hemispheric comparisons of the frequencies of the occurrences of:

    (i) The four Types Connections of Ebeling (grouped data), with respect to the categories of case and control, and

    (ii) The three Patterns of the Anterior Rami (grouped data), with respect to the categories of case and control.

(b) The chi square test (Levin and Rubin, 1980) was applied because:

- The analysis involved a comparison of the proportions of the frequencies with which: the four Types of Ebeling; and the three Patterns of the Anterior Rami, occurred in the right and left cerebral hemispheres.

- The descriptive data could be classified into several categories: four types with respect to two attributes (right and left hemisphere); and three patterns with respect to two attributes (right and left hemisphere).

2.12.2 METHODS USED FOR ANALYSING QUANTITATIVE DATA

(a) The analysis of the quantitative data revolved around the inter-hemispheric comparisons of the means of sulcal lengths for ungrouped- and grouped- data, with respect to the categories of case and control.

(b) In the case of data prior to classfication into either Types of Sulcal Connections or Patterns of the Anterior Rami **(ungrouped data)**, the following were calculated (for both case and control groups in each hemisphere:

- The means of the lengths of individual major- and accessory- sulci (each sulcus was considered separately), in the right cerebral hemisphere, and
- The means of the lengths of individual major- and accessory- sulci (each sulcus was considered separately), in the left cerebral hemisphere, as well as
- The coefficient of variation (ratio of population standard deviation to mean, expressed as a percentage) for the lengths of each relevant sulcus, in the right hemisphere and in the left hemisphere.

The Shapiro-Wilk test for assessing the normality of data, was applied to selected data sets (see Table 3.59 on pg 217) from the tables in Appendix E (see pages 314 to 337). The W-values were calculated by programming the formula into the *Microsoft Excel* (2000) computer program (see appendix **I**, pg 394 to 395). After confirming that the selected data sets were normally distributed, the *Student t-test* was applied since the

analysis involved a comparison of means. The *Microsoft Excel* computer program, mentioned above, was used again.

(c) In the case of data that had been grouped into Types of Connection and Patterns of the Anterior Rami **(grouped data)**, the following were calculated for both the case and control groups:

- The means of the lengths of each relevant *individual* sulcus, in the right cerebral hemispheres,
- The means of the lengths of each relevant *individual* sulcus, in the left cerebral hemispheres
- The coefficient of variation (cv) for the mean lengths of each relevant sulcus in both hemispheres.

Selected data sets (see Tables 3.60, 3.61, 3.62, pages 217 and 218) from the tables of Appendix F (see pages 338 to 348) and Appendix G (see pages 349 to 360) were subjected to inter-hemispheric comparison, by means of the *Student's t-test* as for the ungrouped data.

3. RESULTS

3.1 REPORT ON THE METHODS USED TO ACQUIRE DATA IN THE PRESENT STUDY

3.1.1 REPORT ON THE DESCRIPTIVE METHODS USED IN THE PRESENT STUDY

The recognition of the connections and the patterns of sulci (and fissures) involve personal decision-making relative to the reports of preceding research. This introduces an unavoidable element of subjectivity to studies of this nature. Although care was exercised so as to minimise the effect of the expected subjectivity, the present study still constitutes the observations and decisions of a single individual. Concerns about subjectivity were addressed by:

- Setting out, and strictly adhering to, the criteria for the identification of the descriptive features examined (see section 2.8 on pages 78 to 96).
- Checking for **intra-rater reliability**, by repeating the identification process four times.

The inconstancies revealed by the second check on the descriptive data made it necessary to include the following criteria into the identification process:

- The orientation of the central fissure needed to be checked against the last terminal ascending branch of the lateral fissure (or alternatively the posterior termination of

the posterior ramus, as a means of keeping track of a possible double precentral sulcus [See section 2.6 (b) on pages 71 to 73. Also see Fig 2.3 on page 82; Fig 3.1 on page 116; Fig 3.2 (a, b) on pg 117; and Fig 3.3 (a, b) on page 118].

- Shallow (pseudo) connections of the anterior rami of the lateral fissure were not considered true anterior rami because they did not have continuity with the circular sulcus. These suci were considered to be sulci of the division of the frontal operculum to which they belonged [see Fig 3.5 on pg 120].

- In order to confirm the absence of either of the two anterior rami, the lateral fissure was opened to check whether:

    - The anterior ramus in question was truly absent, or
    - Existed, but did not reach the lateral surface; or
    - Merely notched the visible inferior border of the frontal operculum

- In order to confirm the existence of a connection between two sulci (other than that between the anterior rami and the lateral fissure), the sulcal walls at the site of the connection were also slightly parted, in order to check whether or not a true (deep)- or a shallow (pseudo) connection occurred. If there was a pseudo-connection, it was not recorded as a connection.

The third and forth checks of the descriptive data yielded stable information that was used to compile the descriptive record that is presented in Appendix C on pages 268 to 311.

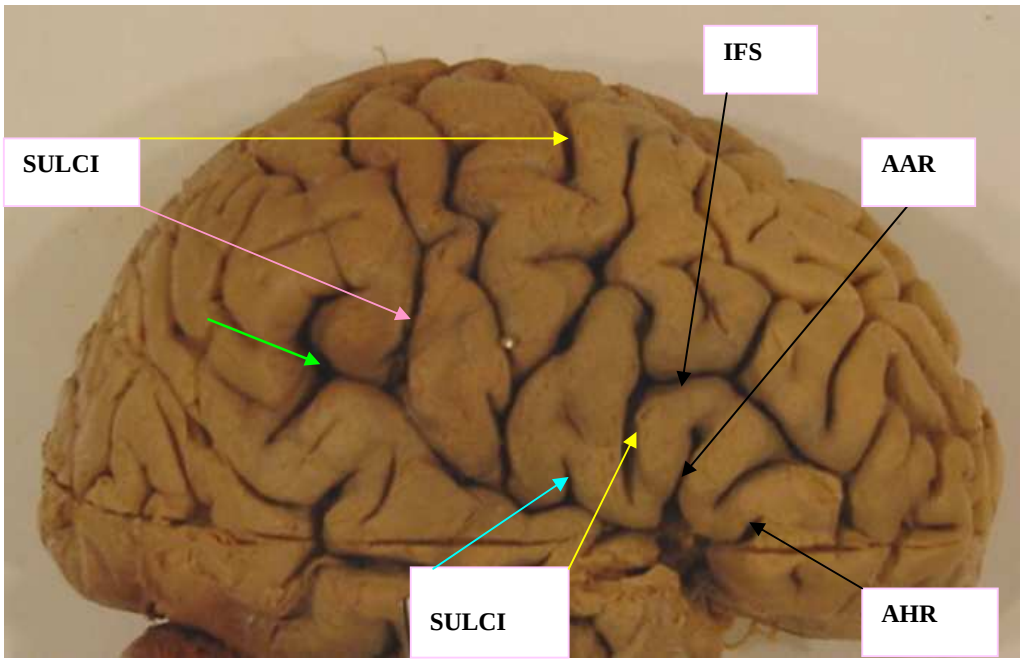

Figure 3.1 Identification of sulci in the frontoparietal operclum [1].

ORIENTATION OF THE RIGHT HEMISPHERE in Fig 3.1 above: The tip of the green arrow lies in the beginning of the upturned end of the posterior ramus of the lateral fissure, which is the landmark for the beginning of the orientation process. The pink arrow marks the inferior part of the postcentral sulcus. An office pin has been inserted into the central fissure (only the head is visible). Note that the central fissure has a connection with the lateral fissure. The blue arrow indicates the anterior subcentral sulcus (note that it lies between the inferior termination of the central fissure and the inferior precentral sulcus (lower yellow arrow).

BOUNDARY SULCI OF THE FRONTAL OPERCULUM in Fig 3.1 above: The yellow arrows point out the two components of the interrupted *single* precentral sulcus. Note that the inferior precentral sulcus has a connection with both the central fissure (office pin) and the inferior frontal sulcus (IFS). The IFS is continuous, has a true connection with the inferior precentral sulcus, and has a bifurcate anterior termination.

SULCI OF THE FRONTAL OPERCULUM in Fig 3.1 above: The major sulci: the anterior ascending ramus (AAR), and the anterior horizontal ramus (AHR) arise separately from the lateral fissure. This specimen can therefore be classified as having the VU pattern of the anterior rami. The only accessory sulcus, the sulcus of the pars triangularis, descends from the IFS into the pars triangularis, between the two anterior rami. In the absence of an opercular sulcus and the presence of a connection between the IFS and the inferior precentral sulcus, this specimen can be classified as a Type 1 [with respect to sulcal connections, see section 3.2.4.1 (pgs 173 and 174); and Fig 3.22 (pg 175)].

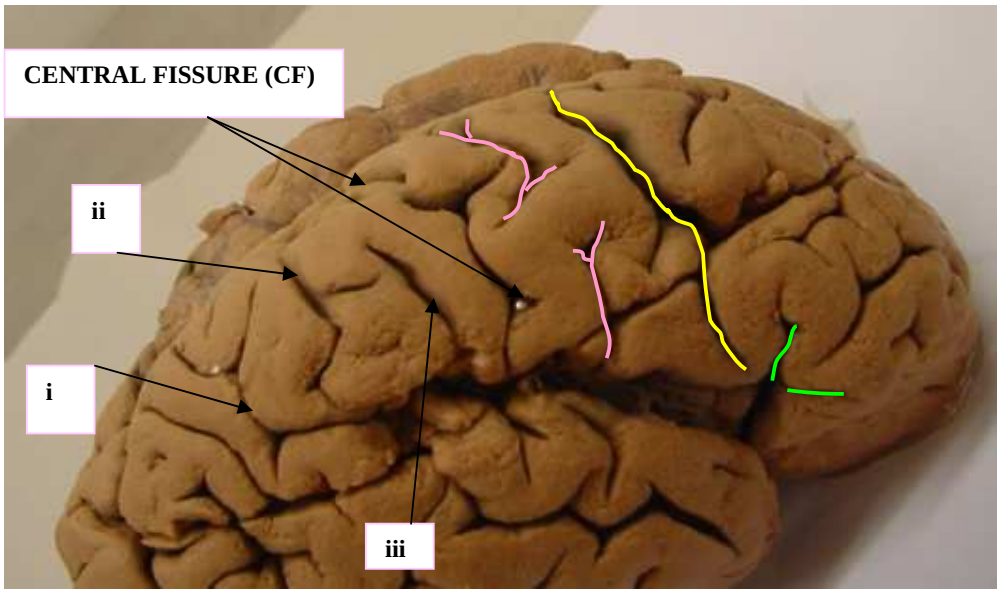

Figure 3.2 (a) Orientation in the frontoparietal operculum [2]. The upturned end of the lateral fissure [i] is followed anteriorly by the postcentral sulcus [ii]. The posterior subcentral sulcus [iii] is longer than usual. Note that two approximately parallel sulci may be interposed between the anterior rami (green) and the CF. The posterior precentral sulcus (pink) and anterior precentral sulcus (yellow) are the *double precentral sulci*. They were traced from the lateral fissure inferiorly to the longitudinal fissure superiorly.

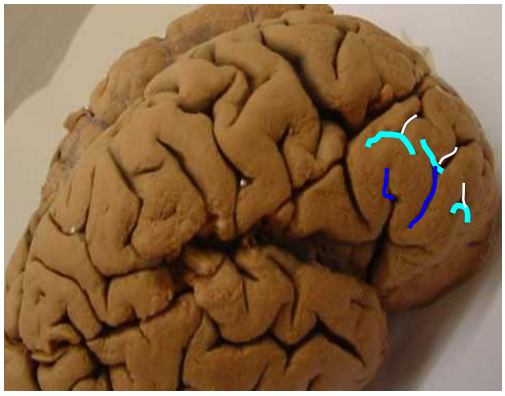

Figure 3.2 (b) *A closer look at the superor boundary of the frontal operculum of Fig 3.2 (a)*. The inferior frontal sulcus (IFS) is highlighted in light blue. Note that its posterior component has no connection with the anterior- or posterior- precentral sulci. The posterior dark blue sulcus is an opercular sulcus arising from the anterior ascending ramus. The anterior dark blue sulcus is a triangular sulcus arising from the intermediate segment of the IFS. Note that each segment of the IFS has a superior branch as well (white).

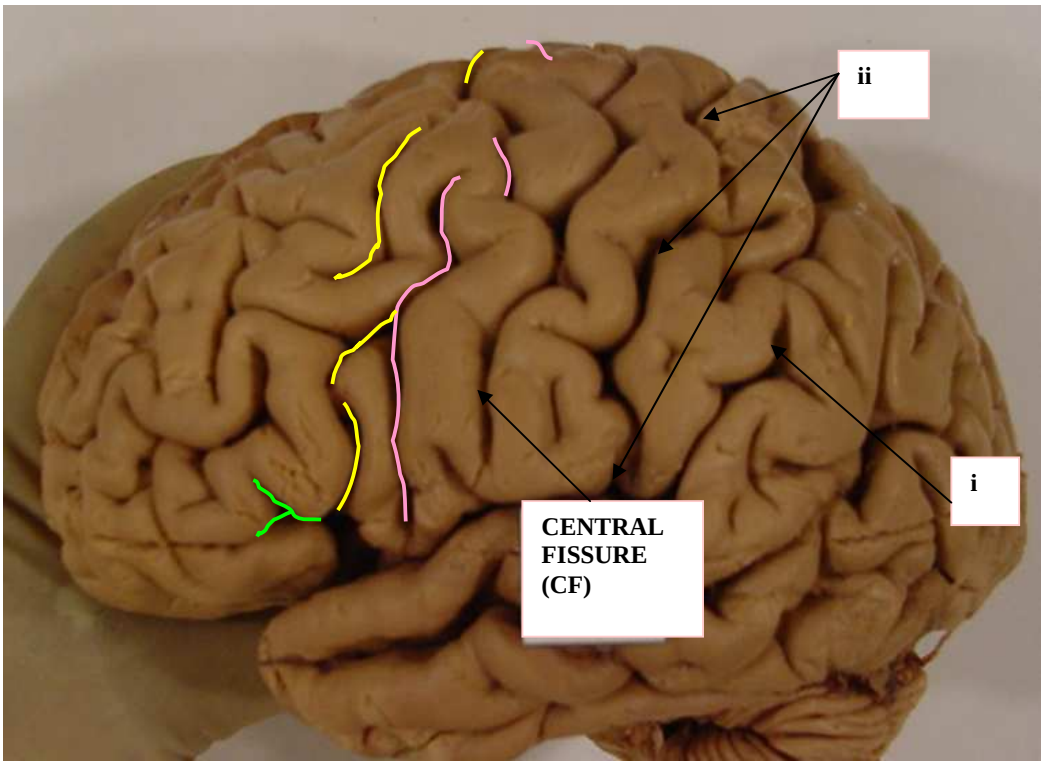

Figure 3.3 (a) Orientation in the frontoparietal operculum [3]. The upturned end of the lateral fissure [i] is followed anteriorly by the postcentral sulcus [ii]. Three components of this sulcus are visible. Note that two approximately parallel sulci may be interposed between the anterior rami (green) and the CF. The posterior precentral sulcus (pink) and anterior precentral sulcus (yellow) are the *double precentral sulci*. They were traced from the lateral fissure inferiorly to the longitudinal fissure superiorly.

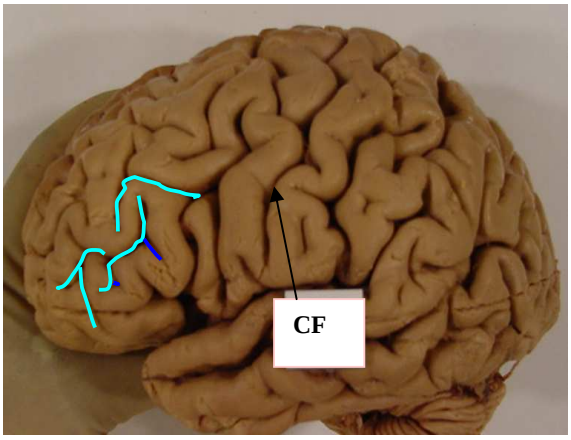

Figure 3.3 (b) *A closer look at the superor boundary of the frontal operculum of Fig 3.3 (a)*. The inferior frontal sulcus (IFS) is highlighted in light blue. Note that its posterior component has a connection with the anterior precentral sulcus and the posterior precentral sulcus as well. The posterior dark blue sulcus is an opercular sulcus arising from the intermediate segment of the IFS. The anterior dark blue notch is a triangular sulcus.

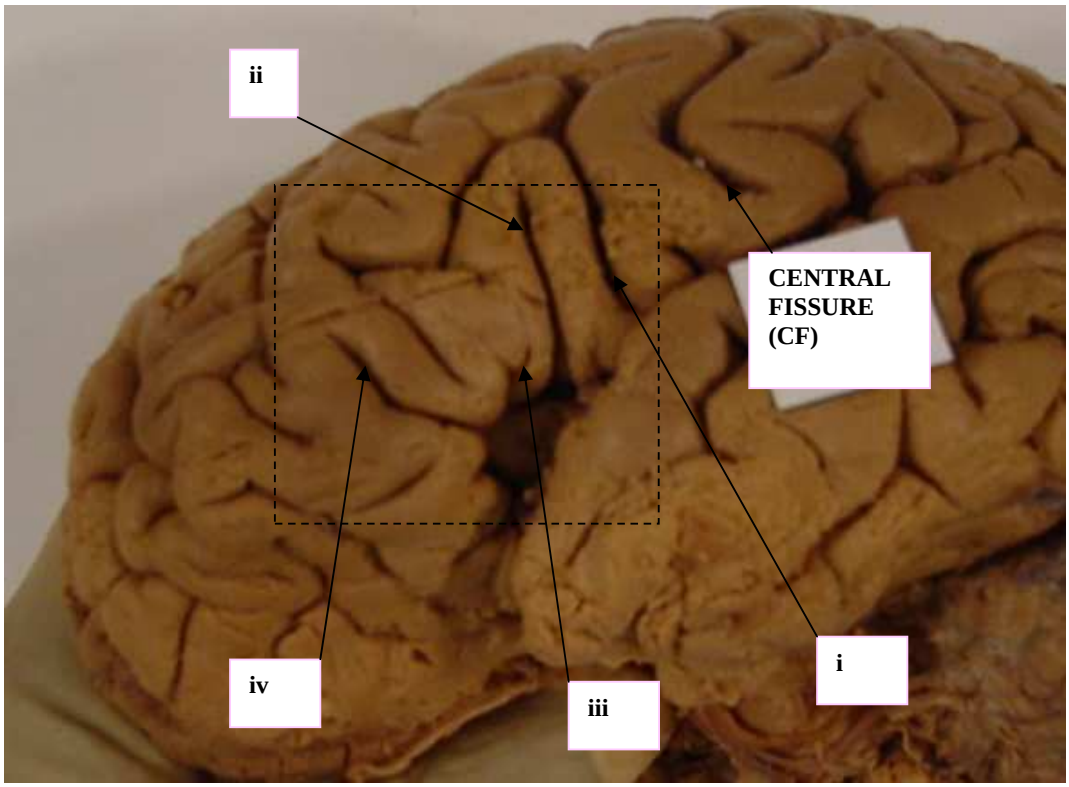

Figure 3.4 (a) A further note on sulci in the frontal operculum.

BRIEF ORIENTATION: An anterior subcentral sulcus notches the superior bank of the lateral fissure between the CF and the inferior precentral sulcus (i)].

SULCI OF THE FRONTAL OPERCULUM: The sulcus immediately anterior to the inferior precentral sulcus is actually an opercular sulcus (ii) arising from the lateral fissure because an anterior ascending ramus exists (iii). The anterior ascending ramus however just notches the frontal operculum. The inferior part of the anterior horizontal ramus (iv) is at the orbital margin.

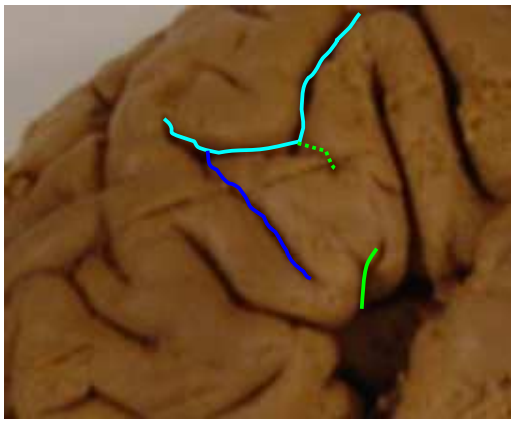

Figure 3.4 (b) Further on intraopercular boundaries The area selected in Fig 3.4 (a) is elaborated on here. The inferior frontal sulcus (light blue) sends two sulci into the frontal operculum. The posterior (broken green) of the two sulci is at the same vertical level as the anterior ascending ramus. It was therefore classified as a sulcus contributing to the boundary between the pars –opercularis and -triangularis. The second inferior branch of the inferior frontal sulcus is a sulcus of the pars triangularis.

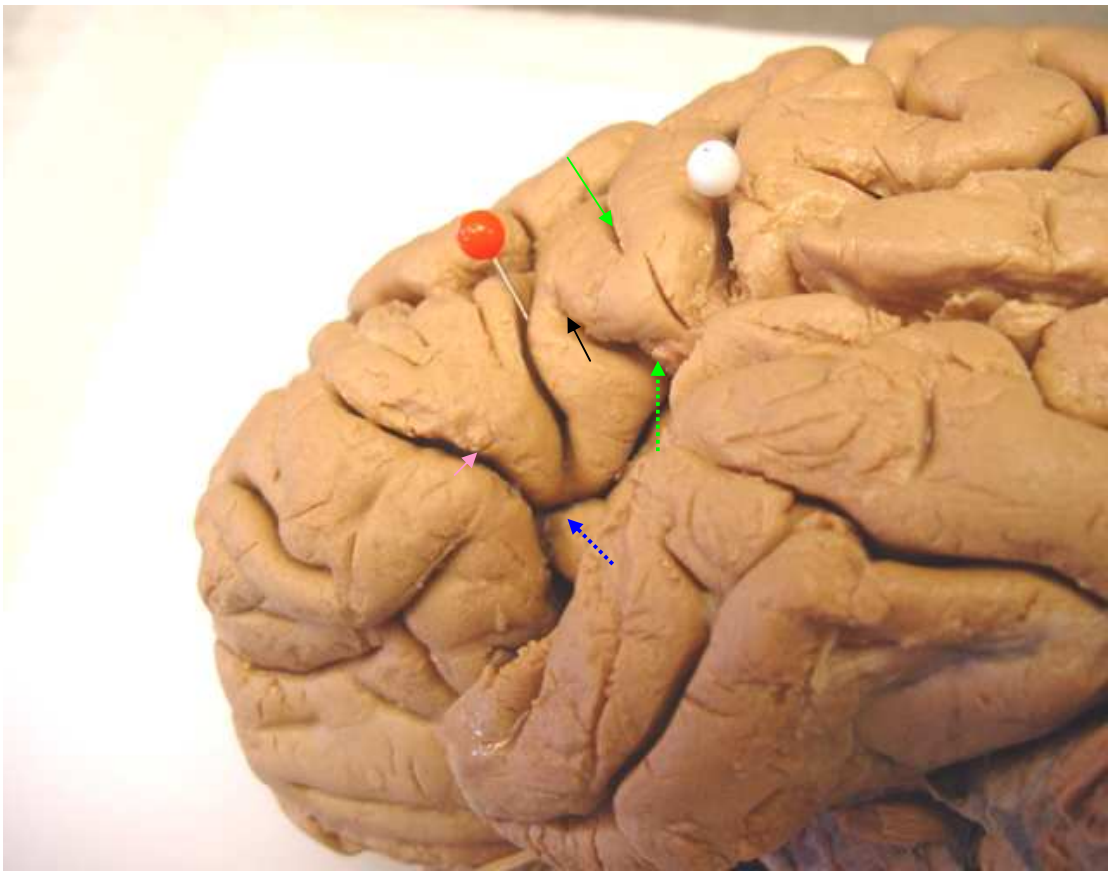

Figure 3.5 A true- versus a pseudo- connection with the lateral fissure.

ORIENTATION: (i) The central fissure (white pin). (ii) The sulci marked by the two green arrows constitute the inferior precentral sulcus because the straight part of the sulcus indicated by the broken green arrow is clearly aligned to the sulcus indicated by the solid green arrow. Note that the sulcus indicated by the solid black arrow is a side branch of the sulcus indicated by the broken green arrow. (iii) The superior temporal gyrus has been cut away in order to closely observe the behaviour of suci as they approach the lateral fissure inferiorly and the circular sulcus medially. The broken blue arrow indicates inular cortex.

A TRUE CONNECTION WITH THE LATERAL FISSURE: When the anterior horizontal ramus (pink arrow) is followed inferiorly, it can be seen to cut the inferior frontal gyrus so deeply that there is a connection between it, the lateral fissure, and the sulcus that surrounds the insula (circular sulcus).

A PSEUDO CONNECTION WITH THE LATERAL FISSURE: When the sulcus indicated by the red pin is followed inferiorly, it can be seen that an intervening bridge of cortex separates the sulcus from the circular sulcus. This was therefore taken to be a pseudo connection with the lateral fissure. Although this sulcus is in the expected position of the anterior assending ramus, its lack of continuity with the lateral fissure (deeply) and circular sulcus (medially) meant that it could only be clssified as a possible opercular sulcus. Note that there are three triangular sulci between the anterior horizontal ramus and the proposed opercular sulcus.

3.1.2 REPORT ON THE QUANTITATIVE METHODS USED IN THE PRESENT STUDY

The method used to measure sulcal lengths in the present study, evolved through a process of trial and error. Disatisfaction with the accuracy of the original direct method used in the initial trial (see section 3.1.2.1, below) led to the exploration of four indirect methods of measuring sulcal length. The failure of these indirect methods to deliver accurate methods for the measurement of sulcal lengths (see section 3.1.2.2 on pg 122), led to the method of choice as described in section 2.9 on pages 97 to 103. The pathway to the final method used to measure sulcal length is described in sections 3.1.2.1 and 3.1.2.2 below.

3.1.2.1 OBSERVATIONS ON THE MEASUREMENT OF SULCAL LENGTHS IN THE INITIAL TRIAL

The method for measuring sulcal lengths, as set out in the original design of the study, involved the simple laying down of a suture thread along a sulcus, and the snipping of it at the termination of the sulcus. The following observations were made on this method during a trial run: it was difficult to stabilise the suture thread without some form of anchor; and the thread tended to fray and splay out at the cut end. This required a decision to be made as to where to begin and end the reading of the length. The conclusion was that this method of measuring sulcal length led to unacceptable levels of inaccuracy. This method was therefore set aside, in the form decribed above.

3.1.2.2 CONSEQUENCES ARISING FROM THE INITIAL OBSERVATIONS ON THE MEASUREMENT OF SULCAL LENGTHS

(a) Indirect methods of measurement were explored (see section 2.11 on pages 108 to 110). The following observations were made on the:

i. THE MEASUREMENT OF SULCAL LENGTHS FROM PHOTOGRAPHIC NEGATIVES (see section 2.11.1 on page 108 for a description of the method)

It was very difficult and time consuming to *get close* to a 1:1 magnification of the negatives using the tuning dials, on the magnifier that was available in the Department of Anatomical Sciences (University of Witwatersrand).

ii. THE MEASUREMENT OF SULCAL LENGTHS FROM PRINTED PHOTOGRAPHS (see section 2.11.2 on page 108 for a description of the method)

While photographing the specimens, it was observed that due to the:

- Curvatures (antero-posterior, and left-right);
- As well as the gradual tapering, of the frontal lobe towards the frontal pole, different points in the frontal operculum were at slightly different heights from the camera.

In order to explore the effect of the curvatures mentioned above, on the measurement of sulcal lengths from printed images, four threads of equal length were placed on one specimen, and then photographed. It was noted that the lengths of these threads appeared different on the printed photograph (see Fig 3.6 on pg 124). An explanation of this feature was sought by photographing a specimen with a floor centimetre marker as well as centimetre markers placed at different heights on the specimen. It was noted that at a 1:1 magnification of the floor centimetre marker, the other centimetre markers displayed slightly different magnifications on the printed photograph (see Fig 3.7 on pg 124).

iii. THE MEASUREMENT OF SULCAL LENGTHS FROM PEN TRACINGS OF SURFACE FISSURES AND SULCI (see section 2.11.3 on page 109 for a description of the method)

It was observed that:

- It was often necessary to fold the plastic sheet of cling wrap used in this method, in order to obtain a 'best- fit' for it over the changing curvatures on the brain surface (see Fig 3.8 on pg 125, for the larger effect of this feature in a tracing of a hemisphere).
- Small kinks were produced in the plastic sheet, at the site of the folding.
- Very small distortions occurred in the plastic sheet between sulci, where it was moulded over gyri. The use of smaller squares of plastic

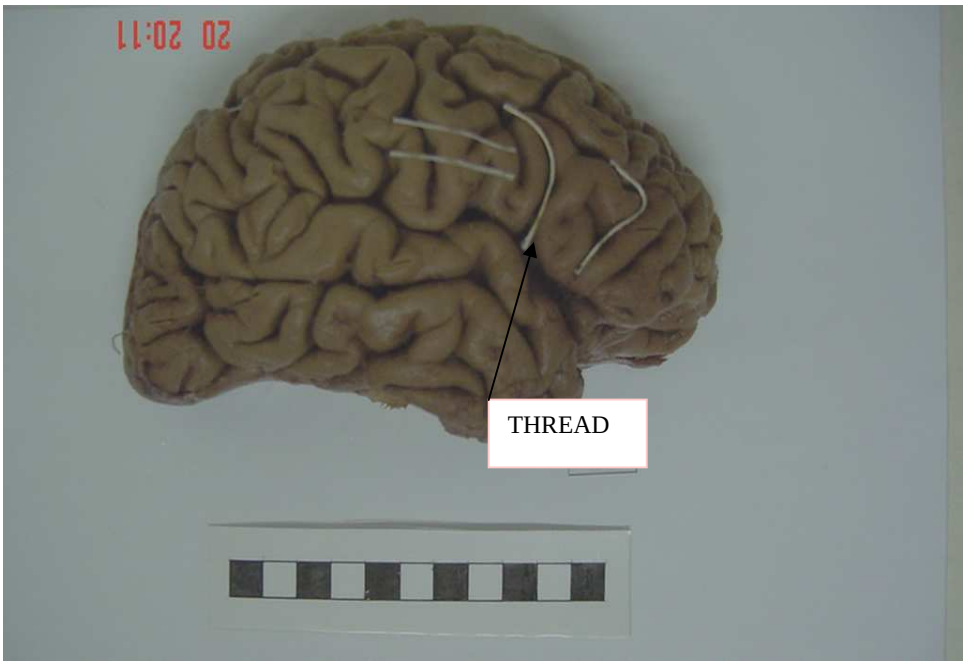

Figure 3.6 The effect of distance from the camera on the perception of sulcal length. Note that threads of equal length at different levels appear to be of unequal length

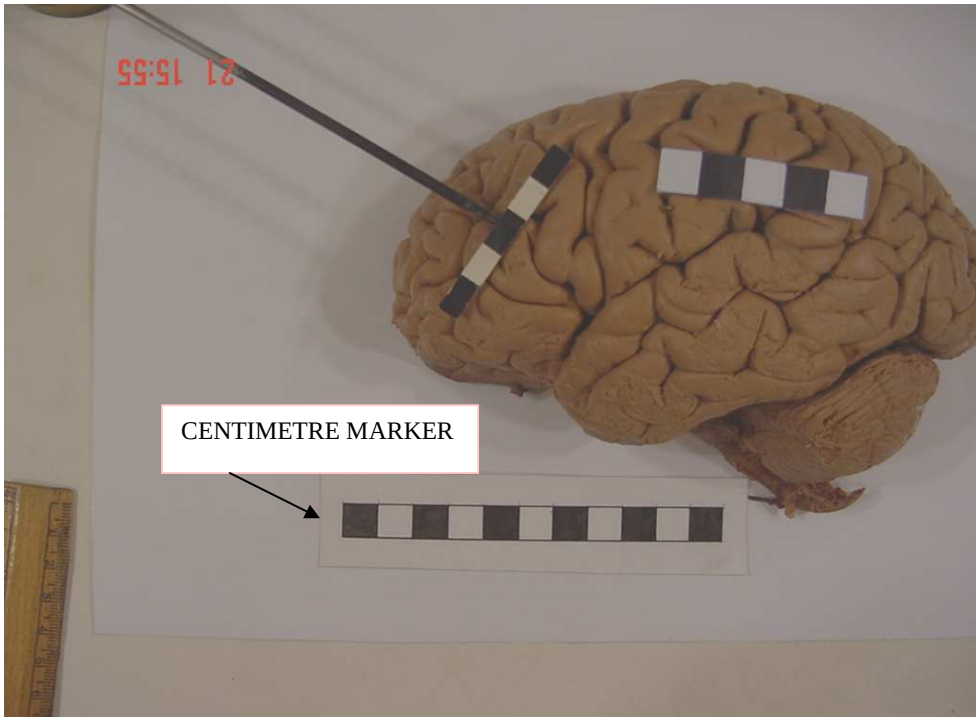

Figure 3.7 Magnification changes relative to changes in height from the camera (on the same specimen). Note the slight magnification change, with a change in height from table level, by comparing the centimetre markings on the three centimetre markers.

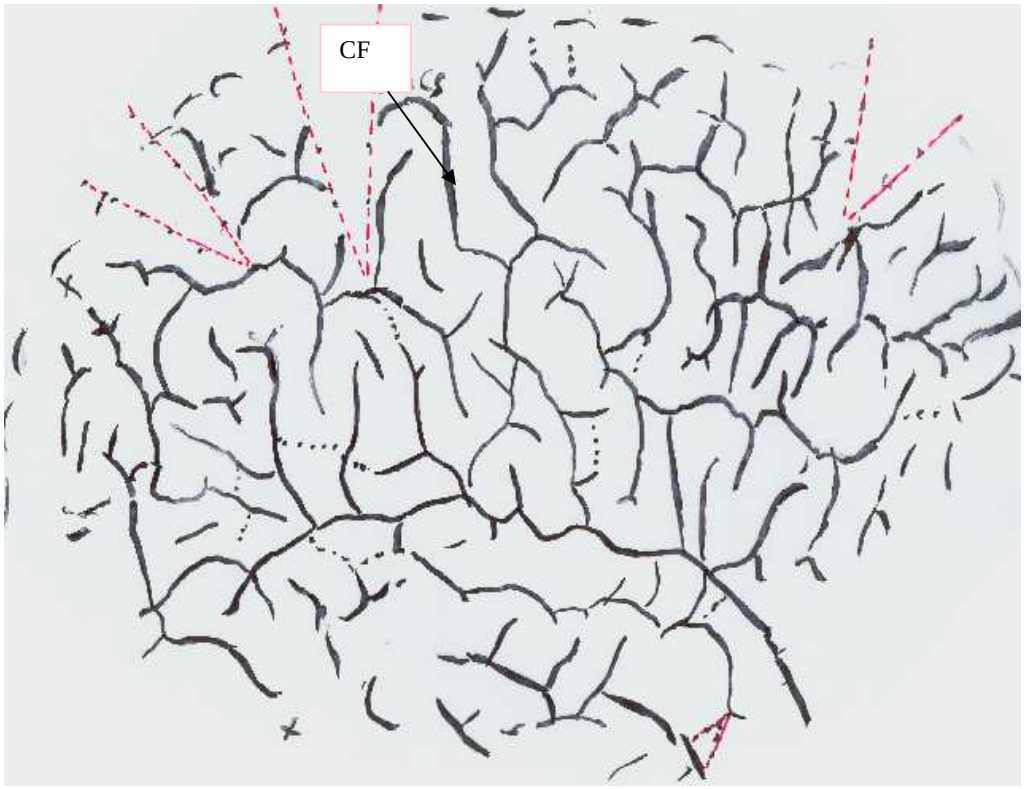

Figure 3.8 Pen tracing of the external cerebral surface. The red lines demonstrate the points at which it was necessary to fold the plastic sheet.

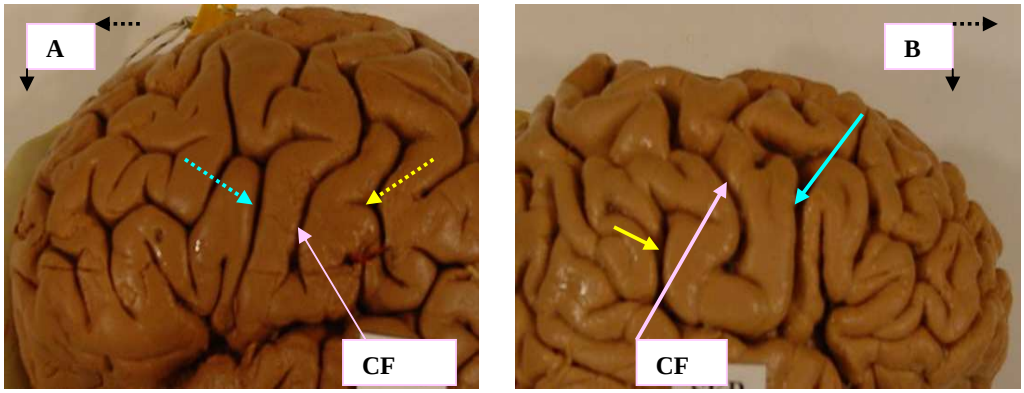

Figure 3.9 Terminations of the inferior ends of orientating and boundary sulci. Inferior terminations of the central fissure (CF): Diagram A - inverted 'Y' shape; Diagram B – inverted 'T' shape. Note that the black arrowheads point in an inferior direction and the broken black arrows in an anterior direction. In diagram B, the post central sulcus (solid yellow arrow) has a straight inferior termination and the precentral sulcus has an inverted 'Y' end (solid blue arrow). In diagram A, the postcentral sulcus (broken yellow arrow) has a straight inferior termination with a posterior inclination and the precentral sulcus has a straight inferior termination (broken blue arrow).

iv. <u>THE MEASUREMENT OF SULCAL LENGTHS BY USE OF THE MICROSCRIBE DIGITISER (see section 2.11.4 on pg 110 for a description of the method)</u>

The soft surface of the brain, and the very nature of sulci, was expected to present a problem for the recording of points in the measurement of sulcal lengths. These aspects, however, did not need to be resolved because the calibration of the machine proved to be out of reach, within the timescale of this project (see the acknowledgements section on page vi). *This method of measurement was therefore not pursued.*

(b) In view of the negative results obtained for the less direct methods for measuring sulcal lengths, a decision was taken to revert to the use of threads (with certain modifications) as a means of measurement.

Various 'threads' including very thin copper wire, dental tape, and ordinary sewing thread were explored and proved unsuitable. White double stranded Coats embroidery thread was eventually chosen. It fitted snugly into the eye of the needle, unlike the ordinary sewing thread, which was very mobile. Also, it did not kink when it was moulded along a sulcus (unlike the copper wire and dental tape).

The following modifications were employed in order to specifically address the two problems listed in the initial observations on the measurement of sulcal length (see section 3.1.2.1 on pg 121):

- The mobility of the thread was reduced by means of an anchor, in the form of an ordinary sewing needle. The use of multiple, and even two needles on a length of thread proved too difficult to manipulate over short distances. One needle inserted at the origin of a sulcus was found to offer sufficient stability for the manipulation of the thread. The head of an office pin marked the point at which the sulcus ended.

- The fraying of the thread was nullified by use of a permanent marker to mark critical points away from the cut edges of the white thread. The first point was marked and the thread was drawn through the eye of the needle until the marked point was located in the eye of the needle. Since the needle was to be inserted at the origin of the sulcus, and pushed in until the thread rested on the sulcus externally, the marked point located in the eye of the needle was almost at the true origin of the sulcus at the surface of the brain. The termination of the sulcus was marked on the centre of the head of the office pin mentioned above. The thread was then snipped beyond the second mark.

The use of the guidelines mentioned above led to the method of choice for the measurement of sulcal lengths [described in section 2.9 on pages 97 to 103 and illustrated in Figure 2.9 (a-g) on pages 99 to 101].

3.1.2.3 OBSERVATIONS ON THE MEASUREMENT OF INTERSULCAL LENGTHS [described in section 2.10 on pages 103-107, and illustrated in Fig 2.10 (a) on page 101 and Fig 2.10 (b) and (c) on page 105]

Measurement of intersulcal distances posterior to the anterior ascending ramus presented no problem. On the other hand, measurement of intersulcal distances anterior to the anterior ascending ramus was not as simple. The anterior horizontal rami sometimes arose from the orbital surface of the frontal lobe. This meant that the intersulcal distance had to be measured across a curved border. This problem was solved, by eliminating these specimens from the calculation of intersulcal distances in the pars triangularis only.

3.2 REPORT ON THE DESCRIPTIVE PART OF THE PRESENT STUDY

3.2.1 REPORT ON THE ORIENTATING SULCI USED IN THE PRESENT STUDY

This section addresses the following question posed in Chapter Two:

- ***What are the incidences of the pertinent features of the fissures and sulci, used for orientation purposes, in both cerebral hemispheres for ungrouped data (data prior to classification into Types of Sulcal Connections and Patterns of the Anterior Rami), in the present study?***

3.2.1.1 THE CENTRAL FISSURE

The three pertinent features examined for the central fissure were: the pattern of the fissure as a whole; the shape of the inferior termination of the fissure; and the connections of the fissure at and below the level of the inferior frontal sulcus.

Three patterns of the central fissure were observed. These were: continuous, interrupted with two segments, as well as interrupted with three segments (see Table 3.1 on pg 131. Fig 3.2 (a) on pg 117 shows a central fissure with two segments, Fig 3.3 (a) on pg 118, shows a continuous central fissure, and Fig 3.10 on pg 130 shows a central fissure with three segments. The predominant pattern was that of a continuous central fissure in both hemispheres, as well as in the control- and case- categories.

Three shapes of the inferior termination of the central fissure were observed. These were straight, 'Y'- shaped, and 'T' shaped (see Table 3.2 on pg 132 as well as Fig 3.9 A and B on pg 125). **The 'Y'- and 'T' shape are inverted as depicted in Fig 3.9 on pg 125, but they are hereafter, in this text, referred to as the 'Y'- and 'T' shape (this applies to all the inferior termnations of the orientating and boundary sulci).** The predominant shape of the inferior termination of the central fissure was straight in both the hemispheres, as well as in the control- and case- categories.

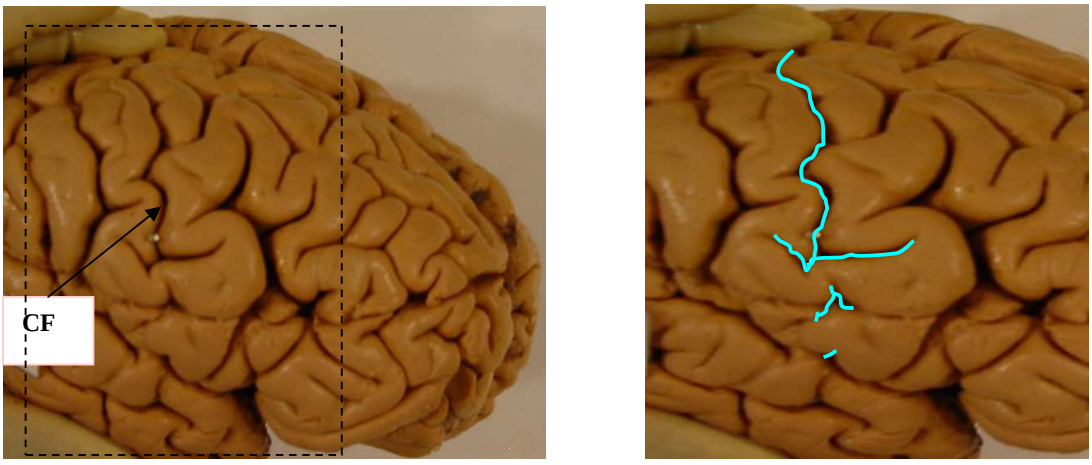

Figure 3.10 The three segment form of the central fissure (CF). The selected area in the figure on the left has been expanded in the figure on the right to demonstrate the three segments (blue sulci). Note that the ineriormost segment has a connection with the lateral fissure and is a notch.

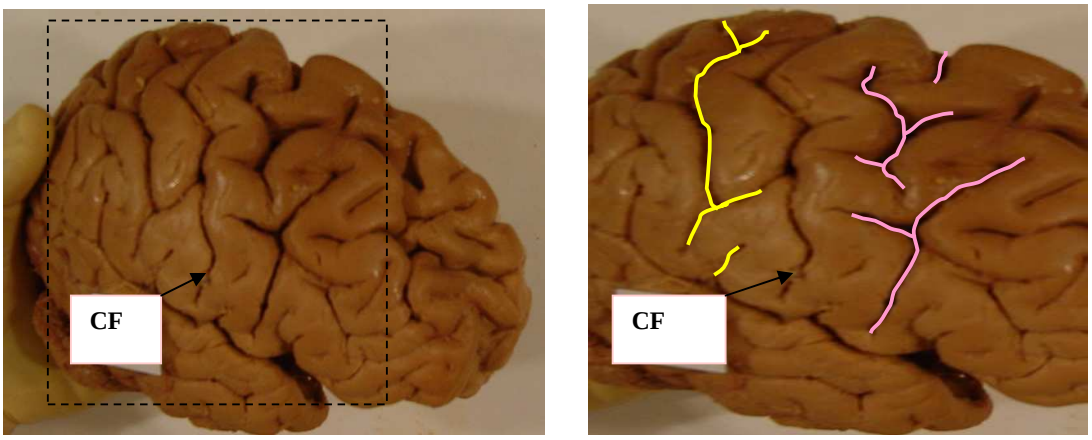

Figure 3.11 Segmetation of the Postcentral- and Precentral- sulcus. The selected area in the figure on the left has been expanded in the figure on the right to show the segmentation of the selected sulci. The postcentral sulcus (yellow) has two segments and the precentral sulcus (pink) has three segments. The central fissure is continuous. Note that all three sulci have straight inferior terminations, and only the postcentral sulcus has a connection with the lateral fissure.

The central fissure, at and below the level of the inferior frontal sulcus was either connected to adjacent sulci or, it was unconnected to them (see Table 3.3 on pg 132. Fig 3.9 on pg 125 shows a central fissure that lacks a connection with the lateral fissure and Fig 3.10 on pg 130 shows a central fissure connecting with the lateral fissure). The predominant feature of its connections at the stipulated level was that it was free of connections in both hemispheres, as well as in the control- and case- categories. It was otherwise connected to the lateral fissure, inferior precentral sulcus, anterior subcentral sulcus or inferior postcentral sulcus. The only connection of note was that of the central fissure with the lateral fissure (see Table 3.3 on pg 132). An anterior subcentral sulcus is shown in Fig 3.1 on pg 116 and a posterior subcentral sulcus in Fig 3.2 (a) on pg 117.

Table 3.1: The pattern of the Central Fissure as a whole.

PATTERNS OF THE CENTRAL FISSURE	n	FREQUENCY (PERCENTAGE) IN THE RIGHT HEMISPHERE	n	FREQUENCY (PERCENTAGE) IN THE LEFT HEMISPHERE
CONTROL	**65**		**65**	
1. Continuous		**51 (78.5)**		**52 (80.0)**
2. Interrupted (2 segments)		**13 (20.0)**		**12 (18.5)**
3. Interrupted (3 segments)		**1 (1.5)**		**1 (1.5)**
CASE	**45**		**44**	
1. Continuous		**41 (91.1)**		**40 (90.9)**
2. Interrupted (2 segments)		**4 (8.9)**		**4 (9.1)**

Table 3.2: The shape of the inferior termination of the Central Fissure (close to the Lateral Fissure).

SHAPE OF THE TERMINATION OF THE CENTRAL FISSURE	n	FREQUENCY (PERCENTAGE) IN THE RIGHT HEMISPHERE	n	FREQUENCY (PERCENTAGE) IN THE LEFT HEMISPHERE
CONTROL	**65**		**65**	
1. Straight		**57 (87.7)**		**44 (67.7)**
2. 'Y'		**7 (10.8)**		**19 (29.2)**
3. 'T'		**1 (1.5)**		**2 (3.1)**
CASE	**45**		**45**	
1. Straight		**36 (80.0)**		**37 (82.2)**
2. 'Y'		**9 (20.0)**		**8 (17.8)**

Table 3.3: The connections[10] of the inferior end of the Central Fissure, at and below the level of the Inferior Frontal Sulcus.

CONNECTIONS OF THE CENTRAL FISSURE INFERIORLY WITH:	n	FREQUENCY (PERCENTAGE) IN THE RIGHT HEMISPHERE	n	FREQUENCY (PERCENTAGE) IN THE LEFT HEMISPHERE
CONTROL	**65**		**65**	
1. Lateral sulcus		**10 (15.4)**		**8 (12.3)**
2. Inferior precentral sulcus		**1 (1.5)**		**3 (4.6)**
3. Anterior subcentral sulcus		**1 (1.5)**		**0**
4. Inferior postcentral sulcus		**0**		**1 (1.5)**
5. No sulcus		**53 (81.5)**		**53 (81.5)**
CASE	**45**		**45**	
1. Lateral sulcus		**8 (17.8)**		**4 (8.9)**
2. Inferior precentral sulcus		**2 (4.4)**		**2 (4.4)**
3. Anterior subcentral sulcus		**0**		**1 (2.2)**
4. Inferior postcentral sulcus		**1 (2.2)**		**0**
5. No sulcus		**35 (77.8)**		**38 (84.4)**

[10] Note that it is possible for a sulcus to have more than one connection

Table 3.4: The frequency of occurrence of the Anterior- and Posterior- Subcentral Sulci

FREQUENCY OF OCCURENCE OF:	n	FREQUENCY (PERCENTAGE) IN THE RIGHT HEMISPHERE	n	FREQUENCY (PERCENTAGE) IN THE LEFT HEMISPHERE
CONTROL	**65**		**65**	
1. Anterior subcentral present		**24 (36.9)**		**14 (21.5)**
2. Posterior subcentral present		**9 (13.8)**		**8 (12.3)**
3. Both are present		**5 (7.7)**		**14 (21.5)**
4. Both are absent		**27 (41.5)**		**29 (44.6)**
CASE	**45**		**45**	
1. Anterior subcentral present		**15 (33.3)**		**11 (24.4)**
2. Posterior subcentral present		**7 (15.6)**		**6 (13.3)**
3. Both are present		**5 (11.1)**		**7 (15.6)**
4. Both are absent		**18 (40.0)**		**21 (46.7)**

3.2.1.2 THE POSTCENTRAL SULCUS

The three pertinent features examined for the Postcentral Sulcus were: the pattern of the sulcus as a whole; the shape of the inferior termination of the sulcus; and the connections of the sulcus at and below the level of the inferior frontal sulcus.

Four patterns of the Postcentral Sulcus were observed. They were: continuous; interrupted with two segments, interrupted with three segments, and interrupted with four segments (the two segment form is shown in Fig 3.11 on pg 130 and the three segment form in Fig 3.3 (a) on pg 118). The predominant pattern was that of an interrupted Postcentral Sulcus in both hemispheres, as well as in the control- and case- categories (see Table 3.5 on

pg 135). The incidence of the two-segment form was greater than that of the three-segment form in the control category, but the reverse was true for the case category in the right hemisphere only.

Three shapes of the inferior termination of the Postcentral sulcus were observed. These were: straight, ‘Y’- shaped, and ‘T’- shaped (Fig 3.9 A and B on page 125 suffices to illustrate this point). The predominant shape of the inferior termination of the Postcentral sulcus was straight in both hemispheres, as well as in the control- and case- categories (see Table 3.6 on pg 135).

The Postcentral sulcus, at and below the level of the Inferior Frontal Sulcus was either connected to adjacent sulci or was unconnected to them (see Table 3.7 on pg 136). The predominant connection of the Postcentral sulcus, at the stipulated level, was with the lateral fissure. It was otherwise (at the stipulated level) almost unconnected to other fissures and sulci (Fig 3.11 on pg 130 shows the connection with lateral fissure and Fig 3.9 on pg 125 shows the lack of a conection with the lateral fissure).

Table 3.5: The pattern of the Postcentral Sulcus as a whole.

PATTERN OF THE POSTCENTRAL SULCUS	n	FREQUENCY (PERCENTAGE) IN THE RIGHT HEMISPHERE	n	FREQUENCY (PERCENTAGE) IN THE LEFT HEMISPHERE
CONTROL	**65**		**65**	
1. A continuous sulcus		**6 (9.2)**		**10 (15.4)**
2. Interrupted (2 segments)		**36 (55.4)**		**25 (38.5)**
3. Interrupted (3 segments)		**17 (26.2)**		**21 (32.3)**
4. Interrupted (4 segments)		**6 (9.2)**		**9 ((13.8)**
CASE	**45**		**44**	
1. A continuous sulcus		**5 (11.1)**		**4 (9.1)**
2. Interrupted (2 segments)		**11 (24.4)**		**21 (47.7)**
3. Interrupted (3 segments)		**23 (51.1)**		**16 (36.4)**
4. Interrupted (4 segments)		**6 (13.3)**		**3 (6.8)**

Table 3.6: The shape of the inferior termination of the Postcentral Sulcus (close to the Lateral Fissure).

SHAPE OF TERMINATION OF THE INFERIOR POSTCENTRAL SULCUS	n	FREQUENCY (PERCENTAGE) IN THE RIGHT HEMISPHERE	n	FREQUENCY (PERCENTAGE) IN THE LEFT HEMISPHERE
CONTROL	**65**		**65**	
1. Straight		**54 (83.1)**		**58 (89.2)**
2. 'Y'		**10 (15.4)**		**7 (10.8)**
3. 'T'		**1 (1.5)**		**0**
CASE	**45**		**44**	
1. Straight		**39 (86.7)**		**37 (84.1)**
2. 'Y'		**6 (13.3)**		**6 (13.6)**
3. 'T'		**0**		**1 (2.3)**

Table 3.7: The connections of the inferior end of the Postcentral Sulcus, at and below the level of the Inferior Frontal Sulcus.

INFERIOR CONNECTIONS OF THE INFERIOR POSTCENTRAL SULCUS WITH:	n	FREQUENCY (PERCENTAGE) IN THE RIGHT HEMISPHERE	n	FREQUENCY (PERCENTAGE) IN THE LEFT HEMISPHERE
CONTROL	**65**		**65**	
1. Lateral Fissure (LF)		**47 (72.3)**		**51 (78.5)**
2. LF and CF		**0**		**1 (1.5)**
3. No sulcus		**18 (27.7)**		**13 (20.0)**
CASE	**45**		**44**	
1. Lateral Fissure		**31 (68.9)**		**35 (79.5)**
2. LF and CF		**1 (2.2)**		**0**
3. No sulcus		**13 (28.9)**		**9 (20.5)**

3.2.2 REPORT ON THE BOUNDARY SULCI OF THE FRONTAL OPERCULUM

This section addresses the following question posed in Chapter Two:

- ***What are the incidences of the pertinent features of the sulci forming the superior- and posterior- boundaries of the frontal operculum, in both cerebral hemispheres for ungrouped data?***

3.2.2.1 THE PRECENTRAL SULCUS

The precentral sulcus was found to be either a single sulcus (Fig 3.1 on pg 116) or a double sulcus (Fig 3.2 on pg 117, Fig 3.3 on pg 118, and Fig 3.12 on pg 139). The incidences of these sulci are given in Table 3.8 (on pg 138).

The predominant pattern was that of an interrupted precentral sulcus (for both the single- and double- sulci) in: both hemispheres, as well as in the control- and case- categories [see Tables 3.9 (on pg 140), 3.10 (on pg 140), and 3.11 (on pg 142]. The incidence of the three-segment form was greater than that of the two- and four- segment forms, in the control- and case- categories for the single precentral sulcus, in both hemispheres. The segmentation of the single precentral sulcus is illustrated in Fig: 3.1, on page 116 (2 segment form); Fig 3.11 on page 130 (3 segment form); and Fig 3.13 on page 141 (4 segment form).

Two shapes of the inferior termination of the precentral sulci were observed (straight and 'Y'. The predominant shape of the inferior termination of the precentral sulci was straight in: both hemispheres, as well as in the control- and case- categories [see Tables 3.12 (on pg 142), 3.13 (on pg 143), and 3.14 (on pg 143); note that the straight from is depicted Fig 3.9 A and the inverted 'Y' form in Fig 3.9 B, both on pg 125].

The connections of the Inferior Precentral Sulcus, at and below the level of the inferior

frontal sulcus [see Tables 3.14 (on pg 143), 3.15 (on pg 144), and 3.16 (on pg 144)], were as follows:

- Lateral Fissure only
- Inferior Frontal sulcus only (see Fig 3.9 A on pg 125)
- Inferior Frontal sulcus and the Lateral Fissure (see Fig 3.9 B on pg 125)
- Inferior Frontal Sulcus and the Central Fissure (see Fig 3.1 on pg 116)
- Other sulci (anterior ascending ramus, intermediate frontal sulcus, anterior subcentral sulcus)
- Unconnected to other sulci.

The predominant connection of the single precentral sulcus was to the inferior frontal sulcus only (see Fig 3.1 on pg 116) in both hemispheres, and in the control- and the case-categories. Comment will not be made on general trends for the anterior- and posterior-precentral sulci, in view of their small sample numbers.

Table 3.8: The Incidence of the Single and Double Precentral Sulci

PATTERN OF THE PRECENTRAL SULCUS	n	FREQUENCY (PERCENTAGE) IN THE RIGHT HEMISPHERE	n	FREQUENCY (PERCENTAGE) IN THE LEFT HEMISPHERE
CONTROL	**65**		**80**	
1. Single		**93.8**		**90.8**
2. Double		**6.2**		**9.2**
CASE	**45**		**45**	
1. Single		**100**		**97.8**
2. Double		**0**		**2.2**

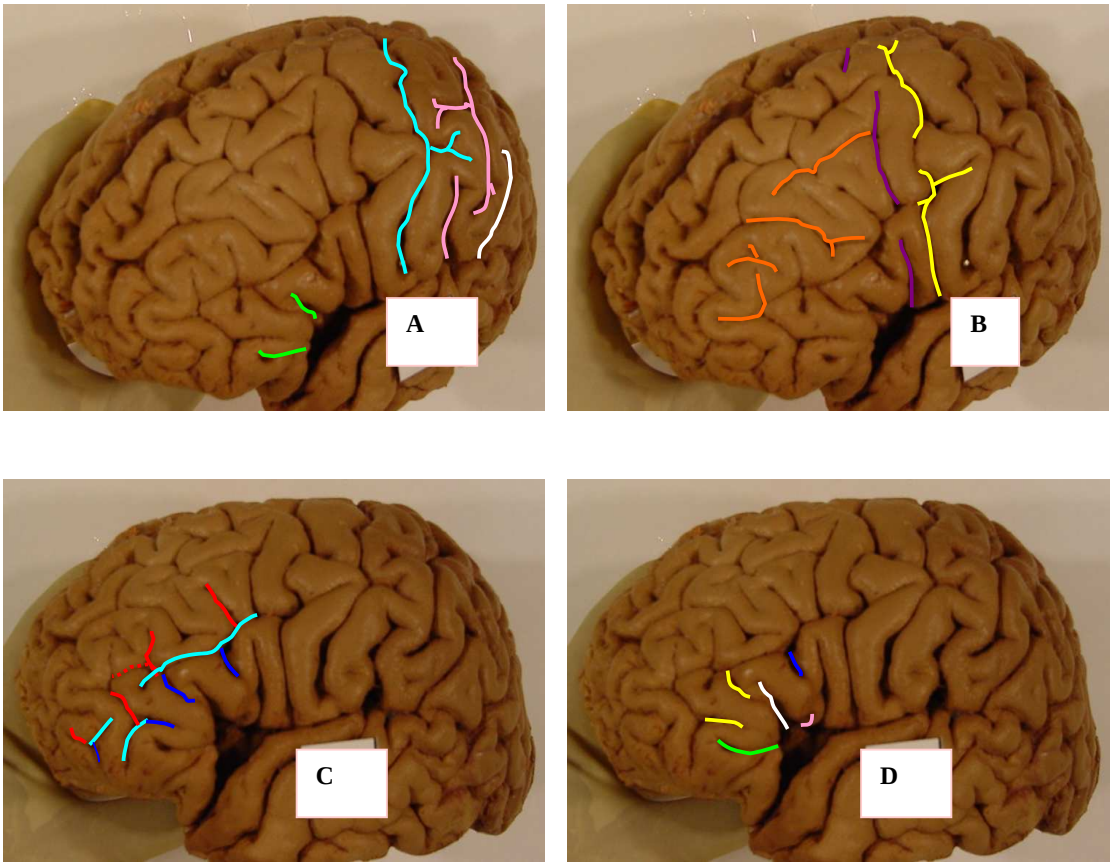

Figure 3.12 Double Precentral Sulci and the Inferor Frontal Sulcus. Figs A-D demonstrate different aspects of the same specimen.

In Figure A, the white sulcus is the upturned end of the lateral fissure. The postcentral sulcus (pink) has two segments, the central fissure (blue) is continuous, and the anterior rami arise separately from the lateral fissure (green).

In Figure B, note that two approximately parallel sulci can be traced, from the lateral fissure to the longitudinal fissure (between the anterior rami and the central fissure). These two sulci are therefore the double precentral sulci. The posterior precentral sulcus (yellow) has two segments and the anterior precentral sulcus (purple) has three segments. Note that the intermediate frontal sulcus is depicted in orange.

In Figure C, the inferior frontal sulcus is highlighted in light blue. It has three segments. There are four superior branches (red). One superior branch has a pseudoconnection (broken red) with the intermediate frontal sulcus. There are four inferior branches (dark blue) into the frontal operculum.

In Figure D, the anterior ascending ramus is highlighted in white and the anterior horizontal ramus in green. Two accessory sulci can be observed in the pars opercularis (sulci of the pars opercularis). One arises from the inferior frontal sulcus (dark blue) and the other notches the lateral fissure (pink). Two accessory sulci (yellow) can also be observed in the pars triangularis (sulci of the pars triangularis). Both arise from the inferior frontal sulcus.

Table 3.9: The pattern of the Single Precentral Sulcus as a whole.

PATTERN OF THE SINGLE PRECENTRAL SULCUS	n	FREQUENCY (PERCENTAGE) IN THE RIGHT HEMISPHERE	n	FREQUENCY (PERCENTAGE) IN THE LEFT HEMISPHERE
CONTROL	**61**		**59**	
1. A continuous sulcus		**1 (1.6)**		**1 (1.6)**
2. Interrupted (2 segments)		**14 (22.9)**		**9 (15.3)**
3. Interrupted (3 segments)		**31 (50.8)**		**33 (55.9)**
4. Interrupted (4 segments)		**14 (22.9)**		**15 (25.4)**
5. Interrupted (5 segments)		**1 (1.6)**		**1 (1.6)**
CASE	**45**		**44**	
1. A continuous sulcus		**1 (2.2)**		**1 (2.3)**
2. Interrupted (2 segments)		**7 (15.6)**		**15 (34.1)**
3. Interrupted (3 segments)		**24 (53.3)**		**19 (43.2)**
4. Interrupted (4 segments)		**13 (28.9)**		**8 (18.2)**
5. Interrupted (5 segments)		**0**		**1 (2.3)**

Table 3.10: The pattern of the Anterior Precentral Sulcus as a whole (when the precentral sulcus occurs as two sulci.

PATTERN OF THE ANTERIOR PRECENTRAL SULCUS	n	FREQUENCY (PERCENTAGE) IN THE RIGHT HEMISPHERE	n	FREQUENCY (PERCENTAGE) IN THE LEFT HEMISPHERE
CONTROL	**4**		**6**	
1. Interrupted (2 segments)		**1 (25.0)**		**0**
2. Interrupted (3 segments)		**1 (25.0)**		**3 (50.0)**
3. Interrupted (4 segments)		**0**		**3 (50.0)**
4. Interrupted (5 segments)		**2 (50.0)**		**0**
CASE	**0**		**1**	
1. Interrupted (2 segments)		**0**		**1 (100)**

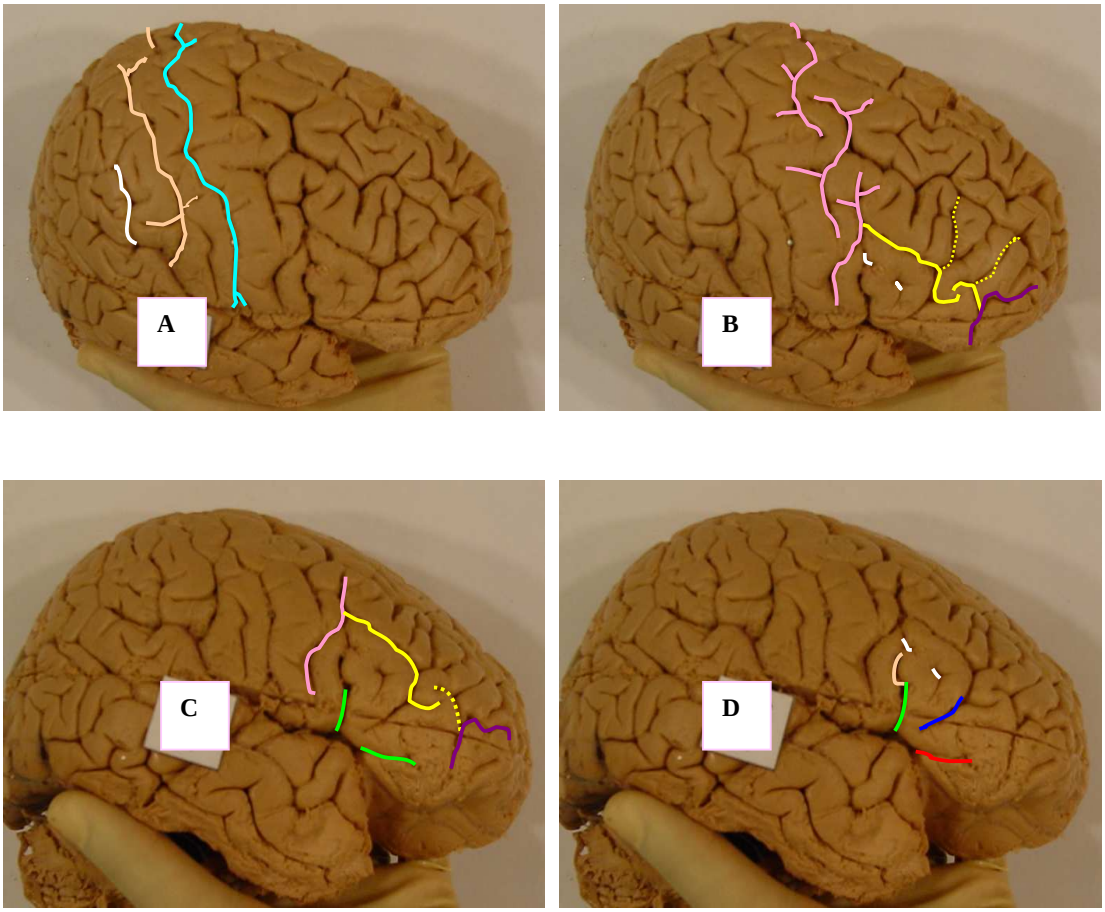

Figure 3.13 A Four- segment Precentral sulcus and a Two- segment Inferior Frontal Sulcus. Note that all four pictures are of the same specimen.

In Figure A: The upturned end of the lateral fissure is the white sulcus. The postcentral sulcus (peach) makes a connection with the lateral fissure. The continuous central fissure (blue) has an inverted 'Y' inferior termination that has a pseudoconnection with the lateral fissure.

In Figure B, the precentral sulcus (pink) has four segments. Note that the superiormost segment notches the longitudinal fissure. The inferior frontal sulcus (yellow) has two segments. Its two superior branches (broken yellow) have a connection with the intermediate frontal sulcus. The anteriormost segment of the inferior frontal sulcus makes a connection with the frontomarginal sulcus (purple). Note the presence of two dimples (white) in the inferior frontal gyrus.

In Figure C, the connection of the posterior segment of the inferior frontal sulcus (yellow) with the inferior precentral sulcus (pink) is emphasised, and so is the connection of the anterior segment of the inferior frontal sulcus (broken yellow) to the frontomarginal sulcus. The anterior rami are highlighted in green.

In Figure D, the only inferior branch of the inferior frontal sulcus (blue) is a sulcus of the pars triangularis. It lies between the anterior ascending ramus (green) and the anterior horizontal ramus (red). An opercular sulcus (peach) joins the termination of the anterior ascending ramus (green). Note that the posterior dimple does not join the opercular sulcus.

Table 3.11: The pattern of the Posterior Precentral Sulcus as a whole (when the precentral sulcus occurs as two sulci.

PATTERN OF THE POSTERIOR PRECENTRAL SULCUS	n	FREQUENCY (PERCENTAGE) IN THE RIGHT HEMISPHERE	n	FREQUENCY (PERCENTAGE) IN THE LEFT HEMISPHERE
CONTROL	**4**		**6**	
1. Continuous		**0**		**1 (16.7)**
1. Interrupted (2 segments)		**1 (25.0)**		**2 (33.3)**
2. Interrupted (3 segments)				**1 (16.7)**
3. Interrupted (4 segments)		**2 (50.0)**		**1 (16.7)**
4. Interrupted (5 segments)		**1 (25.0)**		**1 (16.7)**
CASE	**0**		**1**	
1. Interrupted (3 segments)				**1 (100)**

Table 3.12: The shape of the inferior termination of the Single Precentral sulcus (close to the Lateral Fissure). Note that the, diagram for the shape of the inferior termination of the central fissure aso applies.

SHAPE OF THE TERMINATION OF THE SINGLE PRECENTRAL SULCUS	n	FREQUENCY (PERCENTAGE) IN THE RIGHT HEMISPHERE	n	FREQUENCY (PERCENTAGE) IN THE LEFT HEMISPHERE
CONTROL	**61**		**59**	
1. Straight		**47 (77.1)**		**51 (86.4)**
2. 'Y'		**14 (22.9)**		**5 (8.5)**
3. Other		**0**		**3 (5.1)**
CASE	**45**		**44**	
1. Straight		**38 (84.4)**		**34 (77.3)**
2. 'Y'		**7 (15.6)**		**10 (22.7)**

Table 3.13: The shape of the inferior termination of the Anterior Precentral Sulcus

SHAPE OF THE TERMINATION OF THE ANTERIOR PRECENTRAL SULCUS	n	FREQUENCY (PERCENTAGE) IN THE RIGHT HEMISPHERE	n	FREQUENCY (PERCENTAGE) IN THE LEFT HEMISPHERE
CONTROL	**4**		**6**	
1. Straight		**4 (100)**		**5 (83.3)**
2. 'Y'		**0**		**1 (16.7)**
CASE	**0**		**1**	
1. Straight		**0**		**1 (100)**

Table 3.14: The shape of the inferior termination of the Posterior Precentral Sulcus (close to the Lateral Fissure). Note that the, diagram for the shape of the inferior termination of the central fissure aso applies.

SHAPE OF THE TERMINATION OF THE POSTERIOR PRECENTRAL SULCUS	n	FREQUENCY (PERCENTAGE) IN THE RIGHT HEMISPHERE	n	FREQUENCY (PERCENTAGE) IN THE LEFT HEMISPHERE
CONTROL	**4**		**6**	
1. Straight		**3 (75.0)**		**3 (50.0)**
2. 'Y'		**1 (25.0)**		**2 (33.3)**
3. Other		**0**		**1 (16.7)**
CASE	**0**		**1**	
1. 'Y'				**1 (100)**

Table 3.15: The connections of the Single Precentral Sulcus (at and below the level of the Inferior Frontal Sulcus).

CONNECTIONS OF THE SINGLE PRECENTRAL SULCUS INFERIORLY WITH:	n	FREQUENCY (PERCENTAGE) IN THE RIGHT HEMISPHERE	n	FREQUENCY (PERCENTAGE) IN THE LEFT HEMISPHERE
CONTROL	61		59	
1. Inferor Frontal Sulcus (IFS)		32 (52.5)		39 (66.1)
2. Lateral Fissure (LF) only		2 (3.3)		0
3. IFS and LF		10 (16.4)		11 (18.6)
4. Total connections for LF		12 (19.7)		11 (18.6)
5. IFS and Central Fissure		2 (3.2)		3 (5.1)
6. Other sulci		0		2 (3.4)
7. No other sulcus		15 (22.9)		4 (6.8)
CASE	45		44	
1. Inferor Frontal Sulcus (IFS)		29 (64.4)		30 (68.2)
2. Lateral Fissure (LF) only		3 (6.7)		0
3. IFS and LF		2 (4.4)		6 (13.6)
4. Total connections for LF		5 (11.1)		6 (13.6)
5. IFS and Central Fissure		0		1 (2.3)
6. Other sulci		5 (11.1)		1 (2.3)
7. No other sulcus		6 (13.3)		6 (13.6)

Table 3.16: The connections of the inferior end of the Anterior Precentral Sulcus (close to the Lateral Fissure) when the precentral sulcus is present as two sulci.

CONNECTIONS OF THE ANTERIOR PRECENTRAL SULCUS INFERIORLY WITH:	n	FREQUENCY (PERCENTAGE) IN THE RIGHT HEMISPHERE	n	FREQUENCY (PERCENTAGE) IN THE LEFT HEMISPHERE
CONTROL	4		6	
1. Inferior Frontal Sulcus (IFS)		1 (25.0)		1 (16.7)
2. Lateral Fissure (LF)		1 (25.0)		1 (16.7)
3. IFS and LF		0		2 (33.3)
2. Other sulci		1 (25.0)		1 (16.7)
3. No other sulcus		1 (25.0)		1 (16.7)
CASE	0		1	
1. Lateral Fissure		0		1 (100)

Table 3.17: The connections of the inferior end of the Posterior Precentral Sulcus (close to the Lateral Fissure) when the precentral sulcus is present as two sulci.

CONNECTIONS OF THE ANTERIOR PRECENTRAL SULCUS INFERIORLY WITH:	n	FREQUENCY (PERCENTAGE) IN THE RIGHT HEMISPHERE	n	FREQUENCY (PERCENTAGE) IN THE LEFT HEMISPHERE
CONTROL	**4**		**6**	
1. Lateral Fissure (LF)		**2 (50.0)**		**1 (16.7)**
1. Inferior Frontal Sulcus (IFS)		**1 (25.0)**		**2 (33.3)**
1. IFS and LF		**1 (25.0)**		**0**
2. Any other sulcus		**0**		**1 (16.7)**
3. No other sulcus		**0**		**2 (33.3)**
CASE	**0**		**1**	
1. IFS and LS		**0**		**1 (100)**

3.2.2.2 THE INFERIOR FRONTAL SULCUS

The four pertinent features examined for the inferior frontal sulcus were: the pattern of the sulcus as a whole; the connections of the posterior end of the sulcus; the total number of branches into the frontal operculum; and the existence of the accessory sulci (opercular and triangular) as branches.

The three predominating patterns, in both hemispheres, and in the control- and case-categories, of the inferior frontal sulcus (see Table 3.18 on pg 146) were: interrupted with two segments (Fig 3.13 on pg 141) and interrupted with three segments (Fig 3.12 on pg 139), followed by continuous (Figs 3.1 on pg 116).

The posterior end of the inferior frontal sulcus, was found to be predominantly connected to the single inferior precentral sulcus [see Tables 3.19 (on pg 147), and Fig 3.1 (on pg 116)]. It was also found to have a connection to the inferior part of the anterior precentral sulcus, in the left hemisphere (control) only.

Only rarely did the inferior frontal sulcus, not send a branch into the frontal operculum (see Table 3.20 on pg 147). It frequently had accessory sulci as branches (see Table 3.21 on pg 148 and Fig 3.12 on pg 139). Branches other than the accessory sulci occurred: at the same vertical level as the anterior rami [in which case they were not recorded as accessory sulci (see Fig 3.4 (b) on pg 119)]; or as branches into the pars orbitalis.

Table 3.18: The pattern of the inferior frontal sulcus as a whole.

PATTERN OF THE INFERIOR FRONTAL SULCUS	n	FREQUENCY (PERCENTAGE) IN THE RIGHT HEMISPHERE	n	FREQUENCY (PERCENTAGE) IN THE LEFT HEMISPHERE
CONTROL	**64**		**64**	
1. A continuous sulcus		**15 (23.4)**		**22 (34.4)**
2. Interrupted (2 segments)		**29 (45.3)**		**24 (37.5)**
3. Interrupted (3 segments)		**18 (28.1)**		**14 (21.9)**
4. Interrupted (4 segments)		**2 (3.1)**		**4 (6.3)**
CASE	**44**		**45**	
1. A continuous sulcus		**6 (13.6)**		**8 (17.8)**
2. Interrupted (2 segments)		**18 (40.9)**		**20 (44.4)**
3. Interrupted (3 segments)		**18 (40.9)**		**11 (24.4)**
4. Interrupted (4 segments)		**2 (4.5)**		**5 (11.1)**
5. Interrupted (5 segments)		**0**		**1 (2.2)**

Table 3.19: The connections of the posterior end of the inferior frontal sulcus with the inferior precentral sulcus (IPRCS) or inferior precentral sulcus anterior ($IPRCS_a$):

CONNECTIONS OF THE INFERIOR FRONTAL SULCUS POSTERIORLY WITH:	n	FREQUENCY (PERCENTAGE) IN THE RIGHT HEMISPHERE	n	FREQUENCY (PERCENTAGE) IN THE LEFT HEMISPHERE
CONTROL	64		65	
1. IPRCS		43 (67.2)		57 (87.8)
2. $IPRCS_a$		0		2 (3.1)
3. No connection with IPRCS or $IPRCS_a$		21 (32.8)		6 (9.2)
CASE	45		45	
1. IPRCS		34 (75.6)		37 (82.2)
2. No connection with IPRCS or $IPRCS_a$		11 (24.4)		8 (17.8)

Table 3.20: The total number of branches of the inferior frontal sulcus into the frontal operculum.

TOTAL NUMBER OF INFERIOR BRANCHES OF THE INFERIOR FRONTAL SULCUS	n	FREQUENCY (PERCENTAGE) IN THE RIGHT HEMISPHERE	n	FREQUENCY (PERCENTAGE) IN THE LEFT HEMISPHERE
CONTROL	63		63	
1. One		11 (17.5)		11 (17.5)
2. Two		19 (30.2)		23 (36.5)
3. Three		25 (39.7)		20 (31.7)
4. Four		7 (11.1)		7 (11.1)
5. Five		0		1 (1.6)
6. None		1 (1.6)		1 (1.6)
CASE	44		45	
1. One		12 (27.3)		6 (13.3)
2. Two		14 (31.8)		15 (33.3)
3. Three		11 (25.0)		20 (44.4)
4. Four		7 (15.9)		2 (4.4)
5. Five		0		1 (2.2)
6. None		0		1 (2.2)

Table 3.21: The incidence of the accessory sulci as branches of the inferior frontal sulcus (including notches).

ACCESSORY SULCI AS BRANCHES OF THE INFERIOR FRONTAL SULCUS	n	FREQUENCY (PERCENTAGE) IN THE RIGHT HEMISPHERE	n	FREQUENCY (PERCENTAGE) IN THE LEFT HEMISPHERE
CONTROL				
1. Opercular sulcus as a branch	**64**	**28 (43.8)**	**64**	**16 (25.0)**
2. Triangular sulcus as a branch	**64**	**44 (68.8)**	**64**	**47 (73.4)**
CASE				
1. Opercular sulcus as a branch	**45**	**21 (46.7)**	**45**	**19 (42.2)**
2. Triangular sulcus as a branch		**36 (80.0)**		**34 (75.6)**

3.2.3 REPORT ON THE SULCI OF THE FRONTAL OPERCULUM

This section addreses the following question posed in Chapter Two:

- What are the incidences of the pertinent features of the major- and accessory- sulci [see Figs 1.7, pg 15 and 1.12, pg 43; as well as section 2.8.2 (e-h), pages 93 - 96] in the frontal opercula of both cerebral hemispheres, for ungrouped data?

Note *that ungrouped data* refers to data prior to its grouping according to either the types of sulcal connections, or the patterns of the anterior rami.

3.2.3.1 REPORT ON THE MAJOR SULCI OF THE FRONTAL OPERCULUM

The three pertinent features that were examined for each of the sulci of the frontal operculum were, in general: the frequency of occurrence of the sulci, the shape of the sulci; and the connections of the sulci. The location of the anterior horizontal ramus was also examined. Note that the features of the stem of the anterior rami were not explored, as it generally occurred as a small and straight sulcus.

(a) THE ANTERIOR ASCENDING RAMUS

The anterior ascending ramus appeared to be a very constant sulcus in the frontal operculum [see Table 3.22 on pg 150; and Fig 3.1 (on pg 116), Fig 3.15 and Fig 3.16 (on pg 152]. It was absent to the same extent (although very rarely) in both hemispheres in the control category. It was found to be absent in the left hemisphere only, in the case category (see Fig 3.5 on pg 120).

Seven shapes were observed for the anterior ascending ramus. These were: straight, concave anteriorly, concave posteriorly, concave superiorly, concavo-convex, concavo-concave, and curvilinear. Its predominant shape was straight, followed by concave anteriorly and concave posteriorly in both hemispheres and in the control- and case categories (see Table 3.23 on pg 153, and Fig 3.14 on pg 151). Note that the curvatures ranged from slight to pronounced.

The primary connections of the anterior ascending ramus, were either to the lateral sulcus only (Fig 3.1 on pg 116) or to the stem of the anterior rami only (Fig 3.9 A and B no pg 125), in both hemispheres and in the control- and case categories (see Table 3.24 on pg 154). The connection of the anterior ascending ramus to the Inferior Frontal Sulcus (see Fig 3.16 on pg 152) was not observed in the case category. However, a new connection was observed in the case category, that of the anterior ascending ramus with the inferior frontal sulcus, via the triangular sulcus. Other connections included those of the anterior ascending ramus to both the: Stem and the Opercular sulcus; Lateral Fissure and the Opercular sulcus [see Fig 3.14 (c) on pg 151]; Lateral Fissure and the Inferior Precentral Sulcus.

Table 3.22: The frequency of occurrence of the Anterior Ascending Ramus (AAR).

FREQUENCY OF OCCURRENCE OF THE AAR	n	FREQUENCY (PERCENTAGE) IN THE RIGHT HEMISPHERE	n	FREQUENCY (PERCENTAGE) IN THE LEFT HEMISPHERE
CONTROL	**65**		**65**	
1. Presence		**64 (98.5)**		**64 (98.5)**
2. Absence		**1 (1.5)**		**1 (1.5)**
CASE	**45**		**45**	
1. Presence		**44 (97.8)**		**45 (100)**
2. Absence		**1 (2.2)**		**0**



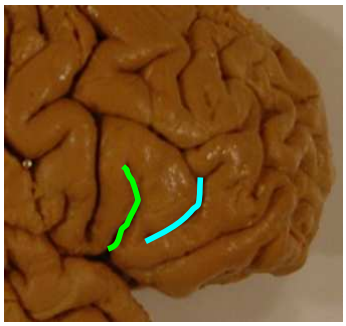

Figure 3.14 (a)

The anterior ascending ramus (green) and the sulcus of the pars triangularis (blue) are concave posteriorly. The head of the office pin is in the central fissure.



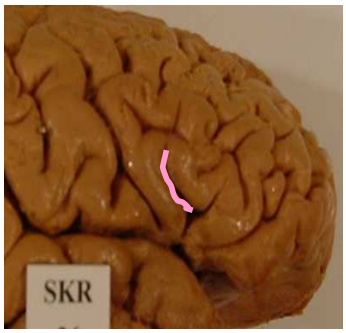

Figure 3.14 (b)

The anterior ascending ramus (pink) is more or less concave superiorly, most of it faces the inferior frontal sulcus. The head of the office pin is in the central fissure.



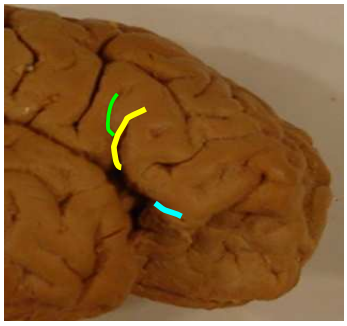

Figure 3.14 (c)

The anterior horizontal ramus (blue) is straight, the anterior ascending ramus (yellow) is concave anteriorly, as well as the opercular sulcus (green). The head of the office pin is in the central fissure.



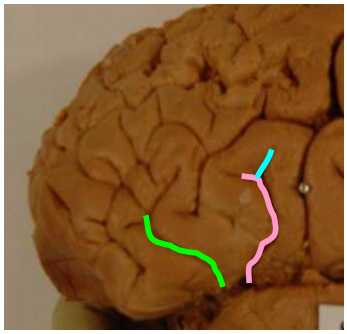

Figure 3.14 (d)

The head of the office pin is in the precentral sulcus. The anterior ascending-(pink)and the anterior horizontal- (green) rami are concavoconvex. The opercular sulcus is diagonally disposed.

Figure 3.14 Selected shapes of sulci in the frontal operculum. The selected sulci have been traced in each of the right hand pictures only, so as to enable comparison with the corresponding sulci in the left hand pictures.

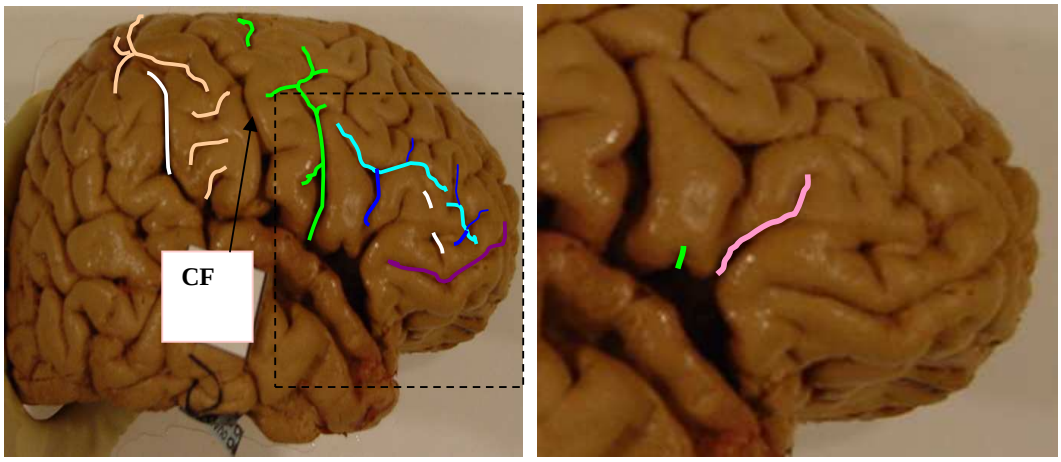

Figure 3.15 The predominance of the anterior horizontal ramus over the anterior ascending ramus.

In the Figure on the left: the upturned end of the lateral fissure (white) is followed successively, from posterior to anterior, by the postcentral sulcus (peach), the central fissure (CF), and the precentral sulcus (green). The two- segment form of the inferior frontal sulcus (light blue) has three superior branches and two inferior branches (dark blue). The pars orbitalis shows a posterior incipient sulcus (white) and an anterior dimple (white). The ventrorostral boundary of the pars orbitalis is marked by the frontomarginal sulcus (purple). The selected area in the Figure on the left has been expanded in the Figure on the right to demonstrate the existence of the anterior ascending ramus (green) as a notch. The anterior horizontal ramus therefore predominates over the anterior ascending ramus. Note that a sulcus of the pars triangularis descends between the two anterior rami.

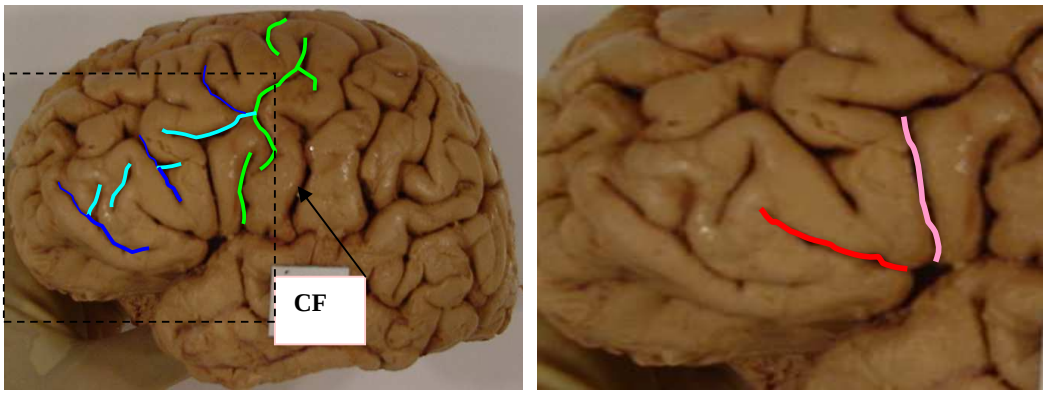

Figure 3.16 A Connection of the anterior ascending ramus with the inferior frontal sulcus (IFS). In the Figure on the left, the precentral sulcus is highlighted in green and the four segment IFS in light blue. The IFS has three superior and two inferior branches (dark blue). The selected area in the Figure on the left has been expanded in the Figure on the right in order to highlight the conection of the anterior ascending ramus (pink) with the IFS. This is in contrast to the notch depicted in Fig 3.15 above. The anterior horizontal ramus (red in the Figure on the right) is almost as long.

Table 3.23: The Shape of the Anterior Ascending Ramus (AAR) as a whole.

SHAPE OF THE AAR	n	FREQUENCY (PERCENTAGE) IN THE RIGHT HEMISPHERE	n	FREQUENCY (PERCENTAGE) IN THE LEFT HEMISPHERE
CONTROL	**64**		**64**	
1. Straight		**30 (46.9)**		**32 (50.0)**
2. Concave anteriorly		**13 (20.3)**		**13 (20.3)**
3. Concave posteriorly		**14 (21.9)**		**13 (20.3)**
4. Concave superiorly		**1 (1.6)**		**0**
5. Concavo-convex		**5 (7.8)**		**5 (7.8)**
6. Concavo-concave		**1 (1.6)**		**1 (1.6)**
CASE	**44**		**45**	
1. Straight		**20 (45.5)**		**18 (40.0)**
2. Concave anteriorly		**13 (29.5)**		**10 (22.2)**
3. Concave posteriorly		**8 (18.2)**		**10 (22.2)**
4. Concave superiorly		**1 (2.3)**		**0**
5. Concavo-convex		**1 (2.3)**		**6 (13.3)**
6. Concavo-concave		**0**		**1 (2.2)**
7. Curvilinear		**1 (2.3)**		**0**

(b) THE ANTERIOR HORIZONTAL RAMUS

The anterior horizontal ramus also appears to be a very constant sulcus in the frontal operculum. It was not absent in the control category, but was very rarely absent in the left hemisphere only, in the case category (see Table 3.25 on pg 154). The frequency of its location: on the lateral surface (Fig 3.1 on pg 116); or at the orbital margin (Fig 3.17 on pg 157); or on the orbital surface (Fig 3.18 on pg 157) of the frontal lobe, varied (see Table 3.25 on pg 154). It was located predominantly on the lateral surface in both hemispheres in the control category. Its location at the orbital margin, was more likely to be seen in the left

Table 3.24: The connections of the Anterior Ascending Ramus (AAR).

CONNECTIONS OF THE AAR WITH:	n	FREQUENCY (PERCENTAGE) IN THE RIGHT HEMISPHERE	n	FREQUENCY (PERCENTAGE) IN THE LEFT HEMISPHERE
CONTROL	**64**		**64**	
1. Stem of (AAR and AHR) only		**22 (34.4)**		**25 (39.1)**
2. Lateral fissure (LF) only		**35 (54.7)**		**32 (50.0)**
3. Stem and Opercular sulcus		**2 (3.1)**		**0**
4. LF and Opercular sulcus		**5 (7.8)**		**5 (7.8)**
5. LF and the Inferior Frontal Sulcus		**0**		**1 (1.6)**
6. LF and Inferior Precentral Sulcus		**0**		**1 (1.6)**
CASE	**44**		**45**	
1. Stem of (AAR and AHR) only		**10 (22.7)**		**17 (37.8)**
2. Lateral fissure (LF) only		**27 (61.4)**		**17 (37.8)**
3. Stem and Opercular sulcus		**0**		**2 (4.4)**
4. LF and Opercular sulcus		**6 (13.6)**		**9 (20.0)**
5. Other		**1 (2.3)**		**0**

Table 3.25: The frequency of occurrence and location of the Anterior Horizontal Ramus (AHR).

FREQUENCY OF OCCURRENCE OF THE AHR	n	FREQUENCY (PERCENTAGE) IN THE RIGHT HEMISPHERE	n	FREQUENCY (PERCENTAGE) IN THE LEFT HEMISPHERE
CONTROL	**65**		**65**	
1. Present on lateral surface		**27 (41.5)**		**31 (47.7)**
2. Present at orbital margin		**19 (29.2)**		**24 (36.9)**
3. Present on orbital surface		**19 (29.2)**		**10 (15.4)**
4. Absent		**0**		**0**
CASE	**45**		**45**	
1. Present on lateral surface		**15 (33.3)**		**14 (31.1)**
2. Present at orbital margin		**14 (31.1)**		**22 (48.9)**
3. Present on orbital surface		**16 (35.6)**		**8 (17.8)**
4. Absent		**0**		**1 (2.2)**

hemisphere, in the control- and case- categories. Its location on the orbital surface, on the other hand, was more likely to be seen in the right hemisphere, in the control- and case-categories.

Table 3.26: The shape of the Anterior Horizontal Ramus (AHR) as a whole.

SHAPE OF THE AHR	n	FREQUENCY (PERCENTAGE) IN THE RIGHT HEMISPHERE	n	FREQUENCY (PERCENTAGE) IN THE LEFT HEMISPHERE
CONTROL	**65**		**65**	
1. Straight		**48 (73.8)**		**36 (55.4)**
2. Concave anteriorly		**1 (1.5)**		**5 (7.7)**
3. Concave posteriorly		**4 (6.2)**		**9 (13.8)**
4. Concave superiorly		**0**		**6 (9.2)**
5. Concave inferiorly		**1 (1.5)**		**3 (4.6)**
6. Concave medially		**6 (9.2)**		**2 (3.1)**
7. Concavo-convex		**5 (7.7)**		**4 (6.2)**
CASE	**45**		**44**	
1. Straight		**31 (68.9)**		**17 (38.6)**
2. Concave anteriorly		**1 (2.2)**		**3 (6.8)**
3. Concave posteriorly		**6 (13.3)**		**9 (20.5)**
4. Concave superiorly		**4 (8.9)**		**5 (11.4)**
5. Concave inferiorly		**0**		**4 (9.1)**
6. Concavo-convex		**3 (6.7)**		**6 (13.6)**

Seven shapes of the anterior horizontal ramus were observed. These were: straight, concave anteriorly, concave posteriorly, concave concave superiorly, concave inferiorly, concave medially, and concavo-convex. The shape of concave medially was not observed in the case category. The predominant shape of the anterior horizontal ramus was straight in both

hemispheres and in the control- and case- categories (see Table 3.26 on pg 155. Fig 3.14 on page 151 shows a few selected shapes). Note that the curvatures ranged from slight to pronounced.

Table 3.27: The connections of the Anterior Horizontal Ramus

CONNECTIONS OF THE AHR WITH:	n	PERCENTAGE IN THE RIGHT HEMISPHERE	n	PERCENTAGE IN THE LEFT HEMISPHERE
CONTROL	**65**		**65**	
1. Stem only		**24 (36.9)**		**24 (36.9)**
2. Lateral fissure (LF) only		**38 (58.5)**		**37 (56.9)**
3. Stem and Frontorbital sulcus		**0**		**1 (1.5)**
4. LF and Frontorbital sulcus		**3 (4.6)**		**2 (3.1)**
5. Frontomarginal sulcus		**1 (1.5)**		**0**
6. LF and Inferior Frontal sulcus		**0**		**1 (1.5)**
CASE	**45**		**44**	
1. Stem only		**11 (24.4)**		**20 (45.5)**
2. Lateral fissure (LF) only		**34 (75.6)**		**23 (52.3)**
3. LF and Inferior Frontal sulcus		**0**		**1 (2.3)**

Six connections were observed for the anterior horizontal ramus, that with the: lateral fissure stem of the anterior rami, stem and frontoorbital sulcus, lateral fissure and frontoorbital sulcus, frontomarginal sulcus, as well as with the lateral fissure and the inferior frontal sulcus. The predominant connection of the anterior horizontal ramus was to

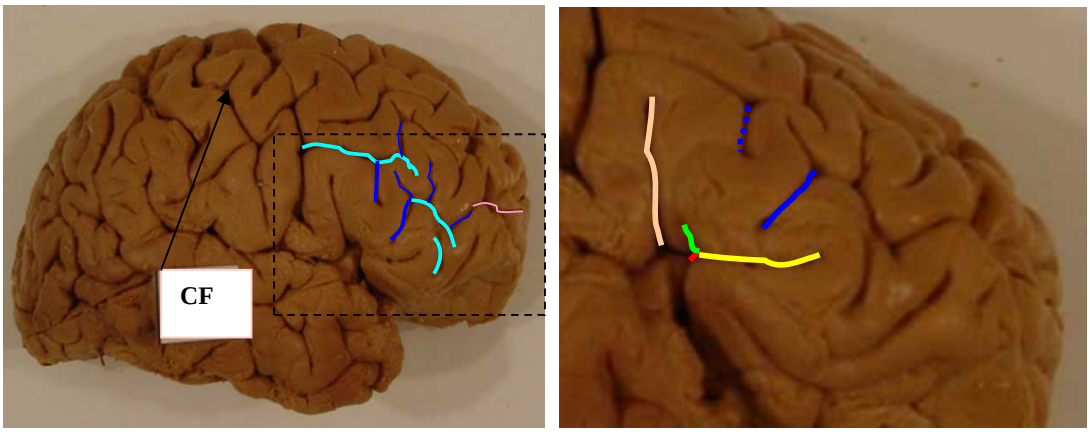

Figure 3.17 Location of the anterior horizontal ramus at the orbital margin. In the Figure on the left, the posterior segment of the inferior frontal sulcus (IFS, light blue) has a connection with the inferior precentral sulcus. The IFS as a whole has three superior branches and two inferior branches. Note that the anteriormost superior branch of the IFS is continuous with the frontomarginal sulcus (pink). The selected area in the Figure on the left has been slightly rotated and expanded in the Figure on the right, in order to demonstrate the anterior rami more clearly. There is a stem (red), an anterior ascending ramus (green), and an anterior horizontal ramus (yellow). Note that the anterior ascending ramus is barely visible in the figure on the left. The posterior descending branch from the IFS (broken blue in the Figure on right) occurs at approximately the same vertical level as the anterior ascending ramus, and is therefore classified as a boundary sulcus. The anterior descending branch of the IFS is a sulcus of the pars triangularis. The sulcus that appeared as though it was the anterior ascending ramus in the Figure on the left is now classified, as a sulcus of the pars opercularis (peach in the Figure on the right).

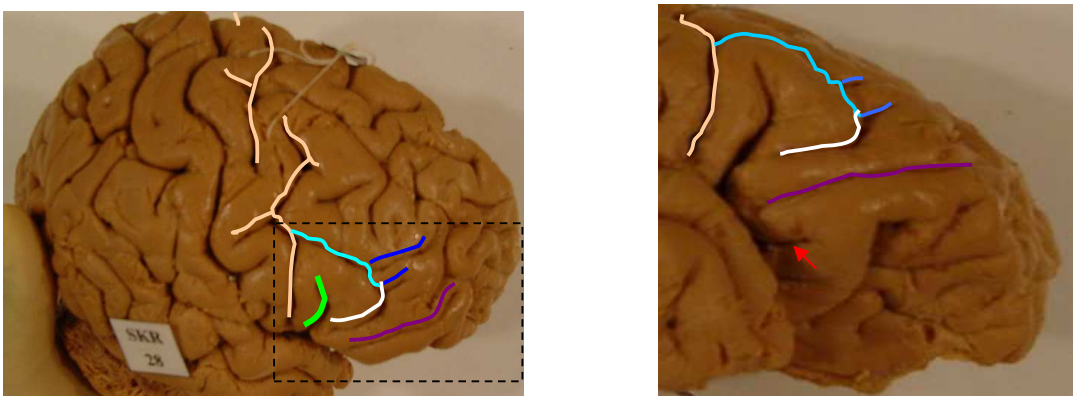

Figure 3.18 Location of the anterior horizontal ramus (AHR) on the orbital surface. The Figure on the left has been rotated and expanded in the Figure on the right in order to demonstrate the AHR. In both Figures, the inferior frontal sulcus (IFS, light blue) has a posterior connection with the inferior precentral sulcus (peach). The anterior ascending ramus (green in the Figure on left) is on the lateral surface, while the AHR (red arrow in Figure on the right) is on the orbital surface. The sulcus of the pars triangularis (white) and the frontomarginal sulcus (purple) descend into the pars triangularis.

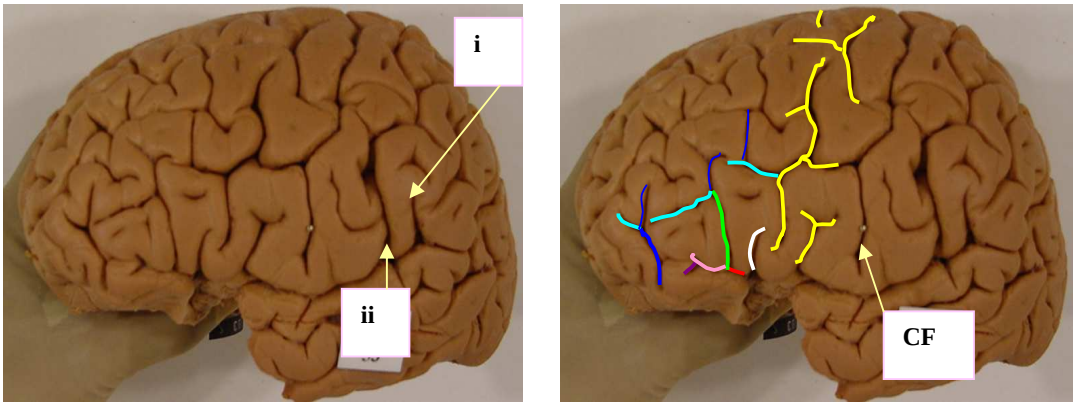

Figure 3.19 Infrequent connections of the anterior rami. The postcentral sulcus (ii) is anterior to the upturned end of the lateral fissure (i). The head of an office pin is visible in the central fissure (CF). The precentral sulcus (yellow) is highlighted in the Figure on the right. The inferior frontal sulcus (IFS, light blue) has: three segments, three superior branches and one inferior branch. There is a short stem of the anterior rami (red). The anterior ascending ramus is connected to both the stem and the IFS. The anterior horizontal ramus (pink) is connected to both the stem and the fronto-orbital sulcus (purple). The opercular sulcus (white) is concave posteriorly. [Note that there are two anterior incipient sulci and one posterior dimple, in the inferior frontal gyrus].

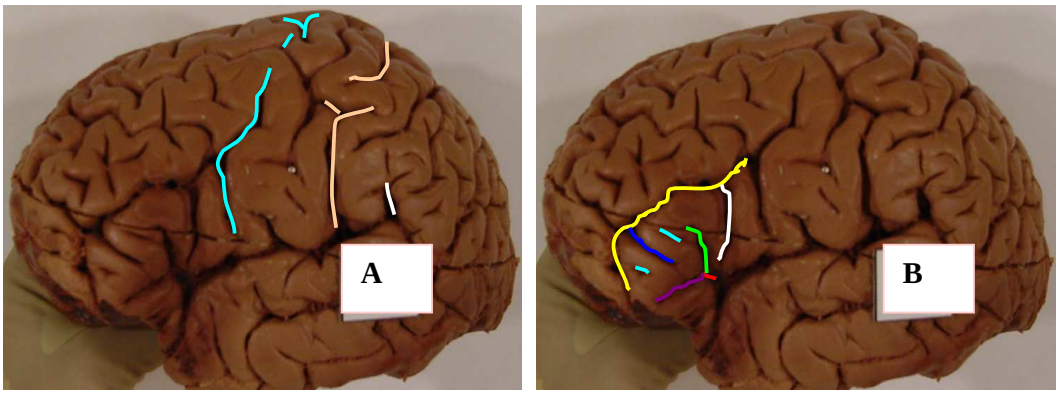

Figure 3.20 Accessory Sulci.

In Figure A, the head of an office pin can be seen in the central fissure. The following sulci are highlighted: upturned end of lateral fissure (white); postcentral sulcus (peach); precentral sulcus (light blue). In Figure B, two accessory sulci arise from the inferior frontal sulcus (IFS), which is yellow in colour. The opercular sulcus (white) descends between the anterior ascending ramus and the inferior precentral sulcus, from the IFS. Two small measurable dimples (light blue) lie unattached in the pars triangularis (on either side of the sulcus of the pars triangularis descending from the IFS). All three lie between the anterior ascending ramus (green) and the anterior horizontal ramus (purple). In this specimen, there are therefore four accessory sulci: three triangular and one opercular.

the lateral fissure, followed by the connection to the stem. The connections of the anterior horizontal ramus to the fronto-orbital and frontomarginal sulci were not observed in the case category.

3.2.3.2 REPORT ON THE ACCESSORY SULCI OF THE FRONTAL OPERCULUM

(a) THE OPERCULAR SULCUS (SULCI)

The opercular sulcus was present as either a single (sole) sulcus or as a double sulcus (see Fig 3.20 (on pg 158) and Fig 3.21 (on pg 160) respectivey, as well as Table 3.28 below) in both hemispheres and in the control- and case- categories. The opercular sulcus was otherwise absent (see Fig 3.1 on pg 116).

Table 3.28: The frequency of occurrence of the Opercular sulcus and the number of such sulci when it is present as more than one sulcus

FREQUENCY OF OCCURRENCE OF THE SOLE- AND MULTIPLE-OPERCULAR SULCI	n	FREQUENCY (PERCENTAGE) IN THE RIGHT HEMISPHERE	n	FREQUENCY (PERCENTAGE) IN THE LEFT HEMISPHERE
CONTROL	**65**	**-**	**65**	**-**
1. Present as one sulcus		**30 (46.2)**		**27 (41.5)**
2. Present as two sulci		**10 (15.4)**		**7 (10.8)**
3. Absent		**25 (38.5)**		**31 (47.7)**
CASE	**44**	**-**	**45**	**-**
1. Present as one sulcus		**25 (56.8)**		**22 (48.9)**
2. Present as two sulci		**5 (11.4)**		**10 (22.2)**
3. Absent		**14 (31.8)**		**13 (28.9)**

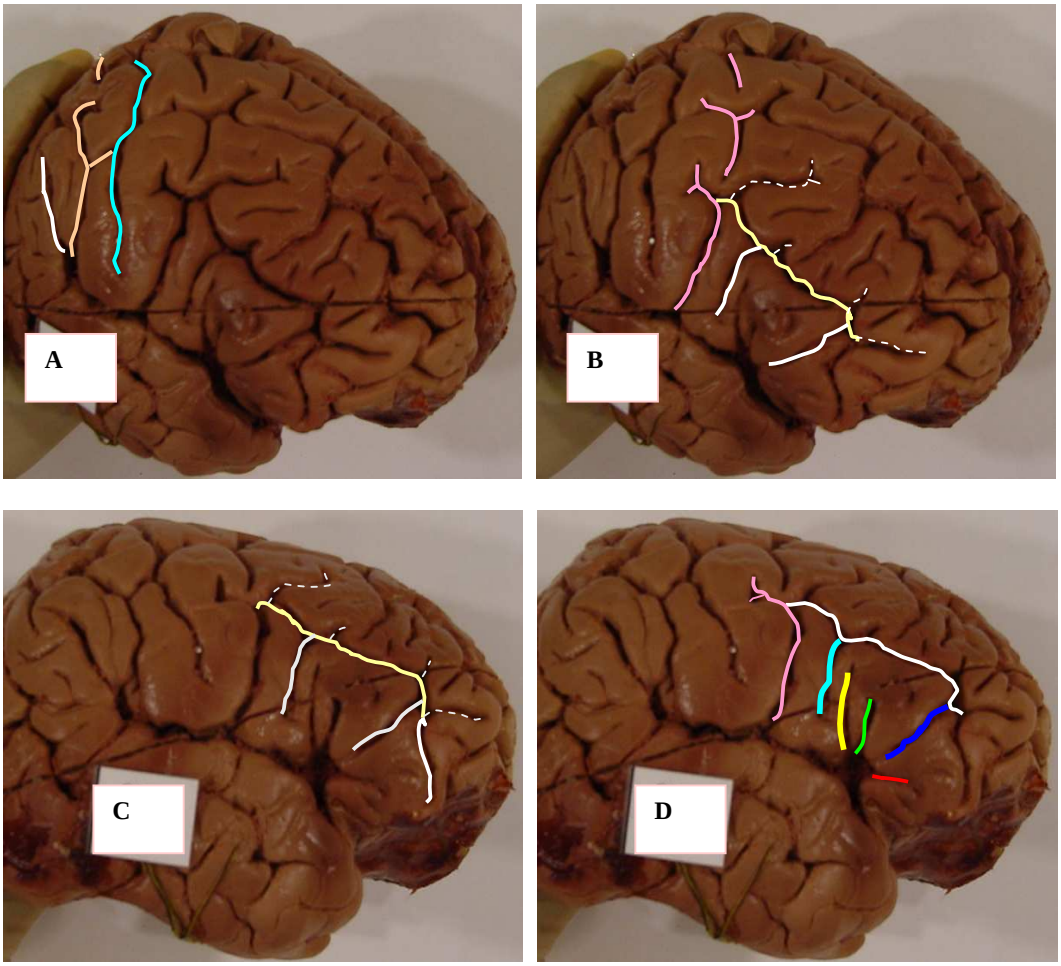

Figure 3.21 A Case of Double Opercular Sulci and a Single Triangular Sulcus. Figs A-D demonstrate different features of the same specimen.

In Figure A, the orientating sulci are: the upturned end of the lateral fissure (white); the postcentral sulcus (peach); and the central fissure (light blue).

In Figure B, the precentral sulcus is highlighted in pink. The continuous inferior frontal sulcus (light yellow) has four superior branches (dashed white) and three inferior banches (solid white).

In Figure C, the specimen has been rotated in order to expose the frontal operculum more fully. Note the orbital origin of the anterior horizontal ramus.

In Figure D, the major and accessory sulci are highlighted. The major sulci are the anterior ascending ramus (AAR, green in colour) and the anterior horizontal ramus (AHR, red in colour). There are two accessory sulci between the inferior precentral sulcus (pink) and the AAR (green). The posterior opercular sulcus (light blue) arises from the inferior frontal sulcus (white). The anterior opercular sulcus (yellow) does not quite reach the lateral fissure. It therefore lies unattached (free) in the pars opercularis. The sulcus of the pars triangularis (accessory sulcus, dark blue) descends from the inferior frontal sulcus between the anterior ascending ramus (green) and the anterior horizontal ramus (red).

Five shapes were observed for the sole opercular sulcus in both hemispheres and in the control category. These were: straight, diagonal, concave anteriorly, concave posteriorly, and concavo-convex. An additional shape, concavo-concave was present in the case category. The predominant shapes of the sole opercular sulcus (see Table 3.29 below) were:

- Concave anteriorly [Fig 3.14 (c) on pg 151], in the right hemisphere in the control- and case- categories, and
- Diagonal [Fig 3.14 (d) on pg 151] followed by concave anteriorly in the left hemisphere, in the control- and case- categories.

Note that the curvatures ranged from slight to pronounced.

Table 3.29: The shape of the Opercular sulcus when it is present alone.

SHAPE OF THE SOLE OPERCULAR SULCUS	n	FREQUENCY (PERCENTAGE) IN THE RIGHT HEMISPHERE	n	FREQUENCY (PERCENTAGE) IN THE LEFT HEMISPHERE
CONTROL	**30**	**-**	**27**	**-**
1. Straight		**2 (6.7)**		**5 (18.5)**
2. Diagonal		**8 (26.7)**		**9 (33.3)**
3. Concave anteriorly		**17 (56.7)**		**6 (22.2)**
4. Concave posteriorly		**1 (3.3)**		**4 (14.8)**
6. Concavo-convex		**2 (6.7)**		**3 (11.1)**
CASE	**25**	**-**	**22**	**-**
1. Straight		**5 (20.0)**		**2 (9.1)**
2. Diagonal		**4 (16.0)**		**10 (45.5)**
3. Concave anteriorly		**11 (44.0)**		**8 (36.4)**
4. Concave posteriorly		**2 (8.0)**		**2 (9.1)**
6. Concavo-convex		**2 (8.0)**		**0**
7. Concavo-concave		**1 (4.0)**		**0**

The connections observed for the sole opercular sulcus (see Table 3.31 on pg 164) in the control category were to the:

- Lateral Fissure only [see Fig 3.19 on pg 158]
- Anterior Ascending Ramus only [see Fig 3.14 (c) and (d) on pg 151]
- Inferior Frontal sulcus only [see Fig 3.3 (b) on pg 118]
- Stem only
- Inferior Precentral Sulcus only
- Anterior Ascending Ramus and to the Inferior Frontal sulcus
- Inferior Frontal sulcus and the Lateral Fissure [see Fig 3.12 (d) on pg 139]
- Stem and the Inferior Frontal sulcus
- Unconnected (Free) in the pars opercularis [see Fig 3.21 (d) on pg 160]

The connection of the sole opercular sulcus to the stem only was not observed in the case group. But, a new connection was reported for the opercular sulcus in the case category. This was to the Intermediate frontal sulcus. The predominant connection in the control category was to the inferior frontal sulcus, in both hemispheres. Also, the opercular sulcus was slightly more likely to be: unconnected (free) in the right hemisphere; and connected to the lateral fissure in the left hemisphere (in the control category). There appeared to be a slightly more even spread of connections for the case category (see Table 3.31 on pg 164).

The small sample numbers for the first- and second- opercular sulci have probably resulted

in a greater variability in the incidence of their shapes and connections as presented in Tables 3.30 (on pg 163) and 3.32 (on pg 165).

Table 3.30: The shape of the Opercular sulcus when it was present as two sulci, see Fig , pg . [**First Opercular (Op_1), Second Opercular (Op_2).**

SHAPE OF THE DOUBLE OPERCULAR SULCI:	n	FREQUENCY (PERCENTAGE) IN THE RIGHT HEMISPHERE	n	FREQUENCY (PERCENTAGE) IN THE LEFT HEMISPHERE
CONTROL	10	-	7	-
1. Straight First Opercular (Op_1)		3 (30.0)		4 (57.1)
2. Straight Second Opercular (Op_2)		3 (30.0)		2 (28.6)
3. Op_1 diagonal in shape		2 (20.0)		1 (14.3)
4. Op_2 diagonal in shape		3 (30.0)		2 (28.6)
3. Op_1 concave anteriorly		2 (20.0)		1 (14.3)
4. Op_2 concave anteriorly		1 (10.0)		2 (28.6)
5. . Op_1 concave posteriorly		3 (30.0)		0
6. Op_2 concave posteriorly		2 (20.0)		1 (14.3)
7. Op_2 concave superiorly		1 (10.0)		0
8. Op_1 concavoconvex		0		1 (14.3)
CASE	-	-	-	-
1. Straight First Opercular (Op_1)	5	0	10	2 (20.0)
2. Straight Second Opercular (Op_2)	5	1 (20.0)	10	1 (10.0)
3. Op_1 diagonal in shape	5	1 (20.0)	10	2 (20.0)
4. (Op_2) diagonal in shape	5	2 (40.0)	10	2 (20.0)
3. Op_1 concave anteriorly	5	2 (40.0)	10	3 (30.0)
4. (Op_2) concave anteriorly	5	0	10	6 (60.0)
5. . Op_1 concave posteriorly	5	0	10	1 (10.0)
6. (Op_2) concave posteriorly	5	2 (40.0)	10	1 (10.0)
7. Op_1 concave superiorly	5	1 (20.0)	10	0
8. Op_1 concavo-convex	5	1 (20.0)	10	1 (10.0)
9. Op_1 concavo-concave	5	0	10	1 (10.0)

Table 3.31: The connections of the opercular sulcus when it is present alone.

CONNECTIONS OF THE SOLE OPERCULAR SULCUS WITH:	n	FREQUENCY (PERCENTAGE) IN THE RIGHT HEMISPHERE	n	FREQUENCY (PERCENTAGE) IN THE LEFT HEMISPHERE
CONTROL	**30**	**-**	**27**	**-**
1. Lateral Fissure (LF)		**2 (6.7)**		**7 (25.9)**
2. AAR[11]		**4 (13.3)**		**4 (14.8)**
3. Inferior Frontal sulcus (IFS)		**15 (50.0)**		**9 (33.3)**
4. AAR and IFS		**1 (3.3)**		**0**
5. IFS and LF		**0**		**2 (7.4)**
6. Stem		**0**		**1 (3.7)**
7. Stem and IFS		**1 (3.3)**		**0**
8. Inferior Precentral sulcus		**1 (3.3)**		**0**
9. Free (unconnected)		**6 (20.0)**		**4 (14.8)**
CASE	**25**	**-**	**22**	**-**
1. Lateral Fissure (LF)		**5 (20.0)**		**0**
2. AAR		**6 (24.0)**		**6 (27.3)**
3. Inferior Frontal sulcus (IFS)		**5 (20.0)**		**8 (36.4)**
4. AAR and IFS		**1 (4.0)**		**3 (13.6)**
5. IFS and LF		**0**		**1 (4.5)**
6. Stem		**0**		**1 (4.5)**
7. Free (unconnected)		**6 (24.0)**		**3 (13.6)**
8. Stem and IFS		**1 (4.0)**		**0**
8. Intermediate Frontal sulcus		**1 (4.0)**		**0**

[11] AAR is the anterior ascending ramus

Table 3.32: The connections of the Opercular sulcus when it is present as two sulci [**First Opercular (Op_1), Second Opercular (Op_2).**

CONNECTIONS OF THE FIRST AND SECOND OPERCULAR SULCI WITH:	n	FREQUENCY (PERCENTAGE) IN THE RIGHT HEMISPHERE	n	FREQUENCY (PERCENTAGE) IN THE LEFT HEMISPHERE
CONTROL	10	-	7	-
1. Op_1 and Lateral Fissure		0		0
2. Op_2 and Lateral Fissure		2 (20.0)		2 (28.6)
3. Op_1 and AAR		1 (10.0)		1 (14.3)
4. Op_2 and AAR		3 (30.0)		0
5. Op_1 and Inferior Frontal Sulcus		7 (70.0)		6 (85.7)
6. Op_2 and Inferior Frontal Sulcus		2 (20.0)		1 (14.3)
7. Op_1 and Stem		0		0
8. Op_2 and Stem		1 (10.0)		1 (14.3)
9. Free (unconnected) Op_1		2 (20.0)		0
10. Free (unconnected) Op_2		2 (20.0)		3 (42.9)
CASE	5	-	10	-
1. Op_1 and Lateral Fissure		0		0
2. Op_2 and Lateral Fissure		2 (40.0)		0
3. Op_1 and Anterior Ascending Ramus		1 (20.0)		2 (20.0)
4. Op_2 and Anterior Ascending Ramus		0		1 (10.0)
5. Op_1 and Inferior Frontal Sulcus		2 (40.0)		7 (70.0)
6. Op_2 and Inferior Frontal Sulcus		1 (20.0)		1 (10.0)
7. Op_1 and Stem		0		0
8. Op_2 and Stem		0		2 (20.0)
9. Free (unconnected) Op_1		2 (40.0)		1 (10.0)
10. Free (unconnected) Op_2		2 (40.0)		4 (40.0)
11. Other connections for Op_2		0		2 (20.0)

(b) THE TRIANGULAR SULCI

The triangular sulcus was found to be present as one sulcus (Fig 3.21 on pg 160)[12], or as two sulci [Fig 3.12 (d) on pg 139][13], or as three[14] sulci (Fig 3.20 on pg 158). This sulcus was otherwise absent. The incidences of these sulci are presented in Table 3.33, below.

Table 3.33: The frequency of occurrence of the Triangular sulcus and the number of such sulci when it was present as more than one sulcus.

FREQUENCY OF OCCURRENCE OF THE SOLE- AND MULTIPLE-TRIANGULAR SULCI	n	FREQUENCY (PERCENTAGE) IN THE RIGHT HEMISPHERE	n	FREQUENCY (PERCENTAGE) IN THE LEFT HEMISPHERE
CONTROL	**64**	**-**	**65**	**-**
1. Present as one sulcus		**34 (53.1)**		**36 (55.4)**
2. Present as two sulci		**16 (25.0)**		**16 (24.6)**
3. Present as three sulci		**4 (6.3)**		**5 (7.7)**
4. Absent		**10 (15.6)**		**8 (12.3)**
CASE	**44**	**-**	**45**	**-**
1. Present as one sulcus		**23 (52.3)**		**23 (51.1)**
2. Present as two sulci		**18 (40.9)**		**14 (31.1)**
3. Present as three sulci		**0**		**5 (11.1)**
4. Absent		**3 (6.8)**		**3 (6.7)**

[12] sole triangular sulcus (when the triangular sulcus was present as one sulcus
[13] anterior- and posterior- triangular sulci, when the triangular sulcus was present as two sulci
[14] anterior-, middle-, and posterior- triangular sulci, when the triangular sulcus was present as three sulci

Four shapes were observed for the sole triangular sulcus. These were straight, concave anteriorly, concave posteriorly, and concavo-convex, in both hemispheres and in the control- and case- categories. An additional shape, the 'Y' shape was seen in the case category. The predominant shape for these sulci appears to be straight (see Tables 3.34, 3.35, and 3.36 on pages 167, 168, and 169 respectively) in both hemispheres as well as in the control- and case- categories. The exception is the middle triangular sulcus in the right hemispheres of the control- and case categories. There is an even spread of shapes for the middle triangular sulcus in the right hemisphere in the control category (this sulcus is absent in the right hemisphere in the case category). Note that the curvatures ranged from slight to pronounced.

Table 3.34: The shape of the Triangular sulcus when it was present alone.

SHAPE OF THE SOLE TRIANGULAR SULCUS	n	FREQUENCY (PERCENTAGE) IN THE RIGHT HEMISPHERE	n	FREQUENCY (PERCENTAGE) IN THE LEFT HEMISPHERE
CONTROL	**34**		**36**	
1. Straight		**21 (61.8)**		**26 (72.2)**
2. Concave anteriorly		**4 (11.8)**		**2 (5.6)**
3. Concave posteriorly		**6 (17.6)**		**5 (13.9)**
4. Concavo-convex		**3 (8.8)**		**3 (8.3)**
CASE	**23**	**-**	**23**	**-**
1. Straight		**15 (65.2)**		**16 (69.6)**
2. Concave anteriorly		**2 (8.7)**		**2 (8.7)**
3. Concave posteriorly		**3 (13.0)**		**2 (8.7)**
4. Concavo-convex		**2 (8.7)**		**1 (4.3)**
5. 'Y' shaped		**1 (4.3)**		**2 (8.7)**

Table 3.35: The shape of the Triangular sulcus when it was present as two sulci.

SHAPE OF THE ANTERIOR- AND POSTERIOR- TRIANGULAR SULCI	n	FREQUENCY (PERCENTAGE) IN THE RIGHT HEMISPHERE	n	FREQUENCY (PERCENTAGE) IN THE LEFT HEMISPHERE
CONTROL	**16**	**-**	**16**	**-**
1. Straight Tra[15]		12 (75.0)		13 (81.3)
2. Straight Trp[16]		**12 (75.0)**		**11 (68.8)**
3. Tra concave anteriorly		3 (18.8)		0
4. Trp concave anteriorly		**1 (6.3)**		**0**
5. Trp concave posteriorly		**2 (12.5)**		**5 (31.3)**
6. Tra concavo-convex		1 (6.3)		2 (12.5)
7. Trp concavo-convex		**0**		**0**
8. Tra 'y' shaped		0		1 (6.3)
9. Trp 'y' shaped		**1 (6.3)**		**0**
CASE	**18**	**-**	**14**	**-**
1. Straight Tra		10 (55.6)		8 (57.1)
2. Straight Trp		**14 (77.8)**		**9 (64.3)**
3. Tra concave anteriorly		6 (33.3)		3 (21.4)
4. Trp concave anteriorly		**1 (5.6)**		**1 (7.1)**
5. Tra concave posteriorly		2 (11.1)		2 (14.3)
6. Trp concave posteriorly		**2 (11.1)**		**2 (14.3)**
7. Tra concavo-convex		0		0
8. Trp concavo-convex		**1 (5.6)**		**2 (14.3)**
9. Tra 'y' shaped		0		1 (7.1)

[15] Anterior triangular sulcus
[16] Posterior triangular sulcus

Table 3.36: The shape of the Triangular sulcus when it was present as three sulci.

SHAPE OF THE ANTERIOR-, MIDDLE- AND POSTERIOR-TRIANGULAR SULCI	n	FREQUENCY (PERCENTAGE) IN THE RIGHT HEMISPHERE	n	FREQUENCY (PERCENTAGE) IN THE LEFT HEMISPHERE
CONTROL	**4**	**-**	**5**	**-**
1. Straight Tra		2 (50.0)		4 (80.0)
2. Straight Trm[17]		**1 (25.0)**		**5 (100)**
3. Straight Trp		**2 (50.0)**		**5 (100)**
4. Tra concave anteriorly		1 (25.0)		1 (20.0)
5. Trm concave anteriorly		**1 (25.0)**		**0**
6. Trp concave anteriorly		**0**		**0**
7. Tra concavo-convex		1 (25.0)		0
8. Trm concavo-convex		**1 (25.0)**		**0**
9. Trp concavo-convex		**2 (50.0)**		**0**
10. Trm curvilinear		**1 (25.0)**		**0**
CASE	**0**	**-**	**5**	**-**
1. Straight Tra		0		3 (60.0)
2. Straigt Trm		**0**		**2 (40.0)**
3. Straight Trp		**0**		**3 (60.0)**
4. Tra concave anteriorly		0		1 (20.0)
5. Trm concave anteriorly		**0**		**2 (40.0)**
6. Trm concave posteriorly		**0**		**1 (20.0)**
7. Trp concave posteriorly		**0**		**2 (40.0)**
8. Tra concavo-convex		0		1 (20.0)

[17] Middle triangular sulcus = Trm

The sole triangular sulcus was observed to be: either connected to the inferior frontal sulcus, or a free sulcus, in both hemispheres, as well as in the control- and case- categories. An additional connection (that of sole triangular sulcus to both the Inferior Frontal sulcus and the Anterior Ascending ramus) was observed in the case category. The predominant connection of the sole triangular sulcus was to the inferior frontal sulcus (see Tables 3.37 on pg 171.

The same pattern of connections observed for the sole triangular sulcus, was manifest for the anterior – and posterior- triangular sulci. The exceptions were:

- The connection of the triangular sulci to both the Inferior Frontal Sulcus and the Anterior Ascending Ramus was not observed.
- An additional connection, that of the triangular sulci to the Intermediate Frontal sulcus, was observed (see Table 3.38 on pg 171)].

The predominant pattern of the connections of the triangular sulcus when it was present as three sulci, was that all three were connected to the inferior frontal sulcus (see Table 3.39 on pg 172.

Table 3.37: The connections of the Triangular sulcus when it was present alone.

CONNECTIONS OF THE SOLE TRIANGULAR SULCUS WITH:	n	FREQUENCY (PERCENTAGE) IN THE RIGHT HEMISPHERE	n	FREQUENCY (PERCENTAGE) IN THE LEFT HEMISPHERE
CONTROL	**34**	**-**	**36**	**-**
1. Inferior frontal sulcus (IFS)		**24 (70.6)**		**27 (75.0)**
2. No sulcus		**10 (29.4)**		**9 (25.0)**
CASE	**23**	**-**	**23**	**-**
1. IFS		**18 (78.3)**		**14 (60.9)**
2. IFS to Anterior Ascending ramus		**1 (4.3)**		**0**
3. No sulcus		**4 (17.4)**		**9 (39.1)**

Table 3.38: The connections of the Triangular sulcus when it was present as two sulci.

CONNECTIONS OF THE ANTERIOR- AND POSTERIOR-TRIANGULAR SULCI	n	FREQUENCY (PERCENTAGE) IN THE RIGHT HEMISPHERE	n	FREQUENCY (PERCENTAGE) IN THE LEFT HEMISPHERE
CONTROL	**16**	**-**	**16**	**-**
1. Tra with inferior frontal sulcus		9 (56.3)		11 (68.8)
2. Trp with inferior frontal sulcus		**9 (52.9)**		**14 (87.5)**
3. Tra with intermediate frontal sulcus		1 (6.3)		0
4. Trp with intermediate frontal sulcus		**1 (5.9)**		**0**
5. Tra with no sulcus		6 (37.5)		5 (31.3)
6. Trp with no sulcus (free)		**7 (41.2)**		**2 (12.5)**
CASE	**18**	**-**	**14**	**-**
1. Tra with inferior frontal sulcus		11 (61.1)		10 (71.4)
2. Trp with inferior frontal sulcus		**15 (83.3)**		**12 (85.7)**
3. Tra with intermediate frontal sulcus		1 (5.6)		2 (14.3)
4. Trp with intermediate frontal sulcus		**1 (5.6)**		**0**
5. Tra with no sulcus		6 (33.3)		2 (14.3)
6. Trp with no sulcus (free)		**2 (11.1)**		**2 (14.3)**

Table 3.39: The connections of the Triangular sulcus when it was present as three sulci.

CONNECTIONS OF THE ANTERIOR-, MIDDLE-, AND POSTERIOR- TRIANGULAR SULCUS WITH:	n	FREQUENCY (PERCENTAGE) IN THE RIGHT HEMISPHERE	n	FREQUENCY (PERCENTAGE) IN THE LEFT HEMISPHERE
CONTROL	4	-	5	-
1. Tra with Inferior Frontal sulcus		3 (75.0)		3 (60.0)
2. Trm with Inferior Frontal sulcus		4 (100)		3 (60.0)
3. Trp with Inferior Frontal sulcus		3 (75.0)		3 (60.0)
4. Tra with no sulcus (free)		1 (25.0)		2 (40.0)
5. Trm with no sulcus (free)		0		1 (20.0)
6. Trp with no sulcus (free)		1 (25.0)		2 (40.0)
7. Trm between Intermediate Frontal sulcus and Anterior Horizontal ramus		0		1 (20.0)
CASE	0	-	5	-
1. Tra with Inferior Frontal sulcus		0		4 (80.0)
2. Trm with Inferior Frontal sulcus		0		5 (100)
3. Trp with Inferior Frontal sulcus		0		4 (80.0)
4. Tra with no sulcus (free)		0		1 (20.0)
5. Trp with no sulcus (free)		0		1 (20.0)

3.2.4 REPORT ON THE SULCI OF THE FRONTAL OPERCULUM WITH RESPECT TO DATA GROUPED ACCORDING TO THE TYPES OF CONNECTIONS

This section addresses the following question posed in Chapter Two:

- ***Can the information gathered on the fissures and sulci of the frontal operculum be used to replicate the study of Ebeling et al (1989), as regards the Types of Connections (see section 1.8.1, pg 22 and Fig 1.9, pg 24), in its original form, or in a modified form?***

3.2.4.1 THE MODIFICATION OF THE CRITERIA FOR THE TYPES OF CONNECTIONS

Data gathered on the -orientating sulci, -boundary sulci, -major sulci, and the –accessory sulci were used to:

- Firstly, modify the criteria for the classification of the above descriptive data into the groups that constitute the four Types of Sulcal Connections, and
- Secondly, classify all the specimens (categorised as control and case) into the four modified groups (Types of Sulcal Connections).

The findings (in the present study) on: the precentral sulcus; the accessory sulci; and the different locations of the anterior horizontal ramus led to the modification of the criteria used for the classification of the combinations of sulcal connections. These modifications are summarised in Figures 3.27 (on pg 180) and 3.28 (on pg 181), and listed as follows:

TYPE 1 (see Fig 3.22 on pg 175):

- The anterior ascending ramus preceeds the single inferior precentral sulcus or the inferior part of the anterior precentral sulcus (when the precentral sulcus occurred as two sulci);

- The inferior frontal sulcus has a connection with the inferior precentral sulcus, or the inferior part of the anterior precentral sulcus (when the precentral sulcus occurred as two sulci);

- The inconstant segments include the:

    - Anterior Horizontal Ramus (on the lateral surface of the frontal operculum;
    - Triangular sulcus (sulci) which occur(s) between the Anterior Ascending Ramus and the Anterior Horizontal Ramus, and frequently descends from the Inferior Frontal Sulcus;
    - Connection of the Inferior Precentral Sulcus (sulci) with the Lateral Fissure, and
    - Connection of the Central Fissure with the Lateral Fissure.

TYPE 2 (see Fig 3.23 on pg 176):

- The anterior ascending ramus preceeds the single inferior precentral sulcus or the inferior part of the anterior precentral sulcus (when the precentral sulcus occurred as two sulci);

- There is no connection between the inferior frontal sulcus and the single inferior precentral sulcus, or with the inferior part of the anterior precentral sulcus (when the precentral sulcus occurred as two sulci);

- The inconstant sulcal segments occur as in Type 1.

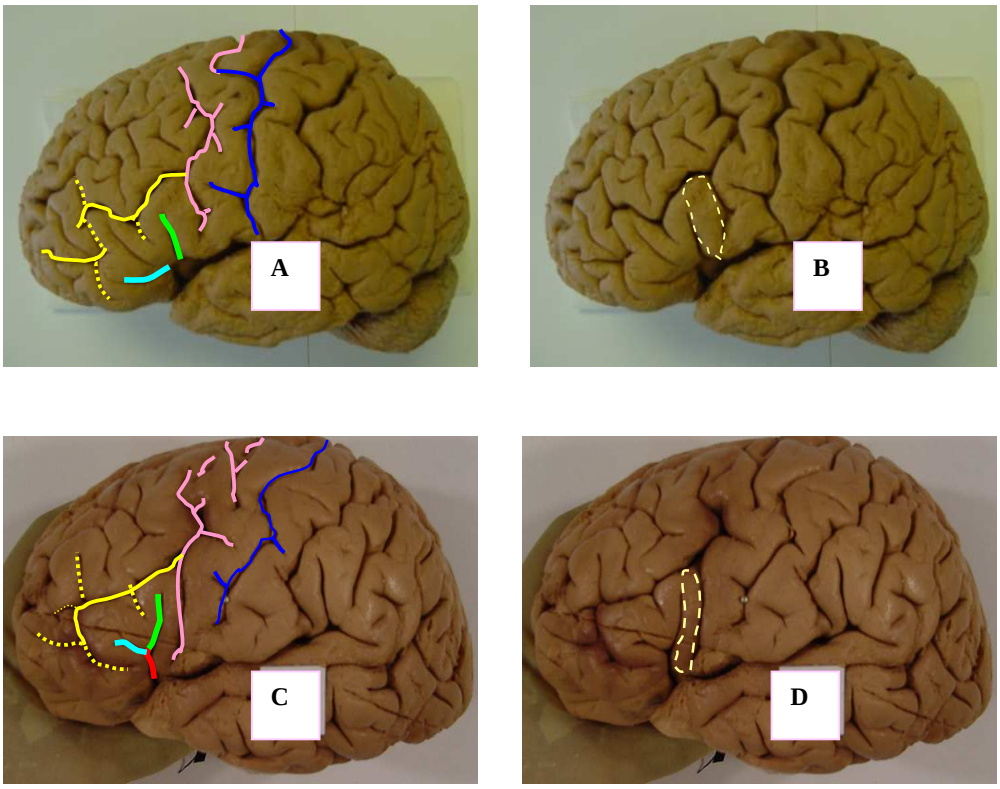

Figure 3.22 Type 1 (of Sulcal Connections) with both 'VU' and 'Y' patterns of the Anterior Rami.

In Figures A and C, the interrupted precentral sulcus (pink) is anterior to the central fissure (CF, dark blue). Note that the posterior end of the inferior frontal sulcus (IFS, highlighted in yellow) is connected to the inferior precentral sulcus. The dashed yellow sulci are the superior and inferior branches of the two IFS. The anterior ascending ramus (green) and the anterior horizontal ramus (light blue) arise separately from the lateral fissure in Figures A and B (same specimen. This constitutes a 'VU' pattern of the anterior rami. The anterior rami arise from a common stem (red) in Figures C and D (same specimen). This constitutes a 'Y' pattern of the anterior rami. In Figures B and D, the selected areas highlight the pars opercularis of Figures A and C respectively. Note that an opercular sulcus is absent.

In the presence of a connection of the IFS with the inferior precentral sulcus and the lack of an opercular sulcus, these specimens were classified as: Type 1, of sulcal connections in the frontal operculum.

There is no connection between: the lateral fissure (LF) and inferior precentral sulcus; LF and CF; LF and postcentral sulcus, in both specimens. A single sulcus of the pars triangularis is present in both specimens.

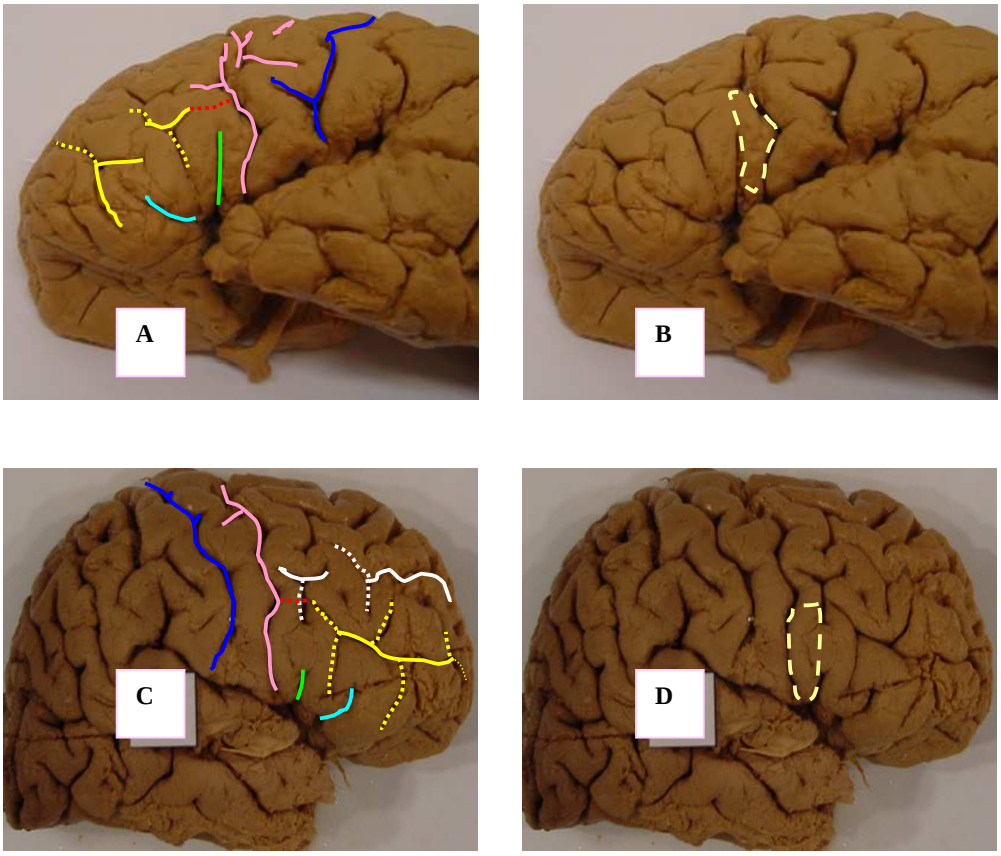

Figure 3.23 Type 2 (of Sulcal Connections) with the VU pattern of the anterior rami.

In Figures A and C, the interrupted precentral sulcus (pink) is anterior to the central fissure (CF, dark blue). Note that the posterior end of the inferior frontal sulcus (IFS, highlighted in yellow) is not connected to the inferior precentral sulcus in either case. The dashed red line completes the superior border of the inferior frontal gyrus in both cases. The dashed yellow sulci are the superior and inferior branches of the two IFS. The anterior ascending ramus (AAR, green) and the anterior horizontal ramus (light blue) arise separately from the lateral fissure in both specimens [(A and B, same specimen) and (Cand D, same specimen). This constitutes a 'VU' pattern of the anterior rami. The solid white sulcus is the intermediate frontal sulcus (Figure C). Its branches are highlighted in dashed white. Note that the posterior branch, of the posterior segment of the intermediate frontal sulcus, sends a branch into the inferior frontal gyrus. Since this branch is at the same vertical level as the AAR, it was classified a boundary sulcus and not as an opercular sulcus. The selected areas in Figures B and D highlight the pars opercularis. Note the absence of an opercular sulcus in it. The absence of a connection between the IFS and the inferior precentral sulcus as well as the absence of an opercular sulcus in both specimens, means that they were classified as: Type 2 of sulcal connections in the frontal operculum. Note the sulcus of the pars triangularis descending between the anterior rami in both specimens.

TYPE 3 (see Fig 3.24 on pg 178):

- An additional branch:
    - With variable shapes and connections,
    - Which may also occur freely in the pars opercularis,
    - That is referred to as the opercular sulcus (in the present study) and by others as the diagonal sulcus, descends between the anterior ascending ramus and the single inferior precentral sulcus, or the inferior part of the anterior precentral sulcus (when the precentral sulcus occurred as two sulci);

- The connection of the inferior frontal sulcus with the single inferior precentral sulcus, or with the inferior part of the anterior precentral sulcus, when the precentral sulcus occurred as two sulci is inconstant.

- The other inconstant sulcal segments occur as in Type 1.

TYPE 4 (see Fig 3.25 on pg 179):

- The anterior ascending ramus is absent, and

- The other inconstant sulcal segments occur as in Type1. Note that the anterior horizontal ramus is present.

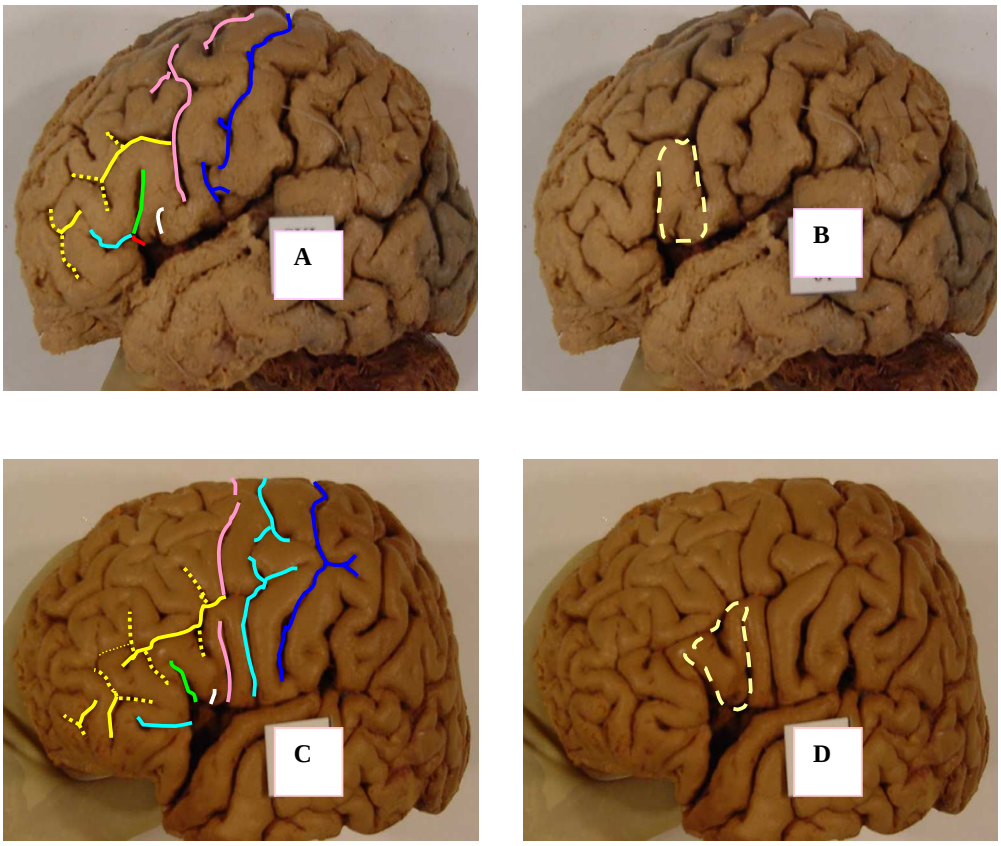

Figure 3.24 Type 3 of Sulcal Connections with Single and Double Precentral Sulci.

In Figure A, the interrupted precentral sulcus (pink) is anterior to the central fissure (CF, dark blue in colour). In Figure C, the anterior precentral sulcus (pink) is separated from the CF by the posterior precentral sulcus (light blue). Note that the posterior end of the inferior frontal sulcus (IFS, highlighted in yellow) is connected to the inferior precentral sulcus in Figure A and the anterior precentral sulcus in Figure C. The dashed yellow sulci are the superior and inferior branches of the two IFS. The anterior ascending ramus (green) and the anterior horizontal ramus (light blue) arise separately from the lateral fissure in Figures C and D (same specimen). This constitutes a 'VU' pattern of the anterior rami. The anterior rami arise from a common stem (red) in Figures A and B (same specimen). This constitutes a 'Y' pattern of the anterior rami. In Figures B and D, the selected areas highlight the pars opercularis of Figures A and C respectively. Note that a single opercular sulcus is present in Figures A and B (white in Fig A), and two opercular sulci are present in Figures C and D (white and yellow in Fig C).

The presence of an opercular sulcus regardless of the connection of the IFS with the inferior precentral sulcus is the hallmark of the Type 3 of sulcal connections in the frontal operculum.

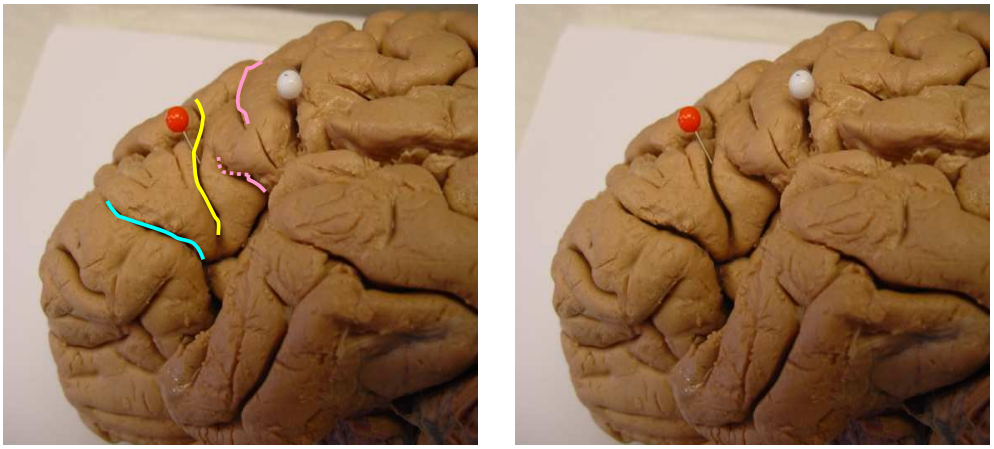

Figure 3.25 Type 4 of Sulcal Connections. [This specimen has already been orientated in Figure 3.5 on page 120]. The anterior ascending ramus was considered to be absent because the sulcus in its position (yellow colour, red pin) makes a pseudoconnection with the lateral fissure. Note that triangular sulci are present. This also constitutes an *ℐ* pattern of the anterior rami.

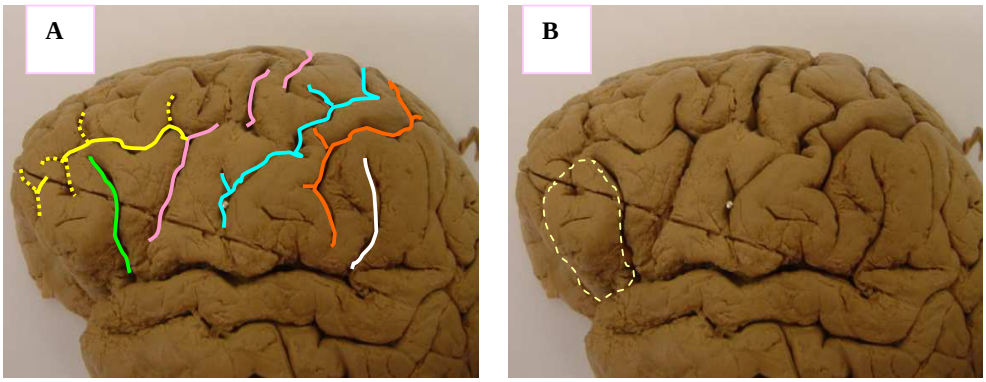

Figure 3.26 The *ℐ pattern* of the Anterior Rami. Figs A and B are of the same specimen.

In Figure A, the upturned end of the lateral fissure (white) is posterior to the postcentral sulcus (orange). The central fissure (CF, light blue) is posterior to the interrupted precentral sulcus (pink). The anterior ascending ramus (green) lies anterior to the inferior precentral sulcus. There are no sulci in the paes opercularis.

In Figure B, the selected area does not reveal an anterior horizontal ramus, and this specimen was therefore classified as an *ℐ pattern* of the anterior rami.. This is in contrast to Figure 3.25 (above) where the anterior ascending ramus was absent and the anterior horizontal ramus present. Note that a sulcus of the pars triangularis descends from the inferior frontal sulcus.

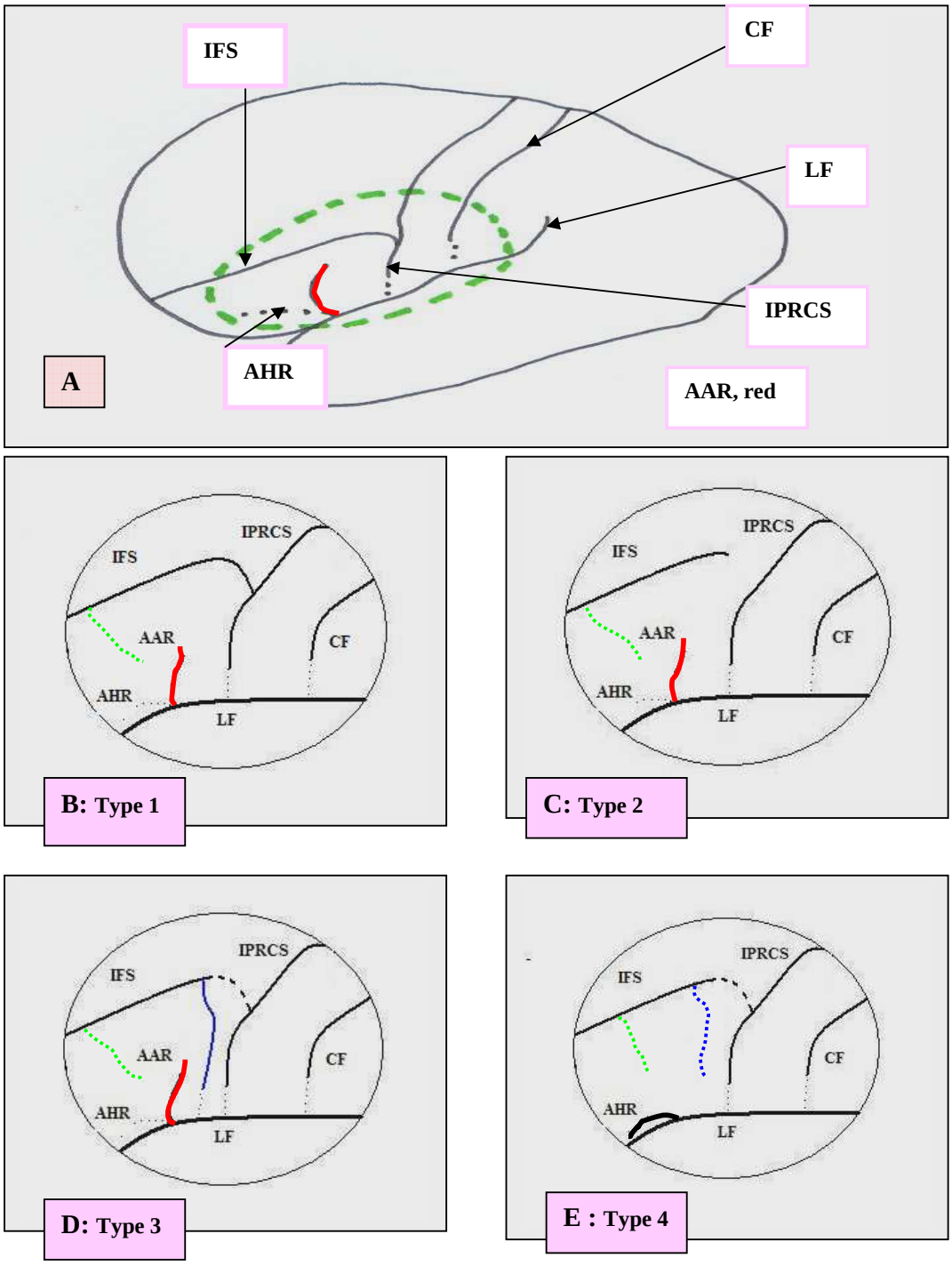

Figure 3.27 A Summary of the Types of Sulcal Connections, in the the presence of a single precentral sulcus. The selected area (broken green ellipse in Diagram A, has been expanded in Diagrams B-E, so as to demonstrate the features each of the four Types of Sulcal Connections. [Fissures – Central (CF), Lateral (LF); Sulci – Inferior precentral (IPRCS), Inferior frontal (IFS), Anterior ascending- (AAR), Anterior horizontal (AHR)- rami, sulcus of pars triangularis (green). Broken lines indicate inconstant connections of fissures or sulci or an inconstant sulcus. Note that the additional *blue* branch in Type 3 (diagram D) is the diagonal (opercular) sulcus. It has other connections besides that to the IFS and is inconstant in Type 4.

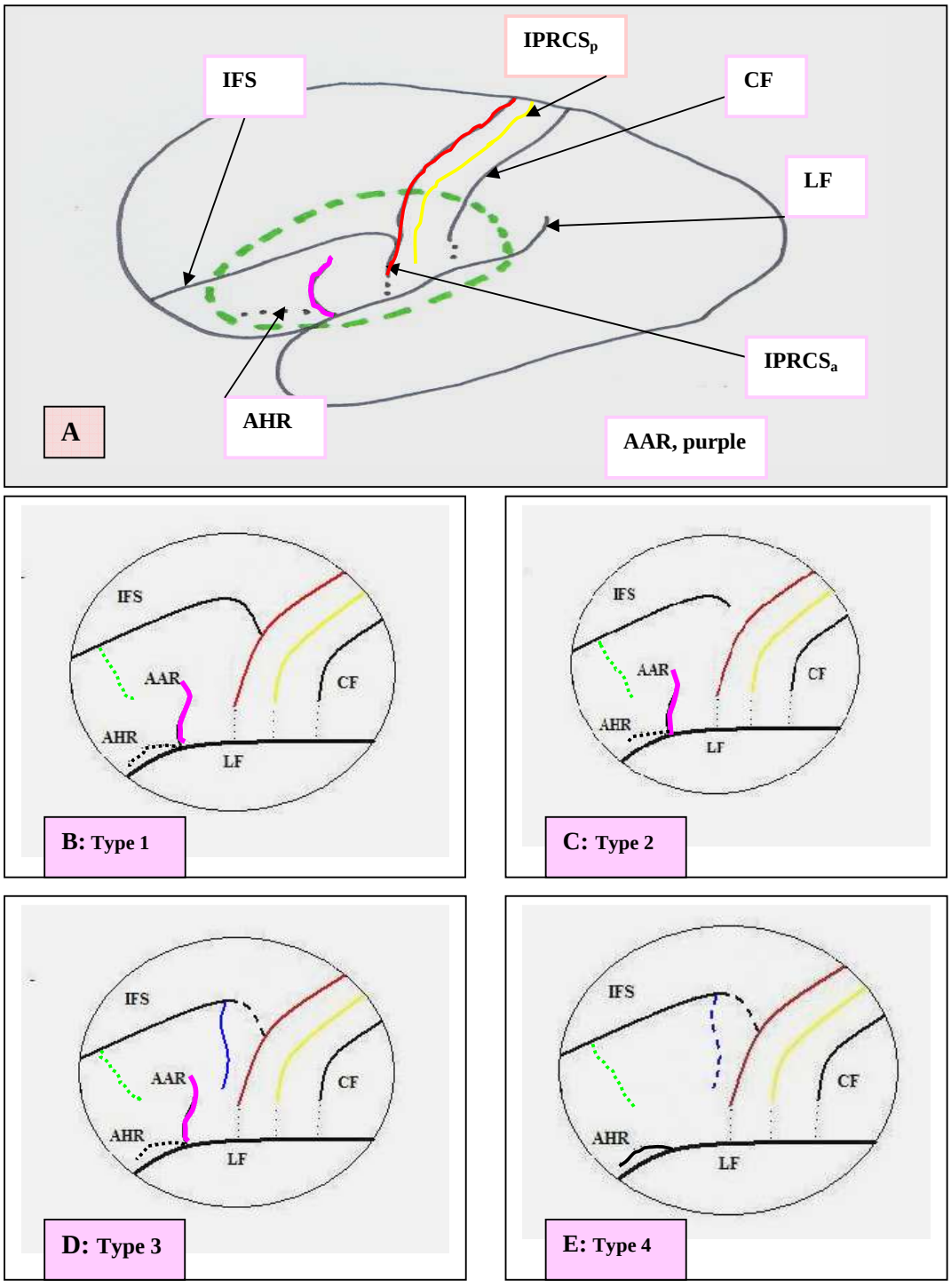

Figure 3.28 A Summary of the Types of Sulcal Connections, in the the presence of double precentral sulci. The selected area (broken green ellipse in Diagram A, has been expanded in Diagrams B-E, demonstrating the features each of the four Types of Sulcal Connections. [Fissures – Central (CF), Lateral (LF); Sulci – Inferior precentral anterior (red), Inferior precentral posterior (yellow), Inferior frontal (IFS), Anterior ascending- (AAR), Anterior horizontal (AHR)- rami, sulcus of pars triangularis (green). Broken lines indicate inconstant connections of fissures or sulci or an inconstant sulcus. Note that the *blue* branch in Type 3 (the opercular sulcus) has other connections also. It is inconstant in Type 4.

3.2.4.2 THE INTERHEMISPHERIC COMPARISON OF THE TYPES OF CONNECTIONS

This section addresses the following question posed in Chapter Two:

- ***Is there a significant interhemispheric difference with respect to the incidences of the four Types of Sulcal Connections that occur in the frontal operculum?***

The chi-square (χ^2) test was applied to the data in Tables C.1 and C.3, on pg 309 and 310 respectively.

Table 3.40: The Incidence of the Types of Sulcal Connections in F3, relative to the right and left cerebral hemispheres in the control group.

HEMISPHERE / EBELING TYPE	RIGHT HEMISPHERE	LEFT HEMISPHERE
TYPE 1	**20**	**31**
TYPE 2	**5**	**0**
TYPE 3	**39**	**33**
TYPE 4	**1**	**1**
		130

RESULTS:

(a) χ^2 **value** = 7.87

(b) Degrees of freedom = 3

(c) p-value < 0.05

(d) The null hypothesis of no association is rejected.

Table 3.41: The Incidence of the Types of Sulcal Connections in F3, relative to the right and left cerebral hemispheres in the case group.

HEMISPHERE / EBELING TYPE	RIGHT HEMISPHERE	LEFT HEMISPHERE
TYPE 1	**11**	**11**
TYPE 2	**3**	**2**
TYPE 3	**30**	**32**
TYPE 4	**1**	**0**
		90

RESULTS:

(a) χ^2 **value** = 1.26

(b) Degrees of freedom = 3

(c) p-value > 0.05

(d) The null hypothesis of no association is not rejected.

3.2.5 REPORT ON THE SULCI OF THE FRONTAL OPERCULUM WITH RESPECT TO DATA GROUPED ACCORDING TO THE PATTERNS OF THE ANTERIOR RAMI

This section addresses the following question posed in Chapter Two:

- ***Can the information gathered on the fissures and sulci of the frontal operculum be used to replicate the study of: Others, as regards the Patterns of the Anterior Rami, of the Lateral Fissure (see section 1.8.2 on pg 32; and Fig 1.10 on pg 35 and Fig 1.11 on, pg 38), in their original form, or in a modified form?***

Three patterns of the anterior rami of the lateral fissure were found in the present study. These were the: **'Y'-**, [**'VU'- + Intermediates]**, ***'𝒥'*- patterns. Note that hereafter in this text, the patterns shall be referred to as the:**

- ***Y** pattern* [see Fig 3.22 (C) on pg 175]
- ***VU** pattern* [see Fig 3.22 (A) on pg 175], and
- ***𝒥** pattern* [see Fig 3.26 on pg 179] for simplicity.

The incidences of the three patterns are reported in Tables 3.42 and 3.43, on pg 185 and 186 respectively. The predominant pattern was the *VU pattern*, followed by the *Y pattern*. The ***𝒥** pattern* was very rare. When three rami arose from the lateral fissure, the

posteriormost sulcus was taken to be an opercular sulcus arising from the lateral fissure [see Fig 3.12 (d) on pg 139].

The chi-square (χ^2) test was applied to the data in Tables C.2 and C.4, on pg 310 and 311 respectively.

Table 3.42: The Incidence of the Patterns of the Anterior Rami, relative to the right and left cerebral hemispheres in the control group.

HEMISPHERE / PATTERN	RIGHT HEMISPHERE	LEFT HEMISPHERE
Y	**24**	**25**
V-U	**40**	**39**
$\mathcal{J}$	**1**	**1**
		130

RESULTS:

(a) **χ^2 value** = 0.03

(b) Degrees of freedom = 2

(c) p-value > 0.05

(d) The null hypothesis of no association is not rejected.

Table 3.43: The Incidence the Patterns of the Anterior Rami, relative to the right and left cerebral hemispheres in the case group.

HEMISPHERE / PATTERN	RIGHT HEMISPHERE	LEFT HEMISPHERE
Y	**11**	**20**
V-U	**33**	**24**
$\mathcal{J}$	**1**	**1**
		90

RESULTS:

(a) χ^2 statistic = 4.03

(b) Degrees of freedom = 2

(c) p-value > 0.05

(d) The null hypothesis of no association is not rejected.

3.2.6 THE INCIDENCES OF THE PATTERNS OF THE ANTERIOR RAMI OF THE LATERAL FISSURE WITH RESPECT TO THE TYPES OF SULCAL CONNECTIONS

This section addresses the following question posed in Chapter Two:

- ***What are the incidences of the Patterns of the Anterior Rami (of the Lateral Fissure) relative to the Types of Sulcal Connections in the frontal operculum?***

These incidences are presented in Tables 3.44, and 3.45 on pages 187 and 188 respectively.

Table 3.44: The Incidence of the Patterns of the Anterior Rami with respect to the Types of Sulcal Connections, in the frontal operculum (in the control group).

	RIGHT HEMISPHERE (n = 65)		**LEFT HEMISPHERE** (n = 65)	
	n	**FREQUENCY (PRECENT)**	n	**FREQUENCY (PRECENT)**
TYPE 1: (a) 'Y' pattern	**20**	**2 (10.0)**	**31**	**10 (32.3)**
(b) 'VU' pattern	**20**	**18 (90.0)**	**31**	**21 (67.7)**
TYPE 2: (a) 'Y' pattern	**5**	**3 (60.0)**	**0**	**0**
(b) 'VU' pattern	**5**	**2 (40.0)**	**0**	**0**
TYPE 3: (a) 'Y' pattern	**39**	**19 (48.7)**	**33**	**15 (45.5)**
(b) 'VU' pattern	**39**	**20 (51.3)**	**33**	**18 (54.5)**
TYPE 4: (c) '𝒮 pattern	**1**	**1 (100)**	**1**	**1 (100)**

Table 3.45: The Incidence of the Patterns of the Anterior Rami with respect to the Types of Sulcal Connections, in the frontal operculum (in the case group).

	RIGHT HEMISPHERE (n = 45)		LEFT HEMISPHERE (n = 45)	
	n	FREQUENCY (PRECENT)	n	FREQUENCY (PRECENT)
TYPE 1: (a) 'Y' pattern	**11**	**1 (9.1)**	**11**	**4 (36.4)**
(b) 'VU' pattern	**11**	**10 (90.9)**	**11**	**6 (54.5)**
(c) '𝒮 pattern	**11**	**0**	**11**	**1 (9.1)**
TYPE 2: (a) 'Y' pattern	**3**	**0**	**2**	**1 (50.0)**
(b) 'VU' pattern	**3**	**3 (100)**	**2**	**1 (50.0)**
TYPE 3: (a) 'Y' pattern	**30**	**10 (33.3)**	**32**	**15 (46.9)**
(b) 'VU' pattern	**30**	**20 (66.7)**	**32**	**17 (53.1)**
TYPE 4: (c) '𝒮 pattern	**1**	**1 (100)**	**0**	**0**

3.3 REPORT ON THE QUANTITATIVE PART OF THE PRESENT STUDY

3.3.1 OVERVIEW OF THE MANNER IN WHICH THE QUANTITATIVE DATA WAS HANDLED

The quantitative study related to the lengths of the major- and accessory- sulci in the frontal operculum, and to intersulcal lengths in the frontoparietal operculum. Note that the major sulci (as described in the present study) were the:

- Stem of the anterior rami (see Fig 3.24A on pg 178),
- Anterior ascending ramus (see Figs 3.24 A and 3.2 C on pg 178),
- Anterior horizontal ramus (see Figs 3.24 A and 3.2 C on pg 178).

Also note that the accessory sulci (as described in the present study) were the:

- Sole opercular sulcus when the opercular sulcus occurred as one sulcus [see Fig 3.14 (c) and 3.14 (d) on pg 151],
- First- and second opercular sulci, when the opercular sulcus occurred as two sulci (see Fig 3.21 A to D on pg 160),
- Sole triangular sulcus when the triangular sulcus occurred as one sulcus (see Fig 3.21D on pg 160),
- Anterior- and posterior- triangular sulci, when the triangular sulcus occurred as two sulci (see Fig 3.24 C on pg 178),

- Anterior-, middle-, and posterior- triangular sulci, when the triangular sulcus occurred as three sulci (see Fig 3.20 on pg 158).

The lengths of each of the major- and accessory- sulci, of the frontal operculum, for the specimens listed in Appendix D (on pages 312 to 313) were measured twice. It was noted that there was a very close correspondence between the values obtained for the first- and the second- recordings, for each sulcal length. This feature is illustrated in Appendix E [Tables E.1 and E.2; Tables E.4 and E.5; Tables E.7 and E.8; Tables E.10 and E.11; Tables E.13 and E.14; Tables E.16 and E.17, on pages 314 to 337]. The conclusion is that the method of measuring sulcal lengths as set out in section 2.9 (on pages 97 to 103) is reproducible and consistent. However (in the present study) the true length of each sulcus was taken to be the mean of the first- and second- recordings (in each hemisphere). This was referred to as the composite recordings of sulcal lengths in the appendices. The composite lengths are also reflected in Appendix E [Tables E.3, E.6, E.9, E.12, E.15, and E.18, on pages: 317&318, 320&321, 325&326, 328&329, 333&334, and 337 respectively].

Data analysis was conducted on the composite recordings of sulcal length for:

(a) **Ungrouped data [***prior to the grouping of the data into the four Types of Sulcal Connections* (see Figs 3.27 and 3.28 on pages 180 and 181 respectively) *or the three Patterns of the Anterior Rami* (see Fig 1.10 on pg 35)**]**, in both the control (whole brain) and case (separate hemispheres) categories, and

(b) Grouped data [*data grouped into either the four Types of Sulcal Connections* **(**see Fig 3.27 and Fig 3.28 on pages 180 and 181 respectively**)** *or the three Patterns of the Anterior Rami* (see Fig 1.10 on pg 35), in both the control (whole brain) and case (separate hemispheres) categories, as follows:

- Mean lengths for each individual sulcus examined (major and accessory), were calculated **prior to any grouping relative to the Types of Sulcal Connections, or the Patterns of the Anterior Rami. This was referred to in the Tables below, as well as in the appendices, as the individual sulcal lengths for ungrouped data**. The data for whole brains was reflected in the control category and that of the separate hemispheres in the case category.

- The entire sample in both the control and case categories was examined and each hemisphere was distributed into one of the four groups that make up the modified Types of Sulcal Connections, as described in the present study [see section 3.2.4.1 on pages 173 to 177, and Fig 3.27 and Fig 3.28 on pages 180 and 181 respectively. Appendix C (on pages 268 to 311) reflects this distribution per specimen]. Note that not all the specimens were considered for quantitative exploration [see Appendix D (on pages 312 to 313) for a list of which specimens were used for the measurement of sulcal lengths]. The composite lengths of the major- and accessory- sulci in each specimen per Type of Sulcal Connection in the frontal operculum, is reported in Appendix F (on pages 338 to 348). *Note that, there was insufficient data for processing in Types 2 and 4.*

The means of each of the individual sulcal lengths (of the major- and accessory- sulci) were calculated for Types 1 and 3 (with new sample numbers). This constitutes the means of individual sulcal lengths grouped according to Type 1 and Type 3 as reported in the tables below.

- The entire sample in the control and case categories was re-examined and each hemisphere was re-distributed into one of the three groups that make up the Patterns of the Anterior Rami [see section 1.8.2 on pages 32 to 40, and Fig 1.10, on pg 35. Appendix C (on pages 268 to 311) also reflects this distribution]. The composite lengths for the major- and accessory- sulci in each specimen relative to the Patterns of the Anterior Rami, is reported in Appendix G (on pages 349 to 360). *Note that there was insufficient data for processing in the 𝒥 pattern of the anterior rami.*

The means of each of the individual sulcal lengths (major- and accessory- sulci) were calculated for the *Y pattern* and *VU pattern* (with new sample numbers). This constitutes the means of individual sulcal lengths grouped according to the *Y pattern* and *VU pattern* as reported in the tables that follow.

3.3.2 REPORT ON THE MEAN LENGTHS OF INDIVIDUAL SULCI IN THE FRONTAL OPERCULUM (F3) FOR UNGROUPED AND GROUPED DATA

(a) This section addresses the following objectives stated in Chapter Two:

- ***What are the mean lengths of individual major- and accessory- sulci of the frontal operculum (in both cerebral hemispheres and in the control and case categories) for ungrouped data?***

- ***What are the mean lengths of individual major- and accessory- sulci of the frontal operculum (in both cerebral hemispheres and in the control and case categories) for data grouped according to the:***

    - ***Types of Sulcal Connections in F3?***
    - ***Patterns of the Anterior Rami of the Lateral Fissure***

(b) This section addresses, in addition, the following objective stated in Chapter Two:

- ***The illustration of the effect of the two systems of classification [listed in 3.3.2 (a)] on sulcal length.***

3.3.2.1 MEAN LENGTHS, STANDARD DEVIATIONS, AND COEFFICIENTS OF VARIATION FOR INDIVIDUAL MAJOR SULCI IN F3

Each of Tables 3.46 to 3.57 below presents a summary of three selected features of the sample data used in this study, namely, the mean lengths, the standard deviations, and the coefficients of variation. The data was measured in centimetres and the coefficient of variation is expressed as a percentage. Tables 3.46 to 3.48 in this subsection present these data in respect of individual major sulci in F3, while in the next subsection, Tables 3.49 to 3.57 provide them for individual accessory sulci in F3.

Table 3.46: Mean lengths ($\bar{x}$), standard deviations (s), and coefficients of variation (cv), for the Stem for ungrouped and grouped data in F3.

	RIGHT HEMISPHERE				LEFT HEMISPHERE			
	n_1	$\bar{x}_1$	s_1	cv_1	n_2	$\bar{x}_2$	s_2	cv_2
UNGROUPED								
CONTROL	18	0.79	0.39	49	19	0.70	0.26	37
CASE	5	0.56	0.18	33	10	0.72	0.49	68
TYPE 1								
CONTROL	2	0.45	0	0	7	0.78	0.34	44
CASE	1	0.75	0	0	2	1.33	0.74	56
TYPE 3								
CONTROL	14	0.86	0.42	49	14	0.68	0.22	32
CASE	4	0.51	0.17	33	8	0.57	0.30	54
Y PATTERN								
CONTROL	18	0.79	0.39	49	19	0.70	0.26	37
CASE	5	0.56	0.18	33	10	0.72	0.49	68
VU PATTERN	The stem is absent in this pattern							

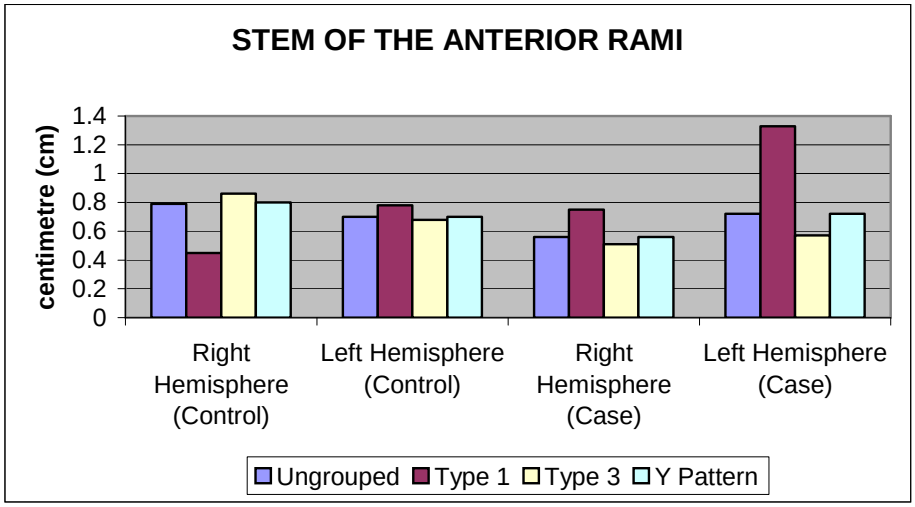

Figure 3.29 Mean Lengths of the Stem clustered according to Grouped and Ungrouped Data. These bar diagrams demonstrate the effect of the systems of classification on the mean lengths of the stem of the anterior rami.

Table 3.47: Mean lengths ($\bar{x}$), standard deviations (s), and coefficients of variation (cv), for the Anterior Ascending Ramus for ungrouped and grouped data in F3.

	RIGHT HEMISPHERE				LEFT HEMISPHERE			
	n_1	$\bar{x}_1$	s_1	cv_1	n_2	$\bar{x}_2$	s_2	cv_2
UNGROUPED								
CONTROL	40	1.43	0.63	44	40	1.50	0.73	48
CASE	26	1.76	0.57	32	26	1.76	0.67	38
TYPE 1								
CONTROL	13	1.69	0.54	32	19	1.54	0.68	39
CASE	8	2.12	0.62	27	6	1.65	1.03	22
TYPE 3								
CONTROL	25	1.37	0.63	46	21	1.47	0.79	53
CASE	17	1.62	0.49	30	20	1.79	0.55	31
Y PATTERN								
CONTROL	18	1.17	0.67	57	19	1.18	0.64	54
CASE	5	1.20	0.46	38	10	1.24	0.53	43
VU PATTERN								
CONTROL	22	1.65	0.52	32	21	1.79	0.69	44
CASE	21	1.89	0.52	29	15	2.01	0.44	62

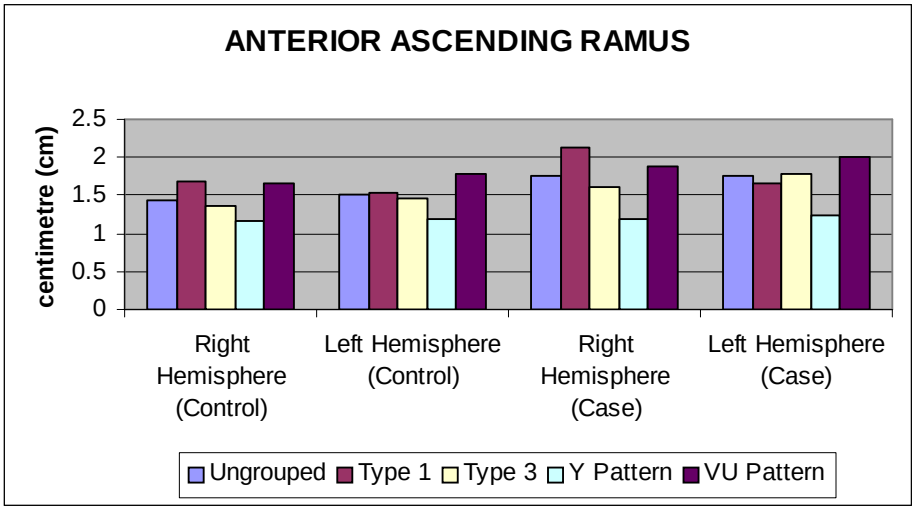

Figure 3.30 Mean Lengths of the Anterior Ascending Ramus (AAR) clustered according to Grouped and Ungrouped Data. These bar diagrams demonstrate the effect of the systems of classification on the mean lengths of the AAR.

Table 3.48: Mean lengths ($\bar{x}$), standard deviations (s), and coefficients of variation (cv), for the Anterior Horizontal Ramus for ungrouped and grouped data in F3

	RIGHT HEMISPHERE				LEFT HEMISPHERE			
	n_1	$\bar{x}_1$	s_1	cv_1	n_2	$\bar{x}_2$	s_2	cv_2
UNGROUPED								
CONTROL	40	1.35	0.53	39	40	1.47	0.53	36
CASE	27	1.70	0.59	35	22	1.69	0.69	41
TYPE 1								
CONTROL	13	1.69	0.49	29	19	1.65	0.54	33
CASE	7	1.68	0.63	37	5	2.15	0.73	34
TYPE 3								
CONTROL	25	1.18	0.46	39	21	1.31	0.48	37
CASE	18	1.63	0.53	33	17	1.55	0.64	41
Y PATTERN								
CONTROL	18	1.23	0.50	40	19	1.27	0.48	38
CASE	5	1.87	0.51	28	10	1.70	0.64	38
VU PATTERN								
CONTROL	22	1.44	0.54	38	21	1.65	0.52	32
CASE	21	1.60	0.54	34	12	1.67	0.76	45

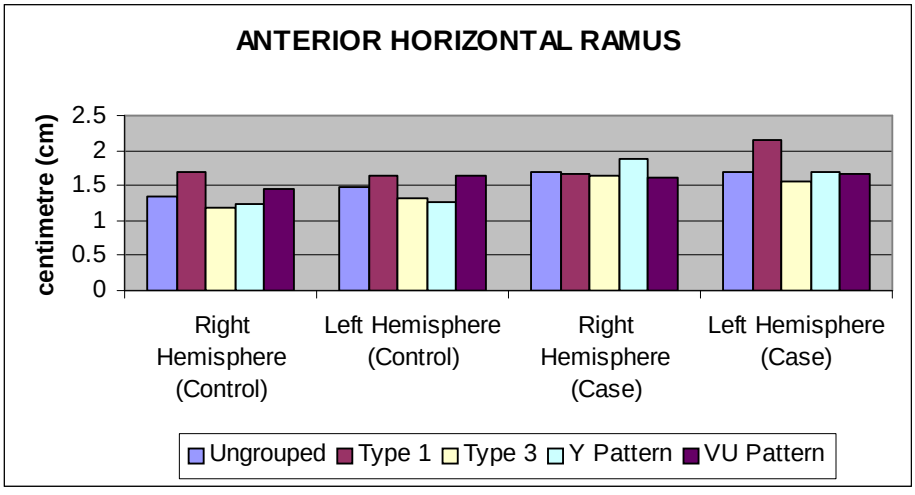

Figure 3.31 Mean Lengths of the Anterior Horizontal Ramus (AHR) clustered according to Grouped and Ungrouped Data. These bar diagrams demonstrate the effect of the systems of classification on the mean lengths of the AHR.

3.3.2.2 MEAN LENGTHS, STANDARD DEVIATIONS, AND COEFFICIENTS OF VARIATION OF INDIVIDUAL ACCESSORY SULCI IN F3

Table 3.49: Mean lengths ($\bar{x}$), standard deviations (s), and coefficients of variation (cv), for the Sole Opercular (accessory) sulcus, for ungrouped and grouped data in F3.

	RIGHT HEMISPHERE				LEFT HEMISPHERE			
	n_1	$\bar{x}_1$	s_1	cv_1	n_2	$\bar{x}_2$	s_2	cv_2
UNGROUPED								
CONTROL	14	1.93	0.781	41	18	1.74	0.817	47
CASE	9	1.74	0.943	54	11	1.27	0.623	49
TYPE 1	The Opercular sulcus does not occur in this type							
TYPE 3								
CONTROL	14	1.93	0.792	41	16	1.85	0.798	43
CASE	9	1.74	0.942	54	11	1.27	0.623	49
Y PATTERN								
CONTROL	7	1.99	0.659	33	11	1.97	0.815	41
CASE	2	1.92	0.445	23	3	1.57	0.185	12
VU PATTERN								
CONTROL	7	1.87	0.956	51	6	1.36	0.860	63
CASE	7	1.68	0.942	63	8	1.16	0.623	61

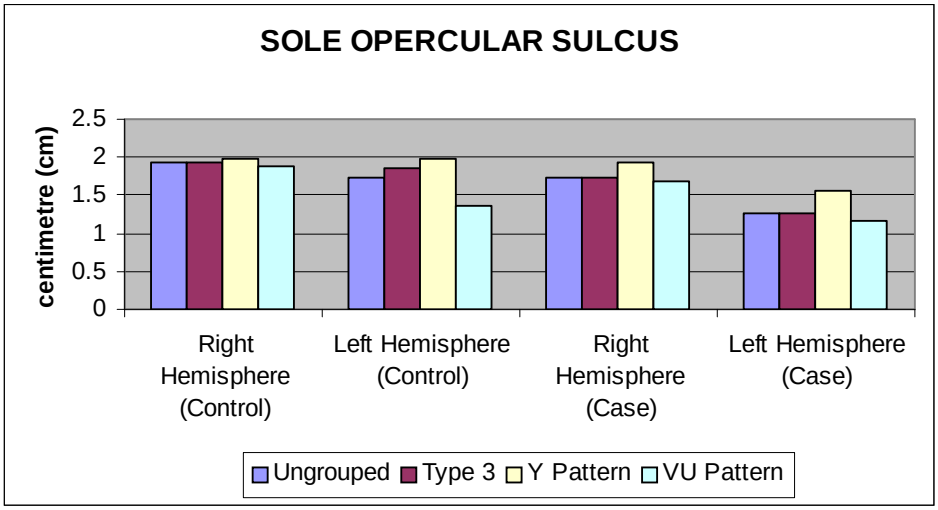

Figure 3.32 Mean Lengths of the Sole Opercular Sulcus clustered according to Grouped and Ungrouped Data. These bar diagrams demonstrate the effect of the systems of classification on the mean lengths of the Sole Opercular Sulcus.

Table 3.50: Mean lengths ($\bar{x}$), standard deviations (s), and coefficients of variation (cv), for the First Opercular (accessory) sulcus, for ungrouped and grouped data in.

	RIGHT HEMISPHERE				LEFT HEMISPHERE			
	n_1	$\bar{x}_1$	s_1	cv_1	n_2	$\bar{x}_2$	s_2	cv_2
UNGROUPED								
CONTROL	7	1.28	0.510	40	4	1.10	0.492	45
CASE	9	0.85	0.425	50	8	1.41	0.757	54
TYPE 1	The Opercular sulcus does not occur in this type							
TYPE 3								
CONTROL	7	1.28	0.510	40	4	1.10	0.492	45
CASE	8	0.85	0.425	50	8	1.41	0.757	54
Y PATTERN								
CONTROL	3	0.94	0.129	14	1	1.7	-	-
CASE	1	1.33	-	-	5	1.01	0.503	50
VU PATTERN								
CONTROL	4	1.55	0.546	35	3	0.90	0.350	39
CASE	7	0.78	0.409	52	3	2.08	0.660	32

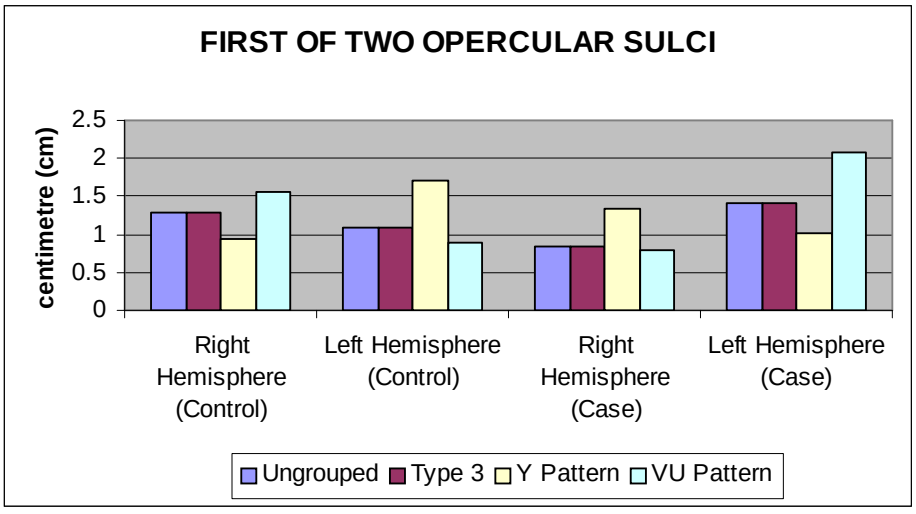

Figure 3.33 Mean Lengths of the First Opercular Sulcus clustered according to Grouped and Ungrouped Data. These bar diagrams demonstrate the effect of the systems of classification on the mean lengths of the First Opercular Sulcus.

Table 3.51: Mean lengths ($\bar{x}$), standard deviations (s), and coefficients of variation (cv), for the Second Opercular (accessory) sulcus, for ungrouped and grouped data in F3

	RIGHT HEMISPHERE				LEFT HEMISPHERE			
	n_1	$\bar{x}_1$	s_1	cv_1	n_2	$\bar{x}_2$	s_2	cv_2
UNGROUPED								
CONTROL	**6**	**1.24**	**0.446**	**36**	**4**	**0.75**	**0.210**	**28**
CASE	**6**	**2.33**	**1.175**	**50**	**8**	**1.07**	**0.448**	**42**
TYPE 1	**The Opercular sulcus does not occur in this type**							
TYPE 3								
CONTROL	**6**	**1.24**	**0.446**	**36**	**4**	**0.75**	**0.210**	**28**
CASE	**6**	**2.33**	**1.175**	**50**	**8**	**1.07**	**0.448**	**42**
Y PATTERN								
CONTROL	**3**	**1.33**	**0.093**	**70**	**1**	**0.68**	**-**	**-**
CASE	**0**	**-**	**-**	**-**	**7**	**1.09**	**0.503**	**46**
VU PATTERN								
CONTROL	**3**	**1.16**	**0.684**	**59**	**3**	**0.77**	**0.252**	**33**
CASE	**6**	**2.33**	**1.175**	**50**	**3**	**1.34**	**0.221**	**16**

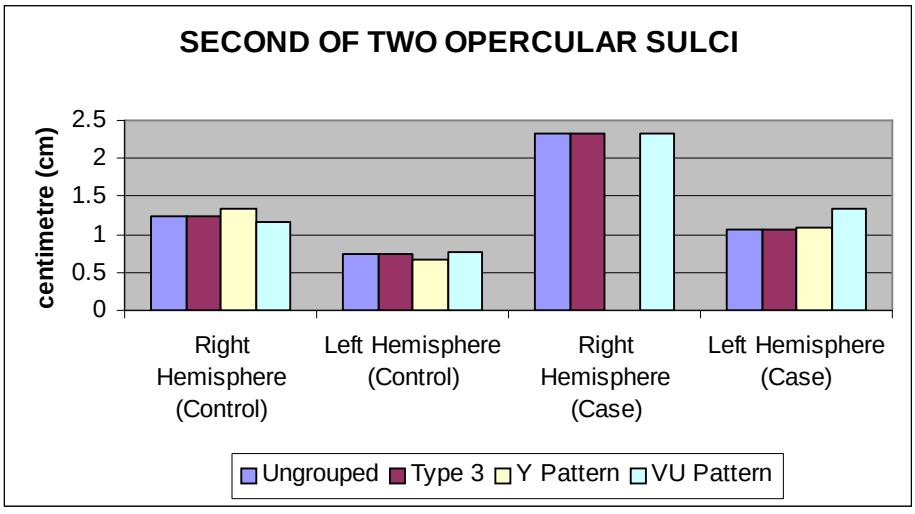

Figure 3.34 Mean Lengths of the Second Opercular Sulcus clustered according to Grouped and Ungrouped Data. These bar diagrams demonstrate the effect of the systems of classification on the mean lengths of the Second Opercular Sulcus.

Table 3.52: Mean lengths ($\bar{x}$), standard deviations (s), and coefficients of variation (cv), for the Sole Triangular (accessory) sulcus, for ungrouped and grouped data in F3.

	RIGHT HEMISPHERE				LEFT HEMISPHERE			
	n_1	$\bar{x}_1$	s_1	cv_1	n_2	$\bar{x}_2$	s_2	cv_2
UNGROUPED								
CONTROL	19	1.53	0.65	43	22	1.42	0.62	44
CASE	13	1.50	0.53	36	13	1.44	0.55	54
TYPE 1								
CONTROL	5	1.50	0.40	24	12	1.34	0.58	43
CASE	4	1.45	0.36	26	3	1.51	0.65	43
TYPE 3								
CONTROL	12	1.62	0.77	48	10	1.52	0.68	45
CASE	8	1.51	0.66	44	10	1.42	0.53	59
Y PATTERN								
CONTROL	9	1.09	0.34	31	11	1.16	0.36	31
CASE	4	1.14	0.24	21	5	0.79	0.33	41
VU PATTERN								
CONTROL	10	1.92	0.67	33	11	1.68	0.71	42
CASE	9	1.67	0.56	34	7	1.94	0.34	36

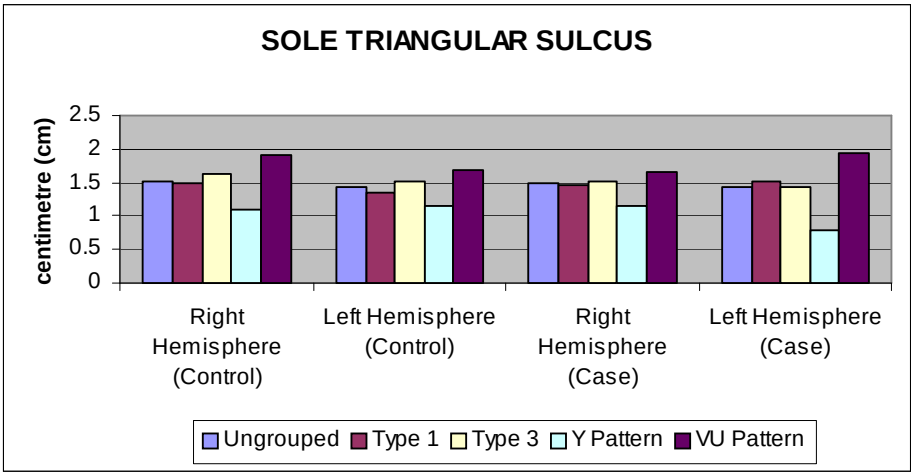

Figure 3.35 Mean Lengths of the Sole Triangular Sulcus clustered according to Grouped and Ungrouped Data. These bar diagrams demonstrate the effect of the systems of classification on the mean lengths of the Sole Triangular Sulcus.

Table 3.53: Mean lengths ($\bar{x}$), standard deviations (s), and coefficients of variation (cv), for the Anterior Triangular (accessory) sulcus, when the triangular sulcus was present as two sulci, for ungrouped and grouped data in F3.

	RIGHT HEMISPHERE				LEFT HEMISPHERE			
	n_1	$\bar{x}_1$	s_1	cv_1	n_2	$\bar{x}_2$	s_2	cv_2
UNGROUPED								
CONTROL	7	1.15	0.50	44	5	1.46	0.82	56
CASE	9	1.39	0.59	43	5	1.16	0.56	48
TYPE 1								
CONTROL	4	1.25	0.61	49	2	1.27	1.01	80
CASE	3	1.47		45	1	0.95		-
TYPE 3								
CONTROL	3	1.03	0.41	40	3	1.59	0.88	55
CASE	6	1.35	0.62	46	4	1.22	0.64	52
Y PATTERN								
CONTROL	2	1.14	0.51	45	0	-	-	-
CASE	0	-	-	-	2	1.18	1.06	90
VU PATTERN								
CONTROL	5	1.16	0.56	49	5	1.46	0.82	56
CASE	9	1.39	0.59	43	3	1.15	0.26	23

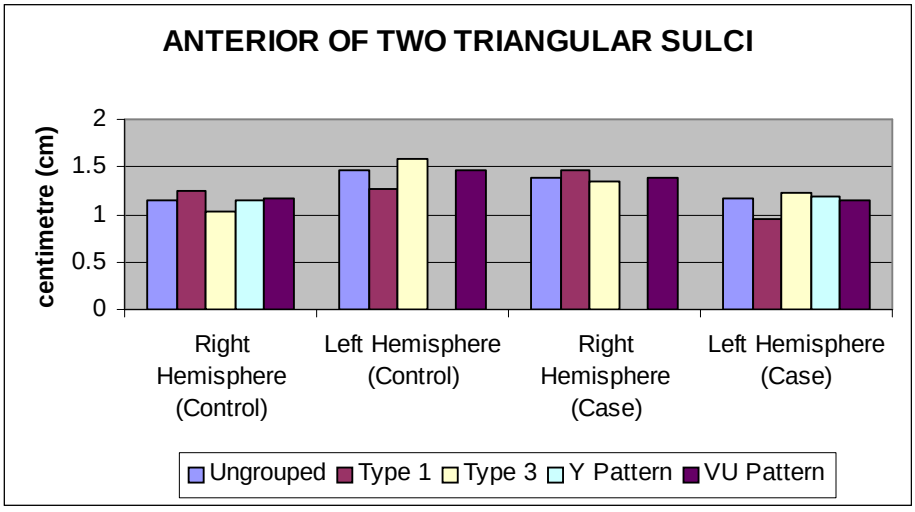

Figure 3.36 Mean Lengths of the Anterior of Two Triangular Sulci clustered according to Grouped and Ungrouped Data. These bar diagrams demonstrate the effect of the systems of classification on the mean lengths of the Anterior of Two Triangular Sulci.

Table 3.54: Mean lengths ($\bar{x}$), standard deviations (s), and coefficients of variation (cv), for the Posterior Triangular (accessory) sulcus, when the triangular sulcus occurred as two sulci, for ungrouped and grouped data in F3.

	RIGHT HEMISPHERE				LEFT HEMISPHERE			
	n_1	$\bar{x}_1$	s_1	cv_1	n_2	$\bar{x}_2$	s_2	cv_2
UNGROUPED								
CONTROL	**9**	**1.06**	**0.54**	**51**	**5**	**1.05**	**0.44**	**42**
CASE	**8**	**1.59**	**0.83**	**52**	**6**	**1.92**	**1.03**	**53**
TYPE 1								
CONTROL	**4**	**0.80**	**0.36**	**46**	**2**	**1.0**	**0.57**	**57**
CASE	**3**	**1.51**	**0.20**	**13**	**1**	**1.55**	**-**	**-**
TYPE 3								
CONTROL	**4**	**1.36**	**0.65**	**47**	**3**	**1.08**	**0.48**	**44**
CASE	**6**	**1.11**	**0.44**	**40**	**5**	**2.0**	**1.13**	**57**
Y PATTERN								
CONTROL	**2**	**2.08**	**0**	**-**	**0**	**-**	**-**	**-**
CASE	**0**	**-**		**-**	**2**	**1.9**		**34**
VU PATTERN								
CONTROL	**6**	**1.01**	**0.43**	**43**	**5**	**1.05**	**0.44**	**42**
CASE	**9**	**1.24**	**0.41**	**34**	**4**	**1.94**	**1.27**	**66**

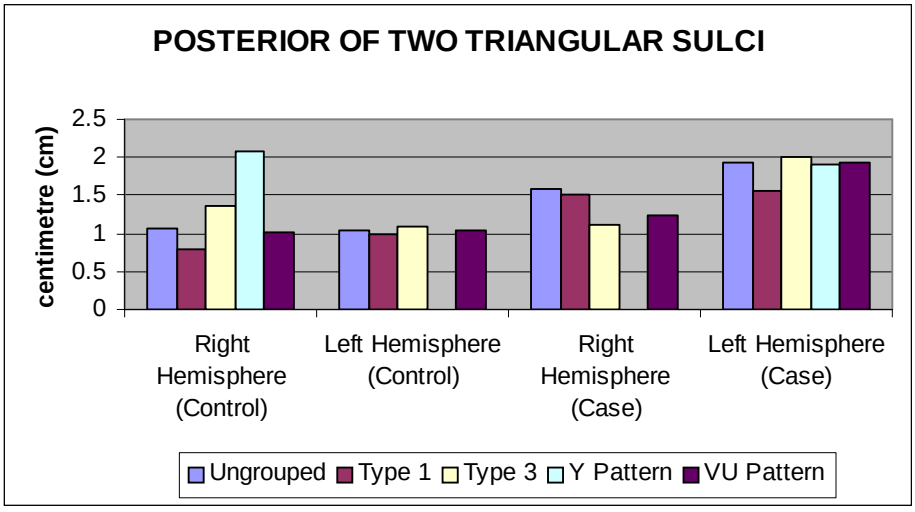

Figure 3.37 Mean Lengths of the Posterior of Two Triangular Sulci clustered according to Grouped and Ungrouped Data. These bar diagrams demonstrate the effect of the systems of classification on the mean lengths of the Posterior of Two Triangular Sulci.

Table 3.55: Mean lengths ($\bar{x}$), standard deviations (s), and coefficients of variation (cv), for the Anterior Triangular (accessory) sulcus, when the triangular sulcus was present as three sulci, for ungrouped and grouped data in F3.

	RIGHT HEMISPHERE				LEFT HEMISPHERE			
	n_1	$\bar{x}_1$	s_1	cv_1	n_2	$\bar{x}_2$	s_2	cv_2
UNGROUPED								
CONTROL	**4**	**0.77**	**0.13**	**17**	**4**	**0.90**	**0.41**	**46**
CASE	**0**	**-**	**-**	**-**	**2**	**1.79**	**1.64**	**92**
TYPE 1								
CONTROL	**2**	**0.87**	**0.02**	**2**	**2**	**1.13**	**0.53**	**47**
CASE	**0**	**-**	**-**	**-**	**1**	**0.63**	**-**	**-**
TYPE 3								
CONTROL	**2**	**0.67**	**0.09**	**13**	**2**	**0.67**	**0.12**	**18**
CASE	**0**	**-**	**-**	**-**	**1**	**2.95**	**-**	**-**
Y PATTERN								
CONTROL	**0**	**-**	**-**	**-**	**1**	**0.58**	**-**	**-**
CASE	**0**	**-**	**-**	**-**	**0**	**-**		**-**
VU PATTERN								
CONTROL	**4**	**0.77**	**0.13**	**17**	**3**	**1.0**	**0.43**	**43**
CASE	**0**	**-**	**-**	**-**	**2**	**1.79**	**1.64**	**92**

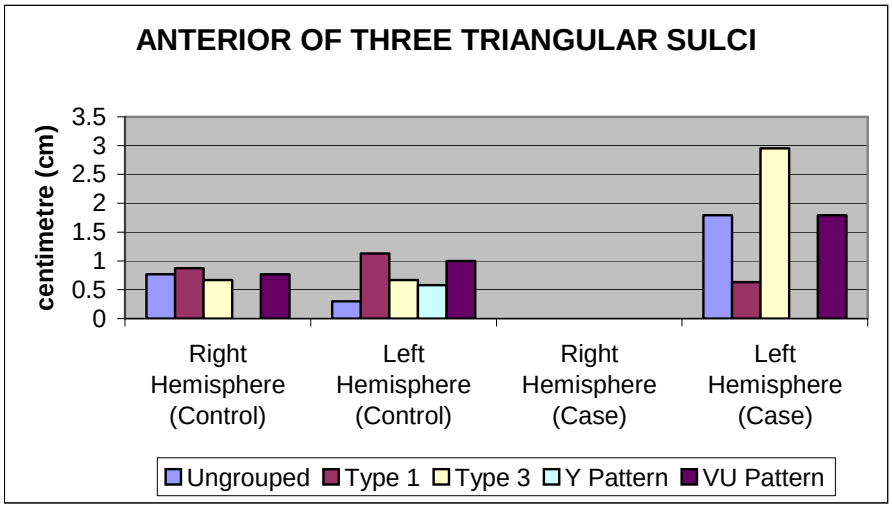

Figure 3.38 Mean Lengths of the Anterior of Three Triangular Sulci clustered according to Grouped and Ungrouped Data. These bar diagrams demonstrate the effect of the systems of classification on the mean lengths of the Anterior of Three Triangular Sulci.

Table 3.56: Mean lengths ($\bar{x}$), standard deviations (s), and coefficients of variation (cv), for the Middle Triangular (accessory) sulcus, for ungrouped and grouped data in F3.

	RIGHT HEMISPHERE				LEFT HEMISPHERE			
	n_1	$\bar{x}_1$	s_1	cv_1	n_2	$\bar{x}_2$	s_2	cv_2
UNGROUPED								
CONTROL	**4**	**2.20**	**0.57**	**26**	**3**	**2.01**	**0.27**	**13**
CASE	**0**	**-**	**-**	**-**	**2**	**1.53**	**0.39**	**25**
TYPE 1								
CONTROL	**2**	**2.22**	**0.09**	**4**	**1**	**2.15**	**-**	**-**
CASE	**0**	**-**		**-**	**1**	**1.8**	**-**	**-**
TYPE 3								
CONTROL	**2**	**2.19**	**0.96**	**44**	**2**	**1.94**	**0.34**	**18**
CASE	**0**	**-**	**-**	**-**	**1**	**1.25**	**-**	**-**
Y PATTERN								
CONTROL	**0**	**-**	**-**	**-**	**1**	**1.7**	**-**	**-**
CASE	**0**	**-**	**-**	**-**	**0**	**-**	**-**	**-**
VU PATTERN								
CONTROL	**4**	**2.20**	**0.57**	**26**	**2**	**2.17**	**0.02**	**0.01**
CASE	**0**	**-**	**-**	**-**	**2**	**1.53**	**0.39**	**25**

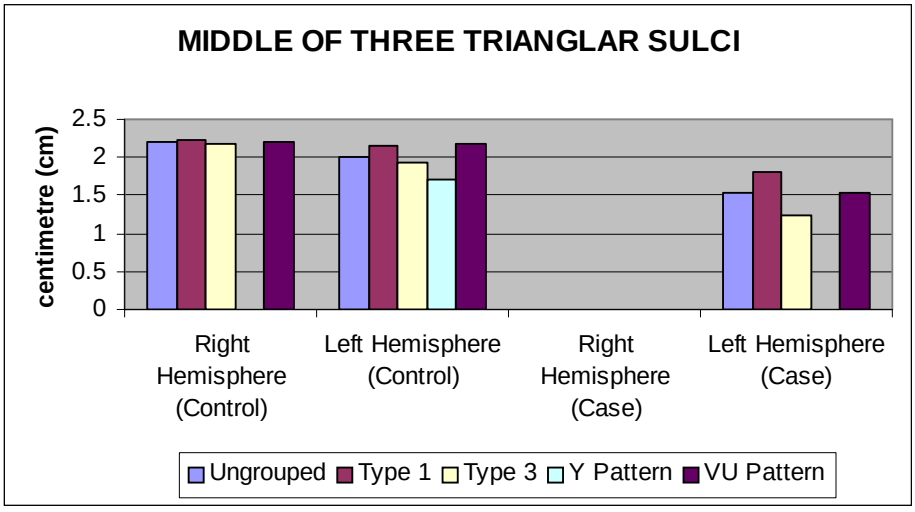

Figure 3.39 Mean Lengths of the Middle of Three Triangular Sulci clustered according to Grouped and Ungrouped Data. These bar diagrams demonstrate the effect of the systems of classification on the mean lengths of the Middle of Three Triangular Sulci.

Table 3.57: Mean lengths ($\bar{x}$), standard deviations (s), and coefficients of variation (cv), for the Posterior Triangular (accessory) sulcus, when the triangular sulcus occurred as three sulci, for ungrouped and grouped data in F3.

	RIGHT HEMISPHERE				LEFT HEMISPHERE			
	n_1	$\bar{x}_1$	s_1	cv_1	n_2	$\bar{x}_2$	s_2	cv_2
UNGROUPED								
CONTROL	4	0.87	0.73	84	3	0.84	0.23	27
CASE	0	-	-	-	2	1.04	0.41	39
TYPE 1								
CONTROL	2	1.24	1.00	81	2	0.88	0.32	36
CASE	0	-		-	1	0.75	-	-
TYPE 3								
CONTROL	2	0.49	0.13	27	1	0.78	-	-
CASE	0	-	-	-	1	1.33	-	-
Y PATTERN								
CONTROL	0	-	-	-	1	0.78	-	-
CASE	0	-	-	-	0	-	-	-
VU PATTERN								
CONTROL	4	0.87	0.73	84	2	0.88	0.32	36
CASE	0	-	-	-	2	1.04	0.41	39

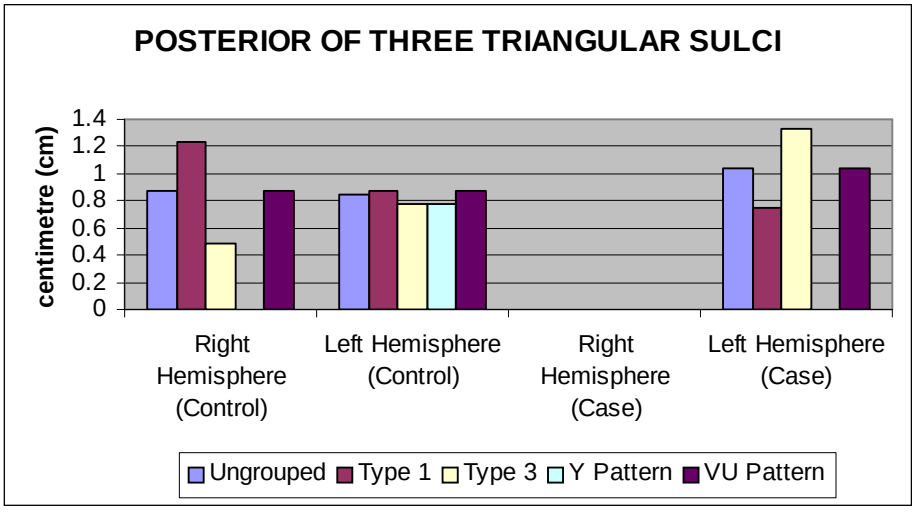

Figure 3.40 Mean Lengths of the Posterior of Three Triangular Sulci clustered according to Grouped and Ungrouped Data. These bar diagrams demonstrate the effect of the systems of classification on the mean lengths of the stem of the anterior rami.

We see in all the Tables 3.46 to 3.57 (pages 195 to 206) that the coefficients of variation are all well below 100% except in a few cases involving very small samples. This low variability is an indicator that our data is (reasonably) not problematic to analyse.

3.3.3 INTERHEMISPHRIC STUDIES ON THE MEAN LENGTHS OF INDIVIDUAL SULCI

This section addresses the following question posed in Chapter Two:

- ***Is there an interhemispheric difference with respect to the mean lengths of individual major- and accessory- sulci of the frontal opercula for ungrouped data and grouped data?***

Note that due to insufficient data for processing in Type 2- and Type 4- of Sulcal Connections, as well as in the $\mathscr{f}$ Pattern of the Anterior Rami, interhemispheric comparisons for grouped data were only possible in: Types 1 and 3 (of Sulcal Connections); as well as the *VU and Y patterns* (of the Anterior Rami). The effect of belonging to either the right- or left- hemisphere (in both control and case categories) is illustrated in Figures 3.41 to 3.52 (on pages 208 to 213).

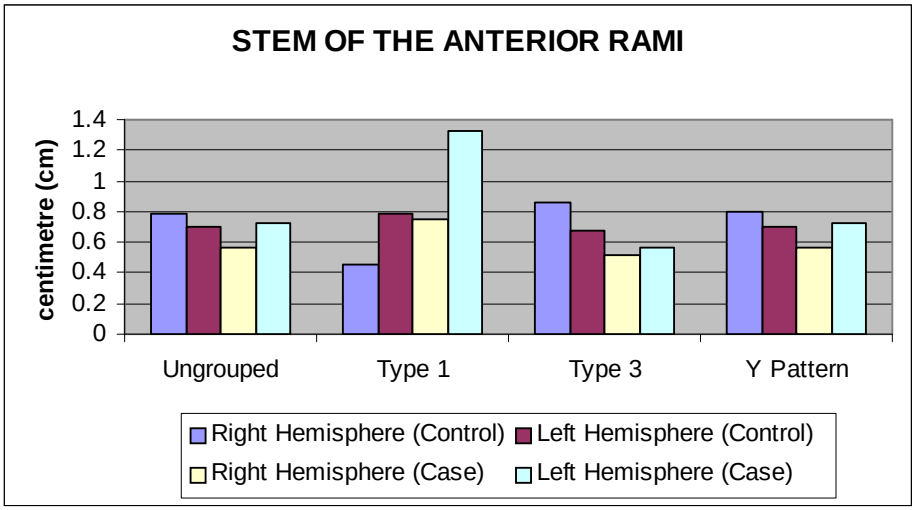

Figure 3.41 Mean Lengths of the Stem clustered according to Cerebral Hemisphere. These bar diagrams demonstrate the effect of belonging to either Hemisphere on the mean lengths of the Stem of the anterior rami (in both control and case groups).

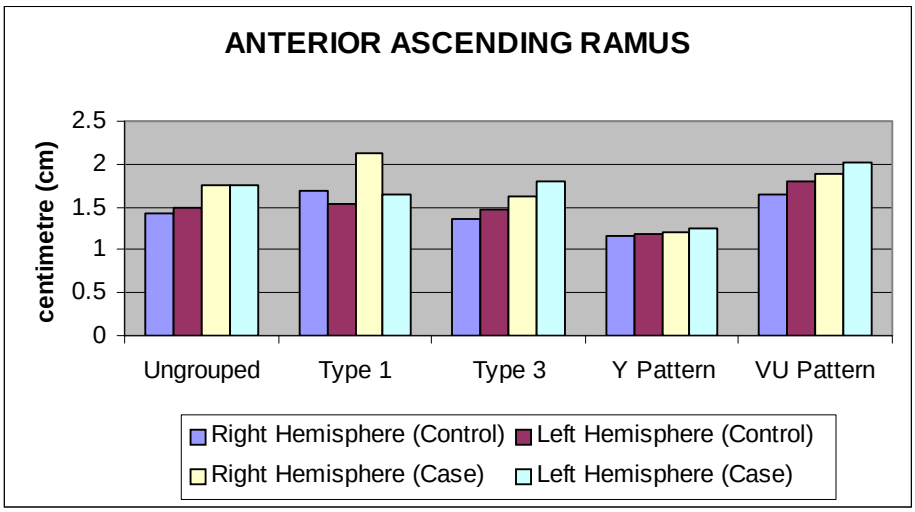

Figure 3.42 Mean Lengths of the Anterior Ascending Ramus (AAR) clustered according to Cerebral Hemisphere. These bar diagrams demonstrate the effect of belonging to either Hemisphere on the mean lengths of the AAR (in both control and case groups).

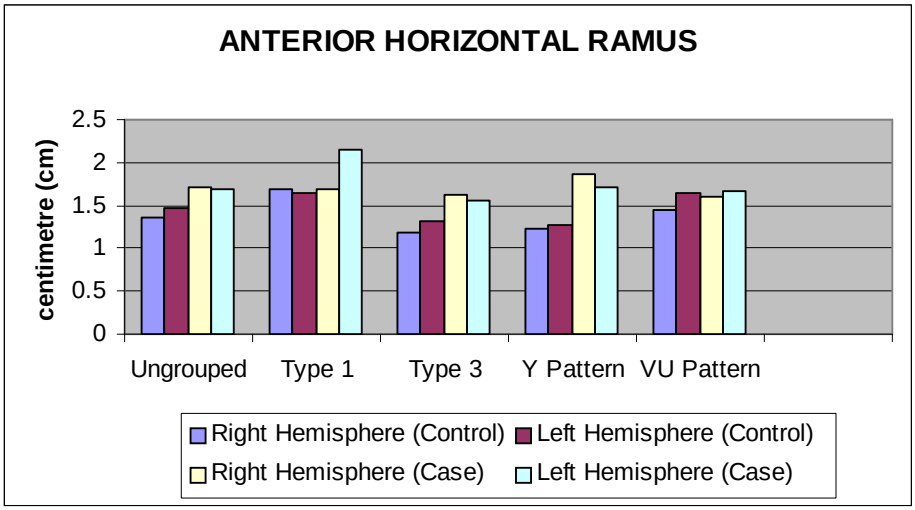

Figure 3.43 Mean Lengths of the Anterior Horizontal Ramus (AHR) clustered according to Cerebral Hemisphere. These bar diagrams demonstrate the effect of belonging to either Hemisphere on the mean lengths of the AHR (in both control and case groups).

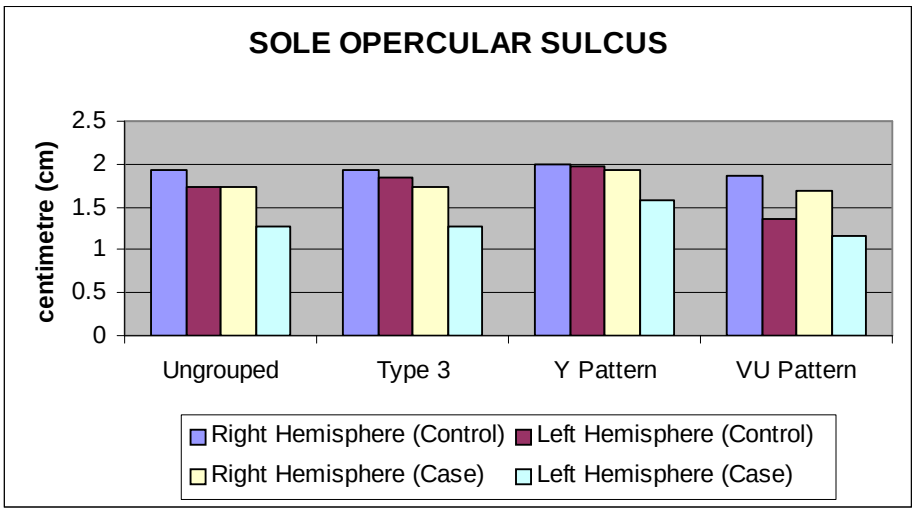

Figure 3.44 Mean Lengths of the Sole Opercular Sulcus clustered according to Cerebral Hemisphere. These bar diagrams demonstrate the effect of belonging to either Hemisphere on the mean lengths of the Sole Opercular Sulcus (in both the control and case groups).

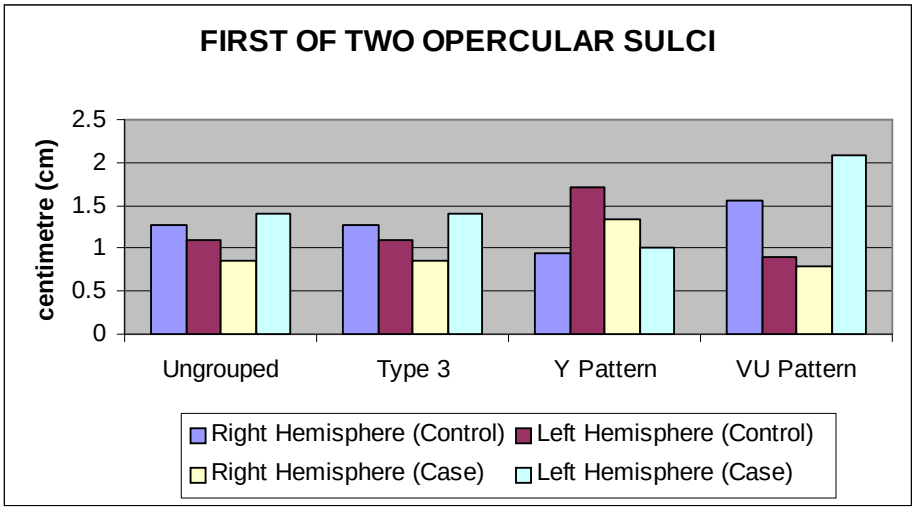

Figure 3.45 Mean Lengths of the First Opercular Sulcus clustered according to Cerebral Hemisphere. These bar diagrams demonstrate the effect of belonging to either Hemisphere on the mean lengths of the First Opercular Sulcus (in both the control and case groups).

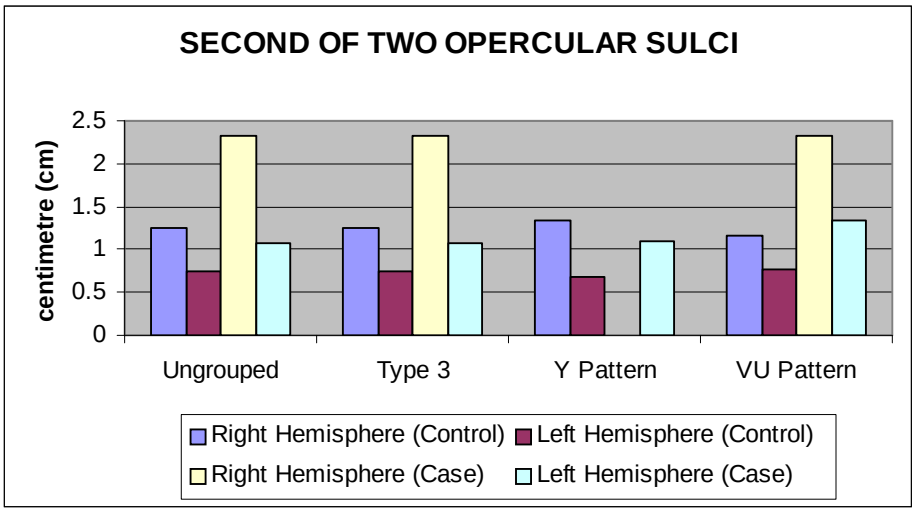

Figure 3.46 Mean Lengths of the Second Opercular Sulcus clustered according to Cerebral Hemisphere. These bar diagrams demonstrate the effect of belonging to either Hemisphere on the mean lengths of the Second Opercular Sulcus (in both the control and case groups).

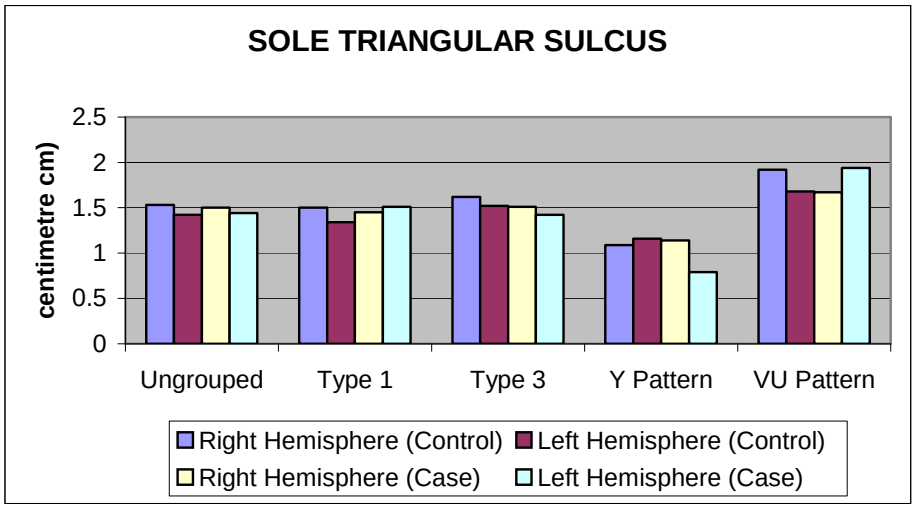

Figure 3.47 Mean Lengths of the Sole Triangular Sulcus clustered according to Cerebral Hemisphere. These bar diagrams demonstrate the effect of belonging to either Hemisphere on the mean lengths of the Sole Triangular Sulcus.

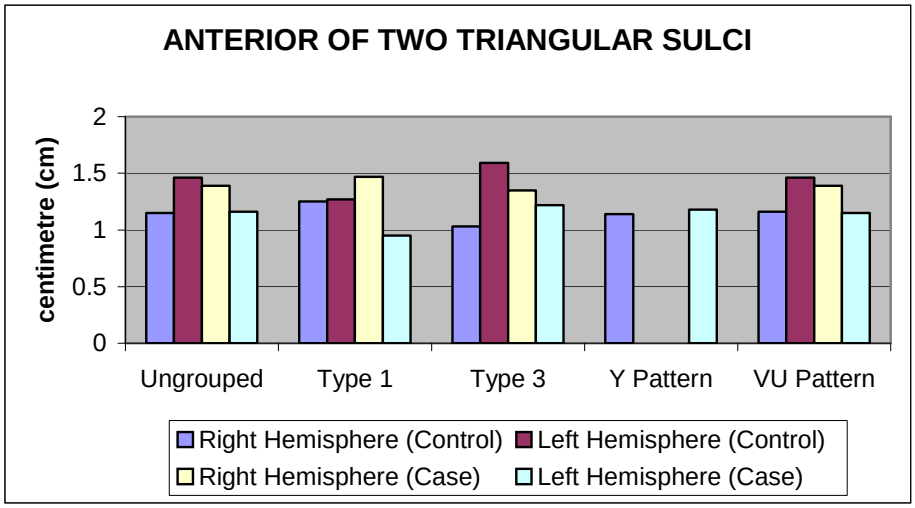

Figure 3.48 Mean Lengths of the Anterior of Two Triangular Sulci clustered according to Cerebral Hemisphere. These bar diagrams demonstrate the effect of belonging to either Hemisphere on the mean lengths of the Anterior of Two Triangular Sulci.

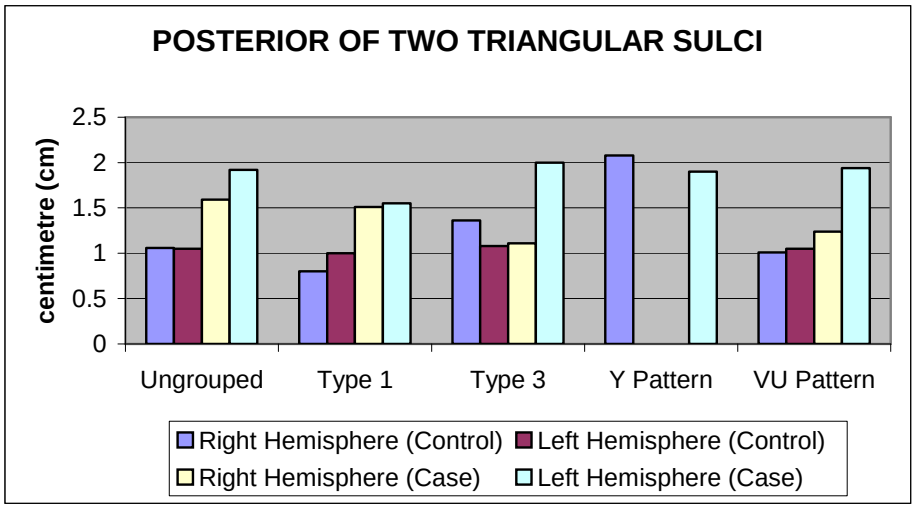

Figure 3.49 Mean Lengths of the Posterior of Two Triangular Sulci clustered according to Cerebral Hemisphere. These bar diagrams demonstrate the effect of belonging to either Hemisphere on the mean lengths of the Posterior of Two Triangular Sulci.

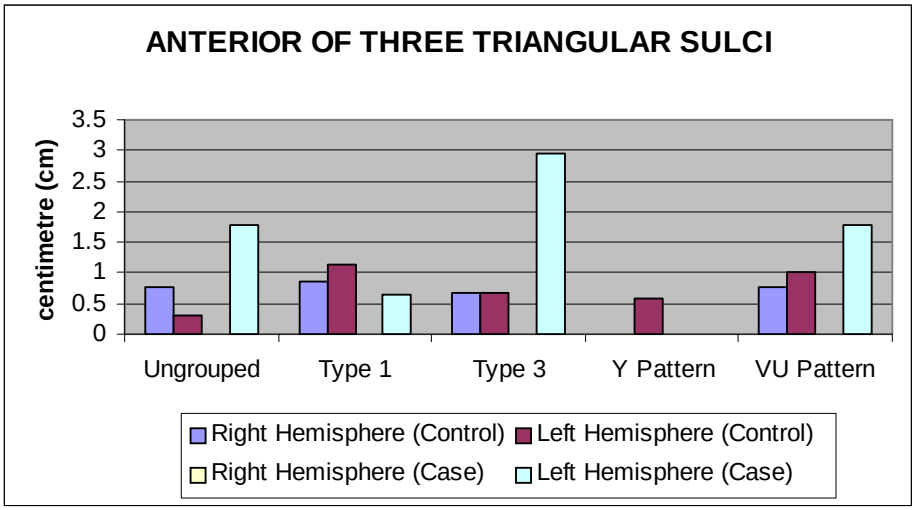

Figure 3.50 Mean Lengths of the Anterior of Three Triangular Sulci clustered according to Cerebral Hemisphere. These bar diagrams demonstrate the effect of belonging to either Hemisphere on the mean lengths of the Anterior of Three Triangular Sulci.

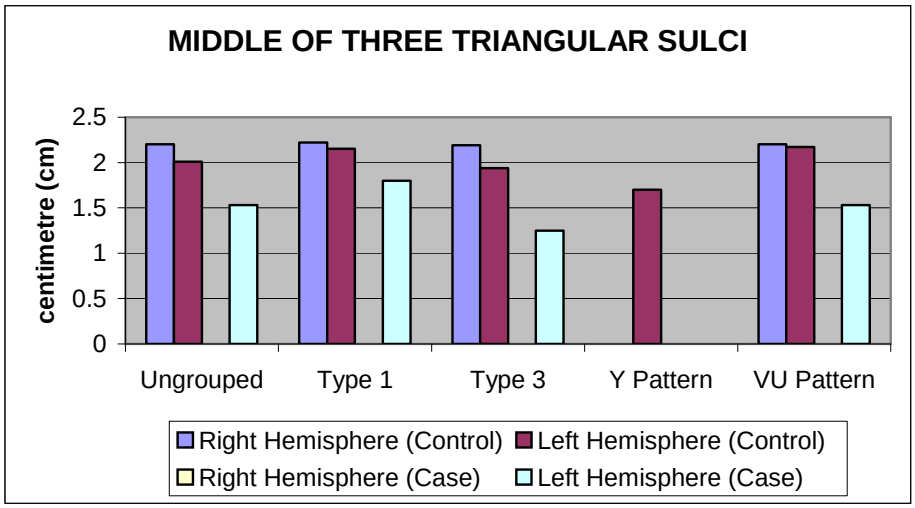

Figure 3.51 Mean Lengths of the Middle of Three Triangular Sulci clustered according to Cerebral Hemisphere. These bar diagrams demonstrate the effect of belonging to either Hemisphere on the mean lengths of the Middle of Three Triangular Sulci.

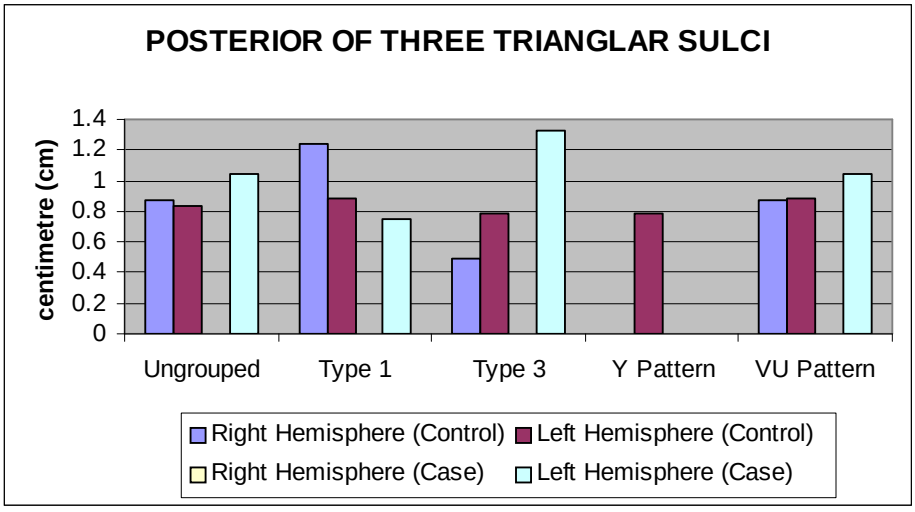

Figure 3.52 Mean Lengths of the Posterior of Three Triangular Sulci clustered according to Cerebral Hemisphere. These bar diagrams demonstrate the effect of belonging to either Hemisphere on the mean lengths of the Three Triangular Sulci.

To statistically compare the inter-hemispheric sulcal lengths, we use a Student's t-test for the mean difference. Only samples of size 18 and higher are considered.

The main results are stated in terms of p-values. *The p-values for a test may be defined as the **smallest** level of significance for which the null hypothesis may be rejected.*

The Student's t-test, which we apply below, rests on two assumptions: equality of variances and the normality.

(a) Equality of Variances:

The small-sample t-test for equality of the population means requires, among others, that the corresponding two population variances be equal. In practice therefore, one ought to check the reasonableness of this assumption *before* one performs the test.

Given *independent random samples* of sizes n_1 and n_2 from two *normal* populations with variances $(\sigma_1)^2$ and $(\sigma_2)^2$, where σ_i represents the standard deviation of the ith population, the *critical regions (i.e. the rejection regions)* for testing the null hypothesis:

$$H_0: \ (\sigma_1)^2 = (\sigma_2)^2$$

against the alternative

$$H_1: \ (\sigma_1)^2 \neq (\sigma_2)^2$$

at 100α% level of significance, depends upon whether $(s_1)^2 \geq (s_2)^2$ or $(s_1)^2 < (s_2)^2$ as

follows:

(i) If $(s_1)^2 \geq (s_2)^2$, or equivalently $R^2 \leq 1$, then the critical region is the one-sided interval

$$R^2 \geq f_1 = f_{(\alpha/2),\ n^*,\ n^{**}}$$

where $R = s_2/s_1$, $n^* = n_1 - 1$, $n^{**} = n_2 - 1$ and $f_{(\alpha/2),\ n^*,\ n^{**}}$ is obtainable from statistical tables for the F-distribution.

(ii) On the other hand, if $(s_1)^2 < (s_2)^2$, or equivalently $R^2 < 1$, then the critical region is the one-sided interval

$$R^2 \geq f_2 = f_{(\alpha/2),\ n^{**},\ n^*}$$

<u>Table 3.58</u>: Test results for the equality of variances regarding sample sizes 18 and above extracted from Tables 3.46 to 3.57 (on pages 195 to 206).

SAMPLE SIZE		SAMPLE VARIANCE RATIO	TABULATED F-VALUES[1]	
n_1	n_2	R^2	f_1 $\alpha = 0.5$	f_2 $\alpha = 0.5$
18	19	**2.2500**	**2.7230 - 2.6158**	**2.6667 – 2.5590**
40	40	**0.7396**	**2.0739 – 2.0089**	**2.0739 – 2.0089**
26	26	**0.7225**	**2.2422 – 2.1816**	**2.2422 – 2.1816**
25	21	**0.6400**	**2.3273**	**2.4076**
18	19	**1.1025**	**2.7230 - 2.6158**	**2.6667 – 2.5590**
22	21	**0.5625**	**2.4247**	**2.4645 – 2.4076**
40	40	**1.0000**	**2.7230 - 2.6158**	**2.6667 – 2.5590**
27	22	**0.7396**	**2.2759 – 2.2174**	**2.3675 –2.3082**
25	21	**0.9216**	**2.3273**	**2.4076**
18	19	**1.0816**	**2.7230 - 2.6158**	**2.6667 – 2.5590**
19	22	**1.1236**	**2.5590 – 2.5027**	**2.5338 – 2.4247**

[1] Obtained from Pearson and Hartley (1976) on page 179

Conclusion:

At the 5% level of significance, we see no instance in the above table where the value of R^2 exceeds the corresponding tabulated value (or value-range). Consequently at this level of significance, we have no reason to reject the null hypothesis of the equality of variances in question.

(b) The normality assumption:

To verify this assumption, we subjected all the ungrouped datasets with sample sizes 18 or above, to the Shapiro-Wilk test. A summary of the results is shown below.

Summary of the results of the Shapiro-Wilk Test

NOTE: *The values of the W–statistic which are tabulated below should to be interpreted* according to Pearson and Hartley (1976) on page 37 *as follows*:

A large value of W close to 1.0000 would be indicative of our sample data order statistics falling very close to the corresponding normal-order statistics. In other words, observed large values of W in the proximity of 1.0000 may be regarded as *not significant*, i.e. associated with the conclusion that the normality assumption is reasonable. See also the authors' Example 27 in which W = 0.970 is regarded as *not significant* in the sense just described *vis a vis* W = 0.714 which is regarded as *significant*, i.e. a value which the authors associate with non-normality.

Table 3.59: The values of the W-statistic for ungrouped samples.

SULCUS CONSIDERED	W-statistic
1. Stem of the Anterior Rami in the right hemisphere (control)	**0.9004**
2. Stem of the Anterior Rami in the left hemisphere (control)	**0.9158**
3. Anterior Ascending Ramus in the right hemisphere (control)	**0.9530**
4. Anterior Ascending Ramus in the left hemisphere (control)	**0.9664**
5. Anterior Ascending Ramus in the right hemisphere (case)	**0.9781**
6. Anterior Ascending Ramus in the left hemisphere (case)	**0.9748**
7. Anterior Horizontal Ramus in the right hemisphere (control)	**0.9611**
8. Anterior Horizontal Ramus in the left hemisphere (control)	**0.9664**
9. Anterior Horizontal Ramus in the right hemisphere (case)	**0.8966**
10. Anterior Horizontal Ramus in the left hemisphere (case)	**0.9791**
11. Sole Triangular Sulcus in the right hemisphere (control)	**0.9177**
12. Sole Triangular Sulcus in the left hemisphere (control)	**0.9446**

We see that, all the values in this table are, to two decimal places, 0,90 and above.

Following the same line of judgement used in *Example 27* in Pearson and Hartley (1976) Biometrika Tables on pg 37, *we see no reason to doubt the normality of the x data used in the t-tests* to be examined shortly below.

Table 3.60: Two-sided t-tests for the mean difference in two pairs of samples selected from Table 3.46 on page 195 [Stem of the Anterior Rami].

	RIGHT HEMISPHERE		LEFT HEMISPHERE		p- VALUE
	n_1	$\bar{x}_1$ (s_1)	n_2	$\bar{x}_2$ (s_2)	
UNGROUPED					
CONTROL	**18**	**0.79 (0.39)**	**19**	**0.70 (0.26)**	**0.387**
Y PATTERN					
CONTROL	**18**	**0.79 (0.39)**	**19**	**0.70 (0.26)**	**0.387**

Table 3.61: Two-sided t-tests for the mean difference in five pairs of samples selected from Table 3.47 on page 196 [Anterior Ascending Ramus].

	RIGHT HEMISPHERE		LEFT HEMISPHERE		p - VALUE
	n	$\bar{x}_1$ (s_1)	n	$\bar{x}_2$ (s_2)	
UNGROUPED					
CONTROL	40	1.43 (0.63)	40	1.50 (0.73)	0.647
CASE	26	1.76 (0.57)	26	1.76 (0.67)	1
TYPE 3					
CONTROL	25	1.37 (0.63)	21	1.47 (0.79)	0.624
Y PATTERN					
CONTROL	18	1.17 (0.67)	19	1.18 (0.64)	0.946
VU PATTERN					
CONTROL	22	1.65 (0.52)	21	1.79 (0.69)	0.447

Table 3.62: Two-sided t-tests for the mean difference in five pairs of samples selected from Table 3.48 on page 197 [Anterior Horizontal Ramus].

	RIGHT HEMISPHERE		LEFT HEMISPHERE		p- VALUE
	n	$\bar{x}_1$ (s_1)	n	$\bar{x}_2$ (s_2)	
UNGROUPED					
CONTROL	40	1.35 (0.53)	40	1.47 (0.53)	0.301
CASE	27	1.70 (0.59)	22	1.69 (0.69)	0.925
TYPE 3					
CONTROL	25	1.18 (0.46)	21	1.31 (0.48)	0.373
Y PATTERN					
CONTROL	18	1.23 (0.50)	19	1.27 (0.48)	0.790
VU PATTERN					
CONTROL	22	1.44 (0.54)	21	1.65 (0.52)	0.213

Table 3.63: Two-sided t-tests for the mean difference in one pair of samples selected from Table 3.52 on page 201 [Sole Triangular Sulcus].

	RIGHT HEMISPHERE		LEFT HEMISPHERE		p- VALUE
	n	$\bar{x}_1$ (s_1)	n	$\bar{x}_2$ (s_2)	
UNGROUPED					
CONTROL	19	1.53 (0.65)	22	1.42 (0.62)	0.592

3.3.4 CONTROL AND CASE STUDIES

This section addresses the following question implied in Chapter Two:

- ***Is there a difference between the means of individual sulcal lengths measured in whole brains (control group) as opposed to the means of individual sulcal lengths measured in separate hemispheres (case group)?***

The above question was posed for ungrouped data only. It was considered unnecessary to pose this question separately for grouped data. The effect of belonging to either the control or the case category is also illustrated in Figures 3.41 to 3.52 (on pages 208 to 213). For a comparison of sulcal lengths with respect to control- and case- categories, we have chosen

to use a t-test for the mean difference. Furthermore only samples of size 18 and higher have been considered. The results are shown below in Tables 3.64 and 3.63.

Table 3.64: Two-sided t-tests for the mean difference in two pairs of samples selected from Table 3.47 on page 196 [Anterior Ascending Ramus].

	CONTROL CATEGORY		CASE CATEGORY		p- VALUE
	n	$\bar{x}_1$ (s_1)	n	$\bar{x}_2$ (s_2)	
RIGHT HEMISPHERE	40	1.43	26	1.76	0.036
LEFT HEMISPHERE	40	1.50	26	1.76	0.152

Table 3.65: Two-sided t-tests for the mean difference in two pairs of samples selected from Table 3.48 on page 197 [Anterior Horizontal Ramus].

	CONTROL CATEGORY		CASE CATEGORY		p- VALUE
	n	$\bar{x}_1$ (s_1)	n	$\bar{x}_2$ (s_2)	
RIGHT HEMISPHERE	40	1.35	27	1.70	0.012
LEFT HEMISPHERE	40	1.47	22	1.69	0.174

Table 3.66: Summary of p-values in Tables 3.59 to 3.65 (on pages 217 to 220).

GROUP A p - values *REFLECTING INTERHEMISPHERIC COMPARISONS* FOR *BOTH CASE (separate hemispheres) and CONTROL (whole brain) CATEGORIES*	**GROUP B p - values** *REFLECTING THE COMPARISON BETWEEN CASE (separate hemispheres) and CONTROL (whole brain) CATEGORIES*
0.387	**0.036**
0.387	**0.152**
0.647	**0.012**
1.000	**0.174**
0.624	
0.946	
0.447	
0.301	
0.925	
0.373	
0.790	
0.213	
0.592	

In this table, GROUP A involves a comparison of the right- and left- hemispheres of both control (whole brains) and case (separate hemispheres), while GROUP B involves a comparison of case and control. In the latter group the right- and left- hemispheres do not necessarily belong to the same individual while they always belong to the same individual in the whole brain category. We see then that all p-values in GROUP A (interhemispheric comparisons) are well above the often-used cut-off of 0.05 level of significance, implying that in all samples belonging to this group, we *do not* reject the null hypothesis of no difference in the mean sulcal lengths of the right- and left- hemispheres. However, in GROUP B (case and control comparisons) the results are, as one would expect from Figures 3.41 – 3.52 (pages 208 – 213) and the nature of the specimens themselves, mixed.

3.3.5 REPORT ON MEAN INTERSULCAL LENGTHS IN THE FRONTOPARIETAL OPERCULUM

Each intersulcal length (recorded at the level of the termination of the anterior ascending ramus) was measured twice. It was noted that there was a very close correspondence between the values obtained for the first- and the second- recordings, of each intersulcal length. This feature is illustrated in the data sets that were recorded Appendix H [Tables H.1 and H.2; Tables H.4 and H.5; Tables H.7 and H.8; Tables H.10 and H.11; Tables H.13 and H.14; Tables H.16 and H.17; Tables H.19 and H.20; Tables H.22 and H.23, on pages to 361 - 393].

The mean of the first- and second- recordings of each intersulcal length, at the stipulated level, was referred to as the composite recording (for each intersulcal length). The composite lengths are also reflected in Appendix H [Tables H.3, H.6, H.9, H.12, H.15, H.18, H.21, and H.24 on pages 364&365, 368&369, 372, 375, 380&381, 386&387, 390, and 393 respectively]. These composite recordings were used to calculate the mean intersulcal lengths as reported in Tables 3.67 to 3.70 on pages 223 to 224.

Note that those specimens having an orbital origin of the anterior horizontal ramus (see Fig 3.18, on pg 157) were excluded from the calculation of intersulcal lengths in the pars triangularis.

Table 3.67: Intersulcal lengths anterior to the anterior ascending ramus for the control group [see Fig 2.10 (c) on page 105], expressed in centimetres.

DISTANCE BETWEEN:	RIGHT HEMISPHERE		LEFT HEMISPHERE	
	n	$\bar{x}_1$ (RANGE)	n	$\bar{x}_2$ (RANGE)
1. AAR and AHR	32	1.92 (0.6 – 3.05)	42	2.0 (1.0 – 3.45)
2. AAR and the Sole Triangular sulcus	16	1. 0 (0.2 – 1.85)	18	1.09 (0.6 – 1.65)
3. AAR and Tra	2	1.3 (0.75 – 1.85)	7	1.67 (1.0 – 2.4)
4. AAR and Trm	2	1.65 (1.15 – 2.15)	2	1.15 (0.9 – 1.4)
5. AAR and Trp	2	1.28 (1.1 – 1.45)	6	1.17 (0.2 – 1.7)

Table 3.68: Intersulcal lengths posterior to the anterior ascending ramus for the control group [see Fig 2.10 (b) on page 105]

DISTANCE BETWEEN:	RIGHT HEMISPHERE		LEFT HEMISPHERE	
	n	$\bar{x}_1$ (RANGE)	n	$\bar{x}_2$ (RANGE)
1. AAR and a single Opercular sulcus	19	0.70 (0.25 – 1.9)	14	0.76 (0.1 – 1.75)
2. AAR and Ope_1	2	0.60 (0.4 – 0.8)	-	-
3. AAR and Ope_2	2	0.90	-	-
2. AAR and IPRCS	46	1.21 (0.4 – 2.4)	45	1.01 (0.3 – 2.1)
3. IPRCS and CF	45	1.48 (0.5 – 2.6)	45	1.41 (0.5 – 2.5)
4. CF and IPOCS	43	1.60 (0.8 – 2.45)	43	1.85 (1.1 – 3.0)

Table 3.69: Intersulcal lengths anterior to the anterior ascending ramus for the case group [see Fig 2.10 (c) on page 105], expressed in centimetres.

DISTANCE BETWEEN:	RIGHT HEMISPHERE		LEFT HEMISPHERE	
	n	$\bar{x}_1$ (RANGE)	n	$\bar{x}_2$ (RANGE)
1. AAR and AHR	15	1.97 (1.45 – 2.65)	18	1.85 (0.9 – 2.95)
2. AAR and a single Triangular sulcus	6	0.96 (0.7 – 1.65)	9	1.02 (0.55 – 1.6)
3. AAR and Tra	6	1.31 (0.8 – 1.65)	1	1.1
4. AAR and Trm	-	-	-	-
5. AAR and Trp	4	0.75 (0.85 – 0.9)	1	0.5

Table 3.70: Intersulcal lengths posterior to the anterior ascending ramus for the case group [see Fig 2.10 (b) on page 105]

DISTANCE BETWEEN:	RIGHT HEMISPHERE		LEFT HEMISPHERE	
	n	MEAN (RANGE)	n	MEAN (RANGE)
1. AAR and a single Opercular sulcus	7	0.88 (0.4 – 1.35)	9	0.74 (0.35 – 1.3)
2. AAR and Ope_1	-	-	-	-
3. AAR and Ope_2	-	-	-	-
4. AAR and IPRCS	26	1.05 (0.1 – 1.85)	25	1.50 (0.5 – 2.55)
5. IPRCS and CF	26	1.60 (0.75 – 2.35)	24	1.40 (0.7 – 2.2)
6. CF and IPOCS	24	1.63 (0.8 – 2.45)	23	1.91 (0.9 – 2.95)

The data of Tables 3.67 to 3.70 (on pages 223 to 224) is submitted as part of the quantitative record of measurements in the frontoparietal operculum (for reference purposes). It is accepted that as they stand, the data is insufficient for either interhemispheric comparisons, or comments on gyral packing.

4 DISCUSSION

The inextricable link between cognition, memory, language, speech, and quality of life, makes the preservation of language areas, as far as is possible, one of the primary goals during surgery of language associated areas. A thorough knowledge of the fissures and sulci, as landmarks, aids in such preservation. The study of the fissures and sulci of the frontal operculum contributes to this end, by elaborating on and clarifying existing knowledge in this field.

The discussion, as follows, first examines the methodology employed in the present study, with a view to exposing its possible limitations. The descriptive- and quantitative-outcomes of this study are then considered relative to the questions posed in Chapter 2. Note that the first level questions posed by this study are reported on in Chapter 3 as part of the results. These questions relate to the:

- Incidences of the Pertinent Features of relevant fissures and sulci,
- Incidences of the Types of Sulcal Connections,
- Incidences of the Patterns of the Anterior Rami,
- Mean Sulcal Lengths, and
- Mean Intersulcal Lengths, in the frontal operculum.

The outstanding questions that relate to the comparison of the findings in the present study

(as presented in Chapter 3), with that reported on in the literature survey form the subject of this discussion.

4.1 DISCUSSION ON THE METHODS USED TO ACQUIRE DATA IN THE PRESENT STUDY

4.1.1 DISCUSSION ON THE METHODS USED TO ACQUIRE DESCRIPTIVE DATA, THE ASSOCIATED LIMITATIONS, AND THE RECOMMENDATIONS ARISING THERE-FROM

The recognition of sulci (and fissures) involves personal decision-making relative to the reports of preceding research. Studies of this nature are therefore saddled with an unavoidable element of subjectivity. Although care was exercised so as to minimise the effect of the expected subjectivity, the present study still constitutes the observations and decisions of a single individual. The procedure for reducing the subjectivity that was inherent in the present study:

- Is set out in sections: 2.8 (on pages 78 to 86); and 3.1.1 (on pages 114 to 115),
- And illustrated in Figures: 3.1 (on pg 116); 3.2 (on pg 117); 3.3 (on pg 118); 3.4 (on pg 119); and 3.5 (on pg 120).

A strict adherence to a chosen convention for the identification and classification of fissures and sulci relative to the expected locality of functional cortical areas, appeared to

be the only route to reliable results, in the absence of supporting electrophysiological-, cytoarchitectonic-, or functional imaging- studies. It is ***however acknowledged, that the validity of the chosen convention can only be established by such supporting studies.***

The convention used in the present study where sulci were identified from posterior to anterior, relative to the last ascending branch (or alternatively the termination of the posterior ramus) of the lateral fissure led to the conclusion that an extra sulcus, when present, was a double precentral sulcus [see Figs 3.1 (on pg 116); as well as Figs 3.2 and 3.3 (on pages 117 and 118 respectively) for an illustration of this procedure]. It might well be that a double postcentral sulcus or even a double central fissure was present. Indeed, Bergman, Afifi, and Miyauchi (2004) in the Virtual Hospital, Illustrated Encyclopedia of Human Anatomic Variation, quote Gerlach. E.J. and Weber. H. (*über ein menschliches Gehirn mit beiderseitiger Verdopplung der Zentralfurche. Anat. Anz. 67:440-452, 1929*) on the presence of a double central fissure. When analysing the picture (as published on the internet) according to the criteria set out for orientation in the present study, it was discovered that the extra sulcus might well be a double precentral sulcus. This serves to reinforce the conclusion that the dilemma associated with the chosen convention for orientation can only be resolved by supporting studies of a discerning nature. The dilemma itself exposes the limitation of examining fissures and sulci without the context provided by adequate supporting studies.

4.1.2 DISCUSSION ON THE METHODS USED TO ACQUIRE QUANTITATIVE DATA, THEIR LIMITATIONS, AND THE RECOMMENDATIONS ARISING THERE-FROM

4.1.2.1 DIRECT METHODS OF MEASURING SULCAL- AND INTERSULCAL-LENGTHS

The measurement of gyri and sulci on the surface of the brain is problematic. The soft texture of the brain makes manipulation difficult. Hardening the brain would invariably involve shrinkage, making the accuracy of measurements under these circumstances questionable. The curvatures of both the brain as a whole, and that of the gyri as well, introduce further complications, as discussed in section 4.1.2.2 at pg 229. The chosen methods for the measurement of sulcal- and intersulcal- lengths in the present study represented the best possible compromise within the timescale of this project. They were far from sophisticated, but simple, easy to execute, and inexpensive. The only drawback was that the measurement of sulcal lengths was very time-consuming. They represent the only clearly stated method of measuring sulci and gyri encountered in the literature to date.

The reproducibility of the methods, were monitored, by taking a repeat measurement in each case. It was noted that there was a very close correspondence between the values obtained for the first- and the second- recordings of each sulcal- and intersulcal length. The data that were recorded in the Tables of Appendices E and H, illustrate this point. The conclusion is that the method for measuring sulcal lengths [see section 2.9 (on pages 97 to 103)] and intersulcal lengths [see section 2.10 (on pages 103 to 107)], produced recordings that were reproducible and were hence reliable. However, the placement of pins and

needles is again, a personal decision. Although the convention for such decision-making is spelt out in detail and was strictly adhered to, inter-observer reliability studies are indicated here as well.

4.1.2.2 INDIRECT METHODS OF MEASURING SULCAL- AND INTERSULCAL- LENGTHS

Obtaining fresh brain specimens, especially for research purposes is a difficult process. The Departments of Anatomy that were explored appeared to rely on existing collections of brain specimens (hence the decision to use the collections of the Departments of Anatomy of the University of Witwatersrand and Walter Sisulu University, in the present study). But, research into fissures and sulci is a protracted process. The ideal would be to work from some sort of permanent visual record, which would release the sample for teaching purposes. This is the background behind which the indirect methods were probed.

The first method explored, was that of measurement by use of photographic negatives. It was considered neither feasible nor sufficiently accurate, in view of the difficulties associated with obtaining a standard magnification of the negatives [section 3.1.2.2 (i), pg 122]. The next method explored, was that of measurement by use of printed photographic images. Thus method was subject to the same pitfall that the previous indirect method of measuring would have faced, if the problems around obtaining a standard magnification (of the negatives) had been resolved. It was found that there were changes in magnification relative to changes in height from the camera on the same specimen [see section 3.1.2.2 (ii) on pages 122 and 123, as well as Figs 3.6 and 3.7 on pg 124]. This led to the conclusion

that the manipulations required to produce accurate recordings of sulcal- and intersulcal-lengths (by analysis of photographic negatives and printed images) were beyond the scope of this study. Both methods were therefore abandoned. The photographic methods of measurement, that were explored by the present study, were also used by other researchers. There appears however, to be no evidence that these methods were properly validated.

The third method explored, was that of measurement by use of pen tracings of the fissures and sulci on the surface of the cerebral hemispheres. In view of the finding in section 3.1.2.2 (iii) on pg 123 (see Fig 3.8 on pg 125) that the margin of error when using pen tracings as a method of measurement, was probably high, it was concluded that the reliability of this method, was probably low. Pen tracings of the fissures and sulci were therefore judged to be unsuitable for the accurate measurement of sulcal- and intersulcal-lengths. This method of measurement was abandoned. Its contribution to a study of this nature is that it is an excellent and inexpensive means of making a visual record of the features of fissures and sulci. It also makes the identification of descriptive details in photographs much simpler.

Although measurement by use of the microscribe digitiser was abandoned [see section 3.1.2.2 (iv), on pg 126] it is the only indirect method explored that holds the promise of providing quick and accurate measurements of sulcal lengths, intersulcal lengths, gyral width, and surface area. Solving the technical problems associated with the equipment is, however, a proviso.

4.1.3 SUMMARY OF THE RECOMMENDATIONS ARISING FROM THE DISCUSSION ON METHODS

It is suggested through the medium of this text that further studies on –fissures and –sulci: be conducted by more than one observer (such studies were beyond the time-scale of the present project) and consider both structure and function.

4.2 DISCUSSION ON THE DESCRIPTIVE ASPECT OF THE PRESENT STUDY

The thrust of the present study was confirmatory and was based on the work of:

- Ebeling et al (1989), as regards the Types of Connections of fissures and sulci of the frontal operculum, and
- Others, as regards the Patterns of the Anterior Rami (anterior ascending and anterior horizontal) of the lateral fissure.

An important preamble to the above- mentioned confirmation was seen to be:

- A rigorous process of orientation and the careful identification of the boundaries of

the frontal opercula, a well as

- A comparison between the features of the relevant individual sulci, as reported in the literature survey, with those that are reported in the present study. The purpose

of such a prolonged preamble was to establish, as far as possible, whether or not equivalent structures were being compared. It should be noted that the only comprehensive reference sourced to date on the fissures and sulci of the frontal lobe was that of Ono et al (1990). This poses a limitation for critical comment especially on sulci that are not well reported on elsewhere in the literature.

4.2.1 DISCUSSION ON ORIENTATING SULCI RELATIVE TO THE REMAINING QUESTIONS POSED IN CHAPTER TWO

The outstanding question is:

- ***Are the incidences of the permanent features of the orientating fissures and sulci [as listed in sections 2.8.2 (a) and 2.8.2 (b) at pages 87 and 89 respectively], consistent with the findings of previous studies reviewed thus far?***

The three pertinent features examined for the central fissure and the postcentral sulcus were: the pattern of the fissure (and sulcus) as a whole; the shape of the inferior termination of the fissure (and sulcus); and the connections of the fissure (and sulcus) at and below the level of the inferior frontal sulcus.

The finding in the present study that the central fissure was predominantly continuous is well established in the literature, as reviewed by Ono et al (1990). Ono et al (1990), in their own study, describe an interrupted pattern only in the right hemisphere and quote an incidence of 8%. The number of segments, when the pattern of the central fissure was of the interrupted type, is not stated. The incidence of the continuous central fissure in the study of Ono (1990) is slightly higher than the incidence reported in the present study for the control group (92% in both hemispheres verses 78.5% in the right hemisphere and 80% in the left hemisphere), but very similar to that reported in the case group (91.1% in the right hemisphere and 90.9% in the left hemisphere).

The straight-, 'Y'(inverted)- and 'T' (inverted) - shapes of the inferior termination of the central fissure reported by Ono et al (1990) were observed in the control group in the present study. Only the inverted 'T'- shape was not observed in the case group. Although there were differences in the incidences of the shapes of the inferior termination of the central fissure between the present study and that of Ono et al (1990), it is not clear whether or not they include the approach to the inferior termination, or the termination itself (as in the present study). A direct comparison of the incidences of the shapes of the inferior termination of the central fissure, between the study of Ono et al 1990) and the present study, was therefore not possible.

The connections of the central fissure as reported by Ono et al, (1990) were also found in the present study. The most significant connection of the central fissure, for the purposes of the present study, was that with the lateral fissure. When comparing the findings of the present study (see Table 3.3 on pg 132) with that of others reviewed in the literature survey

(see Table 1.2 on pg 26), on the connection of the central fissure with the lateral fissure, it can be seen that the incidence of: (15.4%) in the right hemisphere and (12.3%) in the left hemisphere in the control category; and (17.8%) in the right hemisphere and (8.9%) in the left hemisphere in the case category, falls within the reference range of 5% to 19%.

Ide and Aboitiz (2001) in a study of forty postmortem brains report on the inferior termination of the postcentral sulcus. They found the inferior postcentral sulcus to have only two types of endings: either connected to the lateral fissure [Type I of Ide and Aboitiz (2001)], or ending freely [terminating above the lateral fissure, Type II of Ide and Aboitiz (2001)]. The incidence of a connection of the inferior postcentral sulcus with the lateral fissure was 52.5% in the left hemisphere and 47.5% in the right hemisphere. They state that their finding of an approximately equal preponderance of these two connections of the inferior postcentral sulcus, in both hemispheres, concurred with that of Ono et al (1990). Ide and Aboitiz (2001) report a sexual dimorphism in the incidence of their Types I and II. Type I was found to be more predominant in males, and Type II more predominant in females.

The present study reports three possible connections for the inferior postcentral sulcus: a connection with the lateral fissure, a free ending, and a rare connection with both the lateral fissure and the central fissure (1.5% in the left hemisphere only in the control group and 2.2% in the right hemisphere only in the case group, see Table 3.7 on pg 136). In contrast to the previous two studies, the connection of the inferior postcentral sulcus to the lateral fissure predominated in the present study (78,5% in the left hemisphere, and 72.3% in the

right hemisphere, for the control group; as well as 79.5% in the left hemisphere, and 68.9% in the right hemisphere, for the case group). The trend of a higher incidence of this connection in the left hemisphere was however, observed in the present study. The higher incidence of the Type I of Ide and Aboitiz (2001) in the present study may well be a reflection of the predominance of male cadavers over female cadavers in South African medical schools [in the past (personal experience)]. In view of the more consistent results obtained for the central fissure, it is suggested that the connections of the inferior termination of the postcentral sulcus may be subject to greater variability.

The conclusion is that the primary fissure used for orientation purposes in the present study (the central fissure) is similar to the fissure used for orientation purposes, in the studies reported on in the literature review.

The information on the:

- **Connections of the Central Fissure other than to the Lateral Fissure,**
- **Anterior- and, posterior- subcentral sulci, and the**
- **Postcentral sulcus, is submitted as an aid to the recognition of patterns in the frontoparietal operculum (see Table 3.4 on pg 133, and Tables 3.5 to 3.7, pages 135 to 136; with Fig 2.3 on pg 82 and Fig 2.6 on pg 88).**

4.2.2 DISCUSSION ON THE BOUNDARY SULCI RELATIVE TO THE REMAINING QUESTIONS POSED IN CHAPTER TWO

The outstanding question is:

- ***Are the incidences of the pertinent features [see them listed in sections 2.8.2 (c) and 2.8.2 (d) on pages 90 and 91 respectively] of the two boundary sulci mentioned in section 2.1.2 (a) on page 59, consistent with the findings of previous researchers?***

The three pertinent features examined for the precentral sulcus were: the pattern of the sulcus as a whole; the shape of the inferior termination of the sulcus; and the connections of the sulcus at and below the level of the inferior frontal sulcus. The four pertinent features examined for the inferior frontal sulcus were: the pattern of the sulcus as a whole; the connections of the posterior end of the sulcus; the total number of branches into the frontal operculum; and the existence of the accessory sulci (opercular and triangular) as branches.

(a) THE PRECENTRAL SULCUS (SULCI)

Unlike in other studies, a small notch from the longitudinal fissure into the superior frontal gyrus, was also included in the counting of the segments of the precentral sulcus. Including the notch did not interrupt the quick and smooth process of examining the sulcus as a whole (from the lateral fissure inferiorly to the longitudinal fissure superiorly). This notch

is actually a part of the medial precentral sulcus. In contrast to the study of Ono et al (1990), the present study also reports the rare continuous pattern for the single precentral sulcus (one case in each hemisphere in both the control- and case- groups, see Table 3.9 on pg 140).

Double precentral sulci were seen slightly more often in the left- than in the right hemisphere [9.2% in the left hemisphere versus 6.2% in the right hemisphere in the control category; and 2.2% in the left hemisphere versus 0% in the right hemisphere of the case category, see Table 3.8 on pg 138].

The implications of the finding of double precentral sulci (see Figs 3.2 and 3.3 on pages 117 and 118 respectively) in the present study were that: the decision to close the posterior boundary of the frontal operculum with either the inferior precentral sulcus or the inferior part of the anterior precentral sulcus was justified, and that the criteria associated with the description of the Types of Sulcal Connections (of the frontal operculum) required adjustment.

The present study reports the same shapes for the termination of the single precentral sulcus as does Ono et al (1990). The incidences of these shapes in both hemispheres, for the control- and case- categories are also similar to that of Ono et al (1990) although again, it is not clear whether or not the approach to the inferior termination, or the termination of the sulcus itself, was considered (in the study of Ono et al, 1990).

Tables 3.11 and 3.12 (on pg 142) as well as 3.13 and 3.14 on pg 143), relative to the literature surveyed thus far, constitutes new data on the double precentral sulci.

The most significant connections of the single precentral sulcus, for the purposes of this study, were those to the lateral fissure and to the inferior frontal sulcus. When examining Table 3.15 (on pg 144) it can be seen that the inferior precentral sulcus was connected to: the lateral fissure only, as well as to both the lateral fissure and the inferior frontal sulcus. Putting this together yields the total incidence of the connection of the single precentral sulcus with the lateral fissure. When comparing Tables 3.15, on pg 144 and 1.3, on pg 27, it can be seen that the incidences of this connection: 19.7% in the right hemisphere and 18.6% in the left hemisphere, in the control category, falls within the reference range of 15% to 42%, that excludes the study of Ebeling et al (1989). The incidences of this connection for the case category: 11.1% in the right hemisphere, and 13.6% in the left hemisphere, falls slightly short of the 15% that was reported by Cunningham (1892). The implications are that the single precentral sulcus as reported in the present study appears similar to that reported in the literature survey, except for the study of Ebeling et al (1989).

The information on the connections of the inferior ends of the anterior- and posterior-precentral sulci, at and below the level of the inferior frontal sulcus (relative to the literature surveyed thus far) constitutes new data (see Tables 3.16 and 3.17 on pages 144 and 145).

(b) THE INFERIOR FRONTAL SULCUS

A comparison of the findings of the present study [on the connection of the inferior frontal sulcus with the single inferior precentral sulcus (67.2% in the right hemisphere and 87.8% in the left hemisphere, in the control category; as well as 75.6% in the right hemisphere and 82.2% in the left hemisphere, in the case category, see Table 3.18 on pg 146)], with that of other studies reviewed in the literature (see Table 1.4 on pg 27) reveals that the incidence of such a connection is within the reference range of: 67.4% to 90%.

The picture is not so clear- cut when considering the pattern of the inferior frontal sulcus itself. The only pattern observed in the present study, not reported by Ono et al (1990), was that of interruption with five segments (2.2% in the left hemisphere, case group only). The present study has a considerably larger sample number than that of Ono et al (1990), so it is not surprising that evidence of more segmentation of the inferior frontal sulcus has emerged. Ono et al (1990) report that the most frequent pattern of the inferior frontal sulcus was that of a continuous sulcus (56% in the right hemisphere and 40% in the left hemisphere). The incidence of this pattern in the present study (see Table 3.18 on pg 146) was: 23.4% in the right hemisphere and 34.4% in the left hemisphere, in the control group; and 13.6% in the right hemisphere and 17.8% in the left hemisphere in the case group. This was not viewed as a serious difference because it was not clear from the report of Ono et al (1990), whether or not pseudo-connections were considered. In the present study, a pseudo-connection was recorded as an interrupted pattern.

Ono et al (1990) report a range of 1 to 3 branches of the inferior frontal sulcus into the frontal operculum (with 2 branches predominating, 64% in the right hemisphere and 76% in the left hemisphere). The present study reports a range of 1 to 5 branches of the inferior frontal sulcus into the frontal operculum (with 2 and 3 branches predominating in both hemispheres in the control group; and a fairly even spread among 1, 2, and 3 branches in the case category, see Table 3.20 on pg 147).

The general conclusion is that the *critical aspects* of the boundary sulci examined in the present study are similar to that described in the literature survey, with the exception of the incidence of a connection between the inferior precentral sulcus and the lateral fissure, as quoted by Ebeling et al (1989).

4.2.3 DISCUSSION ON THE SULCI OF THE FRONTAL OPERCULUM RELATIVE TO THE REMAINING QUESTIONS POSED IN CHAPTER TWO

The outstanding question is:

- ***Are the incidences of the features of the major- and accessory- sulci of the frontal operculum that were listed in section 2.8.2 (e to h) on pages 93 to 96, consistent with the findings of previous researchers, for ungrouped data?***

4.2.3.1 DISCUSSION ON THE MAJOR SULCI OF F3

Much of the information on the major sulci (anterior ascending ramus-, anterior horizontal ramus-, and stem of the anterior rami where applicable), in the literature reviewed thus far, is devoted to the patterns associated with them. They will therefore be discussed primarily within this context in section 4.2.4 (on pages 247 to 257).

The information on the shapes of the anterior rami (relative to the literature reviewed thus far) constitutes new data (see Tables 3.23 on pg 153 and 3.26, on pg 155; as well as Fig 2.7 on pg 95). Since detailed information on the anterior horizontal ramus in the literature reviewed thus far is scanty, Tables 3.25 and 3.27 (on pages 154 and 156 respectively) are a contribution in this regard.

4.2.3.2 DISCUSSION ON THE ACCESSORY SULCI OF F3

(a) THE OPERCULAR SULCUS (SULCI)

The opercular sulcus, in the present study, was found to be present as one sulcus or as two sulci (see Table 3.28 on pg 159). The only hint of a second opercular sulcus, in the literature reviewed thus far, comes from the study of Tomaiuolo et al (1999), who reports a 'small dimple (see line 6 of the last paragraph on pg 10 for a definition) in almost all hemispheres'. The present study uses a definition of sulci that includes notches and clearly stipulates the boundaries of the pars opercularis. It is possible, that these factors may have

led to a consideration of the opercular sulci that was more inclusive than was considered previously.

In the literature reviewed thus far, the incidence of the opercular sulcus, as described in the present study, has been reported in the studies of Ono et al (1990) and Tomaiuolo et al (1999). These incidences are relative to a single opercular sulcus [although dimples are mentioned by Tomaiuolo et al (1999)]. Ono et al (1990) report an incidence of 64% in the right hemisphere and 72% in the left hemisphere, for a sole diagonal (opercular sulcus), while Tomaiuolo et al (1999) report an incidence of 32% in the right hemisphere and 34% in the left hemisphere. Both studies show a slightly greater incidence in the left hemisphere. Since the present study reports sole- as well as double- opercular sulci, it is difficult to make direct comparisons with the studies of Ono et al (1990) and Tomaiuolo et al (1999) relative to incidences.

The combined incidences of the presence of the opercular sulci (sole and double), including notches, in the present study were:

- 61.6% in the right hemisphere and 52.3% in the left hemisphere in the control category, and
- 68.2% in the right hemisphere and 71.1% in the left hemisphere in the case category (see Table 3.28, at pg 159).

These incidences of the opercular sulcus (sulci) were therefore within the reference range of: 32%-64% in the right hemisphere, and 34%-72% in the left hemisphere. This statement

is also true when considering the sole opercular sulcus only. Note that in the present study, a slightly greater incidence of the opercular sulcus in the left hemisphere was observed only in the case group (when the opercular sulcus was present as two sulci, and the sample size was smaller).

Ono et al (1990) and Tomaiuolo et al (1999) appear to regard the opercular sulcus as a sulcus of the pars opercularis, as does the present study, rather than as a strictly diagonal sulcus. This appears to contrast with the approach of Galaburda (1980) who depicts the opercular sulcus as diagonal in shape, with a connection to the anterior ascending ramus only, in a study of one hundred and two brains.

Galaburda (1980) states that one of the objectives of his study was to determine whether the posterior-superior branch of the anterior ascending ramus, described by Eberstaller in 1884 (as the diagonal sulcus) could be confirmed. It may be possible that the study of Galaburda (1980), focused on one particular opercular sulcus, the diagonal sulcus (see acknowledgements pg vi). Galaburda (1980) found that this diagonal sulcus was: absent (incidence unstated); present in both hemispheres (frequently, incidence unstated); or present in either the right hemisphere (in 13 cases) only or in the left hemisphere (in 27 cases) only. In contrast to the study of Galaburda (1980), the present study reports that there appears to be an approximately equal distribution of the diagonal sulcus (when strictly diagonal) to both hemispheres (see Table 4.1 on pg 244). It is possible that the opercular sulcus when diagonal in shape and the diagonal sulcus of Galaburda (1980) might be similar sulci. However, a comparison of the connections of the diagonal sulcus, in

the present study, with the sole connection reported by Galaburda (1980) reveals a different picture.

The incidence of the connections of the sole opercular sulcus when diagonal in shape is given in Table 4.2 on page 245 (control only). The incidence of the connections of the first- and second- opercular sulci when diagonal in shape is given in Table 4.3 on page 245 (control only). It should be noted that that the frequent connection of the diagonal sulcus with the anterior ascending ramus of the lateral fissure [observed by Galaburda (1980)] was not observed in the present study. An incidence of three in the left hemisphere (in the control group only) for the sole opercular sulcus, and one in the right hemisphere (in the control group only) for the second opercular sulcus, is certainly not frequent. This is a notable discrepancy between studies of comparable sample size (two hundred and four hemispheres in Galaburda (1980) and two hundred and twenty hemispheres in the present study.

Table 4.1: Incidence of the opercular sulcus when diagonal in shape in the present study. Incidences expressed as number of cases.

Sulcus:	PRESENT IN BOTH HEMISPHERES	PRESENT IN RIGHT HEMISPHERE ONLY	PRESENT IN THE LEFT HEMISPHERE ONLY
Sole Opercular :			
Control	**3**	**5**	**6**
Case		**4**	**10**
Double:			
First control		**2**	**1**
First case		**1**	**2**
Second control		**3**	**2**
Second case		**2**	**2**

Table 4.2: Connections of the sole opercular sulcus when diagonal in shape (control only).

CONNECTION WITH:	RIGHT HEMISPHERE		LEFT HEMISPHERE	
	n=8	FREQUENCY (PERCENTAGE)	n=9	FREQUENCY (PERCENTAGE)
1. Inferior Frontal Sulcus		3 (37.5)		2 (22.2)
2. Lateral Fissure		2 (25.0)		3 (33.3)
3. Anterior ascending ramus		0		3 (33.3)
4. Stem of the anterior rami		0		1 (11.1)
5. No sulcus (Free)		3 (37.5)		0

Table 4.3 Connections of the First- and Second Opercular Sulci when the Opercular Sulcus appeared diagonal in shape (control only).

CONNECTION WITH:	RIGHT HEMISPHERE		LEFT HEMISPHERE	
		FREQUENCY		FREQUENCY
FIRST OPERCULAR SULCUS	n=2		n=1	
1. Inferior Frontal Sulcus		1		1
5. No sulcus (Free)		1		0
SECOND OPERCULAR SULCUS	n=3		n=2	
1. Inferior Frontal Sulcus		1		0
2. Lateral Fissure		1		1
3. Anterior ascending ramus		1		0
4. Stem of the anterior rami		0		1

The findings in the present study on the connections of the opercular sulcus:

- Also differs from that of Ebeling et al (1989), who report the opercular sulcus ('probably the diagonal although not diagonal in shape') as only arising from the inferior frontal sulcus.

- Is more in line with that of Tomaiuolo et al (1999), who report three possible connections for the opercular sulcus (see pg 41), including that of a lack of connection with other sulci (that is, it occurred freely in the pars opercularis); and
- It also concurs with the work of Ono et al (1990), who report that there were five possible connections for the diagonal (opercular) sulcus, see Table 1.6 on pg 44.

A possible explanation for the differences may lie in the method of sample selection by both Galaburda (1980) and Ebeling (1989).

The information on the shapes of the opercular sulcus or sulci, other than the diagonal shape (relative to the literature reviewed thus far), appears to be new data, see Tables 3.29 and 3.30 on pages 161 and 163 respectively). It is submitted that the present study, relative to the literature reviewed thus far, is the only comprehensive reference on this sulcus.

(b) <u>THE TRIANGULAR SULCUS (SULCI)</u>

The Triangular sulcus (sulci) occurred much more frequently than the opercular sulcus (sulci), see Tables 3.33 on pg 166; and 3.28 on pg 159. Triangular sulci, in the present study, have a combined incidence of: 84.4% in the right hemisphere and 93.3% in the left hemisphere. This appears to vindicate the decision of Wada et al (1975) and Albanese et al (1989), to use this sulcus as a landmark for measurement purposes. It also points to the value of this sulcus as a landmark when attempting to identify and classify the sulci of the frontal operculum. They were therefore included in the modified description of the Types

of Sulcal Connections [see section 3.2.4.1 (on pages 173 to 179); as well as Figs 3.27 and 3.28 (at pages 180 and 181 respectively].

All data presented on the triangular sulci (relative to the literature reviewed thus far) constitutes new data.

4.2.4 DISCUSSION ON THE TYPES OF SULCAL CONNECTIONS AND THE PATTERNS OF THE ANTERIOR RAMI IN THE FRONTAL OPERCULUM

Comment has already been made on the limitations of studying fissures and sulci without adequate supporting studies [see section 4.1.1 (on pages 226 to 227)]. Notwithstanding this, once the conventions for identifying fissures and sulci are clearly stated, it is possible to use the sulcal maps, of the fissures and sulci, of the frontal operculum, in order to reasonably predict the possible location of the anterior speech areas. The usefulness of the study of Ebeling et al (1989) points to this.

Since the study of Ebeling et al (1989) was the only reference available on the types of sulcal connections in the frontal operculum, it was subjected to indirect probing. This

evaluation is presented in section 1.8.1 (pages 28 to 32). The key areas that required clarification were:

- The possible presence of a double precentral sulcus in view of the findings of Ono et al (1990) on this sulcus,
- The incidence of a connection of the inferior precentral sulcus with the lateral fissure,
- The incidence and connections of the opercular (diagonal sulcus),
- The inconstancy of the anterior horizontal ramus relative to the anterior ascending ramus, and
- The patterns of the anterior rami relative to the types of sulcal connections in the frontal operculum [Ebeling et al (1989) depict only the 'V-U' pattern of the anterior rami].

The results obtained on the central fissure, confirms that the present study is orientating the frontal operculum in a similar fashion to the studies examined in the literature review. The findings on the precentral sulci, accessory sulci, and the different locations of the anterior horizontal ramus led to a *modification of the descriptions of the types of connections* [see section 3.2.4.1 on pages 173, 174 and 177; as well as Figs 3.22 (on pg 175**), 3.23 (**on pg 176**), 3.24 (**on pg 178**), 3.25 (**on pg 179**), 3.27 (**on pg 180**) and 3.28 (**on pg 181**)].**

The finding of double precentral sulci in the present study, meant that the posterior boundary of the frontal operculum could be marked by either the single inferior precentral sulcus or the inferior portion of the anterior precentral sulcus [see Figs 3.2 (on pg 117) and 3.3 (on pg 118)]. When examining Table 4.4 (on pg 250), it can be seen that the double precentral sulci appeared to have made no substantial difference to the frequency with which the four types of sulcal connections occurred in the present study.

The findings of the present study on the connection of the single inferior precentral sulcus to the lateral fissure, is consistent with the studies reviewed in the literature, except with that of Ebeling et al (1989), see section 4.2.2 (a) at pages 236 to 238. The study of Ebeling et al (1989) reports a higher incidence for this connection compared to other studies on this issue, perhaps because different criteria were used to establish whether or not a connection existed between the inferior precentral sulcus and the lateral fissure. It is possible that the opercular sulcus when arising from the lateral fissure or even the anterior subcentral sulcus may have been included as part of the inferior precentral sulcus in the study of Ebeling et al (1989). This could also explain the higher incidence of the connection of the inferior precentral sulcus to the lateral fissure in the anatomical study of Ebeling et al (1989). This higher incidence for a connection between the inferior precentral sulcus and the lateral fissure may also have been an artifact of the sampling technique used. Another possibility is that there may be a relationship between the incidence of certain connections and the predominant language spoken.

Table 4.4: The Incidence of Types of Sulcal Connections in the Frontal Operculum in the present study, relative to that reported by Ebeling et al (1989). [Note that the incidences of each type of sulcal connection in the left hemisphere has been added to its counterpart in the right hemisphere [as in Ebeling et al (1989)] in order to make this comparison possible]. Values are expressed as percentages.

	Type 1	Type 2	Type 3	Type 4
The Study of Ebeling et al (1990):				
Anatomical Study	**76**	**11**	**10**	**3**
MRI Study	**90**	**5**	**5**	**0**
Present study excluding the double precentral sulci:				
Control group	**41.2**	**3.5**	**53.5**	**1.8**
Case group	**24.7**	**5.6**	**68.5**	**1.1**
Present study including the double precentral sulci:				
Control	**39.2**	**3.8**	**55.4**	**1.5**
Case	**24.4**	**5.6**	**68.9**	**1.1**

The major discrepancy between the present study and that of Ebeling et al (1989) lies with the incidence of Type 1 relative to Type 3. This is clearly related to the frequency of occurrence of the opercular sulcus. The analysis of the opercular sulcus in the literature review relative to the present study (section 4.2.3.2 (a), at pages 241 to 246) demonstrates that the incidence and connections of this sulcus was probably underestimated by the study of Ebeling et al (1989). This may possibly be explained by the definition of the opercular sulcus employed by Ebeling et al (1989), or by their sampling technique.

A more inclusive description of the types of sulcal connections is presented in section 3.2.4.1, at pages 173, 174 and 177; and summarised in Figs 3.27 (at pg 180) and 3.28 (at pg 181) in view of the findings on double precentral sulci, opercular sulci, and triangular sulci.

Although this represents a clearer picture anatomically, it is expected that the picture may be slightly different radiologically. The small sulci or notches may be obscured by the meninges and blood vessels, leading possibly to a greater incidence of Type 1 in a radiological study. Further studies exploring the ability of anatomical studies to predict the radiological picture are indicated, in order to evaluate the true contribution of the present study to radiological diagnosis.

In common with the findings of the studies reviewed in the literature survey [Eberstaller (1890); Cunningham (1890) and (1892); Ono (1990); and Ide (1999)], three patterns of the anterior rami, were found in the present study:

- '$\mathscr{I}$' (single ramus, either the anterior ascending or anterior horizontal),
- 'Y', (two anterior rami joined to a common stem), and
- 'V-U' with intermediates (two separate anterior rami)

A possible third ramus from the lateral fissure was classified in the present study, as an opercular sulcus that arose from the lateral fissure (see Tables 3.31 and 3.32 on pages 164 and 165 respectively). The incidence of this particular opercular sulcus was: 6.2% in the right hemisphere and 13.8% in the left hemisphere. Ono et al (1990) report the incidence of a true connection of the opercular sulcus (diagonal sulcus) with the lateral fissure as 0% in the right hemisphere and 4% in the left hemisphere. Although the incidence of this additional ramus and / or opercular sulcus is slightly higher in the present study, the difference is small (under 10%). Cunningham (1890) reports more than two rami in 1% of

cases studied. A description of this third ramus of Cunningham (1890) is however not quoted by the secondary source (Bergman, Afifi, and Miyauchi, 2000).

The '𝒴' pattern of the anterior rami was observed rarely in the present study, in contrast to most reports in the literature review (see Table 4.4 on pg 250). When comparing the present study with that of Cunningham (1890) it can be seen that:

- The incidence of the 'Y' pattern was similar in both studies,
- The higher incidence of the '𝒴' pattern in the study of Cunningham (1890) was accompanied by a lower incidence of the 'VU' pattern (see Table 4.5 on pg 253). A possible explanation may lie with the accepted locations of the anterior horizontal ramus. In common with Ono et al (1990), the present study recognises three possible locations for this sulcus: on the lateral surface, at the orbital margin, and on the orbital surface of the frontal lobe (see Table 3.25 on pg 154). It is possible that the study of Cunningham (1890) does not recognise the location of the anterior horizontal ramus on the orbital surface of the frontal lobe. Note that when we accept the orbital origin of the anterior horizontal ramus, a 'V-U' pattern of the anterior rami is obtained. If we ignore the orbital origin, an '𝒴' pattern of the anterior rami is obtained. Indeed, if the above factor is corrected for in the present study, the incidences of the '𝒴' pattern of the anterior rami closely approach that of Cunningham (1890), as shown in Table 4.5 at pg 253. The above explanation could well account for the trends observed in the right hemispheres, for the '𝒴' and 'VU' patterns, in the studies of Cunningham (1892), Connolly (1950), and Ide (1999), see Table 4.6 on pg 254.

Further weight to this explanation is added by the:

- The similarity of incidences of the 'Y' pattern in the right hemispheres of the studies reported on in Table 4.6 on pg 254, and
- The close correspondence between the incidences of the patterns as reported by Ono et al (1990) and that of the present study, in the right hemisphere (Table 4.6 on pg 254.

Table 4.5: The Incidence of the Patterns of the Anterior Rami in the present study relative to that reported on in the literature review (hemispheres were not considered separately). The incidences are reflected a percentages.

	'Y'	**'V-U'**	**'I'**
Cunningham (1890)[2]	**32.0**	**37.0**	**30.0**
Present study:			
Control group	**37.7**	**60.8**	**1.5**
Case group	**34.4**	**63.3**	**2.2**
Present study when specimens with an orbital location of the anterior horizontal ramus are eliminated:			
Control group	**37.7**	**38.5**	**23.8**
Case group	**34.4**	**36.6**	**28.9**

[2] Note that in the outstanding 1%, there is the situation where more than two anterior rami were present.

Table 4.6: The Incidence of the patterns of the Anterior Rami in the present study relative to that reported on in the literature review (with reference to the right and left hemispheres). The incidences are reflected as percentages. Note that the question marks indicate that these incidences were not quoted in the secondary reference.

STUDY:	RIGHT HEMISPHERE			LEFT HEMISPHERE		
	'Y'	'V-U'	'I'	'Y'	'V-U'	'I'
Cunningham (1892)	?	?	41.0	?	?	15.0
Connolly (1950)	?	?	25.0	?	?	3.0
Ide (1999)	25.0	30.0	45.0	40.0	45.0	15.0
Ono (1990)	28.0	64.0	8.0	24.0	60.0	16.0
Present: Control Group	36.9	61.5	1.5	38.4	60.0	1.5
Case Group	24.4	73.3	2.2	44.4	53.3	2.2

The study of Connolly (1950) reports an incidence of 3% for the '$\mathscr{I}$' pattern in the left hemisphere. This closely corresponds to the incidence of the '$\mathscr{I}$' pattern in the left hemispheres of the present study (1.5% in the control group and 2.2% in the case group). This may appear to contradict the explanation offered on the higher incidence of the '$\mathscr{I}$' pattern of the anterior rami relative to the orbital origin of the anterior horizontal ramus. There is however, no conflict because the present study found a higher incidence for an orbital origin of the anterior horizontal ramus in the right hemisphere, as compared to the left hemisphere [29.2% in the right hemisphere and 15.4% in the left hemisphere in the control group; as well as 35.6% in the right hemisphere and 17.7% in the left hemisphere, in the case group, see Table 3.25 on pg 154].

When examining the incidences of the patterns of the anterior rami in studies of the left hemispheres (Table 4.6 on pg 254) it can be seen that the incidence of the '$\mathscr{I}$' pattern is

slightly elevated in the study of Ono et al (1990). This occurs at the expense of the 'Y' pattern. This is surprising in view of the explanation given about the relationship between the '*J*' pattern and 'V-U' pattern. The smaller sample size of the study of Ono et al (1990) may have masked the general trend of a greater incidence of the 'Y' pattern in the left hemisphere as compared to the right hemisphere.

The two anterior rami were never absent together, indicating that when depicting a Type 4 (of sulcal connections in the frontal operculum), the anterior horizontal ramus ought to be shown as a constant sulcus [compare Fig 1.9 E (on pg 24) to Figs 3.27 E (on pg 180) and 3.28 E (on pg 181)]. Note that the anterior horizontal ramus was no more likely than the anterior ascending ramus to be absent. This sulcus was depicted as being inconstant, by Ebeling et al (1989) see Fig 1.9 B to E, on pg 24. They might have not considered the orbital origin of the anterior horizontal ramus.

Attention was drawn in the literature review to the insufficient reporting of the study of Ebeling et al (1989) on the incidence of the patterns of the anterior rami, relative to the types of sulcal connections in the frontal operculum. In the present study, Types 2 and 4 were seen too infrequently for trends to be commented on. The trends observed for Types 1 and 3, are summarised as follows:

- CONTROL GROUP: TYPE 1 (see Table 3.44 on pg 187)
    - The 'V-U' pattern predominated in both hemispheres

- The ‘Y’ pattern was seen slightly more in the left hemisphere than in the right hemisphere

- CONTROL GROUP: TYPE 3 (see Table 3.44 on pg 187)
    - There was an approximately equal distribution of ‘Y’ and ‘V-U’ patterns in the right and in the left hemispheres.

- CASE GROUP: TYPE 1 (see Table 3.45 on pg 188)
    - The ‘V-U’ pattern predominated in both hemispheres
    - The ‘Y’ pattern was seen slightly more in the left hemisphere than in the right hemisphere

- CASE GROUP: (see Table 3.45 on pg 188)
    - The ‘V-U’ pattern predominated in the right hemisphere
    - There was an approximately equal distribution of ‘Y’ and ‘V-U’ patterns in the left hemisphere.
    - The ‘Y’ pattern was seen slightly more in the left hemisphere than in the right hemisphere

Interhemispheric studies, using the Chi square test, on the types of sulcal connections [see Tables 3.40 and 3.41 (on pages 182 and 183 respectively)] and patterns of the anterior rami [see Tables 3.42 and 3.43, on pages 185 and 186 respectively), in the frontal operculum, revealed no lateralization of either Type of Sulcal Connection, or Pattern of the Anterior Rami, to either hemisphere. It is possible that study of the external features of the sulci of

the frontal operculum may not be able to reveal the expected larger cortical substrate for motor speech function in the left hemisphere. An implication is that that we do not require separate sulcal maps for the right as opposed to the left hemisphere. This is in keeping with the finding of Ebeling et al (1989) and the review of Sherwood, Broadfield, Holloway, Gannon, and Hof (2003).

The revelation of lateralisation with respect to the descriptive features of fissures and sulci, may require a consideration of both the external and internal features of such fissures and sulci. It is also possible that the evidence for the lateralisation of the anterior speech area may be more physiological or biochemical rather than morphological.

4.2.5 SUMMARY OF THE RECOMMENDATIONS ARISING FROM THE DISCUSSION ON THE DESCRIPTIVE STUDY

It is suggested through the medium of this text that:

- More studies of different populations are required in order to determine the extent of variation as regards the features of the frontal operculum. In other words, that the database established by the present study, be extended.

- Such studies be randomised as well as stratified to reflect sex, age, language, and level of education.

4.3 DISCUSSION ON THE QUANTITATIVE ASPECT OF THE PRESENT STUDY AND THE RECOMMENDATIONS ARISING THEREFROM

The main objective of reporting on sulcal- and intersulcal- lengths was to provide reference material to the neuroradiologist, and neurosurgeon. The mean lengths of the major and accessory sulci are presented in Tables 3.46 to 3.57 (on pages 195 to 206) for ungrouped data (data prior to grouping according to either Types of Sulcal Connections or Patterns of the Anterior Rami), as well as for grouped data (data grouped according to, either Types of Sulcal Connections or Patterns of the Anterior Rami). It is suggested that the quantitative database also be extended.

We see from the Table 4.7 (on pg 259) that the quantitative findings of the two studies are very similar. The present study thus broadly confirms the findings of Ono et al (1990).

In view of the mixed results obtained when the sulcal lengths of the whole brains were compared to the separate hemispheres (Table 3.66, at pg 221), it is suggested that further interhemispheric studies be conducted on whole brains only. It is also suggested that the outcomes of studies in the literature that do not clearly state the source of their 'hemispheres' be interpreted with caution.

Table 4.7: Sulcal Lengths for ungrouped data in the present study relative to that of Ono et al (1990).

SULCUS:	MEAN SULCAL LENGTHS (RANGE) (centimetres)	
	RIGHT HEMISPHERE	LEFT HEMISPHERE
1. Stem (of anterior rami):		
(a) Present Study control	0.79 (0.3 - 1.6)	0.70 (0.35 – 1.4)
(b) Present Study case	0.56 (0.35 – 0.75)	0.72 (0.3 – 1.85)
(c) Ono et al (1990)	0.80 (0.4 – 3.0)	0.90 (0.5 – 1.5)
2. Anterior Ascending Ramus:		
(a) Present Study control	1.43 (0.3 – 2.68)	1.50 (0.3 – 3.25)
(b) Present Study case	1.76 (0.45 – 2.68)	1.76 (0.65 – 3.3)
(c) Ono et al (1990)	1.60 (0.2 – 2.7)	1.80 (0.3 – 2.9)
3. Anterior Horizontal Ramus:		
(a) Present Study control	1.35 (0.4 – 2.55)	1.47 (0.45 - 2.38)
(b) Present Study case	1.70 (0.85 – 3.1)	1.69 (0.4 – 3.08)
(c) Ono et al (1990)	1.50 (0.2 – 3.5)	1.40 (0.9 – 2.7)
4. Opercular (Diagonal - sole)		
(a) Present Study control	1.93 (0.53 –3.33)	1.74 (0.3 – 3.25)
(b) Present Study case	1.74 (0.65 – 3.43)	1.27 (0.45 –2.35)
(c) Ono et al (1990)	1.90 (4.0 – 3.0)	1.70 (0.2 – 3.2)

Mean intersulcal lengths taken at the level of the superior termination of the anterior ascending ramus, are presented in Tables 3.67 to 3.70 (at pages 223 to 224). **This constitutes new data relative to the literature surveyed thus far.**

It is suggested the further measurement of intersulcal lengths can contribute to a better picture of gyral packing in the frontal operculum than inspection (as used by Ide et al in 1999) in the absence of reliable surface area measurements. Several measurements taken at successive horizontal levels, from the lateral fissure inferiorly, to the superior termination of the anterior ascending sulcus is worth exploring.

The effect of grouping the data into either Types of Connections or Patterns of the Anterior Rami is summarised in Tables 3.46 to 3.57 (on pages 195 to 206) and illustrated in Figures 3.29 to 3.40 (on pages 195 to 206). The following trends were observed when considering the effect of grouping on the following sulci:

- Stem of the anterior rami (Table 3.46 and Fig 3.29).

  It can be seen that the mean sulcal lengths of the grouped data appear to closely correspond to the ungrouped data with the exception of Type 1 (which has very low sample numbers).

- Anterior ascending ramus (Table 3.47 and Fig 3.30).

  The Type 1 sulci in the right hemisphere appear to have slightly longer mean sulcal lengths. The mean sulcal lengths in the Y pattern appear slightly shorter, while that of the VU pattern appears slightly longer, in both the grouped and ungrouped categories.

- Anterior horizontal ramus (Table 3.48 and Fig 3.31).

  It can be seen that the mean sulcal lengths of the grouped data appear to closely correspond to the ungrouped data with the exception of Type 1 in the right hemisphere (control) and left hemisphere (case).

- Sole Opercular Sulcus (Table 3.49 and Fig 3.32).

  The effect of grouping is only manifest in the Y- and VU patterns. The Y pattern appears to have slightly longer-, and the VU pattern slightly shorter- mean sulcal lengths.

- Sole Triangular Sulcus (Table 3.52 and Fig 3.35).

  The effect of grouping is only manifest in the Y- and VU patterns. The Y pattern appears to have slightly shorter-, and the VU pattern slightly longer- mean sulcal lengths.

The accessory sulci (sole opercular versus sole triangular) seem to show slightly opposite trends. It is possible that the external sulcal lengths adjust themselves in order to maintain a certain level of external fissurisation. It is necessary to have better sample numbers for the remaining accessory sulci in order to determine whether or not the overall effect of the accessory sulci is to correct for the lengths of the major sulci, (slightly shorter anterior ascending ramus in the Y pattern) in the present study.

The anterior speech area is primarily located in the left frontal operculum. It is therefore expected that the left hemisphere would exhibit extra cortical substrates to account for the lateralisation of function. In the present study, statistical interhemispheric comparisons of

mean sulcal lengths were performed only on selected data sets (sample sizes 18 and above). We report no evidence for lateralisation in the present study, with respect to sulcal length.

It is possible that a consideration of the extent of:

- External fissurisation relative to external surface area may yield different results,
- External and internal fissurisation relative to external and internal surface area may yield different results.

It is also possible that lateralisation in the anterior speech area may be more biochemical or physiological rather than morphological.

At a prospective level, the probing of the structural and functional substrates of language, amongst which is the area selected for examination in the present study, could promote a deeper understanding of:

- Normal speech and language,
- Speech and language dysfunction, and
- The recovery of speech and language following destruction of the associated areas, and hence, the manipulation of such areas in order to promote recovery**.**

Since language is part of a widely distributed network, the fibre connections linking the structural and functional substrates for speech and language, are therefore also significant

entities. The developmental significance of fibre connections (connectivity) on gyral modelling and fissurization has already been introduced in section 1.10 on pages 53 to 57. Knowledge of the factors that are associated with gyral modelling, the significance of the structure function relations of the gyral-sulcal-unit, and the mechanisms behind the production of such units could constitute core knowledge in the design of new forms of therapy for destructive injuries at a cortical level. A collaborative effort at Monash University, Australia appears to point in this direction [Laboratory Marketing Spectrum (Volume 23, Issue (6), 2004]. They are proposing that a biodegradable hydrogel which, when injected into a lesioned area of the spinal cord may encourage nerve cells to infiltrate it and grow. This effort is currently operating at cell culture level. If successful, they expect to begin trial tests with rat models. The present study contributes to the description of the gyral-sulcal unit and hence constitutes a first step in the context of the above comments.

5 CONCLUSION

The present study broadly confirms the descriptive and quantitative data reviewed in the literature survey. It goes further and modifies the criteria associated with defining the Types of Sulcal Connections in the frontal operculum. It elaborates on the fissures and sulci of the frontoparietal operculum and clarifies the status of the opercular sulcus.

APPENDIX A

THE RECORD OF THE SAMPLE OBTAINED AT THE DURBAN INSTITUTE OF TECHNOLOGY

A total of forty whole-brains were cleaned, tagged and photographed at the Department of Human Biology, Durban Institute of Technology in December 2001. They were post-mortem brains and were therefore fixed outside the cranial cavity. By April 2002, twenty of the original sample had been used for dissection purposes and were therefore unavailable for processing.

It was only possible to access the records of seventeen of the twenty remaining in the sample. This was because the original tags of three of the brains had fallen off their attachment to the basilar artery.

The patient records were not sufficiently detailed for the purposes of this study (the record of these details are presented in Table A1, pg 263). This set of specimens and the aims associated with them were therefore abandoned.

Table A.1: Patient details of the sample of brains obtained at the Durban Institute of Technology

Specimen	Cause of Death	Ethnic Group	Race	Age (years)	Sex
B1	Gunshot wound to chest	?	B[1]	29	Male
B2	Gunshot wound to mandible and neck	?	B	28	Male
B3	Gunshot wound to chest	?	B	37	Male
B4	Burns	?	B	5	Female
B5	Suicide	?	B	23	Male
B6	Gunshot wound to chest	?	B	24	Male
B7	Stab wound to chest	Zulu	B	35	Male
B8	Stab wound to chest	?	B	24	Male
B9	Suicide	?	B	70	Male
B10	Suicide	?	B	26	Male
B11	Gunshot wound to chest	?	B	34	Male
B12	Injury to head	?	B	21	Male
B13	Drowning	?	B	7	Male
B14	Gunshot wound to chest	?	B	37	Male
B15	Motor vehicle accident	?	B	37	Male
B16	Gunshot wound to chest	?	B	20	Male
B17	Suicide	?	B	40	Male

[1] B=Black African origin (race)

APPENDIX B

COPY OF THE LETTER OF THE WAIVER FOR THE REQUIREMENT OF AN ETHICS CLEARANCE

University
of the Witwatersrand,
Johannesburg

Committee for Research on Human Subjects (Medical): Clinical Trials

SECRETERIATE: Suite 189, Private Bag x2600, Houghton 2041, South Africa • Tel: +27-11-717-2800 • Fax: +27-11-482-1088

PC-J/71dsk5/es

Jill Mainwaring
Postgraduate Office
Faculty of Health Sciences

17 May 2002

Dear Jill

re: **MS S Kamanzi-wa - MSc by research**

Fissures of the Frontal Operculum in a South African Sample

This certifies that this project does not require clearance from the Committee for Research on Human Subjects (Medical). Human tissue was used covered by the Human Tissue Act, No. 65 of 1983.

Yours sincerely

Professor Peter Cleaton-Jones
Chair: Committee for Research on Human Subjects (Medical)

APPENDIX C

THE DESCRIPTIVE RECORD IN DIAGRAMATIC FORM

C. 1 KEY TO THE DESCRIPTIVE RECORD

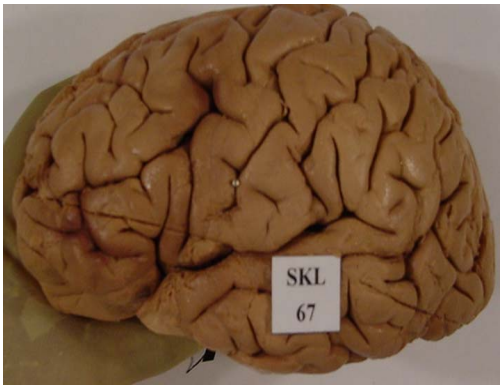

Figure C1 (a) Summary of specimen details.

This is a whole brain specimen (control group). It is identified as the left hemisphere of specimen 67, as recorded by the author (hence SKL 67). Note that there is a single precentral sulcus anterior to the central fissure (an office pin has been inserted in the central fissure).

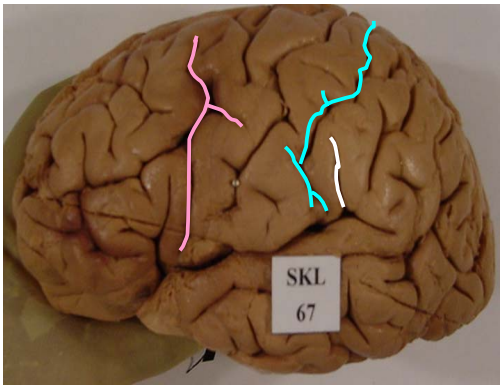

Figure C1 (b) Orientation.

Note that an office pin marks the central fissure and that there is a single (although interrupted) precentral sulcus. The inferior precentral sulcus is highlighted in pink. The postcentral sulcus (blue) is anterior to the upturned end of the lateral fissure (white).

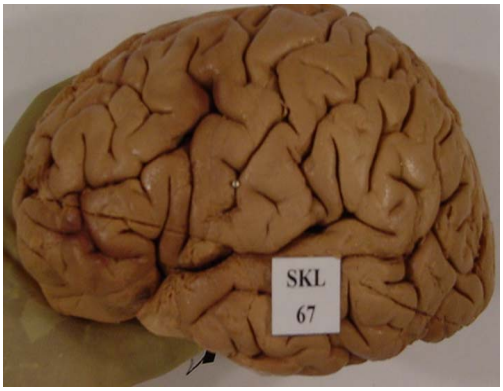

Figure C1 (c) Inferior terminations of boundary and orientating sulci.

The postcentral sulcus and the central fissure have inverted 'Y' endings. The inferior precentral sulcus has a straight ending. Note that none of these endings have a connection with the lateral fissure.

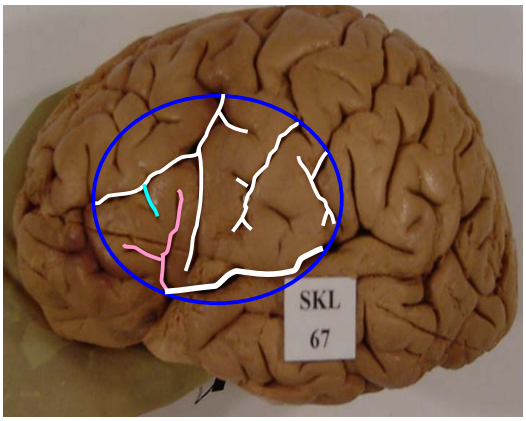

Figure C1 (d) Selection of area of interest.

Since this is the left hemisphere, the area of interest is selected in dark blue. The orientating and boundary sulci are highlighted in white in the area of interest. The major sulci (stem and anterior rami) are highlighted in pink. The only accessory sulcus (sulcus of pars triangularis) is light blue.

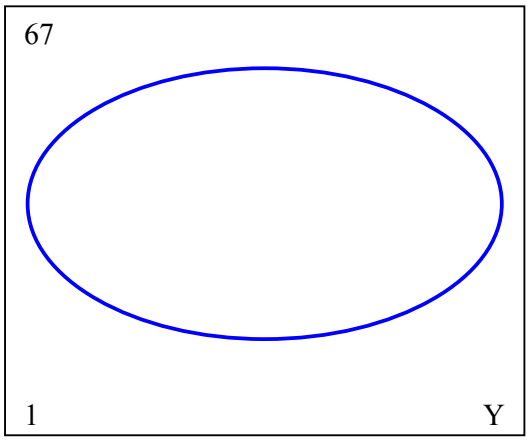

Figure C1 (e) Key to the diagrammatic representation of the area of interest as selected in Figure C1 (d), Part 1.

The specimen number is indicated in the top left hand corner of the box (67). Examination of Figure C1 (d) reveals this to belong to the Type 1 of sulcal connections (lower left hand corner of box) and the Y pattern of the anterior rami (lower right hand corner of box).

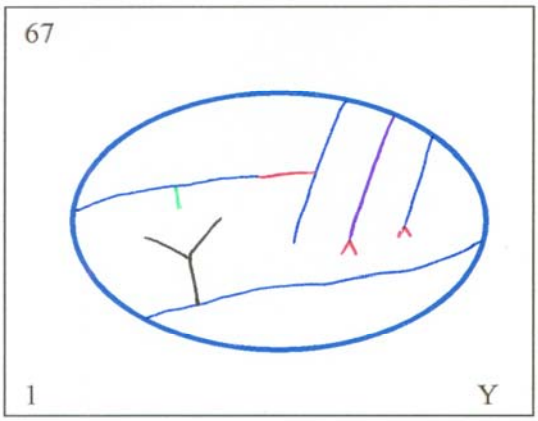

Figure C1 (f) Key to the diagrammatic representation of the area of interest as selected in Figure C1 (d), Part 2. The major sulci (anterior rami and stem (when present) are drawn in black. The accessory sulci are highlighted in green. Connections and endings of boundary and orientating sulci (other than straight) are shown in red. The post-central sulcus and central fissure (purple) have inverted 'Y' inferior endings. The inferor precentral sulcus has a straight inferior ending.

Figure C1 (f) continued
The connection of the inferior precentral sulcus with the inferior frontal sulcus (IFS) as well as the lack of an opercular sulcus, implies a Type 1 of sulcal connections. The major sulci form a 'Y' pattern. A sulcus of the pars triangularis descends between the anterior rami from the IFS.

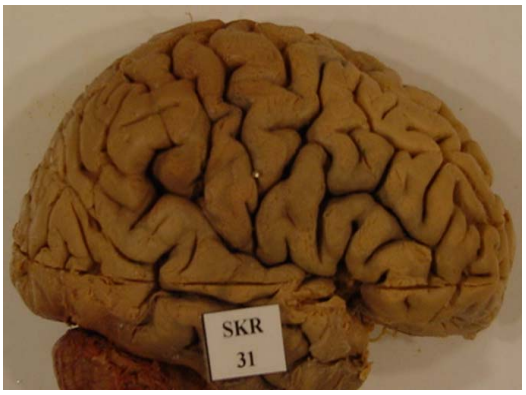

Figure C2 (a) Summary of specimen details.

This is the right hemisphere of specimen 31 (hence SKR 31). It is a separate right hemisphere and therefore belongs to the case category. Note that there is a single precentral sulcus anterior to the central fissure (CF). An office pin has been inserted in the CF). An anterior subcentral sulcus is present.

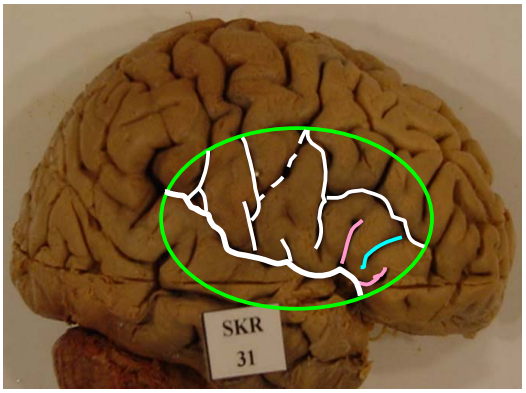

Figure C2 (b) Selection of area of interest.

Since this is the right hemisphere, the area of interest is selected in green. The orientating and boundary sulci are highlighted in white in the area of interest. The major sulci (anterior rami) are highlighted in pink. The only accessory sulcus (sulcus of pars triangularis) is light blue.

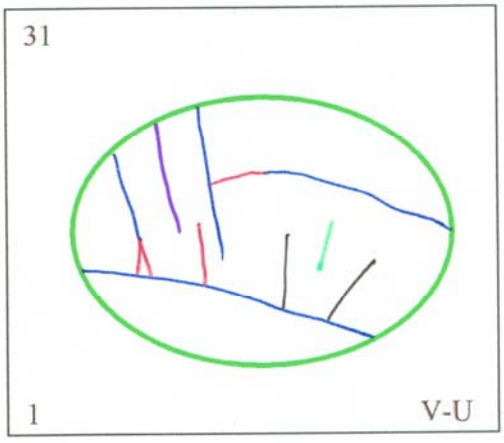

Figure C2 (c) Key to the diagrammatic representation of the area of interest as selected in Figure C2 (b). The major sulci (anterior rami) are drawn in black. The accessory sulci are highlighted in green. Connections and endings of boundary and orientating sulci (other than straight) are shown in red. The post-central sulcus has an inverted 'Y' inferior ending. An anterior subcentral sulcus (red) lies between the central fissure (purple) and the single inferor precentral sulcus.

Figure C2 (c) continued.
The connection of the inferior precentral sulcus with the inferior frontal sulcus (IFS) as well as the lack of an opercular sulcus, implies a Type 1 of sulcal connections. The major sulci form a 'V-U' pattern. A sulcus of the pars triangularis descends as a free (unattached) sulcus between the anterior rami. {Note that a postcentral sulcus [not shown Fig C2 (c)] when present is also shown as a red sulcus arising from the lateral fissure between the central fissure and the postcentral sulcus}.

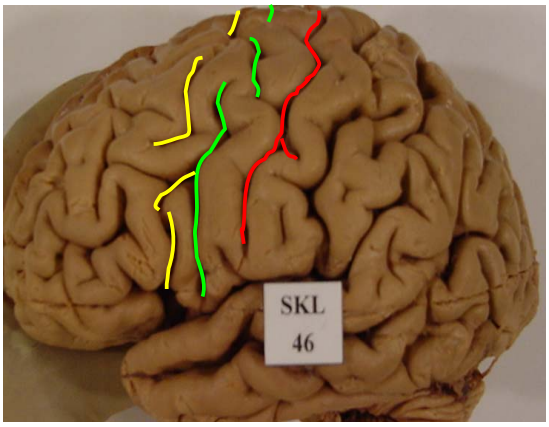

Figure C3 (a) Summary of specimen details.

This is a whole brain specimen (control group). It is identified as the left hemisphere of specimen 46, as recorded by the author (hence SKL 46). Note that there are two precentral sulci (green and yellow) anterior to the central fissure (red).

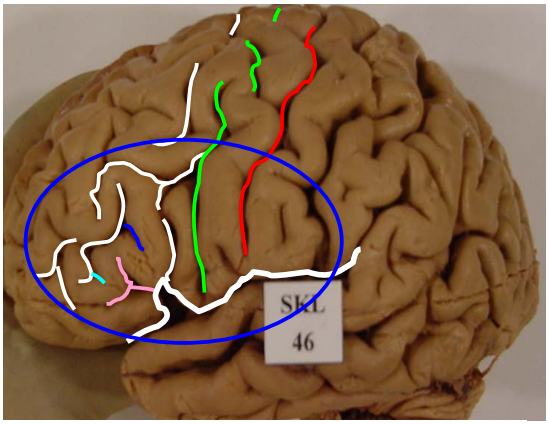

Figure C3 (b) Selection of area of interest.

The boundary sulci are highlighted in white, and the major sulci (stem and anterior rami in pink. The accessory sulci: sulcus of pars opercularis (dark blue) and the sulcus of the pars triangularis (light blue) arise from the inferior frontal sulcus. Note that there are now four vertically disposed sulci in the selected area as opposed to the three in Figs C1 and C2.

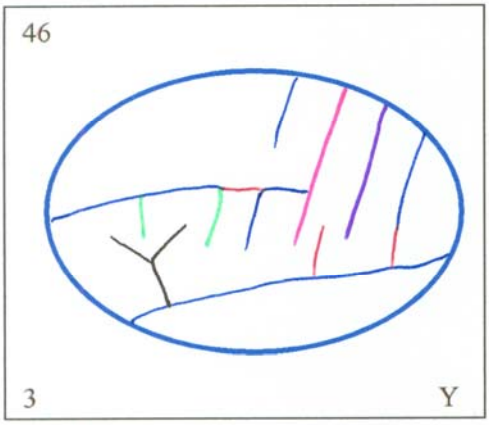

Figure C3 (c) Key to the diagrammatic representation of the area of interest as selected in Figure C3 (d), Part 2. The major sulci (anterior rami and stem (when present) are drawn in black. The accessory sulci are highlighted in green. Connections and endings of boundary and orientating sulci are shown in red. The anterior subcentral sulcus (red) lies between the posterior precentral sulcus (pink) and central fissure (purple).

Figure C3 (c) continued.
The post-central sulcus, the central fissure, the posterior precentral sulcus, and the anterior precentral sulcus have straight inferior endings. The connection of the anterior precentral sulcus with the inferior frontal sulcus (IFS) as well as the presence of an opercular sulcus, implies a Type 3 of sulcal connections. The major sulci form a 'Y' pattern. Note that in the presence of double precentral sulci, there four vertically disposed long sulci are shown in the selected area. A deep gyral bridge between between the inferior precentral sulcus anterior and the lateral fissure makes this a pseudo-connection

C.2 DESCRIPTIVE RECORD FOR THE WHOLE BRAINS (CONTROL CATEGORY)

Note that the key to these diagrams is in section C.1 (pages 268 to 271).

Left Hemispheres **Right Hemispheres**

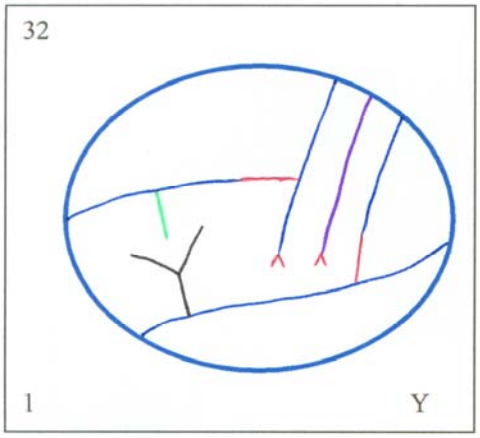

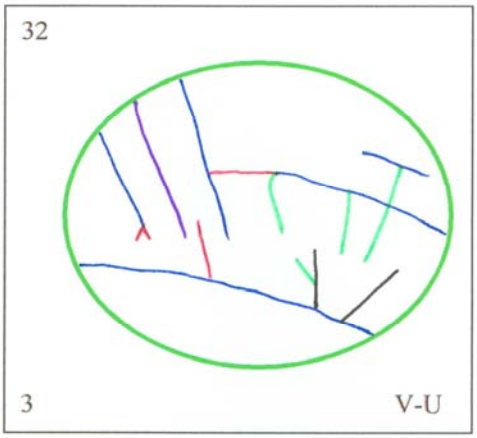

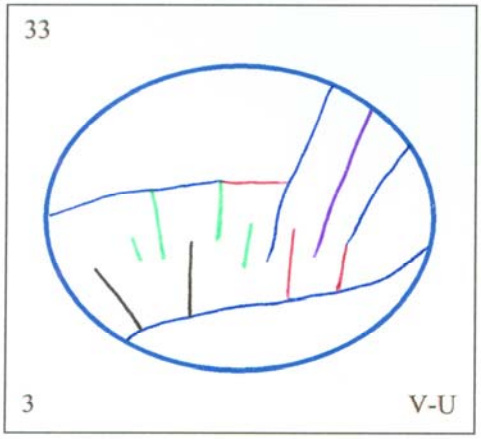

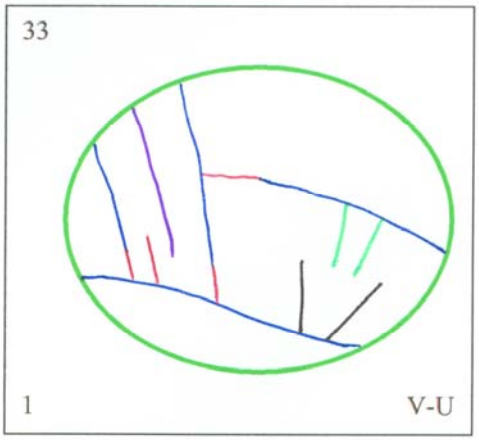

Note that the key to these diagrams is in section C.1 (pages 268 to 271).

Left Hemispheres **Right Hemispheres**

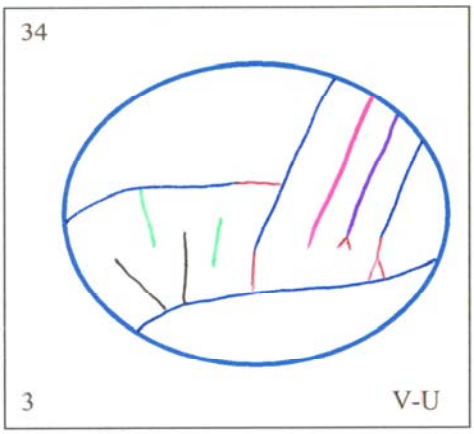

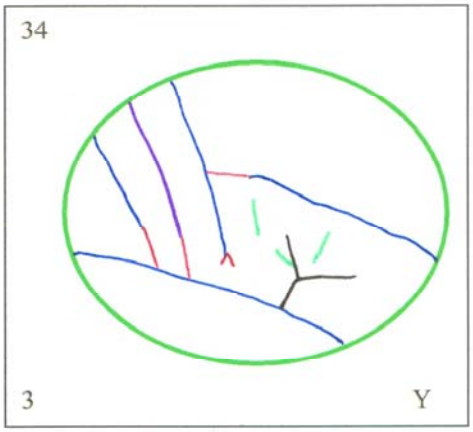

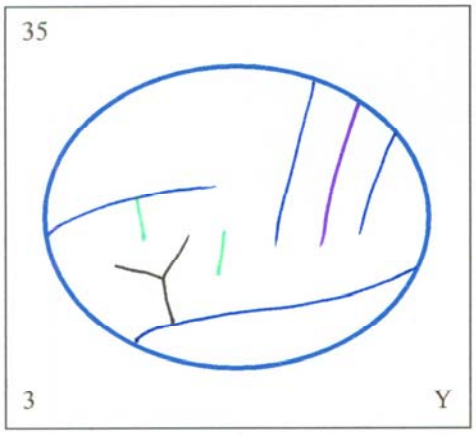

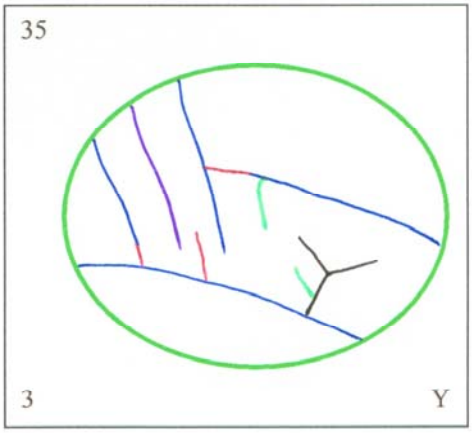

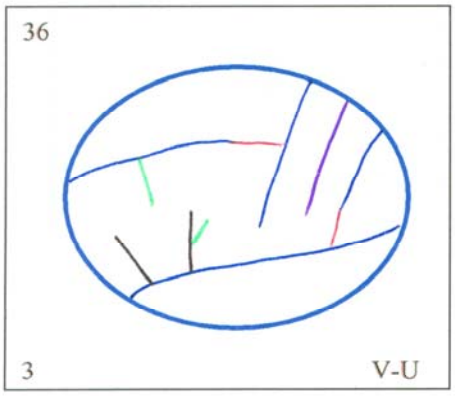

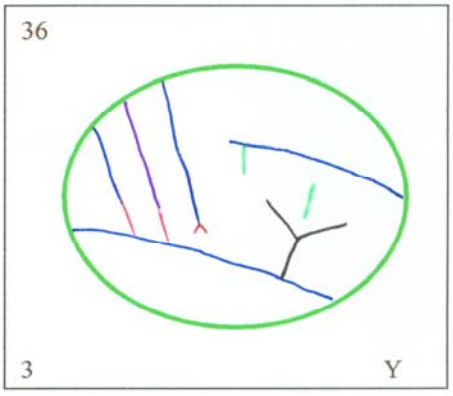

Note that the key to these diagrams is in section C.1 (pages 268 to 271).

Left Hemispheres **Right Hemispheres**

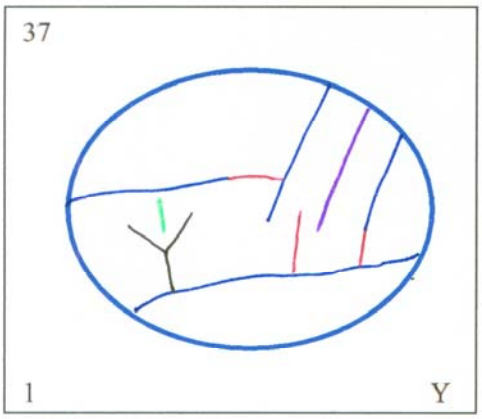

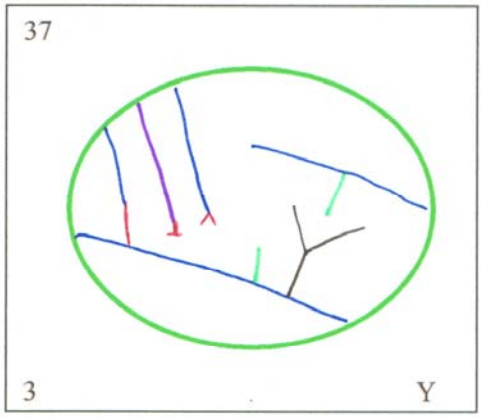



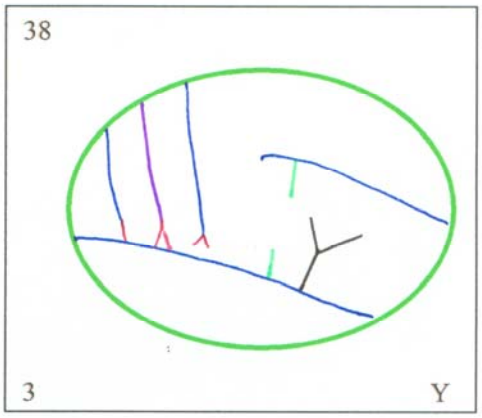

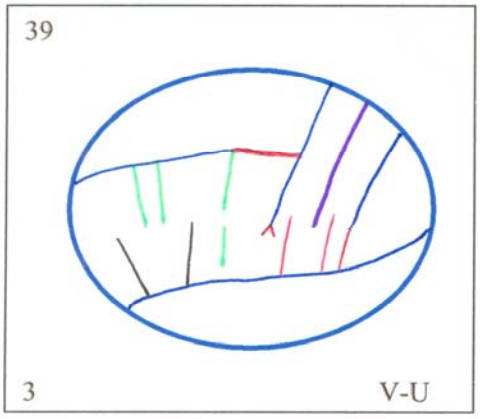

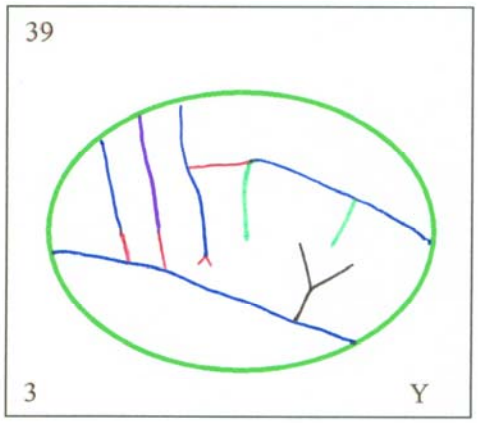

Note that the key to these diagrams is in section C.1 (pages 268 to 271).

Left Hemispheres **Right Hemispheres**

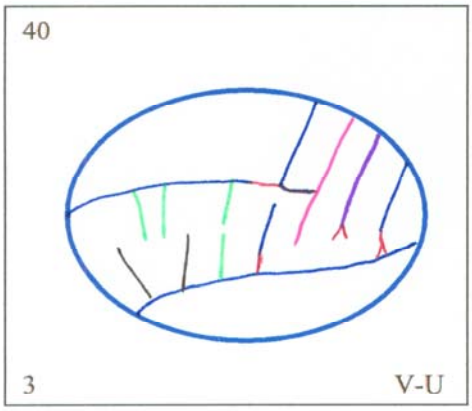

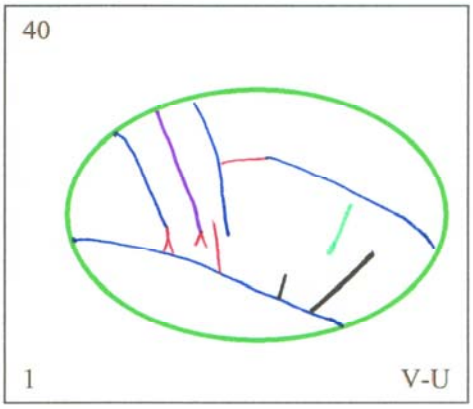

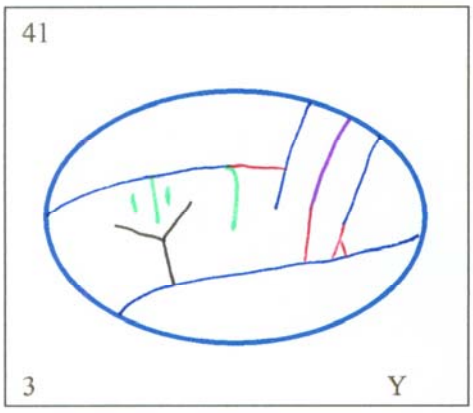

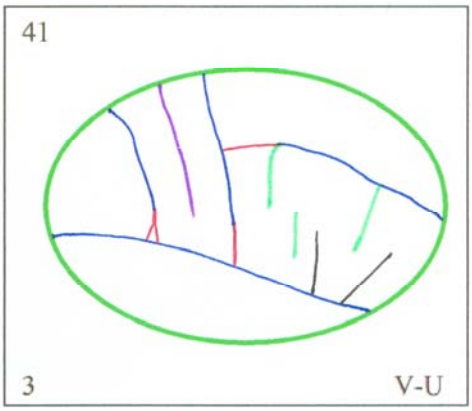

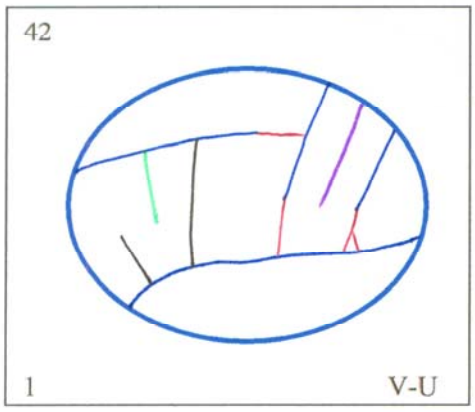

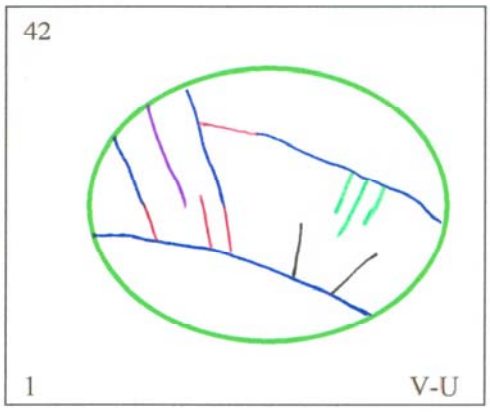

Note that the key to these diagrams is in section C.1 (pages 268 to 271).

Left Hemispheres **Right Hemispheres**

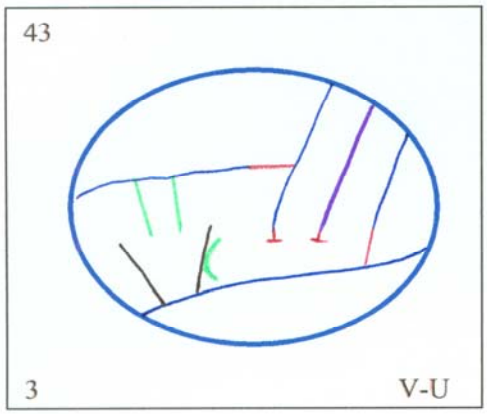

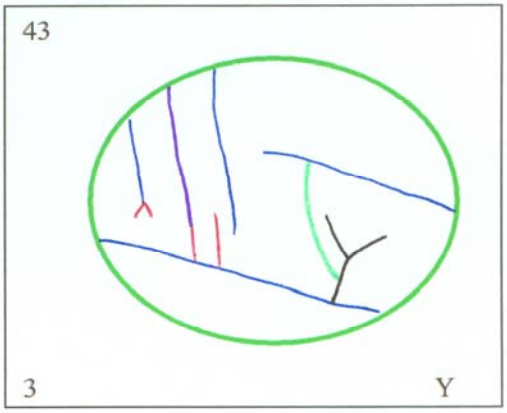

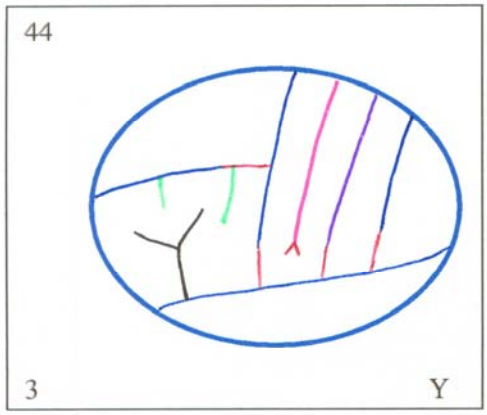

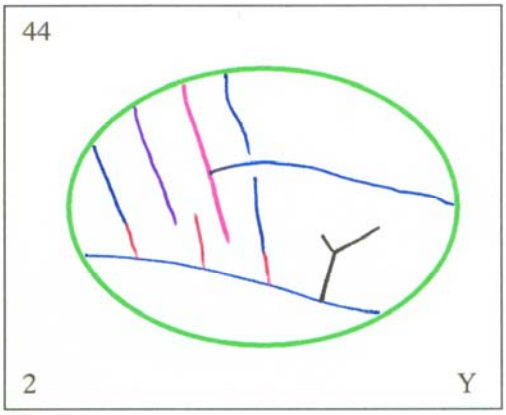

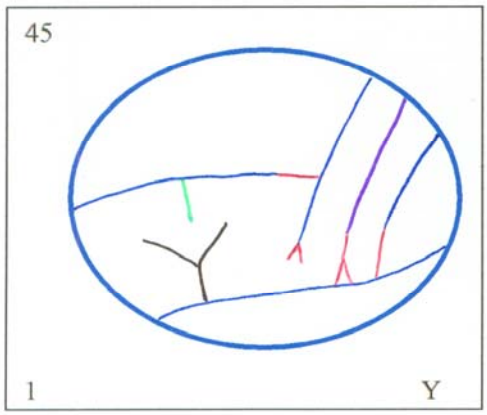

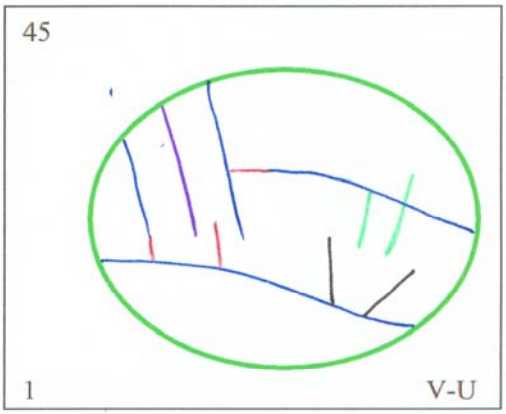

Note that the key to these diagrams is in section C.1 (pages 268 to 271).

Left Hemispheres **Right Hemispheres**



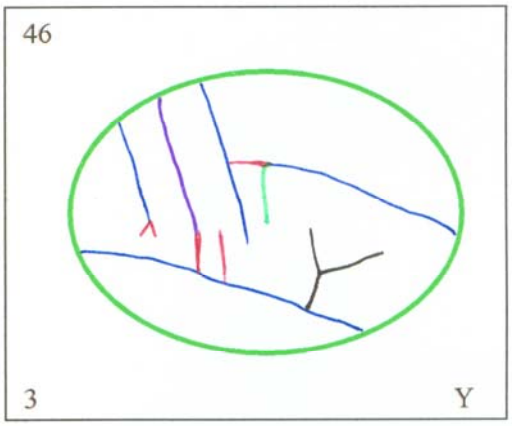

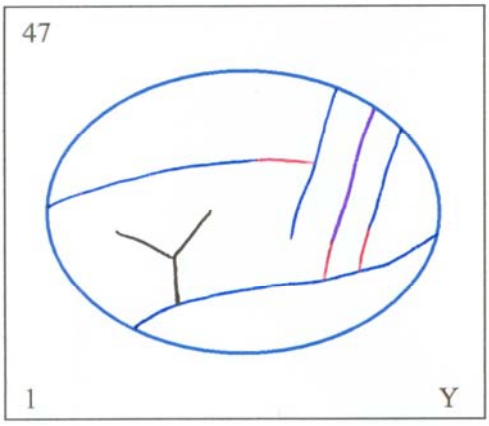

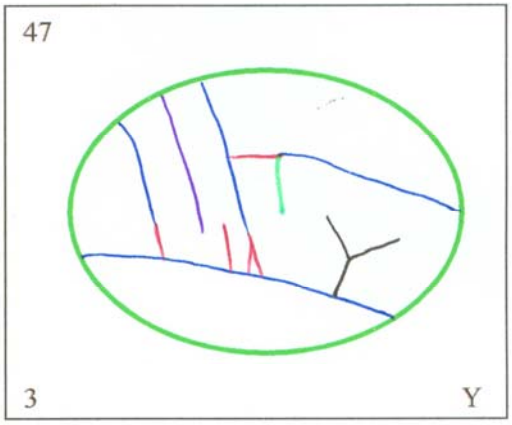

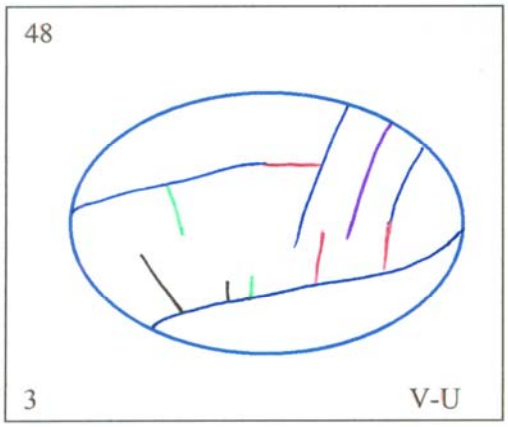

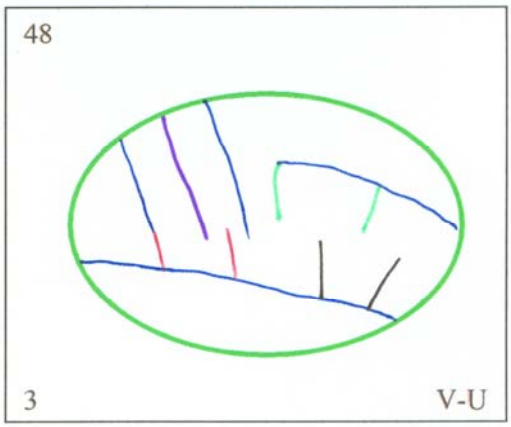

Note that the key to these diagrams is in section C.1 (pages 268 to 271).

Left Hemispheres **Right Hemispheres**

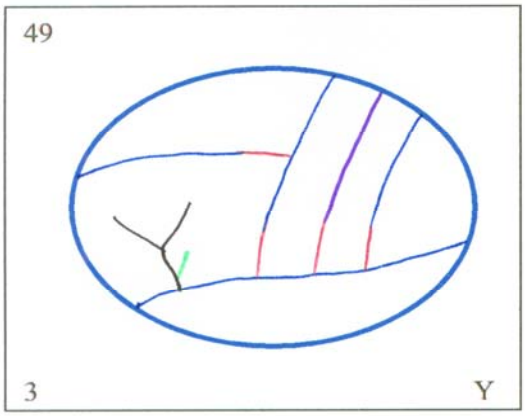

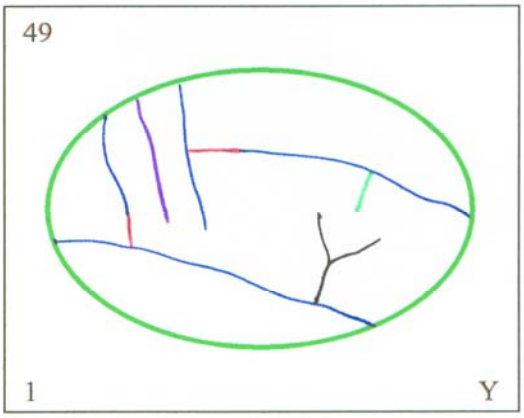



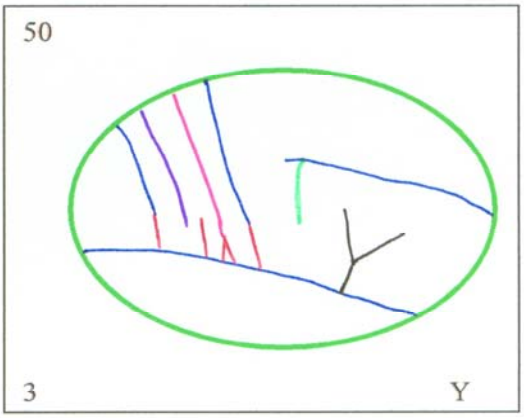

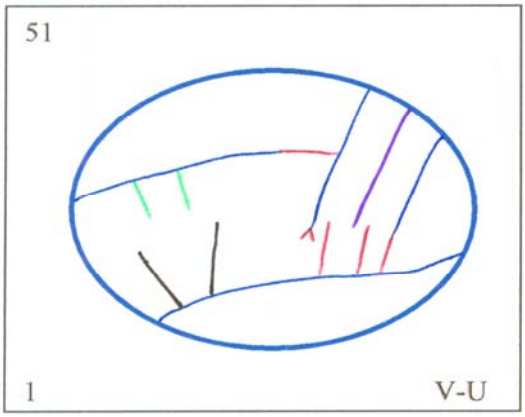

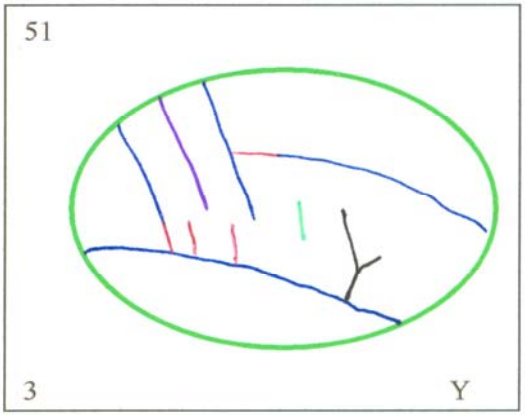

Note that the key to these diagrams is in section C.1 (pages 268 to 271).

Left Hemispheres **Right Hemispheres**

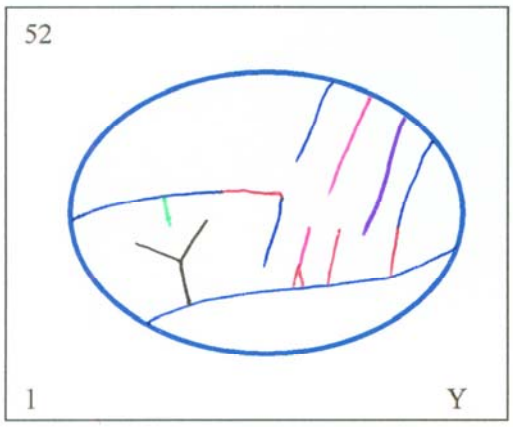

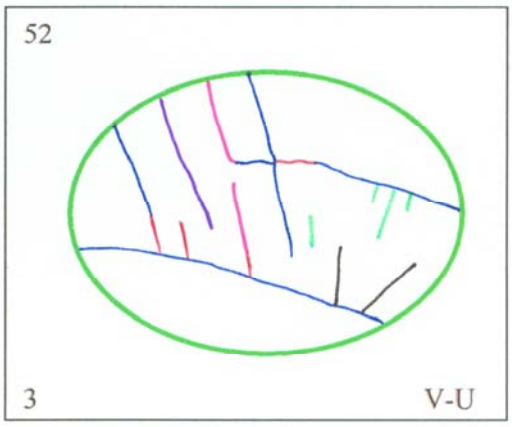

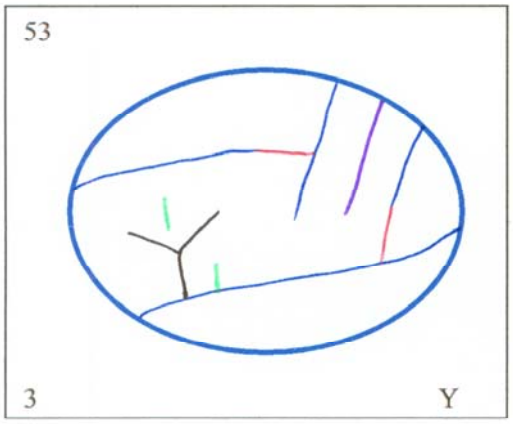

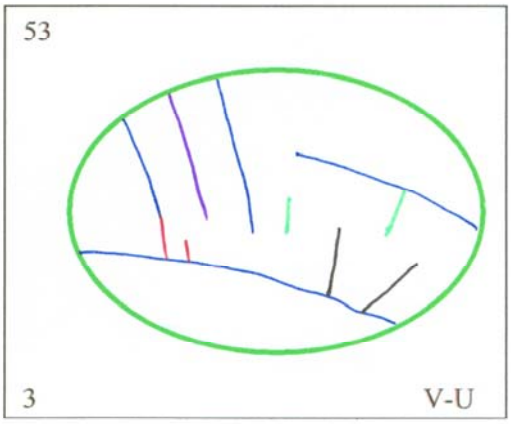

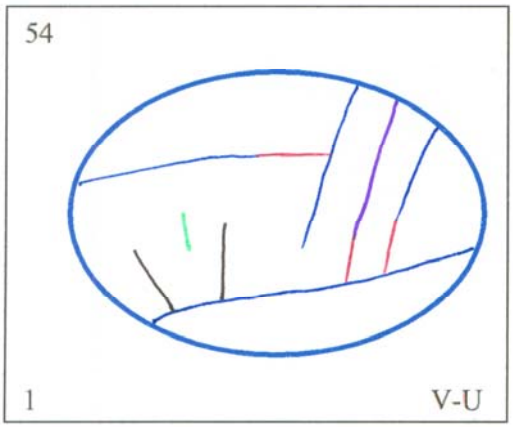

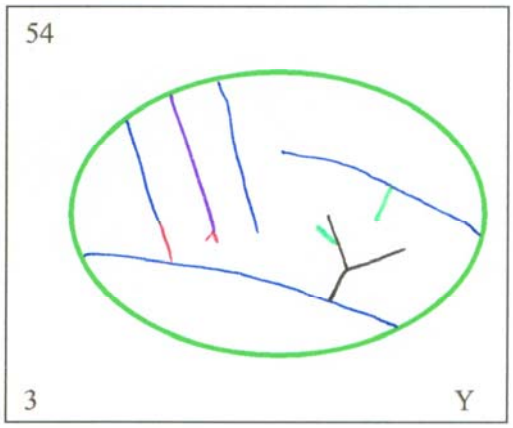

Note that the key to these diagrams is in section C.1 (pages 268 to 271).

Left Hemispheres **Right Hemispheres**

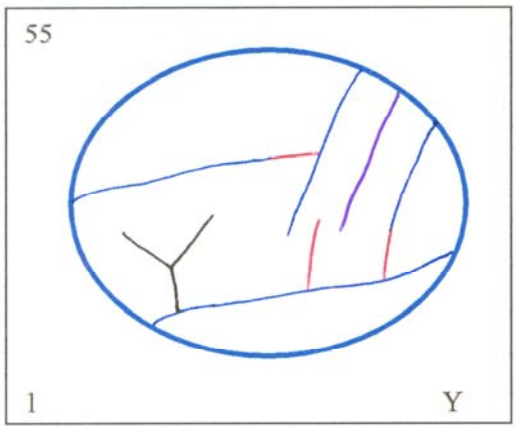

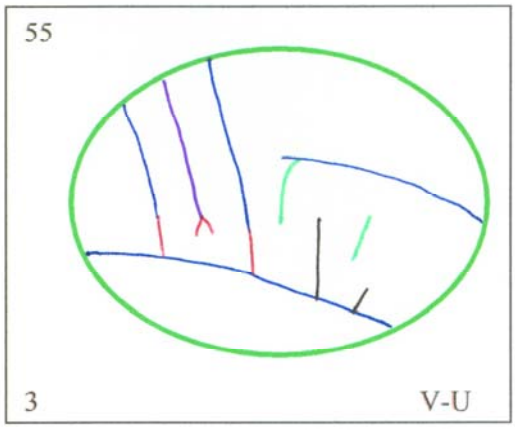

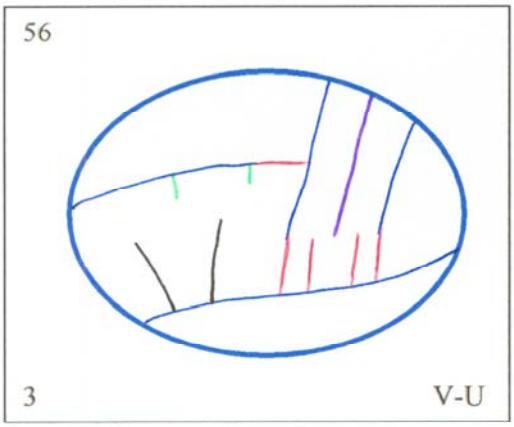

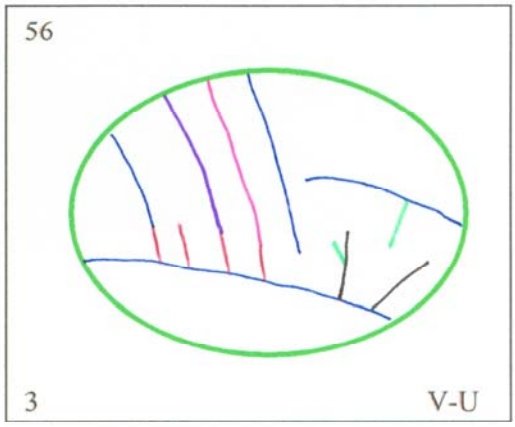

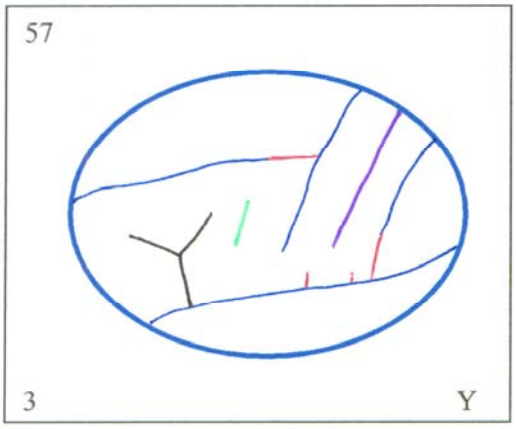

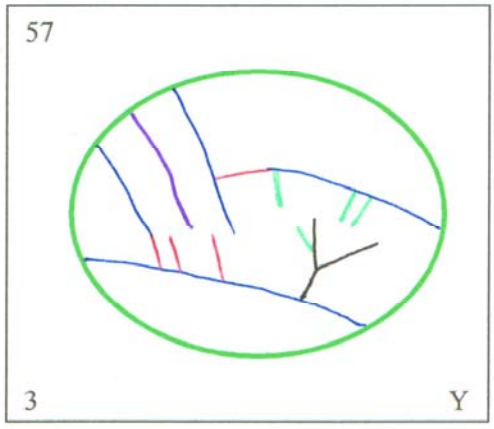

Note that the key to these diagrams is in section C.1 (pages 268 to 271).

Left Hemispheres **Right Hemispheres**

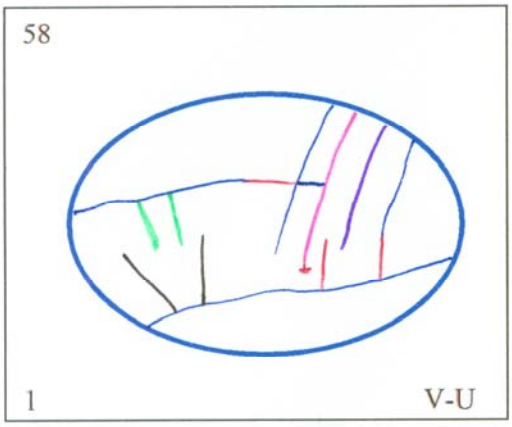

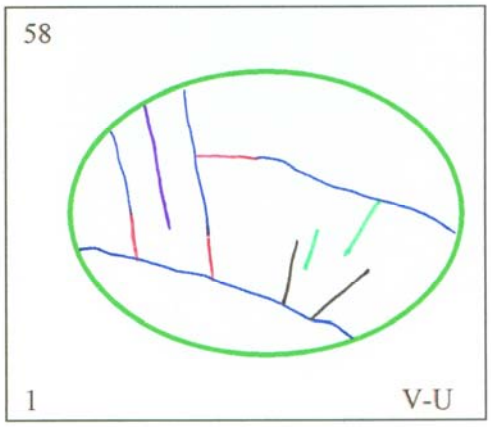

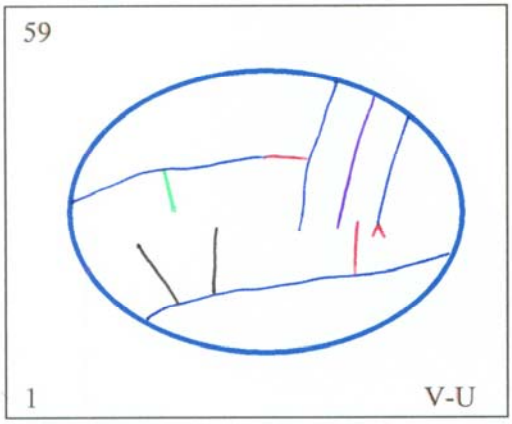

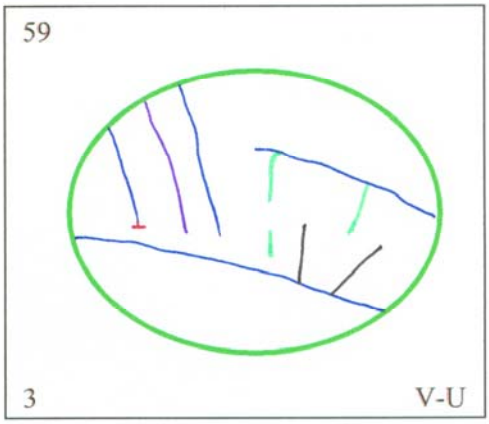

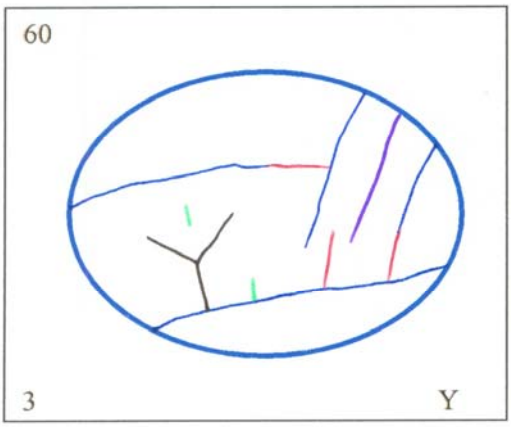

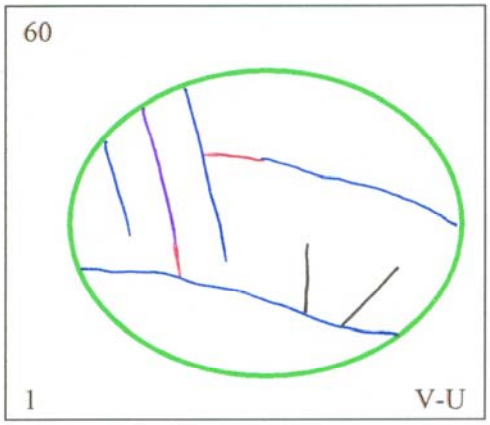

Note that the key to these diagrams is in section C.1 (pages 268 to 271).

Left Hemispheres

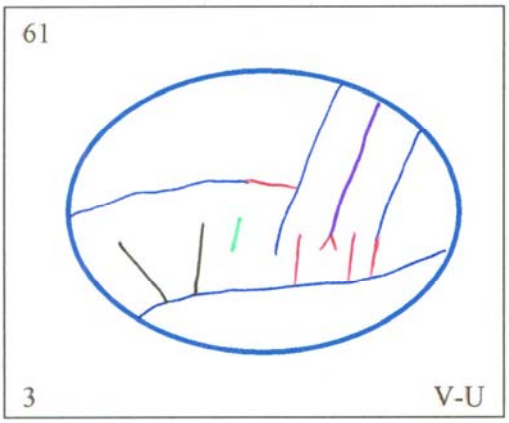

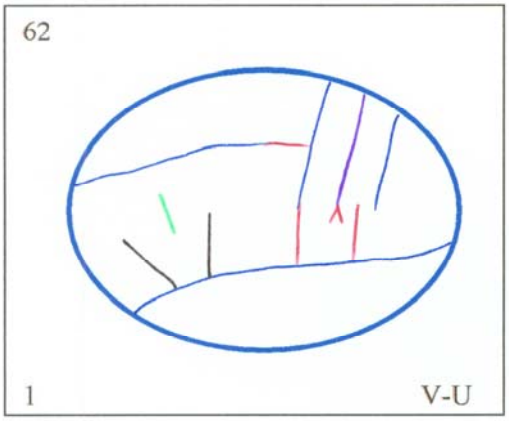

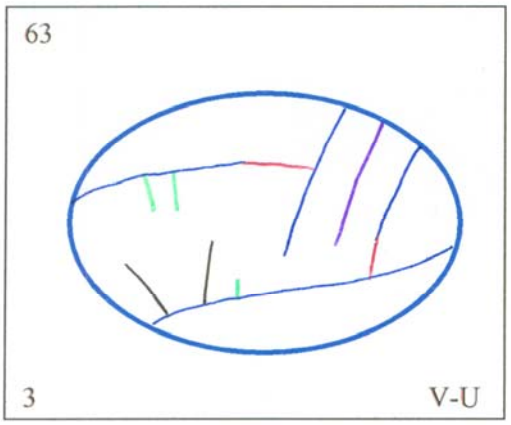

Right Hemispheres

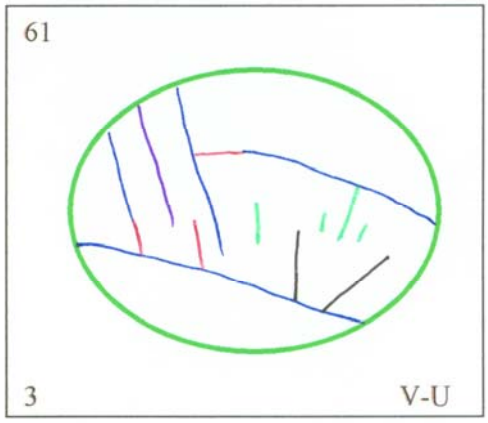

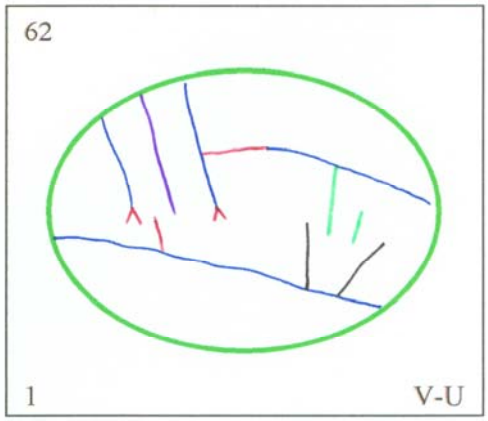

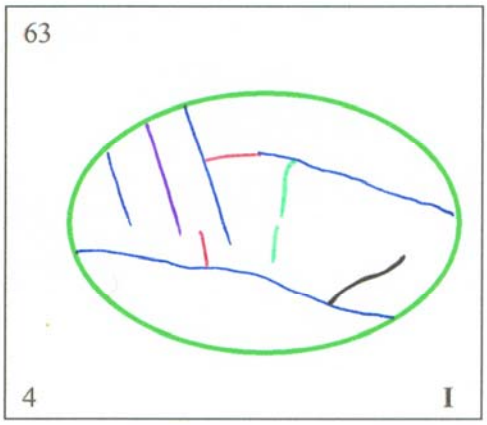

Note that the key to these diagrams is in section C.1 (pages 268 to 271).

Left Hemispheres **Right Hemispheres**

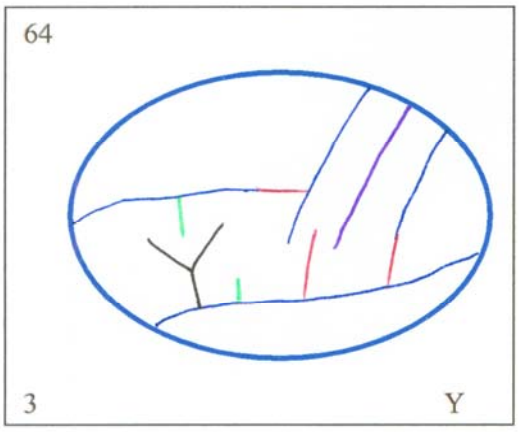

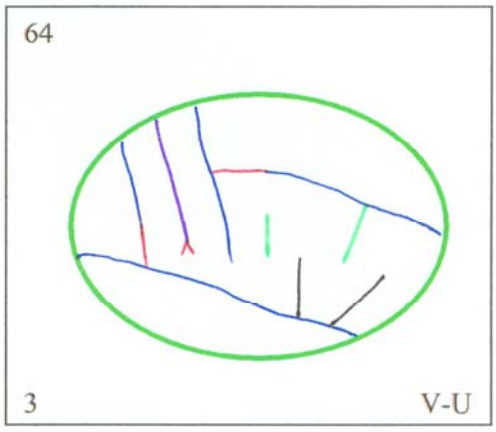

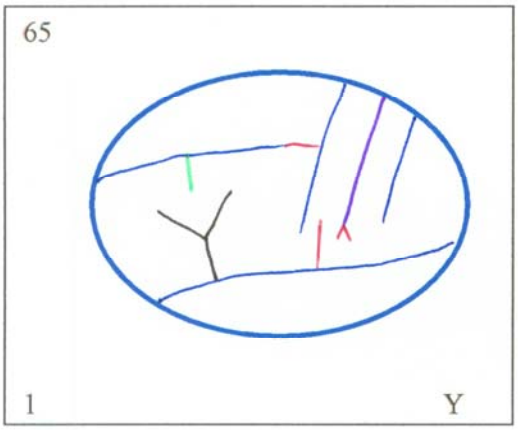

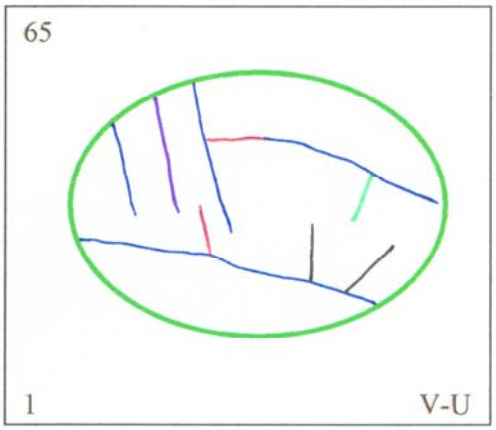

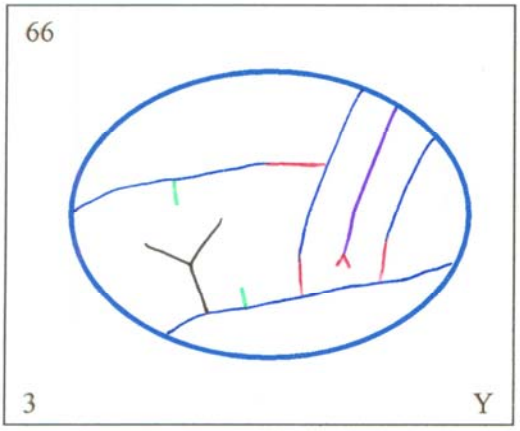

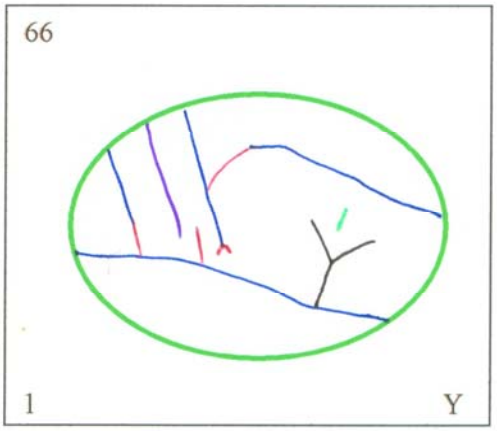

Note that the key to these diagrams is in section C1 C.1 (pages 268 to 271).

Left Hemispheres **Right Hemispheres**

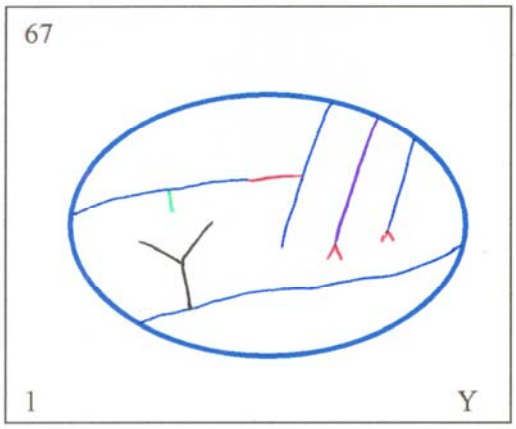

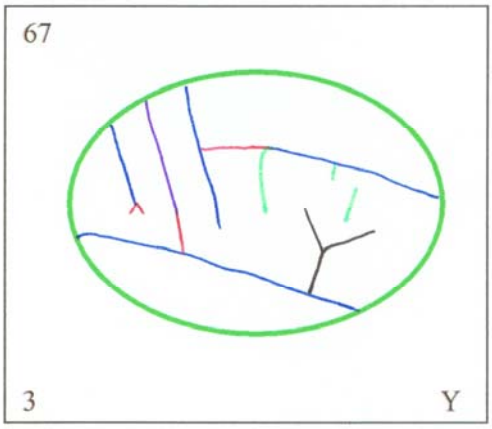

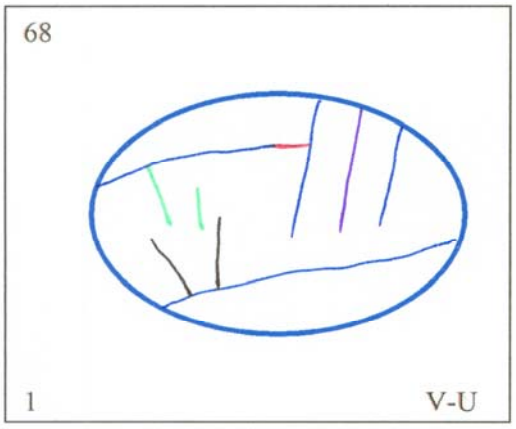

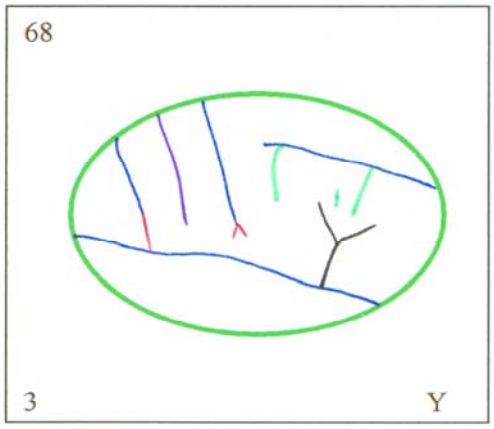

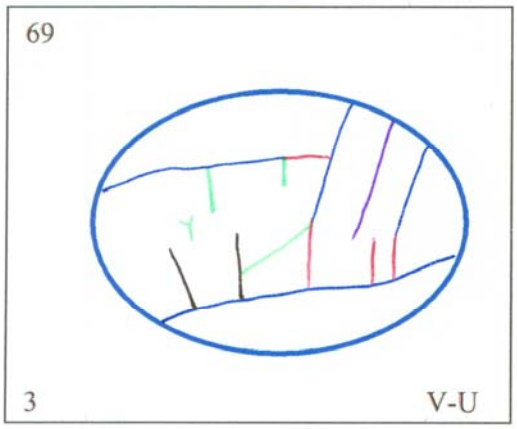

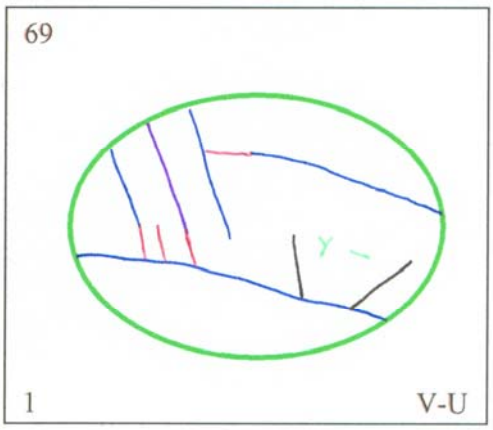

Note that the key to these diagrams is in section C.1 (pages 268 to 271).

Left Hemispheres **Right Hemispheres**



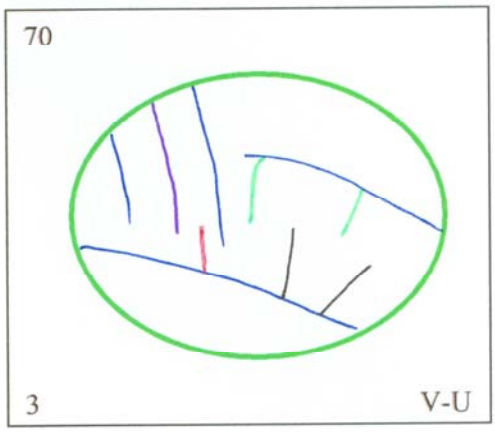

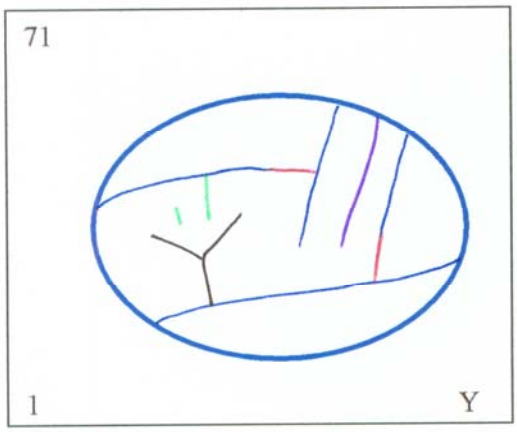

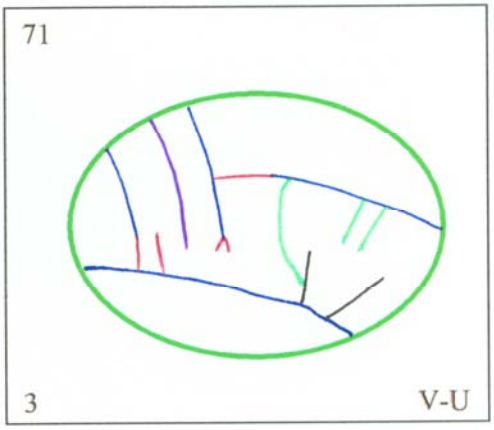



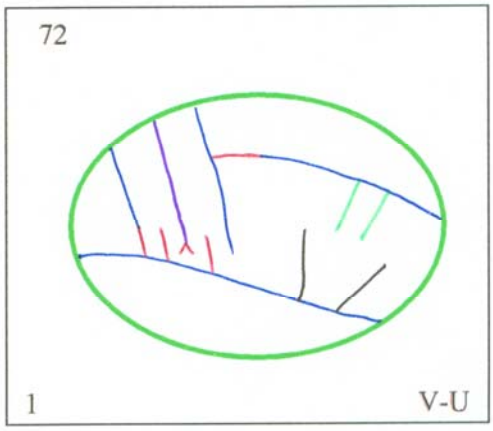

Note that the key to these diagrams is in section C.1 (pages 268 to 271).

Left Hemispheres **Right Hemispheres**



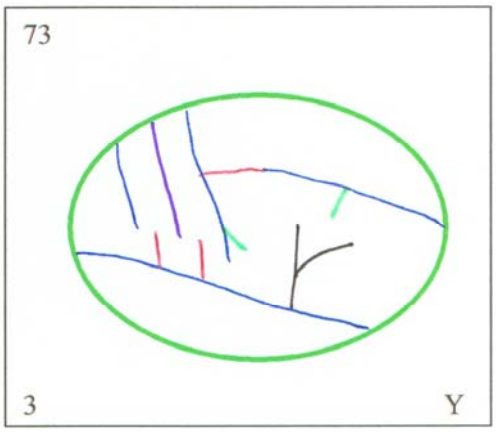

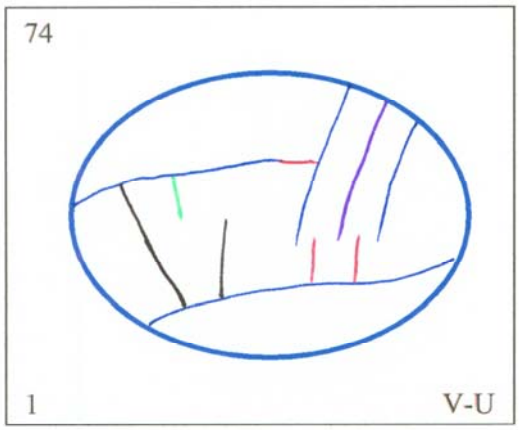

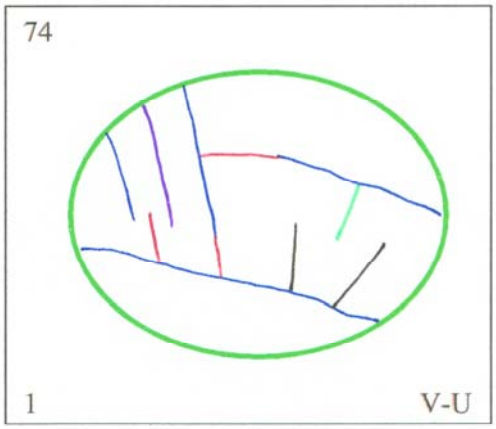

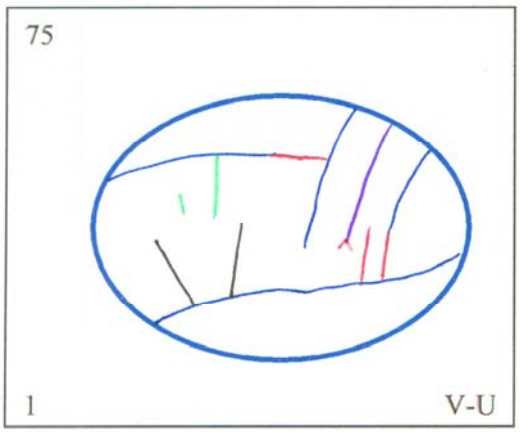

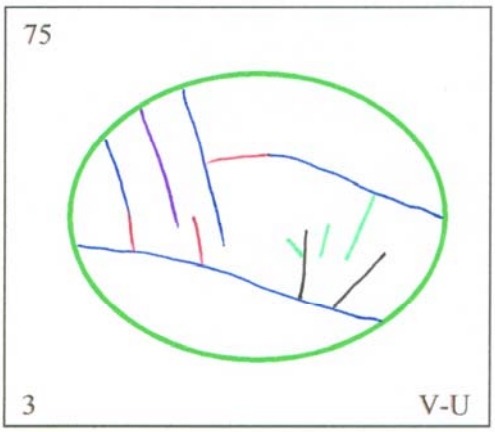

Note that the key to these diagrams is in section C.1 (pages 268 to 271).

Left Hemispheres **Right Hemispheres**

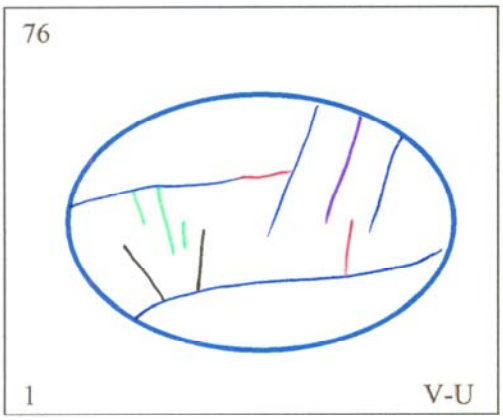

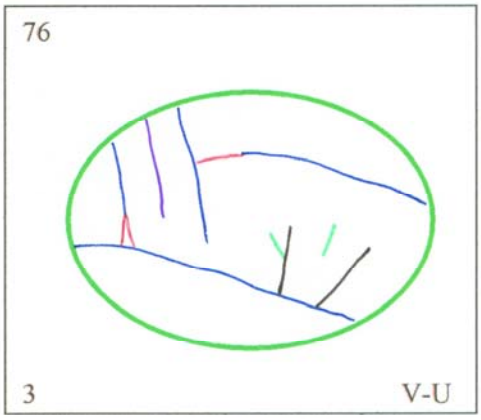

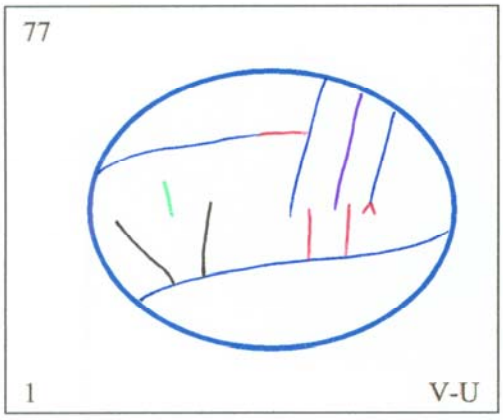

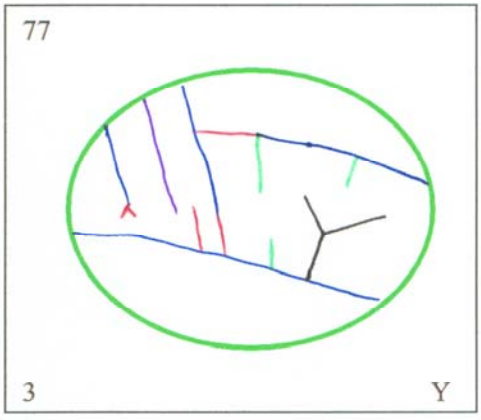

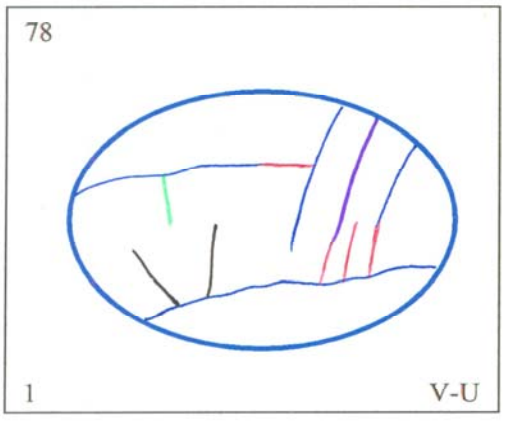

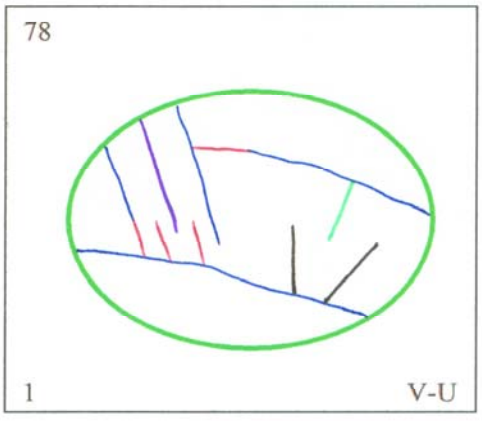

Note that the key to these diagrams is in section C.1 (pages 268 to 271).

Left Hemispheres **Right Hemispheres**

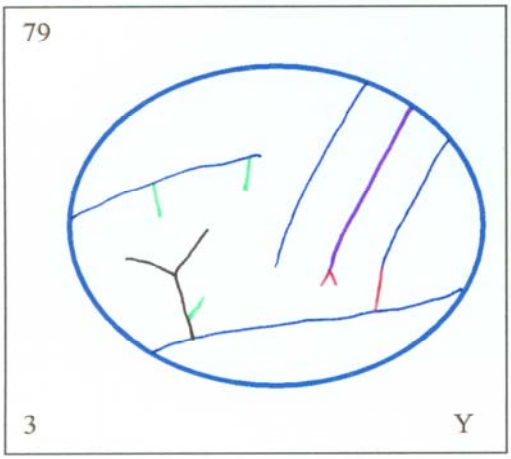

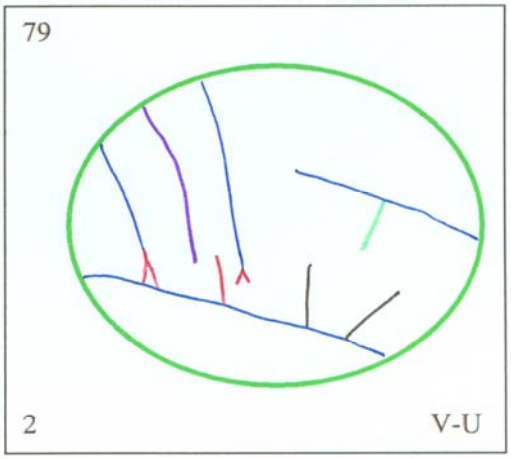

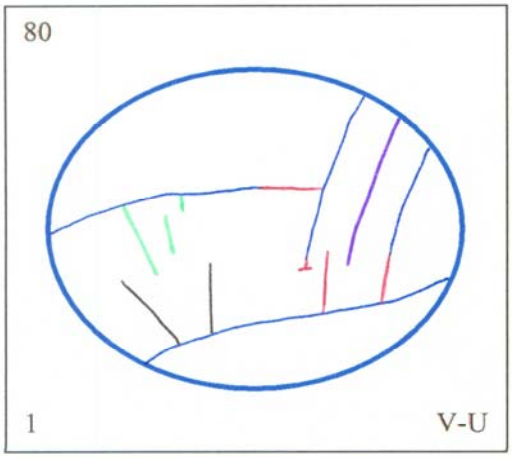

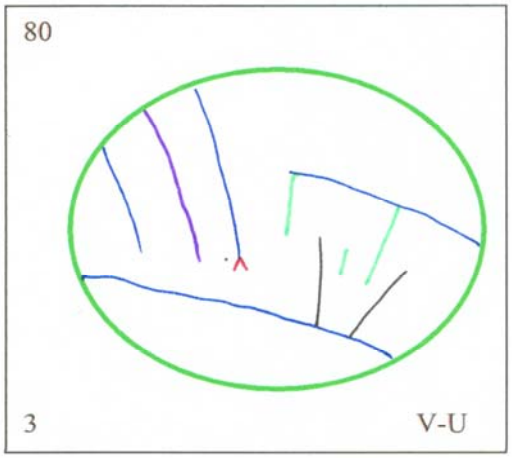

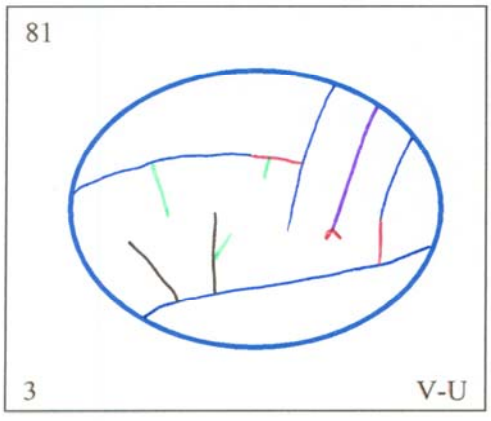

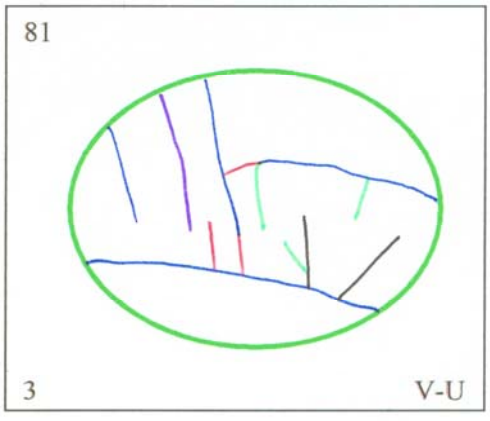

Note that the key to these diagrams is in section C.1 (pages 268 to 271).

Left Hemispheres **Right Hemispheres**

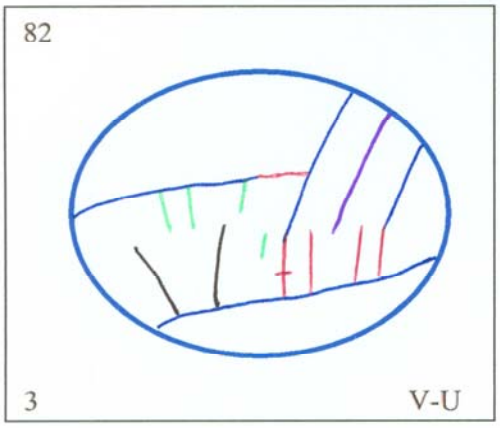

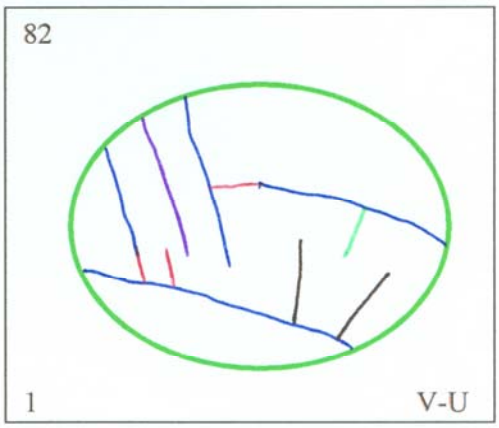

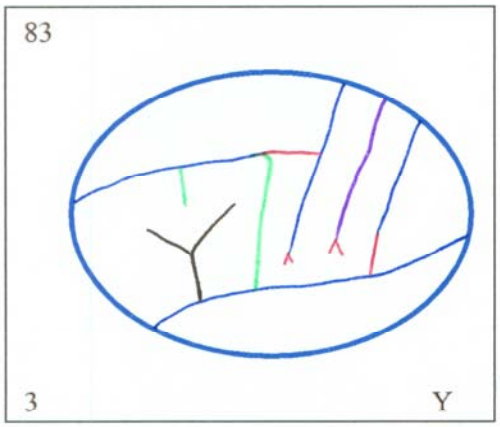

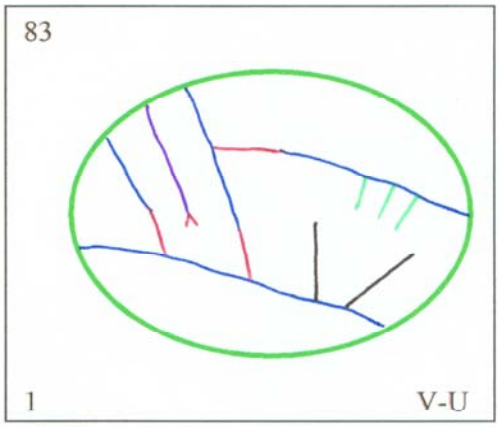

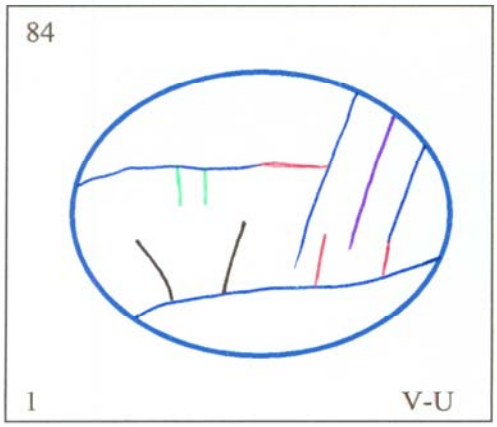

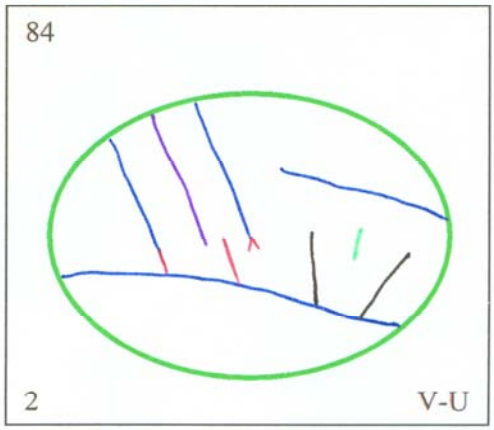

Note that the key to these diagrams is in section C1 C.1 (pages 268 to 271).

Left Hemispheres **Right Hemispheres**

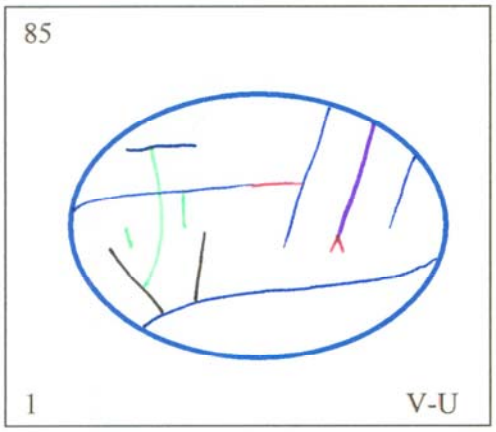

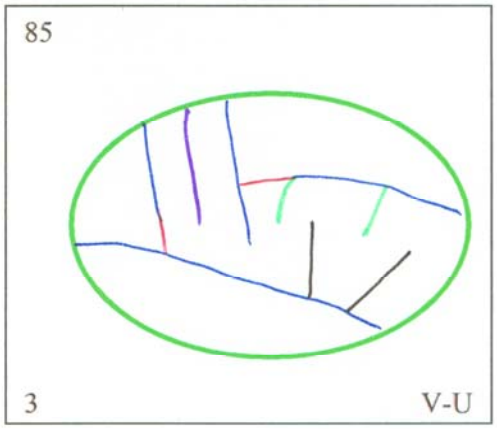

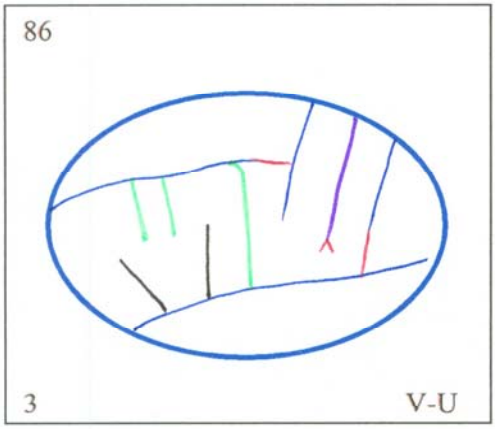

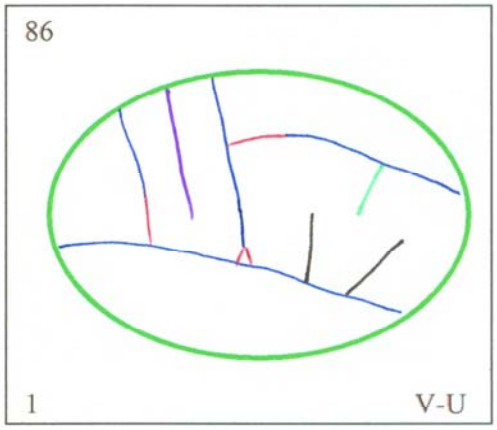

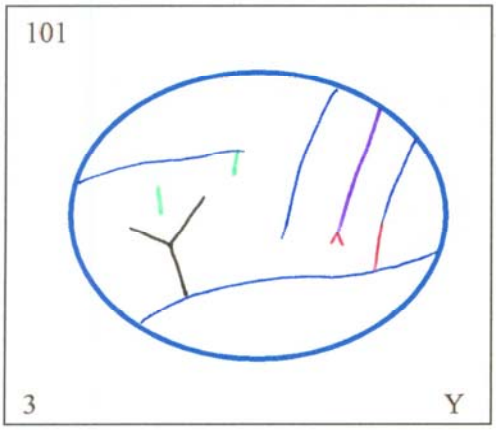

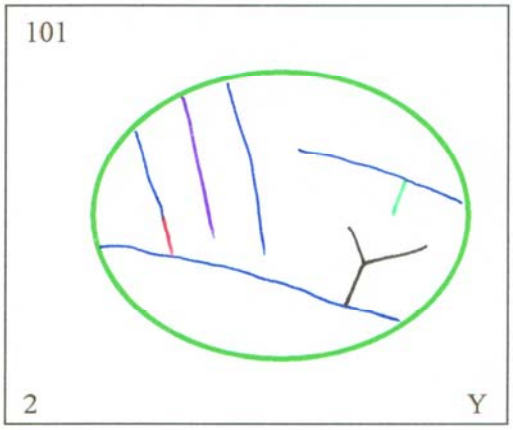

Note that the key to these diagrams is in section C.1 (pages 268 to 271).

Left Hemispheres **Right Hemispheres**

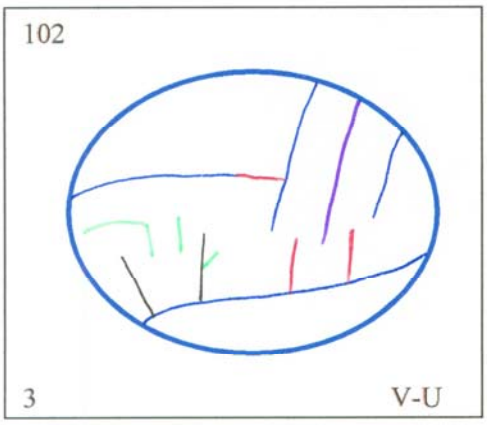

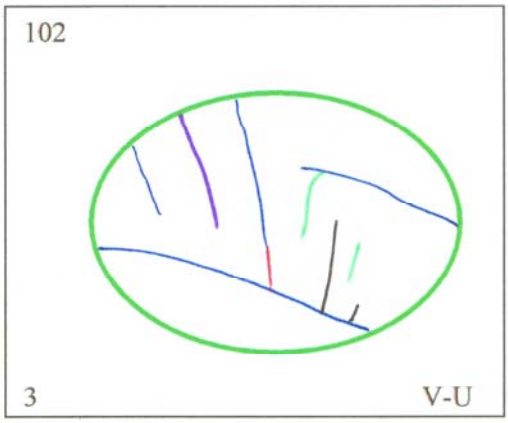

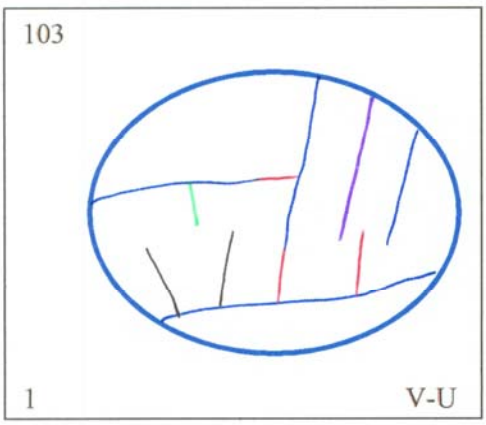

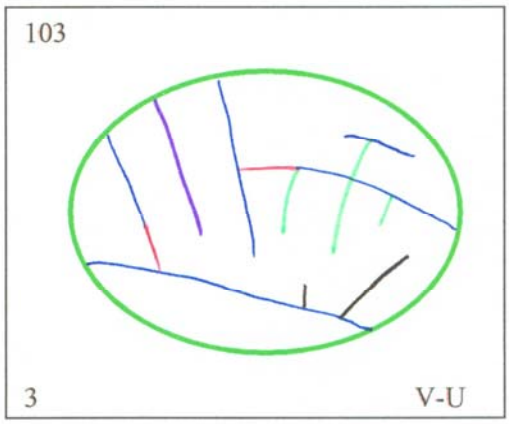

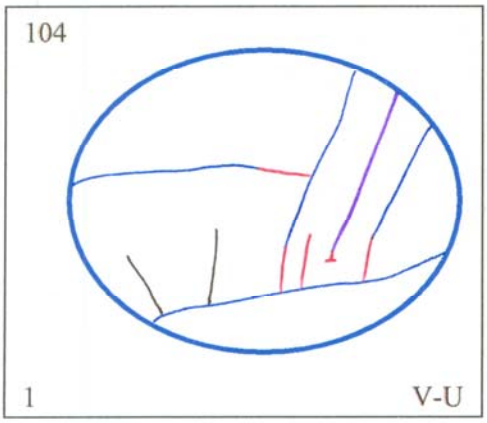

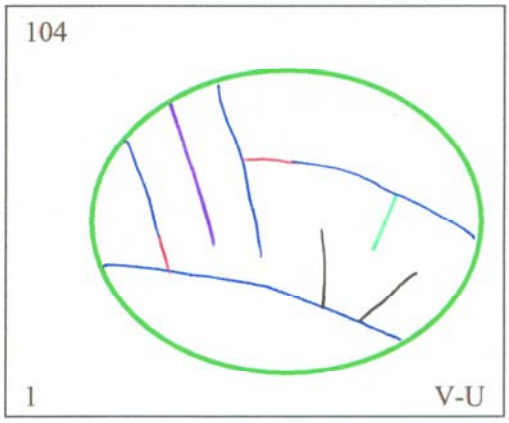

Note that the key to these diagrams is in section C.1 (pages 268 to 271).

Left Hemispheres **Right Hemispheres**

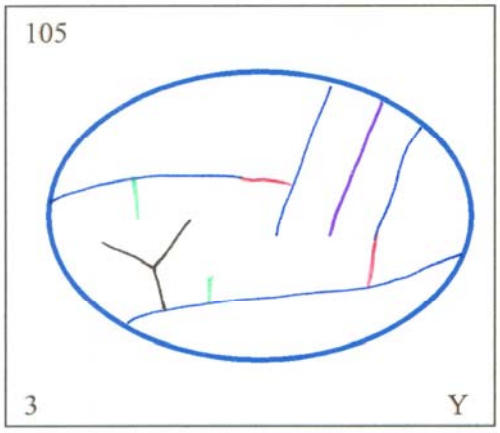

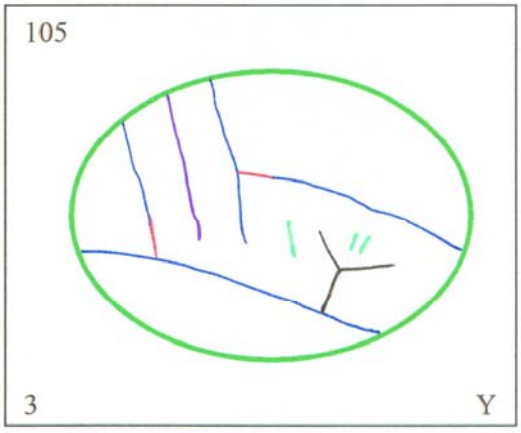

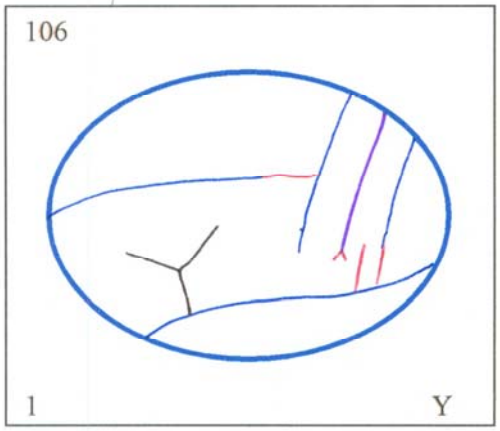





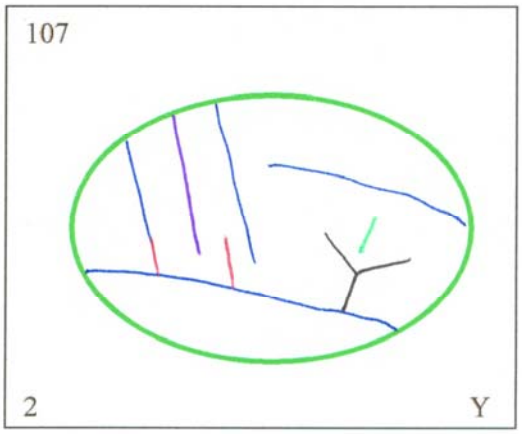

Note that the key to these diagrams is in section C.1 (pages 268 to 271).

Left Hemispheres **Right Hemispheres**





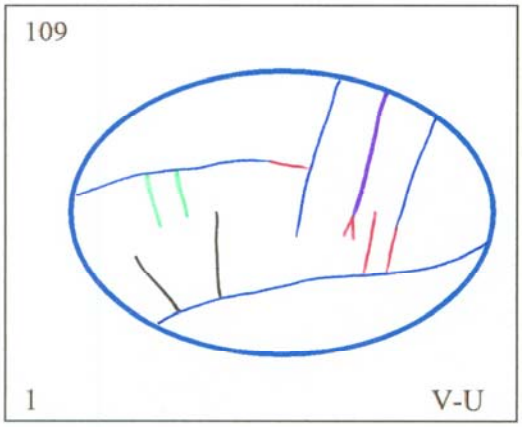

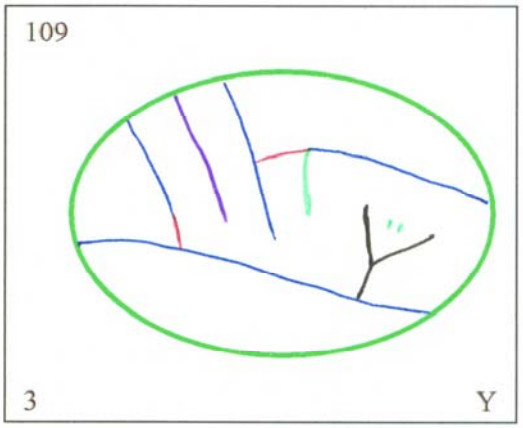

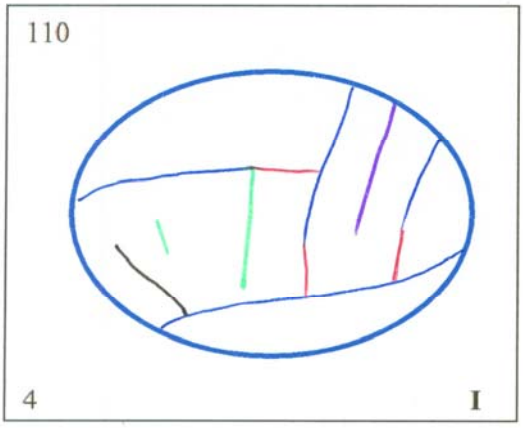

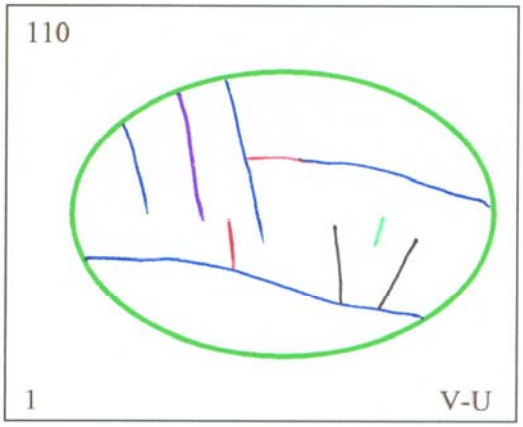

C.3. DESCRIPTIVE RECORD FOR THE SEPARATE LEFT- AND RIGHT- HEMISPHERES (CASE CATEGORY)

Note that the key to these diagrams is in section C.1 (pages 268 to 271).

Left Hemispheres

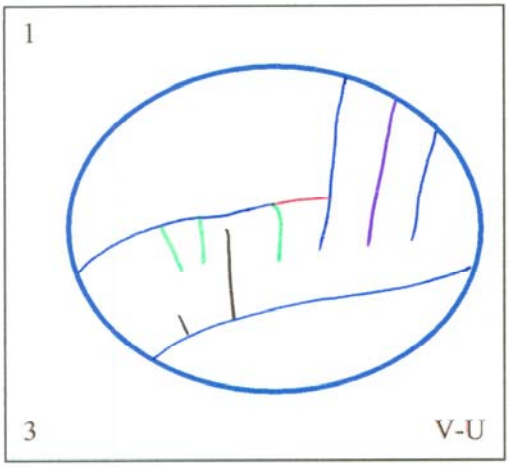

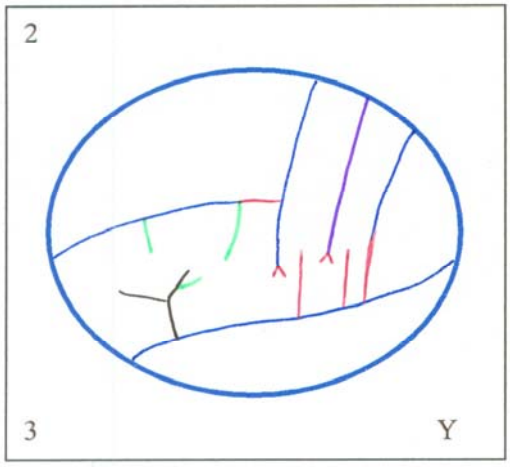

Right Hemispheres

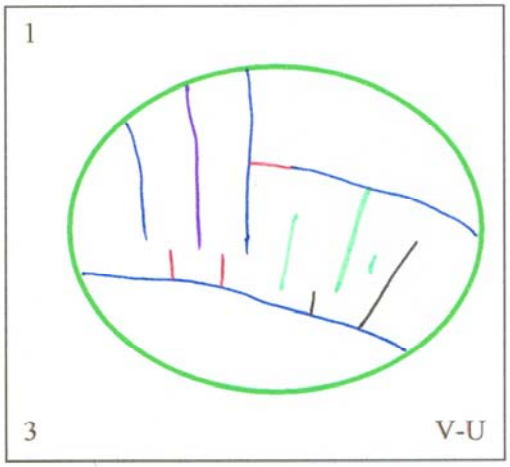

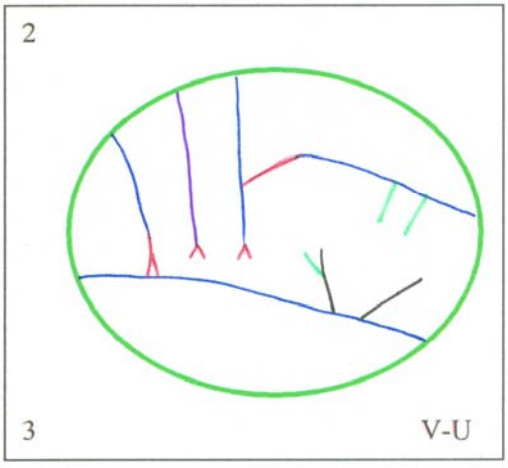

Note that the key to these diagrams is in section C.1 (pages 268 to 271).

Left Hemispheres **Right Hemispheres**

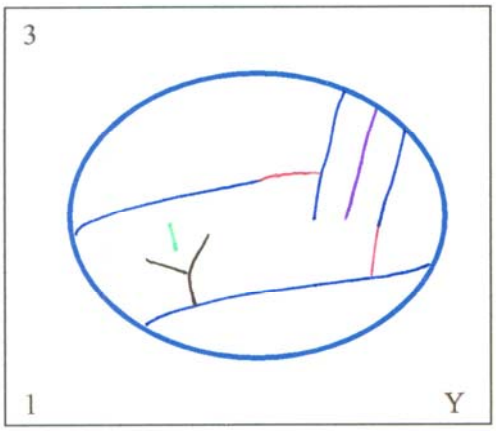

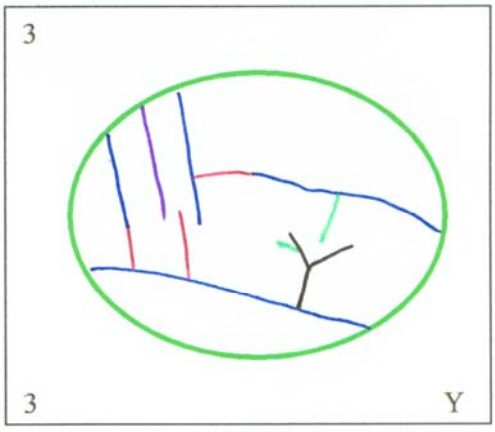

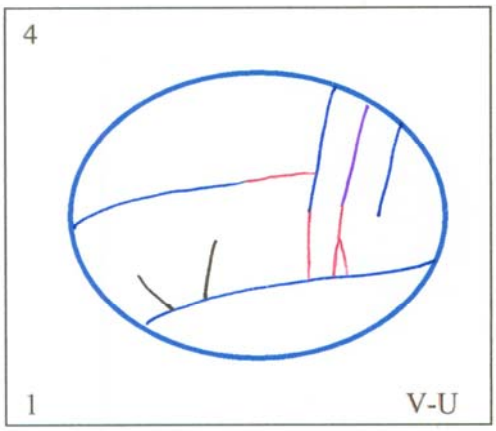

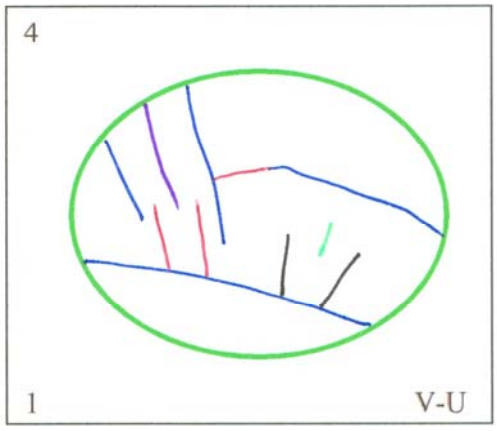

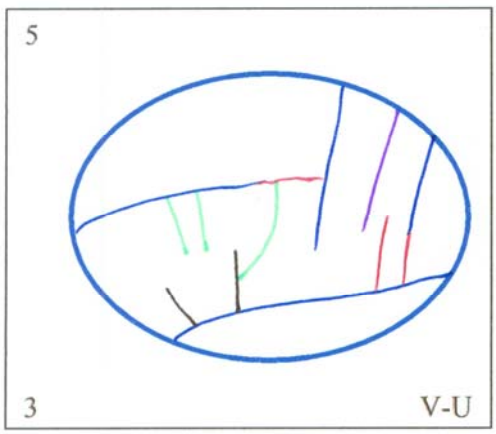

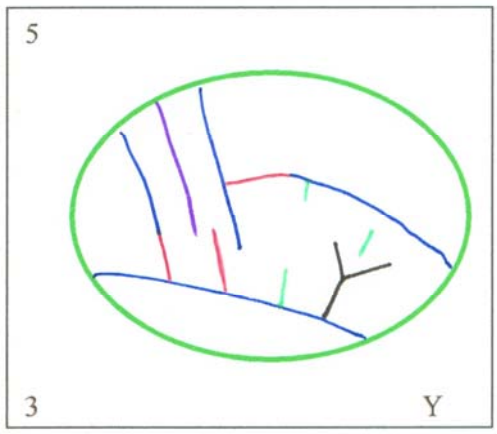

Note that the key to these diagrams is in section C.1 (pages 268 to 271).

Left Hemispheres **Right Hemispheres**

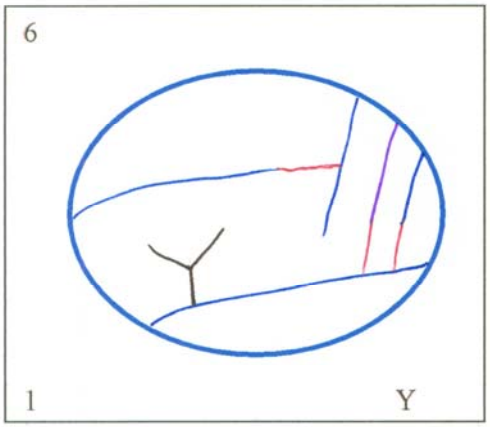

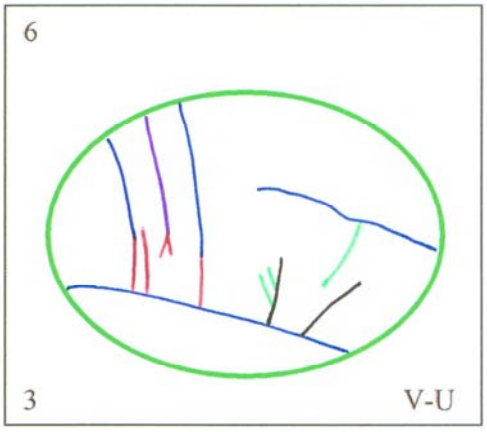

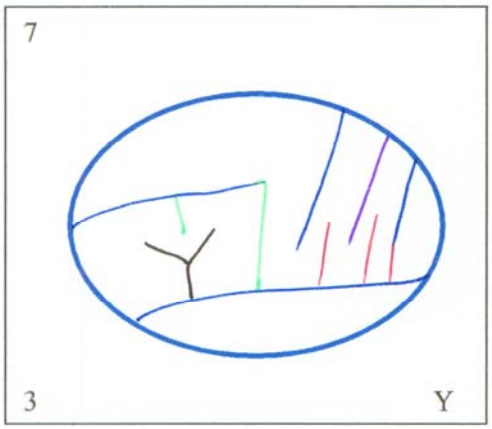

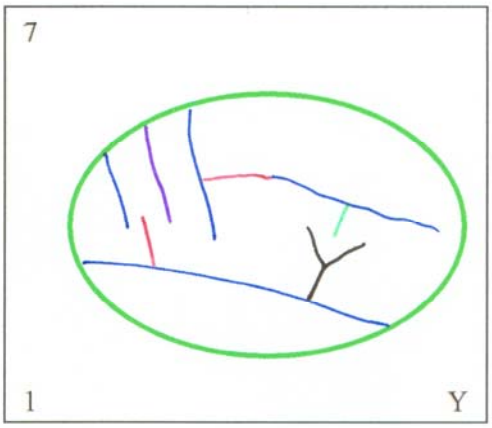

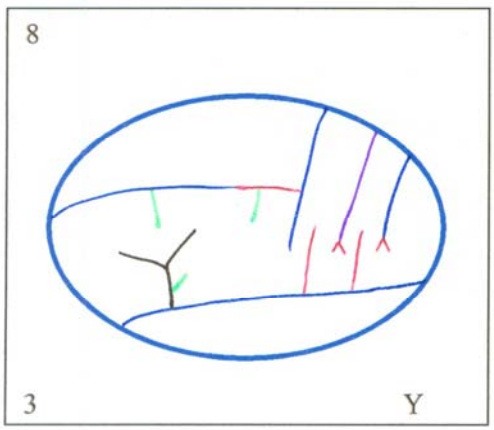

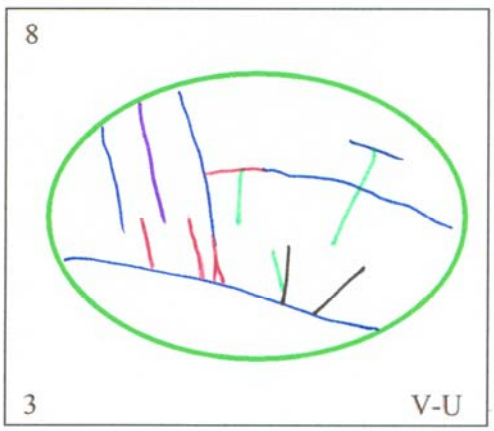

Note that the key to these diagrams is in section C.1 (pages 268 to 271).

Left Hemispheres **Right Hemispheres**

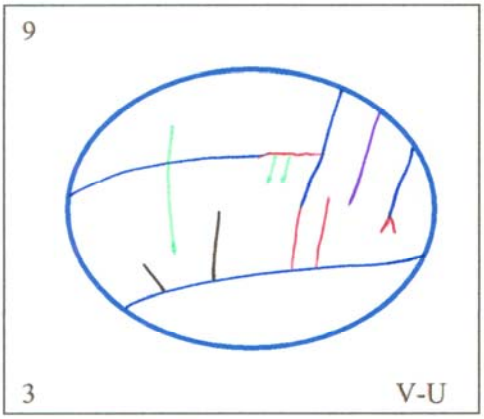

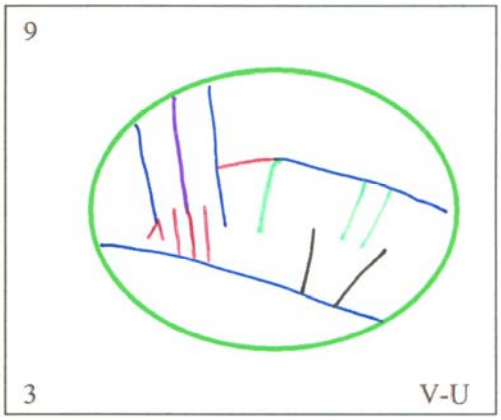

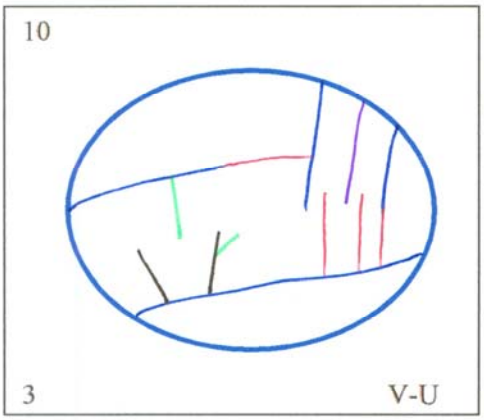

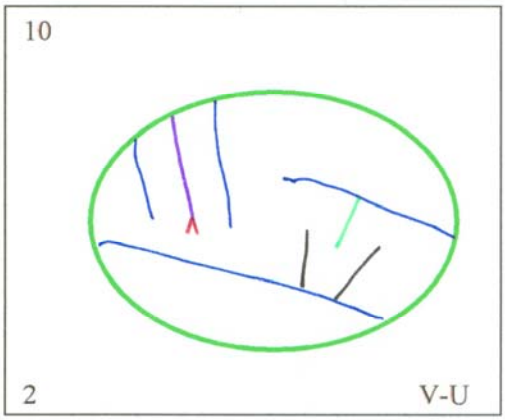

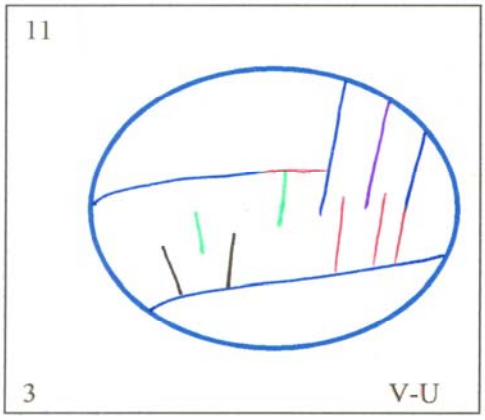

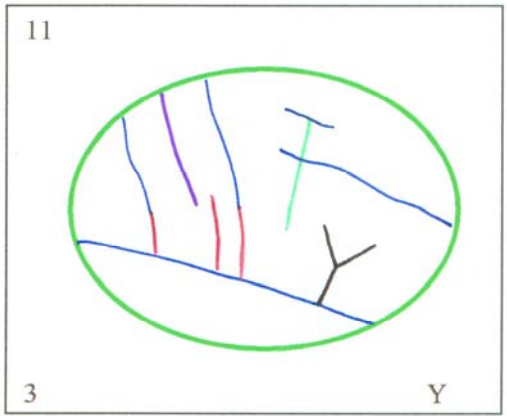

Note that the key to these diagrams is in section C.1 (pages 268 to 271).

Left Hemispheres **Right Hemispheres**

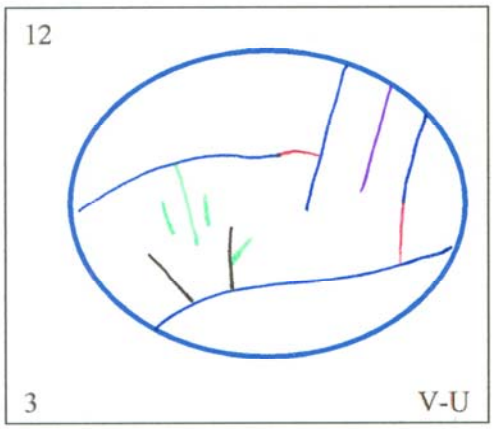

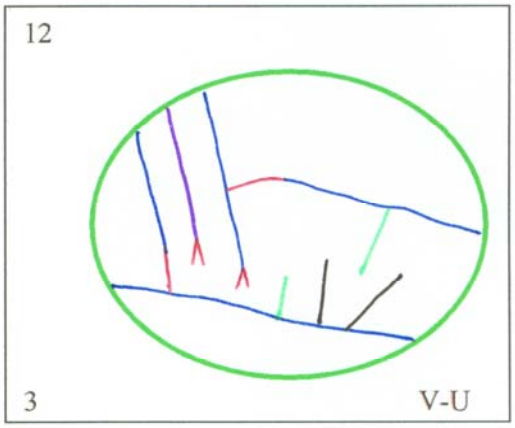

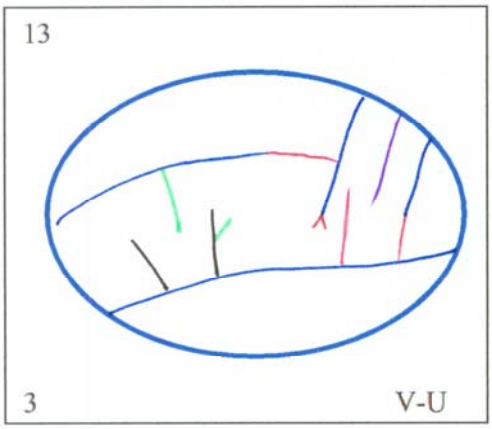

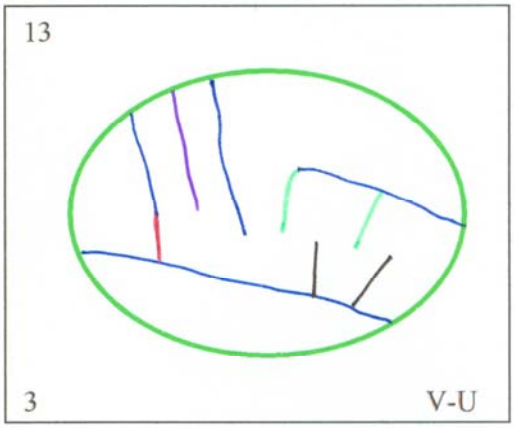

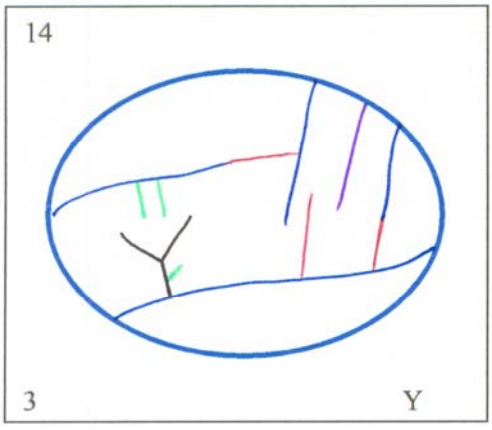

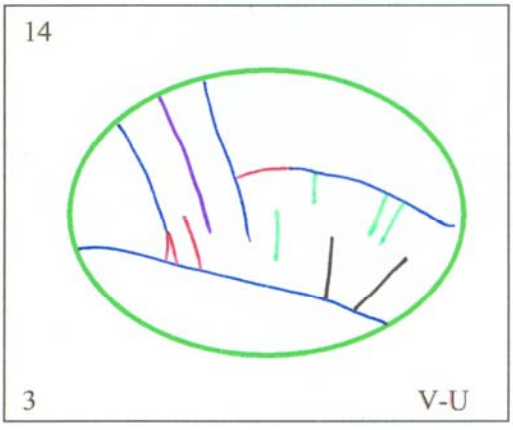

Note that the key to these diagrams is in section C.1 (pages 268 to 271).

Left Hemispheres **Right Hemispheres**

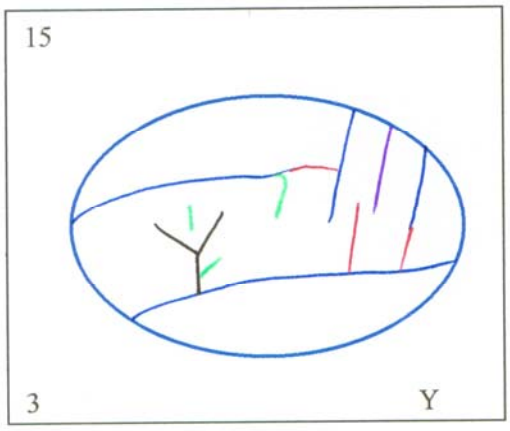

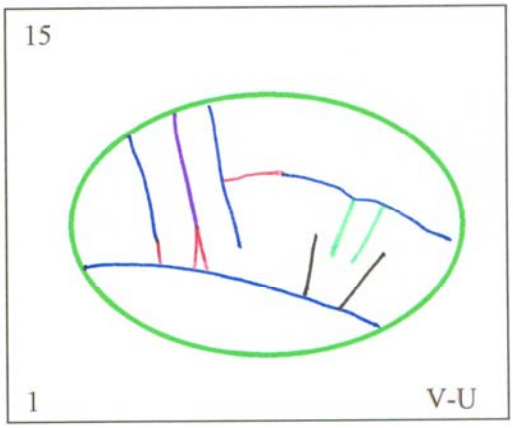

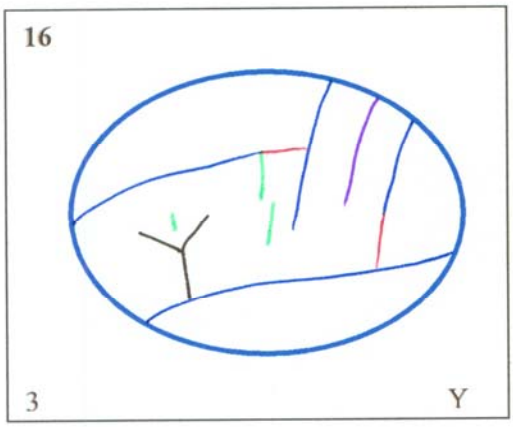

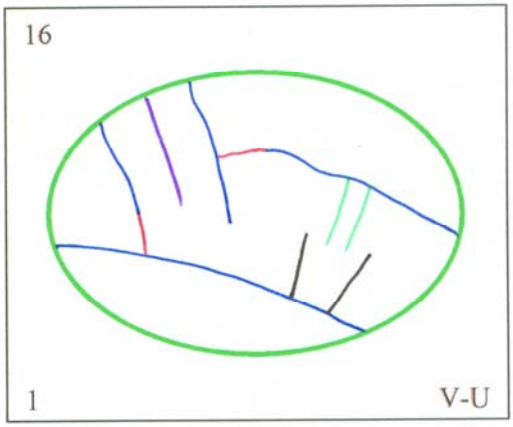

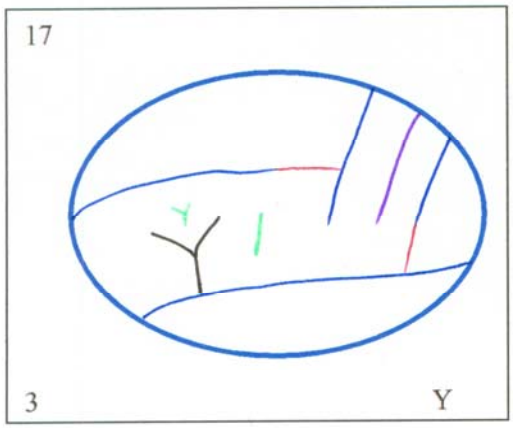

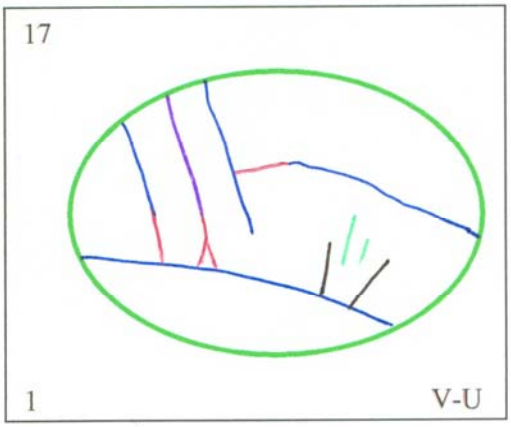

Note that the key to these diagrams is in section C.1 (pages 268 to 271).

Left Hemispheres **Right Hemispheres**

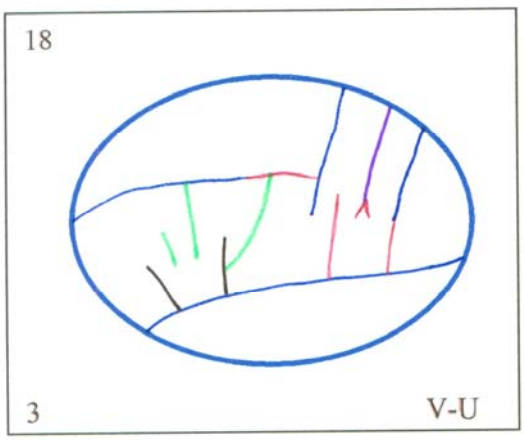



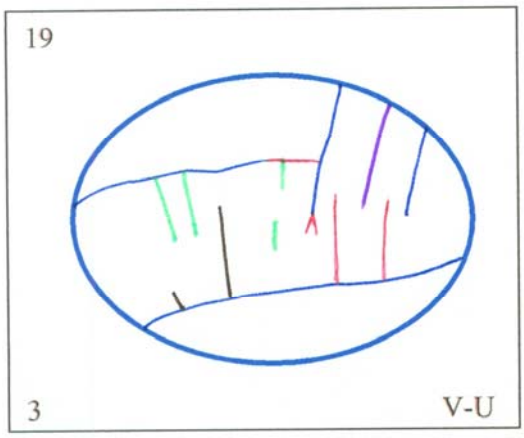

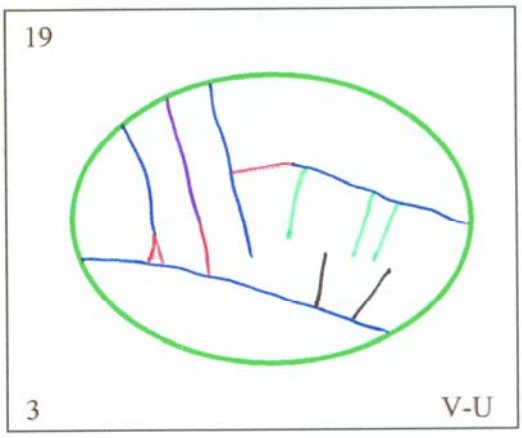

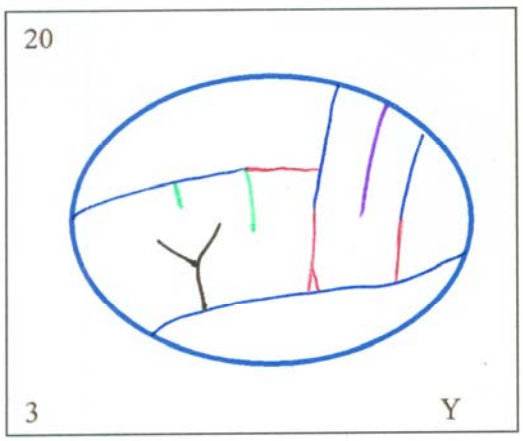

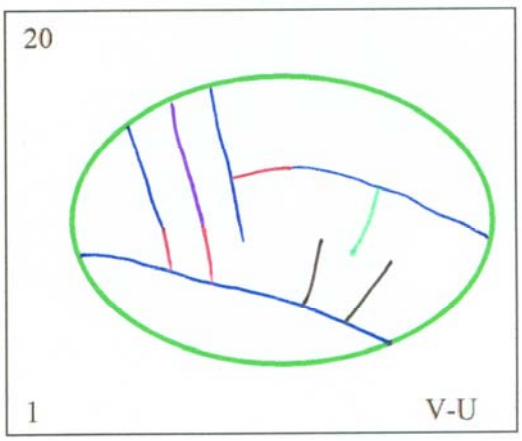

Note that the key to these diagrams is in section C.1 (pages 268 to 271).

Left Hemispheres **Right Hemispheres**

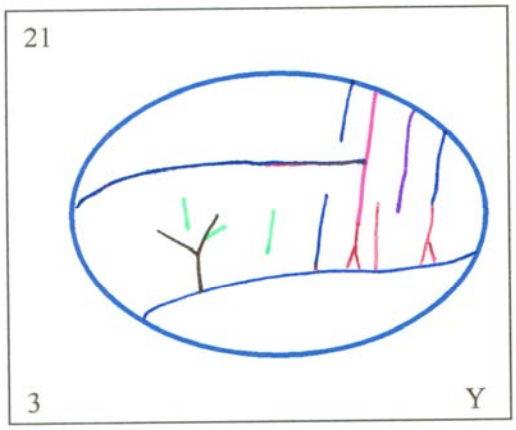

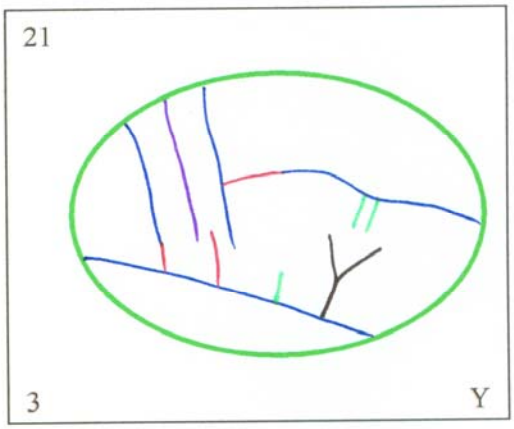



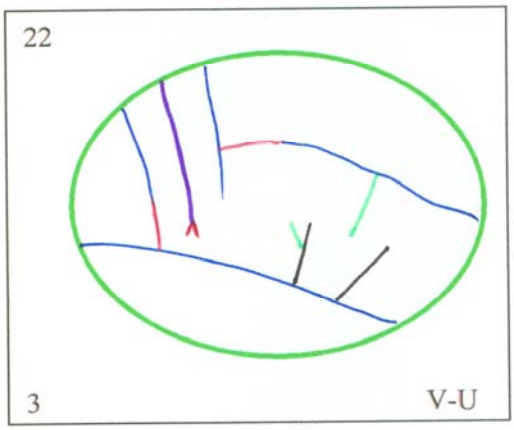



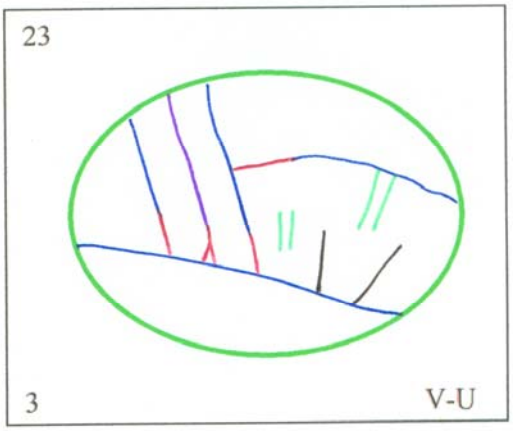

Note that the key to these diagrams is in section C.1 (pages 268 to 271).

Left Hemispheres **Right Hemispheres**

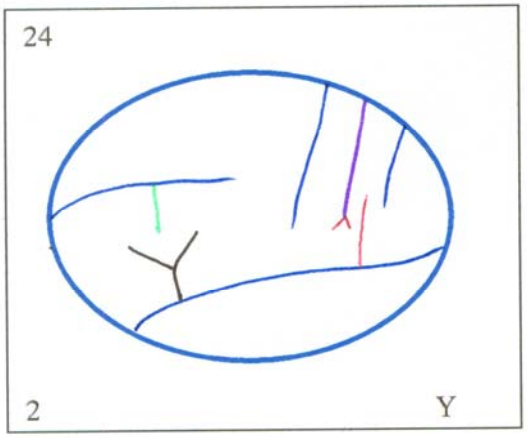

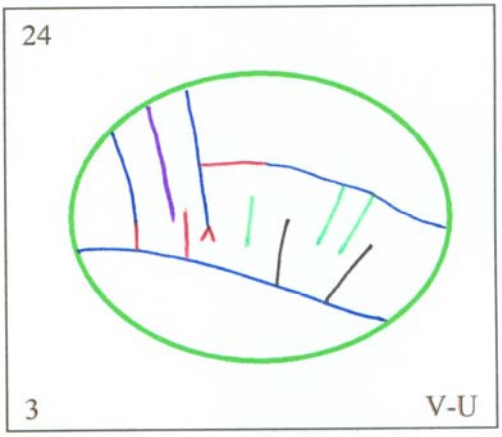

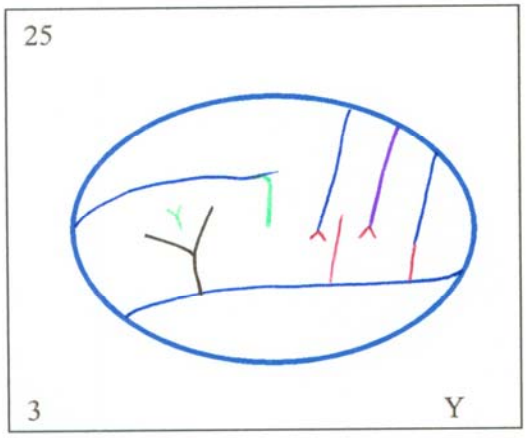

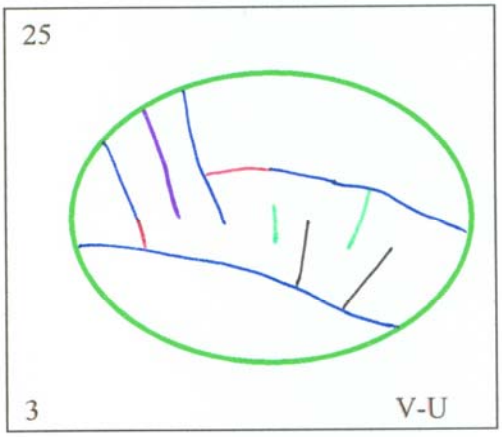

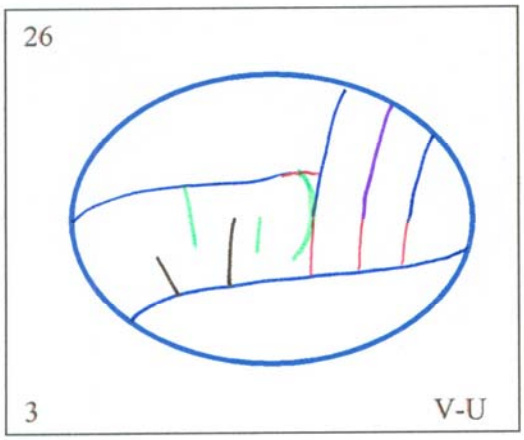

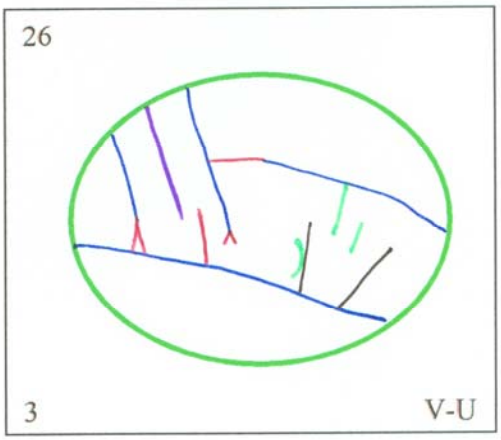

Note that the key to these diagrams is in section C.1 (pages 268 to 271).

Left Hemispheres **Right Hemispheres**

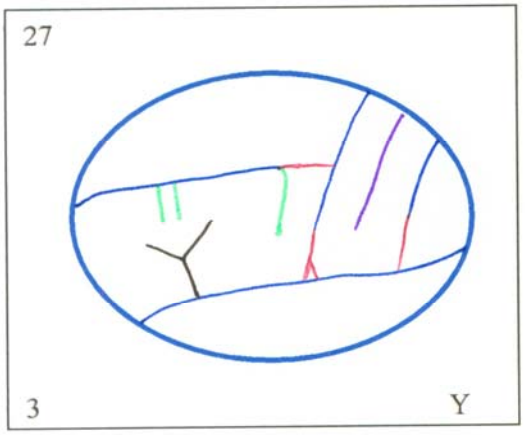

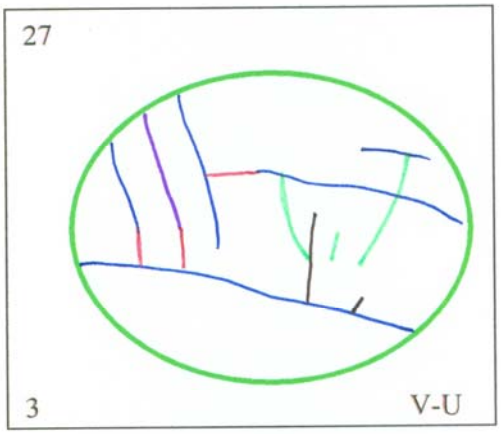

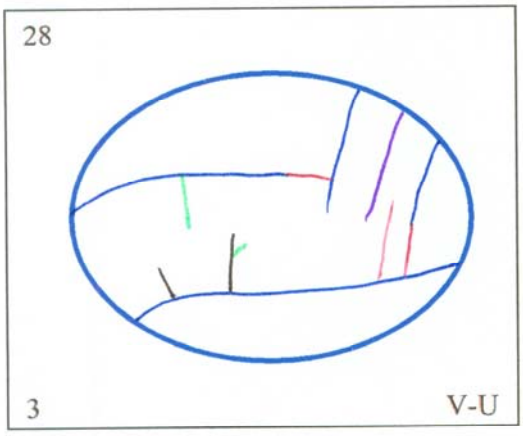

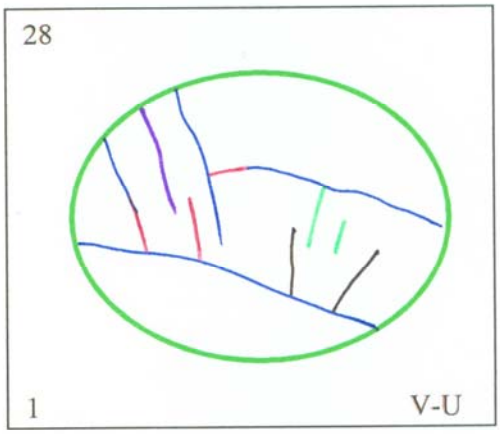

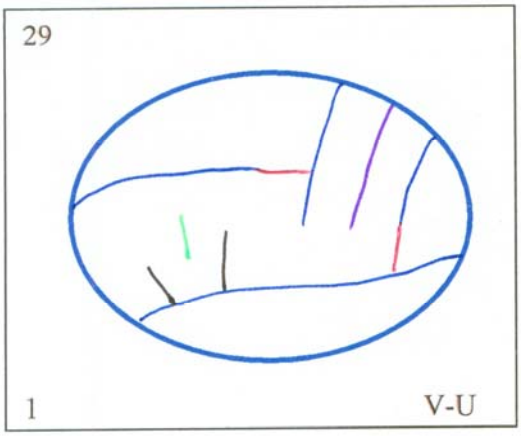



Note that the key to these diagrams is in section C.1 (pages 268 to 271).

Left Hemispheres **Right Hemispheres**

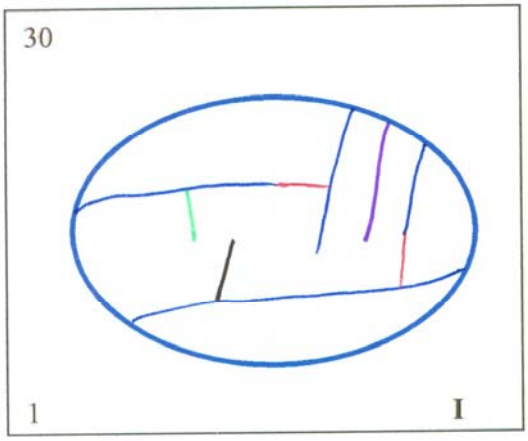

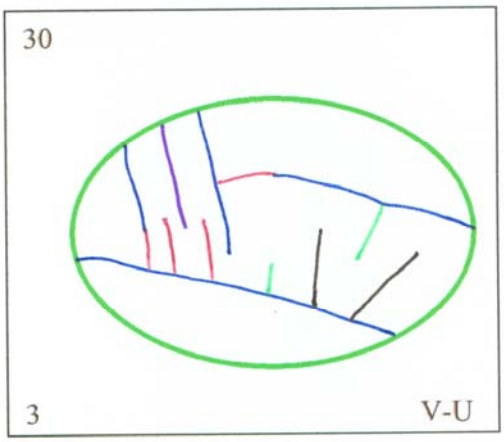

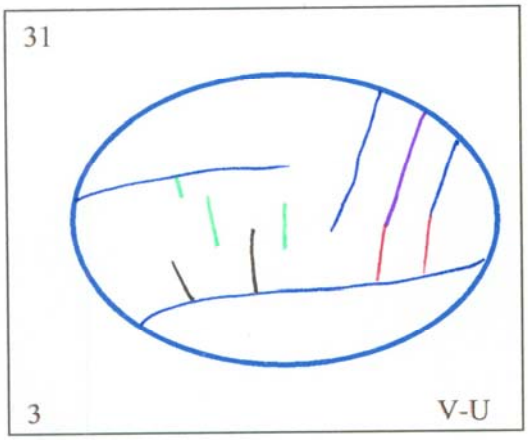

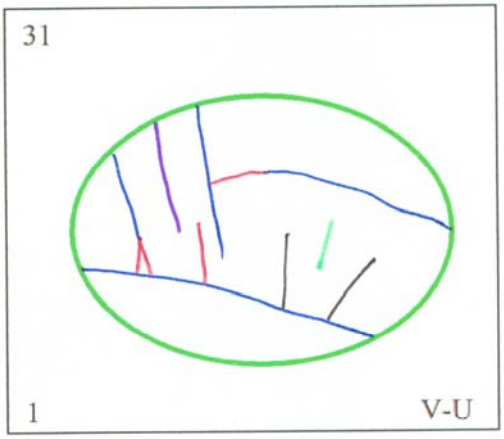

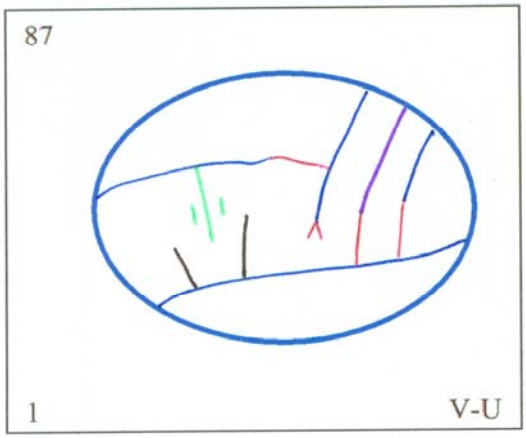

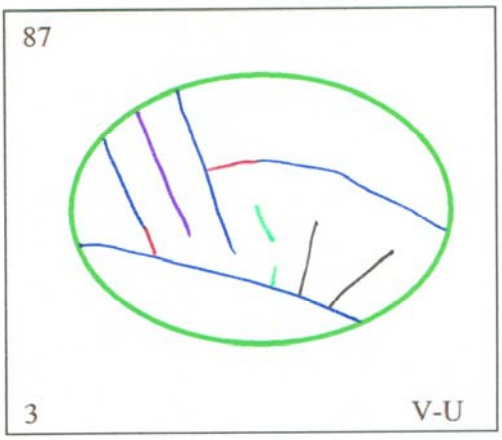

Note that the key to these diagrams is in section C.1 (pages 268 to 271).

Left Hemispheres **Right Hemispheres**

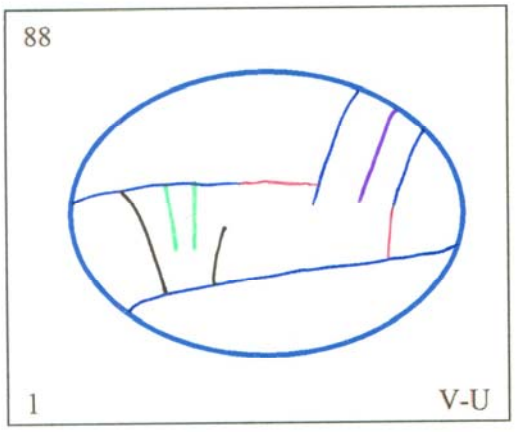

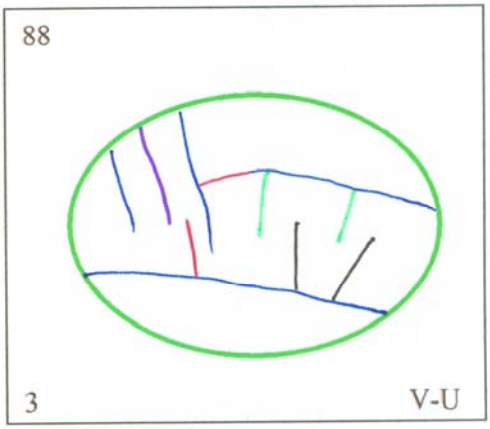

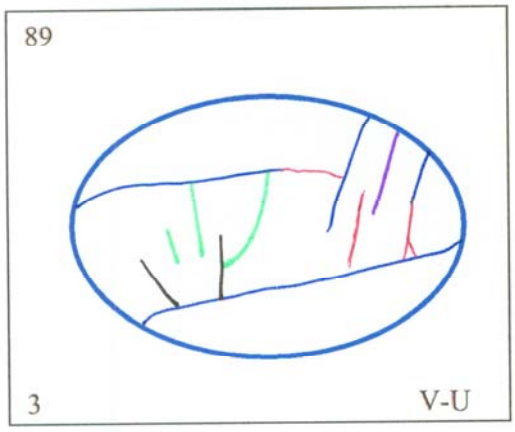

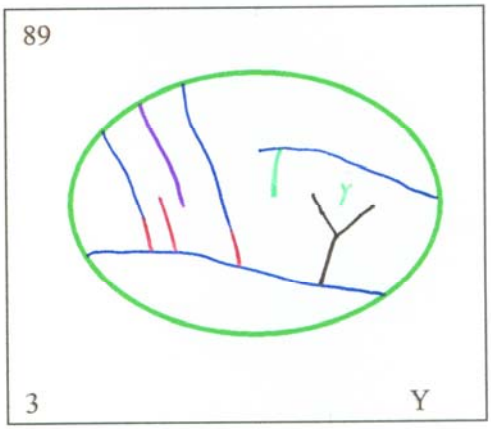

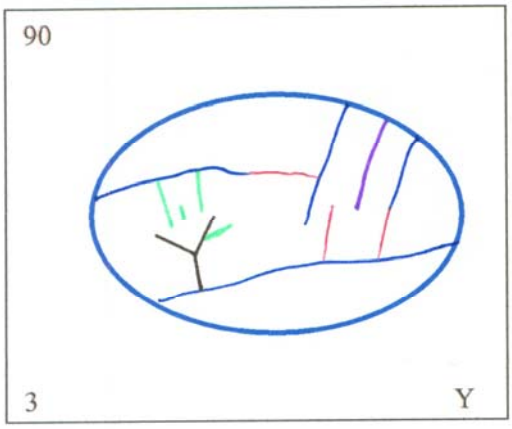

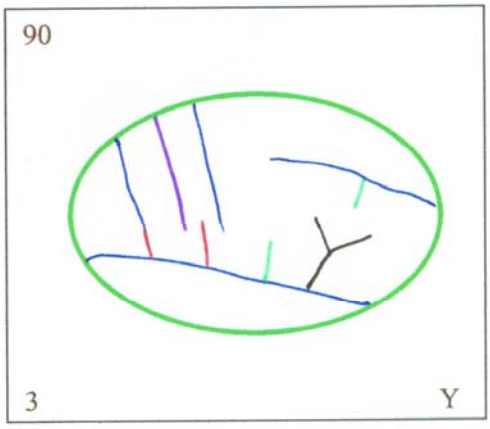

Note that the key to these diagrams is in section C.1 (pages 268 to 271).

Left Hemispheres **Right Hemispheres**

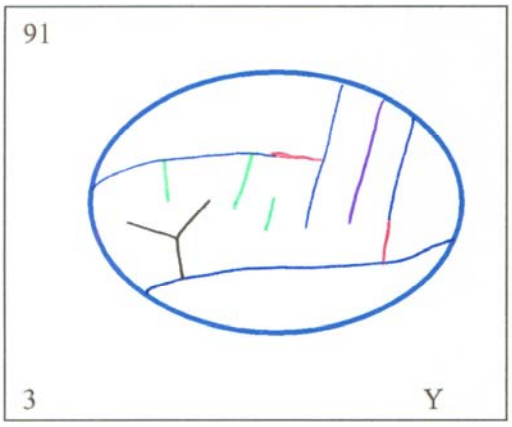

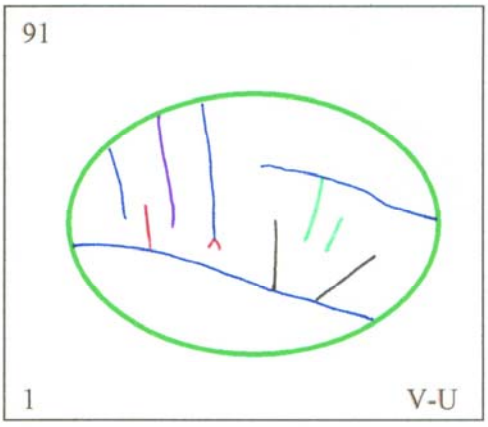



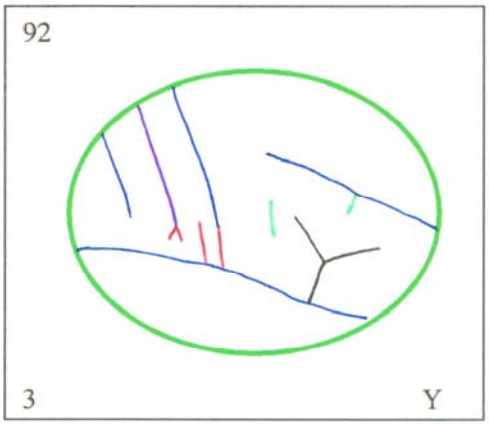

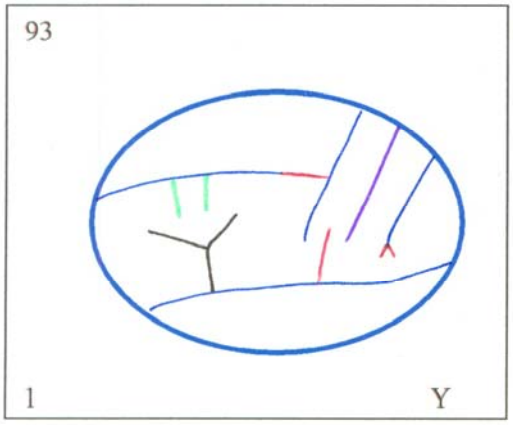

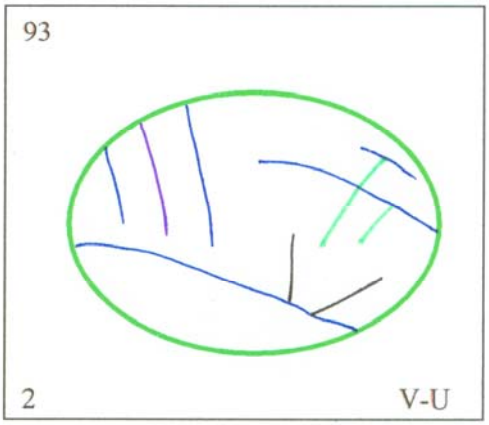

Note that the key to these diagrams is in section C.1 (pages 268 to 271).

Left Hemispheres **Right Hemispheres**

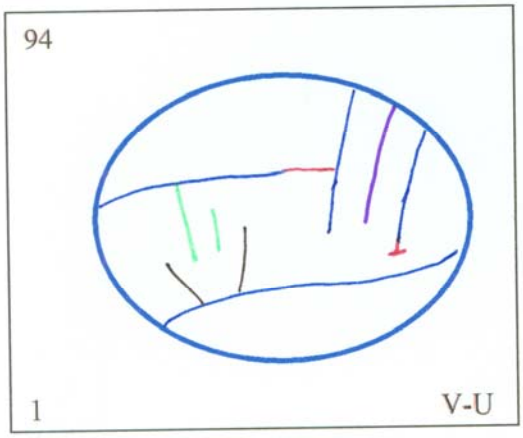

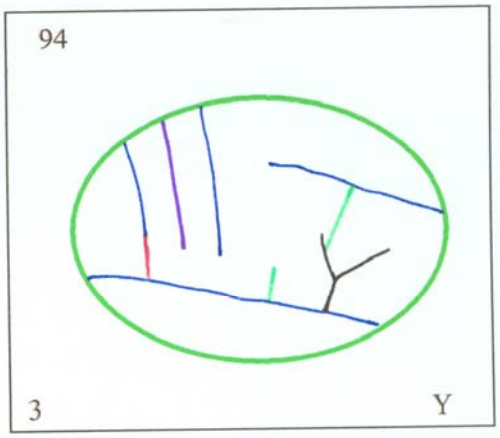

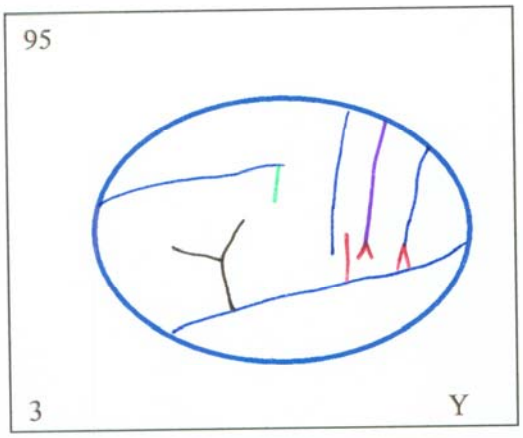

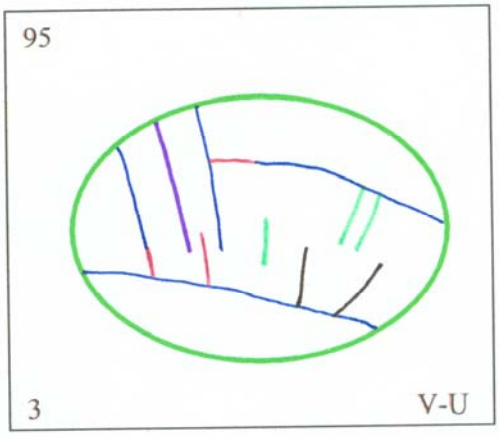



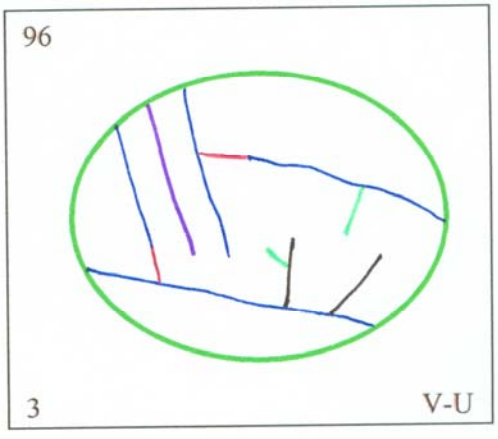

Note that the key to these diagrams is in section C.1 (pages 268 to 271).

Left Hemispheres **Right Hemispheres**

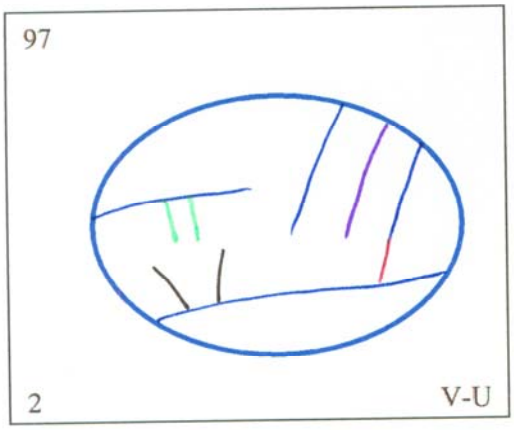

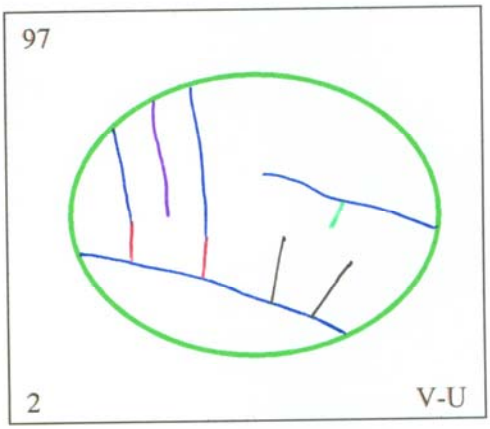

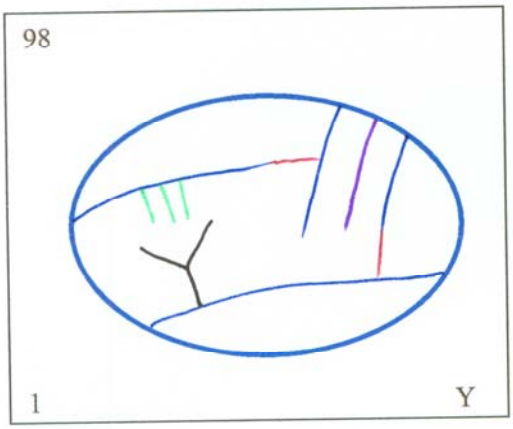

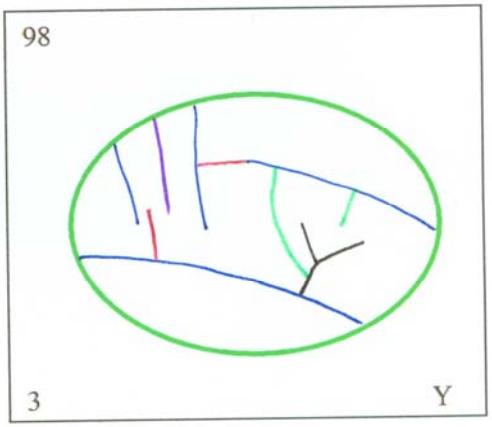

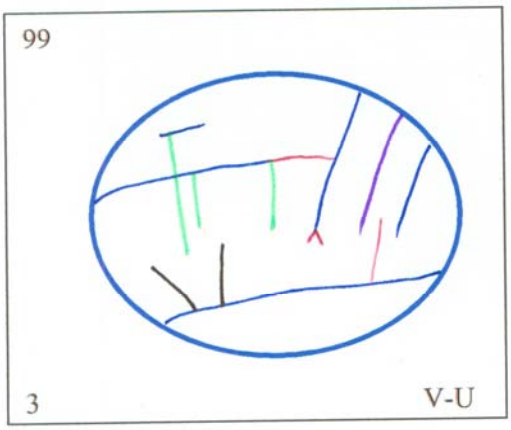

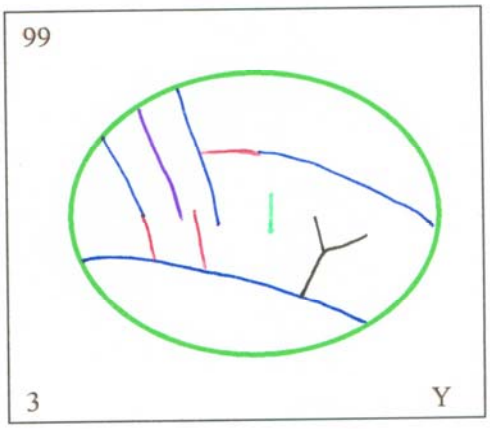

Note that the key to these diagrams is in section C.1 (pages 268 to 271).

Left Hemispheres **Right Hemispheres**

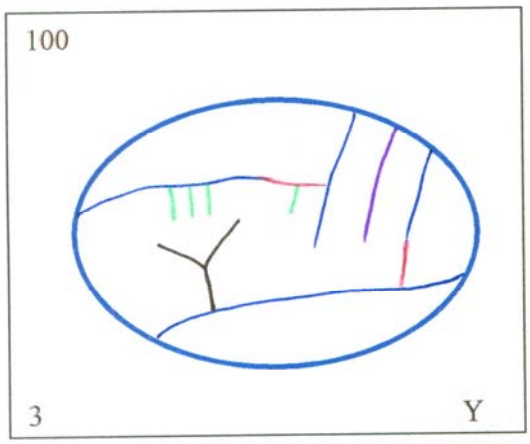

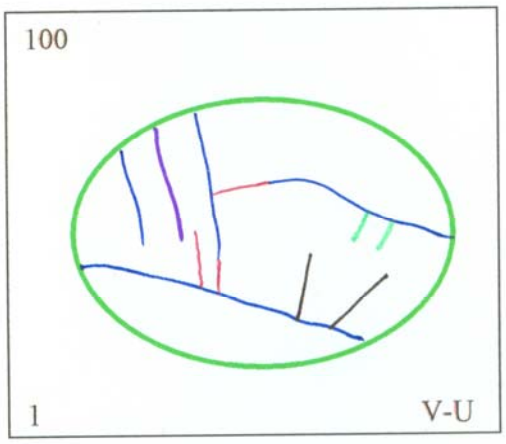

C.4. SUMMARY OF THE DESCRIPTIVE RECORD

C.4.1 FOR THE SEPARATE HEMISPHERES (CASE):

Table C.1: Summary of the specimens in which the Types of Sulcal Connections were observed in the case category.

TYPES OF SULCAL CONNECTIONS	SPECIMENS IN WHICH THE TYPES OF SULCAL CONNECTIONS WERE OBSERVED	
	RIGHT HEMISPHERE	LEFT HEMISPHERE
1	4, 7, 15, 16, 17, 20, 28, 29, 91, 100	3, 4, 6, 29, 30, 87, 88, 93, 94 96, 98
2	10, 93, 97	24, 97
3	1, 2, 3, 5, 6, 8, 9, 11, 12, 13 14, 19, 21, 22, 23, 24, 25, 2 27, 30, 87, 88, 89, 90, 92, 9 95, 96, 98, 99	1, 2, 5, 7, 8, 9, 10, 11, 12, 13 14, 15, 16, 17, 18, 19, 20, 21 22, 23, 25, 26, 27, 28, 31, 89 90, 91, 92, 95, 99, 100
4	18	0

Table C.2: Summary of the specimens in which the Patterns of the Anterior Rami were observed in the case category

TYPES OF SULCAL CONNECTIONS	SPECIMENS IN WHICH THE TYPES OF SULCAL CONNECTIONS WERE OBSERVED	
	RIGHT HEMISPHERE	LEFT HEMISPHERE
'Y'	3, 5, 7, 11, 21, 89, 90, 92, 94, 98, 99	2, 3, 6, 7, 8, 14, 15, 16, 17, 20, 21, 24, 25, 27, 90, 91, 93, 95, 98, 100
'V-U' + INTERMEDIATES	1, 2, 4, 6, 8, 9, 10, 12, 13, 14, 15, 16, 17, 19, 20, 22, 23, 24, 25, 26, 27, 28, 29, 30, 31, 87, 88, 91, 93, 95, 96, 97, 100	1, 4, 5, 9, 10, 11, 12, 13, 18, 19, 22, 23, 26, 28, 29, 31, 87, 88, 89, 92, 94, 96, 97, 99
'I'	18	30

C.4.2 FOR THE WHOLE BRAINS (CONTROL):

Table C.3: Summary of the specimens in which the Types of Sulcal Connections were observed in the control category

TYPES OF SULCAL CONNECTIONS	SPECIMENS IN WHICH THE TYPES OF SULCAL CONNECTIONS WERE OBSERVED	
	RIGHT HEMISPHERE	LEFT HEMISPHERE
1	33, 40, 42, 44, 45, 49, 58, 60, 62, 65, 66, 69, 72, 74, 78, 82, 83, 86, 104, 106, 110	32, 37, 42, 45, 47, 51, 52, 54, 55, 58, 59, 62, 65, 67, 68, 70, 71, 72, 73, 74, 75, 76, 77, 78,80, 84, 85, 103, 104, 106, 109
2	79, 84, 101, 107	0
3	32, 34, 35, 36, 37, 38, 39, 41, 43, 46, 47, 48, 50, 51, 52, 53, 54, 55, 56, 57, 59, 61, 64, 67, 68, 70, 71, 73, 75, 76, 77, 80, 81, 85, 102, 103, 105, 108, 109	33,34,35,36,38,39,40,41, 43,44,46,48,49,50,53,56, 57,60,61,63,64,66,69,79, 81,82,83,86,101,102,105, 107,108
4	63	110

Table C.4: Summary of the specimens in which the Patterns of the Anterior Rami were observed in the control category

TYPES OF SULCAL CONNECTIONS	SPECIMENS IN WHICH THE TYPES OF SULCAL CONNECTIONS WERE OBSERVED	
	RIGHT HEMISPHERE	LEFT HEMISPHERE
'Y'	34, 35, 36, 37, 38, 39, 43, 44, 46, 47, 49, 50, 51, 54, 57, 66, 67, 68, 73, 77, 101, 105, 107, 109	32, 35, 37, 38, 41, 44, 45, 46, 47, 49, 52, 53, 55, 57, 60, 64, 65, 66, 67, 71, 79, 83, 101,105, 106
'V-U' + INTERMEDIATES	32, 33, 40, 41, 42, 45, 48, 52, 53, 55, 56, 58, 59, 60, 61, 62, 64, 65, 69,70, 71, 72, 74, 75, 76, 78, 79, 80, 81, 82, 83, 84, 85, 86, 102, 103, 104, 106, 108, 110	33, 34, 36, 39, 40, 42, 43, 48, 50, 51, 54, 56, 58, 59, 61, 62, 63, 68, 69, 70, 72, 73, 74, 75, 76, 77, 78, 80, 81, 82, 84, 85, 86, 102, 103, 104, 107, 108, 109
'I'	63	110

APPENDIX D

RECORD OF WHICH SPECIMENS WERE USED FOR THE QUANTITATIVE STUDY

D.1 CONTROL CATEGORY (WHOLE BRAIN SPECIMENS)

Table D.1: Specimens falling into the category of control

NUMBER (n)	SPECIMEN NUMBER IN RIGHT- AND LEFT-HEMIPHERES	NUMBER (n)	SPECIMEN NUMBER IN RIGHT- AND LEFT-HEMIPHERES	NUMBER (n)	SPECIMEN NUMBER IN RIGHT- AND LEFT-HEMIPHERES
1	32	**21**	**54**	**41**	**101**
2	33	**22**	**57**		
3	35	**23**	**58**		
4	36	**24**	**59**		
5	37	**25**	**60**		
6	38	**26**	**61**		
7	39	**27**	**62**		
8	40	**28**	**65**		
9	41	**29**	**66**		
10	42	**30**	**67**		
11	43	**31**	**69**		
12	44	**32**	**72**		
13	45	**33**	**73**		
14	46	**34**	**75**		
15	47	**35**	**76**		
16	48	**36**	**77**		
17	49	**37**	78		
18	50	**38**	81		
19	52	**39**	83		
20	53	**40**	85		

D.2 CASE (SEPARATE HEMISPHERES)

Table D.2: Specimens falling into the category of case

NUMBER (n)	SPECIMEN NUMBER (sn) IN RIGHT HEMISPHERE	SPECIMEN NUMBER (sn) IN LEFT HEMISPHERE	NUMBER (n)	SPECIMEN NUMBER (sn) IN RIGHT HEMISPHERE	SPECIMEN NUMBER (sn) IN LEFT HEMISPHERE
1	1	2	**22**	23	28
2	3	3	**23**	24	29
3	4	5	**24**	25	30
4	5	6	**25**	26	87
5	6	7	**26**	28	88
6	7	8	**27**	30	
7	8	9	**28**	31	
8	9	10			
9	10	11			
10	11	12			
11	12	13			
12	13	14			
13	14	15			
14	15	16			
15	16	18			
16	17	19			
17	18	21			
18	19	22			
19	20	23			
20	21	26			
21	22	27			

Note that the abbreviation for specimen number is: sn

APPENDIX E

E.1 LENGTHS OF INDIVIDUAL MAJOR SULCI WITH RESPECT TO UNGROUPED DATA

Table E.1: **First recording of the Lengths of the Individual Major Sulci (see Fig 1.7, pg 15) of the frontal operculum, with respect to Ungrouped Data for the control group.**

[Abbreviations: sn (specimen number); x_1 (stem of the anterior rami); x_2 (anterior ascending ramus); x_3 (anterior horizontal ramus); and control (whole brain specimens)].

	RIGHT HEMISPHERE (centimetre)				**LEFT HEMISPHERE** (centimetre)			
	sn	**x_1**	**x_2**	**x_3**	**x_1**	**x_2**	**x_3**	**sn**
1	**32**	-	2.15	1.0	0.4	1.5	2.1	**32**
2	**35**	1.6	0.7	0.65	0.9	1.8	0.8	**35**
3	**36**	0.6	0.65	1.0	-	3.2	1.0	**36**
4	**37**	0.5	1.85	1.65	0.65	1.1	1.6	**37**
5	**38**	1.1	0.8	0.8	0.9	1.0	0.8	**38**
6	**39**	0.7	1.7	1.85	-	2.25	1.5	**39**
7	**40**	-	0.75	2.4	-	1.4	1.7	**40**
8	**41**	-	1.4	1.2	0.55	1.2	1.5	**41**
9	**42**	-	2.25	2.05	-	2.75	2.4	**42**
10	**43**	1.15	0.65	0.4	-	1.1	1.6	**43**
11	**44**	0.7	0.3	1.1	0.35	2.2	1.25	**44**
12	**45**	-	2.0	1.25	1.45	0.3	0.7	**45**
13	**46**	1.1	0.7	0.75	0.7	0.6	1.6	**46**
14	**47**	0.5	1.0	1.15	1.0	0.85	1.6	**47**
15	**48**	-	1.35	1.85	-	0.6	2.45	**48**
16	**49**	0.4	2.4	1.6	0.6	1.3	1.15	**49**
17	**50**	1.6	0.4	0.6	-	2.0	2.05	**50**
18	**52**	-	2.25	1.4	0.95	0.95	2.15	**52**
19	**53**	-	2.65	1.2	0.9	2.5	1.3	**53**
20	**54**	0.25	1.6	2.0	-	2.1	1.95	**54**
21	**57**	0.45	2.55	1.1	0.85	0.55	1.0	**57**
22	**58**	-	0.6	1.15	-	1.8	2.25	**58**
23	**59**	-	1.75	1.8	-	1.05	1.9	**59**
24	**60**	-	1.6	1.75	0.3	0.5	0.85	**60**
25	**61**	-	1.15	0.95	-	0.85	1.2	**61**
26	**62**	-	1.95	2.5	-	2.2	2.2	**62**

Table E.1 continues on next page.

Table E.1 continued

	RIGHT HEMISPHERE (centimetre)				**LEFT HEMISPHERE** (centimetre)			
	sn	**x_1**	**x_2**	**x_3**	**x_1**	**x_2**	**x_3**	**sn**
27	**65**	-	1.95	0.6	0.5	0.4	1.8	**65**
28	**66**	0.4	1.8	1.9	0.45	1.9	1.4	**66**
29	**67**	0.9	1.05	1.4	0.6	1.8	1.15	**67**
30	**69**	-	1.6	1.5	-	2.7	1.9	**69**
31	**72**	-	1.8	1.2	-	2.3	1.4	**72**
32	**73**	1.0	0.8	1.05	-	1.7	0.4	**73**
33	**75**	-	1.65	1.65	-	2.3	1.3	**75**
34	**76**	-	0.95	0.5	-	1.95	1.3	**76**
35	**77**	0.6	0.75	1.05	-	1.45	1.25	**77**
36	**78**	-	2.15	1.75	-	1.9	2.1	**78**
37	**81**	-	1.2	0.75	-	1.2	1.0	**81**
38	**83**	-	1.25	1.6	0.6	0.5	1.1	**83**
39	**85**	-	1.95	0.9	-	1.15	2.1	**85**
40	**101**	0.7	0.8	2.0	0.8	1.4	0.5	**101**

Table E.2: Second recording of the Lengths of the Individual Major Sulci (see Fig 1.7, pg 15) of the frontal operculum, with respect to Ungrouped Data for the control group.
[Abbreviations: sn (specimen number); x_1 (stem of the anterior rami); x_2 (anterior ascending ramus); x_3 (anterior horizontal ramus); and control (whole brain specimens)].

	RIGHT HEMISPHERE (centimetre)				**LEFT HEMISPHERE** (centimetre)			
	sn	**x_1**	**x_2**	**x_3**	**x_1**	**x_2**	**x_3**	**sn**
1	**32**	-	2.3	1.0	0.5	1.5	2.2	**32**
2	**35**	1.6	0.7	0.7	0.8	2.05	0.5	**35**
3	**36**	0.7	0.75	1.05	-	3.3	0.9	**36**
4	**37**	0.45	1.75	1.7	0.7	1.0	1.5	**37**
5	**38**	1.0	0.95	0.95	0.9	0.9	0.65	**38**
6	**39**	0.7	1.8	1.9	-	2.1	1.55	**39**
7	**40**	-	0.8	2.2	-	1.5	1.7	**40**
8	**41**	-	1.5	1.05	0.5	1.2	1.5	**41**
9	**42**	-	2.2	2.05	-	2.8	2.25	**42**
10	**43**	1.25	0.8	0.4	-	1.0	1.7	**43**
11	**44**	0.65	0.3	1.1	0.4	2.25	1.3	**44**

Table E.2 continues on next page

Table E.2 continued.

	RIGHT HEMISPHERE (centimetre)				**LEFT HEMISPHERE** (centimetre)			
	sn	**x_1**	**x_2**	**x_3**	**x_1**	**x_2**	**x_3**	**sn**
12	**45**	-	2.0	1.35	1.55	0.3	0.7	**45**
13	**46**	1.15	0.8	0.7	0.6	0.7	1.7	**46**
14	**47**	0.5	1.0	1.3	0.9	0.8	1.6	**47**
15	**48**	-	1.4	1.9	-	0.6	2.3	**48**
16	**49**	0.5	2.5	1.75	0.6	1.3	1.1	**49**
17	**50**	1.6	0.5	0.7	-	1.95	2.0	**50**
18	**52**	-	2.2	1.4	0.9	0.9	2.2	**52**
19	**53**	-	2.7	1.05	0.9	2.5	1.25	**53**
20	**54**	0.35	1.6	1.9	-	2.1	2.0	**54**
21	**57**	0.35	2.6	1.0	0.9	0.6	1.05	**57**
22	**58**	-	0.6	1.1	-	1.8	2.1	**58**
23	**59**	-	1.7	1.9	-	1.0	1.7	**59**
24	**60**	-	1.6	1.7	0.4	0.6	0.8	**60**
25	**61**	-	1.25	0.9	-	0.8	1.2	**61**
26	**62**	-	1.8	2.6	-	2.2	2.1	**62**
27	**65**	-	1.75	0.7	0.45	0.4	1.75	**65**
28	**66**	0.5	1.9	1.75	0.5	1.8	1.4	**66**
29	**67**	0.85	1.15	1.3	0.5	1.7	1.2	**67**
30	**69**	-	1.5	1.4	-	2.8	2.1	**69**
31	**72**	-	1.8	1.1	-	2.25	1.3	**72**
32	**73**	0.9	0.85	1.0	-	1.5	0.5	**73**
33	**75**	-	1.7	1.7	-	2.3	1.2	**75**
34	**76**	-	0.8	0.5	-	2.0	**1.3**	**76**
35	**77**	0.6	0.7	0.95	-	1.4	**1.15**	**77**
36	**78**	-	2.05	1.85	-	1.8	**2.2**	**78**
37	**81**	-	1.3	0.8	-	1.2	**1.0**	**81**
38	**83**	-	1.2	1.75	0.5	0.65	**1.0**	**83**
39	**85**	-	2.0	0.9	-	1.0	**2.0**	**85**
40	**101**	0.7	0.85	2.0	0.8	1.4	**0.55**	**101**

Table E.3: Composite recording of the Lengths of the Individual Major Sulci (see Fig 1.7, pg 15) of the frontal operculum, with respect to Ungrouped Data for the control group.
[Abbreviations: sn (specimen number); x_1 (stem of the anterior rami); x_2 (anterior ascending ramus); x_3 (anterior horizontal ramus); and control (to whole brain specimens)].

	RIGHT HEMISPHERE (centimetre)				**LEFT HEMISPHERE** (centimetre)			
	sn	**x_1**	**x_2**	**x_3**	**x_1**	**x_2**	**x_3**	**sn**
1	**32**	-	2.23	1.0	0.45	1.5	2.15	**32**
2	**35**	1.6	0.7	0.68	0.85	1.93	0.65	**35**
3	**36**	0.65	0.7	1.03	-	3.25	0.95	**36**
4	**37**	0.48	1.8	1.68	0.68	1.05	1.55	**37**
5	**38**	1.05	0.88	0.88	0.9	0.95	0.73	**38**
6	**39**	0.7	1.75	1.88	-	2.13	1.53	**39**
7	**40**	-	0.78	2.3	-	1.45	1.7	**40**
8	**41**	-	1.45	1.13	0.53	1.2	1.5	**41**
9	**42**	-	2.23	2.05	-	2.78	2.33	**42**
10	**43**	1.2	0.73	0.4	-	1.05	1.65	**43**
11	**44**	0.68	0.3	1.1	0.38	2.23	1.28	**44**
12	**45**	-	2.0	1.3	1.4	0.3	0.7	**45**
13	**46**	1.13	0.75	0.73	0.65	0.65	1.65	**46**
14	**47**	0.5	1.0	1.23	0.95	0.83	1.6	**47**
15	**48**	-	1.38	1.88	-	0.6	2.38	**48**
16	**49**	0.45	2.45	1.68	0.6	1.3	1.13	**49**
17	**50**	1.6	0.45	0.65	-	1.98	2.03	**50**
18	**52**	-	2.23	1.4	0.93	0.93	2.18	**52**
19	**53**	-	2.68	1.13	0.9	2.5	1.28	**53**
20	**54**	0.3	1.6	1.95	-	2.1	1.98	**54**
21	**57**	0.4	2.58	1.05	0.88	0.58	1.03	**57**
22	**58**	-	0.6	1.13	-	1.8	2.13	**58**
23	**59**	-	1.73	1.85	-	1.03	1.8	**59**
24	**60**	-	1.6	1.73	0.35	0.55	0.83	**60**
25	**61**	-	1.2	0.93	-	0.83	1.2	**61**
26	**62**	-	1.88	2.55	-	2.2	2.15	**62**
27	**65**	-	1.85	0.65	0.48	0.4	1.78	**65**
28	**66**	0.45	1.85	1.83	0.48	1.85	1.4	**66**
29	**67**	0.88	1.1	1.35	0.55	1.75	1.18	**67**
30	**69**	-	1.55	1.45	-	2.75	2.0	**69**
31	**72**	-	1.8	1.88	-	2.28	1.35	**72**
32	**73**	0.95	0.83	1.03	-	1.6	0.45	**73**
33	**75**	-	1.68	1.68	-	2.3	1.25	**75**

Table E.3 continues on next page

Table E.3 continued.

	RIGHT HEMISPHERE (centimetre)				**LEFT HEMISPHERE** (centimetre)			
	sn	**x_1**	**x_2**	**x_3**	**x_1**	**x_2**	**x_3**	**sn**
34	**76**	-	0.88	0.5	-	1.98	1.3	**76**
35	**77**	0.6	0.73	1.0	-	1.43	1.2	**77**
36	**78**	-	2.1	1.8	-	1.85	2.15	**78**
37	**81**	-	1.25	0.78	-	1.2	1.0	**81**
38	**83**	-	1.23	1.68	0.55	0.58	1.05	**83**
39	**85**	-	1.98	0.9	-	1.08	2.05	**85**
40	**101**	0.7	0.83	2.0	0.8	1.4	0.53	**101**

Table E.4: First recording of the Lengths of the Individual Major Sulci (see Fig 1.7, pg 15) of the frontal operculum, with respect to Ungrouped Data for the case group.
[Abbreviations: sn (specimen number); x_1 (stem of the anterior rami); x_2 (anterior ascending ramus); x_3 (anterior horizontal ramus); and case (separate hemispheres)].

	RIGHT HEMISPHERE (centimetre)				**LEFT HEMISPHERE** (centimetre)			
	sn	**x_1**	**x_2**	**x_3**	**x_1**	**x_2**	**x_3**	**sn**
1	**1**	-	n_o	1.6	0.4	2.1	2.55	**2**
2	**3**	0.7	1.4	2.6	1.9	0.7	1.2	**3**
3	**4**	-	1.9	n_o	-	1.6	1.05	**5**
4	**5**	0.4	1.1	1.95	0.8	0.7	1.65	**6**
5	**6**	-	1.65	1.2	0.8	0.9	2.35	**7**
6	**7**	0.7	1.3	1.4	0.7	1.55	0.4	**8**
7	**8**	-	1.65	1.5	-	1.7	1.25	**9**
8	**9**	-	2.1	1.55	-	1.5	0.85	**10**
9	**10**	-	1.3	1.8	-	2.75	n_o	**11**
10	**11**	0.75	1.6	1.5	-	2.3	1.5	**12**
11	**12**	-	1.05	1.55	-	2.15	1.0	**13**
12	**13**	-	1.1	3.1	0.3	1.9	1.4	**14**
13	**14**	-	1.7	1.8	1.1	1.15	2.35	**15**
14	**15**	-	2.2	2.4	0.3	0.85	1.3	**16**
15	**16**	-	2.75	1.4	-	1.7	0.7	**18**
16	**17**	-	2.35	1.65	-	2.5	n_o	**19**
17	**18**	-	0	3.0	0.45	1.1	1.8	**21**
18	**19**	-	2.4	1.2	-	2.1	2.45	**22**
19	**20**	-	2.75	2.8	-	1.95	n_o	**23**

Table E.4 continues on next page

Table E.4 continued.

	RIGHT HEMISPHERE (centimetre)				**LEFT HEMISPHERE** (centimetre)			
	sn	**x_1**	**x_2**	**x_3**	**x_1**	**x_2**	**x_3**	**sn**
20	**21**	0.4	0.5	1.9	-	2.35	1.8	**26**
21	**22**	-	2.4	1.9	0.3	1.45	2.0	**27**
22	**23**	-	2.2	1.25	-	2.2	1.45	**28**
23	**24**	-	1.75	1.1	-	1.25	2.3	**29**
24	**25**	-	1.75	1.2	-	3.25	0	**30**
25	**26**	-	1.85	1.25	-	1.7	3.0	**87**
26	**28**	-	2.55	0.9	-	2.25	2.55	**88**
27	**30**	-	1.55	1.4				
28	**31**	-	1.2	1.4				

Table E.5: Second recording of the Lengths of Individual Major Sulci (see Fig 1.7, pg 15) of the frontal operculum, with respect to Ungrouped Data for the case group.

[Abbreviations: sn (specimen number); x_1 (stem of the anterior rami); x_2 (anterior ascending ramus); x_3 (anterior horizontal ramus); and case (separate hemispheres)].

	RIGHT HEMISPHERE (centimetre)				**LEFT HEMISPHERE** (centimetre)			
	sn	**x_1**	**x_2**	**x_3**	**x_1**	**x_2**	**x_3**	**sn**
1	**1**	-	n_o	1.5	0.35	2.25	2.4	**2**
2	**3**	0.55	1.55	2.65	1.8	0.7	1.2	**3**
3	**4**	-	1.95	n_o	-	1.6	1.0	**5**
4	**5**	0.35	1.25	2.05	0.8	0.6	1.8	**6**
5	**6**	-	1.55	1.05	0.9	0.9	2.4	**7**
6	**7**	0.8	1.25	1.3	0.65	1.5	0.4	**8**
7	**8**	-	1.5	1.45	-	1.6	1.15	**9**
8	**9**	-	2.1	1.45	-	1.5	0.95	**10**
9	**10**	-	1.25	1.85	-	2.85	n_o	**11**
10	**11**	0.6	1.7	1.4	-	2.3	1.6	**12**
11	**12**	-	1.1	1.6	-	2.3	1.1	**13**
12	**13**	-	1.1	3.1	0.4	1.95	1.55	**14**
13	**14**	-	1.75	1.7	1.2	1.1	2.4	**15**
14	**15**	-	2.1	2.2	0.35	0.7	1.3	**16**
15	**16**	-	2.75	1.45	-	1.7	0.8	**18**

Table E.5 continues on next page

Table E.5 continued

	RIGHT HEMISPHERE (centimetre)				**LEFT HEMISPHERE** (centimetre)			
	sn	**x_1**	**x_2**	**x_3**	**x_1**	**x_2**	**x_3**	**sn**
16	**17**	-	2.15	1.85	-	2.5	n_o	**19**
17	**18**	-	0	2.9	0.5	1.1	1.7	**21**
18	**19**	-	2.25	1.2	-	2.0	2.6	**22**
19	**20**	-	2.8	2.6	-	1.85	n_o	**23**
20	**21**	0.3	0.4	1.95	-	2.4	1.85	**26**
21	**22**	-	2.4	1.9	0.3	1.5	1.8	**27**
22	**23**	-	2.15	1.35	-	2.3	1.4	**28**
23	**24**	-	1.8	1.0	-	1.1	2.0	**29**
24	**25**	-	1.6	1.15	-	3.35	0	**30**
25	**26**	-	1.95	1.35	-	1.85	3.15	**87**
26	**28**	-	2.6	0.8	-	2.35	2.6	**88**
27	**30**	-	1.5	1.35				
28	**31**	-	1.2	1.4				

Table E.6: Composite recording of the Lengths of the Individual Major Sulci (see Fig 1.7 pg 15) of the frontal operculum, with respect to Ungrouped Data for the case group.

[Abbreviations: sn (specimen number); x_1 (stem of the anterior rami); x_2 (anterior ascending ramus); x_3 (anterior horizontal ramus); and case (separate hemispheres)].

	RIGHT HEMISPHERE (centimetre)				**LEFT HEMISPHERE** (centimetre)			
	sn	**x_1**	**x_2**	**x_3**	**x_1**	**x_2**	**x_3**	**sn**
1	**1**	-	n_o	1.55	0.38	2.18	2.48	**2**
2	**3**	0.63	1.46	2.63	1.85	0.7	1.2	**3**
3	**4**	-	1.93	n_o	-	1.6	1.03	**5**
4	**5**	0.38	1.18	2.0	0.8	0.65	1.73	**6**
5	**6**	-	1.6	1.13	0.85	0.9	2.38	**7**
6	**7**	0.75	1.28	1.35	0.68	1.53	0.4	**8**
7	**8**	-	1.58	1.48	-	1.65	1.2	**9**
8	**9**	-	2.1	1.5	-	1.5	0.9	**10**
9	**10**	-	1.28	1.83	-	2.8	n_o	**11**
10	**11**	0.68	1.65	1.45	-	2.3	1.55	**12**
11	**12**	-	1.08	1.58	-	2.23	1.05	**13**

Table E.6 continues on next page

Table E.6 continued

	RIGHT HEMISPHERE (centimetre)				**LEFT HEMISPHERE** (centimetre)			
	sn	**x_1**	**x_2**	**x_3**	**x_1**	**x_2**	**x_3**	**sn**
12	**13**	-	1.1	3.1	0.35	1.93	1.48	**14**
13	**14**	-	1.73	1.75	1.15	1.13	2.38	**15**
14	**15**	-	2.15	2.3	0.33	0.78	1.3	**16**
15	**16**	-	2.75	1.43	-	1.7	0.75	**18**
16	**17**	-	2.25	1.75	-	2.5	n_o	**19**
17	**18**	-	0	2.95	0.48	1.1	1.75	**21**
18	**19**	-	2.35	1.2	-	2.05	2.53	**22**
19	**20**	-	2.78	2.7	-	1.9	n_o	**23**
20	**21**	0.35	0.45	1.93	-	2.38	1.83	**26**
21	**22**	-	2.4	1.9	0.3	1.48	1.9	**27**
22	**23**	-	2.13	1.3	-	2.25	1.43	**28**
23	**24**	-	1.78	1.05	-	1.18	2.15	**29**
24	**25**	-	1.68	1.18	-	3.3	0	**30**
25	**26**	-	1.8	1.3	-	1.78	3.08	**87**
26	**28**	-	2.58	0.85	-	2.3	2.58	**88**
27	**30**	-	1.53	1.38				
28	**31**	-	1.2	1.4				

E.2 LENGTHS OF INDIVIDUAL ACCESSORY (OPERCULAR) SULCI WITH RESPECT TO UNGROUPED DATA

Table E.7: First recording of the Lengths of Individual Opercular sulci (see Fig 1.12, pg 43), of the frontal operculum, with respect to Ungrouped Data for the control group.

[Abbreviations: sn (specimen number); Ope (sole opercular sulcus); Ope_1 (First opercular sulcus); Ope_2 (Second opercular sulcus)].

	RIGHT HEMISPHERE (centimetre)				**LEFT HEMISPHERE** (centimetre)			
	sn	**Ope**	**Ope_1**	**Ope_2**	**Ope**	**Ope_1**	**Ope_2**	**sn**
1	**32**	-	1.55	0.7	-	-	-	**32**
2	**35**	-	1.0	1.2	2.35	-	-	**35**
3	**36**	n_o	-	-	0.6	-	-	**36**
4	**37**	n_o	-	-	-	-	-	**37**
5	**38**	d	d	-	-	1.7	0.7	**38**
6	**39**	2.25	-	-	-	0.55	1.0	**39**
7	**40**	-	-	-	-	0.9	0.8	**40**
8	**41**	-	2.0	1.95	2.3	-	-	**41**
9	**42**	-	-	-	-	-	-	**42**
10	**43**	2.2	-	-	1.65	-	-	**43**
11	**44**	-	-	-	1.95	-	-	**44**
12	**45**	-	-	-	-	-	-	**45**
13	**46**	2.7	-	-	0.9	-	-	**46**
14	**47**	d	-	-	-	-	-	**47**
15	**48**	2.7	-	-	2.6	-	-	**48**
16	**49**	-	-	-	n_o	-	-	**49**
17	**50**	1.85	-	-	1.15	-	-	**50**
18	**52**	1.95	-	-	-	-	-	**52**
19	**53**	0.5	-	-	1.75	-	-	**53**
20	**54**	0.7	-	-	-	-	-	**54**
21	**57**	-	0.85	1.4	3.4	-	-	**57**
22	**58**	-	-	-	-	-	-	**58**
23	**59**	-	1.9	0.75	-	-	-	**59**
24	**60**	-	-	-	2.8	-	-	**60**
25	**61**	1.0	-	-	2.05	-	-	**61**

Table E.7 continues on next page

Table E.7 continued.

	RIGHT HEMISPHERE (centimetre)				**LEFT HEMISPHERE (centimetre)**			
	sn	**Ope**	**Ope$_1$**	**Ope$_2$**	**Ope**	**Ope$_1$**	**Ope$_2$**	**sn**
26	**62**	-	-	-	-	-	-	**62**
27	**65**	-	-	-	-	-	-	**65**
28	**66**	-	-	-	1.9	-	-	**66**
29	**67**	2.5	-	-	-	-	-	**67**
30	**69**	-	-	-	0.3	-	-	**69**
31	**72**	-	-	-	-	-	-	**72**
32	**73**	1.95	-	-	-	-	-	**73**
33	**75**	1.6	-	-	-	-	-	**75**
34	**76**	1.8	-	-	-	-	-	**76**
35	**77**	-	1.15	1.25	-	-	-	**77**
36	**78**	-	-	-	-	-	-	**78**
37	**81**	-	0.75	d	-	1.3	0.5	**81**
38	**83**	-	-	-	2.5	-	-	**83**
39	**85**	3.25	-	-	-	-	-	**85**
40	**101**	-	-	-	1.65	-	-	**101**

Table E.8: Second recording of the Lengths of Individual Opercular sulci (see Fig 1.12, pg 43), of the frontal operculum, with respect to Ungrouped Data for the control group.

Abbreviations: sn (specimen number); Ope (sole opercular sulcus); Ope$_1$ (First opercular sulcus); Ope$_2$ (Second opercular sulcus)].

	RIGHT HEMISPHERE (centimetre)				**LEFT HEMISPHERE** (centimetre)			
	sn	**Ope**	**Ope$_1$**	**Ope$_2$**	**Ope**	**Ope$_1$**	**Ope$_2$**	**sn**
1	**32**	-	1.45	0.8	-	-	-	**32**
2	**35**	-	0.8	1.3	2.2	-	-	**35**
3	**36**	n_o	-	-	0.65	-	-	**36**
4	**37**	n_o	-	-	-	-	-	**37**
5	**38**	d	d	-	-	1.8	0.65	**38**
6	**39**	2.15	-	-	-	0.55	1.0	**39**
7	**40**	-	-	-	-	0.85	0.8	**40**
8	**41**	-	2.1	1.95	2.4	-	-	**41**
9	**42**	-	-	-	-	-	-	**42**
10	**43**	2.1	-	-	1.75	-	-	**43**

Table E.8 continues on next page

Table E.8 continued.

	RIGHT HEMISPHERE (centimetre)				**LEFT HEMISPHERE** (centimetre)			
	sn	**Ope**	**Ope$_1$**	**Ope$_2$**	**Ope**	**Ope$_1$**	**Ope$_2$**	**sn**
11	**44**	-	-	-	2.0	-	-	**44**
12	**45**	-	-	-	0.6	-	-	**45**
13	**46**	2.7	-	-	1.05	-	-	**46**
14	**47**	d	-	-	-	-	-	**47**
15	**48**	2.7	-	-	2.5	-	-	**48**
16	**49**	-	-	-	n_o	-	-	**49**
17	**50**	1.8	-	-	1.25	-	-	**50**
18	**52**	1.95	-	-	-	-	-	**52**
19	**53**	0.55	-	-	1.8	-	-	**53**
20	**54**	0.6	-	-	-	-	-	**54**
21	**57**	-	0.8	1.45	3.1	-	-	**57**
22	**58**	-	-	-	-	-	-	**58**
23	**59**	-	1.75	0.8	-	-	-	**59**
24	**60**	-	-	-	2.8	-	-	**60**
25	**61**	0.9	-	-	1.9	-	-	**61**
26	**62**	-	-	-	-	-	-	**62**
27	**65**	-	-	-	-	-	-	**65**
28	**66**	-	-	-	1.9	-	-	**66**
29	**67**	2.35	-	-	-	-	-	**67**
30	**69**	-	-	-	0.3	-	-	**69**
31	**72**	-	-	-	-	-	-	**72**
32	**73**	1.9	-	-	1.1	-	-	**73**
33	**75**	1.7	-	-	-	-	-	**75**
34	**76**	1.9	-	-	-	-	-	**76**
35	**77**	-	1.0	1.35	-	-	-	**77**
36	**78**	-	-	-	-	-	-	**78**
37	**81**	-	0.85	d	-	1.2	0.5	**81**
38	**83**	-	-	-	2.3	-	-	**83**
39	**85**	3.4	-	-	-	-	-	**85**
40	**101**	-	-	-	1.7	-	-	**101**

Table E.9: Composite recording of the Lengths of Individual Opercular sulci (see Fig 1.12, pg 43), of the frontal operculum, with respect to Ungrouped Data for the control group.

[Abbreviations: sn (specimen number); Ope (sole opercular sulcus); Ope_1 (First opercular sulcus); Ope_2 (Second opercular sulcus)].

	RIGHT HEMISPHERE (centimetre)				**LEFT HEMISPHERE** (centimetre)			
	sn	**Ope**	**Ope_1**	**Ope_2**	**Ope**	**Ope_1**	**Ope_2**	**sn**
1	**32**	-	1.5	0.75	-	-	-	**32**
2	**35**	-	0.9	1.25	2.28	-	-	**35**
3	**36**	n_o	-	-	0.63			**36**
4	**37**	n_o	-	-	-	-	-	**37**
5	**38**	d	d	d	-	1.7	0.68	**38**
6	**39**	2.2	-	-	-	0.55	1.0	**39**
7	**40**	-	-	-	-	0.9	0.8	**40**
8	**41**	-	2.05	1.95	2.35	-	-	**41**
9	**42**	-	-	-	-	-	-	**42**
10	**43**	2.2	-	-	1.7	-	-	**43**
11	**44**	-	-	-	1.98	-	-	**44**
12	**45**	-	-	-	-	-	-	**45**
13	**46**	2.7	-	-	0.98	-	-	**46**
14	**47**	d	d	d	-	-	-	**47**
15	**48**	2.7	-	-	2.55	-	-	**48**
16	**49**	-	-	-	n_o	-	-	**49**
17	**50**	1.83	-	-	1.0	-	-	**50**
18	**52**	1.95	-	-	-	-	-	**52**
19	**53**	0.53	-	-	1.78	-	-	**53**
20	**54**	0.65	-	-	-	-	-	**54**
21	**57**	-	0.83	1.43	3.25	-	-	**57**
22	**58**	-	-	-	-	-	-	**58**
23	**59**	-	1.83	0.78	-	-	-	**59**
24	**60**	-	-	-	2.8	-	-	**60**
25	**61**	0.95	-	-	1.98	-	-	**61**
26	**62**	-	-	-	-	-	-	**62**
27	**65**	-	-	-	-	-	-	**65**
28	**66**	-	-	-	1.9	-	-	**66**
29	**67**	2.43	-	-	-	-	-	**67**
30	**69**	-	-	-	0.3	-	-	**69**
31	**72**	-	-	-	-	-	-	**72**
32	**73**	1.93	-	-	-	-	-	**73**
33	**75**	1.75	-	-	-	-	-	**75**
34	**76**	1.85	-	-	-	-	-	**76**

Table E.9 continues on next page

Table E.9 continued.

	RIGHT HEMISPHERE (centimetre)				**LEFT HEMISPHERE** (centimetre)			
	sn	**Ope**	**Ope$_1$**	**Ope$_2$**	**Ope**	**Ope$_1$**	**Ope$_2$**	**sn**
35	**77**	-	1.08	1.30	-	-	-	**77**
36	**78**	-	-	-	-	-	-	**78**
37	**81**	-	0.8	d	-	1.25	0.5	**81**
38	**83**	-	-	-	2.4	-	-	**83**
39	**85**	3.33	-	-	-	-	-	**85**
40	**101**	-	-	-	1.68	-	-	**101**

Table E.10: First recording of the Lengths of Individual Opercular sulci (see Fig 1.12, pg 43), of the frontal operculum, with respect to Ungrouped Data for the case group.
[Abbreviations: sn (specimen number); Ope (sole opercular sulcus); Ope$_1$ (First opercular sulcus); Ope$_2$ (Second opercular sulcus)].

	RIGHT HEMISPHERE (centimetre)				**LEFT HEMISPHERE** (centimetre)			
	sn	**Ope**	**Ope$_1$**	**Ope$_2$**	**Ope**	**Ope$_1$**	**Ope$_2$**	**sn**
1	**1**	2.5	-	-	-	0.8	0.6	**2**
2	**3**	-	-	-	-	-	-	**3**
3	**4**	-	-	-	2.4	-	-	**5**
4	**5**	-	1.4	d	-	-	-	**6**
5	**6**	-	0.4	n_o	1.55	-	-	**7**
6	**7**	-	-	-	-	0.5	0.6	**8**
7	**8**	-	0.5	0.4	-	1.45	1.55	**9**
8	**9**	0.75	-	-	0.9	-	-	**10**
9	**10**	-	-	-	1.0	-	-	**11**
10	**11**	1.6	-	-	0.8	-	-	**12**
11	**12**	2.4	-	-	0.7	-	-	**13**
12	**13**	-	1.3	1.85	1.35	-	-	**14**
13	**14**	-	0.5	2.7	-	1.9	0.8	**15**
14	**15**	-	-	-	-	1.0	1.7	**16**
15	**16**	-	-	-	2.2	-	-	**18**
16	**17**	-	-	-	-	2.8	1.1	**19**
17	**18**	d	d	d	-	0.95	0.75	**21**
18	**19**	-	0.7	3.4	n_o	-	-	**22**
19	**20**	-	-	-	0.45	-	-	**23**
20	**21**	2.25	-	-	-	2.1	1.4	**26**
21	**22**	0.65	-	-	1.8	-	-	**27**

Table E.10 continues on next page

Table E.10 continued.

	RIGHT HEMISPHERE (centimetre)				**LEFT HEMISPHERE (centimetre)**			
	sn	**Ope**	**Ope$_1$**	**Ope$_2$**	**Ope**	**Ope$_1$**	**Ope$_2$**	**sn**
22	**23**	-	1.35	2.1	0.8	-	-	**28**
23	**24**	0.85	-	-	-	-	-	**29**
24	**25**	-	0.7	3.55	-	-	-	**30**
25	**26**	3.45	-	-	-	-	-	**87**
26	**28**	-	-	-	-	-	-	**88**
27	**30**	1.45	-	-				
28	**31**	-	-	-				

Table E.11: Second recording of the Lengths of Individual Opercular sulci (see Fig 1.12, pg 43), of the frontal operculum, with respect to Ungrouped Data for the case group.
[Abbreviations: sn (specimen number); Ope (sole opercular sulcus; Ope$_1$ (First opercular sulcus; Ope$_2$ (Second opercular sulcus)].

	RIGHT HEMISPHERE (centimetre)				**LEFT HEMISPHERE** (centimetre)			
	sn	**Ope**	**Ope$_1$**	**Ope$_2$**	**Ope**	**Ope$_1$**	**Ope$_2$**	**sn**
1	**1**	2.3	-	-	-	0.7	0.65	**2**
2	**3**	-	-	-	-	-	-	**3**
3	**4**	-	-	-	2.3	-	-	**5**
4	**5**	-	1.25	d	-	-	-	**6**
5	**6**	-	0.35	n_o	1.6	-	-	**7**
6	**7**	-	-	-	-	0.55	0.55	**8**
7	**8**	-	0.45	0.4	-	1.4	1.5	**9**
8	**9**	0.7	-	-	1.0	-	-	**10**
9	**10**	-	-	-	0.8	-	-	**11**
10	**11**	1.6	-	-	0.75	-	-	**12**
11	**12**	2.3	-	-	1.0	-	-	**13**
12	**13**	-	1.3	1.85	1.4	-	-	**14**
13	**14**	-	0.45	2.6	-	1.8	0.8	**15**
14	**15**	-	-	-	-	1.0	1.8	**16**
15	**16**	-	-	-	2.15	-	-	**18**
16	**17**	-	-	-	-	2.7	1.1	**19**
17	**18**	d	d	d	-	0.9	0.7	**21**
18	**19**	-	0.7	3.55	n_o	-	-	**22**
19	**20**	-	-	-	0.45	-	-	**23**

Table E.11 continues on next page

Table E.11 continued

	RIGHT HEMISPHERE (centimetre)				**LEFT HEMISPHERE** (centimetre)			
	sn	**Ope**	**Ope$_1$**	**Ope$_2$**	**Ope**	**Ope$_1$**	**Ope$_2$**	**sn**
20	**21**	2.2	-	-	-	2.0	1.4	**26**
21	**22**	0.65	-	-	1.7	-	-	**27**
22	**23**	-	1.45	2.0	0.8	-	-	**28**
23	**24**	0.75	-	-	-	-	-	**29**
24	**25**	-	0.75	3.5	-	-	-	**30**
25	**26**	3.4	-	-	-	-	-	**87**
26	**28**	-	-	-	-	-	-	**88**
27	**30**	1.4	-	-				
28	**31**	-	-	-				

Table E.12: Composite recording of the Lengths of Individual Opercular sulci (see Fig 1.12, pg 43), of the frontal operculum, with respect to Ungrouped Data for the case group.

[Abbreviations: sn (specimen number); Ope (sole opercular sulcus; Ope$_1$ (First opercular sulcus; Ope$_2$ (Second opercular sulcus)].

	RIGHT HEMISPHERE (centimetre)				**LEFT HEMISPHERE** (centimetre)			
	sn	**Ope**	**Ope$_1$**	**Ope$_2$**	**Ope**	**Ope$_1$**	**Ope$_2$**	**sn**
1	**1**	2.4	-	-	-	0.75	0.63	**2**
2	**3**	-	-	-	-	-	-	**3**
3	**4**	-	-	-	2.35	-	-	**5**
4	**5**	-	1.33	d	-	-	-	**6**
5	**6**	-	0.38	n_o	1.58	-	-	**7**
6	**7**	-	-	-	-	0.53	0.58	**8**
7	**8**	-	0.48	0.4	-	1.43	1.53	**9**
8	**9**	0.73	-	-	0.95	-	-	**10**
9	**10**	-	-	-	0.9	-	-	**11**
10	11	1.6	-	-	0.78	-	-	**12**
11	**12**	2.35	-	-	0.85	-	-	**13**
12	**13**	-	1.3	1.85	1.38	-	-	**14**
13	**14**	-	0.48	2.65	-	1.85	0.8	**15**
14	**15**	-	-	-	-	1.0	1.75	**16**
15	**16**	-	-	-	2.18	-	-	**18**
16	**17**	-	-	-	-	2.75	1.1	**19**
17	**18**	d	d	d	-	0.93	0.73	**21**

Table E.12 continues on next page

Table E.12 continued.

	RIGHT HEMISPHERE				LEFT HEMISPHERE			
	sn	**Ope**	**Ope_1**	**Ope_2**	**Ope**	**Ope_1**	**Ope_2**	**sn**
18	**19**	-	0.7	3.48	n_o	-	-	**22**
19	**20**	-	-	-	0.45	-	-	**23**
20	**21**	2.23	-	-	-	2.05	1.4	**26**
21	**22**	0.65	-	-	1.75	-	-	**27**
22	**23**	-	1.4	2.05	0.8	-	-	**28**
23	**24**	0.8	-	-	-	-	-	**29**
24	**25**	-	0.73	3.53	-	-	-	**30**
25	**26**	3.43	-	-	-	-	-	**87**
26	**28**	-	-	-	-	-	-	**88**
27	**30**	1.43	-	-				
28	**31**	-	-	-				

E.3 LENGTHS OF INDIVIDUAL ACCESSORY (TRIANGULAR) SULCI WITH RESPECT TO UNGROUPED DATA

Table E.13: First recording of the Lengths of Individual Triangular Sulci (see Fig 1.12, pg 43) of the frontal operculum, with respect to Ungrouped Data for the control group. [Abbreviations: sn (specimen number); Tri (sole triangular sulcus); $Tria_{2/3}$ (Anterior triangular sulcus when the triangular sulcus was present as either two or three sulci); Trim (Middle of three triangular sulci); $Trip_{2/3}$ (Posterior triangular sulcus when the triangular sulcus was present as either two or three sulci); n_o (notch)].

	RIGHT HEMISPHERE (centimetre)					**LEFT HEMISPHERE** (centimetre)				
	sn	**Tri**	**$Tria_{2/3}$**	**Trim**	**$Trip_{2/3}$**	**Tri**	**$Tria_{2/3}$**	**Trim**	**$Trip_{2/3}$**	**sn**
1	**32**	-	Dis-regard	-	1.55	1.15	-	-	-	**32**
2	**35**	-	-	-	-	1.5	-	-	-	**35**
3	**36**	0.6	-	-	-	2.35	-	-	-	**36**
4	**37**	0.8	-	-	-	1.3	-	-	-	**37**
5	**38**	-	-	-	-	-	-	-	-	**38**
6	**39**	1.1	-	-	-	-	0.85	-	1.35	**39**
7	**40**	1.4	-	-	-	-	1.4	-	1.35	**40**
8	**41**	2.8	-	-	-	-	0.5	1.7	0.8	**41**
9	**42**	-	0.85	2.2	0.5	1.1	-	-	-	**42**
10	**43**	-	-	-	-	-	0.7	2.1	n_o	**43**
11	**44**	-	-	-	-	n_o	-	-	-	**44**
12	**45**	-	-	-	1.0	-	-	-	-	**45**
13	**46**	-	-	-	-	1.6	-	-	-	**46**
14	**47**	-	-	-	-	-	-	-	-	**47**
15	**48**	2.0	-	-	-	1.75	-	-	-	**48**
16	**49**	1.0	-	-	-	-	-	-	-	**49**
17	**50**	-	-	-	-	2.8	-	-	-	**50**
18	**52**	-	0.75	2.85	0.55	1.6	-	-	-	**52**
19	**53**	1.75	-	-	-	-	-	-	-	**53**
20	**54**	1.6	-	-	-	0.7	-	-	-	**54**
21	**57**	-	1.5	-	2.15	-	-	-	-	**57**
22	**58**	-	2.0	-	0.4	-	2.0	-	1.4	**58**
23	**59**	1.1	-	-	-	2.55	-	-	-	**59**
24	**60**	-	-	-	-	1.3	-	-	-	**60**
25	**61**	-	0.6	1.6	0.4	-	-	-	-	**61**
26	**62**	-	1.5	-	0.6	0.9	-	-	-	**62**
27	**65**	1.95	-	-	-	1.1	-	-	-	**65**
28	**66**	1.6	-	-	-	1.3	-	-	-	**66**
29	**67**	-	0.85	-	0.55	0.8	-	-	-	**67**

Table E.13 continues on next page

Table E.13 continued.

	RIGHT HEMISPHERE (centimetre)					**LEFT HEMISPHERE** (centimetre)				
	sn	**Tri**	**Tria$_{2/3}$**	**Trim**	**Trip$_{2/3}$**	**Tri**	**Tria$_{2/3}$**	**Trim**	**Trip$_{2/3}$**	**sn**
30	**69**	-	0.85	-	1.35	-	2.5	-	0.55	**69**
31	**72**	-	0.75	-	0.85	1.85	-	-	-	**72**
32	**73**	1.05	-	-	-	n_o	-	-	-	**73**
33	**75**	-	0.8	-	1.4	-	0.6	-	0.6	**75**
34	**76**	2.7	-	-	-	-	0.8	2.1	0.6	**76**
35	**77**	1.3	-	-	-	1.05	-	-	-	**77**
36	**78**	1.7	-	-	-	2.35	-	-	-	**78**
37	**81**	1.2	-	-	-	1.4	-	-	-	**81**
38	**83**	-	0.8	2.25	2.0	0.5	-	-	-	**83**
39	**85**	2.6	-	-	-	-	1.55	Dis-regard	1.1	**85**
40	**101**	0.7	-	-	-	0.6	-	-	-	**101**

Table E.14: Second recording of the Lengths of Individual Triangular Sulci (see Fig 1.12, pg 43) of the frontal operculum, with respect to Ungrouped Data for the control group. [Abbreviations: sn (specimen number); Tri (sole triangular sulcus); Tria$_{2/3}$ (Anterior triangular sulcus when the triangular sulcus was present as either two or three sulci; Trim (Middle of three triangular sulci); Trip$_{2/3}$ (Posterior triangular sulcus when the triangular sulcus was present as either two or three sulci); n_o (notch)]. Sulcal lengths were disregarded when their sulcal lengths extended beyond the superior limit of the frontal operculum.

	RIGHT HEMISPHERE (centimetre)					**LEFT HEMISPHERE** (centimetre)				
	sn	Tri	**Tria$_{2/3}$**	**Trim**	**Trip$_{2/3}$**	**Tri**	**Tria$_{2/3}$**	**Trim**	**Trip$_{2/3}$**	**sn**
1	**32**	-	Dis-regard	-	1.55	1.2	-	-	-	**32**
2	**35**	-	-	-	-	1.6	-	-	-	**35**
3	**36**	0.6	-	-	-	2.35	-	-	-	**36**
4	**37**	0.9	-	-	-	1.45	-	-	-	**37**
5	**38**	-	-	-	-	-	-	-	-	**38**
6	**39**	1.0	-	-	-	-	0.8	-	1.4	**39**
7	**40**	1.35	-	-	-	-	1.4	-	1.3	**40**
8	**41**	2.75	-	-	-	-	0.65	1.7	0.75	**41**
9	**42**	-	0.9	2.1	0.55	1.05	-	-	-	**42**
10	**43**	-	-	-	-	-	0.8	2.25	n_o	**43**
11	**44**	-	-	-	-	n_o	-	-	-	**44**
12	**45**	-	-	-	0.8	-	-	-	-	**45**

Table E.14 continues on next page

Table E.14 continued.

	RIGHT HEMISPHERE (centimetre)					**LEFT HEMISPHERE** (centimetre)				
	sn	Tri	**Tria$_{2/3}$**	**Tri m**	**Trip$_{2/3}$**	**Tri**	**Tria$_{2/3}$**	**Trim**	**Trip$_{2/3}$**	**sn**
13	**46**	-	-	-	-	1.65	-	-	-	**46**
14	**47**	-	-	-	-	-	-	-	-	**47**
15	**48**	2.15	-	-	-	1.8	-	-	-	**48**
16	**49**	0.95	-	-	-	-	-	-	-	**49**
17	**50**	-	-	-	-	2.7	-	-	-	**50**
18	**52**	-	0.7	2.9	0.6	1.5	-	-	-	**52**
19	**53**	1.8	-	-	-	-	-	-	-	**53**
20	**54**	1.7	-	-	-	0.8	-	-	-	**54**
21	**57**	-	1.5	-	2.0	-	-	-	-	**57**
22	**58**	-	2.0	-	0.5	-	1.95	-	1.4	**58**
23	**59**	1.0	-	-	-	2.4	-	-	-	**59**
24	**60**	-	-	-	-	1.3	-	-	-	**60**
25	**61**	-	0.6	1.4	0.4	-	-	-	-	**61**
26	**62**	-	1.45	-	0.6	0.75	-	-	-	**62**
27	**65**	1.95	-	-	-	0.9	-	-	-	**65**
28	**66**	1.5	-	-	-	1.2	-	-	-	**66**
29	**67**	-	0.7	-	0.5	0.65	-	-	-	**67**
30	**69**	-	0.7	-	1.2	-	2.6	-	0.5	**69**
31	**72**	-	0.7	-	0.9	1.7	-	-	-	**72**
32	**73**	1.0	-	-	-	n_o	-	-	-	**73**
33	**75**	-	0.8	-	1.15	-	0.5	-	0.6	**75**
34	**76**	2.6	-	-	-	-	0.7	2.2	0.7	**76**
35	**77**	1.15	-	-	-	1.1	-	-	-	**77**
36	**78**	1.6	-	-	-	2.2	-	-	-	**78**
37	**81**	1.2	-	-	-	1.35	-	-	-	**81**
38	**83**	-	0.9	2.3	1.9	0.6	-	-	-	**83**
39	**85**	2.75	-	-	-	-	1.45	Dis-regard	1.1	**85**
40	**101**	0.85	-	-	-	0.65	-	-	-	**101**

Table E.15: Composite recording of the Lengths of the Individual Triangular Sulci (see Fig 1.12, pg 43) of the frontal operculum, with respect to Ungrouped Data for the control group. [Abbreviations: sn (specimen number); Tri (sole triangular sulcus); $Tria_{2/3}$ (Anterior triangular sulcus when the triangular sulcus was present as either two or three sulci); Trim (Middle of three triangular sulci); $Trip_{2/3}$ (Posterior triangular sulcus when the triangular sulcus was present as either two or three sulci); n_o (notch)]. Specimens were disregarded if the sulcus measured extended beyond the superior limit of the frontal operculum.

	RIGHT HEMISPHERE					LEFT HEMISPHERE				
	sn	**Tri**	**$Tria_{2/3}$**	**Trim**	**$Trip_{2/3}$**	**Tri**	**$Tria_{2/3}$**	**Trim**	**$Trip_{2/3}$**	**sn**
1	**32**	-	Dis-regard	-	1.55	1.18	-	-	-	**32**
2	**35**	-	-	-	-	1.55	-	-	-	**35**
3	**36**	0.6	-	-	-	2.35	-	-	-	**36**
4	**37**	0.85	-	-	-	1.38	-	-	-	**37**
5	**38**	-	-	-	-	-	-	-	-	**38**
6	**39**	1.05	-	-	-	-	0.83	-	1.38	**39**
7	**40**	1.38	-	-	-	-	1.4	-	1.33	**40**
8	**41**	2.78	-	-	-	-	0.58	1.7	0.78	**41**
9	**42**	-	0.88	2.15	0.53	1.03	-	-	-	**42**
10	**43**	-	-	-	-	-	0.75	2.18	n_o	**43**
11	**44**	-	-	-	-	n_o	-	-	-	**44**
12	**45**	-	-	-	0.9	-	-	-	-	**45**
13	**46**	-	-	-	-	1.63	-	-	-	**46**
14	**47**	-	-	-	-	-	-	-	-	**47**
15	**48**	2.08	-	-	-	1.78	-	-	-	**48**
16	**49**	0.98	-	-	-	-	-	-	-	**49**
17	**50**	-	-	-	-	2.75	-	-	-	**50**
18	**52**	-	0.73	2.88	0.58	1.55	-	-	-	**52**
19	**53**	1.78	-	-	-	-	-	-	-	**53**
20	**54**	1.65	-	-	-	0.75	-	-	-	**54**
21	**57**	-	1.5	-	2.08	-	-	-	-	**57**
22	**58**	-	2.0	-	0.45	-	1.98	-	1.4	**58**
23	**59**	1.05	-	-	-	2.48	-	-	-	**59**
24	**60**	-	-	-	-	1.3	-	-	-	**60**
25	**61**	-	0.6	1.5	0.4	-	-	-	-	**61**
26	**62**	-	1.48	-	0.6	0.83	-	-	-	**62**
27	**65**	1.95	-	-	-	1.0	-	-	-	**65**
28	**66**	1.55	-	-	-	1.25	-	-	-	**66**
29	**67**	-	0.78	-	0.53	0.73	-	-	-	**67**
30	**69**	-	0.78	-	1.28	-	2.55	-	0.53	**69**
31	**72**	-	0.73	-	0.88	1.78	-	-	-	**72**
32	**73**	1.03	-	-	-	n_o	-	-	-	**73**

Table E.15 continues on next page

Table E.15 continued.

	RIGHT HEMISPHERE (centimetre)					**LEFT HEMISPHERE** (centimetre)				
	sn	**Tri**	**Tria$_{2/3}$**	**Trim**	**Trip$_{2/3}$**	**Tri**	**Tria$_{2/3}$**	**Trim**	**Trip$_{2/3}$**	**sn**
33	**75**	-	0.8	-	1.28	-	0.55	-	0.6	**75**
34	**76**	2.65	-	-	-	-	0.75	2.15	0.65	**76**
35	**77**	1.23	-	-	-	1.08	-	-	-	**77**
36	**78**	1.65	-	-	-	2.28	-	-	-	**78**
37	**81**	1.2	-	-	-	1.38	-	-	-	**81**
38	**83**	-	0.85	2.28	1.95	0.55	-	-	-	**83**
39	**85**	2.68	-	-	-	-	1.5	Disre-gard	1.1	**85**
40	**101**	0.88	-	-	-	0.63	-	-	-	**101**

Table E.16: First recording of the Lengths of Individual Triangular Sulci (see Fig 1.12, pg 43) of the frontal operculum, with respect to the case group.

[Abbreviations: sn (specimen number); Tri (sole triangular sulcus); $Tria_{2/3}$ (Anterior triangular sulcus when the triangular sulcus was present as either two or three sulci); Trim (Middle of three triangular sulci); $Trip_{2/3}$ (Posterior triangular sulcus when the triangular sulcus was present as either two or three sulci); n_o (notch); d (damaged)]. Specimens were disregarded if the sulcus measured extended beyond the superior limit of the frontal operculum.

	RIGHT HEMISPHERE (centimetre)					**LEFT HEMISPHERE** (centimetre)				
	sn	**Tri**	**$Tria_{2/3}$**	**Trim**	**$Trip_{2/3}$**	**Tri**	**$Tria_{2/3}$**	**Trim**	**$Trip_{2/3}$**	**sn**
1	**1**	-	0.85	-	1.75	0.5	-	-	-	**2**
2	**3**	0.85	-	-	-	1.0	-	-	-	**3**
3	**4**	2.0	-	-	-	-	1.4	-	0.75	**5**
4	**5**	1.3	-	-	-	-	-	-	-	**6**
5	**6**	1.1	-	-	-	0.4	-	-	-	**7**
6	**7**	1.1	-	-	-	1.2	-	-	-	**8**
7	**8**	n_o	-	-	-	-	-	-	-	**9**
8	**9**	-	2.35	-	0.85	1.4	-	-	-	**10**
9	**10**	1.5	-	-	-	3.4	-	-	-	**11**
10	**11**	-	-	-	-	-	3.0	1.2	1.3	**12**
11	**12**	2.0	-	-	-	1.5	-	-	-	**13**
12	**13**	1.15	-	-	-	-	1.9	-	1.5	**14**
13	**14**	-	0.85	-	1.25	0.8	-	-	-	**15**
14	**15**	-	1.05	-	1.6	-	-	-	-	**16**
15	**16**	-	2.25	-	1.6	-	d	-	1.75	**18**
16	**17**	-	1.1	-	-	-	1.0	-	3.7	**19**
17	**18**	d	d	d	d	d	-	-	-	**21**
18	**19**	-	1.6	-	1.25	1.5	-	-	-	**22**
19	**20**	1.5	-	-	-	1.9	-	-	-	**23**
20	**21**	1.35	-	-	-	1.95	-	-	-	**26**
21	**22**	1.4	-	-	-	-	0.45	-	2.4	**27**
22	**23**	-	d	-	d	d	d	d	d	**28**
23	**24**	-	1.6	-	0.75	2.2	-	-	-	**29**
24	**25**	3.0	-	-	-	1.2	-	-	-	**30**
25	**26**	-	0.95	-	0.7	-	0.6	1.8	0.8	**87**
26	**28**	-	Dis-regard	-	Dis-regard	-	0.95	-	1.6	**88**
27	**30**	d	-	-	-					
28	**31**	1.45	-	-	-					

Table E.17: Second recording of the Lengths of Individual Triangular Sulci (see Fig 1.12, pg 43) of the frontal operculum, with respect to the case group.

[Abbreviations: sn (specimen number); Tri (sole triangular sulcus); $Tria_{2/3}$ (Anterior triangular sulcus when the triangular sulcus was present as either two or three sulci); Trim (Middle of three triangular sulci); $Trip_{2/3}$ (Posterior triangular sulcus when the triangular sulcus was present as either two or three sulci); n_o (notch); d (damaged)]. Specimens were disregarded if the sulcus measured extended beyond the superior limit of the frontal operculum.

	RIGHT HEMISPHERE (centimetre)					**LEFT HEMISPHERE** (centimetre)				
	sn	**Tri**	**$Tria_{2/3}$**	**Trim**	**$Trip_{2/3}$**	**Tri**	**$Tria_{2/3}$**	**Trim**	**$Trip_{2/3}$**	**sn**
1	**1**	-	0.75	-	1.95	0.4	-	-	-	**2**
2	**3**	0.8	-	-	-	1.1	-	-	-	**3**
3	**4**	1.9	-	-	-	-	1.5	-	0.7	**5**
4	**5**	1.35	-	-	-	-	-	-	-	**6**
5	**6**	1.15	-	-	-	0.5	-	-	-	**7**
6	**7**	1.0	-	-	-	1.05	-	-	-	**8**
7	**8**	n_o	-	-	-	-	-	-	-	**9**
8	**9**	-	2.45	-	0.85	1.3	-	-	-	**10**
9	**10**	1.75	-	-	-	3.3	-	-	-	**11**
10	**11**	-	-	-	-	-	2.9	1.3	1.35	**12**
11	**12**	2.0	-	-	-	1.5	-	-	-	**13**
12	**13**	1.15	-	-	-	-	1.95	-	1.4	**14**
13	**14**	-	0.75	-	1.2	0.95	-	-	-	**15**
14	**15**	-	1.1	-	1.7	-	-	-	-	**16**
15	**16**	-	2.2	-	1.6	-	d	-	1.7	**18**
16	**17**	-	1.1	-	-	-	1.1	-	3.75	**19**
17	**18**	d	d	d	d	d	-	-	-	**21**
18	**19**	-	1.45	-	1.3	1.4	-	-	-	**22**
19	**20**	1.4	-	-	-	1.7	-	-	-	**23**
20	**21**	1.3	-	-	-	1.8	-	-	-	**26**
21	**22**	1.4	-	-	-	-	0.4	-	2.3	**27**
22	**23**	-	d	-	d	d	d	d	d	**28**
23	**24**	-	1.5	-	0.65	2.3	-	-	-	**29**
24	**25**	2.85	-	-	-	1.25	-	-	-	**30**
25	**26**	-	1.05	-	0.75	-	0.65	1.8	0.7	**87**
26	**28**	-	Dis-regard	-	Dis-regard	-	0.95	-	1.5	**88**
27	**30**	d	-	-	-					
28	**31**	1.25	-	-	-					

Table E.18: Composite recording of the Lengths of Individual Triangular Sulci (see Fig 1.12, pg 43) of the frontal operculum, with respect to the case group.

[Abbreviations: sn (specimen number); Tri (sole triangular sulcus); $Tria_{2/3}$ (Anterior triangular sulcus when the triangular sulcus was present as either two or three sulci); Trim (Middle of three triangular sulci); $Trip_{2/3}$ (Posterior triangular sulcus when the triangular sulcus was present as either two or three sulci); n_o (notch); d (damaged)]. Specimens were disregarded if the sulcus measured extended beyond the superior limit of the frontal operculum.

	RIGHT HEMISPHERE (centimetre)					**LEFT HEMISPHERE** (centimetre)				
	sn	**Tri**	**$Tria_{2/3}$**	**Trim**	**$Trip_{2/3}$**	**Tri**	**$Tria_{2/3}$**	**Trim**	**$Trip_{2/3}$**	**sn**
1	**1**	-	0.8	-	1.85	0.45	-	-	-	**2**
2	**3**	0.83	-	-	-	1.05	-	-	-	**3**
3	**4**	1.95	-	-	-	-	1.45	-	0.73	**5**
4	**5**	1.33	-	-	-	-	-	-	-	**6**
5	**6**	1.13	-	-	-	0.45	-	-	-	**7**
6	**7**	1.05	-	-	-	1.13	-	-	-	**8**
7	**8**	n_o	-	-	-	-	-	-	-	**9**
8	**9**	-	2.4	-	0.85	1.35	-	-	-	**10**
9	**10**	1.63	-	-	-	3.35	-	-	-	**11**
10	**11**	-	-	-	-	-	2.95	1.25	1.33	**12**
11	**12**	2.0	-	-	-	1.5	-	-	-	**13**
12	**13**	1.15	-	-	-	-	1.93	-	1.45	**14**
13	**14**	-	0.8	-	1.23	0.88	-	-	-	**15**
14	**15**	-	1.08	-	1.65	-	-	-	-	**16**
15	**16**	-	2.23	-	1.6	-	d	-	1.73	**18**
16	**17**	-	1.1	-	-	-	1.05	-	3.73	**19**
17	**18**	d	d	d	d	d	-	-	-	**21**
18	**19**	-	1.53	-	1.28	1.45	-	-	-	**22**
19	**20**	1.45	-	-	-	1.8	-	-	-	**23**
20	**21**	1.33	-	-	-	1.88	-	-	-	**26**
21	**22**	1.4	-	-	-	-	0.43	-	2.35	**27**
22	**23**	-	d	-	d	d	d	d	d	**28**
23	**24**	-	1.55	-	0.7	2.25	-	-	-	**29**
24	**25**	2.93	-	-	-	1.23	-	-	-	**30**
25	**26**	-	1.0	-	0.73	-	0.63	1.8	0.75	**87**
26	**28**	-	Dis-regard	-	Dis-regard	-	0.95	-	1.55	**88**
27	**30**	d	-	-	-					
28	**31**	1.35	-	-	-					

APPENDIX F

RECORD OF INDIVIDUAL, GROUPED SULCAL LENGTHS: PART 1

F.1 LENGTHS OF THE INDIVIDUAL MAJOR SULCI GROUPED ACCORDING TO THE MODIFIED TYPES OF SULCAL CONNECTIONS

Table F.1: **Lengths of Individual Major sulci by Type of Sulcal Connection. [TYPE 1, CONTROL], see Fig 3.27B and 3.28B (pages 179 and 180 respectively).**
[Abbreviations: sn (specimen number); x_1 (stem of the anterior rami); x_2 (anterior ascending ramus); x_3 (anterior horizontal ramus); and case (separate hemispheres)].

	RIGHT HEMISPHERE				LEFT HEMISPHERE			
	sn	**x_1**	**x_2**	**x_3**	**x_1**	**x_2**	**x_3**	**sn**
1	**40**	-	0.78	2.3	0.45	1.5	2.15	**32**
2	**42**	-	2.23	2.05	0.68	1.05	1.55	**37**
3	**45**	-	2.0	1.3	-	2.78	2.33	**42**
4	**49**	0.45	2.45	1.68	1.4	0.3	0.7	**45**
5	**58**	-	0.6	1.13	0.95	0.83	1.6	**47**
6	**60**	-	1.6	1.73	0.93	0.93	2.18	**52**
7	**62**	-	1.88	2.55	-	2.1	1.98	**54**
8	**65**	-	1.85	0.65	-	1.8	2.13	**58**
9	**66**	0.45	1.85	1.83	-	1.03	1.8	**59**
10	**69**	-	1.55	1.45	-	2.2	2.15	**62**
11	**72**	-	1.8	1.88	0.48	0.4	1.78	**65**
12	**78**	-	2.1	1.8	0.55	1.75	1.18	**67**
13	**83**	-	1.23	1.68	-	2.28	1.35	**72**
14					-	1.6	0.45	**73**
15					-	2.3	1.25	**75**
16					-	1.98	1.3	**76**

Table F.1 continues on next page

Table F.1 continued.								
	RIGHT HEMISPHERE				LEFT HEMISPHERE			
	sn	**x_1**	**x_2**	**x_3**	**x_1**	**x_2**	**x_3**	**sn**
17					-	1.43	1.2	**77**
18					-	1.85	2.15	**78**
19					-	1.08	2.05	**85**

Table F.2: **Lengths of Individual Major sulci by Type of Sulcal Connection. [TYPE 2, CONTROL], see Fig 3.27C and 3.28C (pages 179 and 180 respectively).**
[Abbreviations: sn (specimen number); x_1 (stem of the anterior rami); x_2 (anterior ascending ramus); x_3 (anterior horizontal ramus); and case (separate hemispheres)].

	RIGHT HEMISPHERE				LEFT HEMISPHERE			
	sn	**x_1**	**x_2**	**x_3**	**x_1**	**x_2**	**x_3**	**sn**
1	**44**	0.68	0.3	1.1	-	-	-	-
2	**79**[א]	-	-	-	-	-	-	-
3	**84**[א]	-	-	-	-	-	-	-
4	**101**	0.7	0.83	2.0	-	-	-	-
5	**107**[א]	-	-	-	-	-	-	-

[א] Specimen could not be measured

Table F.3: **Lengths of Individual Major sulci by Type of Sulcal Connection. [TYPE 3, CONTROL], see Fig 3.27D and 3.28D (pages 179 and 180 respectively).**
[Abbreviations: sn (specimen number); x_1 (stem of the anterior rami); x_2 (anterior ascending ramus); x_3 (anterior horizontal ramus); and case (separate hemispheres)].

	RIGHT HEMISPHERE				LEFT HEMISPHERE			
	sn	**x_1**	**x_2**	**x_3**	**x_1**	**x_2**	**x_3**	**sn**
1	**32**	-	2.23	1.0	0.85	1.93	0.65	**35**
2	**35**	1.6	0.7	0.68	-	3.25	0.95	**36**
3	**36**	0.65	0.7	1.03	0.9	0.95	0.73	**38**
4	**37**	0.48	1.8	1.68	-	2.13	1.53	**39**
5	**38**	1.05	0.88	0.88	-	1.45	1.7	**40**
6	**39**	0.7	1.75	1.88	0.53	1.2	1.5	**41**
7	**41**	-	1.45	1.13	-	1.05	1.65	**43**
8	**43**	1.2	0.73	0.4	0.38	2.23	1.28	**44**
9	**46**	1.13	0.75	0.73	0.65	0.65	1.65	**46**
10	**47**	0.5	1.0	1.23	-	0.6	2.38	**48**
11	**48**	-	1.38	1.88	0.6	1.3	1.13	**49**
12	**50**	1.6	0.45	0.65	-	1.98	2.03	**50**
13	**52**	-	2.23	1.4	0.9	2.5	1.28	**53**
14	**53**	-	2.68	1.13	0.88	0.58	1.03	**57**
15	**54**	0.3	1.6	1.95	0.35	0.55	0.83	**60**
16	**57**	0.4	2.58	1.05	-	0.83	1.2	**61**
17	**59**	-	1.73	1.85	0.48	1.85	1.4	**66**
18	**61**	-	1.2	0.93	-	2.75	2.0	**69**
19	**67**	0.88	1.1	1.35	-	1.2	1.0	**81**
20	**73**	0.95	0.83	1.03	0.55	0.58	1.05	**83**
21	**75**	-	1.68	1.68	0.8	1.4	0.53	**101**
22	**76**	-	0.88	0.5				
23	**77**	0.6	0.73	1.0				
24	**83**	-	1.23	1.68				
25	**85**	-	1,98	0.9				

Note that there were no recordings for: **Lengths of Individual Major sulci by Type of Sulcal Connection. [TYPE 4, CONTROL], see Fig 3.27E and 3.28E (pages 179 and 180 respectively).**

Table F.4: **Lengths of Individual Major sulci (see Fig 1.7, pg 15) by Type of Sulcal Connection. [TYPE 1, CASE], see Fig 3.27B and 3.28B (pages 179 and 180 respectively).** [Abbreviations: sn (specimen number); x_1 (stem of the anterior rami); x_2 (anterior ascending ramus); x_3 (anterior horizontal ramus); and case (separate hemispheres); n_o (notch)].

	RIGHT HEMISPHERE				LEFT HEMISPHERE			
	sn	**x_1**	**x_2**	**x_3**	**x_1**	**x_2**	**x_3**	**sn**
1	**4**	-	1.93	n_o	1.85	0.7	1.2	**3**
2	**7**	0.75	1.28	1.35	0.8	0.65	1.73	**6**
3	**15**	-	2.15	2.3	-	1.18	2.15	**29**
4	**16**	-	2.75	1.43	-	3.3	0	**30**
5	**17**	-	2.25	1.75	-	1.78	3.08	**87**
6	**20**	-	2.78	2.7	-	2.3	2.58	**88**
7	**28**	-	2.58	0.85				
8	**31**	-	1.2	1.4				

Table F.5: **Lengths of Individual Major sulci (see Fig 1.7, pg 15) by Type of Sulcal Connection. [TYPE 2, CASE], see Fig 3.27C and 3.28C (pages 179 and 180 respectively).** [Abbreviations: sn (specimen number); x_1 (stem of the anterior rami); x_2 (anterior ascending ramus); x_3 (anterior horizontal ramus); and case (separate hemispheres)].

	RIGHT HEMISPHERE				LEFT HEMISPHERE			
	sn	**x_1**	**x_2**	**x_3**	**x_1**	**x_2**	**x_3**	**sn**
1	**10**	-	1.28	1.83				**24**[8]

[8] Specimen could not be measured

Table F.6: **Lengths of Individual Major sulci (see Fig 1.7, pg 15) by Type of Sulcal Connection. [TYPE 3, CASE], see Fig 3.27D and 3.28D (pages 179 and 180 respectively).** [Abbreviations: sn (specimen number); x_1 (stem of the anterior rami); x_2 (anterior ascending ramus); x_3 (anterior horizontal ramus); and case (separate hemispheres); n_o (notch)].

	RIGHT HEMISPHERE				LEFT HEMISPHERE			
	sn	**x_1**	**x_2**	**x_3**	**x_1**	**x_2**	**x_3**	**sn**
1	**1**	-	n_o	1.55	0.38	2.18	2.48	**2**
2	**3**	0.63	1.46	2.63	-	1.6	1.03	**5**
3	**5**	0.38	1.18	2.0	0.85	0.9	2.38	**7**
4	**6**	-	1.6	1.13	0.68	1.53	0.4	**8**
5	**8**	-	1.58	1.48	-	1.65	1.2	**9**
6	**9**	-	2.1	1.5	-	1.5	0.9	**10**
7	**11**	0.68	1.65	1.45	-	2.8	n_o	**11**
8	**12**	-	1.08	1.58	-	2.3	1.55	**12**
9	**13**	-	1.1	3.1	-	2.23	1.05	**13**
10	**14**	-	1.73	1.75	0.35	1.93	1.48	**14**
11	**19**	-	2.35	1.2	1.15	1.13	2.38	**15**
12	**21**	0.35	0.45	1.93	0.33	0.78	1.3	**16**
13	**22**	-	2.4	1.9	-	1.7	0.75	**18**
14	**23**	-	2.13	1.3	-	2.5	n_o	**19**
15	**24**	-	1.78	1.05	0.48	1.1	1.75	**21**
16	**25**	-	1.68	1.18	-	2.05	2.53	**22**
17	**26**	-	1.8	1.3	-	1.9	n_o	**23**
18	**30**	-	1.53	1.38	-	2.38	1.83	**26**
19					0.3	1.48	1.9	**27**
20					-	2.25	1.43	**28**

Table F.7: **Lengths of Individual Major sulci (see Fig 1.7, pg 15) by Type of Sulcal Connection. [TYPE 4, CASE], see Fig 3.27E and 3.28E (pages 179 and 180 respectively).** [Abbreviations: sn (specimen number); x_1 (stem of the anterior rami); x_2 (anterior ascending ramus); x_3 (anterior horizontal ramus); and case (separate hemispheres)].

	RIGHT HEMISPHERE				LEFT HEMISPHERE			
	sn	**x_1**	**x_2**	**x_3**	**x_1**	**x_2**	**x_3**	**sn**
1	**18**	-	0	2.95				**NONE**

F.2 LENGTHS OF THE INDIVIDUAL ACCESSORY SULCI (OPERCULAR) GROUPED ACCORDING TO THE MODIFIED TYPES OF CONNECTIONS (Note that the Opercular sulcus only occurs in Type 3 of the four Types of Connections)

Table F.8: **Lengths of Individual Opercular sulcus/ sulci by Type of Sulcal Connection. [TYPE 3, CONTROL], see Fig 3.27B and 3.28B (pages 179 and 180 respectively).** [Abbreviations: sn (specimen number); Ope (sole opercular sulcus; Ope_1 (First opercular sulcus; Ope_2 (Second opercular sulcus); n_o (notch)].

	RIGHT HEMISPHERE				LEFT HEMISPHERE			
	sn	**Ope**	**Ope_1**	**Ope_2**	**Ope**	**Ope_1**	**Ope_2**	**sn**
1	**32**	-	1.5	0.75	2.28	-	-	**35**
2	**35**	-	0.9	1.25	0.63	-	-	**36**
3	**36**	n_o	-	-	-	1.7	0.68	**38**
4	**37**	n_o	-	-	-	0.55	1.0	**39**
5	**38**	d	d	d	-	0.9	0.8	**40**
6	**39**	2.2	-	-	2.35	-	-	**41**
7	**41**	-	2.05	1.95	1.7	-	-	**43**
8	**43**	2.2	-	-	1.98	-	-	**44**
9	**46**	2.7	-	-	0.98	-	-	**46**
10	**47**	d	-	-	2.55	-	-	**48**
11	**48**	2.7	-	-	n_o	-	-	**49**
12	**50**	1.83	-	-	1.0	-	-	**50**
13	**52**	1.95	-	-	1.78	-	-	**53**
14	**53**	0.53	-	-	3.25	-	-	**57**
15	**54**	0.65	-	-	2.8	-	-	**60**
16	**57**	-	0.83	1.43	1.98	-	-	**61**
17	**59**	-	1.83	0.78	1.9	-	-	**66**
18	**61**	0.95	-	-	0.3	-	-	**69**
19	**67**	2.43	-	-	-	1.25	0.5	**81**
20	**73**	1.93	-	-	2.4	-	-	**83**
21	**75**	1.75	-	-	1.68	-	-	**101**
22	**76**	1.85	-	-				
23	**77**	-	1.08	1.3				
24	**81**	-	0.8	d				
25	**85**	3.33	-	-				

Table F.9: **Lengths of Individual Opercular sulcus/ sulci by Type of Sulcal Connection. [TYPE 3, CASE], see Fig 3.27B and 3.28B (pages 179 and 180 respectively).** [Abbreviations: sn (specimen number); Ope (sole opercular sulcus); Ope_1 (First opercular sulcus); Ope_2 (Second opercular sulcus); n_o (notch)].

	RIGHT HEMISPHERE				LEFT HEMISPHERE			
	sn	**Ope**	**Ope_1**	**Ope_2**	**Ope**	**Ope_1**	**Ope_2**	**sn**
1	**1**	2.4	-	-	-	0.75	0.63	**2**
2	**3**	?			2.35	-	-	**5**
3	**5**	-	1.33	d	1.58	-	-	**7**
4	**6**	-	0.38	n_o	-	0.53	0.58	**8**
5	**8**	-	0.48	0.4	-	1.43	1.53	**9**
6	**9**	0.73	-	-	0.95	-	-	**10**
7	**11**	1.6	-	-	0.9	-	-	**11**
8	**12**	2.35	-	-	0.78	-	-	**12**
9	**13**	-	1.3	1.85	0.85	-	-	**13**
10	**14**	-	0.48	2.65	1.38	-	-	**14**
11	**19**	-	0.7	3.48	-	1.85	0.8	**15**
12	**21**	2.23	-	-	-	1.0	1.75	**16**
13	**22**	0.65	-	-	2.18	-	-	**18**
14	**23**	-	1.4	2.05	-	2.75	1.1	**19**
15	**24**	0.8	-	0	-	0.93	0.73	**21**
16	**25**	-	0.73	3.53	n_o	-	-	**22**
17	**26**	3.43	-	-	0.45	-	-	**23**
18	**30**	1.45	-	-	-	2.05	1.4	**26**
19					1.75	-	-	**27**
20					0.8	-	-	**28**

F.3 LENGTHS OF THE INDIVIDUAL ACCESSORY SULCI (TRIANGULAR) GROUPED ACCORDING TO THE MODIFIED TYPES OF SULCAL CONNECTIONS

Table F.10: **Lengths of Individual Triangular sulcus /sulci by Type of Sulcal Connections [TYPE 1, CONTROL], see Fig 3.27 and 3.28 (pages 179 and 180 respectively).** [Abbreviations: sn (specimen number); Tri (sole triangular sulcus); $Tria_{2/3}$ (Anterior triangular sulcus when the triangular sulcus was present as either two or three sulci); Trim (Middle of three triangular sulci); $Trip_{2/3}$ (Posterior triangular sulcus when the triangular sulcus was present as either two or three sulci)]. Sulcal lengths were disregarded when the measured length exceeded the limit of the frontal operculum.

	RIGHT HEMISPHERE					LEFT HEMISPHERE				
	sn	**Tri**	**$Tria_{2/3}$**	**Trim**	**$Trip_{2/3}$**	**Tri**	**$Tria_{2/3}$**	**Trim**	**$Trip_{2/3}$**	**sn**
1	**40**	1.38	-	-	-	1.18	-	-	-	**32**
2	**42**	-	0.88	2.15	0.53	1.38	-	-	-	**37**
3	**45**	-	-	-	0.9	1.03				**42**
4	**49**	0.98	-	-	-	-	-	-	-	**45**
5	**58**	-	2.0	-	0.45	-	-	-	-	**47**
6	**60**	-	-	-	-	1.55	-	-	-	**52**
7	**62**	-	1.48	-	0.6	0.75	-	-	-	**54**
8	**65**	1.95	-	-	-	-	1.98	-	1.4	**58**
9	**66**	1.55	-	-	-	2.48	-	-	-	**59**
10	**69**	-	0.78	-	1.28	0.83	-	-	-	**62**
11	**72**	-	0.73	-	0.88	1.0	-	-	-	**65**
12	**78**	1.65	-	-	-	0.73	-	-	-	**67**
13	**83**	-	0.85	2.28	1.95	1.78	-	-	-	**72**
14						n_o	-	-	-	**73**
15						-	0.55	-	0.6	**75**
16						-	0.75	2.15	0.65	**76**
17						1.08	-	-	-	**77**
18						2.28	-	-	-	**78**
19						-	1.5	Disre-gard	1.1	**85**

Note that there was **only one recording** for **[TYPE 2, CONTROL],** see Fig 1.9C, pg 25: that of the **sole triangular sulcus** in specimen 101, in the right hemisphere **(0.88 cm)**.

Table F.11: **Lengths of Individual Triangular sulcus /sulci by Type of Sulcal Connections [TYPE 3, CONTROL]], see Fig 3.27 and 3.28 (pages 179 and 180 respectively).** [Abbreviations: sn (specimen number); Tri (sole triangular sulcus); $Tria_{2/3}$ (Anterior triangular sulcus when the triangular sulcus was present as either two or three sulci); Trim (Middle of three triangular sulci); $Trip_{2/3}$ (Posterior triangular sulcus when the triangular sulcus was present as either two or three sulci); n_o (notch)]. Sulcal lengths were disregarded when the measured length exceeded the limit of the frontal operculum.

	RIGHT HEMISPHERE					LEFT HEMISPHERE				
	sn	**Tri**	**$Tria_{2/3}$**	**Trim**	**$Trip_{2/3}$**	**Tri**	**$Tria_{2/3}$**	**Trim**	**$Trip_{2/3}$**	**sn**
1	**32**	-	Dis - regard	-	1.55	1.55	-	-	-	**35**
2	**35**	-	-	-	-	2.35	-	-	-	**36**
3	**36**	0.6	-	-	-	-	-	-	-	**38**
4	**37**	0.85	-	-	-	-	0.83	-	1.38	**39**
5	**38**	-	-	-	-	-	1.4	-	1.33	**40**
6	**39**	1.05	-	-	-	-	0.58	1.7	0.78	**41**
7	**41**	2.78	-	-	-	-	0.75	2.18	n_o	**43**
8	**43**	-	-	-	-	n_o	-	-	-	**44**
9	**46**	-	-	-	-	1.63	-	-	-	**46**
10	**47**	-	-	-	-	1.78	-	-	-	**48**
11	**48**	2.08	-	-	-	-	-	-	-	**49**
12	**50**	-	-	-	-	2.75	-	-	-	**50**
13	**52**	-	0.73	2.88	0.58	-	-	-	-	**53**
14	**53**	1.78	-	-	-	-	-	-	-	**57**
15	**54**	1.65	-	-	-	1.3	-	-	-	**60**
16	**57**	-	1.5	-	2.08	-	-	-	-	**61**
17	**59**	1.05	-	-	-	1.25	-	-	-	**66**
18	**61**	-	0.6	1.5	0.4	-	2.55	-	0.53	**69**
19	**67**	-	0.78	-	0.53	1.38	-	-	-	**81**
20	**73**	1.03	-	-	-	0.55	-	-	-	**83**
21	**75**	-	0.8	-	1.28	0.63	-	-	-	**101**

Table F.11 continued on next page.

Table F.11 continued										
	RIGHT HEMISPHERE					LEFT HEMISPHERE				
	sn	**Tri**	**Tria$_{2/3}$**	**Trim**	**Trip$_{2/3}$**	**Tri**	**Tria$_{2/3}$**	**Trim**	**Trip$_{2/3}$**	**sn**
22	**76**	2.65	-	-	-					
23	**77**	1.23	-	-	-					
24	**83**	-	0.85	2.28	1.95					
25	**85**	2.68	-	-	-					

Note that there was **no recording** for:

(a) **[TYPE 4, CONTROL], see Fig 1.9E, pg 25**

(b) **[TYPE 2, CASE], see Fig 1.9C, pg 25.**

(c) **[TYPE 4, CASE], see Fig 1.9E, pg 25.**

Table F.12: **Lengths of Individual Triangular sulcus /sulci by Type of Sulcal Connections [TYPE 1, CASE], see Fig 3.27 and 3.28 (pages 179 and 180 respectively).** [Abbreviations: sn (specimen number); Tri (sole triangular sulcus); Tria$_{2/3}$ (Anterior triangular sulcus when the triangular sulcus was present as either two or three sulci); Trim (Middle of three triangular sulci); Trip$_{2/3}$ (Posterior triangular sulcus when the triangular sulcus was present as either two or three sulci)]. Sulcal lengths were disregarded when the measured length exceeded the limit of the frontal operculum.

	RIGHT HEMISPHERE					LEFT HEMISPHERE				
	sn	**Tri**	**Tria$_{2/3}$**	**Trim**	**Trip$_{2/3}$**	**Tri**	**Tria$_{2/3}$**	**Trim**	**Trip$_{2/3}$**	**sn**
1	**4**	1.95	-	-	-	1.05	-	-	-	**3**
2	**7**	1.05	-	-	-	-	-	-	-	**6**
3	**15**	-	1.08	-	1.65	2.25	-	-	-	**29**
4	**16**	-	2.23	-	1.6	1.23	-	-	-	**30**
5	**17**	-	1.1	-	-	-	0.63	1.8	0.75	**87**
6	**20**	1.45	-	-	-	-	0.95	-	1.55	**88**
7	**28**	-	Dis-regard	-	Dis-regard					
8	**31**	1.35	-	-	-					

Table F.I3: **Lengths of Individual Triangular sulcus /sulci by Type of Sulcal Connections [TYPE 1, CASE], see Fig 3.27 and 3.28 (pages 179 and 180 respectively).** [Abbreviations: sn (specimen number); Tri (sole triangular sulcus); $Tria_{2/3}$ (Anterior triangular sulcus when the triangular sulcus was present as either two or three sulci); Trim (Middle of three triangular sulci); $Trip_{2/3}$ (Posterior triangular sulcus when the triangular sulcus was present as either two or three sulci); n_o (notch)]. Sulcal lengths were disregarded when the measured length exceeded the limit of the frontal operculum.

	RIGHT HEMISPHERE					LEFT HEMISPHERE				
	sn	**Tri**	**$Tria_{2/3}$**	**Trim**	**$Trip_{2/3}$**	**Tri**	**$Tria_{2/3}$**	**Trim**	**$Trip_{2/3}$**	**sn**
1	**1**	-	0.8	-	1.85	0.45	-	-	-	**2**
2	**3**	0.83	-	-	-	-	1.45	-	0.73	**5**
3	**5**	1.33	-	-	-	0.45				**7**
4	**6**	1.13	-	-	-	1.13				**8**
5	**8**	n_o	-	-	-	-	-	-	-	**9**
6	**9**	-	2.4	-	0.85	1.35				**10**
7	**11**	-	-	-	-	3.35	-	-	-	**11**
8	**12**	2.0	-	-	-	-	2.95	1.25	1.33	**12**
9	**13**	1.15	-	-	-	1.5				**13**
10	**14**	-	0.8	-	1.23	-	1.93	-	1.45	**14**
11	**19**	-	1.53	-	1.28	0.88	-	-	-	**15**
12	**21**	1.33	-	-	-	-	-	-	-	**16**
13	**22**	1.4	-	-	-	-	d	-	1.73	**18**
14	**23**	-	d	-	d	-	1.05	-	3.73	**19**
15	**24**	-	1.55	-	0.7	d	-	-	-	**21**
16	**25**	2.93	-	-	-	1.45				**22**
17	**26**	-	1.0	-	0.73	1.8				**23**
18	**30**	d	-	-	-	1.88				**26**
19						-	0.43	-	2.35	**27**
20						d	d	d	d	**28**

APPENDIX G

RECORD OF GROUPED INDIVIDUAL SULCAL LENGTHS: PART 2

G.1: LENGTHS OF THE INDIVIDUAL MAJOR SULCI GROUPED ACCORDING TO THE PATTERNS OF THE ANTERIOR RAMI

Table G.1: **First recording of the Lengths of the Individual Major Sulci (see Fig 1.11, pg 38) of the frontal operculum, by Pattern. ['Y' PATTERN, CONTROL]**.
[Abbreviations: sn (specimen number); x_1 (stem of the anterior rami); x_2 (anterior ascending ramus); x_3 (anterior horizontal ramus); and case (separate hemispheres)].

	RIGHT HEMISPHERE				LEFT HEMISPHERE			
	sn	**x_1**	**x_2**	**x_3**	**x_1**	**x_2**	**x_3**	**sn**
1	**35**	1.6	0.7	0.68	0.45	1.5	2.15	**32**
2	**36**	0.65	0.7	1.03	0.85	1.93	0.65	**35**
3	**37**	0.48	1.8	1.68	0.68	1.05	1.55	**37**
4	**38**	1.05	0.88	0.88	0.9	0.95	0.73	**38**
5	**39**	0.7	1.75	1.88	0.53	1.2	1.5	**41**
6	**43**	1.2	0.73	0.4	0.38	2.23	1.28	**44**
7	**44**	0.68	0.3	1.1	1.4	0.3	0.7	**45**
8	**46**	1.13	0.75	0.73	0.65	0.65	1.65	**46**
9	**47**	0.5	1.0	1.23	0.95	0.83	1.6	**47**
10	**49**	0.45	2.45	1.68	0.6	1.3	1.13	**49**
11	**50**	1.6	0.45	0.65	0.93	0.93	2.18	**52**
12	**54**	0.3	1.6	1.95	0.9	2.5	1.28	**53**
13	**57**	0.4	2.58	1.05	0.88	0.58	1.03	**57**
14	**66**	0.45	1.85	1.83	0.35	0.55	0.83	**60**
15	**67**	0.88	1.1	1.35	0.48	0.4	1.78	**65**
16	**73**	0.95	0.83	1.03	0.48	1.85	1.4	**66**
17	**77**	0.6	0.73	1.0	0.55	1.75	1.18	**67**
18	**101**	0.7	0.83	2.0	0.55	0.58	1.05	**83**
19					0.8	1.4	0.53	**101**

Table G.2: **First recording of the Lengths of the Individual Major Sulci (see Fig 1.11, pg 38) of the frontal operculum, by Pattern. ['V-U' PATTERN, CONTROL]**.
[Abbreviations: sn (specimen number); x_1 (stem of the anterior rami); x_2 (anterior ascending ramus); x_3 (anterior horizontal ramus); and case (separate hemispheres)].

	RIGHT HEMISPHERE				LEFT HEMISPHERE			
	sn	**x_1**	**x_2**	**x_3**	**x_1**	**x_2**	**x_3**	**sn**
1	**32**	-	2.23	1.0	-	3.25	0.95	**36**
2	**40**	-	0.78	2.3	-	2.13	1.53	**39**
3	**41**	-	1.45	1.13	-	1.45	1.7	**40**
4	**42**	-	2.23	2.05	-	2.78	2.33	**42**
5	**45**	-	2.0	1.3	-	1.05	1.65	**43**
6	**48**	-	1.38	1.88	-	0.6	2.38	**48**
7	**52**	-	2.23	1.4	-	1.98	2.03	**50**
8	**53**	-	2.68	1.13	-	2.1	1.98	**54**
9	**58**	-	0.6	1.13	-	1.8	2.13	**58**
10	**59**	-	1.73	1.85	-	1.03	1.8	**59**
11	**60**	-	1.6	1.73	-	0.83	1.2	**61**
12	**61**	-	1.2	0.93	-	2.2	2.15	**62**
13	**62**	-	1.88	2.55	-	2.75	2.0	**69**
14	**65**	-	1.85	0.65	-	2.28	1.35	**72**
15	**69**	-	1.55	1.45	-	1.6	0.45	**73**
16	**72**	-	1.8	1.88	-	2.3	1.25	**75**
17	**75**	-	1.68	1.68	-	1.98	1.3	**76**
18	**76**	-	0.88	0.5	-	1.43	1.2	**77**
19	**78**	-	2.1	1.8	-	1.85	2.15	**78**
20	**83**	-	1.23	1.68	-	1.2	1.0	**81**
21	**81**	-	1.25	0.78	-	1.08	2.05	**85**
22	**85**	-	1.98	0.9				

Note that there was no recording for the: **['I' PATTERN, CONTROL], see Fig 1.11, pg 38.**

Table G.3: **First recording of the Lengths of the Individual Major Sulci (see Fig 1.11, pg 38) of the frontal operculum, by Pattern. ['I' PATTERN, CASE].** [Abbreviations: sn (specimen number); x_1 (stem of the anterior rami); x_2 (anterior ascending ramus); x_3 (anterior horizontal ramus); and case (separate hemispheres)].

	RIGHT HEMISPHERE				LEFT HEMISPHERE			
	sn	**x_1**	**x_2**	**x_3**	**x_1**	**x_2**	**x_3**	**sn**
1	**18**	-	0	2.95	-	3.3	0	**30**

Table G.4: **First recording of the Lengths of the Individual Major Sulci (see Fig 1.11, pg 38) of the frontal operculum, by Pattern. ['Y' PATTERN, CASE].** [Abbreviations: sn (specimen number); x_1 (stem of the anterior rami); x_2 (anterior ascending ramus); x_3 (anterior horizontal ramus); and case (separate hemispheres)].

	RIGHT HEMISPHERE				LEFT HEMISPHERE			
	sn	**x_1**	**x_2**	**x_3**	**x_1**	**x_2**	**x_3**	**sn**
1	**3**	0.63	1.46	2.63	0.38	2.18	2.48	**2**
2	**5**	0.38	1.18	2.0	1.85	0.7	1.2	**3**
3	**7**	0.75	1.28	1.35	0.8	0.65	1.73	**6**
4	**11**	0.68	1.65	1.45	0.85	0.9	2.38	**7**
5	**21**	0.35	0.45	1.93	0.68	1.53	0.4	**8**
6					0.35	1.93	1.48	**14**
7					1.15	1.13	2.38	**15**
8					0.33	0.78	1.3	**16**
9					0.48	1.1	1.75	**21**
10					0.3	1.48	1.9	**27**

Table G.5: **First recording of the Lengths of the Individual Major Sulci (see Fig 1.11, pg 38) of the frontal operculum, by Pattern. ['V-U' PATTERN, CASE].** [Abbreviations: sn (specimen number); x_1 (stem of the anterior rami); x_2 (anterior ascending ramus); x_3 (anterior horizontal ramus); and case (separate hemispheres); n_o (notch)].

	RIGHT HEMISPHERE				LEFT HEMISPHERE			
	sn	**x_1**	**x_2**	**x_3**	**x_1**	**x_2**	**x_3**	**sn**
1	**1**	-	n_o	1.55	-	1.6	1.03	**5**
2	**4**	-	1.93	n_o	-	1.65	1.2	**9**
3	**6**	-	1.6	1.13	-	1.5	0.9	**10**
4	**8**	-	1.58	1.48	-	2.8	n_o	**11**
5	**9**	-	2.1	1.5	-	2.3	1.55	**12**
6	**10**	-	1.28	1.83	-	2.23	1.05	**13**
7	**12**	-	1.08	1.58	-	1.7	0.75	**18**
8	**13**	-	1.1	3.1	-	2.5	n_o	**19**
9	**14**	-	1.73	1.75	-	2.05	2.53	**22**
10	**15**	-	2.15	2.3	-	1.9	n_o	**23**
11	**16**	-	2.75	1.43	-	2.38	1.83	**26**
12	**17**	-	2.25	1.75	-	2.25	1.43	**28**
13	**19**	-	2.35	1.2	-	1.18	2.15	**29**
14	**20**	-	2.78	2.7	-	1.78	3.08	**87**
15	**22**	-	2.4	1.9	-	2.3	2.58	**88**
16	**23**	-	2.13	1.3				
17	**24**	-	1.78	1.05				
18	**25**	-	1.68	1.18				
19	**26**	-	1.8	1.3				
20	**28**	-	2.58	0.85				
21	**30**	-	1.53	1.38				
22	**31**	-	1.2	1.4				

G.2 LENGTHS OF THE INDIVIDUAL ACCESSORY SULCUS/ SULCI (OPERCULAR) GROUPED ACCORDING TO THE PATTERNS OF THE ANTERIOR RAMI OF THE LATERAL FISSURE

Table G.6: **Lengths of Individual Opercular sulcus/ sulci by Pattern ['Y' PATTERN, CONTROL], see Fig 1.12, pg 43.** [Abbreviations: sn (specimen number); Ope (sole opercular sulcus; Ope_1 (First opercular sulcus); Ope_2 (Second opercular sulcus); n_o (notch); d (damaged)].

	RIGHT HEMISPHERE				LEFT HEMISPHERE			
	sn	**Ope**	**Ope_1**	**Ope_2**	**Ope**	**Ope_1**	**Ope_2**	**sn**
1	**35**	-	0.9	1.25	-	-	-	**32**
2	**36**	n_o	-	-	2.28	-	-	**35**
3	**37**	n_o	-	-	-	-	-	**37**
4	**38**	d	d	d	-	1.7	0.68	**38**
5	**39**	2.2	-	-	2.35	-	-	**41**
6	**43**	2.2	-	-	1.98	-	-	**44**
7	**44**	-	-	-	-	-	-	**45**
8	**46**	2.7	-	-	0.98	-	-	**46**
9	**47**	d	-	-	-	-	-	**47**
10	**49**	-	-	-	n_o	-	-	**49**
11	**50**	1.83	-	-	-	-	-	**52**
12	**54**	0.65	-	-	1.78	-	-	**53**
13	**57**	-	0.83	1.43	3.25	-	-	**57**
14	**66**	-	-	-	2.8	-	-	**60**
15	**67**	2.43	-	-	-	-	-	**65**
16	**73**	1.93	-	-	1.9	-	-	**66**
17	**77**	-	1.08	1.3	-	-	-	**67**
18	**101**	-	-	-	0.3	-	-	**69**
19					2.4	-	-	**83**
20					1.68	-	-	**101**

Table G.7: **Lengths of Individual Opercular sulcus/ sulci by Pattern.**

['V-U' PATTERN, CONTROL], see Fig 1.12, pg 43. [Abbreviations: sn (specimen number); Ope (sole opercular sulcus); Ope_1 (First opercular sulcus); Ope_2 (Second opercular sulcus); (d (damaged)].

	RIGHT HEMISPHERE				LEFT HEMISPHERE			
	sn	**Ope**	**Ope_1**	**Ope_2**	**Ope**	**Ope_1**	**Ope_2**	**sn**
1	**32**	-	1.5	0.75	0.63	-	-	**36**
2	**40**	-	-	-	-	0.55	1.0	**39**
3	**41**	-	2.05	1.95	-	0.9	0.8	**40**
4	**42**	-	-	-	-	-	-	**42**
5	**45**	-	-	-	1.7	-	-	**43**
6	**48**	2.7	-	-	2.55	-	-	**48**
7	**52**	1.95	-	-	1.0	-	-	**50**
8	**53**	0.53	-	-	-	-	-	**54**
9	**58**	-	-	-	-	-	-	**58**
10	**59**	-	1.83	0.78	-	-	-	**59**
11	**60**	-	-	-	1.98	-	-	**61**
12	**61**	0.95	-	-	-	-	-	**62**
13	**62**	-	-	-	0.3	-	-	**69**
14	**65**	-	-	-	-	-	-	**72**
15	**69**	-	-	-	-	-	-	**73**
16	**72**	-	-	-	-	-	-	**75**
17	**75**	1.75	-	-	-	-	-	**76**
18	**76**	1.85	-	-	-	-	-	**77**
19	**78**	-	-	-	-	-	-	**78**
20	**81**	-	0.8	d	-	1.25	0.5	**81**
21	**83**	-	-	-	-	-	-	**85**
22	**85**	3.33	-	-				

Note that there was no recording for:

(a) **['I' PATTERN, CONTROL], see Fig 1.12, pg 43,** and

(b) **['I' PATTERN, CASE], see Fig 1.12, pg 43.**

Table G.8: **Lengths of Individual Opercular sulcus/ sulci by Pattern.**

['Y' PATTERN, CASE], see Fig 1.12, pg 43. [Abbreviations: sn (specimen number); Ope (sole opercular sulcus; Ope_1 (First opercular sulcus); Ope_2 (Second opercular sulcus); d (damaged)].

	RIGHT HEMISPHERE				LEFT HEMISPHERE			
	sn	**Ope**	**Ope_1**	**Ope_2**	**Ope**	**Ope_1**	**Ope_2**	**sn**
1	**3**	-	-	-	-	0.75	0.63	**2**
2	**5**	-	1.33	d	-	-	-	**3**
3	**7**	-	-	-	-	-	-	**6**
4	**11**	1.6	-	-	1.58	-	-	**7**
5	**21**	2.23	-	-	-	0.53	0.58	**8**
6					1.38	-	-	**14**
7					-	1.85	0.8	**15**
8					-	1.0	1.75	**16**
9					-	0.93	0.73	**21**
10					1.75	-	-	**27**

Table G.9: **Lengths of Individual Opercular sulcus/ sulci by Pattern. ['V-U' PATTERN, CASE], see Fig 1.12, pg 43.** [Abbreviations: sn (specimen number); Ope (sole opercular sulcus); Ope_1 (First opercular sulcus); Ope_2 (Second opercular sulcus); n_o (notch)].

	RIGHT HEMISPHERE				LEFT HEMISPHERE			
	sn	**Ope**	**Ope_1**	**Ope_2**	**Ope**	**Ope_1**	**Ope_2**	**sn**
1	**1**	2.4	-	-	2.35	-	-	**5**
2	**4**	-	-	-	-	1.43	1.53	**9**
3	**6**	-	0.38	n	0.95	-	-	**10**
4	**8**	-	0.48	0.4	0.9	-	-	**11**
5	**9**	0.73	-	-	0.78	-	-	**12**
6	**10**	-	-	-	0.85	-	-	**13**
7	**12**	2.35	-	-	2.18	-	-	**18**
8	**13**	-	1.3	1.85	-	2.75	1.1	**19**
9	**14**	-	0.48	2.65	n_o	-	-	**22**
10	**15**	-	-	-	0.45	-	-	**23**
11	**16**	-	-	-	-	2.05	1.4	**26**
12	**17**	-	-	-	0.8	-	-	**28**
13	**19**	-	0.7	3.48	-	-	-	**29**

Table G.9 continues on next page

Table G.9 continued.

	RIGHT HEMISPHERE				LEFT HEMISPHERE			
	sn	**Ope**	**Ope_1**	**Ope_2**	**Ope**	**Ope_1**	**Ope_2**	**sn**
14	**20**	-	-	-	-	-	-	**87**
15	**22**	0.65	-	-	-	-	-	**88**
16	**23**	-	1.4	2.05				
17	**24**	0.8	-	-				
18	**25**	-	0.73	3.53				
19	**26**	3.43	-	-				
20	**28**	-	-					
21	**30**	1.43	-	-				
22	**31**	-	-	-				

G.3 LENGTHS OF THE INDIVIDUAL ACCESSORY SULCUS/ SULCI (TRIANGULAR) GROUPED ACCORDING TO THE PATTERNS OF THE ANTERIOR RAMI OF THE LATERAL FISSURE

Note that there was no recording for:

(a) **['I' PATTERN, CONTROL], see Fig 1.12, pg 43,** and

(b) **['I' PATTERN, CASE], see Fig 1.12, pg 43.**

Table G.10: **Lengths of Individual Triangular sulcus/ sulci by Pattern ['Y' PATTERN, CONTROL], (see Fig 1.12, pg 43).** [Abbreviations: sn (specimen number); Tri (sole triangular sulcus); $Tria_{2/3}$ (Anterior triangular sulcus when the triangular sulcus was present as either two or three sulci); Trim (Middle of three triangular sulci); $Trip_{2/3}$ (Posterior triangular sulcus when the triangular sulcus was present as either two or three sulci); n_o (notch)].

	RIGHT HEMISPHERE					LEFT HEMISPHERE				
	sn	**Tri**	**$Tria_{2/3}$**	**Trim**	**$Trip_{2/3}$**	**Tri**	**$Tria_{2/3}$**	**Trim**	**$Trip_{2/3}$**	**sn**
1	**35**	-	-	-	-	1.18	-	-	-	**32**
2	**36**	0.6	-	-	-	1.55	-	-	-	**35**
3	**37**	0.85	-	-	-	1.38	-	-	-	**37**
4	**38**	-	-	-	-	-	-	-	-	**38**
5	**39**	1.05	-	-	-	-	0.58	1.7	0.78	**41**
6	**43**	-	-	-	-	n_o	-	-	-	**44**
7	**44**	-	-	-	-	-	-	-	-	**45**
8	**46**	-	-	-	-	1.63	-	-	-	**46**
9	**47**	-	-	-	-	-	-	-	-	**47**
10	**49**	0.98	-	-	-	-	-	-	-	**49**
11	**50**	-	-	-	-	1.55	-	-	-	**52**
12	**54**	1.65	-	-	-	-	-	-	-	**53**
13	**57**	-	1.5	-	2.08	-	-	-	-	**57**
14	**66**	1.55	-	-	-	1.3	-	-	-	**60**
15	**67**	-	0.78	-	0.53	1.0	-	-	-	**65**
16	**73**	1.03	-	-	-	1.25	-	-	-	**66**
17	**77**	1.23	-	-	-	0.73	-	-	-	**67**
18	**101**	0.88	-	-	-	0.55	-	-	-	**83**
19						0.63	-	-	-	**101**

Table G.11: **Lengths of Individual Triangular sulcus/ sulci by Pattern. ['V-U' PATTERN, CONTROL], see Fig 1.12, pg 43.** [Abbreviations: sn (specimen number); Tri (sole triangular sulcus); $Tria_{2/3}$ (Anterior triangular sulcus when the triangular sulcus was present as either two or three sulci); Trim (Middle of three triangular sulci); $Trip_{2/3}$ (Posterior triangular sulcus when the triangular sulcus was present as either two or three sulci); n_o (notch)].

	RIGHT HEMISPHERE					LEFT HEMISPHERE				
	sn	**Tri**	**$Tria_{2/3}$**	**Trim**	**$Trip_{2/3}$**	**Tri**	**$Tria_{2/3}$**	**Trim**	**$Trip_{2/3}$**	**sn**
1	**32**	-	4.0	-	1.55	2.36	-	-	-	**36**
2	**40**	1.38	-	-	-	-	0.83	-	1.38	**39**
3	**41**	2.78	-	-	-	-	1.4	-	1.33	**40**
4	**42**	-	0.88	2.15	0.53	1.03	-	-	-	**42**
5	**45**	0.9	-	-	-	-	0.75	2.18	n_o	**43**
6	**48**	2.08	-	-	-	1.78	-	-	-	**48**
7	**52**	-	0.73	2.88	0.58	2.75	-	-	-	**50**
8	**53**	1.78	-	-	-	0.75	-	-	-	**54**
9	**58**	-	2.0	-	0.45	-	1.98	-	1.4	**58**
10	**59**	1.05	-	-	-	2.48	-	-	-	**59**
11	**60**	-	-	-	-	-	-	-	-	**61**
12	**61**	-	0.6	1.5	0.4	0.83	-	-	-	**62**
13	**62**	-	1.48	-	0.6	-	2.55	-	0.53	**69**
14	**65**	1.95	-	-	-	1.78	-	-	-	**72**
15	**69**	-	0.78	-	1.28	n_o	-	-	-	**73**
16	**72**	-	0.73	-	0.88	-	0.55	-	0.6	**75**
17	**75**	-	0.8	-	1.28	-	0.75	2.15	0.65	**76**
18	**76**	2.65	-	-	-	1.08	-	-	-	**77**
19	**78**	1.65	-	-	-	2.28	-	-	-	**78**
20	**81**	1.2	-	-	-	1.38	-	-	-	**81**
21	**83**	-	0.85	2.28	1.95	-	1.5	2.45	1.1	**85**
22	**85**	2.68	-	-	-					

Table G.12: **Lengths of Individual Triangular sulcus/ sulci by Pattern ['Y' PATTERN, CASE], see Fig 1.12, pg 43.** [Abbreviations: sn (specimen number); Tri (sole triangular sulcus); $Tria_{2/3}$ (Anterior triangular sulcus when the triangular sulcus was present as either two or three sulci); Trim (Middle of three triangular sulci); $Trip_{2/3}$ (Posterior triangular sulcus when the triangular sulcus was present as either two or three sulci); d (damaged)].

	RIGHT HEMISPHERE					LEFT HEMISPHERE				
	sn	**Tri**	**$Tria_{2/3}$**	**Trim**	**$Trip_{2/3}$**	**Tri**	**$Tria_{2/3}$**	**Trim**	**$Trip_{2/3}$**	**sn**
1	**3**	0.83	-	-	-	0.45	-	-	-	**2**
2	**5**	1.33	-	-	-	1.05	-	-	-	**3**
3	**7**	1.05	-	-	-	-	-	-	-	**6**
4	**11**	-	-	-	-	0.45	-	-	-	**7**
5	**21**	1.33	-	-	-	1.13	-	-	-	**8**
6						-	1.93	-	1.45	**14**
7						0.88	-	-	-	**15**
8						-	-	-	-	**16**
9						d	-	-	-	**21**
10						-	0.43	-	2.35	**27**

Table G.13: **Lengths of Individual Triangular sulcus/ sulci by Pattern ['V-U' PATTERN, CASE], see Fig 1.12, pg 43.** [Abbreviations: sn (specimen number); Tri (sole triangular sulcus); $Tria_{2/3}$ (Anterior triangular sulcus when the triangular sulcus was present as either two or three sulci); Trim (Middle of three triangular sulci); $Trip_{2/3}$ (Posterior triangular sulcus when the triangular sulcus was present as either two or three sulci); n_o (notch); d (damaged)].

	RIGHT HEMISPHERE					LEFT HEMISPHERE				
	sn	**Tri**	**$Tria_{2/3}$**	**Trim**	**$Trip_{2/3}$**	**Tri**	**$Tria_{2/3}$**	**Trim**	**$Trip_{2/3}$**	**sn**
1	**1**	-	0.8	-	1.85	-	1.45	-	0.73	**5**
2	**4**	1.95	-	-	-	-	-	-	-	**9**
3	**6**	1.13	-	-	-	1.35	-	-	-	**10**
4	**8**	n_o	-	-	-	-	0.48	-	3.35	**11**
5	**9**	-	2.4	-	0.85	-	2.95	1.25	1.33	**12**
6	**10**	1.63	-	-	-	1.5	-	-	-	**13**
7	**12**	2.0	-	-	-	-	d	-	1.73	**18**
8	**13**	1.15	-	-	-	-	1.05	-	3.73	**19**
9	**14**	-	0.8	-	1.23	1.45	-	-	-	**22**
10	**15**	-	1.08	-	1.65	1.8	-	-	-	**23**
11	**16**	-	2.23	-	1.6	1.88	-	-	-	**26**
12	**17**	1.1	-	-	-	d	d	d	d	**28**
13	**19**	-	1.53	-	1.28	2.25	-	-	-	**29**
14	**20**	1.45	-	-	-	-	0.63	1.8	0.75	**87**
15	**22**	1.4	-	-	-	-	0.95	-	1.55	**88**
16	**23**	-	d	-	d					
17	**24**	-	1.55	-	0.7					
18	**25**	2.93	-	-	-					
19	**26**	-	1.0	-	0.73					
20	**28**	-	4.35	-	1.28					
21	**30**	d	-	-	-					
22	**31**	1.35	-	-	-					

APPENDIX H

H.1 RECORD OF INTERSULCAL LENGTHS ANTERIOR TO THE ANTERIOR ASCENDING RAMUS (AAR)

Table H.1: First recording of intersulcal lengths in the right frontoparietal operculum, anterior to the anterior ascending ramus (AAR) in the control category.

[Abbreviations: sn (specimen number); anterior horizontal ramus (AHR); Tri (sole triangular sulcus); $Tria_{2/3}$ (Anterior triangular sulcus when the triangular sulcus was present as either two or three sulci); Trim (Middle of three triangular sulci); $Trip_{2/3}$ (Posterior triangular sulcus when the triangular sulcus was present as either two or three sulci)].

	sn	AAR - AHR	AAR - Tri	AAR – $Tra_{2/3}$	AAR – Trm	AAR – $Trp_{2/3}$
1						
2	35	**0.8**	-	-	-	-
3	36	**1.7**	-	-	-	-
4	37	**1.9**	**0.9**	-	-	-
5	38	**1.5**	-	-	-	-
6	40	**2.3**	**0.8**	-	-	-
7	41	**2.3**	**1.3**	-	-	-
8	43	**0.6**	-	-	-	-
9	46	**1.3**	-	-	-	-
10	47	**1.4**	-	-	-	-
11	48	**2.4**	**0.9**	-	-	-
12	49	**2.1**	**1.5**	-	-	-
13	50	**0.9**	-	-	-	-
14	53	**2.9**	**1.9**	-	-	-
15	54	**2.1**	**0.7**	-	-	-
16	58	**2.6**	-	**1.9**	-	-
17	59	**1.8**	**0.6**	-	-	-
18	60	**2.1**	**0.9**	-	-	-
19	61	**1.9**	-	-	**1.1**	-
20	62	**1.9**	**1.2**	-	-	-
21	66	**2.5**	**1.1**	-	-	-

Table H.1 continued on next page.

Table H.1 continued						
	sn	**AAR - AHR**	**AAR - Tri**	**AAR – $Tra_{2/3}$**	**AAR – Trm**	**AAR – $Trp_{2/3}$**
22	67	**2.0**	-	-	-	-
23	69	**3.0**	-	-	**2.1**	**1.4**
24	70	**1.3**	-	-	-	-
25	73	**1.6**	-	-	-	-
26	74	**1.6**	**0.8**	-	-	-
27	75	**3.0**	-	-	-	-
28	76	**1.3**	-	**0.7**	-	**0.2**
29	77	**1.2**	-	-	-	-
30	78	**2.0**	**1.2**	-	-	-
31	79	**2.0**	**1.0**	-	-	-
32	80	**2.4**	-	-	-	**1.1**
33	83	**2.5**	**1.0**	-	-	-
34	84	**2.1**	**0.2**	-	-	-

Table H.2: Second recording of intersulcal lengths in the right fronto-parietal operculum, anterior to the AAR (control category)

[Abbreviations: sn (specimen number); anterior horizontal ramus (AHR); Tri (sole triangular sulcus); $Tria_{2/3}$ (Anterior triangular sulcus when the triangular sulcus was present as either two or three sulci); Trim (Middle of three triangular sulci); $Trip_{2/3}$ (Posterior triangular sulcus when the triangular sulcus was present as either two or three sulci)].

	sn	**AAR - AHR**	**AAR - Tri**	**AAR – $Tra_{2/3}$**	**AAR – Trm**	**AAR – $Trp_{2/3}$**
1						
2	35	**0.8**	-	-	-	-
3	36	**1.5**	-	-	-	-
4	37	**1.9**	**1.0**	-	-	-
5	38	**1.4**	-	-	-	-
6	40	**2.1**	**0.8**	-	-	-
7	41	**2.3**	**1.3**	-	-	-
8	43	**0.6**	-	-	-	-
Table H.2 continued on next page						

Table H.2 continued

	sn	AAR - AHR	AAR - Tri	AAR – $Tra_{2/3}$	AAR – Trm	AAR – $Trp_{2/3}$
9	46	**1.3**	-	-	-	-
10	47	**1.3**	-	-	-	-
11	48	**2.3**	**0.8**	-	-	-
12	49	**2.0**	**1.5**	-	-	-
13	50	**0.9**	-	-	-	-
14	53	**2.8**	**1.8**	-	-	-
15	54	**2.1**	**0.7**	-	-	-
16	58	**2.6**	**1.8**	-	-	-
17	59	**1.8**	**0.6**	-	-	-
18	60	**2.1**	**0.9**	-	-	-
19	61	**1.9**	**1.2**	-	-	-
20	62	**1.9**	**1.1**	-	-	-
21	66	**2.5**	**1.1**	-	-	-
22	67	**1.9**	-	-	-	-
23	69	**3.1**	-	-	**2.2**	**1.5**
24	70	**1.4**	-	-	-	-
25	73	**1.5**	-	-	-	-
26	74	**1.6**	**0.8**	-	-	-
27	75	**2.9**	-	-	-	-
28	76	**1.3**	**0.8**	-	-	-
29	77	**1.1**	-	-	-	-
30	78	**2.1**	**1.3**	-	-	-
31	79	**2.1**	**1.0**	-	-	-
32	80	**2.4**	**1.1**	-	-	-
33	83	**2.4**	**1.1**	-	-	-
34	84	**2.2**	**0.2**	-	-	-

Table H.3: Composite recording of intersulcal lengths in the right fronto-parietal operculum, anterior to the AAR (control category)

[Abbreviations: sn (specimen number); anterior horizontal ramus (AHR); Tri (sole triangular sulcus); $Tria_{2/3}$ (Anterior triangular sulcus when the triangular sulcus was present as either two or three sulci); Trim (Middle of three triangular sulci); $Trip_{2/3}$ (Posterior triangular sulcus when the triangular sulcus was present as either two or three sulci)].

	sn	AAR - AHR	AAR - Tri	AAR – $Tra_{2/3}$	AAR – Trm	AAR – $Trp_{2/3}$
1						
2	35	**0.8**	-	-	-	-
3	36	**1.5**	-	-	-	-
4	37	**1.9**	**1.0**	-	-	-
5	38	**1.4**	-	-	-	-
6	40	**2.1**	**0.8**	-	-	-
7	41	**2.3**	**1.3**	-	-	-
8	43	**0.6**	-	-	-	-
9	46	**1.3**	-	-	-	-
10	47	**1.3**	-	-	-	-
11	48	**2.3**	**0.8**	-	-	-
12	49	**2.0**	**1.5**	-	-	-
13	50	**0.9**	-	-	-	-
14	53	**2.8**	**1.8**	-	-	-
15	54	**2.1**	**0.7**	-	-	-
16	58	**2.6**	**1.8**	-	-	-
17	59	**1.8**	**0.6**	-	-	-
18	60	**2.1**	**0.9**	-	-	-
19	61	**1.9**	**1.2**	-	-	-
20	62	**1.9**	**1.1**	-	-	-
21	66	**2.5**	**1.1**	-	-	-
22	67	**1.9**	-	-	-	-
23	69	**3.1**	-	-	**2.2**	**1.5**
24	70	**1.4**	-	-	-	-
25	73	**1.5**	-	-	-	-
26	74	**1.6**	**0.8**	-	-	-
27	75	**2.9**	-	-	-	-
28	76	**1.3**	**0.8**	-	-	-
29	77	**1.1**	-	-	-	-
30	78	**2.1**	**1.3**	-	-	-

Table H.3 continued on next page

Table H.3 continued						
	sn	**AAR - AHR**	**AAR - Tri**	**AAR – $Tra_{2/3}$**	**AAR – Trm**	**AAR – $Trp_{2/3}$**
31	79	**2.1**	**1.0**	-	-	-
32	80	**2.4**	**1.1**	-	-	-
33	83	**2.4**	**1.1**	-	-	-
34	84	**2.2**	**0.2**	-	-	-

Table H.4: First recording of intersulcal lengths in the left frontoparietal operculum, anterior to the AAR (control category)

[Abbreviations: sn (specimen number); anterior horizontal ramus (AHR); Tri (sole triangular sulcus); $Tria_{2/3}$ (Anterior triangular sulcus when the triangular sulcus was present as either two or three sulci); Trim (Middle of three triangular sulci); $Trip_{2/3}$ (Posterior triangular sulcus when the triangular sulcus was present as either two or three sulci)].

	sn	**AAR - AHR**	**AAR - Tri**	**AAR – $Tra_{2/3}$**	**AAR – Trm**	**AAR – $Trp_{2/3}$**
1	32	**1.7**	**0.8**	-	-	-
2	35	**1.5**	**0.6**	-	-	-
3	36	**2.3**	**1.6**	-	-	-
4	37	**1.6**	**0.7**	-	-	-
5	38	**1.0**	-	-	-	-
6	39	**2.8**	**1.3**	-	-	-
7	40	**1.7**	**1.1**	-	-	-
8	41	**1.9**	**0.9**	-	-	-
9	42	**2.1**	**1.1**	-	-	-
10	43	**2.8**	-	-	-	-
11	45	**1.5**	-	-	-	-
12	46	**1.1**	-	-	-	-
13	47	**1.6**	-	-	-	-
14	48	**2.1**	**0.9**	-	-	-
15	49	**1.5**	-	-	-	-
16	50	**2.4**	**0.9**	-	-	-
17	52	**1.6**	-	-	-	-
18	53	**1.7**	-	-	-	-

Table H.4 continued on next page

Table H.4 continued						
	sn	**AAR - AHR**	**AAR - Tri**	**AAR – $Tra_{2/3}$**	**AAR – Trm**	**AAR – $Trp_{2/3}$**
19	54	**1.9**	**0.9**	-	-	-
20	55	**1.8**	-	-	-	-
21	57	**1.2**	-	-	-	-
22	58	**2.9**	**1.6**	-	-	-
23	59	**2.3**	**0.9**	-	-	-
24	60	**1.7**	-	-	-	-
25	61	**1.4**	-	-	-	-
26	62	**2.5**	**1.6**	-	-	-
27	63	**3.5**	-	**2.3**	-	**1.4**
28	65	**1.5**	-	-	-	-
29	66	**1.5**	**0.8**	-	-	-
30	67	**1.9**	**0.8**	-	-	-
31	69	**1.9**	-	**1.0**	-	-
32	71	**2.0**	**1.1**	-	-	-
33	72	**2.8**	**1.6**	-	-	-
34	74	**2.2**	**1.0**	-	-	-
35	75	**2.1**	**1.2**	-	-	-
36	78	**2.2**	**1.5**	-	-	-
37	79	**2.2**	**1.4**	-	-	-
38	80	**2.7**	**1.8**	-	-	-
39	83	**1.2**	-	-	-	-
40	84	**1.9**	-	**1.1**	-	**0.2**
41	85	**2.7**	-	**2.0**	**1.4**	**0.8**
42	86	**3.2**	-	**2.4**	-	**1.7**

Table H.5: Second recording of intersulcal lengths in the left fronto-parietal operculum, anterior to the AAR (control category)

[Abbreviations: sn (specimen number); anterior horizontal ramus (AHR); Tri (sole triangular sulcus); $Tria_{2/3}$ (Anterior triangular sulcus when the triangular sulcus was present as either two or three sulci); Trim (Middle of three triangular sulci); $Trip_{2/3}$ (Posterior triangular sulcus when the triangular sulcus was present as either two or three sulci)].

	sn	AAR - AHR	AAR - Tri	AAR – $Tra_{2/3}$	AAR – Trm	AAR – $Trp_{2/3}$
1	32	**1.8**	**0.8**	-	-	-
2	35	**1.6**	**0.6**	-	-	-
3	36	**2.4**	**1.6**	-	-	-
4	37	**1.6**	**0.7**	-	-	-
5	38	**1.0**	-	-	-	-
6	39	**2.8**	**1.3**	-	-	-
7	40	**1.7**	**1.1**	-	-	-
8	41	**2.0**	**0.9**	-	-	-
9	42	**2.2**	**1.2**	-	-	-
10	43	**2.6**	-	-	-	-
11	45	**1.5**	-	-	-	-
12	46	**1.1**	-	-	-	-
13	47	**1.6**	-	-	-	-
14	48	**2.0**	**0.9**	-	-	-
15	49	**1.5**	-	-	-	-
16	50	**2.5**	**0.8**	-	-	-
17	52	**1.5**	-	-	-	-
18	53	**1.6**	-	-	-	-
19	54	**1.8**	**1.2**	-	-	-
20	55	**1.7**	-	-	-	-
21	57	**1.3**	-	-	-	-
22	58	**2.9**	**1.6**	-	-	-
23	59	**2.3**	**0.9**	-	-	-
24	60	**1.8**	-	-	-	-
25	61	**1.3**	-	-	-	-
26	62	**2.5**	**1.6**	-	-	-
27	63	**3.4**	-	**2.2**	-	**1.5**
28	65	**1.6**	-	-	-	-
29	66	**1.5**	**0.7**	-	-	-
30	67	**1.8**	**0.7**	-	-	-

Table H.5 continued on next page

Table H.5						
	sn	**AAR - AHR**	**AAR - Tri**	**AAR – $Tra_{2/3}$**	**AAR – Trm**	**AAR – $Trp_{2/3}$**
31	69	**2.0**	**-**	**1.0**	**-**	**-**
32	71	**2.1**	**1.1**	**-**	**-**	**-**
33	72	**2.9**	**1.7**	**-**	**-**	**-**
34	74	**2.1**	**0.9**	**-**	**-**	**-**
35	75	**2.1**	**1.3**	**-**	**-**	**-**
36	78	**2.3**	**1.7**	**-**	**-**	**-**
37	79	**2.1**	**1.3**	**-**	**-**	**-**
38	80	**2.6**	**1.8**	**-**	**-**	**-**
39	83	**1.3**	**-**	**-**	**-**	**-**
40	84	**1.8**	**-**	**1.0**	**-**	**0.15**
41	85	**2.8**	**-**	**2.1**	**1.5**	**0.9**
42	86	**3.3**	**-**	**2.3**	**-**	**1.7**

Table H.6: Composite recording of intersulcal lengths in the left fronto-parietal operculum, anterior to the AAR (control category)

[Abbreviations: sn (specimen number); anterior horizontal ramus (AHR); Tri (sole triangular sulcus); $Tria_{2/3}$ (Anterior triangular sulcus when the triangular sulcus was present as either two or three sulci); Trim (Middle of three triangular sulci); $Trip_{2/3}$ (Posterior triangular sulcus when the triangular sulcus was present as either two or three sulci)].

	sn	**AAR - AHR**	**AAR - Tri**	**AAR – $Tra_{2/3}$**	**AAR – Trm**	**AAR – $Trp_{2/3}$**
1	32	**1.8**	**0.8**	**-**	**-**	**-**
2	35	**1.6**	**0.6**	**-**	**-**	**-**
3	36	**2.4**	**1.6**	**-**	**-**	**-**
4	37	**1.6**	**0.7**	**-**	**-**	**-**
5	38	**1.0**	**-**	**-**	**-**	**-**
6	39	**2.8**	**1.3**	**-**	**-**	**-**
7	40	**1.7**	**1.1**	**-**	**-**	**-**
8	41	**2.0**	**0.9**	**-**	**-**	**-**
9	42	**2.2**	**1.2**	**-**	**-**	**-**
10	43	**2.6**	**-**	**-**	**-**	**-**
11	45	**1.5**	**-**	**-**	**-**	**-**

Table H.6 continued on next page

Table H.6 continued

	sn	AAR - AHR	AAR - Tri	AAR – $Tra_{2/3}$	AAR – Trm	AAR – $Trp_{2/3}$
12	46	**1.1**	-	-	-	-
13	47	**1.6**	-	-	-	-
14	48	**2.0**	**0.9**	-	-	-
15	49	**1.5**	-	-	-	-
16	50	**2.5**	**0.8**	-	-	-
17	52	**1.5**	-	-	-	-
18	53	**1.6**	-	-	-	-
19	54	**1.8**	**1.2**	-	-	-
20	55	**1.7**	-	-	-	-
21	57	**1.3**	-	-	-	-
22	58	**2.9**	**1.6**	-	-	-
23	59	**2.3**	**0.9**	-	-	-
24	60	**1.8**	-	-	-	-
25	61	**1.3**	-	-	-	-
26	62	**2.5**	**1.6**	-	-	-
27	63	**3.4**	-	**2.2**	-	**1.5**
28	65	**1.6**	-	-	-	-
29	66	**1.5**	**0.7**	-	-	-
30	67	**1.8**	**0.7**	-	-	-
31	69	**2.0**	-	**1.0**	-	-
32	71	**2.1**	**1.1**	-	-	-
33	72	**2.9**	**1.7**	-	-	-
34	74	**2.1**	**0.9**	-	-	-
35	75	**2.1**	**1.3**	-	-	-
36	78	**2.3**	**1.7**	-	-	-
37	79	**2.1**	**1.3**	-	-	-
38	80	**2.6**	**1.8**	-	-	-
39	83	**1.3**	-	-	-	-
40	84	**1.8**	-	**1.0**	-	**0.15**
41	85	**2.8**	-	**2.1**	**1.5**	**0.9**
42	86	**3.3**	-	**2.3**	-	**1.7**

Table H.7: First recording of intersulcal lengths in the right frontoparietal operculum, anterior to the AAR (case category)

[Abbreviations: sn (specimen number); anterior horizontal ramus (AHR); Tri (sole triangular sulcus); $Tria_{2/3}$ (Anterior triangular sulcus when the triangular sulcus was present as either two or three sulci); Trim (Middle of three triangular sulci); $Trip_{2/3}$ (Posterior triangular sulcus when the triangular sulcus was present as either two or three sulci)].

	sn	AAR - AHR	AAR - Tri	AAR – $Tra_{2/3}$	AAR – Trm	AAR – $Trp_{2/3}$
1	3	**2.1**	**0.9**	-	-	-
2	6	**1.8**	**0.8**	-	-	-
3	7	**1.6**	-	-	-	-
4	9	**2.1**	-	**0.8**	-	**0.4**
5	10	**1.6**	**0.9**	-	-	-
6	11	**2.1**	-	-	-	-
7	15	**2.4**	-	**1.1**	-	**0.9**
8	16	**2.5**	-	**1.7**	-	**0.9**
9	17	**2.3**	**1.7**	-	-	-
10	19	**2.1**	-	**1.6**	-	**0.9**
11	20	**2.6**	**1.6**	-	-	-
12	21	**1.8**	-	-	-	-
13	26	**1.6**	-	**1.1**	-	-
14	30	**1.8**	**0.7**	-	-	-
15	31	**1.4**	**0.8**	-	-	-

Table H.8: Second recording of intersulcal lengths in the right fronto-parietal operculum, anterior to the AAR (case category)

[Abbreviations: sn (specimen number); anterior horizontal ramus (AHR); Tri (sole triangular sulcus); $Tria_{2/3}$ (Anterior triangular sulcus when the triangular sulcus was present as either two or three sulci); Trim (Middle of three triangular sulci); $Trip_{2/3}$ (Posterior triangular sulcus when the triangular sulcus was present as either two or three sulci)].

	sn	AAR - AHR	AAR - Tri	AAR – $Tra_{2/3}$	AAR – Trm	AAR – $Trp_{2/3}$
1	3	**2.0**	**1.0**	-	-	-
2	6	**1.6**	**0.7**	-	-	-
3	7	**1.6**	-	-	-	-
4	9	**2.0**	-	**0.8**	-	**0.3**
5	10	**1.6**	**0.9**	-	-	-
6	11	**2.1**	-	-	-	-
7	15	**2.4**	-	**1.0**	-	**0.8**
8	16	**2.4**	-	**1.6**	-	**0.9**
9	17	**2.3**	**1.6**	-	-	-
10	19	**2.0**	-	**1.6**	-	**0.9**
11	20	**2.7**	**1.7**	-	-	-
12	21	**1.7**	-	-	-	-
13	26	**1.6**	-	**1.1**	-	-
14	30	**1.8**	**0.7**	-	-	-
15	31	**1.5**	**0.8**	-	-	-

Table H.9: Composite recording of intersulcal lengths in the right fronto-parietal operculum, anterior to the AAR (case category)

[Abbreviations: sn (specimen number); anterior horizontal ramus (AHR); Tri (sole triangular sulcus); $Tria_{2/3}$ (Anterior triangular sulcus when the triangular sulcus was present as either two or three sulci); Trim (Middle of three triangular sulci); $Trip_{2/3}$ (Posterior triangular sulcus when the triangular sulcus was present as either two or three sulci)].

	sn	AAR - AHR	AAR - Tri	AAR – $Tra_{2/3}$	AAR – Trm	AAR – $Trp_{2/3}$
1	3	**2.0**	**1.0**	-	-	-
2	6	**1.6**	**0.7**	-	-	-
3	7	**1.6**	-	-	-	-
4	9	**2.0**	-	**0.8**	-	**0.3**
5	10	**1.6**	**0.9**	-	-	-
6	11	**2.1**	-	-	-	-
7	15	**2.4**	-	**1.0**	-	**0.8**
8	16	**2.4**	-	**1.6**	-	**0.9**
9	17	**2.3**	**1.6**	-	-	-
10	19	**2.0**	-	**1.6**	-	**0.9**
11	20	**2.7**	**1.7**	-	-	-
12	21	**1.7**	-	-	-	-
13	26	**1.6**	-	**1.1**	-	-
14	30	**1.8**	**0.7**	-	-	-
15	31	**1.5**	**0.8**	-	-	-

Table H.10: First recording of intersulcal lengths in the left frontoparietal operculum, anterior to the AAR (case category)

[Abbreviations: sn (specimen number); anterior horizontal ramus (AHR); Tri (sole triangular sulcus); $Tria_{2/3}$ (Anterior triangular sulcus when the triangular sulcus was present as either two or three sulci); Trim (Middle of three triangular sulci); $Trip_{2/3}$ (Posterior triangular sulcus when the triangular sulcus was present as either two or three sulci)].

	sn	AAR - AHR	AAR - Tri	AAR – $Tra_{2/3}$	AAR – Trm	AAR – $Trp_{2/3}$
1	2	**2.15**	**0.8**	-	-	-
2	3	**1.0**	-	-	-	-
3	6	**1.5**	-	-	-	-
4	7	**1.5**	-	-	-	-
5	8	**1.3**	-	-	-	-
6	9	**1.9**	**0.8**	-	-	-
7	10	**2.1**	-	-	-	-
8	13	**2.6**	**1.1**	-	-	-
9	14	**1.8**	-	**1.1**	-	**0.5**
10	15	**2.0**	**1.0**	-	-	-
11	16	**0.9**	-	-	-	-
12	21	**1.4**	-	-	-	-
13	22	**2.0**	**1.1**	-	-	-
14	23	**1.4**	-	-	-	-
15	26	**2.9**	**0.8**	-	-	-
16	27	**1.5**	**0.6**	-	-	-
17	28	**2.9**	**1.6**	-	-	-
18	29	**2.8**	**1.5**	-	-	-
19	30	-	-	-	-	-

Table H.11: Second recording of intersulcal lengths in the left fronto-parietal operculum, anterior to the AAR (case category)

[Abbreviations: sn (specimen number); anterior horizontal ramus (AHR); Tri (sole triangular sulcus); $Tria_{2/3}$ (Anterior triangular sulcus when the triangular sulcus was present as either two or three sulci); Trim (Middle of three triangular sulci); $Trip_{2/3}$ (Posterior triangular sulcus when the triangular sulcus was present as either two or three sulci)].

	sn	AAR - AHR	AAR - Tri	AAR – $Tra_{2/3}$	AAR – Trm	AAR – $Trp_{2/3}$
1	2	**2.1**	**0.9**	-	-	-
2	3	**1.0**	-	-	-	-
3	6	**1.5**	-	-	-	-
4	7	**1.5**	-	-	-	-
5	8	**1.3**	-	-	-	-
6	9	**1.7**	**0.8**	-	-	-
7	10	**2.1**	-	-	-	-
8	13	**2.5**	**1.0**	-	-	-
9	14	**1.8**	-	**1.1**	-	**0.5**
10	15	**2.0**	**1.0**	-	-	-
11	16	**0.9**	-	-	-	-
12	21	**1.4**	-	-	-	-
13	22	**2.0**	**1.1**	-	-	-
14	23	**1.4**	-	-	-	-
15	26	**3.0**	**0.8**	-	-	-
16	27	**1.4**	**0.5**	-	-	-
17	28	**2.8**	**1.6**	-	-	-
18	29	**2.7**	**1.4**	-	-	-
19	30	-	-	-	-	-

Table H.12: Composite recording of intersulcal lengths in the left fronto-parietal operculum, anterior to the AAR (case category)

[Abbreviations: sn (specimen number); anterior horizontal ramus (AHR); Tri (sole triangular sulcus); $Tria_{2/3}$ (Anterior triangular sulcus when the triangular sulcus was present as either two or three sulci); Trim (Middle of three triangular sulci); $Trip_{2/3}$ (Posterior triangular sulcus when the triangular sulcus was present as either two or three sulci)].

	sn	AAR - AHR	AAR - Tri	AAR – $Tra_{2/3}$	AAR – Trm	AAR – $Trp_{2/3}$
1	2	**2.1**	**0.9**	-	-	-
2	3	**1.0**	-	-	-	-
3	6	**1.5**	-	-	-	-
4	7	**1.5**	-	-	-	-
5	8	**1.3**	-	-	-	-
6	9	**1.7**	**0.8**	-	-	-
7	10	**2.1**	-	-	-	-
8	13	**2.5**	**1.0**	-	-	-
9	14	**1.8**	-	**1.1**	-	**0.5**
10	15	**2.0**	**1.0**	-	-	-
11	16	**0.9**	-	-	-	-
12	21	**1.4**	-	-	-	-
13	22	**2.0**	**1.1**	-	-	-
14	23	**1.4**	-	-	-	-
15	26	**3.0**	**0.8**	-	-	-
16	27	**1.4**	**0.5**	-	-	-
17	28	**2.8**	**1.6**	-	-	-
18	29	**2.7**	**1.4**	-	-	-
19	30	-	-	-	-	-

H2 RECORD OF INTERSULCAL LENGTHS POSTERIOR TO THE ANTERIOR ASCENDING RAMUS

Table H.13: First recording of intersulcal lengths in the right fronto-parietal operculum, posterior to the AAR (control category)

[Abbreviations: IPRCS (inferior precentral sulcus); CF (central fissure); IPOCS (inferior postcentral sulcus); Op (sole opercular sulcus); Op_1 (first opercular sulcus); Op_2 (second opercular sulcus)].

	sn	AAR - IPRCS	IPRCS - CF	CF – IPOCS	AAR – Op	AAR – Op_1	AAR – Op_2
1	32	**1.5**	**1.6**	**1.6**	**0.7**	-	-
2	35	**2.1**	**1.8**	**1.3**	**0.8**	-	-
3	36	**1.2**	**1.8**	**1.4**	-	-	-
4	37	**0.5**	**1.1**	**1.8**	-	-	-
5	38	**2.3**	**1.7**	**1.4**	**0.6**	-	-
6	39	**2.4**	**1.5**	**1.5**	-	**0.8**	**0.9**
7	40	**0.9**	**1.4**	**1.0**	-	-	-
8	41	**1.8**	**1.3**	**1.4**	-	**0.4**	**0.9**
9	42	**0.9**	**2.4**	**1.2**	-	-	-
10	43	**1.6**	**1.6**	**2.0**	**0.8**	-	-
11	45	**0.8**	**1.5**	**1.1**	-	-	-
12	46	**1.8**	**1.0**	**1.9**	**0.8**	-	-
13	47	**1.0**	**1.8**	**2.3**	-	-	-
14	48	**1.4**	**1.3**	**2.3**	**0.7**	-	-
15	49	**0.6**	**1.9**	**1.0**	-	-	-
16	50	**1.7**	**2.0**	**1.6**	**0.7**	-	-
17	52	**1.2**	**2.6**	**1.4**	**0.7**	-	-
18	53	**1.2**	**1.7**	**1.1**	**0.6**	-	-
19	54	**1.6**	**0.8**	**2.2**	-	-	-
20	55	**2.5**	**1.1**	**2.3**	**2.0**	-	-
21	57	**1.9**	**1.4**	**2.0**	-	-	-
22	58	**0.4**	**1.2**	**1.1**	-	-	-
23	59	**1.7**	**1.7**	**1.6**	-	-	-
24	60	**0.8**	**0.9**	**1.2**	-	-	-
25	61	**0.5**	**1.3**	**1.7**	**0.3**	-	-
26	62	**0.8**	**1.4**	**2.6**	-	-	-

Table H.13 continued on next page

Table H.13 continued

	sn	AAR - IPRCS	IPRCS - CF	CF – IPOCS	AAR – Op	AAR – Op_1	AAR – Op_2
27	65	**0.7**	**1.2**	**1.6**	**-**	**-**	**-**
28	66	**0.8**	**1.3**	**-**	**-**	**-**	**-**
29	67	**2.2**	**0.6**	**1.6**	**0.4**	**-**	**-**
30	69	**0.6**	**0.7**	**2.1**	**-**	**-**	**-**
31	70	**1.9**	**1.9**	**0.9**	**0.8**	**-**	**-**
32	71	**1.4**	**1.3**	**2.0**	**0.6**	**-**	**-**
33	72	**1.3**	**1.7**	**2.0**	**-**	**-**	**-**
34	73	**0.4**	**1.2**	**2.4**	**-**	**-**	**-**
35	74	**0.5**	**1.1**	**2.2**	**-**	**-**	**-**
36	75	**1.0**	**1.1**	**1.2**	**0.4**	**-**	**-**
37	76	**0.6**	**1.6**	**-**	**0.2**	**-**	**-**
38	77	**1.2**	**1.3**	**1.6**	**-**	**-**	**0.7**
39	78	**0.7**	**1.5**	**1.4**	**-**	**-**	**-**
40	79	**0.9**	**1.5**	**1.3**	**-**	**-**	**-**
41	80	**1.0**	**1.9**	**0.8**	**0.4**	**-**	**-**
42	81	**1.2**	**d**	**d**	**d**	**d**	**d**
43	83	**0.6**	**1.4**	**2.3**	**-**	**-**	**-**
44	84	**1.1**	**1.7**	**1.1**	**-**	**-**	**-**
45	85	**1.9**	**1.1**	**1.1**	**0.8**	**-**	**-**
46	86	**0.7**	**2.3**	**1.3**	**-**	**-**	**-**

Table H.14: Second recording of intersulcal lengths in the right fronto-parietal operculum, posterior to the AAR (control category)

[Abbreviations: IPRCS (inferior precentral sulcus); CF (central fissure); IPOCS (inferior postcentral sulcus); Op (sole opercular sulcus); Op_1 (first opercular sulcus); Op_2 (second opercular sulcus)].

	sn	AAR - IPRCS	IPRCS - CF	CF – IPOCS	AAR – Op	AAR – Op_1	AAR – Op_2
1	32	**1.6**	**1.5**	**1.7**	**0.7**	-	-
2	35	**2.1**	**1.8**	**1.2**	**0.8**	-	-
3	36	**1.1**	**1.7**	**1.6**	-	-	-
4	37	**0.5**	**1.2**	**1.8**	-	-	-
5	38	**2.3**	**1.7**	**1.5**	**0.7**	-	-
6	39	**2.4**	**1.5**	**1.4**	-	**0.8**	**0.9**
7	40	**0.8**	**1.6**	**1.1**	-	-	-
8	41	**1.8**	**1.3**	**1.3**	-	**0.4**	**0.9**
9	42	**1.0**	**2.3**	**1.1**	-	-	-
10	43	**1.7**	**1.8**	**1.8**	**0.8**	-	-
11	45	**0.9**	**1.5**	**1.0**	-	-	-
12	46	**1.8**	**1.1**	**1.8**	**1.0**	-	-
13	47	**1.2**	**1.5**	**2.3**	-	-	-
14	48	**1.5**	**1.4**	**2.0**	**0.8**	-	-
15	49	**0.6**	**2.0**	**0.9**	-	-	-
16	50	**1.7**	**2.1**	**1.4**	**0.7**	-	-
17	52	**1.1**	**2.6**	**1.5**	**0.7**	-	-
18	53	**1.3**	**1.7**	**1.2**	**0.7**	-	-
19	54	**1.5**	**0.8**	**2.1**	-	-	-
20	55	**2.3**	**1.1**	**2.3**	**1.8**	-	-
21	57	**1.9**	**1.4**	**1.8**	-	-	-
22	58	**0.5**	**1.3**	**1.0**	-	-	-
23	59	**1.7**	**1.7**	**1.5**	-	-	-
24	60	**0.7**	**0.9**	**1.1**	-	-	-
25	61	**0.5**	**1.4**	**1.6**	**0.4**	-	-
26	62	**0.8**	**1.6**	**2.3**	-	-	-
27	65	**0.8**	**1.1**	**1.8**	-	-	-
28	66	**0.8**	**1.2**	-	-	-	-
29	67	**2.1**	**0.4**	**1.8**	**0.4**	-	-
30	69	**0.6**	**0.7**	**1.9**	-	-	-
31	70	**1.9**	**1.9**	**0.7**	**0.8**	-	-
32	71	**1.5**	**1.3**	**1.9**	**0.7**	-	-

Table H. 14 continued on next page

Table H. 14 continued							
	sn	**AAR - IPRCS**	**IPRCS - CF**	**CF – IPOCS**	**AAR – Op**	**AAR – Op_1**	**AAR – Op_2**
33	72	**1.3**	**1.9**	**1.9**	**-**	**-**	**-**
34	73	**0.4**	**1.2**	**2.5**	**-**	**-**	**-**
35	74	**0.5**	**1.1**	**2.2**	**-**	**-**	**-**
36	75	**0.8**	**1.1**	**1.1**	**0.3**	**-**	**-**
37	76	**0.6**	**1.5**	**-**	**0.3**	**-**	**-**
38	77	**1.2**	**1.3**	**1.5**	**-**	**-**	**0.7**
39	78	**0.6**	**1.5**	**1.3**	**-**	**-**	**-**
40	79	**1.1**	**1.5**	**1.3**	**-**	**-**	**-**
41	80	**1.0**	**1.9**	**0.8**	**0.5**	**-**	**-**
42	81	**1.3**	**d**	**d**	**d**	**d**	**d**
43	83	**0.6**	**1.4**	**2.4**	**-**	**-**	**-**
44	84	**1.1**	**1.8**	**1.2**	**-**	**-**	**-**
45	85	**1.7**	**1.2**	**1.1**	**0.7**	**-**	**-**
46	86	**0.7**	**2.3**	**1.3**	**-**	**-**	**-**

Table H.15: Composite recording of intersulcal lengths in the right fronto-parietal operculum, posterior to the AAR (control category)

[Abbreviations: IPRCS (inferior precentral sulcus); CF (central fissure); IPOCS (inferior postcentral sulcus); Op (sole opercular sulcus); Op_1 (first opercular sulcus); Op_2 (second opercular sulcus)].

	sn	AAR - IPRCS	IPRCS - CF	CF – IPOCS	AAR – Op	AAR – Op_1	AAR – Op_2
1	32	**1.6**	**1.5**	**1.7**	**0.7**	-	-
2	35	**2.1**	**1.8**	**1.2**	**0.8**	-	-
3	36	**1.1**	**1.7**	**1.6**	-	-	-
4	37	**0.5**	**1.2**	**1.8**	-	-	-
5	38	**2.3**	**1.7**	**1.5**	**0.7**	-	-
6	39	**2.4**	**1.5**	**1.4**	-	**0.8**	**0.9**
7	40	**0.8**	**1.6**	**1.1**	-	-	-
8	41	**1.8**	**1.3**	**1.3**	-	**0.4**	**0.9**
9	42	**1.0**	**2.3**	**1.1**	-	-	-
10	43	**1.7**	**1.8**	**1.8**	**0.8**	-	-
11	45	**0.9**	**1.5**	**1.0**	-	-	-
12	46	**1.8**	**1.1**	**1.8**	**1.0**	-	-
13	47	**1.2**	**1.5**	**2.3**	-	-	-
14	48	**1.5**	**1.4**	**2.0**	**0.8**	-	-
15	49	**0.6**	**2.0**	**0.9**	-	-	-
16	50	**1.7**	**2.1**	**1.4**	**0.7**	-	-
17	52	**1.1**	**2.6**	**1.5**	**0.7**	-	-
18	53	**1.3**	**1.7**	**1.2**	**0.7**	-	-
19	54	**1.5**	**0.8**	**2.1**	-	-	-
20	55	**2.3**	**1.1**	**2.3**	**1.8**	-	-
21	57	**1.9**	**1.4**	**1.8**	-	-	-
22	58	**0.5**	**1.3**	**1.0**	-	-	-
23	59	**1.7**	**1.7**	**1.5**	-	-	-
24	60	**0.7**	**0.9**	**1.1**	-	-	-
25	61	**0.5**	**1.4**	**1.6**	**0.4**	-	-
26	62	**0.8**	**1.6**	**2.3**	-	-	-
27	65	**0.8**	**1.1**	**1.8**	-	-	-
28	66	**0.8**	**1.2**	-	-	-	-
29	67	**2.1**	**0.4**	**1.8**	**0.4**	-	-
30	69	**0.6**	**0.7**	**1.9**	-	-	-
31	70	**1.9**	**1.9**	**0.7**	**0.8**	-	-
32	71	**1.5**	**1.3**	**1.9**	**0.7**	-	-

Table H.15 continued on next page

Table H.15 continued

	sn	AAR - IPRCS	IPRCS - CF	CF – IPOCS	AAR – Op	AAR – Op_1	AAR – Op_2
33	72	**1.3**	**1.9**	**1.9**	**-**	**-**	**-**
34	73	**0.4**	**1.2**	**2.5**	**-**	**-**	**-**
35	74	**0.5**	**1.1**	**2.2**	**-**	**-**	**-**
36	75	**0.8**	**1.1**	**1.1**	**0.3**	**-**	**-**
37	76	**0.6**	**1.5**	**-**	**0.3**	**-**	**-**
38	77	**1.2**	**1.3**	**1.5**	**-**	**-**	**0.7**
39	78	**0.6**	**1.5**	**1.3**	**-**	**-**	**-**
40	79	**1.1**	**1.5**	**1.3**	**-**	**-**	**-**
41	80	**1.0**	**1.9**	**0.8**	**0.5**	**-**	**-**
42	81	**1.3**	**d**	**d**	**d**	**d**	**d**
43	83	**0.6**	**1.4**	**2.4**	**-**	**-**	**-**
44	84	**1.1**	**1.8**	**1.2**	**-**	**-**	**-**
45	85	**1.7**	**1.2**	**1.1**	**0.7**	**-**	**-**
46	86	**0.7**	**2.3**	**1.3**	**-**	**-**	**-**

Table H.16: First recording of intersulcal lengths in the left fronto-parietal operculum, posterior to the AAR (control category)

[Abbreviations: IPRCS (inferior precentral sulcus); CF (central fissure); IPOCS (inferior postcentral sulcus); Op (sole opercular sulcus); Op_1 (first opercular sulcus); Op_2 (second opercular sulcus)].

	sn	AAR - IPRCS	IPRCS - CF	CF – IPOCS	AAR – Op	AAR – Op_1	AAR – Op_2
1	32	**0.6**	**0.9**	**1.5**	-	-	-
2	35	**1.8**	**2.0**	**1.1**	**1.3**	-	-
3	36	**1.5**	**1.5**	**1.8**	**0.7**	-	-
4	37	**0.6**	**0.8**	-	-	-	-
5	38	**1.7**	**1.7**	**2.1**	**0.9**	-	-
6	39	**2.1**	**1.3**	**1.2**	-	-	-
7	40	**1.7**	**1.6**	**1.4**	**1.0**	-	-
8	41	**1.8**	**0.5**	**2.3**	**0.9**	-	-
9	42	**1.6**	**0.5**	**1.7**	-	-	-
10	43	-	-	-	**0.1**	-	-
11	45	**0.5**	**1.0**	**1.9**	-	-	-
12	46	**1.0**	**2.1**	**1.7**	-	-	-
13	47	**0.6**	**1.4**	**2.0**	-	-	-
14	48	**1.4**	**2.0**	**1.3**	**0.5**	-	-
15	49	**1.2**	**1.8**	**1.3**	-	-	-
16	50	**1.6**	**1.1**	**2.1**	**0.6**	-	-
17	52	**0.4**	**2.5**	**1.8**	-	-	-
18	53	**1.9**	**2.3**	**1.9**	-	-	-
19	54	**0.7**	**1.3**	**1.2**	-	-	-
20	55	**0.7**	**1.5**	**2.4**	-	-	-
21	57	**0.8**	**1.1**	**1.9**	**0.2**	-	-
22	58	**0.3**	**1.8**	**1.1**	-	-	-
23	59	**0.8**	**1.5**	**2.5**	-	-	-
24	60	**1.4**	**1.1**	**1.4**	**0.6**	-	-
25	61	**1.2**	**1.8**	**1.5**	**0.7**	-	-
26	62	**0.3**	**1.6**	**2.5**	-	-	-
27	63	**1.1**	**1.1**	**2.5**	-	-	-
28	65	**0.6**	**2.1**	**1.1**	-	-	-
29	66	**0.8**	**0.9**	**1.6**	**1.8**	-	-
30	67	**0.6**	**1.7**	**1.8**	-	-	-
31	69	**1.9**	**0.5**	**2.3**	-	-	-
32	71	**1.0**	**1.2**	**1.2**	-	-	-

Table H.16 continued on next page

Table H.16 continued

	sn	AAR - IPRCS	IPRCS - CF	CF – IPOCS	AAR – Op	AAR – Op_1	AAR – Op_2
33	72	**0.9**	**1.2**	**2.2**	**-**	**-**	**-**
34	73	**0.4**	**1.4**	**-**	**-**	**-**	**-**
35	74	**0.7**	**1.4**	**3.0**	**-**	**-**	**-**
36	75	**0.5**	**0.8**	**2.5**	**-**	**-**	**-**
37	76	**0.6**	**1.4**	**1.7**	**-**	**-**	**-**
38	77	**0.7**	**1.6**	**2.7**	**-**	**-**	**-**
39	78	**0.4**	**1.6**	**3.0**	**-**	**-**	**-**
40	79	**2.1**	**0.9**	**1.7**	**0.8**	**-**	**-**
41	80	**0.5**	**2.3**	**1.1**	**-**	**-**	**-**
42	81	**1.3**	**1.1**	**2.4**	**-**	**-**	**-**
43	83	**1.4**	**1.0**	**1.7**	**0.6**	**-**	**-**
44	84	**1.0**	**1.5**	**2.1**	**-**	**-**	**-**
45	85	**0.7**	**1.2**	**1.8**	**-**	**-**	**-**
46	86	**0.6**	**1.8**	**1.4**	**-**	**-**	**-**

Table H.17: Second recording of intersulcal lengths in the left fronto-parietal operculum, posterior to the AAR (control category)

[Abbreviations: IPRCS (inferior precentral sulcus); CF (central fissure); IPOCS (inferior postcentral sulcus); Op (sole opercular sulcus); Op_1 (first opercular sulcus); Op_2 (second opercular sulcus)].

	sn	AAR - IPRCS	IPRCS - CF	CF – IPOCS	AAR – Op	AAR – Op_1	AAR – Op_2
1	32	**0.6**	**0.9**	**1.4**	-	-	-
2	35	**1.6**	**2.3**	**0.9**	**1.4**	-	-
3	36	**1.5**	**1.8**	**1.6**	**0.7**	-	-
4	37	**0.5**	**0.8**	-	-	-	-
5	38	**1.7**	**1.6**	**2.4**	**0.9**	-	-
6	39	**2.1**	**1.3**	**1.4**	-	-	-
7	40	**1.7**	**1.6**	**1.4**	**1.0**	-	-
8	41	**1.9**	**0.6**	**2.2**	**0.8**	-	-
9	42	**1.7**	**0.5**	**1.7**	-	-	-
10	43	-	-	-	**0.1**	-	-
11	45	**0.6**	**1.1**	**2.0**	-	-	-
12	46	**1.1**	**2.0**	**1.7**	-	-	-
13	47	**0.6**	**1.5**	**2.2**	-	-	-
14	48	**1.4**	**1.9**	**1.4**	**0.6**	-	-
15	49	**1.2**	**1.7**	**1.2**	-	-	-
16	50	**1.5**	**1.2**	**2.0**	**0.7**	-	-
17	52	**0.4**	**2.3**	**1.8**	-	-	-
18	53	**1.9**	**2.2**	**1.7**	-	-	-
19	54	**0.7**	**1.3**	**1.3**	-	-	-
20	55	**0.7**	**1.4**	**2.3**	-	-	-
21	57	**0.8**	**1.0**	**1.9**	**0.2**	-	-
22	58	**0.3**	**1.9**	**1.1**	-	-	-
23	59	**0.8**	**1.4**	**2.4**	-	-	-
24	60	**1.5**	**1.1**	**1.4**	**0.6**	-	-
25	61	**1.0**	**2.0**	**1.5**	**0.5**	-	-
26	62	**0.3**	**1.4**	**2.7**	-	-	-
27	63	**1.1**	**1.1**	**2.3**	-	-	-
28	65	**0.6**	**2.1**	**1.0**	-	-	-
29	66	**0.7**	**1.0**	**1.7**	**1.7**	-	-
30	67	**0.6**	**1.6**	**1.7**	-	-	-
31	69	**1.7**	**0.7**	**2.3**	-	-	-
32	71	**1.0**	**1.3**	**1.1**	-	-	-

Table H.17 continued on next page

Table H.17 continued

	sn	AAR - IPRCS	IPRCS - CF	CF – IPOCS	AAR – Op	AAR – Op_1	AAR – Op_2
33	72	**0.8**	**1.3**	**2.1**	**-**	**-**	**-**
34	73	**0.5**	**1.3**	**-**	**-**	**-**	**-**
35	74	**0.8**	**1.5**	**2.9**	**-**	**-**	**-**
36	75	**0.5**	**0.9**	**2.3**	**-**	**-**	**-**
37	76	**0.6**	**1.3**	**1.8**	**-**	**-**	**-**
38	77	**0.5**	**1.5**	**2.8**	**-**	**-**	**-**
39	78	**0.4**	**1.6**	**3.1**	**-**	**-**	**-**
40	79	**2.0**	**0.9**	**1.6**	**0.7**	**-**	**-**
41	80	**0.6**	**2.3**	**1.1**	**-**	**-**	**-**
42	81	**1.3**	**1.1**	**2.3**	**-**	**-**	**-**
43	83	**1.3**	**1.0**	**1.6**	**0.7**	**-**	**-**
44	84	**1.1**	**1.6**	**1.8**	**-**	**-**	**-**
45	85	**0.6**	**1.1**	**1.8**	**-**	**-**	**-**
46	86	**0.7**	**1.7**	**1.3**	**-**	**-**	**-**

Table H.18: Composite recording of intersulcal lengths in the left fronto-parietal operculum, posterior to the AAR (control category)

[Abbreviations: IPRCS (inferior precentral sulcus); CF (central fissure); IPOCS (inferior postcentral sulcus); Op (sole opercular sulcus); Op_1 (first opercular sulcus); Op_2 (second opercular sulcus)].

	sn	AAR - IPRCS	IPRCS - CF	CF – IPOCS	AAR – Op	AAR – Op_1	AAR – Op_2
1	32	**0.6**	**0.9**	**1.4**	-	-	-
2	35	**1.6**	**2.3**	**0.9**	**1.4**	-	-
3	36	**1.5**	**1.8**	**1.6**	**0.7**	-	-
4	37	**0.5**	**0.8**	-	-	-	-
5	38	**1.7**	**1.6**	**2.4**	**0.9**	-	-
6	39	**2.1**	**1.3**	**1.4**	-	-	-
7	40	**1.7**	**1.6**	**1.4**	**1.0**	-	-
8	41	**1.9**	**0.6**	**2.2**	**0.8**	-	-
9	42	**1.7**	**0.5**	**1.7**	-	-	-
10	43	-	-	-	**0.1**	-	-
11	45	**0.6**	**1.1**	**2.0**	-	-	-
12	46	**1.1**	**2.0**	**1.7**	-	-	-
13	47	**0.6**	**1.5**	**2.2**	-	-	-
14	48	**1.4**	**1.9**	**1.4**	**0.6**	-	-
15	49	**1.2**	**1.7**	**1.2**	-	-	-
16	50	**1.5**	**1.2**	**2.0**	**0.7**	-	-
17	52	**0.4**	**2.3**	**1.8**	-	-	-
18	53	**1.9**	**2.2**	**1.7**	-	-	-
19	54	**0.7**	**1.3**	**1.3**	-	-	-
20	55	**0.7**	**1.4**	**2.3**	-	-	-
21	57	**0.8**	**1.0**	**1.9**	**0.2**	-	-
22	58	**0.3**	**1.9**	**1.1**	-	-	-
23	59	**0.8**	**1.4**	**2.4**	-	-	-
24	60	**1.5**	**1.1**	**1.4**	**0.6**	-	-
25	61	**1.0**	**2.0**	**1.5**	**0.5**	-	-
26	62	**0.3**	**1.4**	**2.7**	-	-	-
27	63	**1.1**	**1.1**	**2.3**	-	-	-
28	65	**0.6**	**2.1**	**1.0**	-	-	-
29	66	**0.7**	**1.0**	**1.7**	**1.7**	-	-
30	67	**0.6**	**1.6**	**1.7**	-	-	-
31	69	**1.7**	**0.7**	**2.3**	-	-	-
32	71	**1.0**	**1.3**	**1.1**	-	-	-

Table H.18 continued on next page

Table H.18 continued

	sn	AAR - IPRCS	IPRCS - CF	CF – IPOCS	AAR – Op	AAR – Op_1	AAR – Op_2
33	72	**0.8**	**1.3**	**2.1**	**-**	**-**	**-**
34	73	**0.5**	**1.3**	**-**	**-**	**-**	**-**
35	74	**0.8**	**1.5**	**2.9**	**-**	**-**	**-**
36	75	**0.5**	**0.9**	**2.3**	**-**	**-**	**-**
37	76	**0.6**	**1.3**	**1.8**	**-**	**-**	**-**
38	77	**0.5**	**1.5**	**2.8**	**-**	**-**	**-**
39	78	**0.4**	**1.6**	**3.1**	**-**	**-**	**-**
40	79	**2.0**	**0.9**	**1.6**	**0.7**	**-**	**-**
41	80	**0.6**	**2.3**	**1.1**	**-**	**-**	**-**
42	81	**1.3**	**1.1**	**2.3**	**-**	**-**	**-**
43	83	**1.3**	**1.0**	**1.6**	**0.7**	**-**	**-**
44	84	**1.1**	**1.6**	**1.8**	**-**	**-**	**-**
45	85	**0.6**	**1.1**	**1.8**	**-**	**-**	**-**
46	86	**0.7**	**1.7**	**1.3**	**-**	**-**	**-**

Table H.19: First recording of intersulcal lengths in the right fronto-parietal operculum, posterior to the AAR (case category)

[Abbreviations: IPRCS (inferior precentral sulcus); CF (central fissure); IPOCS (inferior postcentral sulcus); Op (sole opercular sulcus); Op_1 (first opercular sulcus); Op_2 (second opercular sulcus)].

	sn	AAR - IPRCS	IPRCS - CF	CF – IPOCS	AAR – Op	AAR – Op_1	AAR – Op_2
1	3	**1.0**	**2.0**	-	-	-	-
2	4	**1.2**	**2.1**	**2.4**	-	-	-
3	5	**1.8**	**1.9**	**1.6**	-	-	-
4	6	**0.9**	**1.4**	**2.4**	-	-	-
5	7	**0.5**	**0.7**	**1.4**	-	-	-
6	8	**1.0**	**1.7**	**1.8**	-	-	-
7	9	**1.2**	**1.8**	**2.4**	-	-	-
8	10	**1.1**	**1.2**	-	-	-	-
9	11	**0.8**	**1.7**	**1.3**	-	-	-
10	12	**1.6**	**1.4**	**1.5**	**1.4**	-	-
11	14	**1.4**	**1.2**	**2.2**	**1.2**	-	-
12	15	**1.2**	**1.6**	**0.9**	-	-	-
13	16	**0.1**	**2.4**	**1.3**	-	-	-
14	17	**0.7**	**1.2**	**1.5**	-	-	-
15	19	**1.2**	**2.2**	**1.6**	-	-	-
16	20	**0.2**	**2.0**	**1.7**	-	-	-
17	21	**1.5**	**1.0**	**2.2**	**0.4**	-	-
18	22	**1.1**	**1.1**	**1.7**	-	-	-
19	23	**1.8**	**1.2**	**1.2**	-	-	-
20	24	**1.1**	**1.4**	**1.8**	**0.6**	-	-
21	25	**0.5**	**1.3**	**1.2**	**1.2**	-	-
22	26	**1.1**	**1.4**	**0.9**	**0.7**	-	-
23	28	**0.7**	**2.2**	**0.8**	-	-	-
24	29	**0.8**	**2.3**	**2.0**	-	-	-
25	30	**1.5**	**1.4**	**1.8**	**0.8**	-	-
26	31	**1.0**	**2.0**	**1.7**	-	-	-

Table H.20: Second recording of intersulcal lengths in the right fronto-parietal operculum, posterior to the AAR (case category)

[Abbreviations: IPRCS (inferior precentral sulcus); CF (central fissure); IPOCS (inferior postcentral sulcus); Op (sole opercular sulcus); Op_1 (first opercular sulcus); Op_2 (second opercular sulcus)].

	sn	AAR - IPRCS	IPRCS - CF	CF – IPOCS	AAR – Op	AAR – Op_1	AAR – Op_2
1	3	**1.0**	**1.9**	-	-	-	-
2	4	**1.3**	**2.1**	**2.5**	-	-	-
3	5	**1.9**	**1.9**	**1.6**	-	-	-
4	6	**1.1**	**1.3**	**2.3**	-	-	-
5	7	**0.6**	**0.8**	**1.3**	-	-	-
6	8	**0.9**	**1.7**	**1.8**	-	-	-
7	9	**1.3**	**1.7**	**2.5**	-	-	-
8	10	**1.1**	**1.2**	-	-	-	-
9	11	**0.7**	**1.7**	**1.2**	-	-	-
10	12	**1.5**	**1.4**	**1.5**	**1.3**	-	-
11	14	**1.5**	**1.2**	**2.0**	**1.1**	-	-
12	15	**1.2**	**1.5**	**1.0**	-	-	-
13	16	**0.1**	**2.3**	**1.2**	-	-	-
14	17	**0.8**	**1.1**	**1.5**	-	-	-
15	19	**1.3**	**2.0**	**1.7**	-	-	-
16	20	**0.2**	**2.0**	**1.6**	-	-	-
17	21	**1.7**	**1.0**	**2.0**	**0.4**	-	-
18	22	**1.0**	**1.0**	**1.6**	-	-	-
19	23	**1.9**	**1.3**	**1.2**	-	-	-
20	24	**1.1**	**1.5**	**1.9**	**0.6**	-	-
21	25	**0.4**	**1.4**	**1.3**	**1.2**	-	-
22	26	**1.1**	**1.5**	**0.8**	**0.6**	-	-
23	28	**0.7**	**2.2**	**0.8**	-	-	-
24	29	**0.8**	**2.3**	**2.0**	-	-	-
25	30	**1.5**	**1.3**	**1.9**	**0.8**	-	-
26	31	**1.1**	**1.9**	**1.6**	-	-	-

Table H.21: Composite recording of intersulcal lengths in the right fronto-parietal operculum, posterior to the AAR (case category)

[Abbreviations: IPRCS (inferior precentral sulcus); CF (central fissure); IPOCS (inferior postcentral sulcus); Op (sole opercular sulcus); Op_1 (first opercular sulcus); Op_2 (second opercular sulcus)].

	sn	AAR - IPRCS	IPRCS - CF	CF – IPOCS	AAR – Op	AAR – Op_1	AAR – Op_2
1	3	**1.0**	**1.9**	-	-	-	-
2	4	**1.3**	**2.1**	**2.5**	-	-	-
3	5	**1.9**	**1.9**	**1.6**	-	-	-
4	6	**1.1**	**1.3**	**2.3**	-	-	-
5	7	**0.6**	**0.8**	**1.3**	-	-	-
6	8	**0.9**	**1.7**	**1.8**	-	-	-
7	9	**1.3**	**1.7**	**2.5**	-	-	-
8	10	**1.1**	**1.2**	-	-	-	-
9	11	**0.7**	**1.7**	**1.2**	-	-	-
10	12	**1.5**	**1.4**	**1.5**	**1.3**	-	-
11	14	**1.5**	**1.2**	**2.0**	**1.1**	-	-
12	15	**1.2**	**1.5**	**1.0**	-	-	-
13	16	**0.1**	**2.3**	**1.2**	-	-	-
14	17	**0.8**	**1.1**	**1.5**	-	-	-
15	19	**1.3**	**2.0**	**1.7**	-	-	-
16	20	**0.2**	**2.0**	**1.6**	-	-	-
17	21	**1.7**	**1.0**	**2.0**	**0.4**	-	-
18	22	**1.0**	**1.0**	**1.6**	-	-	-
19	23	**1.9**	**1.3**	**1.2**	-	-	-
20	24	**1.1**	**1.5**	**1.9**	**0.6**	-	-
21	25	**0.4**	**1.4**	**1.3**	**1.2**	-	-
22	26	**1.1**	**1.5**	**0.8**	**0.6**	-	-
23	28	**0.7**	**2.2**	**0.8**	-	-	-
24	29	**0.8**	**2.3**	**2.0**	-	-	-
25	30	**1.5**	**1.3**	**1.9**	**0.8**	-	-
26	31	**1.1**	**1.9**	**1.6**	-	-	-

Table H.22: First recording of intersulcal lengths in the left fronto-parietal operculum, posterior to the AAR (case category)

[Abbreviations: IPRCS (inferior precentral sulcus); CF (central fissure); IPOCS (inferior postcentral sulcus); Op (sole opercular sulcus); Op_1 (first opercular sulcus); Op_2 (second opercular sulcus)].

	sn	AAR - IPRCS	IPRCS - CF	CF – IPOCS	AAR – Op	AAR – Op_1	AAR – Op_2
1	2	**1.25**	**1.5**	**2.4**	-	-	-
2	3	**1.1**	**1.6**	**1.4**	-	-	-
3	5	**2.3**	**0.8**	**2.4**	**1.3**	-	-
4	6	**0.5**	**0.7**	**2.4**	-	-	-
5	7	**2.3**	**1.4**	**2.0**	**0.5**	-	-
6	8	**2.1**	**1.1**	**2.0**	-	-	-
7	9	**1.8**	**1.5**	**1.9**	-	-	-
8	10	**1.1**	**1.2**	**1.9**	-	-	-
9	11	**2.0**	**1.8**	**2.2**	**0.3**	-	-
10	12	**1.0**	**1.1**	**1.4**	-	-	-
11	13	**1.1**	**1.3**	**0.9**	-	-	-
12	14	**2.3**	**1.4**	-	-	-	-
13	15	**1.3**	**1.5**	**2.6**	**0.6**	-	-
14	16	**1.6**	**1.5**	**2.2**	**0.9**	-	-
15	18	**1.3**	**1.0**	**1.8**	**0.7**	-	-
16	19	**1.7**	**2.1**	**2.0**	**0.8**	-	-
17	21	**1.5**	**0.8**	**1.9**	-	-	-
18	22	**1.3**	**1.7**	**1.2**	-	-	-
19	23	**1.5**	**1.2**	**1.3**	-	-	-
20	26	**1.3**	-	-	-	-	-
21	27	**1.9**	**1.6**	**1.8**	**1.1**	-	-
22	28	**1.1**	**1.6**	**2.9**	-	-	-
23	29	**0.5**	**1.4**	**2.3**	-	-	-
24	30	**2.5**	**2.2**	**1.2**	-	-	-
25	31	**1.4**	**1.4**	**1.9**	**0.5**	-	-

Table H.23: Second recording of intersulcal lengths in the left frontoparietal operculum, posterior to the AAR (case category)

[Abbreviations: IPRCS (inferior precentral sulcus); CF (central fissure); IPOCS (inferior postcentral sulcus); Op (sole opercular sulcus); Op_1 (first opercular sulcus); Op_2 (second opercular sulcus)].

	sn	AAR - IPRCS	IPRCS - CF	CF – IPOCS	AAR – Op	AAR – Op_1	AAR – Op_2
1	2	**1.3**	**1.4**	**2.6**	-	-	-
2	3	**1.0**	**1.6**	**1.4**	-	-	-
3	5	**2.2**	**0.9**	**2.3**	**1.3**	-	-
4	6	**0.6**	**0.7**	**2.5**	-	-	-
5	7	**2.3**	**1.4**	**1.9**	**0.5**	-	-
6	8	**2.1**	**1.1**	**2.2**	-	-	-
7	9	**1.6**	**1.6**	**2.0**	-	-	-
8	10	**1.0**	**1.1**	**1.9**	-	-	-
9	11	**1.9**	**1.9**	**2.0**	**0.4**	-	-
10	12	**0.9**	**1.2**	**1.2**	-	-	-
11	13	**1.1**	**1.2**	**0.9**	-	-	-
12	14	**2.2**	**1.4**	-	-	-	-
13	15	**1.3**	**1.5**	**2.4**	**0.5**	-	-
14	16	**1.5**	**1.5**	**2.1**	**0.9**	-	-
15	18	**1.3**	**1.1**	**2.0**	**0.7**	-	-
16	19	**1.7**	**2.1**	**1.9**	**0.8**	-	-
17	21	**1.3**	**0.9**	**1.8**	-	-	-
18	22	**1.4**	**1.6**	**1.3**	-	-	-
19	23	**1.4**	**1.2**	**1.4**	-	-	-
20	26	**1.3**	-	-	-	-	-
21	27	**1.9**	**1.6**	**1.7**	**1.1**	-	-
22	28	**1.1**	**1.5**	**3.0**	-	-	-
23	29	**0.5**	**1.4**	**2.3**	-	-	-
24	30	**2.6**	**2.2**	**1.1**	-	-	-
25	31	**1.5**	**1.5**	**1.8**	**0.5**	-	-

Table H.24: Composite recording of intersulcal lengths in the left fronto-parietal operculum, posterior to the AAR (case category)

[Abbreviations: IPRCS (inferior precentral sulcus); CF (central fissure); IPOCS (inferior postcentral sulcus); Op (sole opercular sulcus); Op_1 (first opercular sulcus); Op_2 (second opercular sulcus)].

	sn	AAR - IPRCS	IPRCS CF	CF – IPOCS	AAR – Op	AAR – Op_1	AAR – Op_2
1	2	**1.3**	**1.4**	**2.6**	-	-	-
2	3	**1.0**	**1.6**	**1.4**	-	-	-
3	5	**2.2**	**0.9**	**2.3**	**1.3**	-	-
4	6	**0.6**	**0.7**	**2.5**	-	-	-
5	7	**2.3**	**1.4**	**1.9**	**0.5**	-	-
6	8	**2.1**	**1.1**	**2.2**	-	-	-
7	9	**1.6**	**1.6**	**2.0**	-	-	-
8	10	**1.0**	**1.1**	**1.9**	-	-	-
9	11	**1.9**	**1.9**	**2.0**	**0.4**	-	-
10	12	**0.9**	**1.2**	**1.2**	-	-	-
11	13	**1.1**	**1.2**	**0.9**	-	-	-
12	14	**2.2**	**1.4**	-	-	-	-
13	15	**1.3**	**1.5**	**2.4**	**0.5**	-	-
14	16	**1.5**	**1.5**	**2.1**	**0.9**	-	-
15	18	**1.3**	**1.1**	**2.0**	**0.7**	-	-
16	19	**1.7**	**2.1**	**1.9**	**0.8**	-	-
17	21	**1.3**	**0.9**	**1.8**	-	-	-
18	22	**1.4**	**1.6**	**1.3**	-	-	-
19	23	**1.4**	**1.2**	**1.4**	-	-	-
20	26	**1.3**	-	-	-	-	-
21	27	**1.9**	**1.6**	**1.7**	**1.1**	-	-
22	28	**1.1**	**1.5**	**3.0**	-	-	-
23	29	**0.5**	**1.4**	**2.3**	-	-	-
24	30	**2.6**	**2.2**	**1.1**	-	-	-
25	31	**1.5**	**1.5**	**1.8**	**0.5**	-	-

APPENDIX I

AN EXAMPLE OF THE SHAPIRO-WILK TEST PROCEDURE

Below we provide an illustration of computational details of the Shapiro-Wilk test procedure, using *Example* 1.9 at pg 15 of Wetherill (1981).

In the example:

(a) x_i denotes the ith unordered sample observation.

(b) $x_{(h)}$ denotes the hth observation in a sample arranged in ascending order of magnitude.

(c) $d_i = x_{(n-i+1)} - x_{(i)}$

(d) The values of a_{n-i+1} are obtained from statistical tables provided by the author at pages 378 – 379.

(e) k = 0.5n if n is even;

= 0.5n – 0.5 if n is odd, in which case the value $x_{(k+1)}$ is ignored

(f) $b = \Sigma \{d_i * a_{n-i+1}\}$, where the summation is over index i from i =1 to i =k

(g) $n \text{ var } x = \Sigma (x_i - x)^2$

(h) $W = b^2 / n \text{ var } x$

Table **I**.1: **First phase computations**

i	x_i	$x_{(i)}$	$x_{(n-i+1)}$	d_i
1	**5.44**	**4.15**	**6.75**	**2.60**
2	**5.36**	**4.44**	**6.46**	**2.02**
3	**5.60**	**5.36**	**6.03**	**0.67**
4	**6.46**	**5.44**	**5.60**	**0.16**
5	**6.75**	**5.60**	**5.44**	**-0.16**
6	**6.03**	**6.03**	**5.36**	**-0.67**
7	**4.15**	**6.46**	**4.44**	**-2.02**
8	**4.44**	**6.75**	**4.15**	**-2.60**

Table **I**2: **Second phase computations**

i	**a_{n-i+1} (from statistical tables)**	**(d_i * a_{n-i+1})**	**n var x**
1	**0.6052**	**1.5735**	
2	**0.3164**	**0.6391**	5.7388 **(Instead of author erroneous 5.7343)**
3	**0.1743**	**0.1168**	
k = 4	**0.0561**	**0.0090**	
		b = 2.3384	
		b^2 = 5.4681	W = 5.4681/5.7388 = 0.9528

REFERENCES

Albanese. E., Merlo. A., Albanese A., Gomez. E. Anterior Speech Region: Asymmetry and Weight- Surface Correlation. *Archives of Neurology*. (1989) 46: pp 307-310.

Amunts. K., Schleicher. A., Burgel. U., Mohlberg. H., Uylings. HBM., Zilles. K. Broca's Region Revisited: Cytoarchitecture and Intersubject Variability. *The Journal of Comparative Neurology.* (1999) **412**: pp 319-341.

Arey. LB. 1965. *Developmental Anatomy: A Textbook and Laboratory Manual of Embryology*. 7th ed. WB. Saunders Co. pp 493-498.

Bailey. P., Bonin. G. 1951. *The Isocortex of Man*[*]. University of Illinois Press. Urbana.

Bergman. RA., Afifi. AK., Miyauchi. R. 'Sylvian Fissure.' *Virtual Hospital: Illustrated Encyclopedia of Human Anatomic Variation: Part III: Nervous System: Brain: Fissures and Sulci* (2000), <htpp://lib.cpums.edu.cn/jiepou/tutu/atlas/www.vh.org/Providers/Textbooks/AnatomicVariants/NervousSystem/Text/SylvianFissure.html> [Accessed 14 Aug 2000].

Bergman. RA., Afifi. AK., Miyauchi. R. 2004. Variation in Fissures of the Cerebral Hemisphere Showing Doubled Rolandic Fissure.

[*] Secondary reference

<htpp://lib.cpums.edu.cn/jiepou/tutu/atlas/www.vh.org/adult/Provider/anatomy/AnatomicVariants/NervousSystem/Images/0.5.html> [Accessed Dec 2004].

Chi. JG., Dooling. EC., Gilles. FH. Gyral Development of the human Brain. *Annals of Neurology.* (1977) **1(No1)**: pp 86-93.

Connolly. CJ., 1950. *External Morphology of the Primate Brain*[*]. Springfield, Illinois: CC Thomas.

Cunningham. DJ., The Fissure of Rolando[*]. *J. Anat. Physiology.* (1890) **25**: pp 1-23.

Cunningham. DJ., 1892. *Contribution to the Surface Anatomy of the Cerebral Hemispheres*[*]. Dublin: Royal Irish Academy.

Dehay. C., Giroud. P., Berland. M., Berland. M., Killackey. H., Kennedy. H. Contribution of thalamic input to the specification of cytoarchitectonic cortical fields in the primate. Effects of bilateral enucleation in the foetal monkey on the boundaries, dimensions, and gyrification of striate and extrastriate cortex. *The Journal of Comparative Neurology*. (1996) **367**: pp 70-89.

Ebeling. U., Steinmetz. H., Huang Y., Kahn. T. Topography and Identification of the Inferior Precentral Sulcus in MR Imaging. *American Journal of Neuroradiology*. (1989) **10**: pp 937-942.

[*] Secondary reference

Eberstaller. O., 1890. *Das Stirnhirn*[*]. Wien and Leipzig: Urban and Schwarzenberg.

Falzi. G., Perrone. P., Luigi. A., Vignolo. MD. Right-Left Asymmetry in Anterior Speech Region. *Archives of Neurology*. (1989) **39**: pp 239-240.

Fitzgerald. MJT. 1992. *Neuroanatomy: Basic and Clinical*. 2nd ed. London: Baillière Tindall. pp 197.

Foundas. AL., Eure. KF., Luevano. LF., Weinberger. DR. MRI Asymmetries of Broca's Area: The Pars Triangularis and the Pars Opercularis. *Brain and Language*. (1998) **64**: pp 282-296.

Galaburda. AM. La Region de Broca: Observations anatomiques faites un siecle après la mort de son decouvreue. (1980) **10**: pp 609-616.

Greger. R. and Windhorst. U. (Eds). 1996 *Comprehensive Human Physiology: From Cellular Mechanisms to Integration. Volume 1*. Berlin Heidelberg: Springer Verlag. pp 1107-1144.

Ham. AW., Cormack. DH. (1979) *Histology.* (8th ed). JB Lippencott Company.

Ide. A., Aboitiz. F. A sex difference in the postcentral sulcus of the human brain. *Brain Research*. (2001) **890**: pp 330-332.

Ide. A., Dolezal. C., Fernandez. M., Labbe. E., Mandujano. R., Montes. S., Segura. P., Verschae.G., Yarmuch. P., Aboitiz. F., et al. Hemispheric Differences in Variability of Fissural Paterns in Parasylvian and Sylvian Regions of Human Brains. *The Journal of Comparative Neurology*. (1999) **410**: pp 235-242.

Lang. J., Betz. J. Form und Masse der Gyri und Sulci an der Facies superolateralis und Facies inferior hemispherii*. *J. Hirnforsch*. (1981) **22**: 517-533.

Lemre. RJ., Loeser JD., Leech. RW., Ellsworth. C., Alvord. JR. 1975. *Normal and Abnormal Development of the Human Nervous System*. Harper and Row. pp 232- 237; 263-269.

Levin. RI., Rubin. DS. 1980. *Applied Elementary Statistics*. Prentice Hall.

Ono. M., Kubik. S. Abernathey. CD. 1990. *Atlas of the cerebral Sulci*. Georg Thieme Verlag. pp 6-61; 140-161.

Rakic. P. Specification of Cerebral Cortical Areas. *Science*. (1988). **241**: pp 170-176

Richman. DP., Stewart. MR., Hutchinson. JW., Caviness. VS. Mechanical Model of Brain Convolutional Development. *Science*. (1975) **189** : pp 18-21.

Rodgers. JH., Ciossek. T., Menzel. P., Pasquale. EB. Eph receptors and ephrins

* Secondary reference

Demarcate cerebellar lobules before and during their formation. *Mechanisms of Development* (1999) **87**: pp 119-128.

Rubens. AB. Anatomical Asymmetries of Human Cerebral Cortex. In *Lateralization in the Nervous System, ed. Harnad. S., Doty. RW., Goldstein. L., Jaynes. J., Krauthamer. Gl*. 1977. New York: Academic Press. pp 503-514.

Sherwood. CC., Broadfield. DC., Holloway. RL., Gannon. PJ., Hof. PR. Variability of Broca's Area. Homologue in African Great Apes: Implications for Language Evolution. *The Anatomical Record Part* A. (2003) **271A**: pp 276-285.

Tanaka. T., Serneo. FF., Tseng. HC., Kulkarni. AB., Tsai. LH., Gleeson. JG. Cdk5 phosphorylation of doublecortin ser 297 regulates its effect on neuronal migration. *Neuron*. (2004) Jan 22; **41**(2): pp 215-227.

Tomaiuolo. F., MacDonald. JD., Caramanos. Z., Posner. G., Chiavaras. M., Evans. AC., Petrides. M. Morphology, morphometry and probability mapping of the pars opercularis of the inferior frontal gyrus: an *in vivo* MRI analysis. *European Journal of Neuroscience*. (1999) **11**: pp 3033-3046.

Turner. OA. Growth and Development of the Cerebral Cortical Pattern in Man. *Archives of Neurology and Psychiatry.* (1948) **59**: (1) pp 1-12.

Van Essen. DC. A tension-based theory of morphogenesis and compact wiring in the central nervous system. *Nature*. (1997) **385**: pp 313-318.

Wada. JA., Robert Clarke. MS., Hamm. A. Cerebral Hemispheric Asymmetry in Humans. *Archives of Neurology*. (1975) **32**: pp 239-246.

Welker. W. Why does Cerebral Cortex Fissure and fold? A Review of Determinants of Gyri and Sulci. *In Comparative Structure and Evolution of Cerebral Cortex, Part II., ed. Jones. EG., Peters. A. Cerebral Cortex*. (1990) **8B**: pp 3-135.

Williams. PL., Warwick. R., Dyson. M., Bannister. LH. *Grey's Anatomy* (37th ed). 1989. Churchill Livingstone. pp 1021 -1024