

https://dspace.org/

A cytochemical study of the c cell in the thyroid glands of young dogs and human neonates

Roediger, W E W

2015
http://hdl.handle.net/10539/19222

Downloaded from a DSpace repository. https://dspace.org/

A CYTOCHEMICAL STUDY OF THE C CELL IN THE THYROID GLANDS OF YOUNG DOGS AND HUMAN NEONATES

W.E.W. Roediger

A dissertation submitted to the Faculty of Science, University of the Witwatersrand, Johannesburg, in fulfilment of the requirements for the degree of Master of Science.

Johannesburg, December, 1976.

DECLARATION BY CANDIDATE

This dissertation is my own work and has not been submitted for any degree at another university.

W.E.W. Roediger

CONTENTS

		Page
Preface		i
Acknowledgements		ii
Abstract		iii
Publications		vi
1. INTRODUCTION		1
1.1 Discovery of the hormone, calcitonin, and its organ of origin		1
1.2 Cellular source of calcitonin ...		2
1.3 Biochemistry of calcitonin and cytochemistry of C cells		4
1.3.1 Biochemistry of calcitonin ...		4
1.3.2 Cytochemistry of C cells ...		7
1.4 The human C cell...		11
2. AIMS AND PURPOSE OF THE STUDY		15
2.1 Protein cytochemistry		15
2.2 Silver binding in C cells		15
2.3 C cells in the human thyroid		16
3. PROTEIN CYTOCHEMISTRY OF CANINE C CELLS ...		17
3.1 Introduction		17
3.2 Material		19
3.3 Fixation of tissue		21
3.4 Cytochemistry of simple proteins ...		29
3.4.1 Material and methods		29
3.4.2 Results		31
3.4.3 Discussion		45
3.4.4 Conclusion		61
3.5 Cytochemistry of complex proteins ...		62
3.5.1 Introduction		62
3.5.2 Material and methods		63
3.5.3 Results		65
3.5.4 Discussion		67
3.5.5 Conclusions		73
3.6 Cytochemical modifications of protein groups		74
3.6.1 Introduction		74
3.6.2 Material and methods		75
3.6.3 Results		76
3.6.4 Discussion		78
3.6.5 Conclusion		87

		Page
3.7	Enzymatic and chemical cleavage of protein groups	88
3.7.1	Introduction	88
3.7.2	Material and methods	91
3.7.3	Results	94
3.7.4	Discussion	95
3.7.5	Conclusions	98
3.8	Final conclusions on protein cytochemistry of C cells	99
4.	SILVER BINDING IN CANINE C CELLS	101
4.1	Introduction	101
4.1.1	An analysis of methods of silver impregnation used for C cells	102
4.1.2	General principles of silver impregnation	105
4.1.2.1	Electrostatic interaction and silver deposition	108
4.1.2.2	Chemical end-group interaction in silver deposition ...	108
4.1.3	Intracytoplasmic structures concerned with silver binding in C cells ...	109
4.2	Purpose of the present study on metallophilia of C cell granules	110
4.3	Silver impregnation - general methods ...	111
4.3.1	Material and methods	111
4.3.2	Results	112
4.3.3	Discussion	115
4.4	Oxidation, alteration of protein groups and silver impregnation	119
4.4.1	Material and methods	119
4.4.2	Results	121
4.4.3	Discussion	124
4.5	Conclusions	126
5.	C CELLS OF THE NORMAL HUMAN THYROID GLAND ...	128
5.1	Introduction	128
5.2	Terminology of human thyroid cells and historical background	129
5.3	Choice of material	131
5.4	Choice of methods of study	132
5.5	Enzyme demonstration of C cells in canine thyroids	134
5.5.1	Introduction	134
5.5.2	Material and tissue preparation ...	134
5.5.3	Methods	135
5.5.4	Results	137
5.5.5	Discussion	142
5.5.6	Conclusions	146

		Page
5.6	C cells in the thyroid gland of human neonates	146
5.6.1	Material and methods	146
5.6.2	Results	149
5.6.3	Discussion	158
5.6.4	Conclusions	165
6.	CLINICAL APPLICATIONS OF THE PRESENT STUDIES ...	167
6.1	Argyrophilic granules in tumours of C cells	167
6.2	Teratomatous growths of thyroid gland and C cells	167
6.3	C cell distribution and surgery of C cell tumours	167
6.4	Distinction of C cells and oxyphil cells of the human thyroid gland	167
ADDENDUM A	... ...	169
REFERENCES	... ...	170
REPRINTS	... ...	194

LIST OF TABLES

		Page
I.	Terminology applied to C and oxyphil cells of the thyroid (in chronological order of first usage)	13
II.	The prototropic groups and dissociation constants of amino acids found in polypeptides	18
III.	Canine material and it use in the cytochemical study ...	20
IV.	Histochemical reactions for disulphides and sulphydryl radicles	33
V.	Staining reactions of proteins in thyroglobulin, follicular and C cells of the canine thyroid gland	35
VI.	Staining results of protein-conjugated carbohydrates in the thyroglobulin, follicular and C cells of the canine thyroid gland	66
VII.	The effects of blocking and other modifying procedures on the periodic acid-Schiff (PAS), colloidal iron (CI), aldehyde fuchsin (AF) and toluidine blue (TB) staining reactions of the C cell of the canine thyroid gland ...	77
VIII.	The effects of enzymatic and non-enzymatic cleavage procedures on the staining of the C cell cytoplasm by PAS, aldehyde fuchsin, colloidal iron and toluidine blue	95
IX.	Forms of silver and their solvent generally used for silver impregnation of tissue sections	103
X.	Reducing (developing) agents used in silver impregnation methods	105
XI.	A semi-quantitative assessment of the granular metallophilia in the C cells of the canine thyroid gland under different conditions of silver impregnation ...	113
XII.	The results of oxidation and end-group modification on the granular argyrophilia and aldehyde fuchsin staining of canine thyroid C cells	122
XIII.	Substrates suitable for demonstrating simple esterases (a) non-specific and (b) specific esterases ...	136
XIV.	Neonatal thyroidectomies	147
XV.	Cytochemical reactions in follicular and C cells of young dogs and human neonates	150
XVI.	Quantitative distribution of αGPDH and NADH reductase in thyroid cells of human neonates and relationship of presence of these enzymes to toluidine blue metachromasia	158
XVII.	Cytochemical proporties of human (adult) oxyphil and human (neonatal) C and AC cells of the thyroid gland ...	164

PREFACE

The incentive for this study was a universal lack of knowledge about the human thyroid C cells. My plans were conceived in 1968 when few micro-anatomical details were available on the human C cell. Histological texts which mentioned C cells or 'parafollicular' cells, as they were then commonly known, quoted information from observations on non-human animals. These strengthened my resolve to study human tissue. Trials on non-human tissue and some cytochemical experience was needed to realise these aims. My interests therefore widened to embrace a number of cytochemical reactions to which a large portion of this dissertation is now devoted.

Investigations on thyroid C cells by other workers were numerous during 1969-1971 when I undertook the present work. This is reflected in four international symposia that took place on calcitonin and C cells during this time. Papers contained in the proceedings of the symposia initially stimulated my endeavours but then dampened efforts to carry the study to a conclusion as several reports on human C cells appeared. The dissertation is therefore long overdue. This is also shown in the methods which I have employed in the study. They were new in the literature a few years ago but are now established for diagnostic purposes in pathology.

W.E.W.R.

September 1976

ACKNOWLEDGEMENTS

I am gratefully indebted to Professor P.V. Tobias for his enthusiasm and encouragement without which I would never have commenced this study. I wish to express equally my gratitude to Professor A. Andrew and Professor M. Shear for numerous discussions and for their forebearance during the execution of the experimental work and the preparation of this dissertation. I should like to express my thanks to the technical staff of the Departments of Anatomy and Oral Pathology, especially to Mr. A. Scott, Mrs. B. Wray, Miss J. Walker, Mr. R. Herman and Mr. A Hughes for the guidance, tolerance and understanding which they afforded me during this study. Mrs. E.D. Parkin and Mrs. I.A. Tate kindly undertook the typing of the draft dissertation.

This work would not have come to fruition without the financial help of the Medical Research Council (Grant No. : M10/70/A2/RE) and of a Round Table Research Fellowship (1970). I wish to thank both organizations for their generous assistance

To my wife and children I want to extend a warm 'thank you' for their support and gentle prodding throughout the years. None of those late nights devoted to writing and re-writing could have been possible without the patience and unselfish co-operation of my wife. To her I am most grateful of all.

ABSTRACT

A cytochemical analysis was undertaken of C cells of thyroid glands obtained from sixteen young dogs and five human still-born neonates.

Tissues were fixed in selective liquid fixatives (Helly's, Carnoy's, glutaraldehyde-picric-acetic acid, glutaraldehyde-potassium dichromate-sodium sulphate and formol-saline) or fixed in formalin vapour after freeze drying. Cryostat sections and some of the above fixatives were used for enzyme demonstration.

Simple and conjugated proteins in the cytoplasm of canine C cells were studied by numerous cytochemical reactions. Acetylation, methylation, benzoylation, nitrosation, acid hydrolysis and aldehyde blockade as well as enzyme hydrolysis were employed to evaluate the aldehyde fuchsin, colloidal iron, toluidine blue and periodic acid-Schiff staining reactions in canine C cells.

I have confirmed that the cytoplasm of canine C cells contains an abundance of acidic protein groups which are due to side-chain carboxyls. Mild acid hydrolysis, amongst other reactions, may result in peptide hydrolysis at the aspartyl group, which hydrolysis contributes to the anionic charge in the C cell cytoplasm. Basic proteins are not readily stained in the canine C cell. Disulphide groups are numerous and their oxidation adds to the negative charge of the C cell cytoplasm.

I found that the positive aldehyde fuchsin and colloidal iron reactions are not attributable to mucosubstances such as sulphomucins, sialomucins or acidic mucopolysaccharides, but seem to be imparted by an

acidic protein unconjugated to polysaccharide. A positive aldehyde fuchsin reaction probably depends on both disulphide and carboxyl groups within C cells. A positive colloidal iron reaction in canine C cells requires the presence of carboxyl groups but an increased number of these groups does not enhance the staining reaction.

The conditions required generally for silver binding and more specifically for the Grimelius silver impregnation in canine C cells were evaluated by oxidation and various other cytochemical procecures.

I found that the argyrophilia of thyroid C cells depends upon an exogenous reducing agent and upon pH, optimal impregnation occurring at a slightly acid pH. Oxidation preceding silver impregnation by the Grimelius method, reduces the affinity of structures in the cell for silver nitrate. Indirect evidence supports the view that argyrophilia in the C cells depends upon disulphide groups. It is suggested that silver nitrate and disulphide groups react in C cells to form silver mercaptide which produces the argyrophilia.

The presence of C cel s was demonstrated in human neonates by means of cytochemical methods known to demonstrate C cells in dogs. C cells were found predominantly in the posterior region and upper pole of both lobes where they were found scattered in clusters of six to eight cells per high power field Two morphological forms of normal human C cells were observed - an ovoid cell and one with cytoplasmic processes.

By demonstrating oxidative enzymes and masked metachromasia, three categories of epithelial cells have been shown in the neonatal thyroid

gland : A (follicular), C and AC (intermediate) cells. The latter may be homologous with the oxyphil cells observed in normal and pathological adult thyroid glands.

The clinical applications in which I have used the results of the above studies are outlined in the last section of the dissertation.

PUBLICATIONS

The following publications and manuscripts are based on the results of the present study :

(1) Roediger, W.E.W. 'A comparative study of the normal human neonatal and the canine thyroid C cell', Journal of Anatomy, 115:255-276, 1973

(2) Roediger, W.E.W. 'The nature of silver binding in the canine thyroid C cell', South African Journal of Medical Science, 38: 17-22, 1973.

(3) Roediger, W.E.W. 'The oxyphil and C cells of the human thyroid gland. A cytochemical and histopathologic review'. Cancer, 36:1758-1770, 1975.

(4) Roediger, W.E.W. 'Derivation of carboxyl groups for the 'masked metachromasia' of canine C cells by hydrolysis of polypeptides at the aspartyl group', Histochemical Journal (accepted for publication, Sept. 1976).

(5) Roediger, W.E.W. 'The aldehyde fuchsin and colloidal iron reaction in the canine thyroid C cell', in preparation.

Results from this study on C cells were used to support arguments pertinent to clinical observations and clinical practice, made in the following publications :

(1) Roediger, W.E.W., Spitz, L. and Schmaman, A. 'Histogenesis of benign cervical teratomas', Teratology, 10:111-118, 1974.

(2) Roediger, W.E.W. 'Thyroidectomy for non-familial medullary carcinoma', British Journal of Surgery, 63:343-345, 1976.

Reprints of the above publications have been included at the end of this dissertation.

1. INTRODUCTION

1.1 Discovery of the hormone, calcitonin, and its organ of origin

In 1959 Sanderson and his colleagues (Sanderson et al., 1960) undertook a series of experiments which heralded the announcement of a new hormone that participates in the homeostasis of serum calcium in mammals. They showed that dogs which had undergone thyro-parathyroidectomy were unable to handle an intravenous calcium load in the same manner as normal dogs. Serum calcium in the operated dogs, which received an infusion of calcium, attained higher levels compared with those in unoperated dogs and failed to return to normal after 24 hours. This hypercalcaemia was thought to be the result of the loss of a controlling factor surmised to arise from the excised thyroid-parathyroid complex.

Independent studies by Copp et al. (1961) which were also based on the extirpation of the thyroid-parathyroid complex from the dog, led to similar conclusions. They postulated that a hypocalcaemic principle, designated 'calcitonin' (a contraction of 'calcium' and 'tone') was produced by this complex and, more specifically, suggested that it arose from the parathyroid glands. Support for the view that calcitonin arose from the parathyroid gland was marshalled by these workers from the observations that (1) parathyroid extracts administered to animals, produced hypocalcaemia (Copp et al., 1962) and (2) venous 'effluent' of perfused thyroid-parathyroid complex in sheep and dogs induced hypocalcaemia in experimental animals (Copp and Henze, 1964).

Copp's conclusions were by no means incontrovertible. His parathyroid extract was perhaps contaminated with thyroid tissue and the viability of the parathyroid glands in his perfusion experiments may have been questionable. In addition Hirsch et al. (1963) showed, by a different set of experiments in the rat, that the thyroid also contained a

hypocalcaemic principle. To distinguish this from Copp's calcitonin (of parathyroid origin), they named their principle 'thyrocalcitonin'. Hirsch et al. (1964) furthermore showed that a hypocalcaemic factor could be extracted from bovine thyroids but not from the parathyroid or thymus and also that this factor was a polypeptide.

The distinction between parathyroid 'calcitonin' and thyroid 'thyro-calcitonin' was resolved by perfusion experiments in goats conducted by Foster et al. (1964a). In this animal, perfusion of the parathyroid gland alone is possible, because it is separate from the thyroid gland, unlike the situation in the dog which was used by Copp. High ionic calcium perfusion of the parathyroid-thyroid complex and then of the parathyroid gland separately, left no doubt that the hypocalcaemic activity arose from the thyroid and not from the parathyroid gland. Extraction and partial purification of the porcine hypocalcaemic factor from parathyroid-free thyroid glands was reported by the same group of workers (Baghdiantz et al., 1964). Accumulated experimental work reported at two international symposia, (Taylor, 1968, 1970) indicated that the parathyroids have little or no hypocalcaemic activity. Thus in their important pioneering work, Copp et al. erred in their conclusions as to the organ of origin of this hormone.

1.2 Cellular source of calcitonin

The biochemical analyses and chemical purification of calcitonin (Tenenhouse et al., 1965, Potts et al., 1967) proceeded concurrently with the investigation of cells which, within the thyroid, could be related to the production of this hormone. Foster et al. (1964b) were the first to suggest that calcitonin arose from a specific group of cells within the thyroid gland and termed these 'mitochondrion-rich'

cells (subsequently called C cells by Pearse in 1966) as distinct from the follicular cells which were 'mitochondrion-poor'. Their reasoning was based on observations that the former cells had morphological and cytochemical characteristics which were different from those of follicular cells. In the dog these cells contained argyrophilic granules within their cytoplasm and had a high content of cytoplasmic hydrolases (alkaline phosphatase and alpha-glycerophosphate dehydrogenase [α-GPDH]). Such cellular features were not present in follicular cells. In addition quantitative changes of argyrophilic granules and hydrolases could be produced by systemic infusions of high ionic concentrations of calcium (Pearse, 1966; Matsuzawa and Kurosumi, 1967). Argyrophilic granules decrease in numbers following infusions and this was thought to be the result of their release into the systemic circulation.

The foregoing investigations provided indirect evidence that calcitonin could be a cellular product which arose from a separate set of cells within the thyroid gland of mammals. Corroborative evidence from man strengthened this hypothesis. Calcitonin was readily extracted from a tumour which, from histopathological features described by Williams (1966), was thought to arise from C cells of the thyroid gland (Riniker et al., 1968). This calcitonin provided a means for more direct evidence that the cellular origin of this hormone was the C cell. Antibodies against calcitonin could now be raised in experimental animals for use in the immuno-fluorescent antibody technique. By this method Bussolati and Pearse (1967) showed that antibodies against calcitonin were localized to the cytoplasm of C cells in the thyroid gland of dogs. No follicular cells showed any fluorescence. Subsequently the ultrastructural localization of peroxidase-labelled antibody against calcitonin revealed that the antigenic sites of calcitonin were

localized on the secretory granules and the cisternae of the rough endoplasmic reticulum of C cells in the dog (Kalina and Pearse, 1971). Good direct evidence was thereby provided that the C cell of the thyroid was the cellular source of calcitonin.

1.3 Biochemistry of calcitonin and cytochemistry of C cells

Consideration of the biochemical properties of the product secreted by the C cell and of the cytochemical properties of the same cell are relevant to each other in as far as native calcitonin and C cells can be analyzed by the same chemical procedures. These procedures are adapted for analysis of different forms of the same substance, that is, of the native protein by the biochemist and of the processed form in tissue by the cytochemist. Results that are obtained from biochemical analysis of purified calcitonin and those obtained by cytochemical analyses are not necessarily comparable. Nevertheless, chemical properties of calcitonin may be used to assist in the interpretation of cytochemical observations.

1.3.1 Biochemistry of calcitonin

As no analysis of amino acid sequence is available for canine calcitonin, porcine calcitonin and its biological properties were chosen as a reference model in this cytochemical study. It cannot be assumed that porcine and canine calcitonin are identical; however, its polypeptide nature and those biochemical properties common to all mammalian calcitonins can be assumed to apply to canine calcitonin.

Porcine calcitonin is an acidic polypeptide which is constituted by 32 amino acids (Fig. 1) and has a pI (pH at the isoelectric point) of 4,8 (Kutsky, 1973). The proportion of charged amino acids relative to the total number of amino acids is small (Potts et al., 1968).

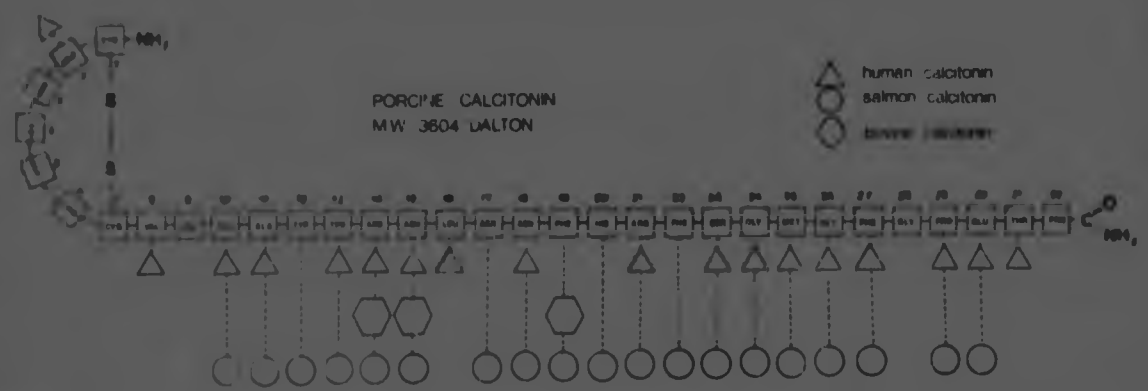

Fig. 1 - Amino acid sequence of calcitonin; the C-terminal amino acid is proline-amide. Symbols △, ○, ⬡, indicate a different amino acid at each point indicated.

Based on 1) Brewer et al.(1968a)
2) Brewer (1970)
3) Riniker et al.(1968)

Calcitonin is readily soluble in aqueous solutions and the solubility is unaltered by denaturing (Potts et al., 1968). The molecular weight of the polypeptide is 3604 Daltons.

Some of the properties of the constituent amino acids within the calcitonin molecule are unique to this hormone whereas others conform to a pattern of properties common to other polypeptide hormones (insulin, glucagon, vasopressin and oxytocin). There is an intra-chain disulphide bridge between amino acids 1 and 7 but no inter-chain disulphide bridge (Brewer et al., 1968b). The polypeptides insulin and vasopressin also contain intra-chain disulphide bridges. The disulphide of calcitonin fails to react with p-mercuribenzoate (Brewer et al., 1968b), a reagent used in cytochemistry for the detection of disulphide groups. However, on chromatograms, the nitroprusside-cyanide reaction for disulphides is weakly positive (Rittel et al., 1968). The other sulphur containing amino acid, methionine, which is in the 25 position, can be oxidized to sulfoxide or alkylated to the carboxyl methylsulfonium salt (Brewer et al., 1968b). All these chemical properties are of application to cytochemical procedures.

There is ready solvent accessibility of tyrosine, tryptophan and methionine in calcitonin (Brewer et al., 1968a). This property is also observed in glucagon (Bromer et al., 1957). Solvent accessibility is not, as is usually the case with proteins, dependent on denaturation. Besides oxidative and sonic denaturation, calcitonin can, for further analysis, be split into subunits of poly-amino acids by enzyme and chemical cleavage. Tryptic digestion splits calcitonin into three peptides; prior oxidation of calcitonin with performic acid may hasten this digestion (Potts et al., 1968). Cyanogen bromide produces a cleavage of amide link 25-26 (Potts et al., 1968) and acid hydrolysis yields multiple peptide

fractions (Brewer et al., 1968a). In addition acid hydrolysis converts asparagine to aspartic acid and glutamine to glutamic acid (Brewer et al., 1968a). Subunits of calcitonin which result from the above fractionation methods can be colorimetrically assessed. Thus the ninhydrin reaction for amines, on chromatograms of peptide fractions, is weakly positive (Khar' et al., 1968) and dansyl chloride readily attaches to tryptic subfractions (Bell et al., 1968). These latter biochemical procedures are also used in cytochemistry and can be applied in the cytochemical analysis of C cells (see section 3.4).

The terminal amino acid of the polypeptide chain of calcitonin is a proline-amide at the carboxyl terminal (C-terminal) (Bell et al., 1968) and a cystine group at the alpha-amino terminal (Brewer et al., 1968). Calcitonin is not conjugated to any lipids or amino sugars at either terminal amino acid or at any intra-chain group of amino acids.

1.3.2 Cytochemistry of C cells

In contrast to the above definitive and detailed observations on native calcitonin, one notes from the literature, that cytochemical investigations of the C cell were empirical prior to 1964. Thereafter biochemical data, which became available, to some extent orientated cytochemical studies. These biochemical data were also used to re-interpret those empirical observations made prior to the discovery of calcitonin. Ludwig (1954), Sandritter et al. (1956) and Gabe (1959, 1961) had undertaken such empirical analyses. They provided limited information about the lipid, carbohydrate and protein content of these cells. Following the discovery of calcitonin, the C cells were investigated further by Foster et al. (1964b), Pearse (1966, 1968b, 1969a, 1969b), Solcia and Sampietro (1968), Lietz and Donath (1970) and Hakanson et al. (1972) who directed their

attention to cellular enzymes, catecholamine uptake, protein cytochemistry and the electron microscopy of this cell. Pertinent is that the structural (amino acid) analysis of calcitonin was made available late in 1968 by Potts et al. (1968). This knowledge added some support to the deductions that had been made concerning the chemical groups, for example carboxyl groups, that were postulated by Solcia and Sampietro (1968) and Pearse (1969b) to be involved in certain staining reactions of the C cell.

A number of amino acids in the C cells are amenable to cytochemical analysis, especially those amino acids which are accessible to solvents (see above). These analyses are often the subject of disagreement and in some instances the nature of the reactive groups which are responsible for a colour reaction is disputed. This is illustrated by investigations on phenols and residues of aromatic amino acids in the C cell. Sandritter et al. (1956) observed that the post-coupled tetrazonium reaction for tryptophan was positive in dog C cells and the maxima of curves of spectrophotometric absorption in the C cell were those for tyrosine and tryptophan. However, Pearse (1966), using Adam's tryptophan reaction and the diazotization-coupling method for tyrosine, could not show detectable amounts of these amino acids in C cells of dogs. In addition, the diazonium-salt coupling for tyrosine was not positive in canine C cells (Solcia and Sampietro, 1968). These results from different workers are at variance and provide a field for further investigation. Collateral evidence for one or other observation could perhaps be found to settle the above contentious points.

After oxidation of tissues with peracetic or performic acid, aldehyde fuchsin is known to stain structures with a high cystine content, for example the beta cells of the pancreas (Scott and Clayton, 1953),

keratin and thyrotrophin-producing cells of the pituitary (Purves and Griesbach, 1957). The positive aldehyde fuchsin reaction given by C cells of the thyroid and beta cells of the pancreas is thought to be due to the disulphide (cystine) bonds of the polypeptide hormones synthesized in these cells (Lietz and Donath, 1970). There is good evidence that the staining of the beta cell by aldehyde fuchsin is due to the insulin molecule (Kvistberg et al., 1966): these workers showed that aldehyde fuchsin selectively stained oxidized insulin which was held fixed in polyacrylamide gel. However, this evidence is no proof that cystine is the reactive group. Other work suggests that carboxyl groups (Ortman et al., 1965) and enamines (Mander et al., 1968) mediate the attachment of this dye.

In view of these diverse opinions of the reactive group, the C cell could provide an additional model of study for the aldehyde fuchsin reaction. Suitable modifications, chemically induced, prior to staining the C cell with aldehyde fuchsin may help to elucidate the problem of which cytochemically reactive groups yield positive staining.

Salts of the heavy metal lead, iron, tungsten and silver are used for staining reactions which, in C cells, bring out tinctoral features different from those seen in follicular cells. Gabe (1959, 1961) employed the standard colloidal iron stain to study canine and reptilian C cells. There gave a positive Prussian blue reaction which indicates the binding sites of colloidal iron and is believed to signify the presence of acidic mucopolysaccharides or conjugated glycoprotein (Pearse, 1951). Sousa and Carvalheira (1969) supported this view and postulated that C cells have a high content of acidic mucopolysaccharide. They were opposed in this interpretation by Lietz and Donath (1970) who preferred the hypothesis that reactive groups of the acidic polypeptide (calcitonin) were responsible

for a positive reaction. It should be possible to resolve these differences by suitable cytochemical manipulations particularly if carbohydrates could be excluded as participant groups in this staining reaction.

As indicated previously, C cells contain argyrophilic granules. These were first observed by Nonidez (1932) who used the Cajal silver impregnation method for an investigation on the innervation of the thyroid gland in dogs. Argyrophilia of the granules was confirmed and also demonstrated with the Cros-Schultze (Sandritter and Klein, 1954), Bodian-type (Kameda, 1968) and Grimelius silver (Solcia et al., 1970) impregnation methods. The reason for selective attachment of silver to secretory granules of these endocrine cells is not clear. In vitro studies on samples of calcitonin, phospholipids and complex carbohydrates failed to indicate what intracellular biochemical substances within the cell, are responsible for silver binding. All these substances failed to react with silver (Solcia, personal communication, 1971).

A general cytochemical study of C cells is incomplete without an evaluation of their carbohydrate content. Sandritter et al. (1956) comment that 'transitional forms' of C cells in the dog give a positive periodic acid-Schiff (PAS) reaction. They provide no further explanation for their terminology of 'transitional forms' and do not elaborate on this observation. C cells of reptiles and amphibians (Gabe,1961) and the cat (Sousa and Carvalheira, 1969) contain a cytoplasmic component that gives a positive PAS reaction, whereas a negative reaction is observed in the C cells of rats (Stux et al., 1961) and pigs (Carvalheira and Pearse, 1967). Interpretations of a positive PAS reaction in C cells have been various. Pearse (1966) states that it indicates a small amount of carbohydrate which is not glycogen whereas Sousa and Carvalheira (1969) attribute this

result to acidic mucopolysaccharides. Certainly other staining reactions used to demonstrate acidic mucopolysaccharides, for example toluidine blue metachromasia and the colloidal iron reaction, give a positive reaction in C cells but no evidence for the groups responsible for the PAS reaction is thereby provided.

One draws the conclusion that the cytochemical characteristics of the thyroid C cell have on numerous occasions been the subject of disagreement. Indeed new knowledge of the biochemistry of the synthetic product from C cells has not altered such disagreement. A further study, taking cognizance of the function of the C cell as a unit producing acidic protein may elucidate some cytochemical observations of proteins that have been made in the past. The C cell therefore warrants further cytochemical study.

1.4 The human C cell

The microanatomy, distribution and cytochemistry of C cells in the human gland, in contrast to the microanatomy and cytochemistry of C cells in other animals, was unknown at the time that this investigation was commenced (1970). Minimal information on human C cells was available. There are several reasons for this.

(1) Studies of normal human thyroid glands in the past had been fairly exhaustive and re-examination of normal tissue was deemed unnecessary. Indeed the C cells cannot be identified if thyroid sections are stained with routine stains such as haematoxylin and eosin (Braunstein and Stephens, 1968). Specialized stains are required to reveal their presence amongst follicular cells.

(2) In the past (1881-1964) differences in opinion over the nomenclature of cells constituting the mammalian thyroid-parathyroid complex were

apparent. The C cell was consequently not identified as a separate entity by all investigators. Ludwig (1954) for instance, disclaimed their existence in the thyroid gland of the rat and dog.

(3) The exact function of C cells in animals was unknown prior to 1964 and no impetus could be found to investigate these cells in human thyroid glands.

(4) The existence of a pathological form of follicular cell (oxyphil cell) within human a thyroid glands produced speculation about the kinship of this cell to the non-human C cell in the thyroid gland (Arvy, 1971, Beskid and Kobuszewska-Faryna, 1972). An inconsistent nomenclature and the poorly understood pathological form of human follicular cell clouded the study of C cells in human glands.

The points of difference between human oxyphil and human C cells have been reviewed (Roediger, 1975 - see Section 5.2). These two cell types have several cytochemical characteristics in common, yet other features make it possible to differentiate them from each other (Table XVII). The nomenclature employed for these cells in man and mammals, has been tabulated (Table I) in order to facilitate correct usage and avoid confusion of terminology and cell types.

As far as I am aware, the demonstration of C cells in the thyroid of normal adults was first reported by Sandritter and Klein (1954). They studied 12 normal human thyroid glands by means of silver impregnation methods and commented on the small number of cells which they found in a 'few' glands. Fourteen years later Beskid and Rosciszewska (1968) searched for C cells in normal human adults using those methods employed by Foster et al. (1964b) to identify C cells in dogs. They did not convincingly demonstrate C cells in normal human thyroid glands.

TABLE I - Terminology applied to C and oxyphil cells of the thyroid (in chronological order of first usage)

C cell	Oxyphil cell
Paranchymatous cell (Baber, 1876)	Askanazy cell (Askanazy, 1898)
Protoplasmreiche Zelle (Hürthle, 1894)	'Hürthle cell' (Ewing, 1919)
Ovoid cell (Bensley, 1914)	Oxyphil cell (Eisenberg and Wallerstein, 1932)
Interfollicular epithelium cell (Takagi, 1922)	Oncocyte (Hamperl, 1937)
Mitochondria-poor cell (Seecof, 1924)	Eosinophilic cell (Roth *et al.*, 1962)
Parafollicular cell (Nonidez, 1932)	
Macrothyrocyte (Zechel, 1933)	
Gray cell (Godwin, 1937)	
Neurohormonal-cell (Sunder-Plassman, 1939)	
Giant-light cell (Altman, 1940)	
Helle Zelle (Feyrter, 1946)	
Argyrophil cell (Sandritter, 1954)	
Replacement or chromophil cell (Dejardin, 1955)	
Light cell (Stux *et al.*, 1961)	
Mitochondrion-rich cell (Foster *et al.*, 1964b)	
C cell (Pearse, 1966b)	

However, their presence in man was proved by Kalina et al. (1970) who demonstrated them by means of fluorescent antibodies to calcitonin.

Further searches for C cells in human adults have been made in pathological thyroid glands. Solcia et al. (1970) noted argyrophilic cells situated posteriorly in thyroids removed for carcinoma. Braunstein and Stephens (1968), in their electron micrographs of goitrous thyroid glands noted two cells which they thought were C cells because of the presence of granules. In another electron microscopic study Teitelbaum et al. (1971) showed several C cells in a normal portion of an adenomatous thyroid gland. These cells contained a higher concentration of cytoplasmic granules than those observed by Braunstein and Stephens (1968).

One concludes from the above that human C cells are few and difficult to define in the mass of follicular cells in the t . Normal human thyroid tissues had not been re-examined and the observations in goitrous glands are hampered by distortions of pathological processes. A systematic investigation of C cells in normal human thyroids remained to be undertaken.

2. AIMS AND PURPOSE OF THIS STUDY

2.1 Protein cytochemistry

From the foregoing appraisal it is evident that calcitonin is a simple polypeptide which is unconjugated to carbohydrates. In the cell the hormone is retained within the cytoplasm after conventional methods of fixation. My aim was to establish whether the known staining reactions of canine C cells were due to simple proteins (polypeptides) or conjugated protein, mainly glycoprotein (proteoglycans). This study was undertaken as an extension to the cytochemical observations already published by others.

During the analyses strongly positive aldehyde fuchsin and colloidal iron reactions were found in canine C cells. Mindful of the original aim I then also wished to establish the reactive groups mediating aldehyde fuchsin and colloidal iron staining. For this purpose several blocking and modifying procedures together with enzyme hydrolysis were used to analyse the aldehyde fuchsin, colloidal iron, PAS and toluidine blue metachromasia of canine C cells. In this way I hoped to use the alteration of the reactive groups which mediate staining of the latter two stains in a comparison of the results of the aldehyde fuchsin and colloidal iron staining reactions.

2.2 Silver binding in C cells

A renewed interest has been shown in the nature of silver binding in tissues (Velican and Velican, 1972, Swift, 1973). The argyrophilia of keratin, neurofibrils and connective tissue was reconsidered in these studies but the argyrophilia of C cells was not analyzed by these authors. Generally, cytologists have been reluctant to ascribe cytochemical specificity to any silver impregnation method because (1) minor changes in methodology of impregnation result in loss of

affinity of tissue structures for silver; (2) different impregnation methods produce the same results; and (3) complete reproducibility is not always achieved with certain methods. Such problems are not the subject of the present investigation. Rather a cytochemical assessment of silver binding is undertaken in conjunction with the results of protein cytochemistry obtained in the preceding analysis to determine the tissue groups participating in silver binding in dog C cells.

2.3 C cells in the human thyroid

There is now sufficient evidence to indicate that C cells occur within the thyroid gland of man. Nevertheless, when this study commenced, a paucity of information on the numbers, distribution and staining reactions of C cells was apparent from the literature. The aim therefore was to identify these cells in normal human glands and to study their distribution within the thyroid. For this purpose the results and experience gained by the preceding investigation (Sections 2.1 and 2.2) were used. Selected staining reactions from studies conducted by previous workers in non-humans, were chosen to demonstrate human C cells.

A further purpose would be served by studying the distribution of human C cells. Knowledge of their distribution would enable one to predict in which areas within the thyroid gland, carcinoma of C cells could potentially arise. This in turn might assist the surgeon in removing the total C cell bearing area of the thyroid gland in order to effect a cure of multifocal C cell carcinoma.

3. PROTEIN CYTOCHEMISTRY OF CANINE C CELLS

3.1 Introduction

There are several limiting factors to contend with in a study of reactive groups of proteins in fixed tissue.

The distinction between simple proteins (polypeptides) and conjugated proteins (lipo-, muco- or glyco-protein) is not easily made within a cell by means of cytochemical analysis. All components of mammalian cells are complex lipid-protein-carbohydrate structures. Furthermore the differentiation of structural proteins from synthetic proteins may be difficult unless the latter are contained within defined granules the case in C cells. Despite these difficulties it is preferable, in a cytochemical analysis, to separate proteins into groups : simple proteins, glycoproteins and lipoproteins. This division has been adhered to in the following sections.

Immunocytochemical studies with the electron microscope have confirmed the presence of immunoreactive groups of calcitonin in the secretory granules and rough endoplasmic reticulum of canine C cells (Kalina and Pearse, 1971). Therefore it may be possible that a diffuse stain and its granular accentuations could indicate components of the synthetic product of the cell. This assumption is upheld in this study but for proof, cytochemical techniques will ultimately have to be performed at an electron microscopic level.

The colorimetric determination of protein groups was initially employed in analytical chemistry, especially chromatography (Hamilton, 1960, Neurath, 1963); many of these methods have been modified for use in cytochemistry. In these methods protein groups and their side chains may react as polar residues (ionic binding) (Table II) or react through

TABLE II - The prototropic groups and dissociation constants of amino acids found in polypeptides

Source	Group	Unionized Uncharged >form	Dissociation Constant (pK Value)
tyrosine-O-sulphate and cysteic acid	sulphonic group	$R\text{-}SO_3H$	2.0
terminal phosphates	pyrophosphates	$HO\text{-}PO_2H\text{-}O\text{-}R$	± 3.0
C-terminal amino acid	terminal carboxyl, α carboxyl, or γ acyl-amido group	R-COOH	3.0-3.5
aspartic/glutamic acid	side chain	R-COOH	3.5-4.5
histidine	imidazole group	R=NH	6.7
asparagine and glutamine	side chain amido group	$R\text{-}CONH_2$	7
N-terminal amino acid	α amino, or terminal amino groups	$R\text{-}NH_2$	7.5-8.5
lysine	side chain amines (ε amino groups)	$R\text{-}NH_2$	9-11
tyrosine	phenyl or hydroxyl phenolic groups	R-OH	10
arginine	guanidyl groups	$H_2N\text{-}C(=NH)\text{-}NH\text{-}R$	9-12

References : (1) Coutts and Smail (1966, p.85)

(2) Pearse (1968a, p.115)

covalent binding or by means of other, non-covalent, bonds (hydrogen bonds or hydrophobic bonds). In the following analysis of the reactive groups of simple proteins, the reactive groups are arranged according to their pK value. In later sections consideration is given to conjugated proteins.

3.2 Material

Thyroid glands of dogs, as young as possible, were employed for cytochemical study. The sex of the animals, though noted, did not influence the choice of material as much as their age did. Young mammals (ox and sheep) have a higher level of calcitonin in the circulation than older animals (Hackeng and Schopman, 1971). This could be a reflection of a greater cellular metabolic activity in young animals. This feature would facilitate both the detection of C cells and demonstration of their cytochemical reactive groups. Indeed C cells were found more readily and in greater numbers in a preliminary study of glands of two young dogs (± 6 to 8 weeks old) than in the glands of two older animals (at least 6 to 8 years old). This discrepancy could be the result of atrophy of C cells with age. In addition, the thyroid gland in young dogs is smaller and the areas in the gland in which C cells are concentrated are therefore easier to find.

A variable in the dogs chosen was their nutritional state - a low protein and calcium intake presumably affects the function of C cells. Moderate malnutrition was sometimes corrected (see Table III) in the animals used though gross disease (worm infestation, skin disease, chronic diarrhoea and gross malnutrition) was eliminated through choice of animals.

Young animals (accurate age not usually known) were obtained from the municipal pound and killed by injecting intravenously with phenobarbitone (50 mg in 5 ml of 0.9% saline). Table III lists the

TABLE III - Canine material and its use in the cytochemical study

Number	Type	Age (Approximate)	State of nutrition	Methods of fixation or other processing
D1	mongrel	1 year	well nourished	80% alcohol, F/S, Helly's
D2	Ridgeback	10 years	obese	80% alcohol, F/S, Carnoy's
D3	mongrel	6 months	wasted, moderately malnourished	Carnoy's, F/S, GPA, Helly's
D4	mongrel	6 months	"	GPA, Bouin's, Helly's, liquid nitrogen
D5	mongrel	6 months	"	GPA, Bouin's, Helly's, liquid nitrogen
D6	mongrel	6 months	housed in Department of Surgery and fed high protein diet for 6 weeks	liquid nitrogen, Pearson's fixative
D7	mongrel	6 months		freeze dried, formalin vapour, GPA
D8	mongrel	6 months		freeze dried, formalin vapour, GPA
D9	mongrel	6 months		freeze dried, formalin vapour, GPA
D10	mongrel	6 months		Helly's, GPA, liquid nitrogen
D11	mongrel	6 months		Helly's, GPA, liquid nitrogen
D12	mongrel	6 months		Helly's, GPA, liquid nitrogen
D13	mongrel	2 years	malnourished	liquid nitrogen, Pearson's fixative
D14	mongrel	1 year	kept at Frankenwald animal farm for approximately 6 weeks - well fed	GDS, GPA
D15	mongrel	1 year		GDS, GPA
D16	mongrel	2 years		GDS, GDA

F'S = formol saline
GPA = glutaraldehyde, picric- and acetic acid
GDS = glutaraldehyde, potassium dichromate and sodium sulphate

animals, and details of each dog used together with the method of fixation. Thyroid glands were removed as rapidly as possible for (1) fixation in fluid fixatives and paraffin embedding; (2) freeze drying and formalin vapour fixation; and (3) sectioning in a cryostat.

3.3 Fixation of tissues

The choice of fixation depended on (i) the known reaction of fixatives with intracellular protein and (ii) the dependence of the cytochemical methods to be used on fixation for successful staining. This information was obtained from the literature on the relevant staining reaction. Fixatives were not chosen for their ability to maintain 'good anatomy': this meant that occasional sections were difficult to study because of artefacts.

(1) For ol-saline : Ten per cent formalin in 0.9 per cent saline (pH 3.6, 1950 m/osmoles) was used for tissue, sections of which were to be stained to demonstrate the distribution of C cells in canine tissue.

(2) Alcoholic fixatives : Alcohol (80 per cent aqueous) was used for the silver impregnation method as advocated by Cajal (Nonidez, 1932). Carnoy's fixative was chosen for its suitability for fluorescent dye staining because it does not induce tissue autofluorescence as does formalin (Eränko, 1964). This fixative was also used in the demonstration of glycogen which is optimally preserved by ethanol (Kugler and Wilkinson, 1950).

(3) Picrate-aldehyde fixatives : Picric acid precipitates proteins and forms salts with many amino acids (Schmidt, 1938). I thought that this property might be of use in preserving the polypeptide of C cells. There is supporting evidence for this in observations on the insulin-producing beta cells of the pancreas. Picric acid

precipitates insulin (Coutts and Smail, 1966) and thus enhances granule preservation of beta cells. Certainly, fixative containing picric acid (Bouin's) is recommended for staining beta cells with the trichrome stains (Culling, 1963). Bouin's fluid was modified by Solcia, et al. (1968) by replacing formaldehyde with glutaraldehyde to give a 6.25 per cent glutaraldehyde solution in aqueous picric and acetic acid. This fixative, called glutaraldehyde-picric-acetic acid or GPA, allows optimal staining of C cells with basic dyes of the thiazine series e.g. toluidine blue O (Solcia and Sampietro, 1968). These authors do not give their reasons for the use of glutaraldehyde but several biochemical and cytochemical reasons can be put forward in favour of such a substitution.

(a) Loss of cytoplasmic proteins is far less with glutaraldehyde- than with formaldehyde-fixation. Liver slices lose most of their protein, and chromaffin granules lose 30-40 per cent of their catecholamines if these tissues are fixed in formaldehyde; less catecholamine and no liver protein is lost with glutaraldehyde fixation (Hopwood, 1969, 1972).

(b) Grillo et al., (1971) have shown that the least loss of insulin (a polypeptide) occurs with glutaraldehyde as compared with other fixatives.

(c) In general the optimum pH for precipitation of proteins is that closest to their iso-electric point (Hopwood, 1972); the pH of glutaraldehyde is best matched for precipitation of calcitonin (pI = 4.8).

(d) Glutaraldehyde-fixed tissues show greater affinity for acid and basic dyes (Chambers et al., 1968) than do other fixatives. This property potentiates staining reactions with basic dyes (toluidine blue, as above).

(4) Dichromate-aldehyde fixatives : Chromate-containing fixatives were chosen as they preserve phospholipids and catecholamines in situ (Elftman 1954a, 1954b; Jaim-Etcheverry and Zieher, 1968, 1971). Phospholipids are by this means rendered insoluble in lipid solvents; this is probably the explanation for the preservation of mitochondria which have a high phospholipid content.

Helly's fixative which contains mercuric chloride, a coagulant protein fixative, was used according to Drury and Wallington's formulation (1967). Mercury was removed from tissue blocks before sectioning, by immersion for 12 hours in 70 per cent alcoholic-iodine.

Orth's fluid (Helly's fixative without mercuric chloride) is routinely used by pathologists in the demonstration of catecholamines in adrenal medulla. Substitution of formaldehyde by glutaraldehyde in Orth's fluid (glutaraldehyde-dichromate-sulphate, GDS) was undertaken by me in this study for several reasons.

(a) Biochemical tests on samples have shown that a mixture of formalin-dichromate and dopamine, nor-adrenalin or 5 hydroxy-tryptamine do not form precipitates whereas the same substances mixed with glutaraldehyde form precipitates with chromates (Jaim-Etcheverry and Zieher, 1971)

(b) As indicated above, glutaraldehyde minimizes loss of protein from tissues and preserves amines far better than does formaldehyde.

The formulation of GDS that was used is as follows :

25% glutaraldehyde		25 ml
potassium dichromate	2.5 gm	in 100 ml aq. dest. 75 ml
sodium sulphate	1.0 gm	

This results in a 6.25% aqueous solution of glutaraldehyde, pH 4.9, 1050 m/osmoles.

(5) Freeze drying and formalin vapour fixation : Vapour fixation was employed on freeze-dried tissue. Freeze-drying is the drying of tissue by sublimation of ice crystals, formed within the cell, in vacuo.

Compared with conventional alcohol dehydration several advantages are attendant on this method :

(a) Unbound water is removed with the least possible change in chemical composition of intracellular constituents.

(b) There is minimal loss of soluble constituents from the cell e.g. polypeptides, mucoproteins and biogenic amines. Tock and Pearse (1965) for instance, showed improved staining of freeze-dried tissue over that of routine methods for mucins. They attributed this to decreased loss of mucoprotein as the degree to which they are dissolved out of the tissue is minimized.

(c) Cytochemical 'reactive groups' are not altered as extensively as in conventional methods of preparation (Pearse, 1968a, p.27)

Disadvantages of freeze-drying are as follows :

(a) Freeze-drying introduces morphological artefacts - there is fracturing and ice crystal formation within the cell and the surrounding tissue components.

(b) The method establishes a transient, intracellular hypertonicity during the fall in temperature between the freezing point ($-10^{o}C$) and the eutectic point of the tissue ($-55^{o}C$) (Mazur, 1966). This intracellular hypertonicity can be counteracted by 'non-penetrating' cryoprotective agents (Mazur, 1970; Meryman, 1971) which protect the cells from damage by reducing the electrolyte concentration (molarity) of the residual unfrozen solutions in and around the cell.

(5) Freeze drying and formalin vapour fixation : Vapour fixation was employed on freeze-dried tissue. Freeze-drying is the drying of tissue by sublimation of ice crystals, formed within the cell, in vacuo.

Compared with conventional alcohol dehydration several advantages are attendant on this method :

(a) Unbound water is removed with the least possible change in chemical composition of intracellular constituents.

(b) There is minimal loss of soluble constituents from the cell e.g. polypeptides, mucoproteins and biogenic amines. Tock and Pearse (1965) for instance, showed improved staining of freeze-dried tissue over that of routine methods for mucins. They attributed this to decreased loss of mucoprotein as the degree to which they are dissolved out of the tissue is minimized.

(c) Cytochemical 'reactive groups' are not altered as extensively as in conventional methods of preparation (Pearse, 1968a, p.27)

Disadvantages of freeze-drying are as follows :

(a) Freeze-drying introduces morphological artefacts - there is fracturing and ice crystal formation within the cell and the surrounding tissue components.

(b) The method establishes a transient, intracellular hypertonicity during the fall in temperature between the freezing point ($-10^{o}C$) and the eutectic point of the tissue ($-55^{o}C$) (Mazur, 1966). This intracellular hypertonicity can be counteracted by 'non-penetrating' cryoprotective agents (Mazur, 1970; Meryman, 1971) which protect the cells from damage by reducing the electrolyte concentration (molarity) of the residual unfrozen solutions in and around the cell.

(c) Slow freezing may disrupt lipid protein complexes (Lovelock, 1957).

(d) Under- or over-drying of proteins may affect their structural stability. They have a definite folded structure that is dependent on bound water (Greiff, 1971). Removal of bound water may therefore alter the physicochemical properties of proteins.

In considering the above advantages and disadvantages for this study, efforts were predominantly made to reduce the artefacts resulting from intracellular ice crystal formation. Pease (1967) states that 95 per cent of the cytoplasmic volume can be frozen without evidence of crystallization damage. The size of crystals formed is related to the cooling velocity or freezing rate of tissue - the more rapid the cooling rate the smaller are the ice crystals. Meryman (1966) established that the rate of temperature fall following completion of freezing and the rate of temperature boundary advance throughout the tissue, are parameters that determine the amount of crystal formation. The latter parameter is to a large extent dependent on the temperature conductivity of the coolant. In addition the rapidity of cooling determines the time of exposure of intracellular components to a hypertonic state (Mazur, 1966).

Cognizance of the above features was taken in the choice of quenching agent for thyroid tissue. Several agents were considered (i) liquid nitrogen; (ii) hexane in alcohol cooled with dry ice; (iii) isopentane cooled in liquid nitrogen; and (iv) mono-chloro-difluoromethane (Freon 22) cooled in liquid nitrogen. Freon 22 was chosen as it has a rapid cooling rate ($0^{o}C$ to $-158^{o}C$ in 9 secs) (Rebhun, 1964) which is slightly more rapid than that of isopentane

(Trump et al., 1964) and that of hexane (Chayen, et al., 1969, p.4), and preserves the microanatomy exceedingly well. Pease (1967) used Freon 22 for preparing sections for electron microscopic studies. Such sections reflected the minimum distortion through ice crystallization.

Method of freeze-drying

A thermo-electric freeze-dryer (Speedivac - Pearse Model 1, Edwards) was employed. The cooling device is a two stage thermo-module producing cold through the Peltier effect. The dessicant used in the vacuum chamber was phosphorus pentoxide contained in aluminium boats. In addition to the one aluminium boat supplied, three further ones were made in order to provide a greater surface area of phosphorus pentoxide in the freeze dryer and therefore more efficient drying (Fig.2).

The following routine was undertaken. The thyroid gland was dissected out in anaesthetized dogs. Transfer time from the moment that the thyroid gland was devascularized until it was quenched was usually less than 20 seconds. Each thyroid lobe was cut into slices 2.0 to 2.5 mm thick and if the diameter of the lobe exceeded 0.5 cm then the slices were cut in half. Thus pieces of tissue 2 mm by 3 mm by 2.5 mm were mounted, one at a time, on 0.5 x 0.5 cm aluminium foil of which one corner was folded up to facilitate handling. This foil was placed on a glass ladle for immersion in the quenching agent. The agent Freon 22 was collected from a storage cylinder into a 50 ml glass beaker which was then lowered into liquid nitrogen. When the Freon 22 began to solidify, the tissue pieces were lowered into the quenching agent and allowed to freeze for 10 - 11 seconds. Not more than four pieces were quenched at any one freeze-drying session in order to ensure optimal dissecation. Tissue pieces were then removed one by one from the quenching agent and as rapidly as possible placed in the freeze-dryer,



Fig. 2 - Four aluminium boats around the cold plate of Edwards Speedivac-Pearse I freeze-dryer.

the cold plate of which was previously cooled to -45°C. Drying was carried out at a pressure of 10^{-3}Torr for 8 - 12 hours at a temperature of -40°C.

Several vapour fixatives are available for freeze-dried tissue (Tock and Pearse, 1965). Formaldehyde, however is convenient to use and the least toxic. This was done as follows :

(a) 20 ml of 10 per cent formaldehyde in water was placed in the floor of a dessicating jar or

(b) paraformaldehyde (Formvar) tablets (6 tablets of 500 mg each) were placed in the floor of the dessicating jar.

Tissues were removed from the freeze-dryer after the cooling plate had been actively warmed to -10°C or room temperature and then placed without delay in the dessicating jar which had been heated to 60°C. Accumulation of moisture in the dried tissue was thereby minimized. Tissue was subjected to immediate vapour fixation for 2 - 3 hours at 60°C. The humidity in the fixation chamber was not a critical factor for the stains employed in the present study.

A mixture (equal weights) of Ralwax (R.A. Lamb) and paraffin wax, M.P. 54° - 56°C, was used for embedding. Wax infiltration lasted for half an hour and was done under moderate negative pressure to remove air bubbles.

Sections were cut at 6 - 8 mμ on a rotary microtome and mounted on glass slides cleaned in sulphuric acid-alcohol. Sections were stretched in a water bath heated to 45°C and were exposed to water for only 3 - 5 seconds. This brief exposure to water was not considered critical in the present study as none of the cytochemical procedures were utilized to demonstrate water soluble, intracellular, components (e.g. catecholamines or histamine).

3.4 Cytochemistry of simple proteins

3.4.1 Material and methods

Thyroid glands were obtained from 13 dogs (D3 to D12 and D14 to D16, Table III). Fixatives (see below) were used according to the recommendations in the literature or as described in Section 3.3. For most techniques sections were used from thyroid glands of two of these animals chosen at random. Five to seven sections from each of the dogs were stained at a time and the staining was repeated once using material from the same animals as used for the initial staining.

C-terminal carboxyl groups of proteins were stained by the method of Barrnett and Seligman (1958) and by that of Stoward and Burns (1967). In the first method, carboxyl groups are converted to mixed anhydrides which are then complexed with a hydrazide and thereafter coupled with a diazo dye. In the method of Stoward and Burns the carboxyl groups are converted to methyl ketones which are then linked to salicyl hydrazide/ zinc acetate to form a fluorochrome. Thyroid tissue fixed in formalin vapour was used for the former procedure whereas the latter method was carried out on tissue fixed in Carnoy's fluid in order to avoid the fluorescence that is induced by formalin.

It is possible to demonstrate delta and gamma carboxyl groups of aspartic and glutamic acid with basic dyes (Linford, 1962). Manocchio's method (1960, 1964) for carboxyl groups, utilizes a basic dye (toluidine blue) in an aqueous solution. Modification of this method by Solcia et al. (1968a) incorporates a buffer (Walpole, pH 5,0) in which the dye is dissolved in a specific concentration (1 : 10000). This modification was employed as was an acid hydrolysis (0.1N HCL at 60°C for 3 hours) prior to staining tissue sections as recommended by Solcia et al. (1968a).

Tissues fixed in GPA and Helly's fixative were used because these fixatives enhance staining with basic dyes (see Section 3.3).

Specific methods were chosen to demonstrate primary amines (epsilon-amino, C-terminal and N-terminal amino groups) secondary (carboxamido groups of asparagine and glutamine) and tertiary amines.

For primary amines the 'azo dye coupled' (3-hydroxy, 2-napthaldehyde) method of Weiss, et al. (1954) and the oxidative deamination (Ninhydrin-Schiff) method of Yasuma and Ichikawa (1953) were employed. A more sensitive method than the preceding one for amines, the Köning-Sassi reaction (Stoward, 1963; Pearse, 1968a) was used in addition. Cyanogen bromide which is used in this method was synthesized by Stoward for his staining reaction. I procured purified cyanogen bromide from Koch Light Laboratories and used this in a 10 per cent aqueous solution in contrast with the 'aqueous cyanogen bromide solution' for which no concentration is detailed in Stoward's description of the metod . The staining reactions above, were carried out on thyroid tissue fixed in Carnoy's fixative, as formalin reacts with primary amine groups and renders them cytochemically inactive (French and Edsall, 1945).

The analysis of terminal amino groups was performed both with Sanger's reagent (2,4 dinitro-fluorobenzene - DNFB) and with dansyl chloride. The latter is a fluorochrome used to label amino acids on chromatograms. DNFB was allowed to react with tissue proteins according to the method of Danielli (1953) except that the reduction of $-NO_2$ (nitrous) groups to $-NH_2$ was undertaken with titanous chloride as recommended by Tranzer and Pearse (1964). Dansyl chloride was used in a way which I thought would produce an optimal reaction with amines. The method used is a combination of the recommendations of Ringertz (1968), Rosselet and Ruch (1968) and Hartley (1970). Cognizance was taken of the following :

(1) The fluorescence of dansyl chloride is pH dependent and maximal labelling of amino acids occurs at a pH of 8 - 11 (Hartley, 1970).

(2) Borate buffer was utilized as suggested by Ringertz (1968). The final pH of the staining solution was 8.3, and the molarity was 0.05 M with 0.1% dansyl chloride.

(3) The buffer was prepared in a 50 per cent ethanolic solution as this suppresses the combination of dansyl chloride with RNA,DNA and tertiary amines and thereby procures considerable specificity of this method for the epsilon amino group of lysine and the terminal amino groups (Rosselet and Ruch, 1968).

Dansyl chloride staining was performed on tissues fixed in Carnoy's fixative and the DNFB reaction carried out on freeze-dried tissue fixed in formalin vapour.

Several methods were selected to demonstrate tertiary amines (aromatic or phenolic hydroxyls). Baker's adaptation of the Millon reaction (Baker, 1956) was initially used. However, it is a drastic and insensitive reaction, so the more sensitive diazotization-coupling reaction of Glenner and Lillie (1959b) for tyrosine was employed. Several reactions are available for detecting tryptophan: the rosindole reaction, the benzylidine coupling reaction and the xanthydrol reaction. The p-dimethylaminobenzaldehyde (DMAB) reaction (Adams, 1957), however, is the more sensitive (Pearse 1968a, p.136) and was used here to detect indole groups of tryptophan.

Detection of basic protein was attempted in two ways : firstly, by establishing the presence of ionized basic proteins with the acidic dye Fast Green FCF at high pH (Alfert and Geschwind, 1953) and then with the use of phosphotungstic acid-haematoxylin (PTAH). The original method of Mallory (1897) was followed and the haematein for this method

prepared as described by Drury and Wallington (1967). Tissue fixed in formalin vapour after freeze-drying and in GDS were stained with PTAH.

To detect arginine, Baker's adaptation (1947) of the Sakaguchi reaction was utilized.

Many reactions can be employed to demonstrate sulphydryl (-SH) and disulphide (-SS-) groups (Table IV). They may be grouped as follows : a direct demonstration of -SH or -SS- groups; (2) blocking reaction for -SH or -SS- groups; (3) conversion of -SS- to -SH groups with repetition of -SH stain before and after conversion; and (4) initial -SH blocking, conversion of -SS- to -SH and then staining of -SH. For the study of C cells four methods, all of which involve oxidation or reduction of -SH and -SS- groups and one method which involves the arylation of these groups were employed. The DDD reaction of Barrnett and Seligman (1952, 1954) (Reaction 1, Table IV) the ferri-ferrocyanide reaction of Adams (1956), with and without prior thioglycollate reduction (Reactions 1 and 7, Table IV), and performic acid-Schiff reaction (Pearse, 1954) (Reaction 1, Table IV) and the aldehyde fuchsin reaction (Landing, et al., 1956) Reaction 8, Table IV) all involve an oxidation process. In the latter procedure the staining solution of aldehyde fuchsin was prepared according to the method of Halmi and Davies (1953) - the basic fuchsin was allowed to ripen for 24 hours at room temperature before use; the final pH of several batches of stain thus prepared, varied between 1.75 - 1.95. I used several oxidants for this reaction: (a) acidified potassium permanganate (Bangle, 1954) for 2 mins, (b) performic acid freshly prepared (Greenspan, 1946), applied for 2, 5 and 10 mins and (c) 1 per cent aqueous periodic acid for 2 mins, 10 mins, ½ h, 1 h and 2 h.

TABLE IV - Histochemical reactions for disulphides and sulphydryl radicles

Action of group	Reagent	Nature of reaction	Reference
SH groups			
(1) oxidation	DDD	SH demonstration	Barrnett & Seligman, 1952
	ferricyanides	SH demonstration	Adams, 1956
	iodides	SH blockage	Lillie, 1965, p.217
	redox dyes	SH/SS demonstration	Barrnett & Seligman, 1954 Pearse, 1954
(2) mercaptide formation	mercurials and organic mercurials	blockage and SH demonstration	Bennett & Watts, 1958 Pearse, 1968, p.621
(3) alkylation	iodacetate	SH blockage	Lillie, 1965, p.212
(4) addition to double bonds	maleates (N-ethyl maleimide)	SH blockage	Seligman et al., 1954
(5) acylation	acid anhydrides	no histochemical reaction	
(6) arylation	DNFB	SH blockage	Danielli, 1950
SS groups			
(7) reduction	thioglycollic acid	SH production from SS	Adams, 1956
	mercaptoethanol	SH production from SS	Barrnett & Seligman, 1954
	benzyl thiol	SH production from SS	Swift, 1963
(8) oxidation	periodic acid	conversion to cysteic acid or SH groups	Scott & Clayton, 1953
	performic acid		Lillie, 1965, p.218
	potassium permanganate		Landing et al., 1956
(9) electrophilic cleavage	ionic silver	no proven histochemical reaction, but see Section 4	
(10) sulphite cleavage	sodium sulphite	SH production by SS cleavage	Gomori, 1952, p.129
(11) cyanolysis	potassium cyanide	SH production by SS cleavage	Barrnett & Seligman, 1952

Tissues fixed in Helly's fixative, GDS and formalin vapour were used . The DNFB reaction, as used above, was employed in conjunction with an -SH blocking agent, N-ethyl maleimide as recommended by Pearse (1968a, p.172).

3.4.2 Results

C cells were easily identified in sections of canine thyroid tissue by their morphological appearance and distribution amongst thyroid follicles. Subjective assessment of their staining reaction could therefore readily be made. Their configuration and cytoplasmic details conformed to those reported by Nonidez (1932) and Pearse (1966). C cells are larger than follicular cells and their nuclei are more nearly centrally disposed than those of follicular cells, in which the nuclei are in a basal position. The position of canine C cells in relation to follicles and follicular cells is either intrafollicular (wedged between follicular cells), parafollicular (adjacent to follicular cells) or interfollicular (in between follicles and separated from follicular cells) (Fig. 35). No further observations on the topography of C cells within the thyroid lobes were made in this part of the study.

A summary of the results of the staining reactions of thyroglobulin (colloid), C and follicular cells is given in Table V. The assessment of intensity of the staining reactions is semiquantitative. It was subjectively assessed and correlated wherever possible with the intensities reported in the literature.

The results of the fluorochrome reaction of Stoward and Burns (1968) for C-terminal carboxyl groups were similar in sets of sections taken from three thyroid glands from three animals. Control sections revealed no primary tissue fluorescence except for a faint reaction in interstitial connective tissue. The stain showed moderate fluorescence

TABLE V - Staining reactions of proteins in thyroglobulin, follicular and C cells of the canine thyroid gland

Reactive group	Reaction	C cell cytoplasm	Follicular cell cytoplasm	Thyro-globulin
terminal carboxyl groups	salicyl hydrazide/zinc acetate reaction	-	-	-
delta and epsilon carboxyl groups	toluidine blue metachromasia after hydrolysis	+++	-	±
	without hydrolysis	++	+	+++
	hydroxynaphthoic hydrazide reaction	++	-	+++
amino groups	hydroxy-naphthaldehyde reaction	++	+	++
	ninhydrin Schiff	-	-	±
	Konig-Sassi	++	+	+++
	DNFB	++	+	+++
	dansyl chloride	++	+	++
phenolic hydroxyls	millon reaction	-	-	+
	diazotization coupling	-	+	+++
tryptophan	DMAB	-	-	±
basic protein	fast green FCF	-	-	++
	PTAH	±	+	++
	sakaguchi reaction	-	-	±
SS/SH groups	DDD	++	-	++
	ferri-ferrocyanide without thioglycollate reduction	-	-	+
	after thioglycollate reduction	++	++	++
	DNFB with SH block	++	+	+++
	aldehyde fuchsin without oxidation	-	-	+
	after oxidation			
	periodic acid (2h)	++	+	+++
	performic acid (5 min)	++	+	+++
	permanganate (2 min)	++	+	+++

-/±/+/++/+++ = subjective assessment of stain reaction; very intense reaction is assigned with +++ and - used to denote no reaction.

of some interstitial fibrillar elements b it no positive reaction in thyroglobulin, follicular or C cells. One set of sections contained parathyroid cells which did not stain with this method.

Results with toluidine blue staining of thyroid tissue were similar whether tissues were fixed in Helly's fixative or GPA. Following acid hydrolysis a gamma metachromasia which was more marked (deeper violet-purple colour) in tissue fixed in GPA, was observed in C cells. All the C cells showed a diffuse cytoplasmic metachromasia (Fig. 3) but no nuclei were stained. Marked coarse granular accentuations of dye occurred throughout the cytoplasm. Maximum staining of C cells following acid hydrolysis was observed after 30 minutes immersion in toluidine blue after which time the intensity of staining was not further increased. The thyroglobulin and follicular cell cytoplasm were a light blue colour when sections were subjected to prior acid hydrolysis but when this was omitted they stained metachromatically. An intense purple metachromasia was observed in cells which were smaller than C cells and situated around medium- and small-sized blood vessels. In these cells, identified as mast cells, metachromasia was localized in densely packed cytoplasmic granules.

The hydroxy-napthoic acid-hydrazide/Diazo dye-coupled method for carboxyl groups revealed a positive reaction in the cytoplasm of C cells (Fig. 4). The diazo dye used in this method is a dicoupler; two colours may form depending on whether it monocouples (red when carboxyl groups are numerous or closely arranged). C cells stained predominantly pink to red though the pale blue colour, which frequently developed in the follicular colloid, is less obvious and may have occurred in some C cells. This could have been recorded as a negative reaction - a few C cells did not stain pink/red and were thought to give a negative reaction. The



Fig. 3 - Intense metachromatic reaction in canine C cells; thyroglobulin in this section does not stain. GPA fixation. Toluidine blue after acid hydrolysis. X100

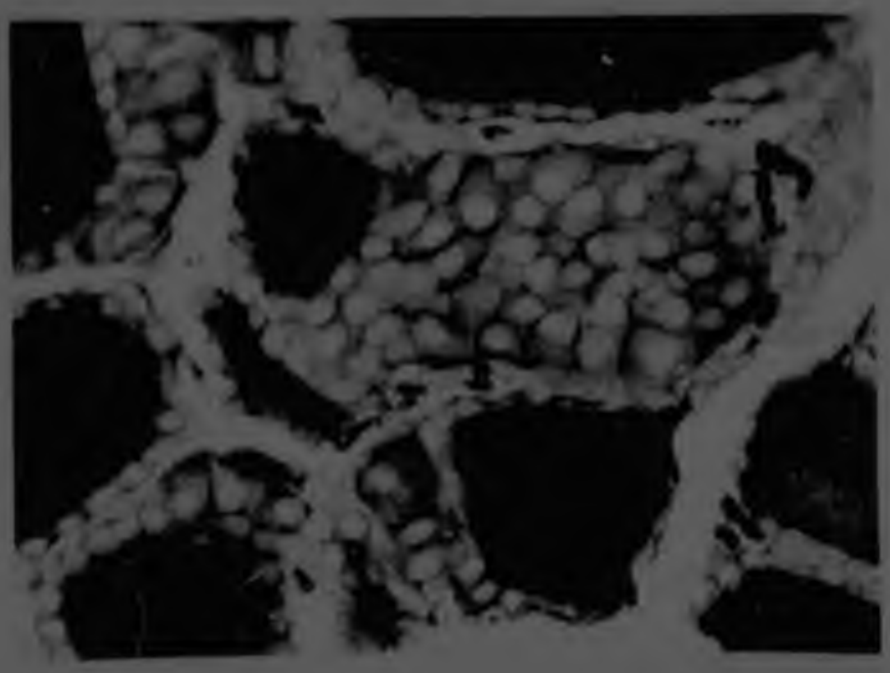

Fig. 4 - A positive reaction for side-chain carboxyl groups in the cytoplasm of C cells and some of their cell borders; thyroglobulin is strongly positive. Freeze-dried, formalin vapour. Hydroxy-naphthoic acid-hydrazide reaction. X540

staining reaction of follicular colloid varied more than that of the C cells. Approximately half of the follicles stained pink/red and the others a pale blue colour; only a few follicles did not stain at all. Follicular cells exhibited no positive staining reaction. Sections from several blocks of freeze-dried tissue were examined and similar results observed on each occasion.

With appropriate modifications, the principle of the azo-dye coupled reaction, as that for carboxyl groups above, was applied to the study of amines, i.e. the hydroxy-naphthaldehyde reaction. Again two colours, red/pink and blue were observed in sections of thyroid tissue. The results for this stain were assessed against those originally described by Weiss et al.,(1953). Thyroglobulin showed a moderate pink-purple colour, judged to lie between the blue of dicoupling which indicates a large number of amines and pink of monocoupling which indicates a smaller number of amines. The colour reaction varied in intensity from follicle to follicle. Nuclei of follicular and C cells stained blue. The faint pink colour of the follicular cell cytoplasm contrasted with the deep purplish colour of the C cell cytoplasm which contained no coarse granulations likely to be secretory granules. The cytoplasm of several C cells showed hardly any colour reaction. Various sizes of follicular cells were observed; the smaller, more flattened follicle cells showed no reaction at all.

The ninhydrin-Schiff reaction produced no positive staining in follicular or C cells of tissues fixed in either Carnoy's fixative or formaldehyde. A pale pink staining of thyroglobulin in tissue fixed in formaldehyde vapour was observed. This was also present in Carnoy-fixed tissue but to a lesser extent. A slight reaction (pale pink) was observed in interstitial connective tissue fixed in Carnoy's fixative.

The König-Sassi reaction for primary and secondary amines was positive in thyroglobulin as well as follicular and C cells (Fig. 5). Follicular cells were moderately, but thyroglobulin intensely, fluorescent; an intermediate degree of fluorescence, was found in the C cell cytoplasm which contrasted in its fluorescence from that of follicular cells. Nuclei and surrounding connective tissue showed minimal or no fluorescence Control (unstained) sections of tissue revealed no primary fluorescence Several sections taken from each of a number of different thyroid glands gave the same result.

Demonstration of terminal amino groups with DNFB yielded reproduceable and consistent results in all tissue sections stained in this way (Fig. 6). The cytoplasm of C cells stained positively. A small number of C cells stained more intensely than others. A few showed no reaction. The staining reaction was diffuse throughout the cytoplasm without granular accentuations except for those due to freezing artefacts. The thyroglobulin produced an intense, and the follicular cell a moderate reaction with this stain. The DNFB reaction parallelled that of dansyl chloride (Fig.7).

No phenyl groups of tyrosine were shown in follicular or C cells with either Baker's modification of the Millon reaction or the diazotization-coupling reaction. The latter produced good colouration of thyroglobulin (Fig. 8) which is known for its high tyrosine content. There was no cytochemically detectable tryptophan in any of the structures of the thyroid gland.

Attachment of the acid dye, fast green FCF, could not be demonstrated in C cells after staining for 30 minutes in citrate buffer at pH 8.0 (Fig.9). The thyroglobulin reacted strongly but no granules reflecting thyroglobulin synthesis were observed in follicular cells. None of the nuclei of

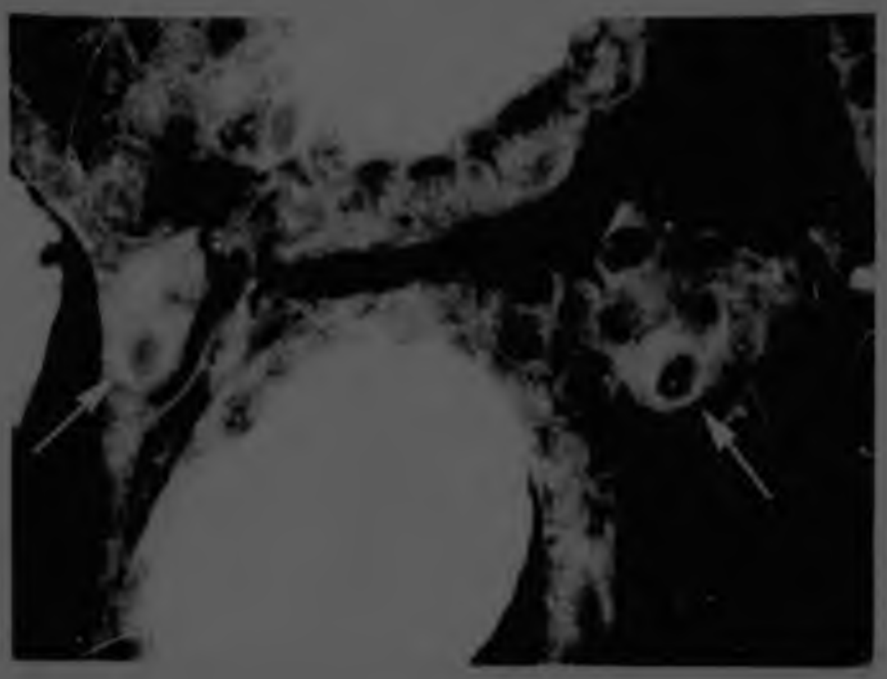

Fig. 5 - Intense fluorescence of thyroglobulin and moderate fluorescence of C cell cytoplasm (arrows) of primary and/or secondary amines. Carnoy's fixation. König-Sassi reaction. X960

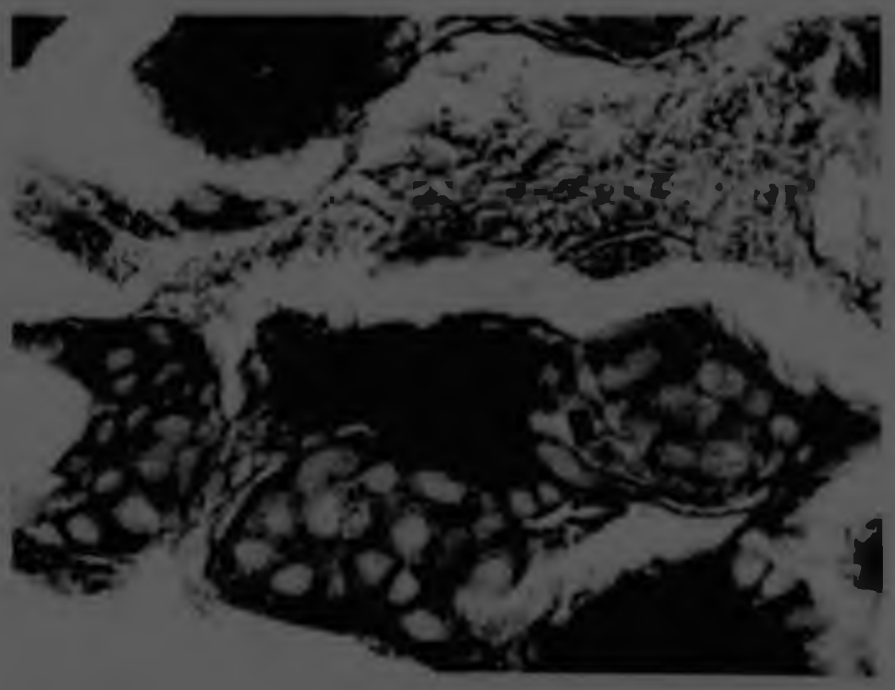

Fig. 6 - A moderate reaction with DNFB in the cytoplasm of C cells; thyroglobulin reacts intensely. Freeze-dried, formalin vapour. DNFB reaction. X700



Fig. 7 - Marked fluorescence of thyroglobulin and moderate fluorescence of alpha and epsilon amino groups in the C cell cytoplasm (arrows) of Carnoy's fixation. Dansyl chloride staining. X960



Fig. 8 - No reaction for tyrosine in the cytoplasm of C cells (arrows) but moderate staining of thyroglobulin. Freeze-dried. Formalin vapour. Diazotization-coupling for tyrosine. X540

epithelial cells stained, as hot picric acid had been used to quench the staining reaction of nucleic acids. The other stain for basic protein, PTAH, was perfc.med on tissues fixed in various fixatives (formc.-saline, GPA, Helly's fixative and GDS). No noteworthy difference in staining characteristics was observed in tissues fixed in the various fixatives. Thyroglobulin and structures in the follicular cell which are known to have a high content of basic protein, that is the nucleus, nucleolus secretory granules and lining of the follicular cells were positively stained (Fig. 10). The nuclei of the C cells stained positively and the cytc lasm showed a faint granularity, more positive in some cells than o' ers. In some C cells there was an aggregation of stained material in a paranuclear position. The granules in the C cell cytoplasm shown with the PTAH method did not conform in distribution or number with those demonstrated by silver staining methods (see Section 4).

The Sakaguchi reaction for arginine was negative in C and follicular cells of the thyroid gland and thyroglobulin.

The DDD reaction for disulphides and sulphydryl groups stained several tissue components. A reddish pink colour, indicating moderate amounts of disulphide groups was observed in (a) thyroglobulin, (b) cell borders of follicular cells, (c) supporting connective tissue and (d) C cell cytoplasm (Fig. 11). No staining was observed in the follicular cell cytoplasm. The reaction products within the C cell cytoplasm were uniformly distributed. These results are similar to those originally observed by Barrnett and Seligman (1954) in rat thyroid tissue in which, however, C cells were not distinguished. The ferri-ferrocyanide reaction performed without prior thioglycollate reduction, revealed no significant staining of epithelian cells or connective tissue - a faint

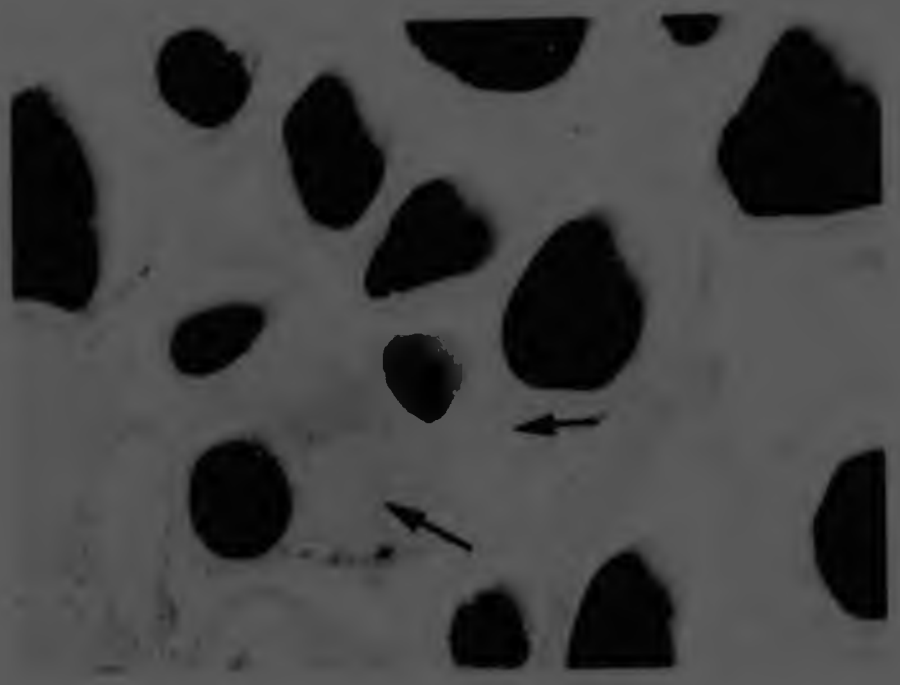

Fig. 9 - No reaction for basic protein groups in C cells (arrows) but thyroglobulin is reactive. Carnoy's fixation. Fast green FCF. X200

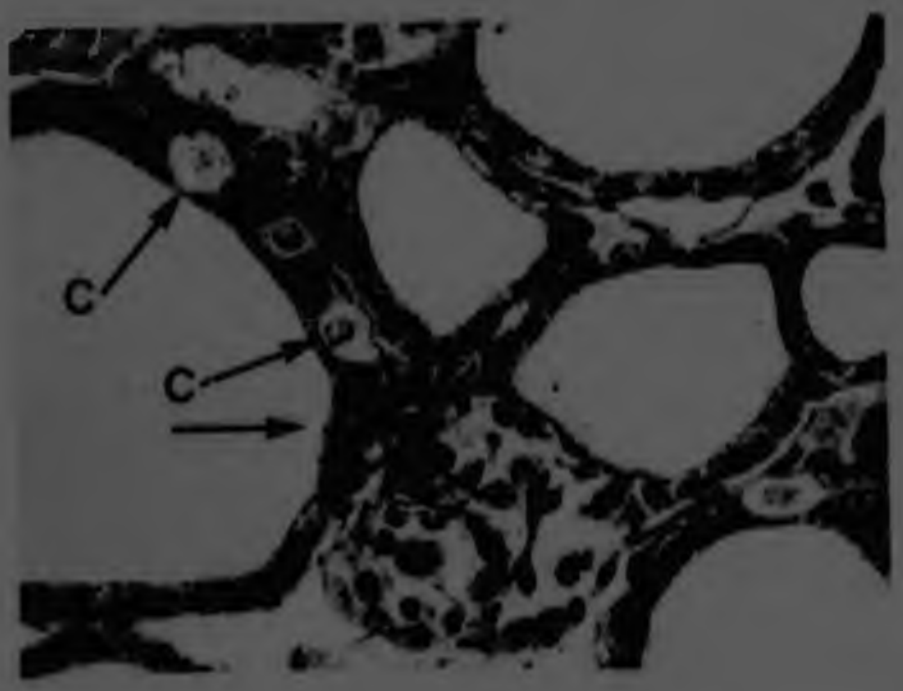

Fig.10 - Basic protein of granules in follicular cells (arrows) are stained. No basic protein, except some granular accentuations is noted in C cells (C). PTAH staining of thyroglobulin is not shown in this microphotograph. Helly's fixation. PTAH. X300



Fig. 11 - Reaction product of both sulphydryl and disulphide groups is shown in thyroglobulin, and group of C cells (arrows). Freeze-dried, formalin vapour. DDD reaction after potassium cyanide reduction. X540

blue reaction was observed in the colloid. The same reaction carried out after one hour's thioglycollate reduction, resulted in a blue green colour in C cell , follicular cells and thyroglobulin, with little difference in staining intensity between follicular and C cells (Fig. 12).

Blockage of -SH groups with N-ethyl maleimide did not alter the DNFB staining reaction n canine C cells.

The aldehyde fuchsin stain in tissue sections that were not oxidized prior to staining showed an intense colour reaction in elastic tissue and mast cells as well as moderate staining of thyroid colloid. No reaction could be detected in follicular or C cells. The same stain preceded by oxidation with potassium permanganate produced a more intense staining reaction in thyroglobulin as well as elastic tissue and now stained the cytoplasm of C cells (Fig. 13). Intense staining reaction in C cells, was noted in tissues fixed in Helly's fixative; a less marked reaction with C cells occurred in freeze-dried tissue fixed in formalin vapour. In order to obtain the equivalent intensity of staining reaction after performic and periodic acid oxidation as that obtained after permanganate oxidation, sections had to be exposed for five minutes in performic acid and 2 h in periodic acid. In the case of the latter oxidant, oxidation times between 2 minutes and 2 h yielded progressively increasing intensity of staining reaction in C cells.

3.4.3 Discussion

The toluidine blue metachromasia seen in the present canine C cells after acid hydrolysis, is similar to that observed in the C cells of dogs by Solcia et al. (1968), Solcia and Sampietro (1963) and Pearse (1969b). I have, a priori, accepted their deduction that the metachromasia is partly due to the carboxyl group in C cells mainly because of the supporting evidence they put forward. However, there are other chromotropes (substances which produce metachromasia and masked

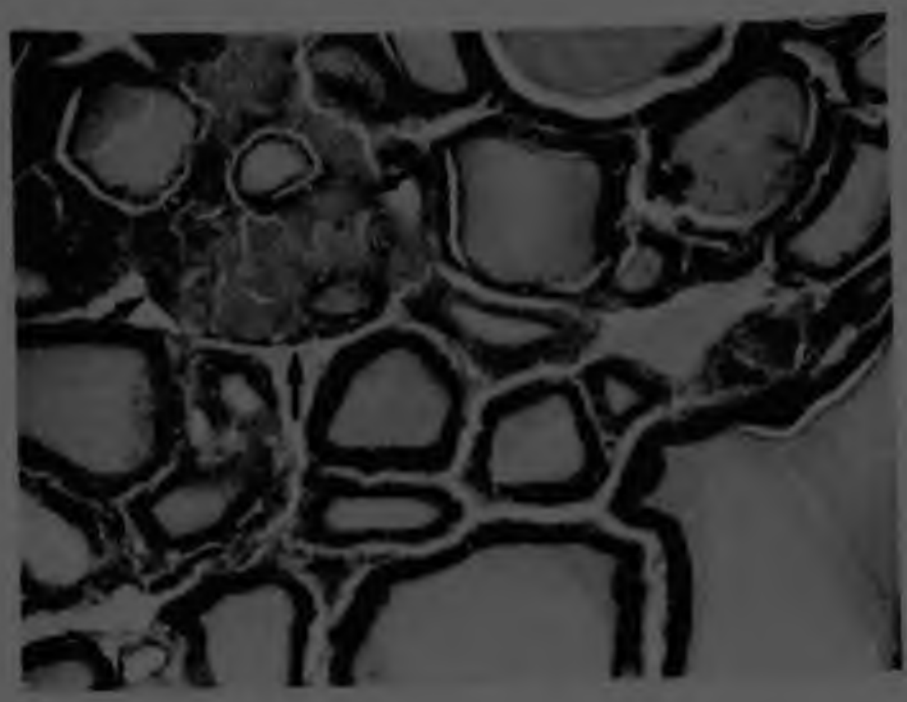

Fig. 12 - Marked staining of disulphide groups in C cells (arrows) and follicular cells, the nuclei of which are obscured. GDS fixation. Ferri-ferrocyanide reaction after thioglycollate reduction. X350

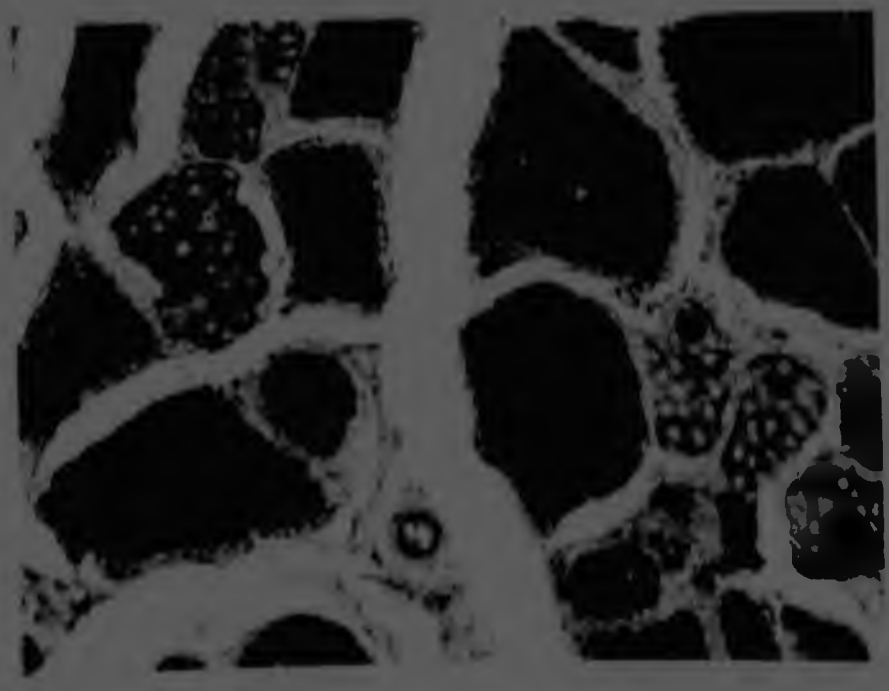

Fig. 13 - Thyroglobulin and cytoplasm of C cells stain markedly with aldehyde fuchsin. Freeze-dried, formalin vapour. Aldehyde fuchsin after permanganate oxidation. X300

metachromasia) which could be involved in metachromatic staining (Schubert and Hamerman, 1956). There are two broad groups of chromotropes : (1) polymers of polyelectrolytes of high molecular weight and (2) micellular aggregations of polar lipids which will produce metachromasia . The metachromasia of the following substances is explained on one or other of these bases: acidic mucopolysaccharides (hyaluronic acid, polysaccharide ester sulphate and polyphosphates), heparin, sialic acid and sialomucin, phospholipids (myelin), nuclear chromatin, and amyloid. Most of the forementioned substances have been excluded in the case of C cells (Solcia et al., 1968). It is noteworthy that metachromasia had never in the past, been attributed to an acidic polypeptide, unconjugated to carbohydrates. Such a possibility was suggested by Solcia et al. (1968) for the C cell and is unique in cytochemistry

The metachromasia of C cells is intensified (a shift from beta-to gamma-metachromasia) by prior acid hydrolysis. This observation, originally made by Solcia et al. (1968), was confirmed in this study.

The canine C cell stains metachromatically even when not pretreated with dilute acid. Acid pretreatment is not always necessary for observing metachromasia in other endocrine cells e.g. alpha cells of the pancreas (Manocchio, 1960).

Several explanations have been put forward for the masked metachromasia in hormone-producing cells following acid treatment.

(1) Acid removes blocking proteins which otherwise form covalent links with intracellular anionic groups that are responsible for the production of metachromasia (Schubert and Hamerman, 1956). Lietz (1971) suggested a similar hypothesis with regard to C cells, that is, that increased basophilia is due to a 'subtraction phenomenon'. His postulate is vague and he does not specify which cellular

constituents are lost. Nevertheless some support for this view is obtained from the work of Rost and Rost (1975). They showed, with the electron microscope, that the limiting membrane of secretory glanules in canine C cells is removed by mild hydrolysis. This alteration to secretory granules may be related to the enhancement of cytoplasmic metachromasia, i.e. to masked metachromasia.

(2) Dilute hydrochloric acid is capable of biochemically cleaving intrachain peptide bonds at the aspartyl position which then leaves shorter peptide chains with terminal dicarboxylic groups (Tsung and Fraenkel-Conrat, 1965; Light, 1967). In vitro, dilute acid, utilized under the same conditions as in the study, is capable of cleaving calcitonin at the aspartyl residue and leaving a terminal dicarboxyl group (Potts, et al., 1968). These dicarboxylic groups provide an increased availability of carboxyl groups for the production of masked metachromasia.

(3) Acid hydrolysis may convert side chain and C-terminal carboxamido groups into carboxyls ($CO.NH_2 \longrightarrow COOH$) which increase the anionic content and therefore enhance metachromasia (Pearse, 1969b). There is some biochemical evidence in support of this supposition (see Chibnall et al., 1968).

On the basis of the present observations some argument can be levelled at the third hypothesis above. Carboxamido groups are non-polar in intact polypeptides and should therefore not themselves elicit basophilia. If these groups were the source of carboxyl groups for the masked metachromasia then metachromasia should not be present without acid hydrolysis. However, basophilia is observed in C cells that are not pretreated with acid. My personal view is that metachromasia observed without acid hydrolysis is due to side chain carboxyl groups which others

(Solcia and Sampietro, 1968) and I have shown to be present (see Section 3.4.2). Additional carboxyl groups for the masked metachromasia following acid hydrolysis are probably obtained as explained in (1) and/or (2) above and less likely from carboxamido groups as suggested by Pearse (1969b) for C cells. Amide groups form strong cross linkages with aldehyde fixatives (French and Edsall, 1945) and that these cross linkages can be hydrolized by dilute hydrochloric acid has not been proven.

An exposure of C cells to dilute acid for one hour longer than used in the present study, produces decreasing metachromasia of C cells (Solcia et al., 1968) and this most probably is due to complete hydrolysis and loss of peptide fragments from tissue sections.

To some extent the type of fixative that is used determines whether metachromasia is strong or weak in canine C cells. Manocchio had shown in 1960 that no basophilia developed in canine beta cells of the pancreas if alcoholic fixatives were used : this observation also applies to canine C cells (Solcia et al., 1968). Alcoholic fixatives were not re-investigated in this study and the choice of fixatives was based on the above observations. Alcoholic fixatives may remove lipid chromotropes, suggesting that polyelectrolytes in C cells may be associated with lipids. Other chromotropes for example nucleic acids which are known not to depend on a lipid association for their metachromasia, show their metachromasia after alcoholic fixation. Their metachromasia is enhanced by aldehyde containing fixatives (Lamm et al., 1965). This enhancement is probably due to a more efficient aggregation of proteins that is brought about by aldehyde fixatives (Pearse, 1968a, p.70). Both factors - a lesser amount of lipid lost and more efficient aggregation of proteins by aldehydes - could explain optimal metachromasia observed in C cells which were fixed in aldehyde-containing fixatives.

Although toluidine blue basophilia at pH 4.0 is good evidence for the presence of prototropic carboxyl groups in C cells, it does not provide information on the type of carboxyl group that is involved. A negative salicyl hydrazide/zinc acetate reaction points to an absence of cytochemically detectable C-terminal carboxyl groups; the observation is in agreement with biochemical data on pure calcitonin where the C-terminal was found to be a proline-amide group (Section 1.3.1). The reaction of Barrnett and Seligman (1958) for carboxyl groups, which is positive in C cells, was originally attributed solely to alpha-acylamido (C-terminal) groups on the basis that these, and not side chain carboxyl groups, are converted to methyl ketones ay acetic-anhydride/pyridine mixtures. These authors did not consider that side chain carboxyls could be converted into reactant groups other than methyl ketones. Karnovsky and Fasman (1960) however, provided biochemical evidence that side chain carboxyl groups are converted to mixed anhydrides and that side chain carboxyl groups, rather than terminal carboxyl groups, are responsible for a positive reaction. Work by Stoward and Burns (1968) has provided further biochemical evidence that mixed anhydrides, and not methyl ketones, predominate in this staining reaction in tissues. One must therefore accept that the Barrnett and Seligman reaction indicates side chain carboxyl groups in general and therefore also in C cells. These conclusions are in line with the biochemical characteristics of calcitonin - bovine calcitonin has side chain carboxyl but no side chain carboxamido groups (Brewer, 1970). The high concentration of side chain carboxyls, as revealed by Barrnett and Seligman's reaction provides some support for the view that the metachromasia of canine C cells, in the absence of acid hydrolysis, could be due to side chain carboxyl groups.

The Ninhydrin-Schiff reaction in C cells revealed no detectable aldehyde groups derived from amines. Biochemically, however, Ninhydrin reacts moderately with amines of peptide fractions derived from porcine calcitonin (Khant et al., 1968). There are several possible reasons for the discrepancy between cytochemical and biochemical observations : (1) Ninhydrin requires the presence of a minimum of 1 µg of protein in order to provide a positive stain on chromatograms (Deveni and Gergely, 1974) - such amounts of protein may not be present in C cells; (2) the reaction is specific for free unconjugated amino acids (Puchtler and Sweat, 1962) which may not be present in C cells; (3) in intact protein Ninhydrin reacts only with alpha- and epsilon-amino groups (Glenner, 1963) and these may only be present in small amounts in C cells; and (4) the colour reactions in cytochemistry and biochemistry are not comparable as the former is due to Schiff's reagent and the latter due to Ruhemann's purple (Moore and Stein, 1948). Apart from these possible explanations, the Ninhydrin-Schiff reactions is often incomplete (Pearse, 1968a, p.121) and is not as specific as suggested by Yasuma and Ichikawa (1953) in their original description of this stain.

The aromatic aldehyde, 3-hydroxy- 2-naphthaldehyde, in contrast to the Ninhydrin-Schiff reaction, demonstrated the presence of amines in C cells. This reaction has received scant critical analysis in the literature. Pearse (1968a, p.119) claims that it is reliable but states that the reagent may react with other tissue groups. The staining of thyroglobulin follicular and C cells, as well as other structures, could support the view of Pearse that several different tissue groups may here be involved in this staining reaction. Reactive groups, other than amines, which may participate in this reaction have not yet been identified. The König-Sassi reaction which was adapted for cytochemical use by

Stoward (1963), was clearly localized where a high content of amines was expected, that is follicular cells, C cells and thyroglobulin. This method, which I slightly modified in that cyanogen bromide was obtained commercially, yielded good results and parallels the results of the hydroxy-naphthaldehyde method for follicular and C cells.

In this study it is shown that a chromogenic product forms following the interaction of the aromatic halogen, DNFB, with cytoplasmic constituents of C cells. When DNFB was first introduced by biochemists, it was employed for chemical end-group analysis of proteins (Sanger, 1945); then it was adopted for cytochemistry by Danielli (1949). It is now known that dinitrophenyl groups are formed with DNFB by alpha-amino groups, epsilon-amino groups of lysine, histidine, sulphydryl groups of cysteine and the hy roxyl group of tyrosine and phosopholipids in tissues (Maddy, 1961). An assessment of the DNFB reaction in tissues (other than thyroid tissue) by Zerlotti and Engel (1962) suggests that staining is predominantly due to epsilon-amino groups. These authors used a DNFB reaction without a dye coupling procedure, a method in which O-dinitro-phenyl tyrosine and m-dinitro phenyl histidine produce no colour reaction. However, in the method which I used and which is dye coupled, both tyrosine and histidine, if present in sufficient quantities, produce a coloured reaction after azo coupling. In assessing which of the above reactive groups are involved in the staining of C cells, the effects of formaldehyde fixation should be first considered. When formalin is used, it has been shown that alpha- and epsilon-amino groups form methylols which are involved in secondary cross linkages between protein chains (French and Edsall, 1945). Amines which are nucleophiles for DNFB are therefore thought normally not to be reactive in formalin-fixed tissue. However, Zerlotti and Engel (1962) showed that prolonged exposure to DNFB for 16 hours,

as was used in this study, could reverse the blockade of amines by formaldehyde. For this reason the positive stain in C cells fixed in formalin, may be due to amine groups. Biochemically the order of preference at which dinitrophenylation proceeds is SH>amino>phenol> imidazole (Cohen, 1968); these groups must be considered as reactants in this stain. They are considered further in the discussion below.

The usefulness of dansyl chloride for N-terminal amino acid analysis was recognized by Hartley (1970). This reagent, partly because it is a fluorochrome, is 100 times more sensitive than DNFB in detecting end-groups of proteins. Such sensitivity is extremely useful for cytochemical purposes. Dansyl chloride was subsequently introduced to cytochemistry as a stain for basic protein (Ringertz, 1968), no doubt due to its reactivity with amines such as protamine, histones and polylysine. Biochemically, dansyl chloride reacts with alpha-amino groups, epsilon-amino groups, cysteine, the phenol group of tyrosine and imidazole group of histidine in decreasing order of sensitivity (Gray, 1967) - these are the same groups that are reactive with DNFB. In the cytochemical application of dansyl chloride in alcohol, as was used in this study, fluorescence is specific for alpha and epsilon amino groups (Rosselet and Ruch, 1968). Dansyl chloride produced a bright fluorescence with thyroglobulin; this finding parallels biochemical observations which showed that dansyl chloride readily attach to native thyroglobulin (Crombrugghe and Edelhoch, 1966). The cationically charged amino acid content of thyroglobulin (glutamine, asparagine, lysine, arginine) is high (Robbins et al., 1974) and as these amino acids are readily accessible to solvents, the attachment of dansyl chloride to thyroglobulin is expected. Whether the reactive groups in thyroglobulin are alpha-

or epsilon-amino is not clear, especially as there is controversy as to the nature of the terminal amino group of the polypeptide chains in thyroglobulin (Spiro, 1970). Probably both alpha- and epsilon-amino groups in thyroglobulin react with dansyl chloride. The positive dansyl chloride reaction in C cells is probably also due to amine groups, as the other groups with which dansyl chloride reacts cannot be cytochemically shown in C cells . A moderate intensity of fluorescence compared with tne fluorescence of thyroglobulin may point to a lower content of amino acids in this cell, in which a substantial proportion of amines must be of alpha-amino type (the N-terminal reactive group). The dansyl chloride reaction mirrors the findings of the König-Sassi reaction and provides support for the view that ionized primary amines are present in thyroid C cells.

Phenolic hydroxyl groups are not cytochemically demonstrable in C cells whereas a strong diazotization coupling reaction occurs in thyroglobulin which has a tyrosine content of approximately 3 per cent of the total amino acids (Edelhoch, 1965). Many of the tyrosine groups in thyroglobulin are not available to solvents or are iodinated, which leaves few tyrosyl radicles for cytochemical demonstration. The diazotization coupling reaction for tyrosine is a sensitive method, which fact explains the improved staining reaction over the Millon method. The negative diazotization coupling reaction for tyrosine in C cells is of relevance to the DNFB reaction which is also a diazotization coupling procedure. Only the initial reactants vary in the two diazotization coupling reactions but thereafter the procedures are similar. If each reaction applied to the same material (C cells), reacts equimolarly, then the negative reaction for tyrosine can be used to exclude tyrosyl groups as reactant with DNFB and therefore one can

conclude that the positive DNFB reaction is not due to tyrosine. Direct proof for this is, however, not available.

Polar basic proteins (arginine, histidine, lysine) are not demonstrable in canine C cells with Fast Green FCF or the Sakaguchi reaction. Even though calcitonin contains these amino acid residues, their demonstration depends on whether they exist in a polar form. As calcitonin is an acidic protein, arginine and lysine are not likely to be available as ionized surface residues. The negative reaction with fast green FCF is therefore explained.

The staining result of PTAH in the C cell does not suggest that secretory granules of calcitonin stain positively as only a few granular accentuations are noted in the cell cytoplasm. Phosphotungstic acid has a strong affinity for basic protein (Scott, 1973) and basic phospholipids (Scott and Webb, 1975). The latter are structural components of mitochondria and these structures react strongly with phosphotungstic acid (Silverman and Glick, 1969). Most probably the small number of granular accentuations in C cells are therefore mitochondria. the larger granules in follicular cells could be attributed to basic protein groups of thyroglobulin which itself stains intensely with PTAH.

The present cytochemical results indicate that there are sulphur-containing chemical groups in thyroglobulin and C cells. A general explanatory note on the biochemistry of these groups follows; many of their properties apply to reactive sulphur-containing groups in tissues, and, especially to calcitonin and thyroglobulin. Every calcitonin polypeptide chain has two cysteine residues and one methionine residue (Section 1.3.1, Fig. 1) and thyroglobulin 101 cysteine and five methionine -SH residues (Pitt-Rivers and Schwartz, 1967). Generally, sulphydryl and

disulphide groups are not found in polysaccharides or lipids (Jocelyn, 1972, p.14)) but are usually found in simple or complex proteins, for example enzymes, protein hormones and mucoproteins in which they are frequently involved in cross linkages. In tissues which contain these substances the sulphur-containing compounds do not exist as the free amino acids (cysteine) but rather are chemically assessed as reactive groups, i.e. thiol (-SH), disulphide (-SS-), sulphonic ($-SO_3H$) or S.carboxymethyl (SCH_2COOH) groups. It has also become known that -SH groups, in contrast to -SS-groups in proteins e.g. ovalbumen and thyroglobulin, are usually inaccessible or unreactive with common analytical techniques for -SH groups(Leach, 1966, Pitt-Rivers and Schwartz, 1967). Biochemical techniques for analysis of -SH and -SS- groups have been reviewed (Neurath, 1963, Leach, 1966, Jocelyn, 1972) and many of these methods have been adopted by cytochemists (Table IV).

The foregoing remarks are pertinent to the results of the staining of -SH and -SS- groups. The DDD reaction, preceded by cyanolysis with KCN, shows numerous -SH groups in C cells and thyroglobulin, some of which are probably derived from disulphides by cyanide reduction. The DDD reaction was not carried out omitting KCN treatment, in order to determine the contribution made by-SH groups alone. The results of the thioglycollic reduction and ferri-ferrocyanide reaction point to an abundance of reactive -SS- groups rather than -SH because no staining occurred when the reduction step with thioglycollate was omitted. The number of available reactive thiols therefore seems small - this is borne out by a biochemical analysis of thyroglobulin with DDD, in which analysis only 3 thiol groups were found per mole of protein (Pitt-Rivers and Schwartz, 1967). A criticism of the DDD reaction in C cells may be its specificity - a wide generalized staining does occur in all tissue structures; it seems

that this reagent can react with carboxyl groups (Gabler and Scheuner, 1966) or histidine (Pearse, 1968a, p.155). However, the ferri-ferrocyanide reaction which is specific for -SS- parallels the results of the DDD reaction suggesting that the contribution by carboxyl groups to the DDD reaction is minimal.

I have included aldehyde fuchsin amongst stains for sulphur-containing groups because of my reasoning (see later in this section) that in C cells basic fuchsin probably reacts with sulphonic groups, though in other tissues different nucleophilic groups may also react with basic fuchsin. When aldehyde fuchsin was introduced as a stain it was observed to stain acidic mucosubstances (Scott and Clayton, 1953) and sulphated mucins (Spicer and Meyer, 1960). It was then noted by Scott (1952) that aldehyde fuchsin stains granules of pancreatic beta cells intensely following oxidation with acidified potassium permanganate. This staining in beta cells was attributed to sulphonic (anionic) groups produced by oxidation of disulphides (Scott and Clayton, 1953). The idea that sulphonic groups are responsible for the staining has found experimental support in that *in vitro*, insulin does react with aldehyde fuchsin after it has been oxidized with performic acid or acidified permanganate (Kvistberg *et al.*, 1966). These oxidants oxidize only cystine, methionine and tryptophan residues of insulin (Sanger, 1960) and other proteins (Toennis, 1942, Hake, 1965). Cystine is probably the source of sulphonic groups in the beta cells of the pancreas. It is perhaps due to these observations on beta cells that Lietz and Donath (1970) cursorily remark that the 'dicysteine acid methionine-sulphonic peptide' of calcitonin, produced by oxidation, is responsible for the positive aldehyde fuchsin staining in C cells. These authors provide no experimental support for their statement.

In order to scrutinize observations with aldehyde fuchsin further, it is necessary to consider the dyes that constitute the staining solution. This is a mixture of (i) pararosanilin (chloride) C.I No. 42500, (ii) rosanilin C.I. No. 42510 and (iii) magenta II, C.I. No. 42520, of which it has been shown that only pararosanilin is the active dye molecule (Ortman et al., 1966). Pararosanilin ('c' in Fig. 14) is thought to be activated by acetaldehyde to form azomethines (Schiff bases) ('a' in Fig. 14) from its amino groups (Bangle, 1954). However, another view is that pararosanilin acts as a basic dye (McConaill and Gurr, 1963) and that its staining is determined by the pH of the staining solution and not by the formation of azomethines.

Pararosanilin is postulated to react with several specific chemical groups in tissues.

(1) acidic groups

(a) not specified (via ionic or salt linkages) (Spicer and Meyer, 1960)

(b) carboxyl groups (via covalent binding) (Ortman et al.,1966)

(c) sulphonic groups produced by oxidation of disulphides of polypeptides e.g. insulin, vasopressin (via covalent binding) (Scott and Clayton, 1953).

(2) tautomeric enamines e.g. oxytalan fibres (by covalent binding) (Mander et al., 1968)

(3) aldehyde groups e.g. glycogen (by non-polar addition) (Kasten, 1960)

(4) enol groups e.g. granules of beta cells (by a non-specific, non-ionic reaction) (Denffer, 1973).

In C cells, carboxyl groups can be excluded as reactant groups for this stain as aldehyde fuchsin shows a positive reaction only after oxidation. It has already been shown that C cells have a high content of carboxyl groups and oxidation is not known to increase the number of

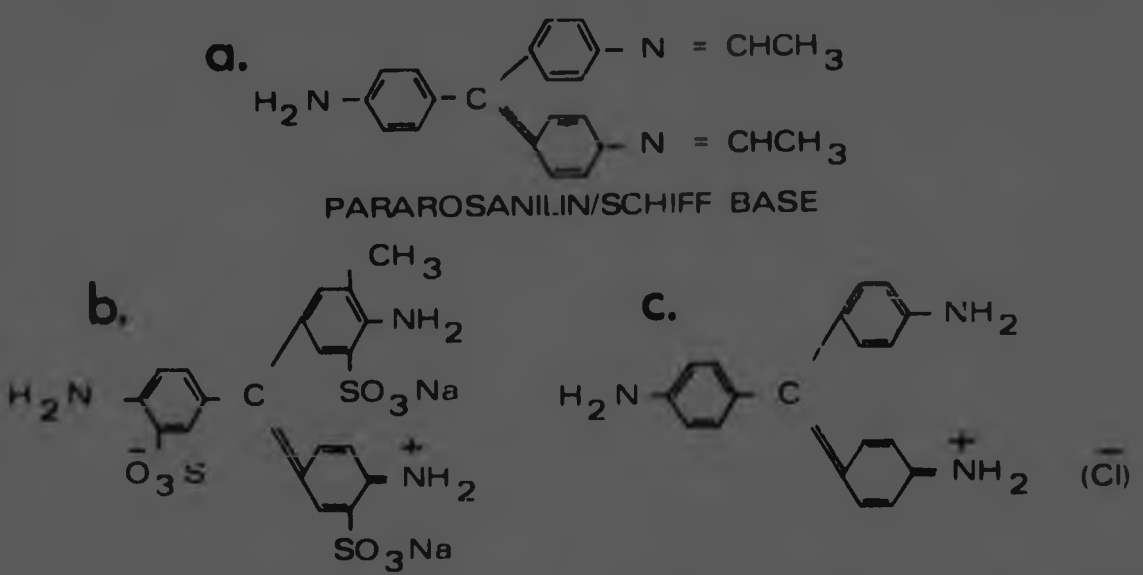

Fig. 14 - The formulation and active groups of (a) pararosanilin/Schiff base, (b) fuchsin acid and (c) pararosanilin.
Based on Gurr (1971).

carboxyl radicles. The aldehyde fuchsin stain should then be positive without prior oxidation if carboxyls were responsible for the positive reaction. The view of Ortman, et al.(1966) that carboxyl groups mediate aldehyde fuchsin attachment is thus not upheld for C cells. It is known that aldehydes and amines are rapidly formed in tissues after short (1-5 min) oxidation with periodic acid (Mander et al., 1968) and therefore a positive aldehyde fuchsin reaction should occur if these are formed in C cells, yet in the present study such short oxidation with periodic acid did not produce a positive stain. The more drastic, permanganate oxidation procedure produced a positive stain with aldehyde fuchsin. Permanganate oxidation produces aldehyde groups but in addition oxidises disulphides rapidly to sulphonic acid (Toennis, 1942; Hake, 1965). The present observations provide strong support for the view that it is the formation of sulphonic groups that produce a positive reaction. The C cell cytoplasm has been shown by the ferri-ferrocyanide reaction to contain a high content of disulphide groups. Sulphonic groups formed are acidic and have a pK value below 2 (Table II) for the demonstration of which an appropriate basic radicle has to be present on the dye molecule. Such a radicle is present in the chloride salt of pararosanilin of which the polarized amine group is nucleophilic ('c' in Fig. 14) (Gurr, 1971). The amine group in acid fuchsin ('b' in Fig. 14), which is an amphoteric dye, and closely related to pararosanilin chloride, is known to react with sulphonic groups (Gurr, 1971). A similar method of dye binding may occur in C cells, though no proof for such a mechanism of dye attachment can at present be provided. In fact it is not at all clear whether specifically the sulphonic groups provide a means of dye attachment or whether the combined negative charge established by their presence and that of other anionic groups (carboxyls) is critical for

dye attachment. The latter explanation is probably more nearly correct because the aldehyde fuchsin attachment to granules of beta cells (the aldehyde fuchsin staining of beta and C cells is analogous) can be eliminated if the anionic carboxyl groups are blocked in the presence of sulphonic groups (Denffer, 1973). The relevance of this aspect of aldehyde fuchsin staining to C cells is considered further in the next section (Section 3.6).

Whether sulphydryl groups are involved in the DNFB reaction was assessed using N-ethyl maleimide as a blocking reagent. This reagent is used for the spectrophotometric titration of thiol groups (Leach, 1966) and has been employed to block thiol groups by Barrnett and Seligman (1954) and Zerlotti and Engel (1962). The N-ethyl maleimide blockade did not alter the effect of the DNFB reaction on C cells. Apart from concluding that-SH groups do not participate in the DNFB reaction another possibility must be considered. This is that DNFB can displace the N-ethyl maleimide that has reacted with thiols in tissues. Such displacement was thought to be possible by Zerlotti and Engel (1962) who found that N-ethyl maleimide inefficiently blocked thiol groups which participate in the DNFB reaction. By further experimentation they showed that DNFB can indeed displace N-ethyl maleimide from thiol groups to which is has become attached. As sulphydryl groups are not demonstrated in C cell cytoplasm (see above) it is probable that thiol groups do not play a major role in the staining with DNFB.

3.4.4 Conclusions

From the above cytochemical observations the following conclusions can be drawn with regard to reactive protein groups in the C cells of the dog.

(1) The cytoplasm of C cells contains an abundance of acidic chemical groups. Numerous side-chain carboxyl groups are present but no terminal carboxyls can be demonstrated.

(2) Mild acid hydrolysis probably results in peptide hydrolysis at the aspartyl group which increases the anionic charge of the C cell cytoplasm.

(3) Basic proteins are not readily stainable in C cells - tyrosine, tryptophan and arginine could not be shown cytochemically in C cells.

(4) Both epsilon- and alpha-amino groups of lysine are demonstrable in C cells but these groups are not present as free cationic groups.

(5) Disulphide groups can probably, by being oxidized, add to the net negative charge of the C cell cytoplasm.

3.5 Cytochemistry of Complex Proteins

3.5.1 Introduction

The previous section was principally concerned with the cytochemical demonstrable groups of proteins. Several of those stains which were used for proteins, in the belief that they react specially with protein alone, e.g. toluidine blue and aldehyde fuchsin, react - as is well known - with glycoproteins and mucopolysaccharides. In order to establish whether peptides, glycoproteins (proteoglycans) and/or mucopolysaccharides are responsible for the above two staining reactions in C cells and thyroglobulin, it was decided to select several staining reactions to provide further information in this regard. The subject of glycoprotein- and mucopolysaccharide-staining is extensively reviewed by Spicer (1962), Quintarelli (1962), Belanger (1962) and Curran (1964).

The staining reactions which were selected are grouped together under the category of 'complex or conjugated protein' stains, as the substances which they demonstrate almost always contain proteins. It

does not follow from this that the stain reacts with protein but it merely implies that the reactive groups may be associated with proteins.

The following definitions are observed : glycoproteins are defined as proteins in which carbohydrate is covalently attached to the peptide portion (Spiro, 1970); the term 'muco' is used to describe a viscous secretion e.g. mucopolysaccharide. Frequently the terms glycoprotein and mucopolysaccharide are applied to the same substance without consideration of the basic definitions - for instance thyroglobulin is called both a glycoprotein and a mucopolysaccharide. In order to avoid misunderstanding by using the terms glycoprotein and mucopolysaccharide the more general term 'mucosubstance' is frequently used. This usage helps to draw attention to the staining reaction (for example colloidal iron, aldehyde fuchsin) which in practice is generally used to demonstrate 'mucosubstances' in sites such as the mucosa of the intestine which contain glycoproteins and mucopolysaccharides.

In this section of the study stains used to demonstrate mucosubstances are applied to canine thyroid tissue.

3.5.2 Material and methods

For each staining method, sections were used from thyroid glands of three animals chosen from D3 - 12 and D14 - 16 (Table III). Ten to twelve sections (three to four from each dog) were stained at a time.

Toluidine blue staining was carried out as previously described (Section 3.4.1) except that the buffer was adjusted to pH 2.5 for staining of sulphated mucosubstances; the dye concentration, staining times etc. were not altered. Sections of tissue fixed in GPA and in Helly's fixative were used.

Alcian blue staining was carried out according to the method of Mowry (1960, 1963). A one per cent solution of alcian blue 8GX in three

per cent acetic acid in distilled water was used. The final pH of the stain was 2.8 in all the batches of stain that were prepared. Sections were stained for 30 mins, washed in water and mounted in DPX. The same staining reaction was carried out but with the stain containing 0.2, 0.4, 0.6, 0.8 M $MgCl_2$ as recommended by Scott and Dorling (1965) and Scott et al. (1968). The procedure was otherwise unaltered. Thyroid glands from three different dogs were utilized. All tissue had been freeze-dried and fixed in formalin vapour.

The periodic acid Schiff reaction was applied to sections of freeze-dried tissue which had been fixed in formalin vapour. Sections of thyroid glands from four dogs were examined. Sections were oxidized for 6-8 minutes in one per cent aqueous periodic acid, rinsed for 2 minutes in distilled water and left for 15 mins in Schiff's reagent. Differentiating, reducing and metabisulphite rinses were omitted. The Schiff's solution was a McManus (1948) type, constituted as follows :

basic fuchsin	1 gm
distilled water	200 ml
1.0N HCl	20 ml
potassium metabisulphate	2 gm
charcoal (activated)	½ gm

The solution was filtered and stored in a dark bottle at 4°C.
The periodic acid was a potassium salt, made up in a one per cent aqueous solution to which 0.5 ml of nitric acid was added per 100 ml.

The high diamine staining reaction of Spicer (1965) was employed. A combination of meta- and para-isomer of diamine was used, which is known to colour predominantly sulphomucins. Sections prepared from freeze-dried thyroid fixed in formalin vapour were immersed in the diamine

for 18 hours. Some sections were pre-treated with an oxidant - either one per cent periodic acid for 10 mins or potassium permanganate (Section 3.4.2) for 5 mins.

The colloidal iron reaction was carried out as recommended by Mowry (1958). Staining solutions were freshly prepared for each batch of sections. The pH of the staining solutions were adjusted by addition of aliquots of glacial acetic acid as suggested by Müller (1964). A pH of 1.8 and 4.5 was chosen to carry out the reaction. Freeze-dried tissue fixed in formalin vapour was used.

Best's carmine stain was applied to tissue fixed in Carnoy's fixative.

3.5.2 Results

The staining results are given in Table VI. The reactive groups or substances which the staining reactions are known to demonstrate in other tissues, are also shown.

Toluidine blue at pH 2.5 failed to stain any cellular component of the thyroid gland. Some elastic fibres and mast cells were readily identified but no reaction occurred in C cells. The basic dye, alcian blue 8GX, failed to stain C cells at low pH. Staining solutions in which the critical electrolyte concentration was changed did not indicate any masked acidic groups i.e. the addition of greater aliquots of $MgCl_2$ produced no positive staining reaction in C cells though a moderate staining of thyroglobulin occurred at 0.8 M $MgCl_2$. The staining of mast cells was positive at all molar concentrations of $MgCl_2$.

A positive periodic acid-Schiff reaction occurred in thyroglobulin, some follicular cells, most of the C cells (Fig. 15) and the basement membrane of the follicular cells. The thyroglobulin stained intensely.

TABLE VI - Staining results of protein-conjugated carbohydrates in the thyroglobulin, follicular and C cells of the canine thyroid gland

Reactive group	Reaction	C Cell	Follicular cell	Thyro-globulin
sulphated mucosubstances	toluidine blue metachromasia pH 2.5	-	-	+
sulphated mucosubstances masked by protein groups	0.1 per cent alcian blue pH 2.8 in 0.2 M $MgCl_2$	-	-	-
	0.4 M $MgCl_2$	-	-	-
	0.6 M $MgCl_2$	-	-	-
	0.8 M $MgCl_2$	-	-	+
1.2 hydroxyl groups of vicinal glycols or substituted 1.2 hydroxyl groups of proteins and lipids	periodic acid-Schiff	++	+	+++
sulphated mucosubstances and sialomucins	high diamine, no oxidation	-	-	-
	after periodic acid oxidation	-	-	-
	after permanganate oxidation	-	-	-
acidic mucopoly-saccharide and (?) acid protein	colloidal iron pH 1.8	+	-	+
	pH 4.5	++	-	++
Glycogen	Best's Carmine	-	-	±

-/±/+/++/+++ = subjective assessment of stain reaction; - indicates a negative reaction and +++ maximum staining. Results are comparable only for each reaction, and not between different reactions.

The follicular cells, some of which did not stain at all, had a 'ground glass' appearance against which some PAS positive granular accentuations were observed. In contrast the cytoplasm of C cells stained more darkly and contained more numerous granular accentuations which did not seem to be due to any artefact attributable to freeze-drying. As with follicular cells there was variation in the intensity of the periodic acid-Schiff reaction from C cell to C cell. In some there was no PAS positive granularity. Differences in C cells staining was occasionally marked and frequently one or two of a cluster of C cells were unstained.

The aromatic amine (diamine) method of Spicer produced no positive reaction even after preceding oxidation.

The colloidal iron reaction at pH 1.0, which was employed for the demonstration of acidic mucopolysaccharide, was faintly positive in thyroglobulin, ~~of C cells~~. At a higher pH the cytoplasm of C cells became stainable and the thyroglobulin slightly more reactive (Fig. 16). In several clusters of C cells the limiting membrane of these cells stained intensely with the colloidal iron reaction. No specific granules in the cytoplasm were observed to stain with colloidal iron.

3.5.4 Discussion

Both toluidine blue and alcian blue failed to stain C or follicular cells below pH 2.5, at which pH acidic mucopolysaccharide, especially sulphated mucosubstances, are readily stained with these dyes (Spicer, 1962). Sulphate and phosphate groups are the only tissue groups ionically dissociated at this pH (Quintarelli, 1962). On the basis of the present observations, significant quantities of these groups are not present in C cells.

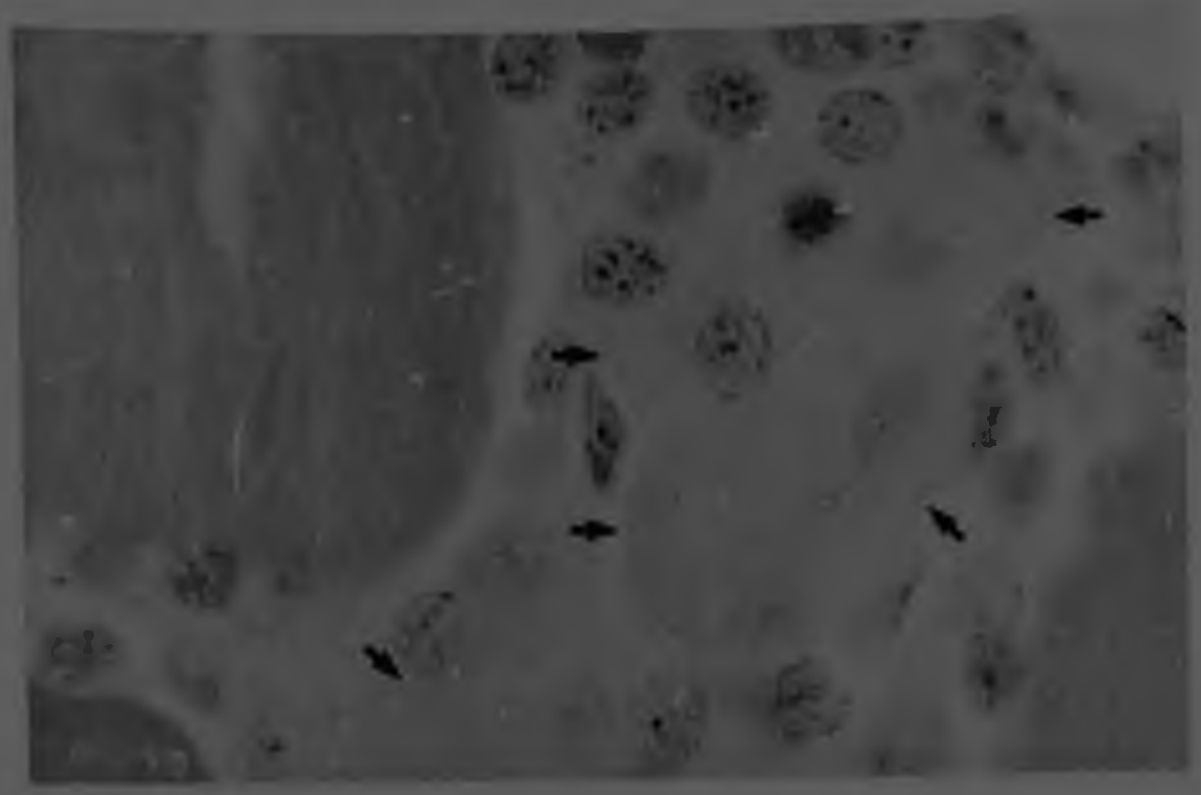

Fig. 15 - Positive periodic acid-Schiff reaction in the cytoplasm of C cells (arrows) and thyroglobulin. Freeze-dried, formalin vapour. PAS. X1200



Fig. 16 - A positive colloidal iron reaction in the cytoplasm of C cells and thyroglobulin. Freeze-dried formalin vapour. Colloidal iron and haematoxylin stain. X600

The reliability of staining with alcian blue depends on several factors which were considered in the application of the stain in the present study. The detection of mucosubstances is far more accurate with alcian blue 8GX (Mowry, 1960) than with alcian blue 8GS which was used by Steedman (1950). The former alcian blue was therefore used. Staining with alcian blue also depends on the molar electrolyte (salt) concentration of the solvent in which it is dissolved (Scott and Dowling, 1965). Strong electrostatic interaction between positive and negative charges of chemical substances (mucosubstances and proteins) in tissue sections can be suppressed by salt solutions (Szirmai, 1963). This permits dissociation of cations and anions of mucosubstances and thereby indicates their presence - the blocking bond is usually attributed to the charged groups of proteins (Scott et al., 1968). Based on this reasoning it was thought possible that cations of calcitonin might suppress the detection of sulphate and phosphate groups. However, from the results it does not seem that blocking factors are prevalent in the canine C cell. Salts did unmask some anionic groups in thyroglobulin (a faint staining occurred with alcian blue in 0.8 $MgCl_2$).

Even though no strongly acidic mucosubstances were demonstrated with alcian blue and toluidine blue, it did still seem possible that acidic sulphate groups ($-SO_3H$) might be present in C cells, especially after oxidation with permanganate. This was an explanation suggested for the positive staining reaction of C cells with basic fuchsin (see Section 3.4.3). Furthermore the possibility that toluidine blue metachromasia might be due to sulphomucins needed to be examined. The diamine reaction of Spicer was chosen to test for sulphated mucosubstances. No detectable sulphomucins or acidic sulphate groups were, however, revealed by this method. This negative reaction does not exclude the explanation

given for basic fuchsin staining, as the specificity of the diamine reaction for $-SO_3H$ has not been established.

The PAS reaction is positive in canine C cells. The wider implications of the PAS reaction must therefore be considered. Since the PAS reaction was described (McManus, 1946, Lillie, 1947, Hotchkiss, 1948) extensive investigations on the nature of the reaction have been undertaken. Results of these are reported in reviews (McManus and Mowry, 1964, Curran, 1964). A positive Schiff reaction is attributable to polysaccharides, neutral mucopolysaccharides, mucoprotein and glycoprotein, glycolipids, unsaturated lipids and phospholipids, but not to acidic mucopolysaccharides, saturated lipids or peptides (Pearse, 1968a, p.307). It is essential for a positive reaction that aldehydes are present or produced in the tissue by oxidation. Even if there is considerable consumption of periodic acid (indicating that oxidation has occurred in the tissue) no positive PAS reaction will develop unless aldehydes are formed (Dahlqvist et al., 1965).

A positive reaction will occur if

(a) there are pre-existing aldehydes in the tissue or

(b) oxidation of 1.2 hydroxyl or substituted hydroxyl groups of the following types occurs :

  (1) unsubstituted vicinal glycol groups as in glycogen, glucose, fucose, galactose and mannose (Leblond et al., 1957);

  (2) alkyl and acyl-amino substitution of one hydroxyl group as in phospholipids, glycolipids (Wolman, 1956, Adams, 1965);

  (3) carboxyl substitution of one hydroxyl group, that is, ketones as in unsaturated lipids;

  (4) amino alcohol substitution of one hydroxyl group as in serine, threonine and hydroxylysine, provided that these are in a C-terminal position (Bangle and Alford, 1953, Lhotka, 1953).

The positive PAS reaction in C cells cannot be readily attributed to lipids - firstly the nature of fixation (formalin vapour does not preserve lipids optimally. For instance, in the adrenal medulla a negative PAS reaction is observed in formalin-fixed tissue but a positive reaction in chromate containing fixatives. This positive reaction is attributed to lipids contained in the adrenal medullary cells (Hopwood, 1968). Secondly, the oxidation times are too brief to convert acyl- and alkyl-amino groups to aldehydes. Dyer (1956) has shown that a brief oxidation of not longer than 10 minutes will nearly completely oxidize all glycols and amino alcohols if periodic acid is present in excess but longer times are required for the oxidation of hydroxyaldehyde and hydroxyketones of lipids. This is borne out by the fact that a positive PAS reaction of these substances requires prolonged oxidation (for 2 - 4 hours) (Wolman, 1956).

There does not seem to be any demonstrable glycogen which could account for a positive PAS stain in thyroid C cells The Best's carmine reaction, which is a relatively specific stain for glycogen was negative. Other substances which could be responsible for a positive PAS reaction are neutral polysaccharides, glycoproteins and peptides. In general (but not in the case of C cells), evidence is available for the positive reaction of the former two substances in the PAS reaction (Leblond et al., 1957), while the involvement of proteins and peptides is usually considered insignificant. Polyamides of peptide chains (collagen, gelatin, egg albumin) are not susceptible to periodate oxidation (Bangle and Alford, 1953, Dahlqvist et al., 1965). However, from experiments with amino acids and peptides (Lhotka, 1953, Bangle and Alford, 1953 and Clamp and Hough, 1965) it is possible that aldehydes can be formed from protein if the following conditions are met (i) if the C-terminal position of

polypeptide is serine or threonine; (ii) if the alpha-amino group is freely available and unsaturated and (iii) if there is a dense alignment of these terminal groups. Such conditions exist for corticotrophin (Dixon, 1962) and chromagranin A of adrenal medullary cells (Hopwood, 1968) but in both instances the density of hydroxyl-amino groups is not thought sufficient to produce a positive reaction. Such hydroxyl-amino groups are not present in calcitonin as the C-terminal group is proline. Shorter peptide chains with a terminal serine group could theoretically exist within C cells but biochemically such fragments have not been found. It therefore seems unlikely that peptides are responsible for a positive PAS reaction in C cells and rather more likely that neutral glycoproteins of structural components or lysosomes may be responsible for the positive PAS reaction. The variable staining reaction from C cell to C cell is perhaps linked to secretion and synthesis of calcitonin in which process a changing pattern of structural glycoproteins occurs, for example in the endoplasmic reticulum, with formation and discharge of the polypeptide in C cells.

In tissue sections which have been exposed to colloidized ferric chloride, iron is attached to the cytoplasm and cytoplasmic margin (which probably is the cell membrane) of C cells, as is indicated by the Prussian blue reaction. Attachment of iron to the latter structure is similar to that observed by Rambourg et al.(1965) who found that most surfaces of cells of many organs in the rat contained a layer stained positively with colloidal iron. They concluded that this was due to the presence of glycoproteins and acidic residues on the cell surface. These conclusions are in line with the contentions of Mowry (1963) that ionic carboxyl or sulphate groups react with ionized groups of iron. A current biophysical model of 'colloidal iron' (Müller, 1964) depicts a central

$FeOH_3$ core with surface FeO+/Cl^- as ionized groups. Despite this feasible explanation, the nature of iron binding, which can take one of several forms in tissue sections, is not understood. Binding may be by means of electrostatic, covalent as well as ligand bonds or a 'complex enmeshing'. The exact tissue groups to which iron attaches are not known but usually stated to be carboxyl or phosphate groups (Pearse, 1968a, p.350).

In the methodology of the colloidal iron stain Mowry (1963) points out that the pH of the staining solution should be below 1.4 and that 'non-specific' staining occurs at pH's above 2.0. This point may be borne out by the present results as the Prussian blue reaction is intensified at pH 4.5. This result is analagous to that of toluidine blue which also depends on ionized groups of the tissue at pH 4.5 for its tinctorial properties. The colloidal iron reaction does stain acidic mucopolysaccharides (Spicer, 1962) but whether it can specifically demonstrate acidic protein has not been proven. Based on the observations that the C cell contains no strongly acidic mucopolysaccarides, the present observations indicate that colloidal iron can specifically stain acidic proteins : these have been shown to be present in the C cell.

3.5.5 Conclusions

(1) No strongly acidic mucosubstances can be cytochemically shown in C cells of the canine thyroid gland.

(2) There are no sulphomucins or sialomucins detectable in these cells.

(3) A positive colloidal iron reaction seems to be related to acidic protein rather than to stainable mucosubstances.

(4) The positive PAS reaction in canine C cells is not due to lipids or glycogen but rather to glycoproteins which may be related to the phasic metabolic activity of these cells.

3.6 Cytochemical modification of protein groups

3.6.1 Introduction

In the two previous sections (3.4 and 3.5) considerable information was obtained on the prototropic groups which are detectable in the cytoplasm of C cells : acidic groups are readily shown and basicity of tissue groups is poorly manifested. Apart from these ionic reactions of dyes with tissue groups, more complex (non-ionic) interactions between protein groups and tinctorial agents do occur. For example, the staining reaction of C cells by aldehyde fuchsin seems to depend on two tissue groups (disulphide and carboxyl groups). Blocking and modifying procedures are particularly useful to determine those groups which are cytochemically active and which are involved in dye attachment.

In selecting the staining reactions which were to be investigated in this manner, a choice was made of those which were either strongly positive in C cells (aldehyde fuchsin reaction and toluidine blue metachromasia) or about which considerable cytochemical knowledge was available (PAS reaction). Apart from these the colloidal iron reaction was investigated because no clarity about the nature of its staining of tissue groups in C cells has been obtained to date. By applying several blocking reactions and comparing changes induced in the four different staining reactions, considerable information could be gathered with regard to interaction of dyes with reactive tissue groups.

The following reactions were selected as blocking or modifying procedures : aldehyde blockade, acetylation, benzoylation, methylation, deamination, acid hydrolysis, sodium chloride baths and maleimide (sulphydryl) blockade.

3.6.2 Materials and methods

For this [illegible] the study, sections of thyroid glands were obtained from 7 dogs [illegible] 012, Table III). Each blocking or modifying reaction was carried out t[illegible]e on six sections from each of two dogs.

The periodic acid-Schiff reaction, colloidal iron reaction, aldehyde fuchsin reaction and toluidine blue staining with acid hydrolysis were carried out as previously described (Sections 3.4 and 3.5). Sections of canine thyroid tissue which was freeze-dried and fixed in formalin vapour, was employed for the first three reactions and tissue fixed in GPA was employed for the latter stain.

Blockade of aldehyde groups was undertaken with acidified aniline according to the method of Lillie and Glenner (1957). Ten per cent aniline in glacial acetic acid was used for 3 hours at room temperature. This blocking procedure was used after the oxidation step of the PAS and aldehyde fuchsin reactions. The toluidine blue staining reaction was not examined in combination with this blocking reaction.

Benzoylation was performed according to the method of Barnard (1961). Water was removed from the tissue sections by immersing them in petroleum ether for 3-5 minutes and benzoylation was carried out with a mixture of dry aceto-nitrile (50 ml.), benzoyl chloride (4.2 ml) and dry pyridine (2.2 ml). Benzoylation was undertaken for 2 and 8 hours. The shorter time was chosen as lengthy benzoylation is a drastic reaction which may lead to loss of tissue sections.

Acetylation of tissue can be undertaken in several ways. The method employed in this investigation is that recommended by Chayen et al. (1969, p.77). Their recommendations are based on the original procedure of McManus and Cason (1950) as modified by Lillie (1965, p.278). Usually a saponification procedure is subsequently performed (Culling, 1963;

Thompson, 1966) in order to demonstrate reversibility of acetylation. Saponification was not used in this study. The acetylation mixture was acetic anhydride (13 ml.) with pyridine (20 ml) and slides were placed in this for 5 hours. Acetylation was performed on tissue sections prior to oxidation for the PAS and aldehyde fuchsin reactions.

Nitrosation (deamination) was carried out as advocated by Pearse (1968a, p.618).

Tissue sections were exposed to a dilute (Feulgen) acid hydrolysis as previously described; 0.2N HCℓ at 60° for 3 hours was used prior to oxidation with permanganate and periodic acid in the aldehyde fuchsin and PAS reactions.

Sulphydryl block was undertaken with N-ethyl maleimide (NEM) according to the method originally described by Barrnett and Seligman (1952) and later adopted by Pearse (1968, p.620). For this, slides were immersed in a 0.1M solution of NEM for 4 hours at 37°C.

Saline baths (0.9%) were used at room temperature for one hour prior to continuing with staining procedures.

3.6.3 Results

A summary of the result as observed in the cytoplasm of C cells is given in Table VII. The intensity of staining reactions was assessed in comparison with control sections.

Aldehyde blockade totally abolished the cytoplasmic staining of thyroid C cells with periodic acid-Schiff: no C cell was found that stained positively. In contrast with the PAS reaction, both the aldehyde fuchsin and colloidal iron reactions were unaffected.

Acetylation prior to oxidation with periodic acid abolished the PAS reaction and moderately diminished the intensity of the colloidal iron staining reactions. Some C cells failed to reveal any basophilia

TABLE VII - The effects of blocking and other modifying procedures on the periodic acid-Schiff (PAS), colloidal iron (CI), aldehyde fuchsin (AF) and toluidine blue (TB) staining reactions of the C cell of the canine thyroid gland.

Procedure	PAS	CI	AF before	AF after oxidation	TB
aldehyde block	0	+	NT	+	NT
acetylation (acylation)	0	±	+	+	±
benzoylation 2 h.	+	0	NT	0	0
8 h.	0	0	NT	0	0
methylation 48 h	+	±	NT	0	0
96 h	0	0	NT	0	0
deamination (nitrosation)	+++	+	NT	+	++
acid hydrolysis	+	0	NT	+	+++
sodium chloride bath	NT	+	NT	+	+
maleimide block	+	+	0	+	+

Subjective assessments of staining intensity as compared with controls (not blocked or modified)

0 = markedly diminished or completely abolished

± = moderate decrease

\+ = no change

++ = moderate increase

+++ = marked increase

NT = not tested

with toluidine blue. However, overall, a diminished reaction for this staining reaction was observed in C cells. Aldehyde fuchsin reaction was not altered by acetylation.

Benzoylation for 2 hours did not alter the PAS reaction whereas colloidal iron, aldehyde fuchsin and toluidine blue staining were completely inhibited by this procedure. Prolonged (8 hour) benzoylation abolished the PAS staining of C cells.

Methylation for 48 hours diminished the colloidal iron and completely abolished aldehyde fuchsin and toluidine blue staining. The PAS reaction was not altered after 48 hours methylation but after 96 hours this and the other staining reactions were all abolished.

Deamination resulted in a noteworthy increase in intensity of the PAS reaction. Connective tissue also stained more strongly. The colloidal iron and aldehyde fuchsin reactions remained unaltered whereas toluidine blue metachromasia was slightly enhanced.

Acid hydrolysis enhanced the metachromatic staining of C cells as has been described in Section 3.4. The colloidal iron reaction was the only other to be affected : staining of C cells was entirely abolished.

Maleimide blockade inhibited the aldehyde fuchsin reaction when such a block was applied before but not after the oxidation step. The PAS, colloidal iron and toluidine blue reactions were not affected.

The use of sodium baths did not alter any of the staining reactions.

3.6.4 Discussion

In extensive work on collagen fibres, Bangle and Alford (1953) showed that aldehyde blockade, interposed between the oxidation step and Schiff staining in the PAS reaction, inhibited a colour reaction in these fibres. The aldehyde blocking agent used by them was aniline chloride (an aryl amine) which proved effective. If aniline chloride or any other method

of aldehyde blockade does not prevent a PAS reaction, as may occur especially with other amines that are used as blocking agents, then the presence of aldehyde is not necessarily excluded. The reason is that these blocking agents may not react with all aldehydes that are formed in tissues after oxidation. Aniline in glacial acetic acid (Lillie and Glenner, 1957) was chosen in this study rather than aniline chloride of Bangle and Alford (1953), hydroxylamine hydrochloride (Danielli, 1950) or dimedone (Lillie, 1965, p.376), because it is a most reliable aldehyde blocking agent. Both Pearse (1968a, p.455) and Lillie state that dimedone and aniline chloride sometimes fail to abolish a positive PAS reaction where aldehyde is known to be present.

Aniline in glacial acetic acid, as expected, completely inhibited the PAS reaction in canine C cells indicating that it efficaciously blocks aldehyde groups. In view of this observation it seems unlikely that in C cells, the aldehyde fuchsin reaction, which remained unaltered after this blocking procedure,is dependent on the formation of aldehydes. Kasten (1960) has expressed the view that the attachment of aldehyde fuchsin to tissue components is most likely due to aldehydes (formed by oxidation) which react with Schiff bases of activated pararosanilin (Fig. 14, Section 3.4.3). From the present observation it seems unlikely that the aldehyde fuchsin reaction in thyroid C cells is dependent on aldehydes and that pararosanilin combines with tissue groups by means of azomethines (Schiff bases). There is further indirect evidence from the present work to support the view that aldehydes do not play a prominent role in the attachment of aldehyde fuchsin to C cells. Both benzoylation and methylation, while not diminishing the PAS reaction (i.e. no aldehyde blockade has occurred) do inhibit the aldehyde fuchsin reaction. This indicates that dye attachment in aldehyde fuchsin staining is dependent on groups other than aldehydes.

Acetylation (with acetic anhydride-pyridine mixture) and benzoylation (with anhydrous benzoyl chloride in a mixture of acetonitrile and pyridine) are similar in that they form acyl derivatives with a number of chemical groups of proteins and carbohydrates (Barnard, 1961, Lillie, 1966). When acetylation was first introduced for cytochemical use, benzoyl chloride in acetic anhydride was used but subsequent workers (McManus and Cason, 1950) modified this method in that benzoyl chloride was excluded from the mixture. They found that 65 per cent acetic anhydride in pyridine was effective in inhibiting leuco-fuchsin (Schiff's reagent) staining after periodic acid oxidation in all tissue components, an observation which was disputed by Lillie (1954, p.278). Consequently, Lillie recommended a slightly changed procedure for effective acetylation. (He altered the concentration of reagents, duration and temperature of reaction.) Lillie's method was adopted in this study as it seemed, from the literature, most reliable. This acetylation method has been used on other tissues to investigate the acetylation of hydroxyl and amino groups (Lillie, 1964).

Acetylation was primarily used to evaluate its effect at a point when a positive PAS reaction is abolished. From this one would be able to exclude amino alcohol, vicinal hydroxyl or aromatic hydroxyls as participating groups in the aldehyde fuchsin, colloidal iron and toluidine blue reactions. A negative PAS reaction would indicate that these groups have been effectively blocked.

Acetylation abolished the PAS reaction in C cells and there was a moderate decrease in intensity of colloidal iron staining and toluidine blue metachromasia. The effect on the latter reaction is most likely the result of a reduction in the number of carboxyl groups, an explanation

which could also be applied to the Cl reaction. Some authorities state that the colloidal iron reaction depends on the number of available carboxyl groups (Pearse, 1968, p.350).

Anhydrous benzoylation by the method as first described by Danielle (1950), blocks phenolic groups of tyrosine, amino alcohol groups of serine and threonine, guanidyl groups of arginine and imidazole groups of histidine as well as terminal and side chain lysine groups of protein (Barnard, 1961). Alteration of aldehyde groups was not considered of significance by Barnard (1961), but subsequently Lillie pointed out that these may be benzoylated (Lillie, 1966). Barnard also indicates that benzoylation predominantly affects groups in the cell cytoplasm but not necessarily in the nucleus. That is, certain protein groups seem to be protected - benzoylation does not abolish the reaction of tetra-azotized anidine attributed to histidine (Barnard, 1961), the DNFB reaction attributed to tyrosyl residues (Maddy, 1961) or the DMAB reaction which is attributed to tryptophan (Curtis and Cowden, 1970).

Acetylation and benzoylation alter virtually the same chemical groups (enumerated above) but they do not act biochemically in the same way. Both procedures were therefore utilized in this study, particularly for the reasons given :

(1) for a comparison with each other - benzoylation may not be as effective as acetylation in blocking certain protein groups.

(2) to detect the presence of any 'protected' protein end groups participating in any of the four (PAS, colloidal iron, aldehyde-fuchsin and toluidine blue) reactions.

A comparison of the results of acetylation with benzoylation draws attention to the failure of benzoylation to inhibit the PAS reaction under the same conditions which can abolish the aldehyde-fuchsin and toluidine

blue reactions. This is an unexpected finding. Barnard (1961) reports that the PAS reaction, in certain sites, is not abolished by prolonged (8 h) benzoylation and thinks this is the result of carbohydrate binding to protein. I have previously drawn the conclusion that the PAS reaction in C cells is due to glycoprotein (Section 3.5.5) and if my deductions are correct, the presence of such groups may prevent effective benzoylation in C cells. There is no biochemical explanation of why benzoylation does not alter vicinal hydroxyl groups in the presence of excess protein.

Benzoylation is most effective in abolishing the aldehyde fuchsin, colloidal iron and toluidine blue reaction. The alteration of the aldehyde fuchsin staining is expected as even short (2 h) benzoylation rapidly acylates sulphydryl and disulphide groups (Cecil and McPhee, 1957). As indicated above, benzoylation affects hydroxyl groups and alteration of these may account for the inhibition of the toluidine blue reaction. The rapidity with which benzoylation alters the toluidine blue, aldehyde fuchsin and colloidal iron reaction indicates that 'protected' groups of histidine, tyrosine or tryptophan do not participate in this reaction as these groups are predominantly altered by 2 h benzoylation (Barnard, 1961). Prolonged (8 h) exposure to benzoyl chloride abolishes the PAS reaction. This is a drastic reaction and probably extracts most cellular components of tissue rather than merely altering reactive groups of proteins and carbohydrates.

Fisher and Lillie (1954) used the biochemical process of methylation (esterification) to study carboxyl groups in tissue sections and especially those stains which are thought to rely on these groups for positive staining. They used acidified methanol (HCl in methanol) for their investigation.

Frankel-Conrat and Olcott (1945), in biochemical analyses, reported that acidified methanol esterifies carboxyl but not phenolic, thiol or indole groups and furthermore that peptide-amide bonds of polypeptides are are not disrupted. These deductions have to a large extent been accepted to hold true in the cytochemical application of methylation (Pearse, 1968a). However, methylation may also be used to abolish the reactivity of phosphate and sulphate groups of carbohydrates and thereby block the staining reactions dependent on these tissue groups (Thompson, 1966, p.510).

Several other reagents such as thionyl chloride and methyl iodide have been used for methylation of tissue groups (Terner, 1964). Nevertheless, acidic methanol was chosen in this study in view of its frequent usage (Pearse, 1968a, Thompson, 1966). It was hoped in this way to compare results with studies on other tissues. I carried out the reaction at room temperature rather than at 60°C, which is frequently used. At higher temperatures the reactivity of tissue groups is altered rapidly whereas at 22°C the reactivity of chemical groups is altered slowly (Willcox, 1967) and changes be more carefully observed.

The results of the present study show that the aldehyde fuchsin and toluidine blue staining of C cells is abolished after 48 hours of methylation. Though it is not indicated in Table VII, these two reactions are already somewhat diminished after 24 hours of methylation. The effect of methylation on these two staining reactions is most probably through an alteration of carboxyl groups. Biochemically carboxyl groups are esterified far more readily than other groups (Willcox, 1967); therefore I would tend to favour the idea that an alteration of carboxyls is responsible for a change in at least these two staining reactions.

Spicer and Lillie (1959) suggest that sulphonic acid (the presence of which in tissue is necessary for a positive aldehyde fuchsin reaction)

can undergo esterification with methanol after prolonged exposure to methanol; such a mechanism most probably also plays a part in the alteration of the aldehyde fuchsin reaction after prolonged methylation.

In gastric mucus the toluidine blue reaction, which is dependent on carboxyl groups, is abolished after 24 hours of methylation, and the PAS reaction, which in this substance relies on vicinal hydroxyl groups, is abolished after 96 hours of methylation (Fisher and Lillie, 1954). Similar periods of methylation are needed to alter these reactions in canine C cells. These observations support the view that carboxyl and vicinal hydroxyl groups in C cells are altered by methylation.

Nitrosation (deamination) as a cytochemical reaction, predominantly affects the reactivity of amino groups and is unlike acetylation or benzoylation which alte several protein side groups. Changes in staining after deamination are described by Wolman and Greco (1952) and Lillie (1958); their deductions are pertinent to the observations of the present study. They noted an increased basophilia with toluidine blue at pH 5.0 and an enhanced PAS reaction. Enhanced basophilia (or decreased acidophilia) has been observed in many tissue structures following nitrosation (Lillie, 1958; Spicer, 1962; Lev and Gerard, 1966). For instance a diminution of staining of basic proteins in red blood cells and mucus was noted. The change in chromasy is attributed to a decreased number of positively charged amines (arginine, lysine and hydroxylysine) which are presumed to form salt linkage with anionic protein groups. A decreased number of cations (of amines) would account for an increased proportion of anionic groups and therefore enhanced basophilia. It has been shown that canine C cells do contain reactive basic amine groups of lysine and hydroxylysine (Section 3.4) and it is presumably nitrosation of these groups that accounts for increased basophilia.

The enhanced PAS reaction following nitrosation cannot be accounted for on the basis of a change in any carbohydrate groups as nitrosation does not affect these radicles (Thompson, 1966, p.509). Theoretically nitrosation may convert amino-alcohols to keto acids and nitro radicles but investigations by Lillie (1958) has shown that secondary amines, of which amino alcohols are an example, are not affected by nitrosation in tissues. An alternative explanation for the enhanced PAS reaction may be that plasmalogens are changed. Addition of keto groups to double bond carboxyls of lipids might provide additional aldehyds to the cell cytoplasm. Such an explanation has been invoked to explain the enhanced PAS reaction observed following deamination of smears of guinea pig fat (Wolman and Greco, 1952). Further studies involving lipid interactions in the C cell are required to provide supporting evidence that this biochemical change occurs in the C cell.

Aldehyde fuchsin and colloidal iron staining of C cells were not altered by nitrosation; it seems that basic protein groups are not involved.

Hydrolysis with hydrochloric acid is used in the well-known Feulgen and plasmal reactions. Usually 0.2N HCl is used at 60°C. Usage of such acid hydrolysis in cytochemistry is milder than the acid hydrolysis of biochemists who use concentrated hydrochloric acid for cleavage of protein and peptides (Neurath, 1963; Hill, 1965). Mild hydrolysis affects both carbohydrate, protein and lipid components of cell structures and effects of hydrolysis are dependent upon the concentration of acid, the temperature at which hydrolysis is carried out and the time that the tissue is exposed to acid.

Chemical modification which are attributed to acid hydrolysis of tissue sections, are as follows :

(1) extraction of RNA, purine bases and phosphates from cells and nuclei;

(2) unmasking or 'release' of aldehyde groups from pentose sugars in DNA;

(3) unmasking of aldehydes from plasmals (acetal phosphatides);

(4) conversion of side chain carboxamido groups to carboxylic acid; and

(5) partial extraction or cleavage of peptide chains in tissue proteins.

The manner in which acid hydrolysis enhances basophilia of the toluidine blue reaction of C cells has already been discussed (Section 3.4.3). It is noteworthy that the colloidal iron reaction is abolished in C cells by acid hydrolysis, an observation that was completely unexpected especially as hydrolysis increases the number of anionic (carboxyl) groups. There may be interference with the colloidal iron solution by residual HCl left in tissue sections and this may prevent staining. One could repeat the experiments after hydrolysis with tissue sections washed for prolonged times.

Acid hydrolysis did not enhance the PAS reaction in C cell cytoplasm; therefore cytochemical reactions (2) and (3) above, do not seem to take place in these cells. In view of the observation that deamination increases the intensity of the PAS reaction one would have expected an enhanced PAS reaction if deamination does in fact act on lipids (plasmals).

N-ethyl maleimide selectively blocks -SH groups by a process of alkylation (Riordan and Vallee, 1967; Jocelyn, 1972). Its effectiveness for blocking -SH groups in tissue was shown by Barrnett and Seligman (1952) in their analysis of the DDD reaction for sulphur-containing tissue components. Apart from reacting with -SH groups N-ethyl maleimide reacts slowly at pH 7.4 with amino-end groups of peptides (Smyth et al., 1960), the epsilon-amino groups of lysine and the imidazole of histidine (Brewer and and Riehm, 1967). These reactions clearly restrict the use of N-ethyl

maleimide for tissue analysis; nevertheless maleimide block has been used as a blocking agent for -SH groups (Pearse, 1968a, p.172).

The only staining reaction which was altered by N-ethyl maleimide blockade was aldehyde fuchsin provided that N-ethyl maleimide was used prior to the oxidation step. Presumably this is due to reaction with the disulphide group in the cell cytoplasm on which the aldehyde fuchsin depends for a positive reaction. No direct biochemical work is available to indicate that disulphides react with maleimides; recent cytochemical analysis of maleimide interaction with -SH groups does not mention their reaction with -SS- (Sippel, 1969). The mechanism whereby N-ethyl maleimide alters the aldehyde fuchsin reaction is thus difficult to explain.

3.6.5 Conclusions

(1) Toluidine blue staining relies on the presence of carboxyl groups in the cytoplasm of C cells for attachment of its dye molecule. Both methylation and benzoylation block carboxyl groups and abolish stainability of C cells with toluidine blue. Basic protein groups in the cell cytoplasm interfere with the reactions of some carboxyl groups with toluidine blue. These basic groups can be dissociated from anionic groups by means of nitrosation.

(2) The aldehyde fuchsin reaction is inhibited by the same blocking procedures that abolish the toluidine blue staining. Aldehyde fuchsin may therefore *in part* depend upon carboxyl groups for its attachment to tissue groups. Acetylation and aldehyde blockade indicate that aldehyde fuchsin staining does not rely on aldehyde in tissues for attachment of dye molecules.

(3) The colloidal iron reaction in C cells requires the presence of carboxyl groups in order to yield a positive result. However,

only a small number of these groups is necessary for a positive stain, as methylation, which abolishes the toluidine blue reaction does not, under the same conditions, abolish the colloidal iron reaction but merely reduces the staining intensity. The production of increased numbers of carboxyl groups in C cells by acid hydrolysis does not enhance the colloidal iron stain, indicating that this staining is the result of an 'all or none' reaction which occurs in the presence of a minimum number of carboxyl groups.

(4) The PAS reaction is positive in C cells. Only nitrosation suggests that lipids contribute but this is not confirmed by the application of acid hydrolysis. Whether amino-alcohols of proteins contribute to the PAS reaction could not be established in this section of the study.

3.7 Enzymatic and chemical cleavage of protein groups

3.7.1 Introduction

Use of enzymes for extraction and hydrolysis of chemical substances in tissues has been made extensively since 1945 when enzymes became available as cytochemical reagents. Enzyme techniques in cytochemistry and their limitations have been reviewed (Kaufman et al., 1950; Benditt and French, 1953). To a great extent the limitations imposed by, for example, impurities in enzyme samples and assessment of the end-point of the enzymatic reaction, still apply. Mindful of the limitations inherent in their use degradation procedures were nevertheless undertaken as it was felt that useful informatic might be derived from them. My rationalization was as follows.

(1) Calcitonin can, biochemically, be broken into fragments of peptides by proteases or by 'chemical' hydrolysis (Brewer, 1970) (Fig. 17).



Fig. 17 - Peptide fragments into which the polypeptide chain of calcitonin (A) is cleaved by dilute acid (DA), cyanogen bromide (CnBr) and trypsin (T). Based on Brewer (1970).

This information from biochemical work prompted a cytochemical exploration of similar methods in C cells.

(2) I thought it possible that enzyme cleavage might make cytochemical identification of protein subunits (peptides) possible. The proteolytic enzymes hydrolyze specific peptide bonds and in this they are superior to hydrolysis by means of concentrated acid which is less specific (Hill, 1965). By employing enzymes of increasing hydrolytic activity (an increased number of peptide bonds of a polypeptide that can be disrupted by one enzyme), it was hoped to establish some specificity for the cytochemical reactions used. For this purpose trypsin, pepsin and papain were chosen, papain having the greatest hydrolytic activity.

(3) PAS, toluidine blue and colloidal iron staining reactions could indicate the presence of glycoproteins in C cells. Enzymes may split the carbohydrate-protein linkages (Spiro, 1970) of glycoproteins and this dissociation could help locate the reactive staining groups in C cells. Both proteases and glycosidases are capable of breaking down the carbohydrate-protein link. More specific information is obtained by splitting off the carbohydrate with glycosidases than splitting off protein with proteases, because protease disruption of this link usually leads to loss of both protein and carbohydrate from the tissue section (Lev and Gerard, 1967, Schultz-Haudt, 1971).

(4) Hydrolysis of proteins other than enzymes, acids and alkalis, may be undertaken with certain chemicals. Chemical hydrolysis with cyanogen bromide has been used to cleave several polypeptides, for example ribonuclease and calcitonin (Gross, 1967; Witkop, 1968; Spande et al.1970). As cyanogen bromide had not been employed in

cytochemistry, attempts were made to use the proteolytic property of this agent to fragment polypeptides of the C cell cytoplasm.

3.7.2 Material and Methods

Sections of thyroid glands from four dogs (D7 - D10 Table III) were chosen at random. Each batch of sections that was exposed to enzymes contained sections of glands from at least two dogs.

Four staining reactions, aldehyde fuchsin, periodic acid-Schiff, colloidal iron and toluidine blue were chosen for the same reasons as given previously (Sections 3.6.1). All the sections were cut from tissue that had been freeze-dried and fixed in formalin vapour. After this method of fixation, staining by aldehyde fuchsin and toluidine blue was somewhat less intense than after GPA fixation. However, I wished to use tissue in which the protein content after fixation was optimal. Enzymatic hydrolysis was undertaken prior to periodic acid oxidation for the Schiff staining. The toluidine blue staining was carried out at pH's of 2.6 and 5.0 with enzymatic hydrolysis following the acid hydrolysis previously described (Section 3.4.1). For each enzyme procedure two sets of five sections each were used, one section in each set acting as control by being immersed in normal saline while the other sections were treated with the relevant enzyme. Enzyme digestion was carried out at 37^{0}C in a humidified atmosphere (humidity not controlled). Humidification was essential in order to prevent evaporation of the enzyme solution covering the sections.

The following enzymes were used : trypsin, pepsin, papain, alpha-amylase, beta-glucuronidase, hyaluronidase and neuraminidase.
The following methods were employed :

Trypsin - Triple-crystallized, salt-free, porcine trypsin (Miles-Seravac, batch No 36-564, UK 7) with 0.04 per cent chymotrypsin impurity and an activity of 4460 NF units/mg was used. The method of Lillie (1965, p.265) and Mancini et al. (1966) was employed: 1 per cent trypsin in 0.1M Sorenson's phosphate buffer, pH 7.6, constituted the enzyme 'broth'. Incubation time was 60 minutes at 37°C.

Pepsin - A double-crystallized pepsin (Difco) was utilized. Incubation was in 10 mgs/ml of 0.02N HCl for 3 hours at 37°C. This incubation time was based on the work of Lev and Gerard (1967) and the recommendation of Pearse (1972, p.1039).

Papain - There is no universally accepted method for applying papain to tissue sections. Cytochemically, papain has been used to elucidate the staining of enterochromaffin granules and mucopolysaccharides (Glenner and Lillie, 1959; Lev and Gerard, 1967). The method as used by Lev and Gerard (1967) was employed here. As the assay of papain is carried out at a pH 6.2 which is the optimal pH for papain activity, a similar pH was employed for the enzyme mixture. Double-crystallized papain (Sigma, batch Nos. 400-1410 and 108b-2240) was used at a concentration of 0.5 per cent in phosphate buffer at pH 6.0. Digestion time was 10 hours at 37°C.

Beta-glucuronidase - The method which I employed for this study is based on methods used for studying mucopolysaccharides (Fullmer, 1960), connective tissue (Moore and Schoenberg, 1958) and thyroid colloid (Kobayashi, et al., 1959). The purest form of glucuronidase obtainable is contaminated significantly with aryl sulphatase. Grade 1 marine mollusc beta-glucuronidase (Miles-Seravac, batch No. 13, 36.03) was used at a concentration of 30 mgs in 50 ml of 0.1M acetate buffer at pH 4.5 as this enzyme has an optimum activity at pH 4.5 (Cox, 1959). Digestion time was for 30 hours at 37°C.

Hyaluronidase - Hyaluronidase activity depends on the purity of the enzyme and the pH : optimal activity is at pH 6.0 (Bowness, 1965). Pearse (1972) dissolves the enzyme in normal saline; however, I consider that the salt content of a phosphate buffer would be equally satisfactory. Ovine hyaluronidase (Miles-Seravac, grade 1A, 1000 units/mg., batch m.s. 298) was used in a concentration recommended by Pearse namely 1 mg/ml of 0.1M phosphate buffer at pH 6.0. Incubation was for 30 hours at 37°C.

Sialidase (neuraminidase) - The digestion procedure was based on the recommendations of Spicer and Warren (1960) and Schmitz-Moorman (1969). Chromatographically purified chlostridial sialidase (Sigma), at a concentration of 1.0 mg/ml in phosphate buffer at pH 6.0, was used. Incubation was for 18 hours at 37°C.

Alpha amylase - Lillie (1965) who pioneered the method of amylase digestion used the enzyme in a phosphate buffer at pH 6.0 in 0.8. saline. Pearse (1972) has remarked that buffering and salt addition increase the activity of ribonuclease found as an impurity in amylase. In order to circumvent possible ribonuclease activity I decided to use 'neutral' (pH 7.35) phosphate buffer (alpha-amylase activity is optimal at pH 6.9) as the solvent vehicle for the enzyme. Porcine alpha-amylase, grade 1A (Sigma, batch 70c-2090) was employed at a concentration of 1 mg/ml 0.1M. Sorenson's phosphate buffer at pH 7.35 in normal saline. Incubation time was 60 mins at 37°C.

Cyanogen bromide - Cyanogen bromide is used for the chemical (non-enzymatic) cleavage of proteins. It was used biochemically for the elucidation of the structure of ribonuclease (a polypeptide) by Gross and Witkop (1961) and thereafter for other polypeptide hormones such as parathormone, gastrin, (Gross, 1967) and calcitonin (Potts, 1968). The desirability of finding a suitable non-enzyme protein-cleaving agent for

cytochemical use is indicated by the following points : (1) enzyme cleavage occurs at multiple sites and numerous peptide bonds are hydrolyzed and (2) the purity of enzymes, though better now than fifteen years ago, can still be improved. Cyanogen bromide attacks only methionyl peptide bonds and does not react with other amino acids, with the exception of cysteine.

As cyanogen bromide has not been used as a cytochemical reagent before, an empirical cytochemical approach, based on the method employed by the biochemist mentioned above, was chosen. Cyanogen bromide, a very volatile agent, was obtained from Koch Light Laboratories. An 0.4 per cent solution in a 60 per cent aqueous mixture of 0.1N HCl was used. Tissue sections were covered with this solution for 24 hours at room temperature in a fume cupboard. Sections were then washed in three changes of distilled water before proceeding with the various staining reactions.

3.7.3 Results

A summary of the results in terms of staining of the cytoplasm of C cells is given in Table VIII. In general the staining of the cytoplasm was either not affected or completely abolished. Exposure to alpha-amylase, beta-glucuronidase, hyaluronidase, sialidase and cyanogen bromide did not alter staining of either the C cell cytoplasm or thyroglobulin.

Exposure to papain abolished staining of these tissue components with aldehyde fuchsin, colloidal iron, PAS and toluidine blue. Trypsin digestion produced the same changes but in addition diminished the basophilia of cell nuclei.

TABLE VIII - The effects of enzymatic and non-enzymatic cleavage procedures on the staining of the C cell cytoplasm by PAS, aldehyde fuchsin, colloidal iron and toluidine blue

	aldehyde fuchsin	periodic acid-Schiff	colloidal iron	toluidine blue pH 2.6	toluidine blue 5.0
trypsin	-	-	-	-	-
pepsin	-	-	-	-	-
papain	-	-	-	-	-
alpha amylase	+	+	+	+	+
beta glucuronidase	+	+	+	+	+
hyaluronidase	+	+	+	+	+
sialidase	+	+	+	+	+
cyanogen bromide	+	+	+	+	+

\- staining abolished

\+ = no difference from staining intensity in control section

3.7.4 Discussion

From the present results it has become evident that positive staining with colloidal iron, aldehyde fuchsin, toluidine blue is abolished by the hydrolytic activity of certain enzymes. In the further discussion I shall limit myself to the degradation of calcitonin, although I am aware that protein cleavage procedures involve all structural proteins also contained in the C cell. Unfortunately no extensive biochemical or cytochemical work is available to facilitate a useful discussion of the effects on these structures.

In ascending order, the hydrolytic activity of the protein-splitting enzymes and chemicals, is as follows : cyanogen bromide < dilute acid < trypsin < pepsin < papain. Cyanogen bromide cleaves methionyl peptide

bonds only (Gross, 1967), dilute acid attacks aspartyl bonds selectively and thereafter releases aspartic acid into solution (Tsung and Fraenkel-Conrat, 1965; Brewer, 1970) and trypsin, which is an endopeptidase, hydrolyses links involving the carboxyl groups of the basic amino acids lysine and arginine (Hill, 1965; Smyth, 1967). In calcitonin this yields three peptide fractions (Brewer, 1970) (Fig. 17). Pepsin is also an endopeptidase which can hydrolyze bonds formed by the amine or carboxyl groups of phenylalanine, tyrosine, glutamine, cystine and cysteine. The most susceptible bonds are the aromatic and leucyl residues of peptides (Hill, 1965; Smyth, 1967). It follows therefore that pepsin will produce several oligopeptide chains from calcitonin (at least four) and this applies under the conditions which were used on the tissue sections.

As neither cyanogen bromide nor dilute acid adversely alter aldehyde fuchsin and toluidine blue staining, it seems that a single peptide break in the calcitonin molecule does not alter its potential to stain, whereas a double break due to trypsin or triple break due to pepsin or papain in the peptide chain does result in loss of staining. This is probably due to loss of peptide fragments in solution.

The fact that proteases alter staining by PAS, colloidal iron, toluidine blue and aldehyde fuchsin probably indicates that proteins are stained by these reactions. However, one cannot exclude the possibility that carbohydrate or lipid, conjugated with proteins, are at least partially responsible for staining as these may be attached to peptides that are lost into solution. Because of this reasoning I utilized glycosidases to exclude carbohydrates as groups which produce staining in the above four procedures. As is explained below, despite careful adherence to methodology it could not be shown that mucopolysaccharides,

chondroitin sulphate, sialic acid or glycogen are present in significant amounts in canine C cells.

Beta glucuronidase hydrolyzes beta glucuronides to release D-glucuronic acid (Levy and Marsh, 1959). Fullmer (1960) demonstrated that beta-glucuronidase digests principally mucopolysaccharides which produce a positive stain with colloidal iron and aldehyde fuchsin.

Hyaluronidase removes chondroitin sulphate A and chondroitin sulphate C from tissues (Zugibe, 1962; Leppi and Stoward, 1965). Cytochemically it has been used to study mucopolysaccharides in skin, synovium, hyaline cartilage, tendons, aorta and in umbilical cord ground substance (Moore and Schoenberg, 1958; Fullmer, 1960; Zugibe, 1962; Leppi and Stoward, 1965 and Schultz-Haudt, 1971). In these studies inhibition of toluidine blue metachromasia and alcian blue staining was reported for most tissues. This enzyme did not affect toluidine blue metachromasia in C cells and it is therefore concluded that mucopolysaccharides containing chondroitin sulphate are not responsible for the toluidine blue staining in these cells.

There is no specific stain for sialic acid (Schmitz-Moorman, 1969); enzyme digestion with sialidase is at present the most reliable method for detecting sialic acid. Sialidase does not alter the chemical component which produces a positive PAS reaction (Spicer and Warren, 1960; Schmitz-Moorman, 1969) but leads to a loss in metachromasia of the same chemical component at low pH's. Such changes did not occur in thyroid C cells, showing that sialic acid is not present in these cells.

There are several types of amylases available for tissue digestion: alpha-amylase attacks all glycogen and starch (branched and straight chain carbohydrates) and beta-amylase digests starch and amylose (only straight

chain carbohydrates). Both enzymes attack the 1-4 glucoside linkage in a random manner. Cytochemically alpha-amylase effectively removes glycogen (Rosa and Johnson, 1967). Reports on the effect of alpha-amylase on glyco-protein are at variance. Schultz-Haudt (1971) in his work on aortic glycoproteins found no alteration of glycoprotein molecules in electrophoretograms. Lillie et al. (1949) noted decreased metachromasia of cartilage and Lovell et al. (1956) demonstrated a marked decrease in stainable thyroglobulin. These results were not reproducable by Kobayashi (1959) who used purified alpha-amylase. Presumably impurities in the amylase must have produced changes in glycoprotein stains in the older studies. No change in staining of C cells or thyroglobulin was noted after the use of alpha-amylase in this study, thereby excluding the possibility that glycogen contributes towards a positive PAS reaction in C cells.

3.7.5 Conclusions

(1) The use of proteases and glycosidases indicates that aldehyde fuchsin, toluidine blue and colloidal iron, stain, in C cells, simple protein unconjugated to mucopolysaccharide, glycogen, sialic acid or chondroitin sulphate.

(2) Protein cleavage procedures which break one peptide bond only, do not result in any change in staining of the C cell cytoplasm, whereas hydrolysis of two or more peptide bonds abolishes staining by the above reactions in C cells.

(3) C cells contain no glycogen, chondroitin sulphate, hyaluronic or sialic acid which therefore do not account for the PAS positive staining.

3.8 Final conclusions on protein cytochemistry of C cells

The combined results from the analyses of reactive groups of proteins in canine C cells, the staining reactions for glycoproteins and the use of blocking procedures as well as enzyme hydrolysis, have led to the following overall conclusions.

(1) The presence of acidic groups of proteins is demonstrated in canine C cells by toluidine blue metachromasia. The reactive groups are side-chain carboxyl groups derived from polypeptides, rather than glycoproteins. It is tentatively suggested that hydrolysis of polypeptides with acid contributes to the number of carboxyl groups by cleaving polypeptides at the aspartyl group. Other prototropic groups of substances that might produce metachromasia, for example, mucopolysaccharides, sialic acid, polyphosphates and polysaccharide ester-sulphate could not be shown in the canine C cells.

(2) The positive colloidal iron reaction in C cells is most likely imparted by reactive groups of polypeptides rather than glycoproteins. A comparison of this staining reaction with the staining by the aldehyde fuchsin, toluidine blue and PAS reactions suggests that carboxyl groups are necessary for a positive colloidal iron staining reaction.

(3) Reactive groups of basic protein, such as alpha- and epsilon-amines, are demonstrable in canine C cells with the sensitive fluorescent stain dansyl chloride. Nitrosation (de-amination) enhances the PAS staining and toluidine blue metachromasia, possibly due to disruption of amino groups which are covalently linked to acidic groups of polypeptides.

(4) The DDD and ferri-ferrocyanide reactions indicate the presence of considerable numbers of disulphide groups in the canine C cells. The sulphonic acid derived from these groups by permanganate oxidation probably induces a positive aldehyde fuchsin reaction. As the aldehyde fuchsin reaction is inhibited by the same blocking procedures that abolish toluidine blue staining, aldehyde fuchsin staining may <u>in part</u> depend upon carboxyl groups for its attachment to tissue groups in C cells.

4. SILVER BINDING IN C CELLS

4.1 Introduction

Nonidez, in 19[illegible], was the first to show that C cells of the canine thyroid gland display an affinity for silver nitrate, far greater than that of the surrounding follicular and connective tissue. This is observed as a granular argyrophilia of the cytoplasm and is so marked in comparisor. with the paucity of silver deposition in follicular cells, that C cells can be readily distinguished from other epithelial cells.

The observations of Nonidez were incidential to a study on the innervation of the thyroid gland, for which study the Cajal (1927) silver impregnation method was selected. A student of Nonidez soon confirmed that his observations were not exclusive to the canine thyroid gland but that argyrophilic C cells were demonstrable in thyroid glands of rabbits (Raymond, 1932). Subsequently they have been shown in several animal species including man, by Sandritter and Klein (1954).

The foregoing work was undertaken in an era (1930-1955) during which extensive study and debate revolved around technical procedures of silver impregnation (Holmes, 1968). For instance, the criteria for detecting argyrophilic and argentaffin cells in the gastrointestinal tract were being debated and neuroanatomists and neuropathologists deliberated on the reliability and use of silver impregnation methods for their studies. Methodology was a prime consideration in silver impregnation during the mid-thirties when Nonidez described the argyrophilia of C cells and the fact may account for the scant notice that was accorded to his observations at that time.

It has gradually emerged that a distinct group of cell types, a endocrine system called the APUD system by Pearse (1967), can be recognized

in mammals and that several members of this group, for example alpha (A) cells of the pancreas, G cells of the gastric antrum, and C cells of the thyroid gland are argyrophilic. However, not all members of this system are argyrophilic. Pearse (1970) suggested, on the basis of this and other staining properties, that the embryonic origin of thyroid C cells might be from the neural crest. There are, however, significant differences in the methods whereby silver can be optimally attached to neural tissue and to C cells. Some of these differences will be referred to again in a subsequent section (4.1.2).

4.1.1 An analysis of methods of silver impregnation used for C cells

Several methods for impregnation with silver have been employed on tissue sections of the thyroid gland. Nonidez used Cajal's method (1927); Sandritter and Klein employed two methods, those of Gros-Schultze (1948) and of Gros-Bielschowsky (Feyrter, 1951). Kameda (1968) utilized the method of Davenport (original reference not available) and Solcia et al. (1970) used the method of Grimelius (1968), which is a modification of Bodian's technique. All these procedures, with the exception of the Gros-Schultze method, produce a granular argyrophilia in the cytoplasm of C cells in animals.

Before analysing the above methods of silver impregnation it is pertinent to the subsequent experimental work to discuss the chemical form of silver that is applied to tissue sections (Table IX). Regardless however, of the chemical form of silver that is used, it is always ionic silver (Ag^{+}) that is deposited on tissue sections. Amounts of ionic silver that are available in each form of silver vary and in silver proteinate, constitute only 25 per cent of the total silver content (the remainder is unionized and attached to the proteinate moeity).

TABLE IX - Forms of silver and their solvent generally used for silver impregnation of tissue sections

Chemical form of silver	Solvent	first usage
silver chloride ($AgCl_2$)	aqueous/buffered/with NH_3	± 1903
silver nitrate ($AgNO_3$)	aqueous/buffered/with NH_3	± 1903
silver proteinate	aqueous/buffered/with NH_3	Bodian (1937)+
silver diamine ($Ag(NH_3)_2OH$)	aqueous solution	Bielschowsky (1902)
silver methenamine	aqueous/buffered	Gomori (1946)

+ first described in 1903 but not used again until 1937.

Several methods of silver impregnation utilize a combination of chemical forms of silver. For example, aqueous silver nitrate is frequently used in combination with silver proteinate (Gray, p.564). The purpose of such combinations has never been clearly established. Probably they are not necessary as either chemical form of silver individually may be adequate for impregnation provided enough silver, in ionic form, is available for deposition.

With regard to the chemical forms of silver, it is noticeable that all the methods for argyrophilia which are employed for C cells, utilize aqueous silver nitrate (Cajal, Gros-Schultze, Grimelius). The Gros-Bielschowsky method utilizes aqueous silver nitrate in combination with silver diamine.

A further feature of the methods of silver impregnation is the use of ammonia. Ammonia is used to produce silver diamine (Table IX) from a mixture of silver nitrate and potassium hydroxide (Gray, 1954, p.575) or ammonia is often added, instead of a buffer, to an aqueous solution of silver nitrate to provide an alkaline pH. Alkaline silver solutions are essential for the impregnation of certain tissues (see below). By

employing ammonia in these two different ways the same results are probably achieved - that is alkaline conditions (high pH) for silver impregnation. The Gros-Bielschowsky method contains silver diamine but none of the above methods which demonstrate argyrophilic granules in C cells use silver nitrate in an ammoniacal solution.

A further consideration in silver impregnation procedures is the method whereby silver ions are reduced to metallic silver in tissue sections. To achieve this, 'developers' or reducing agents are necessary, based on their action, two groups of metallophilia are described. Reducing agents may be endogenous, that is there may be inherent ability within the cell to reduce ionic silver without assistance from external agents, or they may be exogenous. The former type of metallophilia is called argentaffinity and the latter argyrophilia. All the methods for C cells quoted above require exogenous reducing agents and these cells are therefore argyrophilic and not argentaffin.

A list of the reducing agents which are most frequently used is given in Table X. In the Cajal method a combination of pyrogallol and formaldehyde is used, the Gros-Bielchowsky method employs formaldehyde alone and the Grimelius method, hydroquinone. All the reducing agents which are listed, achieve good reduction of ionic to metallic silver provided that sufficient silver salt is present in the tissue sections. Cytochemically it is not known how the reducing agents achieve their effect on silver in tissues (Peters, 1955b).

Table X /...

TABLE X - Reducing (developing) agents used in silver impregnation methods

hydroquinone
chloroquinal
pyrogallol
p-aminophenol (Amidol)
formaldehyde
(sodium sulphite)+
(sodium thiosulphate)+

+ These are 'stabilizing' salts frequently used in conjunction with the above reducing agents.

4.1.2 General principles of silver impregnation

There is hardly a tissue structure which cannot be 'impregnated' with silver or on which deposition of silver cannot occur (Peters, 1965a) The extent of silver impregnation depends on which method is used. There is no universal method that will achieve ideal silvering of all tissues known to be argyrophilic but rather many recipes, each for separate tissues, have been advocated. Gray (1954) lists no fewer than 250 formulations of silver impregnation methods, many of which are minor modifications of older procedures and have little scientific basis. These methods emanate from the empiricism of 'broth mixers' (Holmes, 1968).

Despite the fact that silver is physically deposited on all tissue structures, there are certain components - e.g. neuroglia, granules of enterochromaffin and C cells - which have an affinity for silver in excess of that of their surrounding tissue. The nature of this 'affinity' is not agreed upon nor has a cytochemical basis for it been elucidated.

Until further information becomes available it seems appropriate to use the terms 'high affinity' and 'low affinity' sites for silver in tissues of these two categories.

The principal steps of silver impregnation as far as they have been elucidated at present, are outlined in Fig.17a. An oxidation step may or may not be incorporated prior to exposure to silver baths. Methods for reticulin fibres, basement membrane (Velican and Velican, 1972) or polysaccharides (Pickett-Heaps, 1967) require such oxidation whereas impregnation of neuroglia (Peters, 1955a), enterochromaffin and C cells (Solcia et al., 1970) are performed without oxidation. The chemical forms of silver in the baths has been described above (Section 4.1.1). Deposition of silver in tissues has classically been ascribed to the formation of 'silver nuclei' surrounding which an excess amount of ionized silver aggregates (Velican and Velican, 1972). This phenomenon of excess silver aggregation is well known to biochemists : silver ions that are used for titration of sulphydryl groups of proteins do not combine in a one to one ratio with these groups but rather are found in a number in excess (on a molar basis) of the number of sulphydryl groups (Sluyterman, 1957). The ability of silver to aggregate around a 'nucleus' probably accounts for the ease with which silver impregnation methods can reveal secretory granules in the cytoplasm of C cells when these granules (160-250 mμ diameter in the dog (Azzali, 1968)) are otherwise beyond the resolving power of the light microscope. Accumulation of silver around a 'nucleus' is described as an autocatalytic process (Peters, 1955a). No biophysical or cytochemical explanation for this reaction has been published.

How 'silver nuclei' are formed is hypothetical. Theoretically they may occur either through electrostatic interaction with specific or non-specific tissue groups (Silver, 1942; Samuel, 1953a,b; Gottlob and

Hoff, 1968); or in raction by non-polar addition to specific chemical end-groups in tissue (Peters, 1955a; Wolman, 1957; Lillie, 1965, p.238; Swift, 1968).

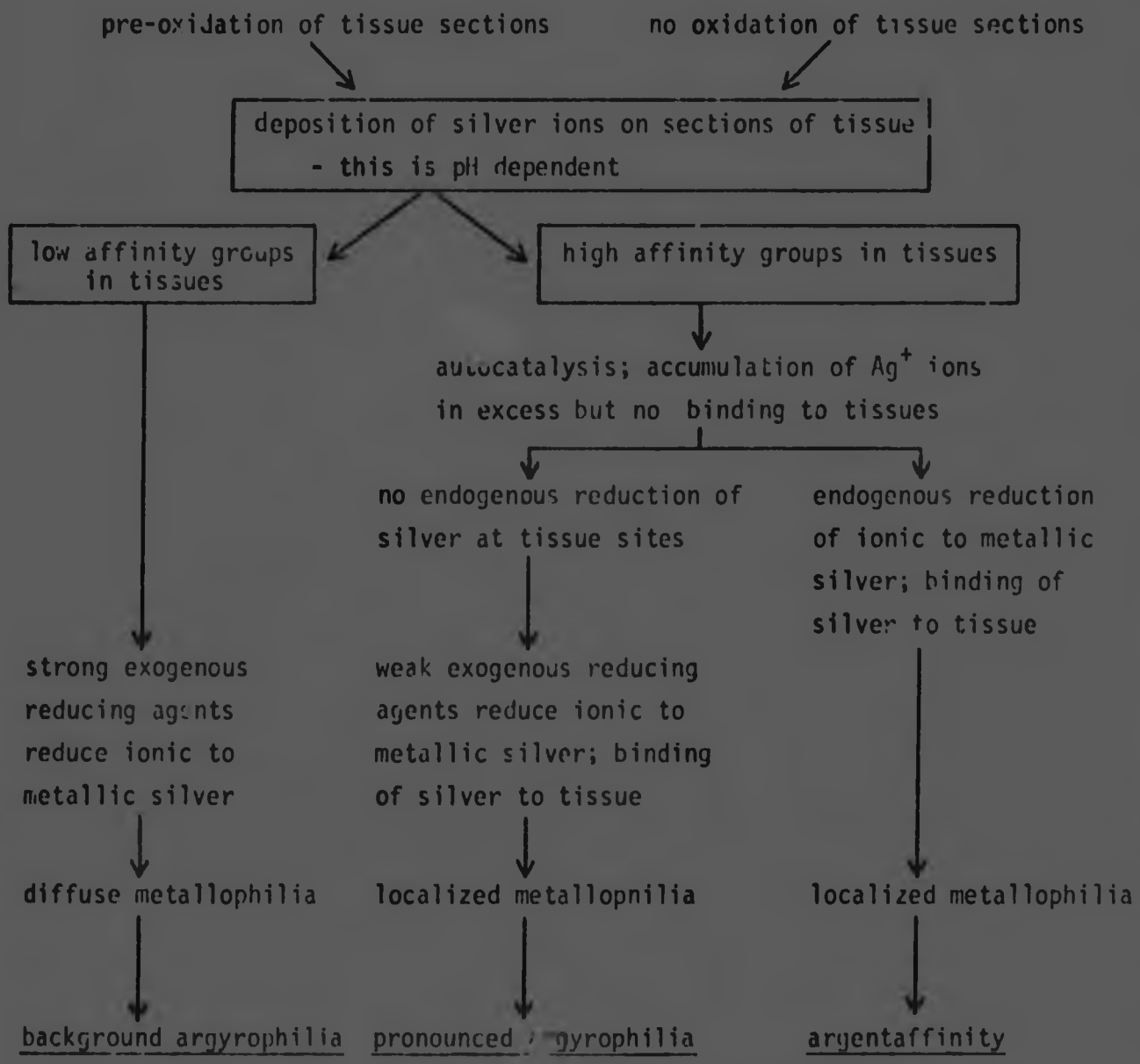

Fig. 17a - Suggested mechanism of silver impregnation in tissues

Based on:

1. Peters (1955a, b)
2. Velican and Velican (1972)
3. Pearse (1968a, p.364)

4.1.2.1 Electrostatic interaction and silver deposition

Silver impregnation is largely controlled by the prevailing pH of the solvent of silver nitrate (Samuel, 1953a). Aqueous silver nitrate has a pH of ± 6.2, ammoniacal silver a pH of ± 8-10, whereas buffers are adjusted to a required pH. There are only two buffers the constituents of which do not precipitate with silver - these are acetic acid/acetate and boric acid/borax buffers both of which are used in silvering solutions. For example the methenamine reaction of Gomori (1952) is performed at an alkaline pH in a boric acid buffer.

There are two optima of pH at which silver impregnation is usually carried out : one is 8.0-8.5 for staining of enterochromaffin granules (Gomori, 1952). cell bodies of microglia (Silver, 1942) and axons (Samuel, 1952a; Peters, 1955a)and the other is 5.5-6.0 for the staining of alpha cells in the pancreas (Hellerström and Hellman, 1960; Grimelius, 1968) and C cells of the thyroid gland (Solcia et al., 1970). A variation in pH of 1.0-1.5 either way produces a markedly diminished metallophilia in the above structures. These observations strongly favour the view that electrostatic interaction either mediates the initial deposition or the further accretion of silver ions in the abovementioned structures.

4.1.2.2 Chemical end group interaction in silver deposition

Many groups have been nominated as the 'reactive' ones responsible for silver attachment. Peters (1955a) proposes that in nerve tissue histidine is of importance. Swift (1968) suggests that in hair and hair follicles disulphides are reactive groups, Wolman (1957) puts forward evidence that in axons ethylenic links of lipoproteins are mediators of silver attachment, Lillie (1965, p.238) suggests that in enterochromaffin granules amine groups are the sites for silver reduction and Velican and Velican (1972) propose

in the glomeru[illegible] basement membrane, the hydroxylysine is the group to which silver is attached. In those silvering methods which require antecedent oxidation, vicinal hydroxyl groups are proposed as the participating chemical group (Pickett-Heaps, 1967).

A criticism of some of the above contentions can be aimed at the cytochemical evidence which is utilized. For instance, there is no direct cytochemical reaction for histidine and its involvement in staining procedures is only suggested from non-specific chemical blocking procedures.

It is noteworthy that some of the above reactive groups (amines, hydroxylysine, disulphides) have pK values in the alkaline range (pH 6-11) which accords with the alkaline conditions under which the silver impregnation is undertaken. Perhaps the formation of 'silver nuclei' in tissue sections depends on a combination of prevailing electrostatic forces and specific chemical groups that provide these forces. The possibility that such a mechanism prevails in impregnation of C cells is to be considered later (Sections 4.3.1 and 4.4.1).

4.3.1 Intracytoplasmic structures concerned with silver binding in C cells

Solcia et al. (1970) showed a granular argyrophilia in the cytoplasm of C cells of the dog with the Grimelius silver impregnation method at the light microscope level. Silver impregnation of nuclei and cell borders (low affinity sites) was faint but the nucleolus (high affinity site) was well demarcated. Adaptation of the Grimelius method for electron microscopic use was readily achieved (Vassallo et al., 1971) and its application indicated that the argyrophilic granules in C cells correspond to secretory granules and to no other cytoplasmic organelles. These workers showed that silver grains attached evenly over the secretory granules and did not preferentially accumulate at their margins - as is seen for example with the secretory

granules of some gastrointestinal endocrine cells. Localization of silver at the margins of granules might represent attachment to the limiting membrane of such granules.

In view of the remarks made in Section 1.2 which reviewed evidence that secretory granules in C cells contained calcitonin or at least a close derivative of this polypeptide, it seems very likely that silver attachment is concerned with the amino acid components of calcitonin. Freeze-etching studies (Welsch and Bucheim, 1972) of secretory granules in C cells suggest that they are homogeneous and that calcitonin is organised in a random coil conformation as was proposed by Pearse (1969). Such steric conformation of calcitonin would allow ready accessibility of silver ions to the amino acids constituting its polypeptide chain.

4.2 Purpose of the present study on metallophilia of C cell granules

The C cells have a clearly defined synthetic product to which silver ions become readily attached. I wished to establish whether metallophilia in C cells is affected by (1) oxidation, (2) alteration of pH and (3) omission of exogenous reduction under alkaline conditions. These features were chosen as they are important points in the general mechanism of silver impregnation as outlined in Fig. 17a. The design of this study takes into consideration the general mechanism of silver impregnation as it is given in Section 4.1.2. I therefore chose a method

(1) that requires an oxidation step for a positive result

(2) that uses ammoniacal silver but no exogenous reduction

(3) that uses silver ions in aqueous solution

(4) that uses silver salt in a buffer.

In the subsequent section, 4.4 I extended the observations on oxidation which is Section 4.3 is shown to inhibit silver binding in C cells.

I thereby hoped to determine the amino acid groups which may have a high affinity for silver ions. Various oxidants and oxidation times were used with the Grimelius impregnation method that produces argyrophilia in C cells. I also wished to elucidate the c tochemical significance of silver impregnation of C cells. An acetylation procedure and a sulphydryl blocking agent were chosen because they block known chemical groups, for example disulphides and sulphydryl groups, which might be involved in silver binding of C cells.

4.3 Silver impregantion - generai methods

4.3.1 Material and methods

All silver impregnation, unless otherwise stated, was performed on canine thyroid fixed in GPA. For each stain five to ten sections were stained in a batch. Each batch comprised sections from one or both of two dogs and for each dog the slides were chosen at random from any area in the thyroid gland.

Cajal's silver impregnation method was employed as advocated by Nonidez (1932) but with some minor changes. For this method, tissues were fixed in 80 per cent alcohol for 4 hours at $0^{o}C$. Tissue blocks were washed in distilled water and placed in freshly prepared 1.5% aqueous silver nitrate (pH 6.2) in the dark for two days. They were then immersed in a reducing fluid of pyrogallol/formaldehyde in distilled water for 24 hours. Thereafter the block of tissue was dehydrated and cleared and embedded in paraffin wax for sectioning. Sections from some blocks of tissue were toned with gold chloride according to the method of Cajal and de Castro as advocated by Gray (1954, p.548).

A reliable method combining silver nitrate and silver diamine with a preceding oxidation step was chosen. The method of Mitchell and Wislocki (1944) demonstrates reticulin fibres and is also claimed to

demonstrate glycogen. This method, including the oxidation step with aqueous potassium permanganate, was carried out as originally described.

An ammoniacal silver impregnation according to Masson-Fontana (Bancroft, 1967, p.168) was applied to sections of thyroid fixed in formalin vapour. No reducing agents are employed but a brief rinse in 'hypo' is incorporated.

The Grimelius impregnation method was carried out as described for alpha cells of the pancreas (Grimelius, 1968a). The silver solution was added to acetic acid/acetate buffer at pH 5.6. Impregnation was for 3 hours at 60°c; the reducing solution constituted a hydroquinone/sodium sulphate mixture. Slides were immersed in this solution for one minute at a temperature of 45°C. The Grimelius stain was repeated at various pH's between 4.0 and 6.5.

4.3.2 Results

The results in terms of the granular argyrophilia of C cells are summarized in Table XI. Each method is assessed against an optimal reaction which is described in the literature for that particular method.

Cajal's silver method produced results that were variable within each block of tissue but in every case there was a granular argyrophilia noticeable in thyroid C cells. Some blocks of tissue were over-impregnated in that the thyroglobulin and follicular cells were dark brown (Fig.18) which indicated that considerable silver had been deposited in these structures. Silver was also deposited in the apical region of the follicular cells. In those blocks in which impregnation was not as heavy, the apical regions of follicular cells usually contained aggregates of granular silver deposit (Fig. 19). The deposition of silver in C cells was in the form of coarse granules throughout the cell cytoplasm; some C cells contained hardly any silver granules while in others the content of such granules was high (Fig. 19).

TABLE XI - A semi-quantitative assessment of the granular metallophilia in the C cells of the canine thyroid gland under different conditions of silver impregnation

Method	Evaluation of Metallophilia
Cajal's method (1.5% aqueous silver nitrate pH 6.1)	+/++/+++
Masson-Fontana (ammoniacal silver)	-
Mitcheli and Wislocki's method (pre-oxidation, aqueous silver nitrate, silver diamine)	-
Grimelius (0.03% buffered silver nitrate)	
pH 5.5	+++
4.0	+
4.5	+
5.0	++
5.5	++++
6.0	+++
6.5	++

+/++++ = subjective assessment of granular metallophilia

- ve = no granular metallophilia

Each method is assessed against an optimal reaction which is described in the literature for that particular method; the evaluations are not comparable with one another.

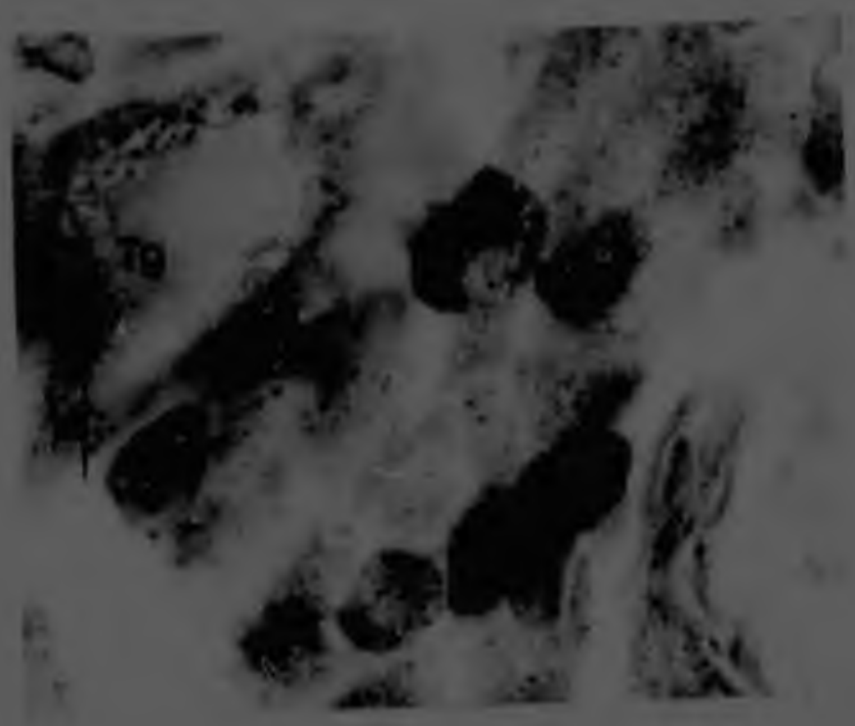

Fig. 18 - Prominent argyrophilic granules in canine C cells; some argyrophilic granules in follicular cells (arrow) and some non-specific silver uptake by thyroglobulin (Tg). Alcohol fixation. Cajal's silver impregnation. X1200

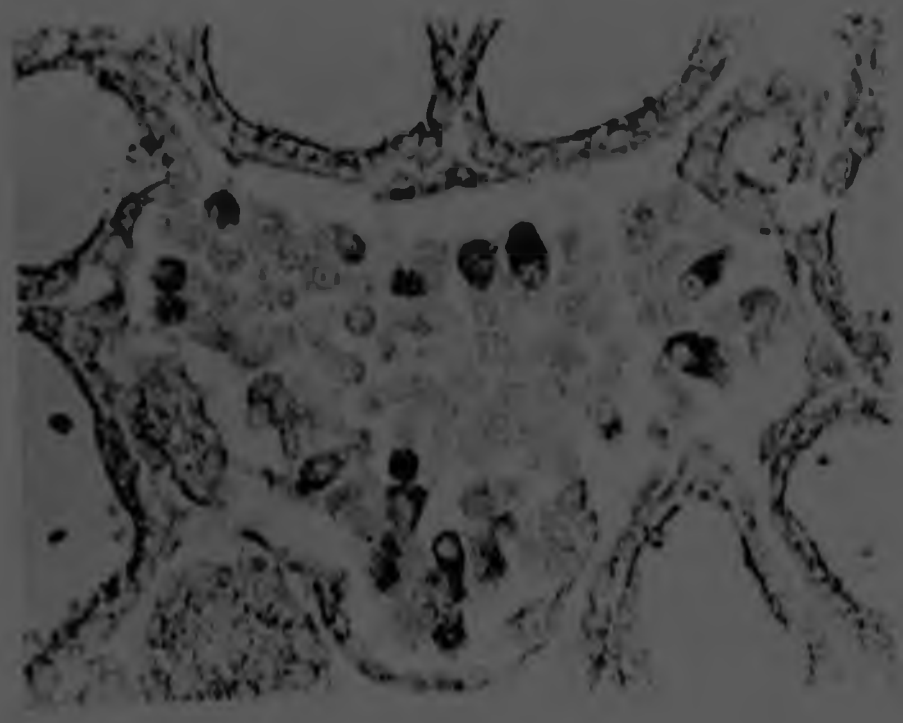

Fig. 19 - Argyrophilic granules in the apical region of follicular cells and in some C cells. Alcohol fixation. Cajal's silver impregnation. X720

No other cell structures except the nucleolus and the outline of the nuclear membrane were impregnated with silver in the C cell.

The Masson-Fontana impregnation method produced no metallophilia in the C cells. The silver method of Mitchell and Wislocki (which includes pre-oxidation) likewise produced no impregnation of C cells even though the reticulin fibres were demonstrated (Fig. 20). These fibres formed a loose network around clusters of C cells and follicles. This method which is claimed to demonstrate glycogen (Mitchell and Wislocki, 1944), did not stain areas within follicular cells which are known to be rich in glycoproteins.

The Grimelius method produced a marked granular argyrophilia in C cells (Fig. 21). There was minimal silver deposition on the follicular cells which were a faint brown colour in comparison with C cells. The effect on pH on silver deposition is such that lowering the pH to 4 or raising it above 6.5 markedly diminished argyrophilia.

4.3.3 Discussion

Three features are evident from the results : firstly, that a silver impregnation method with preceding oxidation of tissue sections did not demonstrate argyrophilia in C cells; secondly, that ammoniacal silver without exogenous reduction is not suitable for demonstrating metallophilia in thyroid C cells and thirdly, that pH of silver solutions markedly affects the deposition of silver in C cells.

The significance of oxidation in the production of argyrophilia has been studied in some detail by Lillie (1954) and Velican and Velican (1972). They studied impregnation methods in which silver deposition failed to occur if there is no prior oxidation. Velican and Velican (1972) favour the view that the production of aldehydes, following oxidation, is

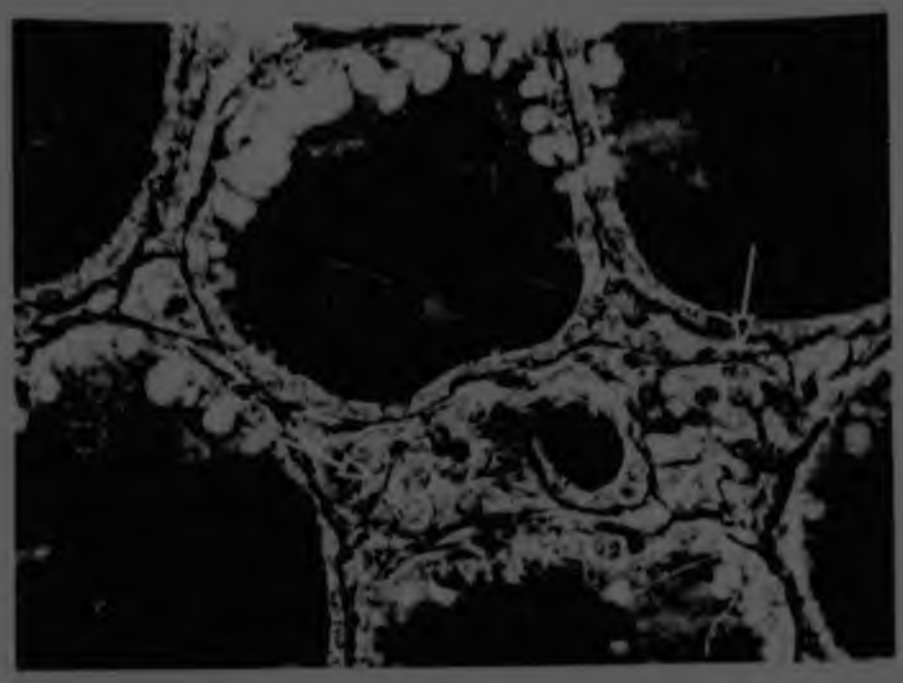

Fig. 20 - C cells (arrows) are not argyrophilic with the silver impregnation method of Mitchell and Wislocki; reticulin fibres are well shown. Formol saline fixation. Mitchell and Wislocki silver impregnation and carmalum counterstain. X540

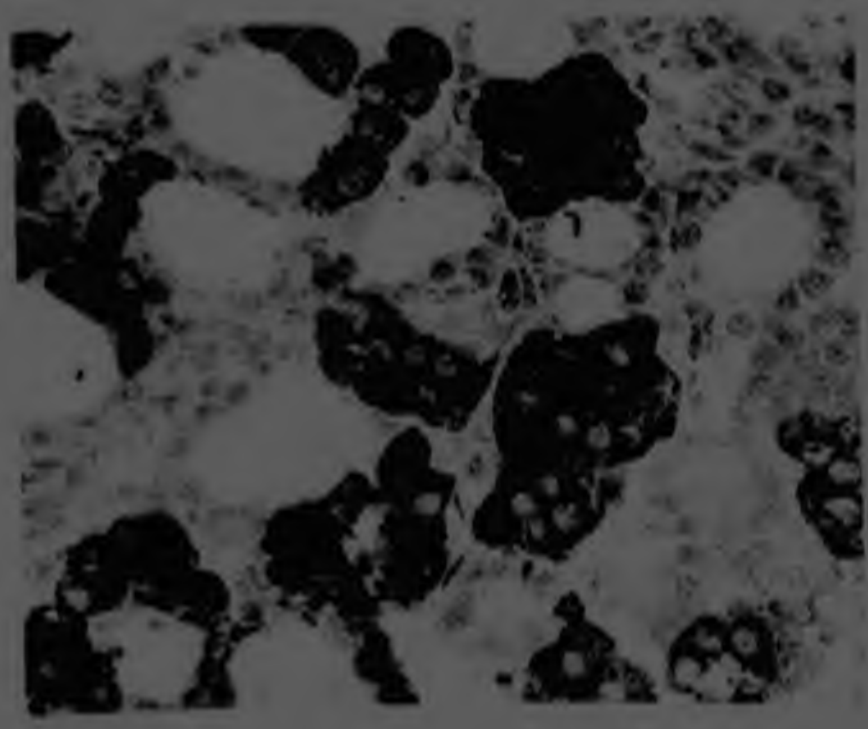

Fig. 21 - Argyrophilic granules in canine C cells. GPA fixation. Grimelius silver impregnation. X360

responsible for silver attachment to reticulin fibres and they provide cytochemical evidence that these groups are involved. However, the study of Lillie, which comprises a comparison of silver impregnation with the PAS reaction (which depends on aldehydes produced by oxidation, for a reaction) in a multitude of tissues indicates that silver deposition does not occur at all sites where aldehydes are so produced. It has already been shown (Section 3.5) that aldehydes are produced in the cytoplasm of canine C cells by oxidation with periodic acid. The present observations (of production of aldehydes but no subsequent deposition of silver) are similar to those of Lillie who however, studied nervous tissue, connective tissue, liver and thyroid but not thyroid C cells. It therefore seems to me that silver impregnation, following oxidation, probably indicates sites of aldehyde formation but that another factor or factors is/are in addition required before silver can be deposited at certain sites where aldehydes are present. What these 'other factors' are is not known and these do not seem to be present in the thyroid C cell.

Optimal argyrophilia with the Grimelius impregnation occurs at pH 5.5. The charge dependency of silver attachment draws attention to those amino acid groups which are ionized at pH 5.5. These are beta-carboxyl (pK = 3.65), gamma-carboxyl (pK = 4.25) and imidazole (pK = 6.0) (Pearse, 1968, p.115). The first two side-groups do not react chemically with silver whereas a reaction of imidazole with silver was suggested by Peters (1955). No supporting evidence can be found in the literature for such a cytochemical or biochemical reaction. A factor mitigating against the involvement of silver with imidazole is that, biochemically, silver salts precipitate with histidine (the reactive group of which is imidazole) at a more alkaline pH, i.e. above pH 5.5 (Dunn and Roekland, 1951).

Another possibility is that silver at a pH of 5.5 may react with

disulphides of calcitonin. The reasons why I suggest that such a cytochemical reaction may occur are derived from experimental work of biochemists. Cecil and McPhee (1957) have shown that at pH 5.7 silver ions may form silver mercaptides with disulphides (Reaction 1). Furthermore, silver has been used to induce an electrophilic cleavage of the disulphide bonds of glutathione (Calam and Waley, 1962) in acetate buffer at pH 6.1.

Reaction 1

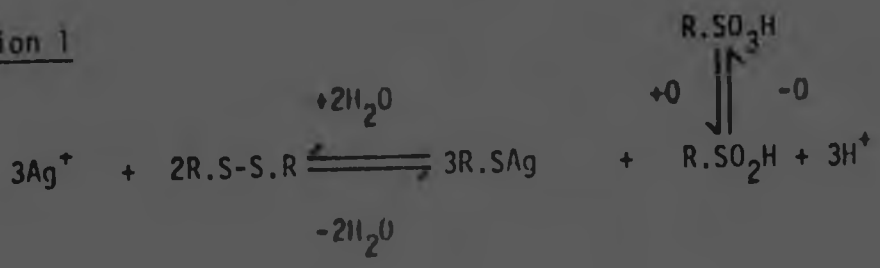

The above biochemical reactions were performed under conditions very similar to those under which silver impregnation occurs in the C cell i.e. acetate buffer pH 5.7 and 6.1 as compared with acetate buffer pH at 5.5. The silver mercaptide forming from cleavage of disulphide, may constitute part of the 'silver nuclei' which were mentioned in Section 4.1.2. Two observations can be put forward in line with my view that silver reacts with the disulphides in the C cells - (1) disulphide groups, in significant amounts, have already been shown in the canine cell (Section 3.4); (2) cytochemical work on keratin and hair (Lillie, 1954; Swift,1968) has revealed that silver has a predilection for sites with a high concentration of disulphide groups. Swift (1973) has provided further evidence that silver reacts with disulphide groups of hair.

Arguments against the reaction of disulphides with silver in C cells are as follows :

(1) Impregnation of hair and keratin is usually undertaken with silver methenamine and not with buffered silver nitrate (as in Grimelius method). The methenamine reaction is performed at alkaline

conditions and the Grimelius reaction is performed at pH 5.5. Even though biochemical cleavage of disulphides is usually done at an alkaline pH (Jocelyn, 1972) this can also be undertaken under mild acid conditions as has been mentioned above. My view is that disulphides of calcitonin would not be cleaved under alkaline conditions as calcitonin is an acidic protein and its ionic charge would hinder dissociation of disulphides under alkaline conditions.

(2) Disulphides in other polypeptides, for example insulin (found in beta cells of the pancreas) and thyroglobulin, are unreactive with silver. The disulphides of insulin form interchain links which are contained within a crystalline lattice work and it seems that they are inaccessible to silver because of steric hindrance. Thyroid colloid may react with silver (Lillie, 1954) but only under alkaline conditions and then if no oxidation is applied. Whether disulphides of colloid are responsible for argyrophilia is not known.

In conclusion it seems that the uptake of silver can be ascribed to several reactive protein groups but that the silver uptake depends on the conditions of impregnation (i.e. oxidation, pH, endogenous or exogenous reduction) and the conformation of polypeptides containing the reactive chemical groups within cells. The reaction of disulphides and proteins is evaluated further in the next section.

4.4. Oxidation, alteration of protein groups and silver impregnation

4.4.1 Material and methods

The argyrophilia produced by the Grimelius silver method was analyzed to see if it is mediated by disulphides or other protein groups. For

this purpose all the thyroid tissue of a dog was fixed in GPA. A number of serial sections was cut from blocks obtained from this thyroid gland. For the silver impregnation alternate consecutive sections were utilized as controls to localize C cells. For the aldehyde fuchsin reaction, which was used for comparison with the silver impregnation method, tissue blocks were freeze-dried and fixed in formalin vapour.

Sections were initially exposed to one of the following :

(1) 0.5 per cent H_2SO_4 — potassium permanganate oxidation for 5, 10, 30 and 60 min (Landing et al., 1956).

(2) 1 per cent periodic acid (pH 2.5) oxidation for 10 min, 30 min, 2 h, 4 h, at 22°C.

(3) Acetylation in 1:1 acetic anhydride/pyridine at 60°C for 30 min (mild), 1 h, 2 h and 4 h (drastic) (McManus and Cason, 1950).

(4) Acetylation both mild and drastic followed by saponification in 0.1N KOH for 15 min.

(5) Sulphydryl block with 0.1M N-ethyl maleimide at pH 7.4 for 4 h at 37°C (Pearse, 1968a). This procedure was also carried out on sections previously oxidized with one per cent periodic acid for 10 min and 4 h.

The aldehyde fuchsin reaction was carried out as previously (Section 3.4) except that oxidation was with periodic acid as in (3) above.

The oxidation procedures used were chosen because of the biochemically known effects that strong and mild oxidants have on protein and amino acids (Toennis, 1942; Sanger, 1945, 1960, Hake, 1965; Clamp and Hough, 1965; Hirs, 1967 and Pearse, 1968a, p.314). The aldehyde fuchsin reaction was selected for a comparison with silver impregnation and as an indicator of the effects of oxidation on disulphides, a chemical group on which this stain is dependent for a positive result (Section 3.4).

4.4.2 Results

The results, assessed subjectively and semi-quantitatively are given in Table XII. Oxidation with acidified potassium permanganate inhibited silver impregnation of thyroid C cells as well as that of epithelial cells. The same oxidation procedure induced an intense staining reaction with aldehyde fuchsin in C cells as described previously.

Periodic acid, an oxidant milder than acidified permanganate, gradually diminished the amount of silver attachment to tissue sections. Decreased argyrophilia was noted as either fewer argyrophilic granules (Fig. 22) in C cells or by a failure of some cells to accumulate any silver. Ten minute oxidation with periodic acid did not induce a positive aldehyde fuchsin stain in C cells but after 2 hours' oxidation, a positive reaction was observed. After four hours of oxidation aldehyde fuchsin clearly stained all C cells. On the other hand after this period of oxidation silver impregnation was abolished.

Mild acetylation completely inhibited silver impregnation in thyroid C cells; alkaline saponification restored the capability of silver to be deposited but after saponification argyrophilia was less intense than previously. Following drastic acetylation no argyrophilia was observed.

N-ethyl maleimide did not block silver impregnation.

Table XII/..

TABLE XII - The results of oxidation and end-group modification on the granular argyrophilia and aldehyde fuchsin staining of canine thyroid C cells

Procedure	Grimelius	Aldehyde Fuchsin
no oxidation (control)	+++	-
H_2SO_4/permanganate 10 min and longer	-	+++
1.0% periodic acid		
10 min	+++	-
30 min	+	+
2 hr	+	++
4 hr	-	+++
acetylation (mild and drastic)	-	
acetylation and alkaline saponification		
mild acetylation	++	
drastic acetylation	- or ±	
N-ethylmaleimide	+++	

-/±/+/++/+++ - subjective assessment of argyrophilia

\- = no reaction

+++ = optimal reaction

blank = not performed

These results are comparable with each other.



Fig. 22 - Several C cells (arrows) show decreased density of cytoplasmic granules contrasted with controls (not shown but see Fig. 21). GPA fixation, Grimelius silver impregnation after 1.0 per cent periodic acid oxidation. X640

4.4.3 Discussion

Strong oxidants, of which acidified permanganate and performic acid are examples, readily oxidize specific amino acids in polypeptides without disrupting their peptide linkages. Performic acid readily oxidizes cystine, methionine and tryptophan in intact protein such as casein and insulin (Toennis, 1942; Sanger, 1949) and permanganate oxidation (for 10 min) oxidizes half-cystine, cysteine, methionine, tryptophan and tyrosine (Hake, 1965). In the latter study amino acids were tested separately and were not contained in a polypeptide chain. Thus strong oxidants in three separate studies have been shown to oxidize the same amino acids. It is therefore reasonable to assume that in C cells acidified permanganate oxidizes the same amino acids, namely cystine, cysteine and methionine as well as tryptophan and tyrosine. The oxidation products of cystine and cysteine are sulphinic ($R.SO_2H$) and sulphonic ($R.SO_3H$) acid and that of methionine is a sulphone (Hirs, 1967). The former acidic groups have been implicated in the staining by aldehyde fuchsin (Section 3.4.3). The evidence for this mechanism of staining has been discussed. From the observations now presented, it seems possible that argyrophilia is inhibited by strong oxidants because disulphide groups, which are converted to sulphonic acid, are no longer available for mercaptide formation with silver.

The weaker oxidizing agent, periodic acid, rapidly oxidizes vicinal hydroxyl groups to form aldehydes (within 10 minutes) but oxidation of amino acids especially disulphides of cystine, is known to take several hours (Lillie, et al., 1954; Clamp and Hough, 1965). Periodic acid is capable of oxidizing test tube samples of cystine, cysteine, tyrosine, tryptophan, histidine and methionine. The slow oxidation rate is demonstrated by the following example : after 6 hours, cystine consumes

0.78 mole of periodic acid while after 28 hours 2.2 moles of periodic acid are consumed (Clamp and Hough, 1965). Although the times of exposure that I used on tissue sections in this study are not as long as the exposure of test tube samples to periodic acid by Clamp and Hough, it seems that gradual oxidation of amino acids may be responsible for decreased argyrophilia. When contained within a polypeptide, those amino acids that could be oxidized by periodic acid in test tubes, were found to be cystine, methionine, tryptophan, tyrosine and histidine (Clamp and Hough, 1965). It is therefore these amino acids that require further consideration.

I have not been able to demonstrate tyrosine and tryptophan, cytochemically in canine C cells (Section 3.4). Lillie et al.(1954) showed that cysteine and cystine can both be oxidized by periodic acid. The times he used to achieve complete oxidation are almost identical to the times used in the present study, that is 2 hour oxidation with periodic acid. This produced sulphonic acid from disulphides as reflected in basophilia that developed in tissue sections. Lillie also compared the oxidation times that are required for the production of sulphonic acids by permanganate and by periodic acid and found that 10 minutes are required by the former strong oxidant and 2 hours by the latter weak oxidant. The present oxidation times add support to the view that it is the formation of sulphonic acid which inhibits attachment of the metal. The remaining amino acids that are oxidized by , namely histidine and methionine, were considered when selecting the present experimental procedures. Histidine is not oxidized by brief permanganate oxidation (Hake, 1965) and I therefore do not think that it contributes to silver attachment in C cells. Unfortunately there is no method of blocking this amino acid without affecting disulphide groups as well. The affinity of silver for

methionine depends on its -SH group (Jocelyn, 1972, p.57) but blockade of this group did not alter the argyrophilia. It is doubtful, however, whether the -SH group is of cytochemical importance in silver impregnation as Cecil (1963) has shown that the methionine (-SH) side chain in intact protein is not accessible to analysis with heavy metals.

Both mild and drastic acetylation abolish silver attachment and in the former case alkali saponification partially restores this ability. Drastic acetylation probably extracts cytoplasmic constituents of cells. This probably explains the failure to restore argyrophilia with saponification after drastic acetylation. Many chemical groups in tissue may be acetylated (or esterified) e.g. aldehydes, glycols, disulphides, hydroxy-amino and carboxyl groups. Disulphides form diacetyl esters and these have been shown by Cecil and McPhee (1957) to be unreactive with silver nitrate. Both cell membranes and thyroglobulin are rich in glycols, hydroxy-amino and carboxyl groups but they demonstrate no intense argyrophilia. On this basis these chemical groups may be excluded as high affinity sites for silver attachment in canine C cells.

4.5 Conclusions

(1) Argyrophilia of thyroid C cells depends upon pH; optimal impregnation occurs at a slightly acid pH and not at an alkaline pH.

(2) Oxidation preceding silver impregnation, does not enhance argyrophilia but reduces the affinity of structures in the C cell for silver nitrate.

(3) Ammoniacal silver without exogenous reduction is not suitable for silver impregnation of canine C cells.

(4) Considerable indirect evidence supports the view that argyrophilia in C cells depends upon disulphide groups. Such evidence is provided by the results of acetylation as well as results of strong and weak oxidation with the aldehyde fuchsin reaction. It is suggested that silver nitrate and disulphides react in C cells to form silver mercaptide which then induces argyrophilia. Furthermore it is suggested that sulphonic acid, formed from disulphides by oxidation, prevents silver mercaptide formation and therefore argyrophilia.

5. C CELLS OF THE NORMAL HUMAN THYROID GLAND

5.1 Introduction

Medullary carcinoma is a malignant growth of the thyroid gland the source of which was postulated, in 1966, to be the C cell (Williams, 1966). My interest in this premise was aroused when encountering a patient with medullary carcinoma in clinical practice in 1968. A cursory search of the literature then did not bring out much information about the micro-anatomical features of this cell type in normal human glands. Indeed some authors ascribed C cells to histological artefact and denied their existence as a definite cell structure in the thyroid gland (Ludwig, 1954). However, a brief remark by Solcia and Sampietro (1968) that human thyroid glands did contain demonstrable C cells prompted me to embark on the present study.

There were several problems to contend with before commencing a light microscopic study of these cells. Firstly, C cells require special staining procedures to demonstrate their presence, and some methods which were introduced between 1968-1969 by Solcia et al. (1968, 1969) and Grimelius (1968a) required assessment as to their usefulness in demonstrating C cells in animals including man. Secondly, there was confusion about the types of cells contained in the thyroid gland of man - the identity of the C cell, a well-established cell type in canine glands, had not been convincingly shown in human thyroids and conversely cells analogous to the oxyphil cells of the human gland could not be identified in canine material. These two issues resulted in misrepresentations and use of erroneous nomenclature. To obtain clarity about the cell types in human thyroid glands and to decide upon acceptable terminology, a brief historical review of the literature on C cells was undertaken.

5.2 Terminology of human thyroid cells and historical background

Calcitonin-producing cells in animals are known by 17 different terms (Table 1, Section 1.4). However, the most common appellations employed are parafollicular cell (Nonidez, 1932) and C cell (Pearse, 1966). The latter term is preferred to that of 'parafollicular cell' because these cells are not always in a parafollicular position a d may furthermore be found outside the thyroid, unrelated to follicles (Kameda, 1970).

The first tentative description of human C cells was given by Sandritter in 1954. Since then they have been shown in normal neonatal and adult thyroid glands and in ultimo-branchial bodies (UBB's) in human foetuses by Kalina et al. (1970), Teitelbaum et al. (1971), Chan and Conen (1971), Roediger (1973) (Section 5.6 of this study), Wolfe et al. (1974) and McMillan et al. (1974) and in pathologic thyroid glands by Solcia et al. (1970), Kracht et al. (1970, Ljungberg (1972), Englund (1972), Tateishi et al. (1972) and Lillis and Balogh (1973).

It is noteworthy that with the exception of my own study (Roediger, 1973) and those of Wolfe et al. (1974) none of the above workers concerned themselves with the distribution of C cells in the thyroid gland but rather aimed at identifying C cells and confirming their existence in human tissue.

Apart from follicular cells and C cells, the human thyroid contains cells termed oxyphil cells. The oxyphil cell was first observed by Askanazy in 1898 in cases of primary thyrotoxicosis in which they were described as large-bodied cells with eosinophilic cytoplasm.

The term 'oxyphil cell' was introduced by Welsh in 1898 to describe cells in the human parathyroid gland. This usage was thereafter adopted by Eisenberg and Wallerstein (1932) to refer to a morphologically similar cell in the thyroid gland; this cell is the same as Askanazy had observed previously. The oxyphil cell of the thyroid was also given the designation

'oncocyte' by Hamperl in 1937. The oxyphil cell is frequently found in pathological thyroid glands and the term has, like 'C cell' several synonyms (Table 1, Section 1.4).

Unfortunately Ewing in 1919 introduced the misnomer of 'Hürthle cell' for the thyroid oxyphil cell in man, when in reality Hürthle had described the canine cell now called the C cell. This error led Hamperl (1962) to lodge a vigorous appeal against the term Hürthle cell which, despite this appeal, is still frequently used in the literature.

The oxyphil cell is found in 15 per cent of normal adult thyroid glands and in 50 per cent of toxic thyroid adenomas (Lennox, 1948). The opinion that oxyphil cells are derived from follicular cells has been expressed by Hamperl (1962), Tremblay (1969) and Heimann et al. (1973) on the reasoning that numerous transitional forms between follicular and oxyphil cells are found within the same gland. Beskid and Kobuszewska-Faryna (1972) who base their conclusions on cytochemical findings in oxyphil cells (toluidine blue metachromasia, phospholipid and enzyme content), have suggested that oxyphil cells are derived from C cells. Indeed several cytochemical properties of C and oxyphil cells are similar (Table XVII, Section 5.6.4); however, assay of oxyphil tumour extracts show that oxyphil cells under such conditions conform, both enzymatically and biochemically, to follicular cells (Heimann et al., 1973).

A working description of the oxyphil cell is as follows: it is a polygonal cell, large-bodied in comparison to follicular or to C cells: It has a granular acidophilic cytoplasm that contains numerous mitochondria; it has a large nucleus and may be binucleate (Roediger, 1975).

The evidence that is now available therefore indicates the presence of three, clearly, definable cell types in the normal thyroid gland: (a) follicular or acinar cells, (b) oxyphil cells and (c) C cells.

5.3 Choice of material

Tissue from human thyroid gland is not easily obtainable. Three avenues were considered for obtaining such tissue in a fresh enough state unaltered by post mortem autolysis. These were (1) thyroid glands immediately obtained from cadavers from which kidneys had been used for transplantation purposes, (2) glandular tissue which was obtained from surgical resections and (3) thyroid glands from 'fresh' still-born neonates, i.e. neonates that died during childbirth as a result of one or other pathological condition. material from the first source was obtainable as permission to remove glands was not granted by the head of the Transplant Unit and the magistrate controlling the medico-legal aspects of tissue donation. An attempt was made to use thyroidectomy specimens freshly obtained from the operating theatre. Despite a careful search no C cells were convincingly demonstrated in two such specimens. Possible explanations are (a) gross distortion of normal anatomy by pathological processes, (e.g. compression of thyroid tissue); (b) the age of the patients which were op rated on was in the fourth-fifth decad when C cells may not be as active as in younger patients; and (c) only the anterior third of each lobe was obtained. Total lobectomy specimens of thyroid gland are not easily obtained, when they were obtainable, they were infiltrated with tumour growth.

Due to the above circumstances I decided to use human neonatal thyroids because whole glands could be obtained. Thus the distribution of cells could be studied throughout the gland and furthermore tissues would not be distorted by surgical intervention or abnormal growths.

A source of neonatal material was available at the Obstetrical Unit, Baragwanath Hospital. Written permission to collect material was

obtained from Dr. Faivelsohn, Superintendent, Baragwanath Hospital (Addendum A), to collect post mortem thyroid tissue from six still-born infants. Parental consent to perform post mortem thyroidectomies was also obtained. The glands were collected between October, 1970 and January, 1971.

Considerable evidence accumulated during 1971 to indicate that the use of neonatal tissue was advantageous for the study of C cells. Kalina et al. (1970) presented a report on immunofluorescent identification of C cells in human neonatal thyroid glands and stated that these cells were identifiable by studying their enzyme content. Tashjian et al.(1972) reported that prenatal and neonatal thyroid tissue in humans contained measurable amounts of immunoreactive calcitonin and that levels were very high in embryonic tissue in UBB's. Chan and Conen (1971) showed that human UBB's contain cells which resemble C cells and that these C cells have numerous secretory granules. Finally, indirect evidence indicated that material from young animals was more suitable than that of older ones - calcitonin levels in peripheral plasma were found to be much higher in young animals (calves) than mature adults (cows) (Hackeng and Schopman, 1971), a point which may indicate that C cells are metabolically more active at a younger age. Welsch (1971, 1972) studied the UBB and thyroid glands of various mammals and found in comparison with adults that C cells were readily identifiable in foetuses (almost full-term) and that these cells are active at birth.

The decision to use neonatal thyroid gland was fortunate and as ultimately shown, a correct one.

5.4 Choice of methods of study

The realisation that human C cells are difficult to find in tissue sections dictated the use of those stains which readily and clearly discriminate C

from follicular cells. The following methods were therefore chosen : (1) silver impregnation (Cajal; Grimelius), (2) aldehyde fuchsin after oxidation and (3) demonstration of 'masked metachromasia' (these methods are described in Sections 3.4.1 and 4.3.1).

An additional method whereby human C cells could possibly be distinguished was the demonstration of intra-cellular enzymes. Certain enzymes, as will be discussed in the next paragraph, are found in large amounts in C, but not follicular, cells.

As early as 1957, Pepler and Pearse showed C cells of rats to contain high levels of non-specific cholinesterase but at that time they did not realise that the C cell was an entity distinct and separate from follicular cells. Hydrolases of human thyroids were investigated by Tremblay and Pearse (1960) but again their studi ' not take cognizance of C cells. The experience gained from the above enzyme studies was later used by Foster et al. (1964a), working with Pearse, to analyze enzymes in canine C cells; Pearse (1966) thereafter published his own results on canine thyroids and encouraged Carvalheira (1967) and Welsch (1968, 1969) to extend these observations. In essence the results of the above studies showed that thyroid C cells had a high content of dehydrogenases (alpha-glycerophosphate dehydrogenase, NADH dehydrogenase) and hydrolases (non-specific esterases and cholinesterases) and furthermore that the cellular content of these enzymes altered with calcium infusion but not after administration of thiouracil. These cellular enzymes are a suitable means for distinguishing C from follicular cells and I therefore decided to use this method of study on human thyroid tissue. Before embarking on this study the methods were tested on canine glands, firstly because the results in this laboratory animal were well-known and secondly because fresh tissue was readily available.

5.5 Enzyme demonstration of C cells in canine thyroids

5.5.1 Introduction

As the intention was not to systematise the analysis of enzymes but to identify C cells amongst follicular cells, only enzymes which are known to be found in canine thyroid C cells were selected for study.

(A systematic study of cellular enzymes would entail an analysis based on either their metabolic significance or on the subcellular structure within which they are found, e.g. enzymes of glycolysis, glycogenesis, the Krebs cycle, phosphorylation, the pentose cycle, glycerol metabolism and protein metabolism or the study of enzymes in mitochondria, microsomes, membranes, lysosomes and endoplasmic reticulum.)

The choice fell on (1) dehydrogenases (a) alpha-glycerophosphate dehydrogenase (∝GPDH) and (b) NADH tetrazolium reductase, and (2) the hydrolases of which the following were selected (a) alkaline phosphatase, (b) acid phosphatase, (c) non-specific esterases and (d) cholinesterase.

5.5.2 Material and tissue preparation

Six thyroid glands were obtained from young dogs (D4 - D6 and D10 - D12 in Table III) of both sexes. The thyroid gland was freshly removed as previously outlined, cut into small pieces approximately 0.5 cm^3. These were placed on a circular disc of cork in a drop of water and the cork with the tissue slowly immersed in liquid nitrogen or in hexane cooled in alcohol to -70°C. Once the tissue was frozen it was stored on dry ice in a deep freeze (-17°C). Tissues were sectioned on a Pearse-Slee cryostat (-16°C) at 8µm and sections mounted on glass cover slips. Post-fixation was performed in formalin-saline or GPA for periods of 15 minutes to one hour. Several tissue blocks were fixed in Pearson's fixative (Pearson, 1963) at 4°C for 12 hours and then quenched in liquid nitrogen for cryostat sectioning.

5.5.3 Methods

Alpha-glycerophosphate dehydrogenase Demonstration of this enzyme is based on the reduction of a colourless tetrazolium salt and simultaneous chelation to form a visible formazan deposit. The method of Nachlas et al. (1957) as modified by Hess et al. (1958) was used. Monotetrazolium bromide (MTT) was employed as hydrogen acceptor (Pearse, 1960) with subsequent cobalt chelation of the formazan. In order to facilitate the reduction of tetrazolium salt to formazan, menadione (menaphthone) was added as co-factor according to the method of Wattenburg and Leong (1960).

NADH tetrazolium reductase (NAD diaphorase) The method of Scarpelli et al. (1958) was used except that monotetrazolium bromide (MTT) was used as a hydrogen acceptor (Pearse, 1960) instead of ditetrazolium chloride-BT (NBT).

Acid phosphatase (non-specific) An azo dye-coupling method using the diazonium salt, fast garnet G.B.C. (Grogg and Pearse, 1952) and sodium αnaphthyl phosphate as substrate (Barka, 1960) was employed. The reaction was carried out at pH 5.0.

Alkaline phosphatase An azo dye-coupling method (Gomori, 1952) was used with sodium αnaphthyl phosphate as substrate. The diazonium salt was fast red T.R. The reaction was carried out at pH of 9.2.

Non-specific esterase Several substrates are available for demonstrating these esterases (Table XIII) and, of these, two were selected. The method of Burstone (1957) was employed using a naphthol ester (naphthol AS-LC acetate) and the diazonium salt fast garnet G.B.C. for coupling. The second method used, that of Holt (1954) and Holt and Withers (1958), employs an indoxylic ester (5-bromo-4-chlorindoxyl acetate) and depends on an oxidation step for the development of an indigo dye at the site of enzymes in the cell.

TABLE XIII - Substrates suitable for demonstrating simple esterases (a) non-specific and (b) specific esterases

	ester substrate	type	identification
(a)	naphthol AS-LC acetate naphthol AS-D acetate naphthol AS cloroacetate	naphthol ester	hexazonium or diazonium coupling
	5-bromindoxyl acetate 5-bromo-4-chloroindoxyl	indoxylic ester	oxidation to indigo dye
	beta naphthyl acetated alpha naphthyl acetate alpha naphthyl propionate	naphthyl ester	hexazonium or diazonium coupling
(b)	acetylthiocholine iodide butyrlthiocholine iodide myristoyl choline	thiocholine ester	copper thiocholine conversion to copper sulphide

Collated from (1) Burstone (1954)

(2) Holt and Withers (1958)

(3) Barka and Anderson (1963)

(4) Dixon and Webb (1964)

(5) Pearse (1968a,1972)

Specific esterase; cholinesterases. The method of Gerebtzoff (1953) was applied to tissue fixed in Pearson's fixative. Acetyl and butyrylthiocholine iodide were used as substrates (Table XIII). Tissue sections were exposed to the substrate for 12 hours at pH 6.8.

5.5.4 Results

The dehydrogenase content found in the follicular and C cells of young dogs was not unlike that obtained by Foster et al. (1964a) and Pearse (1966) in their young dogs.

αGPDH content of C cells was very high (Fig. 23). The formazan deposit, indicating dehydrogenase activity, was dense. In contrast, the follicular cells revealed a much lesser amount of this enzyme distributed throughout the cytoplasm, but in some follicules the granules aggregated along the apical borders.

The demonstration of αGPDH and NADH reductase was technically satisfactory and no extra-cellular enzyme was observed which would have indicated seepage into the surrounding tissue.

The distribution of NADH reductase in follicular and C cells was similar to that of αGPDH - a high content in the latter cells, and little in the follicular cells (Fig. 24).

Acid phosphatase visualization in C and follicular cells was technically very good. The greatest activity of enzyme was found in some follicular cells (Fig. 25); others revealed virtually none. The C cells showed moderate activity but could not be clearly distinguished from follicular cells on the basis of their enzyme content. Acid phosphatase activity was evenly distributed throughout the cell cytoplasm and not concentrated along the cell borders.

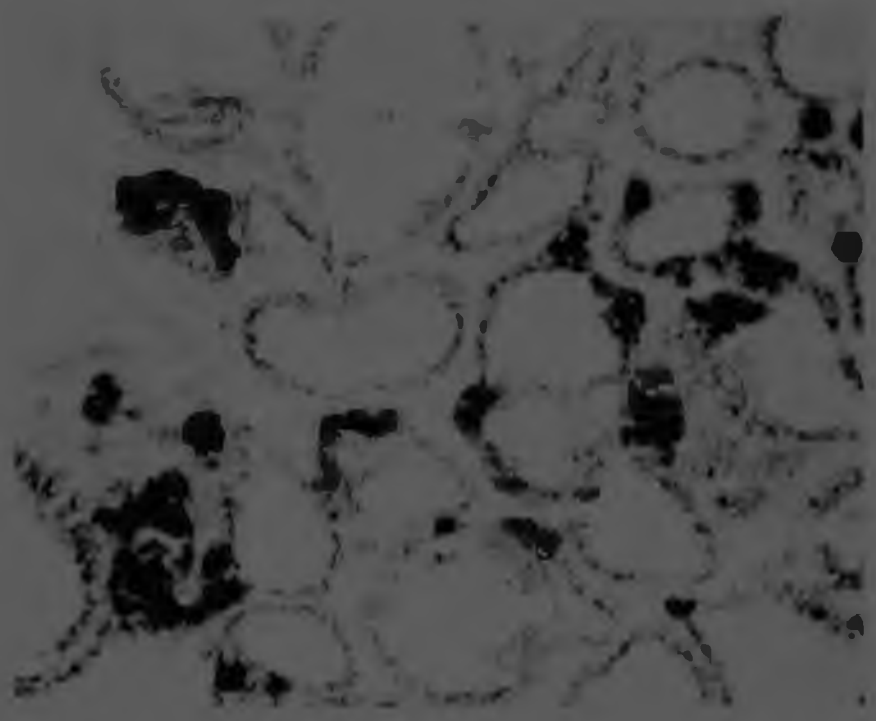

Fig. 23 - A high content of α GPDH in canine C cells and a lesser amount in follicular cells. Cryostat section, formol saline fixation. X 240



Fig. 24 - Content of NADH tetrazolium reductase is high in C cells but less in follicular cells. Cryostat section, formol saline. X240

The alkaline phosphatase activity was hardly detectable in some C cells; it was absent from most cells. This contrasted markedly with the activity in the cells lining capillaries and small arterioles, in which a high content of this enzyme was noticed. Follicular cells showed a faint stain indicating very small amount of enzyme activity.

The naphthol ester method for demonstrating non-specific esterase failed to show any reaction in thyroid tissue but the indoxyl ester method proved efficacious. A blue-indigo dye develops at the site of enzymatic activity which is displayed in a granular form (Fig. 26). Dye diffusion, however, occurs from these granules and spreads throughout the cytoplasm of cells in which the enzyme is contained. The non-specific esterase activity of C cells is very noticeable with more granules per cell than in the follicular cells. Unfortunately diffusion of the blue dye is very marked in both follicular and C cells with the result that this enzyme method is not very suitable for differentiating the two cell types from each other.

The cholinesterase method was carried out at pH 6.8.(Gerebztoff uses this pH if the cholinesterase content of structures is low.) Incubation time was increased to 12 hours instead of the recommended 15-60 minutes. With these modifications excellent visualization of cholinesterases was obtained in C cells (Fig. 27). The final insoluble sulphide product was densely aggregated throughout the cytoplasm of C cells; in several cells it was noted to be along the cell borders. All C cells showed enzyme activity but no cholinesterase activity was observed in follicular cells.

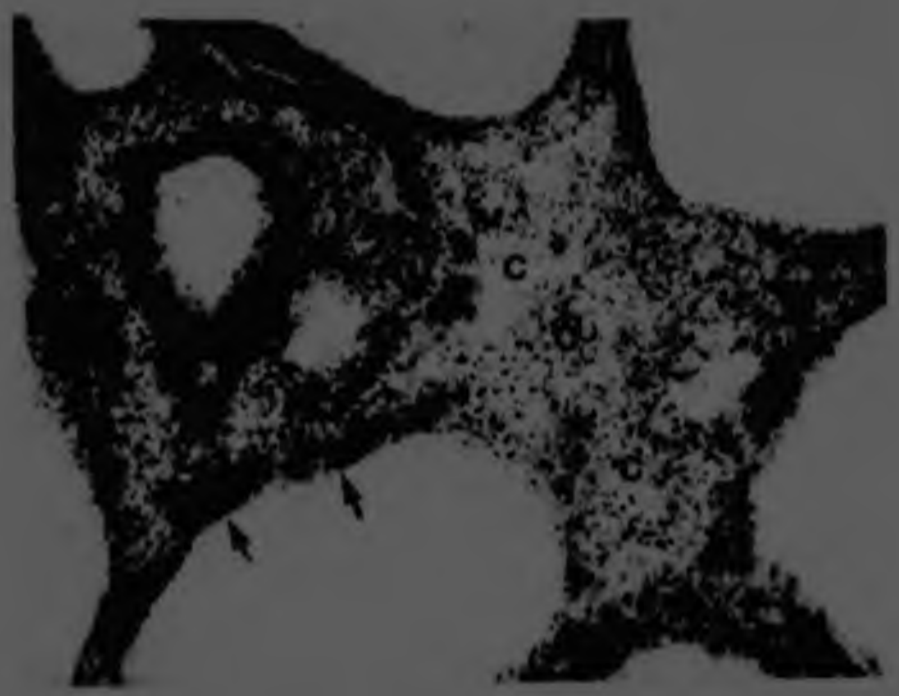

Fig. 25 - Acid phosphatase in follicular and C cells (C). Enzyme content is high in some follicular cells (arrows). Cryostat section, formol saline fixation. Azo dye-coupling with Fast Garnet G.B.C. X960

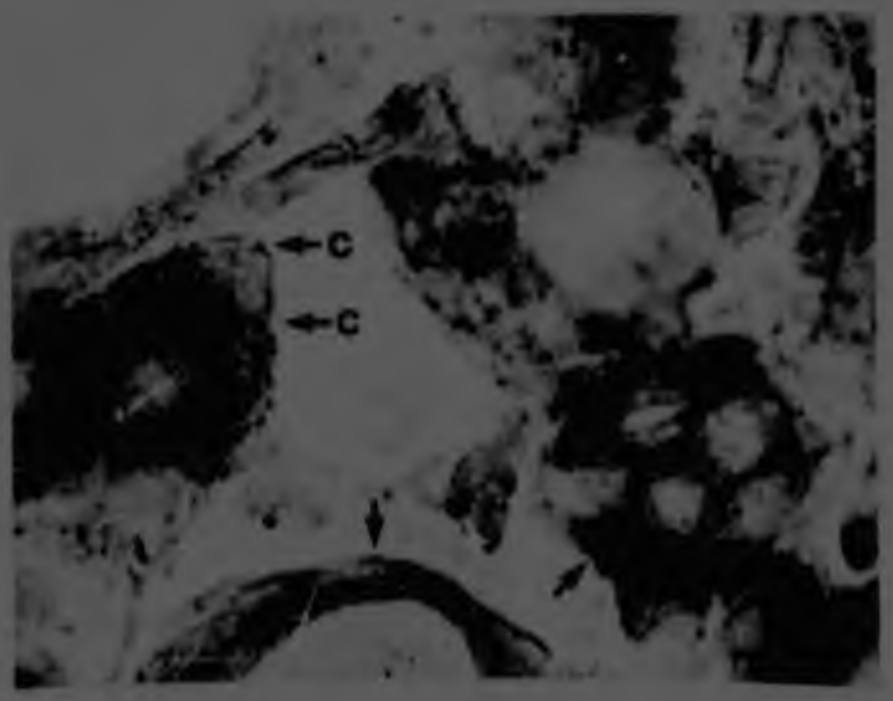

Fig. 26 - Non specific esterase in C (C) and follicular cells (unlabelled arrows). Cryostat section formol saline fixation. Indoxylic ester method. X1200

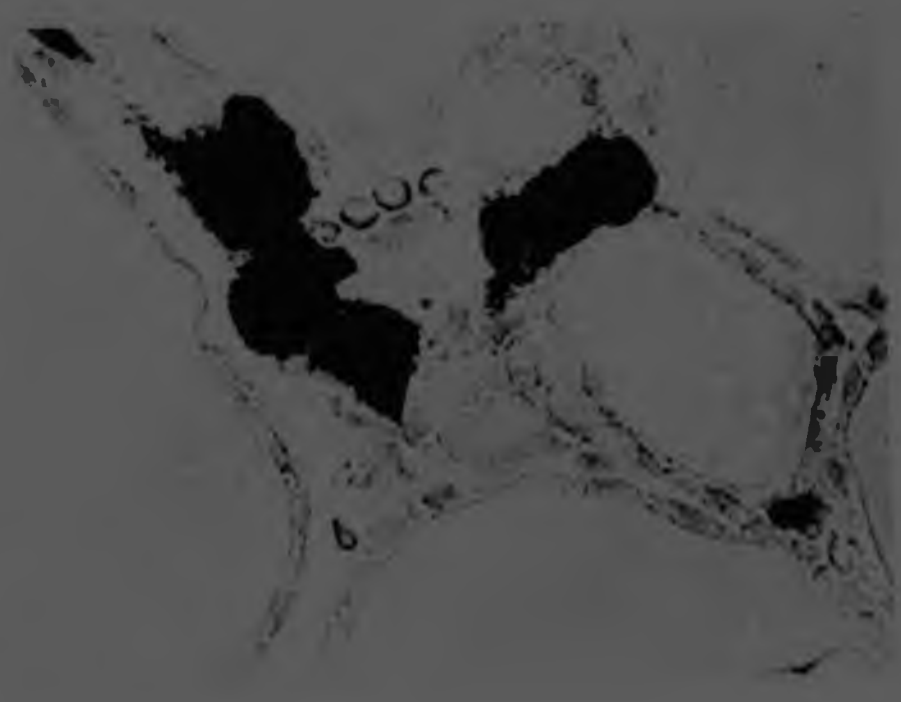

Fig. 27 - A high cholinesterase activity in C cells but none in follicular cells. Cryostat section, Pearson's fixative. Gereb.zoff's method. X960

5.5.5 Discussion

All the enzyme reactions with the exception of alkaline phosphatase yielded the same results as have been reported in the literature by Sandritter et al. (1956), Foster et al. (1964a) and Pearse (1966). It is not clear whether the details of all the methods that I employed are the same as those used by the above investigators. They do not provide exact details of their methods. Considerations of methodology do not, however, seem important as reproduceable results (except for alkaline phosphatase) were obtained in this study.

Alkaline phosphatase was found in canine C cells by Sandritter (1956) and by Pearse (1966) but I could not confirm this observation. No explanation for this is available except that the method I chose is very insensitive.

The presence of acid phosphatase activity, has in general been linked with protein-producing cells especially those in which pinocytosis and emiocytosis is observed (Barka, 1962). Barka points out that acid phosphatase is related to the development and activity of the pinocytotic apparatus. Wetzel et al. (1965) demonstrated that, after pinocytosis of thyroglobulin by follicular cells of the rat, the ingested thyroglobulin is associated with strong acid phosphatase activity. Perhaps this dependence of thyroglobulin ingestion or acid phosphatase activity explains why some canine follicular cells have a marked activity of this enzyme. These cells are presumably active in thyroglobulin absorption. The C cell – which actively discharges its secretory granules into the circulation – has a lesser content of acid phosphatase than follicular cells. The enzyme in C cells also seems to be related to protein synthesis but probably in a different manner to that mentioned above. Foster et al. (1965a) have shown that calcitonin-releasing stimuli lead to an accumulation of acid

phosphatase while unstimulated C cells, show considerably lower levels. The low activity of acid phosphatase that I observed in C cells (Pearse, 1966, has found varying amounts in C cells) probably indicates that the cells have not been subjected to secretory stimuli.

In contrast to the situation as regards acid hydrolases, the function of the hydrolases acting on carboxylic esters (non-specific esterases) is not known. The normal distribution, and the alteration of distribution of this enzyme, in follicular cells of rats following thyroid stimulating hormone and thiouracil administration, was studied by Pepler and Pearse (1957). Their analysis with regard to follicular cells was inconclusive. The non-specific esterase content in canine C cells is somewhat higher than that of follicular cells. Stimulation of the C cells by calcium infusion did not markedly alter the content of this enzyme (Foster, et al., 1964a); presumably therefore it is not involved in the release of the hormone.

The presence of cholinesterase in C cells of dogs, demonstrated first by Sandritter et al. (1956), was confirmed in this study. In canine C cells Carvalheira and Pearse (1967) have found this enzyme to be a pseudo-, rather than a true, cholinesterase. It is also present in C cells of other species such as guinea-pigs (Dejardin, 1955), rats (Pepler and Pearse, 1957), pigs (Carvalheira and Pearse, 1967) and rabbits (Welsch and Pearse, 1969). Functionally this enzyme is most likely related to secretion of granules from the C cell. It is located on the margin of secretory granules or along the cell membrane on which granules are aligned (Welsch et al., 1969). The very marked activity of this enzyme in these cells has made it suitable for identifying C cells. As the enzyme is present in C cells of several animal species one would expect to find it in C cells of human (neonatal) thyroid glands.

Dehydrogenases are enzymes which oxidize by removing hydrogen from their substrates (αglycerophosphate and NADH); biochemically they are mainly involved in the hydrogen transport system (Fig. 28) ('electron ladder') of mitochondria. The oxidation of substrates by dehydrogenases usually activates several co-enzymes and flavoproteins, the function of which is to mediate a rise in the oxidation potential so that energy transformation for example conversion of adenine di-phosphate to adenosine tri-phosphate, can take place. The oxidation potential of tetrazolium salt is usually small so that electron transfer preferentially occurs onto this salt rather than reaching a point where adenosine conversion occurs (Fig. 28). The addition of a hydrogen ion to tetrazolium salts produces an insoluble formazan salt and it is this salt, chelated to cobalt, that is visible in cells as the end product of the cytochemical procedure. In the older methods for dehydrogenase demonstration (Hess et al., 1958) it was necessary to add co-enzymes (NAD) to the substrate to initiate transfer along the electron transport system and to ensure that the oxidation potential was raised to that of the tetrazolium salt. Since then, however, it has been shown that menadione enables electron transfer to by-pass the electron chain (NAD, flavoprotein and cytochromes) thereby raising the electron charge to the oxidation potential of the tetrazolium salt (Wattenburg and Leong, 1960). This latter modification was used by Pearse (1966) and owing to the good results demonstrated by him, I used the same method in this study. The good localization of dehydrogenases in both C and follicular cells indicate the efficacy of the method.

The reason why C cells should have a high content of αGPDH remains speculative. Biochemically this enzyme is implicated in a glycerophosphate 'shuttle' (Boxer and Devlin, 1961) whereby hydrogen ions are transferred

Dehydrogenases are enzymes which oxidize by removing hydrogen from their substrates (αglycerophosphate and NADH); biochemically they are mainly involved in the hydrogen transport system (Fig. 28) ('electron ladder') of mitochondria. The oxidation of substrates by dehydrogenases usually activates several co-enzymes and flavoproteins, the function of which is to mediate a rise in the oxidation potential so that energy transformation, for example conversion of adenine di-phosphate to adenosine tri-phosphate, can take place. The oxidation potential of tetrazolium salt is usually small so that electron transfer preferentially occurs onto this salt rather than reaching a point where adenosine conversion occurs (Fig. 28). The addition of a hydrogen ion to tetrazolium salts produces an insoluble formazan salt and it is this salt, chelated to cobalt, that is visible in cells as the end product of the cytochemical procedure. In the older methods for dehydrogenase demonstration (Hess et al., 1958) it was necessary to add co-enzymes (NAD) to the substrates to initiate transfer along the electron transport system and to ensure that the oxidation potential was raised to that of the tetrazolium salt. Since then, however, it has been shown that menadione enables electron transfer to by-pass the electron chain (NAD, flavoprotein and cytochromes) thereby raising the electron charge to the oxidation potential of the tetrazolium salt (Wattenburg and Leong, 1960). This latter modification was used by Pearse (1966) and owing to the good results demonstrated by him, I used the same method in this study. The good localization of dehydrogenases in both C and follicular cells indicate the efficacy of the method.

The reason why C cells should have a high content of αGPDH remains speculative. Biochemically this enzyme is implicated in a glycerophosphate 'shuttle' (Boxer and Devlin, 1961) whereby hydrogen ions are transferred

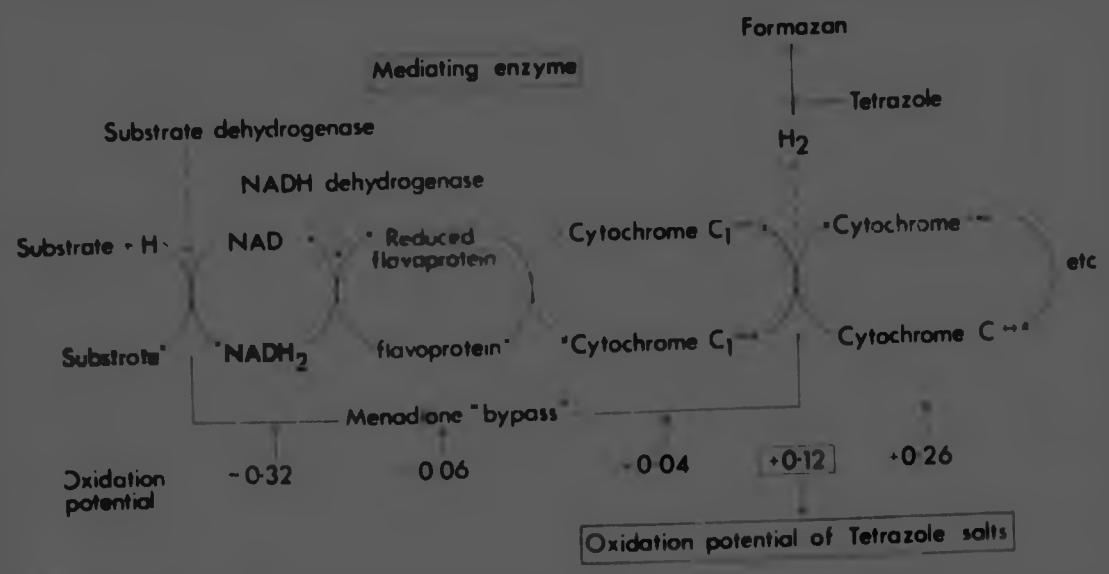

Fig. 28 - The oxidation potential of co-enzymes and flavoproteins of the hypothetical 'electron ladder'. Hydrogen ion release via the menadione bypass reduces tetrazole salts to formazan. 'Substrate' in this figure is represented by glycerophosphate in the present study.

Based on (1) Dixon and Webb (1964)
(2) Chayen et al.(1969)

from the cytoplasm into mitochondria. This biochemical system is presumably well developed in C and other protein-producing cells which have a similarly high content of this enzyme.

5.5.6 Conclusions

(1) Six enzymes (acid phosphatase, alkaline phosphatase, non-specific esterase, NADH reductase, αGPDH, and cholinesterase) have been studied cytochemically in canine thyroid C cells. The results are similar to those reported in the literature, except that alkaline phosphatase was not detected in canine C cells.

(2) Methods for three enzymes, cholinesterase, αGPDH and NADH tetrazolium reductase, are particularly suited for identifying C cells amongst follicular cells.

5.6 The C cells in thyroid glands of human neonates

5.6.1 Materials and methods

Whole thyroid glands were surgically removed from 5 human stillborn neonates. The glands were dissected and removed through a transverse lower neck incision, the steps of a routine thyroidectomy operation (Piercy, 1969) were followed. The time lapse before thyroid removal, the sex, post-gestational age and cause of death are given in Table XIV.

Thyroids were sagitally and transversely cut through the isthmus to provide four quadrants of tissue. Each of the four quadrants was cut in the coronal plane. Thus every thyroid was divided into eight blocks (Fig.29). One lobe for each thyroid (4 blocks) was used for paraffin sectioning and the other lobe (4 blocks) for enzyme studies. Material from each neonate for paraffin sections was fixed in each of Helly's fluid, 80 per cent alcohol and glutaraldehyde picric-acetic acid (GPA) fixatives and sections were cut at 4μm. For enzyme techniques half of the thyroid

TABLE XIV - Neonatal thyroidectomies

code no.	time lapse before thyroid removal (hours)	sex	post-gestational age (weeks)	cause of death
C_1	4	male	32	respiratory distress
C_2	4	female	34	umbilical cord prolapse
C_3	7	female	± 36	pre-eclamptic toxaemia
C_4	1½	female	± 36	deep transverse arrest
C_5	1	male	35	cerebral haemorrhage

lobe used for enzyme studies was fixed in Pearson's fixative (Pearson, 1963) at 4°C for 12 hours and then quenched in liquid nitrogen for cryostat sectioning. The remaining half was quenched in hexane (-70°C) or liquid nitorgen, sectioned on a Pearse-Slee cryostat at 3µm and post-fixed in formol saline or GPA for periods of 15 minutes to 1 hour.

The following staining methods were selected for the identification of C cells in human neonatal thyroid glands : (1) silver impregnation methods of Cajal, Grimelius and Masson-Fontana, (2) aldehyde fuchsin after permanganate oxidation and (3) demonstration of masked metachromasia. (Details of methods are given in Sections 3.4.1 and 4.3.1.) In addition, demonstration of three enzymes was undertaken in human glands. These were cholinesterase, αGPDH and NADH tetrazolium reductase. The methods and fixation were employed as described in Section 5.5.3.

Cryostat sections adjoining those demonstrating αGPDH and NADH tetrazolium reductase were prepared to demonstrate toluidine blue metachromasia which was used as an indicator of calcitonin-producing ability.



Fig. 29 - Diagrammatic representation of C cell distribution within the neonatal human thyroid gland. Cells were consistently found in the hatched area. AA transverse section, BB sagital section, CC coronal section. These planes correspond to the planes of tissue sectioning prior to fixation.

For this purpose the cryostat sections were post-fixed in GPA for 15 minutes then hydrolysed in 0.2N HCl at 60°C for 15 minutes and stained in toluidine blue as previously (Section 3.4) for 30 minutes.

In order to determine the distribution of C cells throughout the neonatal glands, sections of all four blocks of one lobe from the thyroid of each of four neonates were studied. Lobes (constituting 4 blocks from each neonate) embedded in paraffin wax, were used. The Grimelius impregnation method and toluidine blue metachromasia methods were used to assess the overall distribution of these cells. Sections cut in plane AA (Fig. 29) were selected and 10-20 slides were chosen randomly from each of the middle, lower and upper pole regions of the thyroid lobes. Sections from four lobes i.e., four neonates were used to assess distribution. No quantitation of these cells was performed but the region in which they occurred predominantly was noted.

5.6.2 Results

A summary of the results for human neonatal C cells is given in Table XV. In the table the results are compared with those obtained in canine cells (recorded in Sections 3.4 and 5.5).

In this section of the study no attempts were made to distinguish oxyphil cells in human neonatal material but these cells were considered in certain instances when staining results in epithelial cells were similar to those noted in oxyphil cells of adult human thyroid glands by Hamperl (1962) and Tremblay (1969).

The silver impregnation methods of Grimelius and Cajal revealed silver deposition in epithelial and C cells of the thyroid gland but the Masson-Fontana method produced no observable silver in such cells.

Cajal's silver impregnation method showed coarse granules in the cytoplasm of follicular cells. Groups of cells which also contained coarse

TABLE XV - Cytochemical reactions in follicular and C cells of young dogs and human neonates

method	follicular cells		C cells	
	dog	man	dog	man
Cajal	few impregnated granules	many impregnated granules	many impregnated granules	many impregnated granules
Grimelius	N/R	N/R	marked positive cytoplasmic granules	marked positive cytoplasmic granules
Masson	no argentaffinity	no argentaffinity	no argentaffinity	no argentaffinity
aldehyde fuchsin	few +ve cytoplasmic granules	few +ve cytoplasmic granules	diffuse cytoplasmic stain	(?) C cell not identified with this method
αGPDH	+	2 types < + / ++	++++	++++
NADH	+	2 types < + / ++	+++	+++
cholinesterase	nil	nil	pseudo-cholinesterase	nil
toluidine blue metachromasia	nil	nil	metachromatic after or without acid hydrolysis	metachromatic only after acid hydrolysis

N/R = no reaction

+/++/+++/++++ = content of enzyme, subjectively assessed;

+ = small amount and

++++ = maximal content observed

cytoplasmic granules throughout the cytoplasm were found interspersed between thyroid follicles. From the resemblence in size and configuration of cells these cells were presumed to be follicular cells that had not commenced secretion of thyroglobulin. They may have been tangential sections of follicle walls but this was not confirmed on consecutive sections. Despite a careful search the Cajal's method was not suitable for distinguishing C from follicular cells by observing argyrophilic granules.

The Grimelius silver impregnation method, in contrast to the Cajal's procedure, produced no silver uptake in follicular cells but revealed argyrophilic C cells containing numerous impregnated granules throughout the cytoplasm. The C cells observed contained numerous secretorygranules : no obvious quantitative difference could be noted from one C cell to another.

Masked metachromasia of C cells with toluidine blue after hydrolysis was obtained in sections of wax-embedded material and in those cut on the cryostat. Following acid hydrolysis, C cells were easily identified by a beta-metachromasia in either type of section. This staining was present only if acid hydrolysis had been undertaken. Initially paraffin sections were immersed in the basic dye for 20 minutes as recommended by Solcia and Sampietro (1968) for staining of canine C cells; however, metachromasia was not readily detected after this short staining time. Sections were therefore left in the staining solution overnight; unsually an 8 hour immersion was adequate. Metachromasia of the entire cytoplasm, with coarse granular accentuation in the cytoplasm, was noted (Fig. 30), but in general, not as many granules could be discerned in the cells staining with the basic dye as in cells impregnated with silver.

Staining with the other basic dye, aldehyde fuchsin, following potassium permanganate oxidation, produced an intense staining of colloid,

follicular cells and interfollicular connective tissue. This staining reaction was not suitable for detection of C cells as these could not be distinguished from follicular cells. The intense uptake of aldehyde fuchsin in all epithelial and epithelioid cells was unexpected.

Morphology and distribution of C cells

Observations on the morphology and distribution of C cells were made on the toluidine blue-stained and the silver-impregnated sections.

Two apparent morphological forms of C cells were noted. The first form I have termed 'ovoid' (Figs. 31, 32); the second is a more elongated cell with one or more cytoplasmic processes (Figs. 33, 34). These morphological forms might have been C cells cut in different planes of section. Ovoid cells, for example, could have cytoplasmic processes but this was not ascertained on consecutive sections. In both morphological forms argyrophilic granules are densely aggregated throughout the cell body. In cells with cytoplasmic processes, these are applied along the external surface of the follicle parallel to the basement membrane. The appearance suggests that these processes are draped over the spherule constituted by follicular cells. Approximately one third of all the C cells in the neonatal gland have cytoplasmic processes and the remainder have the ovoid appearance. The latter cell form is slightly larger than the follicular cells and has a centrally situated nucleus. The positions of this form of cell with regard to the follicular cells are intrafollicular, parafollicular and interfollicular (Fig. 35). Occasionally 3 to 4 cells were found in association with the same follicle; these were usually in an intra- or parafollicular position. A number of C cells were interspersed usually singly, between follicular cells that had either not yet begun to secrete thyroglobulin or were tangentially cut cells of follicles.

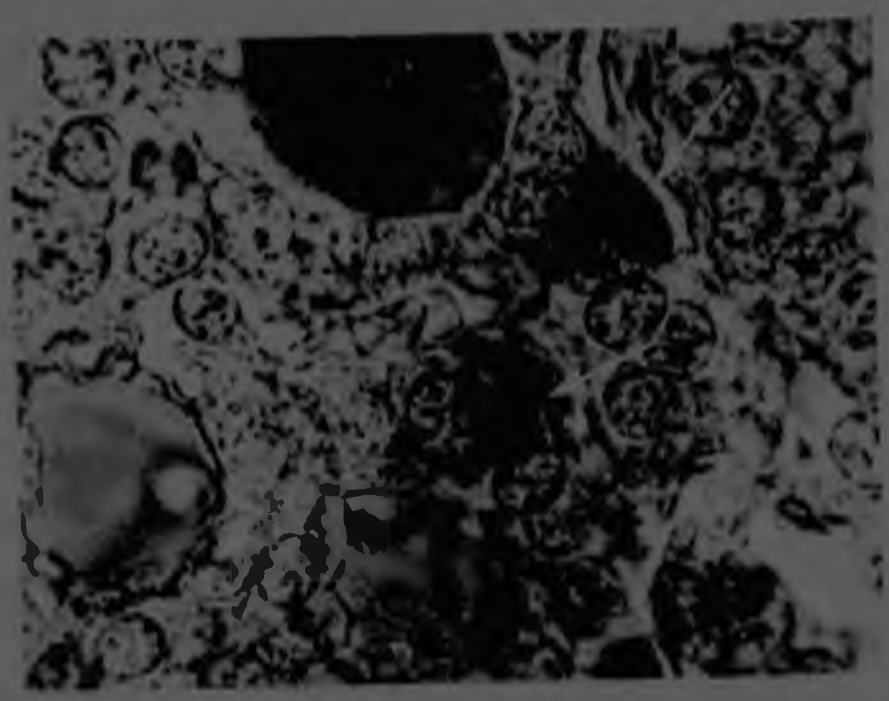

Fig. 30 - Masked metachromasia of two human C cells (arrows). GPA fixation. Toluidine blue after acid hydrolysis. X1200

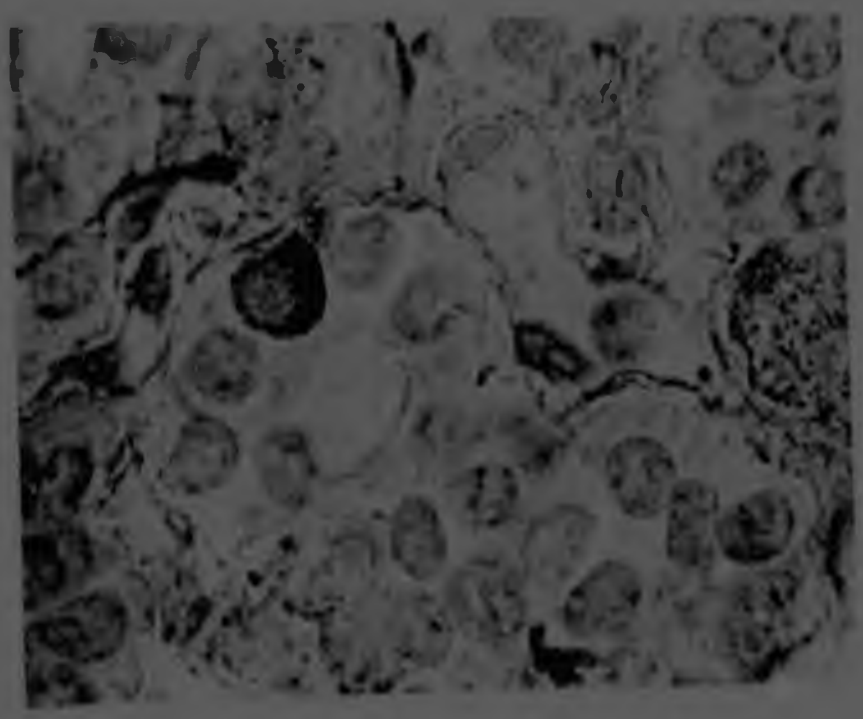

Fig. 31 - Ovoid human C cell in an intrafollicular position. GPA fixation. Grimelius silver impregnation. X1200

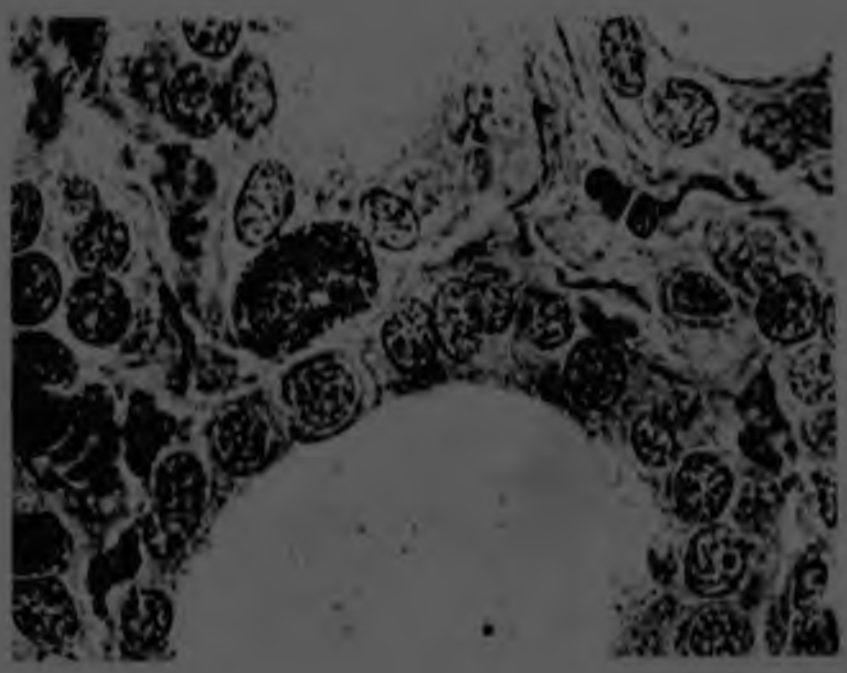

Fig. 32 - Ovoid human C cell in a parafollicular position. GPA fixation. Grimelius silver impregnation. X1200

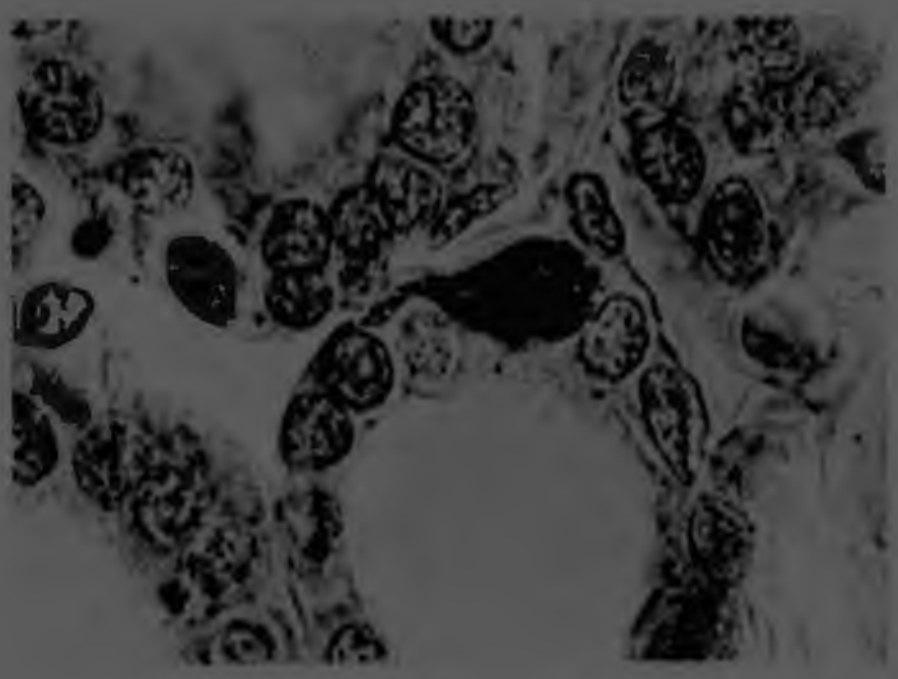

Fig. 33 - Human C cell with cytoplasmic process in a parafollicular position. GPA fixation. Grimelius silver impregnation. X1200



Fig. 34 - Human C cell with cytoplasmic process in an interfollicular position. GPA fixation. Grimelius silver impregnation. X960

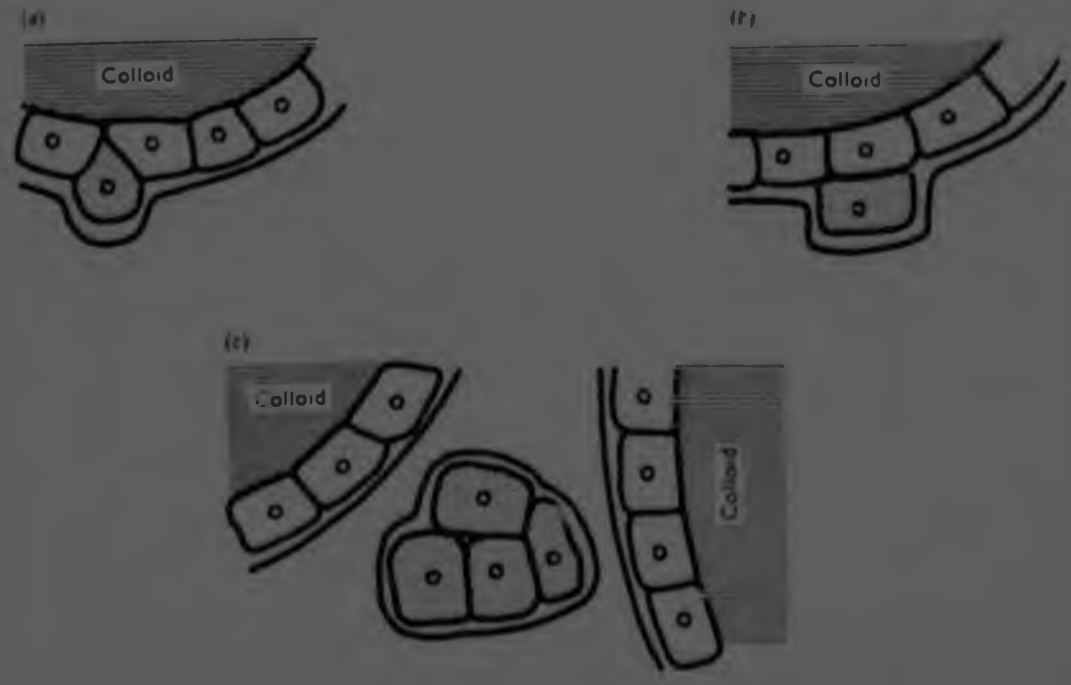

Fig. 35 - Diagrammatic representation of C cells in relation to follicular cells (a) intrafollicular, (b) parafollicular and (c) interfollicular position of C cells.

Numerically the C cells seem far fewer in the human neonatal thyroid gland than in the canine thyroid. The precise overall distribution of C cells has not been determined as no entire lobe was sectioned serially. However, sets of slides taken from upper, middle and lower pole regions indicate clearly that cells are found predominantly in the posterior aspect of the gland and in the upper pole (Fig. 29). Here 6 - 8 cells would be found per high power field (x400 magnification) whereas usually, further anteriorly and at the inferior pole, no C cell could be found.

Cellular enzymes

No cholinesterase activity could be demonstrated in any follicular cells of neonatal thyroid glands. The relevant method was carried out on control sections from canine thyroids and these showed a positive reaction.

The hydrolases were well shown in all the material that was available. Several categories of cells in the thyroid were shown to have a relatively high enzyme content. Of these, two groups of cells could be distinguished from the follicular (acinar or A) cells which showed a minimal amount of αGPDH (Table XVI). One group, C cells, showed a very high content of αGPDH and demonstrated toluidine blue metachromasia in adjoining sections. These cells occurred in both an intra- and a para-follicular position. Occasionally clusters of two to three cells were found to have this high enzyme content. The second group, temporarily termed AC cells, contained a moderately high content of oxidative enzyme (αGPDH) (Fig. 36) but in adjacent sections demonstrated no toluidine blue metachromasia. These cells usually occupied an intrafollicular position, only one or two occurring per follicle, while some were found in an interfollicular position (Fig. 37).



Fig. 36 - Human follicular and AC (arrows) cell types. Cryostat section,formol-saline. αGPDH demonstration. X1200

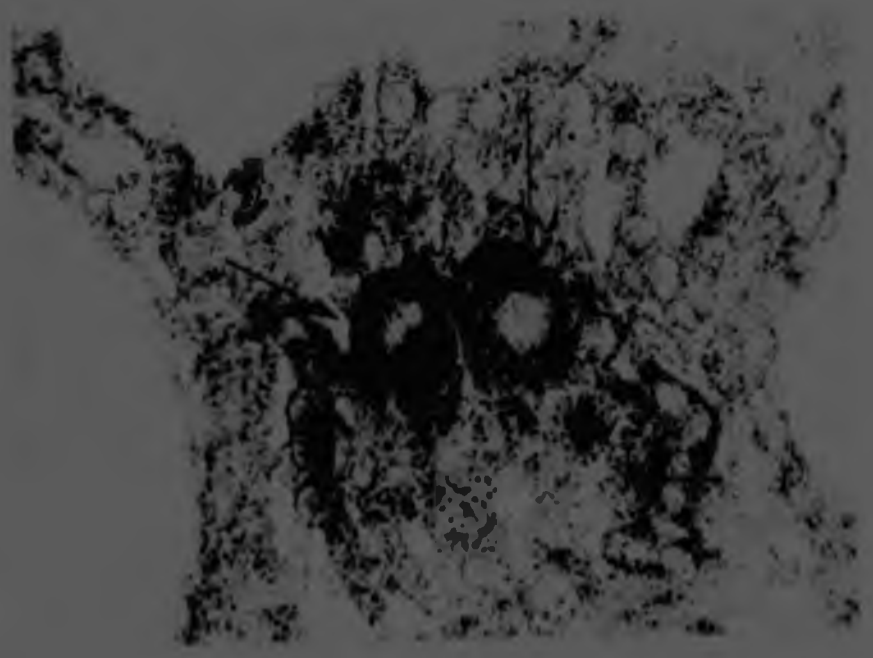

Fig. 37 - Human AC cell in an interfollicular position (arrows). Cryostat section, formol-saline. αGPDH demonstration. X1200

TABLE XVI - Quantitative distribution of αGPDH and NADH reductase in thyroid cells of human neonates and relationship of presence of these enzymes to toluidine blue metachromasia

cell type	αGPDH	NADH reductase	toluidine blue metachromasia
A cells	+	+	-ve
AC cells	++ or +++	+ or ++	-ve
C cells	++++	+++	+ve

+/++/+++ represent subjective assessment of increasing content of enzyme.

In the neonate the distribution pattern of NADH tetrazolium reductase within C cells generally paralleled that of αGPDH. C cells which had a very high content of dehydrogenase also showed a high content of the reductase. However, that cell category (AC cells) which had only a moderately high content of GPDH was not as easily detectable with the NADH tetrazolium reductase method (Table XVI) because the difference in enzyme content between AC and follicular cells was small.

5.6.3 Discussion

The above results indicate that the Grimelius silver impregnation method, toluidine blue metachromasia after hydrolysis and methods for hydrolases adequately demonstrate C cells in the neonatal human thydoid gland whereas the Cajal silver impregnation method and cholinesterase methods are not suitable for the detection of these cells.

The first reports that the Grimelius silver impregnation method is suitable for detecting C cells in human thyroid gland (removed for pathological reasons) appeared in 1970 (Solcia and Sampietro, 1970 and Grandi,1970). Prior to that time attempts were made to use the

Gros-Schultze method (Sandritter, 1954) and Cajal's silver impregnation (Kracht et al., 1970) to demonstrate human C cells. Sandritter was able to demonstrate a few argyrophilic cells but Kracht, using the Cajal impregnation, was not. Due to these difficulties the Grimelius method was subsequently used by other workers : their studies were aimed at confirming the presence of human C cells in pathological material (goitrous glands) (Englund et al., 1972 and Lillis and Balogh, 1973) or to detect argyrophilic granules in carcinomas derived from human C cells (Tateishi et al., 1972 and Meyer et al., 1973). These reports confirmed the efficacious use of this silver impregnation method for human C cells but provided little information on the normal distribution or morphology of this cell.

Solcia and Sampietro (1968) and Solcia et al. (1970) were also the first to use toluidine blue metachromasia (masked metachromasia) to demonstrate C cells in pathological adult human thyroid glands. The present results show that this type of metachromasia also provides adequate means for identification of C cells in neonatal human thyroids. For the success of this stain on human tissue sections, acid hydrolysis is mandatory while metachromasia in canine C cells can be demonstrated without acid hydrolysis. A critical discussion of this reaction is given in earlier sections (3.4.3 and 3.7.4) of this study. Two chemical alterations which induce metachromasia are predominantly brought about by acid hydrolysis. There are a conversion of carboxamido side groups to carboxyl groups and an intra-chain cleavage of polypeptides at the aspartic acid group (Roediger, 1976). Whereas the former of the two reactions is probably not of importance in canine thyroid C cells (see Section 3.4.3), it does seem to be so in human C cells, since without hydrolysis no side chain carboxyl groups are available to provide

metachromasia. Some side chain groups thus seem to be carboxamido groups in human C cells - this is in accordance with biochemical observations of Riniker et al. (1968) on human calcitonin.

The morphological variant of normal human C cells with cytoplasmic processes had not been reported previous to the observations made in this study (Roediger, 1973) but their existence has been subsequently confirmed by Wolfe et al.(1974) in adult human glands. The human UBB also contains C cells with cytoplasmic processes (Chan and Conen, 1971). C cells with elongated cytoplasmic processes have been observed in thyroid glands of the guinea pig and the tree shrew (Welsch et al., 1969). In the pig, C cells are generally flattened with an eccentric nucleus (Carvalheira and Pearse, 1968). Occasionally cells with cytoplasmic process are found in the ox thyroid (Grandi, 1970). In other species, for instance the dog, the rabbit and the opossum, the C cell population is, in contrast, entirely constituted by the ovoid form of cell. An explanation for the peculiar morphological appearance (cytoplasmic processes) is suggested by Welsch et al. (1969) in that this cell appearance may reflect an atavistic locomotor ability.

Even though entire thyroid lobes were not serially sectioned, sections taken from three regions of the neonatal thyroid gland allowed a fairly accurate siting of the C cells in the upper middle and lower regions of thyroid lobes. The distribution of C cells in adult human thyroid glands has been studied by others subsequent to publication of my observations on neonatal glands (Roediger, 1973). The observations of McMillan et al. (1974) and Wolfe et al. (1974) showed that in adults, C cells, are also distributed predominantly in a central and posterior area in which they had been found in human neonates. In addition, they found a few C cells in the adult thyroid more anteriorly than I found

in the human neonatal gland. McMillan et al. and Wolfe et al. used immuno-histochemical procedures, employing an antibody to calcitonin, whereas I used metachromasia and argyrophilia.

The preponderance of C cells in the posterior region of the thyroid gland accords well with the invasion of the human thyroid by cells from the UBB (Kingsbury, 1935; Sugiyama et al, 1959; Sugiyama, 1971). Sugiyama (1971) demonstrated the posterior relationship of the human UBB to the thyroid and the dispersal of cells from this body into the posterior thyroid. C cells in the rodent have been shown to arise from the UBB (Pearse and Carvalheira, 1967) and presumably this also applies in man.

Further embryological studies by Sugiyama et al. (1969) indicate that in the thyroid of human foetuses, cysts derived from the UBB persists into late antenatal life. Such cysts were not found in the neonates of the present study, yet in human adults, follicles lined wholly by C cells have, on two occasions, been observed by Solcia et al. (1970) and by McMillan et al. (1974).

The paucity of C cells in neonatal human thyroids, as compared with numbers in canine thyroids, is remarkable. Though not quantitated, the neonatal human C cell population appears to constitute less than 1% of the total cells in the thyroid gland. It is conceivable that the small number of human cells could be augmented by the presence of C cells in organs other than the thyroid. Galante et al. (1968) have shown that calcitonin can be extracted from the human thymus; this suggests that C cells might be present in the thymus. Thymic tissue was not examined in the present study; parathyroid glands of neonates were examined but contained no C cells. In the dog, C cells can be found adjacent to the pericardial sac (Kameda, 1970): these should be sought in man.

In the present study, enzyme content in epithelial cell types of human neonatal thyroids was compared with masked metachromasia in these cell types. This revealed three categories of cells. The terms A (acinar or follicular cell), C (calcitonin cell) and AC (an intermediate form; this is my own designation) were adopted in order to keep as much as possible in line with the nomenclature that Pearse (1966) used for thyroid cells in the dog. Dog A cells Pearse showed, and I have confirmed, had a low αGPDH content, as did neonatal A cells which demonstrated no masked metachromasia. Neonatal human C cells, as did those for dogs, exhibited definite masked metachromasia; their αGPDH content was very high, as is characteristic of dog C cells according to Foster et al. (1964a) and Pearse (1966). The third category of cell called the AC cell, showed a moderately high content of αGPDH, so resembling C cells, but no masked metachromasia, so resembling A cells.

Pearse (1966) showed that, apart from C cells, dog thyroids exhibit cells which contain less αGPDH than C cells. These he termed C^1 cells. Because AC cells showed no masked metachromasia it is unlikely that they contained an acidic polypeptide hormone. I therefore could not equate AC cells with C^1 cells since the designation implies that these are a variety of C cells.

The results of the present study indicate therefore that the neonatal thyroid gland contains cells distinguished as follicular (A cells), C and AC cells. For clarification it is worthwhile to compare cell types of neonatal thyroids with those found in the thyroid gland of adults (Table XVII), in which I have previously distinguished follicular, C and oxyphil cells (Section 5.2).

Adult and neonatal C cells have similar cytochemical properties. In considering the published results for adult C cells (Solcia et al., 1970 and Kalina et al., 1970) it is clear that C cells in both adult and neonates contain argyrophilic granules, demonstrate masked metachromasia and have a high content of hydrolases.

A comparison of AC cells of neonates and oxyphil cells of adults (Table XVII) shows that these cells have some similar cytochemical properties. Studies of oxyphil cells in adult thyroid glands indicate that they contain a moderately high content of dehydrogenases (NADH tetrazolium reductase, αGPDH and succinic dehydrogenase (Tremblay and Pearse, 1960; Harcourt-Webster and Stott, 1966)). AC cells have a moderately high content of NADH tetrazolium reductase and of αGPDH. Oxyphil cells stain metachromatically with basic dyes (Hamperl, 1962) (whether they demonstrate a masked metachromasia has, unfortunately not been ascertained). AC cells show no masked metachromasia. In addition evidence has been collated to indicate that oxyphil cells do not produce protein (Roediger, 1975). AC cells may also lack an ability to produce protein - an absence of masked metachromasia in AC cells is presumed to indicate a lack of production of acidic protein. Accordingly it is possible that AC cells of the neonatal thyroid are homologous with oxyphil cells of the adult thyroid gland.

AC cells reveal a kinship not only to oxyphil but also to C cells as has been indicated above. AC cells might represent an inactive state of C cells, having liberated their hormone content but having not yet synthesized any more. This could account for the absence of masked metachromasis in AC cells.

At present I prefer to consider AC cells nomologous with oxyphil cells of adult thyroid glands. In order to prove homology, further

TABLE XVII - Cytochemical properties of human (adult) oxyphil and human (neonatal) C and AC cells of the thyroid gland

Feature	Oxyphil cells (adult)	AC cells (neonate)	C cells (neonate)
Enzymes			
αGPDH	+++	++ or +++	++++
NADH reductase	++	++	+++
Metachromasia	++ (not masked)	- (masked)	++++ (masked)
Phospholipids	+++		(++) (a)
PTAH stain	+ve		-ve (b)
Secretory granules	nil		argyrophilic granules

(a) (b) : these reactions have not been recorded in this study

(a) = reported only in animals (Pearse, 1968)

(b) = personal unrecorded observation

+/++/+++/++++ represent increasing amounts subjectively assessed for each cell form; the assessments for oxyphil cells are not strictly comparable to the assessment for C cells. (Differences in age and cytochemical procedures have not been evaluated simultaneously.)

Cytochemical properties of oxyphil cells : (1) Tremblay and Pearse (1960)
(2) Hamperl (1962).
(3) Roth et al.(1962)
(4) Harcourt-Webster and Stott (1966)

experimental work is needed. Simultaneous staining of neonatal and adult thyroid tissue must be undertaken for a comparative evaluation of cytochemical properties of AC and oxyphil cells.

The absence of pseudo-cholinesterase from C cells of neonates was unexpected as C cells of several species (see Section 5.5.5) are known to contain cholinesterase. Lack of this enzyme may perhaps be related to cell immaturity. Welsch (1971) has shown that C cells in young rats and cats have a very low content of this enzyme and that with age an increased amount is detectable.

5.6.4 Conclusions

(1) The presence of C cells has been demonstrated in the thyroids of five human neonates by means of cytochemical methods (toluidine blue metachromasia, argyrophilia, hydrolytic enzymes) known to demonstrate C cells in dogs.

(2) In the neonates the C cells were demonstrated mainly in the posterior region and upper pole of both lobes where they were found scattered in clusters of six to eight cells per high power field.

(3) Two morphological forms of normal human C cells were observed - an ovoid cell and one having cytoplasmic processes. These cell forms may be C cells cut in a different plane of section or represent two distinct morphological forms of human C cells.

(4) The presence of argyrophilic granules was shown in the cytoplasm of human C cells. These granules are most satisfactorily demonstrated by means of the silver impregnation method of Grimelius on tissue fixed in GPA.

(5) By demonstrating oxidative enzymes and masked metachromasia three categories of epithelial cells have been shown in the neonatal thyroid gland : A, C and AC cells. The latter may be homologous with the oxyphil cells observed in normal and pathological adult thyroid glands.

6. CLINICAL APPLICATIONS OF THE PRESENT STUDIES

6.1 Argyrophilic granules in tumours of C cells

An obvious extension of the above studies was to demonstrate argyrophilic granules in tumours believed to be derived from C cells i.e. medullary carcinoma. This had not been done before. I used the Grimelius method for tumour studies early in 1971. The staining results were successful but due to lack of tumour material this study was not extended. Several papers in which this method was used on pathological material have appeared since then (Englund et al., 1972; Tateishi et al., 1972; Lillis and Balogh, 1973; Meyer et al. 1973).

6.2 Teratomatous growths of thyroid gland and C cells

On the basis that C cells are found in neonatal glands together with the evidence that they are derived from the neural crest, I have proposed that teratomas in the thyroid gland arise from all three germ cell layers, in the thyroid gland. A fulldiscussion in favour of this theory has been published and the view contrasted with the 'blastomeric' (single cell origin) theory of thyroid teratomas (Roediger et al., 1974).

6.3 C cell distribution and surgery of C cell tumours

Knowledge of the distribution of C cells within the thyroid gland in neonates (present study, Roediger, 1973) and adults (Wolfe et al., 1974) has made it possible to plan resections of thyroid tissue involved with medullary carcinoma. A proposal in terms of the extent of such resection has been published (Roediger, 1976).

6.4 Distinction of human C cells and oxyphil cells of the thyroid gland

Analysis of the cytochemical properties of normal neonatal human C cells has provided a suitable means for comparison between C and oxyphil cells

of the human thyroid gla[illegible]. Cytochemical properties of the latter cell have been published by ot[illegible] (Tremblay, 1969). The two cells are cytochemically akin but functionally different (Roediger, 1975). They are alike in their hydrolase and lipid content and both cells stain metachromatically although under different conditions but C cells produce calcitonin and oxyphil cells do not. It was my intention to allay past confusion over the distinction between C and oxyphil cells in the human thyroid gland. By collating evidence from this study and other sources I have emphasized that oxyphil and C cells are distinct cell types which are not, as has been claimed, derivatives of one another.

ADDENDUM A

T.P.H. 49

TRANSVAALSE PROVINSIALE HOSPITALE

Telegrafiese Adres
Telegraphic Address

Telefoon Nr.
Telephone No. 830-3434.
Dr. L. Faivelsohn.

IN ANTWOORD VERMELD ASB.
IN REPLY PLEASE QUOTE
No. 5/1/7.

Alle korrespondensie moet aan die Superintendent gerig word.
All communications to be addressed to the Superintendent.

TRANSVAAL PROVINCIAL HOSPITALS

BARAGWANATH HOSPITAAL
HOSPITAL

Private Bag,

P. O. BARAGWANATH.

29th October, 1970.

Dr. W.E.W. Roediger,
Department of Anatomy,
Medical School,
Hospital Street,
JOHANNESBURG.

Dear Doctor,

RE : REMOVAL OF THYROID TISSUE AT POST MORTEM FROM SIX INFANTS.

Your letter of 17 October, 1970, together with a letter of support from Professor P.V. Tobias refers.

We are agreeable that you may obtain thyroid tissue for your research project provided that :

1. You do not contravene the Anatomy Act of this country.

2. That you personally obtain written consent for the post mortem from the deceased child's parents, seeing that you wish to dissect out the thyroid glands yourself.

This would mean that you would have to make yourself easily available to our medical staff who will know when a suitable infant body is available.

I am sure that this could be arranged between Professor Lavery and yourself.

Yours faithfully,

SUPERINTENDENT.
LF/HL.29.10.70.

REFERENCES

Adams, C.W.M. 'A stricter interpretation of the ferric-ferrocyanide reaction with particular reference to the demonstration of protein-bound sulphydryl and di-sulphide groups', Journal of Histochemistry and Cytochemistry, 4:23-35, 1956.

Adams, C.W.M. 'A p-dimethylaminobenzaldehyde-nitrile method for the histochemical demonstration of tryptophan and related compounds', Journal of Clinical Pathology, 10:56-62, 1957.

Adams, C.W.M. Neurohistochemistry. London, Elsevier, 1965.

Alfert, M. and Geschwind, I.I. 'A selective staining method for the basic proteins of cell nuclei', Proceedings of the National Academy of Science, 39:991-999, 1953.

Altman, H.W. 'Die parafollikuläre Zelle der Schildrüse und Ihre beziehungen zu der gelben Zelle des Darmes', Beiträge zur pathologischen Anatomie, 104:420-454, 1940.

Arvy, L. Histoenzymology of the endocrine glands. Oxford, Pergamon Press, pp.185-248, 1971.

Askanazy, M. 'Pathologisch-anatomische Beiträge zur Kenntniss der Morbus Basedowii, insbesondere über die dabei auftretende Muskelerkrankung ', Deutsches Archiv für Klinische Medizin, 61:118-186, 1898.

Azzali, G. 'Ultrastructure of the parafollicular cells', pp.152-166 in Calcitonin Proceedings of the Symposium on Thyrocalcitonin and the C cells, Ed. Taylor, S., London, Heinemann, 1968.

Baghdiantz, A. Foster, G.V., Edwards, A., Kumar, M.A., Slack, E., Soliman, H.A. and MacIntyre, I. 'Extraction and purification of calcitonin', Nature, 203:1027-1028, 1964.

Baillif, N. 'Cytological changes in the rat thyroid following exposure to heat and cold, and their relationship to the physiology of secretion', American Journal of Anatomy, 61:1-20, 1937.

Baker, J.R. 'The histochemical recognition of certain guanidine derivatives', Quarterly Journal of Microscopical Science, 88:115-121, 1947.

Baker, J.R. 'The histochemical recognition of phenols, especially tyrosine', Quarterly Journal of Microscopical Science, 97:161-164, 1956.

Bangle, B. (Jr.) 'Gomori's paraldehyde-fuchsin stain. I Physico-chemical and staining properties of the dye', Journal of Histochemistry and Cytochemistry, 2:291-299, 1954.

Bangle, B. and Alford, W.C. 'The chemical basis of the periodic acid-Schiff reaction of collagen fibres with reference to periodate consumption by collagen and insulin', Journal of Histochemistry and Cytochemistry, I:62-76, 1953.

Bancroft, J.D. 'An Introduction to Histochemical Technique', London, Butterworths, 1967.

Bancroft, J.D. and Stevens, A. 'Histopathological Stains and Their Diagnostic Uses', Edinburgh, Churchill-Livingstone, 1975.

Barka, T. 'Cellular localization of acid phosphatase activity', Journal of Histochemistry and Cytochemistry, 10:231-232, 1962.

Barka, T. and Anderson, P.J. 'Histochemistry, Theory, Practice and Bibliography', New York, Harper and Row, 1963.

Barnard, E.A. 'Acylation and diazonium coupling in protein cytochemistry with special reference to the benzoylation-tetrazonium method', pp.203-258 in 'General Cytochemical Methods', Ed. Danielli, J.F., New York, Academic Press, 1961.

Barrnett, R.J. and Seligman, A.M. 'Histochemical demonstration of protein-bound sulfhydryl groups', Science, 116:323-327, 1952.

Barrnett, R.J. and Seligman, A.M. 'Histochemical demonstration of sulfhydryl and disulfide groups of protein', Journal of the National Cancer Institute, 14:769-793, 1954.

Barrnett, R.J. and Seligman, A.M. 'Histochemical demonstration of protein-bound alpha-acylamido carboxyl groups', Journal of Biophysical and Biochemical Cytology, 4:169-177, 1958.

Belanger, L.F. 'Comparison between different histochemical and histophysical techniques as applied to mucus-secretory cells', Annals of the New York Academy of Sciences, 106:364-378, 1963.

Bell, P.H., Barg, W.F., Colucci, D.F., Davies, H.C., Dziobkowski, C., Englert, M.E., Heyder, E., Paul,R. and Snedeker, E.H. 'Purification and structure of porcine calcitonin', Journal of the American Chemical Society, 10:2704-2706, 1968.

Benditt, E.P. and French, J.E. 'Histochemistry of connective tissue : I The use of enzymes as specific histochemical reagents', Journal of Histochemistry and Cytochemistry, 1:315-320, 1953.

Bennett. H.S. and Watts, R.M. 'The cytochemical demonstration and measurement of sulfhydryl groups by azo-aryl mercaptide coupling with special reference to mercury orange' pp.318-374 in 'General Cytochemical Methods' Vol.I, Ed. Danielli, J.F., New York, Academic Press, 1958.

Bensley, R.R. 'The thyroid gland of the opossum', Anatomical Record, 8:431-440, 1914.

Beskid, M. and Rosciszewska, A. 'C cells in the normal animal and human thyroid gland', Folia Histochemica et Cytochemica, 6:461-468, 1968.

Beskid, M and Kobuszewska-Faryna, M. 'Adenoma oncocyticum glandulae thyreoideae', Folia Histochemica et Cytochemica, 10:31-36, 1972.

Bodian, D. 'A new method for staining nerve fibres and nerve endings in mounted paraffin sections', Anatomical Record, 65:89-97, 1936.

Bowness, J. 'Hyaluronidase assay using a chondroitin sulphate substrate', Biochimica et Biophysica Acta, 101:26-36, 1965.

Boxer, G.E. and Devlin, T.M. 'Pathways of intracellular hydrogen transport', Science, 134:1495-1501, 1961.

Braunstein, H. and Stephens, C.L. 'Parafollicular cells of human thyroid', Archives of Pathology, 86:659-666, 1968.

Br mer, W.W., Staub, A., Diller, E.R., Bird, H.L., Sinn, L.G. and Behrens, O.K., 'The amino acid sequence of glucagon, I-V', Journal of the American Chemical Society, 79:2794-2810, 1957.

Brewer, C.F. and Riehm, J.P. 'Evidence for possible non specific reactions between N-ethylmaleimide and proteins', Annals of Biochemistry, 18:243-255, 1967.

Brewer, H.B. 'Bovine thyrocalcitonin' pp.14-27 in 'Calcitonin 1969, Proceedings of the Second International Symposium' Ed. Taylor, S., London, Heinemann, 1970.

Brewer, H.B., Keutmann, H.T., Potts, J.T., Reisfeld, R.A., Schlueter, R., and Munson, P.L. 'Isolation and chemical properties of porcine thyrocalcitonin', Journal of Biological Chemistry, 243:5739-5747, 1968a.

Brewer, H.B., Keutman, H.T., Reisfeld, R., Munson, P., Schlueter, R. and Potts, J.T. 'Role of sulfur containing amino acids in the biological activity of porcine thyrocalcitonin (TC)', Federation Proceedings, 27:690, 1968b.

Burstone, M.S. 'Cytochemical localization of esterase', Journal of the National Cancer Institute, 18:167-171, 1957.

Bussolati, G. and Pearse, A.G.E. 'Immunofluorescent localization of calcitonin in the 'C' cells of pig and dog thyroid', Journal of Endocrinology, 37:205-209, 1967.

Cajal, 1927, as quoted by Gray, P. 'The Microtomists Formulary and Guide' p.554, London, Constable, 1954.

Calam, D.H. and Waley, S.G. 'Some derivatives of glutathione', Biochemical Journal, 15:417 419, 1962.

Carvalheira, A.F. and Pearse, A.G.E. 'The cytology and cytochemistry of the 'C' cells in the thyroid gland of the pig', Journal of the Royal Microscopical Society, 86:203-209, 1967.

Cecil, R. 'The role of sulfur in proteins' pp.380-477 in The Proteins, Ed. Neurath, H., Vol. I., 2nd Series, New York, Academic Press, 1963.

Cecil, R. and McPhee, J.R. 'Further studies on the reaction of disulphides with silver nitrate', Biochemical Journal, 66:538-543, 1957.

Chambers, R.W., Bowling, M.C. and Grimley, P.M. 'Glutaraldehyde fixation in routine pathology', Archives of Pathology, 85:18-30, 1968.

Chan, A.S. and Conen, P.E. 'Ultrastructural observations on cytodifferentiation of parafollicular cells in the human fetal thyroid' Laboratory Investigation, 25:249-259, 1971.

Chayen, J., Bitensky, L., Butcher, R.G. and Poultier, L.W. 'A Guide to Practical Histochemistry', 1st Edition, Edinburgh, Oliver and Boyd, 1969.

Chibnall, A.C., Haselbach, C., Mungan, J.L. and Rees, M.W. 'Studies on the amide and C-terminal residues in proteins', Biochemical Journal, 68:122-135, 1968.

Clamp, J.R. and Hough, L. 'The periodate oxidation of amino acids with reference to studies on glycoproteins', Biochemical Journal, 94:17-24,1965.

Cohen, L.A. 'Group-specific reagents in protein chemistry', Annual Review of Biochemistry, 37:695-726, 1968.

Copp, D.H., Davidson, A.G.F. and Cheney, B. 'Evidence for a new parathyroid hormone which lowers blood calcium', Proceedings of the Canadian Federation of Biological Societies, 4:17, 1961.

Copp, D.H., Cameron, E.C., Cheney, B.A., Davidson, A.G.F. and Henze, K.G. 'Evidence for calcitonin - a new hormone from the parathyroid that lowers blood calcium', Endocrinology, 70:638-649, 1962.

Copp, D.H. and Henze, K.G. 'Parathyroid origin of calcitonin - evidence from perfusion of sheep glands', Endocrinology, 75:49-55, 1964.

Coutts, R.T. and Smail, G.A. 'Polysaccharides, Peptides and Protein', London, Heinemann, 1966.

Cox, R.I. 'The interaction of some factors affecting the kinetics of a molluscan ß-glucuronidase', Biochemical Journal, 71:763-768, 1959.

Crombrugghe, de, B. and Edelhoch, L. 'The properties of thyroglobulin XIV. The structure of reoxidized thyroglobulin', Biochemistry, 5:2238-2245, 1966.

Culling, C.F.A. 'Handbook of Histopathological Techniques', 2nd Edition, London, Butterworths, 1963.

Curran, R.C. 'The histochemistry of mucopolysaccharides' pp.149-213 in International Review of Cytology, Vol.17, Eds. Bourne, G.H. Danielli, J.F., New York, Academic Press, 1964.

Curtis, S.K. and Cowden, R.R. 'Effects of anhydrous benzoylation on staining with a variety of protein end-group methods', Histochemie, 23:185-188, 1970.

Dahlqvist, A., Olsson, I. and Norden, A. 'The periodate-Schiff reaction: specificity, kinetics and reaction product with pure substrates', Journal of Histochemistry and Cytochemistry, 13:423-430, 1965.

Danielli, J.F. 'Studies on the cytochemistry of proteins', Cold Spring Harbour Symposium on Quantitative Biology, 14:32-39, 1950.

Danielli, J.F. 'Cytochemistry : A Critical Approach', New York, J. Wiley, 1953.

Dejardin, M. 'Les Cholinestérases dans la Glande Thyroïde du Cobaye', Comptes Rendus de la Société de Biologie (Paris), 149: 621-622, 1955.

Denffer, von, H., 'The site and nature of alcehyde fuchsin staining of pancreatic beta granules', Histochemie, 36:97-113, 1973.

Dixon, H.B.F. 'Treatment of corticotrophin with periodate and borohydride', Biochemical Journal, 83:91-94, 1962.

Dixon, M. and Webb, E.C. 'Enzymes', 2nd Edition, London, Longman, 1964.

Drury, R.A.B. and Wallington, E.A. 'Carleton's Histological Technique' 4th Edition, Oxford, Oxford University Press, 1967.

Dunn, M.S. and Rockland, L.B. 'Isolation of amino acids', pp.213-255 in Amino Acids and Proteins, Greenberg, D.M., Springfield, Charles Thomas, 1951.

Dyer, J.R. 'Use of periodate oxidation in biochemical analysis' pp.111-152 in'Methods of Biochemical Analysis', Vol. 3, Ed. Glick, G., New York, Interscience, 1956.

Devenyi, T. and Gergely, J. 'Amino Acids, Peptides and Proteins', Amsterdam, Elsevier, 1974.

Edelhoch, H. 'The structure of thyroglobulin and its role in iodination' Recent Progress in Hormone Research, 21:1-31, 1965.

Eisenberg, A.A. and Wallerstein, H. 'Hürthle cell tumour', Archives of Pathology, 13:716-724, 1932.

Elftman, H. 'Controlled chromation', Journal of Histochemistry and Cytochemistry', 2:1-8, 1954a.

Elftman, H. 'Phospholipid fixation by dichro te sublimate', Stain Technology, 32:29-31, 1954b.

Englund, N.E., Nilsson, G., Owman, C. and Sundler, F. 'Human thyroid C cells : occurrence and amine formation studied by perfusion of surgically removed goitrous glands', Journal of Clinical Endocrinology, 35: 90-96, 1972.

Eränkö, O. 'Histochemical demonstration of catecholamines by fluorescence induced by formaldehyde vapour', Journal of Histochemistry and Cytochemistry, 12:487-489, 1964.

Ewing, J. 'Neoplastic Diseases, a Textbook on Tumours', p.879, 1st Edition, Philadelphia, Saunders, 1919.

Feyrter, F. 'Über die These von den peripheren endocrinen Drüsen', Wiener Zeitschrift für Innere Medizin, 27:9-37, 1946.

Feyrter, F. 'Zur Normung der Silberimprägnation neuraler und nichtneuraler Gewebe', Virchows Archiv, 320:551-563, 1951.

Fisher, E.R. and Lillie, R.D. 'The effect of methylation on basophilia', Journal of Histochemistry and Cytochemistry, 2: 81-88, 1954.

Foster, G.V., Baghdiantz, A., Kumar, M.A., Slack, E., Soliman H.A. and MacIntyre, I. 'Thyroid origin of calcitonin', Nature, 202:1303-1305, 1964a.

Foster, G.V., MacIntyre, I. and Pearse, A.G.E. 'Calcitonin production and the mitochondrion rich cells of the dog thyroid', Nature, 203:1029-1030, 1964b.

Fraenkel-Conrat, H. and Olcott, H.S. : 'Esterification of proteins with alcohols of low molecular weight', Journal of Biological Chemistry, 161:259-268, 1945.

French, D. and Edsall, J.T. 'The reaction of formaldehyde with amino acids and proteins', pp.277-336, in 'Advances in Protein Chemistry', Eds. Anson, M.L. and Edsall, J.T., Vol.2, New York, Academic Press.

Fullmer, M.H. 'Effect of peracetic acid on the enzymatic digestion of various mucopolysaccharides : reversal of the PAS staining reaction of mucin', Journal of Histochemistry and Cytochemistry, 8:113-121, 1960.

Gabe, M. 'Données Histochimiques sur les Cellules Parafolliculaires de la Glande Thyroïde du Chien', Acta Anatomica, 38:332-344, 1959.

Gabe, M. 'Données Histolgiques sur les Macrothyreocytes (cellules parfolliculaires) de quelques Sauropsides et Anamniotes', Acta Anatomica, 47:34-54, 1961.

Gabler, W. and Scheuner, G. 'Zur Spezifität der Dihydroxy-Dinaphthyl-Disulfid (DDD)-Reaktion'. Acta Histochemica, 23:102-109. 1966.

Galante, L., Gudmundsson, T.V., Matthews, E.W., Tse, A., Williams, E.D., Woodhouse, N.J.Y. and MacIntyre, I. 'Thymic and parathyroid origin of calcitonin in man', Lancet, 2:537-539, 1968.

Gerebtzoff, M.A 'Recherches Histochimiques sur les Acétylcholine et Choline Estérases', Acta Anatomica, 19:366-379, 1953.

Glenner, G.G. 'Re-evaluation of the ninhydrin-Schiff reaction', Journal of Histochemistry and Cytochemistry, 11:285-286, 1963.

Glenner, G.G. and Lillie, R.D. 'Pepsin release of guinea-pig enterochromaffin substance', Journal of Histochemistry and Cytochemistry, 7: 204, 1959a.

Glenner, G.G. and Lillie, R.D. 'Observations on the diazotization-coupling reaction for the histochemical demonstration of tyrosine : metal chelation and formazan variants', Journal of Histochemistry and Cytochemistry, 7:416-424, 1959b.

Godwin, M.C. 'Complex IV in the dog with special emphasis on the relation of the ultimobranchial body to interfollicular cells in the post-natal thyroid gland', American Journal of Anatomy, 60. 299-339, 1937.

Gomori,G. 'A new histochemical test for glycogen and mucin',American Journal of Clinical Pathology,(Technical Section), 10:177-179, 1946.

Gomori, G. 'Microscopic Histochemistry, Principles and Practice', Chicago, University of Chicago Press, 1952.

Gottlob, R. and Hoff, H F. 'Histochemical investigations on the nature of large blood vessel endothelial and medial argyrophilic lines and on the mechanism of silver staining, Histochemie, 13:70-83, 1968.

Grandi, de P., 'The routine demonstration of 'C' cells in human and animal thyroid glands. Virchows Archiv (Zell Pathologie), 6:137-150, 1970.

Gray, P. 'The Microtomists Formulary and Guide', London, Constable, 1954.

Gray, W.R. 'Dansyl chloride procedure', pp.139-150 in 'Methods in Enzymology', Vol.XI, Ed. C.H.W. Hirs, New York, Academic Press, 1967.

Greenberg, D.M. 'Amino Acids and Proteins', Springfield, Charles Thomas, 1951.

Greenspan, F.P. 'The convenient preparation of per-acids', Journal of the American Chemical Society, 68:907, 1946.

Greiff, D. 'Protein structure and freeze drying : the effects of residual moisture and gases', Cryobiology, 8:145-152, 1971.

Grillo, T.A., Ogunnaire, P.O. and Fadye,S. 'Effects of histological and electron microscopical fixatives on the insulin content of rat pancreas',Journal of Endocrinology, 51:645-649, 1971.

Grimelius, L. 'A silver nitrate stain for α_2 cells in human pancreatic islets', Acta Societatis medicorum upsaliensis, 73:243-270, 1968a.

Grimelius, L. 'The argyrophil reaction in islet cells of adult human pancreas studied with a new silver nitrate procedure', Acta Societatis medicorum upsaliensis, 73:271-294, 1968b.

Grogg, E. and Pearse, A.G.E. 'Coupling azo-dye methods for histochemical demonstration of alkaline phosphatase', Nature, 170: 578-579, 1952.

Gross, E. and Witkop, B. 'Selective cleavage of the methionyl peptide bonds in ribonuclease with cyanogen bromide', Journal of the American Chemical Association, 83:1510-1511, 1961.

Gross, E. 'The cyanogen bromide reaction', pp.238-255, in 'Methods in Enzymology', Vol. XI, Ed. Hirs, C.H.W., New York, Academic Press, 1967.

Gros-Schultze, As quoted by P. Gray, p.583, in 'The Microtomists Formulary and Guide', London, Constable, 1954.

Gurr, E. 'Synthetic Dyes in Biology, Medicine and Chemistry', London, Academic Press, 1971.

Hackeng, W.H.L. and Schopman, W. 'The radioimmunoassay of calcitonin' pp.101-103, in 'Immunological Methods In Endocrinology' Eds. Federlin, K., Hales, C.N. and Kracht, J., Stuttgart, Thieme, 1971.

Hakanson, R., Lundquist, I., Melander,A., Owman, Ch., Sjöberg, N.-O. and Sundler, F. 'Significance of amines in polypeptide-secreting endocrine cells with special regard to C cells', pp.184-191. in 'Endocrinology 1971, Proceedings of the Third International Symposium', Ed. Taylor, S., London, Heinemann, 1972.

Hakanson, R., Owman, Ch. and Sundler, F. 'Fluorescent histochemical and microspectrofluorometric evidence of tryptophyl peptides in thyroid C cells of cat and pig', Journal of Histochemistry and Cytochemistry, 20:205-210, 1972.

Hake, T. 'Studies on the reaction of OsO_4 and $KMnO_4$ with amino acids, peptides and proteins'. Laboratory Investigation, 14:470-474, 1965.

Halmi, N.S. and Davies, J. 'Comparison of aldehyde fuchsin staining, metachromasia and periodic acid-Schiff reactivity of various tissues', Journal of Histochemistry and Cytochemistry, 1: 447-453, 1953.

Hamilton, L.D.G. 'The estimation of side chain groups in intact protein', pp.59-100, in 'A Laboratory Manual of Analytical Methods of Protein Chemistry (Including Polypeptides)', Vol.2, Eds. Alexander, P. and Block, R.J., Oxford, Pergamon Press, 1960.

Hamperl, H. 'Über das vorkommen von Onkocyten in verschiedenen Organen und ihren Geschwülsten', Virchows Archiv (Patholgische Anatomie), 298:327-375, 1937.

Hamperl, H. 'Benign and malignant oncocytoma', Cancer, 15:1019-1027, 1962.

Harcourt-Webster, J.H. and Stott, N.C.H. 'Histochemical study of oxidative and hydrolytic enzymes in the human thyroid', Journal of Pathology and Bacteriology, 92:291-301, 1966.

Hartley, B.S. 'Strategy and tactics in protein chemistry', Biochemical Journal, 119:805-822, 1970.

Heimann, P., Ljunggren, J.G., Löwhagen, T. and Hjern,B. 'Oxyphilic adenoma of the human thyroid', Cancer, 31:246-254, 1973.

Hellman, B. and Hellerström, C. 'The specificity of the argyrophil Reaction in the islet of Langerhans in man', Acta Endocrinolgica (Kbh), 36:22-30, 1961.

Hess, R., Scarpelli, D.G. and Pearse, A.G.E. 'The cytochemical localization of oxidative enzymes II : Pyridine nucleotide-linked dehydrogenases' Journal of Biophysical and Biochemical Cytology, 4:753-760 1958.

Hill, R.L. 'Hydrolysis of proteins', pp.37-108, in 'Advances in Protein Chemistry', Vol. 20, Eds. Anfinsen, C.B., Anson, M.L., Edsall, J.T. and Richards, F.M., New York, Acadamic Press, 1965

Hirs, C.H.W. 'Performic acid oxidation', pp.197-199, in 'Methods in Enzymology', Vol.XI, Ed. Hirs, C.H.W., New York, Academic Press, 1967.

Hirsch, P.F., Gauthier, G.F. and Munson, P.L. 'Thyroid hypocalcaemic principle and recurrent laryngeal nerve injury as factors affecting the response to parathyroidectomy in rats', Endocrinology, 73:244-252, 1963.

Hirsch, P.F., Voelkel, E.F. and Munson, P.L. 'Thyrocalcitonin : hypocalcaemic hypophosphataemic principle of the tyroid gland',Science,146: 412-413, 1964.

Holmes, W. 'Empiricism - Silver methods and the nerve axon', pp 95-102, in 'Cell Structure and Its Interpretation', Eds. McGee-Russell, S.M. and Ross, K.F.A., London, Edward Arnold, 1968.

Holt, S.J. 'A new approach to the cytochemical localization of enzymes', Proceedings of the Royal Society (Biology), 142:160-169, 1954.

Holt, S.J. and Withers, R.F.J. 'Studies in enzyme cytochemistry V. An appraisal of indogogenic reactions for esterase localization', Proceedings of the Royal Society (Biology), 148:520-532, 1958.

Hopwood, D. 'The periodic acid-Schiff reaction in the adrenal medulla', Histochemie, 12:363-370, 1968.

Hopwood,D. 'A comparison of the crosslinking abilities of glutaraldehyde formaldehyde and α-hydroxyadipaldehyde with bovine serum albumin and casein', Histochemie, 17:151-161, 1969.

Hopwood,D. 'Theoretical and practical aspects of glutaraldehyde fixation', Histochemical Journal, 4:267-304, 1972.

Hotchkiss, R.D. 'A microchemical reaction resulting in the staining of polysaccharide structures in fixed tissue preparations', Archives of Biochemistry, 16:131-141, 1948.

Hürthle, K. 'Beiträge zur kenntniss der secretionsvorgangs in der schilddrüse', Archiv gesammte Physiologie, 56:1-44, 1894.

Jaim Etcheverry, G. and Zieher, L.M. 'Cytochemistry of 5-hydroxytryptamine at the electron microscopic level I : Study of the specificity of the reaction in isolated blood platelets', Journal of Histochemistry and Cytochemistry, 16:162-171, 1968.

Jaim Etcheverry, G. and Zieher, L M. 'Ultrastructural aspects of neurotransmitter storage in adrenergic nerves', pp.343-361 in 'Advances in Cytopharmacology', Eds. Clementi, F. and Ceccarelli,B., Vol. 1, New York, Raven Press, 1971.

Jocelyn, P.C. 'Biochemistry of the SH Group', New York, Academic Press, 1972.

Kalina, M., Foster, G.V., Clark, M.B. and Pearse, A.G.E. 'C cells in man', pp.268-273, in 'Calcitonin 1969, Proceedings of the Second International Symposium', Ed. Taylor, S., London, Heinemann, 1970.

Kalina, M. and Pearse, A.G.E. 'Ultrastructural localization of calcitonin in C-cells of dog thyroid : an immunocytochemical study', Histochemie, 26:1-8, 1971.

Kameda, Y. 'Parafollicular cells of the thyroid as studied with Davenport's silver impregnation', Archivum histologicum japonicum, 30:83-94, 1968.

Kameda, Y. 'The occurrence of a special parafollicular complex in and beside thedog thyroid gland', Archivum histologicum japonicum, 33:115-132, 1971.

Karnovsky, M.J. and Fasman, G.D. 'A histochemical method for distinguishing between side-chain and terminal (acyl-amido) carboxyl groups of proteins', Journal of Biophysical and Biochemical Cytology, 8:319-325, 1960.

Kasten, F.H. 'The chemistry of Schiff's reagent', pp.1-100 in 'International Review of Cytology', eds. Bourne, G.H. and Danielli,J.F., Vol.10, New York, Academic Press, 1960.

Kaufman, B.P., Gay, H. and MacDonald, M.R. 'Localization of cellular proteins by enzymatic hydrolysis', Cold Spring Harbour Symposium on Quantitative Biology, 14:85-91, 1950.

Kiant, F.W., Riniker, B., MacIntyre, I. and Neher, R. 'Thyrocalcitonin I : Isolierung und charakterisierung werksamer Peptide aus Schweineschilddrüsen', Helvetica Chemica Acta, 151:214-217, 1968.

Kobayashi, N., Landing, B. and Wilson, H.E. 'Histochemical analysis of thyroid colloid in various functional states', Laboratory Investigation, 8:403-412, 1959.

Kracht, J., Machmeister, U. and Christ, J. 'C cells in the human thyroid', pp. 274-280 in 'Calcitonin 1969, Proceedings of the Second International Symposium', Ed. Taylor, S., London, Heinemann, 1970.

Kugler, J.H. and Wilkinson, W.J.C. 'Glycogen fractions and their role in the histochemical detection of glycogen', Journal of Histochemistry and Cytochemistry, 8:195-199, 1960.

Kutsky, R.J. 'Handbook of Vitamins and Hormones', p.186, New York, van Nostrand Rheinhold, 1973.

Kvistberg, D., Lester, G. and Lazarow, A. 'Staining of insulin with aldehyde fuchsin', Journal of Histochemistry and Cytochemistry, 14:609-611, 1966.

Lamm, M.E., Childers, L. and Wolf, M.K. 'Studies on nucleic acid metachromasy', Journal of Cell Biology, 27:313-326, 1965.

Landing, B.H., Hall, M.E. and West, C.D. 'Aldehyde-fuchsin positive material of the pituitary', Laboratory Investigation, 5:256-266, 1956.

Leblond, C.P., Glegg, R.E. and Eidinger, D. 'Presence of carbohydrates with free 1,2-glycol groups in sites stained by the periodic acid-Schiff technique', Journal of Histochemistry and Cytochemistry, 5:445-459, 1957.

Leach, S.J. 'The estimation of thiol and disulphide groups', pp.1-76, in 'A Laboratory Manual of Analytical Methods of Protein Chemistry', Vol. 4, Eds., Alexander, P. and Lundgren, H.P., Oxford, Pergamon Press, 1966.

Lennox, B. 'The large-cell small-acinar thyroid tumour of Langhans and the incidence of related cell groups in the human thyroid', Journal of Pathology and Bacteriology, 60:295-305, 1948.

Leppi, T.J. and Steward, P.J. 'On the use of testicular hyaluronidase for identifying acid mucins in tissue sections', Journal of Histochemistry and Cytochemistry, 13:406-407, 1965.

Lev, R. and Gerard, A. 'The histochemical demonstration of protein in epithelial mucins', Journal of the Royal Microscopical Soi Society, 87:361-373, 1967.

Levy, G.A. and Marsh, C.A. 'Preparation and properties of beta glucuronidase', pp.381-428 in 'Advances in Carbohydrate Chemistry', Eds. Wolfrom, M.L. and Tipson, R.S., Vol. 14 , New York, Academic Press, 1959.

Lhotka, J.F. 'Some histochemical observations on periodic acid-amino acid mechanisms', Nature, 171:1123-1124, 1953.

Lietz, H. and Donath, K. 'Cytochemical evidence for the presence of hormonal peptides in thyroid C cells', pp.227-239, in 'Calcitonin 1969, Proceedings of the Second International Symposium', Ed. Taylor, S., London, Heinemann, 1970.

Lietz, H. 'C-cells : source of calcitonin. A morphological review', Current Topics in Pathology, 55:109-146, 1971.

Kugler, J.H. and Wilkinson, W.J.C. 'Glycogen fractions and their role in the histochemical detection of glycogen', Journal of Histochemistry and Cytochemistry, 8:195-199, 1960.

Kutsky, R.J. 'Handbook of Vitamins and Hormones', p.186, New York, van Nostrand Rheinhold, 1973.

Kvistberg, D., Lester, G. and Lazarow, A. 'Staining of insulin with aldehyde fuchsin', Journal of Histochemistry and Cytochemistry, 14:609-611, 1966.

Lamm, M.E., Childers, L. and Wolf, M.K. 'Studies on nucleic acid metachromasy', Journal of Cell Biology, 27:313-326, 1965.

Landing, B.H., Hall, M.E. and West, C.D. 'Aldehyde-fuchsin positive material of the pituitary', Laboratory Investigation, 5:256-266, 1956.

Leblond, C.P., Glegg, R.E. and Eidinger, D. 'Presence of carbohydrates with free 1,2-glycol groups in sites stained by the periodic acid-Schiff technique', Journal of Histochemistry and Cytochemistry, 5:445-459, 1957.

Leach, S.J. 'The estimation of thiol and disulphide groups', pp.1-76, in 'A Laboratory Manual of Analytical Methods of Protein Chemistry', Vol. 4, Eds., Alexander, P. and Lundgren, H.P., Oxford, Pergamon Press, 1966.

Lennox, B. 'The large-cell small-acinar thyroid tumour of Langhans and the incidence of related cell groups in the human thyroid', Journal of Pathology and Bacteriology, 60:295-305, 1948.

Leppi, T.J. and Stoward, P.J. 'On the use of testicular hyaluronidase for identifying acid mucins in tissue sections', Journal of Histochemistry and Cytochemistry, 13:406-407, 1965.

Lev, R. and Gerard, A. 'The histochemical demonstration of protein in epithelial mucins', Journal of the Royal Microscopical Sci Society, 87:361-373, 1967.

Levy, G.A. and Marsh, C.A. 'Preparation and properties of beta glucuronidase', pp.381-428, in 'Advances in Carbohydrate Chemistry', Eds. Wolfrom, M.L. and Tipson, R.S., Vol. 14 , New York, Academic Press, 1959.

Lhotka, J.F. 'Some histochemical observations on periodic acid-amino acid mechanisms', Nature, 171:1123-1124, 1953.

Lietz, H. and Donath, K. 'Cytochemical evidence for the presence of hormonal peptides in thyroid C cells', pp.227-239, in 'Calcitonin 1969, Proceedings of the Second International Symposium', Ed. Taylor, S., London, Heinemann, 1970.

Lietz, H. 'C-cells : source of calcitonin. A morphological review', Current Topics in Pathology, 55:109-146, 1971.

Light, A. 'Partial acid hydrolysis', pp.417-420, In 'Methods In Enzymology', Ed. Hirs, C.H.W., Vol. XI, New York, Academic Press, 1967.

Lillie, R.D. 'Reticulin staining with Schiff reagent after oxidation by acidified sodium periodate', Journal of Laboratory and Clinical Medicine, 32:910-912, 1947.

Lillie, R.D. 'Histopathologic Technic and Practical Histochemistry', 2nd Edition, New York, Blakiston, 1954.

Lillie, R.D. 'Argentaffin and Schiff reactions after periodic acid oxidation and aldehyde blocking reactions', Journal of Histochemistry and Cytochemistry, 2:127-136, 1954.

Lillie, R.D. 'Acetylation and nitrosation of tissue amines in histochemistry', Journal of Histochemistry and Cytochemistry, 6:352-362, 1958.

Lillie, R.D. 'Histochemical acetylation of hydroxyl and amino groups. Effects on the periodic acid Schiff reaction, anionic and cationic dye and von Gieson collagen stains', Journal of Histochemistry and Cytochemistry, 12:821-841, 1964.

Lillie, R.D. 'Histopathologic Technic and Practical Histochemistry' 3rd Edition, New York, Blakiston, 1965.

Lillie, R.D. 'Histochemical acetylation of aldehydes produced by periodic acid oxidation', Journal of Histochemistry and Cytochemistry, 14:529-537, 1966.

Lillie, R.D., Bangle, R. and Fisher, E.R. 'Metachromatic basophilia of keratin after oxidation-cleavage of disulfide bonds', Journal of Histochemistry and Cytochemistry, 2:95-102, 1954.

Lillie, R.D. and Glenner, G.G. 'Histochemical aldehyde blockade by aniline in glacial acetic acid', Journal of Histochemistry and Cytochemistry, 5:167-169, 1957.

Lillie, R.D., Greco, J. and Laskey, A. 'Histochemical studies with malt diastase: partial separation of the fractions destroying cytoplasmic basophilia (ribonucleic acid) and the metachromasia of cartilage', Anatomical Record, 103:635-647, 1949.

Lillis, de R.A., and Balogh, K. 'Histochemical characteristics of parafollicular cells and medullary thyroid carcinoma', American Journal of Pathology, 72:119-124, 1972.

Ljungberg, O. 'Argentaffin cells in human thyroid and parathyroid and their relationship to C cells and medullary carcinoma', Acta Pathologica Scandinavia (A), 80:589-599, 1972.

Lovell, F.W., Stevenson, C.F. and Wartman, W.B. 'Amylase digestion of thyroid colloid', Archives of Pathology, 61:62-64, 1956.

Lovelock, J.E. 'The denaturation of lipid-protein complexes as a cause of damage by freezing', Proceedings of the Royal Society (Series, B), 147:427-433, 1957.

Ludwig, K.S. 'Beiträge zur Schilddrüsenstruktur III. Zur Frage der Makrothyreocyten in der Schilddrüse nebst histophysiologischen Bemerkungen', Acta Anatomica, 20: 1-36, 1954.

MacConaill, M.A. and Gurr, E. 'Parafalg staining of acidic tissues', Irish Journal of Medical Science, 6th Series, pp.481-485, 1963.

Maddy, A.H. 'I-Fluoro-2:4-dinitrobenzene as a cytochemical reagent', pp. 259-286. in 'General Cytochemical Methods', Vol.2, Ed. Danielli, J.F., New York, Academic Press, 1961.

Mallory, F.B. 'On certain improvements in histological technique', Journal of Experimental Medicine, 2:529-533, 1897.

Mancini, A.M., Frizzera, G. and Vecchi, A. 'Histochemical properties of insular β-cells after short tryptic digestion', Histochemie, 6:301-304, 1966.

Mander, S.T.K., Mander, L.N. and Carmichael, G.G. 'The staining mechanism of aldehyde-fuchsin with reference to the oxytalan fiber in the mouse', Journal of Histochemistry and Cytochemistry, 16: 480-485, 1968.

Mannochio, I. 'Metachromatische färbung der A-zellen in pankreas inseln von "Canis familiaris" ', Zentrallblatt fur Allgemeine Pathologie, 101:1-4, 1960.

Mannochio, I. 'The metachromatic 'A' cells in the pancreatic islets of dogs of different ages', pp.105-116 in 'The Structure and Metabolism of the Pancreatic Islet Cells' Ed. Brolin, S., Oxford, Pergamon Press, 1964.

Matsuzawa, T. and Kurosumi, K. 'Morphological changes in the parafollicular cells of the rat thyroid glands after administration of calcium shown by electron microscopy', Nature, 213:927-928, 1967.

Mazur,P. 'Theoretical and experimental effects of cooling and warming velocity on the survival of frozen and thawed cells', Cryobiology, 2:181-192, 1966.

Mazur, P. 'Cryobiology : The freezing of biological systems', Science, 168:939-949, 1970.

McManus, J.F.A. 'The histological demonstration of mucin after periodic acid', Nature, 158:202-203, 1946.

McManus, J.F.A. 'The periodic acid routine applied to the kidney', American Journal of Pathology, 24:643-654, 1948.

McManus, J.F.A. and Cason, J.E. 'Carbohydrate histochemistry studied by acetylation techniques', Journal of Experimental Medicine, 91: 651-654, 1950.

McManus, J.F.A. and Mowry, R.W. 'Staining Methods - Histologic and Histochemical', p.126, Harper and Row, New York, 1964.

McMillan, P.J., Hooker,W.M. and Deftos, L.J. 'Distribution of calcitonin-containing cells in the human thyroid', American Journal of Anatomy, 140:73-80, 1974.

Meryman, H.T. 'The interpretation of freezing rates in biological materials, Cryobiology, 2:165-170, 1966.

Meryman, H.T. 'Cryoprotective Agents', Cryobiology, 8:173-183, 1971.

Meyer, J.S., Hutton, E.W. and Kenny, A.D. 'Medullary carcinoma of the thyroid gland - subcellular distribution and relationship between granules and amyloid' Cancer, 31:433-441, 1973.

Mitchell, A.J. and Wislocki, G.B. 'Selective staining of glycogen by ammoniacal silver nitrate : a new method', Anatomical Record, 90:261-266, 1945.

Moore, R.D. and Schoenberg, M.D. 'Studies on connective tissue IV. The mast cell and its relation to the ground substance. Polysaccharides of the human umbilical cord', Laboratory Investigation, 7:418-425, 1958.

Moore, S. and Stein, W.H. 'Photometric ninhydrin method for use in the chromatography of amino acids', Journal of Biological Chemistry, 176:367-388, 1948.

Mowry, R.W. 'Improved procedure for the staining of acidic polysaccharides by Muller's colloidal (hydrous) ferric oxide and its combination with the Feulgen and the periodic acid Schiff reactions', Laboratory Investigation, 7:566-576, 1958.

Mowry, R.W. 'Revised method producing improved coloration of acidic polysaccharides with Alcian Blue 8GX supplied currently', Journal of Histochemistry and Cytochemistry, 8:323, 1960.

Mowry, R.W. 'The special value of methods that color both acidic and vicinal hydroxyl groups in the histochemical study of mucins with revised directions for the colloidal iron stain, the use of Alcian Blue 8GX and their combinations with the periodic acid-Schiff reaction, Annals of the New York Academy of Science, 106:402-423, 1963.

Müller,G. 'Kolloidchemische untersuchunger zur eisenhydroxydsol reaktion', Acta Histochemica, 17:61-72, 1964.

Nachlas,M.M., Tsou, K.C., de Souza, E, Cheng, C.S., Seligman, A.M. 'Cytochemical demonstration of succinic dehydrogenase by the use of a new p-nitrophenyl substituted ditetrazole', Journal of Histochemistry and Cytochemistry, 5:420-436, 1957.

Neher, R., Riniker, B., Zuber, H., Rittel, W. and Kahnt, F.W. 'Thyrocalcitonin II. Struktur von thyrocalcitonin', Helvetica Chimica Acta, 51: 917-924, 1968.

Neurath, H. 'The Proteins. Composition, Structure and Function', Vol. I, 2nd Edition, New York, Academic Press, 1963.

Nonidez, J.F. 'The origin of the parafollicular' cell, a second epithelial component of the thyroid gland of the dog', American Journal of Anatomy, 49:479-505, 1932.

Ortman, R., Forbes, W.F. and Balasubramanian, A. 'Concerning the staining properties of aldehyde basic fuchsin', Journal of Histochemistry and Cytochemistry, 14:104-111, 1966.

Pearse, A.G.E. 'A review of modern methods in histochemistry', Journal of Clinical Pathology, 4:1-36, 1951.

Pearse, A.G.E. 'Application of the alkaline tetrazolium reaction to the study of reducing groups in tissue sections', Journal of Pathology and Bacteriology, 67:129-136, 1954.

Pearse, A.G.E. 'Intracellular localisation of dehydrogenase systems using monotetrazolium salts and metal chelation of their formazans', Journal of Histochemistry and Cytochemistry, 9:515-527, 1960.

Pearse, A.G.E. 'The cytochemistry of the thyroid C cells and their relationship to calcitonin', Proceedings of the Royal Society (B), 164:478-487, 1966 .

Pearse, A.G.E. 'Histochemistry', Vol. 1, 3rd Edition, London, Churchill, 1968a.

Pearse, A.G.E. 'Common cytochemical properties of cells producing polypeptide hormones (the APUD series) and their relevance to thyroid and ultimobranchial C cells and calcitonin', Proceedings of the Royal Society (B), 170:71-80, 1968b.

Pearse, A.G.E. 'The cytochemistry and ultrastructure of polypeptide hormone-producing cells of the APUD series and the embryologic, physiologic and pathologic implications of the concept', Journal of Histochemistry and Cytochemistry, 17:303-313, 1969a.

Pearse, A.G.E. 'Cytochemical evidence for random-coil conformation in the protein precursors of polypeptide hormones', Nature, 221: 1210-1211, 1969b.

Pearse, A.G.E. 'The characteristics of the C cell and their significance in relation to those of other endocrine polypeptide cells and to synthesis, storage and secretion of calcitonin', pp.125-140, in 'Calcitonin 1969. Proceedings of the Second International Symposium, Ed. Taylor, S., London, Heinemann, 1970.

Pearse, A.G.E. 'Histochemistry', Vol. 2, 3rd Edition, London, Churchill-Livingstone, 1972.

Pearse, A.G.E. and Carvalheira, A.F. 'Cytochemical evidence for all ultimobranchial origin of rodent thyroid C cells', Nature, 214:929-930, 1967.

Pearson, C.K. 'A formalin-sucrose ammonia fixative for cholinesterases', Journal of Histochemistry and Cytochemistry, 11:665-666, 1963.

Pease, D.C. 'The preservation of tissue fine structure during rapid freezing', Journal of Ultrastructural Research, 21: 98-124, 1967.

Pepler, W.J. and Pearse, A.G.E. 'A histochemical study of the esterases of rat thyroid and their behaviour under experimental conditions', British Journal of Experimental Pathology, 38: 221-226, 1957.

Peters, A. 'Experiments on the mechanism of silver staining', Part I. Impregnation', Quarterly Journal of Microscopic Science, 96: 84-102, 1955a.

Peters, A. 'Experiments on the mechanism of silver staining, Part II. Development', Quarterly Journal of Microscopic Science, 96: 103-115, 1955b.

Pickett-Heaps, J.D. 'Preliminary attempts at ultrastructural polysaccharide localization in root tip cells', Journal of Histochemistry and Cytochemistry, 15:442-455, 1967.

Piercy, J.E. 'Surgery of the thyroid gland', pp.203-230 in 'Operative Surgery', Vol. 6, 2nd Edition, Eds. Rob,C. and Smith, R., London, Butterworths, 1969.

Pitt-Rivers, R. and Schwartz, H.L. 'The thiol groups of thyroglobulin', Biochemical Journal, 105:28c-29c, 1967.

Potts, J.T. (Jr.), Reisfeld, R.A., Hirsch, F.F. and Munson, P.L. 'Chemical properties of porcine thyrocalcitonin', American Journal of Medicine, 43:662-667, 1967.

Potts, J.T. (Jr), Niall, H.D., Keutmann, H.T., Brewer, H.B. and Deftos, L.J. 'The amino acid sequence of porcine thyrocalcitonin', Proceedings of the National Academy of Sciences', 59:1321-1328, 1968.

Puchtler, H. and Sweat, F. 'Some comments on the Ninhydrin-Schiff reaction', Journal of Histochemistry and Cytochemistry, 10:365, 1962.

Purves, H.D. and Griesbach, W.E. 'Specific staining of the thyrotrophic cells of the rat pituitary by the Gomori stain', Endocrinology, 49:427-428, 1957.

Quintarelli, G. 'Histochemical identification of the salivary mucins', Annals of the New York Academy of Science, 106:339-363, 1963.

Rambourg, A., Neutra, M. and Leblond, C.P. 'Presence of a 'cell coat' rich in carbohydrate at the surface of cells in the rat', Anatomical Record, 154:41-72, 1965.

Raymond, N. 'The occurrance of parafollicular cells in the thyroid of the rabbit', Anatomical Record, 53:355-360, 1932.

Rebhun, L.I. 'Freeze substitution : fine structure as a function of water concentration in cells', Federation Proceedings, 24, Supp.15: 5217-5232, 1965.

Ringertz, N.R. 'Cytochemical demonstration of basic protein by dansyl staining', Journal of Histochemistry and Cytochemistry, 16: 440-441, 1968.

Riniker, B. Neher, R., Maier, R., Kahnt, F.W., Byfield, P.G.H., Gudmundsson, T.V., Galante, L. and MacIntyre, I. 'Menschliches Calcitonin. I. Isolierung und charakterisierung', Helvetica chimica Acta, 51:1738-1742, 1968.

Riordan, J.F. and Vallee, B.L. 'Reaction with N-ethyl-maleimide and p-mercuribenzoate', pp 541-548, in 'Methods In Enzymology', Vol. XI Ed. Hirs, C.H.W., New York, Academic Press, 1967.

Rittel, W., Brugger, M., Kamber, B., Riniker, B. and Sieber, P. "Thyrocalcitonin. III. Die synthese des αthyrocalcitonins', Helvetica chimica Acta, 51:924-928, 1968.

Robbins, J., Rall, J.E. and Gordon, P. "Thyroglobulin and its synthesis". p.1013, in 'Disease of Metabolism', 7th Edition, Eds. Bondy. P.K., and Rosenberg, L.E., Philadelphia, W.B. Saunders, 1974.

Roediger, W.E.W. 'A comparative study of the normal human neonatal and the canine thyroid C cell', Journal of Anatomy, 115:255-276, 1973.

Roediger, W.E.W. 'The nature of silver binding in the canine thyroid C cell', South African Journal of Medical Science, 38: 17-22, 1973.

Roediger, W.E.W. 'The oxyphil and C cells of the human thyroid gland. A cytochemical and histopathologic review', Cancer, 36: 1758-1770, 1975.

Roediger, W.E.W. 'Thyroidectomy for non-familial medullary carcinoma', British Journal of Surgery, 63:343-345, 1975.

Roediger, W.E.W. 'Derivation of carboxyl groups for the 'masked metachromasia' of canine C cells by hydrolysis of polypeptides at the aspartyl group', Histochemical Journal (accepted for publication, Sept.1976).

Roediger, W.E.W., Spitz, L. and Schmaman, A. 'Histogenesis of benign cervical teratomas', Teratology, 10:111-118, 1974.

Rosselet, A. and Ruch, F. 'Cytofluorometric determination of lysine with dansyl chloride', Journal of Histochemistry and Cytochemistry, 16:459-466, 1968.

Rost, M.C.M. and Rost, F.W.D. 'Storage granules of thyroid C cells in the dog : a cytochemical and ultrastructural study, in relation to the masked metachromasia reaction', Histochemical Journal, 7: 307-320, 1975.

Rosa, F. and Johnson, F.B. 'Enzymatic digestion in the cytochemical demonstration of glycogen', Journal of Histochemistry and Cytochemistry, 15:14-20, 1967.

Roth, S.I., Olen, E. and Hansen, L.S. 'The eosinophilic cells of the parathyroid (oxyphil cells), salivary (oncocytes) and thyroid (Hürthle) glands', Laboratory Investigation, 11: 933-941, 1962.

Samuel, E.P. 'Impregnation and development in silver staining', Journal of Anatomy, 87:268-277, 1953a.

Samuel, E.P. 'The mechanism of silver staining', Journal of Anatomy, 87 278-287, 1953b.

Sanderson, P.H., Marshall, F. and Wilson, R.E. 'Calcium and phosphorous homeostasis in the parathyroidectomized dog; evaluation by means of ethylenediaminetetra-acetate and calcium tolerance test', Journal of Clinical Investigation, 39:662-670, 1960.

Sandritter, W., and Klein, K.H. 'Über argyrophile zellen in der Schilddrüse', Frankfurter Zeitschrift für Pathologie, 65:204-218, 1954.

Sandritter, W., Kummer, E., Pillat, G. and Rowe, L. 'Zur Histochemie und Funktion der parafollikulären Zellen in der Schilddrüse Klinische Wochenschrift, 34:871-872, 1956.

Sanger, F. 'The free amino groups of insulin', Biochemical Journal, 39:507-515, 1945.

Sanger, F. 'Chemistry of insulin', British Medical Bulletin, 16: 83-188, 1960.

Schmidt, C.L.A. 'The Chemistry of the Amino Acids and Protein', pp.487-505, Springfield, Thomas, 1938.

Schmitz-Moorman, P. 'Zur Histochemie der Neuraminsäure', Histochemie, 20:78-86, 1969.

Schubert, M. and Hamperman, D. 'Metachromasia, chemical theory and histochemical use', Journal of Histochemistry and Cytochemistry, 4:159-189, 1956.

Schultz-Haudt, S.D. 'Comparative histochemistry of a glycoprotein from human aorta', Histochemie, 27:205-215, 1971.

Scott, H.R. 'Rapid staining of beta cell granules in pancreatic islets', Stain Technology, 27:267-268, 1952.

Scott, H.R. and Clayton, F.P. 'A comparison of the staining affinities of aldehyde-fuchsin and the Schiff reagent, Journal of Histochemistry and Cytochemistry, 1:336-352, 1953.

Scott, J.E. 'Phosphotungstic acid - 'Schiff-reactive' but not a glycol reagent', Journal of Histochemistry and Cytochemistry, 21: 1084-1085, 1973.

Rosa, F. and Johnson, F.B. 'Enzymatic digestion in the cytochemical demonstration of glycogen', Journal of Histochemistry and Cytochemistry, 15:14-20, 1967.

Roth, S.I., Olen, E. and Hansen, L.S. 'The eosinophilic cells of the parathyroid (oxyphil cells), salivary (oncocytes) and thyroid (Hürthle) glands', Laboratory Investigation, 11: 933-941, 1962.

Samuel, E.P. 'Impregnation and development in silver staining', Journal of Anatomy, 87:268-277, 1953a.

Samuel, E.P. 'The mechanism of silver staining', Journal of Anatomy, 87 278-287, 1953b.

Sanderson, P.H., Marshall, F. and Nelson, R.E. 'Calcium and phosphorous homeostasis in the parathyroidectomized dog; evaluation by means of ethylenediaminetetra-acetate and calcium tolerance test', Journal of Clinical Investigation, 39:662-670, 1960.

Sandritter, W., and Klein, K.H. 'Über argyrophile zellen in der Schilddrüse', Frankfurter Zeitschroft für Pathologie, 65:204-218, 1954.

Sandritter, W., Kummer, E., Pillat, G. and Rowe, L. 'Zur Histochemie und Funktion der parafollikulären Zellen in der Schilddrüse, Klinische Wochenschrift, 34:871-872, 1956.

Sanger, F. 'The free amino groups of insulin', Biochemical Journal, 39:507-515, 1945.

Sanger, F. 'Chemistry of insulin', British Medical Bulletin, 16:183-188, 1960.

Schmidt, C.L.A. 'The Chemistry of the Amino Acids and Protein', pp.487-505, Springfield, Thomas, 1938.

Schmitz-Moorman, P. 'Zur Histochemie der Neuraminsäure', Histochemie, 20:78-86, 1969.

Schubert, M. and Hamerman, D. 'Metachromasia, chemical theory and histochemical use', Journal of Histochemistry and Cytochemistry, 4:159-189, 1956.

Schultz-Haudt, S.D. 'Comparative histochemistry of a glycoprotein from human aorta', Histochemie, 27:205-215, 1971.

Scott, H.R. 'Rapid staining of beta cell granules in pancreatic islets', Stain Technology, 27:267-268, 1952.

Scott, H.R. and Clayton, B.P. 'A comparison of the staining affinities of aldehyde-fuchsin and the Schiff reagent, Journal of Histochemistry and Cytochemistry, 1:336-352, 1953.

Scott, J.E. 'Phosphotungstic acid - 'Schiff-reactive' but not a glycol reagent', Journal of Histochemistry and Cytochemistry, 21: 1084-1085, 1973.

Scott, J.E. and Dorling, J. 'Differential staining of acid glycosaminoglycans (mucopolysaccharides) by alcian blue in salt solutions', Histochemie, 5:221-233, 1965.

Scott, J.E., Dorling, J. and Stockwell, R.A. 'Reversal of protein blocking of basophilia in salt solutions :implications in the localization of polyanions using alcian blue', Journal of Histochemistry and Cytochemistry, 16:383-386, 1968.

Scott, J.E. and Webb, J. 'Phosphotungstate : phospholipid interactions. Direct staining and plasmal reactions', Journal of Histochemistry and Cytochemistry, 23:306-308, 1975.

Seecof, O.P. 'Studies on mitochondria - II. The occurrence of mitochondria-rich and mitochondria-poor cells in the thyroid gland of man and animals', American Journal of Pathology, 3:365-384, 1924.

Seligman, A.M., Tsou, K.C. and Barrnett, R.J. 'A new histochemical method for demonstrating protein-bound sulfhydryl groups with 4-hydroxyl-1-naphthyl-N-maleim , Journal of Histochemistry and Cytochemistry, 2:484, 1954.

Silver, M.L. 'Colloidal factors controlling silver staining', Anatomical Record, 82:507-529, 1942.

Silverman, L. and Glick, D. 'The reactivity and staining of tissue proteins with phosphotungstic acid', Journal of Cell Biology,40: 761-767, 1969.

Sippel, T. 'New colored maleimides for the demonstration of bound sulfhydryl', Journal of Histochemistry and Cytochemistry, 17: 428-430, 1969.

Sluyterman, L.A. 'The amperometric titration of sulfhydryl groups with silver nitrate', Biochemica et Biophysica Acta. 25:402-404, 1957.

Smyth, D.G. 'Techniques in Enzymic hydrolysis', pp.214-231 in 'Methods in Enzymology, Vol.XI, Ed. Hirs, C.H.W., New York, Academic Press, 1967.

Smyth, D.G., Nagamatsu, A. and Fruton, J.S. 'Some reactions of N-ethylmaleimide, Journal of the American Chemical Society, 82: 4600-4604, 1960.

Solcia, E., Capella, C., Sampietro, R. and Vassallo, G. 'The distribution of human C cells and their relationship to osteopetrosis and medullary carcinoma of the thyroid', pp.220-226, in 'Calcitonin (1969). Proceedings of the Second International Symposium', Ed. Taylor, S., London, Heinemann, 1970.

Solcia, E. and Sampietro, R. 'New methods for staining secretory granules and 5-hydroxytryptamine in the thyroid C cells', pp.127-132 in 'Calcitonin. Proceedings of the Symposium on Thyrocalcitonin and the C cells', Ed. Taylor, S., London, Heinemann, 1968.

Solcia, E., Vassalo,G. and Capella, C. 'Selective staining of endocrine cells by the basic dyes after acid hydrolysis', Stain Technology, 43:257-263, 1968.

Sousa, de A.T. and Carvalheira, A.F. 'Sur la Caracterisation des Cellules dites Parafolliculaires dans la Thyroide', Comtes Rendus des Association des anatomistes', 143:1636-1640, 1969.

Spande, T.F., Witkop, B., Degani, Y. and Patchornik, A. 'Selective cleavage and modification of peptides and proteins', pp.98-260, In 'Advances in Protein Chemistry', Eds. Anfinsen, C.B., Edsall, J.T. and Richards, F.M., Vol. 24, New York, Academic Press, 1970.

Spicer, S.S. 'Histochemical differentiation of mammalian mucopolysaccharides', Annals of the New York Academy of Science, 106:379-388, 1963.

Spicer, S.S. 'Diamine methods for differentiating mucosubstances histochemically', Journal of Histochemistry and Cytochemistry, 13:211-234, 1965.

Spicer, S.S. and Lillie, R.D. 'Saponification as a means of selectively reversing the methylation of tissue basophilia', Journal of Histochemistry and Cytochemistry, 7:123-126, 1959.

Spicer, S.S. and Meyer, D.B. 'Histochemical differentiation of acid mucopolysaccharides by means of combined aldehyde fuchsin alcian blue staining', American Journal of Clinical Pathology, 33:453-460, 1960.

Spicer, S.S. and Warren, L. 'The histochemistry of sialic acid containing mucoproteins', Journal of Histochemistry and Cytochemistry, 8:135-137, 1960.

Spiro, M.J. 'Studies on the protein portion of thyroglobulin. Amino acid compositions and terminal amino acids of several thyroglobulins', Journal of Biological Chemistry, 245: 5820-5826, 1970.

Spiro, R.G. 'Glycoproteins', pp. 599-638 in 'Annual Review of Biochemistry', Ed. Snell, E.E., Palo Alto, Annual Reviews Inc., 1970.

Steedman, H.F. 'Alcian blue 8GS : A new stain for mucin', Quarterly Journal of Microscopical Science, 91:477-479, 1950.

Stoward, P.J. 'Fixation in Histochemistry', p.47, London, Chapman and Hall, 1973.

Stoward, P.J. and Burns, J. 'Studies in fluorescent histochemistry IV. The distribution of the C-terminal carboxyl groups of proteins', Histochemie, 10:232-233, 1967.

Stoward, P.J. and Burns, J. 'Some evidence confirming the specificity of Barnett and Seligman's technique for demonstrating side chain carboxyl groups in proteins', Histochemie, 13:7-10, 1968.

Stux, M., Thompson, B. Isler, H. and Leblond, C.P. 'The 'light cells' of the thyroid gland in the rat', Endocrinology, 68:292-308, 1961.

Sugiyama, S. 'The embryology of the human thyroid gland, including ultimobranchial body and others related', Advances in Anatomy, Embryology and Cell Biology', 44:I-III, 1971.

Sugiyama, S., Kitoh, J. and Yokota, S. 'On the problem of the development of the parafollicular cells from the human ultimobranchial body in prenatal life', Okajimas Folia anatomica japonica, 46: 59-63, 1969.

Sugiyama, S., Taki, A., Machida,Y. and Furihata, N. 'The significance and fate of the ultimobranchial body in man in relation to the development of the thyroid gland', Okajimas Folia anatomica japonica, 32:329-340, 1959.

Sunder-Plassmann, P. 'Uber neuro-hormonale Zellen des Vagussystems in der Schilddrüse', Deutsche Zeitschrift für Chirugie, 252: 210-223, 1939.

Swift, J.A. 'The electron histochemistry of cystine-containing proteins in thin transverse sections of human hair', Journal of the Royal Microscopical Society, 88:449-460, 1968.

Swift, J.A. 'The electron histochemical demonstration of cystine-containing proteins in the guinea pig hair follicles', Histochemie, 19: 88-98, 1969.

Swift, J.A. 'The electron cytochemical demonstration of cystine disulphide bonds using silver-methenamine reagent', Histochemie, 35: 307-310, 1973.

Szirmai, J.A. 'Quantitative approaches in the histochemistry of muco-polysaccharides', Journal of Histochemistry and Cytochemistry, II: 24-34, 1963.

Takagi, K. 'A cytochemical study on the dog's thyroid gland', Folia Anatomica Japonica, I : 69-100, 1922.

Takeuchi, T. 'Histochemical demonstration of branching enzyme (amylo-I,4 → I,6-transglucosidase) in animal tissues', Journal of Histochemistry and Cytochemistry, 6:208-216, 1958.

Tanford, C. 'The interpretation of hydrogen titration curves of proteins' pp. 69-165 in 'Advances in Protein Chemistry', Eds. Anfinsen, Anson, M.L., Bailey, K. and Edsall, J.T., Vol.17, New York, Academic Press, 1962.

Tashjian, A., Melvin, K.E.W., Voelkel, E.F., Howland, B.G., Zuckerman, J.E. and Minkin, C. 'Calcitonin in blood, urine and tissue : immunological and biological studies' pp.97-112 in 'Calcium, Parathyroid Hormone and the Calcitonins', Eds. Talmage, R.V. and Munson P.L., Amsterdam Excerpta Medica, 1972.

Tateishi R., Takahashi,Y. and Noguchi, A. 'Histologic and cytochemical studies on thyroid medullary carcinoma -- diagnostic significance of argyrophil secretory granules', Cancer, 30:755-763, 1972.

Taylor, S. (Editor) 'Calcitonin. Proceedings of the Symposium on Thyrocalcitonin and the C cells', London, Heinemann, 1968.

Taylor, S. (Editor) 'Calcitonin 1969. Proceedings of the Second International Symposium', London, Heinemann, 1970.

Teitelbaum, S.L., Moore, K.E. and Shieber, W. 'Parafollicular cells in the normal human thyroid', Nature, 230:334-335, 1971.

Tenenhouse, A., Arnaud, C. and Rasmussen, H. 'The isolation and characterization of thyrocalcitonin', Proceedings of the National Academy of Science (U.S.A.) 53:818-822, 1966.

Terner, J.Y. 'Histochemical alkylation : a study of methyl iodide and its effects on tissues', Journal of Histochemistry and Cytochemistry, 12: 504-511, 1964.

Thompson, S.W. 'Selected Histochemical and Histopathological methods' Springfield, C. Thomas, 1966.

Tock, E.P.C. and Pearse, A.G.E. 'Preservation of tissue mucins by freeze-drying and vapour fixation', Journal of the Royal Microscopic Society, 84:519-537, 1965.

Toennis, G. 'The oxidative conversion of casein into protein free methionine and tryptophan', Journal of Biological Chemistry, 145:667-670, 1942.

Tranzer, J.P. and Pearse, A.G.E. 'Titanous chloride as a reducing agent in the dinitrofluorobenzene reaction for protein', Journal of Histochemistry and Cytochemistry, 12:325-326, 1964.

Tremblay, G. and Pearse, A.G.E. 'Histochemistry of oxidative enzyme systems in the human thyroid with special reference to Askanazy cells', Journal of Pathology and Bacteriology, 80:353-358, 1960.

Tremblay, G. 'The oncocytes', pp.121-140 in 'Methods and Achievements in Experimental Pathology', Vol. 4, Eds. Bajusz, E. and Jasmin, G., Basel, Karger, 1969.

Trump, B.F., Goldblatt, P.J., Griffin, C.C., Waravdekar, V.S. and Stowell,R.E. 'Effects of freezing and thawing on the ultrastructure of mouse hepatic parenchymal cells', Laboratory Investigation, 13:967-1002, 1964.

Tsung, C.M. and Fraenkel-Conrat, H. 'Preferential release of aspartic acid by dilute acid treatment of tryptic peptides', Biochemistry, 4:793-801, 1965.

Vassallo, G., Capella, C. and Solcia, E. 'Grimelius' silver stain for endocrine cell granules as shown by electron microscopy', Stain Technology, 46:7-13, 1971.

Velican, C. and Velican,D. 'Silver impregnation techniques for the histochemical analysis of basement membranes and reticular fiber networks', pp.143-190 in 'Techniques of Biochemical and Biophysical Morphology', Vol.I., Ed. Glick, D. and Rosenbaum, R.M., New York, Wiley, 1972.

Wattenberg, L.W. and Leong, J.L. 'Effects of co-enzyme Q_{10} and menadione on succinic dehydrogenase activity as measured by tetrazolium salt reduction', Journal of Histochemistry and Cytochemistry, 8:296-303, 1960.

Weiss, L.P., Isou, K.C. and Seligman, A.M. 'Histochemical demonstration of protein bound amino groups', Journal of Histochemistry and Cytochemistry, 2:29-49, 1954.

Welsch, U. 'Embrylogical and post-natal differentiation of the thyroid C-cell and their functional development',pp.557-566 in 'Subcellular Organization and Function in Endocrine Tissues', Eds. Heller, H. and Lederis, K., Cambridge University Press, 1971.

Welsch, U. 'Die Entwicklung der C-zellen und das Follikepithels der Säugerschilddrüse', Advances in Anatomy, Embryology and Cell Biology, 46:1-52, 1972.

Welsch, U. and Bucheim, W. 'The fine structure of endocrine polypeptide storage granules', pp. 291-298, in 'Endocrinology 1971, Proceedings of the Third International Symposium', Eds. Taylor, S., London, Heinemann, 1972.

Welsch, U., Flitney, F.W. and Pearse, A.G.E. 'The fine structural localization of acetylcholinesterase in rabbit thyroid C cells and the effect of uptake of 5-hydroxytryptophan or dihydroxyphenylalanine on their morphology', pp.167-179, in 'Calcitonin. Proceedings of the Symposium on Thyrocalcitonin and the C cells'. Ed. Taylor, S., London, Heinemann, 1968.

Welsch, U., Flitney, F.W. and Pearse, A.G.E. 'Comparative studies on the ultrastructure of the thyroid parafollicular C-cells', Journal of Microscopy, 89:83-94, 1969.

Welsch, U. and Pearse, A.G.E. 'Electron cytochemistry of BuChE and AChE in thyroid and parathyroid C cells under normal and experimental conditions', Histochemie, 17:1-10, 1969.

Welsh, D.A. 'Concerning the parathyroid glands - A critical anatomical and experimental study', Journal of Anatomy and Physiology, 32:292-307, 1898.

Wetzel, B.K., Spicer, S.S. and Wollman, S.H. 'Changes in fine structure and acid phosphatase localization in rat thyroid cells following thyrotropin administration', Journal of Cell Biology, 25: 593-618, 1965.

Wilcox, P.E. 'Esterification', pp.605-617, in 'Methods in Enzymology' Vol. XI, Ed. Hirs, C.H.W., New York, Academic Press, 19.

Williams, E.D. 'Histogenesis of medullary carcinoma of the thyroid', Journal of Clinical Pathology, 19:114-118, 1966.

Witkop, B. 'Chemical cleavage of proteins', Science, 162:318-326, 1968.

Wolfe, H.J., Voelkel, E.F. and Tashjian, A.H. 'Distribution of calcitonin-containing cells in the normal adult human thyroid gland : a correlation of morphology with peptide content', Journal of Clinical Endocrinology and Metabolism, 36: 688-694, 1974.

Wolman, M. 'Lipids stained by the periodic acid-Schiff technic', Stain Technology, 31:241-245, 1956.

Wolman, M. 'Studies on the impregnation of nervous tissue elements', Laboratory Investigation, 6:551-557, 1957.

Wolman, M. and Greco, J. 'The effect of formaldehyde on tissue lipids and on histochemical reaction for carbonyl group', Stain Technology, 27:317-324, 1952.

Yasuma, A. and Ichikawa,T. 'Ninhydrin-Schiff and alloxan-Schiff staining', Journal of Laboratory and Clinical Medicine, 41:296-299, 1953.

Zechel, G. 'Observations on the follicular cycle and on the presence of the 'macrothyrocyte' in the human thyroid', Anatomical Record, 56:119-130, 1933.

Zerlotti, E. and Engel, M.C. 'The reactivity of proteins of some connective tissues and epithelial structures with 2,4,dinitrofluorobenzene', Journal of Histochemistry and Cytochemistry, 10:537-546, 1962.

Zugibe, F.T. 'The demonstration of the individual acid mucopolysaccharides in human aortas, coronary arteries and cerebral arteries', Journal of Histochemistry and Cytochemistry, 10: 441-447, 1962.

J. Anat. (1973), **115**, 2, pp. 255 276
With 17 *figures*
Printed in Great Britain

A comparative study of the normal human neonatal and the canine thyroid C cell

W. E. W. ROEDIGER

Department of Anatomy, University of the Witwatersrand, Johannesburg, South Africa

(*Accepted* 12 *April* 1973)

INTRODUCTION

The thyroid C cell was established as a distinct functional unit after the discovery of calcitonin by Copp, Cameron, Cheney, Davidson & Henze in 1962. Subsequent work established that the C cell, distributed within the thyroid parenchyma, contains a granular secretory product that can be dispersed by calcium infusions (Pearse, 1966). Fluorescent antibody methods have confirmed that the cell produces calcitonin (Hargis, Williams, Tenenhouse & Arnaud, 1966; Bussolati & Pearse, 1967).

The cell type now known as the C cell, was well known in the dog thyroid prior to the discovery of calcitonin and had been referred to as the parenchymatous cell (Baber, 1876), *protoplasmareiche* cell (Hurthle, 1894) and parafollicular cell (Nonidez, 1932). Its exact origin and function had been the subject of considerable speculation. From time to time this awareness of a second cell component within the thyroid tissue of dogs has been responsible for studies which attempted to demonstrate similar cell elements in human material. For instance, Zechel (1933) reported clear cells in the thyroids of normal human neonates, and Hamperl (1937) reported large acidophilic cells in adult thyroids. Both authors believed that these were cells analogous to the dog 'parafollicular cells.'

The matter was not clarified until the isolation of calcitonin by Riniker *et al.* (1968) led once again to the study of human thyroids. Solcia & Sampietro alluded briefly to human C cells in 1968 and studied them further in patients with osteopetrosis and thyroid carcinoma (Solcia, Capella, Sampietro & Vassallo, 1970), while Kracht, Hachmeister & Christ (1970) looked for these cells in patients with hyperparthyroidism. Kalina, Foster, Clark & Pearse (1970) successfully demonstrated human neonatal thyroid C cells by means of fluorescent antibody attachment methods.

Despite these rapid advances no detailed study on C cells of normal human neonates has appeared in the literature. A systematic histological and histochemical study has therefore been made in order to show their distribution, morphology and enzyme pattern in neonatal material. As far as possible, identical procedures were carried out on dog thyroids because many histochemical techniques pertaining to C cells have been standardized in this experimental animal and sections of dog thyroid could therefore serve as controls.

Table 1. *Neonatal thyroidectomies*

Time lapse before thyroid removal (hours)	Code no. and sex	Post-gestational age (weeks)	Cause of death	Maternal serum calcium (m-equiv/l)
4	C_2, male	32	Respiratory distress	4·9
4	C_3, female	34	Umbilical cord prolapse	5·0
7	C_4, female	+36	Pre-eclamptic toxaemia	4·8
1½	C_5, female	+36	Deep transverse arrest	4·9
1	C_6, male	34	Cerebral haemorrhage	5·1

MATERIAL

Within 7 hours of death thyroidectomies were performed on five human stillborn neonates of between 32 and 36 weeks gestation (Table 1). Thyroids were sagittally and transversely cut through the isthmus to give four quadrants of tissue. Each of the four quadrants was cut in the coronal plane so that every thyroid was divided into eight blocks (Fig. 9). One lobe of each thyroid was used for paraffin sectioning and the other lobe for enzyme studies. Material for paraffin sections was fixed in Helly's, 80% alcohol, and glutaraldehyde picric acetic acid (GPA) (Solcia & Sampietro, 1968) fixatives, and sections were cut at 4 μm. For enzyme techniques half of the other thyroid lobe was fixed in Pearson's fixative (Pearson, 1963) at 4° C for 12 hours and then quenched in liquid nitrogen for cryostat sectioning. The remaining half was quenched in hexane (− 70° C) or liquid nitrogen, sectioned on a Pearse-Slee cryostat at 8 μm and post-fixed in formol saline or GPA for periods of 15 minutes to 1 hour.

Canine material comprised six dogs (*Canis vulgaris*) of both sexes, all under the age of 8 months, kept at room temperature and fed on a routine laboratory diet for 6 weeks prior to operation. Thyroids were surgically removed under Fluothane anaesthesia or after sacrifice with intravenous Nembutal. The same methods of fixation and cryostat preparation were used as for the human material. In addition, one quarter of each thyroid lobe was cut into small pieces and freeze-dried overnight, after being quenched in monochlorodifluoromethane (Freon 22) at − 173° C. The freeze-dried tissue was fixed in formalin vapour for 2 hours, embedded in paraffin wax, and sectioned at 6 μm.

METHODS

Silver impregnation was undertaken using the Nonidez (1932) method on alcohol-fixed tissue and the Grimelius (1968*a*) method on both Helly- and GPA-fixed tissue. The Masson's (1928) argentaffin reaction was applied on GPA-fixed tissue. Metachromasia was demonstrated according to the method of Solcia & Sampietro (1968) with toluidine blue at a concentration of 1 : 10000 in 0·02 M Walpole buffer at pH 5·0. Staining time was between 20 minutes and 6 hours with or without prior hydrolysis in 0·2 N HCl for 3 hours at 60° C. The periodic acid Schiff (PAS) reaction was

Human neonatal

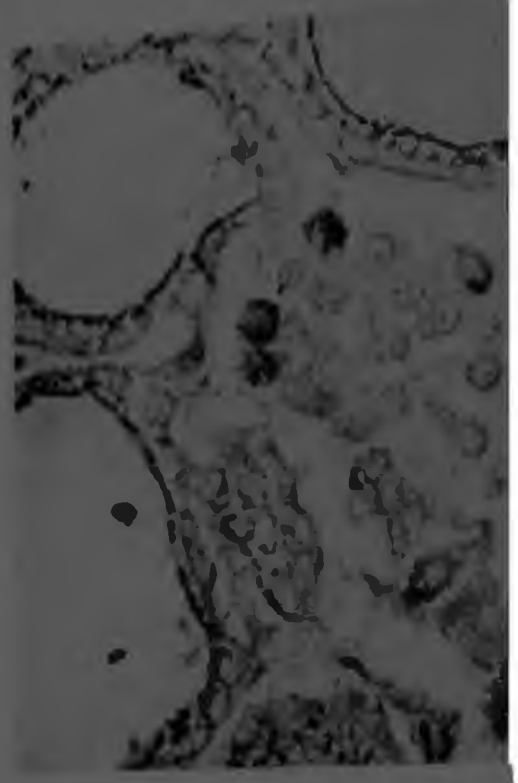

Fig. 1. A group of canine thyroid C cells. Follicular cells show fewer cytoplasmic fixation. Nonidez silver impregnation.

applied to the freeze-dried canine th ment membrane.

The following enzyme procedures

Cholinesterases. The method of P Pearson's fixative utilizing acetyl- Exposure to the substrate was for OMPA, 10^{-4} M were used as inhibit

Alpha-glycerophosphate dehydrog (1957), as modified by Hess, Scar bromide (MTT) was employed as h only half of the canine material stud was added as co-factor according to di- or tri-pyridine nucleotide was ad

NADH tetrazolium reductase. The used. Cryostat sections adjoining th prepared to demonstrate toluidine b sections were post-fixed in GPA for HCl at 60° C for 15 minutes) and 30 minutes.

Cause of death	Maternal serum calcium (m-equiv/l)
[illegible]atory distress	4·9
[illegible] cord prolapse	5·0
[illegible]ic toxaemia	4·8
[illegible] transverse arrest	4·9
[illegible] haemorrhage	5·1

[illegible]formed on five human stillborn [illegible]able 1). Thyroids were sagittally [illegible]ur quadrants of tissue. Each of [illegible] that every thyroid was divided [illegible] was used for paraffin sectioning [illegible]or paraffin sections was fixed in [illegible] acetic acid (GPA) (Solcia & [illegible]at 4 μm. For enzyme techniques [illegible]s fixative (Pearson, 1963) at 4 °C [illegible] for cryostat sectioning. The [illegible] liquid nitrogen, sectioned on a [illegible]l saline or GPA for periods of

[illegible]) of both sexes, all under the [illegible] on a routine laboratory diet for [illegible]ally removed under Fluothane [illegible]l. The same methods of the human material. In addition, [illegible] and freeze-dried overnight, [illegible] (Freon 22) at −153 °C. The [illegible] 2 hours, embedded in paraffin

[illegible]ndez (1932) method on alcohol- [illegible]th Helly- and GPA-fixed tissue. [illegible]ed on GPA-fixed tissue. Meta- [illegible]d of Solcia & Sampietro (1968) [illegible]0·02 M Walpole buffer at pH 5·0. [illegible] with or without prior hydrolysis [illegible] acid Schiff (PAS) reaction was



Fig. 1. A group of canine thyroid C cells with cytoplasmic granules of variable number per cell. Follicular cells show fewer cytoplasmic granules which are apically aligned. 80% alcohol fixation, Nonidez silver impregnation.

applied to the freeze-dried canine thyroid material to demonstrate the follicle basement membrane.

The following enzyme procedures were carried out:

Cholinesterases. The method of Gerebtzoff (1953) was used on tissue fixed in Pearson's fixative utilizing acetyl- and butyryl-thiocholine iodide as substrates. Exposure to the substrate was for 12 hours at pH 6·8. Eserine, 10^{-5} M and iso-OMPA, 10^{-5} M were used as inhibiting agents in order to type the cholinesterase.

Alpha-glycerophosphate dehydrogenase (αGPDH). The method of Nachlas *et al.* (1951) as modified by Hess, Scarpelli & Pearse (1958) was used. Monotetrazolium bromide (MTT) was employed as hydrogen acceptor. In all human material, but in only half of the canine material studied for this enzyme, menadione (menaphthone) was added as co-factor according to the method of Wattenberg & Leong (1960). No di- or tri-pyridine nucleotide was added to the incubating medium.

NADH tetrazolium reductase. The method of Scarpelli, Hess & Pearse (1958) was used. Cryostat sections adjoining those demonstrating the latter two enzymes were prepared to demonstrate toluidine blue metachromasia. For this purpose cryostat sections were post-fixed in GPA for 15 minutes followed by acid hydrolysis (0·2 N HCl at 60 °C for 15 minutes) and then stained in toluidine blue, as above, for 30 minutes.



Fig. 2. Dense aggregation of cytoplasmic granules in cuticle thyroid C cells. GPA fixation. Grimelius silver impregnation.



Fig. 3. Silver impregnation of human neonatal thyroid, prepared as for Fig. 1 shows diffuse silver aggregation in all cells of the thyroid.

Human n



Fig. 4. Silver impregna
shows

Both the silver impregnati
C cells in such a way that
(Pearse, 1966; Solcia & Sa
impregnation was obtained
chromasia was shown equally

In the dog thyroid, Nonic
dense aggregation of impreg
cytoplasm of the follicular ce
The number of granules vari
pactly distributed throughout
pherally situated and distant
of C cells also showed a gran
membranes. The follicular ce
of silver with this latter meth

In the human neonatal ma
and connective tissue impre
elements (Fig. 3). This gener



...ules in canine thyroid
... impregnation

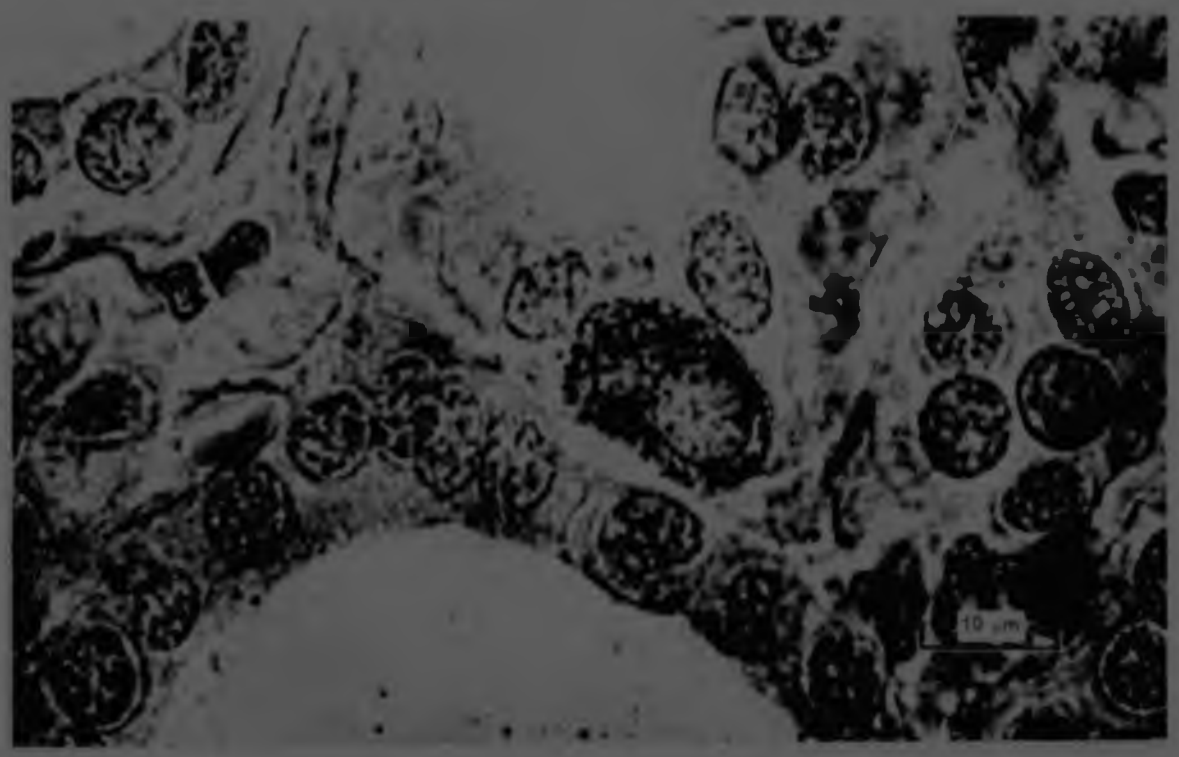

Fig. 4. Silver impregnation of human neonatal thyroid, prepared as for Fig. 1, shows cytoplasmic granules in a single C cell.



...thyroid, prepared as for Fig. 1,
...l cells of the thyroid

RESULTS

Selective C cell reactions

Both the silver impregnation and toluidine blue methods selectively demonstrate C cells in such a way that they can be readily distinguished from follicular cells (Pearse, 1956; Solcia & Sampietro, 1968). In the present study optimal silver impregnation was obtained on GPA-fixed material, whereas toluidine blue metachromasia was shown equally well on Helly- and on GPA-fixed material.

In the dog thyroid, Nonidez's silver impregnation method showed an intense, dense aggregation of impregnated cytoplasmic granules in the C cells, whereas the cytoplasm of the follicular cells contained fewer and more diffuse granules (Fig. 1). The number of granules varied from one C cell to another. They were either compactly distributed throughout the cytoplasm or else more sparsely scattered, peripherally situated and distant from the central nucleus. Grimelius' silver impregnation of C cells also showed a granular pattern (Fig. 2), and silver attachment to some cell membranes. The follicular cells showed no distinct cytoplasmic granular deposition of silver with this latter method.

In the human neonatal material, however, Nonidez's method gave diffuse cellular and connective tissue impregnation of silver with poor selectivity of the C cell elements (Fig. 3). This generalized reaction with silver was found in all neonatal

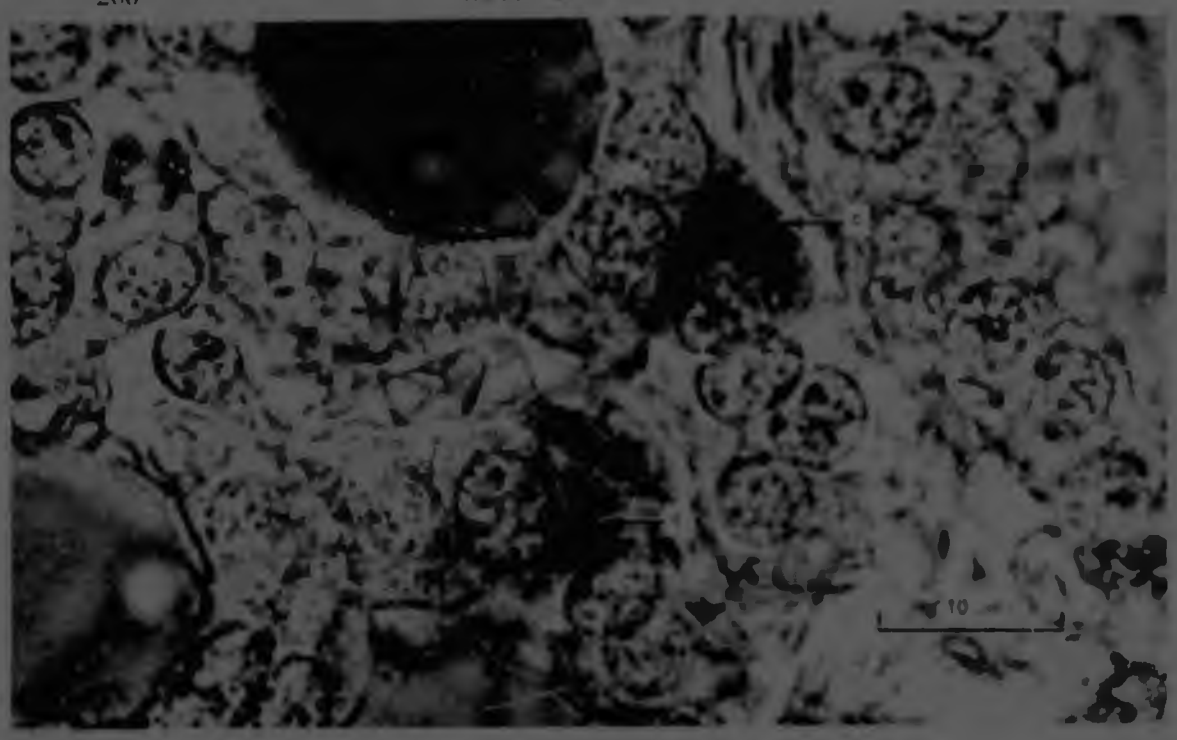

Fig. 5. Toluidine blue metachromasia of human C cells (c). Coarse cytoplasmic granules are present. GPA fixation, water-mounted.

human thyroid sections so impregnated. In contrast, Grimelius' method gave excellent definition of C cells. Distinct intracytoplasmic granules were found scattered throughout the cell body (Fig. 4). The distribution was uniform throughout the cytoplasm and no obvious quantitative differences could be noted from C cell to C cell.

No argentaffinity could be shown in either canine or human neonatal C cells.

Toluidine blue metachromasia in dog C cells was demonstrated as well without as with acid hydrolysis. A β-metachromasia was observed, spread diffusely throughout the cytoplasm, together with scattered granular accentuations against this background. Metachromasia was much better shown in acidic aldehyde-fixed tissue (GPA or Helly fixative) than after neutral fixatives (alcohol or buffered glutaraldehyde) which were employed in initial experiments. Human thyroids showed cells with β-metachromasia only after acid hydrolysis. Consecutive sections showed that these cells were stained orthochromatically when no hydrolysis had been applied. Metachromasia was more easily demonstrated in human material (Fig. 5) after prolonged toluidine blue exposure (8 hours at room temperature) than after 20 minutes as recommended by Solcia & Sampietro (1968) for dogs. Granular accentuation of the toluidine blue staining was noted in the human material too, but not as many granules could be discerned in cells stained with the basic dye as in cells impregnated with silver.



Fig. 6. Diagrammatic repres
(a) intrafollicular, (b)

Observations on distribut
toluidine blue-stained and
distribution was random th
found in the posterior port
the superior th roid artery.

In the dog, cells were found
to the follicle basement m
cells just clear of the colloid
the basement membrane
follicular basement membr
were surrounded by a separ
occasionally showed pseud
around a central lumen.

In the neonatal thyroid the
or parafollicular position
follicular positional types co
staining.

Far fewer cells were foun
clusters of six to eight cells,
widely scattered throughou
centrilobar situations, post
material. Serial sections fro



toplasmic granules

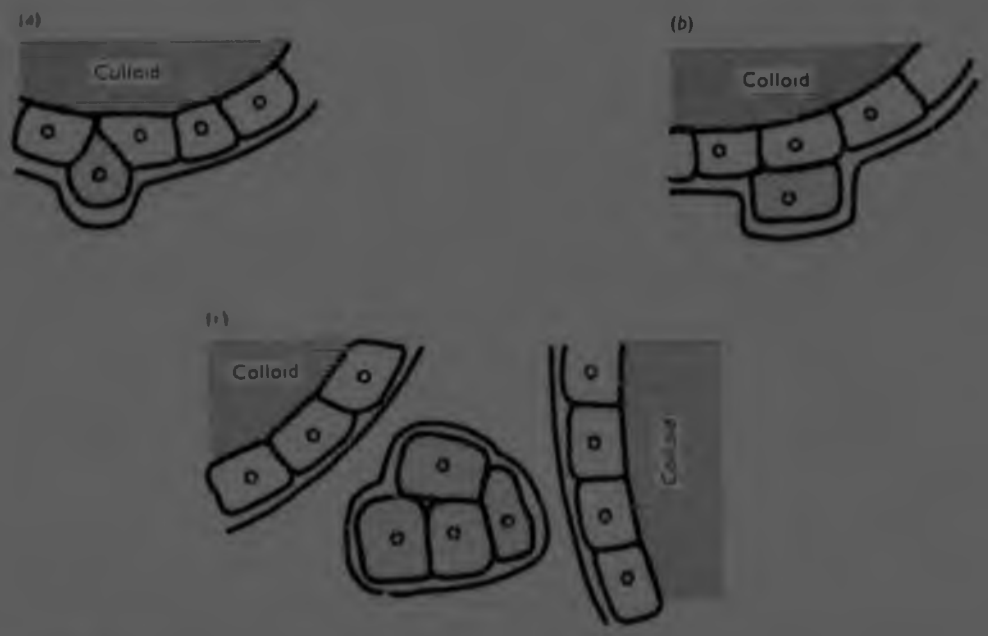

Fig. 6. Diagrammatic representation of C and follicular cells in relation to basement membranes (*a*) intrafollicular, (*b*) parafollicular and (*c*) interfollicular positions of C cells.

Grimelius' method gave
granules were found
uniform throughout
be noted from C cell to

human neonatal C cells.
lrated as well without as
spread diffusely throughout
ions against this back-
acidic aldehyde-fixed tissue
(alcohol or buffered glutar-
Human thyroids showed cells
ive sections showed that
hydrolysis had been applied.
aterial (Fig. 5) after pro-
re) than after 20 minutes
anular accentuation of
l too, but not as many
as in cells impregnated

Distribution and morphology

Observations on distribution and morphology were made predominantly on the toluidine blue-stained and the silver-impregnated sections. In the young dogs C cell distribution was random throughout the thyroid except for a greater concentration found in the posterior portion of the gland, adjacent to the parathyroid glands and the superior thyroid artery. All dog thyroids examined contained C cells.

In the dog, cells were found singly or in groups in one of three locations in relation to the follicle basement membrane (Fig. 6). Some cells were wedged in between follicle cells just clear of the colloid (intrafollicular), others lay between the follicle cells and the basement membrane (parafollicular) (Fig. 7) and yet others lay external to the follicular basement membrane in an interfollicular position, in which case the cells were surrounded by a separate basement membrane (Fig. 8). The interfollicular cells occasionally showed pseudo-follicle formation, in which C cells were arranged around a central lumen.

In the neonatal thyroid the basement membrane was not stained. Cells in an intra- or parafollicular position could be distinguished, but a distinction of the interfollicular positional types could not be achieved in the absence of basement membrane staining.

Far fewer cells were found in the human material. They frequently occurred in clusters of six to eight cells, concentrated within a small area of a section and not widely scattered throughout the sections as in the dog material. Cells were found in centrilobar situations, posteriorly, in three of the five cases of paraffin-embedded material. Serial sections from cases C_4 and C_5 (Table 1) showed no C cells in the

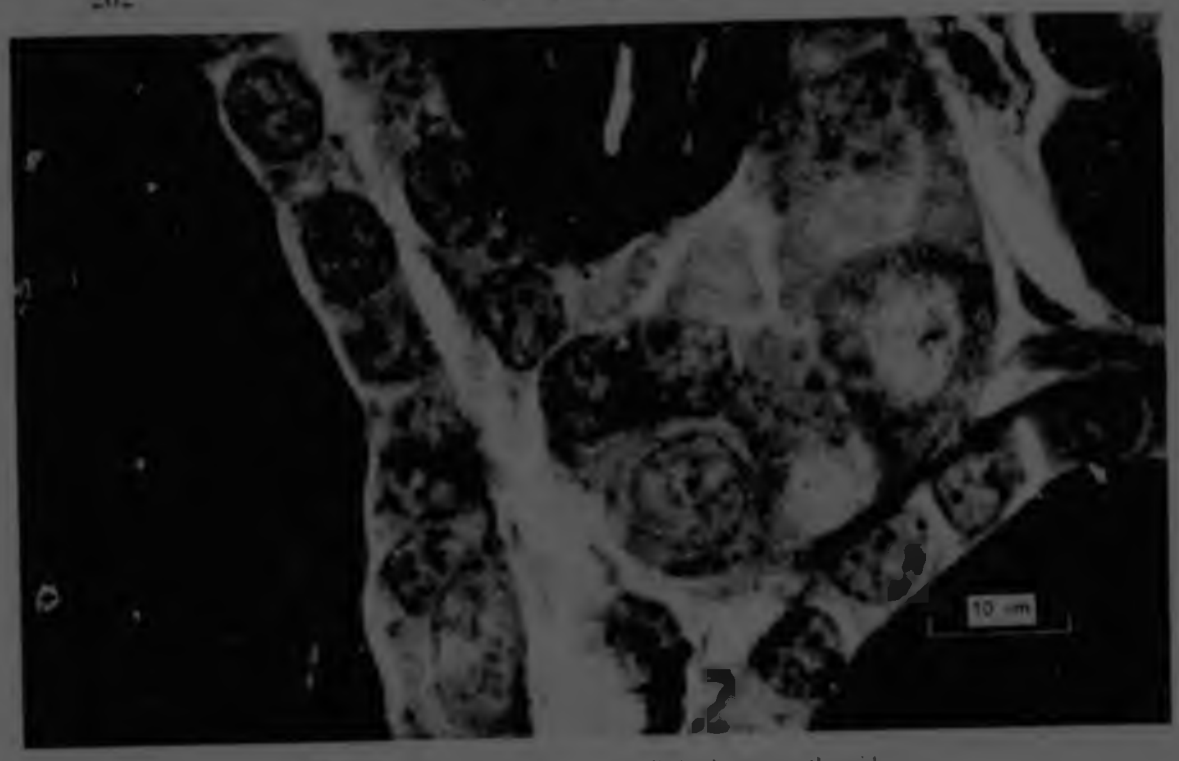

Fig. Parafollicularly positioned C cells in the canine thyroid
Freeze-dried, formalin vapour- fixed: PAS

lower portions of the left lobes. No C cells were noted in any isthmus or in the anterolateral portions of any lobes in the five specimens (Fig. 9).

Various morphological forms of C cells were apparent in the neonatal thyroid. A number of club-shaped cells with prominent cytoplasmic processes were located singly between thyroid follicles, or in relation to primitive follicle cell nests that had not secreted any thyroglobulin. A few of these cells were wedged between follicular cells and in these instances the cytoplasmic processes were applied along the external surface of the follicle cells parallel to the basement membrane (Fig. 10). The length of the cell process varied from 3 to 10 µm. Serial sections were studied which confirmed that these processes were not tangentially cut flat C cells. A second morphological variant of the C cell was ovoid in shape (Fig. 11). These cells were less deeply wedged in between the follicular cells and almost protruded into the colloid, often separated from it by only a thin sliver of follicle cell cytoplasm. Such cells showed no cytoplasmic processes when followed serially.

In the dog cells with cytoplasmic processes were not observed.

Enzyme techniques

Dog C cells showed a high content of zGPDH (Fig. 12) and NADH tetrazolium reductase. The content of both enzymes was far higher in C cells than that observed in the follicular cell (acinar or A cell) and provided a ready method of distinction



Fig. Interfollicularly
Canine
Superior



the canine thyroid
fixed; PAS

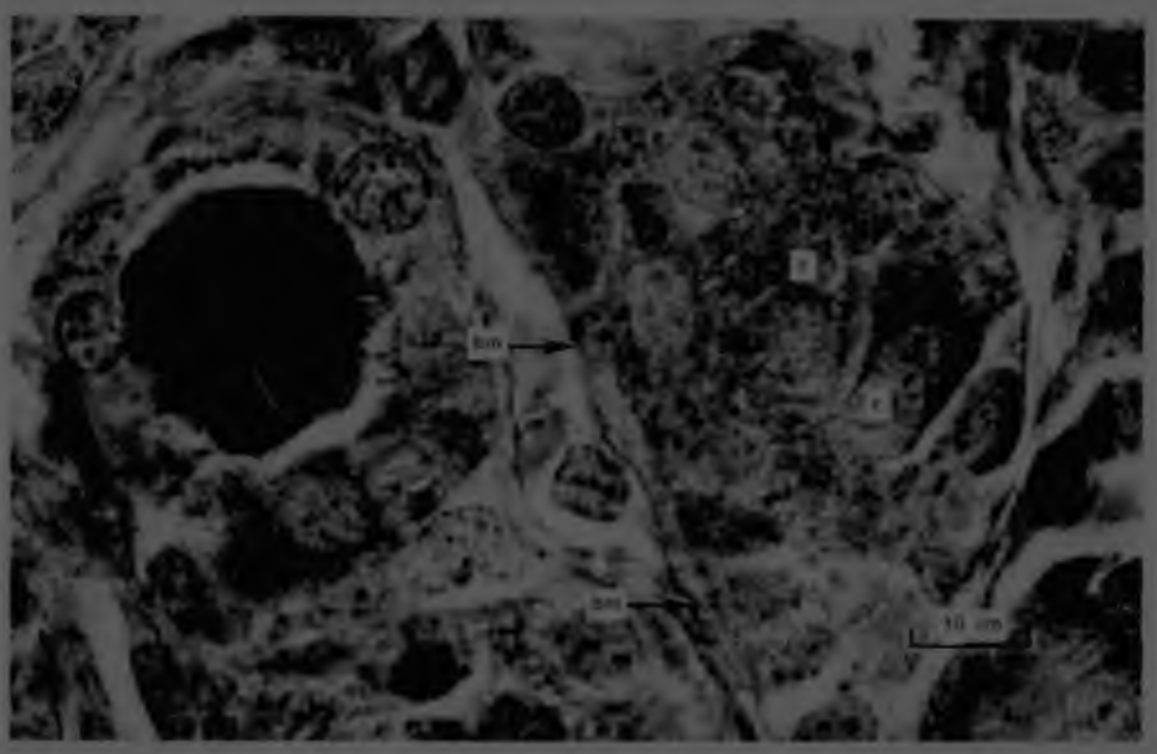

Fig. 8. Interfollicularly positioned C cells (c) with surrounding basement membrane (bm). Canine thyroid. Freeze-dried, formalin vapour-fixed. PAS.

noted in any isthmus or in the
(Fig. 9).
apparent in the neonatal thyroid.
toplasmic processes were located
mitive follicle cell nests that had
ls were wedged between follicular
cesses were applied along the
basement membrane (Fig. 10).
0 μm. Serial sections were studied
entially cut flat C cells. A second
shape (Fig. 11). These cells were
and almost protruded into the
of follicle cell cytoplasm. Such
serially.
not observed.

(Fig. 12) and NADH tetrazolium
ter in C cells than that observed
a ready method of distinction



Fig. 9. Diagrammatic representation of C cell distribution within the neonatal human thyroid. C cells were consistently found in the hatched area. AA, transverse section; BB, sagittal section; CC, coronal section. These planes correspond to the planes of tissue section prior to fixation.

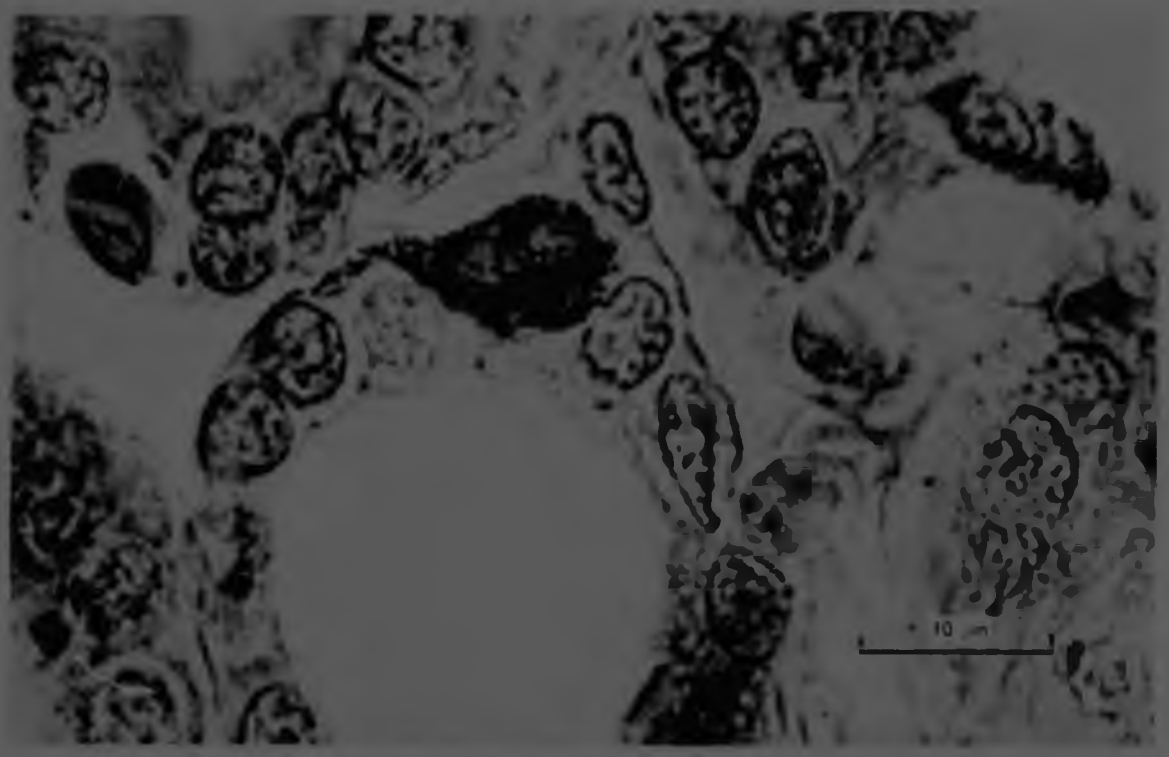

Fig. 10. Human C cell with granule containing cytoplasmic process. GPA fixation; Grimelius silver impregnation.

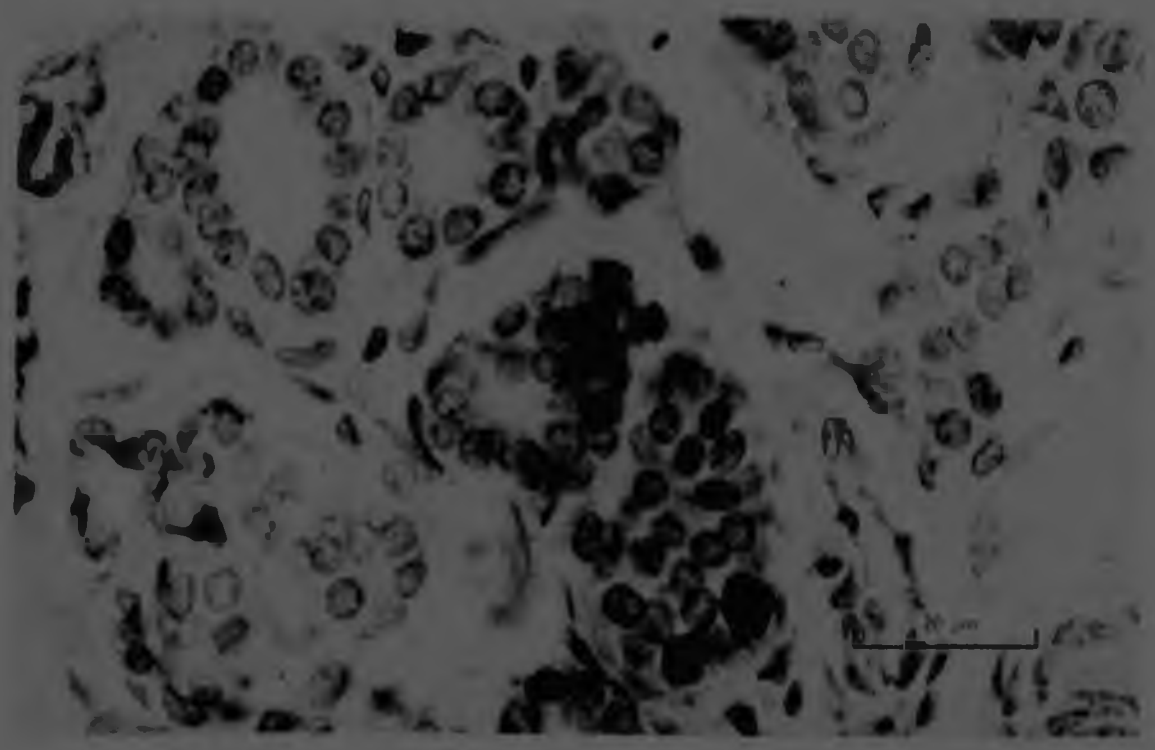

Fig. 11. Four ovoid human C cells in close proximity to each other. No cytoplasmic processes are present. GPA fixation; Grimelius silver impregnation.



Fig. 12. Inter- and intrafollicular

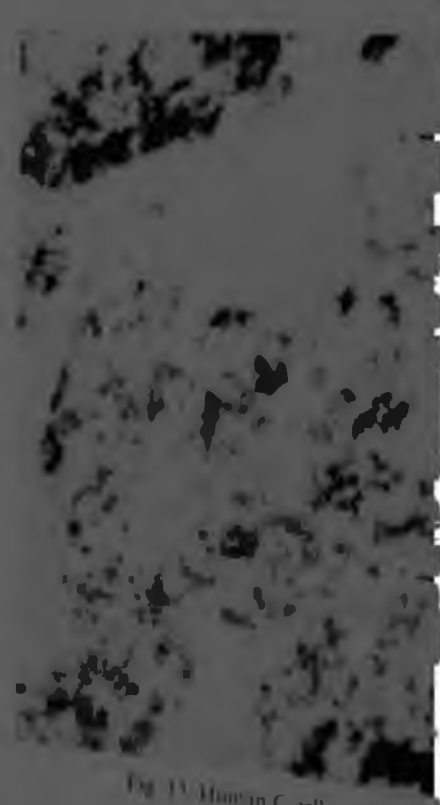

Fig. 13. Human C cells (c) in neon
Cryostat

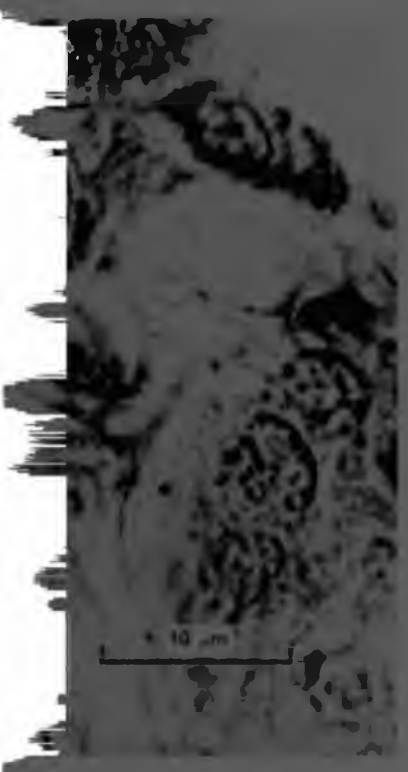

= GPA fixation; Grimelius

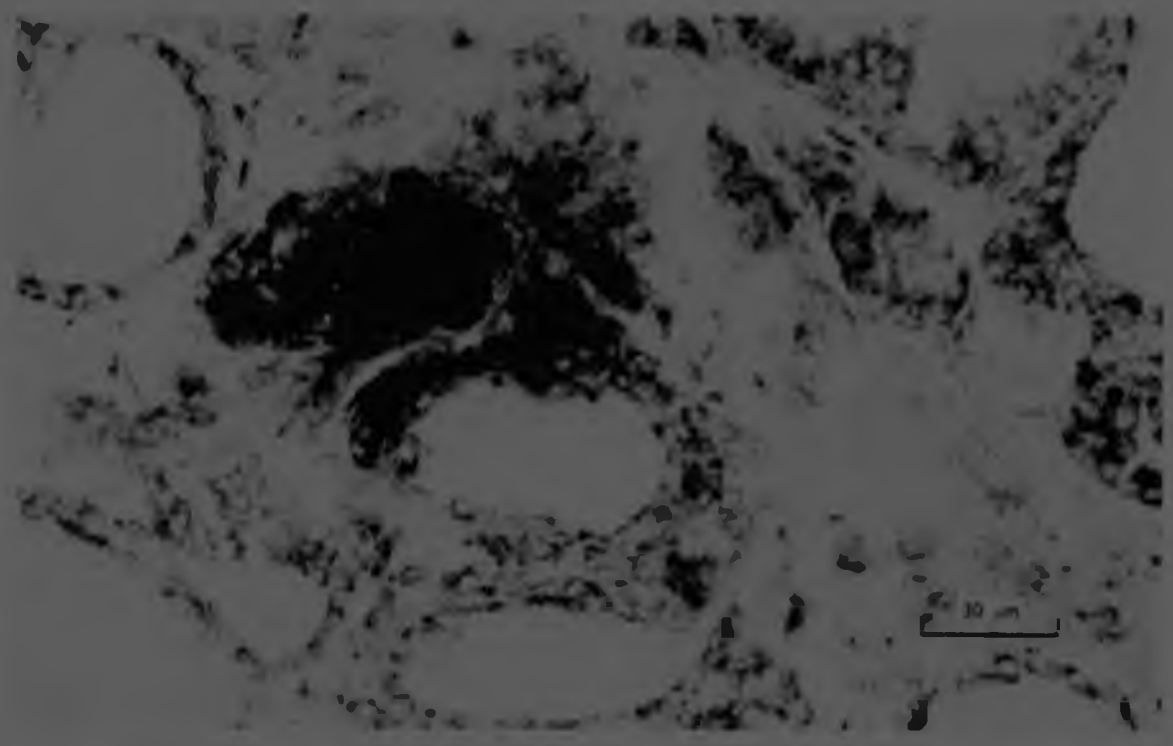

Fig. 12. Inter- and intrafollicular canine C cells with very high αGPDH content. Cryostat section, menadione enhanced reaction



other. No cytoplasmic
impregnation.



Fig. 13. Human C cells (c) in neonatal thyroid that has not yet begun to secrete thyroglobulin. Cryostat section; menadione-enhanced reaction



Fig. 14. Human C cell with very high αGPDH content. Cryostat section, menadione-enhanced reaction.



Fig. 15. Human follicular and AC cell types. Moderate content of αGPDH distinguishes AC from C cells. Cryostat section; menadione-enhanced reaction.



Fig. 16. Human

Table 2. *Quantitative distri*
human neonates and

Cell types	
A cells	
AC cells	
C cells	

between the two. The extr
menadione had been inclu
dog thyroids showed that
reductase activity also den
Alpha glycerophosphate
roids was carried out on
Several categories of cells
content. Of these, two cells
(acinar or A cells) which
group C cells, showed a v



ment) Cryostat section)

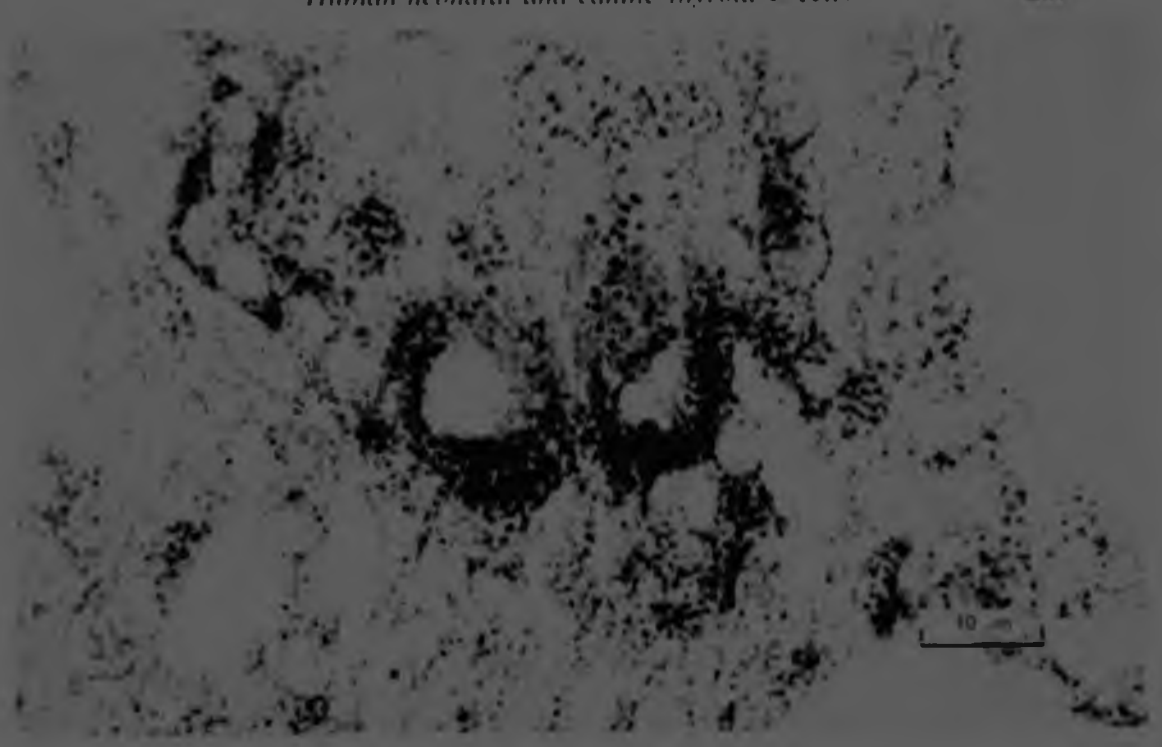

Fig. 16. Human AC cells in an interfollicular position. Cryostat section; menadione enhanced reaction



of zGPDH distinguishes AC from
ed reaction

Table 2. *Quantitative distribution of zGPDH and NADH reductase in thyroid cells of human neonates and their relationship to toluidine blue metachromasia*

Cell types	zGPDH	NADH reductase	Toluidine blue metachromasia
A cells	—	—	−ve
AC cells	+ + or + + +	+ or + +	−ve
C cells	+ + + +	+ + +	+ve

+ or + + represent subjective assessment of enzyme content

between the two. The extraordinarily high content of zGPDH was noted only when menadione had been included in the procedure. Consecutive cryostat sections of dog thyroids showed that all cells with particularly high levels of dehydrogenase and reductase activity also demonstrated toluidine blue metachromasia.

Alpha glycerophosphate dehydrogenase demonstration in neonatal human thyroids was carried out only with the inclusion of menadione in the procedure. Several categories of cells in the thyroid were shown to have relatively high enzyme content. Of these, two cellular groups could be distinguished from the follicular cells (acinar or A cells) which showed only a minimal amount of zGPDH (Table 2). One group (C cells, showed a very high content of zGPDH and demonstrated toluidine



Fig. 17. Bi-iodo cholinesterase activity in canine C cells. Cryostat section; Pearson's fixation

blue metachromasia in adjoining serial sections. These cells occurred in both an intra- and a parafollicular position. Occasionally clusters of two to three cells, all with this high enzyme content, occurred (Figs. 13, 14). The second group, temporarily termed AC cells, had a moderately high content of oxidative enzyme (αGPDH) but in adjacent serial sections demonstrated no toluidine blue metachromasia. These cells usually occupied an intrafollicular position. Only one or several such cells occurred in a follicle while a few were in an interfollicular position (Figs. 15, 16).

In the neonate the distribution of NADH tetrazolium reductase generally paralleled that of αGPDH. C cells which had a very high content of dehydrogenase also showed a high content of the reductase. However, that cell category (AC cells) which had only a moderately high content of αGPDH was not as readily detectable with the NADH tetrazolium reductase method (Table 2).

In the canine C cell, high non-specific cholinesterase activity was found (Fig. 17). This was distributed throughout the cytoplasm or occasionally a large concentration of the enzyme was found to be aligned along the cytoplasmic border of the cells. No cholinesterase activity was shown in the neonatal C cells. In every case the technique was used with canine thyroid sections as controls to assess the efficacy of the procedure.

DISCUSSION

All the cytochemical procedures employed in this study were chosen because they were likely to demonstrate C cells selectively in the thyroid.

The present results confirm that in the canine thyroid, toluidine blue metachromasia and silver impregnation adequately distinguish C cells from follicular cells, as was originally shown in the dog by Nonidez (1932) and Solcia & Sampietro (1968). Utilizing the same procedures C cells were first shown in the adult human thyroid by Solcia & Sampietro (1968) and again by Solcia *et al.* in 1970. It is now shown that metachromasia and silver impregnation also provide adequate means for C cell identification in human neonatal thyroids.

Although toluidine blue metachromasia and silver impregnation are selective for C cells in the thyroid, these techniques are not *specific* for C cells. Other known polypeptide hormone-producing cells such as gastric G and intestinal S cells demonstrate the same selective staining characteristics (Pearse *et al.*, 1970). Therefore these procedures are not specific for calcitonin, although they may indicate calcitonin-producing ability in C cells.

Intrathyroidal distribution and morphology of C cells

Solcia & Sampietro (1968) found that C cells were scattered throughout the canine thyroid. While this applies also to the present material, a definite preponderance of C cells was found posteriorly and related to vessels in the upper pole of each lobe. This difference might be due to a difference in age of the dogs used in the two studies. Growth of the thyroid in older animals may lead to a wider dispersion of C cells, and thus the posterior concentration of these cells may not be as obvious in older animals as in young puppies. The intrathyroid distribution may therefore be variable in dogs, but it is not known whether the total C cell population is altered with age. In the rat

blue metachromasia in adjoining serial sections. These cells occurred in both an intra- and a parafollicular position. Occasionally clusters of two to three cells, all with this high enzyme content, occurred (Figs. 13, 14). The second group, temporarily termed AC cells, had a moderately high content of oxidative enzyme (αGPDH) but in adjacent serial sections demonstrated no toluidine blue metachromasia. These cells usually occupied an intrafollicular position. Only one or several such cells occurred in a follicle while a few were in an interfollicular position (Figs. 15, 16).

In the neonate the distribution of NADH tetrazolium reductase generally paralleled that of αGPDH. C cells which had a very high content of dehydrogenase also showed a high content of the reductase. However, that cell category (AC cells) which had only a moderately high content of αGPDH was not as readily detectable with the NADH tetrazolium reductase method (Table 2).

In the canine C cell, high non-specific cholinesterase activity was found (Fig. 17). This was distributed throughout the cytoplasm or occasionally a large concentration of the enzyme was found to be aligned along the cytoplasmic border of the cells. No cholinesterase activity was shown in the neonatal C cells. In every case the technique was used with canine thyroid sections as controls to assess the efficacy of the procedure.

DISCUSSION

All the cytochemical procedures employed in this study were chosen because they were likely to demonstrate C cells selectively in the thyroid.

The present results confirm that in the canine thyroid, toluidine blue metachromasia and silver impregnation adequately distinguish C cells from follicular cells, as was originally shown in the dog by Nonidez (1932) and Solcia & Sampietro (1968). Utilizing the same procedures C cells were first shown in the adult human thyroid by Solcia & Sampietro (1968) and again by Solcia *et al.* in 1970. It is now shown that metachromasia and silver impregnation also provide adequate means for C cell identification in human neonatal thyroids.

Although toluidine blue metachromasia and silver impregnation are selective for C cells in the thyroid, these techniques are not *specific* for C cells. Other known polypeptide hormone-producing cells such as gastric G and intestinal S cells demonstrate the same selective staining characteristics (Pearse *et al.* 1970). Therefore these procedures are not specific for calcitonin, although they may indicate calcitonin-producing ability in C cells.

Intrathyroidal distribution and morphology of C cells

Solcia & Sampietro (1968) found that C cells were scattered throughout the canine thyroid. While this applies also in the present material, a definite preponderance of C cells was found posteriorly and related to vessels in the upper pole of each lobe. This difference might be due to a difference in age of the dogs used in the two studies. Growth of the thyroid in older animals may lead to a wider dispersion of C cells, and thus the posterior concentration of these cells may not be as c[illegible]s in older animals as in young puppies. The intrathyroid distribution may therefore be variable in dogs, but it is not known whether the total C cell population is altered with age. In the rat,



Fig. 17. Pseudo-cholinesterase activity in canine C cells. Gomori section; Pearse's fixation.

Stux, Thompson, Isler & le Blond (1961) showed that, irrespective of age, the C cell population consistently constitutes 5% of the total thyroid.

In the human neonates, too, most C cells were situated in the posterior portion of the upper lobe of the thyroid, though a few cells were scattered more anteriorly. The posterior distribution accords well with the invasion of the human thyroid by cells from the ultimobranchial body. Kingsbury (1935) and Sugiyama, Taki, Machida & Furihata (1959) demonstrated the posterior relationship of the human ultimobranchial body to the thyroid and the dispersal of cells from this body into the posterior thyroid. C cells in the rodent have been shown to arise from the ultimobranchial body (Pearse & Carvalheira, 1967) and presumably this also applies in man.

Further embryological studies by Sugiyama, Kitoh & Yokoni (1969) indicate that in the thyroid of human foetuses, cysts of the ultimobranchial body persist into late antenatal life. Such cysts were not found in the neonates of the present study, yet in human adults follicles lined wholly by C cells have been observed by Solcia *et al.* (1970).

In the dog thyroid the presence of pseudo-follicles consisting solely of C cells has recently been reported (Teitelbaum, Moore & Shieber, 1971) and is confirmed in the present study. Such formations are known to occur in other species, notably cat and sheep (van Dyke, 1945). Cells forming pseudo-follicles in the dog have cytological staining reactions characteristic of a polypeptide producing cell: they have secretory granules (Teitelbaum, Shieber & Moore, 1970) and stain metachromatically – a property which Pearse (1969) states is related to hormone production.

The paucity of C cells in neonatal human thyroids, as compared with canine thyroids, is remarkable. It is conceivable that the small number of human cells could be compensated for by the presence of C cells in organs other than the thyroid. Galante *et al.* (1968) have shown that calcitonin can be extracted from the thymus: this suggests that C cells might be present in the thymus. Thymic tissue was not examined in the present study; parathyroid glands contained no C cells in any of the neonates used. Though not quantitated, the neonatal human C cell population appears to constitute less than 1% of the total thyroid gland.

Some neonatal C cells have cytoplasmic processes. Similar morphological forms of C cells have been described in guinea-pigs and tree shrews by Welsch, Pitney & Pearse (1969), who believe that the processes are either a fixation phenomenon or reflect a atavistic locomotor ability. However, sections of both Helly- and GPA-fixed neonatal tissue reveal these cell processes, so they are probably not a fixation artefact.

The positions of C cells in the dog thyroid in relation to the follicles are described as either intrafollicular, parafollicular or interfollicular (Fig. 7). "Parafollicular" is used here to describe one type of situation of C cells rather than as synonymous with C cell. This positional terminology is a simplification of Sandritter & Klein's (1954) classification, which, however, does not take cognizance of the basement membrane.

C cell granules

Many argyrophilic reactions can be satisfactorily used to demonstrate C cells in the thyroid. Silver impregnation according to the methods of Cajal, Gross-Schultze, Davenport or Grimelius have been applied successfully in animal studies (Nonidez,

Human neonatal

1932; Sandritter & Klein, 1954; K
method as used by Nonidez (1932
follicular cells in the neonatal hur
(1970) in pathological human mat
are impregnated, whereas the techn
in which impregnation can be cat
sulphide groups, due to generalized
silver attachment such as is seen
method. However, in the present s
follicular cells even in the freshest

Electron microscopic studies ha
periphery of secretory granules o
Granules had been shown previo
staining (Tashiro, 1964; Pearse,
calcitonin is shown to attach to
indicating that at least the antige
in the secretory granules. There
these granules are calcitonin: dog
ionic calcium infusions which pro
MacIntyre & Pearse, 1964. Pearse
differences in granule content obse
reflect different stages in the secr
content in the C cells of neonates
observation may be explained by
exposed to any hormone-releasing
hypercalcaemia, a state which cou
collection of the material.

The presence of secretory gra
embryos (Chan & Conen, 1971),
1968) and normal adult thyroid
electron microscopic studies will

On the basis of histochemical
hormone-producing cells in dog
(Solcia & Sampietro, 1968; Pe
hormone-producing ability.

Although Solcia & Sampietro
after hydrolysis, the present res
contrast, acid hydrolysis is esse
human cells. This might be due
the cell cytoplasm or to an initial
human cells need unmasking. Pe
ve by protein carboxamido side c
groups are thereby unmasked.

In the human thyroid, metac

1932; Sandritter & Klein, 1954; Kameda, 1968; Solcia *et al.* 1970). However, Cajal's method as used by Nonidez (1932) did not provide good discrimination of C from follicular cells in the neonatal human thyroid. This was found also by Kracht *et al.* (1970) in pathological human material. With Cajal's method whole blocks of tissue are impregnated, whereas the technique of Grimelius is carried out on single sections in which impregnation can be carefully controlled. Grimelius (1968*b*) suggests that sulphide groups, due to generalized tissue putrefaction, result in universal cytoplasmic silver attachment such as is seen in human tissue impregnated according to Cajal's method. However, in the present study Cajal's method failed to discriminate C from follicular cells even in the freshest material.

Electron microscopic studies have shown silver attachment to be localized at the periphery of secretory granules in dog C cells (Vassallo, Capella & Solcia, 1971). Granules had been shown previously by using conventional electron microscopic staining (Hashiro, 1964; Pearse, 1966). On electron micrographs the antibody to calcitonin is shown to attach to these secretory granules (Kalina & Pearse, 1971), indicating that at least the antigenic sites of this polypeptide hormone are present in the secretory granules. There is additional evidence which favours the view that these granules are calcitonin: dog C cell granules are dispersed into the circulation by ionic calcium infusions which provide a potent calcitonin-releasing stimulus (Foster, MacIntyre & Pearse, 1964; Pearse, 1966). If the granules do contain calcitonin, the differences in granule content observed in C cells in the dogs of the present study may reflect different stages in the secretory cycle of calcitonin. By contrast, the granule content in the C cells of neonates did not vary to any extent from cell to cell. This observation may be explained by suggesting that in neonates the cells have not been exposed to any hormone-releasing stimuli. The maternal sera showed no evidence of hypercalcaemia, a state which could have led to degranulation of C cells prior to the collection of the material.

The presence of secretory granules in C cells has now been shown in human embryos (Chan & Cohen, 1971), pathological adult thyroid (Braunstein & Stephens, 1968) and normal adult thyroid (Heitelbaum, Moore & Shieber, 1971). No doubt electron microscopic studies will also confirm their presence in neonates.

Metachromasia

On the basis of histochemical studies it is now believed that metachromasia of hormone-producing cells is due to carboxyl side chains of polypeptide hormones (Solcia & Sampietro, 1968; Pearse, 1969). Metachromasia is taken to indicate hormone-producing ability.

Although Solcia & Sampietro (1968) originally showed metachromasia in dogs after hydrolysis, the present results show that acid hydrolysis is unnecessary. By contrast, acid hydrolysis is essential to demonstrate metachromasia in neonatal human cells. This might be due to differences of the microchemical environment of the cell cytoplasm or to an initial unavailability of carboxyl side groups, which in the human cells need unmasking. Pearse (1969) stated that acid hydrolysis either converts protein carboxamido side chains into carboxyl groups or that protein carboxyl groups are thereby unmasked.

In the human thyroid, metachromasia is optimally shown after GPA fixation.

This result is in accordance with that of Solcia, Vassalo & Capella (1968), who showed that in the dog, aldehyde fixatives are necessary for the demonstration of metachromasia of C cells. No doubt methylol cross linkages formed between proteins by aldehyde fixation provide larger protein complexes for dye attachment (French & Edsall, 1945).

Cellular enzymes

In the present study enzyme distribution in all epithelial and epithelioid cells of neonatal human thyroids was compared with toluidine blue metachromasia. This revealed three types of cellular appearances. The terms A (acinar), C (calcitonin) and AC (an intermediate form) were adopted in order to keep as much as possible in line with the nomenclature that Pearse (1966) used for thyroid cells in the dog. Dog A cells, Pearse showed, had a low zGPDH content, as did the A cells of neonates, which in addition demonstrated no toluidine blue metachromasia. Human C cells, too, exhibited definite toluidine blue metachromasia; their zGPDH content was very high, as is characteristic of dog C cells according to Foster *et al.* (1964) and Pearse (1966). A third kind of cell appearance, called the AC cell, was distinguished from A and C cells: these cells showed a moderately high content of zGPDH, so resembling C cells, but no metachromasia, thus resembling A cells. Pearse showed that, apart from C cells, dog thyroids exhibit cells which contain less zGPDH than C cells. These he termed C cells. Because AC cells showed no metachromasia it is unlikely that they contained polypeptide hormone. I therefore could not equate AC cells with C cells, since the designation implies that these are a variety of C cell. Further investigation is necessary before it can be decided whether human AC cells are a unique cell population or whether they warrant inclusion with A or with C cells. It is possible that they might represent an inactive state of the C cells, having liberated, but not yet re-synthesized, their hormone content.

The presence of AC cells was not established in the dog. Present results confirm that there is a large population of dog C cells with a high content of zGPDH. Demonstration of this high zGPDH content depends on the use of menadione as a co-factor: when this is omitted only small amounts of enzyme can be demonstrated. Biochemically, Brodie & Watanabe (1966) have shown that menadione enables electron transfer to bypass the electron chain between NADH and cytochrome *b*, thereby raising the electron charge to the oxidation potential of the tetrazolium salt (MTT). The fact that some zGPDH was shown in the absence of menadione and that more was shown in the presence of menadione lends support to the view of Boxer & Devlin (1961) that two intracellular reaction states of zGPDH exist.

The presence of cholinesterase in dog C cells, demonstrated by Sandritter, Kummer, Pillat & Rowe in 1956, was confirmed in this study. Its presence has also been shown in C cells of guinea-pigs (Dejardin, 1955) and pigs (Carvelheira & Pearse, 1967). In the dog thyroids used in the present study, some enzyme activity was noted along the cell borders. Welsch & Pearse (1969) found the enzyme situated along the cell membrane in their electron micrographs of rabbit thyroids. The absence of pseudo-cholinesterase from C cells of neonates was unexpected, as cells of several species (see above) are known to contain cholinesterases. However, cholinesterase demonstration is capricious and some methodological manipulation may still show this enzyme to be present in the C cell of neonates.

C cells in adults

C cells have been demonstrated by this study in the thyroids of human neonates these cells have been described also in the adult but such reports are few in number As far as I am aware, the first conclusive demonstration of C cells in the thyroid of normal adults was reported by Sandritter & Klein (1954). They studied 12 normal thyroids by means of the C oss Schultze silver impregnation method and commented briefly on the small number of cells which they found in a "few" thyroids. The paucity of these cells in neonates has been remarked on in the present study.

According to Beskid & Rosciszewska (1968) the normal adult C cell has a high content of zGPDH, as was found too in the neonates, but the cells illustrated by these authors do not convincingly resemble C cells.

Further searches for C cells in adults have been made in pathological thyroids. Solcia *et al.* (1970) noted argyrophilic cells situated posteriorly in thyroids removed for carcinoma. Braunstein & Stephens (1968), in their electron micrographs of goitrous thyroids, noted two cells which they felt, because of the presence of granules, were C cells. In another electron microscopic study Teitelbaum *et al.* (1971) showed several C cells in the normal lobe of an adenomatous thyroid gland. These cells contained a higher concentration of cytoplasmic granules than those observed by Braunstein & Stephens (1968).

Oxidative enzyme studies on adult goitres (Tremblay & Pearse, 1960) have revealed cells with a moderately high content of dehydrogenases (NADH diaphorase and succinic dehydrogenase) which in their NADH enzyme content resemble either the AC or the C cells of the neonate.

SUMMARY

The presence of C cells has been demonstrated in the thyroids of five stillborn human neonates by means of histochemical methods known to demonstrate C cells in dogs. These human C cells have been compared with the C cells of young dogs.

In the neonates C cells were distributed mainly in the posterior region of the upper pole of both lobes, where they were found scattered in clusters of six to eight cells; they were not as widely distributed as in the dog thyroid, nor were they by any means as numerous.

C cells of both dogs and neonates were found in positions described as intrafollicular (in between follicular cells), parafollicular (applied between the follicular cells and the follicular cell basement membrane) and interfollicular (in between follicles and surrounded by their own basement membrane).

The presence of secretory granules in dog C cells was confirmed. They were shown also in the cells of human neonates. These granules were most satisfactorily demonstrated by means of the silver impregnation method of Grimelius on tissue fixed with glutaraldehyde–picric acetic acid fixative.

The presence of large amounts of oxidative enzymes (zGPDH and NADH reductase) in human neonatal thyroid cells was correlated with toluidine blue metachromasia, an indicator of polypeptide hormone-producing ability. C cells contained a high content of enzyme and were metachromatic, whereas acinar (A cells)

contained very little enzyme and did not show metachromasia. A distinctive cell appearance was that of cells provisionally termed AC cells: these, like A cells, were not metachromatic but, like C cells, showed high oxidative enzyme levels. Their significance remains to be elucidated.

The author is greatly indebted to Professor M. Shear of the Department of Oral Pathology, University of the Witwatersrand, for the freeze-drying facilities, to Messrs R. Herman, A. Scott and B. Wray for technical assistance, and to Professors P. V. Tobias, A. Andrew and M. Shear for their continual interest and encouragement.

This work was supported in part by a grant from the Medical Research Council and by a Round Table Research Fellowship.

REFERENCES

BAKER, E. C. (1970). Contributions to the minute anatomy of the thyroid gland of the dog. *Proceedings of the Royal Society, London* **B 24**, 240–241.

PISKIN, M. & ROSZKOWSKA, A. (1968). C cells in the mouse, animal and human thyroid gland. *Folia histochemica et cytochemica* **6**, 461–468.

BOYER, G. F. & DENTIN, T. M. (1961). Pathways of intracellular hydrogen transport. *Nature* **134**, 1395–1501.

BRAUNSTEIN, H. & STEPHENS, C. I. (1968). Parafollicular cells of human thyroid. *Archives of Pathology* **86**, 656–666.

BROOM, A. F. & WETNALL, T. (1968). Mode of action of vitamin K in microorganisms. *In Vitamins and Hormones* (Ed. R. S. Harris, J. G. Wool and I. A. Loraine) **24**, 447–463. New York: Academic Press.

BUSSOLATI, G. & PEARSE, A. G. E. (1967). Immunofluorescent localisation of calcitonin in the C cells of the pig and dog thyroid. *Journal of Endocrinology* **37**, 209–209.

CARVALHEIRAS, A. F. & PEARSE, A. G. E. (1967). The cytology and cytochemistry of the C cells in the thyroid gland of the pig. *Journal of the Royal Microscopical Society* **86**, 203–209.

CHAN, A. S. & COMAN, P. F. (1971). Ultrastructural observations on cytodifferentiation of parafollicular cells in the human fetal thyroid. *Laboratory Investigation* **25**, 249–259.

COPP, D. H., CAMERON, E. C., CHENEY, B. A., DAVIDSON, A. G. F. & HENZE, K. G. (1962). Evidence for calcitonin – a new hormone from the parathyroid that lowers blood calcium. *Endocrinology* **70**, 638–649.

DUJARDIN, M. (1955). Les cholinesterases dans la glande thyroïde du cobaye. *Comptes Rendus de la Société de Biologie* **149**, 621–622.

FOSTER, G. V., MACINTYRE, I. & PEARSE, A. G. E. (1964). Calcitonin production and the mammalian C cell of the dog thyroid. *Nature, London* **203**, 1029–1030.

FRASER, D. & GOMORI, G. (1945). The reaction of formaldehyde with amino acids and proteins. In *Advances in Protein Chemistry* (Ed. M. L. Anson and J. T. Edsall) **2**, 277–316. New York: Academic Press.

GALANTE, L., GUDMUNDSSON, T. V., MATTHEWS, E. W., TAL, A., WILLIAMS, E. D., WOOLNOUGH, N. J. V. & MACINTYRE, I. (1968). Thymic and parathyroid origin of calcitonin in man. *Lancet* **ii**, 537–539.

GEREBTZOFF, M. A. (1953). Recherches histochimiques sur les acétylcholine et choline esterases. *Acta anatomica* **19**, 366–379.

GRIMELIUS, L. (1968*a*). A silver nitrate stain for A_1 cells in human pancreatic islets. *Acta Societatis medicorum upsaliensis* **73**, 243–270.

GRIMELIUS, L. (1968*b*). The argyrophil reaction in islet cells of adult human pancreas studied with a new silver nitrate procedure. *Acta Societatis medicorum upsaliensis* **73**, 271–294.

HAMPERL, H. (1937). Über das Vorkommen von Drüsenzyten in verschiedenen Organen und ihren Geschwülsten. *Zeitschrift für die pathologische Anatomie* **298**, 327–378.

HARRIS, C. A., WILLIAMS, G. A., TENNYSON, A. A. ARSAULT, C. D. (1966). Thyrocalcitonin: cytological localization by immunofluorescence. *Science* **152**, 75–77.

HESS, R., SCARPELLI, D. G. & PEARSE, A. G. E. (1958). The cytochemical localization of oxidative enzymes. II. Pyridine nucleotide-linked dehydrogenases. *Journal of Biophysical and Biochemical Cytology* **4**, 753–760.

HURTHLE, K. (1894) Beitrage zur Kenntniss der Secretionsvorgangs in der Schilddruse. *Archiv fur die gesammte Physiologie* **56**, 1–44

KALINA, M., FOSTER, G. V., CLARK, M. B. & PEARSE, A. G. E. (1970). C cells in man. *Calcitonin* 1969. *Proceedings of the Second International Symposium* (Ed. S. Taylor), pp. 268–273. London: Heinemann.

KALINA, M. & PEARSE, A. G. E. (1971) Ultrastructural localisation of calcitonin in C-cells of dog thyroid: an immunocytochemical study. *Histochemie* **26**, 1–8.

KAMIDA, Y. (1968). Parafollicular cells of the thyroid as studied with Davenport's silver impregnation. *Archiva histologia japonica* **30**, 90–94

KINGSBURY, B. F. (1935) On the fate of the ultimobranchial body within the human thyroid gland. *Anatomical Record* **61**, 155–167

KRACHT, J., HACHMEISTER, U. & CHR., L. (1970) C cells in the human thyroid. *Calcitonin* (1969). *Proceedings of the Second International Symposium* (Ed. S. Taylor), pp. 274–280. London: Heinemann.

MASSON, P. (1928) Carcinoids (argentaffin-cell tumours) and nerve hyperplasia of the appendicular mucosa. *American Journal of Pathology* **4**, 181–212

NACHLAS, M. M., TSOU, K. C., DE SOUZA, E., CHENG, C. S. & SELIGMAN, A. M. (1957). Cytochemical demonstration of succinic dehydrogenase by the use of a new *p*-nitrophenyl substituted ditetrazole. *Journal of Histochemistry and Cytochemistry* **5**, 420–436

NONIDEZ, J. F. (1932) The origin of the 'paralollicular' cell, a second epithelial component of the thyroid gland of the dog. *American Journal of Anatomy* **49**, 479–505

PEARSE, A. G. E. (1966) The cytochemistry of the thyroid C cells and their relationship to calcitonin. *Proceedings of the Royal Society, London* B **164**, 478–487

PEARSE, A. G. E. (1969) Random coil conformation of polypeptide hormone precursor protein in endocrine cells. *Nature, London* **221**, 1210–1211

PEARSE, A. G. E. & CARVALHEIRA, A. F. (1967) Cytochemical evidence for an ultimobranchial origin of rodent thyroid C cells. *Nature, London* **214**, 929–930

PEARSE, A. G. E., COLLINGS, I., WEAVERS, B. & ERIKSEN, S. (1970). The endocrine polypeptide cells of the human stomach, duodenum and jejunum. *Gut* **11**, 649–658.

PEARSON, C. K. (1963) A formalin–sucrose–ammonia fixative for cholinesterases. *Journal of Histochemistry and Cytochemistry* **11**, 665–666

RINIKER, B., NEHER, R., MAIER, R., KAHNT, F. W., BYFIELD, P. G. H., GUDMUNDSSON, T. V., GALANTE, I. & MACINTYRE, I. (1968) Menschliches Calcitonin. I. Isolierung und Charackterisierung. *Helvetica chimica acta* **51**, 1728–1742

SANDRITTER, W. & KLEIN, K. H. (1954) Über argyrophile Zellen in der Schilddruse. *Frankfurter Zeitschrift fur Pathologie* **65**, 204–218

SANDRITTER, W., KEMMER, F., PFEIFF, G. & ROWE, I. (1956) Zur Histochemie und Funktion der parafollikularen Zellen in der Schilddruse. *Klinische Wochenschrift* **34**, 871–872

SCARPELLI, D. G., HESS, R. & PEARSE, A. G. E. (1958) The cytochemical localization of oxidative enzymes. I. Diphosphopyridine nucleotide diaphorase and triphosphopyridine nucleotide diaphorase. *Journal of Biophysical and Biochemical Cytology* **4**, 51–52

SOLCIA, E., CAPELLA, C., SAMPIETRO, R. & VASSALLO, G. (1970) The distribution of human 'C' cells and their relationship to osteopetrosis and medullary carcinoma of the thyroid. *Calcitonin* (1969). *Proceedings of the Second International Symposium* (Ed. S. Taylor), pp. 220–226. London: Heinemann

SOLCIA, E. & SAMPIETRO, R. (1968) New methods for staining secretory granules and 5-hydroxytryptamine in the thyroid C cells. *Calcitonin. Proceedings of the Symposium on Thyrocalcitonin and the C cells* (Ed. S. Taylor), pp. 127–132. London: Heinemann.

SOLCIA, E., VASSALLO, G. & CAPELLA, C. (1968) Selective staining of endocrine cells by basic dyes after acid hydrolysis. *Stain Technology* **43**, 257–263

STUDY, M., THOMPSON, B., ISLER, H. & LE BLOND, C. P. (1961). The 'light cells' of the thyroid gland in the rat. *Endocrinology* **68**, 292–308.

SUGIYAMA, S., TAKI, A., MACHIDA, Y. & FURIHATA, N. (1959) The significance and fate of the ultimobranchial body in man in relation to the development of the thyroid gland. *Okajimas Folia anatomica japonica* **32**, 329–340

SUGIYAMA, S., KITOH, J. & YOKOTA, S. (1969) On the problem of the development of the parafollicular cells from the human ultimobranchial body in prenatal life. *Okajimas Folia anatomica japonica* **46**, 811–[illegible]

TASHIRO, M. (1964) Electron microscopic studies of the parafollicular cells in the thyroid gland of the dog. *Okajimas Folia anatomica japonica* **39**, 191–211

TELLEBAUM, S. L., MOORE, K. L. & SHEIBER, W. (1971) Parafollicular cells in the normal human thyroid. *Nature, London* **230**, 334–335

TELLEBAUM, S. L., SHEIBER, W. & MOORE, K. L. (1970) Ultrastructural studies of the parafollicular cells of the dog and human thyroid. *Journal of Cell Biology* **47**, 210*a*.

Tremblay, G. & Pearse, A. G. E. (1960). Histochemistry of oxidative enzyme systems in the human thyroid with special reference to Askanazy cells. *Journal of Pathology and Bacteriology* **80**, 353–358.

van Dyke, J. H. (1945). Behaviour of ultimobranchial tissue in the post-natal thyroid gland: epithelial cysts, their relation to thyroid parenchyma and to 'new growths' in the thyroid gland of young sheep. *American Journal of Anatomy* **76**, 201–252.

Vassallo, G., Capella, C. & Solcia, E. (1971). Grimelius silver stain for endocrine cell granules as shown by electron microscopy. *Stain Technology* **46**, 7–13.

Wattenberg, L. W. & Leong, J. L. (1960). Effects of coenzyme Q_{10} and menadione on succinic dehydrogenase activity as measured by tetrazolium salt reduction. *Journal of Histochemistry and Cytochemistry* **8**, 296–303.

Welsch, U., Elleney, E. & Pearse, A. G. E. (1969). Comparative studies on the ultrastructure of the thyroid parafollicular C cells. *Journal of Microscopy* **89**, 83–94.

Welsch, U. & Pearse, A. G. E. (1969). Electron cytochemistry of BuChe and AChe in thyroid and parathyroid C cells under normal and experimental conditions. *Histochemie* **17**, 1–10.

Zechel, G. (1933). Observations on the follicular cycle and on the presence of the 'macrothyrocyte' in the human thyroid. *Anatomical Record* **56**, 119–130.

S Afr J med Sci (1973), **38**, 17-22

THE NATURE OF SILVER BINDING IN THE CANINE THYROID "C" CELL

by

W. E. W. ROEDIGER

Department of Anatomy, University of the Witwatersrand, Johannesburg, South Africa.

[RECEIVED 6TH FEBRUARY, 1973.]

The "C" cell argyrophilia has been demonstrated using the modified Gros-Schultze, Cajal's and Bodian-type silver impregnation methods [Nonidez, 1932, Sandritter and Klein, 1954, Kameda, 1968]. Light microscopy reveals a granular disposition of silver deposits within the cell cytoplasm (Fig. 1) and recently Vassallo *et al.* [1971] have shown, ultrastructurally, that the silver particles are localized at the periphery and in the substance of the cell secretory granules. Secretory granules are readily dispersed by means of calcium infusions which act as a potent calcitonin-releasing stimulus [Pearse, 1966]. Antibody localization at electron microscope level has revealed that these granules are calcitonin [Kalina and Pearse, 1971]. With this knowledge and the availability of the primary amino acid sequence of the mammalian calcitonin polypeptide chain, the "C" cell was chosen to elucidate the reactive tissue radicles participating in its silver binding.

Silver impregnation parameters in the Grimelius [1968] method have been clearly defined and the procedure was found to yield extremely good results with canine thyroid "C" cells [Solcia, *et al.*, 1970]. This method employs acetate-buffered aqueous silver nitrate for impregnation and subsequent exogenous reduction-fixation with hydroquinone and sodium sulphite. The present investigation was undertaken in order to determine the basis of the argyrophilia in the "C" cells of the dog thyroid.

MATERIALS AND METHODS

Six fresh canine thyroids (*Canis vulgaris*), of random age and sex, were fixed in glutaraldehyde-picric-acetic acid (G.P.A.) and 5 μm paraffin sections were subjected to the following procedures:—

(a) The standard Grimelius silver impregnation was carried out at pH 5.5. This acted as a control. Sections were impregnated in 0.2M acetate buffer varying from pH 4.0 to 6.0 using an otherwise unaltered Grimelius reaction.

(b) Silver impregnation was performed on alternate serial sections that were initially exposed to:

(i) 0.5 per cent H_2SO_4-potassium permanganate oxidation for 10, 30 and 60 min [Landing *et al.*, 1956];

(ii) 1 per cent periodic acid (pH 2.5) oxidation for 10 min, 30 min, 2 h and 4 h at 22° C;

(iii) Acetylation in 1:1 acetic anhydride pyridine at 60° C for 30 min (mild), 1 h, 2 h and 4 h (drastic) [McManus and Cason, 1950];

(iv) Acetylation both mild and drastic followed by saponification in 0.1 N KOH for 15 min;

(v) Sulphydryl block with 0.1M N-ethyl maleimide (NEM) at pH 7.4 for 4 h at 37° C [Pearse, 1968]. This procedure was also carried out on sections previously oxidized with 1 per cent periodic acid for 10 min, and 4 h.

Alternate consecutive sections were utilized as controls to localize "C" cells.

RESULTS

Argyrophilia was recorded semi-quantitatively. On the basis of cell numbers showing positive argyrophilia, when all the cells were positive as compared with controls, this was recorded as (+ + + +); when 80 per cent of cells were involved (+ + +); 60 per cent(+ +); 40 per cent (+); 20 per cent (−) and less than 20 per cent (−).

The results obtained are given in Table I.

TABLE I

Cell argyrophilia expressed relative to control sections impregnated according to the Grimelius silver technique

Grimelius pH 5.5 (control)	+ + + +
pH 5.0	+ + +
pH 4.5	+ +
pH 4.0	+
N ethyl maleimide block	+ + + +
H_2SO_4 permanganate oxidation	
10 min and longer	−
1.0% periodic acid block 10 min	+ + +
30 min	+ +
2 hrs	+
4 hrs	−
Acetylation: mild and drastic	−
Acetylation and alkaline saponification	
mild acetylation	+ + + +
drastic acetylation	− or +

The pH: The Standard Grimelius method performed at pH 5.5 resulted in an intense silver reaction in all cells (Fig. 1). When however, the pH of the acetate buffer was lowered, both the intensity of the reaction and the number of cells with positive argyrophilia were reduced.

Sulphydryl block by means of N-ethyl maleimide did not significantly alter silver attachment in the cells.

Oxidation by means of acid permanganate even for short periods completely inhibited argyrophilia. Periodate oxidation showed a progressive quantitative decrease with increasing time of exposure to periodic acid (Fig. 2).

Acetylation saponification acetylation, both mild and drastic, inhibited silver attachment (Fig. 3) and the results could be reversed with potassium hydroxide saponification on slides that were mildly acetylated. Saponification following drastic 4 h acetylation led to a loss of many sections, but in material which could be examined, argyrophilia was not re-established.

DISCUSSION

In various animal species a polypeptide with thirty-two amino acids can be consistently extracted from tissues containing 'C' cells [Brewer, 1970]. These amino acids relate accurately to the amino acid residues of calcitonin. The extent to which the primary polypeptide structure is modified in the cell granules is unknown, but *in vitro*, porcine and bovine calcitonin show random coil conformation with minimal rotational ability of phenylalanine, tyrosine and tryptophan in solution [Brewer, 1971]. This is supported by the histochemical studies of Pearse [1969] which strongly suggest that calcitonin or calcitonin precursors are arranged in a random coil conformation within the cell. Based on the electron micrographs of Vassallo *et al.* [1971] silver

localization could point to reactive gr
membrane surrounding the secretory gran
peptide chain combination product.

pH. Silver impregnation is to some e
develops below pH 4.0 in 'C' cells. This
to disulphide and sulphydryls where the
Decreased rate of reaction (K value) s
groups occurs at lower pH levels esp
Charge dependency of silver attachment
which are ionized at the experimental
γ carboxyl (pKa 4.25), and imidazole
present in calcitonin and could be imp
However, the pKa's of amino acid side
attachment does occur at higher pH le
acids could not be as extensively dissoc

Effect of oxidation. This is dependent
ganate is a rapid and universal tissue
oxidizing cystine, methionine and tryp
of oxidizing test-tube samples of cyst
and methionine, although the oxidation
pH and temperature [Clamp and Hough,
(22 C) were maintained while the time
decrease of argyrophilia with longer per
with the slow oxidation of amino acids w
acid sample studies. For example, after 6
of periodic acid, while after 28 h 2.20 mol
the times of exposure used on the tissue
test-tube amino acid samples, the poin
seems to be borne out and some change
for the reversal of argyrophilia. Test-t
contained within a polypeptide chain wa
tryptophan, tyrosine and histidine [Cla
acid residues that need further conside
tyrosine and tryptophan histochemically
observation). By inference therefore the
increased exposure time to periodic acid
cystine, cysteine, methionine and histi
oxidized.

Sulphur containing amino acids. Cysti
in calcitonin. Disulphides and sulphydr
are reflected in a positive DDD reacti
S—CH_2 side chain in intact protein
[Cecil, 1963], whereas sulphydryl group
bind excessive silver in a ratio of grea
attachment is shown to align along bande
in hair [Swift, 1968]. N-ethyl malei
[Smyth *et al.*, 1960] yet alkylation fail

localization could point to reactive groups in the secretory granule itself, the membrane surrounding the secretory granule or to the resultant of a vesicle membrane-peptide chain combination product

pH. Silver impregnation is to some extent controlled by pH. Poor argyrophilia develops below pH 4.0 in 'C' cells. This observation is similar to the silver binding to disulphide and sulphydryls where the rate of reaction (K value) is limited by pH. Decreased rate of reaction (K value) and silver attachment to R.S—S.R and —SH groups occurs at lower pH levels especially below 5.0 [Cecil and McPhee, 1957]. Charge dependency of silver attachment draws attention to those amino acid groups which are ionized at the experimental pH levels, namely β carboxyl (pKa 3.65), γ carboxyl (pKa 4.25), and imidazole (pKa 6.00). The relevant amino acids are present in calcitonin and could be implicated in silver binding on an empirical basis. However, the pKa's of amino acid side chains in calcitonin are not known and silver attachment does occur at higher pH levels, i.e. above 6, at which value these amino acids could not be as extensively dissociated ionically.

Effect of oxidation. This is dependent on the nature of the oxidant. Acid permanganate is a rapid and universal tissue oxidizer and not unlike performic acid in oxidizing cystine, methionine and tryptophan [Toennis, 1942]. Periodic acid is capable of oxidizing test-tube samples of cystine, cysteine, tyrosine, tryptophan, histidine and methionine, although the oxidation rate is dependent on the period of exposure, pH and temperature [Clamp and Hough, 1965]. In this study pH (2.5) and temperature (22° C) were maintained while the time of oxidation was varied. The progressive decrease of argyrophilia with longer periods of periodic acid oxidation correlates well with the slow oxidation of amino acids which Clamp and Hough noted in their amino acid sample studies. For example, after 6 h at pH 2.0 cystine had consumed 0.78 mole of periodic acid, while after 28 h 2.20 moles of periodic acid were consumed. Although the times of exposure used on the tissue sections do not correlate with the times of the test-tube amino acid samples, the point of progressive oxidation of amino acids seems to be borne out and some change brought about by this oxidation is responsible for the reversal of argyrophilia. Test-tube amino acids that were oxidized when contained within a polypeptide chain were confined to cystine, cysteine, methionine, tryptophan, tyrosine and histidine [Clamp and Hough, 1965] and it is these amino acid residues that need further consideration. I have not been able to demonstrate tyrosine and tryptophan histochemically in canine thyroid 'C' cells (unpublished observation). By inference therefore the progressive decrease in argyrophilia with increased exposure time to periodic acid strongly suggests that the amino acid residues cystine, cysteine, methionine and histidine in the polypeptide hormone are slowly oxidized.

Sulphur containing amino acids. Cystine, cysteine and methionine are all represented in calcitonin. Disulphides and sulphydryl groups representative of these amino acids are reflected in a positive DDD reaction in the 'C' cell (Fig. 4). The methionine S—CH_3 side chain in intact protein is not accessible to analysis with heavy metals [Cecil, 1963], whereas sulphydryl groups, cysteine and reduced cystine, are known to bind excessive silver in a ratio of greater than 1:1 [Sluyterman, 1957]. Silver metal attachment is shown to align along bands which contain high concentrations of cystine in hair [Swift, 1968]. N-ethyl maleimide is a strong sulphydryl alkylating agent [Smyth *et al.*, 1960] yet alkylation failed to abolish silver attachment. The efficacy

of N-ethyl maleimide as a sulphydryl blocker has previously been demonstrated by Barrnett and Seligman [1952]. Cystine disulphide bonds are readily attacked by silver [Cecil and McPhee, 1957], either directly by the silver ion or via hydrolysis of the R.S—S.R bond to sulphydryl and from there by silver mercaptide formation, with sulphonic or sulphinic acid resulting (reaction 1). Oxidation of cystine provides sulphonic acid. The variable oxidation rates of periodic acid suggest that the conversion of cystine to sulphonic acid might be responsible for the inhibition of argyrophilia.

Reaction 1. Cystine with silver ions produces silvermercaptide with sulphinic and sulphonic acid



Acetylation. Both mild and drastic acetylation abolish this silver attachment and in the former case alkaline saponification partially restores such potential. Drastic acetylation is known to produce extraction of cellular constituents. This explains the failure to restore argyrophilia with saponification. Many residue groups may be acetylated or esterified, e.g. aldehydes, glycols, disulphides, hydroxy-amino, side-chain carboxyl and carboxamido groups [Fillie, 1966]. Carboxyl groups are esterified to methyl ketones or mixed anhydrides while disulphides form diacetyl esters and these latter have been shown by Cecil and McPhee [1957] to be unreactive with silver nitrate. Both cell membranes and thyroglobulin are rich in glycols, hydroxy-amino and carboxyl groups, but they demonstrate no argyrophilia. Exclusion of these same reactive groups also applies to canine 'C' cells in view of the negative results with thyroglobulin.

Carbohydrates and silver attachment. A reliable silver attachment method to demonstrate carbohydrates, utilizing the silver methenamine reaction following periodic acid oxidation, has been reported [Rambourg, 1967]. Comparison of this method with the Grimelius technique shows certain differences. The nature of silver in the present experiment is in the form of simple ionic solution and not amine complexed. The silver methenamine method relies on aldehydic groups, formed by periodic acid oxidation, to produce reduction of silver and a positive reaction. This contrasts with the effects of oxidation in the Grimelius method where a marked *decrease* in silver deposition follows oxidation. Pickett-Heaps [1967] points out that the variable attachment of silver to polysaccharides is dependent on the chemical variance of polysaccharides and the necessity of prior oxidation. Electron micrographs of tissue impregnated according to the Grimelius method reveal no silver attachment in areas which have a high concentration of carbohydrates [Vassallo *et al.*, 1971].

SUMMARY AND CONCLUSION

Acid permanganate oxidation, periodic acid oxidation, acetylation with saponification and sulphydryl block (N-ethylmaleimide) are employed to elucidate the nature of silver binding to the secretory granules in the canine 'C' cell impregnated according to the Grimelius silver technique. In the control sections maximal argyrophilia is obtained at pH 5.5 with a qualitative and quantitative decrease below this pH. Brief permanganate oxidation and two hour periodic acid oxidation prevent silver attachment. Acetylation also inhibits silver attachment while this remains unaffected by

blocker has previously been demonstrated by
disulphide bonds are readily attacked by silver
...ly by the silver ion or via hydrolysis of the
... there to silver mercaptide formation, with
(reaction 1). Oxidation of cystine provides
...tes of periodic acid suggest that the conversion
...sponsible for the inhibition of argyrophilia

...silvermercaptide with sulphinic and sulphonic acid

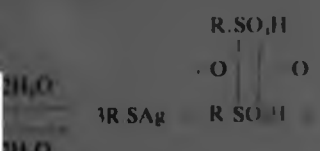

...cutylation abolish this silver attachment and
...on partially restores such potential. Drastic
...tion of cellular constituents. This explains
... saponification. Many residue groups may
..., glycols, disulphides, hydroxy-ammo, side-
... [Lillie, 1966]. Carboxyl groups are esterified
...hile disulphides form diacetyl esters and these
... McPhee [1957] to be unreactive with silver
...globulin are rich in glycols, hydroxy-amino
...trate no argyrophilia. Exclusion of these
...nine 'C' cells in view of the negative results

... A reliable silver attachment method to
...the silver methenamine reaction following
...ried [Rambourg, 1967]. Comparison of this
...ows certain differences. The nature of silver
... of simple ionic solution and not amine
...thod relies on aldehydic groups, formed by
...uction of silver and a positive reaction. This
... in the Grimelius method where a marked
...tion Pickett-Heaps [1967] points out that
...harides is dependent on the chemical
...ulty of prior oxidation. Electron micrographs
...rimelius method reveal no silver attachment
... of carbohydrates [Vassallo *et al.* 1971].

...ND CONCLUSION

... acid oxidation, acetylation with saponifica-
...mide) are employed to elucidate the nature
... in the canine 'C' cell impregnated according
... control sections maximal argyrophilia is
... quantitative decrease below this pH. Brief
...lodic acid oxidation prevent silver attach-
...ttachment while this remains unaffected by

sulphydryl block. Argyrophilia is probably related to disulphides which, with silver nitrate, form silver mercaptide and sulphonic acid. Sulphonic acid formed from disulphides by oxidation prevents silver mercaptide formation and argyrophilia. Acetylation of disulphides produces diacetyl esters which are unreactive with silver.

Argyrophilia is related to the polypeptide-producing potential of 'C' cells. Varying oxidation rates, sulphydryl block and acetylation provide some evidence that disulphide radicles are responsible for silver attachment in 'C' cells. How these disulphides are arranged in the 'C' cell secretory granules is unknown. Further sample studies on calcitonin might reveal whether calcitonin itself or a calcitonin-secretory membrane product acts as silver attacher.

The author is gratefully indebted to Professor M. Shear of the Department of Oral Pathology and Professor A. Andrew of the Department of Anatomy, University of the Witwatersrand, for their helpful advice and criticism in the preparation of this manuscript. Mr. A. Scott of the Department of Oral Pathology kindly assisted in the preparation of the photomicrographs.

This work was supported by a Medical Research Council Grant, No. M10 70 A2 RE.

REFERENCES

BARRNETT, R. J. and SELIGMAN, A. M. (1952). The histochemical demonstration of protein bound sulphydryl groups. *Science*, **116**, 323-327.

BREWER, H. B. (1970). Bovine thyrocalcitonin. *Calcitonin 1969, Proc. Second Int. Symp.*, p. 14-27 (Hememann, London).

BREWER, H. B. (1971). The conformation of porcine (PC), bovine (BC), human (HC) and salmon (SC) calcitonin. *Endocrinology—1971, Third Int. Symp. Abstracts*, p. 74.

CECIL, R. (1963). The role of sulphur in proteins. In *The proteins, composition, structure and function* (Ed. A. Neurath), **1**, 380-470. Academic Press, N.Y.

CECIL, R. and MCPHEE, J. R. (1957). Further studies on the reaction of disulphides with silver nitrate. *Biochem. J.*, **66**, 538-543.

CLAMP, J. R. and HOUGH, L. (1965). The periodate oxidation of amino acids with reference to studies on glycoproteins. *Biochem. J.*, **94**, 17-24.

GRIMELIUS, L. (1968). A silver nitrate stain for α cells in human pancreatic islets. *Acta Soc. Med. Upsal.*, **73**, 243-270.

KALINA, M. and PEARSE, A. G. E. (1971). Ultrastructural localization of calcitonin in C-cells of dog thyroid. An immunocytochemical study. *Histochemie*, **26**, 1-8.

KASHIMA, Y. (1968). Parafollicular cells of the thyroid as studied with Davenport's silver impregnation. *Arch. Histol. Jap.*, **30**, 83-94.

LANDING, B. H., HALL, H. I. and CLARK, D. W. (1956). Aldehyde fuchsin positive material of the posterior pituitary. *Lab. Invest.*, **5**, 256-266.

LILLIE, R. D. (1966). Acetylation of aldehydes produced by periodic acid oxidation. *J. Histochem. Cytochem.*, **14**, 529-537.

MCMANUS, J. F. A. and CASOS, J. I. (1950). Carbohydrate histochemistry studied by acetylation techniques. *J. Exp. Med.*, **91**, 651-654.

NONIDEZ, J. F. (1932). The origin of the "parafollicular" cell, a second epithelial component of the thyroid gland of the dog. *Am. J. Anat.*, **49**, 479-505.

PEARSE, A. G. E. (1966). The cytochemistry of the thyroid "C" cells and their relationship to calcitonin. *Proc. Roy. Soc. (Lond.), Series B*, **164**, 478-487.

PEARSE, A. G. E. (1968). *Histochemistry*, Vol. 1 (J. & A. Churchill, Ltd., London), p. 620.

PEARSE, A. G. E. (1969). Random coil conformation of polypeptide hormone precursor protein in endocrine cells. *Nature*, **221**, 1210-1211.

PICKETT-HEAPS, J. D. (1967). Preliminary attempts at ultrastructural polysaccharide localization in root tip cells. *J. Histochem. Cytochem.*, **15**, 442-455.

RAMBOURG, A. (1967). An improved silver methenamine technique for the detection of periodic acid-reactive complex carbohydrates with the electron microscope. *J. Histochem. Cytochem.*, **15**, 409-413.

SANDRITTER, W. and KEHS, K. H. (1954). Über argyrophile Zellen in der Schilddrüse. *Frankf. Z. Path.*, **65**, 204-218.

SELTZERMAN, L. A. A. (1957). The amperometric titration of sulfhydryl groups with silver nitrate. *Biochem. Biophys. Acta*, **25**, 402-403.

SMYTH, B. J., NAGAMATSU, A. and FRUTON, J. S. (1960). Some reactions of N-ethylmaleimide. *J. Am. Chem. Soc.*, **82**, 4600-4604.

SOLCIA, E., CAPELLA, C., SAMPIETRO, R. and VASSALLO, G. (1970). The distribution of human C cells and their relationship to osteoporosis and medullary carcinoma of the thyroid. *Calcitonin 1969, Proc. Second Int. Symp.*, pp. 220-226. (Heinemann, London).

SWIFT, J. A. (1968). The electron histochemistry of cystine containing proteins in thin transverse sections of human hair. *J. Roy. Micr. Soc.*, **88**, 449-460.

TOENNIS, G. (1942). The oxidative conversion of casein into protein free methionine and tryptophane. *J. Biol. Chem.* **145**, 663-670.

VASSALLO, G., CAPELLA, C. and SOLCIA, E. (1971). Grimelius' silver stain for endocrine cell granules as shown by electron microscopy. *Stain Tech.* **46**, 7-13.

LEGENDS TO PLATE 1

Fig. 1. Section of dog thyroid impregnated according to the Grimelius technique. Densely arranged secretory granules in the cytoplasm of the "C" cells. (× 600, green filter.)

Fig. 2. Grimelius impregnation after initial 30 min 1 per cent periodic acid oxidation. Several "C" cells (c) show decreased density of cytoplasmic granules. (× 200, green filter.)

Fig. 3. Grimelius impregnation after initial two hour acetic anhydride pyridine acetylation. "C" cells (a) show ghost granules or slight silver attachment. (× 480, green filter.)

Fig. 4. Section of freeze dried, formalin vapour fixed canine thyroid subjected to the DDD reaction after potassium cyanide reduction. Moderately high concentrations of both sulphydryl and disulphide groups are shown in the thyroglobulin (TG) and "C" cell cytoplasm (c). (× 200, green filter.)



G. (1970). The distribution of human C cells
carcinoma of the thyroid. *Calcitonin 1969*,
London)
tine containing proteins in thin transverse
into protein free methionine and trypto-
lus' silver stain for endocrine cell granules

TE I

he Grimelius technique. Densely arranged
0, green filter.)
et cent periodic acid oxidation. Several
es. (× 200, green filter.)
anhydride pyridine acetylation. (×
480, green filter.)
subjected to the DDD reaction
of both sulphydryl and disul-
cytoplasm (c). (× 200, green filter.)





PLATE I

Reprinted from CANCER, Vol. 36, No. 5, November 1975 Copyright, © 1975, by the American Cancer Society, Inc. J. B. Lippincott Company
Printed in U.S.A.

THE OXYPHIL AND C CELLS OF THE HUMAN THYROID GLAND

A Cytochemical and Histopathologic Review

W. E. W. ROEDIGER, MB, BCh*

The C and oxyphil cells of the human thyroid are analyzed in the light of recent advances in cellular biology, cytochemistry, and histopathology. The C cell is present in the normal human thyroid, where its identification is cardinally by means of argyrophilic cytoplasmic granules. The morphology, topography and argyrophilia of C cells are discussed with reference to tumor, cyst, and teratoma formation in the thyroid gland. Oxyphil cells of the thyroid are cytochemically akin to C cells but arise from follicular cells. They occur in the thyroid and other protein producing organs, but are themselves inefficient producers of proteins and glycoproteins. Speculation is made on their morphological characteristics, and consideration is given to DNA-RNA involvement in the functional and morphological alterations of this follicular cell type.

Cancer 36:1758–1770, 1975.

THE HUMAN THYROID IS CONSTITUTED BY cells of varied embryologic origin. Of the cells in the normal human thyroid gland, only follicular cells have been studied in detail with the electron microscope.[58] Similar investigations of the normal human C and oxyphil cells in the thyroid gland remain outstanding, though knowledge of their cytochemistry and pathologic behavior has rapidly accumulated. This review was undertaken in an attempt to clarify the normal distribution and histopathology of these two types of cells, which need more accurate anatomical and pathologic definition.[85]

CELLULAR TERMINOLOGY AND HISTORICAL BACKGROUND

Calcitonin-producing cells in animals are known by 17 different terms (Table 1). However, the two most common appellations employed are C cell[75] and parafollicular cell.[74] The former term is preferred to that of "parafollicular cell" because these cells are not always related to follicles in the parafollicular position[81] and may, furthermore, be found outside the thyroid, unrelated to follicles. The first convincing description of human C cells was given by Sandritter in 1954.[89] Since then they have been shown in normal thyroid and ultimobranchial bodies (UBB) by Kalina et al.,[51] Teitelbaum et al.,[106] Chan and Conen,[22] and Roediger,[81] and in pathologic thyroid glands by Solcia et al.,[94] Kracht et al.[59] and Ljungberg.[63]

The oxyphil cell of the thyroid was first described by Askanazy in 1898,[5] from cases of primary thyrotoxicosis, in which they were observed as large-bodied cells with eosinophilic cytoplasm.

The term "oxyphil cell" was introduced by Welsh in 1898[113] to describe cells in the human parathyroid gland. This usage was subsequently adopted by Eisenberg and Wallerstein[27] to describe a morphologically similar cell in the thyroid gland, this cell is the same as Askanazy had observed previously. The oxyphil cell was also given the designation "oncocyte" by Hamperl in 1937.[42,43]

Unfortunately Ewing, in 1919,[26] introduced the misnomer of Hürthle cell for the human thyroid oxyphil cell when in reality Hürthle had described the canine C cell (Fig. 1). This error led Hamperl to lodge a vigorous appeal[44,45] against the term "Hürthle cell" and proffered the term

---

* Research Fellow, Departments of Anatomy and Surgery, University of the Witwatersrand, Johannesburg, South Africa.

Supported by a Research Grant from the South African Medical Research Council (No. MRC 70/A5 RE) and a Round Table Research Fellowship.

Address for reprints: W. E. W. Roediger, Dept. of Surgery, University of the Witwatersrand, Johannesburg 2001, South Africa.

The author is gratefully indebted to Professor P. V. Tobias, Department of Anatomy, and Professor M. Shear, Department of Oral Pathology, for their continual encouragement and advice in the preparation of this report.

Received for publication November 8, 1974.

TABLE 1 Terminology Applied to C and Oxyphil Cells of the Thyroid Gland

C cell	Oxyphil cell
Parrot-Stammaye cell, 1876[5]	Askanazy cell, 1898[7]
Postglandulares bei Zelle, 1901[10]	Hürthle cell, 1894[1]
Oxinal cell, 1911[11]	Oxyphil cell, 1932[19]
Interfollicular-epithelium cell, 1922[16]	Oncocyte, 1951[22]
Mitochondria-poor cell, 1924[18]	Lymphocytic cell, 1962[26]
Paralollicular cell, 1943[24]	
Macrothyroc[illegible] 1933[10]	
Gray cell, 1937[26]	
Interfollicular cell, 194[illegible]	
Neurohormonal cell, 1939[28]	
Giant-light cell, 1940[4]	
Helle Zelle, 1946[30]	
Argyrophil cell, 1954[29]	
Replacement or chromophil cell, 1955[23]	
Light cell, 1961[27]	
Mitochondrion-rich cell, 1964[3]	
C cell, 1966[25]	

"oncocyte" is more correct. Oncocytes have been propagated by anatomists and pathologists on the European Continent.

My personal preference is to use the term "oxyphil cell of the thyroid" rather than "oncocyte," which etymologically suggests a link with "oncogenesis" and thus implies a relationship to carcinoma formation. Certainly such a relationship cannot be validated for all oxyphil cells of the thyroid.

Normal C Cell Morphology and Topography

Hematoxylin and eosin staining is not sufficient to demonstrate human C cells.[2] nor does a granular eosinophilic cytoplasm, nor a parafollicular position, nor a large cell-body characterize all C cells, as is occasionally stated to be the case.[4] To demonstrate human C cells special fixatives and stains are necessary; no single feature does the C cell owe its enigmatic plethora. Normal thyroid C cells, as distinct from human C cells, are distinguishable by numerous cytochemical properties,[6,8,9,12,20] peculiar only to this thyroid cell type. Of these cytochemical methods two are useful for staining human C cells in normal and pathologic thyroid specimens. These are 1) acid-hydrolysis-dependent toluidine blue metachromasia or fluorescent thiochrome[6,8,9,12,20] and 2) argyrophilic granule demonstration in tissue fixed in glutaraldehyde-potassium dichromate-lead nitrate (GPN)[20,21,29] Enzyme histo-

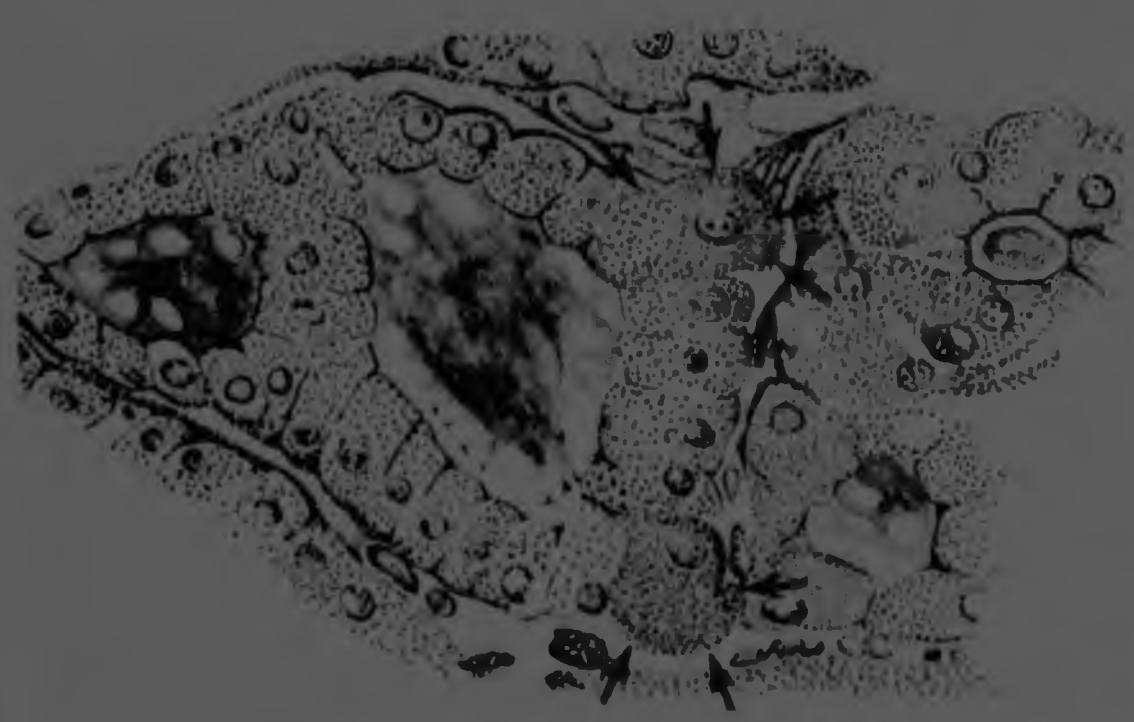

FIG. 1 Proto[illegible] cells in the thyroid gland of [illegible]. These cells are C cells. Redrawn from Hürthle - original illustration 1894

hus implies a relation-
tion. Certainly such a
lidated for all oxyphil

PHOLOGY AND
PHY

n staining is not suf-
man C cells,[17] nor does
ytoplasm, nor a para-
large cell body charac-
casionally stated to be
e human C cells, spe-
are necessary, to this
owe its enigmatic iden-
cells, as distinct from
uishable by numerous
[illegible],75,90,96,97] peculiar only
Of these cytochemical
for staining human C
thologic thyroid speci-
-hydrolysis-dependent
asia or fluorescent dye
2) argyrophilic granule
fixed in glutaraldehyde-
[illegible] Enzyme histo-



chemical methods, especially the demonstration of alpha glycerophosphate dehydrogenase (αGPDH), are helpful in demonstrating C cells, but do not absolutely distinguish the C cells from other epithelial cells, e.g. oxyphil cells, which have a similarly high dehydrogenase content[107] (Table 2).

Two morphological variants of normal human C cells can be distinguished [illegible] 1) a small-bodied, polygonal cell, and 2) a larger-bodied cell with streaming-cytoplasm or a cytoplasmic process (Fig. 2). Both cell variants are scattered mainly among follicles in positions that have been described as parafollicular, intrafollicular, or interfollicular.[81] They are frequently found in clusters. Less than 1% of the cell population in the thyroid gland seems to be constituted by C cells.[81] The distribution of C cells in animals (dog, rabbit, and cat) includes the thyroid, the superior parathyroids, and the thymus, which is contained within the lobes of the thyroid gland.[illegible] In man, their distribution in the thyroid is analogous to that in animals[illegible] (Fig. 3), though no search for C cells in the superior and inferior parathyroid glands or the thymus has been undertaken. The distribution of the human thyroid C cell accords with the regions in which C cell hyperplasia and familial medullary carcinoma originate most frequently, that is, in a posterosuperior position of both thyroid lobes.[71,114,117] Evidence that C cells occur in the human thymus is circumstantial: assay of thymic tissue for calcitonin in one study revealed a high content of hormone,[34] whereas another group of workers was unable to confirm this finding.[illegible] Medullary carcinomas, which occur in the mediastinum, are most likely secondary to a primary thyroid carcinoma.[illegible] These observations at present do not strongly support the view that C cells occur in the human thymus.

TABLE 2. Cytochemical Properties of Human Oxyphil and C Cells of the Thyroid

Features	Oxyphil cells	C cells
Cell size	Large-bodied 10–15 μm	Smaller 8–12 μm
Mitochondria	+ + + + (rich)	+ + (poor)
Enzymes		
αGPDH	+ + + +	[illegible]
NADH reductase	[illegible]	+ +
Metachromasia	+ +[44]	+ + + + (masked)
Phospholipids	[illegible]	(+ +)*
PTAH stain	+ve[66]	—
Secretory granules	nil	argyrophilic granules
Follicule formation	very occasionally	unusual

* Shown only in animal C cells.[illegible]

[illegible] represents [illegible] cell.

SECRETORY GRANULES OF C CELLS

Normal human C cells contain argyrophilic but not argentaffin secretory granules.[illegible] Argyrophilic secretory granules, in animals, are dispersable by hypercalcaemic stimuli.[illegible] With fluorescent antibody methods, canine[18] and human C cells[51] show a granular fluorescence, which presumably correlates with the granular secretory product shown with silver nitrate. Electron microscopic localization of antibody to calcitonin is confined to the secretory granules and endoplasmic reticulum.[52] These features suggest that secretory granules possess the antigenically active sites of calcitonin, which is synthesized in the C cell. The argyrophilia of normal human C cells is dependent upon exogenous reduction-fixation of silver particles.[81,82] However, in cases of medullary carcinoma, in addition to the C cell from which this carcinoma arises, a separate cell species is present.[83] This cell does not require exogenous reduction and is argentaffin.[illegible] It has numerous spidery processes and strong autoflourescence. Argentaffinity of this cell type may reflect an aberrant polypeptide-producing capacity of malignant cells, a feature which is borne out also by their frequent production of amyloid.[48]

Ultrastructurally, silver particles localize at the margin and in the substance of secretory granules in dog C cells[110] and in the same sites in cells of medullary carcinoma.[105] The histochemical significance of silver impregnation is gaining renewed interest.[103,111] Work on canine thyroid C cells[82] with the Grimelius method suggests that disulphide bonds, either of a calcitonin-membrane combination product[illegible] or of calcitonin itself are responsible for silver attachment. Disulphides of other polypeptide hormones (insulin) are unavailable for chemical activity due to steric hindrance,[14,66] and do not show histochemical reactivity with silver nitrate, and therefore argyrophilia.

Silver impregnation of secretory granules with the Grimelius method is possible in several other cells that produce a polypeptide hormone. In these as well as C cells, argyrophilia is correlated with the ultrastructural morphology of the secretory granules. Those granules that have a nonreticulated, randomly granular appearance (C cells of the thyroid),[12] or have an electron-dense core (pancreatic A cells),[40] are argyrophilic with the Grimelius method,[110] whereas



FIG 2 A single normal human C cell with streaming cytoplasm, a cytoplasmic process, and argyrophilic granules (human neonate) (GPA fixation, Grimelius silver impregnation, ×400)

those granules that have a crystalline matrix (pancreatic Beta cells)[40 41] or a regular granular pattern (pancreatic PP cells)[41] are not argyrophilic This correlation of argyrophilia with variations in the form of the secretory granules probably depends upon the steric conformation of the respective polypeptide hormones in their secretory granules Such cytochemical reactivity is similar to the toluidine blue "masked metachromasia" of C and other hormone-producing cells,[97] which metachromasia also is attributed to the conformational arrangement of hormones within the cellular granules [77]

MORPHOLOGY AND TOPOGRAPHY OF OXYPHIL CELLS

The oxyphil cell of the thyroid has remained enigmatic ever since it was first described in 1898 [5] A working description of this cell is as follows It is a polygonal cell, large-bodied in comparison to follicular or C cells, which has a granular acidophilic cytoplasm that contains numerous mitochondria; it has a large nucleus that may be binucleate (Fig 3), which is borne out by a frequent polyploidy of nucleoprotein [35] The oxyphil cell reflects no cellular characteristics of protein or glycoprotein synthesis—there are no PAS-positive-reacting secretory granules or argyrophilic secretory granules, and only infrequently are there indications of colloid formation

Whether oxyphil cells occur as part of the normal thyroid architecture has not been studied in detail. Hamperl[43-46] believes that these cells are an integral part of the gland epithelium and are indicative of an age-dependent process

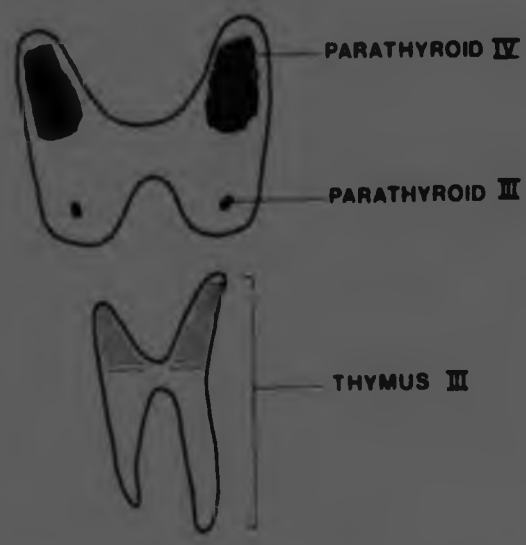

FIG 3 Diagrammatic representation of the topography of human C cells in the thyroid gland and the thymus C cells have not been shown to occur in the human thymus Thymus IV is rudimentary in man



...ecture has not been stud-
...[45] believes that these
...of the gland epithelium
...an age-dependent process

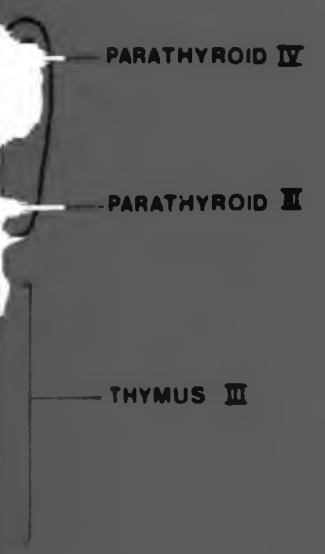

...found
...to occur

...ation of the topography of
...gland and the thymus. C cells
...occur in the human ...
...in man

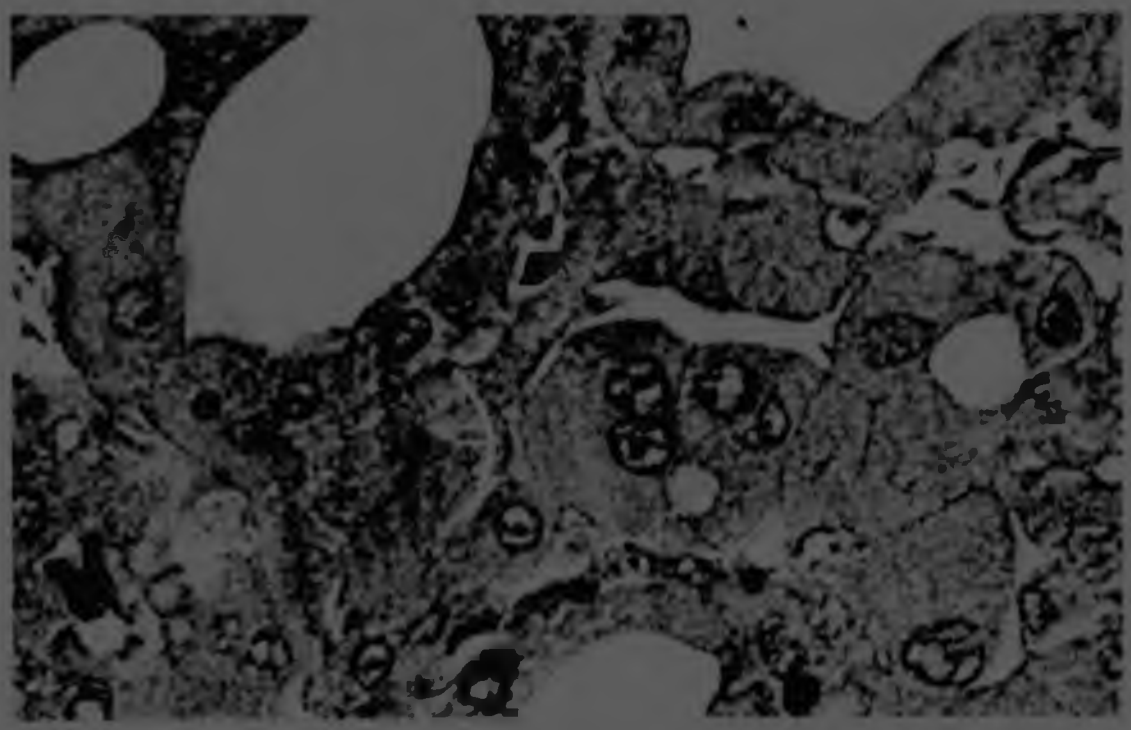

FIG. 4. Oxyphil change within a follicular adenoma. A large binucleate cell is shown (PTAH stain, formalin-saline fixation. × 360)

Lennox[60] examined [illegible] normal human thyroids and found these cells in 1[illegible] cases. They are usually part of a follicle wall, either occurring singly or comprising an entire follicle, but may also be found interspersed between follicles. During an electron-microscopic study of normal human thyroid gland, Heimann[47] was able to find one oxyphil cell. In the neonate, several thyroid epithelial cells are large-bodied and reveal little indication of protein formation.[81] Whether these cells, termed AC cells, are oxyphil cells has not been elucidated.

The topography of oxyphil cells in the human thyroid gland is not known. Increased numbers are observed with age,[43,60] a similar observation has been made of the oxyphil cells in the human parathyroid gland.[illegible]

Histogenesis of Oxyphil Cells

Oxyphil cells are thought to be effete follicular cells[2,45] or to reflect "mitochondrial disease."[illegible] The former hypothesis is supported by the increased number of oxyphil cells that appears with advancing age, and the latter by an increased content of oxidative enzymes in the cytoplasm.[illegible] This high content of oxidative enzymes mirrors increased numbers of mitochondria in oxyphil cells, but hardly permits a conclusion to be drawn as to which cell organnelle is the abnormal one.

The opinion that oxyphil cells are derived from follicular cells has been expressed by Hamperl,[45] Tremblay,[109] and Heimann,[48] on the reasoning that numerous transitional forms between follicular and oxyphil cells are found within the same gland. Beskid,[13] who bases her conclusions on cytochemical findings in oxyphil cells (toluidine blue metachromasia, phospholipid and enzyme content), has suggested that oxyphil cells are derived from C cells. Indeed, several cytochemical features of C and oxyphil cells are similar (Table 2); however, assay of oxyphil tumour extracts shows that oxyphil cells under such conditions conform, both enzymatically and biochemically, to follicular cells.[48] Accumulating evidence therefore suggests that oxyphil cells arise from follicular cells.

Increased numbers of parathyroid oxyphil cells occur in human parathyroid glands stimulated over a lengthy period.[20] The thyroid oxyphil cell is found in 50% of toxic thyroid adenomas, in comparison to 15% of normal thyroids.[60] These observations clearly indicate that chronically hyperactive endocrine glands have a greater preponderance of oxyphil cells

On further consideration of the histopathogenesis of these cells one notes that they are found in organs that produce predominantly polypeptides and glycoproteins (the pancreas, thyroid, parathyroid, parotid, and lacrimal glands) and that wherever these cells do occur, they are characterized by a lack of protein production. Thus, oxyphil adenomas of the thyroid produce no thyroglubulin [48]. Again oxyphil cells (Fig. 5) often occur in follicular adenomas which, on ^{131}I scanning, are hypofunctioning.

Accumulated evidence, therefore, indicates that oxyphil cells are unable to produce protein, but by which sequence of events this is brought about or whether it is reversible is unknown. In experimental animals, thyroxin is a strong inhibitor of protein synthesis in follicular cells;[49] this may play a part in producing oxyphil cells, especially in the hyperfunctioning thyroid.

The Mitochondrion and Oxyphil Cells

The subcellular basis for increased numbers of mitochondria in oxyphil cells is unknown. Whereas Hamperl indicates that these cells and therefore their mitochondria occur as a result of an age-dependnet process, they certainly do not conform to the general features of aging cells. Mitochondria in aging cells generally are vastly decreased in number[88] and show characteristic swelling and morphological atypia. The aging concept of oxyphil cells can no longer be held valid.[25]

An older hypothesis, that mitochondria arise de novo by synthesis from submicroscopic cell components, has gained little factual support.[1] It is more widely held that mitochondria, within cells, replicate from existing mitochondria, probably by a process of fission.[30,85] Such a mode of mitochondrial reduplication occurs in embryonic differentiating cells.[93] Animal experiments have shown that reduplication of mitochondria is in part affected by thyroxin, which influences mitochondrial DNA turnover such that existing mitochondrial populations are replaced with new ones.[41]

The morphology of mitochondria in oxyphil cells varies considerably, from small dumbbell shapes to bizarre giant forms.[47,48] Cristae appear normal, and frequently run across the mitochondrion or are disposed in concentric whorls.[109] Within the mitochondrion, dense fibrillar material may be dispersed in between a granular matrix.[47] The nature of this material is uncertain, but from comparative anatomical analyses it could be mitochondrial DNA necessary for protein synthesis. Mitochondria, apart from their functions of oxidative phosphorylation and calcium-concentrating ability,[21] are capable of



FIG. 5. Small area of oxyphil change (arrows) in a follicular adenoma. The whole adenoma was ^{131}I scanning was hypofunctioning. H & E, formol-saline fixation, ×

and show characteristic
nal atypia The aging
ls can no longer be held

, that mitochondria arise
from submicroscopic cell
nd little factual support.[1]
that mitochondria, within
isting mitochondria, prob-
fission [39,85] Such a mode of
ication occurs in embr-
cells.[93] Animal experiments
ulication of mitochondria
thyroxin, which influences
turnover such that existing
tions are replaced with

mitochondria in oxyphil
ly, from small dumbbell
forms [47,48] Cristae appear
run across the mitochon-
in concentric whorls.[109]
rion, dense fibrillar mate-
in between a granular
of this material is uncer-
rative anatomical analyses
drial DNA necessary for
Mitochondria, apart from
ative phosphorylation and
ability,[19,21] are capable of



whole

on [101]

synthesizing protein [1] Mitochondrial protein synthesis and protein synthesis mediated by cytoplasmic ribosomes are interdependent [9] Similar biochemical mechanisms may be operative in oxyphil cells of the thyroid; that is, those factors which alter cytoplasmic ribosomal protein synthesis, such as thyroglobulin, may likewise affect mitochondrial protein synthesis, which manifests in increased replication of these structures in oxyphil cells.

Comparative Cytochemical Properties of C and Oxyphil Cells

The cytochemical features of oxyphil and C cells are very similar (Table 2) Misrepresentation of C and oxyphil cells, perpetrated by earlier workers, can be attributed to this similarity

Seecof[92] introduced the terms "mitochondria-rich" and "mitochondria-poor" cells in 1924, these terms were again used by Foster et al in 1964 to describe the canine thyroid C cell.[31] Seecof based his observations on pathologic human and animal specimens A re-interpretation of Seecof's findings in the light of present knowledge shows that his animal mitochondria-rich cells are follicular cells, and the mitochondria-poor cells are C cells, whereas, in the pathologic human material, both the mitochondria-rich and mitochondria-poor cells are variants of follicular cells, among which are the oxyphil cells The term "mitochondria-rich" cell applied to C cells[21] is therefore strictly incorrect

The oxidative enzyme content is high in both C and oxyphil cells [51,52,105,106] The oxidative enzymes in oxyphil cells are most likely to be localized to the mitochondria in contrast to the subcellular localization of these enzymes in C cells, which is not clearly established Biochemical work[16] indicates that this enzyme is situated both intra- and extramitochondrially and could be an explanation for the high αGPDH content in C cells in the absence of large numbers of mitochondria

Appropriate staining of oxyphil cells indicates an abundance of phospholipid [4] which no doubt is due to the structural lipids (cardiolipin) contained in mitochondria [28,73] Other lipids, especially polar lipids (phosphatidic acid and phosphatidyl serine) account for the metachromasia in oxyphil cells,[4] in contradistinction to the "masked metachromasia" [65,68,97] which, in C cells, is due to side-chain carboxamido or carboxyl groups of the polypeptide hormone

Recent cytochemical investigation has brought new information on the cellular basis of the phosphotungstic acid hematoxylin (PTAH) stain, which is useful to demonstrate oxyphil cells[86] (Fig 3). Phosphotungstic acid (PTA) preferentially attaches to mitochondria,[94] and the PTA in turn acts as a "lake" for hematoxylin PTA has a strong affinity for basic proteins[91,119] and probably basic lipoproteins, which are structural components of mitochondria. PTAH stainability can therefore be employed as indirect evidence of mitochondria, for staining imparts a fine granular appearance to the cytoplasm (Fig. 3), probably due to these structures. The animal and human C cells do not demonstrate this granular basophilia with the PTAH stain

The Pathology of C Cells

Cysts

Cyst formation and the embryology of C cells are closely linked Advances in the origin of C cells have been reviewed.[32] Briefly, it has been shown in animals that C cells are derived from the UBB and that, in the chick and mouse, the C cell precursors in fact arise from the neural crest and invade the UBB At present the neurectodermal origin[78] of C cell precursors, while demonstrated in chick and mouse, awaits confirmation in man Numerous clinical features in support of such a theory have been marshalled [55,56]

Sugiyama[101,102] found that the human UBB frequently persists in a cystic form in human neonatal thyroid Both normal thyroids and those with medullary carcinomas occasionally contain "follicles" constituted wholly by C cells [8] When intrathyroidal cysts occur,[83] origin from the UBB must be considered Older reports[37,69] hold that cysts of the UBB are lined by squamous epithelium.

Teratomas of the Thyroid

That portion of the thyroid gland that probably arises from ectoderm (C cells), together with the entodermal component, has been used to explain the frequent occurrence of teratomas in the thyroid gland [36] It is postulated that totipotential cells of each germ cell layer found in the thyroid participate in the formation of teratomas

Adenomas and Hyperplasia of C Cells

Several cases of C cell adenomata in the thyroid have been reported [11,12] Features of these cases do not conform histologically to true thy-

roid adenomata as outlined by Meissner and Warren.[70] C cell adenomas were found as nests of cells lying in between follicles, but showed no evidence of encapsulation or compression of adjacent gland. Diagnosis was based on enzyme assay and subsequent bioassay of tissue samples. The authors describing C cell adenomata did not distinguish between C cell hyperplasia or adenomatosis. Chronic hypercalcaemia of primary hyperparathyroidism has been shown to produce C cell hyperplasia.[69,86] C cell hyperplasia is also found in a number of family members that have a familial medullary carcinoma.[117] This hyperplasia is not associated with hyperparathyroidism and is thought to precede the development of medullary carcinoma.

Further case studies are needed before criteria for C cell adenomata and hyperplasia can be considered as established.

C Cell Carcinoma (Medullary Carcinoma)

The histogenesis of medullary carcinoma was correctly adduced by Williams[116] from observations made on thyroid tumors in man and animal. Prior to that, Williams[115] showed that these tumors occur sporadically, or in a familial pat-

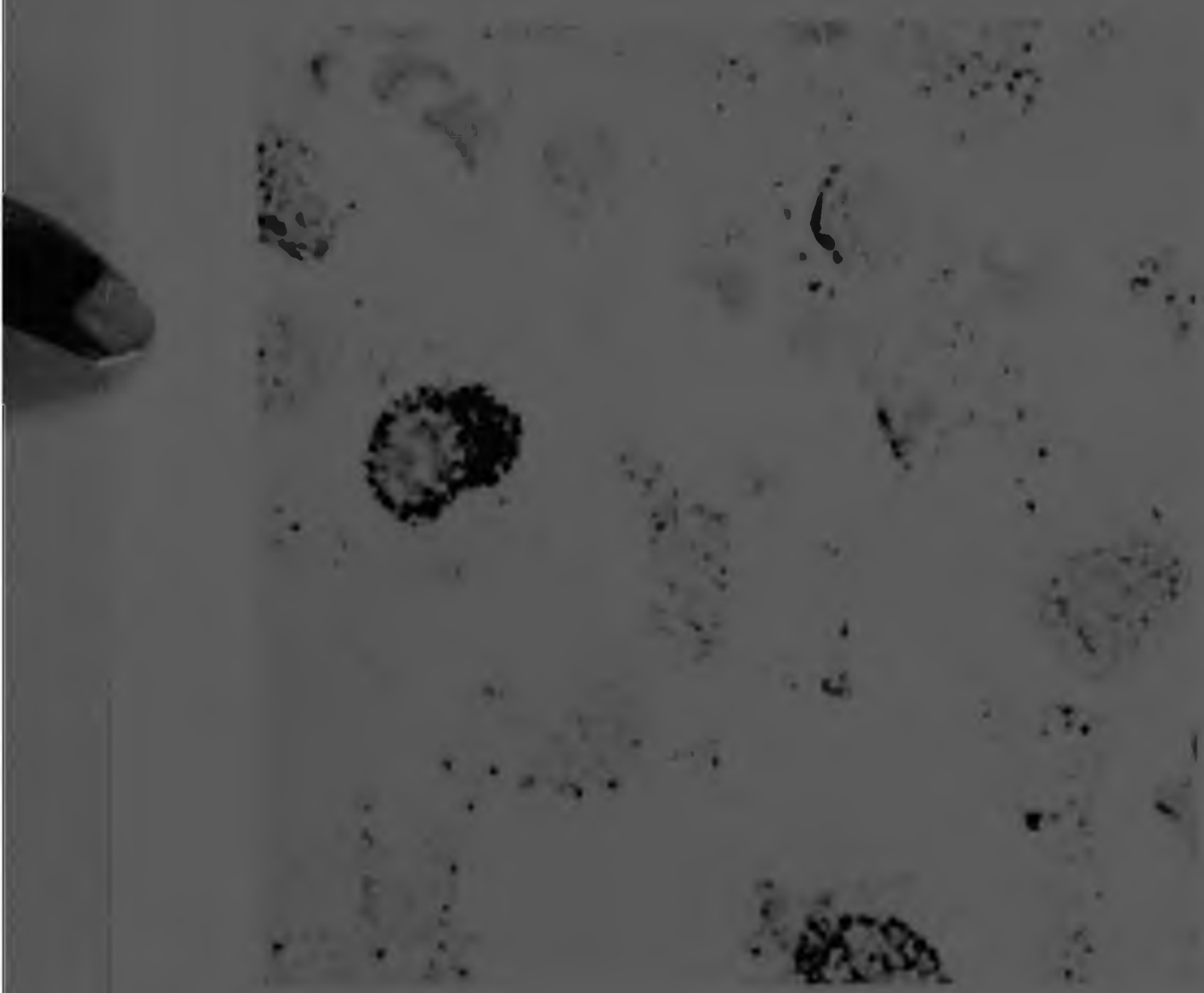

FIG. 6. Medullary carcinoma of the thyroid. Section refixed in GPV and impregnated according to the Grimelius silver technique. Numerous intra- and extracytoplasmic granules are demonstrated. ×400

FIG. 7. Medullary [illegible] amyloid and the cytoplas[illegible]

...is not associated with ...nd is thought to precede ...dullary carcinoma.

...are needed before criteria ...and hyperplasia can be ...ed

...Medullary Carcinoma)

...medullary carcinoma was ...Williams[116] from observa... tumors in man and ani... ...s[11] showed that these ...ally, or in a familial pat-



...ignated according to the ...demonstrated. × 100

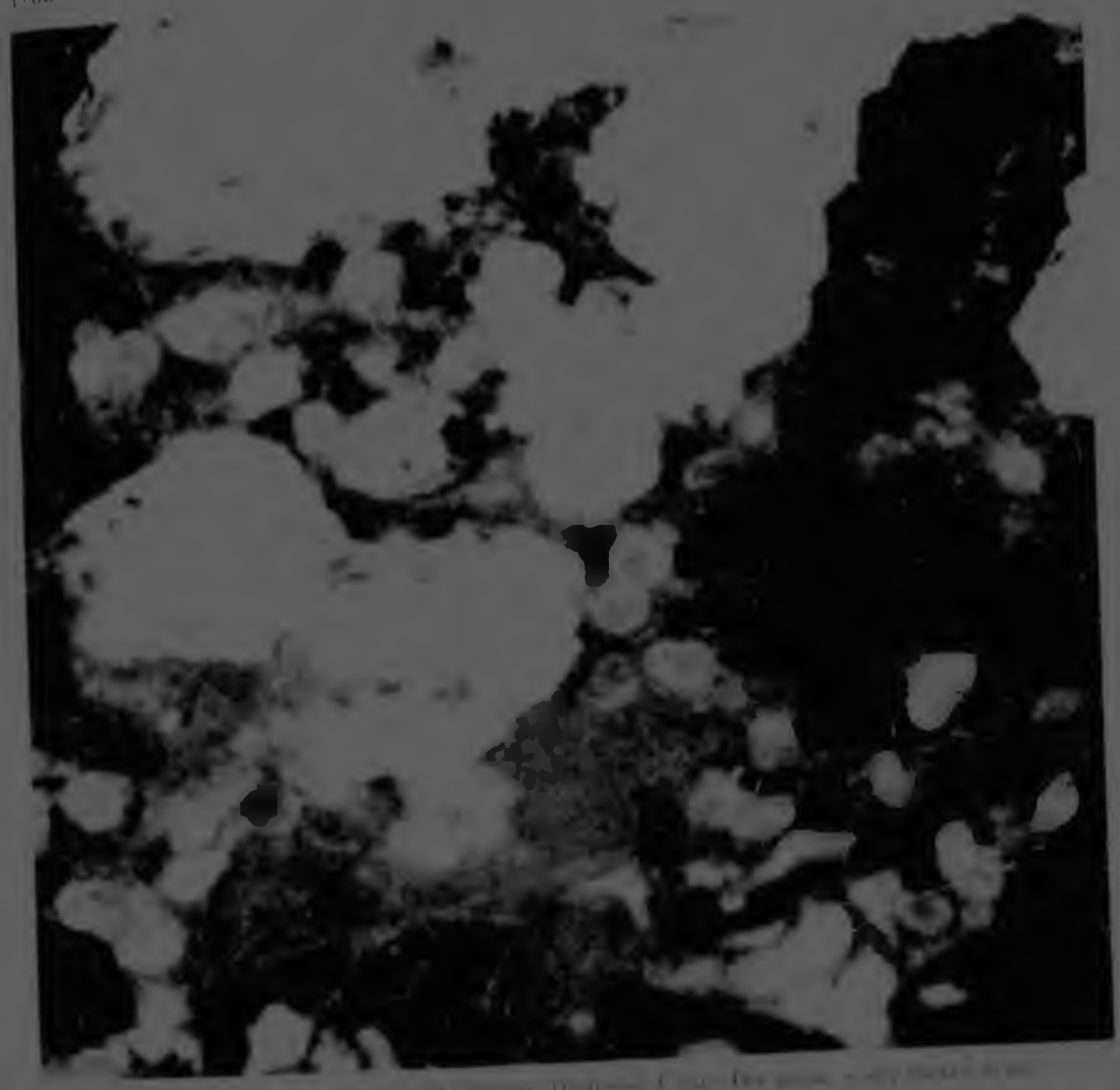

[illegible]

tern, sometimes associated with tumors of other endocrine organs, e.g., pheochromocytoma. A similar association had been described by Sipple[illegible] the syndrome of multiple endocrine tumors associated with medullary carcinoma is now termed Sipple's syndrome[illegible].

A medullary carcinoma that has not spread beyond the thyroid gland is situated posterior superiorly in both lobes of the thyroid gland[illegible]. These tumors, which are of the [illegible] type, are all multicentric, and their distribution within the thyroid gland correlates with the distribution of C cells in the normal thyroid[illegible].

The [illegible] behavior of medullary carcinoma has received considerable [illegible] especially with regard to amyloid and secretory granule formation, as well as cell morphology. Hazard[illegible] originally defined medullary carcinoma as distinguishable by a solid growth pattern, lack of follicular differentiation, and amyloid stroma. Some of these criteria can now be eliminated.

Morphological variants of the cells in medullary carcinoma occur; a round and a spindle cell type are recognized.[38,62,116] The spindle cell type occurs infrequently, usually among round cells of medullary carcinoma, but it is less frequently associated with amyloid formation. This cell type could reflect a more malignant variety of medullary carcinoma or indicate dedifferen-

tiation of cells. C cells with cytoplasmic processes in normal thyroids strike a marked comparison to this tumor cell type.

Secretory granules in cells of medullary carcinoma of the thyroid are a significant criterion for diagnosing medullary carcinoma,[illegible] especially those not associated with amyloid formation. Gordon[38] reported on 3 out of 40 cases of medullary carcinoma that did not produce amyloid. My personal preference is to diagnose medullary carcinoma on the presence of secretory granules, for which purpose I find the Grimelius silver impregnation method, on sections refixed in GPA, as most reliable[24,38] (Fig. 6).

Amyloid deposition in medullary carcinoma is whorled or in an aggregated pattern.[illegible] An intracellular origin of this protein was shown with the electron microscope,[illegible] ne fibrillar structures, which are considered to be amyloid precursors, are found in the cell cytoplasm together with numerous secretory granules. Thioflavine T staining of medullary carcinoma shows fluorescent dye localized to the amyloid and within the C cell cytoplasm (Fig. 7). This "cytoplasmic" amyloid contributes to the main body of amyloid by coalescence, as imprints of cells are often found in the amyloid.[illegible] Pearse, Ewen, and Polak[79] have provided histochemical evidence that the amyloid of medullary carcinoma and carcinomas of other polypeptide-hormone-producing cells can be distinguished histochemically from immune amyloid. They suggest that this amyloid, termed APUD-amyloid, represents a precursor peptide (procalcitonin) of the normal cell secretion, and that APUD-amyloid is of different chemical constitution from immune amyloid.

Despite rapid advances in the knowledge of this tumor, many questions remain unanswered. Do all C cell carcinomas produce amyloid? What is the relationship of secretory granule formation and tumor grading? What is the functional-pathologic correlation of the tumor?

PATHOLOGY OF OXYPHIL CELLS

The oxyphil cell of the thyroid is most frequently found in Hashimoto's thyroiditis, Graves disease, the irradiated thyroid gland,[illegible] and occasionally in follicular adenomas. This ubiquity points to a general stimulus-response effect, though the nature of this "stimulus" is ill defined.

Frequently there is difficulty in deciding whether oxyphil change is benign or malignant in the presence of nuclear atypia and binucleate and occasional mitosing cells, which are observed within a small area. These changes are present in the absence of capsular breakthrough or lymph-vessel invasion. The mitochondria may in some way be related to this nuclear atypia. Recently a hypothesis has been put forward[8] that abnormal mitochondrial DNA may "infect" nuclei and thereby lead towards carcinoma formation. The frequent nuclear polyploidy observed by Garneau[35] indicates that some abnormal DNA-RNA pattern exists in these cells, but whether support for the mitochondrial "infestation theory" can be adduced is doubtful.

In conclusion, the oxyphil cell of the thyroid must be seen as a non-protein-producing derivative of the follicular cell, which is characterized by its capacity for mitochondrial replication and nuclear atypia. These changes may arise as a result of unknown stimuli or absence of stimuli, which probably are mediated through nuclear and mitochondrial RNA-DNA.

ADDENDUM

[illegible] authors.

* [illegible]

Thompson, N. W., [illegible] lesions of the thyroid gland. *Surg. [illegible]* [illegible]

REFERENCES

1 Afzelius B A Morphological aspects of mitochondrial ontogenesis *In* The Generation of Subcellular Structures J Innes Symposium Amsterdam South Holland and American Elsevier 1973 pp 307-340

2 Alvarez [illegible] J Rios G G Rivas M L Rivas M W O Grez C L and Dinochowski E The amyloid in solid carcinoma of the thyroid gland *Lab Invest* 13 [illegible]-93 1964

3 Altman H W Die paratollikulären Zellen der Schilddrüse und ihre Beziehungen zu den gegen Zellen der [illegible] *Beitr Pathol Anat* 104 291-314 1940

4 Arvy L Histoenzymology of the Endocrine Glands Oxford Pergamon Press 1971 pp 18-248

5 Askanazy M Pathologisch-anatomische Beiträge zur Kenntniss des Morbus Basedowii insbesondere über die dabei auftretende Muskelerkrankung [illegible] *Arch Klin Med* 61 118-186 1898

6 Baber E C Contributions to the minute anatomy of the thyroid gland of the dog *Proc R Soc Lond Biol* 24 240-241 1876

7 Ballid R N Cytological changes in the rat thyroid following exposure to heat and cold and their relationship to the physiology of secretion *Am J Anat* 61 1-20 1937

8 Baum H Possible role of mitochondria in oncogenesis *Lancet* ii 98-99 1973

9 Beattie D S Biosynthesis of mitochondrial proteins *Subcell Biochem* 1 1-23 1971

10 Bensley R R The thyroid gland of the opossum *Anat Rec* 8 431-440 1914

11 Beskid M Lerenc R and Roszkowski A Atypical C-cell adenoma in man *J Pathol* 103 1-4 1971

12 Beskid M Lerenc R and Roszkowski A Les adénomes thyroïdiens à cellules C *Virchows Arch Pathol Anat* 9 2113-2116 1971

13 Beskid M [illegible] Kaszewski Lipska H Adenoma oncocytarium glandulae thyreoideae *Folia Histochem Cytochem Acad* 10 31-36 1972

14 Blundell T Dodson G Hodgkin D and Mercola D Insulin The structure in the crystal and its reflection in chemistry and biology *Adv Protein Chem* 26 279-402 1972

15 Borst P Mitochondrial nucleic acids *Annu Rev Biochem* 41 333-376 1972

16 Boyer C J and Deahn T M Pathways for intracellular oestrogen transport *Nature* 231 119-121 1971

17 Brandtzaeg H and Stolte L A Parafollicular cells of human thyroid *J Pathol* 86 659-666 1963

18 Buffa R Solcia G and Pearse A G E Immunofluorescent localization of calcitonin in the C cells of the pig and dog thyroid *J Histochem* 3 205-209 1971

19 Cameron D A Parsons H A and Robinson R A Cytochemical studies on cells after the administration of parathyroid extract *J Cell Biol* 34 1-10 1967

20 Capen C C and Roth S I Ultrastructural and functional relationships of normal and pathologic parathyroid cells *Lab Invest* 8 1291-1313 1959

21 Carafoli E Spagnuolo C Cassani G and De Tomasi L Localization of mitochondrial calcification in the rabbit aorta after adrenaline *Virchows Arch Pathol Anat* 362 1-8 1974

22 Clark A S and Cohen P L Ultrastructural observations on cytodifferentiation of parafollicular cells in the human fetal thyroid *Cell Tissue Res* 149 [illegible]

23 Degandie M L Cholinesterase-containing cells and thyroïde dyscrinies *C R Soc Biol Fil* 144 [illegible]

24 De Groodt P The routine demonstration of C cells in human and animal thyroid *Lab Invest* 13 136-139

25 Dunach L Diseases of endocrine organs The thyroid *In* Recent Advances in Pathology 4th Ed C V Harrison Ed London J & A Churchill 1960; pp 284-285

26 Ewing J Neoplastic Diseases A Textbook on Tumors 1st ed Philadelphia W B Saunders, 1919 p 859

27 Lascelles A K and Wallerstrom H Hürthle cell tumour *Arch Pathol* 13 161-174 1932

28 Ernster L and Kuylenstierna B Structure composition and function for mitochondrial membranes *FEBS Lett* 1 [illegible]31, 1969

29 Fawcett D W Observations on the cytology and electron microscopy of hepatic cells *J Natl Cancer Inst* 13 1449-1502, 1953

30 Feyrter L Über die Thesie von den peripheren endokrinen Drüsen *Wien Z Inn Med* 27 93-[illegible] 1946

31 Foster G V MacIntyre I and Pearse A G E Calcitonin production and the mitochondrion-rich cell of the dog thyroid *Nature* 203 1029-1030, 1964

32 Foster G V Byfield P G H and Gudmundsson I V Calcitonin *Clin Endocrinol Metab* 1 93-124, 1972

33 Gatti M Données histochimiques sur les cellules paratolliculaires de la glande thyroïde du chien *Acta Anat* 38 332-344, 1959

34 Gotanto I Gudmundsson I V Matthews I W Lee V Williams I D Woodhouse N J Y and MacIntyre I Thymic and parathyroid origin of calcitonin in man *Lancet* ii 539, 1968

35 Garneau R Analyses quantitatives cytospectrophotométriques de l'ADN in situ dans la thyroïde humaine *Ann Anat Pathol* 9 [illegible]-211 1964

36 Godwin M C Complex IV in the dog with special emphasis on the relation of the ultimobranchial body to interfollicular cells in the post-natal thyroid gland *Am J Anat* 60 299-339, 1937

37 Goldberg H M and Harvey R Squamous cell cyst of the thyroid *Br J Surg* 43 565-569, 1956

38 Gordon P R Hayes V C and Strong J W Medullary carcinoma of the thyroid gland A clinicopathologic study of 40 cases *Cancer* 31 915-924 1973

Gould V L and Bendit I P Ultrastructural and functional relationships of some human endocrine tumors *Hum Pathol* 8 205-230 1973

39 Gracide M H Bencosme S A and Izchago J The human pancreatic islet cells and their tumors I The normal pancreatic islets *Am Invest* 22 344-354, 1970

40 Gross N J Control of mitochondrial turnover under the influence of thyroid hormone *J Cell Biol* 48 29-40, 1971

41 Hamperl H Beiträge zur normalen und pathologischen Histologie menschlicher Speicheldrüsen *Virchows Arch Pathol Anat* 282 [illegible]-88, 1931

42 Hamperl H Über das Vorkommen von Onkocyten in verschiedenen Organen und Basen Geschwülsten *Virchows Arch Pathol Anat* 298 327-[illegible] 1937

43 Hamperl H Onkocyte and the so-called Hürthle cell [illegible] *Arch Pathol* 19 563-567 1970

44 Hamperl H Benign and malignant oncocytoma [illegible] 1019-1027 1963

45 Hazard J B Hawk W A and Crile G Medullary solid carcinoma of the thyroid Clinicopathologic entity *J Clin Endocrinol* 19 152-161 1959

46 Heinemann P Ultrastructure of human thyroid A study of normal thyroid untreated and treated diffuse toxic goiter [illegible] *Suppl* [illegible] 110-120

47 Heinemann P Lumgair J G Edwards [illegible] and Hertz B Oxyphilic adenoma of the human thyroid *Cancer* 31 246-[illegible] 1973

49 Heywood S M The regulation of amino acid incorporation into thyroid protein Evidence that thyroxin and iodide inhibit synthesis at a ribosomal site *Biochim Biophys Acta* 123 188–196, 1966

50 Hürthle, K Beiträge zur Kenntniss der Secretionsvorgangs in der Schilddrüse *Arch Gesamte Physiol* 56 1–44, 1894

51 Kalina M Foster G V Clark M B and Pearse A G E C cells in man *In* Calcitonin 1969 Proceedings of the Second International Symposium, S Taylor Ed London, Heinemann, 1970 pp 268–273

52 Kalina, M and Pearse A G E Ultrastructural localisation of calcitonin in C-cells of dog thyroid, an immunocytochemical study *Histochemie* 26 1–8, 1971

53 Kameda Y The occurrence of a special parafollicular cell complex in and beside the dog thyroid gland *Arch Histol Jap* 33 115–132 1971

54 Kameda Y The occurrence and distribution of the parafollicular cells in the thyroid parathyroid IV and thymus IV in some mammals *Arch Histol Jap* 33 283– 1971

55 Kaplan, E L and Peskin G W Physiologic implications of medullary carcinoma of the thyroid gland *Surg Clin North Am* 51 125–137 1971

56 Keiser, H R Beaven M A Doppman J Wells, S and Buja L M Sipple's syndrome—Medullary thyroid carcinoma, pheochromocytoma and parathyroid disease *Ann Intern Med* 79 561–579, 1973

57 Kendall J S and Thomson J A The changes in the thyroid gland after irradiation with ^{131}I or partial thyroidectomy for thyrotoxicosis *J Pathol* 112 65–82 1974

58 Klinck, G H Oertel J E and Winship T Ultrastructure of normal human thyroid *Lab Invest* 2 1970

59 Kracht J Hachmeister, U and Christ E C cells in the human thyroid *In* Calcitonin 1969 Proceedings of the Second International Symposium, S Taylor Ed London Heinemann 1970, pp 271–280

60 Lennox B The large-cell small acinar thyroid tumour of Langhans and the incidence of related cell groups in the human thyroid *J Pathol Bacteriol* 60 295–305, 1948

61 Like A A and Orci L Embryogenesis of the human pancreatic islets A light and electron microscopic study *Diabetes* 21 511–534, 1972

62 Ljungberg, O On medullary carcinoma of the thyroid *Acta Pathol Microbiol Scand Suppl* 231 1– 1972

63 Ljungberg O Argentaffin cells in human thyroid and parathyroid and their relationship to C cells and medullary carcinoma *Acta Pathol Microbiol Scand* A 80 589–599, 1972

64 Ljungberg, O and Dkrning J E Pathogenesis of C-cell neoplasia in thyroid gland C-cell proliferation in a case of chronic hypercalcaemia *Acta Pathol Microbiol Scand* [A] 80 577–588 1972

65 Manocchio I Metachromatische Färbung der A zellen in pankreasinseln von Canis familiaris *Zentralbl Allg Pathol* 101 1–4, 1960

66 Marcker K and Graae, J The dimerization of insulin *Acta Chem Scand* 15 565–569 1961

67 Matsuzawa T and Kurosumi K Morphological changes in the parafollicular cells of the rat thyroid glands after administration of calcium shown by electron microscopy *Nature* 213 927–928, 1967

68 Maunder C and Rost F W D A microfluorometric study of masked metachromasia in cells of the endocrine polypeptide (APUD) series *Histochem J* 4 145–153, 1972

69 Meeker I. H Riedel's struma associated with remnants of the post-branchia, body *Am J Pathol* 1 –68, 1925.

70 Meissner, W A and Warren, S Tumors of the thyroid gland Atlas of Tumor Pathology, 2nd ser fasc 4 Washington, DC Armed Forces Institute of Pathology, 1969, pp 1–135

71 Melvin, K E W Tashjian A H and Miller H H Studies in familial medullary thyroid carcinoma *Recent Prog Horm Res* 28 399–470, 1972

72 Meyer J S Hutton, J W and Kenny A D Medullary carcinoma of thyroid gland Subcellular distribution of calcitonin and relationship between granules and amyloid *Cancer* 31 433–441, 1973

73 Munn E A Some aspects of the structure of mitochondria in relationship to their biogenesis *In* The Generation of Subcellular Structures J Innes Symposium Amsterdam North Holland and American Elsevier, 1972, pp 351–360

74 Nonidez J F The origin of the parfollicular cell, a second epithelial component of the thyroid gland of the dog *Am J Anat* 49 479–501 1932

75 Pearse A G E The cytochemistry of the thyroid C cells and their relationship to calcitonin *Proc R Soc Lond [Biol]* 164 478–487, 1966

76 Pearse A G E Histochemistry, vol 1 London Churchill, 1968, pp 435–436

77 Pearse A G E Random coil conformation of polypeptide hormone precursor protein in endocrine cells *Nature* 221 1210–1211, 1969

78 Pearse A G E, and Polak J M The neural crest origin of the endocrine polypeptide cells of the APUD series *In* Endocrinology 1971, Proceedings of the Third International Symposium S Taylor, Ed London, Heinemann, 1972, pp 145–152

79 Pearse A G E Iwen S W B and Polak, J M The genesis of APUD-amyloid in endocrine polypeptide tumours—Histochemical distinction from immune amyloid *Virchows Arch [Zellpathol]* 10 93–107 1972

80 Rinker B Neher R Maier, R Kahnt, F W Byfield P G H Gudmundsson I A Galante, I and MacIntyre I Menschliches calcitonin I Isolierung und Charakterisierung *Helv Chim Acta* 51 1438–1442, 1968

81 Roediger, W E W A comparative study of the normal human neonatal and the canine thyroid C cell *J Anat* 115 255–276, 1973

82 Roediger, W E W The nature of silver binding in the canine thyroid C cell *S Afr J Med Sci* 38 1–22, 1973

83 Roediger W E W and Spitz L Congenital Cyst of the thyroid *S Afr Med J* 47 1120–1122, 1973

84 Roediger W E W Spitz L. and Schmaman A Histogenesis of benign cervical teratomas *Teratology* 10 111–118, 1974

85 Roodyn D B and Wilkie, D The Biogenesis of Mitochondria London Methuen, 1968

86 Roth S I Olen L and Hansen, L S The eosinophilic cells of the parathyroid (oxyphil cells), salivary oncocytes and thyroid (Hürthle cells) glands *Lab Invest* 11 933–941, 1962

87 Rothstein A Sulfhydryl groups in membrane structure and function *In* Current Topics in Membrane Transport vol 1 F Bronner and A Kleinzeller Eds New York, Academic Press, 1970, pp 136–

88 Roulhac C Physiological and pathological changes in mitochondrial morphology *Int Rev Cytol* 9 225–329, 1960

89 Sandritter W and Klein K H Über argyrophile Zellen in der Schilddrüse *Frankfurt Z Pathol* 65 204–218, 1954

90 Sandritter W Kummer I Pillat G and Rowe

...ysial-branchial body *Am J Pathol* 1 57 68,
...r, W A., and Warren, S Tumors of the ... Atlas of Tumor Pathology, 2nd ser , fasc 4 ... DC Armed Forces Institute of Pathology, ...35
... K I W , Tashjian, A H , and Miller, H H ...idal (medullary) thyroid carcinoma *Recent* ... 28 399 470 1972
... J S , Hutton, J W , and Kenny, A D Med... of thyroid gland—Subcellular distribution ...and relationship between granules and am... 433 441, 1973
... A Some aspects of the structure of mito...tionship to their biogenesis *In* The Gener...llular Structures J Innes Symposium Am... Holland and American Elsevier, 1972, pp
... J L The origin of the 'parfollicular' cell, a ...l component of the thyroid gland of the dog ...479 505, 1932
... A G E The cytochemistry of the thyroid C ...elationship to calcitonin. *Proc R Soc Lond* ...467 1966
... A G E Histochemistry, vol 1 London, ... pp 435 436
... G E Random coil conformation of poly... precursor protein in endocrine cells *Nature* ... 1969
... A G E , and Polak, J M The neural crest ...ocrine polypeptide cells of the APUD series ...ey 19 1 Proceedings of the Third Inter...ium S Taylor, Ed London, Heinemann, ...152
... G E , Ewen S W B , and Polak, J M ...PUD-amyloid in endocrine polypeptide tu...ential distinction from immune amyloid ...pathol] 10 93 107, 1972
... H Neher, R Maier, R Kahnt, I W ... H Gudmundsson, I V , Galante L , and Menschliches calcitonin I Isolierung und ... *Hel Chim Acta* 51 1738 1742 1968
... W E W A comparative study of the nor...al and the canine thyroid C cell *J Anat* ...973
... W E W The nature of silver binding in ...d C cell *Ann J Med Sci* 38 17 22, 1973
... W E W , and Spitz, L Congenital Cyst of ...d *Med J* 47 1120 1122, 1973
... W E W Spitz, L , and Schmaman A ...benign cervical teratomas *Teratology* 10
... D B and Wilkie, D The Biogenesis of ...London Methuen, 1968
... Olen, L and Hansen, L S The eosino... parathyroid (oxyphil cells), salivary (on...ocoid (Hürthle cells) glands *Lab Invest*
... A Sulfhydryl groups in membrane struc... *In* Current Topics in Membrane Trans...ner and A Kleinzeller, Eds New York, ... 1970; pp 136–176
... C Physiological and pathological changes ...d morphology *Int Rev Cytol* 9 227 292
... W and Klein K H Über argyrophile ...hilddrüse *Frankfurt Z Pathol* 65 204 218,
... W Kummer, L Pillat, G and Rowe,

... Zur Histochemie und Funktion der paralollikulären Zel...len in der Schilddrüse *Klin Wochenschr* 34 871 8... 19...
91 Scott J E Phosphotungstic acid—Schiff reactive but not a glycol reagent *J Histochem Cytochem* 21 1083 1088, 1973
92 Secord D P Studies on mitochondria II The oc...currence of mitochondria-rich and mitochondria-poor cells in the thyroid gland of man and animals *Am J Pathol* 3 365 384 1924
93 Sherbet G V and Lakshmi M S Structural organ...ization and embryonic differentiation *Int Rev Cytol* 22 147 170, 196...
94 Silverman L and Glick D The reactivity and stain...ing of tissue proteins with phosphotungstic acid *J Cell Biol* 40 761 76... 1969
95 Sipple J H The association of pheochromocytoma with carcinoma of the thyroid gland *Am J Med* 31 163 166, 1961
96 Solcia E and Sampietro R New methods for stain...ing secretory granules and 5-hydroxytryptamine in the thyroid C cell *In* Calcitonin Proceedings of the Symposium on Thyrocalcitonin and the C Cells S Taylor Ed London Heinemann, 1968, pp 220 22...
97 Solcia E Vassallo G and Capella C Selective stai...ning of endocrine cells by basic dyes after acid hydrol...ysis *Stain Technol* 43 2... 263 1968
98 Solcia E Capella C Sampietro R and Vassallo G The distribution of human C cells and their relationship to osteopetrosis and medullary carcinoma of the thyroid *In* Calcitonin 1969 Proceedings of the Second International Symposium S Taylor Ed London Heinemann 1970, pp 220 226
99 Stutz M Thompson R Ister H and Leblond C P The light cells of the thyroid gland in the rat *Endocrinology* 68 292 308 1961
100 Sunder-Plassmann P Über neuro-hormonale Zellen des Vagussystems in der Schilddrüse *Dtsch Z Chir* 252 210 223 1939
101 Sugiyama S Kitoh J and Yokota S On the proolem of the development of the paratollicular cells from the human ultimobranchial body in prenatal life *Okajimas Folia Anat Jap* 46 59 63 1969
102 Sugiyama S The embryology of the human thyroid gland including ultimobranchial body and others related In Advances in Anatomy Embryology and Cell Biology vol 44 New York Springer 197... pp 1 113
103 Swift J A The electron cytochemical demonstration of cystine disulphide bonds using silver-methenamine reagent *Histochem* 35 30 310 ...9...
104 Takagi K A cytological study on the dog's thyroid gland *Folia Anat Jap* 1 69 100 1922
105 Tateishi R Takahashi, Y , and Noguchi, A Histo...logic and cytochemical studies on thyroid medullary carcinoma Diagnostic significance of argyrophil staining *Cancer* 36 ... 63 197...
106 Teitelbaum, S L Moore, K E and Shieber, W Parafollicular cells in the normal human thyroid *Nature* New Biol 231 1971
107 Tremblay G , and Pearse, A G E Histochemistry of oxidative enzyme systems in the human thyroid with special reference to Askanazy cells *J Pathol Bacteriol* 80 353 358, 1960
108 Tremblay G Histochemical study of cytochrome oxidase and adenosine tri-phosphatase in Askanazy cells (Hürthle cells) of the human thyroid *Lab Invest* 11 514 517, 1962
109 Tremblay G The oncocytes *In* Methods and Achievements in Experimental Pathology, vol 4, E Bajusz and G Jasmin, Eds New York, Karger 1969, pp 121 140
110 Vassallo G Capella, C and Solcia E Grimelius ... stain for endocrine cell granules as shown by electron microscopy *Stain Technol* 46 7 15, 1971
111 Velican C and Velican D Silver impregnation techniques for the histochemical analysis of basement membranes and reticular fiber networks *In* Techniques of Biochemical and Biophysical Morphology vol 1, D Glick and R M Rosenbaum Eds New York Wiley-Interscience, 197... pp 143 190
112 Welsch, U and Buchheim, W The fine structure of endocrine polypeptide storage granules *In* Endocrinology 1... Proceedings of the Third International Symposium, S Taylor Ed London Heinemann, 1972, pp 291 298
113 Welsh J D V Concerning the parathyroid glands—A critical anatomical and experimental tudy *J Anat Physiol* 32 292 307, 380 401, 1898
114 White T C Thyroid tumors Surgical manage...ment *In* Endocrine and Non-endocrine Hormone producing ... Chicago, Year Book Medical, 1973, pp 353 362
115 Williams E D A review of 17 cases of carcinoma of the thyroid and pheochromocytoma *J Clin Pathol* 18 288 292 1965
116 Williams, E D Histogenesis of medullary carcinoma of the thyroid *J Clin Pathol* 19 114 118, 1966
117 Wolfe H J , Melvin, K E W Cervi Skinner, S J , Al Saadi, A A Juhar J E Jackson, C E and Tashjian, A H C cell hyperplasia preceeding medullary thyroid carcinoma *N Engl J Med* 289 13... 441 1973
118 Zechel, C Observations on the follicular cycle and on the presence of the macrothyrocyte in the human thyroid *Anat Rec* 56 119 130, 1933
119 Zobel, C R and Beer, M The use of heavy metal salts as electron stains *Int Rev Cytol* 18 363 400, 1965.

Roediger, W. E. W., L. Spitz and A. Schmaman

1974. Histogenesis of Benign Cervical Teratomas

Teratology, v. 10, no 2, October

Pages 111 118.

PRESS OF
THE WISTAR INSTITUTE
OF ANATOMY AND BIOLOGY
PHILADELPHIA, PA., U S A

Reprinted from TERATOLOGY
Vol 10 [illegible] October 1974 The Wistar Institute Press 1974

Histogenesis of Benign Cervical Teratomas

W. T. ROLDIGER[1], E. SPITZ, AND A. SCHMAMAN
Department of Paediatric Surgery and School of Pathology, University of the Witwatersrand, and the South African Institute for Medical Research

ABSTRACT Two cases of cervical teratoma and two of complex cyst of the thyroid are presented with special reference to (i) association with the thyroid gland, (ii) age of presentation, and (iii) differences between hamartomas and teratomas. The authors propose, from clinical and embryological evidence, that anterior neck teratomas arise from the thyroid gland and that failure of organogenesis at an early prenatal stage is involved. These teratomas probably arise from totipotential cells of each of the three germ cell layers found in the thyroid gland.

Swellings of the neck occur infrequently in infants. Judging by the number of new reports of cervical teratomas (table 1) it seems that this tumor comprises a significant proportions of cervical swellings in the neonate. Despite extensive reviews of cervical teratomas (Silberman and Mendelson, '60, Hajdu et al. '66, Rickham, '72) several features have not been sufficiently emphasized: age of onset, differences between hamartomas and teratomas, relation of cervical teratomas to the thyroid, and the histogenesis of teratoma.

To study the above factors further two cases each of cervical teratoma and "complex cyst of the thyroid" were investigated. The characteristics of these tumors are considered together with the clinical features of those reported in the literature. From the collected evidence a theory of the histogenesis of cervical teratoma is proposed.

CASE REPORTS

The clinical and pathological details of four patients with neck swellings are given below. Cases of neck teratomas reported since 1966 are set out in table 1 with particular reference to age of presentation, thyroid involvement and results of treatment.

Case 1

A healthy 4-day old girl was seen with a mass in the left lateral region of the neck. The mother had noticed the mass at birth. Examination of the child revealed a firm tumor, 2 cm in diameter, situated in the left submandibular triangle of the neck. We deemed it advisable to remove the tumor as further enlargement could produce respiratory obstruction. At operation the mass which was found to have replaced the entire left lobe of the thyroid (fig. 1) was completely excised. The immediate postoperative course was complicated by transient laryngeal stridor.

The tumor measured 4 × 2 × 2 cm and contained a primitive eye structure, loops of intestine, and solid areas (fig. 2). Microscopic examination showed areas of thyroid tissue, intestine, squamous epithelial islands, and cystic spaces with a lining of respiratory epithelium. Islands of heavily pigmented cells were present. The well-developed multiorganoid formation in this tumor was typical of a benign cervical teratoma.

Case 2

A 2 month old boy was admitted to hospital with stridor due to an upper respiratory tract infection. A 2.5-cm tumor was found on the right side of the neck in the region of the thyroid gland. Bronchoscopy excluded the presence of an inhaled foreign body. Urgent removal of the neck mass was considered necessary as it could potentiate the respiratory obstruction. At operation it was found that the mass, which contained cystic and solid areas, involved the right lobe of the thyroid gland.

Received Feb. 23, '74. Accepted July 1, '74.
[1] Present address: Department of Surgery, University of the Witwatersrand, Johannesburg, South Africa.

TABLE 1

Cases of neck teratomas reported since 1966

	Cases	Age of presentation and sex	Relation to thyroid	Treatment and result
Hajdu et al. (66)	102			
Retief (66)	3	7 months, male	abutting onto thyroid	successful removal
		at birth, male	lateral to thyroid	successful removal
		2 months, not stated	continuous with R. lobe	died before operation
Hurlbut et al. (67)	2	12 months, female	not stated	successful removal
		at birth, male	anterior to thyroid	successful removal
Chappel (70)	3	all neonatal presentation	all related to the thyroid	one postoperative death due to hemorrhage
Numanoglu et al. (70)	1	3.5 months, male	replaced part of thyroid gland	successful removal
Rickham (72)	4	all neonatal presentation	near thyroid, no specific details	3 successfully removed, 1 postoperative death
Gray (73)	2	at birth, female	replaced most of thyroid	died from hemorrhage
		6 months, not stated	arose from R. thyroid lobe	successful removal
Present cases	2	at birth, female	replaced L. thyroid	successful removal, r. laryngeal nerve damage
		2 months, male	attached to R. thyroid lobe	successful removal



Fig. 1. Operative findings of Case 1. The normal right lobe of the thyroid (forceps) is exposed and the left lobe is replaced by teratomatous growth.



Fig. 2. Teratoma of the left lobe of the and loops of primitive bowel are present.

The left lobe of the thyroid was normal. The mass including the right lobe of the thyroid was removed.

Pathological examination showed a 3 × 2 × 1-cm tumor from which a cyst 1.5 cm in diameter protruded. Microscopic examination showed neural tissue in large amounts, interspersed with cartilage, mucous glands, squamous epithelium, and thyroid follicles. The diagnosis was that of a teratoma of the thyroid gland.

Case 3

A 29 month-old boy was admitted to hospital for treatment of kwashiorkor. On routine physical examination a 1-cm firm nodule was found situated in the midline just above the suprasternal notch. Thyroid function tests were normal. A [illegible] scintiscan showed the presence of a normal thyroid gland with the mass on the

1

[illegible] since 1966

Relation to thyroid	Treatment and result
[illegible]tting onto thyroid	successful removal
[illegible]al to thyroid	successful removal
[illegible]tinuous with L. lobe	died before operation
[illegible] stated	successful removal
[illegible]erior to thyroid	successful removal
[illegible] related to the thyroid	one postoperative death due to hemorrhage
[illegible]d part of [illegible]yroid gland	successful removal
[illegible] thyroid, no [illegible]ific details	3 successfully removed, 1 postoperative death
[illegible] most of thyroid	died from hemorrhage
[illegible] from R. thyroid [illegible]	successful removal
[illegible]ed L. thyroid	successful removal, r. laryngeal nerve damage
[illegible]ned to R. thyroid [illegible]	successful removal



[illegible] lobe of the thyroid (forceps) [illegible]



Fig. 2. Teratoma of the left lobe of the thyroid (Case 1). A rudimentary lens structure and loops of primitive bowel are present.

The left lobe of the thyroid was normal. The mass including the right lobe of the thyroid was removed.

Pathological examination showed a 3 × 2 × 1 cm tumor from which a cyst 1.5 cm in diameter protruded. Microscopic examination showed neural tissue in large amounts, interspersed with cartilage, mucous glands, squamous epithelium, and thyroid follicles. The diagnosis was that of a teratoma of the thyroid gland.

Case 3

A 29 month-old boy was admitted to hospital for treatment of kwashiorkor. On routine physical examination a 1 cm firm nodule was found situated in the midline just above the suprasternal notch. Thyroid function tests were normal. A [illegible] scintiscan showed the presence of a normal thyroid gland with the mass on the anteroinferior aspect of the gland. At operation the mass, with a "gritty" capsule that was confluent with the thyroid fascia, was removed. No tract leading to the hyoid bone was present.

Pathological examination revealed a cystic mass, 1.3 cm in diameter, filled with straw-colored fluid. The cyst was lined by transitional and respiratory type epithelium and contained cartilage in its wall (Fig. 3). The diagnosis was that of a "complete [illegible] of the thyroid gland."

Case 4

[illegible] month-old boy was admitted to hospital with a 6 month history of a mass in the thyroid region. Physical examination revealed a 1.5 cm mass which moved with swallowing and protrusion of the tongue. At exploration the mass was adherent to the right upper pole of the thy

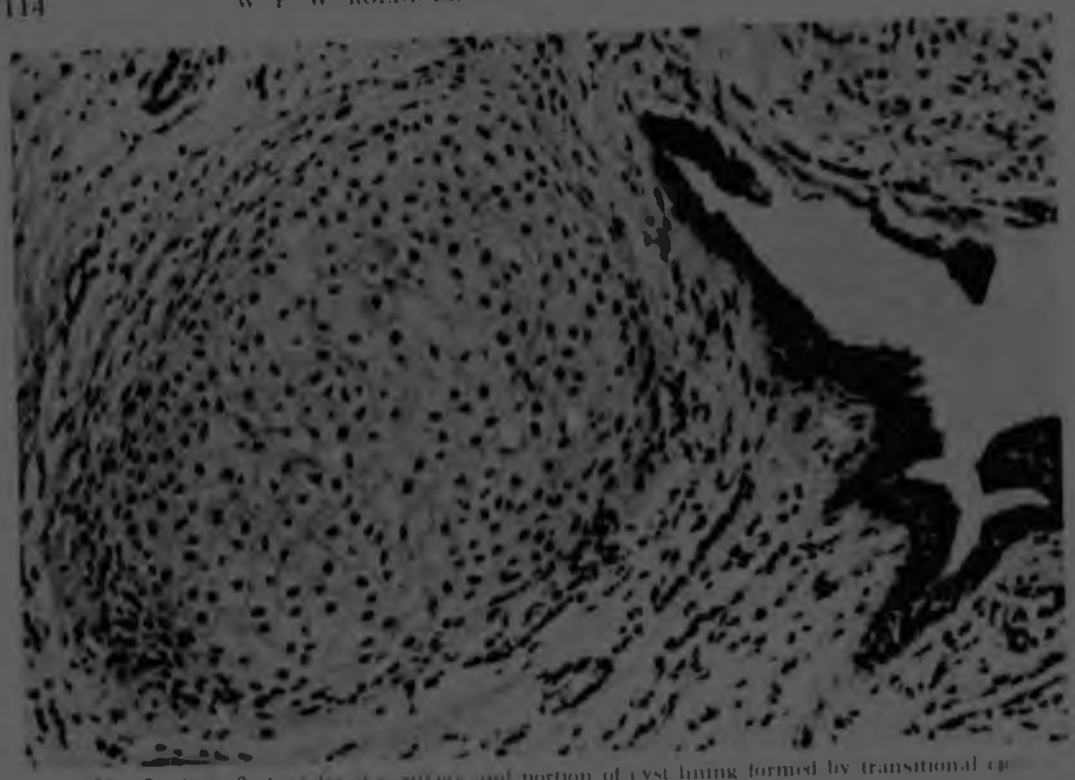

Fig. 3. Case 3. An islet of cartilage and portion of cyst lining formed by transitional epithelium. × 150



Fig. 4. Portion of the cyst wall abutting onto normal thyroid tissue. The wall consists of compressed fibrous tissue which leads into areas of cartilage formation. × 38



of cyst lining formed by transitional ep



thyroid tissue. The wall contains
artilage formation. × 38

roid and contained cartilaginous material in its lateral wall. A tract leading to the hyoid bone was present. The mass including the tract and the portion of the right lobe of the thyroid gland to which it was adherent was excised.

Pathologically the mass was cystic, 1.5 cm in diameter, and consisted of several locules some of which were lined by pseudostratified epithelium and others by squamous or columnar epithelium. Numerous foci of cartilage and areas of compact fibrous tissue, interspersed with thyroid follicles were present in the cyst wall (fig. 4). The diagnosis was that of a complex cyst of the thyroid gland.

DISCUSSION

The term "cervical teratoma" incorporates teratogenous tumors of the anterior and posterior triangles of the neck but excludes facial and basicranial teratomas and those associated with cervical vertebral defects. The first two cases presented above clearly fall into the group of cervical teratomas whereas the last two cases could not be regarded as teratomas. The two complex cysts may be hamartomas of the thyroid, an entity that has received scant description in the literature. Willis (62, p. 107) described two cases of hamartomas of the thyroid with cartilage formation. Both tumors included thyroid tissue within the stroma and histologically resemble the present two cases. Willis favored the diagnosis of chondromatous hamartoma of the thyroid in one of two cases reported as teratomas of the neck by Silberman and Mendelson (60). This tumor was not readily accepted as a true teratoma by all the pathologists reviewing the case at the time. In comparing hamartomas with true teratomas it is important to establish the extent of organ development in each tumor. A multiorganoid differentiation is in keeping with a teratoma whereas hamartomas are overgrowths of tissues found in a particular organ. Hamartomas, unlike teratomas, may in addition retrace the history of the development of that particular organ (Gaillard, 74).

The presence of cartilage in the thyroid gland, as distinct from dystrophic calcification in degenerate tissue, is known in chondrosarcomata (Willis, 67, p. 626; Hedinger, 69), teratomas, and very occasionally in multinodular goiters (Finkle and Goldman, '73). As cartilage is not normally present in the thyroid gland we prefer to use the term "complex cyst" rather than hamartoma and designate it of thyroid origin owing to its attachment to this gland. It is not possible, however, to exclude tracheal or laryngeal origin of such cartilage-containing cysts nor to exclude a metaplastic derivation from the thyroid gland parenchyma.

Age of onset and growth rate of teratoma

Nearly all the reported cases of cervical teratoma have been benign and occurred in infancy. Of the 119 cases collated (table 1) all occurred in infants and only one was malignant. A further 8 cervical teratomas, which are not included in the present discussion, were reported in adults (Kemp, 67).

Almost all the reported cases of benign cervical teratomas were detected clinically before the age of 1 year, 80% of these were present at birth and of this group 17.1% in Silberman's (60) series and 17.7% of Hajdu's ('66) series were stillborn.

From these figures it follows that a considerable part of the tumor growth occurred in utero which is borne out by the large tumor size attained in live- and stillborn infants (Kaynes, '59; Rickham, '72). This large size indicates either a long period of growth because it originated early in fetal development or, quite the opposite, that it occurred at a later stage of fetal development but underwent rapid growth. Experimental teratomas in animals showed wide variation in growth rate (Solter, et al., 70). These teratomas, derived from mouse egg cylinders, either grew very large and compressed surrounding tissue or remained small. The specific growth rate of cervical teratomas is incomparable to that of experimentally produced teratomas which, however, could only be produced with early and relatively undifferentiated embryonic tissue. This suggests that cervical teratomas of human neonates presumably arise at an early, undifferentiated embryonic stage.

Thyroid and cervical teratomas

The association of thyroid and cervical

teratomas has been referred to by several authors (Bale, 50; Keynes, 59, Silberman and Mendelson, 60; Willis, 67; Rickham, '72). The thyroid was involved either by direct continuity or actual replacement of thyroid tissue by teratogenous growth in 10 of 17 cases reported since 1966 (table 1) and in 58 of 71 cases reported by Keynes (59).

Bale (50) classified teratomas of the neck into three groups, of which "thyroid teratoma" was distinguished by its blood supply from the thyroid arteries. This classification is not satisfactory as the arterial supply of very few teratomas is accurately recorded. The classification of Silberman and Mendelson (60) is more acceptable: thyroid teratomas are those in which the tumor replaces, occupies, or is in continuity with the thyroid gland, and all other neck teratomas not fulfilling these criteria are termed cervical teratomas.

Histogenesis of cervical and thyroid teratomas

There is general agreement that teratomas arise from pluripotential cells, though the nature of these cells has not been defined. The current view (Gallard, 74) holds that these pluripotential cells either have the embryonic potential of blastomeres or that they are blastodermic

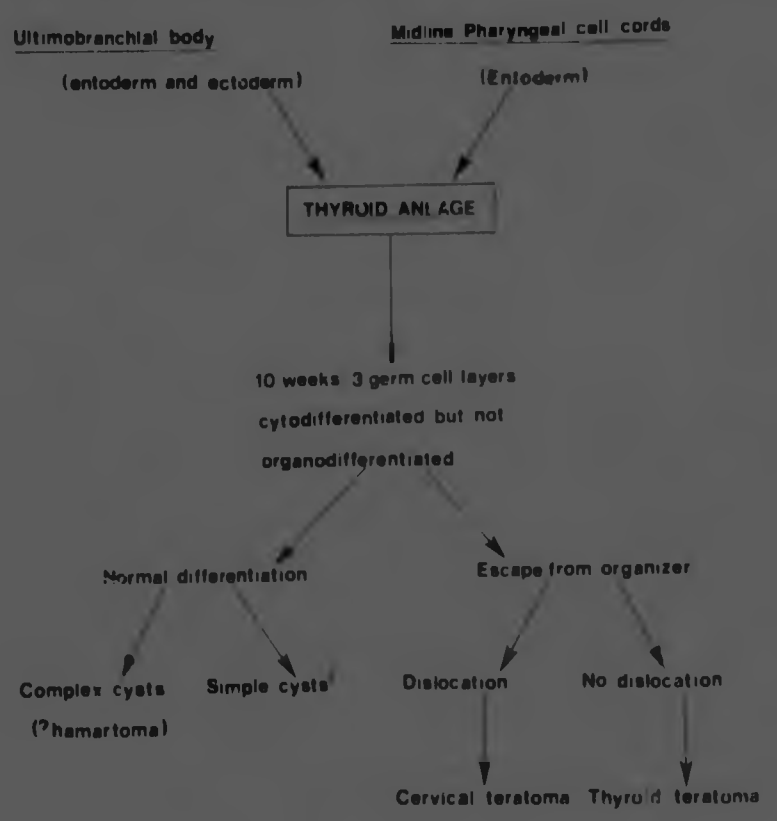

[1] See Roediger and Spitz 73

Fig. 5. Components of the thyroid anlage. Teratoma formation is suggested to occur before the cytodifferentiated stage has progressed to organodifferentiation.

nd Mendelson ('60) is more acceptable
hyroid teratomas are those in which the
umor replaces, occupies, or is in con-
tinuity with the thyroid gland, and all
ther neck teratomas not fulfilling these
iteria are termed cervical teratomas

Histogenesis of cervical and thyroid teratomas

There is general agreement that tera
mas arise from pluripotential cells
hough the nature of these cells has not
en defined. The current view (Gaillard,
'4) holds that these pluripotential cells
ither have the embryonic potential of
lastomeres or that they are blastodermic

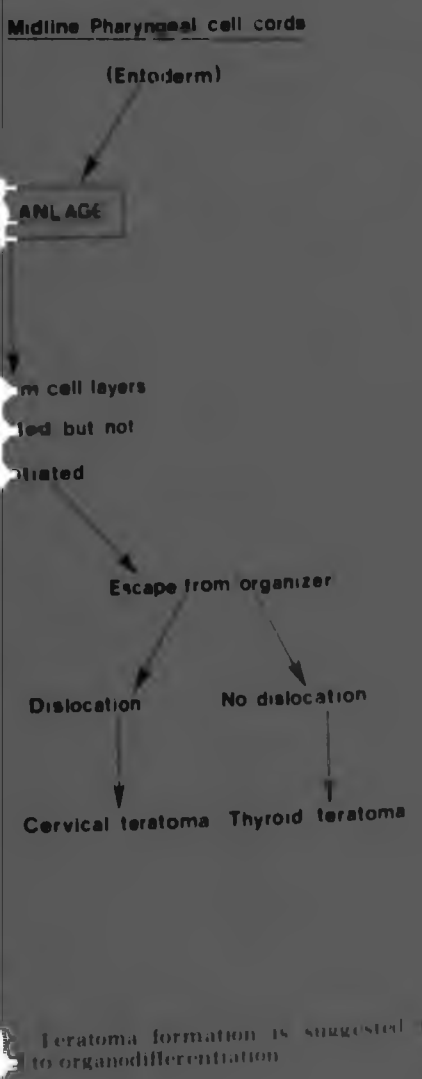

Teratoma formation is suggested to occur
to organodifferentiation

in nature. Support for the former view can be obtained from gonadal teratomas whereas the latter view is invoked to explain the occurrence of extragonadal teratomas. Derivatives of three germ cell layers are needed to produce experimental teratomas in extragonadal sites (Salaun, '68).

Considerations in the histogenesis of teratomas need to include the ontogenetic time of their origin, causal factors in their production, and the topography of cells that give rise to these teratomas. We postulate that neck teratomas arise from the embryonic thyroid anlage (fig. 5), and agree with Willis ('67, p. 998) that "it is significant that most cervical teratomas affect the thyroid gland. Our postulates are made on the premise that (i) the thyroid anlage contains significant derivatives of all three germ cell layers, and that pluripotential cells from each germ cell layer are involved in teratoma formation, (ii) there is failure of organizers to effect organogenesis (Willis, 67, p. 997) at an *early* stage of thyroid development, and (iii) this process may be accompanied by local dislocation of thyroid tissue during early embryogenesis.

The human thyroid gland contains cells derived from the thyroglossal tract and ultimobranchial body (UBB which disperse within the thyroid parenchyma (Sugiyama, 71). In man (Chan and Conen, '71) and other mammals (Pearse and Carvalheira, 67) it has been shown that the UBB gives rise to derivatives known as C cells. Initial beliefs (Pearse, '70) that C cells were of neuroectodermal origin were followed by supportive evidence for this origin in animals (Douarin and Lievre, 70 Pearse and Polak, '71). Though similar proof in humans is not available it is known that neonatal thyroids contain C cells (Roediger, '73), and have histochemical properties similar to rodent C cells in which neural crest origin is known (Pearse and Polak, 71). Three germ cell layers are thus represented in the fetal thyroid anlage at an early stage (9th week), when the UBB is already incorporated into the thyroid (Sugiyama, 71). We feel that factors that will lead to teratoma formation act at this developmental stage on pluripotential representatives of each germ-cell layer that is cyto but not yet organodifferentiated. Origin at an early developmental stage could be reflected by the considerable in utero growth that this tumor is capable of (see above).

There is indirect evidence that organizers are operative in the primitive thyroid anlage. Morphological studies show that parathyroid (Black and Watts, 49) and C cells (Solcia et al., 70) may form follicles similar to thyroid follicles. Widespread follicle formation is attributed to the diffuse effect of organizers. Experimentally it is possible to produce teratomas which are thought to be due to a lack of organizers. Macerated rat embryonic tissue containing derivatives of all three germ-cell layers injected subcutaneously or intraperitoneally into adult rats produced benign teratomas (Salaun, 68). Similar experiments, but with macerated thyroid tissue, might provide some proof as to the origin of teratomas in the neck and confirm or refute the postulates made.

Ectopic normal thyroid tissue usually located in the path of its normal descent is well known. Meissner and Warren (69) recorded that nests of normal thyroid tissue occur frequently in muscle and soft tissue adjacent to the normally situated thyroid. These tissues are not metastatic deposits of carcinoma to which ectopic thyroid derivatives are frequently attributed. Embryonic dislocation of teratomatous growths may account for the small percentage of neck teratomas found further away from the thyroid. Apart from such dislocations other branchiogenic structures could also be involved in the formation of cervical teratomas. As the proportion of cervical teratomas that are distant from the thyroid gland is small we, at present, prefer the view of a common origin for all cervical teratomas rather than invoking the formation of teratomas from other structures.

CONCLUSIONS

Benign teratomas of the neck are congenital tumors with a variable rate of growth. They must be distinguished from complex cysts of the thyroid that do not have a multiorganoid differentiation. The authors propose, on clinical and embryological evidence, that all anterior neck teratomas arise from the thyroid gland and that this involves a failure of organogenesis, at an early developmental stage,

from the three germ-cell layers represented in the thyroid gland.

ACKNOWLEDGMENTS

The authors should like to thank the Superintendent, Baragwanath Hospital, for permission to publish these cases and the Director, South African Institute for Medical Research, for facilities provided to carry out this study

LITERATURE CITED

Bale, G. E. 1950. Teratoma of the neck in the region of the thyroid. Am. J. Path. [illegible]
Black, B. M., and C. E. Watts. 1949. Cysts of parathyroid origin. Surgery, [illegible] 941–949.
Chan, A. S., and P. E. Cohen. 1971. Ultrastructural observations on cytodifferentiation of parafollicular cells in the human fetal thyroid. Lab. Inv. 25: 249–259.
Chappell, J. S. 1970. Teratomas in infancy and childhood. S. Afr. J. Surg. 8: 77–8[illegible].
Douarin, N. Le, and C. Le Lievre. 1970. Demonstration de l'origine neurale des cellules à calcitonine du corps ultimobranchial chez l'embryon de poulet. C. R. Acad. Sci. [illegible]: 2857–2860.
Finkle, H. I., and R. F. Goldman. 1973. Heterotopic cartilage in the thyroid. Arch. Path. 95: 48–49.
Gaillard, J. A. 1974. Differentiation and organization in teratomas. In: Neoplasia and Cell Differentiation. G. A. Sherbet, ed. Karger, Basel. pp. 319–349.
Gray, B. N. 1973. Teratoma of the neck. Aust. New Zeal. J. Surg. 42: 294–297.
Hajdu, S. I., A. A. Farugue, I. O. Hajdu, and W. S. Morgan. 1966. Teratoma of the neck in infants. Am. J. Dis. Child. *111*: 412–416.
Hedinger, C. E. 1969. Sarcomas of the thyroid gland. In: Thyroid Cancer. UICC Monograph Series, Vol. 12. C. E. Hedinger, ed. Springer-Verlag, New York. pp. 36–41.
Hurlbut, H. J., H. W. Webb, and E. Moseley. 1967. Cervical teratoma in infant siblings. J. Paediat. Surg. 2: 424–426.
Kemp, D. R. 1967. Teratoma of the neck in the adult. Aust. New Zeal. J. Surg. 36: 123–127.
Keynes, W. M. 1939. Teratoma of the neck in relation to the thyroid gland. Br. J. Surg. 46: 466–472.
Meissner, W. A., and S. Warren. 1969. Tumors of the thyroid gland. 2nd Ser. Fasc. 1. Armed Forces Institute of Pathology, Washington, D.C. pp. 1–135.
Numanoglu, I. Y. Aksu, and O. Mutaf. 1970. Teratoma of thyroid gland in newborn infant. J. Paediat. Surg. 5: 181–182.
Pearse, A. G. E. 1970. The characteristics of the C cell and their significance in relation to those of other endocrine polypeptide cells and to the synthesis, storage and secretion of calcitonin. Calcitonin 1969. Proceedings of the Second International Symposium. Heinemann, London. pp. 125–140.
Pearse, A. G. E., and A. E. Carvalheira. 1967. Cytochemical evidence for an ultimobranchial origin of rodent thyroid C cells. Nature, *214*: 929–930.
Pearse, A. G. E., and J. M. Polak. 1971. Cytochemical evidence for the neural crest origin in mammalian ultimobranchial C cells. Histochemie, *27*: 96–102.
Rettel, P. J. 1966. Cervical teratoma. Is it rare? S. Afr. J. Surg. 4: 181–185.
Rickham, P. P. 1972. Zervikalteratome. Helv. Paediat. Acta, [illegible]: 549–[illegible].
Roediger, W. E. W. 1974. A comparative study of the normal human neonatal and the canine thyroid C cell. J. Anat. *117*: 255–276.
Roediger, W. E. W., and E. Spitz. 1973. Congenital cyst of the thyroid. S. Afr. Med. J. 47: 1120–1122.
Salaün, J. 1968. Sur la tératogénèse expérimentale de teratomes chez le poulet et le rat. Arch. Anat. Micr. 57: 11–41.
Silberman, R., and E. R. Mendelson. 1960. Teratoma of the neck. Arch. Dis. Child. 35: 159–170.
Solcia, E., C. Capella, R. Sampietro, and C. Vassallo. 1970. The distribution of human C cells and their relationship to osteopetrosis and medullary carcinoma of the thyroid. Calcitonin 1969. Proceedings of the Second International Symposium. Heinemann, London, pp. 220–226.
Solter, D., N. Skreb, and E. Damjanov. 1970. Extrauterine growth of mouse egg cylinders results in malignant teratoma. Nature, *227*: 503–504.
Sugiyama, S. 1971. The embryology of the human thyroid gland including ultimobranchial body and others related. In: Advances in Anatomy, Embryology and Cell Biology. Vol. 44, no. 2. Springer-Verlag, New York. pp. 1–111.
Willis, R. A. 1962. The Pathology of the Tumours of Children. Oliver and Boyd, Edinburgh.
———. 1967. Pathology of Tumours. 4th Ed. Butterworths, London.

REPRINTED FROM



The British Journal of Surgery

VOLUME 63, NUMBER 5, MAY 1976

JOHN WRIGHT & SONS LIMITED · BRISTOL

Br. J. Surg. Vol. 63 (1976) 343–345

Thyroidectomy for non-familial medullary carcinoma

W. F. W. ROEDIGER*

SUMMARY

Two cases of non-familial medullary carcinoma of the thyroid which had thyroid tissue remaining after initial thyroidectomy were shown to contain residual, intraglandular carcinoma at reoperation. This observation, the distribution of C cells in the normal thyroid gland and the lymph node spread of this carcinoma have led to the proposal of a bilateral 90 per cent upper pole thyroidectomy including the superior parathyroids for cases of non-familial medullary carcinoma. This operation removes all the C-cell-bearing area and leaves a small thyroid remnant at the lower pole for preservation of the inferior parathyroid glands. The operation is discussed with reference to these factors.

MEDULLARY carcinoma of the thyroid is a well-established clinical entity. The carcinoma was identified by Hazard et al. in 1959, and since the histogenesis was correctly adduced by Williams in 1966, both the pathological behaviour (Ibanez et al., 1966; Williams et al., 1966; Woolner et al., 1968; Ibanez, 1974; Roediger, 1975; Williams, 1975) and clinical syndromes (Williams, 1967; Melvin, 1974) associated with this tumour have been extensively investigated.

Two distinct types of medullary carcinoma have become apparent, one arising spontaneously, the other being genetically determined and familial. Total thyroidectomy is, by general consensus, advised for familial medullary carcinoma (Block et al., 1968; Miller et al., 1972; Beaugie et al., 1975), whereas opinion is divided about the extent of thyroidectomy for the spontaneous type of tumour (Woolner et al., 1968; Esselstyn and Crile, 1971; Keynes and Till, 1971). Understandably, this is due to the rarity of the tumour: a general surgeon is unlikely to see more than 2 cases in a lifetime (Campbell and Sage, 1975). We consider that treatment should be based on a total excision of the C-cell-bearing area in the thyroid gland and put this proposal forward as most (84 per cent) medullary carcinomas are of the non-familial variety (Chong et al., 1975). At the same time we must stress that no prognostic evaluation of this operation is at present available.

Two cases of non-familial medullary carcinoma are reported. Their initial operations were performed elsewhere. They were then referred for further treatment to the Johannesburg General Hospital.

Case reports

Case 1. A 38-year-old female patient presented with a single nodule on the left side of the neck. Sixteen months previously she had had a left total and right seven-eighth lobectomy performed for medullary carcinoma. The history, apart from treatment for reactive depression and urinary tract infections, was unremarkable. Examination of a nervous patient confirmed a jugular-digastric node, 1 cm in diameter, on the left side. No further nodules or palpable thyroid tissue were evident. Radiographic examination revealed no bony or blood-borne metastases.

Haematological, serological and urine investigations which included VMA estimation and thyroid function tests were normal. An ^{131}I scintiscan demonstrated a substantial thyroid remnant on the right side. At operation this remnant was dissected off the trachea and a standard block dissection of the cervical glands was carried out on the left side. A course of radiotherapy was commenced to the neck 6 weeks later. The patient was tumour-free 7 years after operation but had evidence of chronic hypoparathyroidism. Histological examination of the thyroid remnant confirmed medullary carcinoma which extended to the posterior capsule. Several lymph nodes were involved with tumour cells which produced amyloid (thioflavin-T stain).

Case 2. A 45-year old female patient had a right hemithyroidectomy for a single thyroid nodule which histologically was a well circumscribed medullary carcinoma. She was in good health on referral to Johannesburg General Hospital 1 month after her initial operation. No cervical lymph node enlargement or thyroid nodule was palpable in the remaining lobe. Serum calcium was low (4·3, 4·5 mEq/l) in 2 out of 5 estimations. Scintiscan with ^{131}I showed no hypofunctioning areas or features of displacement. Total lobectomy (left) with preservation of both parathyroid glands was undertaken 6 weeks after her initial operation. There were no palpable lymph nodes. Section of the lobe demonstrated a circumscribed nodule, 1·2 cm in diameter, which was centrally situated towards the posterolateral aspect of the thyroid gland. Histological examination confirmed medullary carcinoma.

Discussion

Both the cases presented here demonstrated residual medullary carcinoma in situations in which primary tumours have most frequently been observed, that is the posterolateral and central regions of each lobe (Melvin et al., 1972; White, 1973). Distribution of tumour in these regions has been noted especially in the familial type and coincides with the area of maximal concentration of thyroid C cells (Roediger, 1973; Wolfe et al., 1974) (*Fig.* 1). Studies of whole thyroid glands from neonates showed that C cells were interspersed in between follicles or were part of follicles which were predominantly in the postero-superior aspect of each gland. In the neonate the highest concentration of C cells is around the superior parathyroid gland which embryologically is associated with the ultimobranchial body (Kingsbury, 1935; Norris, 1937), the anlage of C cells. Adult thyroid glands when compared with those of the neonate have a greater proportion of their C cells anteriorly (Wolfe et al., 1974), presumably owing to dispersion of

* Department of Surgery, University of the Witwatersrand, and Johannesburg General Hospital, Johannesburg.

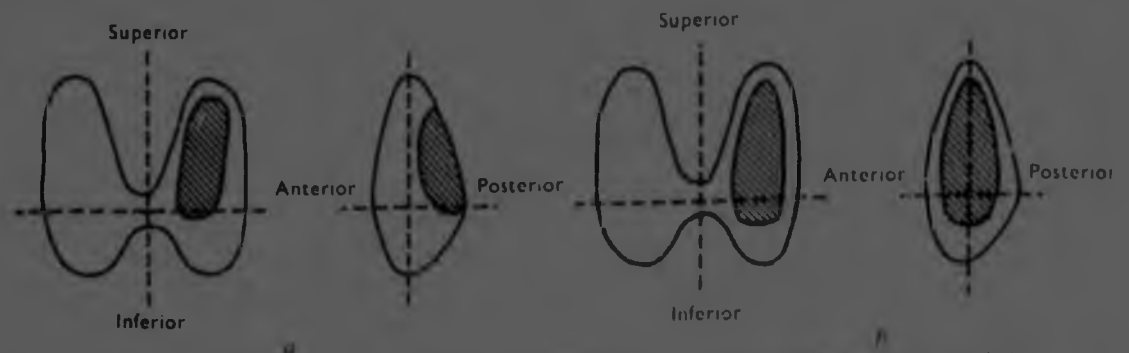

Fig. 1. Intrathyroidal distribution of C cells. Hatched area represents regions in which C cells are predominantly found in the neonatal (*a*) and adult (*b*) human thyroid gland. Redrawn from Roediger (1973) and Wolfe et al. (1973).

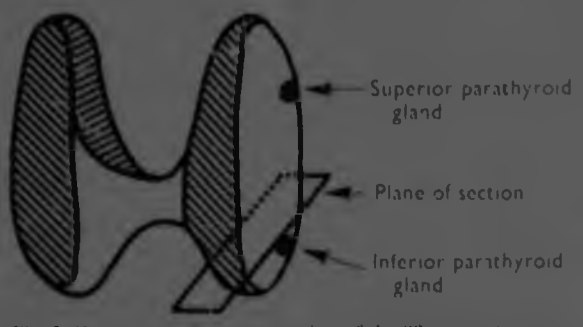

Fig. 2. Diagrammatic representation of the 90 per cent upper pole thyroidectomy. Both lobes and the isthmus are removed

C cells with growth. However, in both neonate and adult virtually no C cells are found in the postero-inferior aspect of each thyroid lobe.

Lymph node involvement, as far as could be ascertained, was not observed at the initial operation in either of the present cases. In non-familial carcinoma 50 per cent of cases have no involvement of lymphatics (Woolner et al., 1968). The 10-year survival rate is 85 per cent for this group compared with 40 per cent for cases with lymph node spread. These findings contrast with those of familial medullary carcinoma: 7 out of 12 cases in one family had lymph node spread (Miller et al., 1972), which is a high incidence in view of the very early diagnosis, often without palpable tumour, that was made with the assistance of radio-immunoassay for calcitonin (Miller et al., 1972; Jackson et al., 1973). Late cases of medullary carcinoma have a pattern of distant lymph node spread similar to that of papillary carcinoma. Mediastinal extension was observed in 10 out of 12 cases of late medullary carcinoma (Ibanez et al., 1966).

Thyroidectomy for medullary carcinoma should carefully avoid leaving a posterior sliver of thyroid tissue in each upper pole. This should be done in spite of the proximity of the recurrent laryngeal nerve, which in this area is most vulnerable to operative damage (Riddell, 1970). A remnant of posterior thyroid tissue leaves areas which are rich in C cells, especially the areas in juxtaposition to the superior parathyroid gland. Furthermore, the initial operation should aim at diagnosing tumour spread to lymph nodes, and therefore a search for lymph nodes should be made at the polar regions of the thyroid gland. Involved lymph nodes at the lower pole may encourage earlier radiotherapy to the mediastinum, whereas upper pole and periglandular lymph nodes which are involved may necessitate a cervical block dissection or at least a very close watch for future cervical lymph node enlargement.

It is suggested that the ideal extent of thyroid resection for non-familial medullary carcinoma is a procedure such as that indicated in *Fig.* 2. The well-established stages of thyroid dissection are followed (Piercy, 1969). We prefer to identify the recurrent laryngeal nerve by the Lahey manœuvre (Lahey, 1938), which is a dissection against a tautened inferior thyroid artery, and then to follow the nerve superiorly with due consideration to its anatomical variations (Riddell, 1970). Parathyroid tissue is carefully localized, and usually the inferior parathyroid gland is easier to find. The inferior parathyroids are the principal glandular elements of parathyroid tissue. This is because the third pharyngeal pouch derivatives are embryologically more advanced than the derivatives of the fourth pouch. In fact derivatives of the ventral fourth pouch (thymus) are rudimentary in man (Norris, 1937; Boyd, 1950), and the contribution of parathyroid tissue from this pouch is less prominent than that of the third pharyngeal pouch. For these reasons and in order to remove the C-cell-bearing tissue we advocate that the 90 per cent upper pole thyroidectomy include the removal of the superior parathyroid glands *en bloc*. The presence of inferior parathyroid tissue must be ascertained prior to embarking on such a procedure.

Our approach differs from that of Miller et al. (1972), who in their cases performed a total thyroidectomy with removal of the inferior, but preservation of the superior, parathyroid glands. Such a resection rightfully aims at removing intraglandular spread to the lower pole. However, we at present prefer to direct attention to an efficient removal of the primary C-cell-bearing area and therefore remove the superior parathyroid gland and then deal with the intraglandular spread at the lower poles according to the merits of each case. In either event some viable parathyroid tissue must be retained and preferably this should be the inferior parathyroid glands.

The 90 per cent upper pole thyroi
forward as a rational and somewhat
cedure which is primarily for cases
node spread. The predominant aim is
C-cell-bearing area and we stress
the posterior thyroid gland with
viable inferior parathyroids. Further
proposals is mandatory but may be
out in a single centre.

Acknowledgements

The cases are reported with the kind
Superintendent, Johannesburg General
most grateful to Mr R. Silbetman for
publish the details of *Case* 2, and to
Lawson for his helpful advice and
preparation of this manuscript.

References

BLACKOW I. M., CECHETTI R. T., BROWN
R. T. and LLOYD M. H. (1975) Rep
with inherited medullary carc
and phaeochromocytoma. *Br. J.*
269.

BLOCK M. A., MILLER J. M. and HOR
Medullary carcinoma of the t
implications. *Arch. Surg.* **96**, 521

BOYD J. D. (1950) Development of t
parathyroid glands and the th
Coll. Surg. Engl. **7**, 455–471.

CAMPBELL D. J. and SAGE R. H. (1975)
twenty-year experience in a
Br. J. Surg. **62**, 207–21

CHONG G. C., BEAHRS O. H., SIZEMO
WOOLNER L. H. (1975) Medullary
the thyroid gland. *Cancer* **35**, 695

ESSELSTYN C. B. and CRILE G. Jun (19
for surgical therapy in thyroid
Nucl. Med. **1**, 474–480.

HAZARD J. B., HAWK W. A. and CRILE G.
lary (solid) carcinoma of the t
pathologic entity. *J. Clin. Endocr.*
'52 161.

IBANEZ M. L. (1974) Medullary ca
thyroid gland. In: SOMMERS S. C.
Annual, Vol. 9. New York: Ap
Crofts, pp. 263–290.

IBANEZ M. L., RUSSELL W. O., ALBOR
TAMPERICO R., WHITE E. C. an
(1966) Thyroid carcinoma: biolog
mortality. *Cancer* **19**, 1039–1052.

JACKSON C. E., TASHJIAN A. H. and BL
Detection of medullary thyro
calcitonin assay in families. *An*
78, 845–852.

KEMNEY W. M. and HILL S. S. (1971)
cinoma of the thyroid gland.
443–456.

KINGSBURY B. F. (1935) On the late
branchial body within the thyro
Rec. **61**, 155–167.

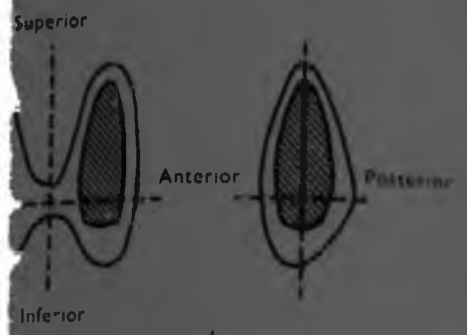

b

in which C cells are predominantly found in
(1973) and Wolfe et al. (1974).

at the polar regions of the thyroid gland
lymph nodes at the lower pole may en-
earlier radiotherapy to the mediastinum,
upper pole and periglandular lymph nodes
involved may necessitate a cervical block
or at least a very close watch for future
lymph node enlargement.

ted that the ideal extent of thyroid resec-
non-familial medullary carcinoma is a
such as that indicated in *Fig.* 2. The well-
d stages of thyroid dissection are followed
1969). We prefer to identify the recurrent
nerve by the Lahey manœuvre (Lahey,
hich is a dissection against a tautened
hyroid artery, and then to follow the nerve
with due consideration to its anatomical
(Riddell, 1970). Parathyroid tissue is care-
lized, and usually the inferior parathyroid
asier to find. The inferior parathyroids are
cipal glandular elements of parathyroid
his is because the third pharyngeal pouch
are embryologically more advanced than
atives of the fourth pouch. In fact derivatives
ntral fourth pouch (thymus) are rudimentary
Norris, 1937; Boyd, 1950), and the contribu-
arathyroid tissue from this pouch is less
t than that of the third pharyngeal pouch
reasons and in order to remove the C-cell-
we advocate that the 90 per cent upper
roidectomy include the removal of the
parathyroid glands *en bloc*. The presence of
thyroid tissue must be ascertained prior
ing on such a procedure.

differs from that of Miller et al
in their cases performed a total thyroidec-
removal of the inferior, but preservation
parathyroid glands. Such a resection
aims at removing intraglandular spread to
pole. However, we at present prefer to
ation to an efficient removal of the primary
ing area and therefore remove the superior
gland and then deal with the intra-
spread at the lower poles according to the
each case. In either event some viable para-
sue must be retained and preferably this
the inferior parathyroid glands.

The 90 per cent upper pole thyroidectomy is put forward as a rational and somewhat idealistic procedure which is primarily for cases without lymph node spread. The predominant aim is removal of the C-cell-bearing area and we stress the removal of the posterior thyroid gland with preservation of viable inferior parathyroids. Further evaluation of our proposals is mandatory but may be difficult to carry out in a single centre.

Acknowledgements

The cases are reported with the kind permission of the Superintendent, Johannesburg General Hospital. I am most grateful to Mr R. Silberman for allowing me to publish the details of *Case* 2, and to Professor H. H. Lawson for his helpful advice and criticism in the preparation of this manuscript.

References

BEAUGIE J. M., BELCHETZ P. E., BROWN C. L., FRANKEL R. J. and LLOYD M. H. (1975) Report of a family with inherited medullary carcinoma of the thyroid and phaeochromocytoma. *Br. J. Surg.* 264–268.

BLOCK M. A., MILLER J. M. and HORN R. C. (1968) Medullary carcinoma of the thyroid: surgical implications. *Arch. Surg.* **96**, 521–526.

BOYD J. D. (1950) Development of the thyroid and parathyroid glands and the thymus. *Ann. R. Coll. Surg. Engl.* **7**, 455–471.

CAMPBELL D. J. and SAGE R. H. (1975) Thyroid cancer: twenty years' experience in a general hospital. *Br. J. Surg.* **62**, 207–217.

CHONG G. C., BEAHRS O. H., SIZEMORE G. W. and WOOLNER L. H. (1975) Medullary carcinoma of the thyroid gland. *Cancer* **35**, 695–704.

ESSELSTYN C. B. and CRILE G. jun. (1971) Indications for surgical therapy in thyroid disease. *Sem. Nucl. Med.* **1**, 474–480.

HAZARD J. B., HAWK W. A. and CRILE G. (1959) Medullary (solid) carcinoma of the thyroid: clinicopathologic entity. *J. Clin. Endocrinol. Metab.* **19**, 152–161.

IBANEZ M. L. (1974) Medullary carcinoma of the thyroid gland. In: SOMMERS S. C. (ed.) *Pathology Annual*, Vol. 9. New York: Appleton-Century-Crofts, pp. 263–290.

IBANEZ M. L., RUSSELL W. O., ALBORES-SAAVEDRA J., LAMPERTICO P., WHITE E. C. and CLARK R. L. (1966) Thyroid carcinoma: biologic behavior and mortality. *Cancer* **19**, 1039–1052.

JACKSON C. E., TASHJIAN A. H. and BLOCK M. A. (1973) Detection of medullary thyroid cancer by calcitonin assay in families. *Ann. Intern. Med.* **78**, 845–852.

KEYNES W. M. and HILL A. S. (1971) Medullary carcinoma of the thyroid gland. *Q. J. Med.* **40**, 443–456.

KINGSBURY B. F. (1935) On the fate of the ultimobranchial body within the thyroid gland. *Anat. Rec.* **61**, 155–167.

LAHEY F. H. (1938) Routine dissection and demonstration, recurrent laryngeal nerve in subtotal thyroidectomy. *Surg. Gynecol. Obstet.* **66**, 775–777.

MELVIN K. E. W. (1974) The paraneoplastic syndromes associated with carcinoma of the thyroid gland. *Ann. NY Acad. Sci.* **230**, 378–390.

MELVIN K. E. W., TASHJIAN A. H. and MILLER H. H. (1972) Studies in familial (medullary) thyroid carcinoma. In: ASTWOOD A. B. (ed.) *Recent Progress in Hormone Research*, Vol. 28. New York, Academic, pp. 399–470.

MILLER H. H., MELVIN K. E. W., GIBSON J. M. and TASHJIAN A. H. (1972) Surgical approach to early familial medullary carcinoma of the thyroid. *Am. J. Surg.* **123**, 438–443.

NORRIS E. H. (1937) Parathyroid glands and lateral thyroid in man. Their morphogenesis, histogenesis, topographic anatomy and prenatal growth. *Contrib. Embryol. Carnegie Inst. Wash.* **26**, 247–294.

PERCY J. E. (1969) Surgery of the thyroid gland. In: ROB C. and SMITH R. (ed.) *Operative Surgery*, Vol. 6, 2nd ed. London, Butterworths, pp. 203–230.

RIDDELL V. (1970) Thyroidectomy: prevention of bilateral recurrent nerve palsy. *Br. J. Surg.* **57**, 1–11.

ROLDIGER W. E. W. (1973) A comparative study of the normal human neonatal and the canine thyroid C cell. *J. Anat.* **115**, 255–276.

ROLDIGER W. E. W. (1975) The oxyphil and C cells of the human thyroid. A cytochemical and histopathological review. *Cancer* **36**, 1758–1770.

WHITE E. C. (1973) Thyroid tumors: surgical management. In: *Endocrine and Non-endocrine Hormone-producing Tumors*. Chicago, Year Book, pp. 353–362.

WILLIAMS E. D. (1966) Histogenesis of medullary carcinoma of the thyroid. *J. Clin. Pathol.* **19**, 114–118.

WILLIAMS E. D. (1967) Medullary carcinoma of the thyroid. *J. Clin. Pathol.* **20**, 395–398.

WILLIAMS E. D. (1975) Medullary carcinoma of the thyroid. In: HARRISON C. V. and WEINBREN K. (ed.) *Recent Advances in Pathology*, Vol. 9. Edinburgh, Churchill Livingstone, pp. 156–182.

WILLIAMS E. D., BROWN C. L. and DONIACH I. (1966) Pathological and clinical findings in a series of 67 cases of medullary carcinoma of the thyroid. *J. Clin. Pathol.* **19**, 103–113.

WOLFE H. J., VOELKEL E. F. and TASHJIAN A. H. (1974) Distribution of calcitonin-containing cells in the normal adult human thyroid gland: a correlation of morphology with peptide content. *J. Clin. Endocrinol. Metab.* **38**, 688–694.

WOOLNER L. B., BEAHRS O. H., BLACK B. M., MCCONAHEY W. M. and KEATING F. R. (1968) Thyroid carcinoma: general considerations and follow-up data on 1181 cases. In: YOUNG S. and ISMAN D. R. (ed.) *Thyroid Neoplasia*. London, Academic, pp. 51–79.

Author Roediger W E W
Name of thesis A Cytochemical Study of the Cell in the Thyroid Glands of Young Dogs and Human Neonates 1976

PUBLISHER:
University of the Witwatersrand, Johannesburg
©2013

LEGAL NOTICES:

Copyright Notice: All materials on the University of the Witwatersrand, Johannesburg Library website are protected by South African copyright law and may not be distributed, transmitted, displayed, or otherwise published in any format, without the prior written permission of the copyright owner.

Disclaimer and Terms of Use: Provided that you maintain all copyright and other notices contained therein, you may download material (one machine readable copy and one print copy per page) for your personal and/or educational non-commercial use only.

The University of the Witwatersrand, Johannesburg, is not responsible for any errors or omissions and excludes any and all liability for any errors in or omissions from the information on the Library website.