

https://dspace.org/

Histopathological Spectrum of Conjunctival Lesions at St John Eye Hospital

Mofokeng, Thabiso

2023-07

University of the Witwatersrand, Johannesburg

https://hdl.handle.net/10539/44635

Mofokeng, Thabiso. (2023). Histopathological Spectrum of Conjunctival Lesions at St John Eye Hospital. [Masters dissertation, University of the Witwatersrand, Johannesburg]. WIReDSpace. https://hdl.handle.net/10539/44635

Downloaded from a DSpace repository. https://dspace.org/

Histopathological Spectrum of Conjunctival Lesions at St John Eye Hospital

Primary Author: Dr Thabiso Mofokeng; MBChB (Natal), Dip Ophth (SA), FC Ophth (SA) Candidate: MMed (Ophthalmology)

Supervisor: Dr Nicole Welsh; MBChB (UCT), MMed (Wits) (Ophth), FC Ophth (SA)

Declaration

I, Thabiso Mofokeng student number 2286225, registered for the degree of Master of Medicine in Ophthalmology, declare that the work submitted for assessment of the above degree is my own unaided work except where I have explicitly stated otherwise.

Dedication

This research report is dedicated to my 92-year-old maternal grandmother, Mrs. Selina Sonile Mofokeng, who single handedly afforded me education all the way up to University without any formal employment.

Mme, I will forever be grateful.

Abstract

Background:

Various non-invasive modalities have been described in diagnosing conjunctival lesions but histology remains the gold standard. Shortages in ophthalmology services and pathology laboratories in non-urban areas is one of the main reasons for delayed presentation and appropriate treatment in sub-Saharan Africa. The purpose of this study is to determine the spectrum of histopathologic findings in conjunctival lesions from patients at St John Eye Hospital (SJEH).

Materials and Methods:

Data of patients who underwent conjunctival surgical biopsies was retrieved from the main theatre register of SJEH for a period of 3 years, starting from 1st November 2016 to 31st October 2019. This data was used to retrieve histology reports from National Health Laboratory Services (NHLS).

Results:

A total of 679 patient records were retrieved from the theatre register, only 585 histology reports from 584 patients could be analysed. There were 305 benign lesions with pterygia making up most of the benign lesions with a total of 249 (42.56%). A total of 174 premalignant lesions were recorded with severe ocular surface squamous neoplasia (OSSN) making up the bulk of premalignant lesions, 147/174(84.48%). Squamous cell carcinoma (SCC) was the main malignant lesion, 102 reported cases of a total 106 malignant lesions.

The age ranged from 1 to 90 years with mean of 43.14 years. The patients were predominantly black, Caucasians constituted only 1%. The average age for SCC was 41.3 years, severe OSSN 43.6 and pterygia 46.3 years.

Benign and premalignant lesions had a slightly higher predilection for females at 55.4% and 58.6% respectively.

Males had a slightly higher predilection of malignancy at 54.7%.

Conclusion

Pterygia are the most common excised benign conjunctival lesions and severe OSSN is the most common premalignant lesion excised at SJEH. SCC made up the bulk of conjunctival malignancies excised at SJEH. Pterygia, OSSN and SCC presents in a significantly younger age group when compared with reports from Europe, North and South America.

Acknowledgements

1. Dr N Welsh for her invaluable guidance and advise in finishing this project successfully
2. Prof Mayet for giving me permission to access SJEH theatre records
3. Dr Y Perner for giving me permission to access NHLS records
4. Ms Hlengiwe Selowa assisting with data analysis

Table of Contents

Introduction 1

Materials and Methods 1

Results 2

Discussion 7

Conclusion 10

References 11

Appendix A: Approved Research Protocol

Appendix B: Consent for Access to NHLS database

Appendix C: Letters of permission to access SJEH theatre records

Appendix D: Ethics Clearance Certificate

Appendix E: Turnitin Originality Report

List of figures

Figure 1: Sex

Figure 2: Race

Figure 3: Age

Figure 4: Benign lesions

Figure 5: Premalignant lesions

Figure 6: Malignant lesions

Figure 7: Age by type of lesion

List of tables

Table 1: Administration issues

Table 2: Sex

Table 3: Race

Table 4: Age

Table 5: Types of lesion

Table 6: Average age per type of lesion

Table 7: Type of lesion and sex

Table 8: Turnaround time per type of lesion

Table 9: Test of homogeneity of variances

Table 10: Anova

Table 11: Test statistics[ab]

List of Abbreviations

OSSN : Ocular Surface Squamous Neoplasia

CIN : Conjunctival Intraepithelial Neoplasia

PAM : Primary Acquired Melanosis

SCC : Squamous Cell Carcinoma

KS : Kaposi Sarcoma

NHLS : National Health Laboratory Services

SJEH : St John Eye Hospital

CHBAH: Chris Hani Baragwanath Academic Hospital

HOD's : Head of Departments

Px no : Patient number

M : Male

F : Female

HREC : Human Research Ethics Committee

M:F : Male to female ratio

USA : United States of America

HIV : Human immune-deficiency virus

AIDS : Acquired immunodeficiency syndrome

HAART: Highly active antiretroviral therapy

Introduction

Lesions of the conjunctiva submitted for histology include a broad spectrum of pathologic conditions ranging from benign, non-neoplastic degenerative lesions such as pterygia and pingueculae, benign neoplastic tumors for example, squamous papilloma, premalignant/preinvasive tumors for instance, CIN (mild-severe) and Primary Acquired Melanosis (PAM) with atypia, to aggressive malignant tumors such as SCC/invasive OSSN, Kaposi Sarcoma (KS), malignant melanoma and lymphoma which can result in vision loss and sometimes fatality if diagnosed late.[(1)]

The term OSSN was first described by Lee and Hirst in 1995 to denote an entire spectrum of dysplastic, pre-invasive and malignant squamous lesions that originate from the epithelium of the cornea or conjunctiva.[(2)] Conjunctival lesions can be classified into, melanocytic and non-melanocytic, neoplastic and non-neoplastic, or broadly divided into benign, pre-malignant and malignant lesions.[(1)] The distribution pattern of conjunctival lesions varies geographically. OSSN and pterygia are the most common conjunctival lesions submitted for histological diagnosis in sub-Saharan Africa. OSSN affects a younger age group in Africa unlike in Europe and the USA where it is still regarded as a disease of older white males. Differentiating early malignancies from benign lesions can be clinically challenging, hence it is important to send all excised lesions for histological diagnosis.[(3)]A study conducted at an Ophthalmology referral unit in Central Mexico where 177 pterygia underwent surgical biopsies over a 2 year period showed OSSN in 11.29% (n=20).[(4)]

Tissue diagnosis remains the gold standard for definitive diagnosis of conjunctival lesions.The two surgical biopsy methods include, incisional biopsy reserved for extensive suspicious tumours that are symptomatic,[(5)] or showing evidence of invading the globe on imaging. The other is excisional biopsy, more commonly performed and is appropriate for smaller tumours (≤4 clock hours limbal tumour or ≤15 mm basal diameter) that are symptomatic or suspected to be malignant.[(5)]

Materials and methods

This is a retrospective study of conjunctival surgical biopsies submitted for histology at St John Eye Hospital (SJEH) theatres during a 3 year period from 1st November 2016 to 31st October 2019. All specimens were submitted to the National Health Laboratory Services (NHLS) histopathology department at the Chris Hani Baragwanath Academic Hospital (CHBAH) based in Soweto for histological analysis. The main register of SJEH which covers three theatres was used to retrieve records of all patients who underwent conjunctival surgical biopsies during the set study period. Patients's demographic information and histopathological diagnoses were retrieved from original biopsy reports. Permission to collect data was given by the Head of Departments (HOD's) at SJEH and NHLS. Our study adhered to the principles of the declaration of Helsinki, approval from the Human Research Ethics Committee (HREC) and the Post Graduate Committee of the University of Witwatersrand was obtained (clearance certificate number M191069).

Frequencies of the different types of conjunctival lesions was reported.

The age of the patients for different lesions was categorized and descriptives of mean, minimum

and maximum provided. Kruskal Wallis Test was used to determine correlation between age and type of lesion. Anova and Levene statistic tests were used to determine correlation of turnaround time between different lesions.

Results

A total of 679 conjunctival biopsies from 678 patients were entered in the SJEH theatre main register from 1st November 2016 to 31st October 2019. Of these, 585 histology reports from 584 patients were retrieved from NHLS. Ninety five theatre entries were not included in the histopathology analysis due to various reasons *(table 1).*

Table 1: Errors in theatre entries

Status	Frequency
Incomplete Details	32
Incorrect Details	10
Mismatch forms	1
No px no on request form	1
No Records	32
Rejected/incomplete	4
Specimen & Request mismatch	1
Tissue lost in the lab	1
Wrong Details	1
Wrong Entry	12
Total	95

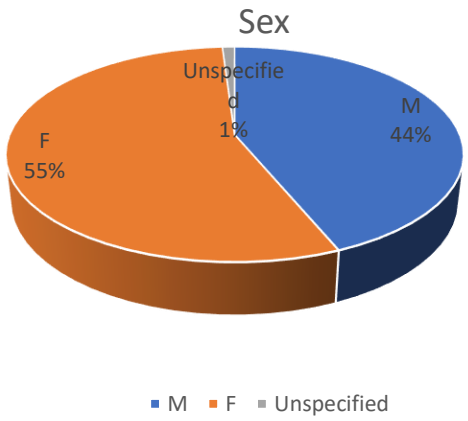

Figure 1: Sex

Data from theatre comprised 297 males, 375 females and 6 patients where the gender was not specified *(table 2, figure 1)*. Only 4 patients were white and the rest were black *(table 3, figure 2)*, no other races were recorded.

Table 3: Race

	Frequency	Percent
Black	675	99.4
White	4	0.6
Total	679	100.0

Table 2: sex

	Frequency	Percent
M	297	43.7
F	375	55.2
Unspecified	6	1.0
Total	678	100.0

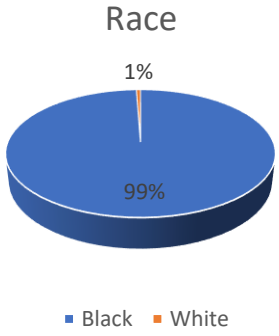

Figure 2: Race

Age distribution captured in years ranged from 1 to 90 years and was not stated in 9 patients *(table 4, figure 3)*. 585 histology reports were retrieved from 584 patients *(table 5)* with 1 patient undergoing biopsies in each eye, histology reported SCC on the right eye and severe CIN on the left.
Benign lesions accounted for 305 cases with pterygium being the most common (249) *(figure 4)*, premalignant 174 cases and malignant 106 cases *(table 5).*

Table 4: Age

Age group	Frequency	Percent
0-17	28	4
18-29	58	8.7
30-49	394	58.9
50-69	154	23
70+	36	5.4
Total	670	100

Table 5: Types of lesion

	Frequency	Percent
Benign lesion	305	52.1
Premalignant lesion	174	29.7
Malignant lesion	106	18.1
Total	585	100.0

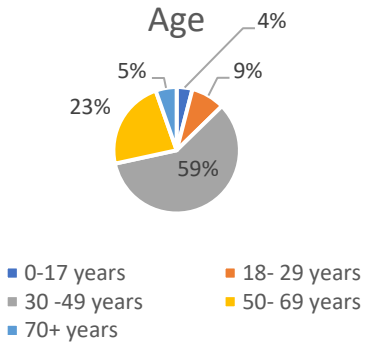

Figure 3: Age

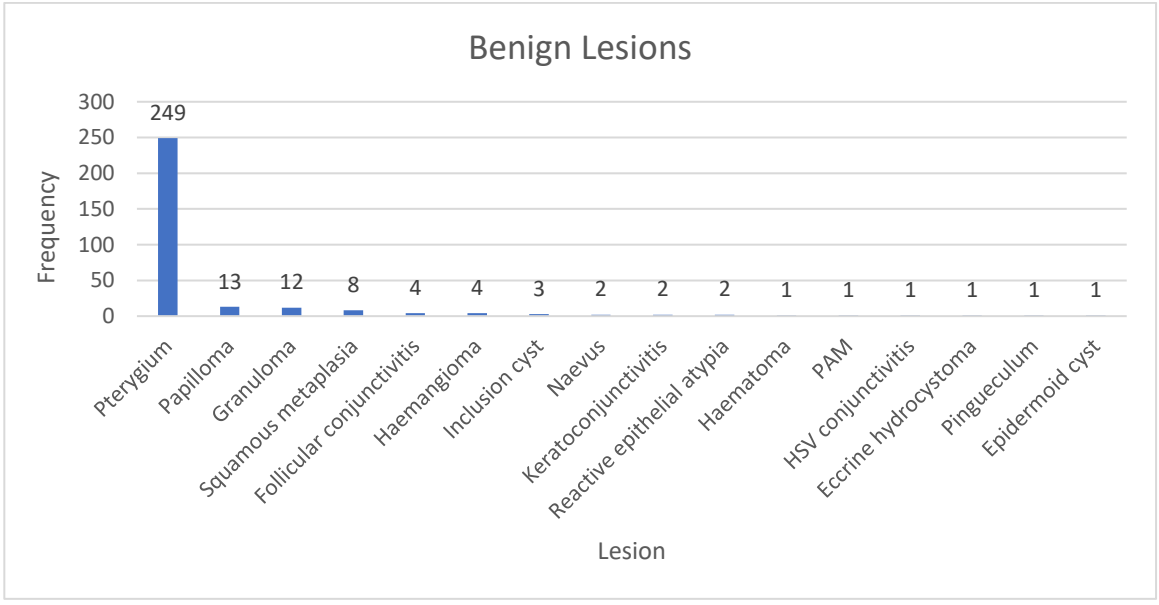

Figure 4: Benign Lesions

Premalignant lesions comprised mostly of severe CIN whilst SCC made up most of the malignancies *(figure 5 & 6)*.

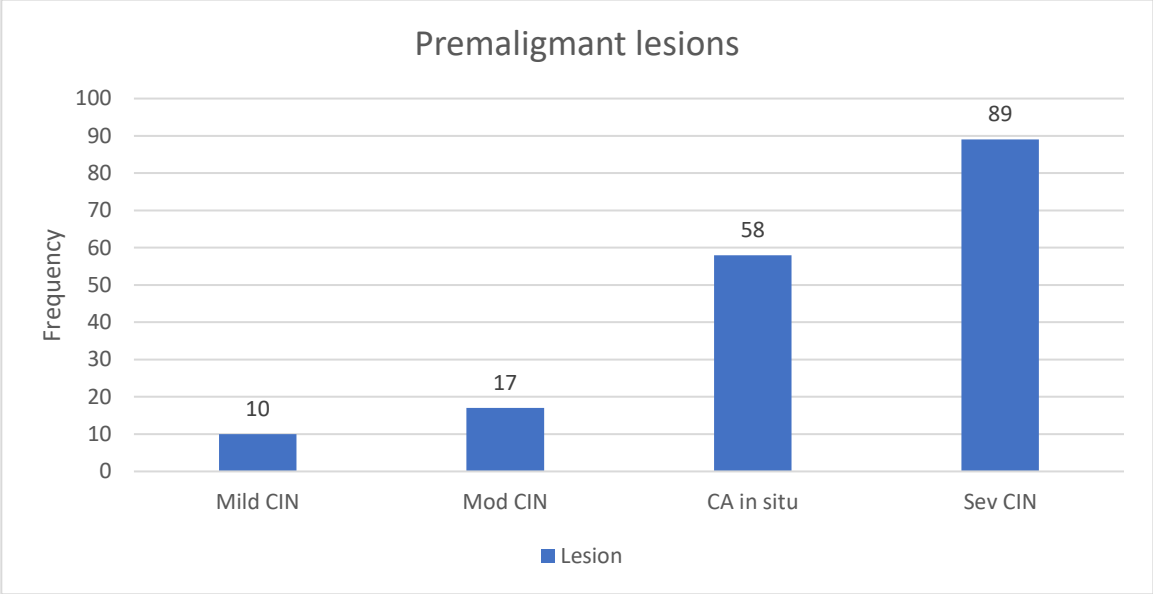

Figure 5: Premalignant lesions

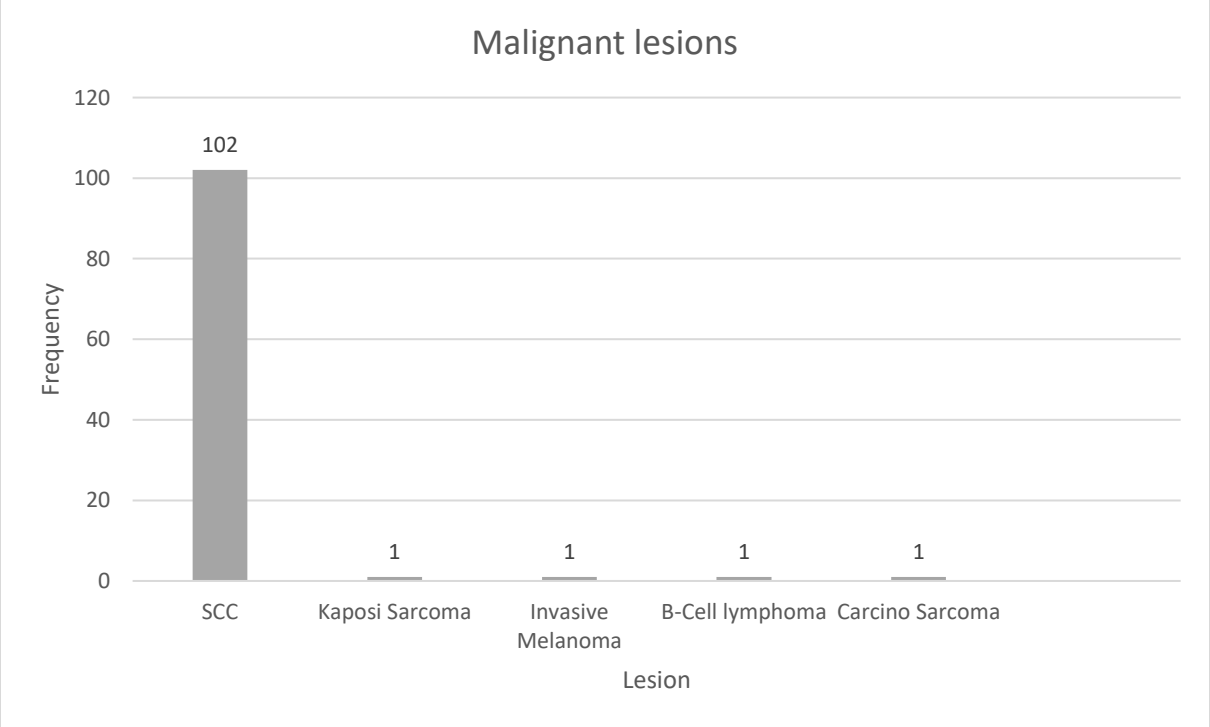

Figure 6: Malignant lesions

Pterygia were diagnosed in older individuals, followed by severe CIN and SCC which were found in slightly younger individuals *(table 6, figure 7).*

The age difference amongst pterygia, severe CIN and SCC was statistically significant (p-value=0.016 *(table 7)*

Table 6:Average age per type of lesion

Lesion	Average Age
Pterygium	46.3
SCC	41.3
Severe CIN	43.6

Table 7: Non parametric equivalent of ANOVA
Test Statistics[a,b]

	AGE
Kruskal-Wallis H	8.218
df	2
Asymp. Sig.	.016

a. Kruskal Wallis Test

b. Grouping Variable: Type of Lesion

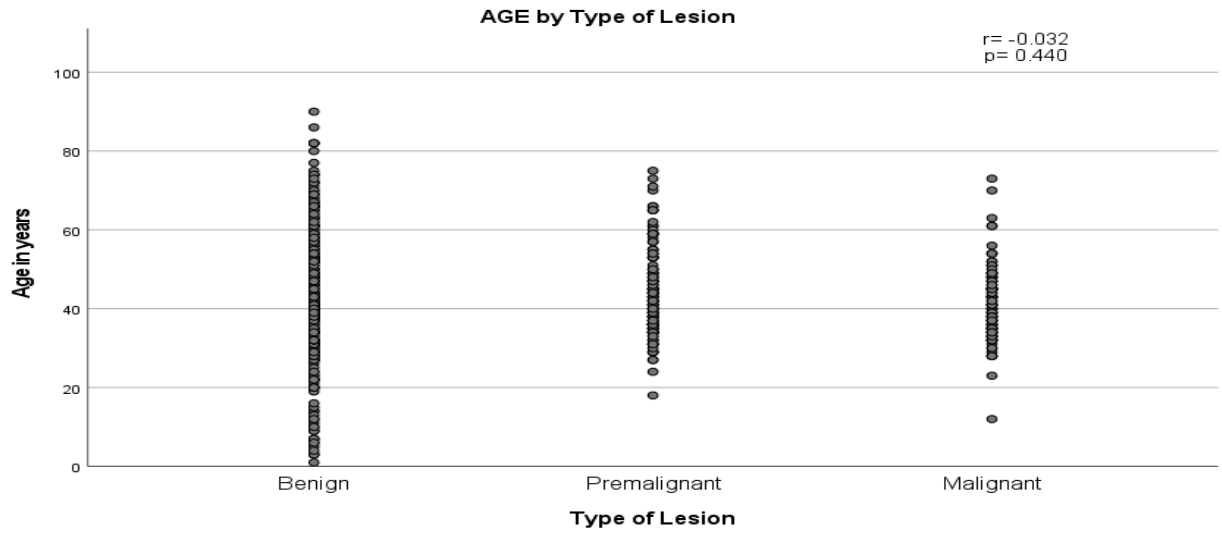

Figure 7: Age by type of lesion

In our study, benign and premalignant lesions had a slightly higher predilection for females and malignant lesions higher in males *(table 8).*This was statistically not significant *(p value=0.069)*Chi-Square Tests (*table 9)*

Table 8: Type of lesion and Sex

			M	F	Unspecified	Total
Type of Lesion	Benign lesion	Count	131	169	5	305
		% within type of lesion	43.0%	55.4%	1.6%	100.0%
	Premalignant lesion	Count	71	102	1	174
		% within type of lesion	40.8%	58.6%	0.6%	100.0%
	Malignant lesion	Count	58	48	0	106
		% within type of lesion	54.7%	45.3%	0.0%	100.0%
Total		Count	260	319	6	585
		% within type of lesion	44.4%	55.6%	1.0%	100.0%

Table 9: Chi-Square Tests

	Value	df	Asymptotic Significance (2-sided)
Pearson Chi-Square	5.355[a]	2	.069
Likelihood Ratio	5.334	2	.069
Linear-by-Linear Association	2.358	1	.125
N of Valid Cases	579		

a. 0 cells (0.0%) have expected count less than 5. The minimum expected count is 47.60.

The turnaround time for histology reports was on average slightly shorter for malignant lesions (7.7 days) even though it was not statistically significant *(tables 10,11 & 12).*

Table 10: Turnaround time per type of lesion (days)

Turnaround time per type of lesion

	N	Mean	Std. Deviation	Std. Error	95% Confidence Interval for Mean		Minimum	Maximum
					Lower Bound	Upper Bound		
Benign lesions	305	8.77	5.537	.317	8.15	9.40	1	43
Premalignant lesions	174	8.91	7.126	.540	7.85	9.98	1	75
Malignant lesions	106	7.70	4.925	.478	6.75	8.65	1	27
	585	8.62	5.963	.247	8.14	9.10	1	75

Table 11: Test of Homogeneity of Variances

		Levene Statistic	df1	df2	Sig.
Turnaround time	Based on Mean	.141	2	582	.868
	Based on Median	.214	2	582	.807
	Based on Median and with adjusted df	.214	2	493.064	.807
	Based on trimmed mean	.324	2	582	.723

Table 12: ANOVA

Turnaround time

	Sum of Squares	Df	Mean Square	F	Sig.
Between Groups	112.317	2	56.159	1.583	.206
Within Groups	20651.437	582	35.484		
Total	20763.754	584			

Discussion

The conjunctiva is exposed to UV light which makes it susceptible to a wide spectrum of pathologies. The distribution of conjunctival lesions varies in different geographic location.

In this report, 99.4% of the specimens were from black patients which is to be expected since SJEH is located in Soweto.

Pterygium was the most common conjunctival surgical biopsy finding accounting for 42,56% of all surgical biopsies performed at SJEH theatres during the 3 year study period, with a M:F of (1:1.5).The mean age was 39.5 years which was similar to studies from India and Iran.[6]Due to theatre constraints, only type 3 pterygia or those which cause significant astigmatism are eligible for excision at SJEH.

In this study, diagnoses of dysplasia occurring in the background of pterygia were recorded as CIN. A few studies are reporting on the incidence of pterygia associated with dysplasia and considering it as an entity on its own.[4] In some studies, pterygia are further subdivided into pure pterygia, pterygia associated with epithelial lesions (dysplasia/SCC)and pterygia associated with a cyst. This illustrates the importance of submitting all excised clinically diagnosed pterygia for histology as the management and follow up of dysplasia is completely different from that of a pure pterygium.

Patients with a pingueculum are treated conservatively at SJEH, hence non were reported in this study.

Histology reports for premalignant lesions were reported as either mild, moderate or severe dysplasia and 'carcinoma in situ'. The descriptive term of mild, moderate and severe CIN was used for this publication. It is important to be familiar with various nomenclature used to describe lesions of the conjunctiva. Carcinoma in situ and severe CIN essentially define similar pathologies which means severe CIN was the most common conjunctival neoplasm in our study *(figure 5)*. This is contrary to most studies in Africa and the USA which reported SCC to be the common conjunctival neoplasm.[4][7] SCC made up the bulk of malignant tumors, with a higher predilection for males at 54.7% vs. 45.3% in females. A retrospective study on :"The spectrum of conjunctival squamous cell carcinoma at SJEH" reported from NHLS between January 2007 to June 2011 by Dolland RS also reported pre-invasive OSSN as the commonest neoplasm with a high predilection for females as is the case in our study.[8] . SCC of the conjunctiva is regarded as a disease affecting older white males in Europe and the USA but our study shows a preponderance towards younger black males, in keeping with most of the reports from other African studies.[9] Pre-invasive OSSN and SCC affects younger age group in sub-Saharan countries as is the case in our study.

This is probably due to the high prevalence of HIV infection in the younger population group, which is associated with Pre-invasive OSSN and SCC.

The prevalence of benign and premalignant lesions were higher in females and malignant lesions higher in males. The plausible explanation for this could be that female patients consult earlier than their male counterpart.

At SJEH, suspicious conjunctival lesions amenable for excisional biopsy are excised with a 4mm clear margin and cryotherapy. Any patient with a histology report of severe dysplasia or SCC involving the margins will undergo a further treatment regimen of topical chemotherapy usually with 5-Fluorouracil *(5FU)* or Mitomycin-C *(MMC).* These patients are then followed up with a series of anterior segment optical coherence tomography (OCT) imaging for residual or recurrence of the neoplasm. Patients with confirmed SCC or OSSN who don't know their HIV status are referred for pre-test counselling for a holistic treatment intervention.

We identified one case of carcino-sarcoma from a 38 year old female patient who had had two previous surgical biopsies in the same eye. The first was reported as margin positive CIN in 2014. The second was margin positive high grade OSSN in 2016. Carcino-sarcoma is a rare type of malignancy that usually originates from epithelial tissue.

A case of conjunctival malignant melanoma was reported from a 54 year old HIV negative African female patient. The histology reported deep stromal invasion with involvement of the margin, PAM with atypia was present in the background. Malignant melanoma of the conjunctiva is a rare tumor occurring mostly in older White patients and up to 75% originate from PAM with atypia.[(10)]

A case of B-cell lymphoma was reported in a 46 year old black male patient. The common conjunctival lymphoma is the low-grade extra nodal B-cell lymphoma which is usually seen in patients > 60 years. Other ocular sites commonly affected include the lacrimal gland and extra ocular muscles. It is important to note that the benign and malignant lesions may have similar clinical appearance and histology assessment is the gold standard for definitive diagnosis and appropriate management. It is reported that a third of patients with conjunctival lymphomas have co-existing systemic lymphoma and an ocular diagnosis should prompt for urgent appropriate referral for a systemic work-up.[(11)]

There was one case of Kaposi Sarcoma (KS) in a 34 year old HIV positive black female patient. The tumor was involving the caruncle and bulbar conjunctiva. KS was very rare before the era of HIV/AIDS. The introduction of HAART with resultant improvent of immunity is known to promote involution of the tumor. KS of the conjunctiva can mimic a subconjunctival haemorrhage, a high level of suspicion in patients presenting with non resolving spontaneous 'subconjunctival haemorrhage' is paramount.[(10)(11)(12)]

There were a few benign cases which could have been monitored or treated conservatively with no need for surgery such as, inflammatory lesions (follicular conjunctivitis and keratoconjunctivits).

A diagnosis of tuberculosis (TB) was reported in a patient with a granuloma of the bulbar conjunctiva. This is a vital piece of information if the patient is not diagnosed with systemic or extrapulmonary TB.

The spectrum of conjunctival lesions is broad with a high incidence of premalignant and malignant lesions in our population. SCC constitutes the majority of malignant lesions affecting younger African patients in our setting. Male gender is mentioned as one of the risk factors for SCC but some studies report equal sexual distribution.[1]

The turnaround time from specimen submission to histology report was on average at least one week, which is fairly reasonable considering the overburdened state facilities and this allows for timeous appropriate intervention. Rejections were as a result of minor human errors from the submitting clinicians team that can be easily rectified for example, proper completion of laboratory request forms. Correct capturing of patient information can be improved by using laboratory stickers instead of writing the specimen reference number by hand. This will also assist in instances where the patient number is entered incorrectly since the correct specimen reference number can still be utilized for easier tracing of histology results.

This study is from a large Ophthalmology referral centre and a lot of data was collected within the study period. It is highlighting the high incidence of severe OSSN, the importance of correct data capturing and submission of all surgical biopsies.

The study is retrospective, patient's clinical assessments were unavailable to match with histology findings. There was no specific Histopathologist designated to Ophthalmology and this resulted in different nomenclature used to describe similar pathologies.

Conclusion

Lesions of the conjunctiva vary tremendously. In most instances, excisional biopsy is not only diagnostic but also therapeutic. On few occasions, life threatening systemic disease can be firstly seen in the eye and diagnosed from conjunctival surgical biopsies eg. Lymphoma, TB and Sarcoid, reiterating the importance of submitting all surgical biopsies.

Despite SJEH serving a predominantly city-based population with access to health facilities, and patients presenting with suspicious conjunctival lesions given priority for theatre, we still have a handful of patients presenting with advanced malignant disease (SCC) requiring exenteration. Aggressive health awareness campaign is needed to prevent unnecessary morbidity and mortality.

References:

1. Hassan S, Habib S, Muhammad I, et al. Morphological Spectrum of Excised Conjunctival Lesions in a Tertiary Hospital in North-Western Nigeria. Niger J Basic Clin Sci. 2020;17(1):7.
2. Lee GA, Hirst LW. Major Review. Ocular Surface Squamous Neoplasia. Surv Ophthalmol. 1995;39(6):429–50.
3. Reynolds J, Pfeiffer M, Ozgur O, et al. Prevalence and Severity of Ocular Surface Neoplasia in African Nations and Need for Early Interventions. J Ophthalmic Vis Res. 2016;11(4):415–21.
4. Lomeli-Linares D, Garcia-Salgado L, Riancho-Sanchez G et al. Frequency of Conjunctival Epithelial Dysplasia in Patients with Pterygium. Arq Bras Oftalmol. (2020) 83(4) 323-328
5. Shields CL, Shields JA. Tumors of the Conjunctiva and Cornea. Surv Ophthalmol. 2004;49(1):3–24.
6. Aliakbar-Navahi R, Ashraf MJ, Seirfar N, Koohestani S, et al. Conjunctival Lesions; A Histopathologic Review in Fars Province, Iran. J Ophthalmic Vis Res. 2015;10(2):98–101.
7. Onwubuya IM, Owoyele TM, Olaofe OO, et al. Morphological Spectrum of Orbitoocular Diseases in a Tertiary Health Centre in Keffi, North Central Nigeria. Adv Med. 2015;2015:1–5.
8. Dolland RS. The Spectrum of Conjunctival Squamous Cell carcinoma at ST John Eye Hospital. 2013;(June). MMed Wits
9. Röck T, Bartz-Schmidt KU, Bramkamp M, Milla J, et al. Clinical Management of Squamous Cell Carcinoma of the Conjunctiva. Am J Case Rep. 2020;21:8–11.
10. Honavar SG, Manjandavida FP. Tumors of the Ocular Surface: A review. Indian J Ophthalmol. 2015;63(3):187–203.
11. Bernardini FP, Bazzan M. Lymphoproliferative Disease of the Orbit. Curr Opin Ophthalmol. 2007;18(5):398–401.
12. Moraes H V. Ocular Manifestations of HIV/AIDS. Curr Opin Ophthalmol. 2002;13(6):397–403.
13. Cicinelli MV, Marchese A, Bandello F, et al. Clinical Management of Ocular Surface Squamous Neoplasia: A Review of the Current Evidence. Ophthalmol Ther [Internet]. 2018;7(2):247–62. Available from: https://doi.org/10.1007/s40123-018-0140-z

APPENDIX A: Research Protocol

Introduction....4

Literature Review....4

Study Rationale....6

Aim....7

Study Objectives....7

Hypothesis....8

Methods....8

Materials and Study Procedures....8

Data Collection....9

Data Analysis....9

Ethical Approval....10

Staff and Administration....10

Timing of Study....10

Funding....11

Limitations....11

Presentation Plans....11

Authorship....11

References....12

Histopathological Spectrum of Conjunctival Lesions at St John Eye Hospital

Introduction

The conjunctiva is readily visible, so related lesions can be recognised at a relatively early stage,[1]hence it is very important to study the spectrum of conjunctival lesions to expedite early definitive diagnosis and appropriate intervention.[1] Lesions of the conjunctiva submitted for histology include a broad spectrum of pathologic conditions ranging from benign degenerative lesions such as, pingueculae and pterygia, benign tumours such as squamous papillomas, naevi, pyogenic granulomas and dermoid cysts to premalignant tumours such as, ocular surface squamous neoplasia (OSSN), primary acquired melanosis (PAM) with atypia and aggressive malignant tumours which can result in loss of vision if diagnosed late such as squamous cell carcinoma (SCC)/ invasive OSSN, Kaposi sarcoma, malignant melanoma and lymphoma.[2]The term OSSN was first described by Lee and Hirst in 1995 to denote an entire spectrum of dysplastic, pre-invasive and malignant squamous lesions of the conjunctiva and cornea.

The conjunctiva is a specialized mucous membrane. It produces tear film which is vital for normal functioning of the eye. Unlike other membranes in the body, the conjunctiva is external and exposed to ultraviolet irradiation and infections. Ultraviolet exposure is implicated in the aetiology of pingueculae, pterygia and SCC. Most conditions of the conjunctiva can be diagnosed clinically but histological confirmation is imperative because diseases of the conjunctiva coexist and this may influence different treatment modalities. By way of illustration, cases that appear clinically as simple pterygia are at times reported with background dysplasia. The latter requires regular monitoring, which would not be otherwise necessary.

Literature Review

The distribution pattern of conjunctival lesions varies geographically as illustrated in findings of similar studies conducted in different countries. A study of 144 conjunctival biopsies by Sundeep, et al.[1] conducted in India between January 2014 to January 2015 covered an age range of 3 years – 88 years. Degenerative lesions occurred in 104 (72.2%) cases with pterygia in the majority of cases 84 (80.7%).[1] Epithelial lesions were only 14 (9.7%) cases, 6 inclusion cysts, 5 squamous cell papillomas, 2 preinvasive OSSN and only 1 SCC.[1]Melanocytic lesions were found in 7 cases, these included 5 naevi, PAM with atypia in 1 case and another without atypia.[1] Other cases were 10 vascular (all pyogenic granulomas), 6 congenital (4 dermoids and 2 dermolipomas), 1 lymphoma and 2 miscellaneous.[1]

Another study, also from India but conducted over a longer period between July 2010 to June 2013 showed almost similar results. A total of 510 conjunctival biopsies was studied, 349 (68.45%) were degenerative lesions and 65 (13%) were epithelial lesions.[2]

Shields, et al (2004) conducted a large study of conjunctival biopsy specimens of adults in America where 1643 subjects were evaluated, majority of cases (876) were classified as melanocytic and 771 as nonmelanocytic.[3]Of the 771 non-melanocytic conjunctival tumours, OSSN was the most common diagnosis in 179 tumours (23%) at a mean age of > 60 years.[3]

Ocular surface squamous neoplasia (OSSN) is the most common ocular surface tumour affecting adults in Africa. Differentiating early malignancies from benign lesions can be clinically challenging.[4]OSSN affects a younger age group in Africa, unlike in Europe and USA where it is still regarded as a disease of old white males.

A study conducted in Nigeria showed SCC to be the commonest conjunctival lesion.[5] A total of 66 cases were seen within the study period and 30 of these were OSSN. There were 14 males and 16 females. There were 13 cases of pre-invasive OSSN and 17 cases of SCC.[5]Of the benign OSSN, squamous cell papilloma was found in 9 cases, pterygia in 6 and inflammatory lesions in 4 cases.[5] The remaining cases included 2 cases each of, haemangioma, benign cyst and retinoblastoma.[5] Benign skin adnexal tumour, rhabdomyosarcoma, Kaposi sarcoma and adenoid cystic carcinoma accounted for one case each.[5] The mean age of pre-invasive OSSN was 35.8 years and for SCC 37.1 years.[5]

A retrospective study was conducted at St John Eye Hospital (SJEH) in Soweto, Johannesburg where 934 conjunctival biopsies were received and analysed at the Histopathology Department of the National Health Laboratory Services (NHLS) between January 2007 and June 2011.[6] OSSN was diagnosed in 185 biopsies. The median age of 32.9 years and there were 119 (65.0%) females and 64 (35.0%) males.[6] Mild conjunctival intraepithelial neoplasia (CIN) was reported in 26 (14.1%) cases, moderate CIN in 54 (29.2%) cases, carcinoma in-situ in 87 (47.0%) cases and invasive OSSN/SCC in 18 (9.7%) cases.[6]

In stark contrast to most reports from studies in Africa is a study by Elshazly conducted in Egypt where 192 conjunctival specimens were collected over a period of ten years.[7] Males accounted for 106 cases and females for 86 cases.[6] Pyogenic granuloma was the most common finding (30.7%) followed by benign pigmented lesions (22.9%). Benign cystic lesions accounted for 12% of cases. OSSN was found in only 10.9% (21 cases) with a slightly older mean age of 45.9 years.[7] Other less common lesions included haemangioma (7.8%), lipoma (4.2%), papilloma (2.5%), benign lymphoid hyperplasia (2.1%), dermoid cyst (1.6%).[7]Pterygia were excluded from this study as they were not submitted for histology.[7]

The incidence of OSSN is higher in regions of tropical climate, for example, the incidence in Australia was reported to be as high as 19/million people/year[8], Uganda 12/million people/year,[8] compared to the United States with only 0.3 to 8.4/million people/year.[8]

The incidence of OSSN is on the increase in Africa, for example, in Uganda, the incidence was 6/million people/year between 1970 and 1988, then followed by a trajectory increase to 35/million people/year.[9]

In vivo staining with dyes like toluidine blue can be utilized for screening. It has high sensitivity (92%) but low specificity (31%), hence a high frequency of false positives. The high negative predictive value suggests that a negative staining result indicates that OSSN is relatively unlikely. This can be useful in patients refusing surgical excision.[10]Toluidine blue is available in our local laboratories (NHLS) for use in pathology specimens but it is not yet used in our ophthalmology units for screening of OSSN.

Anterior segment imaging is vital in the preoperative assessment of OSSN. Ultrasound biomicroscopy (UBM) can be performed to evaluate for intraocular tumour invasion, which will aid the treating clinician to decide on the type of biopsy to undertake. At St John Eye Hospital, optical coherence tomogram (OCT) is used to assess subtle or suspicious conjunctival lesions. It is also used in the follow up of patients on topical chemotherapy (5-fluorouracil) for OSSN, including patients with a histological diagnosis of SCC without clear margins or those patients with recurrent OSSN.

The sensitivity and specificity of high resolution OCT for differentiating between OSSN and pterygia was found to be 94% and 100% respectively in a study by Kieval, et al.[11]

The study previously conducted at St John Eye Hospital by Dolland focused on OSSN[6]. This study will be on all conjunctival surgical biopsies performed at St John Eye Hospital over the specified period.

Study Rationale

One of the challenges facing clinicians managing conjunctival lesions is distinguishing early neoplastic from benign lesions.[3]Histopathology is necessary to confirm the diagnosis of benign, premalignant or malignant conjunctival lesions. Pathology services are generally scarce in Africa outside urban areas. As a result, many lesions are excised without histological analysis.[3]

In Africa OSSN and SCC present at a much younger age. They are the most common excised conjunctival lesions. Early diagnosis is important for best treatment outcome. This is unfortunately not always possible due to shortage of both ophthalmology and laboratory services in most parts of Africa.

The incidence of OSSN is increasing in sub-Saharan Africa, and there are very few studies if any on conjunctival surgical biopsies in South Africa. Pubmed search on spectrum of excised conjunctival lesions in South Africa found only two published reports on OSSN and SCC, no reports on the histopathological spectrum of conjunctival lesions. Degenerative lesions such as pingueculae and pterygia are also very common in sub-Saharan Africa and can lead to life changing visual morbidities if not treated appropriately.

Aim

The purpose of this study is to determine the spectrum of histopathologic findings in conjunctival lesions from patients at St John Eye Hospital.

Study Objectives

Primary objectives :

- To describe and compare the spectrum of different conjunctival lesions found on histology at SJEH.
- To describe the demographics (age and sex) of patients who present with conjunctival lesions and undergo surgical biopsies at SJEH.

Secondary objectives

- To describe which conjunctival surgical biopsies are submitted for histology assessment at SJEH.
- To establish if all conjunctival specimens submitted for histology at SJEH are reported from the laboratory (NHLS).
- To describe the ‘ turnaround ‘ time of histology reports from day of specimen submission.

Hypothesis

Pterygia are the commonest benign lesions, while OSSN (encompassing dysplastic, pre-invasive and SCC) is the commonest malignant (and pre-malignant) conjunctival surgical biopsy performed at St John Eye Hospital.

Methods

Study design

A retrospective audit will be conducted at St John Eye Hospital.

Study population

All surgical cases entered in the St John Eye Hospital theatre register as conjunctival surgical biopsies from 1st November 2016 to 31st October 2019 totalling approximately 500 cases in the 3-year study period. This will include cases recorded as conjunctival lesion, mass or growth and also those entered with a clinical diagnosis such as, pterygium, pinguecula or suspicious conjunctival mass.

Surgical cases with missing data such as age or sex will not be excluded from the study.

Materials and Study Procedures

Site of study

The main register of St John Eye Hospital which covers three theatres will be used to retrieve records of all patients who underwent conjunctival surgical biopsies from 1stNovember 2016 to 31stOctober 2019. All surgical cases including biopsies at SJEH are handwritten in the theatre register.

The theatre records will be used to retrieve histology reports from NHLS at Chris Hani Baragwanath Academic Hospital.

Data collection

Cases will be obtained from SJEH theatre register records for a period of 3 years, from 1st November 2016 to 31st October 2019. An average of 15 surgical conjunctival biopsies are undertaken per month at SJEH, so an analysis of approximately 540 cases will be done in the study period.

A spread-sheet for data capture of conjunctival surgical biopsies with the following parameters will be drawn from theatre records:

- Patient hospital number
- Age of the patient
- Sex of the patient
- Date of surgery (excision/incision)
- Laterality (right or left eye)

The theatre data capture spreadsheet will be stored on a password-protected computer and will only be accessible to the investigator and supervisor.

Each theatre case will be assigned a research theatre reference number, eg. T1601 (T= theatre, 16= year and 01 for patient number 1). Names, date of birth, date of surgery and official hospital numbers will not appear on the study datasheet in view of ethical considerations.

The patient hospital number will be linked with laboratory barcode numbers and the following parameters:

- Laboratory number
- Date of laboratory specimen registration
- Date histology report is made available

Laboratory data such as laboratory number and barcode will be stored on a password-protected computer and will only be accessible to the investigator and supervisor.

Patients will be assigned a research laboratory reference number, names and official laboratory numbers will not appear on the study datasheet in view of ethical considerations, eg. L1601

Data analysis

The data analysis will be done in conjunction with the Statistics Department at the University of the Witwatersrand. Data of surgical conjunctival biopsies during the prescribed study period will be transcribed from the theatre register.

I will report the proportion of various histologic diagnoses of conjunctival biopsies. Proportions will be presented as percentages with 95% confidence intervals. Symmetrically distributed data will be expressed as a mean with standard deviation and non-symmetrically distributed data will be expressed as a median and interquartile range.

Chi squared test (x^2) will be used to analyse difference in proportions between categorical variables such as, sex, laterality and location (nasal/temporal). The Students *t*- test and analysis of variance test (ANOVA) will be used where appropriate to analyse continuous variables such as age. A *P*-value of 0.05 or less, will be considered statistically significant.

Ethical Approval

An ethics application will be submitted to the Human Research Ethics Committee of the University of Witwatersrand by October 2019. Approval from the Postgraduate Committee will be obtained before proceeding with data collection

The following ethical considerations will be made:

1. This is a retrospective audit of conjunctival surgical biopsies.
2. Data will be extracted from theatre register and NHLS. Patient names, hospital number, laboratory number, date of birth and date of surgery will be withheld from the study datasheet and each patient will be assigned a research reference number.
3. No contact with patients. They will remain anonymous.
4. The data capture spreadsheet will be stored on a password-protected computer and will only be accessible to the investigator and supervisor.

Permission for the use of data from St John Eye Hospital theatre records and NHLS will be obtained from the Superintendant of CHBAH, including consent from the Head of Department (HoD) at SJEH and the HoD of Anatomical Pathology at the University of the Witwatersrand and NHLS.

Staff and administration

The study will be carried out by Dr T Mofokeng, a registrar from the Department of Ophthalmology, University of the Witwatersrand. The study will be supervised by Dr N Welsh, Head of Clinical Unit from the Division of Ophthalmology, Department of Neurosciences at Charlotte Maxeke Johannesburg Academic Hospital.

Timing of study

The study will commence as soon as the protocol has been accepted by the postgraduate assessor committee and ethics approval has been obtained. The study is expected to last six months.

2019-2020	Aug	Sep	Oct	Nov	Dec	Jan	Feb	Mar	Apr	May	
Protocol preparation											
Ethics submission											
Protocol submission											
Protocol presentation											
Data collection											
Data analysis											
Research write-up											
Research submission											

Funding

All data that will be collected for this study are already available in the theatre register and on the NHLS database. There will be no extra costs for this study other than that of printing which will be funded by the researcher.

Limitations

Incorrect entry of surgical cases in theatre register can occur. This study will help to highlight such errors.

Presentation Plans

1. Present at departmental research day
2. Present at annual congress (Ophthalmology Society of South Africa)
3. Submission as MMed project
4. Publish in a Wits accredited scientific journal – The African Vision and Eye Health

Authorship

Dr T Mofokeng (First Author)
Dr N. Welsh (Research Supervisor)

References

1. Sundeep, Vinutha BV, Nivenditha H, et al. Clinical Profile of Conjunctival Lesions: A Prospective Study. Int J Sci Stud 2016;3(12) 5.

2. Donna Glens Mary M, Suguna BV, Geethamani V. Histopathological Spectrum of Lesions in Conjunctiva. Indian J Appl Res 2016;6(3) 377-379.

3. Shields CL, Demirci H, Karatza E, et al. Clinical survey of 1643 melanocytic and nonmelanocytic conjuctival tumors. Ophthalmol 2004;111: 1747-54.

4. Nguena MB, Van den Tweel JG, Makupa W, et al. Diagnosing Ocular Surface Squamous Neoplasia in East Africa. Ophthalmol 2014;121:484-491.

5. Ifeyinwa MO, Tunde MO, Olaejirendi OO, et al. Morphological Spectrum of Orbitoocular Diseases in a Tertiary Health centre in Keffi, North Central Nigeria. Advances in Medicine 2015; Article ID 619414, 5 pages.

6. Dolland RS. The Spectrum of Conjunctival Squamous Cell Carcinoma at St John Eye Hospital. MMed research report, University of the Witwatersrand, June 2013.

7. Elshazly LHM. A Clinicopathologic Study of Excised Conjunctival Lesions. Middle East Afr J Ophthalmol 2011;18(1) 48-54.

8. Sayed-Ahmed IO, Palioura S, Galor A, et al. Diagnosing and Medical Management of Ocular Surface Squamous Neoplasia. Expert Rev Ophthalmol.2017; 12(1):11-19.

9. Ateenyi-Agaba C. Conjunctival squamous cell carcinoma associated with HIV infection in Kampala, Uganda. Lancet 1995;345:695-698.

10. Gichuhi S, Macharia E, Kabiru J, et al. Toluidine Blue 0.05% Vital Staining for the Diagnosis of Ocular Surface Squamous Neoplasia in Kenya. JAMA Ophthalmol 2015;133(11):13114-21.

11. Kieval JZ, Karp CL, Shousha MA, et al. Ultra-high resolution optical coherence tomography for differentiation of ocular surface squamous neoplasia and pterygia. Ophthalmol 2012;119(3):481-486.

Appendix

Data spreadsheet

Patient no.	Age	Sex	Date of surgery	laterality	Lab. no.	Date specimen received	Date specimen reported	Histology diagnoses

NATIONAL HEALTH LABORATORY SERVICE
UNIVERSITY OF THE WITWATERSRAND – JOHANNESBURG

UNIVERSITY OF THE WITWATERSRAND, JOHANNESBURG

SCHOOL OF PATHOLOGY
Division of Anatomical Pathology

NATIONAL HEALTH LABORATORY SERVICE

P.O. Box 1038, Johannesburg 2000
Tel : +27-11-489-8477
+27-11- 489-8479
Fax::+27-11-489-8512

Division of Anatomical Pathology
Faculty of Health Sciences
York Road
Parktown e-mail : Yvonne.perner@nhls.ac.za

Dr Y Perner MBBCh (Witwatersrand) FCPath (SA); MMed (Witwatersrand)

Human Research Ethics Committee (Medical)
University of the Witwatersrand
Johannesburg
20000

November 5, 2019

Re: Consent for access to NHLS database

This letter serves to confirm that the Department of Anatomical Pathology at the University of the Witwatersrand and NHLS is happy to assist Dr Thabiso Mofokeng with his research entitled "Histopathological spectrum of conjunctival lesions at St John Eye Hospital".

Publication of such work is encouraged and in the event that the information used comprises the diagnosis only then joint authorship from a member of staff in the Department of Anatomical Pathology would not be expected. However, should additional information be extracted from the report for purposes of further interpretation such as morphological details and immunohistochemical profiles, it would be expected that this would be done in conjunction with a member of staff in the Department of Anatomical Pathology and that joint authorship would follow in resulting publications. Dr Mofokeng will be in contact with the Department of Anatomical Pathology in respect of this.

Assuring you of the Department of Anatomical Pathology's co-operation in this and future research projects.

With best wishes.

Yours sincerely,

Dr Yvonne Perner
Head: Department of Anatomical Pathology

GAUTENG PROVINCE
HEALTH
REPUBLIC OF SOUTH AFRICA

MEDICAL ADVISORY COMMITTEE

CHRIS HANI BARAGWANATH ACADEMIC HOSPITAL

PERMISSION TO CONDUCT RESEARCH

Date: 30th September 2019

TITLE OF PROJECT:

Histopathological spectrum of conjuctival lesions at St John Eye Hospital.

UNIVERSITY: Witswatersrand

Principal Investigator: Dr Thabiso Mofokeng

Department: Ophthalmology

Supervisor : Dr N Welsh

Permission Head Department (where research conducted): Yes

The Medical Advisory Committee recommends that the said research be conducted at Chris Hani Baragwanath Academic Hospital. The CEO / management of Chris Hani Baragwanath Academic Hospital is accordingly informed and the study is subject to:-

- **Permission having been granted by the Committee for Research on Human Subjects of the University of the Witwatersrand.**
- The Hospital will not incur extra costs as a result of the research being conducted on its patients within the hospital
- The MAC will be informed of any serious adverse events as soon as they occur
- Permission is granted for the duration of the Ethics Committee Approval.

Recommended
(On behalf of the MAC)
Date: 30/9/2019

Approved/~~Not Approved~~
Hospital Management
Date: 03/10/2019

Consent to Allow for Collection of Data for the Purposes of Research

To whom it may concern,

This document hereby serves as permission for Dr. Thabiso Mofokeng, student number 2286225, to collect the relevant data needed to complete the research intended under the title:

Histopathological Spectrum of Conjunctival Lesions at St John Eye Hospital

Data will be collected in both the Ophthalmology department as well as the National Health Laboratory Services of the Chris Hani Baragwanath Academic Hospital (CHBAH).

Data that would be needed for this study:

- All surgical conjunctival biopsies conducted at St John Eye Hospital theatres between November 2016 to November 2019.

All data will be collected in a retrospective manner as per the submitted protocol, and will remain strictly confidential to the author. All data collection will be performed after approval by the Human Research Ethics Committee of the University of the Witwatersrand.

The intended research will be fully funded by the applicant and will not interfere with the daily running of the hospital or hospital equipment.

Head of Department Ophthalmology CHBAH

Name..... Ismail Mayet ..... Date..... 26/9/2019 .....

Signature.....

UNIVERSITY OF THE
WITWATERSRAND,
JOHANNESBURG

R14/49 Dr T Mofokeng

HUMAN RESEARCH ETHICS COMMITTEE (MEDICAL)
CLEARANCE CERTIFICATE NO. M191069

NAME: (Principal Investigator)	Dr T Mofokeng
DEPARTMENT:	School of Clinical Medicine Department of Neurosciences Division of Opthalmology Charlotte Maxeke Johannesburg Academic Hospital
PROJECT TITLE:	Histopathological spectrum of conjunctival lesions at St John Eye Hospital
DATE CONSIDERED:	2019/10/25
DECISION:	Approved unconditionally
CONDITIONS:	
SUPERVISOR:	Dr N Welsh
APPROVED BY:	Dr CB Penny, Chairperson, HREC (Medical)
DATE OF APPROVAL:	2019/11/14

This clearance certificate is valid for 5 years from date of approval. Extension may be applied for.

DECLARATION OF INVESTIGATORS

To be completed in duplicate and **ONE COPY** returned to the Research Office Secretary on the 3rd Floor, Phillip Tobias Building, Parktown, University of the Witwatersrand, Johannesburg.

I/we fully understand the conditions under which I am/we are authorized to carry out the above-mentioned research and I/we undertake to ensure compliance with these conditions. Should any departure be contemplated, from the research protocol as approved, I/we undertake to submit details to the Committee. **I agree to submit a yearly progress report**. When a funder requires annual re-certification, the application date will be one year after the date when the study was initially reviewed. In this case, the study was initially reviewed in **October** and will therefore reports and re-certification will be due early in the month of **October** each year. Unreported changes to the application may invalidate the clearance given by the HREC (Medical).

Principal Investigator Signature

Date

PLEASE QUOTE THE CLEARANCE CERTIFICATE NUMBER IN ALL ENQUIRIES

MMed Write-up TURNITIN.docx

by Lieschen Branders

Submission date: 24-Feb-2023 06:34PM (UTC+0200)
Submission ID: 2022112859
File name: MMed_Write-up_TURNITIN.docx (554.45K)
Word count: 2452
Character count: 13320

Histopathological Spectrum of Conjunctival Lesions at St John Eye Hospital

Primary Author: Dr Thabiso Mofokeng; MBChB (Natal), Dip Ophth (SA), FC Ophth (SA) Candidate: MMed (Ophthalmology)

Supervisor: Dr Nicole Welsh; MBChB (UCT), MMed (Wits) (Ophth), FC Ophth (SA)

I, Thabiso Mofokeng student number 2286225, registered for the degree of Master of Medicine in Ophthalmology, declare that the work submitted for assessment of the above degree is my own unaided work except where I have explicitly stated otherwise.

This research report is dedicated to my 92-year-old maternal grandmother, Mrs. Selina Sonile Mofokeng, who single handedly afforded me education all the way up to University without any formal employment.

Mme, I will forever be grateful.

Various non-invasive modalities have been described in diagnosing conjunctival lesions but histology remains the gold standard. Shortages in ophthalmology services and pathology laboratories in non-urban areas is one of the main reasons for delayed presentation and appropriate treatment in sub-Saharan Africa. The purpose of this study is to determine the spectrum of histopathologic findings in conjunctival lesions from patients at St John Eye Hospital (SJEH).

Data of patients who underwent conjunctival surgical biopsies was retrieved from the main theatre register of SJEH for a period of 3 years, starting from 1st November 2016 to 31st October 2019. This data was used to retrieve histology reports from National Health Laboratory Services (NHLS).

A total of 679 patient records were retrieved from the theatre register, only 585 histology reports from 584 patients could be analysed. There were 305 benign lesions with pterygia making up most of the benign lesions with a total of 249 (42.56%). A total of 174 premalignant lesions were recorded with severe ocular surface squamous neoplasia (OSSN) making up the bulk of premalignant lesions, 147/174(84.48%). Squamous cell carcinoma (SCC) was the main malignant lesion, 102 reported cases of a total 106 malignant lesions.

The age ranged from 1 to 90 years with mean of 43.14 years. The patients were predominantly black, Caucasians constituted only 1%. The average age for SCC was 41.3 years, severe OSSN 43.6 and pterygia 46.3 years.

Benign and premalignant lesions had a slightly higher predilection for females at 55.4% and 58.6% respectively.

Males had a slightly higher predilection of malignancy at 54.7%.

Pterygia are the most common excised benign conjunctival lesions and severe OSSN is the most common premalignant lesion excised at SJEH. SCC made up the bulk of conjunctival malignancies excised at SJEH. Pterygia, OSSN and SCC presents in a significantly younger age group when compared with reports from Europe, North and South America.

Acknowledgements

1. Dr N Welsh for her invaluable guidance and advise in finishing this project successfully
2. Prof Mayet for giving me permission to access SJEH theatre records
3. Dr Y Perner for giving me permission to access NHLS records
4. Ms Hlengiwe Selowa assisting with data analysis

Lesions of the conjunctiva submitted for histology include a broad spectrum of pathologic conditions ranging from benign, non-neoplastic degenerative lesions such as pterygia and pingueculae, benign neoplastic tumors for example, squamous papilloma, premalignant tumors for instance, OSSN and Primary Acquired Melanosis (PAM) with atypia, to aggressive malignant tumors such as SCC/invasive OSSN, Kaposi Sarcoma (KS), malignant melanoma and lymphoma which can result in vision loss and sometimes fatality if diagnosed late.[1]

The term OSSN was first described by Lee and Hirst in 1995 to denote an entire spectrum of dysplastic, pre-invasive and malignant squamous lesions that originate from the epithelium of the cornea or conjunctiva.[2]
Conjunctival lesions can be classified into, melanocytic and non-melanocytic, neoplastic and non-neoplastic, or broadly divided into benign, pre-malignant and malignant lesions.[1]

The distribution pattern of conjunctival lesions varies geographically. OSSN and pterygia are the most common conjunctival lesions submitted for histological diagnosis in sub-Saharan Africa. OSSN affects a younger age group in Africa unlike in Europe and the USA where it is still regarded as a disease of older white males. Differentiating early malignancies from benign lesions can be clinically challenging, hence it is important to send all excised lesions for histological diagnosis.[3]A study conducted at an Ophthalmology referral unit in Central Mexico where 177 pterygia underwent surgical biopsies over a 2 year period showed OSSN in 11.29% (n=20).[4]

Tissue diagnosis remains the gold standard for definitive diagnosis of conjunctival lesions.

The two surgical biopsy methods include, incisional biopsy reserved for extensive suspicious tumours that are symptomatic,[5] or showing evidence of invading the globe on imaging. The other is excisional biopsy, more commonly performed and is appropriate for smaller tumours (≤4 clock hours limbal tumour or ≤15 mm basal diameter) that are symptomatic or suspected to be malignant.[5]

This is a retrospective study of conjunctival surgical biopsies submitted for histology at St John Eye Hospital (SJEH) theatres during a 3 year period from 1st November 2016 to 31st October 2019. All specimens were submitted to the National Health Laboratory Services (NHLS) histopathology department at the Chris Hani Baragwanath Academic Hospital (CHBAH) based in Soweto for histological analysis. The main register of SJEH which covers three theatres was used to retrieve records of all patients who underwent conjunctival surgical biopsies during the set study period. Patients's demographic information and histopathological diagnoses were retrieved from original biopsy reports. Permission to collect data was given by the Head of Departments (HOD's) at SJEH and NHLS. Approval from the Human Research Ethics Committee (HREC) and the Post Graduate Committee of the University of Witwatersrand was obtained.

Frequencies of the different types of conjunctival lesions was reported.

The age of the patients for different lesions was categorized and descriptives of mean, minimum and maximum provided. Kruskal Wallis Test was used to determine correlation between age and type of lesion. Anova and Levene statistic tests were used to determine correlation of turnaround time between different lesions.

A total of 679 conjunctival biopsies from 678 patients were entered in the SJEH theatre main register from 1st November 2016 to 31st October 2019. Of these, 585 histology reports from 584 patients were retrieved from NHLS. Ninety five theatre entries were not included in the histopathology analysis due to various reasons

Status	Frequency
Incomplete Details	32
Incorrect Details	10
Mismatch forms	1
No px no on request form	1
No Records	32
Rejected/incomplete	4
Specimen & Request mismatch	1
Tissue lost in the lab	1
Wrong Details	1
Wrong Entry	12
Total	95

Data from theatre comprised 297 males, 375 females and 6 patients where the gender was not specified *(table 2, figure 1)*. Only 4 patients were white and the rest were black *(table 3,* no other races were recorded.

	Frequency	Percent
M	297	43.7
F	375	55.2
Unspecified	6	1.0
Total	678	100.0

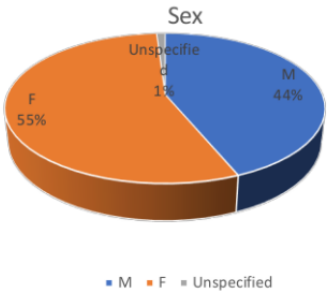

	Frequency	Percent
Black	675	99.4
White	4	0.6
Total	679	100.0

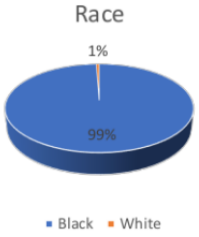

Age distribution captured in years ranged from 1 to 90 years and was not stated in 9 patients

Table 4: Age

Age group	Frequency	Percent
0-17	28	4
18-29	58	8.7
30-49	394	58.9
50-69	154	23
70+	36	5.4
Total	670	100

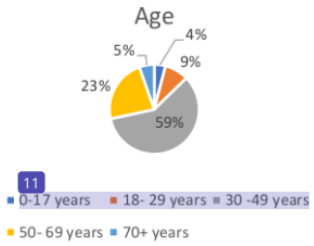

Benign lesions accounted for 305 cases with pterygium being the most common (249) *(figure 4)*, premalignant 174 cases and malignant 106 cases.

Premalignant lesions comprised mostly of severe OSSN whilst SCC made up most of the malignancies.

	Frequency	Percent
Benign lesion	305	52.1
Premalignant lesion	174	29.7
Malignant lesion	106	18.1
Total	585	100.0

585 histology reports were retrieved from 584 patients with 1 patient undergoing biopsies in each eye, histology reported SCC on the right eye and severe CIN on the left.

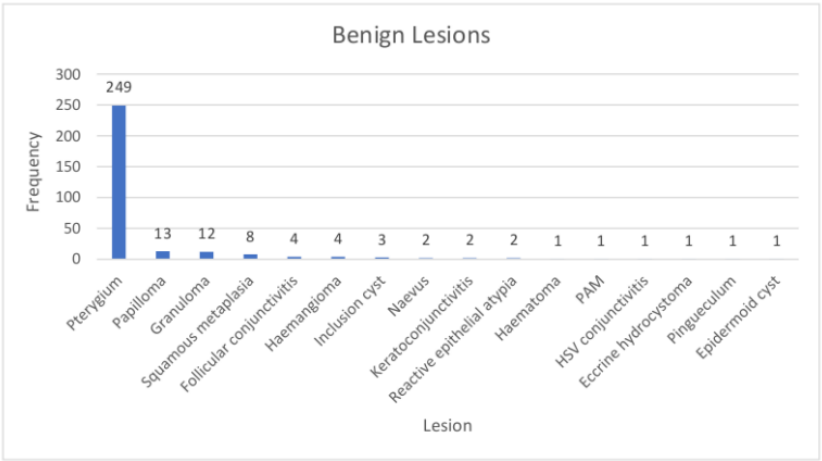

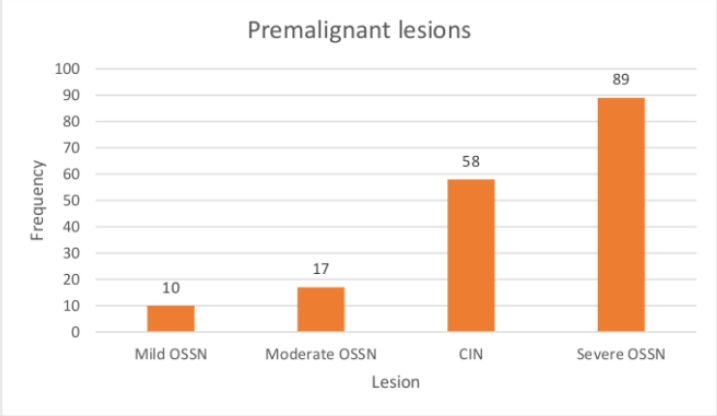

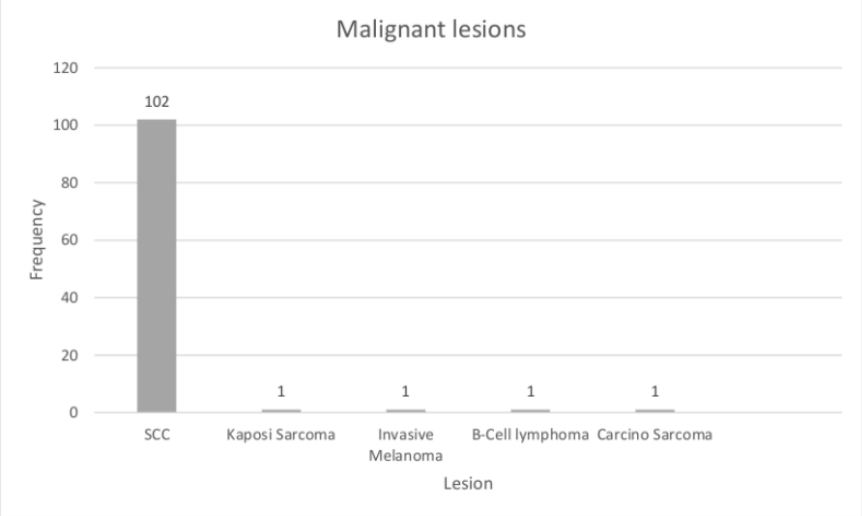

Pterygia were diagnosed in older individuals, The age difference amongst pterygia, severe

4

followed by severe OSSN and SCC which were found in slightly younger individuals

OSSN and SCC was statistically significant (p-value=0.016)

6	AGE
Kruskal-Wallis H	8.218
Df	2
Asymp Sig	0.016

a. Kruskal-Wallis Test

b. Grouping variable: Type of lesion

In our study, benign and premalignant lesions Had a slightly higher predilection for females and malignant lesions higher in males *(table 8)*

Lesion	Average Age
Pterygium	46.3
SCC	41.3
Severe OSSN	43.6

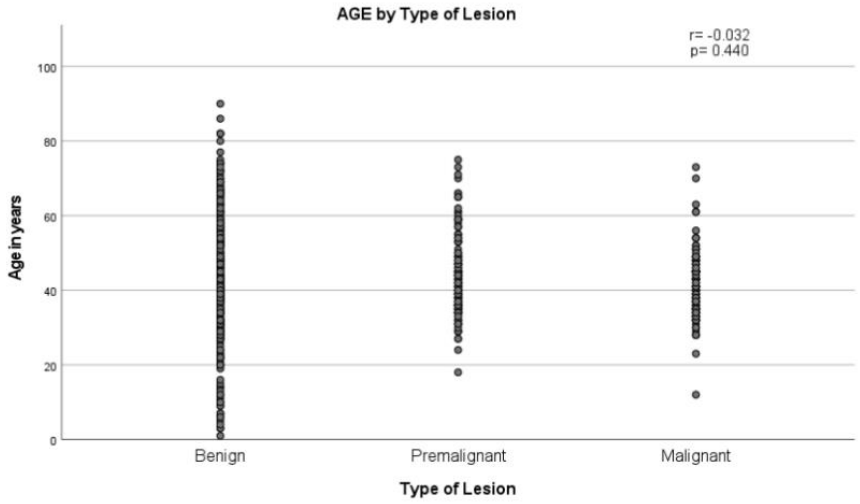

5

			M	F	Unspecified	Total
Type of Lesion	Benign lesion	Count	131	169	5	305
		% within type of lesion	43.0%	55.4%	1.6%	100.0%
	Premalignant lesion	Count	71	102	1	174
		% within type of lesion	40.8%	58.6%	0.6%	100.0%
	Malignant lesion	Count	58	48	0	106
		% within type of lesion	54.7%	45.3%	0.0%	100.0%
Total		Count	260	319	6	585
		% within type of lesion	44.4%	55.6%	1.0%	100.0%

The turnaround time for histology reports was on average slightly shorter for malignant lesions (7.7 days) even though it was not statistically significant

	N	Mean	Std. Deviation	Std. Error	95% Confidence Interval for Mean		Minimum	Maximum
					Lower Bound	Upper Bound		
Benign lesions	305	8.77	5.537	.317	8.15	9.40	1	43
Premalignant lesions	174	8.91	7.126	.540	7.85	9.98	1	75
Malignant lesions	106	7.70	4.925	.478	6.75	8.65	1	27
Total	585	8.62	5.963	.247	8.14	9.10	1	75

6

		Levene Statistic	df1	df2	Sig.
Turnaround time	Based on Mean	.141	2	582	.868
	Based on Median	.214	2	582	.807
	Based on Median and with adjusted df	.214	2	493.064	.807
	Based on trimmed mean	.324	2	582	.723

	Sum of Squares	Df	Mean Square	F	Sig.
Between Groups	112.317	2	56.159	1.583	.206
Within Groups	20651.437	582	35.484		
Total	20763.754	584			

In this report, 99.4% of the specimens were from black patients which is to be expected since SJEH is located in Soweto.

Pterygium was the most common conjunctival surgical biopsy finding accounting for 42,56% of all surgical biopsies performed at SJEH theatres during the 3 year study period, with a M:F of (1:1.5).

The average age was 46.3 years which was similar to studies from India and Iran.[6]

Due to theatre constraints, only type 3 pterygia or those which cause significant astigmatism are eligible for excision at SJEH.

In this study, diagnoses of dysplasia occurring in the background of pterygia were recorded as OSSN.

A few studies are reporting on the incidence of pterygia associated with dysplasia and considering it as an entity on its own.[4] In some studies, pterygia are further subdivided into pure pterygia, pterygia associated with epithelial lesions (dysplasia/SCC)and pterygia associated with a cyst. This illustrates the importance of submitting all excised clinically diagnosed pterygia for histology as the management and follow up of dysplasia is completely different from that of a pure pterygium.

Patients with a pingueculum are treated conservatively at SJEH, hence non were reported in this study.

Histology reports for premalignant lesions were reported as either mild, moderate or severe dysplasia and 'carcinoma in situ'

(CIN). The descriptive term of OSSN was used for this publication. It is important to be familiar with various nomenclature used to describe lesions of the conjunctiva. CIN and severe OSSN essentially define similar pathologies which means severe OSSN was the most common conjunctival neoplasm in our study *(figure 5)*. This is contrary to most studies in Africa and the USA which reported SCC to be the common conjunctival neoplasm.[4][7] SCC made up the bulk of malignant tumors, with a higher predilection for males at 54.7% vs. 45.3% in females. A retrospective study on :"The spectrum of conjunctival squamous cell carcinoma at SJEH" reported from NHLS between January 2007 to June 2011 by Dolland RS also reported OSSN as the commonest neoplasm with a high predilection for females as is the case in our study.[8] . SCC of the conjunctiva is regarded as a disease affecting older white males in Europe and the USA but our study shows a preponderance towards younger black males, in keeping with most of the reports from other African studies.[9] OSSN and SCC affects younger age group in sub-Saharan countries as is the case in our study. This is probably due to the high prevalence of HIV infection in the younger population group, which is associated with OSSN and SCC. The prevalence of benign and premalignant lesions were higher in females and malignant lesions higher in males. The plausible explanation for this could be that female patients consult earlier than their male counterpart.

At SJEH, suspicious conjunctival lesions amenable for excisional biopsy are excised with a 4mm clear margin and cryotherapy.

Any patient with a histology report of severe dysplasia or SCC involving the margins will undergo a further treatment regimen of topical chemotherapy usually with 5-Fluorouracil *(5FU)* or Mitomycin-C *(MMC)*. These patients are then followed up with a series of anterior segment optical coherence tomography (OCT) imaging for residual or recurrence of the neoplasm.

Patients with confirmed SCC or OSSN who don't know their HIV status are referred for pre-test counselling for a holistic treatment intervention.

We identified one case of carcino-sarcoma from a 38 year old female patient who had had two previous surgical biopsies in the same eye. The first was reported as margin positive CIN in 2014. The second was margin positive high grade OSSN in 2016. Carcino-sarcoma is a rare type of malignancy that usually originates from epithelial tissue.

A case of conjunctival malignant melanoma was reported from a 54 year old HIV negative African female patient. The histology reported deep stromal invasion with involvement of the margin, PAM with atypia was present in the background.

Malignant melanoma of the conjunctiva is a rare tumor occurring mostly in older White patients and up to 75% originate from PAM with atypia.[10]

A case of B-cell lymphoma was reported in a 46 year old black male patient. The common conjunctival lymphoma is the low-grade extra nodal B-cell lymphoma which is usually seen in patients > 60 years. Other ocular sites commonly affected include the

lacrimal gland and extra ocular muscles. It is important to note that the benign and malignant lesions may have similar clinical appearance and histology assessment is the gold standard for definitive diagnosis and appropriate management. It is reported that a third of patients with conjunctival lymphomas have co-existing systemic lymphoma and an ocular diagnosis should prompt for urgent appropriate referral for a systemic work-up.[11]

There was one case of Kaposi Sarcoma (KS) in a 34 year old HIV positive black female patient. The tumor was involving the caruncle and bulbar conjunctiva. KS was very rare before the era of HIV/AIDS.

The introduction of HAART with resultant improvent of immunity is known to promote involution of the tumor.

KS of the conjunctiva can mimic a subconjunctival haemorrhage, a high level of suspicion in patients presenting with non resolving spontaneous 'subconjunctival haemorrhage' is paramount.[10][11][12]

There were a few benign cases which could have been monitored or treated conservatively with no need for surgery such as, inflammatory lesions (follicular conjunctivitis and keratoconjunctivits).

A diagnosis of tuberculosis (TB) was reported in a patient with a granuloma of the bulbar conjunctiva. This is a vital piece of information if the patient is not diagnosed with systemic or extrapulmonary TB.

The spectrum of conjunctival lesions is broad with a high incidence of premalignant and malignant lesions in our population.

SCC constitutes the majority of malignant lesions affecting younger African patients in our setting. Male gender is mentioned as one of the risk factors for SCC but some studies report equal sexual distribution.[1

The turnaround time from specimen submission to histology report was on average at least one week, which is fairly reasonable considering the overburdened state facilities and this allows for timeous appropriate intervention. Rejections were as a result of minor human errors from the submitting clinicians team that can be easily rectified for example, proper completion of laboratory request forms. Correct capturing of patient information can be improved by using laboratory stickers instead of writing the specimen reference number by hand. This will also assist in instances where the patient number is entered incorrectly since the correct specimen reference number can still be utilized for easier tracing of histology results.

This study is from a large Ophthalmology referral centre and a lot of data was collected within the study period. It is highlighting the high incidence of severe OSSN, the importance of correct data capturing and submission of all surgical biopsies.

The study is retrospective, patient's clinical assessments were unavailable to match with histology findings. There was no specific Histopathologist designated to Ophthalmology and this resulted in different nomenclature used to describe similar pathologies.

Lesions of the conjunctiva vary tremendously. In most instances, excisional biopsy is not only diagnostic but also therapeutic. On few occasions, life threatening systemic disease can be firstly seen in the eye and diagnosed from conjunctival surgical biopsies eg. Lymphoma, TB and Sarcoid, reiterating the importance of submitting all surgical biopsies.

Despite SJEH serving a predominantly city-based population with access to health facilities, and patients presenting with suspicious conjunctival lesions given priority for theatre, we still have a handful of patients presenting with advanced malignant disease (SCC) requiring exenteration. Aggressive health awareness campaign is needed to prevent unnecessary morbidity and mortality.

MMed Write-up TURNITIN.docx

ORIGINALITY REPORT

7%	5%	4%	4%
SIMILARITY INDEX	INTERNET SOURCES	PUBLICATIONS	STUDENT PAPERS

PRIMARY SOURCES

1	Submitted to University of Witwatersrand Student Paper	1%
2	Submitted to International University - VNUHCM Student Paper	1%
3	mrimsjournal.com Internet Source	1%
4	Submitted to Northcentral Student Paper	1%
5	J L Vaughan, T M Wiggill, N Alli, K Hodkinson. "The prevalence of HIV seropositivity and associated cytopenias in full blood counts processed at an academic laboratory in Soweto, South Africa.", South African Medical Journal, 2017 Publication	<1%
6	Submitted to Manchester Metropolitan University Student Paper	<1%
7	naarm.org.in Internet Source	

		<1 %
8	core.ac.uk Internet Source	<1 %
9	www.journalijar.com Internet Source	<1 %
10	Napaporn Tananuvat, Nirush Lertprasertsuke. "Chapter 2 Ocular Surface Squamous Neoplasia", IntechOpen, 2012 Publication	<1 %
11	epdf.pub Internet Source	<1 %
12	wiredspace.wits.ac.za Internet Source	<1 %

Exclude quotes	On	Exclude matches	< 8 words
Exclude bibliography	On		